

EARN 2 CE CREDITS: WHAT TO DO WHEN YOU SEE UVEITIS, Page 64

# REVIEW<sup>®</sup> of OPTOMETRY

August 15, 2021 • [reviewofoptometry.com](http://reviewofoptometry.com)

Leadership in clinical care

45th ANNUAL  
CONTACT LENS REPORT

- New Products in Practice
- Lens/Tear Interaction
- Toric Lens Fitting Tips
- CL Drug Delivery

Begins p. 32

*Series Finale*

**COMANAGEMENT  
CONNECTIONS**

Part 6 of 6



## INFUSED FOR BALANCE

The only silicone hydrogel daily disposable with a next-generation material infused with ProBalance Technology™ to help maintain ocular surface homeostasis<sup>1</sup>


Find balance at [BauschINFUSE.com](http://BauschINFUSE.com)

REFERENCE: 1. Data on file. Bausch & Lomb Incorporated, Rochester, NY.

®/™ are trademarks of Bausch & Lomb Incorporated or its affiliates.  
©2020 Bausch & Lomb Incorporated or its affiliates. INF.0151.USA.20

**BAUSCH + LOMB**

See better. Live better.



EARN 2 CE CREDITS: WHAT TO DO WHEN YOU SEE UVEITIS, Page 64

# REVIEW<sup>®</sup> *of* OPTOMETRY

August 15, 2021 • [reviewofoptometry.com](http://reviewofoptometry.com)

Leadership in clinical care

45th ANNUAL  
CONTACT LENS REPORT


- New Products in Practice
- Lens/Tear Interaction
- Toric Lens Fitting Tips
- CL Drug Delivery

Begins p. 32

*Series Finale*

**COMANAGEMENT  
CONNECTIONS**

Part 6 of 6



## MASTERING OD-TO-OD REFERRALS

*Here's how to build lasting relationships with  
your peers to provide more complete care.*

**Page 58**





**VYZULTA**

(latanoprostene  
bunod ophthalmic  
solution), 0.024%

# THE HORSEPOWER YOU NEED TO LOWER IOP

**Powerful IOP reduction with excellent tolerability<sup>1,2</sup>**

VYZULTA delivered **up to 9.1 mmHg mean IOP reduction** from baseline in pivotal trials.<sup>1,2\*</sup>

**TAKE A TEST RIDE AT [VYZULTAHCP.COM](http://VYZULTAHCP.COM)**

\*Pivotal study designs: Two Phase 3, randomized, multicenter, parallel-group studies, APOLLO and LUNAR, evaluating noninferiority of once-daily VYZULTA vs twice-daily timolol maleate 0.5% in patients with open-angle glaucoma or ocular hypertension. Primary endpoint was IOP measured at 9 assessment time points in study eye. APOLLO (VYZULTA, n=284; timolol, n=133) and LUNAR (VYZULTA, n=278; timolol, n=136).<sup>2,3</sup>

## INDICATION

VYZULTA® (latanoprostene bunod ophthalmic solution), 0.024% is indicated for the reduction of intraocular pressure (IOP) in patients with open-angle glaucoma or ocular hypertension.

## IMPORTANT SAFETY INFORMATION

- Increased pigmentation of the iris and periorbital tissue (eyelid) can occur. Iris pigmentation is likely to be permanent
- Gradual changes to eyelashes, including increased length, increased thickness, and number of eyelashes, may occur. These changes are usually reversible upon treatment discontinuation
- Use with caution in patients with a history of intraocular inflammation (iritis/uveitis). VYZULTA should generally not be used in patients with active intraocular inflammation
- Macular edema, including cystoid macular edema, has been reported during treatment with prostaglandin analogs. Use with caution in aphakic patients, in pseudophakic patients with a torn posterior lens capsule, or in patients with known risk factors for macular edema
- There have been reports of bacterial keratitis associated with the use of multiple-dose containers of topical ophthalmic products that were inadvertently contaminated by patients
- Contact lenses should be removed prior to the administration of VYZULTA and may be reinserted 15 minutes after administration
- Most common ocular adverse reactions with incidence  $\geq 2\%$  are conjunctival hyperemia (6%), eye irritation (4%), eye pain (3%), and instillation site pain (2%)

For more information, please see Brief Summary of full Prescribing Information on adjacent page.

**References:** **1.** VYZULTA Prescribing Information. Bausch & Lomb Incorporated. **2.** Weinreb RN, Scassellati Sforzolini B, Vittitow J, Liebmann J. Latanoprostene bunod 0.024% versus timolol maleate 0.5% in subjects with open-angle glaucoma or ocular hypertension: the APOLLO study. *Ophthalmology*. 2016;123(5):965-973. **3.** Medeiros FA, Martin KR, Peace J, Scassellati Sforzolini B, Vittitow JL, Weinreb RN. Comparison of latanoprostene bunod 0.024% and timolol maleate 0.5% in open-angle glaucoma or ocular hypertension: the LUNAR study. *Am J Ophthalmol*. 2016;168:250-259.

VYZULTA and the V design are trademarks of Bausch & Lomb Incorporated or its affiliates. Any other product/brand names and/or logos are trademarks of the respective owners. ©2021 Bausch & Lomb Incorporated or its affiliates. All rights reserved. VYZ.0258.USA.20

**BAUSCH + LOMB**



## BRIEF SUMMARY OF PRESCRIBING INFORMATION

This Brief Summary does not include all the information needed to use VYZULTA safely and effectively. See full Prescribing Information for VYZULTA.

### VYZULTA® (latanoprostene bunod ophthalmic solution), 0.024%, for topical ophthalmic use.

Initial U.S. Approval: 2017

#### 1 INDICATIONS AND USAGE

VYZULTA® (latanoprostene bunod ophthalmic solution) 0.024% is indicated for the reduction of intraocular pressure (IOP) in patients with open-angle glaucoma or ocular hypertension.

#### 4 CONTRAINDICATIONS

None

#### 5 WARNINGS AND PRECAUTIONS

##### 5.1 Pigmentation

VYZULTA® (latanoprostene bunod ophthalmic solution), 0.024% may cause changes to pigmented tissues. The most frequently reported changes with prostaglandin analogs have been increased pigmentation of the iris and periorbital tissue (eyelid).

Pigmentation is expected to increase as long as latanoprostene bunod ophthalmic solution is administered. The pigmentation change is due to increased melanin content in the melanocytes rather than to an increase in the number of melanocytes. After discontinuation of VYZULTA, pigmentation of the iris is likely to be permanent, while pigmentation of the periorbital tissue and eyelash changes are likely to be reversible in most patients. Patients who receive prostaglandin analogs, including VYZULTA, should be informed of the possibility of increased pigmentation, including permanent changes. The long-term effects of increased pigmentation are not known.

Iris color change may not be noticeable for several months to years. Typically, the brown pigmentation around the pupil spreads concentrically towards the periphery of the iris and the entire iris or parts of the iris become more brownish. Neither nevi nor freckles of the iris appear to be affected by treatment. While treatment with VYZULTA® (latanoprostene bunod ophthalmic solution), 0.024% can be continued in patients who develop noticeably increased iris pigmentation, these patients should be examined regularly [see Patient Counseling Information (17) in full Prescribing Information].

##### 5.2 Eyelash Changes

VYZULTA may gradually change eyelashes and vellus hair in the treated eye. These changes include increased length, thickness, and the number of lashes or hairs. Eyelash changes are usually reversible upon discontinuation of treatment.

##### 5.3 Intraocular Inflammation

VYZULTA should be used with caution in patients with a history of intraocular inflammation (iritis/uveitis) and should generally not be used in patients with active intraocular inflammation as it may exacerbate this condition.

##### 5.4 Macular Edema

Macular edema, including cystoid macular edema, has been reported during treatment with prostaglandin analogs. VYZULTA should be used with caution in aphakic patients, in pseudophakic patients with a torn posterior lens capsule, or in patients with known risk factors for macular edema.

##### 5.5 Bacterial Keratitis

There have been reports of bacterial keratitis associated with the use of multiple-dose containers of topical ophthalmic products. These containers had been inadvertently contaminated by patients who, in most cases, had a concurrent corneal disease or a disruption of the ocular epithelial surface.

##### 5.6 Use with Contact Lens

Contact lenses should be removed prior to the administration of VYZULTA because this product contains benzalkonium chloride. Lenses may be reinserted 15 minutes after administration.

#### 6 ADVERSE REACTIONS

The following adverse reactions are described in the Warnings and Precautions section: pigmentation (5.1), eyelash changes (5.2), intraocular inflammation (5.3), macular edema (5.4), bacterial keratitis (5.5), use with contact lens (5.6).

##### 6.1 Clinical Trials Experience

Because clinical trials are conducted under widely varying conditions, adverse reaction rates observed in the clinical trials of a drug cannot be directly compared to rates in the clinical trials of another drug and may not reflect the rates observed in practice.

VYZULTA was evaluated in 811 patients in 2 controlled clinical trials of up to 12 months duration. The most common ocular adverse reactions observed in patients treated with latanoprostene bunod were: conjunctival hyperemia (6%), eye irritation (4%), eye pain (3%), and instillation site pain (2%). Approximately 0.6% of patients discontinued therapy due to ocular adverse reactions including ocular hyperemia, conjunctival irritation, eye irritation, eye pain, conjunctival edema, vision blurred, punctate keratitis and foreign body sensation.

#### 8 USE IN SPECIFIC POPULATIONS

##### 8.1 Pregnancy

###### Risk Summary

There are no available human data for the use of VYZULTA during pregnancy to inform any drug associated risks.

Latanoprostene bunod has caused miscarriages, abortion, and fetal harm in rabbits. Latanoprostene bunod was shown to be abortifacient and teratogenic when administered intravenously (IV) to pregnant rabbits at exposures  $\geq$  0.28 times the clinical dose. Doses  $\geq$  20  $\mu\text{g}/\text{kg}/\text{day}$  (23 times the clinical dose) produced 100% embryofetal lethality. Structural abnormalities observed in rabbit fetuses included anomalies of the great vessels and aortic arch vessels, domed head, sternebral and vertebral skeletal anomalies, limb hyperextension

and malrotation, abdominal distension and edema. Latanoprostene bunod was not teratogenic in the rat when administered IV at 150  $\text{mcg}/\text{kg}/\text{day}$  (87 times the clinical dose) [see Data].

The background risk of major birth defects and miscarriage for the indicated population is unknown. However, the background risk in the U.S. general population of major birth defects is 2 to 4%, and of miscarriage is 15 to 20%, of clinically recognized pregnancies.

###### Data

###### Animal Data

Embryofetal studies were conducted in pregnant rabbits administered latanoprostene bunod daily by intravenous injection on gestation days 7 through 19, to target the period of organogenesis. The doses administered ranged from 0.24 to 80  $\text{mcg}/\text{kg}/\text{day}$ . Abortion occurred at doses  $\geq$  0.24  $\text{mcg}/\text{kg}/\text{day}$  latanoprostene bunod (0.28 times the clinical dose, on a body surface area basis, assuming 100% absorption). Embryofetal lethality (resorption) was increased in latanoprostene bunod treatment groups, as evidenced by increases in early resorptions at doses  $\geq$  0.24  $\text{mcg}/\text{kg}/\text{day}$  and late resorptions at doses  $\geq$  6  $\text{mcg}/\text{kg}/\text{day}$  (approximately 7 times the clinical dose). No fetuses survived in any rabbit pregnancy at doses of 20  $\text{mcg}/\text{kg}/\text{day}$  (23 times the clinical dose) or greater. Latanoprostene bunod produced structural abnormalities at doses  $\geq$  0.24  $\text{mcg}/\text{kg}/\text{day}$  (0.28 times the clinical dose). Malformations included anomalies of sternum, coarctation of the aorta with pulmonary trunk dilation, retroesophageal subclavian artery with absent brachiocephalic artery, domed head, forepaw hyperextension and hindlimb malrotation, abdominal distention/edema, and missing/fused caudal vertebrae.

An embryofetal study was conducted in pregnant rats administered latanoprostene bunod daily by intravenous injection on gestation days 7 through 17, to target the period of organogenesis. The doses administered ranged from 150 to 1500  $\text{mcg}/\text{kg}/\text{day}$ . Maternal toxicity was produced at 1500  $\text{mcg}/\text{kg}/\text{day}$  (870 times the clinical dose, on a body surface area basis, assuming 100% absorption), as evidenced by reduced maternal weight gain. Embryofetal lethality (resorption and fetal death) and structural anomalies were produced at doses  $\geq$  300  $\text{mcg}/\text{kg}/\text{day}$  (174 times the clinical dose). Malformations included anomalies of the sternum, domed head, forepaw hyperextension and hindlimb malrotation, vertebral anomalies and delayed ossification of distal limb bones. A no observed adverse effect level (NOAEL) was established at 150  $\text{mcg}/\text{kg}/\text{day}$  (87 times the clinical dose) in this study.

##### 8.2 Lactation

###### Risk Summary

There are no data on the presence of VYZULTA in human milk, the effects on the breastfed infant, or the effects on milk production. The developmental and health benefits of breastfeeding should be considered, along with the mother's clinical need for VYZULTA, and any potential adverse effects on the breastfed infant from VYZULTA.

##### 8.4 Pediatric Use

Use in pediatric patients aged 16 years and younger is not recommended because of potential safety concerns related to increased pigmentation following long-term chronic use.

##### 8.5 Geriatric Use

No overall clinical differences in safety or effectiveness have been observed between elderly and other adult patients.

#### 13 NONCLINICAL TOXICOLOGY

##### 13.1 Carcinogenesis, Mutagenesis, Impairment of Fertility

Latanoprostene bunod was not mutagenic in bacteria and did not induce micronuclei formation in the *in vivo* rat bone marrow micronucleus assay. Chromosomal aberrations were observed *in vitro* with human lymphocytes in the absence of metabolic activation.

Latanoprostene bunod has not been tested for carcinogenic activity in long-term animal studies. Latanoprost acid is a main metabolite of latanoprostene bunod. Exposure of rats and mice to latanoprost acid, resulting from oral dosing with latanoprost in lifetime rodent bioassays, was not carcinogenic.

Fertility studies have not been conducted with latanoprostene bunod. The potential to impact fertility can be partially characterized by exposure to latanoprost acid, a common metabolite of both latanoprostene bunod and latanoprost. Latanoprost acid has not been found to have any effect on male or female fertility in animal studies.

##### 13.2 Animal Toxicology and/or Pharmacology

A 9-month toxicology study administered topical ocular doses of latanoprostene bunod to one eye of cynomolgus monkeys: control (vehicle only), one drop of 0.024% bid, one drop of 0.04% bid and two drops of 0.04% per dose, bid. The systemic exposures are equivalent to 4.2-fold, 7.9-fold, and 13.5-fold the clinical dose, respectively, on a body surface area basis (assuming 100% absorption). Microscopic evaluation of the lungs after 9 months observed pleural/subpleural chronic fibrosis/inflammation in the 0.04% dose male groups, with increasing incidence and severity compared to controls. Lung toxicity was not observed at the 0.024% dose.

U.S. Patent Numbers: 7,273,946; 7,629,345; 7,910,767; 8,058,467.

VYZULTA is a trademark of Bausch & Lomb Incorporated or its affiliates.

© 2020 Bausch & Lomb Incorporated or its affiliates.

###### Distributed by:

Bausch + Lomb, a division of

Bausch Health US, LLC

Bridgewater, NJ 08807 USA

Based on 9612403 (Folded), 9612303 (Flat) 5/2019

VYZ.0109.USA.20 Issued: 5/2020



## OD/MD Glaucoma Telehealth Effort Promising

*Public access to care and patient retention by doctors improved in this shared approach.*

While its long-term viability is still debatable, telemedicine is steadily gaining acceptance in eye care as it can reduce costs and wait time, detect disease earlier and identify patients who would otherwise slip through the cracks. A new investigation looking at a joint optometrist/ophthalmologist glaucoma telemedicine program in Canada found that a shared-care approach offers patients shorter travel and wait times, as well as the continuity of one provider.

The study looked at optometrists and ophthalmologists who worked together in a program called Care1, a full-scope, shared-care teleglaucoma model. The investigators suggest this prototype is less expensive than typical online medical visit platforms since required elements are already built into optometrists' practices.

In Care1, patients are screened for glaucoma by their OD, who collects all clinical and diagnostic testing data and then uploads it to a shared online platform where remote ophthalmologists review it.

"This full-scope, shared-care model benefits patients with reduced time and travel burden as well as increased

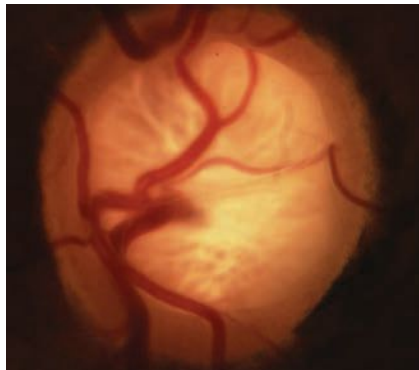


Photo: Michael Dorkowski, OD

**ODs on-site captured images and other diagnostic data to share with MDs remotely.**

continuity of care, optometrists with retention of more of their patients and ophthalmologists with reduced volume burden," the researchers wrote.

The study looked at the results of this arrangement from 2016 to 2017, where optometrists located in high-demand locations in two Canadian provinces saw patients in-person, acquired clinical history, performed physical exams, organized diagnostic testing and then uploaded data to an online platform where they collaborated with ophthalmologists to proceed with patient care.

During this period, 4,070 patients received a glaucoma assessment

at a Care1 teleophthalmology site. Roughly 97% had a best-corrected visual acuity between 20/20 and 20/40, and about 3% had an IOP greater than 26mm Hg.

In-person consultations with an ophthalmologist were recommended for 2% of patients. Additionally, glaucoma patients and suspects represented over half of participants, highlighting the disease burden in high-demand areas.

Glaucoma screening was important for many patients in this group, in which 7.7% had a cup-to-disc ratio of at least 0.8, and more than 10% of optometrists found OCT RNFL "red" ratings in the superior and inferior rims.

Shared-care is likely to be an especially important model during and after the COVID-19 pandemic, since social distancing requirements could limit the number of patients seen in-person, and patients may hesitate to visit specialists until symptoms arise, at which time the opportunity for early screening and intervention has been lost. ◀

Elson MJ, Giangiacomo An, Maa AY, et al. Early experience with full-scope shared-care teleglaucoma in Canada. *J Glaucoma*. June 24, 2021. [Epub ahead of print].

### IN BRIEF

**Vitamin D supplementation at a young age may prevent certain retinal diseases**, as a study found low vitamin D levels correlate with choroidal thinning and structural changes. Deficiency of vitamin D plays a **significant role in retinal maturation** during the early period of life and the development of some retinal diseases.

The study evaluated the following parameters in 150 children: RNFL, central macula, retinal layer, choroidal thickness, central retinal artery equivalent (CRAE) and central retinal vein equivalent (CRVE). Children were divided into a vitamin-D deficiency group (Group 1, n=70) and a group without deficiency (Group 2, n=80).

In both groups, mean peripapillary RNFL (except for the nasal

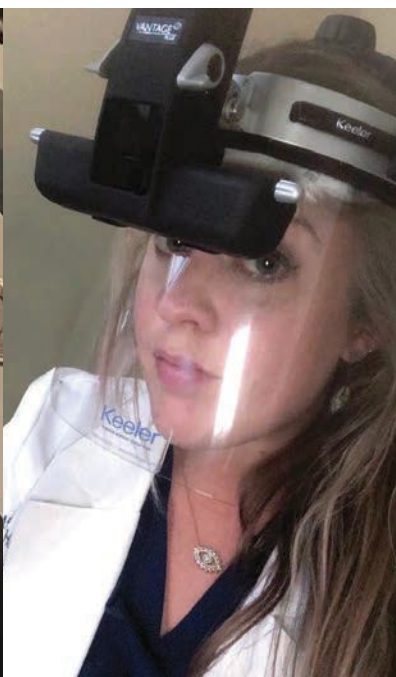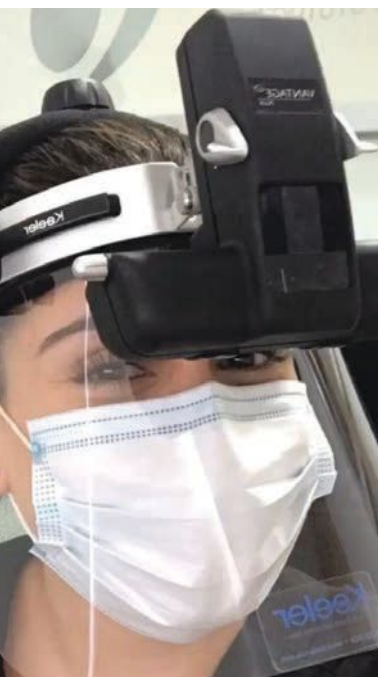superior sector), central macula and retinal layer thicknesses were similar. In Group 1, mean choroidal thickness was lower in the subfoveal and nasal 3,000µm-diameter areas. CRAE was lower and CRVE was higher in Group 1 than 2.

The researchers concluded that specific structural changes—**notably, choroidal thinning, a decrease in CRAE and an increase in CRVE—occurred in pediatric subjects with**

**vitamin D deficiencies.** "Alterations in these parameters became more prominent in pediatric subjects with lower vitamin D levels," they wrote in their paper. "Vitamin D supplementation in the pediatric age may be a new approach in the prevention of some retinal diseases."

Aydemir E, Ilhan C, Aydemir GA, et al. Evaluation of retinal structure in pediatric subjects with vitamin D deficiency. *Am J Ophthalmol*. July 17, 2021. [Epub ahead of print].

# Helping Heroes See Clear And Stay Safe



The Vantage BIO is great for ROP screening! It's lightweight, has settings for different pupil sizes, a cool, white LED light and the longest battery ever!!"

**Dr. Paulina Ramirez Neria**



I'm a big fan of the All Pupil BIO. I had issues with other models so when I started [my practice], I knew the All Pupil would be my go-to BIO...I greatly appreciate the new custom fit Keeler BIO shields as an added safety layer."

**Dr. Annie Bacon**



I chose my [Vantage Plus] for the optics and value...with other brands, I had difficulty focusing up close during my dilated fundus exams. [The oculars] made my eyes feel more relaxed, and I felt like my view was better."

**Dr. Michelle Hammond**



[I've] been seeing emergent and urgent cases every day during the COVID19 pandemic. I really like [the Vantage BIO] because [it's a] very good quality and provides a super clear view."

**Dr. Reza Moradi**


Choose one of the programs below when you purchase a BIO\*  
**(Expires September 30, 2021)**

\*this program is valid for our wireless indirects: All Pupil II and Vantage Plus

1  
RECEIVE A   
**\$850**  
credit towards any PPE

2  
24-MONTH  
**0%**  
lease as low as \$128/month\*

\*All Pupil II: \$127.92/month; Vantage Plus: \$155/month (shipping and taxes not included).

3  
RECEIVE   
**10 FREE**  
bottles of phenylephrine  
2.5%, 15mL

**\*Leasing may also be combined with the PPE credit OR the phenylephrine option.**

Contact us at 800-523-5620 or [customerservice@keelerusa.com](mailto:customerservice@keelerusa.com) to learn more or place your order. This promo cannot be combined with any other Keeler offers.

**Keeler**  
— A world without vision loss —

www.keelerusa.com • 3222 Phoenixville Pike - Bldg. #50 • Malvern, PA 19355  
Tel No: 1-610-353-4350 • Toll Free: 1-800-523-5620 • Fax: 1-610-353-7814

  
A Halma company



# Warby Parker's New App Expands to CL Rxs

Long considered a disruptive threat to traditional modes of eye care, first with online eyeglass sales and more recently in online vision testing, Warby Parker recently expanded its virtual eye exam reach with the launch of an app called Virtual Vision Test that allows users to renew their glasses or contact lens prescriptions remotely through their iPhone. The updated app pivots the company into the telehealth contact lens realm, as its previous vision test—Prescription Check—limited users to spectacle lens Rxs only.

Besides the convenience of a remote vision test that the company says will take only 10 minutes, Warby Parker is also appealing to customers by charging a nominal fee for the service: just \$15, and that's only if the user's prescription is renewed. If the patient is still seeing well with their current prescription—deemed by a Warby Parker doctor—they will receive a renewal Rx within 48 hours.

The company says the test is for individuals between the ages of 18 and 65 who have no ocular health issues, a single-vision distance prescription and can see well in their current spectacle lenses or contacts.

Here's how the new app works: From their phone, users answer a series of questions, including the last time they visited an eye doctor, presence or absence of symptoms (*e.g.*, ocular redness, headache, eye pain, new floaters and light sensitivity) and any relevant history of dry eye, keratoconus, glaucoma, high IOP, macular degeneration, cataracts or diabetes. Based on the responses, users will either be given the green light for the virtual eye exam or will receive a recommendation to schedule an in-person appointment.

## Optometry's Take

Optometrist Brian Chou of San Diego test drove the Virtual Vision



Photo: Getty Images

**Warby Parker muscles in on the contact lens business, posing a potential threat to ODs.**

Test app, compared it to his previous review of Prescription Check, and found the newer version is more user-friendly.

Virtual Vision Test makes use of the iPhone or iPad to automatically detect and guide the user to stand 10 feet away, while Prescription Check was relatively cumbersome and required one digital device to serve as a screen and another as a remote control, Dr. Chou explains.

Prescription Check also required the user to hold a credit card against a screen for letter size calibration, he adds. Those additional steps are gone with Virtual Vision Test, allowing the user to verbally read out loud the letters seen on the eye chart.

Additionally, Vision Test is less ambitious because it only seeks to renew an existing eyeglass or disposable contact lens prescription, abandoning its prior efforts to measure refractive error with a fan dial and duochrome test, Dr. Chou explains.

“Like other online vendors, Warby Parker is driving the market for prescription renewal for glasses and contact lenses,” Dr. Chou says. “COVID-19 has served as a tail wind. Many optometrists themselves have gone from denouncing telemedicine technologies to embracing it. This shift has greased the rails for the online companies to introduce online sight testing services to a more receptive industry.”

The online companies have identified prescription renewal as the low-hanging fruit vs. the more challenging *de novo* refraction, he adds.

“We can all expect continued development in this space, making it easier and easier for consumers to renew their eyeglass and disposable contact lens prescriptions,” Dr. Chou says. “As a result, it is logical to believe that more consumers will forego and delay in-person examination.”

The downstream effect is that in-person exams will increasingly lean toward the evaluation of more severe and involved problems, and the routine and high-volume procedures, which lend themselves susceptible to automation and prescription renewal, will continue to gain traction, he suggests.

“Despite this impending shake-up, I believe optometrists that position themselves to use social intelligence, complex critical thinking and creative problem solving—all of which are the highest and best use of a doctor's time—should do fine,” Dr. Chou says.

## Grudging Acceptance of ODs' Role

Dr. Chou says he finds it noteworthy that Warby Parker's corporate stance has seemingly changed from being hellbent on disintermediating optometrists altogether from prescription fulfillment to the current recognition that ODs are important for patient care.

Case in point: the Virtual Vision Test has multiple touchpoints where the app makes clear that it doesn't replace comprehensive exams and recommends visiting an eye doctor for traditional exams, albeit in a self-dealing manner since it directs users to their own corporate sublease ODs, Dr. Chou explains.

*(Continued on page 8)*

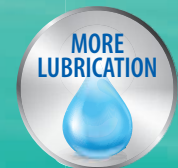# TIME IS RUNNING OUT!

UPGRADE CURRENT AIR OPTIX® WEARERS  
WITH NO REFIT REQUIRED!<sup>1,2</sup>

## THE TRIPLE UPGRADE



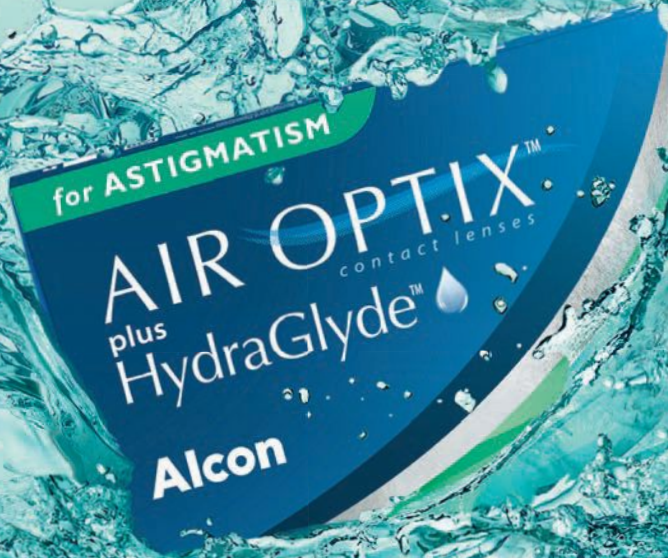Longer-lasting lens  
surface moisture<sup>3,5\*</sup>



Increased surface wetting  
and lubricating effects<sup>3,5\*\*</sup>



Better scribe mark visibility  
and reduced wear markings



Bring more lens surface moisture<sup>3,5\*</sup> and outstanding  
comfort<sup>8,9†</sup> to their AIR OPTIX® performance now!



\*vs. AIR OPTIX® AQUA contact lenses.

\*\*AIR OPTIX® plus HydraGlyde® sphere lenses compared to AIR OPTIX® AQUA and O2 OPTIX® sphere lenses.

†Based on clinical studies with AIR OPTIX® AQUA, AIR OPTIX® AQUA Multifocal and AIR OPTIX® for Astigmatism contact lenses.

**Important information for AIR OPTIX® plus HydraGlyde® (lotrafilcon B) contact lenses:** For daily wear or extended wear up to 6 nights for near/far-sightedness. Risk of serious eye problems (i.e., corneal ulcer) is greater for extended wear. In rare cases, loss of vision may result. Side effects like discomfort, mild burning or stinging may occur.

**Important information for AIR OPTIX® plus HydraGlyde® Multifocal (lotrafilcon B) contact lenses:** For daily wear or extended wear up to 6 nights for near/far-sightedness and/or presbyopia. Risk of serious eye problems (i.e., corneal ulcer) is greater for extended wear. In rare cases, loss of vision may result. Side effects like discomfort, mild burning or stinging may occur.

**Important information for AIR OPTIX® plus HydraGlyde® for Astigmatism (lotrafilcon B) contact lenses:** For daily wear or extended wear up to 6 nights for near/far-sightedness and astigmatism. Risk of serious eye problems (i.e., corneal ulcer) is greater for extended wear. In rare cases, loss of vision may result. Side effects like discomfort, mild burning or stinging may occur.

**References:** 1. Alcon data on file, 2017. 2. Alcon data on file, 2018. 3. Marx S, Sickenberger W. Wettability of different silicone hydrogel lens materials and blister solutions measured using non-invasive keratographic drying up time (NIK-DUT). *Optom Vis Sci.* 2016;93:E-abstract 165113. 4. Tucker R, Lemp J, Guillon M. In vitro and on eye wettability of lotrafilcon B lenses packaged with a substantive wetting agent. *Invest Ophthalmol Vis Sci.* 2017;58:ARVO E-Abstract 3070. 5. Lemp J, Muyo L, Driver-Scott A, Alvord L. A comparison of two methods for assessing wetting substantivity. Poster presented at: 2016 Global Specialty Lens Symposium (GSLSS); January 21-24, 2016; Las Vegas, NV. 6. Alcon data on file, 2017. 7. Lemp J, Zhao X, Perry S. Retention of packing solution comfort agents. Poster presented at: 2017 American Academy of Optometry Annual Meeting; October 11-14, 2017; Chicago, IL. 8. Eiden SB, Davis R, Bergenske P. Prospective study of lotrafilcon B lenses comparing 2 versus 4 weeks of wear for objective and subjective measures of health, comfort, and vision. *Eye Contact Lens.* 2013;39(4):290-294. 9. Lemp J, Kern J. A comparison of real time and recall comfort assessments. *Optom Vis Sci.* 2016;93:E-abstract 165256.

See product instructions for complete wear, care and safety information.

©2021 Alcon Inc. 4/21 US-AHA-2100003

Alcon



# Strabismus Surgery Lowers Child Injury Risk

A recent study revealed that strabismus surgery may decrease injury risk in pediatric patients. Unintentional injury is a leading risk of death in children, and impaired motor skills and depth perception brought on by the disease could make this population even more susceptible. Previous research has shown a 13% higher risk of injury for children with strabismus patients compared to those with healthy eyes; for esotropia specifically, injury risk is even higher at 17%. Children who undergo surgery to correct strabismus could face a 15% decrease in risk of physical injury, as shown in this study based on four years of follow-up.

Researchers reviewed data from 344,794 strabismus cases. Esotropia was the most common diagnosis, followed by exotropia, “strabismus not otherwise specified” and hypertropia. Surgery had been performed in 26,459 (7.7%) of the subjects. Records and injury claims from those who under-

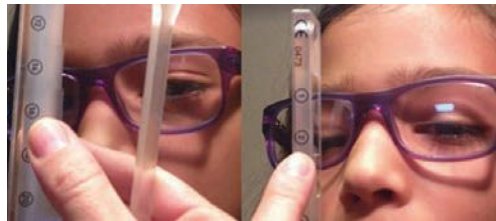

Photo: Jasleen Jhalji

**Research shows procedure may improve motor skills, postural stability, gait safety and balance control in pediatric patients.**

went surgery were compared to those who did not.

Of the patients who didn’t undergo surgery, 29.8% had a diagnosed injury after the first strabismus insurance claim, but for those who had surgery, just 21.9% were diagnosed with injuries after. Exotropic patients experienced the most decreased risk of injury postoperatively, likely due to a better chance of improving binocular vision.

“The adjusted hazard ratio for injuries was 0.85 for the risk of any injuries for strabismus surgery compared with no surgery,” the researchers explained.

“A Kaplan Meier plot revealed a sustained benefit from strabismus surgery in preventing injury over the duration of the follow-up.”

Researchers attribute this reduced injury risk after surgery to improvements in gross motor development, postural stability, gait safety and balance control.

Younger age of strabismus onset and subnormal stereoacuity are associated with poorer motor skills, as observed in a former study. Strabismus affects most areas of motor development, and these effects may be more detrimental to children of younger ages.

Luckily, surgery helps restrengthen motor skills and improve mobility. Based on data, children who receive strabismus surgery face a lower risk of injury and better overall health. ◀

Pineles SL, Repka MX, Yu F, et al. Strabismus surgery decreases the risk of injuries in pediatric patients in the OptumLabs data warehouse. *Am J of Ophthalmol.* July 17, 2021. [Epub ahead of print].

# Warby Parker Angles for Healthy CL Patients

(Continued from page 6)

“Still, this is a welcome change in direction,” Dr. Chou suggests. “Many ODs still harbor negative sentiments toward Warby Parker. Yet, I feel it is time to accept that they have an important role in their contribution to new ways of delivering eye care.”

## Still No Substitute for In-Person Exams

Optometrist Vince Zingaro of Malvern, PA, calls the new app a “slippery slope.”

The introduction on the company’s website states the app is not a substitute for a comprehensive eye exam, but it’s clear that no one is going to get one if they qualify for new glasses through the Virtual Vision Test, Dr. Zingaro says.

This creates the potential for, at

best, a poor-quality eye exam, and at worst, detrimental vision loss, he suggests.

For example, it’s not uncommon for patients in the 18-to-65 range to have no complaints with their vision, as these individuals often think they see well, yet they may have dry eye, retinal holes/tears, allergies, risk factors for glaucoma or other ocular conditions.

“It seems very possible that these findings may be hidden on the screening from this app,” Dr. Zingaro says.

At his practice, Dr. Zingaro says he’s helped patients without contact lens complaints and improved their wearing experience by switching them to another lens with the latest technology based on their lifestyle and ocular surface findings.

Another problem with the app: It’s hard enough to convince the general public about the importance of an annual eye exam, he adds.

“The app is a bit confusing and misleading by blurring the lines between a comprehensive exam and a refraction,” Dr. Zingaro says.

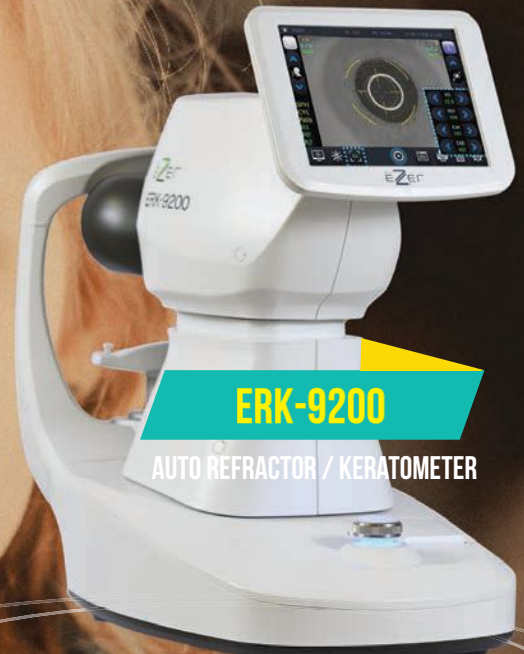## Final Thoughts

If a patient can pass a physical during a primary care exam, feels like they are in “good shape,” and can do 45 push-ups in a minute, Dr. Zingaro asks, should the doctor just skip the blood work, blood pressure readings and other vitals? “I don’t think most primary care providers would be willing to sign off on this, and I don’t think eye care providers should be comfortable doing this for patients’ eye health,” Dr. Zingaro says. ◀





A VISION THAT  
INSPIRES  
YOURS



ERK-9200

AUTO REFRACTOR / KERATOMETER

AVOID HUMAN ERRORS

FULLY AUTOMATED | SMART | AUTO TRACKING | 3D AUTO ALIGNMENT


A TEAM BY YOUR SIDE

SATISFACTION GUARANTEED

FROM ONE INDEPENDENT OWNER TO ANOTHER

WE CARE FOR OUR COMMUNITY

EASY FINANCE  
AVAILABLE



EZER OPHTHALMIC LINE

The Ezer Way of Life

CONTACT US FOR INFORMATION

WWW.USOPHTHALMIC.COM | PH: 1.888.881.1122  
INFO@USOPHTHALMIC.COM

Follow Our Social Media Channels @USOPHTHALMIC



9990 NW 14th Street, Unit #105, Doral, FL 33172 | USA



SCAN TO SEE MORE!

Read all the features and benefits  
this item has to offer by connecting  
to our page.

While you're there, don't forget to  
Request A Virtual Demo Online!

# Medicare Vision Expansion Bill Back in Action

*The proposed legislation would cover the costs for annual visits and materials.*

Over a third of Medicare beneficiaries have vision problems, yet more than half (57%) fail to receive a yearly eye exam.<sup>1</sup> With this in mind, the United States House of Representatives recently reintroduced a bill that would expand vision coverage to those enrolled in Medicare Part B.

The Medicare Vision Act of 2021 would expand Medicare Part B coverage to include routine vision care services and materials for the program's 60 million seniors and younger people with disabilities.<sup>1</sup> This expansion would not only realize the preventive health benefits afforded by routine eye care, including the early detection of systemic disease, but also help seniors retain their sight and independence through affordable vision coverage, according to the American Optometric Association (AOA).<sup>1</sup>

Medicare currently does not provide coverage for annual, comprehensive eye exams—only covering a complete exam if a medical condition is found—and typically requires beneficiaries to pay 100% of costs for eyeglasses or contact lenses, creating conditions wherein many seniors either delay or completely forgo the annual eye exams they need.<sup>1</sup>

The bill would expand Medicare Part B coverage to include annual refraction and contact lens fitting services; ensure direct administration of the benefit by Medicare, which would circumvent vision plans from subcontracting to provide the benefit; and coverage up to \$100 for one pair of eyeglasses or a one-year supply of contact lenses. The bill would also provide a pathway for low vision aids.<sup>1</sup>

“More than ever, Medicare beneficiaries need expanded access to eye health and vision care, including coverage for annual, comprehensive eye exams,” said AOA president, Robert C. Layman, OD, in a statement.

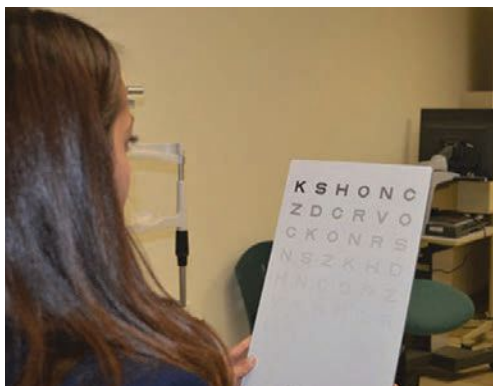

Photo: Alexis Malkin, OD

**As many as 60 million more people would have access to vision care if the legislation passes.**

“The AOA proudly supports the Medicare Vision Act.” Passage would advance vision care as a priority and uphold doctors of optometry and the full breadth of care they deliver to patients, according to Dr. Layman. “We will continue to advocate for this legislation and efforts to maintain doctor-patient decision making at the center of health care.”

State affiliates are also touting the benefits of the pending bill.

“The California Optometric Association supports H.R. 4187, the Medicare Vision Act of 2021,” says Dr. Ida Chung, president of the California Optometric Association. With over 6.4 million residents covered by Medicare, the expansion of vision coverage will have “a tremendous impact” on the people of California, she says.

“Not only will seniors and those with disabilities be able to see more clearly and better maintain their independence, eye exams can diagnose life- and sight-threatening conditions that have no symptoms.”

Research has shown that adding an eyeglass benefit will encourage more diabetic patients to get an annual eye exam, Dr. Chung adds. According to a recent CDC study, just over half of Medicare patients with diabetes have had a recommended annual eye exam.<sup>2</sup>

ODs on the front lines also routinely see the need for expanded vision coverage for their elderly patients who are on limited budgets. Optometrist Mark T. Marciano of West Palm Beach, FL, says older, retired individuals who were previously covered by a vision insurance plan through their employer and now rely on Medicare often shy away from annual eye exams due to their fixed incomes, unless they have ocular diseases that can be charged as medical visits.

Recently, Dr. Marciano, who estimated between 30% and 40% of his patients are age 60 and older, saw a 68-year-old patient wearing a pair of five-year-old glasses that undercorrected him by 0.75D. Still, he decided not to get a new pair of glasses because of the cost.

“Even though you try to adjust pricing for Medicare patients, or you try to provide different products that fit into their budget, it’s still not an incentive for them to get glasses they need to do their day-to-day activities,” Dr. Marciano says.

As a result, this impacts their quality of life, he adds. “Patients don’t want to drive at night, feel uncomfortable in large groups because they can’t see people in dim lighting and choose not to participate in certain social activities, which ultimately impacts their mental health and well-being. So, it’s a cascading effect,” Dr. Marciano says.

A Senate companion bill is possibly on deck for later this summer. ◀

1. AOA advocacy helps shape new U.S. House bill to expand essential eye health and vision coverage for Medicare beneficiaries. [www.aoa.org/news/advocacy/federal-advocacy/medicare-vision-expansion?ss=0](http://www.aoa.org/news/advocacy/federal-advocacy/medicare-vision-expansion?ss=0). July 1, 2021.

2. Lundeen EA, Wittenborn J, Benoit SR, et al. Disparities in receipt of eye exams among Medicare Part B fee-for-service beneficiaries with diabetes—United States, 2017. *Morb Mortal Wkly Rep.* 2019;68(45):1020-3.



**NEW**  
PRODUCTS

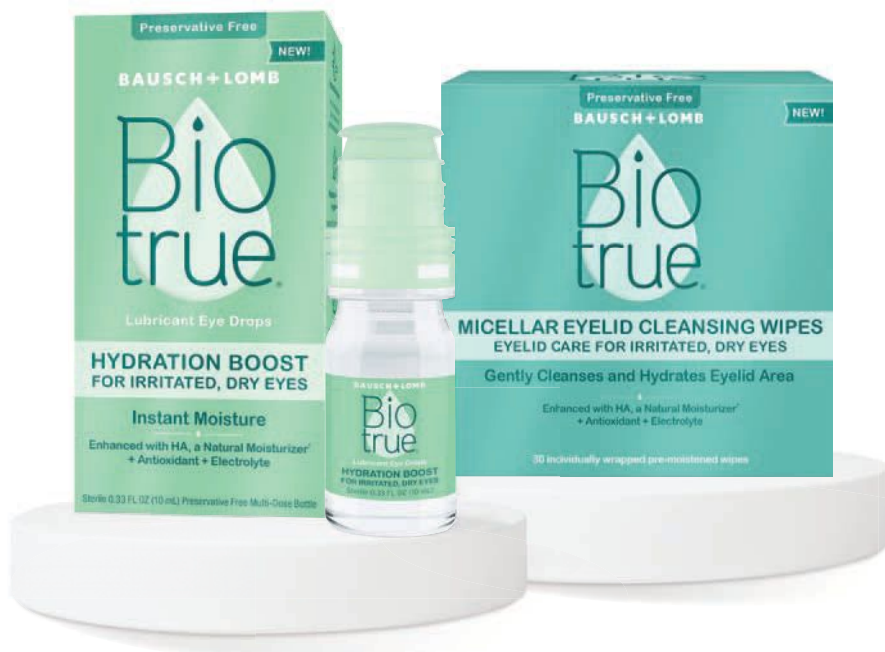# Dry eye symptom relief inspired by the biology of the eye

Helps maintain ocular surface homeostasis

Soothes eye dryness caused by screen and environmental stressors



Contact lens compatible\*



Gently cleanse and hydrate the eyelid area

Lid hygiene supports the health of the Meibomian glands<sup>1</sup>

**98%** patient satisfaction with Biotrue® Hydration Boost Eye Drops<sup>‡</sup>

Informed by  
**TFOS DEWS II**  
report<sup>2,†</sup>



Free from preservatives that can cause irritation



Potassium helps maintain ocular surface homeostasis



Antioxidant protects hyaluronan (HA) against free radicals



HA, a moisturizer found naturally in tears<sup>§</sup>



pH balanced

\*Based on standardized testing of soft contact lenses. Not meant to lubricate or rewet lenses. <sup>†</sup>TFOS DEWS II, Tear Film & Ocular Surface Society, Dry Eye Workshop II. <sup>‡</sup>In-Home Use Study: N=728 dry eye sufferers; April 2021. <sup>§</sup>Hyaluronan is sourced from a large-scale natural fermentation process.

References: 1. Bron AJ, et al. *Ocul Surf.* 2017;15(3):438-510. doi:10.1016/j.jtos.2017.05.011 2. Jones L, et al. *Ocul Surf.* 2017;15(3):575-628. doi:10.1016/j.jtos.2017.05.006

LEARN MORE AT  
[biotrue.com/professional](https://biotrue.com/professional)



# Grading System Could Dictate Pterygium Treatment

Pterygium treatment generally depends on the severity of the disease. In an effort to standardize this metric, a team of international researchers created a multi-pronged grading system based on slit-lamp imaging and believe it is an effective tool to assess cases.

The investigators named their grading system “SLIT2,” an acronym for the eight parameters it comprises, four corneal and four conjunctival:

*Corneal parameters:*

- Stocker’s line
- Length of head
- Injection/vascularity of head
- Thickness of head

*Conjunctival parameters:*

- Size at limbus
- Length of body
- Injection/vascularity of body
- Thickness of body.

The study enrolled 217 patients with pterygium who all underwent slit lamp exams and photography. Two graders evaluated a total of 868 independent assessments based on the 217 slit lamp images, which were divided into eight parameters. Each parameter was then assigned a score of one to four (normal to severe). Each grader evaluated the images twice. Intra-rater and inter-rater reliability was determined by statistical analysis.

Considering conjunctival assessment, the intra-rater reliability was excellent for body thickness and size at limbus, while it was substantial-to-excellent for body vascularity and moderate-to-excellent for body length. Additionally, inter-reliability was excellent for size at limbus, substantial

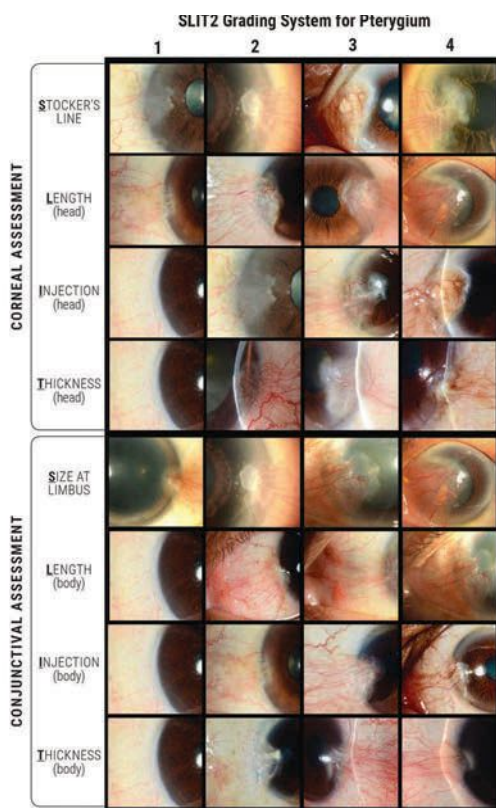


Photo: Jod S. Mehta, PhD, FRCOphth

**The SLIT2 grading system helps standardize the reporting of pterygium severity.**

for body thickness and body vascularity, but only moderate for body length.

For corneal assessment, the intra-rater reliability was excellent for all four parameters and head length, substantial-to-excellent for head vascularity, but only substantial for Stocker’s line and head thickness.

Currently, there are several grading systems for the assessment and reporting of preoperative pterygium severity, each with their own inherent strengths and limitations, the authors noted.

The problem with these approaches,

the researchers said, was that these methods generally evaluate only a single parameter of the pterygium, such as the body thickness/vascularity, caruncle morphology and corneal irregularity. The intra-rater or inter-rater reliability of these grading systems has not been reported, they added.

The team purposely selected graders with different levels of experience, including a medical intern and an experienced ophthalmologist, to demonstrate the consistency of this technique and how it would be applicable to other settings. Also, the study included a mixed ethnicity cohort to highlight the versatility of the grading system.

Recurrence rates are much lower in modern pterygium surgery, especially if done with conjunctival autografts, says researcher Jod S. Mehta, PhD, FRCOphth, of the Singapore National Eye Centre. The reason

his team came up with the new system was because previous classification systems—many of which haven't been validated—attempted to link recurrence with morphology, he explains.

“Since rates of recurrence are low, good post-op cosmesis is now really the most important outcome people want to achieve. Hence, the grading looks at corneal and conjunctival changes pre-op,” Dr. Mehta adds. ◀

Ting DSJ, Liu YC, Patil M, et al. Proposal and validation of a new grading system for pterygium (SLIT2). *Br J Ophthalmol*. 2021;105(7):921-4.

## IN BRIEF

In older adults, **vision impairment (VI) is associated with worse cognitive function**, but the relationship between mid-life vision and future cognitive function remains unknown. Researchers recently found that **moderate or worse VI led to lower scores on measures of cognitive function** over a 15-year period as

women transitioned from mid-life to older adulthood.

A total of 394 women, ages 42-52, with up to 20 years of follow-up were evaluated. Presenting visual acuity (VA) in the better-seeing eye was assessed at baseline and categorized as no or mild VI (VA≥20/60) or moderate or worse VI (VA<20/60). Cognitive function was measured eight times over 15 years using the

East Boston Memory Test immediate (EBMTi) and delayed (EBMTd) recall and the Digit Span Backwards (DSB) tests.

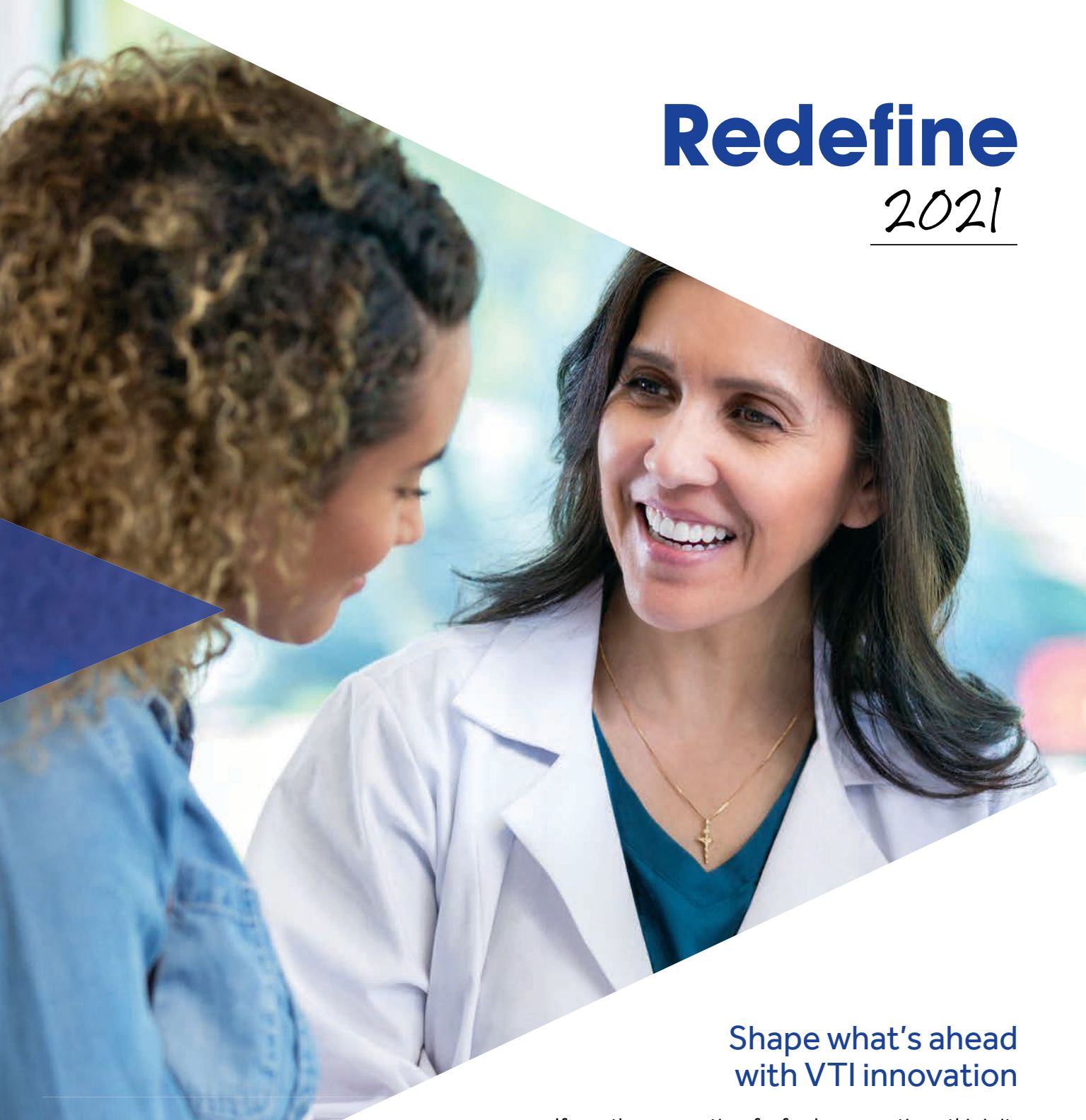Moderate or worse VI was associated with lower EBMTi, EBMTd and DSB scores. There were significant associations between VI and levels of cognitive function scores, but rates of cognitive decline as individuals aged did not vary by VI status.

“Identifying mid-life risk factors for future cognitive decline is an important research priority,” researchers concluded. “In mid-life, effective interventions to improve vision may improve future cognitive function.”

Kolli A, Hood MM, Karvonen-Gutierrez C, et al. Mid-life vision impairment and cognitive function in later life: the Study of Women's Health Across the Nation, Michigan cohort. *J Gerontol A Biol Sci Med Sci*. June 21, 2021. [Epub ahead of print].

# Redefine

2021



## Shape what's ahead with VTI innovation

If ever there was a time for fresh perspectives, this is it. This is your moment for new partnerships and product choices that empower, like contact lenses with our Neurofocus Optics® extended depth of focus design. With VTI, see a wider range of clear vision and stronger retention rates, to redefine success—this year and the next.

**Together We Can See This Through. [vtivision.com](http://vtivision.com)**







## NOW FROM GLAUKOS

Using Photrexa® Viscous (riboflavin 5'-phosphate in 20% dextran ophthalmic solution), Photrexa® (riboflavin 5'-phosphate ophthalmic solution), and the KXL® system, the iLink™ corneal cross-linking procedure from Glaukos is the only FDA-approved therapeutic treatment for patients with progressive keratoconus and corneal ectasia following refractive surgery.\*1

# GET THERE IN TIME

When you see patients with signs of keratoconus, don't hesitate. Refer them for iLink™—the only FDA-approved cross-linking procedure that slows or halts disease progression and is eligible for commercial insurance coverage with over 95% of commercially covered lives.

Connect with an  
iLink™ expert today.  
Visit [iLinkExpert.com](http://iLinkExpert.com)

#### INDICATIONS

Photrexa® Viscous (riboflavin 5'-phosphate in 20% dextran ophthalmic solution) and Photrexa® (riboflavin 5'-phosphate ophthalmic solution) are indicated for use with the KXL System in corneal collagen cross-linking for the treatment of progressive keratoconus and corneal ectasia following refractive surgery.

#### IMPORTANT SAFETY INFORMATION

Corneal collagen cross-linking should not be performed on pregnant women.

Ulcerative keratitis can occur. Patients should be monitored for resolution of epithelial defects.

The most common ocular adverse reaction was corneal opacity (haze). Other ocular side effects include punctate keratitis, corneal striae, dry eye, corneal epithelium defect, eye pain, light sensitivity, reduced visual acuity, and blurred vision.

These are not all of the side effects of the corneal collagen cross-linking treatment. For more information, go to [www.livingwithkeratoconus.com](http://www.livingwithkeratoconus.com) to obtain the FDA-approved product labeling.

You are encouraged to report all side effects to the FDA. Visit [www.fda.gov/medwatch](http://www.fda.gov/medwatch), or call 1-800-FDA-1088.

\*Photrexa® Viscous and Photrexa® are manufactured for Avedro. The KXL® system is manufactured by Avedro.

REFERENCE: 1. Photrexa [package insert] Waltham, MA: Glaukos, Inc. 2016.

MA-02164A  
PM-US-0427

Glaukos® is a registered trademark of Glaukos Corporation. iLink™ is a trademark of Glaukos Corporation. Photrexa®, Photrexa® Viscous, and the KXL® system are registered trademarks of Avedro, a Glaukos company. All rights reserved. ©2021

GLAUKOS®



# FEATURES

REVIEW OF OPTOMETRY • Vol. 158, No. 8 • AUGUST 15, 2021



CATCH UP ON THE LATEST NEWS

- ▶ Stories post online every weekday
- ▶ Weekly recap emailed every Sunday

## 45th ANNUAL CONTACT LENS REPORT



### 32 New Contact Lenses: Where Do They Fit In?

The latest advances tackle newer concerns like myopia control and sun protection, plus the perennial problems of comfort and convenience.

**By Jane Cole, Contributing Editor**

### 46 Build Up Your Toric Lens Talent

For these patients in particular, a one-size-fits-all approach just won't work. Here's how to handle several different kinds of patients in your chair.

**By Tiffany Andrzejewski, OD,  
and Marsha Malooley, OD**

### 40 How to Improve Contact Lens/Tear Interactions

Better understand this relationship between the two, and relay how to best preserve it to patients.

**By Trevor J. Fosso, OD**

### 54 The Coming Rise of Drug-Delivery Contact Lenses

This novel new system could mark a significant advancement for eye care.

**By Melissa Barnett, OD**

Photo credit: Getty Images

## 58 Mastering OD-to-OD Referrals

Here's how to build lasting relationships with your peers to provide more complete care.

**By Catlin Nalley, Contributing writer**

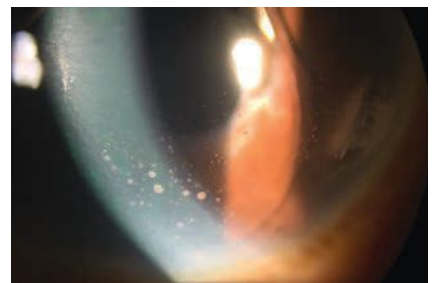


## 64 What to Do When You See Uveitis

Here's how to narrow down the differentials and determine when a case is—or isn't—infectious.

**By Megan Hunter, OD**

—EARN 2 CE CREDITS



**Recently added!**

Enjoy our content on  
Instagram at [@revoptom](https://www.instagram.com/revoptom)

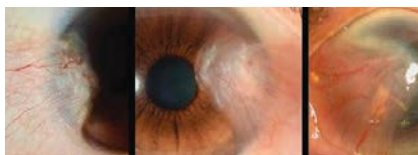# DEPARTMENTS

REVIEW OF OPTOMETRY • AUGUST 15, 2021

## 4

### NEWS REVIEW

Clinical, legislative and practice development updates for ODs.



## 20

### OUTLOOK

#### Appetite for Disruption

Changes are coming in contact lenses, presbyopia correction, drug delivery and more.

*Jack Persico, Editor-in-Chief*

## 22

### THROUGH MY EYES

#### Seven Secrets of Uveitis

These insights will allow you to effectively manage this chronic condition.

*Paul M. Karpecki, OD*

## 24

### CHAIRSIDE

#### The COVID Puppy Bandwagon

I too couldn't resist and hopped on it.

*Montgomery Vickers, OD*

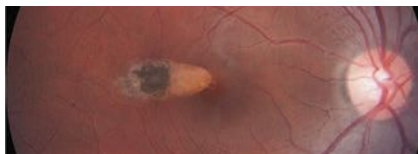## 26

### CLINICAL QUANDARIES

#### Damn the Torpedos

This maculopathy often poses no threat, but keep an eye on it.

*Paul C. Ajamian, OD*



## 28

### FOCUS ON REFRACTION

#### Plus Lenses in Practice

How to assess subjective and objective responses.

*Marc B. Taub, OD, MS, and Paul Harris, OD*

## 30

### CODING CONNECTION

#### Consult or Refer?

Knowing the difference can impact patient care.

*John Rumpakis, OD, MBA*

## 74

### CORNEA AND CONTACT LENS Q+A

#### Pressure Cooker

Avoid sclerals in progressive glaucoma to lower risk of IOP rise.

*Joseph P. Shovlin, OD*

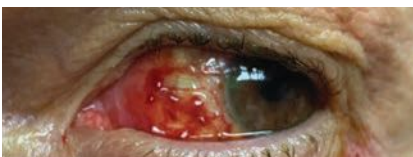## 76

### THERAPEUTIC REVIEW

#### A Sharp Stick to the Eye

Triage is important for this common injury.

*Joseph W. Sowka, OD*



## 78

### OCULAR SURFACE REVIEW

#### Fighting Fungal Keratitis

Though rare, this virulent infection can be mistaken for more benign varieties.

*Paul M. Karpecki, OD*

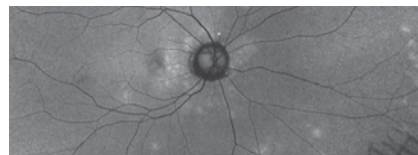
## 80

### RETINA QUIZ

#### Spotty Coverage

A combination of imaging modalities helps reveal subtle changes that led to the diagnosis.

*Mark Dunbar, OD*



## 82

### SURGICAL MINUTE

#### A Promising Offspring

The new Synergy IOL combines the designs of two previous lenses in the same family.

*Derek Cunningham, OD, and Walter Whitley, OD*

## 84

### GLAUCOMA GRAND ROUNDS

#### One Step at a Time

As we gather more information about glaucomatous damage, a management plan comes into focus.

*James L. Fanelli, OD*

## 86

### PRODUCT REVIEW

New items on the market to improve clinical care and strengthen your practice.

## 89

### DIAGNOSTIC QUIZ

#### A Bump in the Road

Even when a patient's concern is purely cosmetic in nature, be sure to rule out systemic involvement.

*Andrew S. Gurwood, OD*



VISIT US ON  
SOCIAL MEDIA

Facebook: [www.facebook.com/revoptom](https://www.facebook.com/revoptom)

Twitter: [twitter.com/revoptom](https://twitter.com/revoptom)

Instagram: [www.instagram.com/revoptom](https://www.instagram.com/revoptom)

# CHALLENGING CONDITIONS? COVERED.



**DRY EYE?  
DONE.**

**AMPEYE**  
SCLERAL



**HIGH CYL?  
HANDLED.**

intelliwave  
**PRO**



**MYOPIA?  
MANAGED.**

**MOONLENS**



**PRESBYOPIA?  
PERFECTED.**

Renovation  
MULTIFOCAL

## SPECIALTY CONTACT LENS SUCCESS. SIMPLIFIED.

[ARTOPTICAL.COM](http://ARTOPTICAL.COM)

**ART**Optical  
contact lens, inc.

800.253.9364

CATEGORY LEADING BRANDS | EXPERT CONSULTATION | NO-WORRY WARRANTY PROGRAM

PROUDLY PARTNERED WITH

OPTIMUM  
by Contamac

tangible™  
HYDRA-PEG

**K** **KATT**  
DESIGNGROUP



## CLINICAL EDITORS

**CHIEF CLINICAL EDITOR** ~ PAUL M. KARPECKI, OD

**ASSOCIATE CLINICAL EDITORS** ~ JOSEPH P. SHOVLIN, OD, CHRISTINE SINDT, OD

## CONTRIBUTING EDITORS

**PAUL C. AJAMIAN, OD, ATLANTA**

**DEREK N. CUNNINGHAM, OD, AUSTIN, TEXAS**

**MARK T. DUNBAR, OD, MIAMI**

**JAMES L. FANELLI, OD, WILMINGTON, NC**

**ANDREW S. GURWOOD, OD, PHILADELPHIA**

**PAUL HARRIS, OD, MEMPHIS, TENN.**

**PAUL M. KARPECKI, OD, LEXINGTON, KY.**

**BISANT LABIB, OD, ELKINS PARK, PA.**

**RICHARD B. MANGAN, OD, BOULDER, COLO.**

**JOHN RUMPAKIS, OD, MBA, PORTLAND, ORE.**

**JOSEPH P. SHOVLIN, OD, SCRANTON, PA.**

**JOSEPH W. SOWKA, OD, FORT LAUDERDALE, FLA.**

**MARC TAUB, OD, MEMPHIS, TENN.**

**MONTGOMERY VICKERS, OD, DALLAS, TEXAS**

**WALTER O. WHITLEY, OD, MBA, VIRGINIA BEACH, VA.**

## EDITORIAL ADVISORY BOARD

**JEFFREY R. ANSHEL, OD, ENCINITAS, CALIF.**

**JILL AUTRY, OD, RPH, HOUSTON**

**SHERRY J. BASS, OD, NEW YORK**

**EDWARD S. BENNETT, OD, ST. LOUIS**

**MARC R. BLOOMENSTEIN, OD, SCOTTSDALE, ARIZ.**

**AARON BRONNER, OD, KENNEWICK, WASH.**

**MILE BRUJIC, OD, BOWLING GREEN, OHIO**

**CHRIS J. CAKANAC, OD, MURRYSVILLE, PA**

**JERRY CAVALLERANO, OD, PhD, BOSTON**

**WALTER L. CHOATE, OD, MADISON, TENN.**

**BRIAN CHOU, OD, SAN DIEGO**

**MICHAEL CHAGLASIAN, OD, CHICAGO**

**A. PAUL CHOUS, MA, OD, TACOMA, WASH.**

**GLENN S. CORBIN, OD, WYOMISSING, PA**

**MICHAEL DELGIODICE, OD, CLIFTON, NJ**

**ANTHONY S. DIECIDUE, OD, STROUDSBURG, PA**

**S. BARRY EIDEN, OD, DEERFIELD, ILL.**

**ARTHUR B. EPSTEIN, OD, PHOENIX**

**STEVEN FERRUCCI, OD, SEPULVEDA, CALIF.**

**MURRAY FINGERET, OD, HEWLETT, NY**

**IAN BEN GADDIE, OD, LOUISVILLE, KY**

**GARY S. GERBER, OD, HAWTHORNE, NJ**

**PAUL HARRIS, OD, MEMPHIS, TENN.**

**MILTON HOM, OD, AZUSA, CALIF.**

**DAVID KADING, OD, SEATTLE**

**JEROME A. LEGERTON, OD, MBA, SAN DIEGO**

**THOMAS L. LEWIS, OD, PhD, PHILADELPHIA**

**BLAIR B. LONSBERRY, MS, OD, MED, PORTLAND, ORE.**

**DOMINICK MAINO, OD, MED, CHICAGO**

**KELLY A. MALLOY, OD, PHILADELPHIA**

**RICHARD B. MANGAN, OD, BOULDER, COLO.**

**DANICA MARRELLI, OD, HOUSTON, TEX.**

**RON MELTON, OD, CHARLOTTE, NC**

**PAMELA J. MILLER, OD, JD, HIGHLAND, CALIF.**

**BRUCE MUCHNICK, OD, COATESVILLE, PA**

**MARC MYERS, OD, COATESVILLE, PA**

**CARLO J. PELINO, OD, JENKINTOWN, PA**

**JOSEPH PIZZIMENTI, OD, FORT LAUDERDALE, FLA.**

**CHRISTOPHER J. QUINN, OD, ISELIN, NJ**

**MICHAEL C. RADOIU, OD, STAUNTON, VA**

**MOHAMMAD RAFIETARY, OD, MEMPHIS, TENN.**

**JOHN L. SCHACHET, OD, ENGLEWOOD, COLO.**

**JACK SCHAEFFER, OD, BIRMINGHAM, ALA.**

**LEO P. SEMES, OD, BIRMINGHAM, ALA.**

**DIANA L. SHECHTMAN, OD, FORT LAUDERDALE, FLA.**

**JEROME SHERMAN, OD, NEW YORK, NY**

**LEONID SKORIN, JR., OD, DO, ROCHESTER, MINN.**

**JOSEPH W. SOWKA, OD, FORT LAUDERDALE, FLA.**

**BRAD M. SUTTON, OD, INDIANAPOLIS**

**LORETTA B. SZCZOTKA, OD, PhD, CLEVELAND**

**MARC TAUB, OD, MEMPHIS, TENN.**

**TAMMY P. THAN, MS, OD, BIRMINGHAM, ALA.**

**RANDALL THOMAS, OD, CONCORD, NC**

**SARA WEIDMAYER, OD, ANN ARBOR, MICH.**

**KAREN YEUNG, OD, LOS ANGELES**



### Business Offices

19 Campus Boulevard, Suite 101  
Newtown Square, PA 19073  
Subscription inquiries (877) 529-1746 (USA only)  
outside USA, call (847) 763-9630

### PUBLISHER

**MICHAEL HOSTER**  
(610) 492-1028  
mhoster@jobson.com

### EXECUTIVE DIRECTOR

**JAMES HENNE**  
(610) 492-1017  
jhenne@jobson.com

### REGIONAL SALES MANAGER

**MICHELE BARRETT**  
(610) 492-1014  
mbarrett@jobson.com

### REGIONAL SALES MANAGER

**JONATHAN DARDINE**  
(610) 492-1030  
jdardine@jobson.com

### PRODUCTION MANAGER

**FARRAH APONTE**  
212-274-7057 faponte@Jobson.com

### PRODUCTION MANAGER

**KAREN LALLONE**  
(610) 492-1010 klallone@Jobson.com

### CLASSIFIED ADVERTISING

(888)-498-1460

### SUBSCRIPTIONS

\$63 PER YEAR, \$99 (US) IN CANADA,  
\$158 (US) IN ALL OTHER COUNTRIES  
revoptometry@cambeywest.com

### CIRCULATION

PO BOX 71, CONGERS, NY 10920-0071  
(877) 529-1746  
OUTSIDE USA: (845) 267-3065

### SENIOR CIRCULATION MANAGER

**HAMILTON MAHER**  
(212) 219-7870  
hmaher@jhihealth.com

### CEO, INFORMATION GROUP SERVICES

**MARC FERRARA**

### SENIOR VICE PRESIDENT, OPERATIONS

**JEFF LEVITZ**

### VICE PRESIDENT, HUMAN RESOURCES

**TAMMY GARCIA**

### VICE PRESIDENT, CREATIVE SERVICES & PRODUCTION

**MONICA TETTAMAZI**

### CORPORATE PRODUCTION DIRECTOR

**JOHN ANTHONY CAGGIANO**

### VICE PRESIDENT, CIRCULATION

**JARED SONNERS**

Jobson Health Information/WebMD  
395 Hudson Street, 3rd Floor, New York, NY 10014

# SIZE MATTERS



**NANO** DR<sup>○</sup>PPER

95% of ODs say Bigger is **NOT** Better\*

*Ask us how less is more for your patients  
...and your clinic's bottom line*

[www.nanodropper.com](http://www.nanodropper.com) | [support@nanodropper.com](mailto:support@nanodropper.com) | (507) 405-5676

**Use discount code REVIEWOPTO10 for 10% off your first order!**

\*According to a survey conducted by Nanodropper in April 2021 out of the 300+ ODs, more than 95% said their patients would benefit from smaller eyedrops.

Founded 1891  
Founding Editor, Frederick Boger

EDITOR-IN-CHIEF  
**JACK PERSICO**  
(610) 492-1006 • jpersico@jobson.com

SENIOR EDITOR  
**JULIE SHANNON**  
(610) 492-1005 • jshannon@jobson.com

SENIOR ASSOCIATE EDITOR  
**CATHERINE MANTHROP**  
(610) 492-1043 • cmanthorp@jobson.com

SENIOR ASSOCIATE EDITOR  
**MARK DE LEON**  
(610) 492-1021 • mdeleon@jobson.com

ASSOCIATE EDITOR  
**LEANNE SPIEGLE**  
(610) 492-1026 • lspiegle@jobson.com

SPECIAL PROJECTS MANAGER  
**JILL GALLAGHER**  
(610) 492-1037 • jgallagher@jobson.com

SENIOR ART DIRECTOR  
**JARED ARAUJO**  
(610) 492-1032 • jaraujo@jobson.com

DIRECTOR OF CE ADMINISTRATION  
**REGINA COMBS**  
(212) 274-7160 • rcombs@jobson.com

#### Clinical Editors

Chief Clinical Editor • Paul M. Karpecki, OD  
Associate Clinical Editors  
Joseph P. Shovlin, OD, Christine W. Sindt, OD  
Clinical & Education Conference Advisor  
Paul M. Karpecki, OD  
Case Reports Coordinator • Andrew S. Gurwood, OD  
Clinical Coding Editor • John Rumpakis, OD, MBA

#### Columnists

*Chairside* – Montgomery Vickers, OD  
*Clinical Quandaries* – Paul C. Ajamian, OD  
*Coding Connection* – John Rumpakis, OD  
*Cornea and Contact Lens Q+A* – Joseph P. Shovlin, OD  
*Diagnostic Quiz* – Andrew S. Gurwood, OD  
*The Essentials* – Bisant A. Labib, OD  
*Focus on Refraction* – Marc Taub, OD, Paul Harris, OD  
*Glaucoma Grand Rounds* – James L. Fanelli, OD  
*Ocular Surface Review* – Paul M. Karpecki, OD  
*Retina Quiz* – Mark T. Dunbar, OD  
*Surgical Minute* – Derek Cunningham, OD, Walter Whitley, OD  
*Therapeutic Review* – Joseph W. Sowka, OD  
*Through My Eyes* – Paul M. Karpecki, OD  
*Urgent Care* – Richard B. Mangan, OD

#### Editorial Offices

19 Campus Blvd., Suite 101 • Newtown Square, PA 19073



Jobson Medical Information/WebMD  
395 Hudson Street, 3rd Floor, New York, NY 10014

Subscription inquiries: (877) 529-1746  
Continuing Education inquiries: (800) 825-4696

Printed in USA



BY JACK PERSICO  
EDITOR-IN-CHIEF  
**OUTLOOK**

# Appetite for Disruption

*Changes are coming in contact lenses, presbyopia correction, drug delivery and more. Are you ready?*

Optometry is no stranger to change. The profession itself is practically an embodiment of it, as the twin engines of education and legislation continually redefine what it means to practice optometry. But aside from optometry's unique growing pains, the science of eye care seems to be at an inflection point, poised to trigger change on a number of fronts.

Probably the one that will make the biggest impact in optometry is presbyopia medications. Before the year is out, you'll likely have access to the first of many products in this category, all of which aim to improve near vision pharmacologically, usually by pupil constriction, though one does so by softening the crystalline lens to restore some flexibility and thus accommodative amplitude as well.

An early test for presbyopia drops will be the need to keep adverse effects tolerable enough to not kill enthusiasm for the idea before it even has a chance. Headache/brow ache, impaired distance vision, ocular surface disruption and questionable durability of effect are all obstacles to success—not to mention the small matter of paying for it. Everyone expects a pilocarpine drop from Allergan to be first out of the gate; others will follow not long after. Before you know it, we'll be off to the races with an entirely new product category to put through its paces.

What will these drops do to traditional presbyopia correction methods? The meds will be targeted at younger presbyopes, so they won't supplant premium IOLs, but they will steal some of the limelight those are currently receiving thanks to the strides made by newer implants. No matter what, all

corrective lens modalities will have an upstart competitor turning up the heat.

Contact lens practice—though currently being battered on the commercial side as the FTC prescription release rule gives online sellers newfound chutzpah to run roughshod over clinical expertise—seems destined to evolve beyond refractive correction and begin providing other eye health benefits, most notably drug delivery.

In this issue, Melissa Barnett, OD, provides an eloquent summary of the state of the science and its implications for practice. A contact lens to treat ocular allergy is already available internationally from Johnson & Johnson and should reach the US before long. Others to follow will target glaucoma, inflammation, pain and postoperative antibiotic prophylaxis. Expect to start thinking about a contact lens's drug content as well as its water content.

A new drug delivery method of another sort is also just around the corner, as Genentech hopes to make monthly or bimonthly intravitreal injections of anti-VEGF a thing of the past. Instead, the company's Port Delivery System—now making its way through FDA trials—uses an implantable reservoir that time-releases ranibizumab over six months, and can be refilled in an office procedure. If they pull it off, the entire infrastructure of anti-VEGF dosing and delivery could be re-engineered.

Lastly, if you'll allow a bit of wishful thinking, I'd like to believe the progress being made in epi-on crosslinking might open the floodgates to optometric adoption of the procedure. Regardless, we're on the precipice of a new wave of disruptive change, with plenty of upside for ODs and your patients. ■



# EXTRA PATIENT SUMMER SAVINGS.

Provide your patients  
extra summer savings  
with Unity BioSync.

UP  
TO **\$270**  
PATIENT SAVINGS<sup>1</sup>

Patients can soak up the sun and save big when ordering **Unity BioSync® with HydraMist®** and a pair of **Featured Frame Brand Marchon® or Altair® Sunglasses<sup>2</sup>**.

Sunwear is not only about fashion and fun – **it protects the health of our eyes, vision and skin.** By offering this valuable savings opportunity for your patients, you'll promote eye-health to your patients and put more fun in their summer.

**To learn more, scan the code below or visit [unitybiosync.com](http://unitybiosync.com).  
Offer ends August 31, 2021.**



<sup>1</sup> Provided in form of Mastercard® Prepaid card. VSP Members can receive maximum savings amount. Non-VSP members can receive up to \$250 rebate with annual supply purchase. <sup>2</sup> Visit [VSP.com/offers](http://VSP.com/offers) for list of qualified Featured Frame Brands. Brands and Promotion are subject to change.

©2021 Plexus Optix, Inc. Unity BioSync and HydraMist are registered trademarks of Plexus Optix, Inc. All other brands or marks are the property of their respective owners. Use of these marks, names, logos, and/or brands does not imply endorsement.





BY PAUL M. KARPECKI, OD  
CHIEF CLINICAL EDITOR

## THROUGH MY EYES

# Seven Secrets of Uveitis

*These insights will allow you to effectively manage this chronic condition.*

**A**nterior uveitis has been a major part of my practice for my whole career. These seven steps are a culmination of 25 years of insights I've gleaned from managing hundreds of iritis patients and working directly with top specialists in the field.

## 1. Rule Out Keratouveitis

If the cornea is involved (as in an infiltrative keratitis) with the presence of an iritis, be suspicious for a microbial cause. In cases of bacterial, viral—such as herpes simplex (HSV)—or fungal keratitis, steroids are contraindicated even though an iritis is present. The iritis is secondary to the infection and usually subsides once the antimicrobial agents have cleared it. Looking for corneal involvement or keratouveitis can help you spot an infectious cause, thus completely changing your treatment approach.

## 2. Investigate Previous Surgery

Along the same lines, if a patient presents with a significant anterior chamber reaction after an ocular surgery such as cataract surgery or corneal transplant, consider endophthalmitis. I've seen glaucoma patients present with a significant iritis and hypopyon, and after raising the upper eyelid, I discovered a trabeculectomy bleb. In these glaucoma procedures, shunts and tubes create a path to the anterior chamber (AC) and could lead to endophthalmitis. Once again, the treatment approach is completely different and requires a referral to a retina specialist.

## 3. Check IOP

While most cases of iritis result in the ciliary body producing less aqueous and lowering pressures, some causes of uveitis are predisposed to a trabeculitis and can cause a significant rise in IOP. These include herpes zoster ophthalmicus (HZO) and HSV or even the presence of fibrin in the AC. I've seen cases of HZO uveitis present with pressures above 50mm Hg, which can cause a vascular occlusion that potentially can lead to an AION or a CRAO.

“ Looking for corneal involvement or keratouveitis can help you spot an infection cause, thus completely changing your treatment approach. ”

## 4. Consider a Systemic Work-up

While I don't believe you need to order labs on every iritis patient, there are times when it's warranted, including severe presentations such as a hypopyon, significant fibrin in the AC (not caused by trauma), synechia, bilateral presentation or recurrence.

## 5. Treat Aggressively

Now that you've completed the above, you have no reason not to be aggressive in your treatment. I recommend treating every iritis, even grade 1, with topical steroids every one or two hours while awake. The exception would be use of

difluprednate, which is twice as strong—an initial QID dosing is sufficient.

Consider adding an overnight steroid, such as loteprednol, in more severe presentations. I've seen synechia break quicker, fibrin resolve, hypopyon improve dramatically and IOP from a trabeculitis lower with this simple addition.

It's also important to cycloplege these patients, as it can alleviate pain, restore the blood-aqueous barrier and prevent synechiae. Try to avoid atropine if there is potential for synechia, as it can result in synechia lock because of its slow acting profile. Other effective aggressive options include a Medrol Dosepak when necessary. I particularly like Acthar Gel (injections) in cases that are recalcitrant, rebound often or are steroid responders.

## 6. Treat and Taper Beyond Cells and Flare

After treatment with a proper but slow taper, continue to maintain a steroid QD for an additional five days after there are no more cells or flare. This seems like an odd rule, but I've seen rebound iritis where I stopped the steroid prior to this additional treatment. It can take three to five days after the last cell has disappeared to completely restore the blood-aqueous barrier.

## 7. Examine the Posterior Segment

Most cases of anterior uveitis are diagnosed without observing the posterior segment, but it can provide great insights. Sometimes, it's actually a vitritis that spills over into the AC. I've seen cotton wool spots, chorioretinitis and even a retinal detachment that presented with an anterior iritis.

Following these “rules” will allow you to manage this condition like a specialist, while also protecting you and the patient! ■

About  
Dr. Karpecki

Dr. Karpecki is medical director for Keplr Vision and the Dry Eye Institutes of Kentucky and Indiana. He is the Chief Clinical Editor for *Review of Optometry* and chair of the New Technologies & Treatments conferences. A fixture in optometric clinical education, he consults for a wide array of ophthalmic clients, including ones discussed in this article. Dr. Karpecki's full disclosure list can be found in the online version of this article at [www.reviewofoptometry.com](http://www.reviewofoptometry.com).



# CHANGE THE FUTURE

AMD is one of optometry's biggest opportunities to impact patient lives.

With the AdaptDx Pro<sup>®</sup> guided by Theia<sup>™</sup>, you can leverage the science of dark adaptation and the power of artificial intelligence to help detect and manage AMD in your practice!

**Discover how our AMD Excellence Program<sup>®</sup> gives you the hands-on training and best practices to change the future of AMD care for your patients and your practice.**



**AdaptDx**<sup>®</sup>  
**PRO**  
Guided by Theia<sup>™</sup>

**SPECIAL SUBSCRIPTION OFFER**

\$99/month for 1st six months

Learn more at [maculogix.com/6months](https://maculogix.com/6months)





BY MONTGOMERY VICKERS, OD  
**CHAIRSIDE**

# The COVID Puppy Bandwagon

*I too couldn't resist and hopped on it.*

**D**id you get a COVID pet? Many, many people did. They were suddenly working from home with nearly zero human contact other than the lovely government bureaucrats who visited the morning shows to tell us that if anyone leaves their home, they will be vaporized—or worse. This produced loneliness, and tequila was not warm and fuzzy enough, so everyone went pet crazy.

Now, for optometrists, this was not as big a thing. We hid out just long enough to decide we would rather not get our homes repossessed, and then we went back into the office dressed like medieval knights just in case somebody showed up. Most of us did not feel the need for a furry friend. After all, every day we basked in the warmth of someone who got their glasses in 2019 but had trouble wearing them and couldn't come in because Gayle King told them to stay home.

What do optometrists know about animals, anyway? Sure, I grew up with a constant flood of dogs and cats. That's a requirement in West Virginia. All I recall is that they laid around outside all day and that Dad

wisely taught us about the proper operation of a shovel out back. But I can't remember any classes on pet care in optometry school. Well, there was that hour we spent on how to handle an angry patient—swat them on the butt with a newspaper. Maybe that's the way to go when it comes to animals, too.

But even the toughest of optometrists (who, on the tough meter, are barely a two out of 100) fell into the puppy/kitten trap—myself included. You heard right.

Lily is a five-month-old toy poochon. Her behavior makes me think she was bred specifically from a long line of dogs trained to pee on their owner's bed.

She tricks us into allowing her into our bed around 3am every morning.

That means I get to

wake up wet and angry every day precisely at 6:30am. Lucky me.

Luckily, Lily does not complain. She just greets me at the door grinning ear to ear and wagging her tail off like I am a T-bone steak. This melts

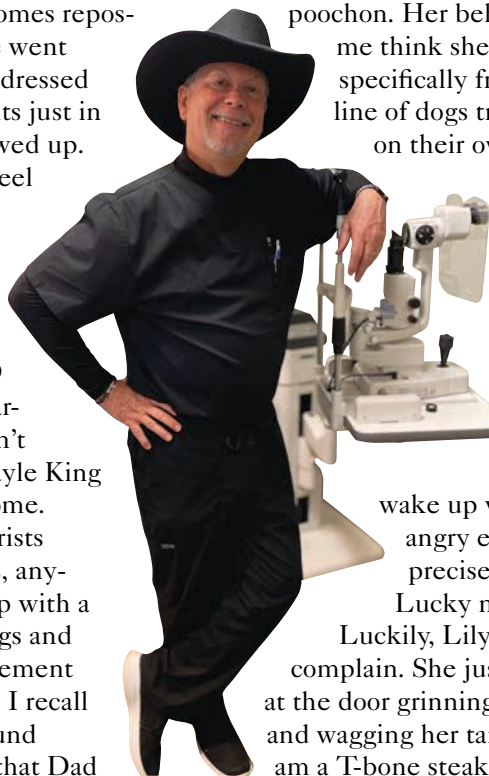
away the stresses of the day, and I am able to immediately forget that Marty's gas permeable multifocals still don't work. All things considered, this is probably good for me.

Marty, accept your fate, get a puppy and put on some reading glasses.

Lily also helps my wife survive working from home and having no friends. I'm schmoozing all day so I really don't want any friends, but she's not like that. For some reason, she believes that friends are enriching. I think reruns of *Seinfeld* are just as good.

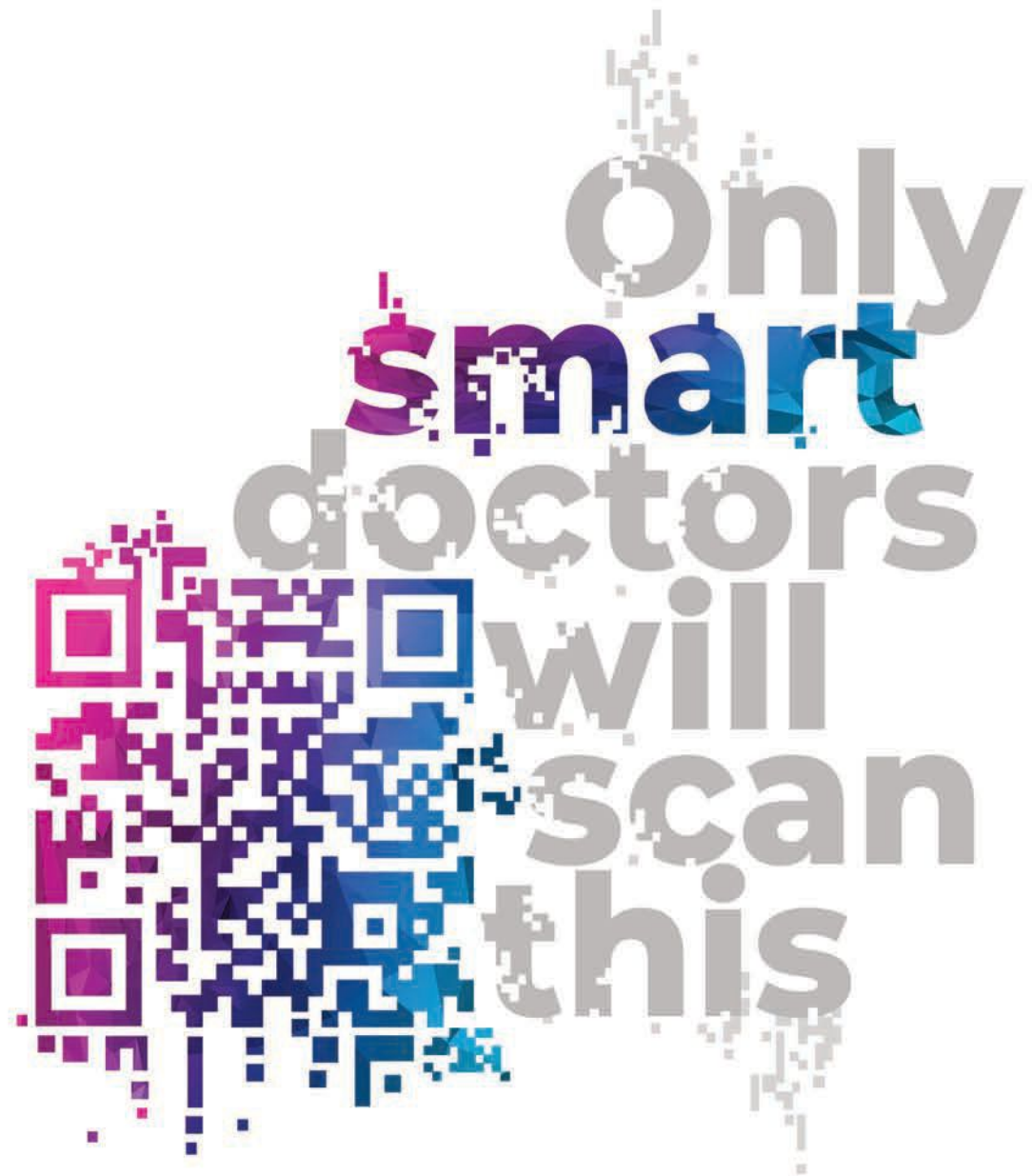If you are looking for a great dog for an optometry-oriented family, here's some (as always) sage advice:

1. Avoid bloodhounds. They always have eye problems because of their saggy eyelids. You already get to take care of that with your mom's sister, Edith.
2. What about a pit bull? Sure, if you live in a state that allows you to stitch up your neighbor's kids' faces.
3. A great dane? Forget the shovel and buy a backhoe.
4. Border collie? Can you stand to have yet another family member smarter than you?
5. Husky? Well, do you knit? There will be an endless supply of piles of hair for your sweater creations.
6. Greyhound? You can't even outrun your four-year-old. What are you thinking?
7. Wait for it... your best bet is a toy poochon! My wife would kill me, but EVERYTHING has a price. Private equity? Give me a call. I have your dog! (Also accepting Bitcoin). ■



About  
Dr. Vickers

Dr. Vickers received his optometry degree from the Pennsylvania College of Optometry in 1979 and was clinical director at Vision Associates in St. Albans, WV, for 36 years. He is now in private practice in Dallas, where he continues to practice full-scope optometry. He has no financial interests to disclose.



Click bait?...Or something **very important!**





EDITED BY PAUL C. AJAMIAN, OD

## CLINICAL QUANDARIES

# Damn the Torpedos

*This maculopathy often poses no threat, but keep an eye on it.*

**Q** A 23-year-old African-American female presented for a routine annual eye exam. Dilated retinal exam and imaging revealed a well-circumscribed macular lesion OD, with areas of hypo- and hyperpigmentation. What is in the differential diagnosis for this patient, and what needs to be done?

**A** “Pigmented macular lesions in young patients are always worrisome and deserve careful attention to arrive at the correct diagnosis,” says Alexander Bottini, MD, retina specialist at Omni Eye Services in Atlanta. “Structure your list around either an infection, a neovascular process, a neoplasm or a congenital lesion.”

In young patients with pigmented macular lesions, consider TORCH syndrome—congenital infection of **T**oxoplasmosis, **O**ther agents (*e.g.*, syphilis, parvovirus), **R**ubella, **C**ytomegalovirus or **H**erpes simplex virus.

Congenital toxoplasmosis, in particular, can leave behind large and devastating chorioretinal scars in the macula.

### List of Lesions

Any choroidal neovascular membrane (CNVM) in a young patient needs a

good explanation. High myopia could be the culprit, so it’s essential to know the patient’s refraction. Remote ocular trauma with an asymptomatic choroidal rupture can result in CNVM years later. A young patient with CNVM who grew up near the Mississippi or Ohio River valleys is always a suspect for presumed ocular histoplasmosis syndrome. White dot syndromes, particularly punctate inner choroiditis and multifocal choroiditis and panuveitis, should also be on the differential.

Choroidal lesions—nevi, melanomas and metastases—can occur in the macula. On exam, these lesions are deep to the retina. To distinguish melanomas from nevi, look for subretinal fluid, orange pigment and significant elevation of the lesion.

Congenital hypertrophy of the retinal pigment epithelium (CHRPE) lesions are often seen in the periphery, but the well-circumscribed, pigmented lesions of the outer retina can occur in the macula. Congenital simple hamartoma of the RPE lesions are more rare but can also appear in the retina as focal, densely pigmented lesions that often extend into the inner layers.

### Ocular Torpedo

This patient’s fundus appearance happened to be a classic presentation of torpedo maculopathy—an oval-shaped lesion in the temporal macula with a hypopigmented, tapered tip pointing toward the fovea and a sometimes hyperpigmented tail extending temporally.<sup>1</sup> RPE attenuation and photoreceptor layers are seen on OCT. Patients are almost uniformly asymptomatic.

“Regarding pathogenesis, we simply don’t have a definite answer,” Dr. Bottini says. “We know it to be a congenital lesion, so various insults occurring during retinal development—such as an intrauterine infection or vascular abnormality—have been suggested.” There is a strong suspicion that the lesion arises during the specific period in fetal development where we see the so-called “fetal temporal bulge”—a dense but transient clustering of RPE cells in the temporal macula.<sup>2</sup> Both the size and shape of the fetal temporal bulge correlates with the torpedo lesions.<sup>2,3</sup>

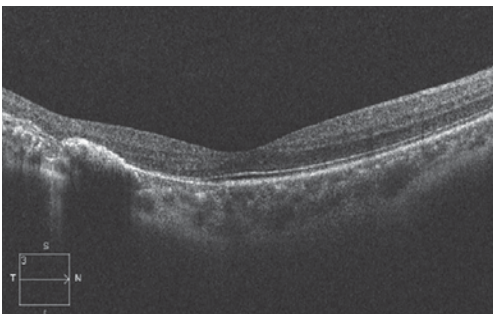
“While torpedo maculopathy lesions are often incidental findings that pose no threat to the eye, they can rarely develop a CNVM, so monitor them as needed. Dr. Bottini says. “Areas of dense hyperpigmentation within the lesion, such as those seen in this case, should raise one’s suspicion and prompt multimodal imaging to look for a CNVM.”

Even if a CNVM is not present, these patients should be educated in the use of an Amsler grid and followed about every six to 12 months. ■

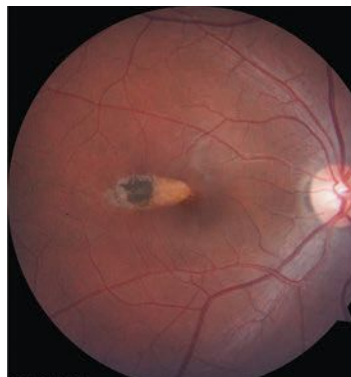
1. Roseman RL, Gass JD. Hypopigmented nevus of the retinal pigment epithelium in the macula. *Arch Ophthalmol.* 1992;110(10):1358-9.

2. Shields CL, Guzman JM, Shaprio MJ, et al. Torpedo maculopathy at the site of the fetal “bulge”. *Arch Ophthalmol.* 2010;128(4):499-501.

3. Shirley K, O’Neill M, Gamble R, et al. Torpedo maculopathy: disease spectrum and associated choroidal neovascularisation in a pediatric population. *Eye (Lond).* 2018;32:1315-20.



Outer retinal changes on the OCT (left) are apparent in the location of the torpedo lesion (right).



About Dr. Ajamian

Dr. Ajamian is the center director of Omni Eye Services of Atlanta. He currently serves as general chairman of the education committee for SECO International. He has no financial interests to disclose.

# Untangling the Causes and Effects of **DEMODEX BLEPHARITIS**

By Milton M. Hom, OD, FAAO; Paul M. Karpecki, OD, FAAO;  
and Ian Ben Gaddie, OD, FAAO

**F**irst, there was dry eye, then it was meibomian gland dysfunction (MGD); now, more and more we are talking about blepharitis in the clinical realm.

Blepharitis affects up to 47% of patients seen in the clinical setting, making it one of the most common ocular pathologies that optometrists encounter.<sup>1,2,3</sup> This chronic inflammatory condition affects individuals of all ages and causes ocular irritation and redness<sup>4</sup> that, in most patients, tends to ebb and flow in an ongoing cycle of exacerbation and remission.<sup>1</sup> Severity varies on a scale that ranges from mild to severe, with some cases resulting in permanent eyelid deformity and vision loss due to keratopathy.<sup>1</sup>

This chronic inflammatory condition affects individuals of all ages and causes ocular irritation and redness<sup>4</sup> that, in most patients, tends to ebb and flow in an ongoing cycle of exacerbation and remission.<sup>1</sup>

The classification of blepharitis generally is based on location and/or etiology. For example, blepharitis can cause anterior or posterior inflammation. In some cases, both anterior or posterior disease occurs simultaneously. This is termed marginal blepharitis. Blepharitis can be further subclassified as *Staphylococcal*, *seborrheic*, or *meibomian gland dysfunction (MGD)*, any of which can occur alongside *Demodex* infestation.



**Milton M. Hom, OD, FAAO**  
Canyon City Eyecare



**Paul M. Karpecki, OD, FAAO**  
Kentucky Eye Institute



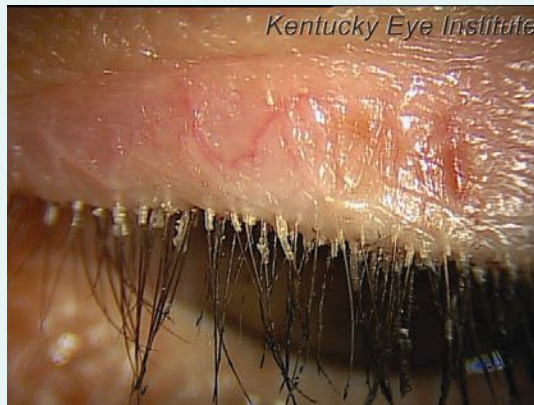**Ian Ben Gaddie, OD, FAAO**  
Gaddie Eye Centers

## DEMODEX BLEPHARITIS

*Demodex* is the most common ectoparasite in human beings, and there is a close connection between infestation and blepharitis.<sup>5</sup> In fact, *Demodex folliculorum* and *Demodex brevis* have been implicated in both anterior and posterior blepharitis.<sup>6</sup>

*D. folliculorum* cluster at the root of the eyelashes, infesting both the lashes and the follicles.<sup>7</sup> These mites consume epithelial cells, which leads to follicular distention and the formation of loose or misdirected lashes.<sup>7</sup> Meanwhile, the mite's claws cause microabrasions, inducing epithelial hyperplasia and reactive hyperkeratinization. Cylindrical dandruff is a tell-tale sign.<sup>7,8,9</sup> *D. brevis* infest the meibomian glands and mechanically block them,<sup>7</sup> leading to a cascade of MGD-related consequences.

*Demodex* mites also cause blepharitis because they are bacterial vectors for *Streptococci* and *Staphylococci*.<sup>7</sup> Finally, *Demodex* causes hypersensitivity reactions due to proteins inside of the mite as well as to their waste.<sup>7,9</sup>



**Demodex blepharitis**

## PRIMARY CLASSIFICATION

From an anatomical perspective, blepharitis is typically categorized as anterior or posterior,<sup>10</sup> but in reality, it is often marginal, meaning both anterior and posterior blepharitis coexist.<sup>1,2,11</sup>

**Anterior blepharitis.** Anterior blepharitis affects the skin of the eyelids, the base of the lashes and the lash follicles.<sup>4,1</sup> *Staphylococcus* infection and seborrheic dermatitis are commonly associated with anterior blepharitis.<sup>1</sup> Squamous debris or collarettes are also often present.<sup>1,2,11</sup>

**Posterior blepharitis.** Blepharitis can be classified as posterior when the meibomian glands are affected.<sup>4</sup> As such, meibomian gland dysfunction (MGD) can be conceptualized as a complication of posterior blepharitis wherein hyperkeratinization occurs, triggering inflammation and an alteration in glandular secretions that leads to tear film instability and dry eye.<sup>10,12</sup> Viewed in this way, MGD is a *result* of blepharitis; however, MGD can also *cause* blepharitis.<sup>1,2,11</sup> The important thing to remember is that MGD and blepharitis



are not interchangeable terms, since both conditions have alternative causes.<sup>1,13</sup>

**Marginal blepharitis.** As most clinicians have witnessed, anterior and posterior blepharitis commonly coexist because the etiologies of blepharitis cause insult both anteriorly and posteriorly.<sup>1</sup> For example, *Demodex* mites<sup>14</sup> and, less commonly, *Phthirus pubis* (crab lice)<sup>15</sup> are both parasitic causes of marginal blepharitis.<sup>1</sup>

Understanding the intersections between MGD and dry eye, and blepharitis and *Demodex*, are fundamental to successfully managing patients. When one condition is present, always look for the others.

---

## SUBCLASSIFICATION

*Staphylococcal*, seborrheic, and MGD are the three most common subcategories of blepharitis, but as with primary categories any of these can coexist.<sup>4,16</sup>

**Staphylococcal blepharitis.** Relative to other forms of blepharitis, *Staphylococcal* blepharitis is most common in younger female patients.<sup>4,16,17</sup> Clinically, it presents with lid margin scaling, crusting, and erythema alongside collarette formation.<sup>4</sup> Severe presentations include ulcerative blepharitis and corneal involvement.<sup>4</sup> Eyelid cultures have shown both coagu-

lase-negative *Staphylococcus* and *Staphylococcus aureus*,<sup>4,16</sup> but less than half of patients diagnosed with *Staph.* blepharitis have positive cultures.<sup>1,18</sup>

**Seborrheic blepharitis.** In patients with seborrheic blepharitis, there is significant crossover between anterior blepharitis and MGD.<sup>1</sup> These patients commonly present with greasy scaling anterior lids and seborrheic dermatitis of the brows and scalp.<sup>4</sup> In fact, 95% of seborrheic blepharitis patients have seborrheic dermatitis.<sup>1,16</sup>

**Meibomian gland dysfunction.** As discussed above, MGD can be both a cause or an effect of blepharitis. MGD also can be particularly insidious because of its close association with evaporative dry eye disease<sup>4,3</sup> and *Demodex brevis*, which mechanically blocks meibomian gland orifices, giving rise to lipid tear deficiency.<sup>7,8</sup> *D. brevis* also burrows deep into the glands, leaving behind a chitinous exoskeleton that can cause a granulomatous reaction.<sup>7</sup> *Demodex folliculorum* is likewise implicated in MGD, and can be clinically discerned by the presence of collarettes or cylindrical dandruff at the base of the lashes.<sup>4,8</sup>

Understanding the intersections between MGD and dry eye, and blepharitis and *Demodex*, are fundamental to successfully managing patients. When one condition is present, always look for the others. ♦

1. Duncan K, Jeng BH. Medical management of blepharitis. *Curr Opin Ophthalmol*. 2015;26(4):289-94.
2. Nelson JD, Shimazaki J, Benitez-del-Castillo JM, et al. The international workshop on meibomian gland dysfunction: report of the definition and classification subcommittee. *Invest Ophthalmol Vis Sci* 2011;52:1930-7.
3. Lemp MA, Nichols KK. Blepharitis in the United States 2009: a survey-based perspective on prevalence and treatment. *Ocul Surf* 2009; 7:S1-14.
4. Amescua G, Akpek EK, Farid M, et al. Blepharitis Preferred Practice Pattern®. *Ophthalmology*. 2019;126(1):P56-93.
5. Hom MM, Mastrotta KM, Schachter SE. Demodex. *Optom Vis Sci*. 2013;90(7):e198-205.
6. Fromstein SR, Harthan JS, Patel J, et al. Demodex blepharitis: clinical perspectives. *Clin Optom (Auckl)*. 2018;10:57-63.
7. Liu J, Sheha H, Tseng SC. Pathogenic role of Demodex mites in blepharitis. *Curr Opin Allergy Clin Immunol*. 2010;10(5):505-10.
8. Gao Y-Y, Di Pascuale MA, Li W, et al. High prevalence of ocular demodex in lashes with cylindrical dandruffs. *Invest Ophthalmol Vis Sci*. 2005;46:3089-94.
9. Bevins CL, Liu FT. Rosacea: skin innate immunity gone awry? *Nat Med*. 2007;13:904-6.
10. Soh Qin R, Tong Hak Tien L. Healthcare delivery in meibomian gland dysfunction and blepharitis. *Ocul Surf*. 2019;17(2):176-8.
11. Pflugfelder SC, Karpecki PM, Perez VL. Treatment of blepharitis: recent clinical trials. *Ocular Surf* 2014; 12:273-84.
12. Schaumberg DA, Nichols JJ, Papas EB, et al. The international workshop on meibomian gland dysfunction: report of the subcommittee on the epidemiology of, and associated risk factors for, MGD. *Invest Ophthalmol Vis Sci* 2011;52:1994-2005.
13. Lindsley K, Matsumura S, Hatef E, et al. Interventions for chronic blepharitis. *Cochrane Database Syst Rev*. 2012 May 16;2012(5):CD005556.
14. Zhao Y, Wu L, Hu L, et al. Association of blepharitis with demodex: a metaanalysis. *Ophthalmic Epidemiol* 2012; 19:95-102.
15. Turgut B, Kurt J, Catak O, et al. Phthiriasis palpebrarum mimicking lid eczema and blepharitis. *J Ophthalmol* 2009; 1-3.
16. McCulley JP, Dougherty JM, Deneau DG. Classification of chronic blepharitis. *Ophthalmology*. 1982;89(10):1173-80.
17. Yeotikar NS, Zhu H, Markoulli M, et al. Functional and morphologic changes of meibomian glands in an asymptomatic adult population. *Invest Ophthalmol Vis Sci*. 2016;57(10):3996-4007.
18. Dougherty JM, McCulley JP. Comparative bacteriology of chronic blepharitis. *Br J Ophthalmol* 1984; 68:524-8.



# THE RICK BAY FOUNDATION

*for Excellence in Eyecare Education*

[www.rickbayfoundation.org](http://www.rickbayfoundation.org)

*Support the Education of Future Healthcare & Eyecare Professionals*



## **About Rick**

Rick Bay served as the publisher of *The Review* Group for more than 20 years.



To those who worked for him, he was a leader whose essence was based in a fierce and boundless loyalty.

To those in the industry and the professions he served, he will be remembered for his unique array of skills and for his dedication to exceeding the expectations of his customers, making many of them fast friends.

Scholarships are awarded to advance the education of students in both **Optometry** and **Ophthalmology**, and are chosen by their school based on qualities that embody Rick's commitment to the profession, including integrity, compassion, partnership and dedication to the greater good.

**Interested in being a partner with us?**

Visit [www.rickbayfoundation.org](http://www.rickbayfoundation.org)

*(Contributions are tax-deductible in accordance with section 170 of the Internal Revenue Code.)*



**THE RICK BAY FOUNDATION®**  
*for Excellence in Eyecare Education*

*(The Rick Bay Foundation for Excellence in Eyecare Education is a nonprofit, tax-exempt organization under section 501(c)(3) of the Internal Revenue Code.)*





BY MARC B. TAUB, OD, MS, AND PAUL HARRIS, OD

## FOCUS ON REFRACTION

# Plus Lenses: Proof is in the Testing

*There are a multitude of evaluations that will get you closer to subjective and objective patient responses.*

In previous columns, we have discussed in detail the use of plus lenses to help abate the signs and symptoms of near point stress. Regardless of the examination findings, when considering the prescription of plus at near, whether in the form of a near vision, bifocal or progressive addition lens, it is important to document some aspect of improvement. This positive change can be objective, subjective or both. This month, we will differentiate the two and discuss the go-to tests we use to demonstrate changes that help guide our decision-making when it comes to plus at near.

Of course, in a perfect world, we trial frame the proposed plus at near and the previously poor data improves to normal values and the patient jumps up and down, claiming we are miracle workers. In reality, the improvement is not always as robust and can actually be quite subtle.

Objectively, we typically hear things like, “the print got larger,” “my eyes do not feel as strained” or “my eyes feel more relaxed.” The key is that the change is in the positive direction. We rely on the patient using their words, not ours, to describe this change. For example, they may not say that something became larger or smaller but that their eyes are working harder or easier. Try your best to not “lead the witness” as they say on TV. There are times in

which you need to probe with some tests. Some patients, especially younger ones, do not know how to describe the change that has taken place. When probing, steer clear of only asking questions that yield positive answers; present both sides equally and perhaps even concentrate on the middle of the spectrum of possibilities.

Keep in mind that the longer the adaptation to the near point stress takes, the less likely you are to receive an immediate positive verbal response. These cases may not yield big or early changes in the vision therapy room, and the patient may need more time to recognize the impact of the lenses.

Subjectively, there are so many tests to choose from to determine the impact of plus lenses. The key is to focus on one or two on which the patient performed poorly. Certain test results indicate that plus at near would be beneficial, so we suggest using these to confirm evidence of improvement:

### Stereo Testing

There are many variations of stereo tests. Whether you like the Random Dot Stereo Test with a mixture of local and global targets or the Random Dot 3 Stereo Test with all global targets, a reduction is considered an indication of a visual efficiency issue. Retesting with trial lenses is a simple and effective way to determine an immediate

impact. For example, if the stereo improves from 70 to 30 sec, you have your objective data.

### Near Point of Convergence

While a reduced NPC is often associated with a convergence insufficiency, it is not pathognomonic for it. A reduced NPC is indicative of a binocular or accommodative disorder, so disregard the unwritten rule that a patient with a convergence issue cannot benefit from plus at near. If there is an accommodative issue compounding the convergence dysfunction, it is very likely that plus will be of benefit. We have also found that if the NPC reduction increases with repetition, plus is more likely to help. Repeat the NPC with the potential plus lenses for proof of improvement.

### Cover Test/Phoria at Near

The expected near posture as determined by either the cover test or von Graefe phoria is 4.00 to 6.00 prism diopters of exophoria. An indication of the need for plus at near would be esophoria or even orthophoria, which should be considered a relative esophoria. If plus lenses are impactful, upon retesting there will be movement toward the ideal 6.00 prism diopters of exophoria. While in a perfect world, the plus will get the patient into the desired exo range, nudging them in the right direction can go a long way and set the stage for success in the vision therapy room.

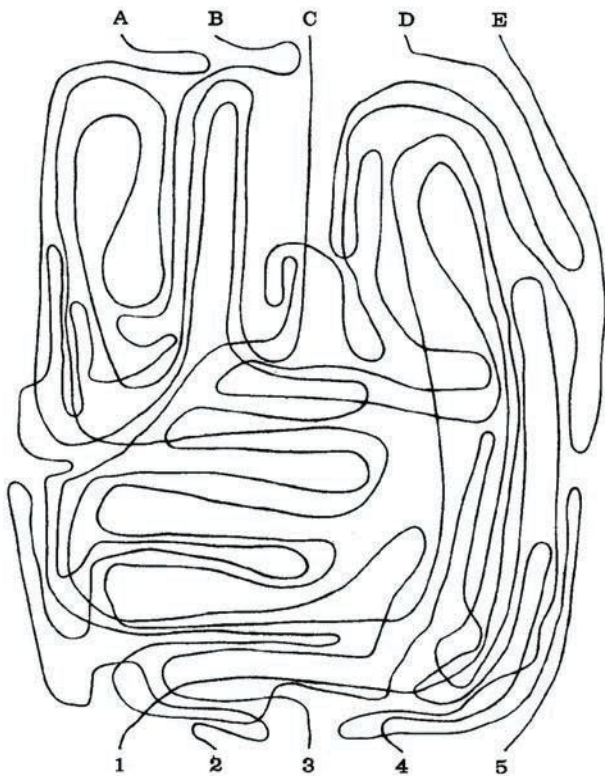
### NRA/PRA

Negative relative accommodation (NRA) and positive relative accommodation (PRA) assess both accommodation and binocularity. An imbalance in which there is a higher NRA (+) than PRA (-) shows the

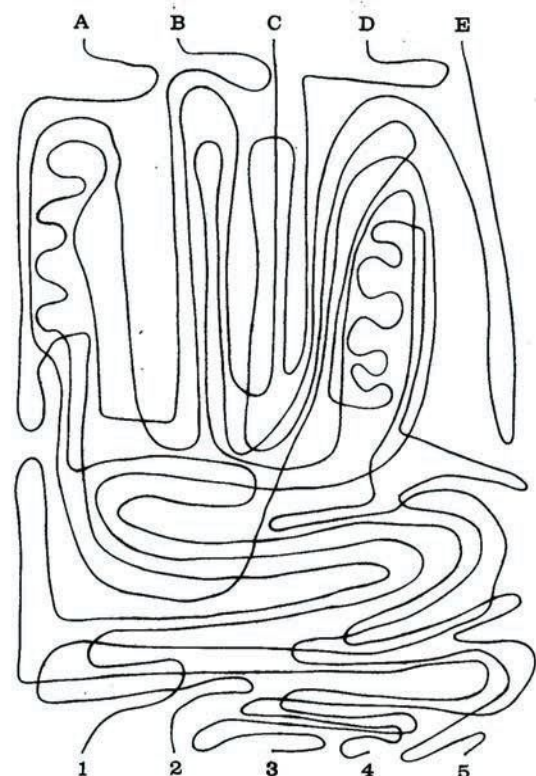
About Drs.  
Taub and Harris

Dr. Taub is a professor, chief of the Vision Therapy and Rehabilitation service and co-supervisor of the Vision Therapy and Pediatrics residency at Southern College of Optometry (SCO) in Memphis. He specializes in vision therapy, pediatrics and brain injury. Dr. Harris is also a professor at SCO. Previously, he was in private practice in Baltimore for 30 years. His interests are in behavioral vision care, vision therapy, pediatrics, brain injury and electrodiagnostics. They have no financial interests to disclose.

### Visual Tracing Test Form "A"



### Visual Tracing Test Form "B"



The Groffman Tests A (left) and B (right) are examples of visual tracing exercises that can help determine the impact of plus lenses.

potential for improvement with plus. This pair of tests is also helpful in providing a starting point for our plus journey. For example, if the NRA/PRA is +2.50/-1.00, the difference is +1.50. Half of that difference, or +0.75, should be your starting near plus prescription. Retesting the NRA/PRA should show better balance if you use this add power, which can then be assessed with any of the tests we cover here and a multitude of others.

### Near Point Retinoscopy

While we don't specify the type of near point retinoscopy, as everyone has their personal preference, the concept of using any of these methods to determine plus acceptance is similar. If the near retinoscopy shows a lag of accommodation of higher plus than +0.25 to +0.75, plus should be considered. As we always strive to leave the patient with the normal near retinoscopy of +0.50, anything in excess could be trialed at near.

### Groffman Visual Tracing Test

You might assume that this is a test of tracking, but in actuality it is so much more. It consists of five intertwined lines beginning at letters at the top of the page and ending on numbers at the bottom. We time the patient while they track each of the five lines from the top to the bottom. If a child performs well below what is expected at their age as part of routine performance testing, we will often grab a pair of plus lenses and have them repeat the test with a second set of lines. If there is an improvement in time or the number of correct trackings, this is a good sign the lenses will be beneficial. We have seen patients perform three- to five-times better on this test with the plus.

### ReadAlyzer Test

Children are commonly referred for poor reading performance. Aside from shorter, number-based tests, the ReadAlyzer (Bernell) is the gold standard. With built-in sensors, we can

finally understand the eye movements that take place while reading. Nearly 10 years ago we conducted a study at the Southern College of Optometry that showed an increase in reading speed with improved reading comprehension with the addition of a plus lens.<sup>1</sup> The reading speed increased by 3%, but it resulted in a 6% improvement in comprehension.<sup>1</sup>

### Takeaways

While we presented these tests separately, one does not make or break the use of plus lenses at near. Using a combination of evaluation methods and all of the data points collected will lead the clinician closer to a subjective and/or objective patient response. If the improvement is nonexistent or minimal, vision therapy is always an option. ■

1. Iyer, J, Harris, P. The effect of low plus lenses on reading rate and comprehension. *Optom Vis Perf.* 2013;1(2):59-61.



BY JOHN RUMPAKIS, OD, MBA  
CLINICAL CODING EDITOR

## CODING CONNECTION

# Consult or Refer?

*Knowing the difference can impact patient care.*

If there is any way to find a good side to the COVID-19 pandemic, it may be that communicating by means other than face-to-face was both necessary and beneficial to caring for a patient. Believe it or not, some newer CPT codes developed and released by the American Medical Association prior to the pandemic were crucial in this aspect of care.

## Definitions

When needing another's expertise to help manage a patient, there are two ways: referring the patient or obtaining a consult. Let's review the practical and legal difference between the two.

**Consult.** Asking for opinion/advice. A short duration relationship between the consulting physician and patient. Continuity of care that involves the patient returning to the physician who requested consult, and ownership of the patient is still with the requesting physician. Documentation is required by both parties in order to get paid.

**Referral.** Sending for treatment/care. A long duration relationship between patient and new physician. Continuity of care involves legal transfer of care, and the referring doctor no longer owns the patient. Documentation and patient consent is not required by both parties in order to get paid.

To understand the documentation relationship between the requesting physician and the consulting physician, think of the "three R's."

**Request.** There must be a written order for a consult request in the requesting physician's patient file.

**Render opinion.** The consulting physician must formulate an opinion

based upon medical expertise and experience and provide it to the requesting physician.

**Report.** The consulting physician must send a written report back to the requesting physician.

“ There are rules for both physicians to meet the definition of an interprofessional consult. ”

By 2019, the interprofessional consult codes were revised and became covered services by CMS. This allowed physicians to communicate via non-traditional methods for the benefit of the patient.

There are rules to meet the definition of an interprofessional consult, such as:

**Billing practitioner.** Interprofessional services are limited to those who can independently bill Medicare for E/M services.

**Benefit of the patient.** Because the patient is going to be responsible for cost-sharing, CMS is concerned about distinguishing Interprofessional Internet Consultations from those undertaken for the edification of the practitioner, such as information shared as a professional courtesy or as continuing education. Verbal consent of the patient must be documented in both practitioners' medical records, and each provider must collect the requisite copayment as with all Medicare Part B services.

## Interprofessional Codes

For the requesting physician, there is only one code to use:

- CPT 99452: Interprofessional Telephone/Internet/EHR Referral Service(s) Provided by a Treating/Requesting Physician or Other Qualified Health Care Professional, 30 minutes; \$36.60 billed by requesting physician.

For the consulting physician, Interprofessional Telephone/Internet/Electronic Health Record Assessment and Management Service Provided by a Consultative Physician, including a *Verbal and Written Report* to the Patient's Treating/Requesting Physician or Other Qualified Health Care Professional, the code sets are:

- CPT 99446: five to 10 minutes of medical consultative discussion and review; \$18.81
- CPT 99447: 11 to 20 minutes of medical consultative discussion and review; \$33.80
- CPT 99448: 21 to 30 minutes of medical consultative discussion and review; \$53.66
- CPT 99449: 31 minutes or more of medical consultative discussion and review; \$73.19

For the consulting physician providing just a written report, the code is:

- CPT 99451: Interprofessional Telephone/Internet/Electronic Health Record Assessment and Management Service Provided by a Consultative Physician, including a *Written Report* to the Patient's Treating/Requesting Physician or Other Qualified Health Care Professional, five minutes or more of medical consultative time; \$36.25 billed by consulting physician.

In a world that is opening up and getting back to normal, physicians and patients alike appreciate making clinical care more efficient and effective, without compromising care; interprofessional consult codes can help greatly. ■

Send your coding questions to [rocodingconnection@gmail.com](mailto:rocodingconnection@gmail.com).

About  
Dr. Rumpakis

Dr. Rumpakis is president and CEO of Practice Resource Management, a firm that provides consulting, appraisal and management services for healthcare professionals and industry partners. As a full-time consultant, he provides services to a wide array of ophthalmic clients. Dr. Rumpakis's full disclosure list can be found in the online version of this article at [www.reviewofoptometry.com](http://www.reviewofoptometry.com).



# The most studied eye vitamin brand.<sup>†</sup>

## PreserVision<sup>®</sup>



PreserVision AREDS 2 is backed by **20 years of clinical studies** and contains **the EXACT nutrient formula** recommended by the National Eye Institute to help reduce the risk of moderate to advanced AMD progression.\*<sup>2,3</sup>

**Recommend PreserVision for your patients today**

For samples, call **1-844-BL-VITES** (1-844-258-4837)

**BAUSCH + LOMB**

\*These statements have not been evaluated by the Food and Drug Administration. These products are not intended to diagnose, treat, cure, or prevent any disease.

Packaging may vary. AREDS=Age-Related Eye Disease Study.  
†Based on the AREDS and AREDS2 clinical studies.  
\*Data on file for #1 Dr. Recommended Brand, Bausch + Lomb. †National Eye Institute, National Institutes of Health; September 2015. Accessed November 4, 2020. [https://www.nei.nih.gov/sites/default/files/health-pdfs/WYSK\\_AMD\\_English\\_Sept2015\\_PRINT.pdf](https://www.nei.nih.gov/sites/default/files/health-pdfs/WYSK_AMD_English_Sept2015_PRINT.pdf) ‡Age-Related Eye Disease Study 2 Research Group. JAMA. 2013;309(19):2005-2015. doi:10.1001/jama.2013.4997

PreserVision is a trademark of Bausch & Lomb Incorporated or its affiliates. AREDS and AREDS2 are registered trademarks of the United States Department of Health and Human Services (HHS). © 2021 Bausch & Lomb Incorporated or its affiliates. PN09897 PVN.0040.USA.21

# NEW CONTACT LENSES: WHERE DO THEY FIT IN?

The latest advances tackle newer concerns like myopia control and sun protection, plus the perennial problems of comfort and convenience.

BY JANE COLE  
CONTRIBUTING EDITOR


By now, most optometrists have a few “old faithful” contact lenses they turn to for various patient types. There’s much to be said for the reliability of a product you know inside and out. Then, when new lenses debut, there’s always a bit of angst as you contemplate whether to stick with the tried and true or gamble on what’s touted as the latest and greatest.

For those interested in kicking the tires on some new lenses, the 2021 landscape looks bright. Increasing availability of toric and multifocal designs in both disposable and reusable lenses, along with much-requested incremental additions in prescription ranges for torics, have greatly expanded the options, says optometrist and professional education team leader Karen Walsh of the Centre for Ocular Research & Education at the University of Waterloo. In addition, new materials technology continues to chip away at the issue of discomfort.

“Beyond these, some voids are being filled too,” she says. “The increas-

ing availability of approved myopia management contact lens designs is an important addition to practice, along with increasing choice of specialty lens materials and designs.”

Recent years have also seen the launch of a photochromic contact lens and a daily disposable with a business model that keeps optometrists in the driver’s seat on product distribution.



**The hoopla about homeostasis that the DEWS II report kicked off was the inspiration for B+L’s Infuse lens.**

If you’ve lost track of what’s new and popular right now, here’s a look at some of the lenses that have hit the market in recent years, along with insight from optometrists on how these CLs might fit into your practice.

## Tackling Discomfort

The number one reason behind contact lens dropout is discomfort. With this in mind, Bausch + Lomb launched Infuse last year, which is designed to be as minimally disruptive to the tear film as possible, according to the company.

The lens is inspired by the Tear Film and Ocular Surface Society’s 2017 DEWS II report to better support the ocular surface, says optometrist Mark Schaeffer of MyEyeDr in Birmingham, AL. DEWS II called out loss of tear film homeostasis (*i.e.*, equilibrium) as an instigator of dry eye.

Infuse, a silicone hydrogel lens in kalifilcon A material, features two osmoprotectants (erythritol and glycerin) and potassium, an electrolyte, all of which are intended to maintain ocular surface homeostasis. B+L’s name for this is “ProBalance Technology.” These elements are designed to help the lens, eye and cornea, and wearers generally get through a 16-hour day without having any issues, Dr. Schaeffer says.

Company literature touts the lens’s high moisture content (55%), low



**Sunglasses for your cornea: J&J worked with Transitions to develop a lens that darkens when exposed to certain frequencies of light, for eye protection and visual comfort.**

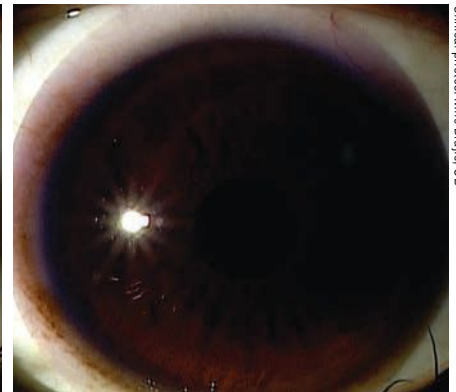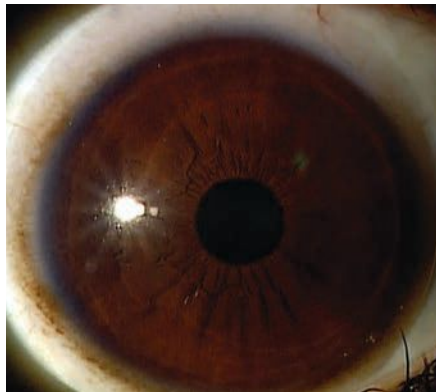modulus (0.5MPa) and high Dk/t (134). Infuse is available in powers of -12.00D to +6.00D, with half-diopter steps in the -12.00D to -6.00D range and quarter-diopter steps thereafter.

Mindful that contact lens wear needs to be visually as well as physiologically comfortable, in 2019 Johnson & Johnson Vision launched Acuvue Oasys with Transitions, a two-week reusable product that continuously adapts from clear to dark and back based on ambient lighting conditions. The lenses become dark in 45 seconds when exposed to UV or HEV light and fade back to clear within 90 seconds in darker lighting, according to J&J. The lens also provides 100% protection against UVB rays, J&J says. The company says the lens filters up to 15% of light in the blue light range indoors and 55% outdoors.

While this lens doesn't get as dark as a photochromic spectacle lens, it is beneficial for those patients who spend a good deal of time outdoors or play outdoor sports, says optometrist Mile Brujic of Bowling Green, OH. "It doesn't replace sunglasses or a photochromic ophthalmic, but patients do notice a difference and are more comfortable when they are outside."

Looking back at pictures from his youth squinting at the camera on the soccer field, Dr. Brujic says this type of lens would have been helpful to him at the time.

"There's a patient population who really benefits from a lens like this. Again, it doesn't negate the need for sunglasses and sun wear protection,



Clinical photos: Mile Brujic, OD

but the lens does have a place in the optometric space and works well in those individuals who enjoy playing outdoor sports but aren't in a position where they can wear sunglasses all the time," he suggests.

### Three Corrections in One

Presbyopes with both astigmatism and spherical refractive error are not uncommon—but all-in-one lenses for them are. B+L's Ultra Multifocal for Astigmatism (MFA) corrects ametropia, astigmatism and presbyopia in one shot and can be pulled from inventory in the practice. Launched in 2019, it remains the only toric multifocal available as a standard offering, B+L says. It is available in sphere from -6.00D to +4.00D with low and high add powers and five cyl options.

"If you think about multifocal toric patients, high astigmats generally come to mind," says Dr. Brujic. "Where this lens has really risen above the other options is that it can correct small levels of astigmatism. Three-quarters of a diopter of cylinder can make these patients much more successful in their multifocal lens."

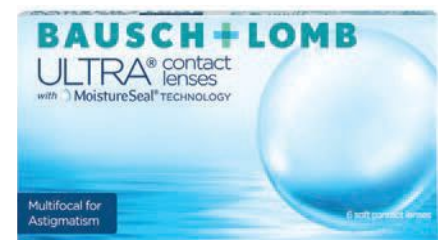The monthly replacement silicone hydrogel lens combines design ideas found elsewhere in B+L's product line. The optics use the company's 3-Zone Progressive multifocal concept: a center-near segment surrounded by concentric rings for intermediate and distance correction. To stabilize the toric element, the lens is ballasted in the lower half and thinner near the top to minimize displace-

ment upon blinking; the company calls this "OpticAlign." For comfort, the Ultra MFA uses the company's dual polymerization approach—first, a silicone meshwork is formed to give the lens structure and then a second, hydrophilic polymer called polyvinylpyrrolidone "grows" around the silicone. B+L calls this two-stage process "MoistureSeal" and says it ensures sustained comfort throughout the day.

The Ultra MFA "is a very stable lens," says Tom Arnold, OD, of Sugar Land, TX. "You don't have mislocation issues, and you can't have a multifocal toric that's rotating." He says he really believes in the optics because the Ultra MFA offers an intermediate zone. "Everyone has an iPad and computer, so the intermediate zone is very important. It's also really nice to correct that -0.75D cylinder and have sharp, glasses-quality vision in a toric multifocal."

The extra attention in recent years to astigmatism correction has been a plus for many practitioners.

"The biggest game-changers for me have been the multifocal toric contact lenses and the extended range toric



**Three corrections in one lens: the Ultra Multifocal for Astigmatism covers all bases.**





**Alcon recently added a toric lens to its Precision1 line of daily disposables. The brand aims to deliver high quality in a mid-priced option. Coming in 2022, the company will look to reinvigorate the monthly replacement category with a new lens to be called Total30.**

lenses,” explains Suzanne Sherman, OD, assistant professor of optometric sciences and director of optometric services in the Department of Ophthalmology at Columbia University in New York. “I order a large volume of more custom lenses, and if the patient loses a lens and needs a replacement, it is more challenging to get a new one. Now, we can order them quicker and in bulk.”

### A Daily for the Masses

The convenience of daily lens disposal has been leaving patients speechless for nearly 30 years—the trouble is, more often than not the price has, too. Especially for lenses that include toric or multifocal correction in addition to sphere, the annual cost can approach

\$1,000 for materials alone. Attempts to ease the sticker shock can cut corners in ways that make the degrade the wearing experience.

Seeing the lay of the land, Alcon introduced a mid-tier contact lens line last year called Precision1, positioned in between its higher-end Dailies Total1 line and its budget-priced, non-SiHy Dailies Aqua Comfort Plus.

Precision1 is offered at a mainstream price, but it’s not a value brand, Dr. Schaeffer says. The company stresses that the lens shares many features of its high-end line to keep patient satisfaction strong, notably including its “water gradient” approach to moisture retention. The lens has a water content of 51% at the core and greater than 80% at the anterior surface.

Alcon says Precision1 can address the three most common reasons why new contact lens wearers drop out within the first year: poor vision, poor comfort and poor handling. The lens uses a new silicone hydrogel material, verofilcon A and includes a thin, permanently adhered layer of moisture. Alcon says this feature, known as SmartSurface, improves comfort and supports a stable tear film to reduce visual fluctuation.

Precision1 is available in a power range of -12.00D to +8.00D, with a 14.2mm diameter, an 8.3 base curve and a Dk/t of 100.

At the beginning of 2021, Alcon added a toric lens to its Precision1 line that comes in sphere powers of -6.00D to plano in quarter-diopter steps and cyl powers of -0.75D, -1.25D and -1.75D.

To reduce rotation, the lens uses prism ballast at the 8 and 4 o’clock points to help reduce lower lid interaction. The company says this design feature allows the lens to settle on-eye in under a minute and within 3° of ideal orientation, resulting in a 99% first fit success rate.

### ORTHO-K: DON'T CALL IT A COMEBACK

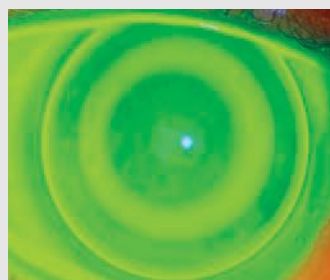
It’s been here for years—the idea of reshaping the cornea through overnight wear of a flat-fit lens used to be the only game in town for myopia management before clinicians started using multifocals for that purpose. But now the rising tide of interest in myopia interventions is lifting ortho-K back into the spotlight.

New entries into this category include J&J’s first lens for myopia control, the Acuvue Abiliti Overnight and X-Cel Specialty Contact’s REMLens.

Abiliti Overnight, slated for release this by the end of this year, will be available in spherical and toric designs. The lens has been shown to reduce axial elongation in myopic children by 0.28mm on average over a two-year period, J&J states. The design is presumably based on the Menicon Z Night lens, as studies cited by J&J reference that product.

Practitioners will use custom software that draws on corneal topography, refractive error and other data to create a lens fit that temporarily reshapes the cornea during overnight wear.

Another new option, REMLens, is available now from X-Cel and manufactured in Boston Equalens II material. Named for what X-Cel calls a “rapid eye molding” effect (hence, “REM”), the lens is appropriate for patients of all ages with low-to-moderate refractive error (up to -5.00D sphere, and up to -1.50D of cyl), the company says. The manufacturer touts an 89% first-fit success rate, a broad




**X-Cel’s REMLens offers lots of design flexibility but, the company says, that doesn’t detract from high rates of first-fit success.**

range of parameter flexibility (four fitting zones, five diameters, three optic zones) and an empirical fitting approach that makes use of an online fitting calculator. The calculator also maintains historical patient information through uploadable corneal topography maps and fluorescein images for convenience during follow-up visits.

Additionally, CooperVision is now offering 5mm back optic zone diameter cus-

tomization for its Paragon CRT ortho-K lenses so that astigmatic patients can take advantage of the modality. Paragon CRT is recommended for patients with <0.75D of corneal astigmatism based on K values, while CRT Dual Axis is designed for those with >0.75D of corneal astigmatism to enhance the cornea-to-fitting relationship. Because this offers more paracentral steepening than a 6mm zone, it may increase the efficacy of myopia management strategies, CooperVision says, assuming a dose-dependent relationship exists between paracentral steepening and ortho-K’s anti-myopia effect.

# Simplify your Lens Fitting.



## OCULUS Pentacam® for efficient specialty lens fitting

Bring efficiency to your specialty lens fitting! Order fewer lenses and decrease patient chair time while increasing the first fit success rate. The Pentacam® simplifies the fitting process by providing true elevation data independent of the tear film. Benefit further with direct links to advanced fitting and design software.

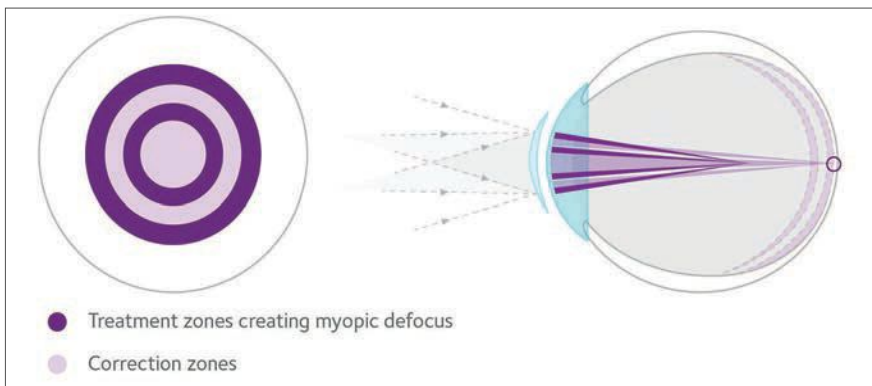
OCULUS Pentacam® – Your new trial lens fitting set!



Scan here or visit  
[www.oculususa.com/lensfitting](http://www.oculususa.com/lensfitting)

Toll free 888-519-5375  
[ads@oculususa.com](mailto:ads@oculususa.com)





**The first soft contact lens approved for myopia mitigation, CooperVision's MiSight 1 Day uses alternating concentric rings to correct refractive error while simultaneously inducing myopic defocus as a signal to slow axial elongation.**

### Monthly Still Matters

Although daily disposables may garner the lion's share of buzz among consumers, in reality the monthly replacement category is a huge market—one that's been neglected of late, some say.

Next year, Alcon says, it will give this segment some overdue attention with a forthcoming lens called Total30.

Details are sketchy, but so far the company has shared that the lens has the same water gradient design as Precision1 and Dailies Total1. The Total30 launch will begin with a spherical lens in powers of -12.00D to +8.00D, with toric and multifocal options to follow within 12 to 18 months.

Although he's not a contact lens wearer himself, Dr. Schaeffer recently test drove the lens on himself and found it to be so comfortable he couldn't feel it on his eye throughout wear time. "I'm excited to see how the lens performs, as we haven't seen new product development in this category for a while," Dr. Schaeffer adds.

About two years ago, Menicon brought its longstanding monthly contact lenses to the United States market after many years of availability in Europe. Called Miru 1month, the product line includes spherical, toric and multifocal options. The lens has a Dk/t of 161 and further optimizes oxygen transmissibility by using a design that controls and minimizes thickness, Menicon says. Surface properties help to achieve high wettability and reduce adhesion of surface contaminants (*e.g.*, bacterial biofilm, lipid deposits, cosmetics), according to the company.

### A Colorful Day

Color-enhancing and color-changing lenses never really achieved mainstream success, but the category still sees periodic advancements aimed at increasing cosmetic appeal and encouraging patients to try the option on a whim to hopefully encourage at least occasional use. As proponents often point out, this is also a way to

extend your contact lens practice to include patients without refractive error, as some emmetropes may find the cosmetic benefit appealing enough on its own terms.

Alcon is now offering a colored contact line in a daily disposable option, with color enhancement and an eye-defining outer ring designed to make eyes appear bigger and brighter. Dailies Colors are available from -8.00D to plano, in half-diopter steps at the higher powers and quarter-diopter steps below -6.00D. Color choices are blue, hazel, gray and green. Water content is 59% and the Dk/t is 26.

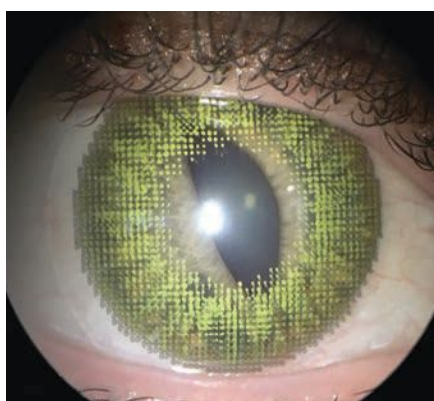
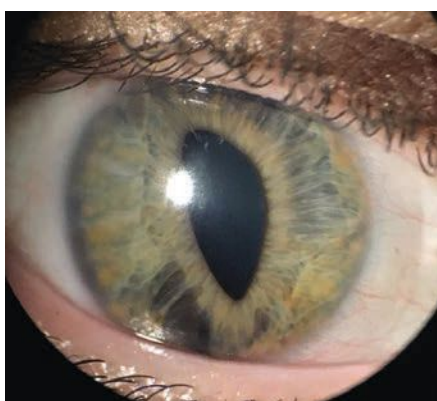
"Dailies Colors has been an unexpected plus for me," Dr. Sherman says. "I see patients with iris atrophy, polycoria or iris abnormalities express interest, and these lenses have even helped some patient's photophobia."

### Myopia Gets Some Muscle

With myopia one of the most common ocular disorders worldwide, and momentum building for interventions, companies are taking notice. CooperVision recently received the first nod from the FDA for a lens to mitigate this condition, its MiSight 1 Day daily disposable. The omafilcon A lens is designed for children ages eight to 12 who have up to -6.00D of myopia.

"For years now, we've used off-label options for myopia management, such as distance-centered multifocals and compounded low concentration atropine drops, so it's nice that the lens has gone through clinical trials, and the data is compelling," Dr. Brujic says.

Clinical photos: Suzanne Sherman, OD; product: Melissa Barnett, OD



**Colored lenses can appeal to both the fashion-conscious and those with iris abnormalities looking for aesthetic improvement, as in this case of iridocorneal endothelial syndrome before (left) and after (middle) application of an iris-print lens.**



## POPULAR CONTACT LENS LINES EXTENDED

If you have a favorite go-to lens but wish it offered greater Rx options or wear schedules, several companies have broadened some of their workhorse CL products to fit more patients.

### More Choices for Astigmatism

In recent years, CooperVision has nearly doubled its prescription options for its Biofinity XR toric, with the lens sphere powers now ranging from -20.00D to +20.00D. Cylinder powers vary based on sphere, but options begin at -0.75D and go up to -5.75D. For hyperopic astigmats, Cooper recently expanded its MyDay torics with added plus powers. The SiHy lenses now come with expanded parameters that include +0.50DS to +6.00DS in 0.50D steps.

Additionally, toric lens wearers now have a monthly replacement option with Alcon's Air Optix Plus Hydraglyde for Astigmatism. Similar to other products in this brand, the monthly toric includes Alcon-specific technologies to increase comfort and lens stability. The lens is made of Alcon's lotrafilcon B silicone hydrogel material and has a water content of 33% and Dk/t of 108. Sphere power range is -10.00D to +6.00D, and cyl powers are -0.75, -1.25, -1.75 and -2.25 at axes 10 to 180 in 10° steps.

Alcon also added new parameters to its Dailies Aqua Comfort Plus Toric contact lens line, including a -2.25D cylinder, around-the-clock axes in core parameters and expanded high-minus sphere powers. Combined with its existing coverage, the new range includes 2,360 parameters and allows 94% of astigmatic patients to be a candidate for the lens, according to the company.

Another expansion in this category comes from Bausch + Lomb. The company added to the parameters of its Biotrue OneDay for Astigmatism daily disposable. The expansion extends the full power range to -9.00D to +4.00D in three-cylinder powers of -0.75, -1.25 and -1.75; it also adds additional parameters in a -2.25 cyl.

In another B+L update in this category, the company added a new -2.75D cyl option for its Ultra for Astigmatism contact lenses. The new option is available across all power ranges in the portfolio, from 9.00D to +6.00D.

Toric lens patients now have another colored lens option with the recent introduction of ToriColors Comfort Cosmetic Lens by

X-Cel Specialty Contacts. In partnership with Ireland-based cosmetic lens manufacturer PolyDev, the company is offering both low and mid-cylinder options as monthly disposable lenses in four colors. The lenses are available in powers of -4.00D to -2.00D in half-diopter steps and -2.50D to plano in quarter-diopters.

### Extended Wear Resurfaces

Though early attempts at contact lens wear for extended periods were tumultuous and ultimately prompted a pull-back from the original offering of 30 days of continuous wear, the idea of not having to remove lenses at night remains enticing when done safely. A few years ago, Bausch + Lomb's line of Ultra contact lenses received FDA approval for extended wear for up to six nights and seven days. The product line includes single vision, toric and multifocal options. Ultra lenses are intended for monthly replacement.

### More Options for Myopes

The sweet spot for soft lens correction of myopia seems to be -6.00D or less, as that's the range all manufacturers target for mass production of products, but there's a sizable base of patients with an Rx above that who often leave an optometrist's practice empty-handed. To help bring them into the fold, Bausch + Lomb expanded its BioTrue OneDay parameters to include high myopes with six new minus powers: -9.50D, -10.00D, -10.50D, -11.00D, -11.50D and -12.00D, giving the lens a power range of -12.00D to +6.00D.

### Greater Choices for Two-Week Wearers

If your patients are happy in their Acuvue Oasys lenses but are now presbyopic, J&J recently added a multifocal in the same material (senofilcon) and also for two-week replacement. The new products use the pupil optimized design of the 1-Day Acuvue Moist Multifocal, which allows the lens to be fit independent of pupil size, J&J suggests. The design uses a hybrid back curve: an aspheric center allows the lens to drape across the cornea without creating distortion while a spherical skirt holds the lens in place. Acuvue Oasys Multifocal is available in sphere powers from -9.00D to +6.00D and three add power ranges: low (+0.75D to +1.25D), mid (+1.50D to +1.75D) and high (+2.00D to +2.50D).

CooperVision's lens uses a different concept of multifocality than a traditional presbyopia-correcting lens. The MiSight 1 Day is comprised of four concentric rings—two of which are “treatment zones” that create a myopic defocus of +2.00D; the other two are “correction zones” that neutralize myopia.

Over a three-year study period, MiSight 1 Day wearers experienced a 59% reduction in myopia progression by spherical equivalent refraction and 52% by axial length, CooperVision says. Visual acuity results were favorable, but some children need time to adapt to the lens's effects.

“We are now scratching the surface of how we will manage myopia when we catch the condition early enough,”

Dr. Brujic says. Also, Dr. Schaeffer notes, MiSight offers the health and safety of a daily lens, which is important for a practice's most vulnerable patients: children and youth.

“We want to make sure they have the best safety profile, and that's what this lens does,” Dr. Schaeffer suggests. “Not only does the lens help with long-term issues, but it also ensures short-term that these young patients are in the safest and healthiest wearing option.”

### “Doctor-controlled” Daily

Optometrists hoping to keep CL sales within the practice now have an ally in Eyeris, a company founded by contact lens specialist Jeffrey Sonsino, OD. The Eyeris Daily is a hioxifilcon A

daily disposable lens with an 8.5 base curve, a 14.3 diameter and a power range of -13.00 to +6.00. The material has the lowest modulus on the market and was designed by an industry veteran with successful track record in materials science, Dr. Sonsino explains.

The company doesn't supply its product to online venues such as 1-800 Contacts, Hubble or Warby Parker, so it can't be substituted by online middlemen, Dr. Sonsino says. The patient can purchase the Eyeris Daily in the OD's office or online directly from the company. If patients choose to order the lens online, the prescribing doctor receives the margin as if it were purchased in their office, the company says.

Photo: Melissa Barnett, OD



**The Eyeris Daily is sold under a business model that aims to keep doctors in charge of product distribution, protecting practices against disreputable third-party suppliers.**

Dr. Sonsino attributes the idea for the Eyeris to his experience as former chair of the American Optometric Association’s Contact Lens Section and current chair of the Academy’s new Innovation Council. In these roles, he says he’s been exposed to what the industry will be facing in the next five years, which he says, “isn’t pretty.”

“Disruptive middlemen are extremely well-funded and will not stop outspending us with lobbying efforts until they prevail,” Dr. Sonsino says. “We wanted to give private practice ODs a highly viable option in contact lenses that allows them to win against disrupters.

Here’s how the model works: Eyeris distributes the lens directly from its facility in Nashville. When doctors in the network prescribe and order the lens, a duplicate profile is automatically created on the consumer side of the website. Patients can go online

and purchase the balance of what they didn’t buy in the office or opt for a monthly subscription, CEO Andy Barrow says. The subscription option insulates the OD from having to do anything differently and the patient can spread out the annual supply cost over the rest of the year, while paying the exact same box cost, he adds.

“When the patient spends less on contact lenses in the office, that means more money can be spent in your optical on glasses,” Mr. Barrow suggests.

The company is currently working on a center-distance bifocal lens, which could be launched next year, Dr. Sonsino says.

### Wish Lists

With an eye on the future, optometrists weigh in on what they’d like to see in new CL designs.

“I would love to push the boundaries a little further on the comfort experience a contact lens can deliver,” Dr. Walsh says. “We have all experienced the feeling of hot, gritty eyes, come 6pm as we leave the office and computer behind. Imagine being able to wear a contact lens that could at least maintain the morning level of comfort throughout the day, if not actually being able to enhance comfort such that it felt better to wear a lens than not.”

Dr. Walsh also points to promising drug-delivering contact lenses on the horizon that will allow practitioners to treat a condition and remedy its symptoms in a sustained-release fashion. The first such lens will treat ocular allergy. Further down the line, she hopes drug delivery lenses will expand to treat acute infection.

Looking more to the horizon, Dr. Walsh anticipates that “the ability to create lenses that can support augmented vision both for people with low vision and for more general use with social media applications is exciting, as is the potential for automatically focusing lenses that can help presbyopes regain much younger-feeling vision.”

Dr. Arnold, who has a focus on specialty lenses, would like to see the majority of scleral manufacturers offer free-form designs where the first lens put on a patient is the right one.

Adds Dr. Sherman, “I find that some of the monthly multifocal lenses that offer distance or near focus achieve the best vision. A daily multifocal that provides high near correction as well as distance would make a lot of patients happy.” She’d also like to see more extended ranges and higher myopia prescriptions in dailies.

For patient convenience, Dr. Brujic suggests a soft lens that would have a different color in the bowl of the lens when it is positioned appropriately and ready to be applied to the eye.

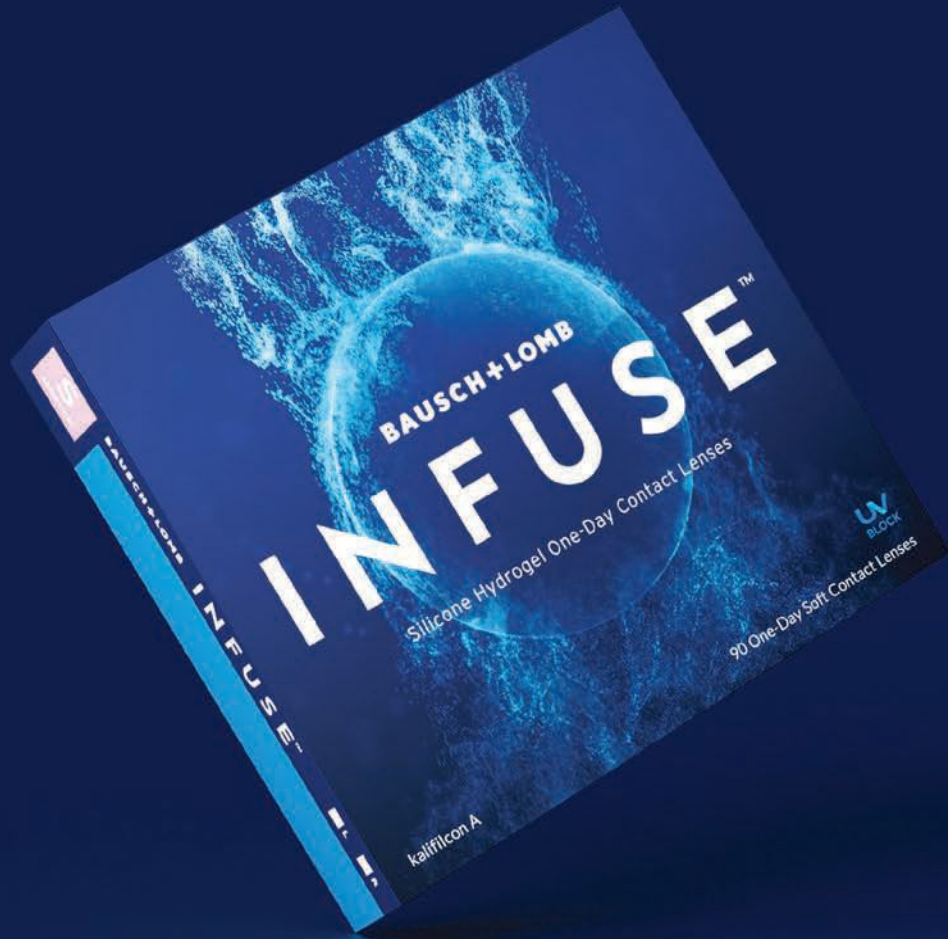This would help both new and veteran CL wearers more easily determine if the lens is properly oriented and not inverted on the first try, he says.

Dr. Walsh believes the biggest opportunities lie on either end of the age spectrum—myopia management and presbyopia—categories that have recently been amplified due to increasing lens choices in each.

“Many patients can benefit in both groups, and with availability of lenses only set to increase, this is the area in which I feel most excited for the future,” Dr. Walsh says. “The ability to manage myopia in my young patients, and the option to recommend contact lenses to enhance the lives of my young-feeling, vibrant group of presbyopes, opens up increasing possibilities for how I care for my patients.”

### Takeaways

“It’s such an exciting time to be a prescriber of contact lenses,” Dr. Schaeffer says. “Having all these technologies available now has made my job so much easier. When I hear patient complaints in the chair, I can connect the dots between what they’re expressing to me and a new path forward I can recommend by switching or prescribing them a new lens.” With these newer options within reach, he says, “ultimately, patients can have a better wearing experience.” ■



# INFUSED FOR BALANCE

Next-generation material + ProBalance Technology™  
working together to help maintain ocular surface homeostasis  
to aid in minimizing symptoms of contact lens dryness.<sup>1</sup>



Next-Generation Material



Ocular Surface  
Homeostasis



ProBalance Technology™

Find balance at [BauschInfuseECP.com](https://www.BauschInfuseECP.com)

REFERENCE: 1. Data on file. Bausch & Lomb Incorporated, Rochester, NY.

\* /™ are trademarks of Bausch & Lomb Incorporated or its affiliates.  
©2020 Bausch & Lomb Incorporated or its affiliates. INF.0243.USA.20

**BAUSCH+LOMB**

See better. Live better.



# HOW TO IMPROVE CONTACT LENS/TEAR INTERACTIONS

Better understand this relationship between the two, and relay how to best preserve it to patients.



TREVOR J. FOSSO  
SARTELL, MN

Contact lenses are a medical marvel that, in today's world, is often taken for granted. First made from blown glass in the late 1800s, contact lenses have progressed significantly over the last 120 years. With every advancement in contact lens technology, access to contact lens wear has increased exponentially, but despite that, reactions have become somewhat ho-hum.

While patients who require contacts for medical purposes appreciate their life-changing benefits, many of our day-to-day patients are no longer astounded by the promise and impact of a little piece of plastic on their eye that helps them see. But little do they realize how their vision relies on the relationship between these medical marvels and the tear film.

This article will discuss the interactions of contact lenses with the tear film, how suboptimal contact lens-tear film interactions can impact contact lens wear and various management strategies to improve and optimize that interaction.

## Inside the Layers

From a patient's perspective, successful contact lens wear depends on vision and comfort, and nothing plays a greater role in promoting success than the tear film. The tear film consists of an outer oil layer produced by the meibomian glands of the eyelids that prevents evaporation of the aqueous portion of the tear film. Below the lipid layer exists a mixture of aqueous fluid produced by the main and accessory lacrimal glands and soluble mucins produced by conjunctival goblet cells that hydrate and lubricate the ocular surface.

The innermost layer is the glycocalyx, which consists of insoluble mucins produced by conjunctival goblet cells and assists in adhering the tear film to the corneal epithelium.<sup>1</sup> When a contact lens is applied to the eye, it splits the tear film into two halves: a pre-lens tear film and a post-lens tear film (*Figure 1*).<sup>2-5</sup>

The pre-lens tear film consists of the outer lipid layer of the tear film and a portion of the aqueous and mucin mixture.<sup>2,4,5</sup> It covers the outer surface of the lens and provides the smooth optical surface required for vision as well as a lubrication layer

between the contact lens and the palpebral conjunctiva of the eyelids.

The post-lens tear film consists of the remaining portion of the aqueous and mucin mixture and the glycocalyx layer, providing lubrication and a cushion between the contact lens and cornea and bulbar conjunctiva.<sup>2,4,5</sup>

For an individual with a normal tear film, there is adequate volume to both the pre-lens and post-lens tear films such that they do not become destabilized when divided by the contact lens. This leads to good quality, stable vision and good comfort, resulting in successful contact lens wear.

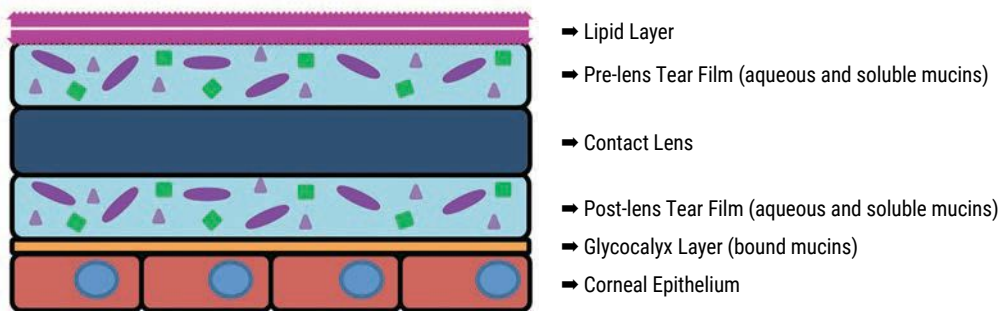
Contrary to that, an individual who is deficient in one or multiple of these tear film components may struggle with contact lens wear due to poor vision, comfort or both.

## Common Complications

Every eye care provider likely has at least one patient per day who complains of blurry, fluctuating vision that changes constantly as they blink. And many can probably think of several patients who have this complaint specifically with wearing their contact lenses. Visual instability like this may

### About the author

Dr. Fosso is the director of contact lens services at PineCone Vision Center in Sartell, MN. He is a fellow of the American Academy of Optometry as well as the Scleral Lens Society. He has consulted and lectured for the STAPLE Program, Euclid Systems Corp. and Valley Contax.



**Fig. 1. A contact lens splits the tear film into pre-lens and post-lens layers with different components.**

be the result of an unstable lipid layer leading to more rapid evaporation of the tear film, or it may be due to poor lens surface wetting. Patients with rapid tear break-up time typically suffer from various lid conditions such as meibomian gland dysfunction or blepharitis, and management of those conditions should be targeted to improve their symptoms.

In the absence of some pathology, poor surface wetting of contact lenses can develop secondary to lens deposits, which may be organic or inorganic in nature. Common organic deposits include lipids and proteins commonly found in the tear film. Common inorganic deposits include contamination from mascara, hairspray, lotions and soaps.<sup>6</sup>

With the increased use of daily disposable lenses, surface deposits have become far less common, but when they are encountered, remind patients to rub their lenses and thoroughly wash their hands prior to handling the lens or recommend a different cleaning regimen such as a surfactant or enzymatic cleaner. Enforcing these steps can make all the difference.<sup>6</sup>

For gas permeable (GP)-style contact lenses, including corneal and scleral modalities, maintaining excellent surface wetting can sometimes be a challenge. The materials used to create these lenses are typically hydrophobic in nature, thus care regimens for GP-style modalities involve both cleaning and conditioning the lens to promote lens surface wettability.<sup>7</sup> Surface contamination by various cosmetic products can greatly

reduce surface wettability and may require thorough rubbing to remove or the use of a strong laboratory-style cleaner.<sup>6</sup>

To help promote initial surface wetting, the lens manufacturer can do plasma treatment, which removes a thin layer of organic matter present on the surface of the lens producing a hyper-clean surface.<sup>6</sup> The removal of this layer of organic matter helps to improve the surface wettability of these lenses.

Practitioners can also request to have Tangible Science's Hydra-PEG coating added to lenses, which is a hydrophilic layer chemically bonded to the surface of GP lenses, promoting tear film adherence to the lens surface. Hydra-PEG has been a game-changer and has become a first-line treatment strategy for GP contact lens wearers suffering from issues associated with surface wettability.

Another common issue practitioners encounter is contact lens discomfort. Patients who are asymptomatic without contact lens wear may complain of grittiness, dryness, scratching, irritation, redness or myriad other symptoms when wearing contact lenses.<sup>4,8-10</sup>

The tear film provides lubrication between the contact lens and the ocular surfaces it interacts with, including the palpebral conjunctiva lining the eyelids, the bulbar conjunctiva covering the sclera and the cornea itself. Without lubrication, these tissues are directly exposed to the harsh mechanical interaction of the contact lens as it moves during blinking.<sup>4,8-10</sup> The palpebral conjunctiva rubs across

the surface of the contact lens rather than gliding. This can lead to the development of papillary and/or giant papillary conjunctivitis as well as keratinization of the palpebral conjunctiva along the lid margin, known as lid wiper epitheliopathy (LWE).<sup>3,11</sup> The bulbar conjunctiva can be affected similarly. Without adequate tear film volume,

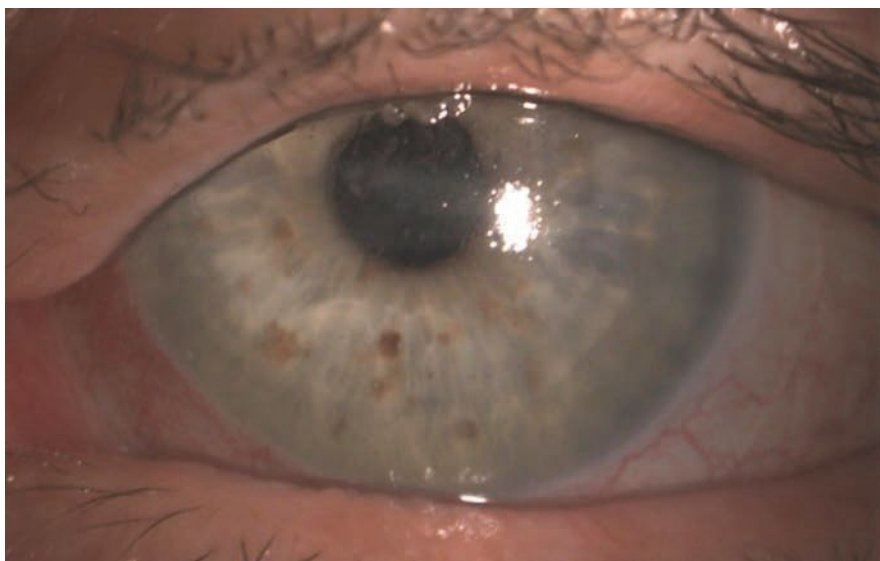a contact lens's movement is limited or may not move at all. This in turn leads to irritation and inflammation of the ocular surface, which decreases patient comfort.

Adjusting a lens parameter such as the base curve or diameter of a soft contact lens or the landing zone of a scleral or hybrid contact lens to loosen the fit of the lens may be enough to remedy this issue.<sup>6,7</sup> Otherwise, ensuring adequate tear volume is present provides a cushion for the contact lens to rest on rather than directly bearing on the cornea or conjunctiva. The cornea and conjunctiva are both very highly innervated tissues, and slight changes in pressure, temperature and pain can be readily detected.<sup>1,3,4</sup> Therefore, reducing or eliminating any extra pressure or pain stimulation of those nerves is paramount to contact lens wearing success.

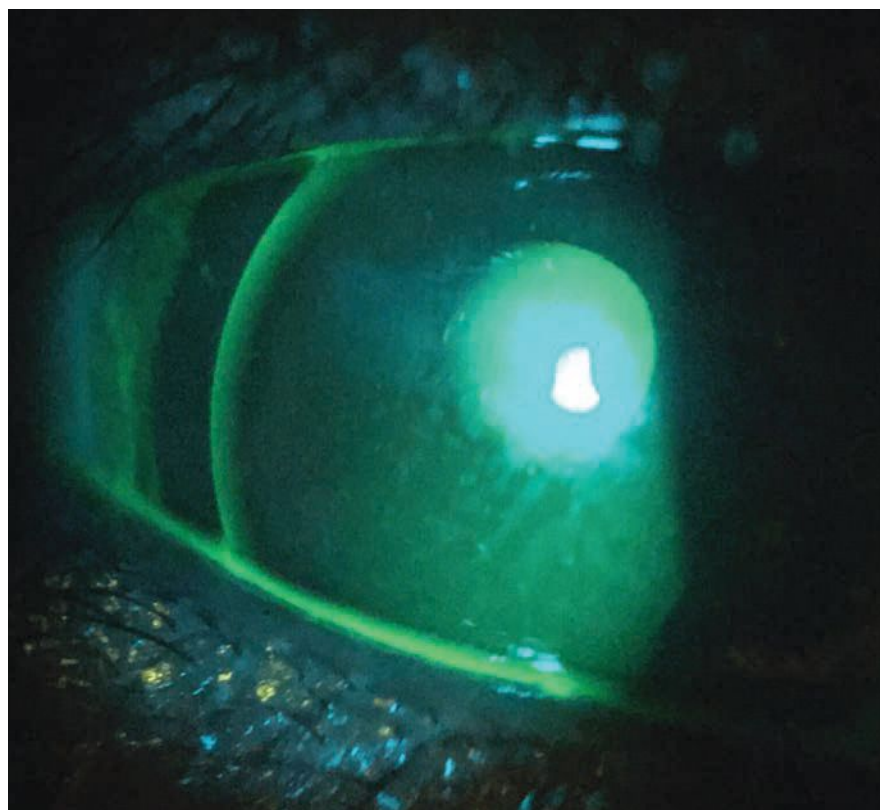
## Neophyte Evaluation

When examining a new patient who desires contact lenses, start with a thorough ocular health evaluation for any signs of meibomian gland dysfunction, blepharitis, reduced tear break-up time or low tear volume. More advanced testing such as non-invasive tear break-up time, lipid layer analysis, meibography, blink analysis, tear osmolarity and InflammDry (Quidel) can help further identify these potential troublemakers and provide guidance for a targeted treatment approach.

For patients who are looking to begin wearing contact lenses, iden-



**Fig. 2.** A scleral lens evaluated with white light that demonstrates poor surface wetting and mucus build-up on a patient with neurotrophic keratitis.



**Fig. 3.** Sodium fluorescein staining demonstrates front surface tear film break-up in this GP lens patient.

tifying and treating these conditions prior to lens wear can increase their success.<sup>12</sup>

For new contact lens wearers and those returning for their annual evaluations, it is imperative to assess the ocular surface both during and after

contact lens wear. Begin the assessment with white light to evaluate the contact lens fit for movement, lens centration and surface wetting (*Figure 2*). Also, evaluate the lid margin for signs of meibomian gland dysfunction, tear film debris and signs of ocu-

lar surface irritation such as injection or corneal infiltrates.

For GP and hybrid lenses, apply sodium fluorescein to the ocular surface to assess the fit of the contact lens prior to removal. By staining the tear film, the interaction of the contact lens and the ocular surface can be more directly visualized. It also makes it possible to visualize the surface wettability of GP lenses more directly (*Figure 3*). This can also be done with silicone hydrogel (SiHy) soft contact lenses but not hydrogel lenses, as the fluorescein can be absorbed into the matrix of those lenses.

Following removal of the contact lenses, use both lissamine green and sodium fluorescein vital dyes to thoroughly evaluate the ocular surfaces. Lissamine green provides excellent visualization of the conjunctiva and highlights areas of irritation associated with contact lens wear, such as circumferential staining around the cornea that can result from a contact lens that is too tight.

Staining is also needed for visualizing LWE on the palpebral conjunctiva (*Figure 4*). Typically, there should be a line of staining at the mucocutaneous junction, known as the line of Marx; any staining of the adjacent palpebral conjunctiva beyond that is evidence of LWE.<sup>8,9</sup>

The lid wiper normally contacts the ocular surface and contact lens and acts as a squeegee to distribute the tears, but as the tissue becomes keratinized, it can no longer distribute the tears across the ocular surface as easily or efficiently.

Imagine a car whose windshield wipers are moving back and forth without any windshield wiper fluid. Rather than gentle gliding across the windshield, the wiper blades streak and stutter across, resulting in damage to the wipers and poor cleaning of the windshield. The same effect happens as the lids blink across a poorly wetting contact lens, which can develop in both soft and GP contact lens wearers alike. This results in increased friction, which further exacerbates the





REMLens<sup>®</sup>  
RAPID EYE MOLDING

Changing Sight, Overnight™

Introducing REMLens<sup>®</sup>,  
**Rapid Eye Molding**, that  
changes sight, overnight.

Discover how REMLens<sup>®</sup>  
can benefit your patients,  
and your practice.

89% First Fit  
Success Rate\*

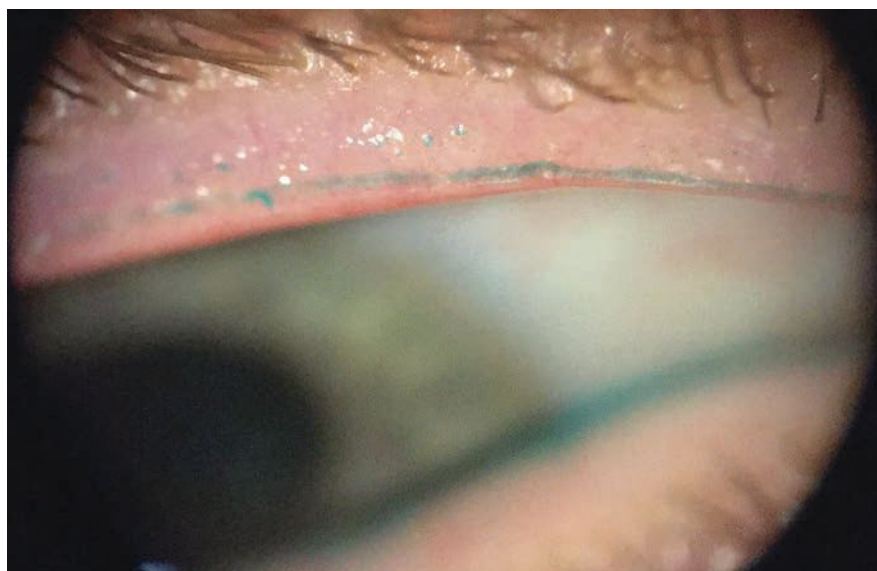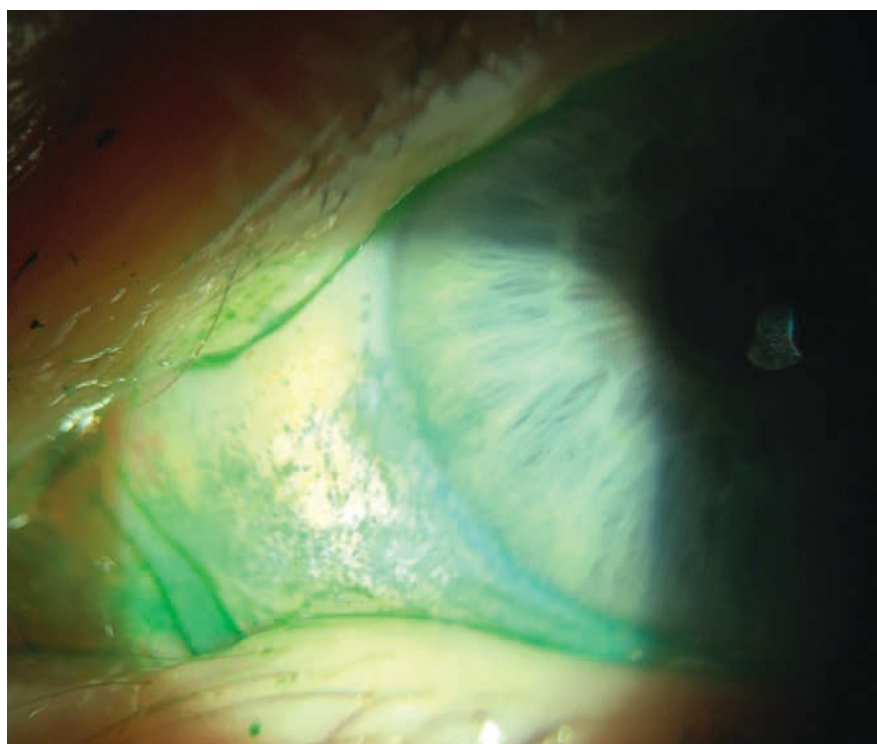
X-Cel Specialty Contacts has been committed to the management of myopia for nearly two decades. The introduction of REMLens<sup>®</sup> is another step forward in our dedication to the myopia management category. With REMLens<sup>®</sup>, you can expect:

- **89% First fit success rate\***
- Dynamic Edge Profile™ delivers remarkable comfort
- Simplified lens design, and ease of ordering
- Online lens design calculator
- Highly adjustable parameters
- Multiple diameter and optic zone options
- Worry-free refit policy
- Consultation from NCLE certified experts
- Practice management tools
- 24-hour turnaround time
- Competitive pricing
- Hassle-free, no return warranty

Vision Shaping  
Treatment VST<sup>®</sup>

  
**X-CEL**  
SPECIALTY CONTACTS

800.241.9312 | [xcelinfo@xcelspecialtycontacts.com](mailto:xcelinfo@xcelspecialtycontacts.com)



**Fig. 4. Bulbar conjunctival staining with lissamine green (top) and palpebral conjunctival staining (bottom) characteristic of mild LWE.**

epitheliopathy and worsens patient symptoms (e.g., foreign body sensation, grittiness, irritation).<sup>11</sup>

Sodium fluorescein can stain dead epithelial cells on both the cornea and conjunctiva, highlighting areas of compromised integrity of the ocular surface, which results from both contact lens wear and dry eye.<sup>12</sup> The presence of this staining is a good indicator of ocular surface inflamma-

tion related to dry eye but can also be the result of increased friction as the contact lens moves across the cornea or conjunctiva. Areas that become dehydrated during contact lens wear can also develop these points of staining, a common example of this being 3 and 9 o'clock staining that can be seen with corneal GP lenses (*Figure 5*). By providing direct visualization of the tear film, fluorescein allows for

evaluation of tear film break-up time and tear meniscus height. In cases of GP, hybrid and SiHy lens modalities, by assessing this staining both during and after contact lens wear, one is able to evaluate the impact a contact lens has on the tear film dynamics.

### Treat Underlying Conditions

For patients with underlying conditions such as meibomian gland dysfunction or dry eye disease, management of those conditions should be targeted first. For meibomian gland dysfunction, there are typically two different levels of treatment: at-home thermal therapy, which use various heat masks to improve or maintain gland function, or in-office thermal pulsation therapies, which combine thermal treatment with mechanical pulsation to more fully express the meibomian glands.

Improving meibomian gland function helps increase the lipid layer of the tear film and promotes tear film stability. For patients who have significant meibomian gland dropout, supplementation with a lipid-based artificial tear may also be beneficial.

Dry eye disease may present in a myriad of ways and often requires multiple treatment strategies. To manage ocular surface inflammation, topical immune modulators, such as Restasis (cyclosporine A emulsion 0.05%, Allergan), Xiidra (lifitegrast ophthalmic solution 5%, Novartis) and Cequa (cyclosporine ophthalmic solution 0.09%, Sun Ophthalmics), are commonly used.<sup>13</sup>

For patients with reduced tear volume, techniques to increase it can be targeted towards supplementation, decreasing tear outflow or stimulating tear production. Increasing tear volume via artificial tear supplementation can be effective but tedious. Some patients may only require two or three drops throughout the day, while others may require one drop per hour to maintain comfort and vision. When using artificial tears more than four times per day, I recommend patients use preservative-free artificial tears.

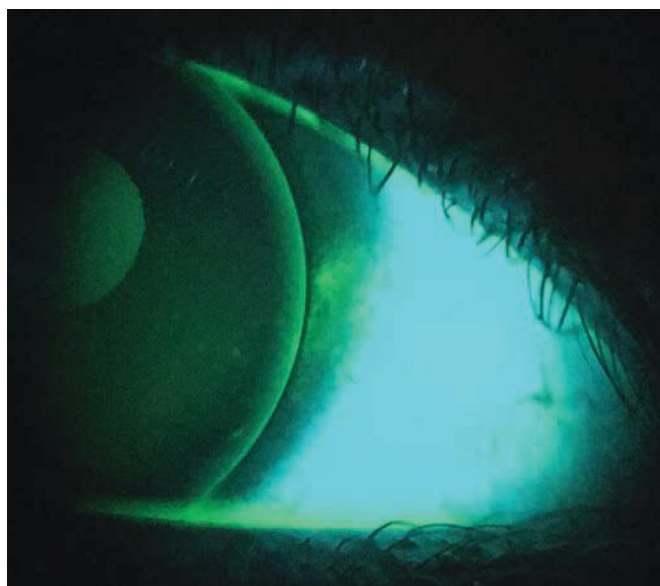


For those patients requiring several supplemental drops throughout the day, punctal plugs can help reduce or eliminate the need for artificial tear drops by blocking the nasolacrimal drainage system. Increasing the production of the natural tear film components is another great method. Various oral medications, such as cevimeline and pilocarpine, and topical medications, such as diquafosol and rebamipide, exist that increase tear production and may be indicated based on the severity of the patient's condition.<sup>2,5,9,10,14</sup>

Once other underlying diseases are managed in patients still struggling with contact lens wear, consider changing the contact lens parameters or modality. Standard soft contact lenses provide limited variation and often require changing brands to obtain a different base curve or diameter that is more desirable. For frequent-replacement soft lens modalities, reviewing and recommending care systems that reduce or eliminate exposure to preservatives can help improve patient comfort. Switching patients to daily disposable lenses can help improve patient comfort by reducing the tear film interference as well as providing a fresh lens every day for wear.

For custom soft and GP lens modalities there is a lot of freedom to adjust lens parameters such as base curve, diameter, optic zone size, peripheral curves and material that may be altered to optimize the contact lens fit and patient comfort. The addition of different lens treatments (e.g., plasma treatment) or coatings (e.g., Hydra-PEG) can also improve lens wettability and patient comfort.

For some trickier patients, sometimes a change in modality is required. Two of my favorite options are orthokeratology (ortho-K) and scleral contact lenses. Ortho-K pres-



**Fig. 5. Punctate staining present along the edge of a corneal GP lens characteristic of "3 and 9 o'clock" staining.**

ents an excellent correction option for myopic patients, especially those who report issues of dryness when wearing their contact lenses during the day but not their glasses. By wearing the ortho-K lenses at night in a closed-eye system, tear film evaporation is reduced and there is less interaction between the lens and eyelids. For those patients who are not candidates for or are not interested in ortho-K, scleral lenses provide another correction option.

Scleral lenses have become a mainstay treatment for chronic, severe dry eye patients but can also provide symptomatic relief and excellent comfort for patients who are otherwise intolerant to contact lens wear. Oftentimes, I will have patients return for an in-office scleral lens trial, where we place lenses on their eye and they can experience them in-office. Many patients appreciate the extra hydration and comfort of the lenses even during this short trial period in the office and choose to pursue scleral lenses.

## Takeaways

For patients struggling to wear contact lenses, identification and management of any underlying conditions will greatly improve patient success

and help keep them in their contact lenses. Once other causes have been ruled out, evaluation of the lenses and how they impact the ocular surface can help to direct what changes need to be made to help improve patient comfort. Some cases may require larger changes, such as switching to a different modality.

Whatever the situation, identifying your patient's issue, explaining it to them, providing them with a targeted treatment plan, and delivering on that plan can build their confidence in you and keep them wearing contact lenses longer. ■

1. Remington LA. Ocular adnexa and lacrimal system. In: *Clinical Anatomy and Physiology of the Visual System*. 3rd ed. St. Louis: Elsevier Butterworth Heinemann; 2012:159-81.
2. Nichols JJ, Willcox MDP, Bron AJ, et al. The TFOS International Workshop on Contact Lens Discomfort: executive summary. *Invest Ophthalmol Vis Sci*. 2013;54(11):TFOS7-13.
3. Efron N, Jones L, Bron AJ, et al. The TFOS International Workshop on Contact Lens Discomfort: report of the contact lens interactions with the ocular surface and adnexa subcommittee. *Invest Ophthalmol Vis Sci*. 2013;54(11):TFOS98-122.
4. Craig JP, Wilcox MDP, Argüeso P, et al. The TFOS International Workshop on Contact Lens Discomfort: report of the contact lens interactions with the tear film subcommittee. *Invest Ophthalmol Vis Sci*. 2013;54(11):TFOS123-56.
5. Kojima T. Contact lens-associated dry eye disease: recent advances worldwide and in Japan. *Invest Ophthalmol Vis Sci*. 2018;59(14):DES102-8.
6. Bennett ES, Henry VA. Soft lens care and patient education. In: *Clinical Manual of Contact Lenses*. 4th ed. Philadelphia: Wolters Kluwer/Lippincott Williams & Wilkins; 2014:294-7.
7. Bennett ES, Henry VA. Gas-permeable lens care and patient education. In: *Clinical manual of contact lenses*. 4th ed. Philadelphia: Wolters Kluwer/Lippincott Williams & Wilkins; 2014:157-61.
8. Jones L, Brennan NA, González-Méjome J, et al. The TFOS International Workshop on Contact Lens Discomfort: report of the contact lens materials, design and care subcommittee. *Invest Ophthalmol Vis Sci*. 2013;54(11):TFOS37-70.
9. Chen Q, Wang J, Shen M, et al. Lower volumes of tear menisci in contact lens wearers with dry eye symptoms. *Invest Ophthalmol Vis Sci*. 2009;50(7):3159-63.
10. Chen Q, Wang J, Shen M, et al. Tear menisci and ocular discomfort during daily contact lens wear in symptomatic wearers. *Invest Ophthalmol Vis Sci*. 2011;52(5):2175-80.
11. Lievens C, Roberts L, Rayborn E, et al. Lid wiper epitheliopathy: what the OD needs to know. *Rev Optom*. 2020;157(11):62-8.
12. Bennett ES, Henry VA. Preliminary Evaluation. In: *Clinical manual of contact lenses*. 4th ed. Philadelphia: Wolters Kluwer/Lippincott Williams & Wilkins; 2014:9-18.
13. Gann D, Nichols JJ. 2020 report on dry eye diseases. *CL Spectrum*. 2020;35(7):24-31,55.
14. Koh S. Contact lens wear and dry: beyond the known. *Asia Pac J Ophthalmol (Phila)*. 2020;9(6):498-504.



# BUILD UP YOUR TORIC LENS TALENT

For these patients in particular, a one-size-fits-all approach just won't work. Here's how to handle several different kinds of patients in your chair.



BY TIFFANY ANDRZEJEWSKI, OD,  
AND MARSHA MALOOLEY, OD  
CHICAGO

In the United States, around 30% of soft contact lens (CL) fits are toric (most often in tandem with correction of ametropia), while 47% of patients receive a spectacle correction of 0.75 diopters of cylinder (DC) or greater in at least one eye.<sup>1,2</sup> For astigmats, adequately correcting their astigmatism is the priority to provide clear vision.<sup>3</sup> And yet, astigmatism may very well be the most idiosyncratic optical problem we encounter, surpassing myopia, hyperopia and even presbyopia in the uniqueness of how it manifests for each patient. Our approach to correction should be equally patient-specific.

Decisions regarding how best to correct astigmatism with contact lenses, including fitting strategies and lens modalities, are driven by numerous factors. Considerations include total amount of astigmatism, the

amount of refractive vs. corneal astigmatism and cylinder orientation—specifically, with-the-rule (WTR), against-the-rule (ATR) or oblique.

It's also critical to understand each patient's visual demands and goals for lens wear. To reduce chair time, this article will discuss the most appropriate CL designs to address various types of astigmatic correction.

## Case #1: The "Average" Astigmat

A 21-year-old female presents for a CL exam, wearing aspheric monthly replacement soft contact lenses. She is satisfied with the comfort but not her vision, noting that her glasses provide better acuity. She reports difficulty taking notes from the back of her college lecture hall but finds it challenging to wear her glasses due to fogging from mask wear.

### Entering VA with CLs:

OD -2.00DS 20/20-3  
OS -4.00DS 20/25

### Refraction:

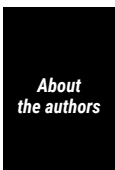
OD -1.75 -0.50x005 20/20  
OS -3.75 -1.00x015 20/20

### Topography Sim Ks:

OD 44.25/44.25@95  
OS 44.50/44.50@90

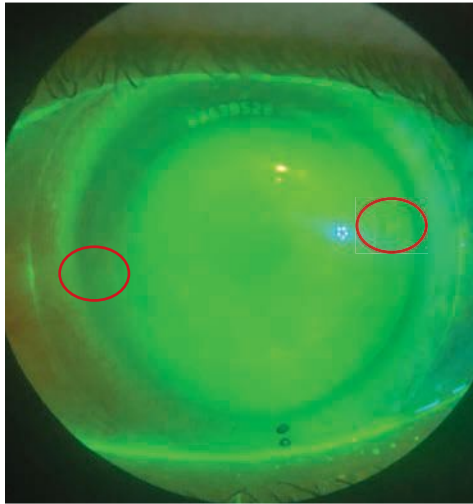
Given this patient's vocational needs, it makes sense to fit her in lenses that will correct her astigmatism.

Spherical and aspheric lenses do not significantly "mask" corneal astigmatism. It was shown that for larger pupils (*i.e.*, over 2mm), aspheric lenses did not provide adequate vision compared to toric CLs even in patients with 0.75 to 1.0DC. High myopes and hyperopes benefit from correction of even small amounts of astigmatism. It's outdated to simply prescribe the spherical equivalent in patients whose refractive cylinder is less than or equal to 1/4th the spherical component of the refraction. It was reported that 71% of patients with astigmatism in the 0.75DC range



**Dr. Andrzejewski** works at Chicago Cornea Consultants with special areas of interest in the management of dry eye, keratoconus and other cornea and contact lens-related issues, as well as scleral contact lenses. She also is an adjunct clinical faculty member of the Illinois College of Optometry and the Chicago College of Optometry. She is a key opinion leader for Synergeyes and on the speakers bureau for Bausch + Lomb Specialty Vision Products.

**Dr. Malooley** is director of optometric services at Chicago Cornea Consultants. She is a Diplomate in the CCLRT section of the American Academy of Optometry with professional focus on specialty contact lenses for keratoconus, irregular cornea and prosthetic patients. She is adjunct faculty at both the Illinois College of Optometry and Chicago College of Optometry. She has no financial interests to disclose.



**Fig. 1.** This scleral has toric haptics. The flat meridian is denoted by hashmarks, which are rotated 15° counterclockwise.

prefer toric correction and that low astigmats benefit from full correction of their astigmatism.<sup>5,6</sup> Comparing K readings to total refractive error is an important step to determine whether to refit into gas permeable (GP) lenses (and what type) vs. a toric soft contact lens.

Mass-produced soft CLs start with -0.75DC, so in deciding whether to proceed with a toric soft lens for her right eye, attention was paid during her refraction Jackson cross-cylinder (JCC) testing. For her right eye, she oscillated between 0.50DC and 0.75DC and in the left between 0.75DC and 1.00DC, indicating she would benefit more from toric correc-

tion in her CLs which matches her chief complaint. By demonstrating monocularly in the phoropter the difference between the full astigmatic correction vs. spherical equivalent, she noted a significant difference in clarity, which also confirms she is sensitive to residual astigmatism (RA).

Since her keratometry readings indicate spherical corneas, her refractive astigmatism is attributed to lenticular astigmatism and spherical GPs may not provide good clarity. We therefore fit her into soft toric CLs.

**Final CL Rx:**

OD 8.6/14.5/-1.50 -0.75x010 20/20  
OS 8.6/14.5/-3.75 -0.75x010 20/20

**Case #2:  
The “Moderate” Astigmat**

A 44-year-old male primarily wears glasses, and occasionally two-week disposable CLs, which he wished to update. His occupation requires him to be in front of the computer more than nine hours a day. Summer is coming and he wants to have contact lenses to wear for sports like baseball and golf but also admits to having bad environmental allergies.

**Refraction:**

OD -0.50 -2.50x105 20/20  
OS -0.50 -2.50x075 20/20

**Topography Sim Ks:**

OD 45.50/44.00@15  
OS 45.75/44.00@165

In this case, refractive astigmatism is significantly greater than corneal astigmatism, and most GP options are likely suboptimal to adequately correct residual astigmatism (RA). A hybrid design GP cannot have the RA incorporated into the CL, as front toric optics don't exist. There isn't enough corneal cylinder for a back or bitoric GP, and a front toric GP can be less comfortable or have problems with stability. In addition, the patient is looking for part-time wear and adaptation to GPs is easier with consistent wear. Sclerals would allow for good stability and incorporation of front surface toricity, but he prefers something low maintenance.

This patient would benefit from the convenience and hypoallergenic nature of daily disposable toric CLs. Since mass-produced contact lenses only come in 10° steps, it is impossible to exactly align the CL axis with the refractive axis. Fortunately, the lenses displayed stable rotation of 5° to 10° to the right OD and 5° to 10° to the left OS, providing better axis alignment and a visually favorable outcome.

**Final CL Rx:**

OD 8.5/14.3/-0.50 -2.25x100 20/20  
OS 8.5/14.3/-0.50 -2.25x080 20/20

**OUR FITTING PROTOCOL FOR SOFT TORIC CONTACT LENSES**

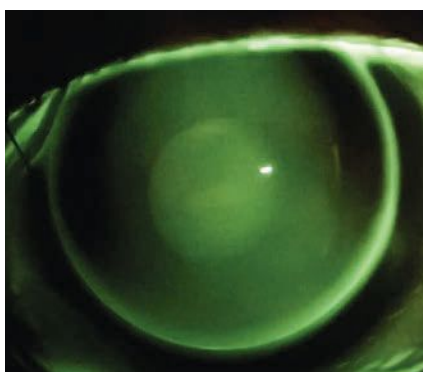
1. When choosing a trial lens, it's always best to prioritize matching the axis, followed by the cylinder amount and sphere power.
2. For the axis, round towards 180 for WTR and 90 for ATR astigmatism. In case #1, we would round to axis 180 OD and 10 OS.
3. When working with the cylinder power that is between options, we generally round down because most rotate ~5° on average and this will decrease visual distortion.<sup>7</sup> When going down on the cylinder power, it's customary to then round up on the sphere to maintain the spherical equivalent power. For example, when fitting the patient in case #1, for OS we would pull -4.00 -0.75x10 from the fitting set, but for the OD, since the only choice we have is to over-correct the cyl at -0.75DC, we would compensate by going down on the sphere power and pull -1.50 -0.75x180).

Lastly, be aware that there may be flexure along the power meridian, depending on the lens design and thickness, and often the patient requires less astigmatism for that reason alone.

4. For patients under the age of 40, round up the sphere when the fitting set only comes in -0.50D steps. For those over 40, round down.
5. For stable axis misalignment due to CL rotation, remember the acronym “LARS”: *Left Add, Right Subtract*. If the lens rotates clockwise, this is considered left rotation and the degree of rotation is added to the spectacle axis. Counterclockwise rotation is right rotation and requires subtracting.

In case #1, the right trial lens rotated 5° left, so we add 5° to the refractive axis to come up with 10°. When the patient applies this 2nd trial lens, it should still only rotate 5° left. We aren't trying to eradicate the rotation itself; instead, we are simply changing the optical orientation of the lens to improve vision. The higher the cyl power and/or the higher the percentage of the Rx that is composed of cyl, the more precision in axis location is needed for good visual acuity; conversely, the more axis misalignment there is, the worse the acuity will be.<sup>8</sup>

Courtesy of John Galles, OD



**Fig. 2.** Evaluation revealed a high-riding, lid-attached fit. There was a dumbbell-shaped fluorescein pattern with pooling in the vertical meridian and bearing in the horizontal indicative of WTRA. This is how a spherical GP looks on a toric cornea.

### Case #3: The Astigmat Who Has “Tried Everything”

A 17-year-old male presents for a contact lens fitting. He’s been seen

at two practices over the last eight months and says that after trying numerous designs, no CLs have been comfortable nor delivered vision as clear as his glasses. He plays varsity baseball and doesn’t like the appearance of sport goggles. After reviewing his previous records, it appears he has tried most of the commercially available soft toric CLs.

**Refraction:**

OD +6.00 -1.50x120 20/20  
OS +6.00 -1.75x064 20/20

**Topography Sim Ks:**

OD 40.98@38/39.60@128 1.38D oblique  
OS 40.89@148/40.15@58 0.74D oblique

The patient has a horizontal visible iris diameter (HVID) of 12.2mm and

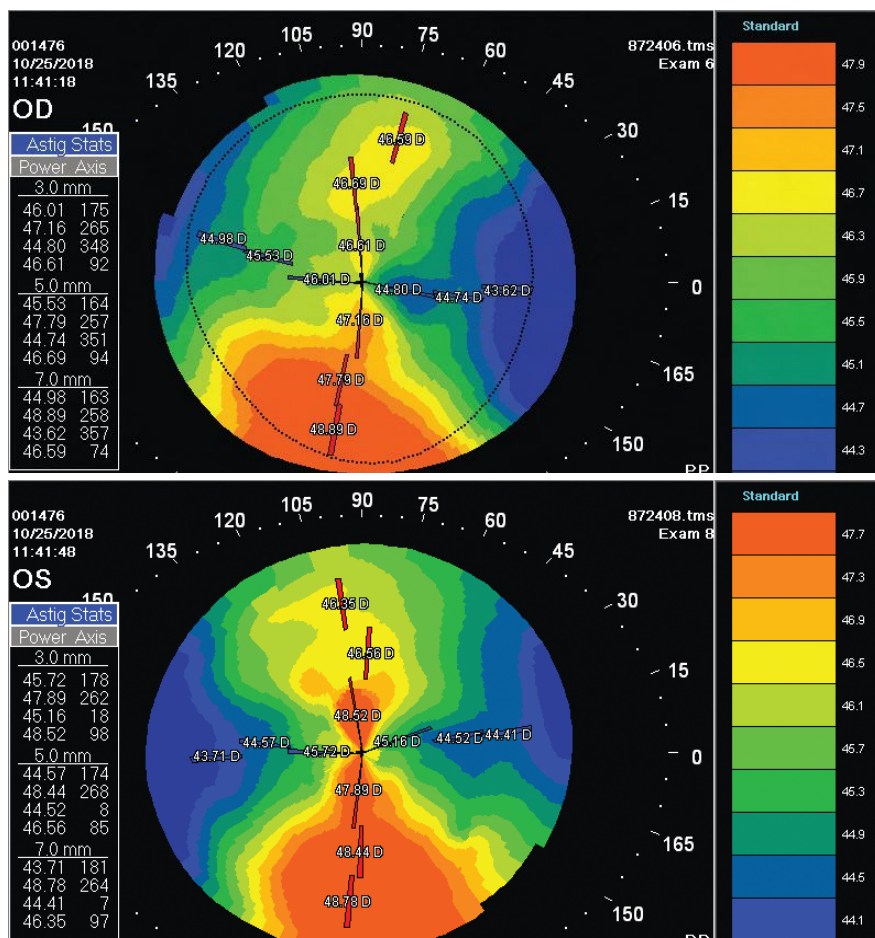
6mm pupils in normal illumination and 7.5mm in dim illumination.

A patient complaining of vision fluctuation with every blink, despite trying multiple brands of toric soft contact lenses, is likely to have an unusual sagittal depth and corneal diameter. To achieve a better, more comfortable fit, match the sagittal depth and diameter of the cornea and the lens. Sagittal depth of the cornea is impacted by HVID, eccentricity, corneal curvature and scleral shape, although HVID has the greatest impact.<sup>10</sup> For the same corneal curvature, the larger the cornea, the greater the sagittal depth and a larger diameter lens will be necessary for stability.

Most commercially available lenses have a diameter that ranges from 13.8mm to 14.5mm and are designed for an average cornea with an HVID between 11.6mm to 12.0mm. However, 50% of patients have an HVID that falls outside this range and may do better with a custom lens. Custom designs can be ordered in nearly any sphere and cylinder powers in 0.1D steps and to 1° axis increments, as well as nearly any diameter and base curve (BC). This comes in handy for the visually discriminative patient and enables practitioners to fit a broad range of corneal curvature and diameter combinations.

This patient has a flatter than average corneal curvature, larger than average HVID (12.2mm), oblique astigmatism and large pupils, all of which contribute to his poor VA with toric lenses. The presence of RA, as well as the goal of wearing the lenses for sports, makes a corneal GP an undesirable choice; a dusty baseball diamond isn’t a good environment for comfortable GP wear. A hybrid design GP is again contraindicated, as front surface toricity is not available. That leaves either a custom soft toric or a scleral lens. A custom soft lens was elected due to his previous familiarity and schedule constraints.

When designing custom soft lenses, clinicians should calculate



**Fig. 3.** Distorted corneal topography because of temporary corneal warpage from a high-riding GP contact lens.





# A NEW WAY TO EXPERIENCE REVIEW OF OPTOMETRY

Follow us on Instagram at @revoptom for striking clinical images, daily news headlines, issue previews and great content from the magazine—all formatted for mobile



**REVIEW OF OPTOMETRY**

NEWS FEED • THE NEWS FEED • THE NEWS FEED • THE NEWS FEED • THE NEWS FEED

**Stories for 3-26-21**

**Missed Neuro Diagnosis Common, Can Lead to Patient Harm**  
Study finds half of all refractive error diagnoses are done in face of strong evidence some kind of adverse lesion on health.

**CDC Aims to Break Down Tangled Bacteria in Oculoma**  
These untreatable eye findings for a two-year investigation into the organism and clinical value of genetic sequencing.

**Thyroid Eye Disease Increases Risk of Optic Nerve Damage**  
A recent eye procedure causing of the eye, but can be reversed. Study indicates the likelihood of depression in unilateral optic neuropathy.

Read today at [www.reviewofoptometry.com/news](http://www.reviewofoptometry.com/news)

**REVIEW OF OPTOMETRY**

High myopia with a tessellated fundus, choroidal neovascularization (CNV) (red line), RPE disruption (gray line), DSI (yellow line), DR (green line) extensive photoreceptor loss (red) with early RPE and hyperreflective material (gray) (red) of choroidal neovascularization.

Choroidal folds causing sub-RPE exudates (red line).

From "Late Manifest OCT in High Myopia" by Lisa Brinkmann, MD available at [www.reviewofoptometry.com/issue/march-19-2021](http://www.reviewofoptometry.com/issue/march-19-2021)

**REVIEW OF OPTOMETRY**

**DRY EYE READER SURVEY RESULTS**

What percent of your patients in each of these categories suffer from dry eye?

Age Group	0%	10%	20%	30%	40%	50%	60%	70%
Adolescents and teens	0	0	0	0	0	0	0	0
Adults 20-49 years old	0	0	0	0	0	0	0	0
Adults 50-69 years old	0	0	0	0	0	0	0	0
Adults 70 and older	0	0	0	0	0	0	0	0
Contact lens wearers	0	0	0	0	0	0	0	0
Men	0	0	0	0	0	0	0	0
Women	0	0	0	0	0	0	0	0
Post-menopausal women	0	0	0	0	0	0	0	0

From "Dry Eye Prevalence Trends, Habits and Longevity" available at [www.reviewofoptometry.com/issue/march-19-2021](http://www.reviewofoptometry.com/issue/march-19-2021)

**REVIEW OF OPTOMETRY**

Reflex associated with a subconjunctival hemorrhage.

From "The Eye Reflexes: How and How and How" by Alan T. Lee, MD and Brian L. Hersh, MD available at [www.reviewofoptometry.com/issue/march-19-2021](http://www.reviewofoptometry.com/issue/march-19-2021)

**REVIEW OF OPTOMETRY**

**CLINICAL FEATURES OF COMMON SECONDARY CONDITIONS ASSOCIATED WITH GLAUCOMA**

CONDITION	CLINICAL FEATURES	OPHTHALMIC FINDINGS
Systemic hypertension	Systemic hypertension, arteriosclerosis, atherosclerosis, stroke, and peripheral vascular disease	Asymmetric optic atrophy, enlargement of the optic cup, and/or optic disc pallor
Diabetes mellitus	Diabetes mellitus, retinopathy, and other systemic complications	Optic atrophy, enlargement of the optic cup, and/or optic disc pallor
Systemic lupus erythematosus	Systemic lupus erythematosus, arthritis, and other systemic complications	Optic atrophy, enlargement of the optic cup, and/or optic disc pallor
Systemic sclerosis	Systemic sclerosis, Raynaud's phenomenon, and other systemic complications	Optic atrophy, enlargement of the optic cup, and/or optic disc pallor
Systemic amyloidosis	Systemic amyloidosis, renal disease, and other systemic complications	Optic atrophy, enlargement of the optic cup, and/or optic disc pallor
Systemic mastocytosis	Systemic mastocytosis, skin lesions, and other systemic complications	Optic atrophy, enlargement of the optic cup, and/or optic disc pallor

From "The Clinical Features of Common Secondary Conditions Associated with Glaucoma" by Alan T. Lee, MD and Brian L. Hersh, MD available at [www.reviewofoptometry.com/issue/march-19-2021](http://www.reviewofoptometry.com/issue/march-19-2021)

**REVIEW OF OPTOMETRY**

**REVIEW OF OPTOMETRY**

From "The Clinical Features of Common Secondary Conditions Associated with Glaucoma" by Alan T. Lee, MD and Brian L. Hersh, MD available at [www.reviewofoptometry.com/issue/march-19-2021](http://www.reviewofoptometry.com/issue/march-19-2021)

**REVIEW OF OPTOMETRY**

**MAR 2021**

**Dry Eye Issue**

AVAILABLE MARCH 19, 2021  
[www.reviewofoptometry.com](http://www.reviewofoptometry.com)

**REVIEW OF OPTOMETRY**

CLINICAL CORRELATION: A 71-year-old female presented with a red eye, a painful eye of the lower lid and eyelid. What do you think is happening and how would you treat it? Post a comment below the discussion and management plan.

From "The Case of the Week" by Paul Hershman, MD available at [www.reviewofoptometry.com/issue/march-19-2021](http://www.reviewofoptometry.com/issue/march-19-2021)

**REVIEW OF OPTOMETRY**

**FAST FACTS ON CLAO**

- only present in approximately one in three people
- provide a secondary blood supply to the inner layers of the macula
- comprises only 3.3% to 7.1% of all retinal artery occlusions
- has been associated with embolism, hypertension, arteriosclerosis, diabetes, pregnancy, and systemic hypertension
- can present in three ways: (1) with ischemic optic neuropathy in giant cell arteritis, (2) with concomitant central retinal vein occlusion or (3) isolation

Management and prognosis

- BCA:** Critical to arrange for some dry eye and eye patching and then IT clinic. Visual prognosis is the worst of the three due to lack of neovascularization.
- OCVD:** Treatment focuses on macular edema and neovascularization. Better prognosis, as the vessels occluded tends to be non-vascular.
- if isolated:** Treatment can include ocular massage, paracentesis, intra-ocular thrombolysis and hyperbaric oxygen. Best visual prognosis.

From "The Case of the Week" by Paul Hershman, MD available at [www.reviewofoptometry.com/issue/march-19-2021](http://www.reviewofoptometry.com/issue/march-19-2021)

**REVIEW OF OPTOMETRY**

Additional studies that might yield diagnostically pertinent data:

- 10- to 15- to 20- to 25- to 30- to 35- to 40- to 45- to 50- to 55- to 60- to 65- to 70- to 75- to 80- to 85- to 90- to 95- to 100- to 105- to 110- to 115- to 120- to 125- to 130- to 135- to 140- to 145- to 150- to 155- to 160- to 165- to 170- to 175- to 180- to 185- to 190- to 195- to 200- to 205- to 210- to 215- to 220- to 225- to 230- to 235- to 240- to 245- to 250- to 255- to 260- to 265- to 270- to 275- to 280- to 285- to 290- to 295- to 300- to 305- to 310- to 315- to 320- to 325- to 330- to 335- to 340- to 345- to 350- to 355- to 360- to 365- to 370- to 375- to 380- to 385- to 390- to 395- to 400- to 405- to 410- to 415- to 420- to 425- to 430- to 435- to 440- to 445- to 450- to 455- to 460- to 465- to 470- to 475- to 480- to 485- to 490- to 495- to 500- to 505- to 510- to 515- to 520- to 525- to 530- to 535- to 540- to 545- to 550- to 555- to 560- to 565- to 570- to 575- to 580- to 585- to 590- to 595- to 600- to 605- to 610- to 615- to 620- to 625- to 630- to 635- to 640- to 645- to 650- to 655- to 660- to 665- to 670- to 675- to 680- to 685- to 690- to 695- to 700- to 705- to 710- to 715- to 720- to 725- to 730- to 735- to 740- to 745- to 750- to 755- to 760- to 765- to 770- to 775- to 780- to 785- to 790- to 795- to 800- to 805- to 810- to 815- to 820- to 825- to 830- to 835- to 840- to 845- to 850- to 855- to 860- to 865- to 870- to 875- to 880- to 885- to 890- to 895- to 900- to 905- to 910- to 915- to 920- to 925- to 930- to 935- to 940- to 945- to 950- to 955- to 960- to 965- to 970- to 975- to 980- to 985- to 990- to 995- to 1000- to 1005- to 1010- to 1015- to 1020- to 1025- to 1030- to 1035- to 1040- to 1045- to 1050- to 1055- to 1060- to 1065- to 1070- to 1075- to 1080- to 1085- to 1090- to 1095- to 1100- to 1105- to 1110- to 1115- to 1120- to 1125- to 1130- to 1135- to 1140- to 1145- to 1150- to 1155- to 1160- to 1165- to 1170- to 1175- to 1180- to 1185- to 1190- to 1195- to 1200- to 1205- to 1210- to 1215- to 1220- to 1225- to 1230- to 1235- to 1240- to 1245- to 1250- to 1255- to 1260- to 1265- to 1270- to 1275- to 1280- to 1285- to 1290- to 1295- to 1300- to 1305- to 1310- to 1315- to 1320- to 1325- to 1330- to 1335- to 1340- to 1345- to 1350- to 1355- to 1360- to 1365- to 1370- to 1375- to 1380- to 1385- to 1390- to 1395- to 1400- to 1405- to 1410- to 1415- to 1420- to 1425- to 1430- to 1435- to 1440- to 1445- to 1450- to 1455- to 1460- to 1465- to 1470- to 1475- to 1480- to 1485- to 1490- to 1495- to 1500- to 1505- to 1510- to 1515- to 1520- to 1525- to 1530- to 1535- to 1540- to 1545- to 1550- to 1555- to 1560- to 1565- to 1570- to 1575- to 1580- to 1585- to 1590- to 1595- to 1600- to 1605- to 1610- to 1615- to 1620- to 1625- to 1630- to 1635- to 1640- to 1645- to 1650- to 1655- to 1660- to 1665- to 1670- to 1675- to 1680- to 1685- to 1690- to 1695- to 1700- to 1705- to 1710- to 1715- to 1720- to 1725- to 1730- to 1735- to 1740- to 1745- to 1750- to 1755- to 1760- to 1765- to 1770- to 1775- to 1780- to 1785- to 1790- to 1795- to 1800- to 1805- to 1810- to 1815- to 1820- to 1825- to 1830- to 1835- to 1840- to 1845- to 1850- to 1855- to 1860- to 1865- to 1870- to 1875- to 1880- to 1885- to 1890- to 1895- to 1900- to 1905- to 1910- to 1915- to 1920- to 1925- to 1930- to 1935- to 1940- to 1945- to 1950- to 1955- to 1960- to 1965- to 1970- to 1975- to 1980- to 1985- to 1990- to 1995- to 2000- to 2005- to 2010- to 2015- to 2020- to 2025- to 2030- to 2035- to 2040- to 2045- to 2050- to 2055- to 2060- to 2065- to 2070- to 2075- to 2080- to 2085- to 2090- to 2095- to 2100- to 2105- to 2110- to 2115- to 2120- to 2125- to 2130- to 2135- to 2140- to 2145- to 2150- to 2155- to 2160- to 2165- to 2170- to 2175- to 2180- to 2185- to 2190- to 2195- to 2200- to 2205- to 2210- to 2215- to 2220- to 2225- to 2230- to 2235- to 2240- to 2245- to 2250- to 2255- to 2260- to 2265- to 2270- to 2275- to 2280- to 2285- to 2290- to 2295- to 2300- to 2305- to 2310- to 2315- to 2320- to 2325- to 2330- to 2335- to 2340- to 2345- to 2350- to 2355- to 2360- to 2365- to 2370- to 2375- to 2380- to 2385- to 2390- to 2395- to 2400- to 2405- to 2410- to 2415- to 2420- to 2425- to 2430- to 2435- to 2440- to 2445- to 2450- to 2455- to 2460- to 2465- to 2470- to 2475- to 2480- to 2485- to 2490- to 2495- to 2500- to 2505- to 2510- to 2515- to 2520- to 2525- to 2530- to 2535- to 2540- to 2545- to 2550- to 2555- to 2560- to 2565- to 2570- to 2575- to 2580- to 2585- to 2590- to 2595- to 2600- to 2605- to 2610- to 2615- to 2620- to 2625- to 2630- to 2635- to 2640- to 2645- to 2650- to 2655- to 2660- to 2665- to 2670- to 2675- to 2680- to 2685- to 2690- to 2695- to 2700- to 2705- to 2710- to 2715- to 2720- to 2725- to 2730- to 2735- to 2740- to 2745- to 2750- to 2755- to 2760- to 2765- to 2770- to 2775- to 2780- to 2785- to 2790- to 2795- to 2800- to 2805- to 2810- to 2815- to 2820- to 2825- to 2830- to 2835- to 2840- to 2845- to 2850- to 2855- to 2860- to 2865- to 2870- to 2875- to 2880- to 2885- to 2890- to 2895- to 2900- to 2905- to 2910- to 2915- to 2920- to 2925- to 2930- to 2935- to 2940- to 2945- to 2950- to 2955- to 2960- to 2965- to 2970- to 2975- to 2980- to 2985- to 2990- to 2995- to 3000- to 3005- to 3010- to 3015- to 3020- to 3025- to 3030- to 3035- to 3040- to 3045- to 3050- to 3055- to 3060- to 3065- to 3070- to 3075- to 3080- to 3085- to 3090- to 3095- to 3100- to 3105- to 3110- to 3115- to 3120- to 3125- to 3130- to 3135- to 3140- to 3145- to 3150- to 3155- to 3160- to 3165- to 3170- to 3175- to 3180- to 3185- to 3190- to 3195- to 3200- to 3205- to 3210- to 3215- to 3220- to 3225- to 3230- to 3235- to 3240- to 3245- to 3250- to 3255- to 3260- to 3265- to 3270- to 3275- to 3280- to 3285- to 3290- to 3295- to 3300- to 3305- to 3310- to 3315- to 3320- to 3325- to 3330- to 3335- to 3340- to 3345- to 3350- to 3355- to 3360- to 3365- to 3370- to 3375- to 3380- to 3385- to 3390- to 3395- to 3400- to 3405- to 3410- to 3415- to 3420- to 3425- to 3430- to 3435- to 3440- to 3445- to 3450- to 3455- to 3460- to 3465- to 3470- to 3475- to 3480- to 3485- to 3490- to 3495- to 3500- to 3505- to 3510- to 3515- to 3520- to 3525- to 3530- to 3535- to 3540- to 3545- to 3550- to 3555- to 3560- to 3565- to 3570- to 3575- to 3580- to 3585- to 3590- to 3595- to 3600- to 3605- to 3610- to 3615- to 3620- to 3625- to 3630- to 3635- to 3640- to 3645- to 3650- to 3655- to 3660- to 3665- to 3670- to 3675- to 3680- to 3685- to 3690- to 3695- to 3700- to 3705- to 3710- to 3715- to 3720- to 3725- to 3730- to 3735- to 3740- to 3745- to 3750- to 3755- to 3760- to 3765- to 3770- to 3775- to 3780- to 3785- to 3790- to 3795- to 3800- to 3805- to 3810- to 3815- to 3820- to 3825- to 3830- to 3835- to 3840- to 3845- to 3850- to 3855- to 3860- to 3865- to 3870- to 3875- to 3880- to 3885- to 3890- to 3895- to 3900- to 3905- to 3910- to 3915- to 3920- to 3925- to 3930- to 3935- to 3940- to 3945- to 3950- to 3955- to 3960- to 3965- to 3970- to 3975- to 3980- to 3985- to 3990- to 3995- to 4000- to 4005- to 4010- to 4015- to 4020- to 4025- to 4030- to 4035- to 4040- to 4045- to 4050- to 4055- to 4060- to 4065- to 4070- to 4075- to 4080- to 4085- to 4090- to 4095- to 4100- to 4105- to 4110- to 4115- to 4120- to 4125- to 4130- to 4135- to 4140- to 4145- to 4150- to 4155- to 4160- to 4165- to 4170- to 4175- to 4180- to 4185- to 4190- to 4195- to 4200- to 4205- to 4210- to 4215- to 4220- to 4225- to 4230- to 4235- to 4240- to 4245- to 4250- to 4255- to 4260- to 4265- to 4270- to 4275- to 4280- to 4285- to 4290- to 4295- to 4300- to 4305- to 4310- to 4315- to 4320- to 4325- to 4330- to 4335- to 4340- to 4345- to 4350- to 4355- to 4360- to 4365- to 4370- to 4375- to 4380- to 4385- to 4390- to 4395- to 4400- to 4405- to 4410- to 4415- to 4420- to 4425- to 4430- to 4435- to 4440- to 4445- to 4450- to 4455- to 4460- to 4465- to 4470- to 4475- to 4480- to 4485- to 4490- to 4495- to 4500- to 4505- to 4510- to 4515- to 4520- to 4525- to 4530- to 4535- to 4540- to 4545- to 4550- to 4555- to 4560- to 4565- to 4570- to 4575- to 4580- to 4585- to 4590- to 4595- to 4600- to 4605- to 4610- to 4615- to 4620- to 4625- to 4630- to 4635- to 4640- to 4645- to 4650- to 4655- to 4660- to 4665- to 4670- to 4675- to 4680- to 4685- to 4690- to 4695- to 4700- to 4705- to 4710- to 4715- to 4720- to 4725- to 4730- to 4735- to 4740- to 4745- to 4750- to 4755- to 4760- to 4765- to 4770- to 4775- to 4780- to 4785- to 4790- to 4795- to 4800- to 4805- to 4810- to 4815- to 4820- to 4825- to 4830- to 4835- to 4840- to 4845- to 4850- to 4855- to 4860- to 4865- to 4870- to 4875- to 4880- to 4885- to 4890- to 4895- to 4900- to 4905- to 4910- to 4915- to 4920- to 4925- to 4930- to 4935- to 4940- to 4945- to 4950- to 4955- to 4960- to 4965- to 4970- to 4975- to 4980- to 4985- to 4990- to 4995- to 5000- to 5005- to 5010- to 5015- to 5020- to 5025- to 5030- to 5035- to 5040- to 5045- to 5050- to 5055- to 5060- to 5065- to 5070- to 5075- to 5080- to 5085- to 5090- to 5095- to 5100- to 5105- to 5110- to 5115- to 5120- to 5125- to 5130- to 5135- to 5140- to 5145- to 5150- to 5155- to 5160- to 5165- to 5170- to 5175- to 5180- to 5185- to 5190- to 5195- to 5200- to 5205- to 5210- to 5215- to 5220- to 5225- to 5230- to 5235- to 5240- to 5245- to 5250- to 5255- to 5260- to 5265- to 5270- to 5275- to 5280- to 5285- to 5290- to 5295- to 5300- to 5305- to 5310- to 5315- to 5320- to 5325- to 5330- to 5335- to 5340- to 5345- to 5350- to 5355- to 5360- to 5365- to 5370- to 5375- to 5380- to 5385- to 5390- to 5395- to 5400- to 5405- to 5410- to 5415- to 5420- to 5425- to 5430- to 5435- to 5440- to 5445- to 5450- to 5455- to 5460- to 5465- to 5470- to 5475- to 5480- to 5485- to 5490- to 5495- to 5500- to 5505- to 5510- to 5515- to 5520- to 5525- to 5530- to 5535- to 5540- to 5545- to 5550- to 5555- to 5560- to 5565- to 5570- to 5575- to 5580- to 5585- to 5590- to 5595- to 5600- to 5605- to 5610- to 5615- to 5620- to 5625- to 5630- to 5635- to 5640- to 5645- to 5650- to 5655- to 5660- to 5665- to 5670- to 5675- to 5680- to 5685- to 5690- to 5695- to 5700- to 5705- to 5710- to 5715- to 5720- to 5725- to 5730- to 5735- to 5740- to 5745- to 5750- to 5755- to 5760- to 5765- to 5770- to 5775- to 5780- to 5785- to 5790- to 5795- to 5800- to 5805- to 5810- to 5815- to 5820- to 5825- to 5830- to 5835- to 5840- to 5845- to 5850- to 5855- to 5860- to 5865- to 5870- to 5875- to 5880- to 5885- to 5890- to 5895- to 5900- to 5905- to 5910- to 5915- to 5920- to 5925- to 5930- to 5935- to 5940- to 5945- to 5950- to 5955- to 5960- to 5965- to 5970- to 5975- to 5980- to 5985- to 5990- to 5995- to 6000- to 6005- to 6010- to 6015- to 6020- to 6025- to 6030- to 6035- to 6040- to 6045- to 6050- to 6055- to 6060- to 6065- to 6070- to 6075- to 6080- to 6085- to 6090- to 6095- to 6100- to 6105- to 6110- to 6115- to 6120- to 6125- to 6130- to 6135- to 6140- to 6145- to 6150- to 6155- to 6160- to 6165- to 6170- to 6175- to 6180- to 6185- to 6190- to 6195- to 6200- to 6205- to 6210- to 6215- to 6220- to 6225- to 6230- to 6235- to 6240- to 6245- to 6250- to 6255- to 6260- to 6265- to 6270- to 6275- to 6280- to 6285- to 6290- to 6295- to 6300- to 6305- to 6310- to 6315- to 6320- to 6325- to 6330- to 6335- to 6340- to 6345- to 6350- to 6355- to 6360- to 6365- to 6370- to 6375- to 6380- to 6385- to 6390- to 6395- to 6400- to 6405- to 6410- to 6415- to 6420- to 6425- to 6430- to 6435- to 6440- to 6445- to 6450- to 6455- to 6460- to 6465- to 6470- to 6475- to 6480- to 6485- to 6490- to 6495- to 6500- to 6505- to 6510- to 6515- to 6520- to 6525- to 6530- to 6535- to 6540- to 6545- to 6550- to 6555- to 6560- to 6565- to 6570- to 6575- to 6580- to 6585- to 6590- to 6595- to 6600- to 6605- to 6610- to 6615- to 6620- to 6625- to 6630- to 6635- to 6640- to 6645- to 6650- to 6655- to 6660- to 6665- to 6670- to 6675- to 6680- to 6685- to 6690- to 6695- to 6700- to 6705- to 6710- to 6715- to 67

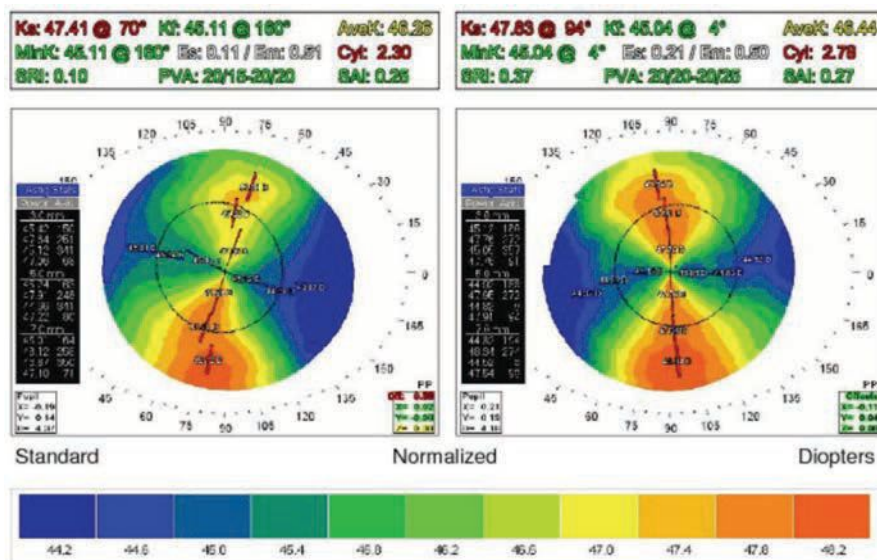


Fig. 4. The topography one week after cessation of CL wear.

the lens diameter using the HVID + 3.0mm formula to ensure better stabilization.<sup>11</sup> At minimum, a 1.5mm overlap on either side of the cornea should be planned for, with 0.5mm to 1.0mm of movement on primary gaze. To enhance on-eye stability, the diameter can be increased or additional prism can be added to the ballasting design of the lens. This adds more weight to the lens to bring and keep the optics in place, which was necessary for this patient’s right eye due to the oblique axis of the astigmatism.

Unique to this case, the optic zone (OZ) needs to be made larger to accommodate his large pupil size. An increase of the OZ by 1mm resolved his complaint of glare and haloes in dim illumination.

When vision is less than adequate, it’s most efficient to check the fit first before doing an over-refraction. A poorly fitting or excessively rotating lens will diminish vision and cause an over-refraction to be variable and unreliable. First, perform spherical over-refractions, but if they don’t produce a visually significant improvement, perform a sphero-cylindrical over-refraction (SCOR). A cross-cylinder calculation to determine the new lens power can be obtained using a website, app, or lab consultation.

**Final CL Rx:**

OD 8.6/15.4/+7.00 -1.75x120/9.5  
 OZ/1.3 BD prism for stabilization  
 OS 8.8/15.2/+6.50 -2.00x74/9.5 OZ/1.0  
 BD prism for stabilization

**Case #4: The Astigmat with Fluctuating Vision**

A 15-year-old female presents for a contact lens evaluation and fit. She has noticed her vision fluctuating while playing tennis on her high school team. In addition, she feels her overall vision is sharper in her glasses than with contact lenses. The mother is concerned, as the patient will be learning to drive soon. She has been wearing quarterly replacement soft toric lenses the past two years after initially trying corneal GPs but struggling with comfort. The patient has a shy demeanor and is clearly worried about her vision.

**Entering VA (CLs):**

OD 20/30  
 OS 20/40

**Refraction:**

OD +4.25 -1.75x005 20/20  
 OS +5.25 -2.00x178 20/25

**Topography Sim Ks:**

OD 43.17@101/41.04@11 2.13D WTRA  
 OS 43.08@82/40.82@172 2.26D WTRA

The patient has an HVID of 11.3mm and smaller fissures. She would benefit from a CL design that would provide consistent visual correction independent of lens rotation or movement. Her refractive astigmatism and corneal astigmatism are similar in both amount and orientation, and with both measuring  $\leq 2.50D$ , she has a wide array of options. Since corneal GPs, sclerals and hybrid lenses all rely on the tear layer to correct astigmatism, they can correct her refractive error without inducing blur with lens movement.

Due to her past failure with corneal GPs and her smaller palpebral fissure width, she was refit into hybrid lenses. Hybrids are a standard 14.5mm diameter like that of mass produced soft toric CLs vs. sclerals, which are often larger and can be more cumbersome for handling, contributing to lower patient success.<sup>12</sup> In addition, since the application/removal process and care regimen of hybrids is like that of soft CLs, they provide minimal disruption for a habitual soft CL wearer and can be a natural transition for those patients hesitant to try something new but dissatisfied with their current lens modality.

**Final CL Rx**

OD 8.0/14.5/med/+4.00sph 20/20  
 OS 7.9/14.5/med/+4.50sph 20/25

Understanding the personality of the patient in addition to her refractive needs can help in finding the most suitable CL design. Most hybrid lenses can be empirically ordered, allowing patients a positive visual experience with their initial application. Studies have shown hybrid lenses are a good option for patients with moderate to higher amounts of regular astigmatism (provided there’s minimal residual astigmatism), and some patients experience better VA and contrast sensitivity and less glare compared to with soft toric CLs.<sup>1,13</sup> In cases when the refractive astigmatism and corneal astigmatism are similar, but

the patient is GP intolerant, hybrid contacts lenses are an excellent option to deliver stable, clear vision.

### **Case #5: The New Wearer with High Astigmatism**

A 14-year-old female, accompanied by her dad, has been referred for a CL fitting by her pediatric ophthalmologist. She is a high school freshman with no previous contact lens history but has worn glasses since age five. Her dad inquires about hybrid CLs, and her mom wears corneal GPs.

#### **Refraction:**

OD +0.75 -4.50x002 20/20  
OS +0.75 -4.25x170 20/20

#### **Topography Sim Ks:**

OD 44.51@94/40.37@004 4.14D  
WTRA  
OS 45.05 @80/40.76@170 4.29D  
WTRA

It was evident during the refraction that the patient is sensitive to small cylinder power and axis adjustments. The high amount of refractive WTR astigmatism aligned with the measurements from corneal topography. As for the option of hybrid CLs, flexure was a concern given the amount of corneal astigmatism. A contact lens design with a toric back surface would provide a horse/saddle type fit, better aligning to the overall toric corneal shape. GP lenses were recommended with a discussion involving adaptation and highlighting all their benefits. It has been shown the manner in which GP contact lens options are presented has an impact on success of new GP wearers.<sup>15</sup>

#### **The patient was empirically fit in bitoric GPs:**

OD 8.44/7.75/+1.00/-2.75/10.0  
OS 8.33/7.67/+1.00/-2.50/10.0

Tangible Hydra-PEG coating can be added to the lenses to improve initial comfort and wettability, potentially assisting with adaptation for

novice lens wearers, as in this case.<sup>1</sup> The patient found insertion, removal and handling of the contact lenses easy. Empirical fitting of toric GPs is successful for patients with moderate to severe astigmatism.<sup>17</sup> Using online fitting calculators, methods such as Mandell-Moore or laboratory consultants can aid in determining parameters, saving chair time. Although this patient ultimately required one minor adjustment to her left CL, the initial GPs ordered fit well, provided good vision and were dispensed, starting the patient down the path of lens adaptation.

### **Case #6: The High Astigmat with Anisometropia**

A 30-year-old female grad student with a history of amblyopia OS is referred for a contact lens fit for her left eye. She presents wearing glasses, but says she suffers frequent headaches during wear. She was able to successfully wear a two-week replacement soft toric lens on her right eye but was unsuccessful OS with a custom soft toric, a bitoric GP and piggybacking of the bitoric GP.

#### **Entering VAs (SRx):**

OD 20/30-2  
OS 20/50

#### **Refraction:**

OD -4.50 -3.00x180 20/25-2  
OS +1.25 -7.25x174 20/40  
HVID=11.7

#### **Topography Sim Ks:**

OD 45.95@90/42.85@180 3.1D  
WTRA  
OS 48.00@86/42.25@176 5.75D  
WTRA

Sclerals are her final remaining option, but 1.00D of residual astigmatism is still expected because she has 6.75D of refractive astigmatism (after vertexing) and only 5.75D WTR corneal astigmatism. However, unlike hybrid lenses, sclerals can correct residual lenticular astigmatism and there's no limit on how much corneal

toricity can be corrected, since they vault the cornea. A scleral lens will provide her with good comfort and consistent vision.

The rotational stability of scleral lenses allows for reliable incorporation of front-surface toricity. Front toric optics can be incorporated into scleral lenses one of two ways: (1) prism ballasting by the same mechanism as corneal GP lenses or (2) using toric haptics for scleral alignment, as some degree of scleral toricity or asymmetry exists approximately in 94% of the population.<sup>1</sup> Her corneal and scleral toricities are highly correlated, requiring not only a toric haptic but also toric limbal curves to improve scleral lens centration and alignment.<sup>19,20</sup>

Using a diagnostic fitting set that has toric haptics, the front toric optics could be ordered on the very first lens. This is done by taking note of the exact axis position of the laser markings indicating the flat meridian after the lens has settled on the eye for 20 minutes and performing a SCOR.

To determine a cylinder axis to compensate for any misalignment of the toric haptic, subtract the axis location of the flat meridian from the over-refraction axis. If the resulting value is positive, that is the correct cylinder axis to order; if negative, subtract that number from 180 to find which axis to order. For example, the toric hash marks were positioned at axis 15 (*Figure 1*), the SCOR over the -2.00DS diagnostic lens was +2.50 -1.00x175. Since  $175-15=160$ , the final power should be +0.50 -1.00x160.

Similar to soft toric CLs, the axis of the toric haptics should always rotate into the same position, just like the toric marking of a soft lens after using LARS to compensate for lens rotation.

#### **Final CL Rx:**

OD 8.6/14.5/-4.50-2.25x180 20/25+2  
OS 8.05/16.0/PL -1.00x160/4.65  
sag/+150 x -150 limbal clearance/  
flat 11 x steep 10 20/40+2



### Case #7: The Astigmat with Spectacle Blur

A new patient, a 53-year-old female, presents wearing corneal GP lenses dispensed a year ago. She complains of worse vision with glasses after removing her lenses. She also feels her acuity with monovision spherical GPs is not as good as it was in the past. Despite wearing her driving glasses over her CLs to enhance her distance vision, she still experiences halos and glare driving at night.

#### Entering VAs (CLs):

OD 20/25 (fuzzy), J12  
OS 20/200, J1

#### Over-refraction:

OD Plano 20/25  
OS -2.00 -0.50x170 20/25

Topography taken over the contact lenses was spherical OD but revealed 0.48D of cylinder OS. Contact lens verification revealed a single base curve and power with no warpage. Refraction and topography were performed after lens removal.

#### Refraction:

OD -3.00 -1.50x010 add +2.50  
20/25, J1  
OS -5.25 -2.50x175 add +2.50  
20/25, J1

#### Topography Sim Ks:

OD 46.90@94/45.48@4 1+ distortion  
OS 47.76@94/45.05@7 1+ distortion

The corneal topography was consistent with corneal warpage from a high-riding GP lens (*Figure 3*). In addition, the cylinder found on over-refraction and topography measurements taken over the left GP indicated the presence of lens flexure.

A one-week CL holiday was advised after which the patient returned for new measurements. Upon follow-up, an increase in both refractive and corneal astigmatism resulted in improved BCVA and corneal irregularity (*Figure 4*).

#### Refraction:

OD -2.50 -2.75x015 add  
+2.50 20/20, J1+  
OS -4.00 -3.00x165 add  
+2.50 20/20, J1+

#### Topography Sim Ks :

OD 47.41@70/45.11@160  
MCAR  
OS 47.83@94/45.04@004  
MCAR

The patient can be refit into bitoric GPs to improve centration and overall vision, including night driving (*Figure 5*). In this case, the superior lens decentration affected her corneal shape, manifesting as decreased vision quality and spectacle blur.

The position of a GP lens plays an important role in inducing corneal warpage, with a high-riding GP lens producing flattening superiorly and steepening inferiorly.<sup>21</sup> The left eye also had RA due to the spherical GP bending or “flexing” due to the high-riding position and the suboptimal fitting relationship of the spherical GP on a toric cornea.

Refitting this patient into a back-surface toric lens that more closely matched the corneal shape improved centration and comfort, eliminated lens flexure (resulting in less flare and no spectacle blur) and improved VA both with the lens on and post-removal. Other common options for addressing flexure include increasing lens thickness or using a stiffer material. The most comprehensive solution to correct both corneal warpage and lens flexure is to fit a GP with a toric back surface when indicated.

### Case #8: The Post-Cataract Astigmat with a Toric IOL Implant

A 65-year-old female presents for contact lens fitting after having cataract surgery OU. She was previously a highly myopic astigmat and now wears corneal GPs for 15 to 20 hours a week for distance correction and will wear readers over. She finds GPs to be

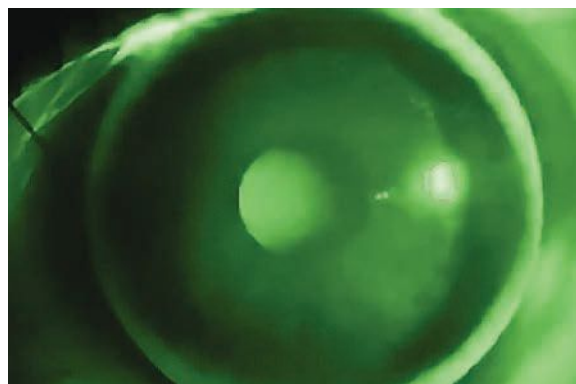


Fig. 5. A well fit bitoric GP on a toric cornea will have an alignment fluorescein pattern comparable to a spherical GP.

uncomfortable and is eager to remove them after just a few hours. She previously elected to be corrected for near during cataract surgery and had a toric IOL implanted in her OD and a monofocal IOL with limbal relaxing incisions in her left eye.

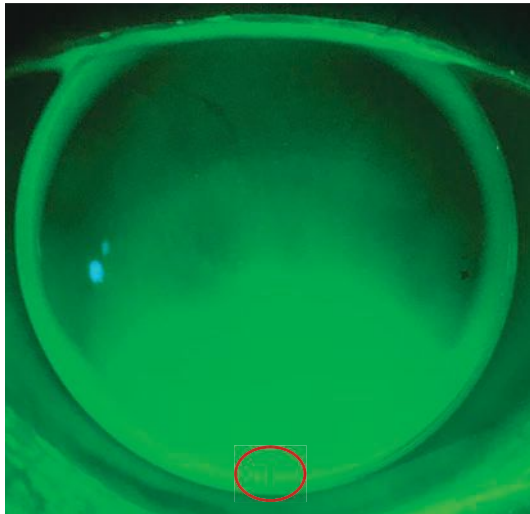
#### Refraction:

OD -2.75 -0.75x160 add +2.50  
20/20, J1+  
OS -2.00 -1.50x165 add +2.50  
20/20, J1+

#### Topography Sim Ks:

OD 46.48@98/44.30@008 2.18D  
WTRA  
OS 46.20@82/46.68@172 1.52D  
WTRA

A soft toric CL makes the most sense, given the patient’s goal of part-time wear, desire for better comfort and self-reported history of GP intolerance with modest refractive astigmatism. But due to her familiarity with corneal GPs, the patient was unwilling to try a soft lens. Ordinarily, with the refractive cyl being less than or equal to the corneal cyl and  $\leq 2.50D$ , this patient would’ve been a good corneal GP candidate; however, the refractive and corneal cylinder no longer match due to internal astigmatism created by the toric IOL. The only option available to adequately correct her vision and meet her needs would be a front-toric GP OD, while the OS is a perfect candidate for a spherical GP.



**Fig. 6.** This front toric GP shows no rotation with the marking located at 6:00.

Although GPs can be designed empirically, it's difficult to know just how much RA from the toric IOL exists without a series of complex calculations vertexing the IOL to the corneal plane. Two possible clinical approaches are to: (1) empirically order a spherical GP based on the Ks and refraction, perform a sphero-cylindrical over-refraction once the lens arrives and reorder the lens with the correct amount and location of toricity, or (2) apply a diagnostic spherical GP and over-refract before ordering.

The patient was informed that she will notice that the right lens “feels” different than her left and that the vision in her right eye may fluctuate with blinking due to the rotational forces generated by her eyelids when blinking. She was also reminded she could reconsider a soft lens if symptoms aren't able to be minimized.

Taking time to discuss appropriate expectations assists in building a better doctor-patient relationship. Patients will have more awareness with front-toric GPs in the beginning because the majority incorporate a prism ballast design for stabilization. This adds weight to the lens and can cause some decentration. Typically, 0.75D prism to 1D is recommended for moderate to high minus lenses and 1.25D to 1.5D for low minus and plus lenses.<sup>22</sup>

The patient did notice some initial awareness differences, which resolved within a week. As expected, the initial right lens did exhibit some rotation but was stable and had a SCOR. By using the same guidelines for soft lenses, the power was adjusted using a cross-cylinder calculator. The patient successfully achieved stable 20/20 vision.

When ordering a front toric GP, it's important that you request the base of the prism be marked to help evaluate the fit (*Figure 6*). Occasionally, a patient's lid forces and anatomy may result in rotational instability even with an adequate amount of prism ballasting. In these cases, prescribing a truncated design can help. When all else fails, if the patient has tight lids or a forceful blink, prescribing a pair of glasses over the CLs is another alternative and works especially well for presbyopes, who can incorporate it as a progressive or bifocal for optimal correction at all distances.

#### **Final CL Rx:**

OD 7.60/9.2/-2.00-1.50x110/1.5D  
prism 20/20  
OS 7.50/9.2/-2.75D 20/20

#### **Takeaways**

There really has never been a better time to be a contact lens wearer who has astigmatism. As clinicians, we have so many options to choose from; it would be a shame not to give our patients the crispest vision possible. Keys to success include listening to the patient, assessing their visual needs and lifestyle and carefully comparing the refractive and corneal astigmatism. Considering all of these factors will help in devising an individualized solution that best address the patient's contact lens needs. Keep in mind that the common 0.75D cut-off of residual astigmatism isn't a hard and fast rule.

**Why settle for adequate? Show your patients the difference that full astigmatism correction can make today, and they will appreciate it. ■**

- Nichols J, Fisher D. Contact lenses. *Cont Lens Spectrum*. 2020;36(1): 24-9; 51.
- Young G, Sulley A, Hunt C. Prevalence of astigmatism in relation to soft contact lens fitting. *Eye Contact Lens*. 2011;37(1):20-5.
- Stephanie MC, Berntsen DA, Bickle KM, et al. Efficacy of toric contact lenses in fitting and patient-reported outcomes in contact lens wearers. *Eye and Contact Lens*. 2018;44:S296-9.
- Morgan P, Efron S, Efron N, Hill E. Inefficacy of aspheric soft contact lenses for the correction of low levels of astigmatism. *Optom Vision Sci*. 2005;82(9): 823-8.
- Dabkowski JA, Roach MP, Begley CG. Soft toric vs. spherical contact lenses in myopes with low astigmatism. *Int Contact Lens Clin*. 1992;19(11):252-6.
- Richdale K, Berntsen D, Mack C, Merchea M, Barr J. Visual acuity with spherical and toric soft contact lenses in low- to moderate astigmatic eyes. *Optom Vision Sci*. 2007; 84(10): 969-75.
- Momeni-Moghaddam H, Naroo SA, Askarizadeh F, Tahmasebi F. Comparison of fitting stability of the different soft toric contact lenses. *Cont Lens Anterior Eye*. 2014;37(5):346-50.
- Myers RI, Jones DH, Meinell P. Using overrefraction for problem solving in soft toric fitting. *Cont Lens Anterior Eye*. 1990;17(9):232-5.
- Caroline PJ, André MP. The effect of corneal diameter on soft lens fitting, part 1. *Cont Lens Spectrum*. 2002;17(4):56.
- Young, Graeme. Ocular sagittal height and soft contact lens fit. *J Br Cont Lens Assoc*. 1992;15(1): 45-9.
- Davis R, Becherer D. Techniques for improved soft lens fitting. *Cont Lens Spectrum*. 2005;20(8). Available at: <https://www.clspectrum.com/issues/2005/august-2005/techniques-for-improved-soft-lens-fitting>. Accessed June 5, 2021.
- Rute J, Macedo-de-Araújo, Eef van der Worp, José M. González-Méjome. A one-year prospective study on scleral lens wear success. *Contact Lens Ant Eye*. 2020; 43(6): 553-61.
- Abou Samra WA, El-Emam DS, Kasem MA. Clinical performance of a spherical hybrid lens design in high regular astigmatism. *Eye Contact Lens*. 2018;44(9):S66-S70.
- Lipson M, Musch D. Synergeyes versus soft toric lenses: vision-related quality of life. *Optom Vis Sci*. 2007; 84 (7): 593-7.
- Bennett E, Et Al. Effect of patient personality profile and verbal presentation on successful rigid contact lens adaptation, satisfaction and compliance. *Optom Vis Sci*. 1998;75(7):500-505.
- Sindt CW. Tangible Hydra-PEG: A novel custom contact lens coating technology designed to improve patient comfort and satisfaction. *Whitepaper*. [Google Scholar]. 2016.
- Michaud L, Barriault C, Dionne A, Karwatsky P. Empirical fitting of soft or rigid gas-permeable contact lenses for the correction of moderate to severe refractive astigmatism: a comparative study. *J Am Optom Assoc*. 2009;80(7):375-83.
- DeNaeyer G, Sanders D, van der Worp E, et al. Qualitative assessment of scleral shape patterns using a new wide field ocular surface elevation topographer. *J Contact Lens Res Sci*. 2017;1(1):12-22.
- Macedo-de-Araújo RJ, Amorim-de-Sousa A, Queiros A, et al. Relationship of placido corneal topography data with scleral lens fitting parameters. *Cont Lens Ant Eye*. 2019;42(2):20-27.
- Consejo A, Rozema JJ. Scleral shape and its correlations with corneal astigmatism. *Cornea*. 2018;37(8):1047-52.
- Wilson SE, Lin DT, Klyce SD, et al. Rigid contact lens decentration: a risk factor for corneal warpage. *CLAO J*. 1990;16:177-82.
- Borish IM. *Vision correction with contact lenses*. Clinical Refraction. 3rd ed. Chicago: Professional Press: 1970:971-1005.

# THE COMING RISE OF DRUG-DELIVERY CONTACT LENSES

This novel new system could mark a significant advancement for eye care.



BY MELISSA BARNETT, OD  
SACRAMENTO, CA

The use of contact lenses as ocular drug delivery systems was first introduced as an idea decades ago. As contact lenses have advanced, the once-futuristic thought of drug-delivery contact lenses is now becoming a reality. This article discusses how improvements in contact lenses have helped pave the way for a new wave of drug delivery systems.

## Background

We are well aware that visual impairment and ocular disease are highly prevalent worldwide and can be debilitating. According to the National Eye Institute, the estimated number of people affected by the most common eye diseases will double between 2010 and 2050.<sup>1</sup> These conditions include diabetic retinopathy, glaucoma, age-related macular degeneration and cataracts. Modern treatment modalities for ocular disease range from conventional liquid eye drops and ocular medications to invasive injections in

the vitreous and surgical procedures to the removal of damaged areas and implant devices.<sup>2,4</sup>

Eye drops have traditionally been the standard method for delivering medications to the eye. Unfortunately, a major disadvantage with eye drops is their low bioavailability of less than 5%.<sup>5</sup> That's not all. A landmark review illustrated that eye drops are associated with a pulsatile delivery, with a wide range of tissue concentrations.<sup>6</sup> This variability is undesirable, particularly in the case of chronic treatment of glaucoma with molecules of short duration of action. Eye drops for long-term use come with the same risk associated with any chronic patient-administered medication, requiring treatment adherence.

With respect to the application of drops, patient adherence to therapy is impacted by a variety of issues, including drug cost, accessibility, availability, regimen, convenience, iatrogenic discomfort or irritation, dropper tip contamination and side effects.<sup>7</sup> At times, poor communication or understanding of why the medication is recommended is the culprit of nonadher-



These mainstays of drug delivery can make drop instillation challenging for patients.

ence.<sup>8</sup> Equally as important is proper instillation of eye drops, which is only correctly performed by a smaller subset of patients.<sup>9-11</sup> Systemic disease such as advanced rheumatoid arthritis, poor dexterity, tremor, reduced grip strength, loss or deformity of digits and poor aim may make eye drop instillation difficult and bring about product waste.

Eye drops tend to have excessive volume since one dose is usually 20µL to 50µL, larger than the precorneal

### About the author

**Dr. Barnett** is a principal optometrist at the University of California, Davis Eye Center in Sacramento and Davis, CA. She is chair of the American Optometric Association Contact Lens and Cornea Section, a fellow of the American Academy of Optometry, a diplomate of the American Board of Certification in Medical Optometry, a fellow and global ambassador of the British Contact Lens Association and a board member of both the Gas Permeable Lens Institute and the International Society of Contact Lens Specialists. Dr. Barnett is a consultant for Johnson & Johnson.



space of approximately 7 $\mu$ L.<sup>12</sup> Typically, approximately only 1% to 5% of applied drug is absorbed into the eye.<sup>13</sup> Ocular drug delivery systems are designed to overcome the limitations of eye drops in various ways, including extended residence time, decreased pulsatile delivery, controlled delivery and enhanced local delivery to the posterior segment.

The application of scleral lenses as drug delivery devices has been illustrated with the advantage of a large fluid reservoir. Scleral lenses provide a protected environment in which the corneal surface is continuously bathed in preservative-free fluid. These lenses are inherently stable to provide lasting ocular penetration of a drug. The main detriments of scleral lenses include handling and cost.<sup>14</sup>

Various publications have reported the use of scleral lenses as ocular drug delivery systems. Specifically, corneal infiltrates have been treated with topical fortified preservative-free antibiotics in the bowl of the lens.<sup>15</sup> Preservative-free antibiotics in the bowl of a continuously worn scleral lens have helped treat persistent epithelial defects.<sup>16</sup> Anti-VEGF agents have been used in the bowl of a scleral lens to treat corneal neovascularization.<sup>17,18</sup> In addition, stem cells on a scleral lens carrier have been used in the management of chemical burns in an animal model.<sup>19</sup>

## Design Methodology

There are a number of different methodologies that can be used to develop therapeutic contact lenses, each with their own advantages and disadvantages.

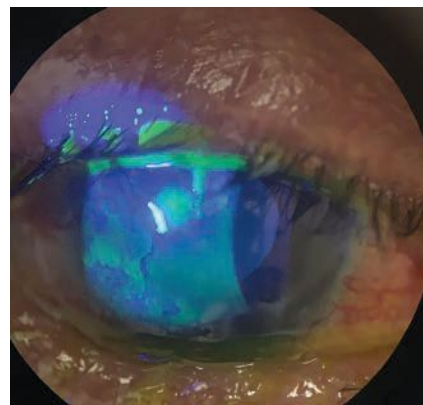
**Soaking method.** This simple, cost-effective approach involves soaking the contact lenses in a drug solution, which is then followed by drug uptake and release in the pre- and post-lens tear film.<sup>20</sup> There are several factors that impact the drug reservoir's ability, including water content, lens thickness, molecular weight of the drug, soaking time and the concentration of drug in the soaking solution.

Significant research has been conducted in this area. One study, which explored the uptake and release of timolol maleate and brimonidine tartrate using the soaking method, found that this drug delivery system may be a feasible method to control intraocular pressure (IOP) among glaucoma patients.<sup>21</sup> The researchers found that 30 minutes of wear time per day for two weeks led to a reduction in IOP. This treatment corresponds to a 10x lower dose of eye drops.

There are limitations to this approach that must also be considered. Research has shown that drugs or polymers of a high molecular weight—such as hyaluronic acid—do not penetrate the aqueous channels of contact lenses. As a result, this approach has not proven effective for the treatment of dry eye.<sup>20</sup> Another challenge is the low affinity that contact lenses have demonstrated for the majority of ophthalmic drugs such as timolol maleate, olopatadine hydrochloric acid and brimonidine tartrate. Lenses retain these drugs poorly and release them quickly, followed by a sharp decline.

**Molecular imprinting.** This technique, which uses hydrogel contact lenses, combines the drug with functional monomers that rearrange and interact with drug molecules. Following polymerization, the drug is removed from the contact lens, resulting in macromolecular memory sites with high drug affinity and increased drug loading capacity.<sup>20</sup> The drug release pattern can be tailored based on the monomer composition. While this approach has promise, there are limits to its use. The highly crosslinked structure of the hydrogel impacts both the optical and physical performance of the contact lens. Extended wear is also limited due to insufficient ion and oxygen permeability caused by a decrease in water content.<sup>20</sup>

**Colloidal nanoparticle-laden lenses.** This method creates nanoparticle-loaded contact lenses that can deliver drugs at a controlled rate over an extended period of time. Using various colloidal nanoparticles, researchers

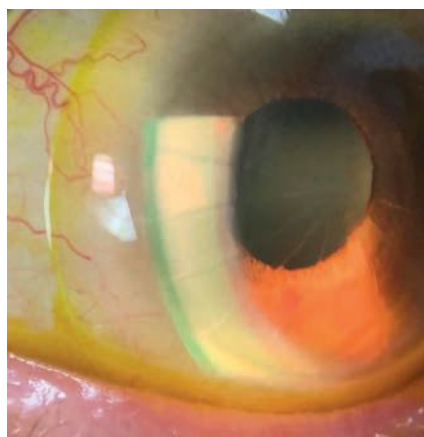


**Antibiotics in the bowl of a scleral could help heal persistent epithelial defects and neurotrophic keratitis, as seen in this eye.**

have developed therapeutic contact lenses that not only offer extended drug delivery but also comfortability.<sup>20</sup> For example, various efforts have been focused on polymeric nanoparticles. One research team looking at treatment for glaucoma incorporated timolol-loaded propoxylated glyceryl triacylate nanoparticles in contact lenses. The *in vitro* release profile showed that the drug was present for one month.<sup>22</sup> Additionally, animal studies demonstrated a reduction in IOP.<sup>23</sup> However, a reduction in ion and oxygen permeability as well as an increase in storage modulus was also observed.

Cyclodextrins have been used to achieve continued delivery of hydrophobic agents. Data from an animal study demonstrated an increase in drug residence time. The researchers also observed a higher concentration of the drug in the tear fluid and vitreous humor when compared with conventional hydrogel lenses and eye drops.<sup>24</sup>

Liposomes, which are biocompatible and biodegradable, have a variety of drug delivery applications, and extensive research has been done to better understand their potential for therapeutic contact lenses. In one study, researchers encapsulated lidocaine-loaded dimyristoyl phosphatidylcholine liposomes in a contact lens and found that lidocaine is released for approximately eight days.<sup>20</sup> Other data found that hydrogel lenses with two layers of liposomes released the drug



**A sclera with sodium fluorescein on an eye with radial keratectomy, *Acanthamoeba* keratitis and neovascularization.**

for up to 30 hours. Comparatively, 10 layers demonstrated drug release for as many as 120 hours.<sup>25</sup> It is important to note that, while these results have potential, multilayer liposomes decreased the oxygen and carbon dioxide permeability of the contact lenses.

Another promising avenue of study involves microemulsion and micelles, which have potential due to their thermodynamic stability, high drug-loading capacity, increased wettability and ability to easily tailor the drug release pattern.<sup>20</sup>

**Use of vitamin E.** To address some of the limitations associated with drug-eluting contact lenses, the role of vitamin E is under investigation. In addition to being biocompatible, vitamin E is hydrophobic and exhibits low water solubility. And so, it has been used to slow down the rate at which a drug is released.<sup>26</sup>

One study showed that the release of timolol was significantly extended by increasing vitamin E loading; however, it also posed a challenge to oxygen and ion permeability.<sup>20</sup> Another team of researchers created dexamethasone contact lenses with 30% vitamin E loading, which extended the drug-release duration for nine days.<sup>27</sup>

While the addition of vitamin E holds promise as a means to slow the release of several hydrophilic agents, it has its own limitations that must be taken into consideration. These include a reduction in ion and oxygen

permeability and an increase in storage module and protein adsorption due to its hydrophobic properties.<sup>20</sup>

### New and Future Developments

With ongoing research and a growing understanding of the potential clinical applications, advancements in contact lens drug delivery systems continue. Recently, the first lens for drug delivery was approved in Japan and Canada. Called Acuvue Theravision with Ketotifen (Johnson & Johnson Vision), it is a daily disposable lens for patients who experience itchy eyes due to allergic conjunctivitis.<sup>28</sup> FDA trials of the lens are ongoing.

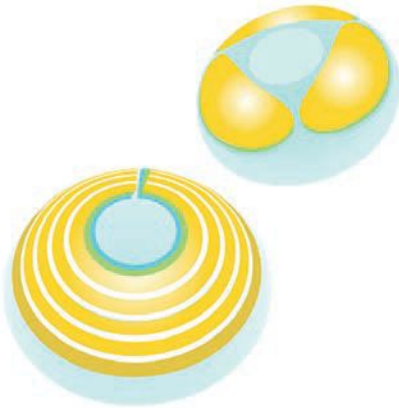
Up to 20% of the US population experiences ocular allergies. Globally, the prevalence is similar. Results from two Phase III trials evaluated the antihistamine-releasing contact lens (etafilcon A with 0.019mg ketotifen) demonstrated that patients who wore the lenses had lower mean itching scores following exposure to allergens compared with those wearing non-medicated lenses.<sup>29</sup> In clinical trials, itching was prevented for up to 12 hours.<sup>30</sup> The approval of this novel contact lens delivery system is a significant advancement, highlighting the potential to simultaneously correct vision and provide therapeutic interventions for contact lens wearers.

Another promising development in contact lens drug delivery is the SIGHT (Sustained Innovative Glaucoma and Ocular Hypertension Treatment) clinical program, which seeks to treat mild to moderate glaucoma and ocular hypertension. The Phase IIa SIGHT-1 trial evaluated LLT-BMT1 (MediPrint Ophthalmics), a drug-eluting lens for glaucoma treatment that uses the FDA-approved drug bimatoprost.<sup>31</sup> This process allows for the printing of drug and barrier layers on the lens surface to control the diffusion release kinetics of drugs. Five patients underwent treatment wearing an LLT-BMT1 lens in each eye for seven days continuously. Study participants were neophyte contact lens wearers with an average age of 77.4.

The study demonstrated strong safety signals with 100% tolerability and no significant adverse events. The researchers also found that the incidence of hyperemia among study participants was lower than what is observed for bimatoprost drops—a standard of care approach for this condition.<sup>31</sup> The SIGHT-1 data also indicated that a single dose has efficacy, which led to the initiation of SIGHT-2, a larger Phase IIb study. There are also plans for a Phase III study to further explore the potential of this treatment approach.

Researchers are also exploring latanoprost-eluting contact lenses as a means to lower IOP in glaucoma patients. Preclinical data has shown that continued delivery of latanoprost via contact lenses is at least as effective as daily latanoprost ophthalmic solution.<sup>32</sup> This efficacy study of glaucomatous monkeys evaluated latanoprost-eluting low- and high-dose contact lenses. The researchers reported that latanoprost ophthalmic solution led to an IOP reduction of 5.4±1.0mm Hg on day three and a peak IOP reduction of 6.6±1.3mm Hg on day five. Comparatively, latanoprost-eluting low-dose contact lenses lowered IOP by 6.3±1.0mm Hg, 6.7±0.3mm Hg and 6.7±0.3mm Hg on days three, five and eight, respectively. The high-dose lenses reduced IOP by 10.5±1.4mm Hg (day three), 11.1±4.0mm Hg (day five) and 10.0±2.5mm Hg (day eight).<sup>32</sup> Further study is necessary to better understand the safety, efficacy and ideal dosage of this system.

Patients who undergo ocular surgery, such as cataract or LASIK, must follow strict postoperative guidelines to avoid complications. This often includes using eye drops; however, as previously discussed, they are not always administered properly or at the required frequency. Contact lenses that deliver anti-inflammatory, antibiotic and pain-reducing drugs evenly over time are currently under investigation as a way to improve postoperative care for these patients as well as those who suffer from corneal abrasions.<sup>33</sup>



**The MediPrint printing process can print multiple layers surrounding the optical zone. The layers may contain the same or different drugs; each layer may have diverse release kinetics.**

Another area where drug-eluting contact lenses could have significant impact is in the treatment of ocular inflammation—a leading cause of blindness. Currently, the standard of care is topical ophthalmic solutions, such as dexamethasone eye drops. However, the side effects as well as a need for frequent administration can make adherence challenging.

In an effort to find a better delivery system, researchers developed a dexamethasone-releasing contact lens. Animal models have demonstrated this approach is a safe and effective treatment for anterior ocular inflammation.<sup>34</sup> The researchers reported that the lenses inhibited suture-induced corneal neovascularization and inflammation for seven days and lipopolysaccharide-induced anterior uveitis for five days. While more research is needed, dexamethasone-eluting lenses could prove to be an effective treatment for ocular inflammation and a promising drug delivery system.

## Clinical Applications

As far as in-clinic application goes, there are multiple management strategies for patients with dry eye disease, seasonal ocular allergies, glaucoma or ocular infection, for example. In general, it is usually safe to initiate the following protocol and proceed according to your findings on a case-by-case

basis. Prior to the ocular examination, provide a questionnaire about ocular symptoms to better inform the evaluation process. Upon identification of the patient's condition, offer various management options, including drug-delivery contact lenses, and review the risks and benefits of each.

If both the practitioner and patient opt to go the drug-delivery contact lens route and the patient is not an existing wearer, conduct lens application and removal training, review the lens wearing schedule and provide written instructions to the patient. Soft drug-delivery contact lenses can usually be dispensed the same day. However, a scleral drug-delivery contact lens may take a few days to manufacture.

After initiating this form of therapy, schedule a follow-up visit to review the therapeutic effects of the drug-delivery contact lens, contact lens handling and patient compliance.

## Takeaways

Drug-eluting contact lenses are poised to become a viable alternative therapeutic option for various ocular diseases and beyond. As advancements continue, doctors and their patients will be able to experience firsthand the impact these systems can have on overall health and quality of life. ■

1. National Eye Institute. Eye health data and statistics. July 17, 2019. [nei.nih.gov/eyedata](https://www.nei.nih.gov/eyedata). Accessed July 8, 2021.
2. Abell RG, Darian-Smith E, Kan JB, et al. Femtosecond laser-assisted cataract surgery versus standard phacoemulsification cataract surgery: outcomes and safety in more than 4000 cases at a single center. *J Cataract Refract Surg*. 2015;41(1):47-52.
3. Chuang AT, Margo CE, Greenberg PB. Retinal implants: a systematic review. *Br J Ophthalmol*. 2014;98(7):852-6.
4. Zhang YX, Chen YF, Shen XY, et al. Reduction- and pH-sensitive lipoic acid-modified poly(L-lysine) and polypeptide/silica hybrid hydrogels/nanogels. *Polymer*. 2016;86:32-41.
5. Jones L, Hui A, Phan CM, et al. CLEAR - Contact lens technologies of the future. *Cont Lens Anterior Eye*. 2021;44(2):398-430.
6. Shell JW. Ophthalmic drug delivery systems. *Surv Ophthalmol*. 1984;29(2):117-28.
7. Hennessy AL, Katz J, Covert D, et al. Videotaped evaluation of eyedrop instillation in glaucoma patients with visual impairment or moderate to severe visual field loss. *Ophthalmology*. 2010;117(12):2345-52.
8. Slota C, Sayner R, Vitko M, et al. Glaucoma patient expression of medication problems and nonadherence. *Optom Vis Sci*. 2015;92(5):537-43.
9. Stone JL, Robin AL, Novack GD, et al. An objective evaluation of eye-drop instillation in glaucoma patients. *Arch Ophthalmol*. 2009;127(6):732-6.
10. Kass MA, Hodapp E, Gordon M, et al. Patient administration of eyedrops: observation. Part II. *Ann Ophthalmol*. 1982;14(9):889-93.
11. Kass MA, Hodapp E, Gordon M, et al. Part I. Patient administration of eyedrops: interview. *Ann Ophthalmol*. 1982;14(8):775-9.
12. Mishima S, Gasset A, Klyce SD, et al. Determination of tear volume and tear flow. *Invest Ophthalmol Vis Sci*. 1966;5:264-76.
13. Tang-Liu DD, Liu S, Neff J, et al. Disposition of levobunolol after an ophthalmic dose to rabbits. *J Pharm Sci*. 1987;76(10):780-3.
14. Johns LK, McMahon JA, Barnett M. *Contemporary Scleral Lenses: Theory and Application*. Vol 4. Bentham Science; 2017:201-41.
15. Kalwerisky K, Davies B, Mihora L, et al. Use of the Boston Ocular Surface Prosthesis in the management of severe periorbital thermal injuries: a case series of 10 patients. *Ophthalmology*. 2012;119(3):516-21.
16. Ciralsky JB, Chapman KO, Rosenblatt MI, et al. Treatment of refractory persistent corneal epithelial defects: a standardized approach using continuous wear PROSE therapy. *Ocul Immunol Inflamm*. 2015;23(3):219-24.
17. Keating AM, Jacobs DS. Anti-VEGF treatment of corneal neovascularization. *Ocul Surf*. 2011;9(4):227-37.
18. Lim M, Jacobs DS, Rosenthal P, et al. The Boston Ocular Surface Prosthesis as a novel drug delivery system for bevacizumab. *Semin Ophthalmol*. 2009;24(3):149-55.
19. Espandar L, Caldwell D, Watson R, et al. Application of adipose-derived stem cells on scleral contact lens carrier in an animal model of severe acute alkaline burn. *Eye Contact Lens*. 2014;40(4):243-7.
20. Maulvi FA, Soni TG, Shah DO. A review on therapeutic contact lenses for ocular drug delivery. *Drug Deliv*. 2016;23(8):3017-26.
21. Schultz CL, Poling TR, Mint JO. A medical device/drug delivery system for treatment of glaucoma. *Clin Exp Optom*. 2009;92(4):343-8.
22. Jung HJ, Chauhan A. Extended release of timolol from nanoparticle-loaded fornix insert for glaucoma therapy. *J Ocul Pharmacol Ther*. 2013;29(2):229-35.
23. Jung HJ, Abou-Jaoude M, Carbia BE, et al. Glaucoma therapy by extended release of timolol from nanoparticle loaded silicone-hydrogel contact lenses. *J Control Release*. 2013;165(1):82-9.
24. Xu J, Li X, Sun F. Cyclodextrin-containing hydrogels for contact lenses as a platform for drug incorporation and release. *Acta Biomater*. 2010;6(2):486-93.
25. Danion A, Arsenault I, Vermette P. Antibacterial activity of contact lenses bearing surface-immobilized layers of intact liposomes loaded with levofloxacin. *J Pharm Sci*. 2007;96(9):2350-63.
26. Holgado MA, Anguiano-Domínguez A, Martín-Banderas L. Contact lenses as drug-delivery systems: a promising therapeutic tool. *Arch Soc Esp Oftalmol (Engl Ed)*. 2020;95(1):24-33.
27. Kim J, Peng CC, Chauhan A. Extended release of dexamethasone from silicone-hydrogel contact lenses containing vitamin E. *J Control Release*. 2010;148(1):110-6.
28. Cision PR Newswire. Johnson & Johnson Vision receives approval in Canada for world's first and only drug-releasing contact lens for vision correction and allergic eye itch: Acuvue Theravision with Ketotifen. April 27, 2021. [www.prnewswire.com/news-releases/johnson-johnson-vision-receives-approval-in-canada-for-worlds-first-and-only-drug-releasing-contact-lens-for-vision-correction-and-allergic-eye-itch-acuvue-theravision-with-ketotifen-301277041.html](https://www.prnewswire.com/news-releases/johnson-johnson-vision-receives-approval-in-canada-for-worlds-first-and-only-drug-releasing-contact-lens-for-vision-correction-and-allergic-eye-itch-acuvue-theravision-with-ketotifen-301277041.html). Accessed July 8, 2021.
29. Pall B, Gomes P, Yi F, et al. Management of ocular allergy itch with an antihistamine-releasing contact lens. *Cornea*. 2019;38(6):713-7.
30. Johnson & Johnson Vision. ACUVUE Theravision with Ketotifen. [www.jnjvisionpro.ca/products/acuvue-theravision](https://www.jnjvisionpro.ca/products/acuvue-theravision). Accessed July 8, 2021.
31. Business Wire. MediPrint Ophthalmics announces successful completion of its SIGHT-1 Phase 2a clinical study. March 1, 2016. [www.businesswire.com/news/home/20210316005609/en/MediPrint-Ophthalmics-Announces-Successful-Completion-of-Its-SIGHT-1-Phase-2a-Clinical-Study](https://www.businesswire.com/news/home/20210316005609/en/MediPrint-Ophthalmics-Announces-Successful-Completion-of-Its-SIGHT-1-Phase-2a-Clinical-Study). Accessed July 8, 2021.
32. Ciolino JB, Ross AE, Tulsan R, et al. Latanoprost-eluting contact lenses in glaucomatous monkeys. *Ophthalmology*. 2016;123(10):2085-92.
33. OCU Medic. New drug-eluting contact lens to provide timed drug delivery directly to eye; improving recovery, reducing cost for millions after eye surgery and LASIK. May 15, 2018. [www.ocumedical.us/new-drug-eluting-contact-lens-to-provide-timed-drug-delivery-directly-to-eye-improving-recovery-reducing-cost-for-millions-after-eye-surgery-and-lasik/](https://www.ocumedical.us/new-drug-eluting-contact-lens-to-provide-timed-drug-delivery-directly-to-eye-improving-recovery-reducing-cost-for-millions-after-eye-surgery-and-lasik/). Accessed July 8, 2021.
34. Bengani LC, Kobashi H, Ross AE, et al. Steroid-eluting contact lenses for corneal and intraocular inflammation. *Acta Biomater*. 2020;116:149-61.



# MASTERING OD-TO-OD REFERRALS

Here's how to build lasting relationships with your peers to provide more complete care.

BY CATLIN NALLEY  
CONTRIBUTING WRITER

Throughout this series, we have explored how to effectively comanage patients with ophthalmologists and other medical specialists. While this is a critical component of optometric practice, in many circumstances another OD can be the preferred partner. Intraprofessional collaboration can offer you three vital things that, frankly, may be lacking in some other comanagement relationships: access, trust and respect.

“I believe that optometry as a profession would be much stronger if we collectively referred patients to one another more, and not just to ophthalmology,” says Brian Chou, OD, of San Diego, who concentrates on helping patients with keratoconus and other corneal disorders who need specialty contact lens fits. “It is a privilege to help other optometrists in the community,” he says. “Their patient’s experience in my practice reflects on the referring doctor. For this reason, I feel accountable to the referring doctor and will do my best to help their patient.”

Practicing at the highest level not only means cultivating your expertise and knowledge as a primary eye care



provider, but also recognizing when a referral is the right choice.

“We all take an oath to provide our patients with the best care possible, and the only way to do so is to recognize when one of our colleagues is better equipped to handle a patient’s specific needs,” notes Joshua L. Robinson, OD, director of the low vision rehabilitation service at the Vanderbilt Eye Institute. “Whether by virtue of skill-set, experience, equipment, time, location or resources, sometimes a fellow OD is able to better care for a particular patient. It is thus important to recognize and make appropriate referrals in a timely manner.”

This final article in our six-part comanagement series will delve into intraprofessional optometric referrals. It will highlight how to successfully collaborate with a fellow OD. This includes building relationships, addressing challenges and identifying when it’s the right time to tap into another OD’s expertise.

## OD/OD Collaboration

There are a variety of reasons why an OD may consider employing the skills of another optometrist. Whether you don’t feel comfortable, don’t have the necessary equipment or prefer not to manage a certain aspect of a patient’s care, it is important to know you have an ally when you refer to a colleague.

Let’s first consider some of the more clear-cut paths to intraprofessional collaboration—instances where the OD on the receiving end is a specialist in a niche aspect of care much like the ophthalmology subspecialists profiled in other installments of this series.

**Vision therapy.** An estimated one in four children have undiagnosed vision problems that interfere with learning and lead to academic and/or behavioral problems, according to Megan Lott, OD, FCOVD, a developmental optometrist at a specialty clinic in Hattiesburg, MS. There is a widespread

need for vision therapy, and ODs are in the perfect position to identify these patients.

While all ODs have some training in the concepts and practices of vision therapy, not all have chosen to specialize in this area of care. Therefore, it is important to know when to refer to another optometrist. This includes taking a thorough case history and evaluating visual efficiency. Dr. Lott recommends adding a quality of life checklist from the College of Optometrists in Visual Development (COVD) to your intake forms.

“It is a brief, 19-item checklist that can help determine if a patient might have a functional vision problem,” she says. “If there is evidence of an issue, the OD can choose to dig deeper or refer to someone who will. This is a tool that is easy to integrate into practice and a good way to determine if further examination or a referral is needed.” You can find a copy in the online version of this article at [www.reviewofoptometry.com](http://www.reviewofoptometry.com) or on COVD’s website at [www.covd.org](http://www.covd.org).

It is also important to think about what you want for your patient. “For example, if you’re sending to an ophthalmologist, your patient with an eye turn is probably going to undergo surgery,” Dr. Lott notes. “If you refer them to me, the intervention will be much more conservative with a focus on trying to fix the root of the problem.” Surgery should not be your first line of treatment for strabismus, she stresses, and patching should not be your first line of treatment for amblyopia. “There are so many better ways to treat this condition.”

So, Dr. Lott notes, you must ask yourself how you will define treatment success. “Is it simply cosmetic enhancement? Is this a child who is struggling in school? What intervention will provide the best outcome?” Referring to an optometrist who specializes in vision therapy not only helps your patient, but also means you are working with someone who is more likely to align with your treatment modality, notes Dr. Lott.

**Low vision.** You’d be hard-pressed to find a discipline more in line with the core values of optometry than low vision, an area of care characterized by precise visual assessment, expertise in optics and empathy for patients—all optometric hallmarks.

This is an area where many of your patients could derive significant benefit from working with an OD whose specialty is low vision. Especially as optometry continues to take on the role of primary eyecare provider, practitioners will see increasingly more patients with uncorrected acuity deficits caused by AMD, diabetic eye disease and glaucoma, to name a few. Leaving them with a visual deficit simply because their eye health has stabilized would be a disservice.

The question is: when do you refer? A common approach is to set a visual acuity threshold, but that’s not the only consideration. While thresholds like visual acuity/visual field/contrast sensitivity can be helpful, the most important consideration is whether a patient has functional needs that cannot be addressed by medicine/surgery or the spectacle and contact lenses you’re able to prescribe, according to Dr. Robinson. “If the answer is ‘yes,’ they should be referred.”

Listen to your patient and their needs. Ask them questions, *e.g.*, “Do you have trouble doing what you want to do because of your vision?” This could include reading the mail, watching television, signing your name and reading screens, to name a few.

Whether you are the referring OD or the low vision specialist, you must not forget about the person behind

Quality of Life Checklist					
Patient Name: _____					
Form Completed by: _____					
Date: _____					
Check the column which best represents the occurrence of each symptom	Never 0	Seldom 1	Occasionally 2	Frequently 3	Always 4
Blurred close vision					
Double vision					
Headaches with near work					
Words run together reading					
Burning, itchy, watery eyes					
Falls asleep reading					
Sees worse at the end of day					
Skips/repeats lines reading					
Dizzy/nauseated by near work					
Head tilt/one eye closed to read					
Difficulty copying from chalkboard					
Avoids near work/reading					
Omits small words when reading					
Writes uphill/downhill					
Misaligns digits/columns of numbers					
Poor reading comprehension					
Poor/inconsistent in sports					
Holds reading too close					
Trouble keeping attention on reading					
Difficulty completing work on time					
Says "I can't" before trying					
Avoids sports/games					
Poor hand/eye coordination					
Poor handwriting					
Does not judge distance accurately					
Clumsy, knocks things over					
Poor time use/management					
Does not make change well					
Loses things/belongings					
Car or motion sickness					
Forgetfulness/poor memory					
Total for each column:	x 0 = 0	x 1 =	x 2 =	x 3 =	x 4 =
<b>Grand Total:</b>					

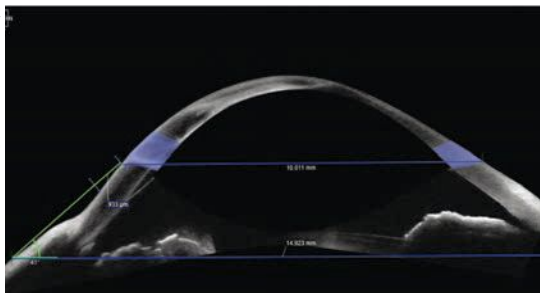
**<15** = Routine eye exam recommended      **16-24** = Comprehensive exam with developmental OD recommended      **>25** = Developmental vision problem likely, comprehensive exam with developmental OD strongly recommended

**This form can help you identify patients with functional vision problems so you can direct them to specialty care.**

the diagnosis. “While it may be easy to fixate on the medical management of a condition, which is of course incredibly important on its own, we can’t lose track of the person who feels the impact of that condition,” says Dr. Robinson. “Equipping that individual to function despite their vision impairment is the core purpose of low vision rehabilitation.”

If an OD does not have the tools to provide comprehensive low vision rehabilitation, it is crucial for the well-being of their patient to refer them to a provider who does. “Stocking simple handheld magnifiers and a few digital magnification tools can be helpful, but a disservice is done to our patients when they aren’t exposed to a comprehensive program and end up with any of their needs left unmet,” urges Dr. Robinson. “Partner with services that have the time and financial flexibility to navigate the challenges of low vision rehabilitation while you comanage the patient’s medical eye care needs,” he emphasizes.

Photo: Amy Comer, OD



**ODs who offer specialty lens fits typically have access to advanced equipment like anterior segment OCT, allowing for more precise results.**

**Specialty lenses.** The field of specialty contact lenses, especially scleral lenses, has seen significant growth in recent years, offering many patients new avenues of treatment. However, fitting these lenses and other custom designs requires extensive expertise and a significant time commitment.

Not every OD wants to handle this aspect of care, and that’s okay—there are optometrists who are passionate about this niche and are ready and willing to comanage alongside the primary eye care provider.

“I am here to provide support and be a resource to the ODs in my area,” says John Gelles, OD, of Teaneck, NJ, whose clinical work is dedicated solely to specialty lenses and complex corneal disease. “I will manage all aspects of the fitting process and the ongoing care of the disease being managed with the lens and the lens itself while ensuring the patient continues being cared for by their primary provider.”

The most important aspect of specialty lenses is the management of the condition prompting a need for them, such as severe ocular surface disease, keratoconus or other corneal conditions. How involved Dr. Gelles will be depends, in part, on the skills and comfort of the referring OD. “I am not here to step on anyone’s toes,” he says. However, it is vital to make sure the patient receives the care they need. “The majority of patients I see with severe ocular surface disease who need PROSE treatment or therapeutic lenses are extremely complex, requiring a management team which could include oncology, neurology, rheuma-

tology, ophthalmology and so on,” he continues. “It can be a lot to manage.”

Dr. Gelles will have a conversation with the referring OD to determine what the comanagement relationship will look like and set roles and expectations. “It’s important to avoid a ‘too many cooks’ situation because it can degrade the confidence a patient has in both providers

if they aren’t on the same page. The relationship works best when roles are clearly defined, and each stays committed to them.”

Key questions he asks aid in guiding the relationship by understanding the referring doctor’s comfort level and preparedness such as, “What is your comfort level in managing the disease?” and “Do you have the diagnostic equipment needed to follow this disease at a high level?”

These questions help the providers understand each other’s capabilities and limitations. If a referring doctor feels equipped to handle the disease follow-up, Dr. Gelles will step aside once the lens is finalized and the acute

condition is resolved or stabilized. If not, he will manage follow-up for the condition requiring the contact lens, while the referring OD will continue to manage the patient’s primary vision needs and all other aspects of their overall ocular health.

**Ocular disease.** Beyond optometry-specific services focused on visual needs, there are countless opportunities to turn to another OD for medical eye care assistance rather than assuming such patients must see an ophthalmologist.

“At times our primary care colleagues have an instinct to refer their patients only to the OMDs instead of their OD colleagues in the same practice,” says Mohammad Rafieetary, OD, of a large retina practice in Memphis. However, he points out that “if the OMDs trust us to practice side by side with them, our community-based colleagues should feel confident extending us the same courtesy.”

In fact, optometrists in a multidisciplinary setting are often the ideal liaison for other ODs in the community, proving them access and attention that may be harder to obtain from the ophthalmologists in the practice.

### DIVIDE AND CONQUER

Optometry doesn’t have formal subspecialties, so there’s a sense that ODs need to be able to manage anything that walks in the door—a concept that is increasingly untenable, especially as scope of practice continues to expand.

“I take exception to the suggestion that an OD should handle as much as possible in their office before referring out,” says Dr. Chou, likening this to trying to be a jack of all trades and master of none. Because his practice is specifically attuned to serving keratoconus patients and addressing their needs at a higher level of service, Dr. Chou has on hand topography, anterior segment OCT, hybrid and scleral diagnostic sets, impression-based scleral lens capability, various scleral lens removal tools, genetic testing for keratoconus and patient literature on keratoconus—not to mention countless hours of clinic time with this patient population.

“Sure, a practitioner who does not routinely care for keratoconus patients can manage them without outside referral, yet it may not be their best use of time and it may not be in the patient’s best interests,” he says. This is not to dissuade practitioners from continually expand their skillset and reflexively refer out all the time, he emphasizes. “Rather, each OD needs to practice within their own capability. If I have a patient who would benefit from low vision services, I will not hold onto that patient. Even though I could provide the service, it would underserve the patient’s best interests. Likewise, I will also refer out patients who would benefit from vision therapy.”

Dr. Rafieetary concurs. “If the OD is both professionally and financially satisfied in practicing the mode they have chosen to practice, I don’t think they are lacking in any way.” As long as they stay abreast of changes in the healthcare environment, keep up-to-date with available technology and treatment options, are able to detect vision- and life-threatening conditions and make appropriate and timely referrals, “they are playing their part admirably and appropriately,” he suggests.





# OD CLINICAL UPDATE

A Monthly Enduring Series

## OVERVIEW

Brought to you by Review Education Group and MedscapeLIVE!, join our renowned experts who will deliver comprehensive, results-oriented strategies you can implement in your practice for improved patient outcomes. OD Clinical Update is your opportunity to stay relevant in the ever-changing landscape, while earning continuing education credits from your trusted partner in optometric education.

\*Earn 1 COPE credit per video, \$14.99

FOR MORE INFORMATION VISIT  
[www.ReviewEdu.com](http://www.ReviewEdu.com)



\*Approval pending



Pennsylvania College of Optometry

Review Education Group partners with Salus University for those ODs who are licensed in states that require university credit.

**REVIEW**  
Education GROUP

Photo: David Lewenz, OD



**While all optometrists should be cognizant of low vision interventions that can help their patients, some cases will require a referral to a specialist for optimal results.**

“I understand everyone has the prerogative to refer to whom they feel comfortable with based on clinical skills, personal relationship and so on,” says Dr. Rafieetary, “but I would suggest primary care ODs communicate with the referral center OD to understand their roles in the practice and use these optometric colleagues as their resource and referral point.” Doing so frees the practice’s ophthalmologists to provide the care they are uniquely trained for, most notably surgical services, and gives the referring doctor a more engaged partner to work with.

“The ODs in our community have learned we will take their pathology cases on the spot, which is comforting to them for emergent cases that need help immediately,” says Houston’s Jill Autry, OD, RPh, who works at a large multidisciplinary practice. “All the ODs in town have our cell phone numbers, and we answer their calls and texts during the day, night, weekends and while on vacation. They know we have trained alongside ophthalmology for years and trust our care. They know we will turn to the ophthalmologists in our practice if we need them.”

### Connection and Communication

As with any comanagement arrangement, success depends on strong relationships as well as effective communication. This means both optometrists must take the time to not only connect with one another but

also develop an understanding of each other’s approach to patient care.

“Communication and expectations are probably the most important components of effective comanagement,” emphasizes Dr. Robinson. “I rely on the referring OD or MD to continue to monitor and effectively manage a patient’s eye condition to help prevent further loss of vision.”

At the same time, “The referring doctor relies on me to address the patient’s functional needs created by that eye condition,” he continues. “Establishing a realistic understanding of this collaborative setup and communicating effectively once the relationship is established are both incredibly important.”

A comprehensive referral letter is key. It should provide detailed clinical information, including diagnoses and treatment history as well as ancillary testing results such as visual fields. It is also important for the referring OD to clearly outline what they need from the optometrist they are referring to.

An open line of communication ensures everyone is on the same page. “While a patient may be under my care for a certain period of time, I am not their primary provider,” explains Dr. Lott. “Just as the referring OD shares information with me, I will provide a thorough report on what I have done and why so that they remain included in care.”

“We call or send the referring doctor a message regarding the exam that same day,” Dr. Autry says, “and we discuss the case with them so they also learn about something they may not see as often as we do.”

Patient communication is also vitally important, especially since you are referring to a fellow OD and there can be confusion regarding the role of each provider. Helping your patients navigate this requires a thorough explanation of the process as well as clearly and repeatedly outlining the care each optometrist will provide.

“From the very beginning of the referral process, I make sure that the patient understands what I do and the

part I will play in their care,” says Dr. Gelles. “I emphasize to the patient that I don’t provide any primary eye care and that they will return to their OD for that aspect.”

The doctor receiving the referral should work to strengthen the patient’s bond with their primary OD. “I feel it is important to reinforce to the patient how they were fortunate to see the referring doctor,” says Dr. Chou. “It takes humility for a doctor to admit that what is best for the patient may be beyond their scope of care and comfort level.” The referring doctors deserve praise and recognition, he emphasizes. “When a keratoconus patient experiences an exceptional outcome and thanks me for it, I let the patient know that the credit really goes to the referring doctor.”

Patients who require a referral will often need frequent follow-up with the specialist OD in addition to primary eye care. As a result, the patient may be under the misconception that their routine care is being managed.

“We have a responsibility to make sure the patient understands the importance of maintaining comprehensive care, including routine exams,” emphasizes Dr. Gelles. For example, progressive corneal diseases, such as keratoconus, involve ongoing monitoring, and patients may assume that this qualifies as their routine eye exam. “I make sure they know that they need to return to their primary OD for routine care and that is something I reinforce during every visit.”

### Addressing Challenges

While collaborating with a fellow optometric professional—instead of an ophthalmologist or another medical specialist—can be easier in many ways, navigating the intraprofessional dynamic can prove challenging for different reasons.

Given you are referring to a doctor with comparable education and training, there can be concerns that this opens the door to losing a patient to a fellow OD. However, many optometrists who are passionate about a

specialty want to focus most of their time on that area of care. They are there to complement the primary care services you already provide, not commandeer a patient and their overall vision management.

If anything, the fact that you share the same training and, oftentimes, a similar mindset, is invaluable, notes Dr. Lott. “There are plenty of patients for everyone,” she says. “And you can’t see them all. In fact, you cannot provide the very best care for your patients when you are trying to see everyone.”

Collaborating with ODs who have committed their time and energy to a subspecialty is in your best interest as well as your patient’s, she adds. “So, reach out. Ask for support. Work together for the betterment of our patients and the profession.”

In the case of vision therapy, ODs may not be referring patients as often as they could. “If you don’t look for it, you don’t see it,” says Dr. Lott. “These exams have to go beyond reading an eye chart and giving an Rx.”

Many times, the technicians will dilate the child as soon as they come in, she notes, which makes it difficult to conduct the necessary tests to determine if a patient could benefit from vision therapy.

“Optometry has become so focused on managing medical conditions that we have completely forgotten about functional visual disorders,” Dr. Lott states. “Many times, I see children who have already been diagnosed with a learning disorder such as ADD or dyslexia. And while medical conditions are a key component of our profession, we also have the power to change the entire trajectory of a child’s life who is failing school because of a vision-related learning problem.”

Dr. Lott also notes that ODs should not be hesitant to refer due to cost or distance. She acknowledges that insurance does not cover most vision therapy services and as a result some subspecialists, including herself, do not accept insurance. However, that should not be a reason to not refer.

“**Recognizing when one’s resources cannot meet a patient’s needs and directing them to someone better equipped for this component of care is one way we uphold the optometric oath.**”

“It’s not the job of the OD to decide if a parent can or cannot afford vision therapy,” she advises. “It is important to provide parents with all the information as well as their options and let the family make the decision.” Same goes for travel. “When their child is struggling, parents are willing to travel to get them the help they need.”

Concerning low vision rehabilitation referrals, Dr. Robinson notes that the biggest challenge is simply contending with the burgeoning demand. “Considering the continually growing number of visually impaired patients under our care, we are going to need more ODs committing themselves to low vision rehabilitation and students completing residency programs in this subspecialty area,” he says.

However, this is complicated by the reality that proper low vision care is time-consuming and very difficult to fit into a private practice model, according to Dr. Robinson, who explains that a comprehensive low vision rehab plan often involves a multidisciplinary team that can include occupational therapists, orientation and mobility specialists, vocational rehab teachers, teachers of the visually impaired, social workers and counselors.

“Putting together the most appropriate prescriptive devices with the best team to handle a patient’s very specific needs is time-intensive and requires a working knowledge of these referral resources,” Dr. Robinson emphasizes, while noting that these are some of the reasons why most comprehensive programs are found in the academic and nonprofit realms.

How can this change? “It likely won’t,” says Dr. Robinson, “until

insurance reimbursement structures for low vision devices and services are altered to lessen the time and financial burdens that make it impractical for private practice ODs to take part.”

These challenges also underscore the importance of comanagement to ensure patients have access to these subspecialized providers.

## For Patients and the Profession

There’s no shame in recognizing when you need outside support, advises Dr. Gelles, emphasizing that there are allies within the optometric profession who are more than willing to help care for your patients while allowing you to continue to take the lead.

It is also important to recognize the times when specialists refer out to you. “These complex patients still need primary eye care and often other optometric specialties, such as low vision or binocular vision,” notes Dr. Gelles. “I frequently refer to other ODs to manage these aspects, and I’m thrilled to refer the patient to someone super passionate about their specialty. I know the patient is getting the best care possible. Additionally, this allows me to stay focused on what I do best.”

“Recognizing when one’s resources cannot meet a patient’s needs and directing them to someone who is better equipped to handle this component of care is one of the many ways in which we uphold the optometric oath,” reiterates Dr. Robinson.

Comanagement is a cornerstone of healthcare and optometrists must feel comfortable working alongside one another for the greater good of their patients—and profession. ■

### KEY TAKEAWAYS

- Establish a strong comanagement relationship
- Maintain ongoing communication
- Recognize when a referral is necessary
- Set clear expectations and treatment plans
- Explain the comanagement process to your patients



Earn 2 CE Credits  
 (COPE APPROVED)

# WHAT TO DO WHEN YOU SEE UVEITIS

Here's how to narrow down the differentials and determine when a case is—or isn't—infectious.



BY MEGAN HUNTER, OD  
HINES, IL

**U**veitis—a threat to vision due to its potential to cause ocular complications—is responsible for 10% to 15% of severe visual handicap in the developed world and can affect all age groups.<sup>1,2</sup> It stems from a wide array of conditions, both infectious and non-infectious. When a clinician sees a patient with uveitis, their differential list is long, and they must know how to narrow it down to arrive at the correct diagnosis; effective treatment depends on it.

The condition can be a result of systemic diseases such as HLA-B27 seronegative spondyloarthropathies, juvenile idiopathic arthritis, sarcoidosis and lupus, to name a few. It can also have infectious etiologies, such as herpes, syphilis, tuberculosis (TB) and Lyme disease.

This article will help clinicians wade through the differentials and

better understand how to determine whether the uveitis is infectious, and, if not, how to reveal the systemic association. The location, onset and duration are key factors in the differential, as are the clinical findings that vary based on the underlying cause.

## Clinical Features

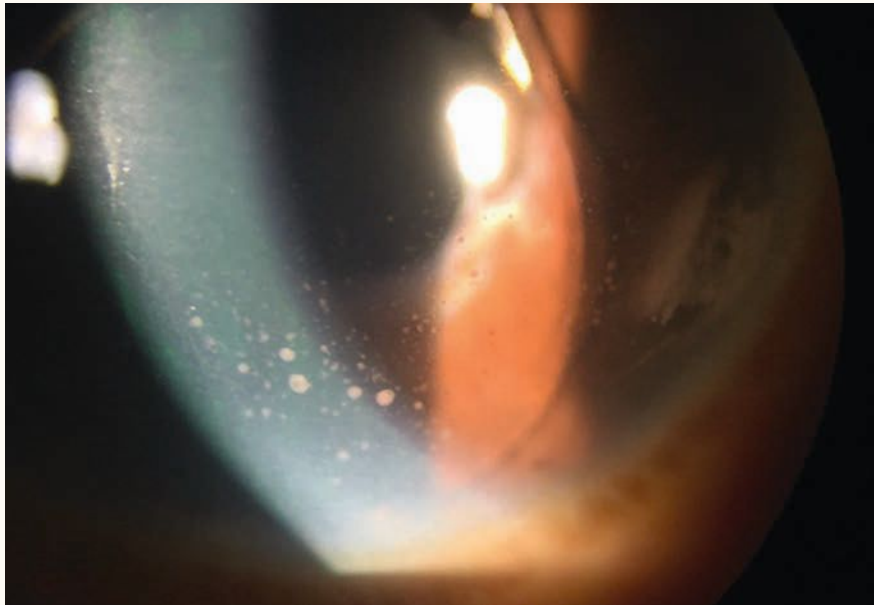
The most common symptoms of anterior uveitis are pain, redness and severe photophobia. Patients may also experience tearing, blurred vision and floaters. Clinical signs of anterior uveitis include ciliary flush or circumlimbal injection, corneal edema and keratic precipitates (KPs). KPs are clumps of inflammatory cells that deposit on the corneal endothelium. They are more common on the inferior portion of the cornea. Fine KPs are referred to as nongranulomatous, and granulomatous KPs are greasy-appearing and made up of multiple cell clusters, including macrophages and giant cells.<sup>3</sup>

Anterior chamber cell and/or flare is a hallmark sign. In severe cases, the white inflammatory anterior chamber cells become layered and a hypopyon forms. Nodules are possible on the iris, and inflammation causes the iris to become sticky, leading to posterior synechiae and peripheral anterior synechiae. Vitreal signs of uveitis include vitreous cells, puffballs or snow banking and the accumulation of vitreous cells over the pars plana and peripheral retina. Posterior uveitis can be associated with additional inflammation in the posterior segment: cystoid macular edema, phlebitis, arteritis or disc edema.

The term *uveitis* is used to describe any inflammation along the uveal tract—the middle layer of the eye, which includes the iris, ciliary body and choroid. The word is not actually accurate regarding pathogenesis because other ocular structures are often the inflammatory target.<sup>4</sup> The uvea transports more than 80% of the ocular blood volume, so it is regularly involved in intraocular inflammation.<sup>5</sup>

About the  
author

**Dr. Hunter** graduated from the Illinois College of Optometry in 2002 and completed a residency in ocular disease at the Bascom Palmer Eye Institute in 2003. She is currently an associate professor of ophthalmology at the Loyola University Medical Center and the Hines VA Medical Center. She has no financial interests to disclose.



**Keratic precipitates are evident in this eye.**

Uveitis is classified by location: anterior, intermediate, posterior or panuveitis. The latter term is used when there is no single predominant site of inflammation; rather, the condition is present in the anterior chamber, vitreous, retina and/or choroid.<sup>6</sup> Posterior uveitis occurs when tissues that are typically protected by the blood-retinal barrier become affected. Examples include retinitis, retinal vasculitis, retinochoroiditis and optic neuritis.<sup>4</sup> Cystoid macular edema can also occur in uveitis due to a disruption of the blood-retinal barrier.

Intraocular pressure (IOP) may be lower in patients with uveitis due to ciliary body inflammation, which leads to decreased aqueous production or higher due to trabeculitis characterized by debris and inflammatory cells, fibrin and edematous trabecular bands clogging the trabecular meshwork's outflow channels.<sup>7</sup>

Angle closure is a possibility in uveitis. Inflammatory cells and fibrin can cause posterior synechiae, which may obstruct aqueous flow and lead to complete pupillary block. Chronic angle closure can occur when inflam-

matory cells and fibrin cause peripheral anterior synechiae through adhesions between the iris and trabecular meshwork. Furthermore, ciliary body inflammation and edema can cause it to rotate forward, closing the angle.

## Examination and Diagnosis

When a patient comes in complaining of symptoms of anterior uveitis, a thorough ocular evaluation is important to make the diagnosis, discover the etiology and gauge the response to treatment. A key step includes recording visual acuity. A careful slit lamp examination is a must to assess the cornea for any KPs, followed by a careful examination of the anterior chamber for inflammatory cells or protein (flare).

Inflammatory cells in the anterior chamber are a result of spillover from the inflammation in the iris and/or ciliary body. Anterior chamber cells are best detected in a dark room with a bright slit lamp beam with higher magnification obliquely directed through the aqueous.

The Standardization of Uveitis Nomenclature (SUN) Project was started by a group of uveitis specialists to develop criteria to standardize the reporting of uveitis in the literature and at academic meetings. The group met for the first time in 2004 and first published standard

**Release Date:** August 15, 2021

**Expiration Date:** August 15, 2024

**Estimated Time to Complete Activity:** 2 hours

Jointly provided by Postgraduate Institute for Medicine (PIM) and Review Education Group

**Educational Objectives:** After completing this activity, the participant should be better able to:

- Describe the various causes of uveitis.
- Identify and diagnose a patient with uveitis.
- Determine if a case of uveitis is infectious or the result of a systemic disease.
- Discuss systemic etiologies of uveitis.

**Target Audience:** This activity is intended for optometrists engaged in uveitis management.

**Accreditation Statement:** In support of improving patient care, this activity has



been planned and implemented by the Postgraduate Institute for Medicine and Review Education Group. Postgraduate Institute for Medicine is jointly accredited by the Accreditation Council for Continuing Medical Education (ACCME), the Accreditation Council for Pharmacy Education (ACPE) and the American Nurses Credentialing Center (ANCC) to provide continuing education for the healthcare team. Postgraduate Institute for Medicine is accredited by COPE to provide continuing education to optometrists.

**Reviewed by:** Salus University, Elkins Park, PA



**Faculty/Editorial Board:** Megan Hunter, OD

**Credit Statement:** This course is COPE approved for 2 hours of CE credit. Activity #122212 and course ID 73692-SD. Check with your local state licensing board to see if this counts toward your CE requirement for relicensure.

**Disclosure Statements:** *Authors:* Dr. Hunter has no financial interests to disclose. *Managers and Editorial Staff:* The PIM planners and managers have nothing to disclose. The Review Education Group planners, managers and editorial staff have nothing to disclose.

**Table 1. Anterior Chamber Cell Grading (based on SUN Working Group)<sup>6</sup>**

Grade	Cells in Field
0	<1
1/2+	1-5
1+	6-15
2+	16-25
3+	26-50
4+	>50

reporting guidelines in 2005.<sup>6</sup> They determined how to grade anterior chamber cells based on the amount of cells seen in a 1mm x 1mm slit beam and established criteria for the grading of anterior chamber flare (Tables 1 and 2). It is important to measure IOP and check gonioscopy if pressure is elevated. A dilated fundus examination is crucial to look for vitreous and posterior segment inflammation.

**Underlying Etiology**

After making the diagnosis of uveitis, it is important to start considering the underlying etiology. Detailed history and examination as well as imaging studies and laboratory testing, when indicated, help determine the underlying systemic condition if there is one. Most importantly, the clinician must determine if the uveitis is of infectious origin and caused by one of the following underlying etiologies:

**Syphilis.** A systemic infection caused by the spirochete bacterium *Treponema pallidum*, syphilis is almost exclusively spread by sexual contact.<sup>8</sup> Syphilis is on the rise, and its incidence has been increasing across many groups in the United States.<sup>8</sup> It has been called the “great imitator” due to its multiple ocular presentations and, therefore, its ability to mimic many ocular diseases.

Posterior uveitis and panuveitis are the most common syphilitic presentations of uveitis. There are three stages of systemic syphilis infection: primary, secondary and

tertiary. Primary syphilis is characterized by a chancre, which is a painless erythematous ulcer seen on the anus, mouth, penis or vagina. It appears approximately 21 days after exposure to *Treponema pallidum* and heals in one to two months even if untreated. The fluid produced from a chancre is very infectious. Ocular syphilis is almost nonexistent in the primary stage.<sup>9</sup>

Secondary syphilis develops four to 10 weeks after the initial infection and is characterized by a body maculopapular or pustular rash most common on flexor and volar surfaces. Other secondary syphilis signs are fever, malaise, headache, nausea, loss of appetite and joint pain. Ocular involvement is possible in the secondary stage and may present as keratitis, iridocyclitis, episcleritis, scleritis, chorioretinitis or vitritis.<sup>8</sup> The latent stage begins one year after infection, with most people remaining in this stage. A patient with latent syphilis will have positive serology but no clinical signs or symptoms of infection.

Roughly 15% to 30% of infected individuals who do not get treatment will develop tertiary syphilis.<sup>10</sup> This

is a destructive immune response to the low levels of remaining *Treponema pallidum*. Tertiary syphilis is characterized by benign gummas under the skin but can cause skeletal, heart and blood vessel damage. It typically appears three to 15 years after initial infection.

Ocular syphilis occurs more commonly in the latent and tertiary stages.<sup>9</sup> In latent syphilis, it can be the only presenting sign.<sup>9</sup>

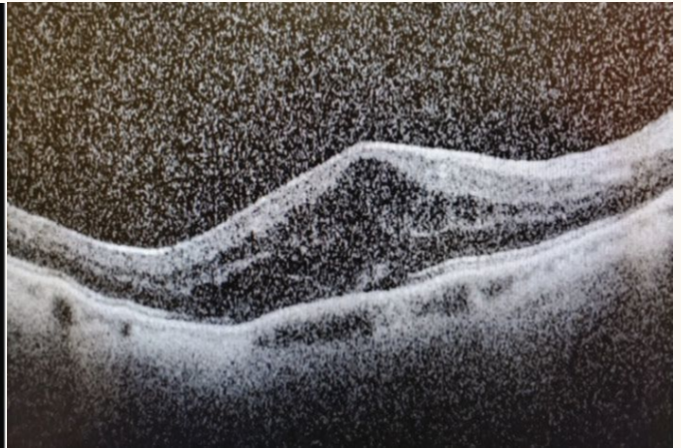
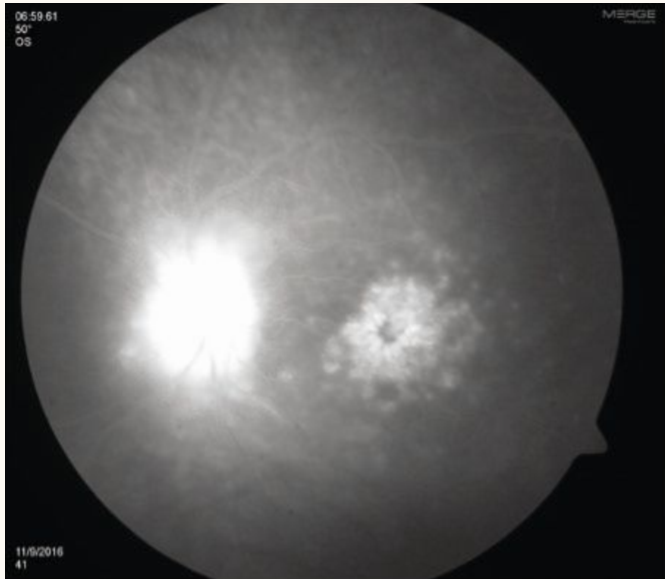
Uveitis caused by syphilis can be granulomatous or non-granulomatous, unilateral or bilateral and anterior, intermediate, posterior or panuveitic.<sup>11</sup> Chorioretinitis is the most common presentation of syphilitic posterior uveitis and is often accompanied by vitritis and characterized by grayish-yellow chorioidal lesions in the posterior pole and mid-periphery.<sup>12</sup> Focal retinal edema, vasculitis and papillitis are all signs of syphilitic uveitis, as well as necrotizing retinitis, retinal vasculitis and exudative retinal detachment. Neurosyphilis is characterized by aseptic meningitis with cranial nerve palsies, Argyll Robertson pupil (small pupils that react to accommodation but not to light), progressive loss of cortical function and tabes dorsalis (degeneration of the dorsal root ganglia of the spinal cord causing pain, ataxia, paresthesias, hypoesthesias and decreased deep tendon reflexes).

Diagnosis of syphilis is commonly made through serologic testing, of which there are two categories: nontreponemal (regain) tests and treponemal-specific tests. Nontreponemal tests (rapid plasma regain and

**Table 2. Anterior Chamber Flare Grading (based on SUN Working Group)<sup>6</sup>**

Grade	Cells in Field
0	None
1+	Faint
2+	Moderate (iris and lens details clear)
3+	Marked (iris and lens details hazy)
4+	Intense (fibrin or plastic aqueous)





**Cystoid macular edema on fluorescein angiography (left) and optical coherence tomography (above).**

venereal disease research laboratory) detect nonspecific treponemal antibody. Treponemal-specific tests (fluorescent treponemal antibody absorption and micro-hemagglutination treponemal pallidum) detect specific treponemal antibody.

Nontreponemal tests are used as screening tests but also successfully monitor response to treatment and disease activity. A four-fold change in titer or two dilutions represents a successful response to treatment. High titers may not decrease for 12 to 24 months following treatment.

Treponemal tests are more specific and are used to confirm the diagnosis after a positive nontreponemal test. They have a lower percentage of false positive results.

Nontreponemal tests become positive within three weeks of primary infection, so a negative result may represent a very early infection.<sup>15</sup> A negative test result when there is a high index of suspicion should be repeated in two to three weeks. Both types of tests—nontreponemal and treponemal—are needed to confirm a diagnosis of syphilis.<sup>14</sup>

Syphilis is treated with penicillin G with dose and type of administration depending on the stage of disease. In primary, secondary and early latent syphilis, one intramuscular administration of 2.4 million units is

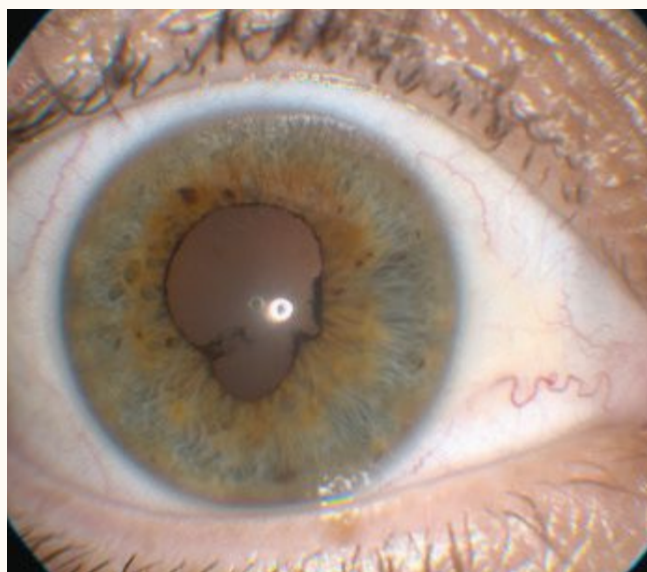
sufficient treatment. In latent syphilis of unknown duration, late latent syphilis and tertiary syphilis, three intramuscular doses are given at one-week intervals. For neurosyphilis cases, three to four million units are given intravenously every four hours for 10 to 14 days. The CDC recommends a lumbar puncture to check for neurosyphilis in all patients with ocular syphilis.<sup>15</sup> Ocular syphilis is treated the same as neurosyphilis even with a normal cerebrospinal fluid study.

It is always wise to consider syphilis in any case of uveitis. Ask about sexual activity and prior presence of a chancre or body rash. According to uveitis specialist Janet Davis, “For most incident cases of uveitis, a strict rule of always placing syphilis in the differential diagnosis and including treponemal serological testing in any laboratory work-up is wise.”<sup>11</sup>

**TB.** This condition—caused by infection from *Mycobacterium TB*—is transmitted by aerosolized droplets. It is important to note that exposure is not equivalent to active infection. Most patients develop a self-limiting pneumonia that heals with calcified granuloma formation that can later reactivate if the patient becomes immunosuppressed. Signs of active infection are coughing, malaise, fever, night sweats and weight loss.

Incidence has decreased dramatically in the United States, but TB infection remains a concern due to immunocompromise and immigration.<sup>16</sup> Most TB cases in the United States occur in foreign-born individuals likely due to reactivation of latent infection acquired prior to arriving in the country, most commonly from Mexico, the Philippines, India, Vietnam and China.<sup>16</sup> Other risk factors for TB infection are human immunodeficiency virus (HIV) coinfection, diabetes, excessive alcohol abuse, drug use, homelessness and incarceration.

Intraocular tuberculosis (IOTB) is a form of extrapulmonary TB and is caused by either hypersensitivity to the tubercular antigen or by tubercle bacilli directly invading the eye. A primary pulmonary source is often not found in IOTB as is the case in other forms of extrapulmonary TB.<sup>17</sup> Posterior uveitis is the most common manifestation of IOTB, and the choroid is commonly the involved structure, resulting in choroidal tuberculomas, multifocal choroiditis or serpiginous-like choroiditis.<sup>18</sup> Choroidal tubercles are grayish-white/yellow in color and can be unilateral or bilateral and single lesions or multiple. Large, single choroidal TB granulomas can cause exudative retinal detachments.



This patient has posterior synechiae.

TB serpiginous-like choroiditis occurs in younger patients and is often bilateral and associated with significant vitritis. Anterior segment inflammation is common. This condition begins as multifocal yellowish-white lesions that are initially discreet but become confluent over a few weeks.<sup>19</sup> Alternatively, this condition may present as a placoid pattern with a large plaque-like lesion with a leading edge that is yellowish-white and elevated with a flatter and pigmented center.<sup>19</sup> Tubercular serpiginous-like choroiditis is a distinct entity common in younger adults from Asian-Pacific regions where TB is endemic.<sup>18-20</sup> Other, less common signs of ocular TB are conjunctivitis, conjunctival nodules, interstitial and phlyctenular conjunctivitis, anterior uveitis, episcleritis, scleritis, retinal perivasculitis and optic neuritis.

Work-up for the patient with suspected tuberculosis includes a chest X-ray to look for active pulmonary involvement and either a TB skin test (PPD) or interferon gamma release assay (IGRA) blood test (QuantiFERON-TB Gold, T-SPOT TB test). The skin test injects purified protein derivative intradermally. TB-infected patients will show a delayed hypersensitivity reaction within six weeks of active infection,

which will remain positive for life.

The skin test must be read 48 to 72 hours after injection of the purified protein derivative; this requires a return to clinic. The IGRA blood tests have become more popular in the work-up of TB because results are available in 24 hours and do not require a second visit. Both TB skin tests

and IGRA blood tests are accurate in the detection of latent infection, but both are not accurately able to predict risk for progression from latent infection to active infection.<sup>21</sup> Confirmation of pulmonary TB requires microbiological evidence of *Mycobacterium TB* from sputum.

Confirming the diagnosis of intraocular TB is tough and requires microbiological confirmation of *Mycobacterium TB* from ocular fluid through PCR testing of aqueous or vitreous tap. Due to the invasive nature of the test, it has yet to be routinely adopted. Intraocular TB is often presumed in the presence of at least one clinical sign of the condition, signs of confirmation of pulmonary TB, immunologic evidence of TB infection or documented exposure.<sup>22</sup>

Treatment of TB includes a combination of four drugs: rifampin, isoniazid, pyrazinamide and ethambutol (RIPE therapy). Patients on ethambutol must be monitored for ocular toxicity due to the risk of ethambutol-induced optic neuropathy. RIPE therapy has been shown to be effective against intraocular TB due to the treatment of latent TB infection of the body decreasing the hypersensitivity reaction in the eye.<sup>23,24</sup>

**Toxoplasmosis.** Ocular toxoplasmosis is caused by the protozoan parasite *Toxoplasma gondii*. Humans catch this parasite by eating undercooked meat or by hand contamination when cleaning cat litter boxes and transferring the germs onto food. Children can become infected by eating dirt that contains spore of the parasite. In endemic areas, water contamination aids in transmission of the disease.<sup>9</sup>

Clinical manifestation of active disease is a focal gray-white lesion of retinal necrosis, which typically develops on the edge of a preexisting pigmented chorioretinal scar. Active toxoplasmosis infection is associated with a dense vitritis. Patients are at lifetime risk of recurrence because tissue cysts remain in the retina.<sup>25</sup> Treatment of active lesions includes antibiotics and corticosteroids. The most frequent treatment regimen is a pyrimethamine-sulfadiazine combination in addition to steroids.<sup>9</sup> Prophylactic antibiotic treatment has recently been proposed.<sup>25</sup>

**Lyme disease.** This is caused by the spirochete *Borrelia burgdorferi* and leads to a multisystem infectious response. It is spread by certain species of ticks. Symptoms include erythema, migraines, fever, headache and fatigue. If untreated, infection can lead to arthritis, neurological manifestations and cardiac involvement. Ocular findings are rare and occur in less than 1% of cases.<sup>26</sup>

Lyme can cause all types of uveitis but it is very rare, accounting for less than 1% of cases.<sup>27</sup> The CDC recommends serological testing in symptomatic patients with a risk of exposure to black-legged ticks.<sup>28</sup> In July 2019, the FDA cleared serologic assays that use enzyme immunoassay in a two-test format in place of the confirmatory western immunoblot assay as the second test.<sup>29</sup> Lyme disease is treated with antibiotics, and those treated in the early stages of disease recover completely.

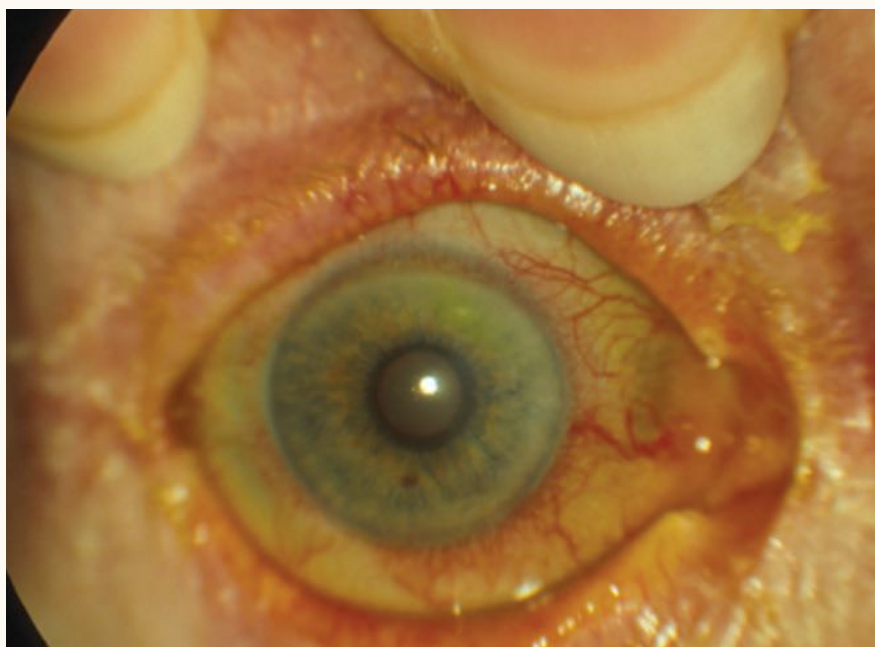**Viral uveitis.** The most common viruses associated with anterior

uveitis are herpes simplex virus (HSV), varicella-zoster virus (VZV), cytomegalovirus (CMV) and rubella virus (RV).<sup>30</sup> Clinical features of viral uveitis include KPs, elevated IOP and iris atrophy. Viral uveitis has a spectrum of clinical presentations, and different viruses cause similar presentations of uveitis, making it difficult to determine the causative virus.

Fuchs' uveitis syndrome is usually unilateral and has a mild anterior chamber reaction, no ciliary injection, KPs, heterochromia, vitritis and posterior subcapsular cataract. The affected eye is typically lighter in color due to pigment loss but can appear darker in brown eyes due to anterior stromal atrophy, which reveals the darker pigmented epithelium.<sup>31</sup> Structural iris changes are common with atrophy, affecting all layers and causing the loss of the corrugated texture.<sup>31</sup>

Fuchs' likely represents a low-grade immunoreactivity to viral antigen. RV is the most common causative virus in the United States and Europe, with rubella-specific antibodies detected in the aqueous humor of eyes diagnosed with Fuchs' uveitis syndrome.<sup>32,33</sup> This disease is less common in patients born in the United States after initiation of the rubella vaccination program.<sup>34</sup> CMV is the most common cause of Fuchs' uveitis syndrome in East Asia.<sup>35</sup>

Posner-Schlossman syndrome (PSS) is associated with recurrent attacks of elevated IOP and corneal endotheliitis manifested by corneal edema, mild anterior chamber reaction and a few KPs. In endotheliitis, the corneal endothelium is thought to be the primary inflammatory source. IOP is markedly high (mean 48mm Hg to 50mm Hg), which can cause mild discomfort, mild visual blur and the presence of halos alerting the patient to seek eye care.<sup>35</sup> CMV-specific antibodies have been detected in the aqueous of patients diagnosed with PSS, with CMV appearing to be a frequent cause of



**A ciliary flush is visible on examination.**

PSS.<sup>35,36</sup> Treatment includes ocular hypotensive medication and topical steroids to control the inflammation and help lower IOP.

HSV anterior uveitis occurs more often during reactivation of the virus than during the primary infection.<sup>30</sup> The HSV virus lays dormant in the trigeminal ganglion, and its reactivation can cause intraocular inflammation. Clinical signs of HSV anterior uveitis include elevated IOP due to trabeculitis, moderate anterior chamber reaction and ciliary flush. Vitritis and posterior synechiae are possible clinical features. Iris involvement leads to loss of pigment epithelial cells with iris atrophy and transillumination defects in up to 50% of affected individuals.<sup>37</sup>

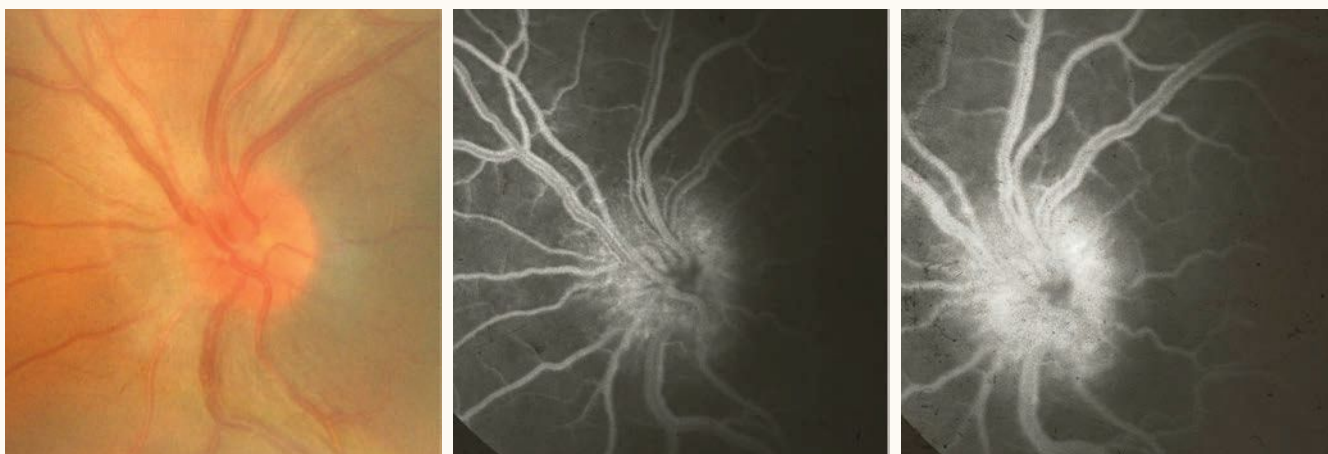Ask patients about a history of frequent cold sores or previous keratitis. Corneal scars and decreased corneal sensitivity may be present from previous infection. HSV anterior uveitis is more common in patients with active corneal infection or a history of prior keratitis.<sup>38</sup> Dendritic keratitis is the hallmark presentation of epithelial keratitis from HSV.

Anterior uveitis from HSV is treated with oral antiviral medications, topical prednisolone acetate every

one to two hours and a cycloplegic agent to relax the ciliary body.<sup>39</sup> When considering an antiviral, oral medications are necessary to penetrate the anterior chamber, and topical antivirals are eventually toxic to the cornea. Oral antiviral options are 400mg of acyclovir five times daily or 500mg of valacyclovir three times daily. A history of epithelial disease can accompany HSV anterior uveitis. Prophylactic antiviral therapy to prevent epithelial recurrence is important and dosed at 400mg of acyclovir two times daily or 500mg to 1,000mg of valacyclovir once daily.

VZV lies dormant in the neural sensory ganglia after primary infection. It can reactivate after immunity wanes, which is common later in life.<sup>30</sup> Herpes zoster ophthalmicus (HZO) presents with pain and a vesicular skin rash along the ophthalmic division of the trigeminal nerve. Some patients have only the skin rash in HZO, but anterior uveitis can develop as well. The uveitis that arises from VZV is often more severe than that of HSV and is accompanied by a higher incidence of synechiae and vitritis. Corneal pseudodendrites are seen in HZO, which are elevated but lack terminal bulbs.





**Pictured here is an HLA-B27–positive uveitis patient. Optic nerve head edema is evident on fundus photography (left), early fluorescein angiography (middle) and late fluorescein angiography (right).**

HZO is treated with acyclovir 800mg five times daily or valacyclovir 1,000mg three times daily. Topical prednisolone acetate and cycloplegic agents are used to control the anterior chamber inflammation. IOP-lowering medications are utilized to help control pressure in patients with viral uveitis, although controlling the inflammation also helps manage the eye pressure. Prostaglandin analogs should be avoided due to their potential to contribute to inflammation.

Viruses that are emerging as causes of uveitis are dengue virus and chikungunya virus. Dengue is

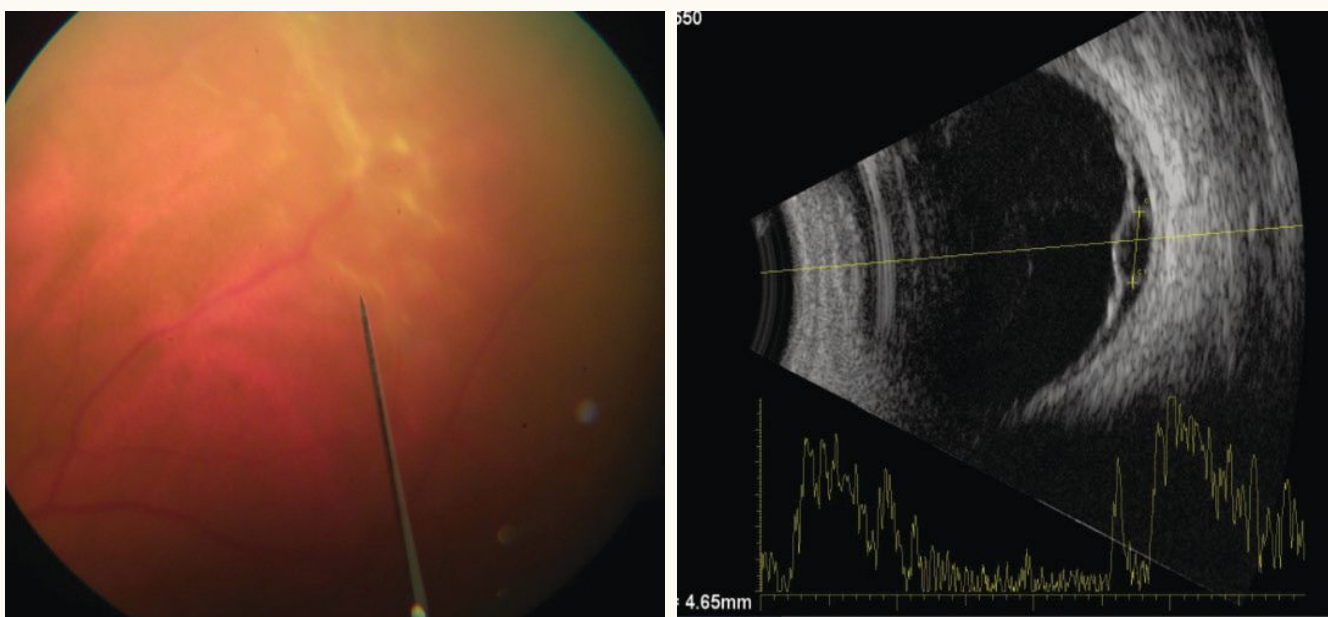
spread through mosquitos, and while rare in the United States, it is more common in Southeast Asian countries and is on the rise in the Caribbean.<sup>40</sup> Most reported cases in the United States have been associated with recent travel.

Dengue fever symptoms include high fever, headache, vomiting, joint pain and rash. Common ocular manifestations are chorioretinitis with macular edema, foveolitis and periphlebitis.<sup>41</sup> Foveolitis is the presence of well-defined, yellow subretinal lesions in the macula accompanied by retinal striae.<sup>42</sup> Ocular associations can improve without interven-

tion, although some patients need treatment with systemic steroids to control inflammation.

Chikungunya is also spread through mosquito bites and is endemic in Asia and Africa.<sup>20</sup> Infection causes fever and joint pain. Common ocular signs of chikungunya infection are conjunctivitis, anterior uveitis, dendritic keratitis and increased IOP. Treatment of chikungunya is supportive in nature, including the ocular inflammation which is treated with steroids and cycloplegic agents.

**CMV retinitis.** In immunocompetent people, CMV is associated



**Retinal detachment in a patient with a solitary tubercular granuloma (left) on B-scan ultrasonography (right).**

with Fuchs' uveitis syndrome and PSS. CMV retinitis is the most common opportunistic infection in the immunosuppressed and much more devastating for these individuals.<sup>9</sup> Active CMV retinitis can be hemorrhagic with white/yellow retinal lesions, granular with no necrosis or hemorrhage or perivascular with white lesions surrounding the blood vessels. Early CMV retinitis can resemble large cotton wool spots. Treatment options include intravenous, intravitreal and oral antiviral medications.

**Non-infectious cases.** A common cause of non-infectious, immune-mediated posterior uveitis is sarcoidosis. This is a multisystem inflammatory disorder characterized by non-caseating granulomas. Sarcoidosis can involve any organ or system but most commonly affects the lungs, skin and reticuloendothelial system (liver, spleen and lymph nodes).<sup>43</sup> Taking a chest X-ray, conducting liver enzyme blood testing and asking about skin lesions is a good investigational approach.<sup>43</sup>

Pulmonary sarcoidosis is diagnosed by the detection of bilateral hilar adenopathy on a chest X-ray. Lysozyme- and angiotensin-converting enzymes are released by granulomas; therefore, blood tests that aid in granuloma detection are often ordered in the work-up of a uveitis patient, even though they have a low positive predictive value.<sup>43</sup> Common ocular signs of sarcoidosis include vitritis, periphlebitis, multifocal choroiditis and papillitis.

A detailed case history can help separate the possibility of syphilis, TB or sarcoidosis as the etiology of posterior uveitis. Ask about sexual habits, HIV status, country of origin and history of previous lung infection, chancre or body rash.

The most common anterior uveitis in the United States is not infectious but rather immune-mediated HLA-B27-associated uveitis.<sup>30</sup> This is typically unilateral and acute, associated with marked fibrinous anterior chamber reaction with hypopyon.

IOP is often lower due to reduced aqueous production caused by ciliary body inflammation.

## Conclusion

A detailed case history and careful examination are key elements of our clinical regimen when tasked with the diagnosis and management of uveitis. It is important to rule out infectious causes of uveitis so that necessary systemic therapy can be initiated. In cases of posterior uveitis, consider the possibility of syphilis or tuberculosis. In cases of anterior uveitis, consider a viral origin whenever IOP is elevated or iris atrophy is present. ■

- Dick AD, Tundia N, Sorg R, et al. Risk of ocular complications in patients with noninfectious intermediate uveitis, posterior uveitis, or panuveitis. *Ophthalmology*. 2016;123(3):655-62.
- Miserocchi E, Fogliato G, Modorati G, et al. Review on the worldwide epidemiology of uveitis. *Eur J Ophthalmol*. 2013;23(5):705-17.
- Chan NS, Chee SP. Keratic precipitates: the underutilized diagnostic clue. *Ocul Immunol Inflamm*. 2021;1:1-10.
- Forrester JV, Kuffova L, Dick AD. Autoimmunity, autoinflammation, and infection in uveitis. *Am J Ophthalmol*. 2018;189:77-85.
- Forrester JV, Dick AD, McMamin P, et al. *The Eye – Basic Science and Practice*. 4th ed. London: Elsevier; 2015.
- Jabs DA, Nussenblatt RB, Rosenbaum JT, et al. Standardization of uveitis nomenclature for reporting clinical data. Results of the First International Workshop. *Am J Ophthalmol*. 2005;140(3):509-16.
- Kesav N, Palestine AG, Yaloo MY, et al. Current management of uveitis-associated ocular hypertension and glaucoma. *Surv Ophthalmol*. 2020;65(4):397-407.
- Centers for Disease Control and Prevention. Sexually transmitted disease surveillance 2019. [www.cdc.gov/std/statistics/2019/default.htm](http://www.cdc.gov/std/statistics/2019/default.htm). Accessed July 29, 2021.
- Majumder PD, Ghosh A, Biswas J. Infectious uveitis: an enigma. *Middle East Afr J Ophthalmol*. 2017;24(1):2-10.
- Radhakrishnan R. MedicineNet. What happens if syphilis is left untreated? August 26, 2020. [www.medicinenet.com/what\\_happens\\_if\\_syphilis\\_is\\_left\\_untreated/article.htm](http://www.medicinenet.com/what_happens_if_syphilis_is_left_untreated/article.htm). Accessed July 29, 2021.
- Davis JL. Ocular syphilis. *Curr Opin Ophthalmol*. 2014;25(6):513-8.
- Koundanya VV, Tripathy K. StatPearls [Internet]. Syphilis ocular manifestations. February 14, 2021. [www.ncbi.nlm.nih.gov/books/NBK558957/](http://www.ncbi.nlm.nih.gov/books/NBK558957/). Accessed July 29, 2021.
- Mattei PL, Beachkofsky TM, Gilson RT, et al. Syphilis: a reemerging infection. *Am Fam Physician*. 2012;86(5):433-40.
- Centers for Disease Control and Prevention. Syphilis – CDC fact sheet. [www.cdc.gov/std/syphilis/stdfact-syphilis.htm](http://www.cdc.gov/std/syphilis/stdfact-syphilis.htm). Accessed July 29, 2021.
- Workowski KA, Bolan GA. Centers for Disease Control and Prevention. Sexually transmitted diseases treatment guidelines. June 5, 2015. [www.cdc.gov/mmwr/preview/mmwrhtml/rr6403a1.htm](http://www.cdc.gov/mmwr/preview/mmwrhtml/rr6403a1.htm). Accessed July 29, 2021.
- Centers for Disease Control and Prevention. Trends in tuberculosis, 2019. [www.cdc.gov/tb/publications/factsheets/statistics/tbtrends.htm](http://www.cdc.gov/tb/publications/factsheets/statistics/tbtrends.htm). Accessed July 29, 2021.
- Gupta V, Gupta A, Rao NA. Intraocular tuberculosis – an update. *Surv Ophthalmol*. 2007;52(6):561-87.
- Gupta V, Shouhry SS, Mahajan S, et al. Clinics of ocular tuberculosis. *Ocul Immunol Inflamm*. 2015;23(1):14-24.
- Bansal R, Gupta A, Gupta V, et al. Tubercular serpiginous-like choroiditis presenting as multifocal serpiginoid choroiditis. *Ophthalmology*. 2012;119(11):2334-42.
- Agarwal A, Aggarwal K, Gupta V. Infectious uveitis: an Asian perspective. *Eye (Lond)*. 2019;33(1):50-65.
- Trajman A, Steffen RE, Menzies D. Interferon-gamma release assays versus tuberculin skin testing for the diagnosis of latent tuberculosis infection: an overview of the evidence. *Pulm Med*. 2013;2013:601737.
- Gupta A, Sharma A, Bansal R, et al. Classification of intraocular tuberculosis. *Ocul Immunol Inflamm*. 2015;23(1):7-13.
- Bansal R, Gupta A, Gupta V, et al. Role of anti-tubercular therapy in uveitis with latent/manifest tuberculosis. *Am J Ophthalmol*. 2008;146(5):772-9.
- Agrawal R, Gupta B, Gonzalez-Lopez JJ, et al. The role of anti-tubercular therapy in patients with presumed ocular tuberculosis. *Ocul Immunol Inflamm*. 2015;23(1):40-6.
- Reich M, Mackensen F. Ocular toxoplasmosis: background and evidence for antibiotic prophylaxis. *Curr Opin Ophthalmol*. 2015;26(6):498-505.
- Weinberg RS. AAO. Ocular involvement in Lyme disease. November 5, 2008. [www.aao.org/current-insight/ocular-involvement-in-lyme-disease](http://www.aao.org/current-insight/ocular-involvement-in-lyme-disease). Accessed July 29, 2021.
- Rosenbaum JT, Rahn DW. Prevalence of Lyme disease among patients with uveitis. *Am J Ophthalmol*. 1991;112(4):462-3.
- Centers for Disease Control and Prevention. Lyme disease. [www.cdc.gov/lyme](http://www.cdc.gov/lyme). Accessed July 29, 2021.
- Mead P, Petersen J, Hinckley A. Updated CDC recommendation for serologic diagnosis of Lyme disease. *MMWR Morb Mortal Wkly Rep*. 2019;68(32):703.
- Chan NSW, Chee SP. Demystifying viral anterior uveitis: a review. *Clin Exp Ophthalmol*. 2019;47(3):320-33.
- Jones NP. Fuchs' heterochromic uveitis: a reappraisal of the clinical spectrum. *Eye (Lond)*. 1991;5:649-61.
- Quentin CD, Reiber H. Fuchs heterochromic cyclitis: rubella virus antibodies and genome in aqueous humor. *Am J Ophthalmol*. 2004;138(1):46-54.
- Rothova A. The riddle of Fuchs heterochromic uveitis. *Am J Ophthalmol*. 2007;144(3):447-8.
- Birnbaum AD, Tessler HH, Schultz KL, et al. Epidemiologic relationship between Fuchs heterochromic iridocyclitis and the United States rubella vaccination program. *Am J Ophthalmol*. 2007;144(3):424-8.
- Chee SP, Jap A. Presumed Fuchs heterochromic iridocyclitis and Posner-Schlossman syndrome: comparison of cytomegalovirus-positive and negative eyes. *Am J Ophthalmol*. 2008;146(6):883-9.
- Bloch-Michel E, Dussaix E, Cerqueti P, et al. Possible role of cytomegalovirus infection in the etiology of the Posner-Schlossmann syndrome. *Int Ophthalmol*. 1987;11(2):95-6.
- Tabbara KF, Chavis PS. Herpes simplex anterior uveitis. *Int Ophthalmol Clin*. 1998;38(4):137-47.
- Liesegang TJ, Melton LJ, Daly PJ, et al. Epidemiology of ocular herpes simplex. Natural history in Rochester, Minn, 1950 through 1982. *Arch Ophthalmol*. 1989;107(8):1155-9.
- Doran M. AAO. Understanding and treating viral anterior uveitis. September 2009. [www.aao.org/eyenet/article/viral-anterior-uveitis](http://www.aao.org/eyenet/article/viral-anterior-uveitis). Accessed July 29, 2021.
- Centers for Disease Control and Prevention. Dengue. [www.cdc.gov/dengue](http://www.cdc.gov/dengue). Accessed July 29, 2021.
- Lim WK, Mathur R, Koh A, et al. Ocular manifestations of dengue fever. *Ophthalmology*. 2004;111(11):2057-64.
- Chan DPL, Teoh SCB, Tan CSH, et al. Ophthalmic complications of dengue. *Emerg Infect Dis*. 2006;12(2):285-9.
- Jabs DA, Busingye F. Approach to the diagnosis of the uveitides. *Am J Ophthalmol*. 2013;156(2):228-36.

## OPTOMETRIC STUDY CENTER QUIZ

To obtain continuing education credit through the Optometric Study Center, complete the test form on the following page and return it with the \$35 fee to: Jobson Healthcare Information, LLC, Attn.: CE Processing, 395 Hudson Street, 3rd Floor New York, New York 10014. To be eligible, please return the card within three years of publication. You can also access the test form and submit your answers and payment via credit card online at [revieweducationgroup.com](http://revieweducationgroup.com). You must achieve a score of 70 or higher to receive credit. Allow four weeks for processing. For each Optometric Study Center course you pass, you earn 2 hours of credit. Please check with your state licensing board to see if this approval counts toward your CE requirement for relicensure.

- Which of the following ocular structures is not protected by the blood-retinal barrier?
  - Retina.
  - Optic nerve.
  - Iris.
  - Macula.
  - All structures are protected by the blood-retinal barrier.
- Which of the following is true regarding uveitis?
  - It is the leading cause of blindness in the world.
  - It is a very common eye disease.
  - It always involves the posterior segment of the eye.
  - It can affect people of all age groups.
- Which of the following is FALSE regarding the SUN Project?
  - It was formed by a group of glaucoma specialists.
  - The founding group met for the first time in 2004.
  - It served to standardize uveitis reporting at academic meetings and in the literature.
  - According to the group, if six to 15 anterior chamber cells are seen in the field of a 1mm x 1mm slit beam, the anterior chamber reaction should be classified as 1+.
- All of the following ocular complaints are consistent with a diagnosis of uveitis EXCEPT:
  - Photophobia.
  - Peripheral vision loss.
  - Floaters.
  - Blurred vision.
- Which medication is used to treat syphilis?
  - Prednisone.
  - Penicillin.
  - Doxycycline.
  - Ciprofloxacin.
- Which is NOT a sign of ocular syphilis?
  - Papillitis.
  - Chorioretinitis.
  - Vitritis.
  - All are signs of ocular syphilis.
- Which is true regarding the stages of systemic syphilis?
  - Ocular involvement is common in primary syphilis.
  - A chancre in primary syphilis does not resolve without treatment.
  - Most infections will remain in the latent stage.
  - Ocular syphilis is treated much differently than neurosyphilis.
- Which is FALSE about syphilis?
  - Syphilis is often called the "great imitator."
  - Syphilis rates have been declining in the United States.
  - Syphilis is spread through sexual contact.
  - Syphilis is treatable and preventable.
- The ocular structure most commonly affected in IOTB is \_\_\_\_\_.
  - The choroid.
  - The iris.
  - The anterior chamber.
  - The optic nerve.
- Which of the following is TRUE regarding TB?
  - Rates of infection are increasing in the United States.
  - Incidence is most common among American-born individuals.
  - Foreign-born TB patients in the United States are most commonly from Europe.
  - HIV infection increases the risk of TB coinfection.
- Which of the following is FALSE regarding TB?
  - Treatment is with a combination of four drugs.
  - Self-limiting pneumonia is the most common presentation of pulmonary TB.
  - Patients with extrapulmonary TB always have concomitant pulmonary infection.
  - Mycobacterium TB* is spread through aerosolized droplets.
- Which of the following medications is NOT used in the treatment of TB?
  - Ethambutol.
  - Isoniazid.
  - Cefalexin.
  - Rifampin.
- Which is the most common cause of anterior uveitis in the United States?
  - HSV.
  - CMV.
  - Dengue virus.
  - HLA-B27-associated uveitis.
- Which of the following is FALSE regarding viral anterior uveitis?
  - Iris involvement is common.
  - Many viruses can cause anterior uveitis and their clinic signs overlap.
  - IOP is decreased in viral uveitis.
  - All viral uveitis is self-limiting and treatment is not necessary.
- Which of the following may be detected in the work up in a patient with sarcoidosis?
  - Bilateral hilar adenopathy.
  - Elevated rheumatoid factor.
  - Elevated HSV-1 and IgG antibodies.
  - Radiological changes in the sacroiliac joints.
- All of the following medications are used in the treatment of viral uveitis EXCEPT:
  - Acyclovir.
  - Prednisolone acetate.
  - Doxycycline.
  - Timolol.
- For a patient with ocular pain, redness, vitreous haze and elevated IOP, which of the following additional findings would suggest a diagnosis of non-infectious uveitis?
  - Grayish-yellow choroidal lesions in the posterior pole.
  - A history of sarcoidosis.
  - Heterochromia.
  - Recent shingles.
- Which is FALSE regarding viral uveitis?
  - The incidence of Fuchs' uveitis syndrome decreased in the United States due to the rubella vaccination program.
  - PSS has been linked to cytomegalovirus.
  - Uveitis is often more severe in HZO than in HSZ uveitis.
  - Hypersensitivity of the cornea is a common finding.
- Which of the following is NOT associated with HZO?
  - Vesicular skin rash.
  - Corneal pseudodendrites.
  - Dacryoadenitis.
  - Anterior chamber cell and flare.
- Which of the following are clinic signs of anterior uveitis?
  - Ciliary flush.
  - KPs.
  - Corneal edema.
  - All of the above.



# Examination Answer Sheet

**What to Do When You See Uveitis**  
Valid for credit through August 15, 2024

**Online:** This exam can be taken online at [revieweducationgroup.com](http://revieweducationgroup.com). Upon passing the exam, you can view your results immediately and download a real-time CE certificate. You can also view your test history at any time from the website.

**Directions:** Select one answer for each question in the exam and completely darken the appropriate circle. A minimum score of 70% is required to earn credit.

**Mail to:** Jobson Healthcare Information, LLC, Attn.: CE Processing, 395 Hudson Street, 3rd Floor New York, New York 10014

**Payment:** Remit \$35 with this exam. Make check payable to Jobson Healthcare Information, LLC.

**Credit:** This course is COPE approved for 2 hours of CE credit. Course ID is 73692-SD.

**Processing:** There is a four-week processing time for this exam.

*Jointly provided by Postgraduate Institute for Medicine and Review Education Group. Salus University has sponsored the review and approval of this activity.*

**Answers to CE exam:**

1.  A  B  C  D
2.  A  B  C  D
3.  A  B  C  D
4.  A  B  C  D
5.  A  B  C  D
6.  A  B  C  D
7.  A  B  C  D
8.  A  B  C  D
9.  A  B  C  D
10.  A  B  C  D
11.  A  B  C  D
12.  A  B  C  D
13.  A  B  C  D
14.  A  B  C  D
15.  A  B  C  D
16.  A  B  C  D
17.  A  B  C  D
18.  A  B  C  D
19.  A  B  C  D
20.  A  B  C  D

**Post-activity evaluation questions:**

Rate how well the activity supported your achievement of these learning objectives. 1=Poor, 2=Fair, 3=Neutral, 4=Good, 5=Excellent

21. Describe the various causes of uveitis. ① ② ③ ④ ⑤
22. Identify and diagnose a patient with uveitis. ① ② ③ ④ ⑤
23. Determine if a case of uveitis is infectious or the result of a systemic disease. ① ② ③ ④ ⑤
24. Discuss systemic etiologies of uveitis. ① ② ③ ④ ⑤
25. Based upon your participation in this activity, do you intend to change your practice behavior? (Choose only one of the following options.)
  - A I do plan to implement changes in my practice based on the information presented.
  - B My current practice has been reinforced by the information presented.
  - C I need more information before I will change my practice.
26. Thinking about how your participation in this activity will influence your patient care, how many of your patients are likely to benefit? (please use a number):
27. If you plan to change your practice behavior, what type of changes do you plan to implement? (Check all that apply.)
 

<input type="checkbox"/> A Apply latest guidelines	<input type="checkbox"/> D Change in current practice for referral	<input type="checkbox"/> G More active monitoring and counseling
<input type="checkbox"/> B Change in diagnostic methods	<input type="checkbox"/> E Change in vision correction offerings	<input type="checkbox"/> H Other, please specify: _____
<input type="checkbox"/> C Choice of management approach	<input type="checkbox"/> F Change in differential diagnosis	
28. How confident are you that you will be able to make your intended changes?
  - A Very confident
  - B Somewhat confident
  - C Unsure
  - D Not confident
29. Which of the following do you anticipate will be the primary barrier to implementing these changes?
30. Additional comments on this course: \_\_\_\_\_
 

<input type="checkbox"/> A Formulary restrictions	<input type="checkbox"/> D Insurance/financial issues	<input type="checkbox"/> G Patient adherence/compliance
<input type="checkbox"/> B Time constraints	<input type="checkbox"/> E Lack of interprofessional team support	<input type="checkbox"/> H Other, please specify: _____
<input type="checkbox"/> C System constraints	<input type="checkbox"/> F Treatment related adverse events	

**Please retain a copy for your records. Please print clearly.**

First Name

Last Name

E-Mail

The following is your:  Home Address  Business Address

Business Name

Address

City  State

ZIP

Telephone #  -  -

Fax #  -  -

OE Tracker Number

**Rate the quality of the material provided:**

1=Strongly disagree, 2=Somewhat disagree, 3=Neutral, 4=Somewhat agree, 5=Strongly agree

31. The content was evidence-based. ① ② ③ ④ ⑤
32. The content was balanced and free of bias. ① ② ③ ④ ⑤
33. The presentation was clear and effective. ① ② ③ ④ ⑤

By submitting this answer sheet, I certify that I have read the lesson in its entirety and completed the self-assessment exam personally based on the material presented. I have not obtained the answers to this exam by any fraudulent or improper means.

Signature \_\_\_\_\_ Date \_\_\_\_\_ Lesson 121517 RO-OSC-0821



EDITED BY JOSEPH P. SHOVLIN, OD

## CORNEA AND CONTACT LENS Q+A

# Pressure Cooker

*Avoid sclerals in progressive glaucoma to lower risk of IOP rise.*

**Q** I have a graft patient with advanced glaucoma who needs a scleral lens. Should I be concerned about an increase in IOP? If so, what are my other options?

**A** The relationship between scleral lens wear and IOP is well documented through a multitude of studies, according to Langis Michaud, OD, professor at the University of Montreal.

### Research Findings

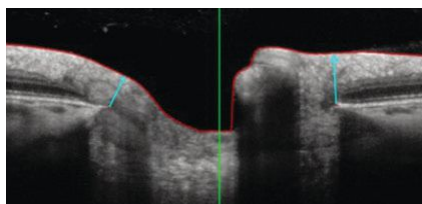
A 2016 study hypothesized that sclerals can contribute to increased IOP through compression of the episcleral veins and/or Schlemm's canal.<sup>1</sup> This implies that IOP is restored as soon as the lens is removed or the compression is released.

One review reported a 5mm Hg to 30mm Hg increase in IOP following one hour of glass scleral use.<sup>2</sup> Another established that glaucoma patients experience a pressure spike upon scleral lens removal and a longer recovery time.<sup>3</sup>

One report found no IOP variation at lens removal as measured by air tonometer.<sup>4</sup> Another used a pneumotonometer during lens wear (one to two hours) and observed high inter-subject variability, but little increase on average.<sup>5</sup> With a Tonopen (Reichert), researchers found a <1mm Hg increase in IOP after PROSE lens wear.<sup>6</sup>

A rebound tonometer resulted in a 5mm Hg gain (one patient spiked 15mm Hg) after eight hours of lens wear.<sup>7</sup> These results match another recent study that used a Diaton transpalpebral tonometer (Escalon Medical) during four hours of lens wear and documented an IOP increase of 5mm Hg regardless of the lens diameter.<sup>8</sup>

A study applying Goldmann tonometry through a fenestrated scleral



Arrows illustrate the MRW assessment.

found IOP increase of 4mm Hg in the minutes following lens application.<sup>9</sup> Another found no variation using a Schiøtz tonometer (Medline) applied on the conjunctiva during four hours of wear.<sup>10</sup>

The most interesting studies are coming from optic nerve head observation during lens wear, says Dr. Michaud. One found minimum rim width (MRW) thinning during six hours of scleral lens wear, which objectively translates into an IOP increase.<sup>11</sup> Another study also looked at MRW but took into account diurnal physiological variation as well.<sup>12</sup> The team found that IOP increased significantly (average 5mm Hg) over six hours of lens wear.<sup>12</sup>

### Clinical Takeaways

Due to conflicting and inconsistent findings, no formal conclusion regarding scleral lens wear and IOP changes can be made at this point, notes Dr. Michaud. Nonetheless, these elements must be considered:

- Solid trends prove that IOP can rise during scleral lens wear (range of 0mm Hg to 30mm Hg with an average of 5mm Hg over four to six hours of use).
- High inter-subject variability means we cannot predict who will spike and who will remain stable.
- Keratoconus may also occur, as there is a higher prevalence of normotensive glaucoma in this patient population.<sup>13</sup>

• Lens design/diameter likely does not influence the outcome. Most lenses land around the same area, and the lens weight is not distributed along the conjunctiva with a larger scleral lens.

- Longitudinal studies are needed to evaluate IOP in different populations.
- Scleral lenses are not likely to induce glaucoma in a normal patient. But close monitoring is recommended.

Knowing this information, remain very cautious when caring for severe glaucoma patients, warns Dr. Michaud. He suggests exploring other ways to compensate for corneal irregularities and restore visual acuity before considering scleral lenses, including hybrid and gas permeable lenses.

If scleral lenses are fitted as a last resort, Dr. Michaud recommends limiting lens compression through toric and flatter peripheral curves, fenestrations, channels, etc. He adds to pay close attention to the optic nerve profile and visual fields. As a final thought, he emphasizes that IOP measurement at lens removal is not indicative of what is happening during wear. ■

1. McMonnies CW. A hypothesis that scleral contact lenses could elevate intraocular pressure. *Clin Exp Optom.* 2016;99(6):594-6.

2. Hugert A. Increase of the intraocular pressure when using contact glasses. *Acta Ophthalmol.* 1951;29(4):475-81.

3. Huggert A. The intraocular pressure in glaucomatous eyes, following the use of contact lenses. *Acta Ophthalmol (Copenh).* 1953;31(2):141-52.

4. Vincent SJ, Alonso-Caneiro D, Collins MJ. Evidence on scleral contact lenses and intraocular pressure. *Clin Exp Optom.* 2017;100(1):87-8.

5. Nau CB, Schomack MM, McLaren JW, et al. Intraocular pressure after 2 hours of small-diameter scleral lens wear. *Eye Contact Lens.* 2016;42(6):350-3.

6. Shahnazi KC, Isozaki VL, Chiu GB. Effect of scleral lens wear on central corneal thickness and intraocular pressure in patients with ocular surface disease. *Eye Contact Lens.* 2020;46(6):341-7.

7. Aitsebaomo AP, Wong-Powell J, Miller W, et al. Influence of scleral lens on intraocular pressure. *JCLRS.* April 22, 2019. [Epub ahead of print].

8. Michaud L, Samaha D, Giasson CJ. Intra-ocular pressure variation associated with the wear of scleral lenses of different diameters. *Cont Lens Anterior Eye.* 2019;42(1):104-10.

9. Cheung SY, Collins MJ, Vincent SJ. The impact of short-term fenestrated scleral lens wear on intraocular pressure. *Cont Lens Anterior Eye.* 2020;43(6):585-8.

10. Obinwanne CJ, Echendu DC, Agbonlahor O, et al. Changes in scleral tonometry and anterior chamber angle after short-term scleral lens wear. *Optom Vis Sci.* 2020;97(9):720-5.

11. Walker MK, Pardon LP, Redfern R, et al. IOP and optic nerve head morphology during scleral lens wear. *Optom Vis Sci.* 2020;97(9):661-8.

12. Samaha D, Michaud L. Bruch membrane opening minimum rim width changes during scleral lens wear. *Eye Contact Lens.* 2021;47(5):295-300.

13. Cohen EJ, Myers JS. Keratoconus and normal-tension glaucoma: a study of the possible association with abnormal biomechanical properties as measured by corneal hysteresis. *Cornea.* 2010;29(9):955-70.

About  
Dr. Shovlin

**Dr. Shovlin**, a senior optometrist at Northeastern Eye Institute in Scranton, PA, is a fellow and past president of the American Academy of Optometry and a clinical editor of *Review of Optometry* and *Review of Cornea & Contact Lenses*. He consults for Kala, Aerie, AbbVie, Novartis, Hubble and Bausch + Lomb and is on the medical advisory panel for Lentechs.

# THE **WORLD SIGHT DAY CHALLENGE** IS COMING

## September and October

WE THANK OUR MAJOR  
CORPORATE DONORS  
FOR THEIR SUPPORT

CooperVision

Vision Source

Bausch+Lomb

PECAA

Jobson Optical Group

Carl Zeiss Vision

Eye Recommend

OSI Group

PentaVision

Invision

ABB Optical Group

Alcon Foundation

Allergan Foundation

Essilor

Healthy Vision Association

Hoya Canada

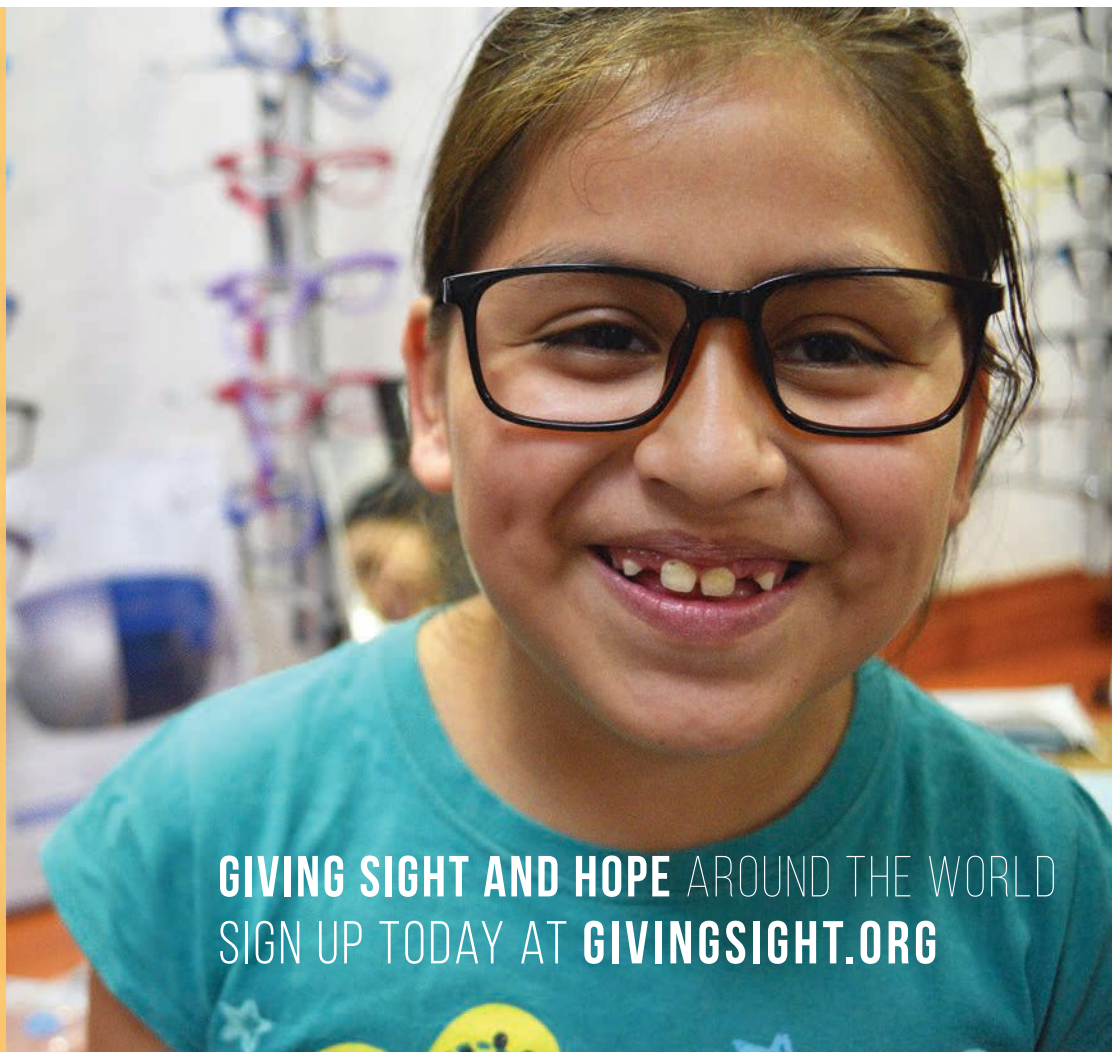Johnson & Johnson Vision  
Canada

LensFerry

National Vision

Terracycle

WestGroupe



**GIVING SIGHT AND HOPE** AROUND THE WORLD  
SIGN UP TODAY AT **GIVINGSIGHT.ORG**



OPTOMETRY  
**giving sight**

THANK YOU FOR YOUR SUPPORT!

To get started, go to  
**givingsight.org** or contact us at:

**USA** 303 526 0430  
usa@givingsight.org

**CANADA** 403 670 2619  
canada@givingsight.org





BY JOSEPH W. SOWKA, OD

## THERAPEUTIC REVIEW

# A Sharp Stick to the Eye

*Triage is important for this common injury.*

**A** 71-year-old man presented urgently with a bloody left eye that had been injured that morning. He had been pruning an areca palm tree when he bent down and caught the sharp end of a new shoot on his left eye. He immediately knew that it had done damage, especially when his eye started bleeding. He initially went to an Urgent Care walk-in clinic, where the physician there directed him immediately to see an eye care practitioner instead.

When he arrived, he reported significant ocular pain OS with tearing but no photophobia. His uncorrected visual acuity (VA) was 20/40 OD and 20/25 OS. His pupils were normal without afferent defect. Biomicroscopy revealed a corneal laceration with bare sclera visible. There were numerous dirt specs and dried blood

within the wound area. There was also a mild hemorrhagic oozing in the wound. There appeared to be no breach of the sclera. The anterior chamber was fully formed and deep with no cells or flare. Intraocular pressure was 17mm Hg OS.

A dilated fundus examination showed no abnormalities and/or evidence of globe rupture or perforation. While potentially ominous due to the type of trauma that could have easily perforated the globe, the patient was fortunate in that he escaped with only a conjunctival laceration.

### Wear and Tear

Conjunctival lacerations result from mechanical tearing of the tissue.<sup>1-3</sup> Patients report a history of ocular injury from a sporting accident, assault, fall, poke, child-or-pet scratch or self-induced trauma such as eye rubbing or contact lens removal. Symptoms include variable levels of blepharospasm and discomfort, foreign body sensation, tearing and possibly photophobia if there is substantial ocular inflammation.<sup>4</sup> Signs include sectoral conjunctival injection, subconjunctival hemorrhage

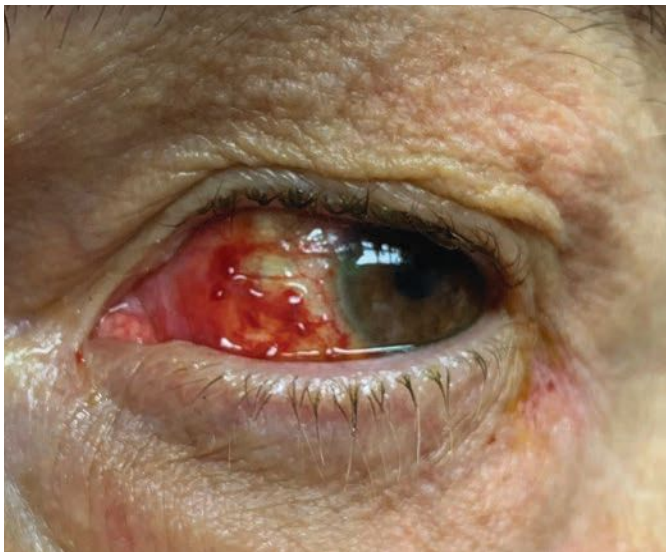and a visible conjunctival defect with retracted conjunctival edges and bare sclera.

The palpebral portion of the conjunctiva is tightly adherent to the eyelid, while the bulbar portion is loosely adherent, giving the globe mobility. The conjunctiva is reflected upon itself so that it can stretch with ocular excursion. The conjunctiva is composed of nonkeratinized, stratified, squamous epithelium overlying stromal tissue. Because the conjunctiva is far less innervated than the cornea, conjunctival injuries are less symptomatic than corneal abrasions of the same severity. Given its position, the bulbar conjunctiva has the greatest chance of sustaining injury.<sup>4</sup>

In conjunctival laceration, the tissue is torn and split, revealing bare sclera beneath. In these cases, the trauma itself acts as an antigen and sets off an inflammatory cascade resulting in vasodilation and edema of the involved and surrounding tissues.<sup>4</sup> If the injury is more substantial, the sclera may be breached, and dark uveal tissue may extrude through. This takes the issue in a different, more severe direction.

Treatment for conjunctival laceration begins with history, looking for possible indication of globe perforation. Assess VA initially. If discomfort and blepharospasm is intense, administer a drop of topical anesthetic. The examination should proceed in a logical fashion from external adnexa to dilated fundus examination.

Evert the eyelids and scrutinize the fornices for foreign material. Instill fluorescein dye (preferably without anesthetic) to assist in identifying defects. The lesion should be photographed, if possible, and measured using the height and width of the biomicroscope beam.



**Mild hemorrhagic oozing in the laceration wound.**

**About Dr. Sowka**

Dr. Sowka is an attending optometric physician at Center for Sight in Sarasota, FL, where he focuses on glaucoma management and neuro-ophthalmic disease. He is a consultant and advisory board member for Carl Zeiss Meditec and Bausch Health.

Perform close observation of the sclera to assess for possible globe penetration, especially if the injury came from a sharp object.<sup>5,6</sup> If particulate matter is present, clean the lesion after instilling anesthetic. Observe the anterior chamber for any evidence of inflammation. Most importantly, assess and record the depth of the anterior chamber, as flattening or shallowing indicates a globe perforation.

Use forceps or moistened cotton-tipped applicator with topical anesthesia to manipulate the ragged areas of conjunctiva back into position. Bleeding can be arrested with light, direct pressure. If possible, tonometry should be performed as hypotony also may indicate a globe perforation. Complete a dilated examination (either at time of initial evaluation or at follow-up) to rule out any posterior effects from the trauma.

## Treatment

The eye can be either patched or left open. If the eye is not patched, treatment includes topical broad-spectrum antibiotic solution QID. Consider topical cycloplegia, either applied in office or prescribed QD-BID, depending upon the severity of the injury and degree of inflammatory discomfort. Additionally, prescribe a topical nonsteroidal anti-inflammatory (NSAID) QD-QID for local analgesia.

Topical antibiotic ointments can be used for increased contact time and extra comfort cushioning but are often not tolerated well as they blur vision. Topical steroids have the potential to slow healing and, in the setting of trauma, may be postponed until initial tissue healing takes place. Topical antibiotic/steroid combination drops and/or ointments are a reasonable alternative if inflammation must be addressed on the day of the injury.

Small conjunctival lacerations (<1cm) will heal within a week without special attention. Larger lacerations, after appositional placement of the tissue edges, can be remediated with antibiotic ointment and pressure

patching for 24 hours. Repair with either sutures or tissue glue is only necessary for only the largest lesions (> 2cm). Bed rest, limited activity, cold compresses, artificial tear drops and over-the-counter analgesics such as acetaminophen or ibuprofen can relieve acute pain for a day or so. Acetaminophen can be recommended in cases where there is bleeding as it does not encourage antiplatelet effects.

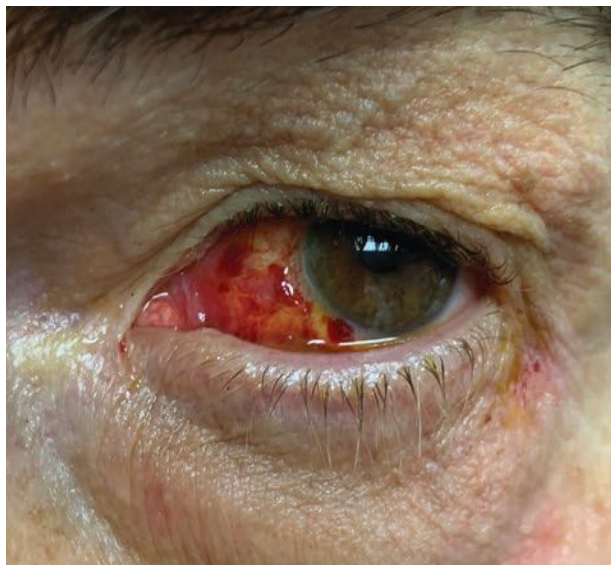Conjunctival lacerations without globe perforation tend to be uncomfortable and unpleasant but will resolve with only a modicum of care and triage.

## Laceration Care

For the patient presented here, he was carefully assessed for a globe perforation due to the nature of his injury. Following topical anesthesia, the conjunctival edges were manipulated to fully assess the underlying sclera, which was intact. His IOP was measured, and anterior chamber was assessed to eliminate the possibility of hypotony and shallowing, both of which would indicate a globe perforation. A dilated exam was also performed to rule out tears, detachments and other untoward traumatic effects.

After this assessment was performed, all dirt and blood were lavaged out with sterile saline wash. The edges of the abrasion were manipulated together with a cotton-tipped applicator. He was prescribed topical bacitracin-polymyxin B ointment QID. He was not patched or cyclopleged. Acetaminophen was recommended for pain. A 24-hour follow-up telephone call revealed that he felt much better and that the acetaminophen helped sufficiently.

When he returned for follow-up



**Be sure to lavage all dirt and blood with sterile saline wash.**

one week later, the conjunctival laceration was well healed with mild residual subconjunctival hemorrhage. He was instructed to stop all medications and to wear eye protection when gardening as the next time he might not be as fortunate with a similar injury.

## Takeaways

Conjunctival lacerations are minor problems that typically resolve with minimal intervention, yet patients of ten present with great anxiety. Hemorrhaging causes great concern, even though there may be little pain or other symptoms. While it is important to rule out a penetrating injury, you can safely reassure most patients that they have a simple “cut” on their eye and that it will heal in a few days. ■

1. Gordon KD. The incidence of eye injuries in Canada. *Can J Ophthalmol.* 2012;47(4):351-3.

2. Leinert J, Griffin R, Blackburn J, McGwin G Jr. The epidemiology of lawn trimmer injuries in the United States: 2000-2009. *J Safety Res.* 2012;43(2):137-9.

3. Locke LC. Conjunctival abrasions and lacerations. *J Am Optom Assoc.* 1987;58(6):488-93.

4. Murthy SI, Das S, Deshpande P, et al. Differential diagnosis of acute ocular pain: teleophthalmology during COVID-19 pandemic—a perspective. *Indian J Ophthalmol.* 2020; 68(7): 1371-9.

5. Freidman NJ, Kaiser PK. The conjunctiva. In: Freidman NJ, Kaiser PK. *Essentials of Ophthalmology.* Philadelphia, PA, Saunders Inc; 2007:149-59.

6. Muller L, Kohlen T. Scleral and corneal laceration with iris prolapse caused by an eagle claw. *Graefes Arch Clin Exp Ophthalmol.* 2005;243(4):377-9.



BY PAUL M. KARPECKI, OD  
CHIEF CLINICAL EDITOR

## OCULAR SURFACE REVIEW

# Fighting Fungal Keratitis

*Though rare, this virulent infection can be mistaken for more benign varieties, with potentially devastating results.*

**K**eratitis is a rather nonspecific term and one we should try to move away from in pursuit of greater specificity, as inflammation of the cornea can be caused by injuries, infection by numerous organisms, countless diseases and even contact lens overwear. Though often mild and temporary, some types can be severe and ultimately lead to permanent vision loss. Fungal keratitis (FK) is a challenging diagnosis, and if its identification and treatment are delayed or incorrect, the sequelae can be irreversible. Practitioners should maintain a high level of clinical suspicion in these cases and know how to safely and effectively manage cases of FK.

## Causes

Infectious or microbial keratitis can be due to bacteria, viruses (*e.g.*, HSV), protozoa (most notably *Acanthamoeba*) or fungi. It has been reported that FK

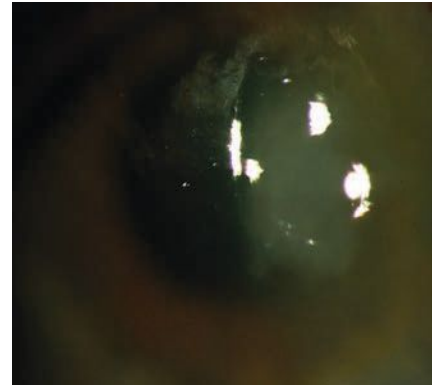
is more virulent and damaging than bacterial disease.<sup>1</sup> Trauma is a major factor for FK in developing countries and is often accompanied by a microorganism invasion that leads to corneal surface changes and immune-mediated inflammation, causing tissue necrosis. The deeper fungi penetrate in the stroma, the more extensive tissue damage, scarring and corneal opacification become. Early diagnosis and treatment are imperative to avoid sight-threatening complications.

The most common fungi in keratitis are filamentous, such as *Fusarium* and *Aspergillus*, or yeast-like fungi, such as *Candida*. The prevalence of specific agents is directly related to geography, and FK often occurs in tropical and subtropical regions.

In the United States, 30,000 new cases are reported annually with *Candida* and *Aspergillus* being the most common causes.<sup>2</sup> *Fusarium* is more common in southern states such as Florida.<sup>3,4</sup> There has also been a general increase in filamentous FK cases in contact lens wearers.<sup>5,6</sup>

## Presentation

Patients with keratitis will report a sudden onset of pain, photophobia, discharge and reduced vision with an inflamed, hyperemic eye and an opacity suggestive of an ulcer. In trauma involving vegetative matter or in contact



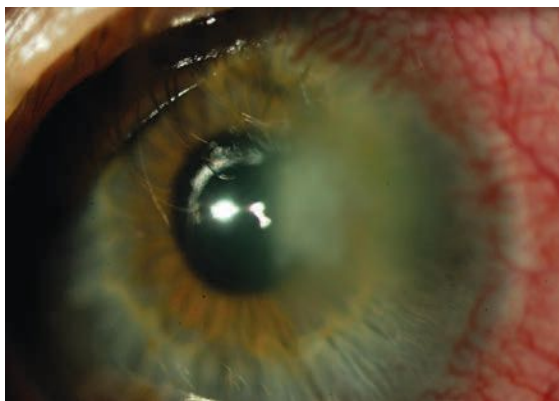
**FK can lead to corneal scarring, glaucoma and endophthalmitis.**

lens wearers, practitioners should have a high degree of suspicion. Corneal ulcers that do not respond to broad-spectrum antibiotics, centrally located infiltrates and/or the presence of satellite lesions are signs that should raise a red flag to the possibility of a mycotic agent.

Due to the challenges in making the differential diagnosis based on traditional features, cultures may be necessary in suspected FK. I consider the one-two-three rule when determining the need for a culture or comanagement with a cornea specialist: if the ulcer is 1mm from the visual axis, if there are two or more infiltrates (satellite lesions or multiple infiltrates are an indication of fungal causes) and if an infiltrate 3mm or larger is present.

## Slit Lamp Exam

Look for evidence of ocular surface disease, determine the amount and type of secretions and assess lid swelling. The upper eyelid should be everted to ensure there is no retained foreign body. The size and depth of the lesion as well as the presence of satellite lesions should be ascertained. Note any anterior chamber reaction and especially evidence of hypopyon,

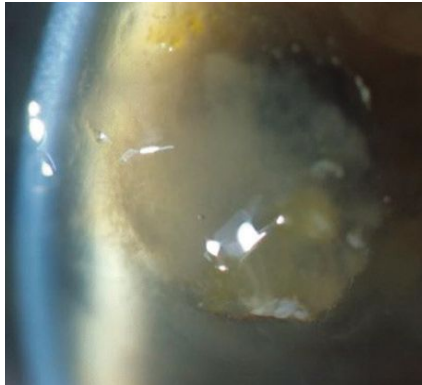


**Take note of any anterior chamber reaction, which can occur in the presentation of FK.**

About  
Dr. Karpecki

Dr. Karpecki is medical director for Keplr Vision and the Dry Eye Institutes of Kentucky and Indiana. He is the Chief Clinical Editor for *Review of Optometry* and chair of the New Technologies & Treatments conferences. A fixture in optometric clinical education, he consults for a wide array of ophthalmic clients, including ones discussed in this article. Dr. Karpecki's full disclosure list can be found in the online version of this article at [www.reviewofoptometry.com](http://www.reviewofoptometry.com).





**FK may be more virulent and damaging than bacterial disease.**

which can occur in an FK presentation. If there is a vitreous reaction, intraocular spread of the disease may be likely.

Under the slit lamp, a lesion might be similar in appearance to an unhealed corneal abrasion with scant infiltrates and no discharge. Over time, an FK ulcer will develop thicker infiltrates and fuzzy margins. Redness and periocular edema are also common and combined with a history of trauma, especially with vegetable matter, ocular surface disease or chronic use of topical steroids, should alert the practitioner to the possibility of a mycotic etiology.

## Treatment

It is crucial to avoid steroids (including combination antibiotic/steroid agents) until the true etiology is determined. In the meantime, patients can be started on a strong fluoroquinolone, and if there is a central lesion, alternate with a fortified antibiotic—ideally vancomycin.

In a contact lens wearer, where *Pseudomonas* is a possibility, I favor fortified tobramycin; otherwise, fortified vancomycin. Continue this regimen every hour on the first day depending on severity. Cycloplegics can be added when there is significant pain. The reason for beginning with an antibacterial, even in suspicious cases,

is because most MK looks similar in initial presentation and the vast majority is bacterial.

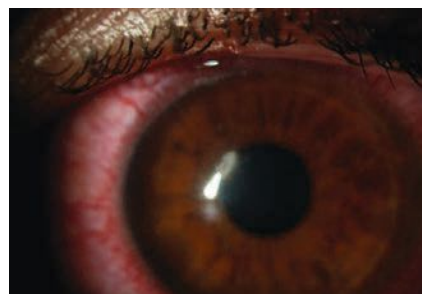
If the culture indicates FK, natamycin (Natacyn, Eyeavance Pharmaceuticals) is the first-line treatment. Natacyn is the first antifungal agent approved for FK and is considered the most effective medication against *Fusarium* and *Aspergillus*, binding preferentially to ergosterol on the fungal plasma membrane.<sup>7,8</sup>

Prior to the development of natamycin, the most commonly used antifungal was amphotericin B, a polyene; it is still used alone and in combination with natamycin with relatively good results. Voriconazole, a triazole antifungal agent derived from fluconazole, can be used either topically at 1% dilution or orally at 400mg twice a day and has been injected in the corneal stroma around the fungal lesion.<sup>9</sup>

A newer-generation oral triazole, posaconazole, has been successful in eradicating deep infections of resistant *Fusarium*.<sup>10</sup> Because subconjunctival antifungals can cause severe pain and potentially induce tissue necrosis, they are no longer used.

## Disease Course

The response in these patients is slow, with improvement seen in about three to six weeks. Continuing with the cycloplegic will help with pain and discomfort. Ibuprofen and/or acetaminophen can be added as necessary.



**Early diagnosis and treatment of FK are critical to avoid complications.**

Follow-up is daily until the epithelium closes, and once stable, patients can be seen weekly.

FK can lead to corneal scarring, corneal perforation, anterior segment disruption, glaucoma and even endophthalmitis, the latter potentially resulting in evisceration if it cannot be contained. There is severe visual loss in 26% to 63% of patients, and 15% to 20% may require evisceration. Penetrating keratoplasty is required in 31% to 38% of cases.<sup>11,12</sup> Because it can be a catastrophic disease, FK must be differentiated from other corneal conditions with similar presentation; especially its bacterial counterpart, which accounts for the majority of microbial corneal infections.

In my experience, numerous cases of FK are not diagnosed in a timely fashion, leading to irreversible damage, and it's important to obtain an accurate diagnosis and administer effective management. ■

1. Ansari Z, Miller D, Galor A. Current thoughts in fungal keratitis: diagnosis and treatment. *Curr Fungal Infect Rep*. 2013;7(3):209-18.
2. Pepose JS, Wilhelmus KR. Divergent approaches to the management of corneal ulcers. *Am J Ophthalmol*. 1992;114:630-2
3. Jones DB, Sexton R, Rebell G. Mycotic keratitis in South Florida: a review of thirty-nine cases. *Trans Ophthalmol Soc U K*. 1970;89:781-97.
4. Rosa RH, Jr, Miller D, Alfonso EC. The changing spectrum of fungal keratitis in south Florida. *Ophthalmology*. 1994;101:1005-13.
5. Bullock JD, Elder BL, Khamis HJ, Warwar RE. Effects of time, temperature, and storage container on the growth of *Fusarium* species: implications for the worldwide *Fusarium* keratitis epidemic of 2004-2006. *Arch Ophthalmol*. 2011;129:133-6.
6. Gower EW, Keay LJ, Oechsler RA, et al. Trends in fungal keratitis in the United States, 2001 to 2007. *Ophthalmology*. 2010;117:2263-7.
7. Natamycin approved—first U.S. drug for fungal keratitis. *FDA Drug Bull*. 1978;8:37-8.
8. Medoff G, Kobayashi GS. Strategies in the treatment of systemic fungal infections. *N Engl J Med*. 1980;302:145-55.
9. Sharma N, Goel M, Titilal JS, Vajpayee RB. Evaluation of intrastromal injection of voriconazole as a therapeutic adjunctive for the management of deep recalcitrant fungal keratitis. *Am J Ophthalmol*. 2008;146(1):56-9.
10. Tu EY, McCartney DL, Beatty RF, et al. Successful treatment of resistant ocular fusariosis with posaconazole (SCH-56592). *Am J Ophthalmol*. 2007;143:222-7.
11. AAO. Basic and Clinical Science Course. Section 8: External Disease and Cornea, 2015-2016.
12. Rondeau N, Bourcier T, Chaumeil C, et al. Fungal keratitis at the Centre Hospitalier National d'Ophthalmologie des Quinze-Vingts: retrospective study of 19 cases. *J Fr Ophtalmol*. 2002;25(9):890-6.

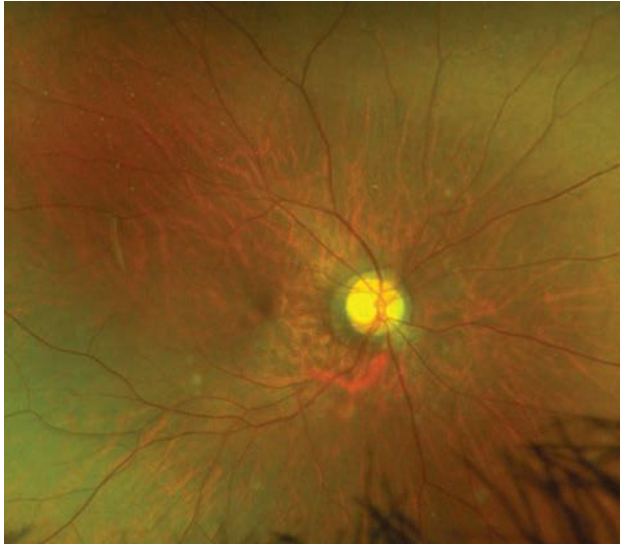
# Spotty Coverage

*A combination of imaging modalities helps reveal subtle changes that led to the diagnosis.*

**A** 53-year-old Hispanic female presented on an emergent basis with complaints of blurred vision and difficulty focusing in her right eye for the past two days. She reported blurry vision when she woke up, as well as seeing floaters and colored lights in the same eye. She denied any viral or flu-like illnesses, and her past ocular history was significant for trauma in the left eye as a child that resulted in a corneal scar. Because of this, she has always had a significant difference in refractive error between her two eyes but usually wears contact lenses, which helps. Her medical history is unremarkable.

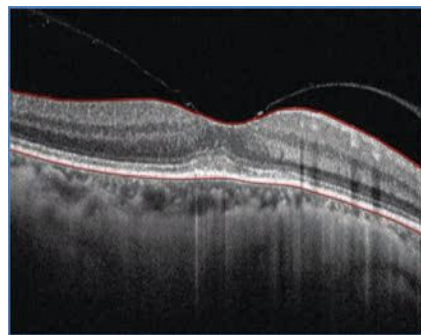
Upon exam, best-corrected visual acuity was 20/50 OD and 20/25 OS. Ocular motility and cover testing were normal. Confrontation visual fields were full to careful finger counting OU. Pupils were equally round and reactive to light; there was no afferent pupillary defect. The anterior segment of the right eye was unremarkable, and the left eye was significant for a geographic corneal scar that involved the axis.

Dilated fundus exam of the right eye showed a clear vitreous and nor-



**Fig. 1. Look carefully around the optic nerve and inferior arcade in this patient's right eye.**

mal-appearing optic nerves with good rim coloration and perfusion. The rest of the right eye findings appeared normal; however, on closer inspection there were peculiar changes (*Figure 1*). The left eye was completely normal. A fluorescein angiogram, OCT (*Figure 2*) and fundus autofluorescence (FAF)



**Fig. 2. SD-OCT through the macula of the left eye. What does it show?**

were performed (*Figure 3*). An image from late in the angiogram is available for review (*Figure 4*).

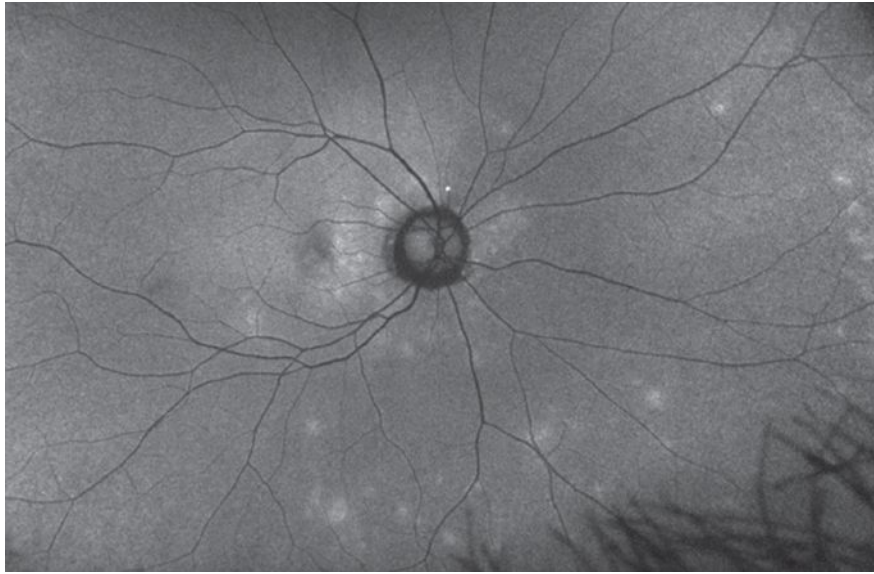
## Take the Retina Quiz

1. What does our patient have?
  - a. Acute macular neuroretinitis (AMN).
  - b. Multiple evanescent white dot syndrome (MEWDS).
  - c. Diffuse unilateral subacute neuroretinitis (DUSN).
  - d. Birdshot retinochoroiditis.
2. What is the most likely etiology?
  - a. Autoimmune.
  - b. Viral.
  - c. Infectious.
  - d. Inflammatory.
3. How should she be managed?
  - a. Observation.
  - b. Oral prednisone 80mg.
  - c. Anthelmintic drugs (thiabendazole).
  - d. Oral antiviral agent (Valtrex).
4. Which is the likely clinical course?
  - a. Progressive with total loss of vision.
  - b. Chronic and recurrent with loss of central vision.
  - c. Episodic recurrences with generally good vision.
  - d. Self-limited with good recovery of central vision.

*For answers, see page 89.*

## Discussion

There are multiple small gray-white “spots” scattered throughout the posterior pole in the right eye of our patient. They are subtle, but can more easily be seen along the inferior arcade below the macula and also extending to the nasal side of the optic nerve. These spots are more easily observed on the FAF, where numerous hyperfluorescent lesions can be seen scattered throughout the poste-



**Fig. 3. FAF image of the right eye. How is it different than the clinical photo?**

rior pole; many more than what we were able to see on the clinical exam and appear to be concentrated around the optic nerve and extend into the macula. The fluorescein angiogram shows late staining of the lesions and confirms that these are located in the outer retinal layers.<sup>1</sup>

So, what’s going on with our patient? She probably has a post-viral retinal syndrome—likely multiple evanescent white dot syndrome, or MEWDS as it is commonly known. MEWDS was originally described in 1983 as an acute, unilateral, multifocal retinopathy that affects young adults—most commonly females in 75% of reported cases.<sup>1</sup> Approximately one-third of patients report having a flu-like or viral illness before develop-

ing vision loss.<sup>1-3</sup> Our patient denied having any such symptoms, but she did report receiving the COVID-19 vaccine about six weeks earlier. When asked about travel history, she reported having gone to Colorado a few weeks prior.

The age of presentation of MEWDS ranges from 14 to 57 years old.<sup>1,2</sup> Patients most commonly complain of blurred vision in addition to photopsia or flashing lights, and clinical findings include small, multifocal gray-white spots that are mostly concentrated in the paramacular area. The macula will usually have a granular appearance with tiny yellow or orange dots in the center of the fovea that may disrupt the IS/OS junction.<sup>1-3</sup> Though we did not appreciate these changes

in the macula on clinical exam, she does have some mild disruption in the outer retinal layers on the OCT. Most patients with MEWDS will have a mild vitritis; this was not present in our patient. In addition to the blurred vision and photopsia, patients

may also have an enlarged blind spot on visual field testing which has emerged as part of the spectrum of MEWDS.

Imaging studies such as fluorescein angiography (FA), FAF and indocyanine green (ICG) may be helpful in establishing a MEWDS diagnosis. On fluorescein angiography the gray-white patches will hyperfluoresce in a “wreath-like” pattern, which was seen in our patient. FAF also shows hyperfluorescence, but interestingly ICG will show hypofluorescence spots. Both imaging modalities will reveal spots in greater numbers than what is seen on the clinical exam—we were able to clearly see this on the FAF. ICG was not performed, as we felt we had enough information to establish a diagnosis without needing to do additional testing.

The natural history of MEWDS is a complete recovery of the vision over a period of several weeks; therefore, no treatment is recommended. The white patches and granular appearance in the macula will slowly fade away over time and become less apparent. This can make the diagnosis even more challenging, depending on when the patient is seen.

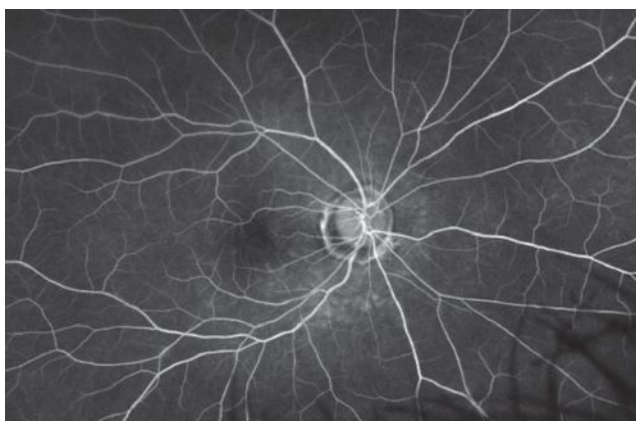The etiology of MEWDS remains a mystery. It is thought to be related to a viral illness, but so far none of the more common viral etiologies such as herpes zoster, herpes simplex, measles or mumps have been identified as a source. MEWDS is a disease of the photoreceptors and is almost completely reversible. It can be considered a “common cold” of the retina.<sup>3</sup>

Our patient presented with symptoms that began only two days earlier. She was seen one month later and her visual acuity had improved back to 20/20 and white spots were nearly gone. ■

1. Aaberg TM, Campo RV, Joffe L. Recurrences and bilaterality in the multiple evanescent white-dot syndrome. *Am J Ophthalmol.* 1985; 100:29–37.

2. Jampol LM, Sieving PA, Pugh D, et al. Multiple evanescent white dot syndrome. I. clinical findings. *Arch Ophthalmol.* 1984; 102:671–4.

3. Tavallali A, Yannuzzi LA. MEWDS, A common cold of the retina. *J Ophthalmic Vis Res.* 2017; 12(2):132-4.



**Fig. 4. Late frame of the FA of the right eye.**





EDITED BY DEREK N. CUNNINGHAM, OD,  
AND WALTER O. WHITLEY, OD, MBA

## SURGICAL MINUTE

# A Promising Offspring

*The new Synergy IOL combines the designs of two previous lenses in the same family.*

BY ETHAN ZIMMERMAN, OD

AUSTIN, TX

Innovations in presbyopia correction are popular in eye care today, and for good reason: the population of those over 65 is expected to almost double from 43.1 million in 2012 to 83.7 million in 2050.<sup>1</sup>

Intraocular lens (IOL) manufacturers have been pursuing this market for over 30 years, with varying degrees of success. No lens can give everyone complete freedom from glasses both at distance and near, but careful patient selection combined with surgical expertise can bring more people than ever closer to that goal for most visual tasks. Newer designs that have increased our success include improved aspheric lenses, methods to increase depth of focus and diffractive concentric rings in a trifocal design. The Tecnis Synergy IOL by Johnson & Johnson Vision is the latest entrant. Available internationally since 2019, it was recently FDA-approved for use in the US.

Synergy combines elements of two earlier J&J lenses—the Tecnis Multifocal (a trifocal) and the Tecnis Symphony (an extended depth of focus, or EDOF, lens). In this way, the Synergy aims at giving patients the widest range of continuous vision, as well as minimizing nighttime photopic phenomena that have been historically reported with most multifocal IOLs.

For a video of the procedure, read this article online at [www.reviewofoptometry.com](http://www.reviewofoptometry.com).

In a J&J-funded case series involving 103 patients undergoing bilateral implantation of the Synergy lens, 96% of subjects achieved 20/20 uncorrected binocular distance acuity and 91% uncorrected near acuity.<sup>2</sup> Mean monocular and binocular uncorrected near acuity was  $0.09 \pm 0.03$  logMAR and  $0.04 \pm 0.02$  logMAR, respectively. Mean mesopic uncorrected near acuity was a bit worse compared with photopic light conditions at  $0.14 \pm 0.03$  logMAR, as is typical with trifocal lens designs. Still, it is worth noting these differences tended to be smaller than with other trifocals.

By reducing reliance on diffractive optics, the Synergy may become a viable option for more patients. Historically, trifocal lens designs have required the most pristine eyes with virtually no ocular disease affecting the integrity of the visual pathway due to their diffractive nature. Non-diffractive EDOF lenses are more forgiving of comorbidities such as epiretinal membranes, Fuchs' dystrophy, irregular astigmatism and macular degeneration. Synergy does include diffractive optics but in a smaller range of focal lengths, relying instead on EDOF for improved near to intermediate vision; proponents say this

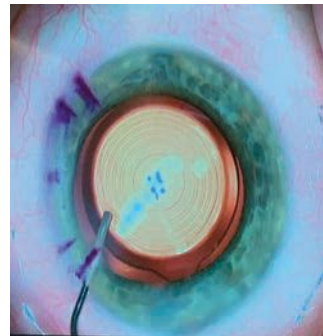
approach has the potential to reduce incidence of halos around lights at night.

Another thing to consider due to these EDOF properties is the ease of which it is to over-minus patients when refracting. Be aware of this and try to push as much plus power as possible.

## Top Two Factors

It is still of utmost importance to consider lifestyle factors when recommending Synergy or any other

Photo: Derek Cunningham, OD



**The Synergy aims to give patients a wider range of vision by combining two optical concepts.**

presbyopia-correcting IOL for patients. As the physician, ask questions regarding occupation and hobbies to properly assess a patient's visual demands. You should also gauge their personality when conversing with them in your chair. It has been shown that the personality of the patient is one of the leading factors in determining success with a multifocal IOL, with two of the most

important traits being conscientiousness and agreeableness.<sup>3</sup>

Secondly, surgical skill is equally critical to patient satisfaction, as any residual refractive error or induced astigmatism will manifest in the patient's visual experience. As always, choose your surgeon wisely. ■

1. Ansari Z, Miller D, Galor A. Current thoughts in fungal keratitis: diagnosis and treatment. *Curr Fungal Infect Rep.* 2013;7(3):209-18.

2. Pepose JS, Wilhelmus KR. Divergent approaches to the management of corneal ulcers. *Am J Ophthalmol.* 1992;114:630-2.

3. Jones DB, Sexton R, Rebell G. Mycotic keratitis in South Florida: a review of thirty-nine cases. *Trans Ophthalmol Soc U K.* 1970;89:781-97.

## ABOUT THE AUTHOR



**Dr. Zimmerman** is an ocular disease resident at Dell Laser Consultants in Austin, TX. He has no financial disclosures.

**About Drs. Cunningham and Whitley**

**Dr. Cunningham** is the director of optometry at Dell Laser Consultants in Austin, TX. He has no financial interests to disclose. **Dr. Whitley** is the director of professional relations and residency program supervisor at Virginia Eye Consultants in Norfolk, VA. He is a consultant for Alcon.

## Optometry CE Study Center



The CE You  
Need in 2021

As low as  
**\$17.50**  
per Credit Hour

Buy just one 2-hour course for \$35 or buy as many as you need

Choose from over 50 individual CE courses

Includes the hard to find topics that fulfill your state requirements

All available in a convenient online format

Visit [www.ReviewEdu.com](http://www.ReviewEdu.com) for additional information and purchasing options.

The CE Study Center courses have been developed in conjunction with expert faculty from leading schools of optometry and are oriented toward clinical practice issues that are designed to assist eye care professionals in serving their patient's healthcare needs. CE Courses also appear in print monthly in *Review of Optometry*.

1-800-825-4696 • [INFO@REVIEWSCE.COM](mailto:INFO@REVIEWSCE.COM)

These COPE-Accredited CE courses are administered in partnership with an accredited school of optometry.





BY JAMES L. FANELLI, OD

## GLAUCOMA GRAND ROUNDS

# One Step at a Time

*As we gather more information about the status of glaucomatous damage, a management plan comes into focus.*

**A** 64-year-old Caucasian male presented as a new patient in May with complaints of decreased vision OU. His spectacle Rx was from 2016, and he reported that his vision had gradually declined OU over the past several years, with his left eye “dropping off” rather significantly within the past few months.

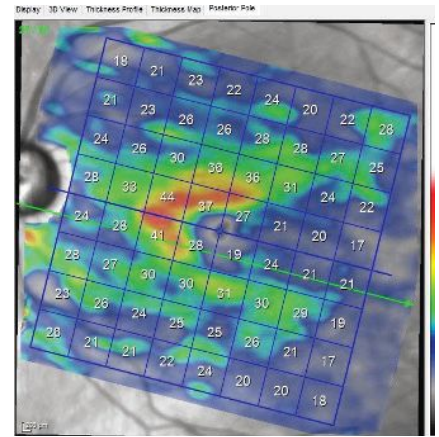
### The Case

The patient’s meds included lamotrigine, and he reported no drug allergies. His entering acuities were 20/30- OD and 20/50- OS. His pupils were equal, round and reactive to light and accommodation with an equivocal afferent pupillary defect OS. His best-corrected visual acuities were 20/25 OD and 20/40 OS through hyperopic astigmatic and presbyopic correction OS>OD. His extraocular muscles were full in all positions of gaze.

He had a “vascular problem” in his right eye several years ago that affected vision for several weeks but ultimately “returned to normal.” There have been no similar issues since.

A slit lamp examination of the anterior segment was completely unremarkable, with clear corneas, well-formed and quiet anterior chambers and a clear external examination. Applanation tensions were 18mm Hg OD and 19mm Hg OS at 2:46pm.

Through dilated pupils, the crystalline lenses were characterized by 1+ and 2+ nuclear sclerosis OD and OS, respectively, though acuities were somewhat worse than expected given the lenticular changes. Bilateral posterior vitreous detachments were present, as were epiretinal membranes outside the foveal avascular zone. The central foveal avascular zone was unremarkable at the slit lamp.

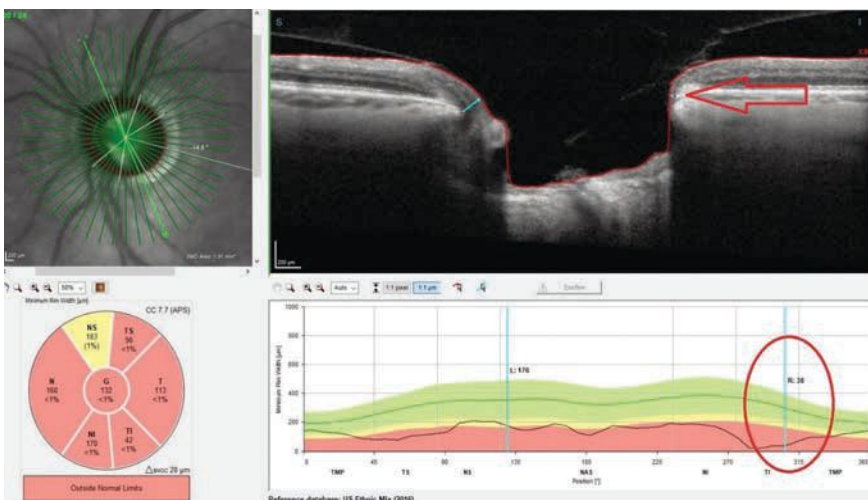


**A macular scan of the left eye, specifically isolating the ganglion cell layer. A normal ganglion cell layer falls within the 40µm range.**

His cup-to-disc ratios were judged to be 0.70x0.70 OD and 0.70x0.85 OS, with significant thinning and notching inferotemporally OS. The right neuroretinal rim was also thin, and both optic nerves were of average size. The retinal vascular examination was characterized by mild arteriosclerotic retinopathy OU. The peripheral retinal examination was unremarkable.

Following the fundus evaluation, corneal pachymetry was obtained, and central corneal thicknesses were 490µm OD and 496µm OS. Optic nerve photos were taken, and the patient was asked to return in one to two weeks for optic nerve OCT and HRT3 imaging in the context of a glaucoma evaluation.

The patient followed up as requested, at which point his intraocular pressures (IOPs) were 22mm Hg OD and 26mm Hg OS at 8:53am. HRT3 imaging correlated well with the estimated cup-to-disc ratios previously recorded. OCT examination of the optic nerves confirmed neuroretinal rim loss OS>OD and periopic retinal



**Significant thinning in the neuroretinal rim OS. Inferotemporally, Bruch’s membrane opening is reduced to less than 38µm (circle and arrow).**

About Dr. Fanelli

Dr. Fanelli is in private practice in North Carolina and is the founder and director of the Cape Fear Eye Institute in Wilmington, NC. He is chairman of the EyeSki Optometric Conference and the CE in Italy/Europe Conference. He is an adjunct faculty member of PCO, Western U and UAB School of Optometry. He is on advisory boards for Heidelberg Engineering and Glaukos.



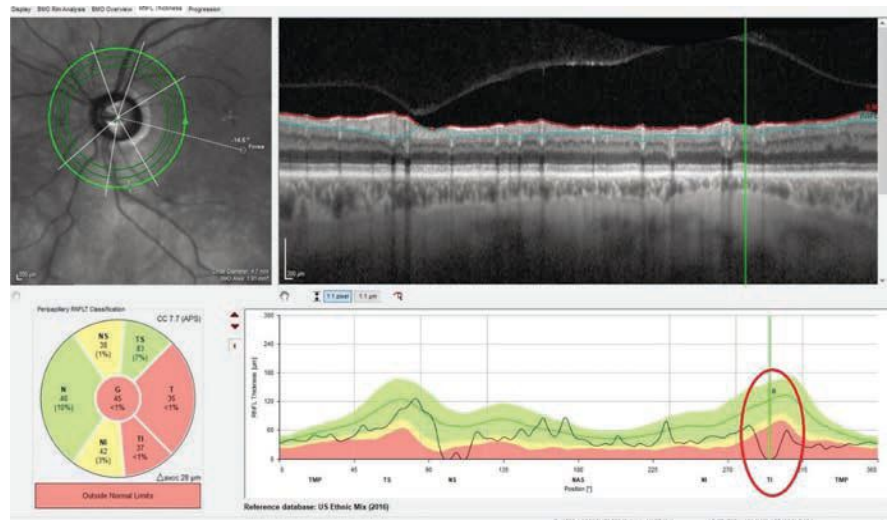
nerve fiber layer (RNFL) loss OS>OD, especially in the inferotemporal sector of the left eye. Macular ganglion cell body analysis demonstrated marked loss of cell bodies in the macula OS, greater below than above the horizontal raphe.

## Discussion

The findings of moderate OD and advanced OS glaucomatous damage are clearly evident in this case. Thin corneal pachymetry values and variable IOPs can play a role in delayed detection of glaucoma, though it doesn't help that the patient had not sought care for five years.

While the diagnosis in this case is straightforward, management options vary from topical medication to selective laser trabeculoplasty to surgical intervention. Physician preference and experience play a role in setting a course for treatment. In this case, obtaining a visual field study may provide more insight, as, given the patient's complaints of recent decreased vision and his advanced state of glaucomatous damage in the left eye, it's not unreasonable to expect a field defect that involves fixation. The Hood report, along with the amount of structural damage, indicates that a 24-2 standard automated perimetry strategy is appropriate for this patient.

Stabilization of the glaucoma is very important, especially in the left eye, as the disease is more advanced OS. What ganglion cells remain in advanced disease tend to be more fragile, making matters even more



**Thinning of the peripoptic RNFL OS, with complete loss of the RNFL in one small sector inferotemporally. This area coincides with the thinned neuroretinal rim in the first image.**

challenging. At the completion of the second visit, I elected to medicate the patient with one drop of Xelpros (latanoprost ophthalmic emulsion, Sun Ophthalmics) OU HS to lower IOP and give me more time to determine the best course of action. Following two weeks of medication use, the patient's IOPs were 12mm Hg OD and 13mm Hg OS.

I have yet to completely determine the extent to which the patient's cataracts are affecting his vision, especially in the left eye, as the field testing is still pending. The likelihood of a field defect extending to fixation is a distinct possibility.

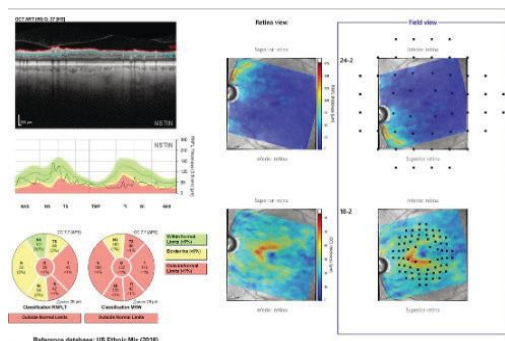
If we opt for cataract surgery, which will probably be the case, we can combine lens extraction with implantation of an iStent (Glaukos) inject device. Currently, this MIGS procedure is approved for implantation in the United States only when combined with cataract surgery. Its efficacy has been well documented, with a very low complication profile.<sup>1,2</sup> More recently, data has indicated that these devices can be used in advanced glaucoma with good results, and they can also be successfully utilized in pseudoexfoliative glaucoma as well.<sup>3</sup>

## Takeaways

I am part of a European ophthalmology chat room, and, interestingly enough, a colleague recently posted a similar case of advanced glaucoma at the time of diagnosis, cataracts and decreased vision. Several of the doctors in the forum suggested immediately heading to cataract surgery with a combined trabeculectomy. While trabeculectomies can be very effective, they also are not without complications. I personally think there are less invasive ways to proceed initially (MIGS device, cataract surgery and perhaps topical therapy), reassessing as you move forward.

There are many viable strategies in cases like this, and ultimately, you will develop your own protocols based on what works for you. Just about all of them are acceptable options. Think about it like this: if you were the patient, with your expertise in the matter, how would you want the plan to proceed? ■

1. Popovic M, Campos-Moller C, Saheb H, et al. Efficacy and adverse event profile of the iStent and iStent inject trabecular micro-bypass for open-angle glaucoma: a meta-analysis. *J Curr Glaucoma Pract.* 2018;12(2):67-84.
2. Voskanyan L, García-Feijóo J, Belda JJ, et al. Prospective, unmasked evaluation of the iStent inject system for open-angle glaucoma: synergy trial. *Adv Ther.* 2014;31(2):189-201.
3. Clement CI, Howes F, Ioannidis AS, et al. One-year outcomes following implantation of second-generation trabecular micro-bypass stents in conjunction with cataract surgery for various types of glaucoma or ocular hypertension: multicenter, multi-surgeon study. *Clin Ophthalmol.* 2019;13:491-9.



**The Hood report of the left eye, with concordance of the neuroretinal rim and peripoptic RNFL damage.**

# PRODUCT REVIEW

New items on the market to improve clinical care and strengthen your practice.



**ONLINE FIRST:**  
GET THE LATEST  
PRODUCT NEWS AT  
[www.reviewofoptometry.com](http://www.reviewofoptometry.com)

## ► DRY EYE REMEDIES

### **Preservative-Free Eye Drop in Multi-Use Bottle**

Artificial tears made without preservatives are traditionally packaged in single-dose vials that are only good for one use—but that's not the only option anymore. If any of your patients are in the market for a more convenient and environmentally friendly preservative-free (PF) eye drop to help relieve dry eye symptoms, they're in luck. Oasis Medical has launched a version of its Oasis Tears PF Plus lubricant eye drops in a multi-use 10mL bottle.

A valve on the tip of the bottle releases a drop of the product but blocks airflow into the unit to prevent contamination and microbial growth, allowing the drops to remain sterile for up to 90 days after opening, according to a company press release. Oasis says the PF Plus drops, like its others, are designed for quick relief and are recommended for daily use as needed in mild to moderate dry eye.



### **Two Products to Naturally Relieve Dry Eye**

With dry eye ever-present, and in fact on the rise thanks to excessive screen time of late, new palliative options are always welcome. Bausch + Lomb recently released two new products, both in its Biotrue line: Hydration Boost Lubricant Eye Drops and Micellar Eyelid Cleansing Wipes. Both are free of preservatives, pH-balanced and designed with naturally inspired ingredients that support the biology of the eye, according to the company.



The Hydration Boost drops can be used during soft contact lens wear to deliver quick relief from dry eye symptoms, the company says, and the pH-balanced formula helps to maintain ocular surface

homeostasis. The drops are designed to mimic healthy tears with ingredients such as an electrolyte, an antioxidant and hyaluronan, a moisturizer found naturally in tears.

The Cleansing Wipes can help reduce eyelid buildup that contributes to dry and irritated eyes. B+L says they can be used as needed to hydrate the eyelid and increase ocular comfort. Like the drops, the wipes contain natural ingredients such as hyaluronan and an electrolyte as a micellar cleanser, in addition to aloe, licorice and dandelion root extract to provide natural soothing, the company says.

## ► DIAGNOSTIC DEVICES

### **Auto-Pupillometer to Detect Neurological Injury**

Pupillary assessments can aid in the early detection of neurological injuries or diagnoses including brain trauma, stroke, seizure or events that follow medical conditions such as cardiac arrest. The sooner issues are identified, the quicker treatment decisions can be made to help preserve vision and prevent lasting damage. NeurOptics recently released an automated pupillometer, the NPi-300, that the company says can help assess changes in pupillary light reflex, one of the common indications of neurological injury.

The device uses an infrared camera to measure pupil size and reactivity, which are then compared against a normative database to generate a composite score using an algorithm called the Neurological Pupil index (NPI), developed by the company, with values ranging from 0 to 4.9 (<3 is considered abnormal). Expressing this data numerically allows it to be tracked over time, which may help doctors make better and more informed treatment decisions, NeurOptics says.



### **Macular Pigment Test May Open Patients' Eyes**

If you're interested in quantifying a patient's vulnerability to AMD, tests of macular pigment density can help you encourage mitigation strategies and will document any changes in their status over time, proponents say. A new device called MP-eye, from Azul Optics, can detect macular pigment levels in under a minute, the company says. The speediness of the test means it can be done in a pre-screening or routine eye exam, Azul Optics says, allowing low pigment levels to be detected before further damage occurs.

The device uses polarized light to cast a shadow of the macular pigment layer onto the retina. The more macular pigment that's present, the stronger and more visible the shadow, resulting in a higher score on the MP-eye test, company literature explains.

This test is particularly useful for patients at greater risk of blue light and oxidative damage, which could lead to AMD, according to the company. Azul Optics notes that the early detection of low pigment levels could help patients take advantage of protective strategies such as dietary supplements and sun protection to lower their likelihood of developing permanent vision loss.



Practice For Sale



Practice Sales • Appraisals • Consulting  
[www.PracticeConsultants.com](http://www.PracticeConsultants.com)

**PRACTICES FOR SALE  
 NATIONWIDE**

Visit us on the Web or call us to learn more about our company and the practices we have available.  
[info@PracticeConsultants.com](mailto:info@PracticeConsultants.com)  
**925-820-6758**

[www.PracticeConsultants.com](http://www.PracticeConsultants.com)

**FOR SALE**

**CALIFORNIA – LAKE COUNTY**

Turnkey practice consistently grossing over \$1,000,000 and net of \$340,000+ per year on 4 days/week. Fully-equipped exam rooms featuring Optos, Optovue OCT, and Octopus Visual Fields Analyzer. Experienced, well-trained staff in place. Seller will assist with the transition.

**100% Financing Available**

**800-416-2055**  
[www.TransitionConsultants.com](http://www.TransitionConsultants.com)



Targeting Optometrists?

**CLASSIFIED ADVERTISING WORKS**

- JOB OPENINGS • CME PROGRAMS
- PRODUCTS & SERVICES • AND MORE...

Contact us today for classified advertising:  
 Toll free: **888-498-1460**  
 E-mail: [sales@kerhgroup.com](mailto:sales@kerhgroup.com)



**OPTOMETRIC PRACTICE FOR SALE**

Well established thriving Optometric practice for sale in Northwest New Mexico.

Reasonably priced!

Contact: Judi Painter  
 (505)486-4617  
[retniapj@hotmail.com](mailto:retniapj@hotmail.com)

*Practice for Sale*

Well established rural optometry practice including building and land in Lake Isabella, Ca.

Contact  
[llwagwag@yahoo.com](mailto:llwagwag@yahoo.com)

**Do you have CE Programs?**

**CONTACT US TODAY FOR CLASSIFIED ADVERTISING**

Toll free:  
**888-498-1460**  
 E-mail:  
[sales@kerhgroup.com](mailto:sales@kerhgroup.com)



Targeting Optometrists?

**CLASSIFIED ADVERTISING WORKS**

- JOB OPENINGS • CME PROGRAMS
- PRODUCTS & SERVICES • AND MORE...

Contact us today for classified advertising:  
 Toll free: **888-498-1460**  
 E-mail: [sales@kerhgroup.com](mailto:sales@kerhgroup.com)






# ADVERTISER INDEX

This index is published as a convenience and not as part of the advertising contract. Every care will be taken to index correctly. No allowance will be made for errors due to spelling, incorrect page number, or failure to insert.

Alcon Laboratories ..... 7	Keeler Instruments ..... 5
..... <a href="http://www.alcon.com">www.alcon.com</a>	..... (800) 523-5620
	..... <a href="mailto:customerservice@keelerusa.com">customerservice@keelerusa.com</a>
Art Optical ..... 17	..... <a href="http://www.keelerusa.com">www.keelerusa.com</a>
..... (800) 253-9364	
..... <a href="http://www.artoptical.com">www.artoptical.com</a>	MacuLogix ..... 23
	..... <a href="http://www.maculogix.com">www.maculogix.com</a>
Bausch + Lomb ..... 2 & 3	MedEdicus ..... Polybag Insert
..... <a href="http://www.vyzultahcp.com">www.vyzultahcp.com</a>	..... <a href="http://tinyurl.com/tearstimCE">tinyurl.com/tearstimCE</a>
Bausch + Lomb ..... 11	Nanodropper ..... 19
..... <a href="http://www.biotrue.com">www.biotrue.com</a>	..... (507) 405-5676
Bausch + Lomb ..... 31	..... <a href="mailto:support@nanodropper.com">support@nanodropper.com</a>
..... (844) 258-4837	..... <a href="http://www.nanodropper.com">www.nanodropper.com</a>
..... <a href="http://www.bausch.com">www.bausch.com</a>	Oculus, Inc. .... 35
Bausch + Lomb ..... 39	..... (888) 519-5375
..... <a href="http://www.bauschInfuseECP.com">www.bauschInfuseECP.com</a>	..... <a href="mailto:ads@oculususa.com">ads@oculususa.com</a>
Bausch + Lomb ..... 92	..... <a href="http://www.oculususa.com">www.oculususa.com</a>
..... <a href="http://www.bausch.com">www.bausch.com</a>	Tarsus Pharmaceuticals ..... Insert
Bausch + Lomb ..... Cover Tip	US Ophthalmic ..... 9
..... <a href="http://www.bauschInfuse.com">www.bauschInfuse.com</a>	..... (888) 881-1122
CooperVision ..... 90	..... <a href="mailto:info@usophthalmic.com">info@usophthalmic.com</a>
..... <a href="http://www.coopervision.com">www.coopervision.com</a>	..... <a href="http://www.usophthalmic.com">www.usophthalmic.com</a>
CooperVision ..... 91	Visioneering Technologies ..... 13
..... <a href="http://www.coopervision.com">www.coopervision.com</a>	..... <a href="http://www.vtvision.com">www.vtvision.com</a>
Eyeris ..... 25	VSP ..... 21
..... <a href="http://www.myeyeris.com">www.myeyeris.com</a>	..... <a href="http://www.unitybiosync.com">www.unitybiosync.com</a>
Glaukos ..... 14	Xcel Specialty ..... 43
..... (800) 452-8567	..... (800) 241-9312
..... <a href="http://www.iLinkExpert.com">www.iLinkExpert.com</a>	..... <a href="mailto:xcelinfo@xcelspecialtycontacts.com">xcelinfo@xcelspecialtycontacts.com</a>
	..... <a href="http://www.xcelspecialtycontacts.com">www.xcelspecialtycontacts.com</a>

# 2021 OFFICE DESIGN CONTEST



## CALL FOR ENTRIES



Have you recently renovated your office or redesigned a new space? Enter our office design contest and share your new look with your colleagues!

**Eligibility:** Newly built offices, remodels or expansions completed between July 2019 and July 2021.

**Judging:** Entries will be judged by a panel of fellow ODs previously recognized for their expertise in office design.

**Awards:** "Office Design of the Year" and two runners-up will be awarded based on functional design, efficient space planning, style and integration of equipment. Winners will receive editorial coverage in our November 2021 edition.

**Deadline:** All entries must be received by October 1, 2021.

Entry form available at [www.reviewofoptometry.com](http://www.reviewofoptometry.com) or by writing to [editor@reviewofoptometry.com](mailto:editor@reviewofoptometry.com)



# A Bump in the Road

*Even when a patient's concern is cosmetic in nature, be sure to rule out systemic involvement.*

**A** 74-year-old woman presented to the office with a chief complaint of a troublesome bump on her eyelid OD that had been present “for years.” She said the issue has gradually become worse, making her right eye un-sightly.

She did not report any pain. She denied trauma, systemic disease or allergies of any kind.

## Diagnostic Data

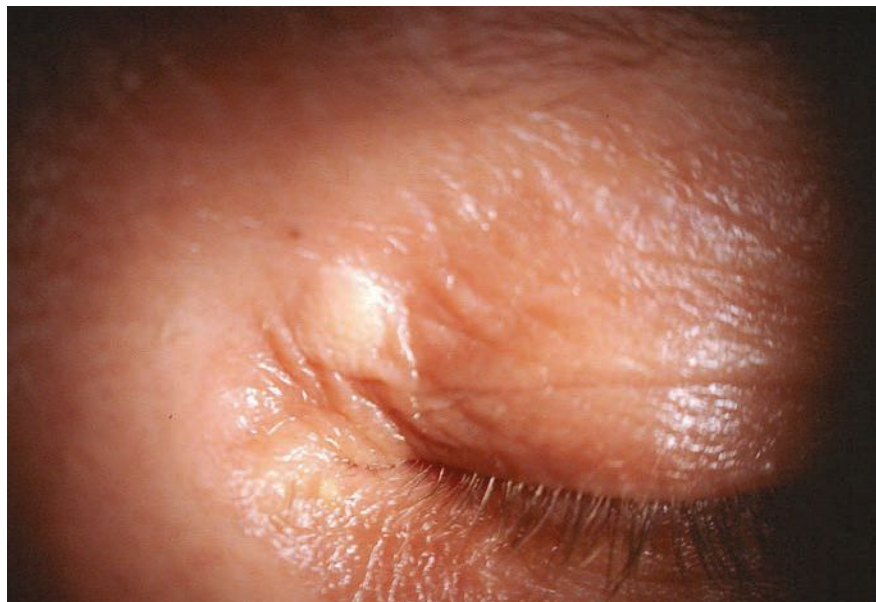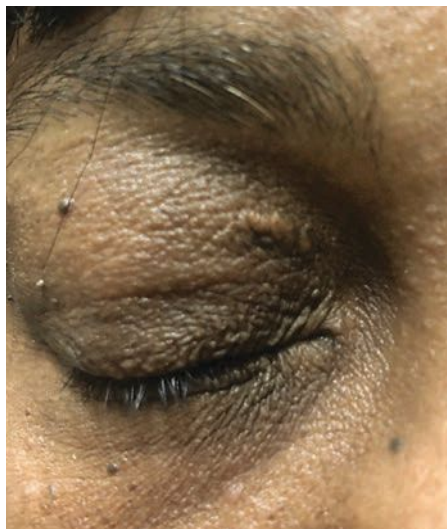Her best-corrected entering visual acuities were 20/30 OD and 20/30 OS. Her external examination was unremarkable, with no evidence of afferent pupillary defect. Images comparable to the blemish in question are shown below. Her anterior segment findings were normal and Goldmann tonometry measured 17mm Hg OU.

## Additional Information

To learn more, other exam techniques included palpation and inspection of the lesion for tissue firmness, intact margins and any evidence of bleeding or oozing. Health history questions were also asked to rule out conditions of the skin related to undiagnosed systemic disease.

## Your Diagnosis

What would be your diagnosis in this case? How would you approach management? What is the patient's likely prognosis? To find out, please read the online version of this article at [www.reviewofoptometry.com](http://www.reviewofoptometry.com). ■



**Two examples of periocular skin findings similar to those of the patient in question.**

### About Dr. Gurwood

Dr. Gurwood is a professor of clinical sciences at The Eye Institute of the Pennsylvania College of Optometry at Salus University. He is a co-chief of Primary Care Suite 3. He is attending medical staff in the department of ophthalmology at Albert Einstein Medical Center, Philadelphia. He has no financial interests to disclose.

## Retina Quiz Answers (from page 94)—Q1: b, Q2: b, Q3: a, Q4: d

### NEXT MONTH IN THE MAG

In September, we present our 44th annual technology report.

Articles will include:

- Zoom in on Retinal Imaging—Techniques From Basic to Advanced
- How to Get More Out of Your OCT

- Tools for Assessing the Eyelids and Ocular Surface
- At-Home Monitoring: What Makes Sense For Your Patients?

*Also included in September:*

- When the Patient Complains of Ocular Pain
- Kidney Disease and the Eye: Correlations Worth Noting

# My Clinical Experience with CooperVision's MiSight® 1 day



Certification for CooperVision's Brilliant Futures™ Myopia Management Program featuring MiSight® 1 day began more than one year ago in March 2020. An early adopter of the program, Dr. Carlee Young from Clarkson Eyecare for Kids was the first certified prescriber in the U.S. to fit an age-appropriate patient with MiSight® 1 day soft contact lenses. Since then, Dr. Young has seen incredible patient results. She also shares some of her key takeaways that will help eye care practitioners successfully integrate Brilliant Futures™ into their practice.

**Carlee Young, OD, FAAO**, Clarkson Eyecare for Kids, Frisco, Texas

**The MiSight® 1 day clinical trial found that over a three year period the lens slowed myopia progression by 59% on average and slowed axial length by 52% on average,<sup>1†</sup> and that participants' myopia progressed less than 1.00D on average over six years while wearing MiSight®.<sup>2††</sup> How do your patients' results compare?**

To date, I've fit more than 30 age-appropriate patients with the MiSight® 1 day lens. Of those, only 1 or 2 patients have experienced more than a 0.25D change. The very first patient I fit in the lens is now more than one year into wearing MiSight® and his prescription has remained stable – an incredible feat considering his prescription jumped 1.00D in power in less than a year before I prescribed him MiSight® 1 day. So, in my experience, the MiSight® 1 day lens is even more effective than the study had found!

**How can other eye care practitioners become successful in integrating Brilliant Futures™ into their practice?**

I have two tips for ECPs who are planning to certify and bring Brilliant Futures™ into their practice.

- Educate early and often. Myopia management education is key to success with the Brilliant Futures™ program. It is especially valuable to start educating families on risk factors for myopia, such as family

**59%**  
average reduction in myopia progression with MiSight® 1 day lenses<sup>1†</sup>

genetics and environmental factors, early in the process. I often plant the seed during an appointment, send parents home with brochures and educational materials provided by CooperVision, and then follow up with them in a few months to see if they might want to talk more about myopia management.

- Confidently prescribing MiSight® 1 day is important. The Brilliant Futures™ Myopia Management Program and FDA-approval\* is

**52%**  
average reduction in axial lengthening with MiSight® 1 day lenses<sup>1†</sup>

what sets MiSight® 1 day above the rest. Through the support of the CooperVision Myopia Management team and the MiSight® App, I can drive home the point that myopia control goes beyond vision correction. The program is a commitment made by the doctor, parent and age-appropriate patient to improve the patient's lifelong visual health with MiSight® 1 day. I find parents understand the commitment to management better when it is presented in this way.<sup>3</sup> I had to refine my presentation to parents a few times to convey the urgency in a simple and motivating manner. We have such a privilege and responsibility as eye care providers since parents trust us to do what's in the best interest for their children.



Build your myopia management clinic with CooperVision's Brilliant Futures™ Myopia Management Program with MiSight® 1 day.

Visit [www.coopervision.com/practitioner/myopia-management](http://www.coopervision.com/practitioner/myopia-management) to register for more information about bringing Brilliant Futures™ to your practice.

\* **Indications for use:** MiSight® 1 day (omafilcon A) soft (hydrophilic) contact lenses for daily wear are indicated for the correction of myopic astigmatism and for slowing the progression of myopia in children with non-diseased eyes, who at the initiation of treatment are 8-12 years of age and have a refraction of -0.75 to -4.00 diopters (spherical equivalent) with ≤ 0.75 diopters of astigmatism. The lens is to be discarded after each removal.

<sup>†</sup> Compared to a single vision 1 day lens over a 3 year period.

<sup>††</sup> No clinically meaningful change in refractive error -0.25D or less from baseline.

#### References:

- 1 Chamberlain P, et al. A 3-year randomized clinical trial of MiSight® lenses for myopia control. *Optom Vis Sci.* 2019; 96(8):556-567. Compared to a single vision 1 day lens over a 3 year period.
- 2 Chamberlain P, Arumugam B, Jones D et al. Myopia Progression in Children wearing Dual-Focus Contact Lenses: 6-year findings. *Optom Vis Sci.* 2020;97(E-abstract): 200038.
- 3 CVI data on file 2019. Global survey by Decision Analyst with 1,009 parents in UK, Canada, Germany, Spain, Hong Kong, Australia/NZ.





# KIDS SHOULD GROW STRONGER

Their myopia shouldn't.



Now you can help slow the progression of myopia in your age-appropriate patients.<sup>1</sup>

Introducing the **Brilliant Futures™ Myopia Management Program with MiSight® 1 day** contact lenses.

MiSight® 1 day is the first and only FDA-approved\* soft contact lens to slow the progression of myopia in children aged 8-12 at the initiation of treatment.<sup>1†</sup>

**59%**

**Slows Myopia Progression**  
on average<sup>1†</sup>

**52%**

**Axial Length  
Elongation Reduction**  
on average<sup>1†</sup>



**Child Friendly<sup>1</sup>**  
1 day lens

**BRILLIANT FUTURES™**

WITH MiSIGHT® 1 day



CooperVision®

Ask your CooperVision sales representative about Brilliant Futures™ with MiSight® 1 day lenses

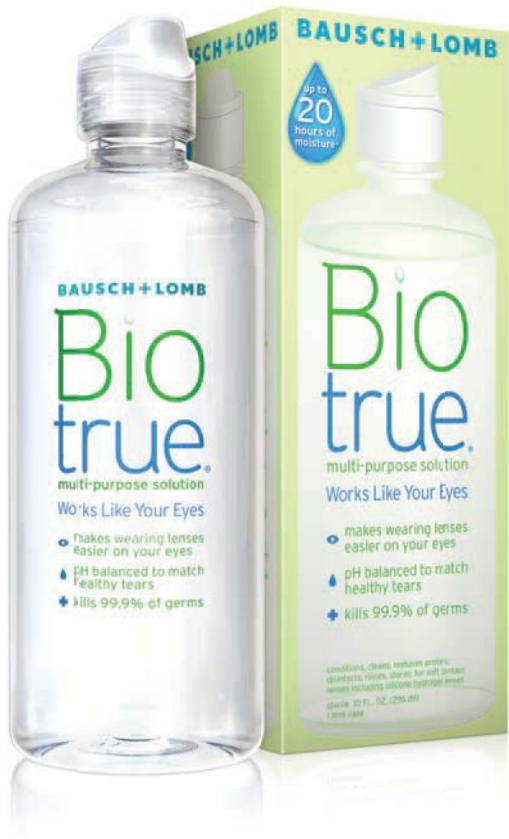**Indications for use:** MiSight® 1 day (omafilcon A) soft (hydrophilic) contact lenses for daily wear are indicated for the correction of myopic ametropia and for slowing the progression of myopia in children with non-diseased eyes, who at the initiation of treatment are 8-12 years of age and have a refraction of -0.75 to -4.00 diopters (spherical equivalent) with ≤ 0.75 diopters of astigmatism. The lens is to be discarded after each removal.

<sup>†</sup>Compared to a single vision 1 day lens over a 3 year period.

<sup>1</sup>Chamberlain P, et al. A 3-year randomized clinical trial of MiSight® lenses for myopia control. *Optom Vis Sci.* 2019; 96(8):556-567.

©2021 CooperVision, Inc. 10307RCCL 02/21

# Biotrue<sup>®</sup> is the only multi-purpose solution enhanced with hyaluronan



For a solution inspired by  
the biology of the eye,  
**recommend Biotrue  
multi-purpose solution.**

Biotrue with hyaluronan  
helps provide



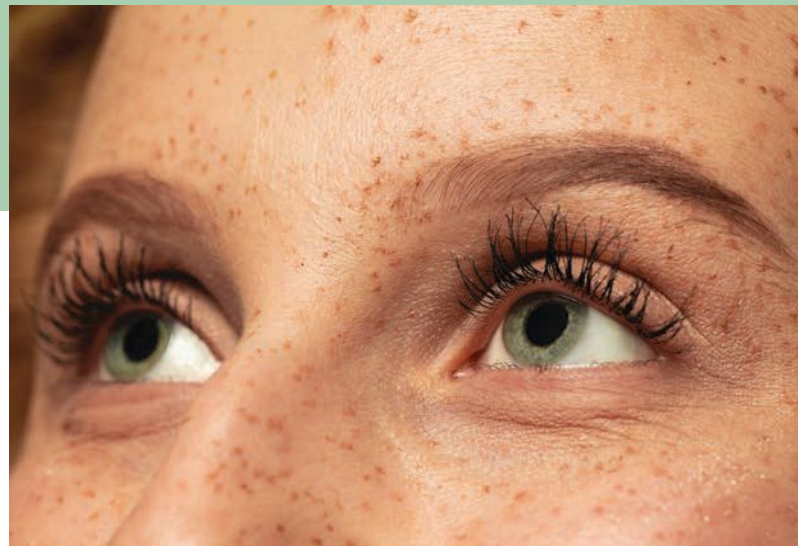Up to 20 hours of hydration\*



Unsurpassed disinfection at  
low preservative concentrations<sup>†</sup>



All-day comfort despite  
extensive digital device use<sup>‡</sup>



\*Based on a laboratory study.

<sup>†</sup>vs multi-purpose solutions based on a standardized testing (ISO 14729)  
against 5 common organisms.

<sup>‡</sup>Based on an in-home usage survey.

Biotrue is a trademark of Bausch & Lomb Incorporated or its affiliates.  
© 2020 Bausch & Lomb Incorporated or its affiliates.  
BIO.0042.USA.20 07/2020

**BAUSCH + LOMB**