

Top Docs' Message: Knowledge is Power

Beloved ODs Ron Melton and Randall Thomas shared their perspective on patient care and where the profession needs to go.

Sonny and Cher, Donnie and Marie, Melton and Thomas—all dynamic duos. The only difference is that the last pair, while expert performers on stage, aren't known for their singing but rather their optometric expertise, good-natured banter and often-blunt delivery about what they think optometrists should be doing. All were on display during "Clinical Perspectives in Patient Care," the team's Friday morning special session.

"Use your God-given brain and do some rational thinking," said a comically exasperated Dr. Thomas when lamenting overuse of OCT and visual fields. Instead, he advised, ask the patient about recent changes in their medication regimens or other life factors. Start small, he suggested.

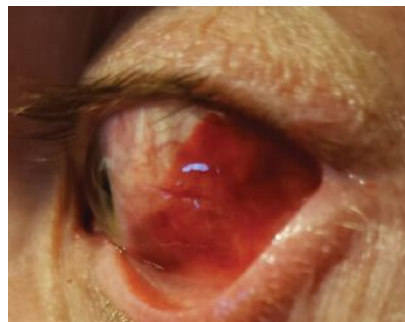
Witniness aside, his and Dr. Melton's passion for optometry

shone through, as they covered dozens of current trends in clinical management, how optometry can enhance public health and the importance of managing medical eye conditions rather than referring out.

Take the Lead

Early on, as Dr. Thomas showed two long lists of various medical eye conditions (corneal dystrophies, injuries and abrasions, ocular migraines, epiphora, systemic medication toxicity, to name a few), he talked about how you can make a full practice out of nothing but medical eye care. But to do so, you have to have patients coming in and staying in your office to build such a practice.

"From a public health perspective, we should be managing these conditions," said Dr. Thomas. "If you're doing all these things and refractive



Severe conjunctival laceration demands expert attention immediately, a role the optometrist is well-suited to play, argue Drs. Melton and Thomas.

gets stolen from artificial intelligence (AI), for me, I won't care—I'm going to be plenty busy taking care of medical patients. You need to start shaping your practice to be *the* medical practitioner of the eye, and you'll be as busy as you care to be. But you have to build this."

Offering access to your care 24/7 is not only vital for the community but also a savvy way to build your practice, Dr. Thomas explained. Patients with after-hours eye problems often get substandard care in an ER, depriving them of better attention—and your practice of the opportunity to build patient loyalty.

AI and its impact on optometrists now and in the future was a topic of conversation, as Drs. Melton and Thomas discussed the pros and cons of this technology, including remote patient monitoring—using the iCare Home tonometer as an example. Dr. Melton noted that over half of patients have the highest IOP outside of office hours; allowing them to take their own pressures at 11pm or 5am, for example, can help develop a true IOP profile.

See **CLINICAL PERSPECTIVES**, Page 13


EYE ALLERGENS ARE OUT THERE

FULL 24 HOUR

EYE ALLERGY ITCH RELIEF IS HERE

Pazeo® has become Pataday® Once Daily Relief Extra Strength

Recommend to your patients for all day and night eye allergy itch relief.



EXTRA STRENGTH Pataday® ONCE DAILY RELIEF
 Olopatadine hydrochloride ophthalmic solution 0.7%
 Antihistamine
Eye Allergy Itch Relief

Works in Minutes
 Relief from Allergens:
 • Pet Dander • Pollen
 • Grass • Ragweed

FULL 24 HOUR

Alcon

FULL 24 HOUR
 One Drop Once a Day for 24-Hour Relief

Works in Minutes

Full Prescription Strength Pazeo® Available OTC

Visit patadaypro.com

Alcon

© 2020 Alcon Inc. 12/20 US-PTD-2000172

Top Docs' Message: Knowledge is Power

Beloved ODs Ron Melton and Randall Thomas shared their perspective on patient care and where the profession needs to go.

Sonny and Cher, Donnie and Marie, Melton and Thomas—all dynamic duos. The only difference is that the last pair, while expert performers on stage, aren't known for their singing but rather their optometric expertise, good-natured banter and often-blunt delivery about what they think optometrists should be doing. All were on display during "Clinical Perspectives in Patient Care," the team's Friday morning special session.

"Use your God-given brain and do some rational thinking," said a comically exasperated Dr. Thomas when lamenting overuse of OCT and visual fields. Instead, he advised, ask the patient about recent changes in their medication regimens or other life factors. Start small, he suggested.

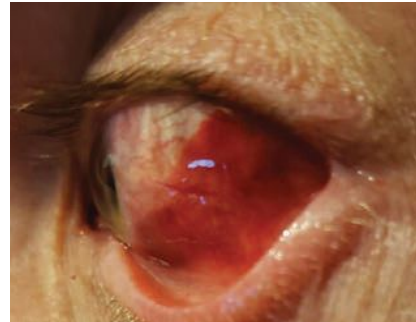
Wittiness aside, his and Dr. Melton's passion for optometry

shone through, as they covered dozens of current trends in clinical management, how optometry can enhance public health and the importance of managing medical eye conditions rather than referring out.

Take the Lead

Early on, as Dr. Thomas showed two long lists of various medical eye conditions (corneal dystrophies, injuries and abrasions, ocular migraines, epiphora, systemic medication toxicity, to name a few), he talked about how you can make a full practice out of nothing but medical eye care. But to do so, you have to have patients coming in and staying in your office to build such a practice.

"From a public health perspective, we should be managing these conditions," said Dr. Thomas. "If you're doing all these things and refractive



Severe conjunctival laceration demands expert attention immediately, a role the optometrist is well-suited to play, argue Drs. Melton and Thomas.

gets stolen from artificial intelligence (AI), for me, I won't care—I'm going to be plenty busy taking care of medical patients. You need to start shaping your practice to be *the* medical practitioner of the eye, and you'll be as busy as you care to be. But you have to build this."

Offering access to your care 24/7 is not only vital for the community but also a savvy way to build your practice, Dr. Thomas explained. Patients with after-hours eye problems often get substandard care in an ER, depriving them of better attention—and your practice of the opportunity to build patient loyalty.

AI and its impact on optometrists now and in the future was a topic of conversation, as Drs. Melton and Thomas discussed the pros and cons of this technology, including remote patient monitoring—using the iCare Home tonometer as an example. Dr. Melton noted that over half of patients have the highest IOP outside of office hours; allowing them to take their own pressures at 11pm or 5am, for example, can help develop a true IOP profile.

See **CLINICAL PERSPECTIVES**, Page 13

WHAT'S INSIDE

- Expert addresses corneal challenges.....3
- Don't ignore eyelid lumps and bumps.....4
- Be aggressive when managing uveitis.....4
- SECO expands reach during pandemic.....5
- Teach patients the ocular risks of wearing makeup.....5
- SECO names 2021 awardees.....6
- Exhibit hall info.....8
- Today's courses.....10
- Tomorrow's courses.....12

What We See With OCT

Morning session provided tips to interpret scans more confidently.

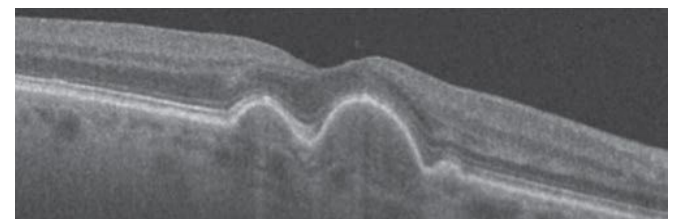
Early Friday, SECO attendees got a wonderful introduction to OCT use and analysis from Julie Rodman, OD, professor and chief of the Eye Care Institute at Nova Southeastern University. She guided everyone through a journey in ocular disease from anterior to posterior. "We'll start at the top of the eye and move our way down," she explained to the early-bird crowd at 7am. To properly understand and interpret OCT, Dr. Rodman believes optometrists must know which diseases affect which layer of the retina. With this anatomical perspective, attendees were able to distinguish these diseases from one another.

Digging Through the Layers

The journey started with anomalies of the vitreous and two common pro-

cesses due to aging: liquefaction and contraction. Dr. Rodman said that it would be super important to not give somebody a diagnosis suggestive of disease if it's essentially a normal, age-related process.

The conversation then pivoted to the stages of posterior vitreous detachment (PVD). She advised ODs to look at the vitreous cortex. Any sign of it lifting off suggests it's going to move anteriorly. As it continues to detach—from the fovea and then the optic nerve head, the last point of detachment—you'll see black pockets. "Don't write 'complete PVD' if you



OCT is extremely useful in differentiating various types of pigment epithelial detachment. A drusenoid PED is shown here.

don't see a Weiss ring," Dr. Rodman also advised.

Regarding macular holes, she discussed the importance of ascertaining how much tissue is present from the internal limiting membrane (ILM) to the retinal pigment epithelium (RPE). With full-thickness ones, Dr. Rodman advised, measure the defect at its narrowest point with the OCT's caliper function.

See **OCT**, Page 14

Refresh[®]
DIGITAL

CRACK THE CODE: RELIEVE EYE DRYNESS

 Artificial Tears for Today's
Digital Device Users.

When using digital devices, incomplete blinking contributes to tear film instability, resulting in eye dryness.

REFRESH[®] DIGITAL:

- Supports all three tear film layers
- Features *HydroCell*[™] technology
- Prevents tear evaporation



Visit Allergan Booth #806 for a **FREE** Sample.
Available while supplies last.

Today: 4:00pm–6:00pm ROOM A311/312

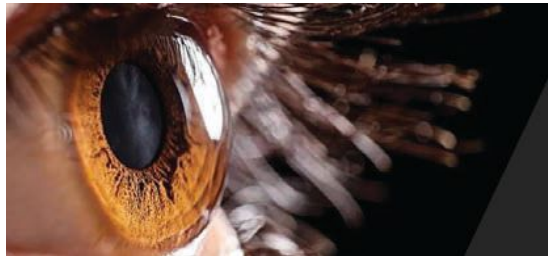Boost Your Confidence in Corneal Care

Stay up-to-date on the latest in available treatments to give your patients the best chance of success.

ODs are on the front lines of keratoconus care but aren't always sure when to advocate for and comanage corneal cross-linking (CXL). They must also make an effort to increase their understanding of neurotrophic keratitis and Fuchs' dystrophy and how to identify and manage each, notes Justin Schweitzer, OD. His course this afternoon, "The Challenges of the Cornea," will attempt to bridge these gaps and arm attendees with the tools they need to successfully manage keratoconus patients and others suffering from corneal issues.

Keratoconus is a bilateral, asymmetric, progressive corneal ectasia resulting in irregular astigmatism and visual function loss. Adverse effects include central corneal thinning, Fleischer's ring, corneal scarring, vertical striae (Vogt's lines), irregular astigmatism, poor best-corrected visual acuity with spectacles and "oil droplet" reflex (Charleux sign). Keeping these signs and symptoms in mind, Dr. Schweitzer notes that ODs should focus on diagnosing as early as possible with the technology available (e.g., slit lamp exam, topography, tomography).

Next comes stopping progression with CXL, which involves removing the epithelium, soaking



Diagnosing early and preventing progression is key in cases of keratoconus.

the cornea in riboflavin, measuring corneal thickness upon observation of flare (should be at least 400µm) and irradiating for 30 minutes while continuing to apply riboflavin. Rehabilitating visual acuity brings up the rear, with treatment options including spectacles, rigid or specialty contact lenses, intracorneal ring segments and corneal transplantation or refractive procedures. In his talk, he'll walk attendees through the procedure and give comanagement pearls.

Patients who develop neurotrophic keratitis typically progress through three stages: (1) hyperplasia and/or irregularity of the epithelium that may evolve to punctate keratopathy, corneal edema, neovascularization and stromal scarring;

(2) recurrent or persistent epithelial defect or the latter without stromal thinning; (3) stromal involvement leading to corneal ulceration, melting and perforation. Treatment options include amniotic membranes, endogenous nerve growth factor and topical drops (acyclovir, valacyclovir, famciclovir), continuing with prophylaxis for at least a year.

Fuchs' dystrophy occurs when endothelial pump cells atrophy, leaving guttae and eventually causing corneal edema. Surgical options include various forms of lamellar keratoplasty.

Dr. Schweitzer will also go over how to proceed in the event that varying clinical findings present and how to decipher between infectious and sterile cases based on location; central likely means more virulent, and peripheral is more commonly sterile.

He hopes that attendees will come away from the session ready to embrace management of tougher cases that enter the clinic and continue to educate themselves on the most recent advancements in treatment options in keratoconus. Overall, he wants to instill a new sense of confidence in ODs when it comes to identifying and managing a variety of corneal concerns. ■

SPEAKER SPOTLIGHT



John Berdahl, MD

Board-certified ophthalmologist John Berdahl, MD, practices in Sioux Falls, SD. He is widely regarded as one of the leading international cataract surgeons. He is one of the very few surgeons in the United States who is also fellowship trained in cornea, glaucoma and refractive surgery.

Dr. Berdahl has already performed more than 35,000 eye surgeries around the globe. His published work has primarily focused on the fundamental causes of glaucoma, the role of minimally invasive glaucoma surgery, and astigmatism management during and after cataract surgery.

He has been involved in numerous FDA-monitored clinical trials on some of the most exciting technologies in ophthalmology. He also founded the company Equinox, which is developing the first non-surgical, non-pharmacologic way to lower eye pressure for glaucoma treatment.

Dr. Berdahl's SECO 2021 course schedule includes:

Special Session:
Anterior Segment Advances: The Future is Now!

Today
8:00am–10:00am

Amphitheater A2

SPEAKER SPOTLIGHT



Lawrence Woodard, MD

Dr. Woodard is a board-certified ophthalmologist who serves as Medical Director of Omni Eye Services of Atlanta. He specializes in cataract surgery and corneal surgery.

Dr. Woodard was the first surgeon in the Atlanta metro area to offer bladeless laser cataract surgery. As one of the nation's leading cataract surgeons, he lectures extensively, educating other doctors on techniques and new technologies. His expertise has been featured in *EyeWorld*, *Review of Optometry* and other national publications.

Dr. Woodard trained at Duke University, Case Western Reserve University, the Scheie Eye Institute and a corneal and refractive surgery practice in Louisville, KY. He is a Fellow of the American Academy of Ophthalmology, a founding member of the American College of Ophthalmic Surgery and a member of the American Society of Cataract and Refractive Surgery.

Dr. Woodard's SECO 2021 course schedule includes:

Special Session:
Anterior Segment Advances: The Future is Now!

Today
8:00am–10:00am

Amphitheater A2

Today: 4:00pm–6:00pm ROOM A411/412

Get Ready for a Bumpy Ride

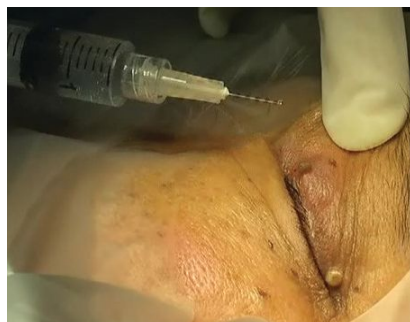Don't ignore eyelid lesions—ODs can easily take care of these directly or indirectly.

This afternoon, attendees will review how to identify select eyelid neoplasms, benign and malignant, and review treatment and management. During “Lumps and Bumps,” Michelle Welch, OD, staff optometrist for the Idabel Choctaw Nation Health Clinic and professor at the Northeastern State University Oklahoma College of Optometry, will help optometrists be aware of common and less common types of lesions that are important to identify early for the best long-term outcome for patients. “Whether or not an optometrist provides excision services of lesions to their patient population, one must be very familiar with them,” Dr. Welch says.

Dr. Welch will start her two-hour lecture with the adage, “biopsy all suspicious lesions.” According to her, these lesions should be evaluated by biopsy, and all patients should be offered the opportunity,

as every suspicious lesion should have a pathology screening. “We will review how to discuss lesion characteristics and the risk of malignancy with a patient,” Dr. Welch says. “A decision regarding biopsy should be made with the patient having appropriate education and being fully informed.” She also warns that any suspicious pigmented lesion should be approached with caution due to the risk of melanoma. One should not biopsy a melanoma without the appropriate technique and knowledge of how to do so.

Dr. Welch will give an overview of lesions that can easily be removed in-office by the OD and those that should be referred for oculoplastic management. “When evaluating a lesion for in-office excision, optometrists should “pick their lesion carefully.” She will provide attendees tips for successful evaluation of these lesions.



Today: learn the indications and risks surrounding papilloma removal.

Most lesions that optometrists will be addressing are likely to be superficial, so Dr. Welch will provide examples of techniques for appropriate excision while decreasing the risk of infection and scarring. “The healing process of the skin is important to remember, so educate the patient on to help them have the best outcome after their procedure,” she notes.

“Any time we are planning to offer a patient treatment for any

lesion, we educate them on the indications, risks, contraindications and all alternative management strategies—not just the ones optometrists can provide,” Dr. Welch says. “Be sure to convey this in language the patient can understand and document it through an informed consent process and form.”

Part of the lecture will go over chalazia management, including techniques for incision and curettage, an increasingly common procedure among optometrists. Dr. Welch believes that guiding these patients post-procedure is essential. “Advise them on expected and unexpected results and what to do in case any unexpected finding is encountered,” she says.

According to Dr. Welch, this extensive session will be a great benefit to those who will manage these patients in office as well as those who will be comanaging. ■

Understanding Uveitis: An Intro for ODs

Today: 11:15am–12:15pm

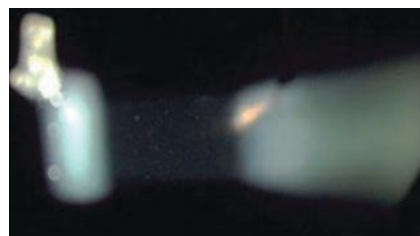ROOM A411/412

Learn the systemic and ocular approaches to management in this informative lecture.

Optometrists are certainly familiar with uveitis and its many possible manifestations. But what exactly causes it, what does the diagnosis portend and what's the treatment?

In this morning's lecture, “Uveitis: Systemic and Ocular Approaches to Management,” Dr. Nathan Lighthizer, OD, will discuss all that and everything else you need to know about uveitis, including the common symptoms (e.g., pain, red eye, tearing, photophobia, blurred vision) and why it's so important to figure out the cause.

In fact, Dr. Lighthizer says that's the first step. While looking into the cause, some questions to ask include:



Characteristic “cells and flare” presentation in acute anterior uveitis.

- Is it idiopathic?
- Is it HLA-B27?
- Is it sarcoidosis?
- Is it from ankylosing spondylitis?
- Is it from inflammatory bowel disease?

In many instances, sending the patient for bloodwork or other lab testing can reveal the origin. After

figuring out the cause, it's time to classify uveitis into a group, which is key to the proper diagnosis and management. Dr. Lighthizer will go into great length about the three most common classifications of uveitis, which each have variations of their own to contend with: (1) acute or chronic, (2) unilateral or bilateral, (3) granulomatous anterior uveitis or non-granulomatous anterior uveitis. The most common, he says, is acute, unilateral, non-granulomatous anterior uveitis.

Most anterior uveitis is idiopathic in nature, with HLA-B27 being the second most common etiology. Dr. Lighthizer will discuss various conditions, explaining how to trace the presenting signs and symptoms

to the likely cause and let that guide the approach to management.

Given the severity of pain that may accompany uveitis, the next important step is to treat it strongly and swiftly. Dr. Lighthizer says you can always taper or decrease steroids later, but it's important to treat inflammatory conditions aggressively so it doesn't linger and have potential side effects, such as elevated IOP.

Dr. Lighthizer hopes the main thing attendees take away from his lecture is a reminder of how just many entities can cause inflammation in front of the eye and to not take an overly cautious, wait-and-see approach when treating this condition. ■

Message from outgoing SECO President Max Raynor, OD

Turning the Corner on Pandemic Hardships

Welcome back to Atlanta! This past year has been a challenging and exciting one on many levels.

SECO was the last large meeting in 2020, and we are the first in 2021. We were committed to creating an event experience this year where our participants could safely and effectively come together to access a wide variety of learning opportunities, see the latest in technology and services, and forge new connections with the eyecare community.

The exciting part of this past year was the success of our year-round online education portal, SECO University. Immediately following the pandemic, we had our new online

webinars (“SECO Live”) up and running for optometrists. We also partnered with the National Academy of Opticianry and launched an online CE for opticians. SECO Live delivered over 100 hours of CE and was considered a monumental success.

In addition, we also launched a virtual registration offering to attendees that could not be with us this week in person. A total of 49 courses and 70 hours of CE over six days is available to our virtual participants. These initiatives continue to expand the reach and relevance of SECO continuing education.

SECO is most fortunate to have a group of dedicated professionals working year-round to make the an-

nual Congress and SECO University online CE program the leading resource for continuing education. The SECO CE programs are developed for the profession, by the profession. We would also like to thank our industry partners for their support of our overall program and organization.

With the unprecedented year we have experienced in the profession, now more than ever, we needed to come together as a community



Max Raynor, OD

and are grateful for the continued support of SECO. With strong continued financial support from our industry partners, SECO is able to continue delivering an unparalleled education program, in an affordable offering for optometrists, opticians, paraoptometric technicians and the entire team.

Last but certainly not least, *thank you* for your support of SECO, and we look forward to seeing everyone again next year in New Orleans, March 9-13! ■

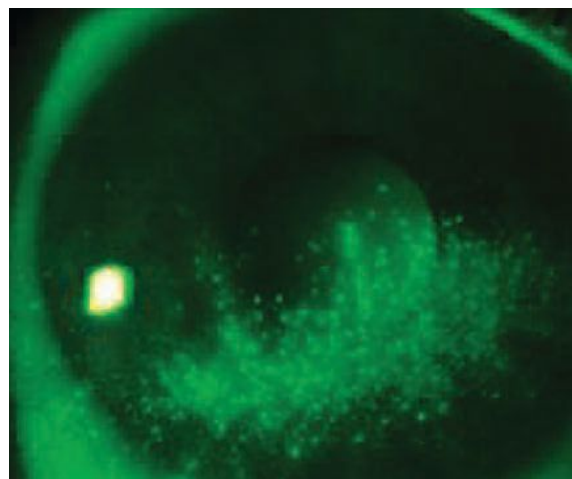
The Price We Pay For Beauty

Makeup doesn't just take a financial toll; the eye may also find itself in the crossfire.

Consumers splurge for cosmetic and anti-aging products at alarming rates,” said Leslie O’Dell, OD, as she opened her course, “Beauty and the Beast,” yesterday morning. In the United States alone, Dr. O’Dell noted, 37% of women have used an anti-aging product. She added that the anti-aging industry brings in \$2.1 billion each year, and the cosmetic industry as a whole comprises \$62.5 billion yearly.

Dr. O’Dell then moved into a discussion of beauty industry regulation shockers. First, the law that governs cosmetics took effect 83 years ago and hasn’t kept up with the times. There are few banned chemicals in the United States—just 11 compared with 1,300+ in the European Union—and no mandatory recalls in place to protect consumers, according to Dr. O’Dell. She also warned attendees that labels cannot be trusted, as cosmetic marketing is misleading.

The average female patient uses 12 cosmetic products daily (nine out of 10 in the 18 to 54 age group use mascara), exposing herself to an average of 167 different chemicals in the process; the average male patient uses six. Of the 10,000 industrial-strength chemicals that are commonly used, only 20% have been



Even low concentrations of preservatives like BAK, which typically aren't listed as ingredients, are known to cause ocular surface disease.

proven safe. This is especially concerning when you add in the lack of education and awareness among clinicians and consumers regarding cosmetics and eye health; only 11% of patients have conversations with their eye care provider.

As they relate to the eye, cosmetics can obstruct the meibomian gland terminal orifices, limit meibum delivery to the lid margin lipid reservoirs and subsequent delivery onto the

tear film, desiccate the tear film and increase the inflammation, inducing evaporative load of patients with ocular surface disease. To evaluate for these adverse effects, Dr. O’Dell recommended conducting an ocular exam that progresses from the lids and lashes to the conjunctiva to the cornea to lid eversion to the meibomian glands.

She warned attendees that patients who choose to wear makeup must realize the risks that come with use, including contamination and injury. To prevent these, she suggested avoiding waterproof products, retinol, benzalkonium chloride (BAK), application to the waterline and Botox. She also recommended steering clear of cosmetic sharing, product misuse, heat alterations, saliva moistening and application while moving. Best practices for cosmetic wear without risk include sharpening eyeliner pencils prior to each use, replacing moist cosmetics monthly, removing makeup daily and cleaning makeup brushes regularly, to name a few.

Dr. O’Dell closed the discussion by advising clinicians to offer patients a list of appropriate techniques and products, teach them to read ingredient lists and advise them on preferred shopping places for eye-friendly products. ■

SECO's 2021 Award Winners

The organization recognizes the following leaders in optometry for their significant contributions.

The leadership of SECO International proudly announces the recipients of its 2021 awards. SECO recognizes the following leaders in optometry and their significant contributions to the profession.

"It is the continuous contributions of knowledge, leadership, advocacy and service that is the foundation of our profession," said Dr. Max Raynor, SECO's outgoing president. "SECO celebrates those that are going above and beyond in their efforts to serve. SECO leadership wants to thank James Sandefur, OD, Lauren Stirling, OD, Andrew Cook, OD, and Caydie George, CPOT, for their personal and professional contributions."

Optometrist of the South

The 2021 Optometrist of the South award is presented to James Sandefur, OD, of Oakdale,



LA. Dr. Sandefur is being recognized for his outstanding work in the community and profession for over 50 years.

In private practice for the majority of his career, Dr. Sandefur continues to serve the optometric community as executive director of the Optometry

Association of Louisiana, 1997 to present. Dr. Sandefur is widely recognized and respected by his peers for his extraordinary career, leadership in professional associations and numerous contributions, as evidenced by receiving the SCO Lifetime Achievement Award in 2001, and being named Louisiana's Optometrist of the Year in 1993 and 2014.

In his honor, the OAL Board created the Dr. James D. Sandefur Distinguished Service award, which he was awarded for his many years of outstanding service and earned the moniker "The Father of Louisiana Optometry." Because of his tireless service on local, state and national levels, it is impossible to overstate the impact Dr. Sandefur has had on the profession of optometry and the public. Perhaps his greatest accomplishment is the immeasurable influence he's had by selflessly mentoring students and doctors of optometry across the country and abroad.

Young Optometrist of the South

The 2021 Young Optometrist of the South award is presented to Lauren Stirling, OD, of Florence, AL. Dr. Stirling is currently in private practice at the Campbell Vision Center in Russellville, AL.



Before completing her residency at the Veterans Affairs Medical Center in Tuscaloosa in June 2012, Dr. Stirling obtained her OD degree from the University of Alabama School of Optometry in 2011; prior to that, she earned a bach-

elor of science degree in biology at Southeastern Louisiana University in 2007.

During her time in optometry school, she was a Beta Sigma Kappa member, received the Walmart Scholarship and the New Orleans Contact Lens Society Scholarship, and won the Jess Boyd Eskridge Clinical Excellence Award.

Dr. Stirling has reviewed three pieces of professional development literature and has been a presenter and author of numerous academic presentations and publications. Dr. Stirling is a board member for the Alabama Board of Optometric Scholarship Awards as well as a Fellow of the American Academy of Optometry. In addition she became board-certified by the American Board of Optometry in 2012.

Dr. Stirling was named the Alabama Optometric Association (ALOA) Young Optometrist of the Year in 2020 and currently serves as an ALOA board member.

Paraoptometric of the South

The 2021 Paraoptometric of the South award is



presented to Caydie George of Tupelo, MS. Currently working for four optometrists and three ophthalmologists, she has been in the optometry/ophthalmology field for 21 years, completing her CPOT in 2007 and her COA in

2009. Never one to stop learning, she is currently studying for her COT.

Mrs. George trains new hires at the practice, and her skills include team leadership, scheduling, MIPS reporting and comprehensive patient workup. Outside of business hours, Mrs. George is fiercely passionate about children's eyesight, regularly visiting classrooms to talk about the anatomy of the eyes and how to maintain healthy vision. She also enjoys volunteering with elderly and handicapped to assist with their unique vision issues.

Mrs. George looks forward to the opportunity to realize her dreams and participate in a mission trip to offer eye exams in underprivileged areas.

President's Award

The Southern Council of Optometrists is pleased to honor Andrew G. Cook, OD, of Garner, NC, with the 2021 President's Award in recognition of his dedicated years and outstanding advancements to the profession of optometry.



Dr. Cook received his doctor of optometry degree with honors from Southern College of Optometry in Memphis, TN, before founding his private practice in Garner, which he owned for 33 years. Currently Dr. Cook serves as optometrist and

clinical affairs liaison at MyEyeDr. He previously served as president of the Southern Council of Optometrists, the North Carolina State Board of Optometry and the North Carolina State Optometric Society.

Among many other distinguished service awards, he was recognized as the North Carolina State Optometric Society Optometrist of the Year in 2008. Dr. Cook's involvement and service to numerous organizations within the profession as well as his local community demonstrates his commitment to the growth of optometry.

These optometry experts are recognized for their commitment to the profession and their exceptional skills. SECO congratulates the 2021 award recipients. ■



A NEW WAY TO EXPERIENCE REVIEW OF OPTOMETRY

Follow us on Instagram at @revoptom for striking clinical images, daily news headlines, issue previews and great content from the magazine—all formatted for mobile



Stories for 3-26-21

Missed Neuro Diagnoses Common, Can Lead to Patient Harm
Study finds half of all retinal vein aneurysms and one in four of those experienced some kind of adverse impact on health.

CDC Aims to Break Down Telemed Barriers in Glaucoma
These universities get funding for a two-year investigation into the logistics and clinical value of remote screening.

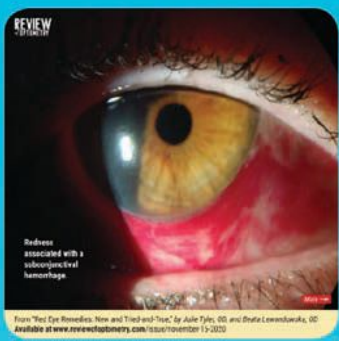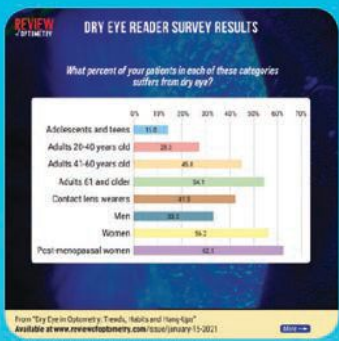
Thyroid Eye Disease Increases Risk of Optic Nerve Damage
Affected eyes experience thinning of the RNFL and ganglion cell layer, increasing the likelihood of progressing to subclinical optic neuropathy.

Read today at www.reviewofoptometry.com/news

High myopia with a tessellated and thin choroid (red line), SRF disruption (gray line), SRF (yellow line) and photoreceptors (blue line) with early subretinal and hyperreflective material (purple line)—all consistent with myopic DME.

Chorioidal folds causing sub-RPE undulations (red line).

From "Take Macular OCT to a Whole New Level" by Sara Woldring, OD
Available at www.reviewofoptometry.com/issue/february-19-2021



CLINICAL FEATURES OF COMMON SECONDARY CONDITIONS ASSOCIATED WITH GLAUCOMA

CONDITION	KEY CLINICAL FEATURES	OPHTHALMIC FINDINGS
Pigment dispersion syndrome	Flare and deposits on anterior segment structures (e.g., anterior lens surface and corneal endothelium)	Active stage shows homogeneous pigmentation of the anterior angle; inactive stage shows more segmented lamellar bodies and
Pseudoexfoliation syndrome	Extensive lamellar deposits on anterior segment structures (e.g., anterior lens surface, corneal endothelium, trabecular meshwork, iris transillumination defects)	Deposition of extracellular material in anterior chamber angle; lamellar bodies; pigmentation of the trabecular meshwork
Anterior segment inflammation	Anterior chamber cells or flare; anterior chamber flare; anterior chamber cells	Peripheria anterior structure
Angle recession	Angle recession; history and/or acute information; iris sprouts; iris, myopia; peripheral anterior synechia; iris transillumination defects	Widening of the ciliary body band; atrophy of the ciliary body; angle recession; hyperpigmentation of the angle; narrowing of the ciliary spur (iris root attachment)
Neovascularization	Neovascularization	Neovascularization within the angle

From "Glaucoma: Update on Clinical Care" by Sara Woldring, OD, and Sara Woldring, OD
Available at www.reviewofoptometry.com/issue/march-15-2021

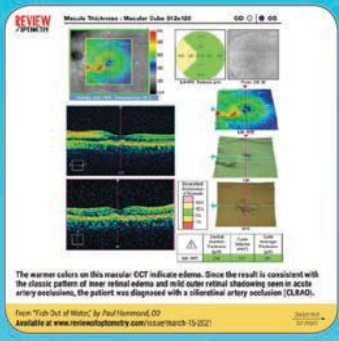
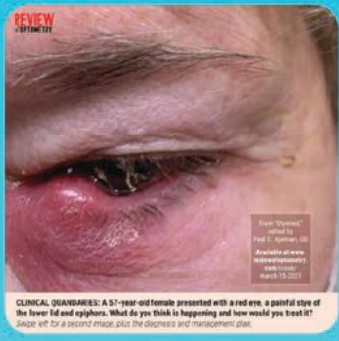RETINA DISEASE: A 23-year-old white female high myope presented with blurred vision, OD=OS, for over six months, and said she felt like there was a "dead spot" in her central vision. Medical history was significant for Crohn's disease since age 14, which had a recent flare-up. OCTA measured 20400 OD with eccentric viewing and 28719 OS. Amalgar grid showed a central scotoma in both eyes but was very dense OD. There was stria inversus of both optic nerves. She had a myopic-appearing fundus, and other significant changes noted above. Larger left for OCT scans.

From "Dead Spot" by Eric DeBaker, OD, edited by Mark D'Amico, OD
Available at www.reviewofoptometry.com/issue/march-15-2021

MAR 2021

Dry Eye Issue

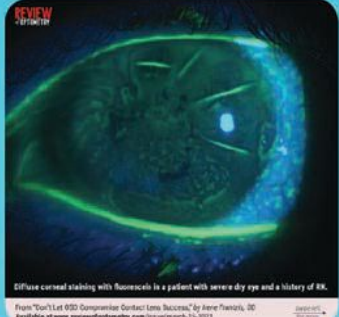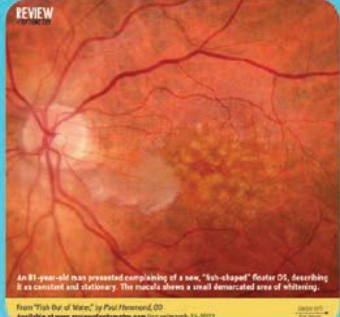AVAILABLE MARCH 2021
www.reviewofoptometry.com



Additional studies that might yield diagnostically pertinent data:

- 30-30 test for peripheral vision
- ENG and dark adaptation looking for rod function depression
- 5- or 7- line raster OCT of the macula
- Blood work (panels levels of creatinine and urea nitrogen)

From "More Than 99% by Andrew S. Gansland, OD
Available at www.reviewofoptometry.com/issue/march-15-2021



FAST FACTS ON CLRAO

- only present in approximately one in three people
- provides a secondary blood supply to the inner layers of the macula
- comprises only 5.3% to 7.1% of all retinal artery occlusions
- has been associated with embolism, lupus, antiphospholipid syndrome, sickle cell, pregnancy and systemic hypertension
- can present in three ways: (1) with ischemic optic neuropathy in giant cell arteritis, (2) with concomitant central retinal vein occlusion or (3) in isolation

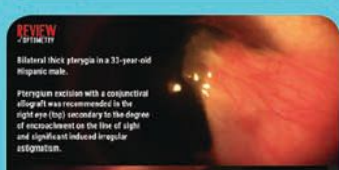Management and prognosis:

- GCA: Critical to arrange for same-day ESR and CRP testing and begin IT steroid. Visual prognosis is the worst of the three due to lack of redundant circulation.
- CRVO: Treatment focuses on macular edema and macularization. Better prognosis, as the vessel occlusion tends to be non-ischemic.
- If isolated: Treatments can include ocular massage, paracentesis, intra-arterial thrombolysis and hyperbaric oxygen. Best visual prognosis.

CASE OUTCOME

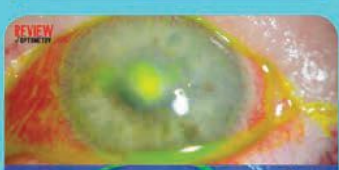This patient's case was deemed likely retinal and central in nature. The field defect persisted, but his vision remained 20/20 and the symptoms were not as bothersome.

From "Itch Out of Water" by Paul Howard, OD
Available at www.reviewofoptometry.com/issue/march-15-2021



Stories for 3-26-21

Missed Neuro Diagnoses Common, Can Lead to Patient Harm
Study finds half of all retinal vein aneurysms and one in four of those experienced some kind of adverse impact on health.





EXHIBITOR BOOTH LISTINGS FOR SECO 2021

Optometry's Marketplace™ puts you in the same room with leading suppliers offering brands representing everything you need to keep your practice on the cutting edge. Through integrated learning, discover the technology, equipment and services that will help you create an exceptional experience for your patients and run a more profitable practice.

ACEP USA.....	1019	MacuLogix	635
Acculens	1149	MedTech International Group.....	736
Aerie Pharmaceuticals	1227	Modern Optical International	958
Alcon	1037	MyEyeDr	917
Allergan	806	National Academy of Opticianry.....	1210
American Association of Corporate Optometrists	1225	Next Vision Instruments	539
American Board of Opticianry & National Contact Lens Examiners	1111	Nidek	742A
American Board of Optometry	1123	Notal Vision	955
Arbor Eyewear	1053	Novartis Pharmaceuticals.....	840
Armed Forces Optometric Society.....	637	Oasis Medical.....	722
Avellino Labs.....	731	Ocular Innovations.....	953
Bausch + Lomb.....	103	Oculus	636
BlephEx.....	759	Olleyes.....	859
Bruder Healthcare Company.....	653	Opticians Association of Georgia	1118
Coburn Technologies.....	1249	Opticam Tech	1148
Compulink Healthcare Solutions.....	929	Optometric Architects	629
CooperVision	835	Optos	1153
Design Eyewear Group.....	V14	Optovue	638
DGH Technology	1059	Orgreen Goldsmith.....	V8
Digital Healthcare Professionals	738	Ottica Venets IISospriri Eyewear	V3
Diopsys	1058	Enhanced Therapy USA	1254
Doctor Multimedia	1131	Pharmanex/MD Solution.....	644
Eastern Ophthalmic Supply & Repair.....	1147	qPlusoptix	1222
Edison Optics	752	Poets Eyewear.....	V4
eSee Acuity	1154	Popsharp.....	754
Etnia Barcelona	V1	Premier Ophthalmic Services	642
Eventsphere	1213	Quantel Medical	634
Ye Designs	825	Remote Area Medical	1251
Eyefficient.....	744A	Review of Optometry	611
Eyefunc.....	631	RVL Pharmaceuticals	73
Eyes of Faith	734	Salt.....	V6
Eyevance Pharmaceuticals.....	1141	Santinelli International	1125
Falck Medical	860	Scleral Lens Education Society.....	1221
Faniel Eyewear	V10	Scope Eyecare.....	1224
FCI Ophthalmics	1223	Scratchpay	1117
Fusion Eyewear	V12	Opticwash	1116
Gazal Eyewear.....	V9	Sight Sciences.....	619
Heidelberg Engineering.....	1243	Kodak Lens/Signet Armorlite	724
Heine	535	Simplifeye.....	639
Henau Eyewear	V7	Southern College of Optometry.....	823
Icare USA	1122	Studio Optyx.....	V13
Idealoptics	1017	Sun Ophthalmics	818
Innovative Technology Solutions of NC.....	537	TelScreen	742
Invision Magazine.....	1219	The Dry Eye Doctor.....	744
Jeunesse Innovations	1155	ThermaMedx	925
Kala Pharmaceuticals	1113	Topcon Healthcare	1135
Karl-Optical Distribution.....	655	Vision Center South	643
Kasperek USA Optical	822	Visual Inspirations	V11
Kids Bright Eyes	723	VOSH International.....	1148A
Lands' End Business Outfitters.....	1247	Walman.....	630
Luxottica Group	911	Wolters Kluwer	1245
MacuHealth.....	728	Zeiss.....	829

SATURDAY AT A GLANCE

OD & AHP ADVANCED LEARNING COURSES (SHADED IN GREEN) HAVE VARIOUS ACCREDITATIONS BASED ON CONTENT, AND THE ACCREDITATION INFORMATION IS LISTED FOR EACH COURSE BELOW.

7:00 AM	145 When Topical Just Isn't Enough 7:00 AM-8:00 AM Room A411/412 Justin Schweitzer, OD	515 OD & AHP Advanced Swollen Optic Nerves: Now What? 7:00 AM-8:00 AM Room A311/312 & Streaming Nate Lighthizer, OD			
7:15 AM					
7:30 AM					
7:45 AM					
8:00 AM	062 OD & AHP Advanced SPECIAL SESSION Anterior Segment Advances: The Future is Now! 8:00 AM-10:00 AM Amphitheater A2 & Streaming Lawrence Woodard, MD John Berdahl, MD				
8:15 AM					
8:30 AM					
8:45 AM					
9:00 AM					
9:15 AM					
9:30 AM					
9:45 AM					
10:00 AM	OPTOMETRY'S MARKETPLACE™ DISCOVER EFFICIENCY-ENHANCING SOLUTIONS, STATE-OF-THE-ART EQUIPMENT, FASHIONABLE EYEWEAR STYLES, AND INTERACTIVE EDUCATIONAL EVENTS AS FAR AS THE EYE CAN SEE - ALL ON THE SHOW FLOOR.		202 FREE OD Presentation Theater A Patient Management Perspective on Dry Eye Disease 10:00 AM-11:00 AM Exhibit Hall Presentation Theater Ron Melton, OD; Randall Thomas, OD		
10:15 AM					
10:30 AM					
10:45 AM					
11:00 AM	4/30 9:00 AM-5:00 PM 5/1 9:00 AM-4:00 PM		PRESENTATION THEATER THE VIEW OPTIX & OD LOUNGE		
11:15 AM	146 A Refresher on OCT for Primary Eye Care Providers 11:15 AM-12:15 PM Room A311/312 & Streaming Chris Wroten	148 Uveitis: Systemic and Ocular Approaches to Management 11:15 AM-12:15 PM Room A411/412 Nate Lighthizer, OD	149 The Nuances of Normal Tension Glaucoma 11:15 AM-12:15 PM Room A313/314 Justin Schweitzer, OD	208 Creating Perceived Value 11:15 AM-12:15 PM Exhibit Hall OPTIX Zone Pete Hanlin	212 Frame Fashion Tour II 11:30 AM-12:00 PM Exhibit Hall The View Laurie Pierce
11:30 AM					
11:45 AM					
12:00 PM					
12:15 PM	307 FREE LUNCH OD Lunch Symposia Presby What: Enhancing the Presbyopia Dialogue with Patients, Rachel Wruble, OD; Mark Shaeffer, OD, presented by Allergan Innovations In Dry Eye and Ocular Health, Walt Whitley, OD, presented by Alcon 12:15 PM-1:15 PM GWCC Amphitheater EH A2				
12:30 PM					
12:45 PM					
1:00 PM					
1:15 PM	PRESENTATION THEATERS EARN FREE CE CREDITS AND GAIN VALUABLE INFORMATION IN OPTOMETRY'S MARKETPLACE™.			203 FREE OD Presentation Theater New Treatment Options for Patients with Acquired Blepharoptosis 1:15 PM-2:15 PM Exhibit Hall Presentation Theater April Jasper, OD	
1:30 PM					214 Movie & Cinema Influencing Fashion & Style 1:30 PM-2:15 PM Exhibit Hall The View Gazal Tabrizipour
1:45 PM					
2:00 PM					
2:15 PM	150 Floaters: A New Solution to an Old Problem 2:15 PM-3:15 PM Room A411/412 Nate Lighthizer, OD	151 Eyeing Glaucoma in the 21st Century 2:15 PM-3:15 PM Room A311/312 & Streaming Ben Casella, OD	159 Human Trafficking 2:15 PM-3:15 PM Room A302 April Jasper, OD	153 The Silent Thieves: Secondary Glaucoma 2:15 PM-3:15 PM Room A313/314 Justin Schweitzer, OD	
2:30 PM					
2:45 PM					
3:00 PM					
3:15 PM					
3:30 PM					
3:45 PM					
4:00 PM	154 Lumps and Bumps 4:00 PM-6:00 PM Room A411/412 Michelle Welch, OD	516 OD & AHP Advanced The Challenges of the Cornea 4:00 PM-6:00 PM Room A311/312 & Streaming Justin Schweitzer, OD	155 Following AMD with OCT 4:00 PM-6:00 PM Room A313/314 Julie Rodman, OD	156 Prevention of Medical Errors Within Eyecare 4:00 PM-6:00 PM Room A302 April Jasper, OD	161 A Painful Practice 4:00 PM-6:00 PM Room A404/405 & Streaming Will Smith OD
4:15 PM					
4:30 PM					
4:45 PM					
5:00 PM					
5:15 PM					
5:30 PM					
5:45 PM					
6:00 PM					
6:15 PM	157 The Inside Scoop on Retinal Breaks 6:15 PM-7:15 PM Room A313/314 Jessica Steen, OD	158 More Than Meets the Dry Eye 6:15 PM-7:15 PM Room A302 Scott Moscow, OD	517 OD & AHP Advanced CL Management for the Team 6:15 PM-7:15 PM Room A311/312 & Streaming April Jasper, OD	160 Innovations in Eyecare Technology 6:15 PM-7:15 PM Room A411/412 Paul Karpecki, OD	
6:30 PM					
6:45 PM					
7:00 PM					
7:15 PM					
7:30 PM					
7:45 PM					

OPTOMETRY'S MARKETPLACE™ 9:00AM-5:00PM

SECO's comprehensive program offers more than 70 educational courses throughout the conference.

For course descriptions and the entire five-day education program, visit attendseco.com/education.























Here are **today's courses** for optometrists and allied health professionals.

Missed a course at SECO 2021? Log on to secouniversity.com throughout the year to access all courses.

- OD-ONLY COURSES
- ALLIED HEALTHCARE PROFESSIONALS-ONLY COURSES
- OD & AHP ADVANCED COURSES
- MedPRO360 COURSES
- ABO
- AOA Paraoptometric
- Treatment & Management of Ocular Disease: Anterior Segment
- Florida CE Broker (live only)
- CEE/TQ Course (live only)
- Contact Lenses

7:00 AM	735 Are You Feeling ANSI About Standards? 7:00 AM-8:00 AM Room A315/316 & Streaming Phernell Walker				
7:15 AM					
7:30 AM					
7:45 AM					
8:00 AM	736 Case Studies of the Rich and Famous: Troubleshooting From the Exam Room to the Optical 8:00 AM-10:00 AM Room A311/312 & Streaming Phernell Walker				
8:15 AM					
8:30 AM					
8:45 AM					
9:00 AM					
9:15 AM					
9:30 AM					
9:45 AM					
10:00 AM					
10:15 AM	737 The Clear and Present Danger of Diabetes 10:15 AM-11:15 AM Room A313/314 Phernell Walker	738 Clinical Terminology for Opticians and Technicians 10:15 AM-11:15 AM Room A404/405 Rebecca Johnson	420 MedPRO360 Post COVID Leadership Tactics to Implement Daily 10:15 AM-11:15 AM Room A311/312 & Streaming Ted McElroy, OD	OPTOMETRY'S MARKETPLACE™ DISCOVER EFFICIENCY-ENHANCING SOLUTIONS, STATE-OF-THE-ART EQUIPMENT, FASHIONABLE EYEWEAR STYLES, AND INTERACTIVE EDUCATIONAL EVENTS AS FAR AS THE EYE CAN SEE- ALL ON THE SHOW FLOOR. 4/30 9:00 AM-5:00 PM 5/1 9:00 AM-4:00 PM PRESENTATION THEATER THE VIEW OPTIX & OD LOUNGE	
10:30 AM					
10:45 AM					
11:00 AM					
11:15 AM	306 FREE LUNCH Student Lunch Symposia				
11:30 AM	NETWORKING RECEPTION: clariti®1 day: Continuous Improvement, Steve Rosinski, OD, presented by Coopervision and Alcon				
11:45 AM					
12:00 PM					
12:15 PM	739 Mastering Ophthalmic Formulæ 11:15 AM-12:15 AM Room A315/316 & Streaming Phernell Walker	740 Refractive Errors Defined 11:15 AM-12:15 AM Room A404/405 Rebecca Johnson	421 MedPRO360 Creating Influencers to Promote Your Practice for You 11:15 AM-12:15 AM Room A411/412 Darryl Glover, OD		
12:30 PM					
12:45 PM					
1:00 PM	PRESENTATION THEATERS EARN FREE CE CREDITS AND GAIN VALUABLE INFORMATION IN OPTOMETRY'S MARKETPLACE™.				
1:15 PM					
1:30 PM					
1:45 PM					
2:00 PM					
2:15 PM	741 Fastest Finger First-Identify this Corneal Pathology 2:15 PM-3:15 PM Room A410 Buddy Russell	742 Triage for Techs: Managing Emergencies 2:15 PM-3:15 PM Room A404/405 Rebecca Johnson	422 MedPRO360 Artificial Intelligence in Eye Care 2:15 PM-3:15 PM Room A315/316 & Streaming Chris Wroten, OD		
2:30 PM					
2:45 PM					
3:00 PM					
3:15 PM					
3:30 PM		210 Frames Advisor 3:15 PM-4:15 PM Exhibit Hall OPTIX Zone Jonathan Smith			
3:45 PM					
4:00 PM	743 Contact Lenses to improve Quality of Life 4:00 PM-6:00 PM Room A315/316 & Streaming Buddy Russell				
4:15 PM					
4:30 PM					
4:45 PM					
5:00 PM					
5:15 PM					
5:30 PM					
5:45 PM					
6:00 PM					
6:15 PM	744 Advanced Prism Applications 6:15 PM-7:15 PM Room A315/316 & Streaming Phernell Walker	426 MedPRO360 Hello, Is Anybody Listening? 6:15 PM-7:15 PM Room A404/405 & Streaming Rebecca Johnson			
6:30 PM					
6:45 PM					
7:00 PM					
7:15 PM					
7:30 PM					
7:45 PM					





OPTOMETRY'S MARKETPLACE™ 9:00AM-5:00PM

- | | | | |
|---|---|--|---|
|  Ethics/Jurisprudence |  Neuro-Optometry |  Treatment & Management of Ocular Disease: Posterior Segment |  Low Vision/Vision Impairment & Rehabilitation |
|  Glaucoma |  Oral Pharmaceutical |  Refractive Surgery Management |  Facilitated Lab/Workshop |
|  General Optometry |  Principles of Diagnosis |  Systemic/Ocular Disease |  Virtual Session |
|  Injection Skills |  Pharmacology |  Surgical Procedures |  Food Course |
|  Laser Procedures |  Practice Management |  Functional Vision/Pediatrics | |
|  NCLE |  Peri-Operative Management of Ophthalmic Surgery |  Public Health | |

* Brought to you by the National Academy of Opticianry

SUNDAY AT A GLANCE





OD & AHP ADVANCED LEARNING COURSES (SHADED IN GREEN) HAVE VARIOUS ACCREDITATIONS BASED ON CONTENT, AND THE ACCREDITATION INFORMATION IS LISTED FOR EACH COURSE BELOW.





























7:00 AM	AACO@SECO 2021 Education Program Corporate Optometry Day 8:00 AM-4:30 PM Omni Room TBA Educational Program Chairs: Nikil Patel, OD Naheed Ahmad, OD			
7:15 AM				
7:30 AM				
7:45 AM				
8:00 AM		171 My Latest and Greatest Cases 8:00 AM-10:00 AM Room A311/312 & Streaming Paul C. Ajamian, OD 	750 Preventing Medical Errors in the Optical Environment 8:00 AM-10:00 AM Room A315/316 & Streaming Diane Drake 	
8:15 AM				
8:30 AM				
8:45 AM				
9:00 AM				
9:15 AM				
9:30 AM				
9:45 AM				
10:00 AM				
10:15 AM	172 Steering Clear of Malpractice 10:15 AM-11:15 AM Room A311/312 & Streaming Paul C. Ajamian, OD 	751 Georgia Opticianry Laws and Rules 10:15 AM-11:15 AM Room A315/316 & Streaming Diane Drake 		
10:30 AM				
10:45 AM				
11:00 AM				
11:15 AM				
11:30 AM				
11:45 AM				
12:00 PM				
12:15 PM				
12:30 PM				
12:45 PM				
1:00 PM				
1:15 PM				
1:30 PM				
1:45 PM				
2:00 PM				
2:15 PM				
2:30 PM				
2:45 PM				
3:00 PM				
3:15 PM				
3:30 PM				
3:45 PM				
4:00 PM				
4:15 PM				
4:30 PM				
4:45 PM				
5:00 PM				

SECO's comprehensive program offers more than 70 educational courses throughout the conference.

Here are **Sunday's courses** for optometrists and allied health professionals. For course descriptions and the entire five-day education program, visit attendseco.com/education.

Missed a course at SECO 2021? Log on to secouniversity.com throughout the year to access all courses.

-  OD-ONLY COURSES
-  ALLIED HEALTHCARE PROFESSIONALS-ONLY COURSES
-  OD & AHP ADVANCED COURSES
-  MedPRO360 COURSES

- | | | | |
|---|---|--|---|
|  ABO |  General Optometry |  Practice Management |  Public Health |
|  AOA Paraoptometric |  Injection Skills |  Peri-Operative Management of Ophthalmic Surgery |  Low Vision/Vision Impairment & Rehabilitation |
|  Treatment & Management of Ocular Disease: Anterior Segment |  Laser Procedures |  Treatment & Management of Ocular Disease: Posterior Segment |  Facilitated Lab/Workshop |
|  Florida CE Broker (live only) |  NCLB |  Refractive Surgery Management |  Virtual Session |
|  CEE/TQ Course (live only) |  Neuro-Optometry |  Systemic/Ocular Disease |  Food Course |
|  Contact Lenses |  Oral Pharmaceutical |  Surgical Procedures | |
|  Ethics/Jurisprudence |  Principles of Diagnosis |  Functional Vision/Pediatrics | |
|  Glaucoma |  Pharmacology | | |

* Brought to you by the National Academy of Opticianry

Top Docs' Message: Knowledge is Power

CLINICAL PERSPECTIVES, cont. from Page 1

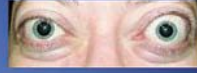Speaking of glaucoma, Dr. Melton said this is an area ODs should get more involved in. He talked about a practice with five glaucoma specialists—and a three- to four-month waiting list for patients. This is an example where specialists are overwhelmed, and there's a big need for ODs to step in and fill that role.

In response, Dr. Thomas didn't hold back.

"I'm kind of sick and tired of hearing how these glaucoma specialists are so crushed," Dr. Thomas said. "I just saw a [patient] three weeks ago and she's been going to a glaucoma specialist for pigment dispersion syndrome for the last 30 years. What is a glaucoma surgeon doing following a patient with pigment dispersion syndrome? That's a waste; for us, it would be a pinnacle of our expertise."

Treatment for Thyroid-related Proptosis

- New breakthrough drug to reduce proptosis
- Tepezza™ (teprotumumab) Horizon Therapeutics
- 75% achieved ~2.5mm reduction in proptosis
- I.V. infusion every 3 weeks for 8 sessions
- Mild to moderate side effects:
 - » Muscle spasm » Nausea
 - » Alopecia » Diarrhea
 - » Fatigue » Hyperglycemia
 - » Hearing loss » Dry skin
 - » Dysgeusia » Headache
- Cost is about \$100,000.00 for 6 month treatment



NEJM January 23, 2020

Dr. Melton agrees: "We need to educate our patients as a profession as to what we can take on and what we can do—we're obviously not doing that."

When discussing medications, they touched on emerging headlines for a drug as old as Timolol. On the mar-

ket since 1978, it's now shown to prevent migraines. Once a patient feels symptoms coming on, a recent study shows, topical administration can quickly abort the headache on the spot.

It's going to be systemically absorbed without going through the liver and being metabolized and delays onset.

Drs. Melton and Thomas also discussed hydroxychloroquine (Plaquenil), and how almost half of patients on this drug are overdosed. Proper dosing is a critical step in minimizing the risk of Plaquenil maculopathy,

and they recommend an app called DoseChecker, which helps calculate a patient's correct dosage based on their ideal body weight.

For thyroid eye disease and thyroid-related proptosis, they discussed the virtues of Tepezza (Horizon Therapeutics), which has been available for a little over a year. It "melts away" orbital fat and sinks the globe back 2mm to 3mm. There are quite a few side effects though, including muscle spasms, alopecia, fatigue, hearing loss, dysgeusia, nausea, diarrhea, hyperglycemia, dry skin and headache, and it's quite costly at \$100,000 for a six-month treatment.

Attendees left Drs. Melton and Thomas's lecture more educated on the unmet need for medical eye care services, as well as the knowledge to provide patient care services and the importance of taking care of people and building lasting relationships. ■

SECO 2021
WHERE SIGHT MEETS VISION™
APRIL 24 - MAY 2 | ATLANTA, GA

MAY 1, 2021
8:00PM - 12:00AM
OMNI HOTEL
GRAND BALLROOM

FEATURING THE BAND
BAD HABITS
THE EYEDOC OF ROCK

MASK-QUERADE
President's Celebration

SPONSORED IN PART BY
VISION SOURCE
SIGNATURE EYE CARE

LUXOTICA **OPTOMETRIC PHYSICIANS**

2022

NEW ORLEANS
MARCH 9-12
ERNEST N. MORIAL CONVENTION CENTER

SECO 2022
WHERE SIGHT MEETS VISION™

What OCT Reveals, Layer by Layer

OCT, continued from Page 1

Partial-thickness holes come in two varieties: tractional (based on presence of an epiretinal membrane and a schisis within the neurosensory retina) and degenerative (mostly epiretinal thickening over the ILM without schisis). While a tractional partial-thickness hole looks like a mustache and a degenerative one looks like a top hat, a pseudohole looks more like a sink or a rounded 'U.'

"With inner retinal disease, we're now focusing on the ILM to the external limiting membrane (ELM)," Dr. Rodman stated as she discussed diabetic retinopathy (DR) and vascular disease. For DR, she gave tips on how to distinguish hemorrhages, which are more superficial in the outer nuclear layer, from exudates, which exist on the plexiform layer. "When looking at diabetic OCTs, figure out how close the cystic spaces are to the macula and fovea to determine center-involving DME."

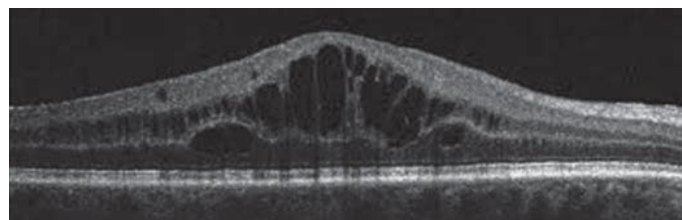
In proliferative DR, the OD will want to look at any involvement at the vitreomacular interface. "Neovascularization lives above the ILM," Dr. Rodman said. However, she interjected that real-life neovascularization examples won't be as clear on OCT as those she was presenting.

OCT & Outer Retinal Disease

The journey now took a look at the ELM down to the choroid. "I probably use OCT more with outer retinal disease because there are so many more conditions that need OCT to diagnose," Dr. Rodman said. A drusen would live between the RPE and Bruch's membrane. "When you use OCT, find the RPE, since it is the easiest," she suggested. Reticular pseudodrusen live in the subretinal space above the RPE and usually have a bad visual prognosis. Dr. Rodman is glad she can use OCT to help differentiate the two.

For pigment epithelial detachments (PEDs), Dr. Rodman advises looking for material beneath the RPE. Black on OCT denotes serous fluid, white signals homogenous drusen and the two colors together note hemorrhagic PEDs. She noted how hemorrhagic PEDs are similar to choroidal neovascularization (CNV). "Central serous chorioretinopathy (CSC) can be differentiated from PED since the RPE stays down and the fluid is above it," Dr. Rodman pointed out.

In an overview of dry and wet AMD, Dr. Rodman explained that type 1 CNV has the abnormality located below the RPE and above Bruch's membrane, while the abnor-



This OCT illustrates cystoid macular edema associated with a retinal vein occlusion.

malities in type 2 CNV are located above both the RPE and Bruch's. In geographic atrophy, the RPE is absent and there is choroidal shadowing since the usual reflexivity no longer bounces off the RPE.

Dr. Rodman then discussed pachychoroid entities. While choroids can vary within individuals, thickness over 390µm would designate a pachychoroid. Patients with no symptomatology would possibly have pachychoroid pigment epitheliopathy. Chronic central serous chorioretinopathy differentiates itself from its acute based on the how much the enlarged choroid vessels pushes up on the underlying tissue. Dr. Rodman noted polypoidal choroidal vasculopathy as a variant of AMD, with aneurysmal polyps pushing up on the RPE and causing PEDs, "like putting marbles underneath a tight surface."

The session ended with advice on

using OCT on the optic nerve. Dr. Rodman began this last section by distinguishing papilledema from pseudo-papilledema.

In the former, she said, look for an "m" sign with smooth contour of elevation, nasal tissue greater than 86µm on RNFL analysis and a thick hyporeflexive area separating the neurosensory retina and the RPE, dubbed the "lazy v" sign. Bruch's membrane will also be pushed anteriorly by increased intracranial pressure. "Optic nerve head drusen will be bumpy," Dr. Rodman said. "But you have to be super careful that you move your calipers off of blood vessels in a line scan." Also, Bruch's membrane is going down, not up. "If you get a good drusen, it will have a hyporeflexive center and a hyperreflexive margin," she noted.

Dr. Rodman demonstrated in a short amount of the time how OCT is useful in myriad conditions and provides a noninvasive way to assess retinal, choroidal and ONH anatomy. ■

THE VIEW

LUXURY EYEWEAR

VIEW What is Next for 2021!

The View is the place to be at SECO if you make or influence eyewear buying decisions. Learn what's new and what's next and how to solve even your most difficult fitting challenges. Mix and mingle with your peers who face the same issues you do. Share ideas and strategies for creating the most dynamic inventory mix for your unique environment while increasing patient satisfaction and practice revenue.

In The VIEW Presentations

Frame Fashion Trends Impacting Optometry Sales!

NOT FOR CE CREDIT, NO REGISTRATION NECESSARY

Frame Fashion Tour

Laurie O'Keefe Pierce
Friday, April 30th, 4:30 PM – 5:00 PM
Saturday, May 1st, 11:30 AM – 12:00 PM

Sell \$1000 Frames on a Daily Basis

Andy Tabrizipour
Friday, April 30th, 10:30 AM - 11:00AM

Movie & Cinema Influencing Fashion & Style

Gazal Tabrizipour
Saturday, May 1st, 1:30 PM - 2:15 PM

CO-LOCATED MEETINGS

SECO 2021 is excited to host affiliate and associated organizations during this year's annual meeting. A continued build of the profession's most valuable education offering, SECO 2021 provides a synergy of more learning and more variety in one meeting place!



**EYSUVIS (loteprednol etabonate ophthalmic suspension) 0.25%,
for topical ophthalmic use**

BRIEF SUMMARY OF FULL PRESCRIBING INFORMATION

INDICATIONS AND USAGE

EYSUVIS is a corticosteroid indicated for the short-term (up to two weeks) treatment of the signs and symptoms of dry eye disease.

CONTRAINDICATIONS

EYSUVIS, as with other ophthalmic corticosteroids, is contraindicated in most viral diseases of the cornea and conjunctiva including epithelial herpes simplex keratitis (dendritic keratitis), vaccinia, and varicella, and also in mycobacterial infection of the eye and fungal diseases of ocular structures.

WARNINGS AND PRECAUTIONS

Delayed Healing and Corneal Perforation—Topical corticosteroids have been known to delay healing and cause corneal and scleral thinning. Use of topical corticosteroids in the presence of thin corneal or scleral tissue may lead to perforation. The initial prescription and each renewal of the medication order should be made by a physician only after examination of the patient with the aid of magnification, such as slit lamp biomicroscopy, and, where appropriate, fluorescein staining.

Intraocular Pressure (IOP) Increase—Prolonged use of corticosteroids may result in glaucoma with damage to the optic nerve, as well as defects in visual acuity and fields of vision. Corticosteroids should be used with caution in the presence of glaucoma. Renewal of the medication order should be made by a physician only after examination of the patient and evaluation of the IOP.

Cataracts—Use of corticosteroids may result in posterior subcapsular cataract formation.

Bacterial Infections—Use of corticosteroids may suppress the host response and thus increase the hazard of secondary ocular infections. In acute purulent conditions of the eye, corticosteroids may mask infection or enhance existing infection.

Viral Infections—Use of corticosteroid medication in the treatment of patients with a history of herpes simplex requires great caution. Use of ocular corticosteroids may prolong the course and may exacerbate the severity of many viral infections of the eye (including herpes simplex).

Fungal Infections—Fungal infections of the cornea are particularly prone to develop coincidentally with long-term local corticosteroid application. Fungus invasion must be considered in any persistent corneal ulceration where a corticosteroid has been used or is in use. Fungal cultures should be taken when appropriate.

Risk of Contamination—Do not to allow the dropper tip to touch any surface, as this may contaminate the suspension.

Contact Lens Wear—The preservative in EYSUVIS may be absorbed by soft contact lenses. Contact lenses should be removed prior to instillation of EYSUVIS and may be reinserted 15 minutes following administration.

ADVERSE REACTIONS

Adverse reactions associated with ophthalmic corticosteroids include elevated intraocular pressure, which may be associated with infrequent optic nerve damage, visual acuity and field defects, posterior subcapsular cataract formation, delayed wound healing and secondary ocular infection from pathogens including herpes simplex, and perforation of the globe where there is thinning of the cornea or sclera.

Clinical Trials Experience—Because clinical trials are conducted under widely varying conditions, adverse reaction rates observed in the clinical trials of a drug cannot be directly compared to rates in the clinical trials of another drug and may not reflect the rates observed in practice.

The most common adverse reaction observed in clinical trials with EYSUVIS was instillation site pain, which was reported in 5% of patients.

USE IN SPECIFIC POPULATIONS

Pregnancy—**Risk Summary**: There are no adequate and well controlled studies with loteprednol etabonate in pregnant women. Loteprednol etabonate produced teratogenicity at clinically relevant doses in the rabbit and rat when administered orally during pregnancy. Loteprednol etabonate produced malformations when administered orally to pregnant rabbits at doses 1.4 times the recommended human ophthalmic dose (RHOD) and to pregnant rats at doses 34 times the RHOD. In pregnant rats receiving oral doses of loteprednol etabonate during the period equivalent to the last trimester of pregnancy through lactation in humans, survival of offspring was reduced at doses 3.4 times the RHOD. Maternal toxicity was observed in rats at doses 347 times the RHOD, and a maternal no observed adverse effect level (NOAEL) was established at 34 times the RHOD.

The background risk in the U.S. general population of major birth defects is 2 to 4%, and of miscarriage is 15 to 20%, of clinically recognized pregnancies.

Data—Animal Data: Embryofetal studies were conducted in pregnant rabbits administered loteprednol etabonate by oral gavage on gestation days 6 to 18, to target the period of organogenesis. Loteprednol etabonate produced fetal malformations at 0.1 mg/kg (1.4 times the recommended human ophthalmic dose (RHOD) based on body surface area, assuming 100% absorption). Spina bifida (including meningocele) was observed at 0.1 mg/kg, and exencephaly and craniofacial malformations were observed at 0.4 mg/kg (5.6 times the RHOD). At 3 mg/kg (41 times the RHOD), loteprednol etabonate was associated with increased incidences of abnormal left common carotid artery, limb flexures, umbilical hernia, scoliosis, and delayed ossification. Abortion and embryofetal lethality (resorption) occurred at 6 mg/kg (83 times the RHOD). A NOAEL for developmental toxicity was not established in this study. The NOAEL for maternal toxicity in rabbits was 3 mg/kg/day.

Embryofetal studies were conducted in pregnant rats administered loteprednol etabonate by oral gavage on gestation days 6 to 15, to target the period of organogenesis. Loteprednol etabonate produced fetal malformations, including absent innominate artery at 5 mg/kg (34 times the RHOD); and cleft palate, agnathia, cardiovascular defects, umbilical hernia, decreased fetal body weight and decreased skeletal ossification at 50 mg/kg (347 times the RHOD). Embryofetal lethality (resorption) was observed at 100 mg/kg (695 times the RHOD). The NOAEL for developmental toxicity in rats was 0.5 mg/kg (3.4 times the RHOD). Loteprednol etabonate was maternally toxic (reduced body weight gain) at 50 mg/kg/day. The NOAEL for maternal toxicity was 5 mg/kg.

A peri-/postnatal study was conducted in rats administered loteprednol etabonate by oral gavage from gestation day 15 (start of fetal period) to postnatal day 21 (the end of lactation period). At 0.5 mg/kg (3.4 times the clinical dose), reduced survival was observed in live-born offspring. Doses \geq 5 mg/kg (34 times the RHOD) caused umbilical hernia/incomplete gastrointestinal tract. Doses \geq 50 mg/kg (347 times the RHOD) produced maternal toxicity (reduced body weight gain, death), decreased number of live-born offspring, decreased birth weight, and delays in postnatal development. A developmental NOAEL was not established in this study. The NOAEL for maternal toxicity was 5 mg/kg.

Lactation—There are no data on the presence of loteprednol etabonate in human milk, the effects on the breastfed infant, or the effects on milk production. The developmental and health benefits of breastfeeding should be considered, along with the mother's clinical need for EYSUVIS and any potential adverse effects on the breastfed infant from EYSUVIS.

Pediatric Use—Safety and effectiveness in pediatric patients have not been established.

Geriatric Use—No overall differences in safety and effectiveness have been observed between elderly and younger adult patients.

NONCLINICAL TOXICOLOGY

Carcinogenesis, Mutagenesis, Impairment of Fertility—Long-term animal studies have not been conducted to evaluate the carcinogenic potential of loteprednol etabonate. Loteprednol etabonate was not genotoxic *in vitro* in the Ames test, the mouse lymphoma thymidine kinase (tk) assay, in a chromosome aberration test in human lymphocytes, or *in vivo* in the single dose mouse micronucleus assay. Treatment of male and female rats with 25 mg/kg/day of loteprednol etabonate (174 times the RHOD based on body surface area, assuming 100% absorption) prior to and during mating caused pre-implantation loss and decreased the number of live fetuses/live births. The NOAEL for fertility in rats was 5 mg/kg/day (34 times the RHOD).

**For a copy of the Full Prescribing Information, please visit
www.EYSUVIS.com.**

Manufactured for:
Kala Pharmaceuticals, Inc.
Watertown, MA 02472

Part # 2026R02

Marks designated by [™] or [®] are owned by Kala Pharmaceuticals, Inc.
Patented. www.kalarx.com/patents

© 2020 Kala Pharmaceuticals, Inc. All rights reserved.

October 2020

Kala[®]

US-EYS-2000115

The **FIRST AND ONLY FDA APPROVED SHORT-TERM**
(up to two weeks) Rx treatment for the signs and symptoms of Dry Eye Disease

IN THE BATTLEGROUND OF DRY EYE...

**When Dry Eye
Flares strike,**

INDICATION

EYSUVIS is a corticosteroid indicated for the short-term (up to two weeks) treatment of the signs and symptoms of dry eye disease.

IMPORTANT SAFETY INFORMATION

Contraindication:

EYSUVIS, as with other ophthalmic corticosteroids, is contraindicated in most viral diseases of the cornea and conjunctiva including epithelial herpes simplex keratitis (dendritic keratitis), vaccinia, and varicella, and also in mycobacterial infection of the eye and fungal diseases of ocular structures.

Warnings and Precautions:

Delayed Healing and Corneal Perforation: Topical corticosteroids have been known to delay healing and cause corneal and scleral thinning. Use of topical corticosteroids in the presence of thin corneal or scleral tissue may lead to perforation. The initial prescription and each renewal of the medication order should be made by a physician only after examination of the patient with the aid of magnification, such as slit lamp biomicroscopy, and, where appropriate, fluorescein staining.

Intraocular Pressure (IOP) Increase: Prolonged use of corticosteroids may result in glaucoma with damage to the optic nerve, as well as defects in visual acuity and fields of vision. Corticosteroids should be used with caution in the presence of glaucoma. Renewal of the medication order should be made by a physician only after examination of the patient and evaluation of the IOP.

Cataracts: Use of corticosteroids may result in posterior subcapsular cataract formation.

Bacterial Infections: Use of corticosteroids may suppress the host response and thus increase the hazard of secondary ocular infections. In acute purulent conditions, corticosteroids may mask infection or enhance existing infection.

Viral Infections: Use of a corticosteroid medication in the treatment of patients with a history of herpes simplex requires great caution. Use of ocular corticosteroids may prolong the course and may exacerbate the severity of many viral infections of the eye (including herpes simplex).

**fight
back
first
with
fast.**

EYSUVIS is an eye drop,
not a spray.



Fungal Infections: Fungal infections of the cornea are particularly prone to develop coincidentally with long-term local corticosteroid application. Fungus invasion must be considered in any persistent corneal ulceration where a corticosteroid has been used or is in use.

Adverse Reactions:

The most common adverse drug reaction following the use of EYSUVIS for two weeks was instillation site pain, which was reported in 5% of patients.

Please see Brief Summary
of Prescribing Information
for EYSUVIS on the next page.

kala PHARMACEUTICALS

US-EYS-2100080

www.EYSUVIS.com

Learn More About
EYSUVIS at Booth 1113

EYSUVIS
(loteprednol etabonate
ophthalmic suspension) 0.25%
THE FAST FLARE FIGHTER