

# REVIEW<sup>®</sup> OF OPTOMETRY

November 15, 2020


[www.reviewofoptometry.com](http://www.reviewofoptometry.com)

## OCULAR SURFACE HEALTH

RED EYE REMEDIES:

**NEW AND  
TRIED-AND-TRUE**

CRACK THE CODE:  
RELIEVE EYE DRYNESS

 Artificial tears for today's  
digital device users.



NEED REFRESH<sup>®</sup> SAMPLES AND RESOURCES?

Call **Refresh<sup>®</sup> CONCIERGE** at **833-REF-SMPL** today!

 **Allergan**  
an AbbVie company

## NEW REFRESH® DIGITAL:

- Low-viscosity, lipid-enhanced formulas act fast to relieve eye dryness from screen time
- Supports all three tear film layers
- Features **HydroCell™** technology—our proprietary NaCl-free, glycerin-based solution that enables hydration and maintains the volume of cells on the ocular surface
- Prevents tear evaporation due to lipid layer deficiencies



Reboot. Relieve. **REFRESH®**

[refreshbrand.com/doc](https://refreshbrand.com/doc)



CNS Disease: In the Eye and in Your Chair, p. 34 • How to Add Ortho-K, p. 78

# REVIEW<sup>®</sup> OF OPTOMETRY

November 15, 2020

[www.reviewofoptometry.com](http://www.reviewofoptometry.com)

## OCULAR SURFACE HEALTH

RED EYE REMEDIES:

# NEW AND TRIED-AND-TRUE

Page 40

How to Answer the “Why” of Dry Eye

Page 48

Artificial Tears: What Matters and Why

Page 54

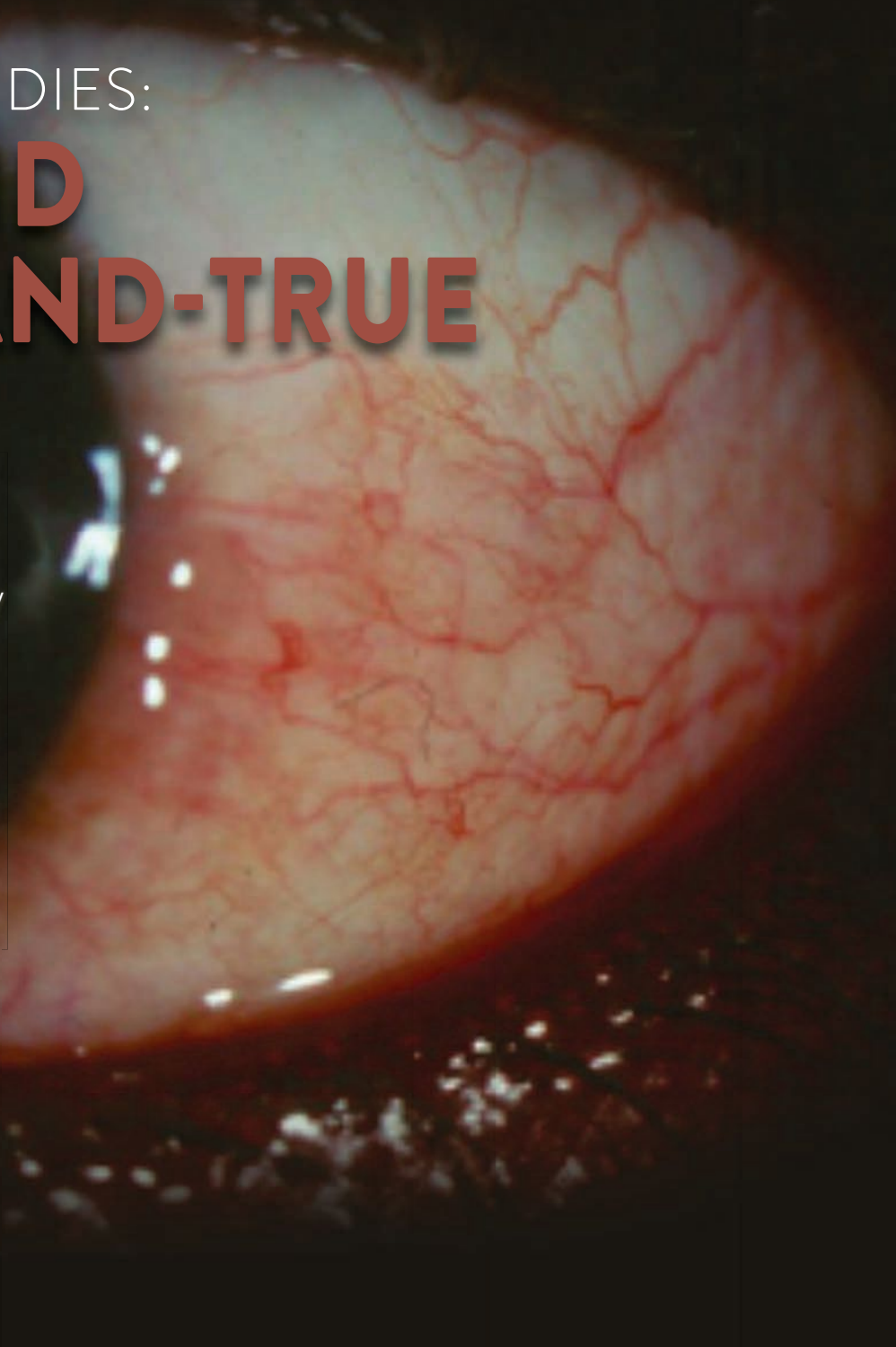LWE: What the OD Needs to Know

Page 62

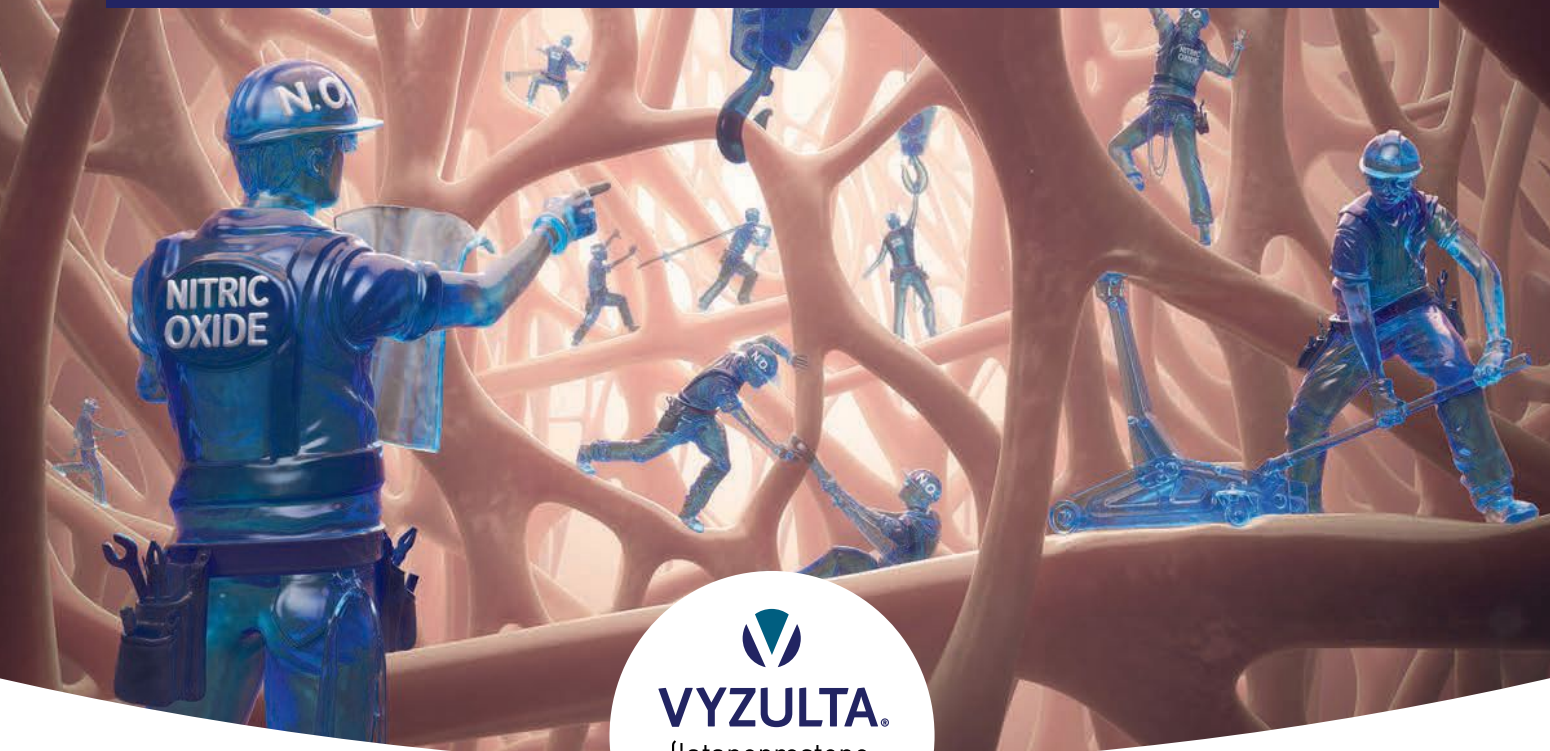EARN 2 CE CREDITS:

A Modern Approach to MGD

Page 70



Only dual-action VYZULTA reduces intraocular pressure (IOP) by targeting the trabecular meshwork with nitric oxide and the uveoscleral pathway with latanoprost acid<sup>1</sup>



**VYZULTA**

(latanoprostene bunod ophthalmic solution), 0.024%

## EXPAND THE TRABECULAR MESHWORK WITH THE POWER OF NITRIC OXIDE<sup>2-6</sup>

### VYZULTA achieved significant and sustained long-term IOP reductions vs Timolol 0.5% in pivotal trials<sup>7</sup>

$P < 0.001$  vs baseline at all pre-specified visits over 12 months in a pooled analysis of APOLLO and LUNAR clinical trials (N=831)

### VYZULTA demonstrated safety profile in clinical trials

Only 6 out of 811 patients discontinued due to ocular adverse events in APOLLO and LUNAR clinical trials<sup>1,8,9</sup>

Visit [VYZULTANOW.com](http://VYZULTANOW.com) to see our efficacy results

### INDICATION

VYZULTA® (latanoprostene bunod ophthalmic solution), 0.024% is indicated for the reduction of intraocular pressure (IOP) in patients with open-angle glaucoma or ocular hypertension.

### IMPORTANT SAFETY INFORMATION

- Increased pigmentation of the iris and periorbital tissue (eyelid) can occur. Iris pigmentation is likely to be permanent
- Gradual changes to eyelashes, including increased length, increased thickness, and number of eyelashes, may occur. These changes are usually reversible upon treatment discontinuation
- Use with caution in patients with a history of intraocular inflammation (iritis/uveitis). VYZULTA should generally not be used in patients with active intraocular inflammation
- Macular edema, including cystoid macular edema, has been reported during treatment with prostaglandin analogs. Use with caution in aphakic patients, in pseudophakic patients with a torn posterior lens capsule, or in patients with known risk factors for macular edema

### IMPORTANT SAFETY INFORMATION cont'd

- There have been reports of bacterial keratitis associated with the use of multiple-dose containers of topical ophthalmic products that were inadvertently contaminated by patients
- Contact lenses should be removed prior to the administration of VYZULTA and may be reinserted 15 minutes after administration
- Most common ocular adverse reactions with incidence  $\geq 2\%$  are conjunctival hyperemia (6%), eye irritation (4%), eye pain (3%), and instillation site pain (2%)

For more information, please see Brief Summary of Prescribing Information on adjacent page.

**References:** 1. VYZULTA Prescribing Information. Bausch & Lomb Incorporated. 2. Cavet ME. *J Ocul Pharmacol Ther.* 2018;34(1):52-60. DOI:10.1089/jop.2016.0188. 3. Wareham LK. *Nitric Oxide.* 2018;77:75-87. DOI:10.1016/j.niox.2018.04.010. 4. Stamer DW. *Curr Opin Ophthalmol.* 2012;23:135-143. DOI:10.1097/ICU.0b013e32834ff23e. 5. Cavet ME. *Invest Ophthalmol Vis Sci.* 2015;56(6):4108-4116. 6. Kaufman PL. *Exp Eye Research.* 2008;86:3-17. DOI:10.1016/j.exer.2007.10.007. 7. Weinreb RN. *J Glaucoma.* 2018;27:7-15. 8. Weinreb RN. *Ophthalmology.* 2016;123(5):965-973. 9. Medeiros FA. *Am J Ophthalmol.* 2016;168:250-259.

## BRIEF SUMMARY OF PRESCRIBING INFORMATION

This Brief Summary does not include all the information needed to use VYZULTA safely and effectively. See full Prescribing Information for VYZULTA.

**VYZULTA®** (latanoprostene bunod ophthalmic solution), 0.024%, for topical ophthalmic use.

Initial U.S. Approval: 2017

### 1 INDICATIONS AND USAGE

VYZULTA® (latanoprostene bunod ophthalmic solution) 0.024% is indicated for the reduction of intraocular pressure (IOP) in patients with open-angle glaucoma or ocular hypertension.

### 4 CONTRAINDICATIONS

None

### 5 WARNINGS AND PRECAUTIONS

#### 5.1 Pigmentation

VYZULTA® (latanoprostene bunod ophthalmic solution), 0.024% may cause changes to pigmented tissues. The most frequently reported changes with prostaglandin analogs have been increased pigmentation of the iris and periorbital tissue (eyelid).

Pigmentation is expected to increase as long as latanoprostene bunod ophthalmic solution is administered. The pigmentation change is due to increased melanin content in the melanocytes rather than to an increase in the number of melanocytes. After discontinuation of VYZULTA, pigmentation of the iris is likely to be permanent, while pigmentation of the periorbital tissue and eyelash changes are likely to be reversible in most patients. Patients who receive prostaglandin analogs, including VYZULTA, should be informed of the possibility of increased pigmentation, including permanent changes. The long-term effects of increased pigmentation are not known.

Iris color change may not be noticeable for several months to years. Typically, the brown pigmentation around the pupil spreads concentrically towards the periphery of the iris and the entire iris or parts of the iris become more brownish. Neither nevi nor freckles of the iris appear to be affected by treatment. While treatment with VYZULTA® (latanoprostene bunod ophthalmic solution), 0.024% can be continued in patients who develop noticeably increased iris pigmentation, these patients should be examined regularly [see Patient Counseling Information (17) in full Prescribing Information].

#### 5.2 Eyelash Changes

VYZULTA may gradually change eyelashes and vellus hair in the treated eye. These changes include increased length, thickness, and the number of lashes or hairs. Eyelash changes are usually reversible upon discontinuation of treatment.

#### 5.3 Intraocular Inflammation

VYZULTA should be used with caution in patients with a history of intraocular inflammation (iritis/uveitis) and should generally not be used in patients with active intraocular inflammation as it may exacerbate this condition.

#### 5.4 Macular Edema

Macular edema, including cystoid macular edema, has been reported during treatment with prostaglandin analogs. VYZULTA should be used with caution in aphakic patients, in pseudophakic patients with a torn posterior lens capsule, or in patients with known risk factors for macular edema.

#### 5.5 Bacterial Keratitis

There have been reports of bacterial keratitis associated with the use of multiple-dose containers of topical ophthalmic products. These containers had been inadvertently contaminated by patients who, in most cases, had a concurrent corneal disease or a disruption of the ocular epithelial surface.

#### 5.6 Use with Contact Lens

Contact lenses should be removed prior to the administration of VYZULTA because this product contains benzalkonium chloride. Lenses may be reinserted 15 minutes after administration.

### 6 ADVERSE REACTIONS

The following adverse reactions are described in the Warnings and Precautions section: pigmentation (5.1), eyelash changes (5.2), intraocular inflammation (5.3), macular edema (5.4), bacterial keratitis (5.5), use with contact lens (5.6).

#### 6.1 Clinical Trials Experience

Because clinical trials are conducted under widely varying conditions, adverse reaction rates observed in the clinical trials of a drug cannot be directly compared to rates in the clinical trials of another drug and may not reflect the rates observed in practice.

VYZULTA was evaluated in 811 patients in 2 controlled clinical trials of up to 12 months duration. The most common ocular adverse reactions observed in patients treated with latanoprostene bunod were: conjunctival hyperemia (6%), eye irritation (4%), eye pain (3%), and instillation site pain (2%). Approximately 0.6% of patients discontinued therapy due to ocular adverse reactions including ocular hyperemia, conjunctival irritation, eye irritation, eye pain, conjunctival edema, vision blurred, punctate keratitis and foreign body sensation.

### 8 USE IN SPECIFIC POPULATIONS

#### 8.1 Pregnancy

##### Risk Summary

There are no available human data for the use of VYZULTA during pregnancy to inform any drug associated risks.

Latanoprostene bunod has caused miscarriages, abortion, and fetal harm in rabbits. Latanoprostene bunod was shown to be abortifacient and teratogenic when administered intravenously (IV) to pregnant rabbits at exposures  $\geq 0.28$  times the clinical dose. Doses  $\geq 20 \mu\text{g}/\text{kg}/\text{day}$  (23 times the clinical dose) produced 100% embryofetal lethality. Structural abnormalities observed in rabbit fetuses included anomalies of the great vessels and aortic arch vessels, domed head, sternebral and vertebral skeletal anomalies, limb hyperextension

and malrotation, abdominal distension and edema. Latanoprostene bunod was not teratogenic in the rat when administered IV at 150 mcg/kg/day (87 times the clinical dose) [see Data].

The background risk of major birth defects and miscarriage for the indicated population is unknown. However, the background risk in the U.S. general population of major birth defects is 2 to 4%, and of miscarriage is 15 to 20%, of clinically recognized pregnancies.

##### Data

##### Animal Data

Embryofetal studies were conducted in pregnant rabbits administered latanoprostene bunod daily by intravenous injection on gestation days 7 through 19, to target the period of organogenesis. The doses administered ranged from 0.24 to 80 mcg/kg/day. Abortion occurred at doses  $\geq 0.24$  mcg/kg/day latanoprostene bunod (0.28 times the clinical dose, on a body surface area basis, assuming 100% absorption). Embryofetal lethality (resorption) was increased in latanoprostene bunod treatment groups, as evidenced by increases in early resorptions at doses  $\geq 0.24$  mcg/kg/day and late resorptions at doses  $\geq 6$  mcg/kg/day (approximately 7 times the clinical dose). No fetuses survived in any rabbit pregnancy at doses of 20 mcg/kg/day (23 times the clinical dose) or greater. Latanoprostene bunod produced structural abnormalities at doses  $\geq 0.24$  mcg/kg/day (0.28 times the clinical dose). Malformations included anomalies of sternum, coarctation of the aorta with pulmonary trunk dilation, retroesophageal subclavian artery with absent brachiocephalic artery, domed head, forepaw hyperextension and hindlimb malrotation, abdominal distention/edema, and missing/fused caudal vertebrae.

An embryofetal study was conducted in pregnant rats administered latanoprostene bunod daily by intravenous injection on gestation days 7 through 17, to target the period of organogenesis. The doses administered ranged from 150 to 1500 mcg/kg/day. Maternal toxicity was produced at 1500 mcg/kg/day (870 times the clinical dose, on a body surface area basis, assuming 100% absorption), as evidenced by reduced maternal weight gain. Embryofetal lethality (resorption and fetal death) and structural anomalies were produced at doses  $\geq 300$  mcg/kg/day (174 times the clinical dose). Malformations included anomalies of the sternum, domed head, forepaw hyperextension and hindlimb malrotation, vertebral anomalies and delayed ossification of distal limb bones. A no observed adverse effect level (NOAEL) was established at 150 mcg/kg/day (87 times the clinical dose) in this study.

#### 8.2 Lactation

##### Risk Summary

There are no data on the presence of VYZULTA in human milk, the effects on the breastfed infant, or the effects on milk production. The developmental and health benefits of breastfeeding should be considered, along with the mother's clinical need for VYZULTA, and any potential adverse effects on the breastfed infant from VYZULTA.

#### 8.4 Pediatric Use

Use in pediatric patients aged 16 years and younger is not recommended because of potential safety concerns related to increased pigmentation following long-term chronic use.

#### 8.5 Geriatric Use

No overall clinical differences in safety or effectiveness have been observed between elderly and other adult patients.

### 13 NONCLINICAL TOXICOLOGY

#### 13.1 Carcinogenesis, Mutagenesis, Impairment of Fertility

Latanoprostene bunod was not mutagenic in bacteria and did not induce micronuclei formation in the *in vivo* rat bone marrow micronucleus assay. Chromosomal aberrations were observed *in vitro* with human lymphocytes in the absence of metabolic activation.

Latanoprostene bunod has not been tested for carcinogenic activity in long-term animal studies. Latanoprost acid is a main metabolite of latanoprostene bunod. Exposure of rats and mice to latanoprost acid, resulting from oral dosing with latanoprost in lifetime rodent bioassays, was not carcinogenic.

Fertility studies have not been conducted with latanoprostene bunod. The potential to impact fertility can be partially characterized by exposure to latanoprost acid, a common metabolite of both latanoprostene bunod and latanoprost. Latanoprost acid has not been found to have any effect on male or female fertility in animal studies.

#### 13.2 Animal Toxicology and/or Pharmacology

A 9-month toxicology study administered topical ocular doses of latanoprostene bunod to one eye of cynomolgus monkeys: control (vehicle only), one drop of 0.024% bid, one drop of 0.04% bid and two drops of 0.04% per dose, bid. The systemic exposures are equivalent to 4.2-fold, 7.9-fold, and 13.5-fold the clinical dose, respectively, on a body surface area basis (assuming 100% absorption). Microscopic evaluation of the lungs after 9 months observed pleural/subpleural chronic fibrosis/inflammation in the 0.04% dose male groups, with increasing incidence and severity compared to controls. Lung toxicity was not observed at the 0.024% dose.

U.S. Patent Numbers: 7,273,946; 7,629,345; 7,910,767; 8,058,467.

VYZULTA is a trademark of Bausch & Lomb Incorporated or its affiliates.

© 2020 Bausch & Lomb Incorporated or its affiliates.

##### Distributed by:

Bausch + Lomb, a division of

Bausch Health US, LLC

Bridgewater, NJ 08807 USA

Based on 9612403 (Folded), 9612303 (Flat) 5/2019

VYZ.0109.USA.20 Issued: 5/2020

## IN THE NEWS

A recent study found that **IOP is significantly correlated with body mass index, waist circumference and diastolic blood pressure.** The study population of 346 subjects had a 5.5% prevalence of ocular hypertension (defined as >21mm Hg). The researchers found that with each 10mm Hg increase in diastolic blood pressure, there was a corresponding 0.51mm Hg increase in IOP.

Reddy A, Halenda K, Cromer P, et al. The association of intraocular pressure with obesity and cardiometabolic risk in a young farmworker population. *J Glaucoma*. October 15, 2020. [Epub ahead of print].

**To distinguish between pellucid marginal degeneration (PMD) and keratoconus, try looking closely at corneal sublayer pachymetry.** A recent study noted PMD exhibited higher total cornea and epithelium values in the inferotemporal 2mm to 5mm sector as well as a lower epithelium value in the inferior 7mm to 9mm sector. The calculated ratio between total cornea in the inferotemporal 2mm to 5mm sector and in the inferior 7mm to 9mm sector yielded the highest diagnostic accuracy.

Mohr N, Shajari M, Krause D, et al. Pellucid marginal degeneration versus keratoconus: distinction with wide-field SD-OCT corneal sublayer pachymetry. *Br J Ophthalmol*. October 14, 2020. [Epub ahead of print].

Researchers found that **anti-VEGF therapy provided visual gains for the majority of patients with macular edema due to retinal vein occlusion.** The study noted that at six months and one year, the mean letter gain increased with the number of anti-VEGF injections. Those with a baseline acuity of 20/40 or better tended to lose visual acuity in one year, indicating a ceiling effect.

Ciulla T, Pollack JS, Williams DF. Visual acuity outcomes and anti-VEGF therapy intensity in macular oedema due to retinal vein occlusion: A real-world analysis of 15,613 patient eyes. *Br J Ophthalmol*. October 14, 2020. [Epub ahead of print].

# Identify Sjögren's With Four Questions

A simple screening questionnaire could help you catch these patients earlier than ever before.

**By Catherine Manthorp, Associate Editor**

The researchers of a recent study stress the importance of diagnosing Sjögren's syndrome (SS) early, as the chronic autoimmune condition comes with serious systemic complications, including an increased risk of B-cell non-Hodgkin's lymphoma. However, patients whose primary complaint is dry eye aren't diagnosed, on average, for another 10 years after the onset of ocular symptoms. To address this, the team developed a four-question screening questionnaire that can help to identify patients with dry eye with a high likelihood of having underlying SS.

The cross-sectional study included 848 participants with dry eye complaints who were self-referred or referred by an ophthalmologist to the Sjögren's International Collaborative Clinical Alliance study. The team assessed the discriminatory value of 88 screening questions to pinpoint the association between dry eye signs and symptoms and SS. They assigned the questions numerical values within different regression models and assessed the subsequent likelihood scores.

Of the initial set of questions, the investigators found four that were statistically significant:

1. Is your mouth dry when eating a meal? (Yes = OR 1.63)

2. Can you eat a cracker without drinking a fluid or liquid? (No = OR 1.46)
3. How often do you have excessive tearing? (None of the time = OR 4.06)
4. Are you able to produce tears? (No = OR 2.24).

They noted that the SS likelihood score had a moderate discriminative ability for detecting SS, which improved with the addition of tear break-up time and conjunctival staining.

Even if clinicians are asking patients about dry mouth, the wording is important. The researchers found that asking, "Does your mouth feel dry?" was not useful in discriminating between the SS patients and controls. However, more specific questions about dryness while eating a meal or even a cracker helped to differentiate one group from the other.

"With future refinement and validation, this screening tool could be used alone or in combination with examination findings to identify patients with SS earlier, thereby facilitating better clinical outcomes," the study authors concluded in their paper.

Bunya VY, Maguire MG, Akpek EK, et al. A new screening questionnaire to identify patients with dry eye with a high likelihood of having Sjögren syndrome. *Cornea*. October 13, 2020. [Epub ahead of print].

NEWS STORIES POST EVERY WEEKDAY MORNING AT [www.reviewofoptometry.com/news](http://www.reviewofoptometry.com/news)

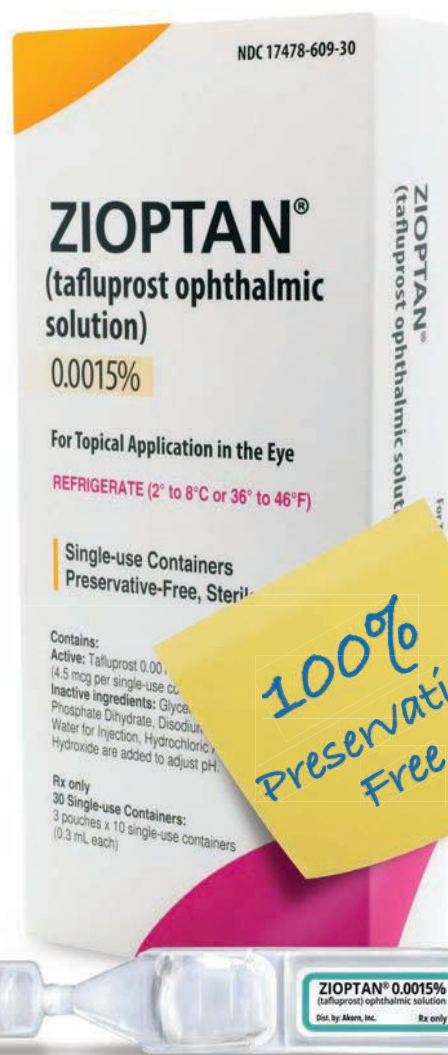# 100% PRESERVATIVE FREE Now Easier to Prescribe

## New Improved Coverage

Now a preferred brand on  
**Express Scripts®**  
Preferred Drug list

Now covered on >90% of  
**OPTUMRx®**  
Medicare Part D Plans

**ZIOPTAN®**  
(tafluprost ophthalmic  
solution) 0.0015%



Additional Practice Support Available At:

[MyAkornEyeCare.com](http://MyAkornEyeCare.com)

ZIOPTAN® is a registered trademark of Merck Sharp & Dohme Corp. and is used under license. ZIOPTAN® is licensed by Santen Pharmaceutical Co., Ltd. Express Scripts is a registered trademark of Express Scripts Strategic Development, Inc. OPTUMRx is a registered trademark of Optum, Inc.

©2020 Akorn, Inc. 1925 West Field Court, Suite 300 Lake Forest, IL 60045

**AKORN** | EYE CARE

JA013 Rev 6/20

# CVS Launches Online CL Prescription Renewal

CVS Pharmacy recently announced plans to move into online optical sales with the launch of QuickRenew, a prescription renewal platform that is part of Premium Vision, one of 1-800-Contacts' portfolio companies.

This telehealth technology, currently available on the CVS Optical website, allows patients to renew their prescription with an independent ophthalmologist and order contact lenses to be shipped to their home, according to a company press release.<sup>1</sup>

Like it or not, this announcement continues a trend of normalizing remote contact lens prescription renewal, says Brian Chou, OD, of San Diego. "The tacit suggestion to the consumer is that traditional contact lens services are not needed, unless for *de novo* prescriptions. The slippery slope ends when consumers purchase disposable soft lenses without a prescription, even if *de facto*."

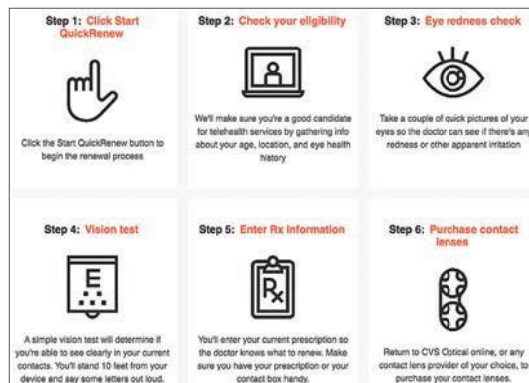
Online companies continue promoting this practice, even if it's not optimal for the wearers and diminishes the strength of the doctor-patient relationship, Dr. Chou adds. "COVID-19 is a dream come true for businesses inhabiting the virtual realm."

In a press release, CVS said the company continues to adapt and evolve its digital offerings in response to the pandemic.

## Another Player in Online Glasses Sales

In addition to QuickRenew, CVS Optical has also launched an online glasses site that offers a variety of "trendy and classic styles" starting at \$79, and a single-vision prescription comes at no extra cost. Each pair of glasses includes premium polycarbonate lenses that provide UV and scratch protection, and lenses can be upgraded to include blue light filtering to reduce eye strain and fatigue from digital devices.

"In terms of glasses, the public has indicated a desire for in-person service rather than mail order lenses," Dr. Sonsino says. "Just look at the number of brick and mortar stores that have popped up all over the country by once-online glasses provider Warby Parker."



**These instructions for CVS's service demonstrate the technology's approach to doctor-patient interaction.**

"This addition to our optical site gives customers a new way to fulfill an important health care need safely and confidently from the comfort of their homes," Michele Driscoll, a vice president with CVS Health, said in the release. "This is especially important when customers are trying to limit their interactions or are finding it difficult to schedule time with an optometrist. Digital screening takes less than 15-20 minutes, and information is reviewed by a licensed independent ophthalmologist."

The QuickRenew online prescription renewal service is currently available in 32 states, where permitted. To participate, patients must be between the ages of 18 and 55, have been previously fitted with contact lenses, underwent a full eye exam within the last four years and have a healthy eye history.

In a statement, the American Optometric Association called on CVS "to acknowledge that this offering will lower the overall level of eye health care received by the public and that this test places them in the ranks of questionable vision test apps that have and should continue to be investigated by the FDA."<sup>2</sup>

"It is unfortunate that CVS Health, a company seemingly concerned with the public's health and well-being, has chosen to implement an online vision test that has neither been properly evaluated nor approved by the FDA," says Jeffrey Sonsino, OD, of Nashville. "Ultimately, the public will decide whether they wish to entrust their ocular health to a skilled professional with the ability to examine the eyes and find nuanced signs leading to blinding eye disease, or a singular test with little to no diagnostic capability, expressly designed to work around rules enacted to protect the public."

Dr. Sonsino adds, "Telehealth works great for warts and psychiatry, but the technology is nowhere close to where it is rational for eye care. Large companies concerned with only profit often push these untested technologies in order to be the first to market. For my family's eyes... no thanks."

1. CVS Pharmacy launches QuickRenew, an at-home contact lens prescription renewal tool. AP News. [apnews.com/press-release/pr-newswire/business-virus-outbreak-health-eye-health-pharmacy-operators-340a5f0b0401616d649ca95959518efe](https://apnews.com/press-release/pr-newswire/business-virus-outbreak-health-eye-health-pharmacy-operators-340a5f0b0401616d649ca95959518efe). October 27, 2020. Accessed October 28, 2020.

2. AOA. American Optometric Association statement regarding CVS launch of QuickRenew. [www.aoa.org/about-the-aoa/press-room/statements/statement-regarding-cvs-launch-of-quickrenew?ss=y](https://www.aoa.org/about-the-aoa/press-room/statements/statement-regarding-cvs-launch-of-quickrenew?ss=y) October 27, 2020. Accessed October 28, 2020.





By  
Paul M. Karpecki,  
OD, FAAO

# Seizing the Millennial Eye Care Opportunity

## Omnichannel offerings can help attract a younger demographic

The COVID lockdowns have accelerated a trend that some of us in eye care have long expected, which is that a growing number of patients prefer to make purchases online. Between March and June, visits to the top North American ecommerce sites jumped 125% on average compared with 2019.<sup>1</sup>

The fact that COVID shut down many eye care practices also made clear that we can and should be focusing more attention on providing a seamless experience to patients, whether they are visiting brick-and-mortar practices or searching for products online.

Millennials—and increasingly all age groups—tend to look online to discover new service providers and brands. As a result it's imperative that eye care practices have an online platform to meet patients where they already are. In addition, Millennial patients—those between 22 and 38—actually prefer to shop online and will spend more money for greater convenience than previous generations.<sup>2</sup> Millennials represent more than \$200 billion in annual spending,<sup>3</sup> and in 2019 they made 60% of their purchases online.<sup>4</sup>

Given this preference by Millennials, an omnichannel strategy makes prudent business sense.

### HISTORICAL HURDLES

Though omnichannel sales offer tremendous potential for eye care practices, optometry lags behind other industries in this respect. Some ODs have focused almost exclusively on routine ocular care, to the exclusion of other areas of business. And while some practices have successfully branched into medical eye care or added an online presence in addition to their brick-and-mortar visibility, very few ODs have fully embraced the conveniences preferred by Millennial patients.

To successfully dive into this new domain, optometrists must first acknowledge that they need to combine in-person eye health visits with other service areas, such as telehealth, clinical use of artificial intelligence, and online delivery of test results and products to patients. Providing a broader range of offerings for patients—especially a growing base of Millennials who are accustomed to the convenience of online services—may strengthen practice revenues and build relationships with patients who might not otherwise discover or consider a given eye care provider.

### A PARTNER IN EYE CARE & BUSINESS


Hubble is poised to meet the heightened demand for eye care convenience. And Hubble wants to do so in alignment with optometrists—which would also be in the best interests of patients. The company was founded on the ideals of providing the safest form of contact lens wear (daily disposables) to patients at an affordable cost, and in the most convenient manner. This company philosophy persists, and supports the same health and safety goals for patients that optometrists pursue each day.

Hubble's lenses are available through convenient online subscrip-

### Hubble Works With Existing Sales Models

An optometrist who partners with Hubble sells contact lenses in the same way they sell other in-office lenses:

1. The optometrist fits the patient with Hubble contact lenses and provides a Hubble prescription
2. The patient purchases Hubble contact lenses and pays the optometrist at the point of care
3. The office staff places the order at <http://doctor.hubblecontacts.com>. Hubble ships the contact lenses directly to the patient, who receives them within 3-4 business days
4. At month's end, Hubble bills the optometrist the wholesale price of the contact lenses



tions, which promote compliance and reduce overwear by enabling patients to maintain a consistent supply of lenses. These subscriptions fulfill directly to the patient's door through a user-friendly online platform.

From a business standpoint, Hubble provides optometrists with the opportunity to earn higher margins by providing daily disposable contact lenses instead of monthly or biweekly daily-wear contact lenses. In addition, with Hubble's online platform and in partnership with optometry, Hubble can promote to patients the importance of ongoing eye care facilitated by seeing the optometrist on an ongoing basis. Furthermore, Hubble is able to share with eye care providers powerful patient leads from among its tens of thousands of site visitors, some of whom may lack a current contact lens prescription and be in need of an eye exam.

### Reaping Practice Benefits

Partnering with Hubble offers eye care practices the following benefits:

- Patient reminder emails about the need to book exams with the optometrist
- Referrals from among the tens of thousands of visitors to the Hubble site who likely lack a valid prescription
- The choice of annual, semi-annual or quarterly patient shipments
- Same-day order fulfillment to patients nationwide, with 3-4-day shipping
- A recommended in-office annual supply price of \$395 vs. \$507 at [hubblecontacts.com](http://hubblecontacts.com)
- Marketing to patients about optometrist partnerships via the Hubble website, social media, paid ads, and in-office literature

### TAKING THE FIRST STEP

In this new era of eye care, omnichannel sales avenues are critical to expanding eye care businesses. The potential upside from providing a convenient online sales pathway preferred by Millennial patients is massive and can no longer be ignored by ODs. Eye care providers interested in exploring benefits of the Hubble model or receiving a fitting set can reach out to [doctor@hubblecontacts.com](mailto:doctor@hubblecontacts.com).

1. Ali F. Traffic jumps an average 125% on top retail sites during pandemic. 2020; Sep 8: <https://www.digitalcommerce360.com/2020/09/08/traffic-jumps-an-average-125-on-top-retail-sites-during-pandemic/>

2. U.S. News & World Report. A Look at How Millennials Spend Their Money: <https://money.usnews.com/money/personal-finance/spending/articles/how-millennials-spend-their-money>

3. SYZYGY: The Ego Tech Report 2016. <https://media.szygy.io/uploads/media/58945d2f06998/szygy-egotech-report-2016.pdf>

4. CouponFollow: The Millennial Shopping Report. Winter 2019

SPONSORED BY **HUBBLE**

# New Tools Detect Early Changes in DR

Recent research has found that clinicians can use technology to better assess diabetic retinopathy (DR) before it fully develops. Multifocal electroretinography (mfERG) may be a valuable tool for evaluating neuroretinal dysfunction and swept-source OCT (SS-OCT) can show macular thinning before retinopathy develops.

## The Effects of Duration

The early detection of functional abnormalities may prompt clinicians with access to mfERG to keep a closer eye on their diabetes patients, according to researchers.<sup>1</sup>

The investigation, published in *BMC Ophthalmology*, found patients with diabetes without retinopathy had reduced mfERG N1–P1 amplitude and delayed P1-implicit time compared with normal controls. The research team also found implicit time and amplitude were significantly affected by diabetes duration.<sup>1</sup>

Although previous studies showed implicit time is affected more than amplitude in diabetes patients and is a better indicator of developing clinical DR, the current investigation reported both may be affected in Type 2 diabetes.

The study enrolled 20 eyes of 20 Type 2 diabetes patients without retinopathy and 20 eyes of 20 age- and gender-matched healthy controls. All study participants underwent mfERG, and the N1–P1 amplitude and P1-implicit time of each subject's five retinal rings were measured and analyzed. Additionally, fasting blood sugar was measured within a few days of performing mfERG.

The researchers found the

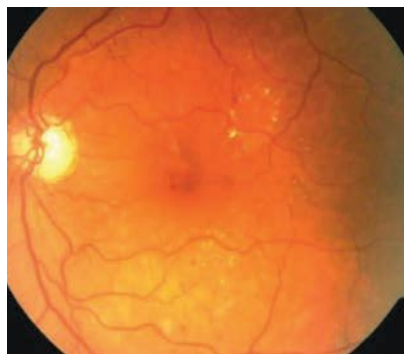

Photo: Thomas A. Wong, MD

**Using mfERG and SS-OCT can give ODs a chance to catch signs of advancing disease much earlier and avoid severe non-proliferative DR, as seen here.**

reduction in N1–P1 amplitude and the delay in P1-implicit time in the patients with diabetes was statistically significant in most of the assessed rings compared with the controls. Additionally, N1–P1 amplitude was negatively correlated with diabetes duration, although there was a positive correlation between P1-implicit time and diabetes duration in those with diabetes in four out of five rings.

The researchers note that more well-designed studies are needed to address some of their study's limitations, including measuring fasting blood sugar instead of HbA1c. Additionally, some diabetes data was obtained from patient medical records, they said in their report.<sup>1</sup>

## Inner Retinal Thinning

Research shows that neurodegeneration occurs early in the DR disease process, manifesting as structural, functional and molecular changes even in the absence of visible microvascular abnormalities.<sup>2,3</sup> OCT is one diagnostic tool that shows promise for detecting these changes early, with a new study finding it can

detect thinning of the inner retinal layers before DR becomes visible.<sup>4</sup>

The researchers compared the macular thickness and retinal nerve fiber layer between age-matched pregnant patients with gestational diabetes, non-pregnant women with Type 2 diabetes without DR and healthy non-pregnant women.

Mean best-corrected visual acuity, IOP, age and mean subfoveal choroidal thickness were similar across all three groups. The mean central macular thickness measurements were:

- Gestational diabetes group: 215.3 ± 10.83µm
- Type 2 diabetes group: 220.58 ± 21.62µm
- Controls: 230.03 ± 21.24µm

The researchers found that, compared with the control group, the retinal nerve fiber layer was slightly thinner only in the inferior zone of the two study groups. They also observed a statistically significant difference in thickness of all sectors of the ganglion cell layer among all groups, with non-pregnant Type 2 diabetes patients exhibiting the lowest values.

The researchers suggest that, "SS-OCT plays an important role in detecting retinal neurodegenerative changes and choroidal thickness induced by gestational and Type 2 diabetes before the development of retinopathy."<sup>4</sup>

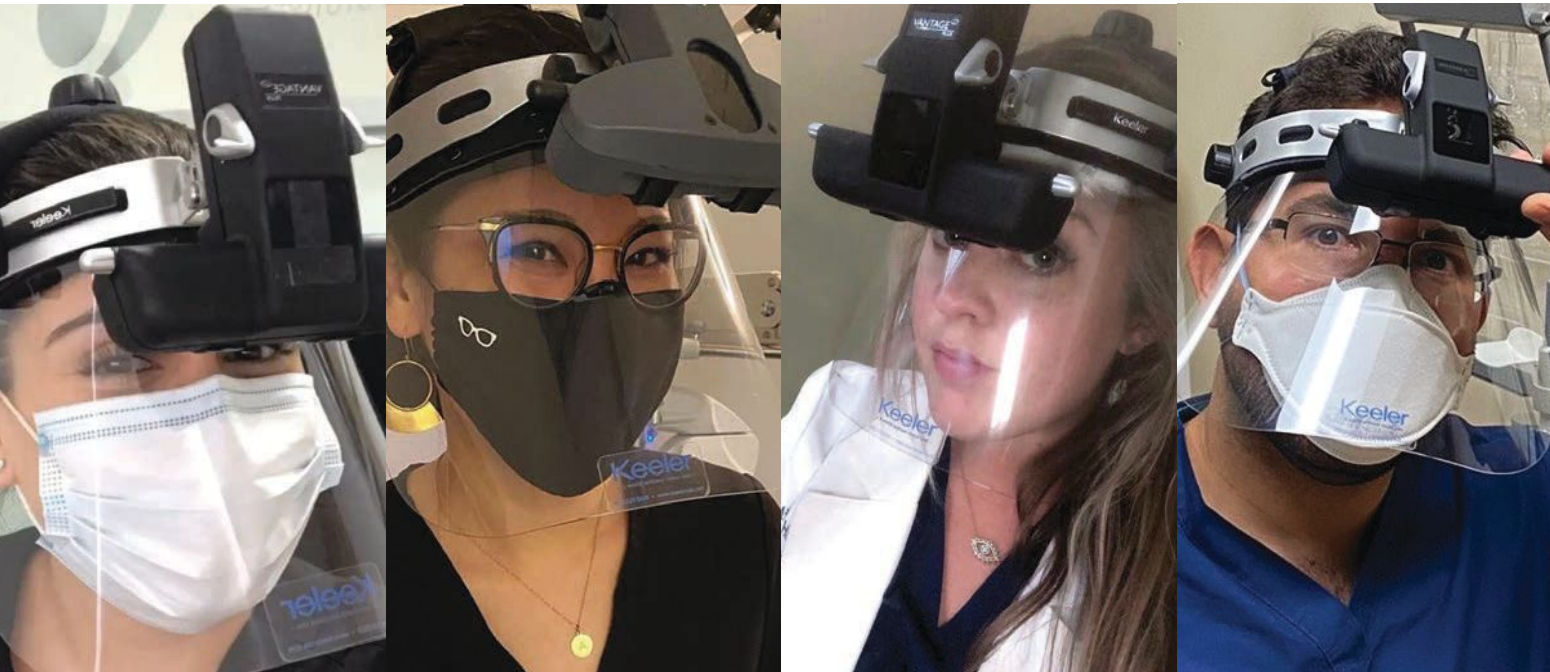1. Rabiolo A, Leadbetter D, Alagband P, et al. Primary deep sclerectomy in open-angle glaucoma: long-term outcomes and risk factors for failure. *Ophthalmology*. August 31, 2020. [Epub ahead of print].

2. Garcia-Ramirez M, Hernández C, Villarroel M, et al. Interphotoreceptor retinoid-binding protein (IRBP) is downregulated at early stages of diabetic retinopathy. *Diabetologica*. 2009;52:12:2633-41.

3. Chhablani J, Sharma A, Goud A, et al. Neurodegeneration in type 2 diabetes: Evidence from spectral-domain optical coherence tomography. *Invest Ophthalmol Vis Sci*. 2015;56:11:6333-8.

4. Akpolat C, Kurt MM, Evliyaoglu F, et al. Analysis of retinal neurodegeneration in gestational and type 2 diabetes using swept-source optical coherence tomography. *Can J Ophthalmol*. October 13, 2020. [Epub ahead of print].

# Helping Heroes See Clear And Stay Safe



The Vantage BIO is great for ROP screening! It's lightweight, has settings for different pupil sizes, a cool, white LED light and the longest battery ever!!"

**Dra. Paulina Ramirez Neria**



I'm a big fan of the All Pupil BIO. I had issues with other models so when I started [my practice], I knew the All Pupil would be my go-to BIO...I greatly appreciate the new custom fit Keeler BIO shields as an added safety layer."

**Dr. Annie Bacon**



I chose my [Vantage Plus] for the optics and value...with other brands, I had difficulty focusing up close during my dilated fundus exams. [The oculars] made my eyes feel more relaxed, and I felt like my view was better."

**Dr. Michelle Hammond**



[I've] been seeing emergent and urgent cases every day during the COVID19 pandemic. I really like [the Vantage BIO] because [it's a] very good quality and provides a super clear view."

**Dr. Reza Moradi**

Choose one of the programs below when you purchase a BIO\* between **September 1, 2020 and November 31, 2020**

\*this program is valid for our wireless indirects: All Pupil II and Vantage Plus

1

RECEIVE A

**\$850**

credit towards any PPE



2

24-MONTH

**0%**

lease as low as \$128/month\*

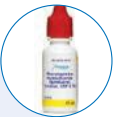\*All Pupil II: \$127.92/month; Vantage Plus: \$155/month (shipping and taxes not included).

3

RECEIVE

**10 FREE**

bottles of phenylephrine 2.5%, 15mL



**\*Leasing may also be combined with the PPE credit OR the phenylephrine option.**

Contact us at 800-523-5620 or customerservice@keelerusa.com to learn more or place your order. This promo cannot be combined with any other Keeler offers.

**Keeler**

— A world without vision loss —

www.keelerusa.com • 3222 Phoenixville Pike - Bldg. #50 • Malvern, PA 19355  
Tel No: 1-610-353-4350 • Toll Free: 1-800-523-5620 • Fax: 1-610-353-7814

  
A Halma company

# Injection Complications Rare in Practice

Intravitreal injections are one of the most commonly performed ocular procedures, but they have often been associated with a host of complications as chronicled in randomized controlled trials. However, a new study in *Ophthalmology Retina* found that complication rates in routine clinical practice are low compared with clinical trial reporting. As such, the investigators suggest providers should feel confident in the safety and administration of intravitreal injections during times when follow-up office visits and resources may be limited.

The study considered the complications and risk factors related to 44,734 injections performed on 5,318 patients from 2012 to 2015.

Overall, complications arose in 1.9% of all injections, with 1,031 unique complications in 685 patients (12%). This rate was significantly less than previously reported in clinical trials, which ranged from 62.5% to 90.1%, the

study authors noted.

The protocol-driven studies, in the quest to establish safety and efficacy, used pre-determined follow-up schedules in which all adverse events are included, while the current study assessed patient-initiated encounters concerning a complication, which researchers said more closely represents routine clinical practice. Patients may not always report or even notice a transient complication, which could explain the difference between the rates observed in clinical trials and the present study, the investigators explained.

In the current study, the most common minor complications, or those not requiring intervention, were irritation (312) and subconjunctival hemorrhage (284).

The most common serious complications requiring intervention were corneal abrasion (46) and iritis (31). The majority of complications (66%) were adequately managed by

a telephone/electronic message encounter.

Of note: no injection protocol parameter—such as type of anesthesia, preparation or post-injection medication—increased the risk of a complication. However, patient sex, age, number of previous injections and provider strongly influenced the risk of patient-reported complications, which providers should take into account to ensure the best possible outcomes, the researchers noted.

Given that most retina providers are still performing intravitreal injections during the COVID-19 pandemic, “knowledge of anticipated complication rates, including those which can be handled with a virtual or telephone encounter, and those of a more serious nature, is helpful for resource planning,” the researchers wrote in their paper.

Ramos MS, Xu LT, Singuri S, et al. Patient-reported complications after intravitreal injection and their predictive factors. *Ophthalmology Retina*. October 11, 2020. [Epub ahead of print].

# Lipid Layer a Useful Biomarker for MGD

A recent study identified a new screening tool for detecting obstructive meibomian gland dysfunction (MGD): lipid layer thickness (LLT). In the study, researchers divided 209 eyes diagnosed with obstructive MGD into

three groups based on age: young, middle-aged and older (*Table 1*).

The median LLT was 57nm, but from group to group, this value differed significantly. Additionally, the researchers noted that LLT was positively correlated with age, and that there was a negative correlation between LLT and meibomian gland dropout in all groups. LLT was positively correlated with gland expressibility in all groups but not

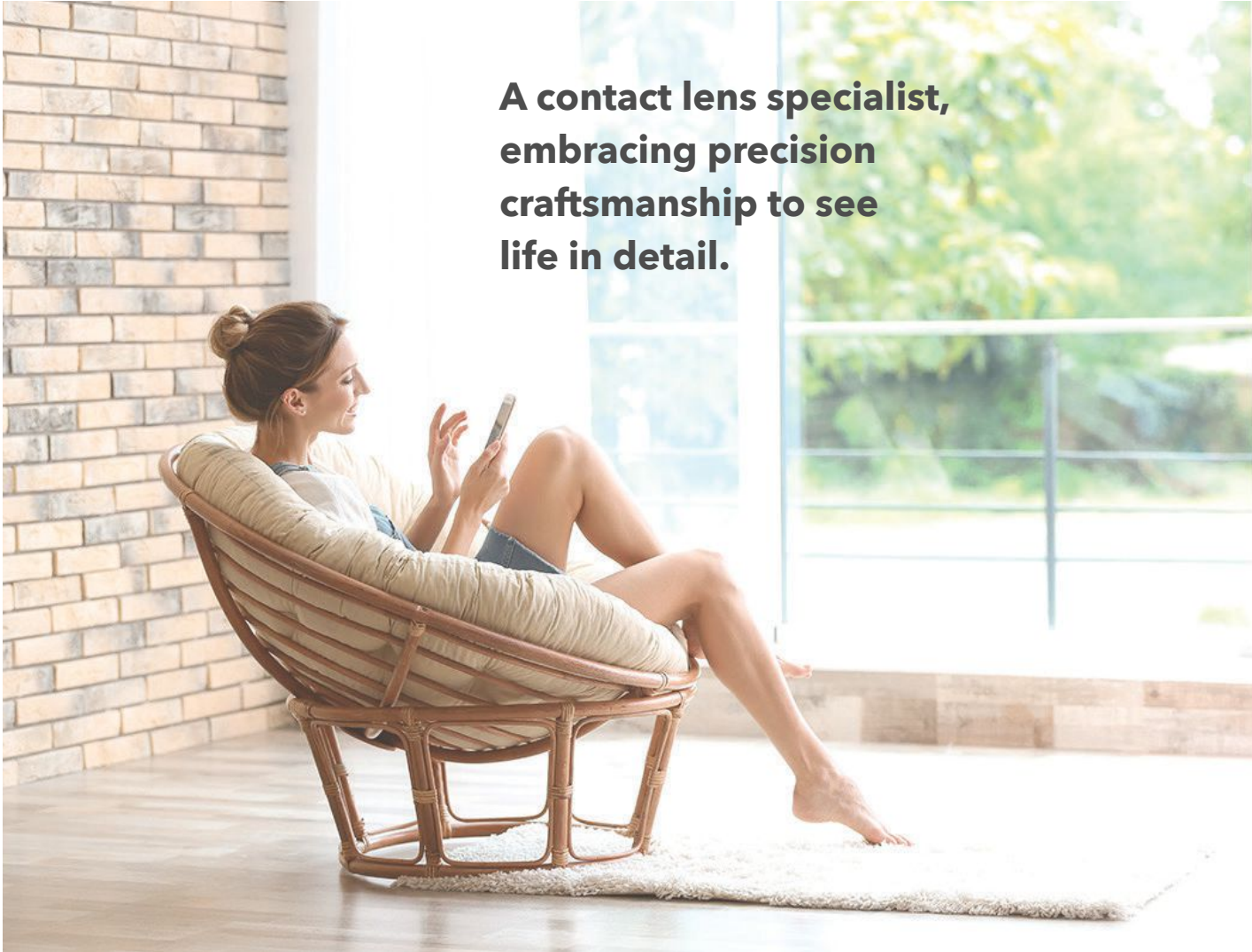statistically significant in the young group.

The researchers concluded that LLT increases with age and is significantly correlated with both meibomian gland secretion and morphology in middle-aged and older patients with obstructive MGD. They suggest using LLT as a screening tool for detecting obstructive MGD, as well as taking age into account when interpreting LLT values. ■

Li J, Ma J, Hu M, et al. Assessment of tear film lipid layer thickness in patients with meibomian gland dysfunction at different ages. *BMC Ophthalmol*. October 6, 2020. [Epub ahead of print].

**Table 1. Median Lipid Layer Thickness**

MGD Groups (n=209)	Median LLT
Young (ages 20 to 39)	51nm
Middle-aged (ages 40 to 59)	59.5nm
Older (ages 60+)	62nm



**A contact lens specialist,  
embracing precision  
craftsmanship to see  
life in detail.**



**Menicon is a contact lens  
manufacturer born in Japan.**

For over 60 years, Menicon has been a pioneer in contact lens innovation, delivering groundbreaking contact lenses and lens care solutions across the globe.

To learn more, visit: [www.meniconamerica.com](http://www.meniconamerica.com)

She deserves to know what  
she will pay before she gets  
to the pharmacy.

Not an actual patient.

Learn more at [www.MyChoiceRx.com/hcp](http://www.MyChoiceRx.com/hcp).

With MyChoiceRx™, both you and your patients will always know their cost of medications up front. All patients, even those on Medicare, get a set price on select Novartis medications.\*

It's just one of the ways we're putting patients first.

\*Limitations apply. Patients with federal or state prescription plans using MyChoiceRx™ must remain in the program for the calendar year. Program purchases not eligible for reimbursement.



**Novartis Pharmaceuticals Corporation**  
East Hanover, New Jersey 07936-1080

© 2020 Novartis

9/20

T-AAF-1394119



# Contents

Review of Optometry  
November 15, 2020

## Ocular Surface Health

### **40** Red Eye Remedies: New and Tried-and-True

Eye care providers already have a robust arsenal to help their patients combat this common ocular complaint. Here are the latest additions.

By Julie A. Tyler, OD, and Beata I. Lewandowska, OD, MS

### **48** How to Answer the “Why?” of Dry Eye

Patients have a lot of questions with this diagnosis, and how you respond is key to achieving positive outcomes.

By Whitney Hauser, OD

### **54** Artificial Tears: What Matters and Why

When selecting the right drop for your DED patient, experts say the devil's in the details.

By Jane Cole, Contributing Editor

### **62** Lid Wiper Epitheliopathy: What the OD Needs to Know

Observe and assess this aspect of the ocular surface to better deal with dry eye. By Chris Lievens, OD, Laurel Roberts, OD, Elyse Rayborn, OD, Yvonne Norgett, PhD, FCOptom, Nancy Briggs, PhD, Peter M. Allen, PhD, FCOptom, and Marta Vianya-Estopa, PhD, MCOptom

EARN 2 CE CREDITS:

### **70** A Modern Approach to Meibomian Gland Dysfunction

Learn how to effectively identify, diagnose and treat this condition. By Kambiz Silani, OD

### **34** CNS Disease: In the Eye and in Your Chair

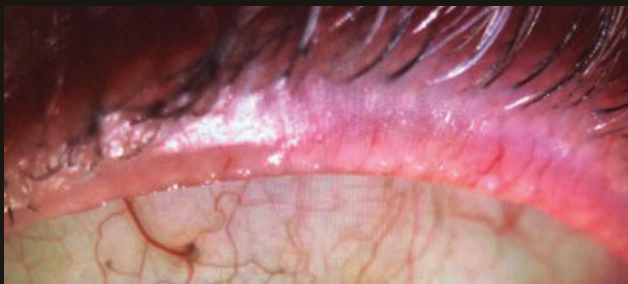These systemic conditions are on the rise, and new research suggests we can catch early signs with an eye exam. Here's what you need to know.

By Christopher L. Suhr, OD, MPH, and Saurin Patel, OD

### **78** How to Add Ortho-K to Your Toolkit

This valuable service may require thorough education but will provide enormous benefits to your patients and practice.

By Dan Fuller, OD



# Departments

Review of Optometry November 15, 2020

## 4 News Review

## 16 Letters to the Editor

## 18 Outlook

Caveat Emptor  
JACK PERSICO

## 20 Through My Eyes

DED: A Road Well-Traveled  
PAUL M. KARPECKI, OD

## 22 Chairside

Family is Family  
MONTGOMERY VICKERS, OD

## 24 Clinical Quandaries

Off to a Bad Start  
PAUL C. AJAMIAN, OD

## 26 The Essentials

The Ophthalmic Workhorse  
BISANT A. LABIB, OD

## 31 Coding Connection

New Codes: A Waiting Game  
JOHN RUMPAKIS, OD, MBA

## 84 Cornea + Contact Lens Q&A

Heart to Heart  
JOSEPH P. SHOVLIN, OD

## 86 Ocular Surface Review

Put a Damper on Flareups  
PAUL M. KARPECKI, OD

## 90 Retina Quiz

A Hazy Shade of Winter  
MARK T. DUNBAR, OD

## 94 Classifieds

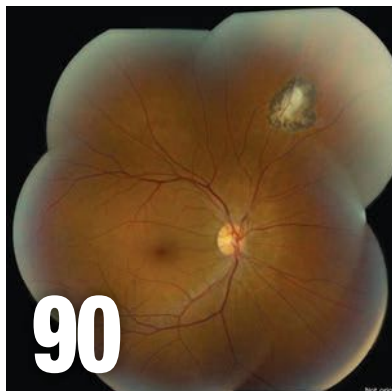
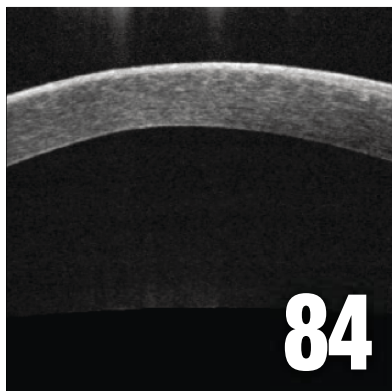
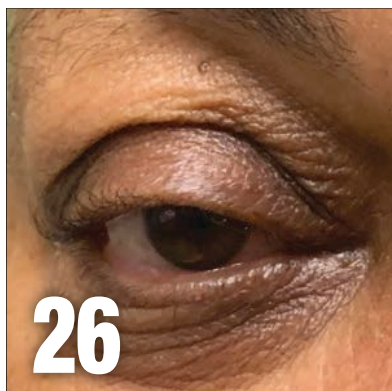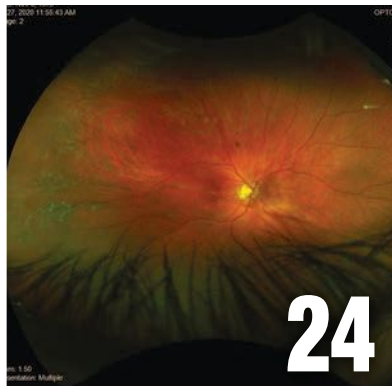## 96 Urgent Care

Straight to the Point  
LARAE ZIMPRICH, OD, AND  
RICHARD MANGAN, OD

## 97 Advertisers Index

## 98 Diagnostic Quiz

An Unexpected Turn  
ANDREW S. GURWOOD, OD



## REVIEW<sup>®</sup> OF OPTOMETRY

### BUSINESS OFFICES

19 CAMPUS BLVD., SUITE 101  
NEWTOWN SQUARE, PA 19073

### EXECUTIVE DIRECTOR

JAMES HENNE  
(610) 492-1017 • JHENNE@JOBSON.COM

### PUBLISHER

MICHAEL HOSTER  
(610) 492-1017 • MHOSTER@JOBSON.COM

### REGIONAL SALES MANAGER

MICHELE BARRETT  
(610) 492-1014 • MBARRETT@JOBSON.COM

### REGIONAL SALES MANAGER

JONATHAN DARDINE  
(610) 492-1030 • JDARDINE@JOBSON.COM

### VICE PRESIDENT, CLINICAL CONTENT

PAUL M. KARPECKI, OD, FAAO  
PKARPECKI@JOBSON.COM

### PRODUCTION MANAGER

FARRAH APONTE  
(212) 274-7057 • FAPONTE@JOBSON.COM

### SENIOR CIRCULATION MANAGER

HAMILTON MAHER  
(212) 219-7870 • HMAHER@JHIHEALTH.COM

### CLASSIFIED ADVERTISING

(888) 498-1460

### SUBSCRIPTIONS

\$56 A YEAR, \$88 (US) IN CANADA,  
\$209 (US) IN ALL OTHER COUNTRIES.

### SUBSCRIPTION INQUIRIES

(877) 529-1746 (US ONLY)  
OUTSIDE US CALL: (845) 267-3065

### CIRCULATION

PO Box 81  
CONGERS, NY 10920  
TEL: (TOLL FREE): (877) 529-1746  
OUTSIDE US: (845) 267-3065

### CEO, INFORMATION SERVICES GROUP

MARC FERRARA

### SENIOR VICE PRESIDENT, OPERATIONS

JEFF LEVITZ

### VICE PRESIDENT, HUMAN RESOURCES

TAMMY GARCIA

### VICE PRESIDENT, CREATIVE SERVICES & PRODUCTION

MONICA TETTAMANZI

### CORPORATE PRODUCTION DIRECTOR

JOHN ANTHONY CAGGIANO

### CIRCULATION DIRECTOR

JARED SONNERS



# Simplicity.

Quote, buy,  
and download  
your policy all  
in 5 minutes.

Savings + Simplicity + Security,  
it all adds up with Berxi. Get a  
**medical malpractice insurance**  
quote at [berxi.com](https://berxi.com).



**BERXI IS PART OF BERKSHIRE HATHAWAY SPECIALTY INSURANCE COMPANY**

© Copyright 2020. The information contained herein is for general informational purposes only and does not constitute an offer to sell or a solicitation of an offer to buy any product or service. Any description set forth herein does not include all policy terms, conditions and exclusions. Please refer to the actual policy for complete details of coverage and exclusions. All policies are underwritten by Berkshire Hathaway Specialty Insurance Company, 1 Lincoln Street, 23rd Floor, Boston, MA 02111

## NCT Safer in Practice Than Report Alleges

A news story published online September 28 and in the October print issue (“Avoid Tonometry With High Tear Volume”) provided an overview of a *Journal of Glaucoma* publication, along with editorial comments.<sup>1</sup> Unfortunately, the reporting largely misrepresented the conclusions, and the essence, of the study (“Quantitative high-speed assessment of droplet and aerosol from an eye after impact with an air-puff amid COVID-19 scenario,” by Shetty et al.). The news story proclaims, “Even non-contact options can create droplets and aerosols, increasing the risk of contamination.” The article goes on to state: “Researchers are now recommending clinicians avoid non-contact tonometry (NCT) in patients with high tear volume, whether natural or due to eye drops, as the diagnostic procedure could spread droplets to the device and the operator.”

By focusing on these unlikely outcomes, the news story leads readers to believe that non-contact tonometry is unsafe and, in doing so, fails to accurately portray the overall findings of the study by Shetty, which were *positive* with regards to the safety of non-contact tonometry. The study demonstrated that droplet spray *did not occur* when the instrument was used “in the natural setting.” Droplets were only detected when supplemental artificial tears were experimentally added to the eye—and it took *two drops* to produce substantial scatter. However, this is not how non-contact tonometers are intended to be used and not how they are used routinely in clinic. NCTs are used without drops of any kind.

Beyond this, I implore authors of medical and scientific articles to use the term “aerosols” properly as to not misinform readers. Even the Shetty paper used this term haphazardly. An aerosol is a tiny particle suspended in air. Particles of 100µm and larger are not usually considered aerosols. In the context of the COVID discussion, when talking about aerosols we are generally talking about 10µm or less. The Shetty study depicted “droplets” ranging from 100µm to 500µm. Droplets this large will not become airborne. There is no credible published evidence that NCTs generate “aerosols.” Finally, it is important for readers to be made aware that the probability of SARS-CoV-2 being present in tears is exceedingly low based on published evidence.<sup>2-4</sup>

All things considered, with respect to tonometry and COVID, non-contact tonometers are likely the safest option. Goldmann requires direct eye contact, close patient-clinician distance and, frequently, lid-holding. Handheld tonometers also require relatively close distance, direct contact and frequent lid-holding. NCTs

provide the maximum possible distance between patient and clinician, no lid-holding and no mucous membrane contact.

This briefing did not present a balanced view of the Shetty paper, focusing instead on unlikely hypothetical fears. This is a disservice to clinicians and the patients who benefit from these measurements and is unnecessarily damaging to NCT manufacturers’ reputations.

—David A. Taylor, Director

Product Management & Business Development  
Reichert Technologies

1. Shetty R, Balakrishnan N, Shroff S, et al. Quantitative high-speed assessment of droplet and aerosol from an eye after impact with an air-puff amid COVID-19 scenario. *J Glaucoma*. September 17, 2020. [Epub ahead of print].

2. Jianhua Xia MM, Jianping Tong MD, Mengyun Liu MM, et al. Evaluation of coronavirus in tears and conjunctival secretions of patients with SARS CoV 2 infection. *J Med Virol*. 2020;92(6):589-94.

3. Guan WJ, Ni Z, Hu Y, et al. Clinical characteristics of coronavirus disease 2019 in China. *N Engl J Med*. 2020;382:1708-20.

4. Yu Jun IS, Anderson DE, Zheng Kang AE, et al. Assessing viral shedding and infectivity of tears in coronavirus disease 2019 (COVID-19) patients. *Ophthalmology*. 2020;127(7):977-79.

## Keep Referrals Within Optometry When Possible

I enjoyed Dr. Fanelli’s article in the June issue entitled “The Dangers of DNR” and just wanted to congratulate him on the creativity and wisdom of his timely commentary. I agree with him that the time has come for our profession to cease the pathological *modus operandi* of referring non-surgical cases to a surgeon.

There is now a critical mass of highly competent clinical optometrists ready, willing and able to handle medical eye conditions and we, as a profession, need to be doing *intra*-professional consultations rather than reflexively dumping these patients on eye surgeons. Such a sea change will require a two-step process. First, medically oriented optometrists should seek out their local non-medically inclined colleagues and let them know they would be happy to consult with them. Second, the non-medically inclined optometrists should seek out the more medical colleagues in their area and begin to use them as a resource. The consultant OD should make every good-faith attempt to send the referred patient back to the primary OD. That being said, once any patient leaves your practice to see any OD or MD, there is always the risk of losing such patients (and their family and friends), which is why I would like to see *all* ODs embrace greater patient care responsibilities.

Again, Dr. Fanelli, thank you for your always excellent articles, but this one was especially timely for our profession. Thank you for your many contributions to enhance the profession of optometry.

—Randall Thomas, OD, MPH  
Concord, NC

# Dry eye relief that goes the distance



VeraPlug™  
**FlexFit™**

**Long-term occlusion** with enhanced fit, comfort and retention



Vera**180**™

Synthetic absorbable plugs for approximately **6 months of treatment**



Vera**C7**™

**7 day** absorbable plugs for diagnostic use

For every leg of the race, we'll help you keep the pace. From **temporary diagnostic occlusion** to **long-term silicone plugs**, Lacriversa offers a complete line of innovative products for the treatment of dry eye.



A FRESH PERSPECTIVE™

[lacriversa.com](http://lacriversa.com) (855) 857-0518

2500 Sandersville Rd • Lexington KY 40511 USA





PRINTED IN USA

FOUNDING EDITOR, FREDERICK BOGER  
1891-1913

EDITORIAL OFFICES  
11 CAMPUS BLVD., SUITE 100  
NEWTOWN SQUARE, PA 19073

SUBSCRIPTION INQUIRIES  
1-877-529-1746

CONTINUING EDUCATION INQUIRIES  
1-800-825-4696

EDITOR-IN-CHIEF • JACK PERSICO  
(610) 492-1006 • JPERSICO@JOBSON.COM

MANAGING EDITOR • REBECCA HEPP  
(610) 492-1005 • RHEPP@JOBSON.COM

ASSOCIATE EDITOR • CATHERINE MANTHORP  
(610) 492-1043 • CMANTHORP@JOBSON.COM

ASSOCIATE EDITOR • MARK DE LEON  
(610) 492-1021 • MDELEON@JOBSON.COM

SPECIAL PROJECTS MANAGER • JILL GALLAGHER  
(610) 492-1037 • JGALLAGHER@JOBSON.COM

ART DIRECTOR • JARED ARAUJO  
(610) 492-1032 • JARAJO@JOBSON.COM

DIRECTOR OF CE ADMINISTRATION • REGINA COMBS  
(212) 274-7160 • RCOMBS@JOBSON.COM

EDITORIAL BOARD

CHIEF CLINICAL EDITOR • PAUL M. KARPECKI, OD

ASSOCIATE CLINICAL EDITORS • JOSEPH P. SHOVLIN, OD;  
CHRISTINE W. SINDT, OD

DIRECTOR OPTOMETRIC PROGRAMS • ARTHUR EPSTEIN, OD

CLINICAL & EDUCATION CONFERENCE ADVISOR  
PAUL M. KARPECKI, OD

CASE REPORTS COORDINATOR • ANDREW S. GURWOOD, OD

CLINICAL CODING EDITOR • JOHN RUMPAKIS, OD, MBA

COLUMNISTS

CHAIRSIDE • MONTGOMERY VICKERS, OD

CLINICAL QUANDARIES • PAUL C. AJAMIAN, OD

CODING CONNECTION • JOHN RUMPAKIS, OD

CORNEA & CONTACT LENS Q+A • JOSEPH P. SHOVLIN, OD

DIAGNOSTIC QUIZ • ANDREW S. GURWOOD, OD

THE ESSENTIALS • BISANT A. LABIB, OD

FOCUS ON REFRACTION • MARC TAUB, OD;  
PAUL HARRIS, OD

GLAUCOMA GRAND ROUNDS • JAMES L. FANELLI, OD

OCULAR SURFACE REVIEW • PAUL M. KARPECKI, OD

RETINA QUIZ • MARK T. DUNBAR, OD

SURGICAL MINUTE • DEREK N. CUNNINGHAM, OD;  
WALTER O. WHITLEY, OD, MBA

THERAPEUTIC REVIEW • JOSEPH W. SOWKA, OD

THROUGH MY EYES • PAUL M. KARPECKI, OD

URGENT CARE • RICHARD B. MANGAN, OD

JOBSON MEDICAL INFORMATION LLC



# Outlook

By Jack Persico, Editor-in-Chief



## Caveat Emptor

Another online seller pushes convenience over quality.

A lot of damage can happen in four years. No, I'm not talking about presidential terms. But consider the eligibility requirements for QuickRenew, the new online contact lens prescription service from CVS: "Patients must be age 18-55, have been fitted for contact lenses in the past, have had a full eye exam within the last four years and have healthy eye history."

Excuse me? Since when is an eye exam only needed once every four years? That flies in the face of the recommendations from all corners of eye care—doctors, societies, industry—as well as the general sentiment across all of medicine that advocates for routine preventive care.

To check ocular surface health, QuickRenew instructs users to "take a couple of quick pictures of your eyes so the doctor can see if there's any redness or other apparent irritation." Then the patient undergoes one of the now-infamous online vision tests while wearing their current lenses. If they meet CVS's (undisclosed) visual acuity threshold—bam! Click here to order. Will they get the same brand-name lenses, or just an equivalent Rx? Unclear.

Does any of that sound like "health care" to you? It does to the company, which notes in a press release, "This addition to our optical site gives customers a new way to fulfill an important health care need safely and confidently from the comfort of their homes." The statement also explains that "QuickRenew requests are reviewed by a board-certified ophthalmologist, and users are prominently reminded that this service does not take the place of an in-person comprehensive eye exam."

I took the test myself. The software does attempt to screen out problems, but the effort is entirely user-driven. The customer is asked if they have experienced infection, redness, flashes, double vision and other concerns. As long as you say no to all the above, you're free and clear. You also tell them when your last eye exam was—again, entirely on the honor system. I had one last month but chose "four years ago" to see if it might trigger any flags. Nope.

The vision test gave me just three lines of acuity targets: one each for OD, OS and OU. I wear multifocals, but near vision testing wasn't part of the protocol. No biggie, right? And the "eye redness check" photos were taken not with my phone's excellent camera but my laptop's lousy one.

What bothers me most is the service's disingenuous use of the signifiers of health care. I intentionally failed my quickie refraction—and immediately got an email reassuring me that "the doctor recommended trying again." Oh, "the doctor" said so, huh? At 10:30pm and within seconds? My CVS doctor then encouraged me to "take a new exam."

If a company wants to offer a bare-bones way to buy stuff, fine, go ahead. Just don't cloak it in the trappings of health care, with phantom *doctors* and dubious *exams*. Let customers know they're choosing convenience over quality—and accepting a huge amount of risk in the process.

Maybe I have my dander up because this issue of *Review*, devoted to ocular surface health, plainly demonstrates the complexity of eye care and the value of a doctor's expertise. I hope it helps you build up yours even more. ■

Affordable | Portable | Scientifically Proven

Eliminates contamination, MRF sanitizes in under 2 minutes

# VISUAL FIELD SUITE

M&S | Melbourne Rapid Fields (MRF)

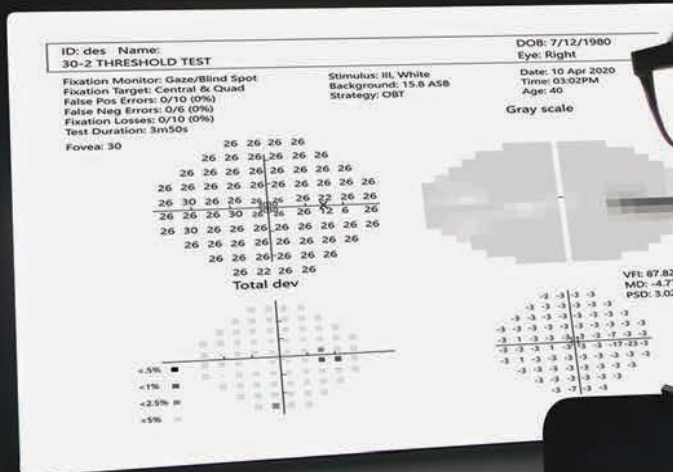
Now offering  
reimbursement  
for At-Home  
Visual Field  
Testing



In-Clinic



At-Home



Offering two convenient solutions to Visual Field testing developed by a name you can trust.

## In-Clinic

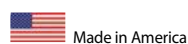- MRF Full Grid 30-2, 24-2, 10-2, Screening
- Built-in adaptive patient response timer
- Quicker test times
- Doctor may review reports remotely
- Built-in progression analysis
- High test / retest repeatability
- Portable with small footprint



Peer reviewed & published

## At-Home

- Convenient at home testing
- Straight-forward, user friendly interface for both doctor and patient
- Email patients a secure link for their visual field test
- Securely view patient's results immediately upon completion
- Record patient progression with ease and confidence



The First Choice in Vision Testing Systems



847-763-0500 mstech-eyes.com



Powered by: EyeSimplify™





# DED: A Road Well-Traveled

Here are some tips to help you avoid the potholes I've hit along my 20-year journey as a dry eye specialist. **By Paul M. Karpecki, OD, Chief Clinical Editor**

Since focusing on dry eye disease (DED) in 1997 and starting a dry eye/cornea practice two years later, I've made a lot of mistakes and learned from legends like Donald Korb, OD. But now I know what to do—and what not to do.

## Check Under the Hood

The eyelids are the key to almost 86% of DED.<sup>1</sup> Begin with a detailed observation of the eyelids:

- At the slit lamp, assess for collarettes at the base of the lashes indicating *Demodex* blepharitis.
- Scan for debris, discharge and biofilm indicating bacterial/staphylococcal blepharitis.
- Express the lower nasal to central glands. If the meibum is turbid, thickened, paste-like or non-expressible, the patient likely has MGD.
- Look for a frothy tear film or froth on the eyelid margins, which indicates saponified oils in MGD.
- Watch as the patient blinks to see if there is partial or incomplete closure. Perform the K-B test to assess for improper eyelid closure. Have the patient close their eyes, then shine a penlight onto the closed lid to see if light escapes inferiorly.
- Check for lid laxity, entropion and ectropion.

## Find a Map

The TFOS DEWS II diagnostic approach, while it seems complex, is actually straightforward, effective and easy to perform:<sup>2</sup>

- Ask triaging questions about how patients' eyes feel and look,

whether they use artificial tears, digital device use and blurred vision.

- Look at risk factors such as smoking, certain medications, contact lens wear, previous ocular surgery and systemic diseases.
- Use a validated DED questionnaire such as the DEQ-5 or SPEED.
- Perform one to two homeostasis-determining tests, such as osmolarity testing, tear film break-up time and ocular surface staining.
- If you note DED signs and symptoms, determine the subtype. For evaporative DED, express the meibomian glands and perform meibography, if available. For aqueous deficiency, look at the tear meniscus height when you instill NaFl dye.

## A Winding Road

I've found the traditional approach to DED usually results in frustration for everyone. Instead, consider these clinical pearls:

- DED starts as episodic, but if the disease progresses, the patient will require life-long therapy.
- Educate patients that it will be three to six months before they notice symptomatic improvement.
- Use a slit lamp camera system to recall previous signs and educate patients; also consider patient education tools for efficiency.
- Don't just treat the tear film; also address the obstructed glands, blepharitis and inflammation.
- For aqueous deficiency, consider 180-day dissolvable punctal plugs.
- Add a red eye treatment, such as alpha-2 specific agonists, to boost

patient confidence.

- Provide in-office procedures such as low-light level therapy, BlephEx, intense pulsed light and thermal in-office treatments directed at the meibomian glands.
- Consider a dental model of in-office treatments combined with at-home maintenance.
- Incorporate biologics such as amniotic membrane, autologous serum and cytokine extract drops.
- Multiple options exist if a therapeutic drop is too expensive. For example, cyclosporine now has three formulations: Restasis (Allergan), Cequa (Sun Pharma) and Klarity-C (Imprimis).
- Research shows omega fatty acid supplements with GLA and fish oil are effective and safe.<sup>3-6</sup>
- A 10-second eyelid debridement dramatically helps patients with MGD/evaporative DED.
- The best option for DED flare-ups is topical corticosteroids such as loteprednol for four to seven days. ■

*Note: Dr. Karpecki consults for companies with products and services relevant to this topic.*

1. Lemp MA, Crews LA, Bron AJ, et al. Distribution of aqueous-deficient and evaporative dry eye in a clinic-based patient cohort: a retrospective study. *Cornea*. 2012;31(5):472-8.  
 2. Wolfssohn JS, Arita R, Chalmers R, et al. TFOS DEWS II Diagnostic Methodology report. *Ocul Surf*. 2017;15(3):539-74.  
 3. Sheppard JD, Pflugfelder SC, McClellan AJ, et al. Long-term supplementation with n-6 and n-3 PUFAs improves moderate-to-severe keratoconjunctivitis sicca: a randomized double-blind clinical trial. *Cornea*. 2013;32:1297-1304.  
 4. Liu A, Ji J. Omega-3 essential fatty acid therapy for dry eye syndrome: a meta-analysis of randomized controlled studies. *Med Sci Monit*. 2014;20(1):1583-9.  
 5. Zhu W, Wu Y, Li G, et al. Efficacy of polyunsaturated fatty acids for dry eye syndrome: a meta-analysis of randomized controlled trials. *Nutr Rev*. 2014;72(10):662-71.  
 6. Mudil P. Evaluation of use of essential fatty acids in topical ophthalmic preparations for dry eye. *Ocul Surf*. October 4, 2019. [Epub ahead of print].

# Adapt. Evolve. Grow.



As you **adapt** to the changes our industry is facing, you'll find there is also opportunity.

Discover how dark adaptation testing with AdaptDx Pro™ guided by Theia™ can help you **evolve** your approach to AMD care. Become an AMD Center of Excellence™ and unlock your potential to **grow** your practice revenue.

**AdaptDx**<sup>™</sup>  
**PRO**  
Guided by Theia<sup>™</sup>

Download *Practical Opportunities in AMD Management* for real-life perspectives from your fellow optometrists at [maculogix.com/opportunity](https://maculogix.com/opportunity)

# Family is Family

They're great and all, but they'll drive you nuts. And you can't even escape them at the office. **By Montgomery Vickers, OD**

Optometrists, by nature, are a friendly, loving and slightly neurotic bunch of folks, which lends itself to being pathologically involved with families.

Of course, families—all of them—are also a challenge. Sometimes each of us gets a little fried and will have disagreements that may result in ultimate fighting-level cage battles. But in the end, we find a way through it, especially if everyone admits we were right. Optometrists, by nature, are also a little narcissistic. Just admit it.

## The Others

But our patients also have families. One time a patient called me aside before his father's eye exam and asked me to please tell the patient, who had early dementia, that he should no longer drive. The son knew this was a big moment, and I saw a tear sneak out.

I did it. It was hard but the right thing to do. Two months later the son cancelled his own appointment, saying: "My father won't let us come to a doctor who took his driver's license away."

*Family.*

How about when you check the next day's schedule and see that four family members are coming in together? You know what's coming:

1. There's a 50/50 chance all of them cancel, reschedule or no show.
2. There's an 80% chance some don't make it because mom forgot they had soccer practice.
3. There's a 90% chance that if

they buy anything, it will be the cheapest thing they can get because sticker shock can be quite a deterrent if you are writing a check for four pairs of glasses.

4. There's at least a 10% chance they walk away with their Rx's.

*Family.*

Now, parents are very concerned about their kids stuck on computers all day for school. This just cannot be as healthy as what they did last summer... play video games all day.

After you spend 15 minutes explaining the possible risks of 430nm to 450nm high-energy light and the importance of getting the kids outside, they go home and spend two hours on social media sharing their newfound knowledge, only to have a guy who used to work for their cousin convince them it's all a bunch of malarkey.

*Family.*

## The Second Family

Your office is a family unit too, like it or not. You spend your time trying to keep your staff away from the hot stove but still want them in there cooking, right? And you can't really discipline them, since spanking and time-out are

off the table. Too bad.

Your office family has all the requisite members:

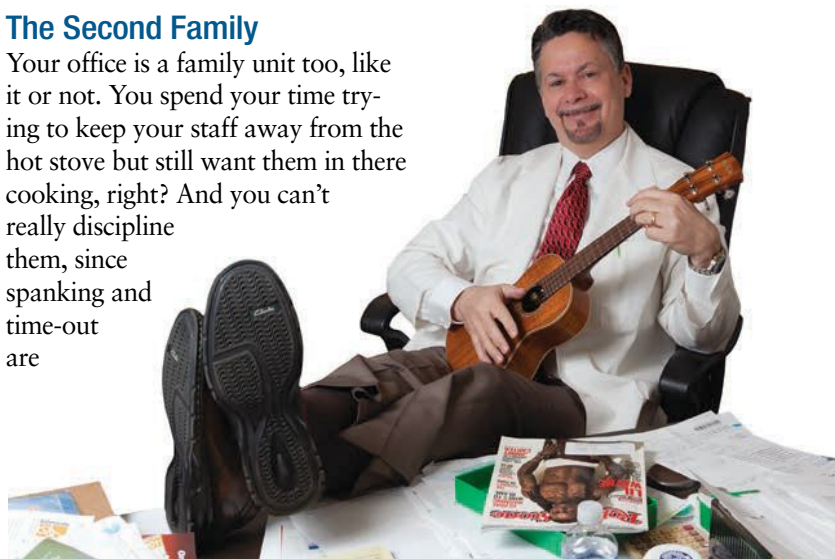There's the mom who spends her time making sure everyone is fed and listens, so she knows everything. For goodness' sake, keep mom on your side or your office is doomed!

There's dad. He's kind and wants to fix everything, even if it makes it worse. Try to find dad a chair and a TV to keep him out of trouble.

There's the crazy teenage daughter who can ruin your day with a mere glance suggesting, "You might be an idiot."

There's the rebellious son. Don't forget to remind him who's boss, i.e., mom.

Family is the most confounding and blessed gift to us all. I say "confounding" because no one can ever decipher them. I say "blessed" in case my family reads this. ■

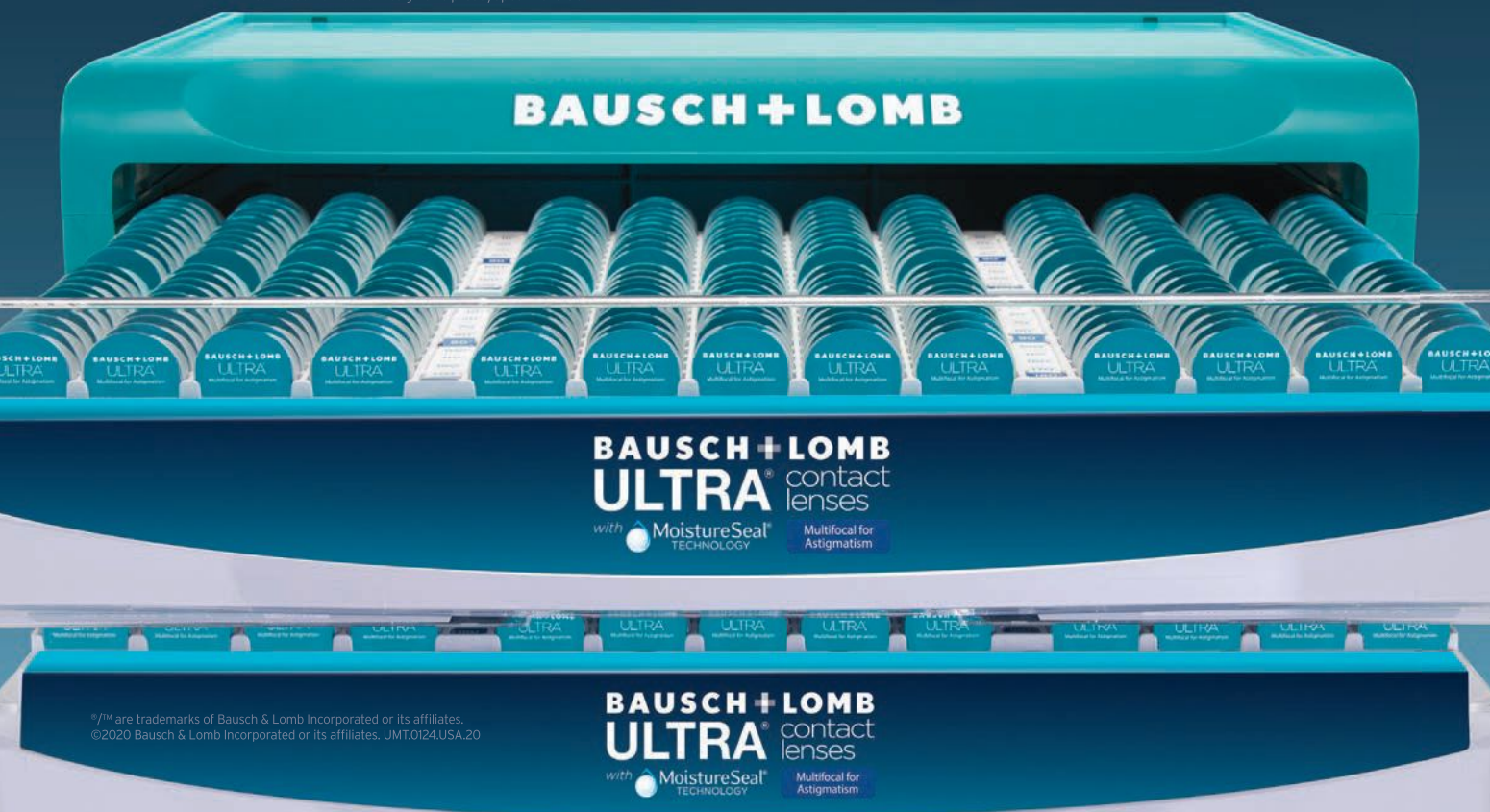



# WHY MAKE 32 MILLION\* PATIENTS WAIT?

The time for same-day multifocal toric fitting is now.  
Unlike other brands, **Bausch + Lomb ULTRA® Multifocal for Astigmatism**  
is available in office to save time and reduce follow-ups. Prescribe the  
only multifocal toric lens with **same-day convenience**.

\*Estimated number of astigmatic presbyopes in the US.





# Off to a Bad Start

The timing of surgical intervention for macula-off RD is debateable, and COVID could complicate things further. **Edited by Paul C. Ajamian, OD**

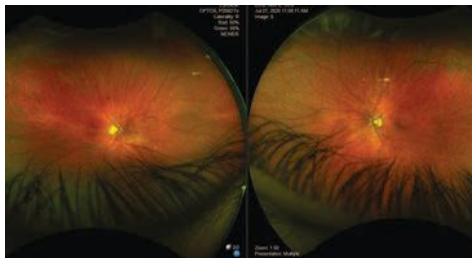**Q** A 41-year-old Caucasian male came in for his annual comprehensive eye exam. However, the retinal exam revealed a total macula-off retinal detachment (RD). How quickly does surgery need to be performed?

**A** “It’s not often a retinal detachment presents without any symptoms, but in this case, that’s exactly what happened,” says Andrea Knouff, OD, of Eyelectic Vision Source in Atlanta. The prior year patient’s VA was 20/20 OU, and his eye health exam was normal. Family history revealed his father was a high myope and had a history of RD. Dilated fundus examination revealed a total macula-off detachment OD.

Dr. Knouff pressed to see if he had noticed any flashes, floaters or curtain. The patient told her that he has been working from home due to COVID for the past three months and hadn’t noticed any changes. She immediately referred him to retina specialist Ajey Alurkar, MD, at Omni Eye Services in Atlanta.

“Practitioners should always be alert for cases like these, especially if the patient is highly myopic and has a family history of RD,” Dr. Knouff says. High myopes >-6.00D are 10 times more likely to have a retinal detachment in their lifetime.

According to the American Academy of Ophthalmology, macula-off RD may be more urgent than previously thought. A recent study from 2019 determined that macular photoreceptors may undergo more damage the longer the detachment



**All standard cases of mac-off RD should get fixed as quickly as possible.**

remains, thus changing the way doctors should think about macula-off detachments as an emergent situation.<sup>1</sup>

## COVID Delay

In the case of Dr. Knouff’s patient, there was a twist. He was seen immediately that Tuesday by Dr. Alurkar and was scheduled for surgery on Thursday. He was then tested for COVID-19 by the hospital as standard protocol. Unfortunately, he was positive despite being symptom-free, and the procedure was cancelled.

“In all standard cases of macula-off RD, they should get fixed as quickly as possible because chronic detachments can dramatically affect the prognosis,” Dr. Alurkar says. “Surgery should be performed within seven to 10 days from the date of presentation or detection,” he says.

Because of his COVID positive status, this patient would have to wait another week or two so that he could complete his isolation. “It’s not the best timetable, but until he tested negative, we had no choice,” Dr. Alurkar notes. He further adds that some facilities in the Atlanta

area are dropping their COVID testing requirements and basing admission on symptoms alone.

The treatment and post-op management of a macula-off RD is the same as a macula-on RD, which are often repaired within 24 to 72 hours.

Unfortunately, vision loss of three to four lines is common in macula-off RD. According to Dr. Alurkar, the outcome varies depending on age, neural plasticity, health of the patient and co-existing ocular conditions. “Macula-off detachments do cause some degree of permanent vision loss,” he says.

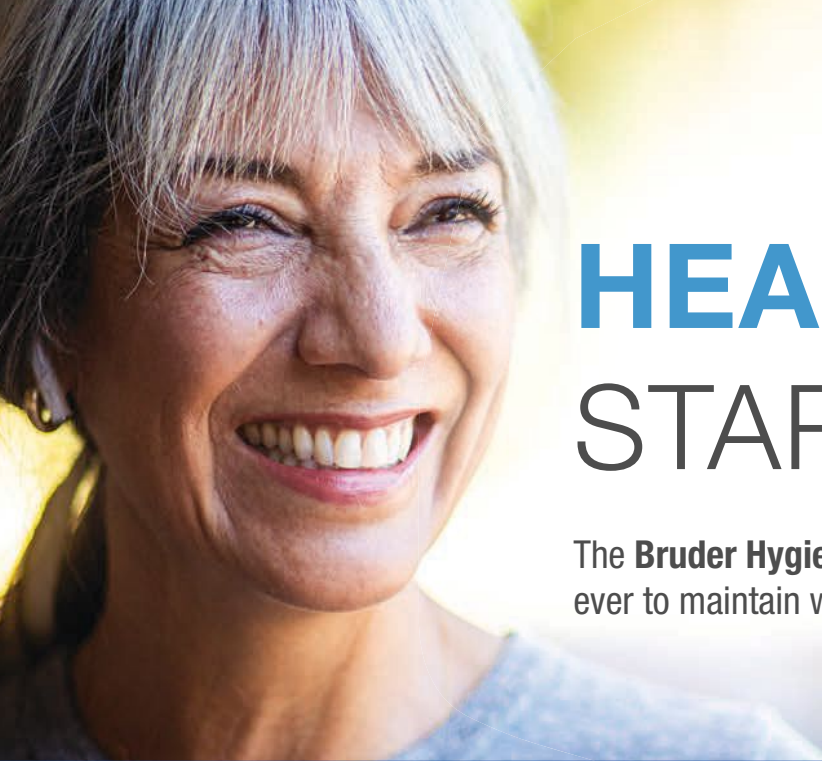## Be Thorough

The crucial factors in obtaining good outcomes for an RD include timely diagnosis, selection of the right intervention and careful follow-up. In an era of ultra widefield scanners and patients that may resist dilation, stand firm and make dilation a routine part of your exam. Lawsuits are still a common result of avoiding or deferring dilation.

“Try using a 30D lens to get a better look through smaller pupils,” says Dr. Knouff. “Assume everyone has peripheral retinal issues until you prove that they don’t.”

Lastly, document carefully that you dilated the patient and how you examined them. “It will guarantee the best care for the patient, and it will protect you for many years to come,” she says. ■

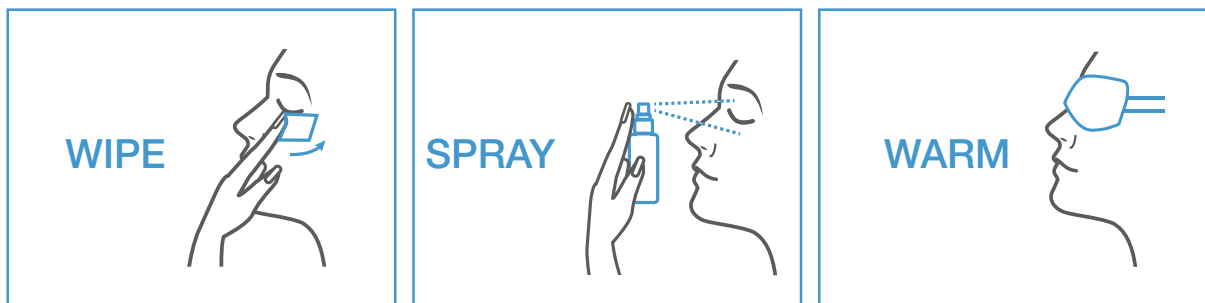1. Greven MA, Leng T Silva RA, et al. Reductions in final visual acuity occur even within the first three days after a macula-off retinal detachment. *Br J Ophthalmol.* 2019;103:1503-6.



# HEALTHY EYES START HERE

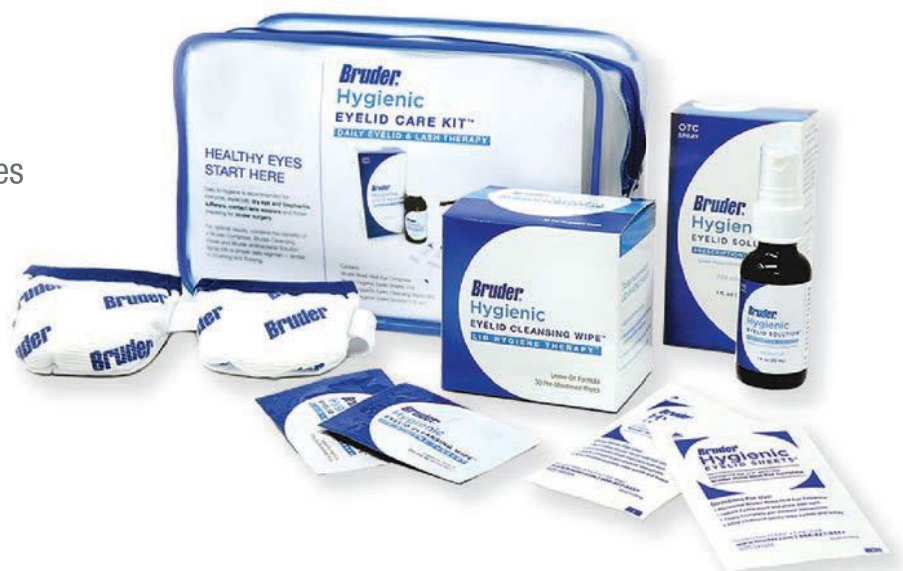The **Bruder Hygienic Eyelid Care Kit** makes it easier than ever to maintain wellness and manage dry eye disease.

## IMPROVE EYELID HEALTH IN 3 EASY STEPS



Whether you are seeing patients in-office, or communicating online or over the phone, the all-in-one Bruder Eyelid Care Kit can help keep their eyes healthy until their next appointment.

Three easy steps—*available in one convenient kit*—are just what the doctor ordered!



Watch the Kit Educational Video  
[www.bruder.com/review2020](http://www.bruder.com/review2020)

Purchase online at [order.bruder.com](http://order.bruder.com)

**Bruder** | Better. By Design.

888-827-8337 | [eyes@bruder.com](mailto:eyes@bruder.com)



# The Ophthalmic Workhorse

Phenylephrine's effect on the sympathetic nervous system provides numerous applications far beyond dilation. **By Bisant A. Labib, OD**

**P**henylephrine hydrochloride is ubiquitous among all ophthalmic practices. While it is used mostly to perform routine dilations, this readily available drug has a robust roster of ophthalmic uses, some of which might surprise you. But once you understand its mechanism of action, you will be confident when reaching for phenylephrine for far more than dilation; you will also be prepared for any potential side effects.

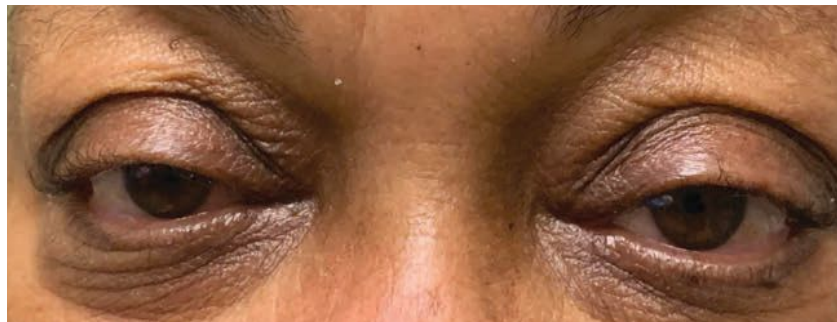## How it Works

Phenylephrine functions as a direct-acting sympathomimetic agent, which works to primarily stimulate alpha-1 adrenergic receptors.<sup>1</sup> The body's autonomic nervous system (ANS), which regulates many involuntary organ functions, is divided into the parasympathetic and the sympathetic nervous system. The parasympathetic system is responsible for functions that occur when the body is at rest while the sympathetic nervous system elicits an action response.

These two branches work synergistically to regulate internal organs

## General Uses

Beyond optometry, phenylephrine hydrochloride is indicated for intravenous use to elevate blood pressure in patients with severe hypotension in the setting of septic shock or anesthesia. It's also used intranasally for congestion and topically as a component of hemorrhoid cream due to its vasoconstrictive properties.<sup>2</sup>



**Mild ptosis secondary to sympathetic dysfunction.**

within the body.<sup>2</sup> Administering phenylephrine stimulates the sympathetic branch, giving rise to its various applications (*Table 1*).

## In-office Uses

Ophthalmic solutions of phenylephrine are available in different concentrations, depending on use. The 1% formulation is primarily for dilated ophthalmic exams in newborns. The most widely used concentration is the 2.5% phenylephrine hydrochloride solution, which is used routinely for dilations in adults and children over three months of age. Finally, 10% is also available but used less commonly due to its potential systemic absorption.<sup>1</sup> Here's a look at the many ways you can use this ophthalmic drug in your practice:

### *Pharmacologic dilation.*

Phenylephrine acts on the alpha-1 receptors located on the iris dilator, which stimulates smooth muscle contraction and allows for pupillary dilation and funduscopy examination.<sup>3</sup> While the end result is pupillary dilation, phenylephrine

has little effect on accommodation. Instead, ciliary muscle contraction causes accommodation and yields a change in power within the crystalline lens. This is regulated via the parasympathetic, not the sympathetic, branch of the ANS.

Though there has been conflicting evidence in the literature, researchers generally believe phenylephrine administration does not interfere with parasympathetic activity; however, testing accommodation through a dilated pupil increases blur and reduces the depth of field, making it difficult to acquire accurate measurements.<sup>2</sup>

**Inflammation.** Phenylephrine causes sympathetic stimulation of blood vessels, leading to vasoconstriction.<sup>2</sup> In the ophthalmic setting, 0.12% phenylephrine is an ingredient in some over-the-counter eye drops that are marketed to alleviate red eyes through vasoconstriction.<sup>1</sup>

This function is also useful in determining the degree of ocular inflammation, specifically when distinguishing scleritis from episcleritis. Episcleritis is the inflam-



**Safer Distances. Greater Efficiencies.  
Increased Revenue.**

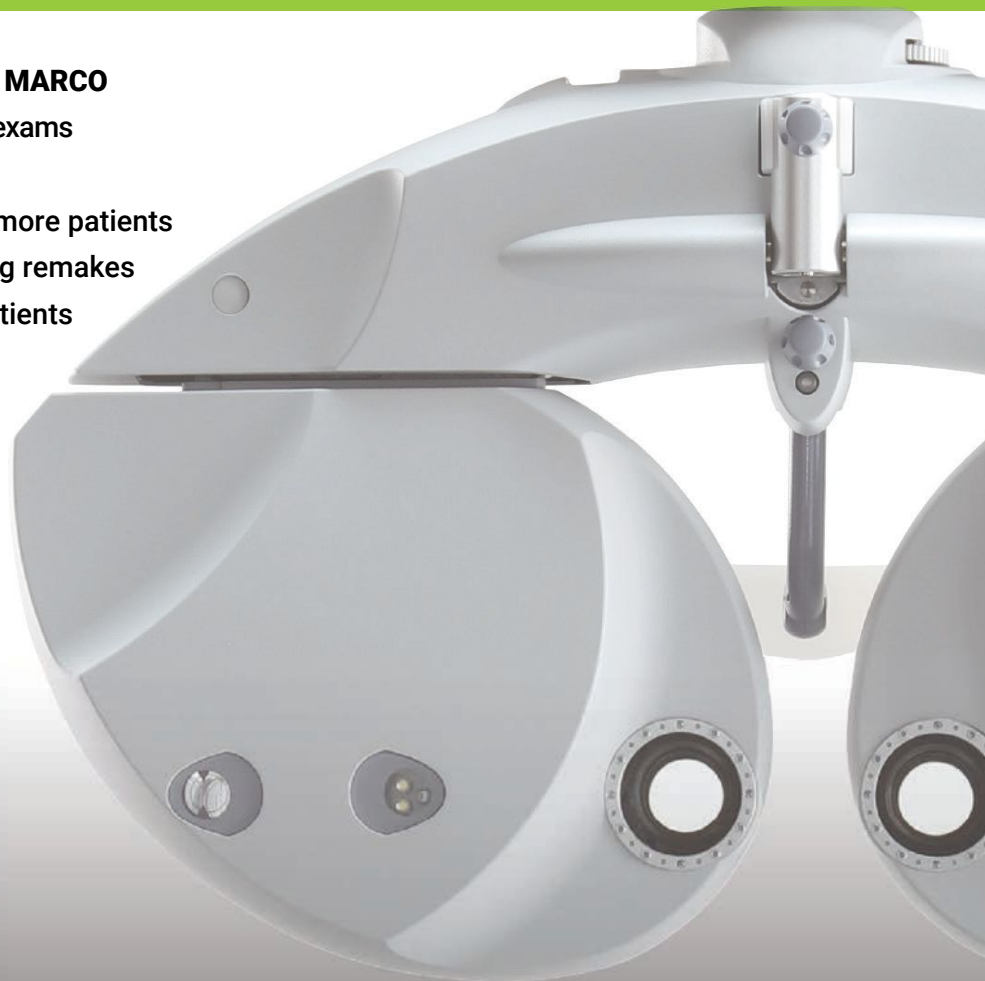


The 6100 Series digital refraction systems provide a functional solution to the challenges we are currently facing. Built for the ultimate in flexibility with unparalleled options, you can now perform refractions from anywhere!

**LET US SHOW YOU WHAT'S POSSIBLE. CONTACT MARCO FIRST.**

**EXPERIENCE THE DIFFERENCE WITH MARCO**

- Remote refraction for comprehensive exams from a safe social distance
- Reduce exam times so you can see more patients
- Maximize optical sales by minimizing remakes
- High-tech solutions to 'wow' your patients and increase referrals



mation of the episcleral vascular network, which causes activation of immune cells and inflammatory mediators that lead to vasodilation. Thus, application of 2.5% phenylephrine can be a useful tool to evaluate the depth of vascular inflammation. Approximately 10 to 15 minutes following instillation, the superficial blood vessels of the episclera will blanch, leaving an otherwise white and quiet eye. However, if scleritis is present, hyperemia will remain after phenylephrine instillation due to the lack of drug penetration to the deeper vessels of the sclera.<sup>4</sup>

**Uveitis.** In the management of anterior uveitis, phenylephrine has many benefits. Due to the mechanism resulting in dilation, the 10% concentration is often potent enough to aid in breaking recalcitrant posterior synechia.<sup>5</sup>

Since photophobia in these conditions is attributed to the pupillary response to light, phenylephrine's mydriatic properties will also help paralyze the pupil and mitigate pain. Researchers further suggest that phenylephrine acts on aqueous flow dynamics and vascular permeability of the uvea, yielding improvement in anterior chamber flare following instillation.<sup>6</sup>

**Ptosis.** Patients may present with ptosis for several reasons, and phenylephrine may help you weed through the differentials. The eyelid is innervated primarily through cranial nerve III and, to a lesser degree, the sympathetic muscle of Müller. Thus, the phenylephrine test can be helpful in the diagnosis and potential surgical outcome for patients with mild ptosis.

This test is performed by instilling 2.5% phenylephrine to the superior fornix and re-measuring the ptosis after 10 minutes. An improvement after phenylephrine

**Table 1. Ophthalmic Uses of Topical Phenylephrine**

Diagnostic	Therapeutic
<ul style="list-style-type: none"> <li>• Pharmacologic dilation for fundus exam</li> <li>• Distinguishing episcleritis vs. scleritis</li> <li>• Müller ptosis diagnosis and Müller muscle resection surgical outcome</li> </ul>	<ul style="list-style-type: none"> <li>• Breaking posterior synechia in uveitis</li> <li>• Reducing flare and pain in uveitis</li> <li>• Relieving "red eye"</li> </ul>

indicates a sympathetic etiology.<sup>7</sup> This test is an important indicator for successful Müller's muscle resection prior to surgical repair.<sup>8</sup>

**Retinal vasculature.** While phenylephrine has many anterior segment applications, topical ophthalmic application may also penetrate the posterior segment and affect the retinal vasculature.

Recent studies using OCT angiography have determined that the topically administered drug can diffuse through the ocular tissues and reach the retrobulbar region, activating its vasoconstrictive properties on the short posterior ciliary arteries and the central retinal artery. The result is a significant reduction in the peripapillary retinal vessel density. As such, clinicians should be cautious when using phenylephrine in patients who already have severe damage to their optic disc vasculature.<sup>9</sup>

## Stay on Alert

As with all pharmaceutical agents, phenylephrine is not free of side effects, even with topical administration. The most common reactions include nausea, vomiting and headache.<sup>1</sup> Systemically, it can increase blood pressure and heart rate and decrease oxygen saturation.<sup>10</sup> While these potentially devastating side effects are more common with intravenous use, they are possible with more potent concentrations of ophthalmic versions, such as the 10% form that runs the risk of systemic absorption.


Maximum plasma level of phenylephrine is reached approximately 20 minutes following topical application, at which time patients should be carefully assessed for any adverse reactions. To limit systemic absorption, clinicians can apply digital pressure over the lacrimal sac or eyelid closure to reduce absorption through the conjunctival blood vessels and nasolacrimal duct.<sup>11</sup>

While eye care practitioners come across phenylephrine on a daily basis for routine dilations, several other ophthalmic uses are within reach as well. Phenylephrine's unique mechanism provides many diagnostic and therapeutic capabilities, if used with caution. ■

1. Richards E, Lopez MJ, Maani CV. Phenylephrine. Treasure Island, FL: StatPearls Publishing; January 2020: 30521222.
2. Esteve-Taboada JJ, Del Aguila-Carrasco AJ, Bernal-Molina P, et al. Effect of phenylephrine on the accommodative system. *J Ophthalmol.* 2016;2016:7968918.
3. Liu JC, Green W, Van Stavem GP, Culican SM. Assessing the utility of 2.5% phenylephrine for diagnostic pupillary dilation. *Can J Ophthalmol.* 2017;52(4):349-54.
4. Schonberg S, Stokkermans TJ. Episcleritis. 2020 Aug 10. Treasure Island, FL: StatPearls Publishing; January 2020: 30521217.
5. Agrawal RV, Murthy S, Sangwan V, Biswas J. Current approach in diagnosis and management of anterior uveitis. *Indian J Ophthalmol.* 2010;58(1):11-9.
6. Zaczek A, Zetterström C. The effect of phenylephrine on pain and flare intensity in eyes with uveitis. *Acta Ophthalmol Scand.* 2000;78(5):516-8.
7. Koka K, Patel BC. Ptosis Correction. Treasure Island, FL: StatPearls Publishing; January 2020: 30969650.
8. Grace Lee N, Lin LW, Mehta S, Freitag SK. Response to phenylephrine testing in upper eyelids with ptosis. *Digit J Ophthalmol.* 2015;21(3):1-12.
9. Cheng J, Yu J, Jiang C, Sun X. Phenylephrine affects peripapillary retinal vasculature—an optic coherence tomography angiography study. *Front Physiol.* 2017 Dec;8:996.
10. Alpay A, Canturk Ugurbas S, Aydemir C. Efficiency and safety of phenylephrine and tropicamide used in premature retinopathy: a prospective observational study. *BMC Pediatr.* 2019;19(1):415.
11. Ahmed N, Riad W, Altorpaq A, Zahoor A. Ocular phenylephrine 2.5% continues to be dangerous. *BMJ Case Rep.* 2009;2009:bcr08.2008.0795.

TREAT OCULAR INFLAMMATION  
AND INFECTION, AND...

**TURN ON  
RELIEF**



**TobraDex<sup>®</sup> ST**  
(tobramycin/dexamethasone  
ophthalmic suspension)  
0.3%/0.05%  
FORMULATED WITH **XanGen<sup>™</sup>**

PRESCRIBE TOBRADEX<sup>®</sup> ST to control ocular inflammation with risk of bacterial infection



Rapid relief from blepharitis/  
blepharoconjunctivitis symptoms<sup>1,a</sup>



XanGen<sup>™</sup> suspension technology  
provides increased viscosity  
for improved ocular bioavailability  
of drug and consistent delivery<sup>2</sup>



TOBRADEX ST contains half the  
dexamethasone as TobraDex<sup>®</sup>,  
yet similar ocular tissue exposure<sup>2,b</sup>

Eligible patients could pay as little as \$45 for TOBRADEX ST  
LEARN MORE AT MYTOBRADEXST.COM

## Indications and Usage

For steroid responsive inflammatory ocular conditions of the palpebral and bulbar conjunctiva, cornea, and anterior segment of the globe and chronic anterior uveitis, corneal injury from chemical, radiation or thermal burns, or penetration of foreign bodies for which a corticosteroid is indicated and where the risk of superficial bacterial ocular infection is high or where there is an expectation that potentially dangerous numbers of bacteria will be present in the eye.

## Important Safety Information

### CONTRAINDICATIONS:

Most viral disease of the cornea and conjunctiva including epithelial herpes simplex keratitis (dendritic keratitis), vaccinia, and varicella, and also in mycobacterial infection of the eye and fungal disease of ocular structures. Hypersensitivity to any components of the medication.

### WARNINGS & PRECAUTIONS:

- **IOP increase** – Prolonged use may result in glaucoma with damage to the optic nerve, defects in visual acuity and fields of vision. IOP should be monitored.
- **Aminoglycoside sensitivity** – Sensitivity to topically applied aminoglycosides may occur.
- **Cataracts** – Posterior subcapsular cataract formation may occur.
- **Delayed healing** – May delay healing and increase the incidence of bleb formation. Perforations of the cornea or sclera have occurred. Slit lamp biomicroscopy, and fluorescein staining should be conducted.
- **Bacterial infections** – May suppress host response and increase secondary ocular infections. In acute purulent conditions, steroids may mask infection or enhance existing infection. If signs and symptoms fail to improve after 2 days, the patient should be re-evaluated.

- **Viral infections** – Use with history of herpes simplex requires great caution. The course and severity of many viral infections of the eye (including herpes simplex) may be exacerbated.
- **Fungal infections** – Fungal infections of the cornea may occur and should be considered in any persistent corneal ulceration.
- **Use with systemic aminoglycosides** – Total serum concentration of tobramycin should be monitored.

### ADVERSE REACTIONS:

The most frequent adverse reactions (<4%) to topical ocular tobramycin are hypersensitivity and localized ocular toxicity, including eye pain, eyelid pruritus, eyelid edema, and conjunctival hyperemia.

The reactions due to the steroid component are increased intraocular pressure with possible development of glaucoma, and infrequent optic nerve disorder; subcapsular cataract; and impaired healing.

The development of secondary infection has occurred. Fungal infections of the cornea may occur. Secondary bacterial ocular infection following suppression of host responses also occurs.

Non-ocular adverse events (0.5% to 1%) included headache and increased blood pressure.

**Please see Brief Summary of Full Prescribing Information on the adjacent page.**

<sup>a</sup>Randomized, investigator-masked, active-controlled, parallel-group trial conducted at 7 private practice clinical sites in the United States with 122 adult patients who had moderate to severe blepharitis/blepharoconjunctivitis.<sup>1</sup>

<sup>b</sup>Multicenter, double-blind, parallel-group, single-dose study of 987 patients receiving a single dose of TOBRADEX ST or TobraDex ophthalmic suspension.<sup>2</sup>

**References:** 1. Torkildsen GL, Cockrum P, Meier E, et al. *Curr Med Res Opin.* 2011;27(1):171-178. 2. Scoper SV, Kabat AG, Owen GR, et al. *Adv Ther.* 2008;25(2):77-88.



© 2020 Eyeveance Pharmaceuticals LLC. All rights reserved.  
TOBRADEX<sup>®</sup> ST and XanGen<sup>™</sup> are trademarks of Eyeveance Pharmaceuticals LLC.  
All other trademarks are the property of their respective owners. TST-01-20-AD-04

## **TOBRADEX® ST (tobramycin/dexamethasone ophthalmic suspension) 0.3%/0.05%**

### **Brief Summary**

**This Brief Summary does not include all the information needed to use TOBRADEX ST safely and effectively. Please see Full Prescribing Information for TOBRADEX ST at MyTobraDexST.com.**

### **INDICATIONS AND USAGE**

TOBRADEX ST is a topical antibiotic and corticosteroid combination for steroid-responsive inflammatory ocular conditions for which a corticosteroid is indicated and where superficial bacterial ocular infection or a risk of bacterial ocular infection exists.

Ocular steroids are indicated in inflammatory conditions of the palpebral and bulbar conjunctiva, cornea and anterior segment of the globe where the inherent risk of steroid use in certain infective conjunctivitis is accepted to obtain a diminution in edema and inflammation. They are also indicated in chronic anterior uveitis and corneal injury from chemical, radiation or thermal burns, or penetration of foreign bodies.

The use of a combination drug with an anti-infective component is indicated where the risk of superficial ocular infection is high or where there is an expectation that potentially dangerous numbers of bacteria will be present in the eye.

### **DOSAGE AND ADMINISTRATION**

**Recommended Dosing:** Instill one drop into the conjunctival sac(s) every four to six hours. During the initial 24 to 48 hours, dosage may be increased to one drop every 2 hours. Frequency should be decreased gradually as warranted by improvement in clinical signs. Care should be taken not to discontinue therapy prematurely.

### **CONTRAINDICATIONS**

**Nonbacterial Etiology:** TOBRADEX ST is contraindicated in most viral diseases of the cornea and conjunctiva including epithelial herpes simplex keratitis (dendritic keratitis), vaccinia, and varicella, and also in mycobacterial infection of the eye and fungal diseases of ocular structures.

**Hypersensitivity:** Hypersensitivity to any component of the medication.

### **WARNINGS AND PRECAUTIONS**

**IOP increase:** Prolonged use of corticosteroids may result in glaucoma with damage to the optic nerve, defects in visual acuity and fields of vision. IOP should be monitored.

**Aminoglycoside sensitivity:** Sensitivity to topically applied aminoglycosides may occur.

**Cataracts:** May result in posterior subcapsular cataract formation.

**Delayed healing:** May delay healing and increase the incidence of bleb formation after cataract surgery. In those diseases causing thinning of the cornea or sclera, perforations have been known to occur with the use of topical steroids.

**Bacterial infections:** May suppress the host response and thus increase the hazard of secondary ocular infections. In acute purulent conditions, steroids may mask infection or enhance existing infection. If signs and symptoms fail to improve after 2 days, the patient should be re-evaluated.

**Viral infections:** Treatment in patients with a history of herpes simplex requires great caution. Use of ocular steroids may prolong the course and may exacerbate the severity of many viral infections of the eye (including herpes simplex).

**Fungal infections:** Fungal infections of the cornea are particularly prone to develop with long-term use. Fungal invasion must be considered in any persistent corneal ulceration.

**Use with systemic aminoglycosides:** Use with systemic aminoglycoside antibiotics requires monitoring for total serum concentration of tobramycin.

### **ADVERSE REACTIONS**

The most frequent adverse reactions to topical ocular tobramycin (TOBREX®) are hypersensitivity and localized ocular toxicity, including eye pain, eyelids pruritis, eyelid edema, and conjunctival hyperemia. These reactions occur in less than 4% of patients. Similar reactions may occur with the topical use of other aminoglycoside antibiotics.

Non-ocular adverse events occurring at an incidence of 0.5% to 1% included headache and increased blood pressure.

The reactions due to the steroid component are: increased intraocular pressure (IOP) with possible development of glaucoma, and infrequent optic nerve disorder; subcapsular cataract; and impaired healing.

Secondary Infection.

The development of secondary infection has occurred. Fungal infections of the cornea are particularly prone to develop with long-term use. Fungal invasion must be considered in any persistent corneal ulceration. Secondary bacterial ocular infection following suppression of host responses also occurs.

### **USE IN SPECIFIC POPULATIONS**

#### **Pregnancy and Nursing Mothers**

There are no adequate and well controlled studies in pregnant women. TOBRADEX® ST ophthalmic suspension should be used during pregnancy only if the potential benefit justifies the potential risk to the fetus. Caution should be exercised when TOBRADEX® ST is administered to a nursing woman.

**Pediatric Use:** Safety and effectiveness in pediatric patients below the age of 2 years have not been established.

**Geriatric Use:** No overall differences in safety or effectiveness have been observed between elderly and younger patients.

#### **Rx Only**

**Distributed by:** Eyevance Pharmaceuticals LLC.  
Fort Worth, TX 76102







# New Codes: A Waiting Game

Carriers may not pay yet, but Category III codes are crucial, particularly for a number of new ocular surface procedures. **By John Rumpakis, OD, MBA, Clinical Coding Editor**

As wonderful as new technology can be for our patients and practice, it's often frustrating when a new procedure doesn't come to market with reimbursement from third-party insurances. That doesn't mean we shouldn't embrace new technology. On the contrary, with careful coding—and a good dose of patience—we can help new technologies mature into full CPT-coded options.

## The Path to Coverage and Reimbursement

When new innovation is brought to market, the owners of that technology have to decide whether or not they want to pursue a formal code that allows health care providers to submit for insurance reimbursement. This path begins with the application for a Category III code. The following criteria are used by the CPT/HCPAC Advisory Committee and the CPT Editorial Panel for evaluating Category III code applications:<sup>1</sup>

- The procedure or service is currently or recently performed in humans and at least one of these additional criteria has been met:
  - (1) The application is supported by at least one CPT or HCPAC advisor representing practitioners who would use this procedure or service.
  - (2) The actual or potential clinical efficacy of the specific procedure or service in question is supported by

peer-reviewed literature that is available in English for examination by the CPT Editorial Panel.

(3) There is an Institutional Review Board–approved protocol of a study of the procedure or service being performed; a description of a current and ongoing United States trial outlining the efficacy of the procedure or service; or other evidence of evolving clinical use.

Category III codes generally have no coverage or reimbursement by third party carriers; instead, they are created to track the use of emerging technologies, services and procedures. They generally have five years of use before they move to a Category I, or CPT, code.

Although coverage and payment for performing a Category III–coded procedure is not common when the code is initially released, physicians are required to use the most appropriate code to describe the service provided. Thus, reporting a Category III code for a service accurately described by the code is appropriate. In fact, the correct reporting of a Category III service is essential to that code moving up to a CPT code, as carriers track use of Category III codes.

## Ocular Surface Tech

As an example, let's look at two Category III codes recently established for evaluation and treatment of the ocular surface:

**0507T: Near-infrared dual imaging (i.e., simultaneous reflective and trans-illuminated light) of meibomian glands, unilateral or bilateral,**

*with interpretation and report.*<sup>2</sup>

This was changed in July of 2018 to specifically define meibography and separate it from anterior segment photography. This is generally considered a patient-pay code and will “sunset” or expire in 2024 (five years past the official listing in the CPT of January 2019).

**0563T: Evacuation of meibomian glands using heat delivered through wearable, open-eyelid treatment devices and manual gland expression, bilateral.**<sup>2</sup>

This code is specific to the TearCare device (Sight Sciences), materials and procedure. It was first included in the CPT reference in January 2020 and will sunset in 2025. When performing meibomian gland expression with the TearCare device, you must use this code and submit to the carrier, even though you know it will likely be denied. The patient should pay the day of the procedure in accordance with a properly adjudicated ABN form.

New technology will continue to come to market, and not all of it will be covered by third-party insurance. For companies that want coverage and reimbursement, it all starts with a Category III code. Understanding the importance of these codes is critical to both the compliance and financial health of your practice. ■

Send your coding questions to [rocodingconnection@gmail.com](mailto:rocodingconnection@gmail.com).

1. American Medical Association. Criteria for CPT Category I and Category III codes. [www.ama-assn.org/practice-management/cpt/criteria-cpt-category-i-and-category-iii-codes](http://www.ama-assn.org/practice-management/cpt/criteria-cpt-category-i-and-category-iii-codes). Accessed October 1, 2020.  
2. [www.CodeSAFEPLUS.com](http://www.CodeSAFEPLUS.com). Accessed October 1, 2020.



To learn more about code categories, visit [www.reviewofoptometry.com](http://www.reviewofoptometry.com), or scan the QR code.

# MOST.

The contact lens with the **most moisture** among leading brands.

# MORE.

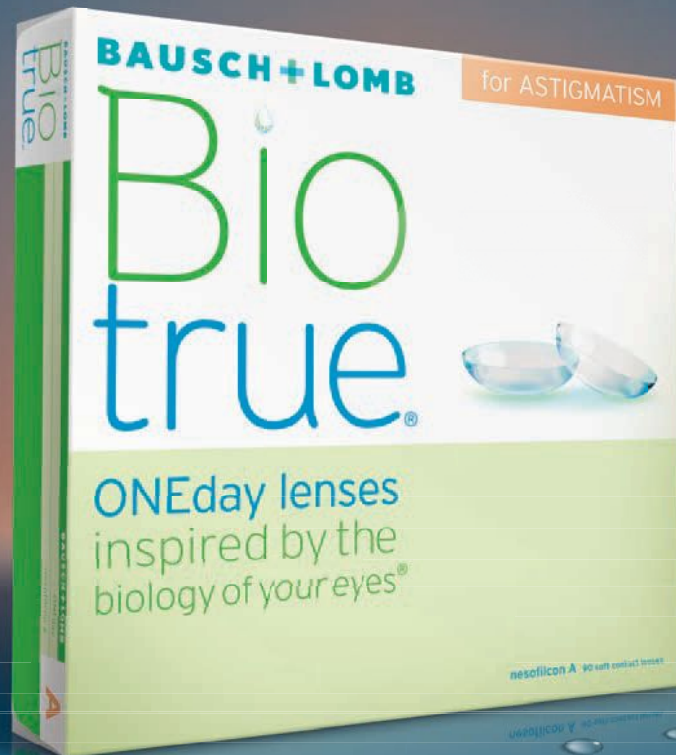
The toric daily disposable with **more parameters** than any other.

# ONLY.

Now, the **first and only** daily disposable with **-2.75 Cylinder** available as a standard offering.

# -2.75 CYLINDER

DAILY DISPOSABLE IS NOW AVAILABLE



Fit the first and only daily disposable with a -2.75 Cylinder offering—Biotrue® ONEday for Astigmatism.



**Most moisture** and **toric parameters** among leading daily disposables



**Helps reduce halos and glare**, even in low light<sup>1</sup>



**Fast to fit with excellent centration** at dispensing and follow-up<sup>2</sup>

Now available as a **standard offering** for **same-day fitting**.

**REFERENCES:** **1.** Results of an online survey with patients who completed an evaluation program for Biotrue® ONEday for Astigmatism contact lenses and wore their trial lenses for  $\geq 4$  days (n=1001). **2.** Results from a 7-investigator, multi-site study of Biotrue® ONEday for Astigmatism contact lenses on 123 current non-daily disposable toric soft contact lens wearers. Lenses were worn on a daily wear basis for 1 week.

®/™ are trademarks of Bausch & Lomb Incorporated or its affiliates.  
©2020 Bausch & Lomb Incorporated or its affiliates. BFA.0051.USA.20

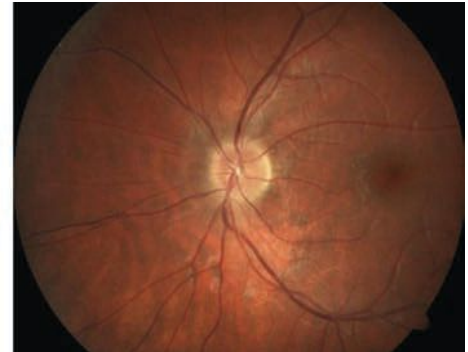
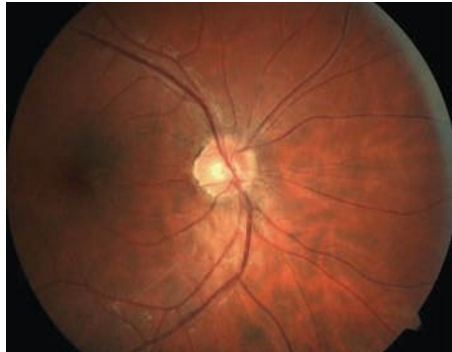**BAUSCH + LOMB**  
See better. Live better.

# CNS Disease: In the Eye and in Your Chair

These systemic conditions are on the rise, and new research suggests we can catch early signs with an eye exam. Here's what you need to know.

By Christopher L. Suhr, OD, MPH, and Saurin Patel, OD

**A**s optometrists, we see patients of all walks of life and with many different conditions. Although patients usually present for specific visual and ocular issues, some may present with non-specific and vague concerns not directly linked with a refractive condition; rather, they are secondary to a neurological systemic issue. Because the eye is derived from neuroectoderm and is an extension of the central nervous system (CNS), many conditions, such as Parkinson's, Alzheimer's and multiple sclerosis (MS), can have early—even pre-clinical—ocular signs. New research is beginning to build a case for early detection, even from the optometrist's chair. Here, we discuss these three common neurological conditions and the ocular manifestations that may present during an exam.



**Patients with MS may present with retinal findings such as irregular or indistinct optic nerve margins.**

## An Eye on Diagnostics

Discovering neurodegenerative disorders early can be a challenge, given the expensive and relatively unreliable diagnostic tests it requires. Moreover, no noninvasive measures exist to accurately diagnose preclinical neurodegenerative conditions. Traditionally, a functional magnetic resonance imaging (fMRI) is required to properly identify early disease.<sup>1</sup>

However, evidence now suggests

that ocular technologies can help, given that the cerebral cortex and retina share many features, including anatomical structure, vascular supply and the blood/tissue barrier. Technologies such as optical coherence tomography (OCT), blue light autofluorescence and scanning laser ophthalmoscopy are showing promise in detecting many early neurological diseases.<sup>2</sup> The added benefit is that these are noninvasive and cost-effective tools.

## Parkinson's Disease

A hallmark of this condition, reduced dopamine production, can cause significant complications in the eye. Patients with Parkinson's disease may experience reduced contrast sensitivity, for example, and researchers speculate that the lateral inhibition of dopamine in the retina is to blame, ultimately resulting in the global loss of dopamine receptors.<sup>3</sup> This leads to visual hallucinations that, with the right patient/caregiver questions, might come up during an ocular exam.<sup>4</sup>

Recent studies found other local metabolic and histopathologic changes in the primary visual cortex in patients that have early Parkinson's disease as well, leading to visual dysfunction, pupil abnormality, lens opacity and retinal neuronal loss and dysfunction.<sup>1,5</sup>

One of the most clinically relevant findings in early Parkinson's disease, from an ocular standpoint, is retinal thinning. Researchers first used OCT to find circumpapillary retinal nerve fiber layer (RNFL) thinning in Parkinson's patients in 2004, noting that 70% of Parkinson's patients in the study had an inferotemporal RNFL thickness less than 153µm, while all control mea-

surements were above this threshold.<sup>6</sup> A 2018 study pinpointed retinal thinning to the temporal and inferior 2.22mm sectors and found patients with the thinnest retinas also had the severest disease.<sup>7</sup> Since then, research has shown that Parkinson's disease may be identified early by a thin macular ganglion cell-inner plexiform (GC-IPL) complex on OCT, especially in the parafoveal region.<sup>2,4,9-11</sup>

OCT-angiography (OCT-A) is another promising imaging tool that can measure retinal capillary complexes—a decrease of which has been linked to oxidative stress observed in the Parkinson's disease process.<sup>2,11,12,13-15</sup> *In vivo*, OCT-A analyzes both the retina and chorioidal microvasculature by high speed B-scans. It plots high, slow or no flow zones that indicate areas of abnormal blood flow, possibly confirming decreased retinal microvascular density observed in Parkinson's patients.<sup>16</sup> For example, both the lower retinal capillary quantity and the lower densities of these vascular complexes may be objective biomarkers for Parkinson's disease.<sup>2,11-14</sup>

Several other ocular findings have been implicated in Parkinson's

## Tears Tell the Story

A series of studies evaluated possible CNS disease biomarkers in tears and the ocular surface. The researchers found a decrease in expression of amyloid precursor protein as well as beta amyloid protein degradation in corneal fibroblasts in Alzheimer's patients. Parkinson's patients showed a decrease in blink rate, a decrease in corneal sensitivity, increased expression of specific tear proteins and, ultimately, ocular surface disease.<sup>1</sup>

Another study found that tear levels of alpha-synuclein may be able to discriminate between patients with Parkinson's disease and healthy controls, noting that reflex tear alpha-synuclein levels demonstrated a greater increase and sensitivity in distinguishing Parkinson's patients from healthy controls than basal tears.<sup>2</sup> In addition, differences in lactoferrin of reflex tears, not seen in basal tears, may offer a more reliable and sensitive source of biomarkers for Parkinson's disease.<sup>2</sup>

1. Roda M, Ciavarella C, Giannaccare G, Versura P. Biomarkers in tears and ocular surface: A window for neurodegenerative diseases. *Eye Contact Lens*. 2020;46(Suppl 2):S129-34.

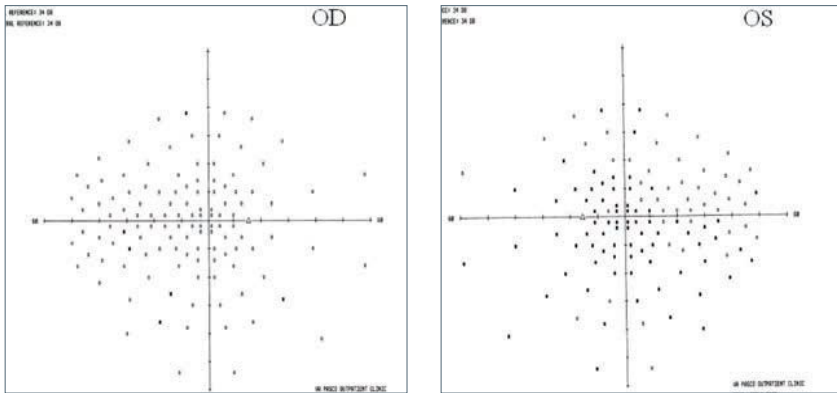
2. 41. Edman MC, Janga SR, Freire D, et al. Tear biomarkers for Parkinson's disease in basal versus reflex tears. *Invest Ophthalmol Vis Sci*. 2019;60:4196.

# Optimize space and functionality.



## Affordable, space-saving chair & stand solutions.

Small footprint  
41.2" x 34.2"



**In MS, visual fields may show areas that aren't as clear as others.**

disease, including abnormal electroretinogram responses and reduced motion perception in patients with mild cognitive disorders.<sup>17</sup>

In addition, patients with Parkinson's show an increase in alpha-synuclein in both the axons and dendrites of ganglion cells, resembling that of Lewy bodies in the brain, even before clinical signs of disease are noted.<sup>17</sup> Early animal models show retinal imaging can measure expression of this protein, suggesting its clinical utility in tracking the disease.<sup>18</sup>

Another protein, the GPR109A

receptor, is upregulated in Parkinson's and can be found in the retinal pigment epithelium.<sup>19</sup> Because GPR109A has a high affinity for niacin, which is necessary for dopamine production, researchers speculate that niacin supplementation can provide a potential treatment option for Parkinson's disease.<sup>19</sup>

### Alzheimer's Disease

Researchers have identified several possible biomarkers in Alzheimer's disease, including a significant increase in amyloid plaque deposits in the retina. In addition, investiga-

tors consider an increase in drusen a precursor to Alzheimer's disease. Another biomarker is *tau*, and an abnormal phosphorylated *tau* accumulates in the ganglion cell layer in this disease process.<sup>20-23</sup> On imaging, researchers found significantly diminished *tau* protein at the retinal ganglion cell layer at the optic nerve.

An increase in these biomarkers increases local inflammation and ultimately disrupts the function of the retinal ganglion cells.<sup>24</sup>

Although these early retinal findings occur in mild Alzheimer's disease, they are hard to detect prior to the mild cognitive decline with current noninvasive technology.

Beyond biomarkers, studies have identified marked ocular changes in Alzheimer's patients, including decreased RNFL thickness and volume, retinal ganglion cell degeneration and reduced retinal blood flow associated with vascular changes observed on OCT. Specifically, only the outer photoreceptor layer shows statistically significant thinning in early Alzheimer's patients.<sup>25</sup>

Vascular findings, observed by OCT-A, include enlarged foveal avascular zone, reduced vessel branching, tortuosity and density, increased retinopathy, reduced blood flow, pulsatility, pulse pressure and choroidal changes. Researchers note that the choroid is the thinnest nasally to the macula and thickest temporally to the macula and within the macula.<sup>26-29</sup> Clinicians should keep Alzheimer's in mind when evaluating patients for glaucoma, the GC-IPL complex specifically is atrophied in early Alzheimer's disease, possibly confounding the diagnosis.<sup>26-29</sup>

### A Mixed Bag

There are many overlapping ocular findings between various neurodegenerative conditions and even

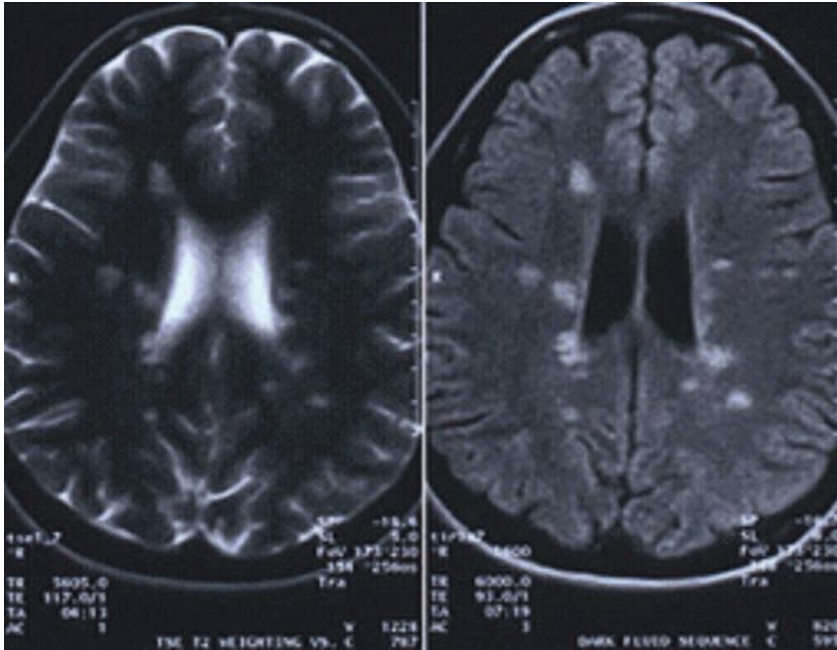
### The Many Phases of MS

Also called disseminating sclerosis, MS has myriad variations, all of which have the similar signs of demyelination that occur in a waxing and waning manner. A patient often has an initial bout where inflammation and demyelination first occur. This is called the clinically isolated syndrome (CIS), which is considered a precursor to the eventual diagnosis of MS.<sup>34,36</sup>

The most common variation of MS is called relapsing-remitting (RRMS). This is commonly noted to have episodes where the disease process activates and is followed by a remission of the inflammation and symptoms. These activations, or relapses, can result in a near complete return to normalcy. At times, however, the recovery may not result in a return to baseline; rather, the patient has an incomplete recovery. From this new level there can be further relapses and remissions that continue to demyelinate and damage the CNS. This is the hallmark of progression with this variation. RRMS is responsible for nearly 85% of MS cases.<sup>36</sup>

There are also two types that are labeled as progressive: primary and secondary. Primary progressive is characterized by progression that does not have remissions that return to a level close to baseline. Though it may have instances of remission, these instances result with stability rather than regression.

Secondary progressive (SPMS) is often preceded by a designation of RRMS. This is because there is an initial phase similar to the step gradation noted in RRMS. However, there is a more continual and gradual increase in degradation from the disease in SPMS, whereby the trend continues to worsen with less improvement.

**COMBO**COMBINE WITH OUR  
UNIQUE STAND

**This MRI with and without contrast is positive for MS, showing a lesion located around the ventricles and juxtacortical and in the temporal lobe.**

other ocular conditions, further complicating accurate diagnosis of a specific disease entity. For example, the saccade velocities and accuracy decrease in patients with motor dysfunction secondary to Parkinson's, Alzheimer's and other neurodegenerative conditions, leading to significant overshoot or undershoot.<sup>21</sup> The activation of microglia causes an increase in inflammatory cytokines and, ultimately, impaired brain and retinal function as seen with both Parkinson's and Alzheimer's patients.<sup>30</sup>

Thus, while a promising diagnostic finding, GC-IPL thinning on OCT cannot help clinicians differentiate between the many possible etiologies.<sup>2,8-13</sup>

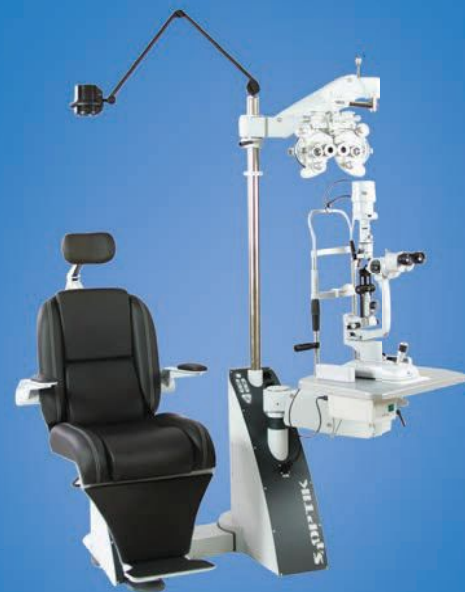Despite the growing body of literature supporting the role of the eye in these CNS diseases, Parkinson's disease and Alzheimer's disease remain in neurology's domain, and clinicians who suspect either of them should refer patients appropriately.

**MS: A Clinical Perspective**

Unlike Parkinson's and Alzheimer's, MS is a condition that optometrists may help to diagnose in their chair. The condition has myriad ocular findings that are precursors to the disease and are often the first symptoms (see, "*The Many Phases of MS*").

In our clinical experience, the main ocular symptoms are color vision abnormalities, blurred vision and general asthenopia.<sup>31</sup> During confrontation fields, clinicians may note areas that are not as clear as others in the field and even some loss of visual field due to demyelinating lesions along the visual pathway.<sup>32</sup> Extraocular motilities are typically normal in early MS, though there can be jerky movements noted later in the disease process. Nystagmus may also be present.

It is not typical to have full restriction in MS. Pupils may also be atypical. In instances of advanced disease with multiple episodes of optic neuritis, an afferent pupillary defect

**Effortless  
instrument  
positioning****Advanced  
ergonomics**

(APD) is likely, as over time, optic neuropathy develops. In early cases, an APD may also be present, though often the pupils may show an APD in one instance but appear normal immediately after.

Color vision testing may also reveal deficits, often with one eye more affected than the other.<sup>31</sup> However, retinal or media issues, such as asymmetric cataracts, may cause false positives. The density loss is due to changes of the optic nerve and includes optic neuritis and, ultimately, optic neuropathy.

If after preliminary testing the clinician notes irregular findings, the dilated exam should focus on the optic nerve to assess for irregular or indistinct optic nerve margins, whether 360° or sectoral, which is due to inflammation to the optic nerve. Active cases of unilateral optic neuritis should have MS at the top of the differential diagnosis list, particularly if the patient is in a higher-risk demographic, which includes patients who are between 20 and 40 years of age, female and of Northern European descent.<sup>33</sup> If optic neuritis is the suspected diagnosis, consider further consultation with neurology.

Although MS is diagnosed with the patient's symptomatology, an MRI and gadolinium contrast media is beneficial (unless contraindicated). A positive MRI would show a classic lesion presentation located around the ventricles and juxtacortical and in the temporal lobe.<sup>34,35</sup> These lesions are pathognomonic for MS.

## Clinical Takeaways

Detecting and managing these neurodegenerative conditions requires a multidisciplinary approach. The recently discovered retinal biomarkers, while promising, are not specific for a definitive neurodegenerative condition. Further study and longitudinal research will hopefully

validate a connection with various neurodegenerative conditions.

Until then, optometrists can keep a close eye on the literature and be ready to recognize the possible early signs of CNS disease manifesting in the eye. As the population's age increases, so does neurodegenerative disease, and optometrists need to stay vigilant to catch it prior to any cognitive decline. ■

*Dr. Suhr is the chief of optometry at the Philadelphia Corporal Michael J. Crescenz VA Medical Center. He is a fellow of the Optometric Retina Society and the American Academy of Optometry. His clinical focus is primarily on retinal disease, glaucoma, neuro-ophthalmic disease and oculosystemic disease.*

*Dr. Patel is a staff optometrist at the Philadelphia Corporal Michael J. Crescenz VA Medical Center. He is a fellow of the American Academy of Optometry. His main clinical focus is primarily on glaucoma, and he has a deep interest in neuro-ophthalmic disease.*

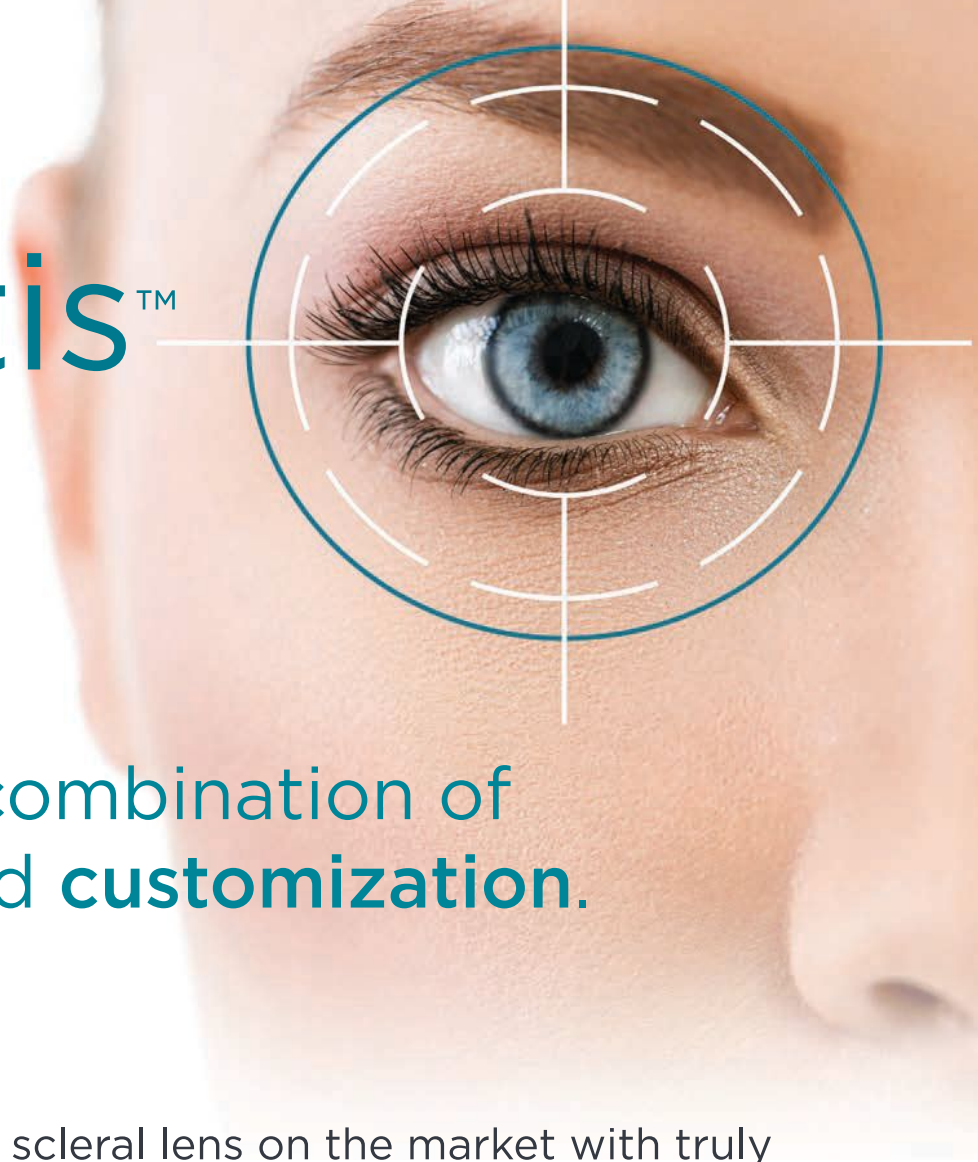- Moro, E, Bellot E, Meoni S, et al. Visual dysfunction of the superior colliculus in de novo parkinsonian patients. *Ann Neurol*. 2020;87(4):533-46.
- Chrysou A, Jansoniuss NM, van Laar T. Retinal layers in Parkinson's disease: A meta-analysis of spectral-domain optical coherence tomography studies. *Parkinsonism Relat Disord*. 2019;64:40-49.
- Whitfield WH, Barr GO, Khayata MJ, et al. Contrast sensitivity visual acuity in REM sleep behavior disorder: a comparison with and without Parkinson disease. *J Clin Sleep Med*. 2020;16(3):385-88.
- Kurita A, Koshikawa H, Akiba T, et al. Visual hallucinations and impaired conscious visual perception in Parkinson disease. *J Geriatr Psychiatry Neurol*. 2019 December 6;891988719892318.
- Guo L, Normando EM, Shah PA, et al. Oculo-visual abnormalities in Parkinson's disease: Possible value as biomarkers. *Mov Disord*. 2018;33(9):1390-1406.
- Inzelberg R, Ramirez JA, Nisipeanu P, Ophir A. Retinal nerve fiber layer thinning in Parkinson disease. *Vision Research*. 2004;44(24):2793-7.
- Ahn J, Lee JY, Kim TW, et al. Retinal thinning associates with nigral dopaminergic loss in de novo Parkinson disease. *Neurology*. 2018;91(11):e1003-12.
- Lee JY, Ahn J, Oh S, et al. Retina thickness as a marker of neurodegeneration in prodromal lewy body disease. *Mov Disord*. 2020;35(2):349-54.
- Tugcu B, Melikov A, Yildiz GB, et al. Evaluation of retinal alterations in Parkinson disease and tremor diseases. *Acta Neurologica Belgica*. 2020;120(1):107-13.
- Wong BM, Cheng RW, Mandelcorn ED, et al. Validation of optical coherence tomography retinal segmentation in neurodegenerative disease. *Tran Vis Sci Technol*. 2019;8(5):6.
- Murueta-Goyena A, Del Pino R, Reyero P, et al. Parafoveal thinning of inner retina is associated with visual dysfunction in

- Lewy body diseases. *Mov Disord*. 2019;34(9):1315-24.
- Mailankody P, Lenka A, Pal PK. The role of optical coherence tomography in parkinsonism: a critical review. *J Neurol Sci*. 2019;403:67-74.
- Esquiva G, Hannibal J. Melanopsin-expressing retinal ganglion cells in aging and disease. *Histol Histopathol*. 2019;34(12):1299-1311.
- Shi C, Chen Y, Kwapong WR, et al. Characterization by fractional dimension analysis of the retinal capillary network in parkinson disease. *Retina*. 2020;40(8):1483-91.
- Martin-Nieto J, Uribe ML, Esteve-Rudd J, et al. A role for DJ-1 against oxidative stress in the mammalian retina. *Neurosci Letters*. 2019;708:134361.
- Kwapong WR, Ye H, Peng C, et al. Retinal microvascular impairment in the early stages of Parkinson's disease. *Invest Ophthalmol Vis Sci*. 2018;59(10):4115.
- Ortuño-Lizarán I, Beach TG, Serrano GE, et al. Phosphorylated  $\alpha$ -synuclein in the retina is a biomarker of Parkinson's disease pathology severity. *Mov Disord*. 2018;33(8):1315-24.
- Price DL, Koike MA, Khan A, et al. The small molecule alpha-synuclein misfolding inhibitor, NPT200-11, produces multiple benefits in an animal model of Parkinson's disease. *Sci Rep*. 2018;8(1):16165.
- Wakade C, Chong R. A novel treatment target for Parkinson's disease. *J Neurol Sci*. 2014;347(1-2):34-38.
- Kile S, Au W, Parise C, et al. Reduction of amyloid in the brain and retina after treatment with IVIG for mild cognitive impairment. *Am J Alzheimers Dis Other Dement*. 2020;35:1533317519899800.
- Benvenuto A, Guedj E, Felician O, et al. Clinical phenotypes in corticobasal syndrome with or without amyloidosis biomarkers. *J Alzheimers Dis*. 2020;74(1):331-43.
- Papadopoulos Z. Neovascular age-related macular degeneration and its association with Alzheimer's disease. *Curr Aging Sci*. January 29, 2020. [Epub ahead of print].
- Chintapaludi SR, Uyar A, Jackson HM, et al. Staging Alzheimer's disease in the brain and retina of B6.APP/PS1 mice by transcriptional profiling. *J Alzheimers Dis*. 2020;73(4):1421-34.
- Hart NJ, Koronyo Y, Black KL, Koronyo-Hamaoui M. Ocular indicators of Alzheimer's: exploring disease in the retina. *Acta Neuropathologica*. 2016;132(6):767-87.
- Jáñez-Escalada L, Jáñez-García L, Salobrar-García E, et al. Spatial analysis of thickness changes in ten retinal layers of Alzheimer's disease patients based on optical coherence tomography. *Sci Rep*. 2019;9(1):13000.
- Alber J, Goldfarb D, Thompson LJ, et al. Developing retinal biomarkers for the earliest stages of Alzheimer's disease: What we know, what we don't, and how to move forward. *Alzheimers Dementia*. 2020;16(1):229-43.
- Asanad S, Ross-Cisneros FN, Barron E, et al. The retinal choroid as an oculo-vascular biomarker for Alzheimer's dementia: A histopathological study in severe disease. *Alzheimers Dementia*. 2019;11:775-83.
- Almeida ALM, Pires LA, Figueiredo EA, et al. Correlation between cognitive impairment and retinal neural loss assessed by swept-source optical coherence tomography in patients with mild cognitive impairment. *Alzheimers Dementia*. 2019;11:659-69.
- Chiquita S, Campos EJ, Castelhan J, et al. Retinal thinning of inner sub-layers is associated with cortical atrophy in a mouse model of Alzheimer's disease: a longitudinal multimodal in vivo study. *Alzheimers Res Thera*. 2019;11(1):90.
- Ramirez AI, de Hoz R, Salobrar-García E, et al. The role of microglia in retinal neurodegeneration: Alzheimer's disease, Parkinson, and Glaucoma. *Front Aging Neurosci*. 2017;9:214.
- Piro A, Tagarelli A, Nicoletti G, et al. Impairment of acquired color vision in multiple sclerosis: an early diagnostic sign linked to the greatness of disease. *Int Ophthalmol*. 2019;39(3):671-76.
- Costello F. Vision disturbances in multiple sclerosis. *Semin Neurol*. 2016;36(2):185-95.
- Kamm CP, Uitdehaag BM, Polman CH. Multiple sclerosis: current knowledge and future outlook. *Eur Neurol*. 2014;72(3-4):132-41.
- The Radiology Assistant: Multiple Sclerosis. <https://radiologyassistant.nl/neuroradiology/multiple-sclerosis>. May 13, 2013. Accessed September 16, 2020.
- Wilson JA, Islam O. Brain imaging in multiple sclerosis: practice essentials, computed tomography, magnetic resonance imaging. <https://emedicine.medscape.com/article/342254-overview>. March 27, 2019. Accessed September 16, 2020.
- Ruiz F, Vigne S, Pot C. Resolution of inflammation during multiple sclerosis. *Semin Immunopathol*. 2019;41(6):711-26.



# Atlantis™

SCLERAL



The perfect combination of **simplicity** and **customization**.

The easiest to fit scleral lens on the market with truly customizable independent zone design options for any corneal SAG or scleral shape.

- Independent central SAG adjustments
- Quadrant specific scleral zone
- Quadrant specific limbal zone
- 14.0 and 14.5 diameters for normal corneas

**Deepest discounts available on all fitting sets right now! Call today!**



**X-CEL**

SPECIALTY CONTACTS

Recommended in:

**OPTIMUM**  
**INFINITE**

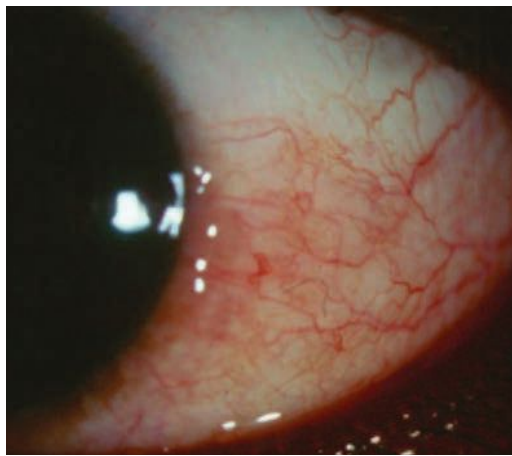[xcelspecialtycontacts.com](http://xcelspecialtycontacts.com) | 800.241.9312 | [xcelfinfo@xcelspecialtycontacts.com](mailto:xcelfinfo@xcelspecialtycontacts.com)

# Red Eye Remedies: New and Tried-and-True

Eye care providers already have a robust arsenal to help their patients combat this common ocular complaint. Here are the latest additions.

By Julie A. Tyler, OD, and Beata I. Lewandowska, OD, MS

**R**ed eyes are one of the most common ocular complaints, whether occasional or chronic. After all, studies show that individuals with eye redness appear less happy, healthy and attractive than those with a whiter sclera.<sup>1</sup> While the treatment for ocular redness should target the etiology of hyperemia, in the absence of obvious pathology clinicians can consider prescribing topical vasoconstrictors and supportive measures.



**Sectoral hyperemia such as this may be difficult to appreciate if the patient is using OTC Lumify.**

## Behind the Scenes

The conjunctiva and anterior episclera are nourished by blood vessels from the anterior and long posterior ciliary arteries, which stem from the ophthalmic artery. Redness, one of the five cardinal signs of inflammation, comes from vasodilation. The increased blood vessel diameters in response to tissue insult can lead to increased blood flow and leakage

through the opened capillary sphincters. This results in edema, another sign of inflammation, increased inflammatory cells and mediators and, potentially, tissue damage.

In addition to tissue insult, an array of other factors, such as hypoxia and the presence of vasoactive amines, induce endothelial cell spreading, flattening and leakage

through the capillary walls, causing vasodilation.

The quality of ocular redness is variable depending on the layer affected (conjunctiva, episclera, sclera or ciliary body) and the hue and pattern of hyperemia (circumlimbal, sectoral or diffuse), which may help differentiate between diagnoses and determine appropriate treatment options.

## Contemporary Solutions

In the last three years, the FDA has approved a host of medications that can address red eyes,

depending on the etiology:

**Dry eye.** In 2018, the FDA approved **Cequa** (0.09% cyclosporine A ophthalmic solution, Sun Pharma).<sup>2</sup> This adds to the arsenal of prescription dry eye therapies that includes the well-established **Restasis** (0.05% cyclosporine A ophthalmic emulsion, Allergan) and **Xiidra** (5% lifitegrast ophthalmic

solution, Novartis). A calcineurin inhibitor immunosuppressant, Cequa is indicated twice daily to increase tear production in adult patients with dry eye. The formulation uses nanomicelles to improve the penetration to ocular tissues.

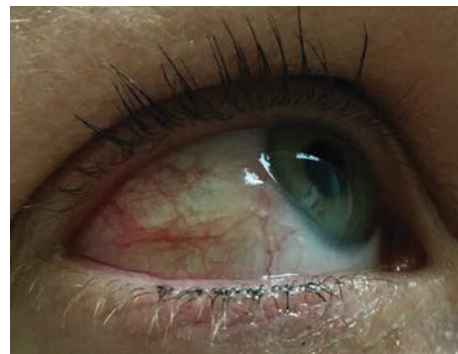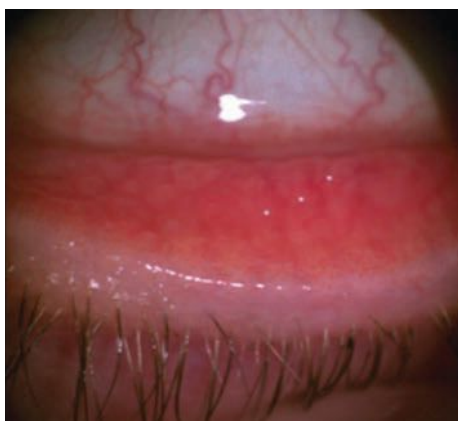Nanomicelles are ultra-microscopic structures made of exterior hydrophilic polar heads and an interior hydrophobic fatty chain.<sup>3</sup>

The outer layer allows the cyclosporine-carrying nanomicelle to move through the tear film and deliver the drug to the ocular surface.

While designed to treat dry eye, it can also reduce ocular surface irritation and redness.<sup>4,5</sup> Ironically, the most common adverse reactions are pain and conjunctival hyperemia upon instillation; therefore Cequa is not recommended for immediate redness relief. Cequa is available in a box of 60 sterile, preservative-free, single-use vials.

**Eysuvis** (loteprednol etabonate ophthalmic suspension 0.25%, Kala Pharmaceuticals) gained FDA approval in October 2020 for the short-term (two weeks) treatment of the signs and symptoms of dry eye. The Phase II and Phase III trials showed the treatment led to statistically significant improvements in conjunctival hyperemia and ocular discomfort severity. The company plans to launch the product by the end of 2020.<sup>6</sup>

Alcon's OTC **Systane Complete** contains propylene glycol 0.6% and is preserved with Polyquad (polidronium chloride 0.001%).<sup>7</sup> It is formulated with nano-droplet technology designed to disperse the active ingredient across the surface and stabilize the tear film. Propylene glycol can hold up to three times its own weight in water, increase



**Allergic conjunctivitis can present with bulbar and palpebral conjunctival hyperemia.**

the viscosity of solutions and form a protective layer over mucous membranes, which may lead to the reduction of ocular redness. **Systane Complete** is designed to provide relief for patients suffering from any type of dry eye. It is supplied in a sterile 10mL bottle.

**Refresh Relieva** (Allergan), an OTC eye drop available since 2018, contains 0.5% carboxymethylcellulose, 0.9% glycerin and a glycerin-based solution called **HydroCell**.<sup>8</sup> The drop may provide temporary relief of ocular irritation and burning, thereby decreasing some redness. Aqueous formulations of carboxymethylcellulose are known to reduce the production of inflammatory biomarkers.<sup>9</sup> In addition, research shows formulations of carboxymethylcellulose with glycerin can relieve symptoms of dry eye in seven days and improve tear break-up time and corneal and conjunctival staining when used at least twice daily.<sup>10</sup> The most common adverse side effect is temporary blurry vision. **Refresh Relieva** and **Refresh Relieva PF** are supplied in sterile 10mL bottles. **Refresh Relieva for Contacts** is supplied in a sterile 8mL bottle.

**Allergic conjunctivitis.** In 2017, the FDA approved **Zerviate** (0.24% cetirizine ophthalmic solution, Eyeavance Pharmaceuticals) as a prescription BID drop for the treatment

of ocular itching associated with allergic conjunctivitis in patients older than age two.<sup>11</sup>

Cetirizine, the active ingredient in **Zyrtec** (Johnson & Johnson), is a second-generation histamine-1 (H1) receptor antagonist with both antihistamine and mast-cell stabilizing properties, known to reduce ocular redness. **Zerviate** is formulated with glycerin and hydroxypropyl methylcellulose. The most commonly reported adverse reactions are ocular hyperemia, instillation site pain and reduced visual acuity.

While the goal of treatment may be to reduce redness due to the underlying allergic reaction, it is possible that some individuals will experience redness as a side effect of this medication. **Zerviate** is supplied in sterile 7.5mL and 10mL bottles and as a box of 30 sterile, preservative-free, single-use vials.

In February 2020, **Pataday Once Daily Relief** (0.2% olopatadine hydrochloride ophthalmic solution, Alcon) and **Pataday Twice Daily Relief** (0.1% olopatadine hydrochloride ophthalmic solution, Alcon) were FDA approved for OTC sale.<sup>12</sup> Olopatadine is a well-established second-generation antihistamine and a mast-cell stabilizer.<sup>13</sup> This dual-action selective H1 receptor antagonist inhibits histamine release from mast cells, preventing histamine-

## Nanocarriers for Improved Ophthalmic Drug Delivery

Nanosuspensions	A colloidal dispersion of submicron drug particles stabilized by polymer(s) or surfactant(s). <sup>1</sup>
Nanoparticles	Nanocapsules enclose the drug inside a polymeric shell. Nanospheres have the drug uniformly distributed throughout polymeric matrix. <sup>1</sup> These are commonly 10nm to 1,000nm. <sup>1</sup>
Nanomicelles	Microscopic structures, usually 10nm to 100nm, that consist of an interior hydrophobic core that holds the drug and an exterior hydrophilic layer. <sup>1</sup>
Mucus-penetrating particle	Nanoparticle technology that possesses non-adhesive coatings that allow them to rapidly penetrate mucus layers through openings in the mucus mesh. <sup>2</sup> These are commonly 200nm to 500nm. <sup>3</sup>
Liposomes	Lipid vesicles with one or more phospholipid bilayers enclosing an aqueous core. <sup>1</sup> These are commonly 0.08µm to 10.00µm. <sup>1</sup>

1. Patel A, Cholkar K, Agrahari V, Mitra AK. Ocular drug delivery systems: an overview. *World J Pharmacol*. 2013;2(2):47.

2. Ensign LM. Mucus penetrating nanoparticles: biophysical tool and method of drug and gene delivery. *Adv Mater*. 2012;24(28):3887-94.

3. Lai SK, Wang Y-Y, Hanes J. Mucus-penetrating nanoparticles for drug and gene delivery to mucosal tissues. *Adv Drug Deliv Rev*. 2009;61(2):158-71.

induced effects on conjunctival epithelial cells, including redness.

It is indicated for temporary relief of itchy eyes due to pollen, ragweed, grass, animal hair and dander in adults and children over the age of two. It has a low benzalkonium chloride (BAK) concentration of 0.01%, reducing potential side effects due to the preservative. The most common adverse reactions associated with olopatadine are blurred vision, punctate keratitis, dry eye, abnormal eye sensations and dysgeusia. Pataday Once Daily Relief is supplied in a box with two 2.5mL bottles. Pataday Twice Daily Relief is supplied in a 5mL bottle.

**Inflammation.** Prescription cor-

ticosteroids are often used in the treatment of ocular inflammatory conditions, as they are highly effective in suppressing inflammatory, allergic and immune responses, including signs of redness. Corticosteroids suppress phospholipase A2 as well as the expression of cyclooxygenase/PGE isomerase (COX-1 and COX-2).

When a patient presents with hyperemia related to underlying inflammatory, allergic or immune responses, topical corticosteroids may help to rapidly improve signs and symptoms. However, they are known to delay healing and suppress the immune response and should, therefore, be judiciously

prescribed—especially for keratitis of unknown etiology or for prolonged use, as steroids may exacerbate the prevalence of secondary bacterial, viral and fungal infections.<sup>14</sup>

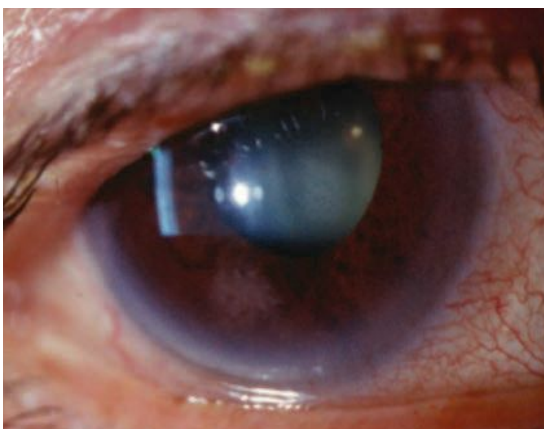
Several options exist, including **Pred Forte** (1% prednisolone acetate, Allergan), **Omni-pred** (1% prednisolone acetate, Novartis), dexamethasone, **FML** (0.1%

fluorometholone acetate, Allergan), **Flarex** (0.1% fluorometholone acetate, Eyevance Pharmaceuticals) and **Vexol** (1% rimexolone, Novartis), all of which are ketone steroids that depend on liver metabolism to become inactive. These tried-and-true formulations are widely used as they are effective and readily available; however, caution is advised as their potential side effects include an increase in the intraocular pressure as well as posterior subcapsular cataract formation.<sup>14</sup>

**Loteprednol**, on the other hand, is an ester steroid that binds to glucocorticoid receptors and is rapidly metabolized into inactive metabolites. Loteprednol has consistently demonstrated a low propensity to increase intraocular pressure (IOP) in adults, even in known steroid responders.<sup>15</sup> In addition, because of the ester group at C-20 position, loteprednol is unable to form covalent bonds with crystalline lens proteins, making it an unlikely culprit in cataract formation.<sup>16</sup>

**Lotemax** (loteprednol etabonate 0.5%, Bausch + Lomb), first approved in 2012, is available by prescription in three distinct formulations. As an ophthalmic suspension, it is indicated for the treatment of steroid-responsive inflammatory conditions of the palpebral and bulbar conjunctiva, cornea and anterior segment. As a gel and ointment, it is indicated for the treatment of postoperative inflammation and pain following ocular surgery.

In February 2019, the FDA approved **Lotemax SM** (loteprednol etabonate 0.38% ophthalmic gel, Bausch + Lomb) with TID dosing for the treatment of postoperative inflammation and pain following ocular surgery.<sup>17</sup> This new formulation takes advantage of submicron-size technology and uses particles that are significantly smaller than



**Limbal hyperemia associated with anterior uveitis.**

# LUMIFY<sup>®</sup>

BRIMONIDINE TARTRATE OPHTHALMIC SOLUTION 0.025%  
REDNESS RELIEVER EYE DROPS



SIMULATION REFLECTS AVERAGE CLINICAL TRIAL RESULTS.

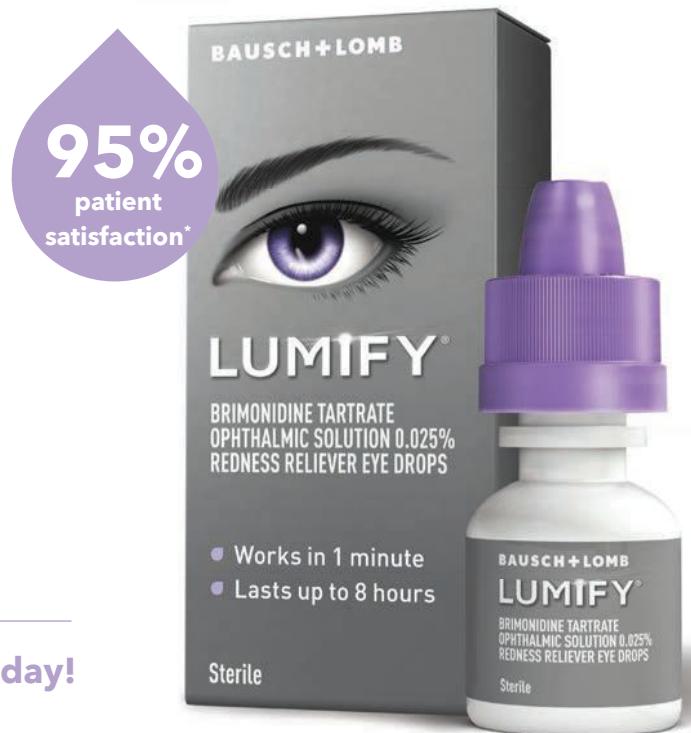● **The first and only OTC eye drop with low dose brimonidine tartrate (0.025%)**

● **Unique method of action<sup>†</sup> with no tachyphylaxis and virtually no rebound redness in clinical trials<sup>1</sup>**

● **Starts working within 1 minute—lasts up to 8 hours<sup>1</sup>**

**Recommend LUMIFY to your patients today!**

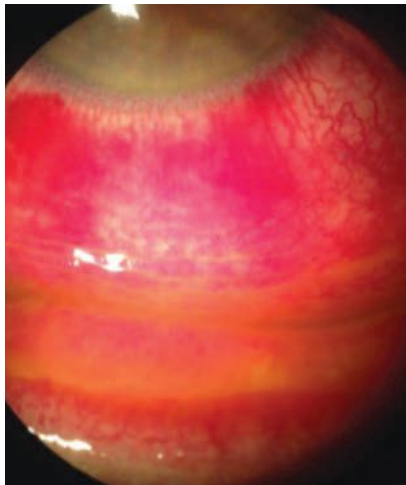
Call 1-800-828-9030 to start selling LUMIFY in your office.



\*In Home Use Test, March 2018. n=301. <sup>†</sup>LUMIFY is an OTC selective  $\alpha_2$ -AR agonist. <sup>1</sup>McLaurin E, Cavet ME, Gomes PJ, Ciolino JB. Brimonidine ophthalmic solution 0.025% for reduction of ocular redness: a randomized clinical trial. *Optom Vis Sci.* 2018;95(3):264-271.  
LUMIFY is a trademark of Bausch & Lomb Incorporated or its affiliates. © 2020 Bausch & Lomb Incorporated or its affiliates. PN09464 LUM.0179.USA.20

**BAUSCH + LOMB**

Watch the mechanism of action video at [LumifyDrops.com/Professional](https://LumifyDrops.com/Professional)



**Staining with fluorescein sodium reveals diffuse conjunctival hyperemia associated with a viral infection causing severe inflammation, subconjunctival hemorrhages and pseudomembranes.**

has been used in previous formulations; thus, the drug's delivery to target tissues is improved.

Lotemax SM has a low BAK (0.003%) concentration and a neutral pH. The presence of glycerin, hypromellose and propylene glycol make it friendly to the ocular surface, and the use of polycarboxophil prolongs its surface exposure. Safety and effectiveness have not been established in the pediatric population. Lotemax SM is available as 5g in a sterile 10mL bottle.

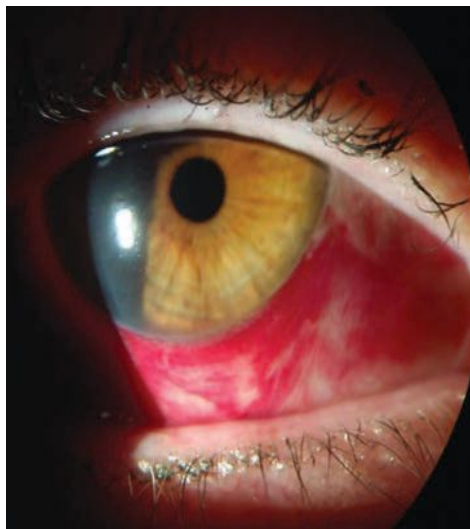In August 2018, the FDA approved prescription **Inveltys** (1% loteprednol etabonate ophthalmic suspension, Kala Pharmaceuticals) as BID dosing to treat inflammation and pain following ocular surgery.<sup>18</sup> This formulation takes advantage of mucus-penetrating particle drug delivery technology with nanoparticle size and a proprietary coating to prevent adherence of the drug to the tear film mucins, all of which is designed to improve drug delivery. It has a low BAK (0.01%) concentration. The safety and efficacy of

this drop have not been established for children. Inveltys is available in a sterile 5mL bottle.

**Vasodilation.** In 2017, the FDA approved OTC **Lumify** (0.025% brimonidine tartrate ophthalmic solution, Bausch + Lomb) to relieve ocular redness due to minor eye irritation in patients older than age five.<sup>19</sup> It can be instilled up to four times per day.

Currently available OTC vasoconstrictors are  $\alpha$ -adrenergic receptor (AR) agonists that induce smooth muscle contraction but differ in their affinity for the  $\alpha$ 1- and  $\alpha$ 2- AR subtypes. Phenylephrine and tetrahydrozoline are considered selective  $\alpha$ 1-AR agonists while naphazoline and oxymetazoline are considered mixed  $\alpha$ 1/ $\alpha$ 2- AR agonists.<sup>20</sup>

Brimonidine is a third-generation selective  $\alpha$ 2-adrenergic receptor agonist. While  $\alpha$ 1-ARs appear to be present in arteries,  $\alpha$ 2-ARs appear to be primarily expressed in veins.<sup>19</sup> Thus, the potential for vasoconstrictor-induced ischemia and responsive release of vasodilators is decreased with Lumify. Research suggests 0.025% brimonidine effectively reduces and maintains the reduc-



**Redness associated with a subconjunctival hemorrhage.**

tion of ocular redness for four hours post-instillation without significant rebound following discontinuation. In addition, the pupils and IOP are not affected when used as directed. It has a low BAK (0.01%) concentration and is supplied in sterile 2.5mL and 7.5mL bottles.

Of interest, 0.2% brimonidine tartrate ophthalmic solution, indicated for lowering IOP in patients with open-angle glaucoma or ocular hypertension, can result in a rare but well-described late side-effect of acute anterior uveitis in some elderly patients.<sup>21,22</sup> While the brimonidine concentration for IOP-lowering (0.1% to 0.2%) is considerably higher than for redness reduction as provided by Lumify—and the uveitis cases presented after many months of chronic use—clinicians should still be aware of this potential side effect, particularly since Lumify is available without a prescription.<sup>23</sup>

## Treatment Pearls

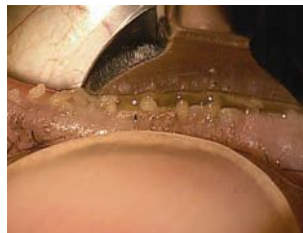
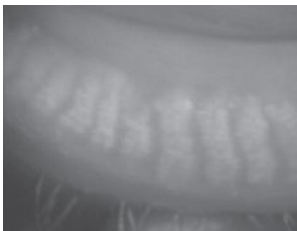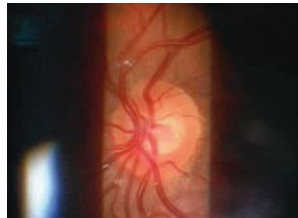
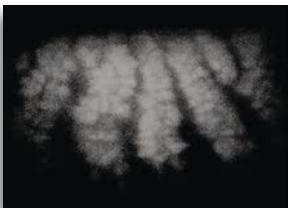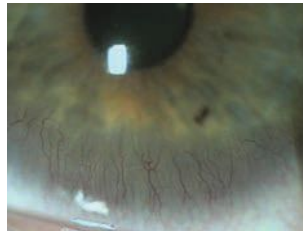
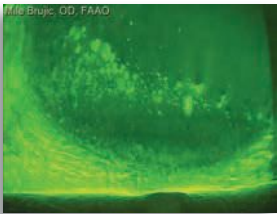
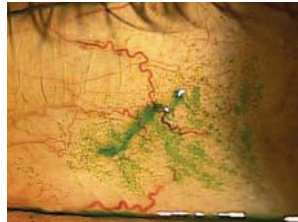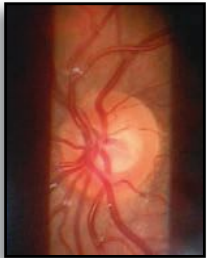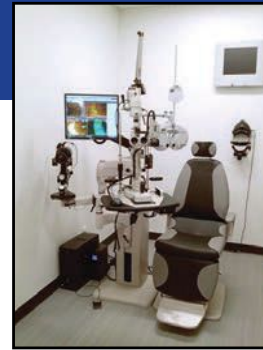The right medications to use when managing conjunctival hyperemia vary depending on the severity and nature of the underlying pathology. Primarily supportive medications, such as artificial tears, which can be kept in the fridge to be applied cold, can provide relief and decrease redness by limiting allergens and supporting the ocular surface, but their efficacy is limited in truly reducing redness. For some patients, cool compresses that induce vasoconstriction may be more beneficial.

Topical vasoconstrictors are more likely to be directly beneficial in reducing the severity of hyperemia, but they have limited efficacy and the formulations available prior to Lumify have a potential for tachyphylaxis or rebound effect.

Also, vasoconstrictors do not

Keep a close relationship with your patients  
... at a distance.

**EyeRes**<sup>TM</sup>  
Digital Imaging Systems



**Show the Reason for  
your Concern**

*With a large monitor  
mounted on the wall,*  
the EyeRes system  
enables you to educate  
your patients from a  
safer distance. You  
can be 6 feet from each  
other while both of you  
are within 5 feet of  
the monitor. Acquire  
images or video during  
your slit lamp exam,  
then show the patient  
the reason for your  
concern.

Call **502.515.1806** today or  
send email to [Wes.Harris@TelScreen.com](mailto:Wes.Harris@TelScreen.com)

[www.TelScreen.com](http://www.TelScreen.com)

**TelScreen**

address the ocular redness trigger; medications that limit vascular dilation or perfusion will only address the blood and substances present within the vessels. Therefore, in the case of a subconjunctival hemorrhage, a vasoconstrictor may be beneficial initially to limit further bleeding, but a patient should be advised that the medication won't eliminate the redness outside of the vessels associated with the bleed.

Patients often present with a complaint of redness and their primary concern is cosmetic in nature. However, the clinician must focus on addressing the underlying cause of the hyperemic reaction. Clinicians should specifically inquire during the case history about the presence of recent eye redness or the use of any agents designed to reduce ocular hyperemia. When patients report having prior redness, recent use of OTC agents or using old medications found at home, a careful slit-lamp examination is warranted. Clinicians should look for a pattern of any persistent redness and other potential signs of infection or inflammation, such as follicles or papillae, to reveal the diagnosis of an underlying condition. Here are a few patient examples to be on the lookout for:

- A patient does not have red eyes on gross examination due to the use of an OTC vasoconstricting agent but reports light sensitivity or foggy vision. This patient may require a more in-depth

corneal and anterior chamber evaluation to rule out uveitis, even though one of the early signs associated with anterior uveitis—redness—is reduced or difficult to assess altogether.

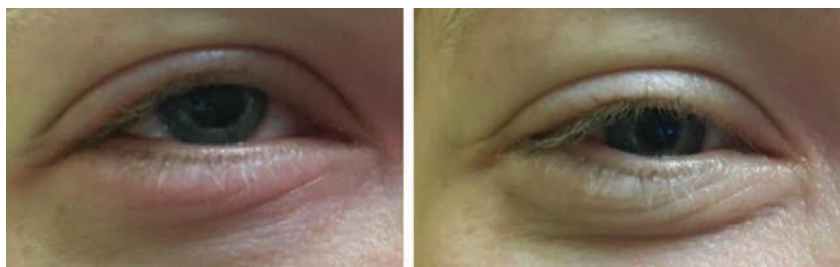- A patient suffering from adenoviral conjunctivitis may also turn to OTC redness reducing agents, leading to a delayed presentation for an ocular evaluation. This, in turn, could cause a missed or delayed diagnosis, furthering the transmission of the pathogen.
- A symptomatic contact lens wearer may self-treat with topical redness-reducing medications, masking the earliest symptom—hyperemia—of a poor contact lens fit or corneal hypoxia. The subsequent delayed care can have dire consequences for patients who are abusing their contact lenses, including a higher risk for infections and corneal disruption.

In the majority of ocular redness cases, supportive measures, including appropriate artificial tears and cool compresses, can provide some benefits. However, for many patients, addressing the underlying etiology of their ocular redness is key to truly providing long-lasting relief with minimal long-term sequelae. ■

*Dr. Tyler is an associate professor at the Southern California College of Optometry at Marshall B. Ketchum University, Fullerton, CA.*

*Dr. Lewandowska is an assistant professor at the College of Optometry at Nova Southeastern University, Davie, FL.*

1. Provine RR, Cabrera MO, Brocato NW, Krosnowski KA. When the whites of the eyes are red: A uniquely human cue. *Ethology*. 2011;117(5):395-99.
2. Sun Pharma Global FZE. Cequa [package insert]. [www.accessdata.fda.gov/drugsatfda\\_docs/label/2018/210913s000lbl.pdf](http://www.accessdata.fda.gov/drugsatfda_docs/label/2018/210913s000lbl.pdf). Revised August 2018. Accessed September 16, 2020.
3. Vadlapudi AD, Mitra AK. Nanomicelles: an emerging platform for drug delivery to the eye. *Ther Deliv*. 2013;4(1):1-3.
4. Prabhawati P, Tesavibul N, Karnchanachetane C, Kasemson S. Efficacy of cyclosporine 0.05% eye drops in Stevens Johnson syndrome with chronic dry eye. *J Ocul Pharmacol Ther*. 2013;29(3):372-7.
5. Deveci H, Kobak S. The efficacy of topical 0.05% cyclosporine A in patients with dry eye disease associated with Sjögren's syndrome. *Int Ophthalmol*. 2014;34(5):1043-8.
6. Steroid Approved for Dry Eye. *Rev Optom*. October 27, 2020. [www.reviewofoptometry.com/article/steroid-approved-for-dry-eye](http://www.reviewofoptometry.com/article/steroid-approved-for-dry-eye). Accessed November 6, 2020.
7. Alcon. Systane Complete lubricant eye drop. <https://systane.mylcon.com/eye-care/systane/products/systane-complete>. Accessed September 18, 2020.
8. Allergan. Refresh Relieva lubricant eye drops. [www.refresh-brand.com/Practitioner](http://www.refresh-brand.com/Practitioner). Accessed September 17, 2020.
9. Labetoulle M, Messmer EM, Pisella PJ, et al. Safety and efficacy of a hydroxypropyl guar/polyethylene glycol/propylene glycol-based lubricant eye-drop in patients with dry eye. *BR J Ophthalmol*. 2017;101(4):487-92.
10. Lievens C, Berdy G, Douglass D, et al. Evaluation of an enhanced viscosity artificial tear for moderate to severe dry eye disease: A multicenter, double-masked, randomized 30-day study. *Cont Lens Ant Eye*. 2019;42(4):443-49.
11. Evance Pharmaceuticals, LLC. Zerviate [package insert]. [www.accessdata.fda.gov/drugsatfda\\_docs/label/2020/208694s006lbl.pdf](http://www.accessdata.fda.gov/drugsatfda_docs/label/2020/208694s006lbl.pdf). Revised February 2020. Accessed September 16, 2020.
12. FDA approves three drugs for nonprescription use through Rx-to-OTC switch process. U.S. Food and Drug Administration. [www.fda.gov/news-events/press-announcements/fda-approves-three-drugs-nonprescription-use-through-rx-to-otc-switch-process](http://www.fda.gov/news-events/press-announcements/fda-approves-three-drugs-nonprescription-use-through-rx-to-otc-switch-process). February 14, 2020. Accessed September 18, 2020.
13. Kam KW, Chen LJ, Wat N, et al. Topical olopatadine in the treatment of allergic conjunctivitis: a systematic review and meta-analysis. *Ocul Immunol Inflamm*. 2017;25(5):668-82.
14. David D, Berkowitz J. Ocular effects of topical and systemic corticosteroids. *The Lancet*. 1969;294(7612):149-51.
15. Sheppard JD, Comstock TL, Cavet ME. Impact of the topical ophthalmic corticosteroid loteprednol etabonate on intraocular pressure. *Advance Thera*. 2016;33(4):532-52.
16. Comstock TL, Sheppard JD. Loteprednol etabonate for inflammatory conditions of the anterior segment of the eye: twenty years of clinical experience with a retrometabolically designed corticosteroid. *Expert Opin Pharmacother*. 2018;19(4):337-53.
17. Valeant Pharmaceuticals. Lotemax SM [package insert]. [www.accessdata.fda.gov/drugsatfda\\_docs/label/2019/208219s000lbl.pdf](http://www.accessdata.fda.gov/drugsatfda_docs/label/2019/208219s000lbl.pdf). Accessed September 16, 2020.
18. Kala Pharmaceuticals. Inveltys [package insert]. [www.accessdata.fda.gov/drugsatfda\\_docs/label/2018/210565s000lbl.pdf](http://www.accessdata.fda.gov/drugsatfda_docs/label/2018/210565s000lbl.pdf). Revised August 2018. Accessed September 16, 2020.
19. Bausch & Lomb. Lumify redness reliever eye drops. [www.lumifydrops.com/professional](http://www.lumifydrops.com/professional). Accessed September 17, 2020.
20. Torkildsen GL, Sanfilippo CM, DeCory HH, Gomes PJ. Evaluation of efficacy and safety of brimonidine tartrate ophthalmic solution, 0.025% for treatment of ocular redness. *Curr Eye Research*. 2018;43(1):43-51.
21. Byles DB, Frith P, Salmon JF. Anterior uveitis as a side effect of topical brimonidine. *Am J Ophthalmol*. 2000;130(3):287-91.
22. Beltz J, Zamir E. Brimonidine induced anterior uveitis. *Ocul Immunol Inflamm*. 2016;24(2):128-33.
23. Clemente-Tomás R, Arciniegas-Perasso CA, Hervás-Hernández JM, et al. Hypertensive acute granulomatous anterior uveitis as a side effect of topical brimonidine. *Arch Soc Esp Ophthalmol*. 2018;93(10):511-14.



**Allergic lid inflammation before, at left, and after treatment with Lotemax 0.5% ophthalmic gel.**





# WORKING TOGETHER to relieve dry eyes

Clinically proven to reduce the signs and symptoms of dry eyes<sup>1</sup>

**47%**  
improvement  
in symptoms

**20%**  
improvement  
in tear breakup time

**67%**  
reduction  
in number of  
glands blocked

**40%**  
improvement  
in meibum quality

Critical **first steps** to treating dry eye symptoms include ocular lubricants, lid hygiene and dietary modifications such as oral fatty acid supplementation.<sup>2</sup>  
-2017 DEWS II Report



**RESTORES**



**CLEANSES**



**NOURISHES**

More than eye drops,  
dry eye therapy™



[theratears.com/professionals](http://theratears.com/professionals)

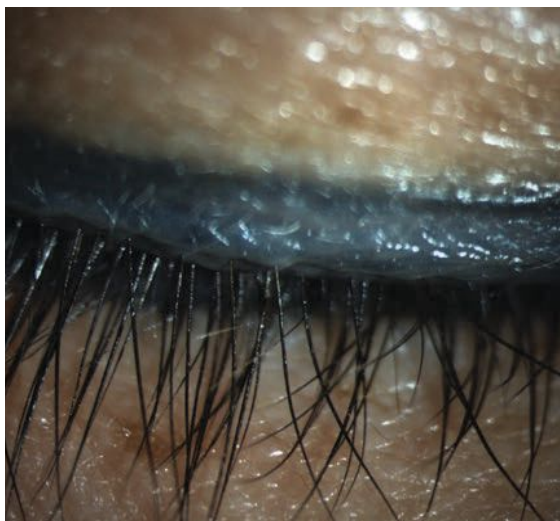

**References:** 1. Ngo W, Srinivasan S, Houtman D, Jones L. The relief of dry eye signs and symptoms using a combination of lubricants, lid hygiene and ocular nutraceuticals. *J Optom.* 2017 Jan-Mar;10(1):26-33. 2. Jones L, Downie L, Korb D, et al. TFOS DEWS II Management and Therapy Report. *Ocul Surg.* Jul 2017;15:575-628.  
© 2020 Akorn Consumer Health | A Division of Akorn, Inc. | M16-040-01

# How to Answer the “Why?” of Dry Eye

Patients have a lot of questions with this diagnosis, and how you respond is key to achieving positive outcomes. **By Whitney Hauser, OD**

**T**reating dry eye disease (DED) often raises more questions than it answers, for both doctors and patients. After all, the disease is difficult to understand and even harder to explain. The Tear Film and Ocular Surface Society’s (TFOS) 2017 Dry Eye Workshop II (DEWS II) report defines dry eye as “a multifactorial disease of the ocular surface characterized by a loss of homeostasis of the tear film, and accompanied by ocular symptoms, in which tear film instability and hyperosmolarity, ocular surface inflammation and damage, and neurosensory abnormalities play etiological roles.” That definition, while thorough and elegant, leaves a lot for us to unpack with our patients.<sup>1</sup>



**Patients require extensive education on the importance of removing makeup properly to help reduce dry eye symptoms related to MGD.**

The complex, multifactorial nature of the disease makes treating it feel like pulling on the thread of a sweater—the many facets of the disease are woven together,

and uncovering one starts to unravel the whole thing. The cascade of “whys” can be a challenge for optometrists to explain and difficult for patients to accept. But an educated patient is a motivated patient, and success often hinges on compliance. Here, we discuss the dry eye questions patients often have and how clinicians can keep patients focused on what’s important: improving their ocular health.

*Editor’s note: This article was planned and written while Dr. Hauser was a private practitioner. By the time of publication, Dr. Hauser had become an employee of Novartis Pharmaceuticals Corporation; however, the company did not review or influence the content and no products are discussed.*

## Why Me?

This used to have a straightforward answer: because you are a woman over the age of 50 or you have an autoimmune or other systemic disease.<sup>2</sup> However, the DED patient profile is evolving. While older women continue to dominate the dry eye demographic (with a prevalence of 17.9% vs. 10.5% in men), clinicians are reporting larger numbers of men and younger patients.<sup>3</sup> These emerging demographic trends may cause practitioners to reassess how they answer the question, “Why me?”

The complexity of dry eye makes it difficult to explain to patients why they have the condition. Risk factors are not only variable in their total number but also in their frequency, as some lifestyle and environmental risk factors can wax and wane with seasons or the patient’s visual, occupational and lifestyle demands. Demographics (i.e., age, sex, race), meibomian gland dysfunction (MGD), connective tissue disease, Sjögren’s syndrome, androgen deficiency, hematopoietic stem cell transplantation, environmental conditions and medication use are all consistent risk factors (Table 1).<sup>3-6</sup>

Another commonly associated risk factor is dermatologic rosacea, which can manifest with ocular complications—including dry eye—in up to 72% of patients.<sup>7</sup> Menopause and fluctuating hormone levels remain controversial risk factors, although recent research shows low androgen levels are associated

with increased DED, and hormone therapy in postmenopausal women can increase the risk of dry eye by as much as 70% for estrogen users and 30% for those taking estrogen+progesterone/progestin.<sup>2</sup>

The “why me” is difficult to answer for patients because many have multiple risk factors for DED. As doctors begin to explain the patient’s specific risks, these tend to accumulate into a compendium, and “why me” transitions to “of course you” as the physician works their way through the list and


inevitably hits a few. Whenever possible, try to prioritize just a few key risk factors in your discussion to help the patient retain as much as possible.

## Why Do I Need to Change My Habits?

Once patients understand the underlying causes of DED, a good question to pose back to them is, “What can you do?” Although many demographic features and systemic associations are unavoidable, the patient’s hygiene habits, environment and medication regimen all provide an opportunity for adjustment. While making a change to a single variable in the equation may appear inconsequential, it could make an immeasurable improvement in the patient’s quality of life.

**Environment.** A crucial—and often modifiable—environmental factor today is increased digital device use. Many patients reluctantly acknowledge their screen time is higher than ever before. Even if they are unable or unwilling to decrease the time spent on digital devices, clinicians can help patients incorporate healthy screen time habits to reduce the risk of dry eye. In addition to modern influences such as digital device use, airflow and low humidity levels are also environmental triggers that can cause an increase in symptoms.

Blinking is key to maintaining the integrity of the ocular surface, and several studies have identified a reduction in blink rate with computer use.<sup>8</sup> One team found a mean rate of 18.4



**MGD patients will have abnormal, if any, gland secretion upon expression.**

## Blinking and Thinking

While several studies have found decreased blink frequency with digital device use, clinicians must keep in mind that increased cognitive demand may also play an important role in the altered blink frequency. Higher cognitive load (such as more challenging reading material) can worsen the impact of existing stressors, such as low contrast text and uncorrected refractive error.

One team of researchers presented 16 teenagers with text written on a modern tablet computer and a hard copy printed version. The study found the mean blink rates for the low demand task were 8.34 and 9.06 blinks/minute for the computer tablet and the paper versions, respectively. When the subjects were presented with material requiring increase cognitive demand, the mean blink rates decreased significantly to 7.43 and 6.67 blinks/minute. The study suggests that technological advances in digital displays may more closely replicate printed materials.<sup>1</sup>

1. Sheppard AL, Wolffsohn JS. Digital eye strain: prevalence, measurement and amelioration. *BMJ Ophthalmol.* 2018;3:e000146.

blinks/minute that decreased to 3.6 blinks/minute with computer use. With an approximate 80% decrease in blink frequency, it's not surprising that patients will have accompanying dry eye symptoms such as irritation, burning and intermittent blur.<sup>8</sup> Most doctors now recommend the 20-20-20 rule for screen use: every 20 minutes, look at something 20 feet away for 20 seconds.

**Hygiene.** Patients also need to learn how to better care for their eyelids. Researchers note that as many as 86% of patients with dry eye also have some form of MGD.<sup>9</sup> The condition is characterized by duct obstruction, abnormal (or even non-existent) gland secretion and gland atrophy.<sup>10</sup> The symptoms of this dysfunction are the

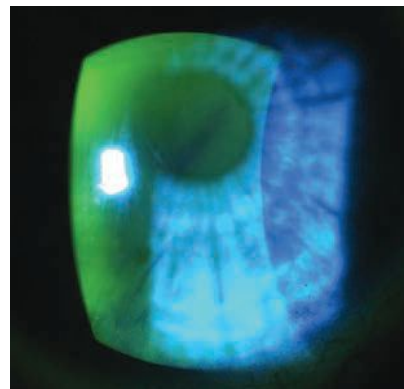
hallmarks of dry eye: eye fatigue or pain, dryness, gritty sensation, itching, redness and blurred vision, to name a few.<sup>10</sup>

To avoid this complication, patients should be caring for their eyelids the same way they care for their teeth. Optometrists can use the dental model as an analogy to help patients understand the importance of lid hygiene. Lid wipes and warm compresses can help keep the eyelids clean and healthy, just as brushing keeps teeth clean and disease-free. Deeper in-office dental cleanings are likened to in-office thermal treatments for the eyelids.

Unfortunately, patients often understand what doctors are saying but don't necessarily embrace it. Most adults have been exposed to the necessity of good oral hygiene since they were children.

Optometrists, however, are often beginning the lid hygiene conversation at the patient's mid-life when it is arguably the most difficult to change behavior patterns. Even once clinicians provide a reasonable rationale for ocular hygiene, they must remember that mid-life behavior changes are not easily executed no matter how cogent the argument. Patience is required with multiple educational touch points.

The drivers behind non-compliance are not black and white and are unique to each patient. Like DED itself, non-compliance tends to be multifactorial. Physicians can be guilty of over-simplifying why patients fail to adhere to recommendations rather than trying to better understand why they don't. Lack of adequate patient education could be chief among the reasons, but compliance issues can also



**Dry eye patients need ongoing patient education and encouragement to stay the course of treatment and self-care.**

be a result of a poor physician-patient relationship, limited patient involvement in decision-making, physical barriers and others.<sup>11</sup>

**Therapies.** The well-known association between systemic medications and ocular surface disease needs to be investigated with each patient and, if need be, their primary care provider or other prescribing physician. If a likely culprit is found but there's no practical way to replace it with an ocular surface-sparing alternative, explain to the patient the potential need for palliative artificial tear use or other mitigating strategies. If prescription dry eye therapy is warranted, explain that the goal is to interrupt the vicious cycle of inflammation so that other mitigation efforts can have time to take hold.

## Why Won't it Go Away?

That's a valid question—with a complicated answer. Notably, the DEWS II definition includes no mention of the chronicity of the disease. When the TFOS members were updating the definition of DED, they elected to retain some of the original language of the foundational definition, such as the loss of homeostasis and significant etiological roles of inflammation

**Table 1. DED Risk Factors<sup>3,5,6</sup>**

Risk Factor	Odds Ratio
<i>Age (18 to 34 as reference)</i>	
35 to 44	1.29
45 to 54	1.95
55 to 64	3.34
65 to 74	3.74
Older than 75	4.95
<i>Race (white as reference)</i>	
Asian	1.08
Hispanic	1.34
African American	0.96
Other	1.44
<i>Chronic conditions</i>	
Arthritis	1.59
Osteoporosis	1.70
Allergies	1.81
Thyroid disease	1.62
Migraine headache	1.69
<i>Medication use</i>	
Antihistamine	1.65
Steroids	1.84
Antidepressants	1.44
Hormones (women)	1.54
<i>Contact lens wear</i>	2.14
<i>Female sex (male as reference)</i>	1.88

# MIGS SURGEONS GET ONE SHOT MAKE A WISE DECISION

Progression in glaucoma never stops. Neither does the need for effective IOP management. That's why your best shot in MIGS with cataract surgery is the Hydrus® Microstent—the one option proven in a pivotal trial to deliver:

- The greatest improvement of medication elimination<sup>1-4,\*</sup>
- The largest IOP reduction<sup>1-4,\*</sup>
- A statistically significant reduction in risk of invasive secondary glaucoma surgeries<sup>†</sup>

When it's time to make a decision about MIGS, give your one shot the best chance to deliver the highest quality patient outcomes.

## Experience A New Confidence



©2020 Ivantis, Inc. Ivantis and Hydrus are registered trademarks of Ivantis, Inc. All rights reserved. IM-0070 Rev A



Delivering A New Confidence

**CAUTION: Federal law restricts this device to sale by or on the order of a physician.**

**INDICATIONS FOR USE:** The Hydrus Microstent is indicated for use in conjunction with cataract surgery for the reduction of intraocular pressure (IOP) in adult patients with mild to moderate primary open-angle glaucoma (POAG). **CONTRAINDICATIONS:** The Hydrus Microstent is contraindicated under the following circumstances or conditions: (1) in eyes with angle closure glaucoma; and (2) in eyes with traumatic, malignant, uveitic, or neovascular glaucoma or discernible congenital anomalies of the anterior chamber (AC) angle. **WARNINGS:** Clear media for adequate visualization is required. Conditions such as corneal haze, corneal opacity or other conditions may inhibit gonioscopic view of the intended implant location. Gonioscopy should be performed prior to surgery to exclude congenital anomalies of the angle, peripheral anterior synchiae (PAS), angle closure, rubeosis and any other angle abnormalities that could lead to improper placement of the stent and pose a hazard. **PRECAUTIONS:** The surgeon should monitor the patient postoperatively for proper maintenance of intraocular pressure. The safety and effectiveness of the Hydrus Microstent has not been established as an alternative to the primary treatment of glaucoma with medications, in patients 21 years or younger, eyes with significant prior trauma, eyes with abnormal anterior segment, eyes with chronic inflammation, eyes with glaucoma associated with vascular disorders, eyes with preexisting pseudophakia, eyes with uveitic glaucoma, eyes with pseudoexfoliative or pigmentary glaucoma, eyes with other secondary open angle glaucoma, eyes that have undergone prior incisional glaucoma surgery or cilioabative procedures, eyes that have undergone laser trabeculoplasty (ALT), eyes with unmedicated IOP < 22 mm Hg or > 34 mm Hg, eyes with medicated IOP > 31 mm Hg, eyes requiring > 4 ocular hypotensive medications prior to surgery, in the setting of complicated cataract surgery with iatrogenic injury to the anterior or posterior segment and when implantation is without concomitant cataract surgery with IOL implantation. The safety and effectiveness of use of more than a single Hydrus Microstent has not been established. **ADVERSE EVENTS:** Common post-operative adverse events reported in the randomized pivotal trial included partial or complete device obstruction (7.3%); worsening in visual field MD by > 2.5 dB compared with preoperative (4.3% vs 5.3% for cataract surgery alone); device malposition (1.4%); and BCVA loss of  $\geq 2$  ETDRS lines  $\geq 3$  months (1.4% vs 1.6% for cataract surgery alone). For additional adverse event information, please refer to the instructions for use. **MR INFORMATION:** The Hydrus Microstent is MR-Conditional meaning that the device is safe for use in a specified MR environment under specified conditions. **Please see the Instructions for Use for complete product information.**

**References:**

1. Samuelson TW, Chang DF, Marquis R, et al; HORIZON Investigators. A Schlemm canal microstent for intraocular pressure reduction in primary open-angle glaucoma and cataract: The HORIZON Study. *Ophthalmology*. 2019;126:29-37. 2. Vold S, Ahmed II, Craven ER, et al; CyPass Study Group. Two-Year COMPASS Trial Results: Supraciliary Microstenting with Phacoemulsification in Patients with Open-Angle Glaucoma and Cataracts. *Ophthalmology*. 2018;123(10):2103-2112. 3. US Food and Drug Administration. Summary of Safety and Effectiveness Data (SSED): Glaukos iStent® Trabecular Micro-Bypass Stent. US Food and Drug Administration website. [https://www.accessdata.fda.gov/cdrh\\_docs/pdf8/P080030B.pdf](https://www.accessdata.fda.gov/cdrh_docs/pdf8/P080030B.pdf). Published June 25, 2012. 4. US Food and Drug Administration. Summary of Safety and Effectiveness Data (SSED): iStent inject Trabecular Micro-Bypass System. US Food and Drug Administration website. [https://www.accessdata.fda.gov/cdrh\\_docs/pdf17/P170043b.pdf](https://www.accessdata.fda.gov/cdrh_docs/pdf17/P170043b.pdf). Published June 21, 2018.

\*Comparison based on results from individual pivotal trials (of those devices for which pivotal trials are available) and their respective controls and not head to head comparative studies. Other MIGS treatments have not been tested in pivotal trials.

†Data on file - Compared to control and includes trabeculectomy and tube shunt.



©2020 Ivantis, Inc. Ivantis and Hydrus are registered trademarks of Ivantis, Inc. All rights reserved. IM-0070 Rev A

## Patient Education

and hyperosmolarity. The consensus also broadened the definition to include neurosensory abnormalities as one of the additional etiologies. While we don't fully understand the mechanisms behind these abnormalities, their role in DED is undeniable, and their inclusion in the updated definition was important for differentiating DED from other ocular surface diseases.<sup>1</sup>

Interestingly, the term *chronic* is mentioned only once in the Definition and Classification section of TFOS DEWS II.<sup>1</sup> The report recognizes that the chronic and progressive nature of DED is often described clinically, but the committee considered the current evidence insufficient to include chronicity in the definition.<sup>1</sup> The report does, however, emphasize the vicious and cyclic nature of DED, with the many drivers of ocular surface inflammation feeding into one another.<sup>12</sup>

Other sources support the foundational DEWS II definition, but further categorize DED into chronic and episodic. Episodic dry eye tends to be triggered by environmental or visual tasks that result in a reduction in blink rate and tear film stability, causing dry eye symptoms. Although chronic dry eye can be exacerbated by the same environmental or ergonomic provocations, it persists with symptoms and possible damage to the ocular surface.<sup>13</sup>

The chronic nature of dry eye tends to have parallels with other chronic conditions, such as the inflammatory forms of arthritis (non-inflammatory variants also exist). Chronic dry eye is also an inflammatory condition with symptomatic exacerbations precipitated by activity. It can impede the patient's quality of life and cause varying degrees of pain. Both dis-

eases have effective treatments, but no cure.

The prevalence of arthritis between 2013 and 2015 was approximately 54.4 million in the United States, a number projected to rise to 78 million by 2040 (26% of the US population).<sup>14</sup> Similarly, approximately 34 million Americans are symptomatic for dry eye, and the TFOS DEWS II report notes that the global prevalence can range anywhere from 5% to 50%—and as much as 75% of patients over the age of 40.<sup>3,15,16</sup>

Because public awareness of arthritis may be more widely accepted than DED, clinicians can use the analogy as an educational tool when discussing the “why” of the chronic nature of dry eye. Just like inflammatory joint pain, DED may require daily treatment or medication to quell the symptoms. In spite of daily mitigation, exacerbations may occur and require additional short-term management.

### Why Are You Asking About My Feelings?

When managing DED, practitioners are often desensitized to the impact the diagnosis and the subsequent management has on the patient; however, it is life-altering.

Eye care providers may consider DED a less significant diagnosis than other chronic, progressive diseases such as age-related macular degeneration or glaucoma, because it rarely poses a threat to vision. However, patients who hear that their eye irritation and vision fluctuations can't be solved with an updated prescription will be understandably upset. They have a chronic condition without a cure that, if severe enough, requires attention and behavior change for the foreseeable future.

Research shows DED comes

## The Makeup Argument

Patients who wear makeup may be surprisingly resistant to a good lid cleansing routine, despite a clear understanding of the negative effects of these products. A survey in the United Kingdom asked 1,500 women about their nighttime cleansing habits and found that approximately one in four go to bed with makeup on. The survey also found that the rationale behind the habit wasn't always about laziness—25% said they left their makeup on to maintain the illusion they were fresh-faced all day, every day. Even though 59% of respondents felt like leaving makeup on negatively affected their quality of sleep and 33% acknowledged their skin looked worse because of it, many still chose to sleep in cosmetics.<sup>1</sup>

Impaired sleep and deleterious dermatological effects were not motivational enough to overcome one of the primary reasons women slept in makeup: insecurity. The survey found that 53% of woman identified as feeling insecure without their makeup, followed by wanting to look good for a partner and others simply couldn't be bothered. Additionally, the survey found the majority of survey takers who slept in makeup had been with their partner for less than one year while only 12% had been with their partner for over 10 years.<sup>1</sup>

1. Women wear makeup during sleep to impress partner. Business Standard. [www.business-standard.com/article/news-ians/women-wear-makeup-during-sleep-to-impress-partner-113081100557\\_1.html](http://www.business-standard.com/article/news-ians/women-wear-makeup-during-sleep-to-impress-partner-113081100557_1.html). August 11, 2013. Accessed October 21, 2020.

with a significant burden, both physically and financially. It can impair physical and mental functioning and, in moderate-to-severe disease, can have symptoms equivalent to severe migraine.<sup>17</sup> A recent study found that for each 10-unit difference in Ocular Surface Disease Index scores, participants' work and activity were impaired by 4.3% and 4.8%, respectively.<sup>18</sup>

A 2011 study found dry eye patients in the United States spend

approximately \$11,302 treating their disease.<sup>19</sup>

Depression and anxiety are widely accepted comorbidities of DED, and the diagnoses are often intertwined. The diagnosis of chronic illness and the management of chronic pain can induce a “stress state” that can aggravate both the disease and a patient's depressive tendency. Similarly, patients on depression medications, such as selective serotonin reuptake inhibitors, for reasons unrelated to eye health can experience dry eye side effects. In recent years, several studies have established overlap between pain- and depression-induced neuroplasticity changes, as well as neurobiological changes.<sup>20</sup>

Researchers note that patients with DED are also more likely to be diagnosed with dementia, bipolar disorder, depression and neurotic disorders.<sup>21</sup> They further speculate that DED and depression may have similar inflammatory etiologies, as DED patients have increased production of inflammatory cytokines in the tears and conjunctiva, while those with depression have high levels of the same inflammatory cytokines and neuropeptides in the blood.<sup>21</sup>

In addition, the medical management of depression can have sicca effects, especially in at-risk patients. Research shows medications with anticholinergic effects, such as tricyclic antidepressants, can cause decreased lacrimation.<sup>22,23</sup>

When patients ask the many *whys* of dry eye, be prepared with answers as unique as the people asking them. Canned responses don't inspire trust, compliance or loyalty to the practice—an individualized approach that takes into consideration each patient's risk factors, hygiene habits and medical history will. ■

*Dr. Hauser is director of peer education for ophthalmics at Novartis. She continues to practice clinical care in limited capacity at The Eye Specialty Group in Memphis, Tenn., with a focus on ocular surface disease and surgical management.*

1. Craig JP, Nichols KK, Akpek EK, et al. TFOS DEWS II definition and classification report. *Ocul Surf.* 2017;15(3):276-83.
2. Matossian C, McDonald M, Donaldson KE, et al. Dry eye disease: Consideration for women's health. *J Womens Health (Larchmt).* 2019;28(4):502-14.
3. Paulsen AJ, Cruickshanks KJ, Fischer ME, et al. Dry eye in the Beaver Dam Offspring Study: Prevalence, risk factors, and health-related quality of life. *Am J Ophthalmol* 2014;157:799-806.
4. Craig JP, Nelson JD, Azar DT, et al. TFOS DEWS II report executive summary. *Ocul Surf.* 2017;15(4):802-12.
5. Ward MF, Le P, Donaldson JC, et al. Racial and ethnic differences in the association between diabetes mellitus and dry eye disease. *Ophthalmic Epidemiol.* 2019;26(5):295-300.
6. Farrand KF, Fridman M, Stillman IO, Schaumberg DA. Prevalence of diagnosed dry eye disease in the United States among adults aged 18 years and older. *Am J Ophthalmol.* 2017;182:90-98.
7. Oge' LK, Muncie HL, Phillips-Savoy AR. Rosacea: diagnosis and treatment. *Am Fam Physician.* 2015;92(3):187-96.
8. Sheppard AL, Wolffsohn JS. Digital eye strain: prevalence, measurement and amelioration. *BMJ Ophthalmol.* 2018;3:e000146.
9. Lemp MA, Crews LA, Bron AJ, et al. Distribution of aqueous-deficient and evaporative dry eye in a clinic-based patient cohort: a retrospective study. *Cornea.* 2012;31(5):472-8.
10. Chhadva P, Goldhardt R, Galor A. Meibomian gland disease: the role of gland dysfunction in dry eye disease. *Ophthalmology.* 2017;124(11S):S20-S26.
11. Martin LR, Williams SL, Haskard KB, DiMatteo MR. The challenge of patient adherence. *Ther Clin Risk Manag.* 2005;1(3):189-99.
12. Bron AJ, de Paiva CS, Chauhan SK, et al. TFOS DEWS II pathophysiology report. *Ocul Surf.* 2017;15(3):438-510.
13. Gayton JL. Etiology, prevalence, and treatment of dry eye disease. *Clin Ophthalmol.* 2009;3:405-12.
14. Hootman JM, Helmick CG, Barbour KE, et al. Updated projected prevalence of self-reported doctor-diagnosed arthritis and arthritis-attributable activity limitation among US adults, 2015–2040. *Arthritis Rheumatol.* 2016;68(7):1582-87.
15. Stapleton F, Alves M, Bunya VY, et al. TFOS DEWS II Epidemiology Report. *Ocul Surf.* 2017;15(3):334-65.
16. US Census Bureau. Current Population Survey, Annual Social and Economic Supplement, 2008. Accessed May 1, 2020.
17. Galor A, Levitt RC, Felix ER, et al. Understanding the true burden of dry eye disease. *Expert Rev Ophthalmol.* 2015;10(5):403-5.
18. Greco G, Pistilli M, Asbell PA, Maguire MG. Association of severity of dry eye disease with work productivity and activity impairment in the Dry Eye Assessment & Management Study. *Ophthalmology.* October 14, 2020. [Epub ahead of print].
19. Yu J, Asche CV, Fairchild CJ. The economic burden of dry eye disease in the United States: a decision tree analysis. *Cornea.* 2011;30(4):379-87.
20. Sheng J, Liu S, Wang Y, et al. The link between depression and chronic pain: neural mechanisms in the brain. *Neural Plast.* 2017;2017:9724371.
21. Liang C, Cheang W, Wang C, et al. The association of dry eye syndrome and psychiatric disorders: a nationwide population-based cohort study. *BMC Ophthalmol.* March 20, 2020. [Epub ahead of print].
22. Malone DA Jr, Camara EG, Krug JH Jr. Ophthalmologic effects of psychotropic medications. *Psychosomatics.* 1992;33(3):271-7.
23. Richa S, Yazbek JC. Ocular adverse effects of common psychotropic agents. *CNS Drugs.* 2010;24(6):501-26.

# Artificial Tears: What Matters and Why

When selecting the right drop for your DED patient, experts say the devil's in the details. **By Jane Cole, Contributing Editor**

**T**ear supplementation with artificial tears is traditionally considered a first-line treatment for dry eye disease (DED). While these agents don't target the underlying pathophysiology, they often help to alleviate symptoms.<sup>1</sup>

Myriad formulations exist, making the selection process something of a mining expedition. All of them are considered safe, with just a few reported side effects, including blurred vision, ocular discomfort and foreign body sensation.<sup>1-3</sup>

Although relatively few trials compare formulations, a 2016 Cochrane review found no evidence of any difference in efficacy or side effects when comparing different artificial tear formulations.<sup>2</sup> However, limited data on lipid-containing artificial tears existed at the time of the review, and more recent research may affect the findings.<sup>2</sup>

With little to differentiate the



**The ingredients of an artificial tear may impact its efficacy and the patient's comfort.**

options, at least superficially, selecting the right one can be intimidating, and patients, if left unguided, are likely to make misinformed product decisions that could impact the therapy's efficacy.

Here, dry eye experts weigh in

on the many artificial tears currently available, which options are best for certain dry eye patients and when to consider switching from one type of tear to another.

## The Building Blocks

Artificial tears have both active and inactive ingredients that can impact a patient's treatment success. Some patients have sensitivities to certain ingredients, and some formulations may be more compatible for certain types of DED, says Jennifer S. Harthan, OD, professor and chief of the Cornea Center for Clinical Excellence at Illinois College of Optometry, Illinois Eye Institute.

"Patients often view artificial tears as interchangeable, and it's important to make a specific recommendation to them based on the type of dry eye disease they have and educate them on the differences," she explains. Treat artificial tears as a prescription. Prescribe



them for the specific condition that the patient has, she adds.

Artificial tears are comprised of two main active ingredients: demulcents and emollients.

**Demulcents.** These are usually a water-soluble polymer that helps to protect and lubricate the mucous membranes of the eye. Most commonly used in this category is carboxymethylcellulose, which increases the viscosity of tears and has mucoadhesive properties that allow for longer corneal coverage, explains Cecilia Koetting, OD, of Norfolk, VA.

Along with carboxymethylcellulose, another common demulcent is hydroxymethylcellulose. Some of these types of demulcents can be found in Refresh Tears (Allergan), TheraTears (Akorn) and Retaine (OcuSoft), Dr. Harthan says.

Propylene glycol, polyethylene glycol and glycerin are other common demulcents. Some of these can be found in Systane (Alcon), Blink (Johnson & Johnson Vision) and Soothe (Bausch + Lomb), according to Dr. Harthan.

Demulcents are sometimes used alone or in combination of up to three, explains Suzanne Sherman, OD, assistant professor of optometric sciences and director of optometric services in the Department of Ophthalmology at Columbia University Irving Medical Center.

The drops range in demulcent concentrations of 0.2% to 1%. The higher the percentage, the more vis-

### One Piece of the Puzzle

DED is a chronic, multifactorial disease, and patients may have varying degrees of signs and symptoms based on the underlying etiology, explains Dr. Harthan.

She suggests using a standardized symptom questionnaire at baseline and at follow up exams to assess treatment effects. Additionally, a complete dry eye evaluation should be done to determine disease severity and which management options are best suited for each patient. "Artificial tears are often not sufficient treatment alone and are commonly used in combination with other therapies. It's important to consider what long-term, specific treatments are needed to target the underlying disease process for each individual patient," explains Dr. Harthan. "Patients also experience flare-ups throughout the course of their disease. Education is critical for patients to understand their disease and enhance compliance with treatment."

"Artificial tears shouldn't be seen as the primary treatment of DED for most patients, but as a tool for temporary relief of DED symptoms," Dr. Koetting adds. "Patients should be evaluated for underlying causes of dry eye and appropriate treatment initiated concurrently."

Dr. Koetting won't typically start with an artificial tear if a patient has identifiable DED but will instead start to treat the underlying problem. "The patient can supplement the medication with an artificial tear as needed," she says.

cous it is and the greater the transient blur, Dr. Sherman adds.

"It's thought that the higher-concentration drops remain on the eye longer to provide prolonged relief," explains Dr. Sherman. "If a patient complains of too much blur from their artificial tears, you could look for an alternative with a lower concentration."

**Emollients.** Lipid-containing eye drops, formulated as emulsions, are growing in both availability and popularity, likely due to the increased attention being paid to meibomian gland disease (MGD) and lipid deficiency.<sup>1,4,5</sup>

Emollients are a fat or oil found in both tears and ointments. Most artificial tears use mineral oil, cas-

tor oil or flaxseed oil. They are used to increase the lipid layer thickness, help stabilize the tear film and reduce evaporation. They are typically classified based on the size of the oil droplets: macroemulsions, microemulsions and nanoemulsions, Dr. Koetting says. The size of the oil particle and concentration vary depending on the formulation and can affect the emulsion stability and bioavailability.

Emollients are important ingredients to look for when MGD is an underlying cause of DED, adds Dr. Harthan. However, most emollients added to artificial tears create an emulsion that requires some products to be shaken before instillation. It's important to fully understand

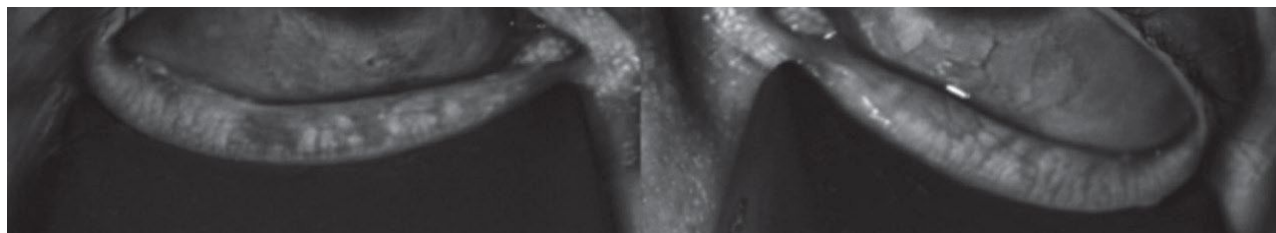
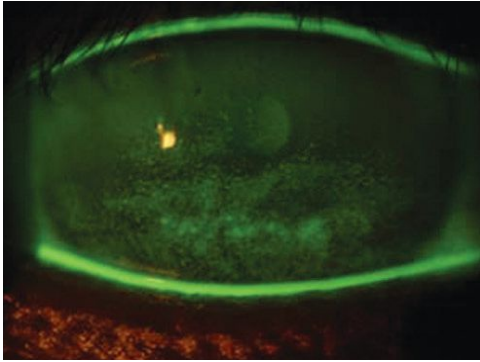


Image: Suzanne Sherman, OD

**This patient with moderate to severe gland loss would do well with a lipid-containing eye drop to help supplement the depleted lipids in the tear film.**

# Tear Supplementation

Photo: Jennifer Harthan, OD



**Sodium fluorescein staining in a patient with dry eye and exposure keratopathy. Patients with severe dry eye may do better with a viscous artificial tear, gel or ointment.**

the specifications for each separate artificial tear, Dr. Harthan explains.

Artificial tears containing emollients include Systane Balance (Alcon), Systane Complete (Alcon), Systane Nighttime (Alcon), Refresh Optive Advanced (Allergan), Refresh Optive Mega-3 (Allergan), Refresh PM (Allergan), Soothe XP (Bausch + Lomb) and Retaine MGD (OcuSoft), Dr. Harthan says.

A slew of inactive ingredients are often what set individual drops apart from each other and include preservatives, buffers, emulsifiers, electrolytes, viscosity-enhancing agents and osmo-protectants.

**Preservatives.** Many artificial tears that come in a multi-dose bottle contain preservatives designed to decrease the growth of bacteria once the bottle has been opened. Commonly used preservatives include benzalkonium chloride (BAK), polixetonium, polyquaternium (Polyquad) and OcuPure, in addition to sodium chlorite, which is considered a less harsh preservative, Dr. Sherman says.

The most common preservative in ophthalmic drops is BAK, but it can be detrimental to the ocular surface as it decreases goblet cell density, delays wound healing, damages corneal nerves and disrupts

corneal and conjunctival cells, Dr. Harthan explains.

One alternative to BAK, Polyquad, may be less toxic to the ocular surface for some patients, Dr. Harthan adds.

Preservative-free options generally have fewer additives and commonly come in single-dose vials.

Dr. Sherman considers switching to a preservative-free drop if a patient tends to have chronic allergies, sensitive skin, if they report mild-to-moderate stinging or

irritation from non-preservative free formulations or if they need to use the drops more than four times per day. Other considerations would be for individuals, such as glaucoma patients, who are on other topical eye drops that contain preservatives.

In addition, Dr. Harthan considers recommending a preservative-free drop for postoperative cases, those with moderate-to-severe DED, any patient using artificial tears more than four times a day and contact lens wearers. A recent report found that artificial tears and rewetting drops, with or without preservatives, are safe and effective when used before, during or after contact lenses wear, although the author recommends using preservative-free options whenever possible to avoid eye irritation.<sup>6</sup>

Clinicians should also take note whenever a patient says they are using a daily regimen of artificial tears. These patients should receive a more thorough dry eye evaluation and are likely candidates for escalated therapy.<sup>1</sup>

“In my opinion, there is not a single patient who wouldn’t benefit from using preservative-free versions of artificial tears,” adds Dr. Koetting. “Even in patients who

aren’t known to have sensitivity, when used in high volume, the preservatives can cause corneal damage, furthering their DED.”

If frequent use of preservative-free artificial tears is cost-prohibitive for patients, consider recommending a drop with a preservative that has a demonstrated safety profile, not BAK or thimerosal.

**Other ingredients.** The buffers and electrolytes within most artificial tears have been adjusted to mimic the pH and osmolarity of the tear film, which can be important for comfort and to avoid stinging upon installation. “Patients may have burning or stinging with certain artificial tears if the pH of the drop doesn’t align with their own tears,” Dr. Harthan explains.

If a patient has burning or stinging with certain artificial tears, it could be due to the preservative or it could be due to the pH or osmolarity of the artificial tear. With a full understanding of artificial tear ingredients, clinicians can help patients choose the right product to enhance comfort, maximize efficacy and minimize toxicity to the ocular surface, Dr. Harthan adds.

Normal tear pH is around 7.4 and the “comfort zone” is about 6.6 to 7.8.<sup>7</sup> Although manufacturers don’t advertise the pH in their products, making it hard to find, most artificial tears have a pH between 7.0 and 7.6.<sup>7</sup>

The physiologic pH of tears is well understood, but the impact of DED on tear pH is less clear, says Meaghan Horton, OD, who practices in Cincinnati. “Tear pH is not a diagnostic criterion for DED and is not routinely measured in clinic,” she explains.<sup>8</sup> “Some studies show a small alkaline shift in dry eye patients, but the amount was small and has not been validated as clinically relevant.<sup>9,10</sup> Ocular discomfort

When it comes to ocular surface inflammation, FLAREX® is **A PROVEN WINNER**

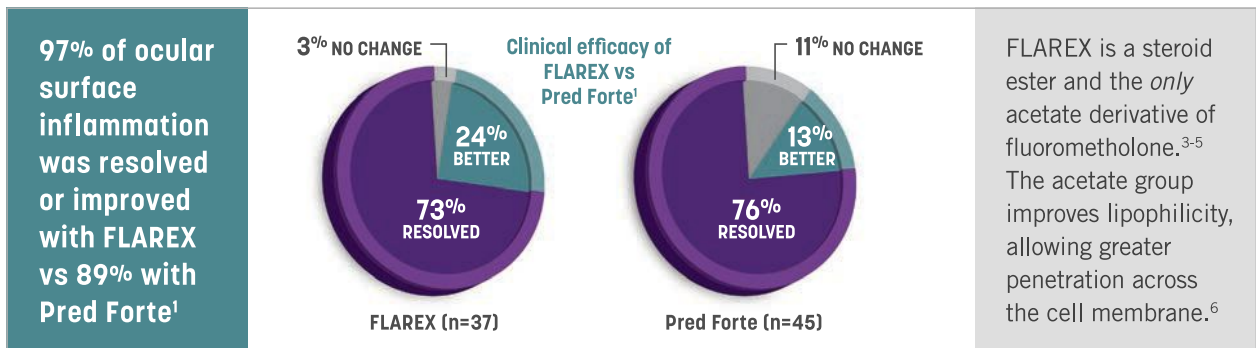


The power of Pred Forte\* (prednisolone acetate ophthalmic suspension, USP) 1% with the safety of FML\* (fluorometholone ophthalmic suspension, USP) 0.1%<sup>1a</sup>

Ocular surface inflammation is a key etiological factor in Dry Eye Disease<sup>2</sup>

FLAREX offers the efficacy of Pred Forte for ocular surface inflammation<sup>1</sup>

In the FDA pivotal trial evaluating patients with ocular surface inflammation,<sup>a</sup> there was no significant difference in clinical efficacy with FLAREX vs Pred Forte,  $P=0.49$ .<sup>1</sup>



In clinical trials, there were no adverse reactions reported in the FLAREX and FML treatment groups and FLAREX and Pred Forte treatment groups.<sup>1</sup>

There is no generic equivalent of FLAREX—be sure to prescribe by name<sup>4</sup>

INDICATIONS AND USAGE

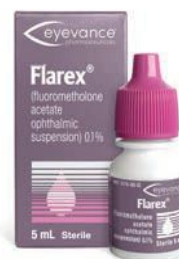FLAREX® (fluorometholone acetate ophthalmic suspension) is indicated for use in the treatment of steroid-responsive inflammatory conditions of the palpebral and bulbar conjunctiva, cornea, and anterior segment of the eye.

IMPORTANT SAFETY INFORMATION

**ADVERSE REACTIONS:** Glaucoma with optic nerve damage, visual acuity and field defects, cataract formation, secondary ocular infection following suppression of host response, and perforation of the globe may occur. Please see the Full Prescribing Information on the next page.

**\*STUDY DESIGN:** The efficacy and safety of FLAREX were evaluated in two identical, randomized, double-blind clinical trials. In one trial of 78 patients with ocular surface inflammation (eg, conjunctivitis, episcleritis, scleritis) in one or both eyes, patients administered either FLAREX (n=41) or fluorometholone alcohol (n=37) every 2 hours for the first 2 days and then every 4 hours thereafter, with signs and symptoms of inflammation assessed at Days 1, 3, 8, and 13. In a separate but identical trial in 82 patients with ocular surface inflammation, patients administered either FLAREX (n=37) or prednisolone acetate 1.0% (n=45). At each visit, investigators determined if signs and symptoms in the involved eye were resolved, improved, unchanged, or worsened. If a patient was rated as signs and symptoms resolved before the end of the study, steroid drops were discontinued and the patient was considered to have completed the trial.<sup>1</sup>

**References:** 1. Leibowitz HM, Hyndiuk RA, Lindsey C, et al. Fluorometholone acetate: clinical evaluation in the treatment of external ocular inflammation. *Ann Ophthalmol.* 1984;16(12):1110-1115. 2. Craig JP, Nichols KK, Akpek EK, et al. TFOS DEWS II Definition and Classification report. *Ocul Surf.* 2017 Jul;15(3):276-283. doi: 10.1016/j.jtos.2017.05.008. 3. FLAREX (package insert). Fort Worth, TX: Alcon Laboratories, Inc; 2017. 4. US Department of Health and Human Services, Food and Drug Administration. *Approved drug products with therapeutic equivalence evaluations.* (Orange Book), 40th ed. Washington, DC: US Department of Health and Human Services, Food and Drug Administration; 2020. 5. National Center for Biotechnology Information, PubChem. Fluorometholone acetate. <https://pubchem.ncbi.nlm.nih.gov/compound/fluorometholone-acetate>. Accessed September 10, 2020. 6. Sendrowski DP, Jaanus SD, Semes LP, et al. Anti-inflammatory drugs. In: Bartlett JD, Jaanus SD, eds. *Clinical Ocular Pharmacology.* 5th ed. St Louis, MO: Butterworth-Heinemann; 2008:221-244.



**Flarex®**  
(fluorometholone acetate ophthalmic suspension) 0.1%

**FLAREX NDC NUMBER: 71776-100-05**

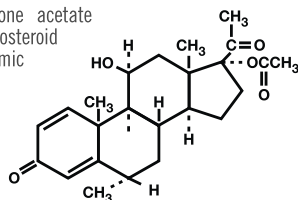


© 2020 Eveance Pharmaceuticals LLC. All rights reserved. FLAREX® is a registered trademark of Alcon Research, Ltd.  
\*All other trademarks are the property of their respective owners. FLA-20-AD-74-00



# When it comes to ocular surface inflammation, FLAREX® is A PROVEN WINNER

**DESCRIPTION:** FLAREX® (fluorometholone acetate ophthalmic suspension) is a corticosteroid prepared as a sterile topical ophthalmic suspension. The active ingredient, fluorometholone acetate, is a white to creamy white powder with an empirical formula of C<sub>24</sub>H<sub>31</sub>FO<sub>5</sub> and a molecular weight of 418.5. Its chemical name is 9-fluoro-11, 17-dihydroxy-6-methylpregna-1, 4-diene-3, 20-dione 17-acetate. The chemical structure of Fluorometholone Acetate is presented above:



**Each mL contains: Active:** fluorometholone acetate 1 mg (0.1%). Preservative: benzalkonium chloride 0.01%.

**Inactives:** sodium chloride, monobasic sodium phosphate, edetate disodium, hydroxyethyl cellulose, tyloxapol, hydrochloric acid and/or sodium hydroxide (to adjust pH), and purified water. The pH of the suspension is approximately 7.3, with an osmolality of approximately 300 mOsm/kg.

**CLINICAL PHARMACOLOGY:** Corticosteroids suppress the inflammatory response to inciting agents of mechanical, chemical or immunological nature. No generally accepted explanation of this steroid property has been advanced. Corticosteroids cause a rise in intraocular pressure in susceptible individuals. In a small study, FLAREX (fluorometholone acetate ophthalmic suspension) demonstrated a significantly longer average time to produce a rise in intraocular pressure than did dexamethasone phosphate; however, the ultimate magnitude of the rise was equivalent for both drugs and in a small percentage of individuals a significant rise in intraocular pressure occurred within three days.

**INDICATIONS AND USAGE:** FLAREX (fluorometholone acetate ophthalmic suspension) is indicated for use in the treatment of steroid responsive inflammatory conditions of the palpebral and bulbar conjunctiva, cornea, and anterior segment of the eye.

**CONTRAINDICATIONS:** Contraindicated in acute superficial herpes simplex keratitis, vaccinia, varicella, and most other viral diseases of cornea and conjunctiva; mycobacterial infection of the eye; fungal diseases; acute purulent untreated infections, which like other diseases caused by microorganisms, may be masked or enhanced by the presence of the steroid; and in those persons who have known hypersensitivity to any component of this preparation.

**WARNINGS: FOR TOPICAL OPHTHALMIC USE ONLY. NOT FOR INJECTION.** Use in the treatment of herpes simplex infection requires great caution. Prolonged use may result in glaucoma, damage to the optic nerve, defect in visual acuity and visual field, cataract formation and/or may aid in the establishment of secondary ocular infections from pathogens due to suppression of host response. Acute purulent infections of the eye may be masked or exacerbated by presence of steroid medication. Topical ophthalmic corticosteroids may slow corneal wound healing. In those diseases causing thinning of the cornea or sclera, perforation has been known to occur with chronic use of topical steroids. It is advisable that the intraocular pressure be checked frequently.

#### PRECAUTIONS:

**General:** Fungal infections of the cornea are particularly prone to develop coincidentally with long-term local steroid application. Fungus invasion must be considered in any persistent corneal ulceration where a steroid has been used or is in use.

**Information for Patients:** Do not touch dropper tip to any surface, as this may contaminate the suspension. The preservative in FLAREX® (fluorometholone

acetate ophthalmic suspension), benzalkonium chloride, may be absorbed by soft contact lenses. Contact lenses should be removed during instillation of FLAREX (fluorometholone acetate ophthalmic suspension) but may be reinserted 15 minutes after instillation. Patients should be advised that their vision may be temporarily blurred following dosing with FLAREX (fluorometholone acetate ophthalmic suspension). Care should be exercised in operating machinery or driving a motor vehicle.

**Carcinogenesis, Mutagenesis, Impairment of Fertility:** No studies have been conducted in animals or in humans to evaluate the possibility of these effects with fluorometholone.

**Pregnancy:** Fluorometholone has been shown to be embryocidal and teratogenic in rabbits when administered at low multiples of the human ocular dose. Fluorometholone was applied ocularly to rabbits daily on days 6-18 of gestation, and dose-related fetal loss and fetal abnormalities including cleft palate, deformed rib cage, anomalous limbs and neural abnormalities such as encephalocele, craniorachischisis, and spina bifida were observed. There are no adequate and well controlled studies of fluorometholone in pregnant women, and it is not known whether fluorometholone can cause fetal harm when administered to a pregnant woman. Fluorometholone should be used during pregnancy only if the potential benefit justifies the potential risk to the fetus.

**Nursing Mothers:** Systemically administered corticosteroids appear in human milk and could suppress growth, interfere with endogenous corticosteroid production, or cause other untoward effects. It is not known whether topical administration of corticosteroids could result in sufficient systemic absorption to produce detectable quantities in human milk. Because many drugs are excreted in human milk, caution should be exercised when FLAREX (fluorometholone acetate ophthalmic suspension), is administered to a nursing woman.

**Pediatric Use:** Safety and effectiveness in pediatric patients have not been established.

**Geriatric Use:** No overall differences in safety or effectiveness have been observed between elderly and younger patients.

**ADVERSE REACTIONS:** Glaucoma with optic nerve damage, visual acuity and field defects, cataract formation, secondary ocular infection following suppression of host response, and perforation of the globe may occur.

**Postmarketing Experience:** The following reaction has been identified during post-marketing use of FLAREX® (fluorometholone acetate ophthalmic suspension) in clinical practice. Because reactions are reported voluntarily from a population of unknown size, estimates of frequency cannot be made. The reaction, which has been chosen for inclusion due to either its seriousness, frequency of reporting, possible causal connection to FLAREX, or a combination of these factors, includes: dysgeusia.

**DOSAGE AND ADMINISTRATION: Shake Well Before Using.** One to two drops instilled into the conjunctival sac(s) four times daily. During the initial 24 to 48 hours the dosage may be safely increased to two drops every two hours. If no improvement after two weeks, consult physician. Care should be taken not to discontinue therapy prematurely.

**HOW SUPPLIED:** FLAREX (fluorometholone acetate ophthalmic suspension) is supplied in white low density polyethylene (LDPE) bottles, with natural LDPE dispensing plugs and pink polypropylene closures. The product is supplied as 5mL in an 8 mL bottle.  
5 mL: NDC 71776-100-05

**STORAGE:** Store upright between 2°C -25°C (36°F -77°F). Protect from freezing.

**Manufactured by:**  
Eyevance Pharmaceuticals, LLC  
Fort Worth, TX 76102 USA

**LEARN MORE AT MYFLAREX.COM**



# Tear Supplementation

such as burning and stinging can result from use of solutions with pH that significantly differs from the pH of the precorneal tear film.

TheraTears has been shown to be more alkaline than most artificial tears and would be a good first choice for a patient with significant complaints of stinging on instillation, according to Dr. Horton.<sup>11,12</sup>

The 2017 TFOS DEWS II report emphasized that tear film osmolarity is central to the pathophysiology of DED as a biomarker of tear film homeostasis.<sup>8</sup>

“What needs more research is which type of artificial tear, and its relative properties of osmolarity, can impact the osmolarity of the tear film in dry eye patients,” says Dr. Horton. “We know that tear osmolarity changes parallel improvements in the signs and symptoms of DED, but there is limited data available that directly correlates this improvement with a particular type of artificial tear.”

Patients with an osmolarity of up to around 295mOsm/L would be candidates for most artificial tears of low viscosity if they are using the lubricant infrequently or for episodic symptoms, explains Dr. Horton. Patients at 317mOsm/L or more, signifying moderate disease, should be on anti-inflammatory medications, and the clinician should consider artificial tears with osmoprotective agents, she adds.

“In general, artificial tears should be pH neutral and iso or hypotonic. This would mean a pH very close to 7.4 (may have better comfort profile if slightly alkaline to 7.4) and a hypo or near iso-osmolar quality,” Dr. Horton advises.

Glycerin and trehalose are just two examples of osmoprotectants that have demonstrated *in vivo* protective effects on desiccated epithelial cells.<sup>13,14</sup>

Trehalose, found in Refresh Optive Mega-3, is an additive designed to help stabilize cell membranes, while sodium hyaluronate, a glycosaminoglycan, is an ingredient in both Blink and Oasis Tears (Oasis Medical) to enhance viscosity, thereby increasing lubrication to the ocular surface, Dr. Harthan says.

Additionally, hydroxypropyl-guar (HP-guar) is found in Systane artificial tears and helps keep the demulcent on the eye longer, she adds. HP-guar is a polymetric thickener that combines with the two demulcents in Systane to form a low viscosity gel that activates as it interacts with the ocular surface, changing the pH.<sup>15</sup>

Also new to the field is Refresh Optive Repair (Allergan), a drop that contains both carboxymethyl-cellulose and sodium hyaluronate.<sup>16</sup> This option is said to offer osmoprotective benefits that safeguard the health of epithelial cells against hyperosmotic stress.<sup>16</sup>

## How to Choose

When selecting an artificial tear for a patient, clinicians must consider several factors, including efficacy, duration of relief, ease of installation, viscosity, type of dry eye disease targeted and how a patient will be impacted by the amount of blur a drop may cause, Dr. Harthan suggests. The artificial tear’s pH and the presence or absence of a preservative are also key factors.

The most important first step is determining the patient’s individual needs based on ocular history and the clinical exam, Dr. Sherman suggests. Only once clinicians understand the type of ocular surface disease the patient has can they

determine which type of tear is right, she adds.

**MGD.** A patient with this form of dry eye may benefit from an artificial tear with emollients to help replace the decreased lipids in the tear film, Dr. Koetting says. Some tears in this category include Systane Balance, Soothe XP and Refresh PM.

**Evaporative dry eye.** This form of DED is often a consequence of MGD; thus, patients often do well with artificial tears containing emollients in combination with warm compresses, environmental management and acknowledgment of systemic medications, according to Dr. Sherman.

**Aqueous-deficient dry eye.** Artificial tears are a large part of the treatment for this form, and patients often have their favorite, depending on what’s comfortable for them, she says. Here, frequency is key, she adds.

Unfortunately, if dry eye is severe, the patient will need some kind of anti-inflammatory as well. These are the patients who are put on cyclosporine, steroids and/or serum tears, Dr. Sherman says.

“It’s important to emphasize these tears must be used frequently to see results,” Dr. Sherman explains. Artificial tears are often used in combination with anti-

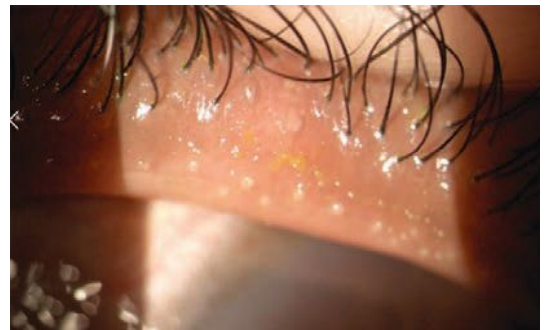

Photo: Jennifer Harthan, OD

**Patients with MGD can benefit from artificial tears, but they will also need therapies that target the underlying etiology.**

# Tear Supplementation

inflammatory agents, punctal plugs and omega-3 vitamins, she says.

**Mixed dry eye.** The TFOS DEWS II findings suggest that up to 70% of dry eye patients may have a hybrid of evaporative and aqueous-deficient dry eye.<sup>1</sup> At least one artificial tear, Systane Complete, is marketed to help alleviate symptoms from evaporate, aqueous deficient and mixed dry eye.

If a patient has mixed DED, Dr. Sherman will always start with addressing the lid margins, including cleaning them and getting the meibomian glands to the highest functioning potential. Using artificial tears that are helpful for evaporative DED will not worsen the aqueous dry eye condition, she adds.

“Often just improving one aspect of their DED will improve the clinical signs and patient symptoms enough to not have to use prescription-strength medications,” Dr. Sherman says.

Some patients require trial and error when choosing the right drop. “If a patient is sensitive to ingredients, do not select an artificial tear that has the same ingredients. Preservative-free tears are beneficial for many,” Dr. Harthan reiterates.

**Disease severity.** Along with DED type, the staging will help dictate the artificial tear of choice.

Some products target only one aspect of DED, while others target multiple aspects, significantly affecting efficacy depending on the condition, and severity, in question.

“Patients with more severe dry eye or those with exposure keratopathy may require a viscous artificial tear, gel or ointment,” according to Dr. Harthan.

Another point: Take into account what artificial tears your patient has already tried, as many individuals may have tried numerous tears before they reach your chair.

Unfortunately, selecting a comfortable drop for a patient is often a trial and error process. But if it goes beyond removing preservatives and changing viscosity, “the patient most likely has uncontrolled underlying disease and should have targeted therapy to control surface inflammation and/or osmolarity,” Dr. Horton says.

## A Generic Debate

Dr. Koetting typically will tell her patients to avoid preserved generic artificial tears. “Even though the active ingredients listed may be the same as the brand name, it’s the preservatives that sometimes aren’t listed. Most notable is BAK, which can lead to further irritation and corneal toxicity,” Dr. Koetting says.

On the other hand, Dr. Sherman says many patients tolerate generic preserved drops well, and it is important to keep in mind that generic drops are significantly cheaper. “I will not ask a patient to switch to non-generic or preservative-free drops if the patient is accepting the drop well, and the artificial tears are providing sufficient results.”

## Time to Switch

If an artificial tear is not well tolerated, Dr. Sherman will recommend the patient change brands.

“We are all different, and we tend to have distinctive likes and dislikes,” she says. “No one artificial tear works for everyone. I often tell patients, ‘You have to try a bunch before you find the one that is the most soothing for you.’”

If the patient has tried a few different drops and reports poor tolerance, it is time to switch to non-generic, preservative-free or medicated drops, she says.

If the artificial tear is insufficient in easing symptoms, the clinician

needs to look into why, Dr. Sherman adds. Optometrists need to question whether they are targeting the wrong type of dry eye or whether the patient may have other underlying conditions such as an autoimmune disorder or MGD that exacerbate their symptoms, she says.

Whatever artificial tear you recommend, first consider the formulations of each specific product and the signs and symptoms of your dry eye patients. All products may look the same at first glance, but when it comes to artificial tears, the devil’s in the details. ■

1. Jones L, Downie LE, Korb D, et al. TFOS DEWS II management and therapy report. *The Ocular Surface*. 2017;15(3):575-628.
2. Pucker AD, Ng SM, Nichols JJ. Over the counter (OTC) artificial tear drops for dry eye syndrome. *Cochrane Database Syst Rev*. 2016;2:CD009729.
3. Downie LE, Keller PR. A pragmatic approach to dry eye diagnosis: evidence into practice. *Optom Vis Sci*. 2015;92(12):1189-97.
4. Lee SY, Tong L. Lipid-containing lubricants for dry eye: a systematic review. *Optom Vis Sci*. 2012;89(11):1654-61.
5. Moshirfar M, Pierson K, Hanamakaik K, Santiago-Caban L, Muthappan V, Passi SF. Artificial tears potpourri: a literature review. *Clin Ophthalmol*. 2014;8:1419-33.
6. Pucker AD. A review of the compatibility of topical artificial tears and rewetting drops with contact lenses. *Cont Lens Anterior Eye*. 2020;43(5):426-32.
7. Perrigin JA, Morgan A, Quintero S, et al. Comparison of pH values of selected ocular lubricants. *Invest Ophthalmol Vis Sci*. 2004;45:3913.
8. Wolffsohn JS, Arita R, Chalmers R, et al. TFOS DEWS II diagnostic methodology report. *Ocul Surf*. 2017;15(3):539-74.
9. Khurana AK, Chaudhary R, Ahluwalia BK, Gupta S. Tear film profile in dry eye. *Ophthalmol (Copenh)*. 1991;69(1):79-86.
10. Norm MS. Tear fluid pH in normals, contact lens wearers, and pathological cases. *Acta Ophthalmol*. 1988;66(5):485-9.
11. Stahl U, Willcox M, Stapleton F. Role of hypo-osmotic saline drops in ocular comfort during contact lens wear. *Cont Lens Ant Eye*. 2010;33(2):68-75.
12. Dalton K. pH osmolality and viscosity of artificial tears. *American Academy of Optometry*. 2008. [www.aaopt.org/detail/knowledge-base-article/ph-osmolality-and-viscosity-artificial-tears](http://www.aaopt.org/detail/knowledge-base-article/ph-osmolality-and-viscosity-artificial-tears). Accessed September 28, 2020.
13. Baudouin C, Cochener B, Pisella P-J, et al. Randomized, phase III study comparing osmoprotective carboxymethylcellulose with sodium hyaluronate in dry eye disease. *European J Ophthalmol*. 2012;22(5):751-61.
14. Hovakimyan M, Ramoth T, Löbler M, et al. Evaluation of protective effects of trehalose on desiccation of epithelial cells in three dimensional reconstructed human corneal epithelium. *Curr Eye Res*. 2012;37(11):982-9.
15. Christensen MT. Corneal staining reductions observed after treatment with Systane. *Advances in Therapy*. 2008;25(11):1191-9.
16. Allergan Expands Refresh Portfolio With New Refresh Repair Lubricant Eye Drops. Chicago: PR Newswire. 2018. [www.prnewswire.com/news-releases/allergan-expands-refresh-portfolio-with-new-refresh-repair-lubricant-eye-drops-300677992.html](http://www.prnewswire.com/news-releases/allergan-expands-refresh-portfolio-with-new-refresh-repair-lubricant-eye-drops-300677992.html). Accessed September 15, 2020.

# CHANGING TIMES REQUIRES A CHANGE IN THINKING

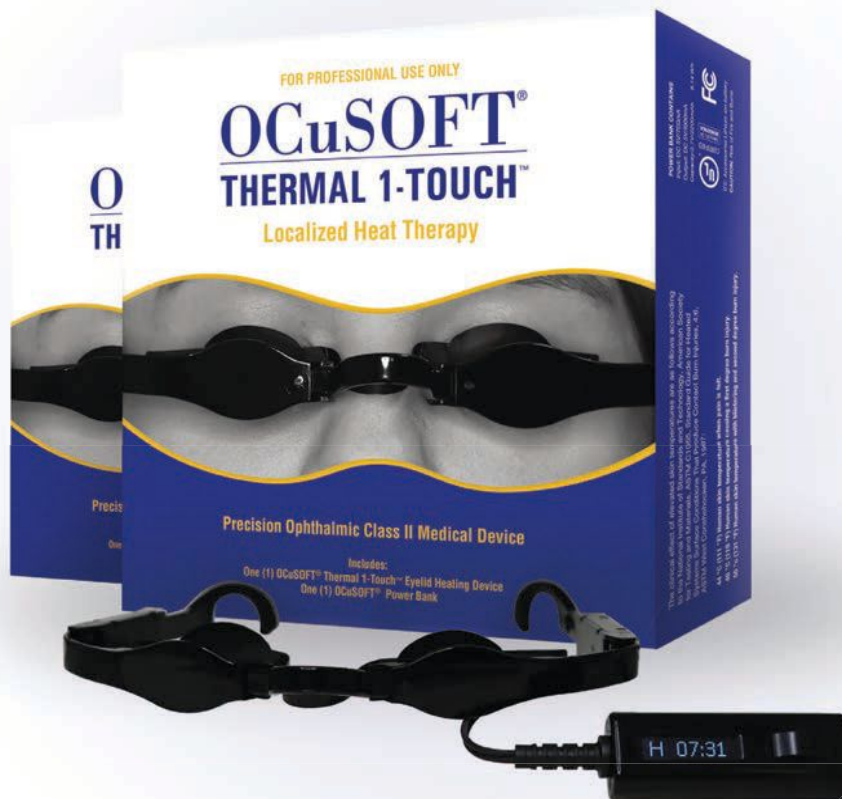Stop. Take a moment. Think it over.

In the new world of COVID, you simply can't conduct business (or health care) in the same way. Individuals without incomes are likely postponing office visits unless it's an emergency. Those that you are seeing want the very latest in treatment.

This is why you need OCuSOFT®'s Thermal 1-Touch™. When compared to other office-based units, its low price of \$2,650 provides for a lower procedural cost for patients. To demonstrate how this works in your office, you can now try the Thermal 1-Touch™ for 30 days...**FREE OF CHARGE!**

Thermal 1-Touch™ offers preset modes, temperature settings and can treat all 4 eyelids simultaneously providing improved patient convenience. So, before you buy and commit to an in-office eyelid heating device, call our Customer Support Team at **(800) 233-5469** to learn why changing times requires a change in thinking.

CALL FOR A FREE DEMO UNIT  
**(800) 233-5469**



# Lid Wiper Epitheliopathy:

## What the OD Needs to Know

Observe and assess this aspect of the ocular surface to better deal with dry eye.

By Chris Lievens, OD, Laurel Roberts, OD, Elyse Rayborn, OD, Yvonne Norgett, PhD, FCOptom, Nancy Briggs, PhD, Peter M. Allen, PhD, FCOptom, and Marta Vianya-Estopa, PhD, MCOptom

**L**id wiper epitheliopathy (LWE) was first proposed as a contact lens (CL) friction issue in 2002. The undersurface of the upper eyelid was named the “lid wiper,” as it spread the tear film over the ocular surface with every blink, much like the windshield wiper does on an automobile.<sup>1</sup> It is now generally accepted that any lid-to-surface friction can cause LWE.

LWE is visualized by everting the eyelid after an ophthalmic vital dye has been instilled and the area proximal to the eyelashes has been clinically inspected (*Figure 1*).<sup>2</sup> An observable line at the mucocutaneous junction, called the line of Marx, is present in all eyelids, and any further staining of the tissue in the palpebral marginal conjunctiva is evidence of LWE (*Figure 2*).<sup>2</sup>

Because of the blinking mechanism of the eyes, LWE can be observed in both CL wearers and non-lens wearers, especially when a patient has complaints of dryness

without typical clinical signs.<sup>3,4</sup> It has also been proposed that LWE is a sign of subclinical inflammation that could exacerbate the conundrum of dry eye progression.<sup>1,4</sup> Consistently and accurately assessing LWE is fast becoming an important component of dry eye disease (DED) identification and treatment.

### A Multifactorial Condition

No matter the underlying etiology, DED can result in an inadequate, unstable or otherwise defective tear film. Proper lubrication from a healthy tear film prevents the sheering stress believed to cause LWE.<sup>3,5</sup> As such, it is not surprising that LWE is reported to be found in almost 90% of patients with known dry eye issues.<sup>4</sup> Compromise to the epithelium of the wiping system can result in symptomatology akin to that of DED.<sup>3,6-8</sup>

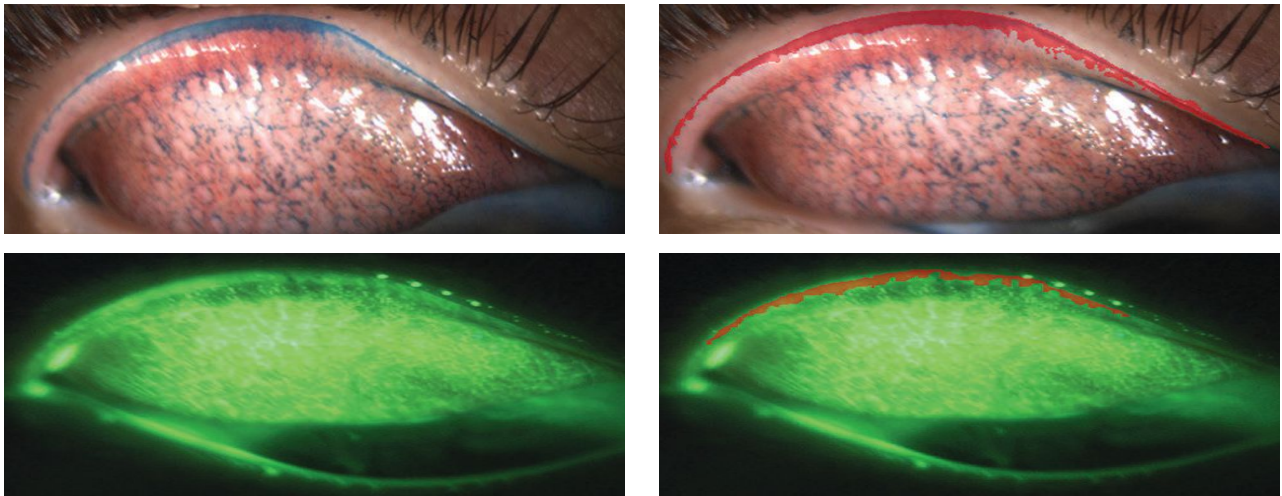
A healthy tear film is vital in the management of LWE and its associated symptoms. The disruption of any of the tear film components can

cause decreased lubricity, leading to increased friction between the eyelids and the ocular surface. The tear film must also be thick enough to mask any ocular surface irregularities, and all types of DED can exacerbate LWE through resultant friction-related damage.<sup>5</sup>

Meibomian gland dysfunction (MGD) and LWE are often diagnosed together.<sup>9</sup> Atrophied or congested meibomian glands do not produce or excrete adequate lipid into the tears. This leads to altered tear viscosity, reduced tear break-up time, and a thinner tear layer.

Severe MGD can cause tear saponification with inspissated, clogged and capped gland orifices. Altered tear composition oftentimes leads to a hyperosmolar condition, which can further damage the ocular surface and the lid wiper region.<sup>10</sup> Hyperosmolar tears are also implicated in goblet cell damage or destruction, and, a lack of secreted mucins could lead to problems with lubricity.<sup>5,11</sup> Any of these





**Fig. 1.** All images are of everted upper lids. Images on the left use lissamine green and sodium fluorescein, respectively. See the areas colored in red on the right that outline what is considered to be lid wiper epitheliopathy.

factors, and more likely a combination of these factors, can lead to dryness, discomfort, epithelial changes, and concurrent LWE.

### Contributing Factors

LWE can be present on both the upper and lower eyelids, though each is likely due to differing etiologies. Upper LWE has been reported to be associated with greater patient discomfort and symptomatology; whereas, the lower lid LWE has not.<sup>9,10,12,13</sup> Multiple theories have been proposed to explain this disparity. It is possibly due to differences in lid anatomy. For example, there are more meibomian glands present in the upper lid than the lower lid, which can lead to a higher prevalence of MGD in the upper lid.<sup>9</sup> One study postulated that upper LWE is caused by decreased tear volume and/or viscosity, while lower LWE is attributed to altered tear osmolarity and increased contact time of the tears on the lower lid surface.<sup>11</sup>

A major contributing factor to LWE is the anatomy of the blink itself, as the upper lid travels across a greater surface area during a

typical blink.<sup>5</sup> Greater contact time between the upper lid and the dry or irregular ocular surface could result in more epithelial damage and increased patient discomfort. The repeated movement of the lower lid along the nasal bulbar conjunctiva may be related to higher lid-parallel conjunctival fold (LIPCOF) scores, which correlate with increased LWE due to shared related mechanisms of friction.<sup>14-16</sup>

LIPCOFs are small visible folds in the inferotemporal and inferonasal quadrants of the bulbar conjunctiva, parallel to the lower lid margin.<sup>17</sup> Their presence may relate to increased the shear forces between the bulbar conjunctiva and palpebral conjunctiva of the eyelid during blinking.<sup>18</sup> Shear forces due to friction may be the root cause of LWE, particularly in cases of DED and those with CL discomfort.

Lid anatomy changes as a factor of age and with differing demographics. The prevalence of LWE in the upper and lower lids decreases with increasing age, due to changes in lid laxity that alter the shearing forces of blinks.<sup>16</sup> There is also a higher prevalence of LWE in Asians,

which may be explained by lid anatomy and meibum composition differences between ethnicities.<sup>10</sup> As with DED, there are multiple contributing factors that are not distinctly separate.

### Proposed Mechanisms

The studies that demonstrated increases in LWE in CL patients proposed several possible, and likely interrelated, mechanisms contributing to damage of the stratified squamous epithelial cells that make up the lid wiper. Based on current theories, a combination of mechanical shearing forces during the blink and decreased tear film stability can result in LWE in CL wearers.<sup>1,14</sup> It has been widely demonstrated and accepted that CL wear will alter the normal biochemical structure of the tear film and affect the rate of evaporation.<sup>19-24</sup>

When comparing symptomatic and asymptomatic soft CL wearers, the mucin, MUC5AC, significantly decreased in symptomatic patients, and the study concluded CL wearers with dry eye symptoms had decreased mucin concentrations at the ocular surface.<sup>14</sup> Increased

tear film evaporation resulting from incomplete blinks accelerates the precipitation of deposits on the lens surface.<sup>25</sup> An incomplete blink approximately doubles the interblink interval and tear evaporation time for the inferior corneal surface or CL, and deposits are more easily precipitated on a CL anterior surface when the pre-lens tear layer thins or evaporates.<sup>25</sup>

The frictional forces that are the suspected underlying mechanism of LWE are, therefore, the greatest during a complete blink following an incomplete blink, as the fluid layer between the lens and lid wiper is the thinnest and provides less lubrication than between full blinks.<sup>25</sup> After the tear film has evaporated in this area, a concentration of tear constituent remains and increases the tear osmolarity. However, a study exploring tear osmolarity, comfort and LWE was unable to demonstrate a relationship among the three.<sup>26</sup> The authors proposed that this is possibly due to lack of diag-

nostic equipment currently capable of testing the tear osmolarity on the surface of the lens.<sup>25</sup>

The Tear Film and Ocular Surface (TFOS) International Workshop on Contact Lens Discomfort updated the definition of CL discomfort and proposed environmental factors that play a role.<sup>27</sup> In assessing the impact of low humidity on CL wearers, researchers demonstrated that LWE grades increased significantly in the upper and lower lids and that artificial tears did not improve the LWE when used two hours after the patient left the humidity chamber.<sup>28</sup>

### Avoid Falling Short

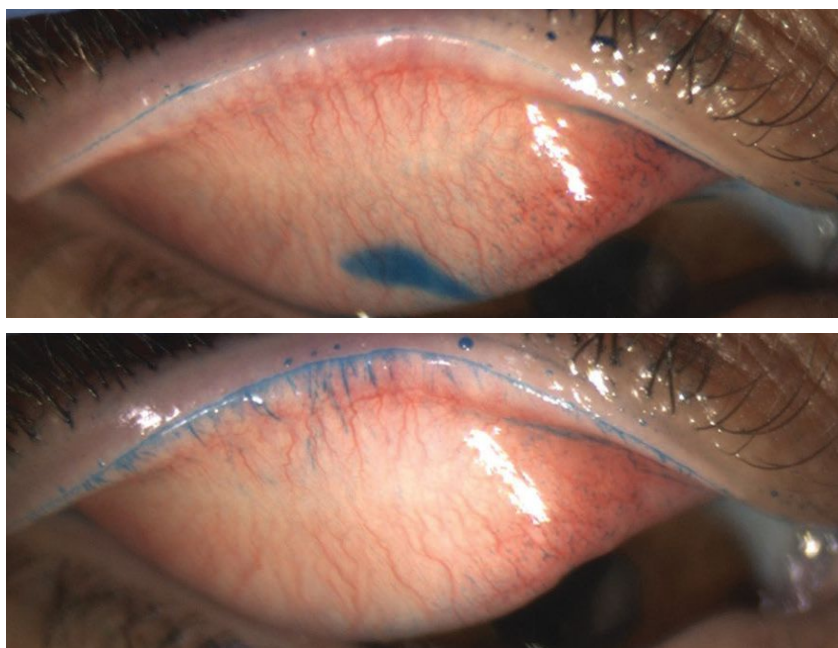
Understanding the anatomy is crucial to properly identifying LWE. There are several possible reasons why LWE was not previously a focal point of conversation in research and clinical care.<sup>3</sup> Eyelids are infrequently everted during routine anterior segment evaluations. When eyelids are everted, the lid margins are generally not inspected; instead,

the attention is typically directed to the tarsus. Vital dye staining to show compromise of the tissue prior to lid eversion is uncommon in practice. Not only is vital dye staining important for visualization of LWE but timing also matters.<sup>3</sup>

Clinical inspection can influence findings when using vital dyes. One study found that a non-specific time point in making observations with sodium fluorescein (NaFl) can yield misleading results due to a reduction in the clinical presentation of LWE.<sup>29</sup> Similarly, observation without sufficient dye instillations may not yield the full extent of LWE.

### Optimal LWE Identification

An evidence-based approach with both NaFl and lissamine green (LG) dyes can reveal and identify LWE in practice.<sup>30</sup> The proper quantity of dye and the ideal timing for clinical observation can fully uncover this condition. For both LG and NaFl, a repeat instillation of dye (two drops of 10 $\mu$ L LG and 2 $\mu$ L NaFl) is necessary to reveal the full extent of LWE staining.<sup>30</sup> Optimal viewing time is critical with using NaFl, as clinicians need to wait five minutes if using one drop, or three to five minutes when using two drops.<sup>30</sup> The latest TFOS DEWS II report recommends waiting three to six minutes after repeat NaFl instillation with strips when observing LWE (*Figure 3*).<sup>31</sup> Similarly, research showed that when using two drops of LG, optimal observation can occur between one and five minutes. When using a strip wetted with one drop of saline observation should occur after between one and four minutes.<sup>31</sup> A simple and easy-to-remember clinical protocol would be to use two drops of either dye and observe the eyelid after three minutes (*Table 1*).



**Fig. 2.** The image on top only reveals the line of Marx, whereas the image underneath shows additional proximal LWE staining.

# PASSIONATELY AT WORK IN EVERY ASPECT OF EYE HEALTH

**AKORN** | EYE CARE

At Akorn, eye care is our passion. We are present in all aspects of eye health, from anterior to posterior segments, from diagnosis to treatment to maintenance. Since 1971, we have been building partnerships in the eye care community and supporting you in making a lasting impact in your patients' lives.

**AK-FLUOR**  
(fluorescein injection, USP)

**Akten**  
(lidocaine HCl ophthalmic gel) 3.5%

**AzaSITE**  
(azithromycin ophthalmic solution) 1%

**BETIMOL**  
(timolol ophthalmic solution) 0.25%, 0.5%

**CosoptPF**  
(dorzolamide HCl-timolol maleate ophthalmic solution) 2%/0.5%

**ICoGreen**  
(indocyanine green 101 injection, USP)

**PAREMYD**  
(hydroxyamphetamine hydrobromide and tropicamide ophthalmic solution) 1%/0.25%

**thera tears**  
THERAPY FOR YOUR EYES.

**ZIOPTAN**  
(tafluprost ophthalmic solution) 0.0015%

**Akorn Ophthalmic Generics**

**Table 1. Step-by-step LWE Identification Procedure**

1.	Instill one drop of vital dye (LG or NaFl)
2.	Wait one minute
3.	Instill second drop of same vital dye
4.	Wait three minutes
5.	Evert lid and evaluate the lid margin for LWE

Improper observation timing and inadequate dye quantity can easily mislead a clinician into prematurely concluding that LWE is not present.

Impregnated paper strips are more commonly used in clinical practice than liquid vital dyes. As such, it is nearly impossible to know the exact dye volume delivered with paper strip instillation. This is further rationale to require two instillations to ensure adequate dye delivery to the ocular tissues.

### Treatment and Management

To address the multifactorial mechanisms of increased LWE in CL wearers, eye care practitioners must employ a variety of weapons from their DED arsenal. The preventive treatments for LWE should augment hydrodynamic lubrication and reduce or eliminate excess trauma. Preventive measures should also counteract possible associated inflammation—assist in shear stress reduction and prevent of “dry” contact between the eyelid wiper and the CL surface.<sup>32</sup>

Recently published data on treating DED subjects with concurrent LWE compared a lipid-based nano-emulsion drop (Systane Complete, Alcon) and a non-lipid-based aqueous drop (Systane Ultra, Alcon). The study found that both treatments significantly reduced LWE.<sup>33</sup>

Lipid emulsion artificial tears and meibomian gland management can substantiate the diminished tear cushion (especially the lipid layer) between the lid and CL, steroids can reduce para-inflammation from

microtrauma of the shearing forces during blinks, punctal plugs can improve the tear volume available to the ocular surface and ointment at night after lens removal can be helpful.<sup>30</sup>

Other considerations include discontinuing lens wear or changing lens materials or wear schedule.<sup>30,32,34,35</sup> One report demonstrated an improvement in upper LWE with the use of 0.1% hyaluronic acid (HA) drops and discontinuation of lens wear.<sup>15</sup> Others found that adding HA to standard carboxymethylcellulose (CMC) artificial tear drops improved clinical performance without additional adverse effects and should be considered in these cases.<sup>36</sup>

### LWE and Contact Lenses

Some have proposed that LWE could be the missing link between CL discomfort and the lack of clinical signs.<sup>1</sup> One study demonstrated an increase in LWE in symptomatic soft CL wearers (80%) compared with asymptomatic lens wearers (13%) that was most likely a product of the characteristics of the tear film between the lens surface and the lid wiper.<sup>1</sup>

Though LWE may occur in the absence of CL wear, many studies have shown an increase in LWE in CL wearers, including gas permeable lenses (GPs) and both hydrogel and silicone-hydrogel soft lenses.<sup>3,15,34,37</sup> One study in particular documented and classified six slightly different patterns of LWE in silicone-hydrogel CL wearers.<sup>34</sup> Just like corneal

staining patterns can differ by patient and etiology, the same is true for LWE. Clinical examination of any staining proximal to the line of Marx on the lid margin is key, especially considering it may not yield one particular and exact pattern of staining.

Another study used imaging to study increased density of the microvascular network of the lid wiper after six hours of CL wear and demonstrated a significant correlation with CL discomfort.<sup>38</sup>

However, according to a meta-analysis, the number of studies failing to show an association between LWE and CL discomfort were roughly equal to those that did find a correlation.<sup>28</sup>

Due to the recent discovery of the lid wiper and the potential clinical impacts, further studies must be done to determine the true association between LWE and CL. Several have recommended a standardized protocol for LWE identification to better compare LWE severity across studies.<sup>28,30,35,39,40</sup>

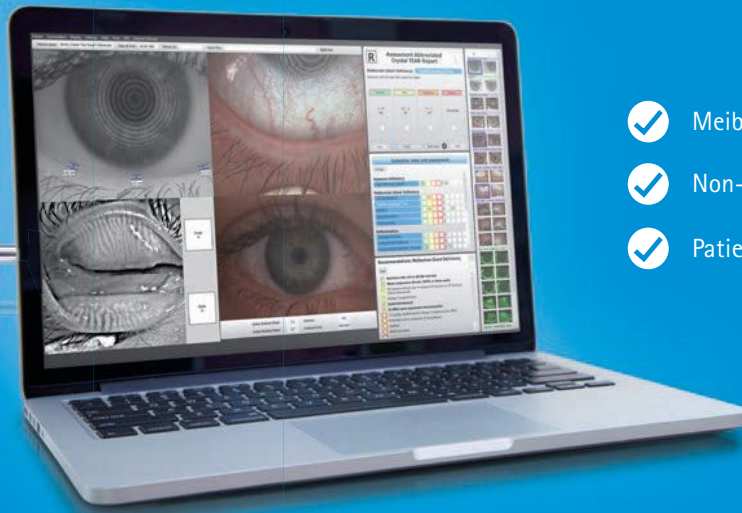### Predicting Successful CL Wear

Novel clinical tests designed to predict success in neophyte CL wearers demonstrated a close relationship between LWE and hyperemia and between LWE and LIPCOF scores.<sup>14,41</sup> Another study also attempted to predict success of new silicone hydrogel wearers, and the researchers noted a significant increase in LWE over six months.<sup>37</sup> Interestingly, the latter study found that LWE was associated with tear volume but not tear meniscus height, suggesting that tear volume of the surface plays a role in decreasing friction along the lower lid margin.

Until we learn more about the role that it plays in CL discomfort, make sure to consider LWE during

# Searching for Dry Eye?

Find out in 60 seconds



- ✓ Meibography
- ✓ Non-invasive break-up time
- ✓ Patient education and compliance

## OCULUS Keratograph® 5M: More than Meibography

Streamline your dry eye analysis with the baseline data of the tear film quality, quantity, or gland structure. This comprehensive assessment enhances patient care and outcomes.

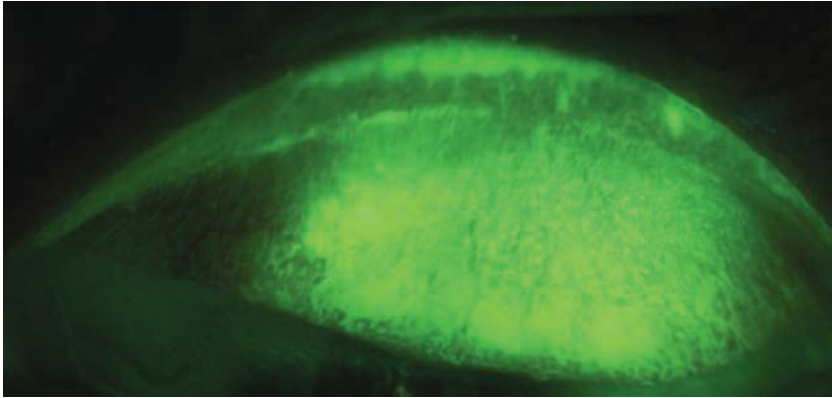
Contact us today to learn more!



Scan here or visit  
[www.oculususa.com/dryeye](http://www.oculususa.com/dryeye)

Toll free 888-519-5375  
[ads@oculususa.com](mailto:ads@oculususa.com)

 **125 YEARS**  
OCULUS®



**Fig. 3.** LWE is apparent after staining with NaFl.

your clinical examinations moving forward. Any interventions that can keep CL wearers from becoming symptomatic are advantageous for a successful practice.

Microtrauma due to blinking over a non-lubricious ocular surface can exacerbate the DED and confound CL wearers. Pay close attention to the anatomy around the lid margins and the lid wiper. In order to correctly examine these tissues, carefully deliver adequate dye volume through a repeat administration to avoid premature observation and false diagnosis of the lid wiper post-dye instillation. Proper adherence to the optimal methodology to identify LWE may lead to more successful outcomes. ■

*Dr. Lievens is a professor and chief of internal clinics of The Eye Center at the Southern College of Optometry in Memphis.*

*Dr. Roberts and Dr. Rayborn practice at The Eye Center.*

*Dr. Norgett is a senior lecturer at Anglia Ruskin University in Cambridge, England.*

*Dr. Briggs is a senior statistical consultant at the Mark Wainwright Analytical Centre in UNSW Sydney.*

*Dr. Allen is a professor of optometry and visual science at Anglia Ruskin University.*

*Dr. Vianya-Estopa is a senior lec-*

*turer of optometry at Anglia Ruskin University.*

1. Korb DR, Greiner J V, Herman JP, et al. Lid-wiper epitheliopathy and dry-eye symptoms in contact lens wearers. *CLAO J.* 2002;28(4):211-6.
2. Efron N, Brennan NA, Morgan PB, Wilson T. Lid wiper epitheliopathy. *Prog Retin Eye Res.* 2016;53:140-74.
3. Korb DR, Herman JP, Greiner JV, et al. Lid wiper epitheliopathy and dry eye symptoms. *Eye Contact Lens.* 2005;31(1):2-8.
4. Korb DR, Herman JP, Blackie CA, et al. Prevalence of lid wiper epitheliopathy in subjects with dry eye signs and symptoms. *Cornea.* 2010;29(4):377-83.
5. Cher I. A new look at lubrication of the ocular surface: fluid mechanics behind the blinking eyelids. *Ocul Surf.* 2008;6(2):79-86.
6. Knop E, Korb DR, Blackie CA, Knop N. The lid margin is an underestimated structure for preservation of ocular surface health and development of dry eye disease. *Dev Ophthalmol.* 2010;45:108-22.
7. Varikooty J, Srinivasan S, Jones L. Atypical manifestation of upper lid margin staining in silicone hydrogel lens wearers with symptoms of dry eye. *Contact Lens Anterior Eye.* 2008;31(1):44-6.
8. Pult H, Purslow C, Murphy PJ. The relationship between clinical signs and dry eye symptoms. *Eye.* 2011;25(4):502-10.
9. Korb DR, Blackie CA. Meibomian Gland Diagnostic Expressibility: Correlation With Dry Eye Symptoms and Gland Location. *Cornea.* 2008;27(10):1142-7.
10. Li W, Yeh TN, Leung T, et al. The relationship of lid wiper epitheliopathy to ocular surface signs and symptoms. *Investig Ophthalmol Vis Sci.* 2018;59(5):1878-87.
11. Golebiowski B, Chim K, So J, Jalbert I. Lid margins: Sensitivity, staining, meibomian gland dysfunction, and symptoms. *Optom Vis Sci.* 2012;89(10):1443-9.
12. Siddireddy JS, Vijay AK, Tan J, Wilcox M. The eyelids and tear film in contact lens discomfort. *Contact Lens Anterior Eye.* 2018;41(2):144-53.
13. Navasques-Cornago M, Morgan PB, Maldonado-Codina C. Lid margin sensitivity and staining in contact lens wear versus no lens wear. *Cornea.* 2015;34(7):808-16.
14. Berry M, Pult H, Purslow C, Murphy PJ. Mucins and Ocular Signs in Symptomatic and Asymptomatic Contact Lens Wear. *Optom Vis Sci.* 2008;85(10):E930-8.
15. Pult H, Purslow C, Berry M, Murphy PJ. Clinical tests for successful contact lens wear: relationship and predictive potential. *Optom Vis Sci.* 2008;85(10):E924-9.
16. Shiraishi A, Yamaguchi M, Ohashi Y. Prevalence of upper and lower-lid-wiper epitheliopathy in contact lens wearers and non-wearers. *Eye Contact Lens.* 2014;40(4):220-4.
17. Bandlitz S, Purslow C, Murphy PJ, Pult H. Lid-parallel conjunctival fold (LIPCOP) morphology imaged by optical coherence tomography and its relationship to LIPCOP grade. *Contact Lens Anterior Eye.* 2019;42(3):299-303.
18. Pult H, Tosatti SG, Spencer ND, et al. Spontaneous blink-

ing from a tribological viewpoint. *Ocul Surf.* 2015;13(3):236-49.

19. Craig JP, Wilcox MDP, Argüeso P, et al. The TFOS International Workshop on Contact Lens Discomfort: report of the contact lens interactions with the tear film subcommittee. *Invest Ophthalmol Vis Sci.* 2013;54(11):TFOS123.
20. Refojo M. Tear Evaporation Considerations and Contact Lens Wear. Considerations in Contact Lens Use under Adverse Conditions. Washington, DC: National Academies Press. 1991.
21. Korb DR. Tear film—contact lens interactions. In: Sullivan DA (ed). *Lacrimal Gland, Tear Film, and Dry Eye Syndromes.* Advances in Experimental Medicine and Biology. Vol 350. Boston, MA: Springer. 1994:403-10.
22. Guillon M, Guillon JP. Hydrogel lens wettability during overnight wear. *Ophthalmic Physiol Opt.* 1989;9(4):355-9.
23. Maldonado-Codina C, Efron N. Dynamic wettability of pHEMA-based hydrogel contact lenses. *Ophthalmic Physiol Opt.* 2006;26(4):408-18.
24. Lin M, Copley KA, Radke CJ. Assessment of pre-lens tear film stability by slit-lamp examination, placido ring reflection, IBUT and advancing contact angles: do they correlate? *Invest Ophthalmol Vis Sci.* 2006;47(13):95.
25. McMonnies CW. Incomplete blinking: exposure keratopathy, lid wiper epitheliopathy, dry eye, refractive surgery and dry contact lenses. *Contact Lens Anterior Eye.* 2007;30(1):37-51.
26. Stahl U, Jalbert I. Exploring the links between contact lens comfort, osmolarity and lid wiper staining. *Contact Lens Anterior Eye.* 2018;41(1):110-6.
27. Nichols KK, Redfern RL, Jacob JT, et al. The TFOS International Workshop on Contact Lens Discomfort: report of the definition and classification subcommittee. *Invest Ophthalmol Vis Sci.* 2013;54(11).
28. Jones L, Varikooty J, Keir N, et al. The evaluation of lid wiper epitheliopathy in contact lens wearers in a controlled low humidity environmental exposure chamber. *Invest Ophthalmol Vis Sci.* 1977;54(15):5475.
29. Markoulli M, Isa NA, Pappas EB. Temporal characteristics of sodium fluorescein in the tear meniscus. *Optom Vis Sci.* 2017;94(2):166-73.
30. Lievens CW, Norgett Y, Briggs N, et al. Optimal methodology for lid wiper epitheliopathy identification. *Contact Lens Anterior Eye.* May 14, 2020. [Epub ahead of print].
31. Wolffsohn JS, Arita R, Chalmers R, et al. TFOS DEWS II Diagnostic Methodology report. *Ocul Surf.* 2017;15(3):539-74.
32. Lin MC, Yeh TN. Mechanical complications induced by silicone hydrogel contact lenses. *Eye Contact Lens Sci Clin Pract.* 2013;39(1):114-23.
33. Craig JP, Muntz A, Wang MTM, et al. Six-month therapeutic profiles of lipid and non-lipid-based artificial tear supplements in managing dry eye. Poster presented at American Academy of Optometry Meeting 2020.
34. Varikooty J, Srinivasan S, Subbaraman L, et al. Variations in observable lid wiper epitheliopathy (LWE) staining patterns in wearers of silicone hydrogel lenses. *Contact Lens Anterior Eye.* 2015;38:471-76.
35. Schulze M-M, Srinivasan S, Hickson-Curran SB, et al. Lid wiper epitheliopathy in soft contact lens wearers. *Optom Vis Sci.* 2016;93(8):943-54.
36. Nichols JJ, Lievens CW, Bloomstein MR, et al. Dual-polymer drops, contact lens comfort, and lid wiper epitheliopathy. *Optom Vis Sci.* 2016;93(8):979-86.
37. Best N, Drury L, Wolffsohn JS. Predicting success with silicone-hydrogel contact lenses in new wearers. *Contact Lens Anterior Eye.* 2013;36(5):232-7.
38. Deng Z, Wang J, Jiang H, et al. Lid wiper microvascular responses as an indicator of contact lens discomfort. *Am J Ophthalmol.* 2016;170:197-205.
39. Varikooty J, Lay B, Jones L. Optimization of assessment and grading for lid wiper epitheliopathy. *Optom Vis Sci.* 2012;88.
40. Muntz A, Subbaraman LN, Craig JP, Jones L. Cytomorphological assessment of the lid margin in relation to symptoms, contact lens wear and lid wiper epitheliopathy. *Ocul Surf.* 2020;18(2):214-20.
41. Pult H, Murphy PJ, Purslow C. A novel method to predict the dry eye symptoms in new contact lens wearers. *Optom Vis Sci.* 2009;86(9):E1042-50.

# RETINAUPDATE2020

DECEMBER 4–5, 2020

 VIRTUAL EVENT

## CHAIR



**Mohammad Rafieetary, OD, FAAO**

Consultative Optometric  
Physician  
Charles Retina Institute  
Germantown, TN

## TOPIC AREAS INCLUDE

- Diabetic Retinopathy
- Macular Disease
- AMD
- Peripheral Retina

## REGISTRATION

**Super early rate: \$149**  
Rate increases November 21: \$199

## CO-CHAIR



**Steven Ferrucci, OD, FAAO**

Chief, Optometry Section  
Sepulveda VA Medical Center  
Sepulveda, CA

## ORS MISSION STATEMENT

The mission of the Optometric Retina Society (ORS) is to promote the advancement of vitreoretinal knowledge for clinicians, ophthalmic educators, residents, and students. The ORS is dedicated to posterior segment disease prevention, diagnosis, management and co-management.

\*Earn up to 8 LIVE COPE Credits and 4 Enduring Online Credits

To register visit:

[www.ReviewEdu.com/ORSRetUpdate2020](http://www.ReviewEdu.com/ORSRetUpdate2020)

e-mail: [ReviewMeetings@MedscapeLIVE.com](mailto:ReviewMeetings@MedscapeLIVE.com)



\*Approval pending

Partially supported by an unrestricted educational grant from Maculogix.

Review Education Group partners with Salus University for those ODs who are licensed in states that require university credit.



Administered by

**REVIEW**  
EDUCATION GROUP

# A MODERN APPROACH TO MEIBOMIAN GLAND DYSFUNCTION

Learn how to effectively identify, diagnose and treat this condition. **By Kambiz Silani, OD**

**M**eibomian gland dysfunction (MGD), a well-known driver of ocular surface disease, can prove challenging for both clinicians and patients. To provide effective care, clinicians must understand the causes of this condition and the underlying mechanisms at play. This article provides a closer look at the meibomian glands and the pathophysiology of MGD. It also delves into the clinical steps that can help patients prevent dysfunction. New imaging technologies are valuable tools not only for disease

assessment, but also patient education. The ability to properly guide the exam journey—from the diagnostic testing to treatment plan—is imperative for optimal outcomes and patient satisfaction.

## MGD Explained

Meibomian glands are sebaceous glands present within eyelids that secrete meibum, a compound made of lipids that form the superficial layer of the tear film. Meibum is delivered to the ocular surface, where it coats the aqueous layer and provides tear film stability and pro-

tection against microbial agents.<sup>1</sup> In healthy individuals, there are approximately 25 to 40 glands in the upper eyelid and about 20 to 30 in the lower eyelid with lengths of about 5.5mm in the upper eyelids and 2mm in each of the lower eyelids.<sup>2</sup>

Proper functioning of the glands serves to: (1) minimize tear film evaporation, (2) enhance the tear film stability, (3) provide a smooth optical surface for the cornea and (4) seal the opposing lid margins during sleep.<sup>3</sup>

A number of different factors

**Release Date:** November 15, 2020  
**Expiration Date:** November 15, 2023  
**Estimated Time to Complete Activity:** 2 hours

**Jointly provided by Postgraduate Institute for Medicine (PIM) and Review Education Group**

**Educational Objectives:** After completing this activity, the participant should be better able to:

- Discuss the cause of meibomian gland dysfunction.
- Describe the necessary clinical steps to help patients prevent gland dysfunction and ocular surface disease.
- Discuss the new imaging technologies that can help clinicians assess gland function.
- Review the diagnosis with patients and how treatment is changing their glands.

**Target Audience:** This activity is intended for optometrists engaged in the care of patients with meibomian gland dysfunction.

**Accreditation Statement:** In support of improving patient care, this activity has been planned and implemented by the Postgraduate



Institute for Medicine and Review Education Group. Postgraduate Institute for Medicine is jointly accredited by the Accreditation Council for Continuing Medical Education, the Accreditation Council for Pharmacy Education, and the American Nurses Credentialing Center, to provide continuing education for the healthcare team. Postgraduate Institute for Medicine is accredited by COPE to provide continuing education to optometrists.

**Faculty/Editorial Board:** Kambiz Silani, OD, chief clinical director of Beverly Hills Optometry.

**Credit Statement:** This course is COPE approved for 2 hours of CE credit. Course ID is **70084-AS**. Check with your local state licensing board to see if this counts toward your CE requirement for relicensure.

### Disclosure Statements:

*Dr. Silani* receives consulting fees from NuLids and fees for non-CME/CE services from Sight Sciences, Johnson and Johnson and Lumenis. *Managers and Editorial Staff:* The PIM planners and managers have nothing to disclose. The Review Education Group planners, managers and editorial staff have nothing to disclose.



may contribute to dysfunction of meibomian glands, which leads to dry eye disease and its characteristic ocular surface inflammation.

Of the estimated 30 to 40 million Americans with dry eye disease, 86% have some form of MGD.<sup>4</sup> This condition, defined as a chronic, progressive and diffuse abnormality of the meibomian glands, is commonly characterized by duct obstruction, static meibum, cystic dilation, abnormal gland secretion and eventual gland atrophy and dropout.<sup>1</sup> Obstruction of the meibomian glands reduces delivery of meibum to the lid margin and may present with or without inflammatory features.<sup>5</sup> Disruption of meibomian gland function negatively impacts both the quality and quantity of meibum secreted, which in turn affects ocular surface health through changes in tear film composition.<sup>1</sup>

In the early stages of MGD, anatomical changes are present even though patients are often asymptomatic. The lack of symptoms can cause delays in proper diagnosis and treatment. As the disease progresses, the tear film consistency and uniformity may be disrupted across the ocular surface, often leading to uncomfortable and sometimes intolerable symptoms.

Some of the most common ocular symptoms include eye fatigue, discharge, foreign body sensation, dryness, gritty or sticky sensation, eye pain, epiphora, itching, redness, light sensitivity, excessive blinking, blurred vision and a history of chalazion or hordeolum.<sup>1</sup> One method to identify these symptomatic patients is by integrating a standardized dry eye questionnaire (e.g., SPEED, OSDI, DEQ-5).

If left untreated, the stagnant meibum could lead to gland structure damage in the form of gland recession and atrophy. Of note,

when meibomian glands are treated in the early stages, it is possible to restore their function, potentially before recession and atrophy sets in.<sup>6</sup>

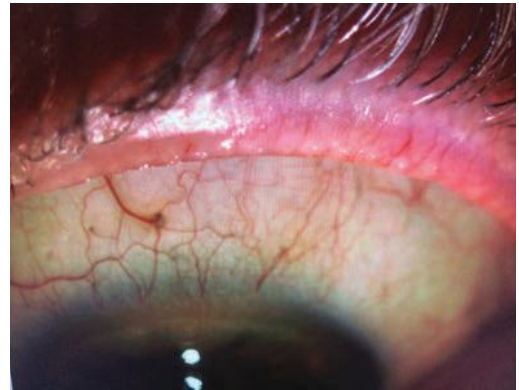### Gland Regeneration Controversy

Among eye care professionals, the general consensus was previously thought that meibomian gland atrophy was permanent. Recently, evidence suggests that some office-based treatments may modestly improve gland structure.<sup>7-9</sup> Specifically, thermal pulsation therapy, intense pulsed light (IPL) and meibomian gland probing have some potential to reverse gland atrophy.

In one study, IPL treatment improved the OSDI symptom score, meibomian gland function and macrostructure and eyelid hygiene. IPL treatment also improved meibomian gland microstructure and decreased meibomian gland inflammation in MGD patients.<sup>7</sup>

Another study suggests that intraductal meibomian gland probing in patients with obstructive MGD could lead to growth and regeneration of gland tissue. Meibomian gland probing works, in part, by the introduction of a stainless steel wire instrument (76µm in diameter) to the gland orifice and into the ductal outflow tract that relieves obstruction and maintains patency of the outflow channel. Interestingly, meibography of post-probing patients revealed an increase in meibomian gland tissue area and regrowth of atrophied glands.<sup>8</sup>

Research looking into thermal pulsation therapy shows up to a 10% improvement in visual gland structure of the lower lids in 69% of patients with MGD.<sup>9</sup> The potential to regenerate glands that have trun-



IPL can help remove telangiectasia in the eyelid margins of MGD patients.

cated is promising, although further research is necessary to reinforce these early findings and our understanding of true meibomian gland regeneration.

### Leading Causes

There is an extensive list of risk factors for dry eye disease and MGD. When reviewing patient history, keep these major contributing factors in mind:

**Hormone fluctuation.** Among women with a hormonal imbalance, current research suggests that sex hormone levels may influence meibomian gland gene expression and lipid production.<sup>10</sup>

**Cosmetics.** Another risk factor is the improper application and removal of eye makeup. The regular use of eyeliner induces tear film instability and MGD.<sup>11</sup> Additionally, common topical preservatives in cosmetics and topical drops may be toxic to the meibomian gland epithelial cells.<sup>12</sup>

**Medications.** Some drugs, such as antihistamines, antidepressants, birth control pills and blood pressure medicine, can cause MGD.<sup>13</sup> For instance, glaucoma drops have potential adverse effects on the cornea and ocular surface. Specifically, prostaglandin analogs are associated with both a higher prevalence and severity of obstructive MGD.<sup>14</sup>

When looking at certain oral medications such as Accutane (isotretinoin), research shows this class of medication can alter the quality of the meibum or reduce the vitality of the glands as a whole.<sup>15,16</sup>

**Digital devices.** A notable risk factor for MGD is infrequent and improper blinking, especially when using digital devices, as this leads to stagnant oils and damage to the meibomian gland anatomy.<sup>17</sup>

**Other causes.** Research has uncovered a number of other risk factors, including:<sup>18-22</sup>

- increased age
- female gender
- certain medical conditions such as diabetes, rosacea and autoimmune conditions
- poor diet
- allergies
- laser eye surgery and cataract surgery
- contact lens overwear
- dry climate or low humidity
- windy conditions
- exposure to smoke
- bacterial/*Demodex* overgrowth

## Diagnostics

Modern imaging and point-of-care testing elevate the patient care experience by providing valuable diagnostic metrics. A robust dry eye workup helps set a baseline, the

characteristics of which include the following six diagnostic tests:

**Evaluation of the eyelid anatomy.** Lid margin assessment with a slit lamp or external photography can rule out vascular engorgement, plugged meibomian gland orifices, displacement of the mucocutaneous junction and overgrowth of *Demodex*/bacteria.<sup>23,24</sup>


**Meibography.** This is a useful tool to help clinicians grade the anatomy of the meibomian glands. There are two commonly used scales with a grading of 0 to 3 or 0 to 4, where 0 represents no disease and grades 3 and 4 represent end-stage disease with loss of more than 67% (grade 3 max scale) or more than 75% (grade 4 max scale) of the gland structure. These grading systems are useful to group patients by disease severity (normal, mild, moderate, severe).<sup>25</sup>

**Tear film break-up time (TBUT).** This is a standard, reliable and repeatable metric that determines which areas of the tear film are more susceptible to quicker evaporation and, therefore, have a higher potential for ocular surface dryness and damage.<sup>26</sup> TBUT can be performed with fluorescein dye during slit lamp examination, while non-invasive TBUT can be performed with a specialized device that requires no drops or dyes.

**Meibometry.** When grading the function of the meibomian glands, evaluate the flow of the meibum with moderate digital pressure. This can be applied with a cotton swab or a meibomian gland expressor (Johnson & Johnson Vision). One commonly accepted grading system uses a scale of 0 to 3, where grade 0 represents no secretion of meibum (severe), grade 1 is inspissated, toothpaste-like consistency (moderate), grade 2 is cloudy, diffuse turbid fluid (mild) and grade 3 is clear, normal meibum.<sup>25</sup>

**Inflammatory marker.** Clinicians can assess matrix metalloproteinase-9 (MMP-9) levels using the MMP-9 test (InflammaDry, Quidel), a single-use, rapid-result test. When performing the in-office test, a tear film sample is collected and the results are displayed in 10 minutes as either positive or negative depending on whether the concentration of MMP-9 levels are greater or less than 40ng/ml. Awareness of the presence or absence of inflammation on the ocular surface aids in clinical decision making and the treatment plan.<sup>27</sup>

**Tear osmolarity.** TearLab is an easy-to-use, handheld diagnostic instrument that uses disposable, test cards to measure the solute concentration of tears. The results are considered abnormal, indicating a loss



**This patient presented with evidence of gland dropout and evaporative dry eye secondary to obstructive MGD. He was treated with BlephEx, immediately followed by LipiFlow. Non-invasive TBUT improved significantly pre- and post-LipiFlow treatment (left and right, respectively).**

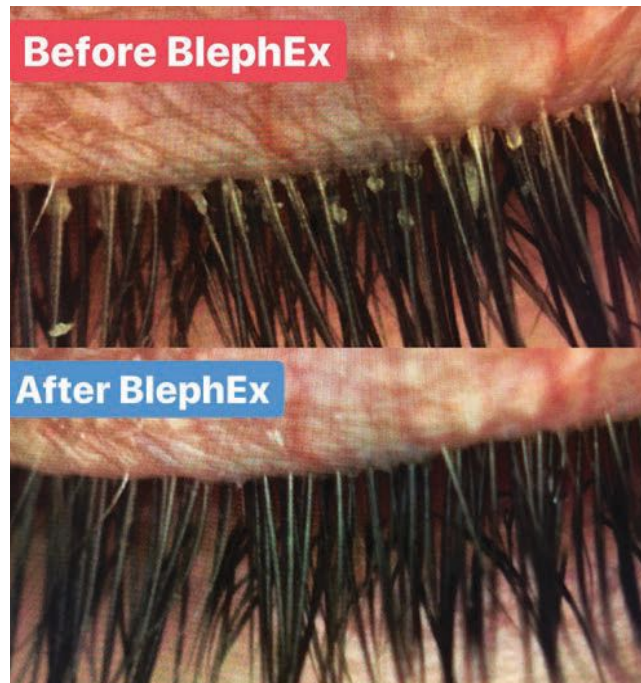
of homeostasis, when either eye has an osmolarity of greater than 300mOsm/L or there is a difference greater than 8mOsm/L between the eyes. Loss of meibum expression in patients with obstructive MGD leads to increased evaporation of water, increased tear osmolarity and symptoms of MGD.<sup>28</sup>

### Office-based Treatments

Vast advances have been made in the management of MGD, leading to a number of new treatment options for an otherwise complex disease process. When using office-based therapeutics, consider a three-step approach: lid margin hygiene, removal of obstruction and reduction or elimination of inflammation. These three treatment categories are synergistic and most effective when performed earlier in the disease process, before patients reach end-stage MGD with significant gland atrophy and dropout.

**Microblepharoxfoliation.** Early biofilm may seal off the gland orifices and gradually fill the gland, mixing with meibum and leading to chronic lid disease and discomfort. Lid debridement can remove biofilm and debris and uncap the openings of the oil glands. There are two electronic debridement devices, BlephEx and AB Max (Myco Industries), as well as a new manual debridement technique with Zocular Eyelid System Treatment (ZEST, Zocular).

A recent study demonstrated that one ZEST session improved contact lens-related discomfort, doubled contact lens wear time, decreased usage of rewetting drops and reduced MMP-9 levels.<sup>29</sup>



**Advances in the management of MGD include a number of office-based therapeutics, such as BlephEx. Lid debridement helps remove biofilm and debris and uncap the openings of the oil glands.**

#### *Thermal expression options.*

These thermal modalities heat the meibum and melt the stagnant oils, allowing for proper expression and clearance. For patients with obstructive MGD, consider following lid debridement with thermal expression to maximize the therapeutic efficacy. Applying lid debridement pre-thermal expression removes surface biofilm and allows for easier outflow of meibum post-thermal expression. A number of office-based devices are available, including LipiFlow (Johnson & Johnson Vision), TearCare (Sight Sciences), iLux (Alcon), MiBo Thermoflo (MiBo Medical Group) and Thermal 1-Touch (Ocusoft).

LipiFlow treats the root cause of MGD. One study looked at the benefits of this treatment for contact lens wearers with MGD. Data shows that a single vectored pulsation treatment increased comfortable wearing time by approximately four hours per day.<sup>30</sup>

A single treatment with TearCare, a portable tool that addresses obstructive MGD, can provide a safe and successful improvement in signs and symptoms of dry eye disease in patients with MGD.

Researchers also compared the treatment with LipiFlow, where TearCare met non-inferiority treatment standards.<sup>31</sup> In a randomized clinical trial there were no statistically significant differences between the iLux system and LipiFlow.<sup>32</sup>

The MiBo Thermoflo system and the Thermal 1-Touch device both heat and melt solidified oils that have become stuck inside the meibomian glands and should be followed immediately by manual gland expres-

sion. Researchers found that MiBo Thermoflo treatment resulted in a statistically significant improvement in the condition of the eyelids.<sup>33</sup>

To date, there are no studies on the Thermal 1-Touch device.

The MiBo Thermoflo requires a doctor, technician or staff member to apply the heat, while the Thermal 1-Touch device, similar to a trial frame, is placed on the patient and heats automatically.

Neither device has disposable options; therefore, they must be sterilized thoroughly prior to each patient use.

**Intense pulsed light.** This treatment addresses telangiectasia, lid swelling and inflammation. Through the use of photobiomodulation properties, IPL selectively targets abnormal blood vessels leaking inflammatory mediators, heats and liquifies meibum, eradicates *Demodex* and suppresses MMP-9 levels.<sup>34</sup> Multiple studies show that

### Billing Tips

Dry eye visits, point-of-care testing, external photography and minor surgical procedures are often covered by medical plans if billed properly. When submitting a claim for office visits, you may bill the initial dry eye consultation as well as any necessary follow-up appointments. To bill for point-of-care testing, you must apply for a CLIA waiver. Once a CLIA waiver for lab testing has been obtained, tests such as InflammDry and TearLab may be performed at the approved facility.

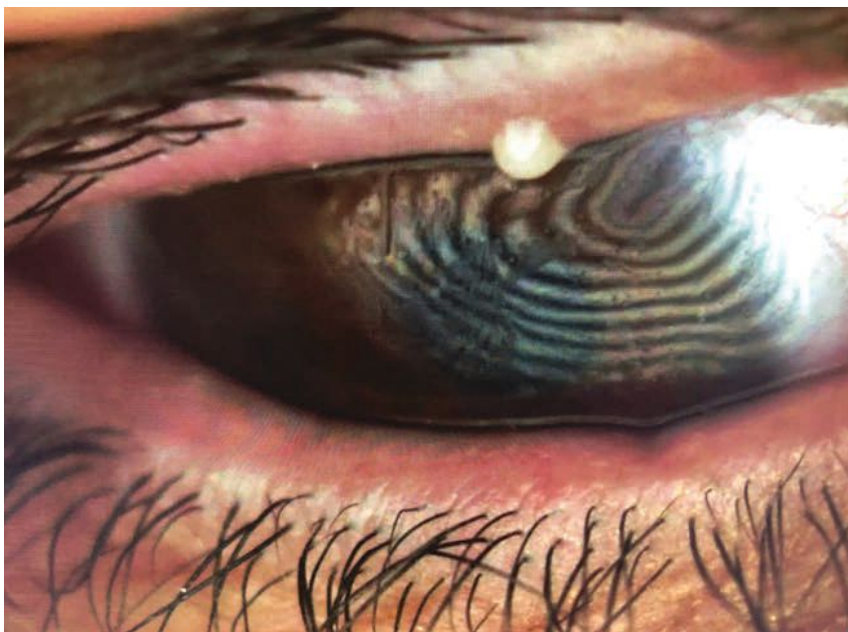During the dry eye workup, external photography is considered billable when linked with an appropriate diagnosis such as corneal neovascularization, external hordeolum or anterior blepharitis secondary to *Demodex* infestation. Unfortunately, meibography, which was previously billable under external photography, now has its own level three CPT code and is no longer payable until the new code is considered a level one CPT code. Of the office-based treatments, only two have billable codes: punctal plugs and amniotic membranes. Unfortunately, neither of these address the obstruction, lid hygiene and ocular surface inflammation concerns.

Although lid debridement, thermal expression and IPL devices do not have reimbursable codes, our patients recognize the importance of early detection and intervention with these treatments to preserve the gland structures and function.

IPL combined with gland expression provides significant improvement in objective and subjective findings.<sup>35</sup> As a bonus, post-IPL patients may also notice skin rejuvenation effects such as reduction in sunspots, minimization of vascular lesions and stimulation in collagen growth, leading to improvement in fine lines and wrinkles.

### At-home Eye Care

Setting a customized home routine for MGD patients may enhance the effects of office-based treatment and allows for continued maintenance between follow-up visits. This can be analogous to a patient visiting their dentist, where a deep cleaning is performed while stressing the importance of maintaining proper



Imaging shows lid engorgement, telangiectasia and blocked meibomian glands with a milky, thick appearance (grade 1 on meibometry).

dental hygiene between visits.

Depending on your patient's signs and symptoms of MGD, consider the following at-home routine:

**Eyelid cleansers.** Hypochlorous acid (HOCL) and tea tree oil are effective at targeting bacterial overgrowth and eliminating *Demodex*, respectively.<sup>31,32</sup> HOCL is a powerful, natural compound that kills a broad spectrum of bacteria without altering the floral diversity on the periocular skin.<sup>36</sup> It also successfully helps relieve chronic eye conditions, such as dry eye, blepharitis, MGD, contact lens intolerance and inflammation. Additionally, tea tree oil has proven effective in treating MGD associated with *Demodex*.<sup>37</sup> Clean eyelid margins provide lasting relief and create healthier and happier MGD patients.

**Warm compress therapy.** Some patients will use a warm washcloth or other "do-it-yourself" methods of creating a pseudo-compress. These may be ineffective at properly maintaining and distributing the heat for a five- to 10-minute timeframe. Using an antimicrobial warm compress once or twice daily provides sustained, deep penetrating moist heat to the eyelids, leading to improvement of MGD.<sup>38</sup>

**Omega fatty acids.** Oral supplementation and consumption of omega-3 fatty acids can improve the meibum quality and expression.<sup>39</sup> It is associated with a statistically significant improvement in tear osmolarity, TBUT, MMP-9 and OSDI symptom scores.<sup>40</sup>

**Artificial tears.** When considering lubricating drops for evaporative dry eye patients, clinicians should select ones with a higher viscosity to support abnormal lipid layer.

**At-home debridement.** The NuLids system (NuSight Medical) is a handheld device for at-home treatment of MGD and blepharitis. The oscillating action of the dispos-

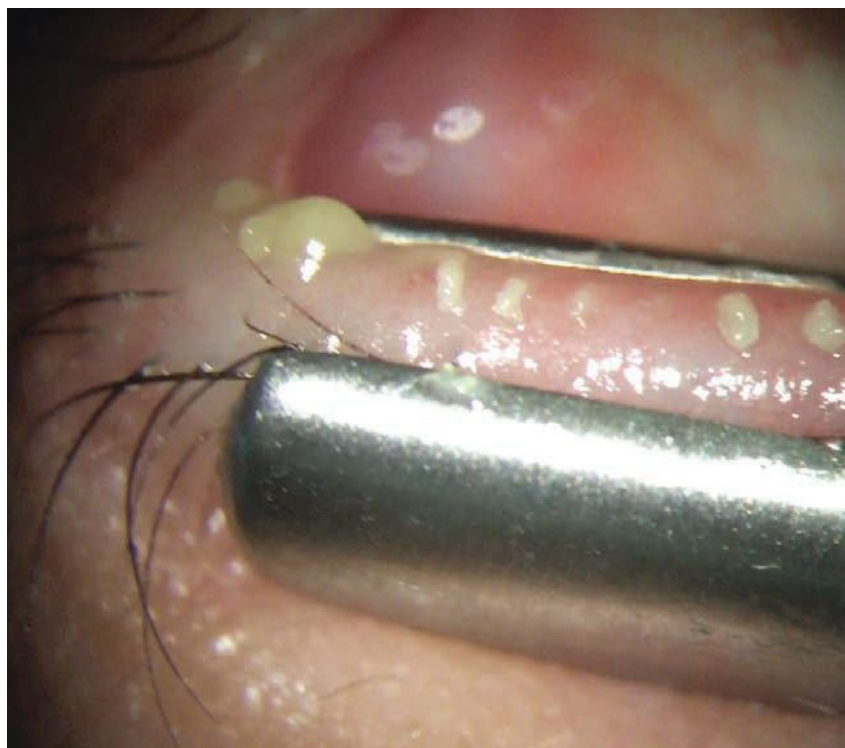able tip cleans the lid margins and is designed to reduce the biomass load, remove collarettes, uncap blocked glands and stimulate production of meibum.

**Lifestyle modifications.** Discussing lifestyle adjustment is equally important to maximize success. Depending on various factors, some recommendations to consider for your MGD patients include increasing water intake, modifying diet, improving computer ergonomics and reviewing blink exercise techniques and proper cosmetic application and removal.

To provide comprehensive patient care, clinicians must understand MGD and its mechanisms. Additionally, imaging can be used to educate patients on the role of the meibomian glands and emphasize the importance of lid hygiene. This lays the foundation for success while motivating patients to collaborate with their clinician to create a treatment plan that aligns with their lifestyle and clinical goals. ■

*Dr. Silani is the chief clinical director of Beverly Hills Optometry in Beverly Hills, Calif.*

1. Chhadva P, Goldhardt R, Galor A. Meibomian gland disease: the role of gland dysfunction in dry eye disease. *Ophthalmology*. 2017;124(11S):S20-S26.
2. Knop E, Knop N, Millar T, et al. The international workshop on meibomian gland dysfunction: report of the subcommittee on anatomy, physiology, and pathophysiology of the meibomian gland. *Invest Ophthalmol Vis Sci*. 2011;52(4):1938-78.
3. Paulsen AJ, Cruickshanks KJ, Fischer ME, et al. Dry eye in the Beaver Dam Offspring Study: prevalence, risk factors, and health-related quality of life. *Am J Ophthalmol*. 2014;157(4):799-806.
4. Lemp MA, Crews LA, Bron AJ, et al. Distribution of aqueous-deficient and evaporative dry eye in a clinic-based patient cohort: a retrospective study. *Cornea*. 2012;31(5):472-8.
5. Korb DR, Henriquez AS. Meibomian gland dysfunction and contact lens intolerance. *J Am Optom Assoc*. 1980;51:243-51.
6. Kim S, Blackie CA, Korb DR. Restoration of meibomian gland function after treatment for meibomian gland dysfunction. *Invest Ophthalmol Vis Sci*. 2012;53(14):601.
7. Yin Y, Liu N, Gong L, et al. Changes in the meibomian gland after exposure to intense pulsed light in meibomian gland dysfunction (MGD) patients. *Curr Eye Res*. 2018;43(3):308-13.
8. Maskin SL, Testa WR. Growth of meibomian gland tissue after intraocular meibomian gland probing in patients with obstructive meibomian gland dysfunction. *Br J Ophthalmol*. 2018;102:59-68.
9. Hura A, Epitropoulos A, Czyz C, et al. The potential effect of LipiFlow on meibomian gland structure: A preliminary analysis utilizing dynamic meibomian imaging. *Invest Ophthalmol Vis Sci*. 2018;59:935.
10. Versura P, Giannaccare G, Campos EC. Sex-steroid imbalance in females and dry eye. *Curr Eye Res*. 2015;40(2):162-75.
11. Prabhawat P, Chirapapaisan C, Chitkornkijsin C, et al. Eyeliner induces tear film instability and meibomian gland dysfunction. *Cornea*. 2020;39(4):473-8.



**Modern imaging and point-of-care testing, including meibometry, offers valuable diagnostic metrics and helps reveal the severity of MGD.**

12. Wang J, Liu Y, Kam WR, et al. Toxicity of the cosmetic preservatives parabens, phenoxyethanol and chlorphenesin on human meibomian gland epithelial cells. *Exp Eye Res*. 2020;196:108057.
13. Fraunfelder FT, Sciubba JJ, Mathers WD. The role of medications in causing dry eye. *J Ophthalmol*. 2012;2012:285851. [correction: *J Ophthalmol*. 2019;2989680].
14. Mocan MC, Uzunosmanoglu E, Kocabeyoglu S, et al. The association of chronic topical prostaglandin analog use with meibomian gland dysfunction. *J Glaucoma*. 2016;25(9):770-4.
15. Yeh T. Effects of isotretinoin on meibomian glands. *UC Berkeley*. 2019. <https://escholarship.org/uc/item/3mm9k54s>. Accessed October 8, 2020.
16. Moy A, McNamara NA, Lin MC. Effects of isotretinoin on meibomian glands. *Optom Vis Sci*. 2015;92(9):925-30.
17. Sheppard AL, Wolffsohn JS. Digital eye strain: prevalence, measurement and amelioration. *BMJ Open Ophthalmol*. 2018;3(1):e000146.
18. Nien CJ, Massei S, Lin G, et al. Effects of age and dysfunction on human meibomian glands. *Arch Ophthalmol*. 2011;129(4):462-9.
19. Park Y, Hwang HB, Kim HS. Observation of influence of cataract surgery on the ocular surface. *PLoS One*. 2016;11(10):e0152460.
20. Kwan JT, Opitz DL, Hom MM, et al. Gender differences in a meibomian gland dysfunction-specific symptom questionnaire. *Invest Ophthalmol Vis Sci*. 2014;55:22.
21. WebMD. What is meibomian gland dysfunction? [www.webmd.com/eye-health/meibomian-gland-dysfunction](http://www.webmd.com/eye-health/meibomian-gland-dysfunction). Accessed October 8, 2020.
22. Markoulli M, Kolanu S. Contact lens wear and dry eyes: challenges and solutions. *Clin Optom*. 2017;9:41-8.
23. Jester JV, Parfitt GJ, Brown DJ. Meibomian gland dysfunction: hyperkeratinization or atrophy? *BMC Ophthalmol*. 2015;15(Suppl 1):156.
24. Mudgil P, Borchman D, Yappert MC, et al. Lipid order, saturation and surface property relationships: A study of human meibum saturation. *Exp Eye Res*. 2013;116:79-85.
25. Tomlinson A, Bron AJ, Korb DR, et al. The international workshop on meibomian gland dysfunction: report of the diagnosis subcommittee. *Invest Ophthalmol Vis Sci*. 2011;52(4):2006-49.
26. Tsubota K. Short tear film breakup time—type dry eye. *Invest Ophthalmol Vis Sci*. 2018;59(14):DES64-70.
27. Lanza NL, Valenzuela F, Perez VL, et al. The matrix metalloproteinase 9 point-of-care test in dry eye. *Ocul Surf*. 2016;14(2):189-95.
28. Mathers WD, Shields WJ, Sachdev MS, et al. Meibomian gland morphology and tear osmolality: changes with Accutane therapy. *Cornea*. 1991;10:286-90.
29. Narayanan S, Kasraie N, Stewart M, et al. Lid margin debridement improves contact lens discomfort caused by meibomian gland dysfunction. *Invest Ophthalmol Vis Sci*. 2019;60(9):6368.
30. Blackie CA, Coleman CA, Nichols KK, et al. A single vectored thermal pulsation treatment for meibomian gland dysfunction, increases mean comfortable contact lens wearing time by approximately 4 hours per day. *Clin Ophthalmol*. 2019;12:169-83.
31. Loh J, Trattler WB, Dhamdhere KP, et al. A novel, targeted, open eye, thermal therapy and meibomian gland clearance in treatment of dry eye: A randomized control trial (OLYMPIA). American Society of Cataract and Refractive Surgery (ASCRS) Virtual Annual Meeting. May 16, 2020.
32. Tauber J, Owen J, Bloomstein M, et al. Comparison of the iLUX and the LipiFlow for the treatment of meibomian gland dysfunction and symptoms: A randomized clinical trial. *Clin Ophthalmol*. 2020;14:405-18.
33. Connor CG, Narayanan S, Miller WL. The efficacy of MiBo Thermoflo in treatment of meibomian gland dysfunction. *Invest Ophthalmol Vis Sci*. 2016;57(12):5678.
34. Dell SJ. Intense pulsed light for evaporative dry eye disease. *Clin Ophthalmol*. 2017;11:1167-73.
35. Dell SJ, Gaster RN, Barbarino SC, et al. Prospective evaluation of intense pulsed light and meibomian gland expression efficacy on relieving signs and symptoms of dry eye disease due to meibomian gland dysfunction. *Clin Ophthalmol*. 2017;11:817-27.
36. Stromm DW, Mintun K, Epstein AB, et al. Reduction in bacterial load using hypochlorous acid hygiene solution on ocular skin. *Clin Ophthalmol*. 2017;11:707-14.
37. Maher TN. The use of tea tree oil in treating blepharitis and meibomian gland dysfunction. *Oman J Ophthalmol*. 2018;11(1):11-15.
38. Olson MC, Korb DR, Greiner JV. Increase in tear film lipid layer thickness following treatment with warm compresses in patients with meibomian gland dysfunction. *Eye Contact Lens*. 2003;29(2):96-9.
39. Liu Y, Kam WR, Sullivan DA. Influence of omega 3 and 6 fatty acids on human meibomian gland epithelial cells. *Cornea*. 2016;35(8):1122-6.
40. Epitropoulos AT, Donnerfeld ED, Shah ZA, et al. Effect of oral re-esterified omega-3 nutritional supplementation on dry eyes. *Cornea*. 2016;35(9):1185-91.

## OSC QUIZ

**Y**ou can obtain continuing education credit through the Optometric Study Center. Complete the test form and return it with the \$35 fee to: Jobson Healthcare Information, LLC, Attn.: CE Processing, 395 Hudson Street, 3rd Floor New York, New York 10014. To be eligible, please return the card within three years of publication. You can also access the test form and submit your answers and payment via credit card at *Review Education Group* online, [revieweducationgroup.com](http://revieweducationgroup.com).

You must achieve a score of 70 or higher to receive credit. Allow four weeks for processing. For each Optometric Study Center course you pass, you earn 2 hours of credit from Pennsylvania College of Optometry.

Please check with your state licensing board to see if this approval counts toward your CE requirement for relicensure.

- For healthy individuals, how many meibomian glands are in the lower eyelids?
  - 25 to 40.
  - 10 to 20.
  - 20 to 30.
  - 40 to 50.
- What is the leading cause of dry eye disease?
  - MGD.
  - Makeup.
  - Contact lens wear.
  - Decreased water intake.
- Regular use of cosmetics such as eyeliner may:
  - Lengthen the oil gland structures.
  - Improve contact lens comfort.
  - Induce tear film instability.
  - Reduce dry eye symptoms.
- Properly functioning meibomian glands serve to:
  - Maximize tear film evaporation.
  - Enhance the tear film stability.
  - Unseal the lid margins during sleep.
  - All of the above.
- What is the average length of the glands in the upper eyelids?
  - 2mm.
  - 7mm.
  - 1mm.
  - 5.5mm.
- MGD is commonly characterized by:
  - Duct obstruction.
  - Static meibum.
  - Abnormal gland secretion.
  - All of the above.
- Which of the following is an example of a validated dry eye questionnaire?
  - SPEED.
  - OSDI.
  - RUN.
  - Both a and b.
- Which of the following is a common ocular symptom with dry eye and MGD?
  - Eye fatigue.
  - Blurry vision.
  - Epiphora.
  - All of the above.
- Research suggest that \_\_\_\_\_ is a common cause of MGD in women.
  - Beta-blockers.
  - Abnormal lacrimal gland.
  - Hormone imbalance.
  - Mediterranean diet.
- Which of the following cosmetics induces MGD?
  - Lipstick.
  - Eyeliner.
  - Hairspray.
  - None of the above.
- Which of the following systemic drugs can cause MGD?
  - Antihistamines.
  - Antidepressants.
  - Birth control.
  - All of the above.
- Which of these are helpful modern imaging devices and techniques to assess MGD?
  - Meibography.
  - Tear break-up time.
  - Meibometry.
  - All of the above.
- Which of the following is a point-of-care diagnostic test available for dry eye testing and MGD?
  - InflammaDry.
  - Meibography.
  - Schirmer's test.
  - Phenol red thread test.
- What would be considered an abnormal tear osmolarity result?
  - 285mOsm/L OD and 290mOsm/L OS.
  - 330mOsm/L OD and 315mOsm/L OS.
  - 298mOsm/L OD and 299mOsm/L OS.
  - 280mOsm/L OD and 287mOsm/L OS.
- When using office-based treatments for MGD, which of the following therapeutic techniques may be beneficial?
  - Lid margin hygiene.
  - Removal of obstruction.
  - Reduction or elimination of inflammation.
  - All of the above.
- IPL can help to address which of the following?
  - Aqueous deficiency.
  - Telangiectasia.
  - High intraocular pressure.
  - Uveitis.
- Which of the following is a thermal expression device?
  - BlephEx.
  - ZEST.
  - TearCare.
  - Meibomian gland probing.
- Which of the following is an at-home device to help patients treat MGD and blepharitis?
  - iLux.
  - ABMax.
  - Optima M22.
  - NuLids.
- Which treatment is most effective for patients with evaporative dry eye?
  - Artificial tears with lower viscosity.
  - Artificial tears with higher viscosity.
  - Xalatan.
  - Patanol.
- Which office-based treatment has evidence to suggest modest improvement in gland regrowth?
  - Meibomian gland probing.
  - IPL.
  - Thermal pulsation therapy.
  - All of the above.

# Examination Answer Sheet

## A Modern Approach to Meibomian Gland Dysfunction

Valid for credit through November 15, 2023

**Online:** This exam can be taken online at [revieweducationgroup.com](http://revieweducationgroup.com). Upon passing the exam, you can view your results immediately and download a real-time CE certificate. You can also view your test history at any time from the website.

**Directions:** Select one answer for each question in the exam and completely darken the appropriate circle. A minimum score of 70% is required to earn credit.

**Mail to:** Jobson Healthcare Information, LLC, Attn.: CE Processing, 395 Hudson Street, 3rd Floor New York, New York 10014

**Payment:** Remit \$35 with this exam. Make check payable to Jobson Healthcare Information, LLC.

**Credit:** This course is COPE approved for 2 hours of CE credit. Course ID is 70084-AS.

**Jointly provided by Postgraduate Institute for Medicine and Review Education Group.**

**Salus University has sponsored the review and approval of this activity.**

**Processing:** There is a four-week processing time for this exam.

### Answers to CE exam:

1.  A  B  C  D
2.  A  B  C  D
3.  A  B  C  D
4.  A  B  C  D
5.  A  B  C  D
6.  A  B  C  D
7.  A  B  C  D
8.  A  B  C  D
9.  A  B  C  D
10.  A  B  C  D
11.  A  B  C  D
12.  A  B  C  D
13.  A  B  C  D
14.  A  B  C  D
15.  A  B  C  D
16.  A  B  C  D
17.  A  B  C  D
18.  A  B  C  D
19.  A  B  C  D
20.  A  B  C  D

### Post-activity evaluation questions:

Rate how well the activity supported your achievement of these learning objectives:

1=Poor, 2=Fair, 3=Neutral, 4=Good, 5=Excellent

21. Discuss the cause of meibomian gland dysfunction. ① ② ③ ④ ⑤
22. Describe the necessary clinical steps to help patients prevent gland dysfunction and ocular surface disease. ① ② ③ ④ ⑤
23. Discuss the new imaging technologies that can help clinicians assess gland function. ① ② ③ ④ ⑤
24. Review diagnosis with patients and how treatment is changing their glands. ① ② ③ ④ ⑤

25. Based upon your participation in this activity, do you intend to change your practice behavior? (choose only one of the following options)

- A I do plan to implement changes in my practice based on the information presented.  
 B My current practice has been reinforced by the information presented.  
 C I need more information before I will change my practice.

26. Thinking about how your participation in this activity will influence your patient care, how many of your patients are likely to benefit? (please use a number):

27. If you plan to change your practice behavior, what type of changes do you plan to implement? (check all that apply)

- a Apply latest guidelines  b Change in pharmaceutical therapy  c Choice of treatment/management approach  
 d Change in current practice for referral  e Change in non-pharmaceutical therapy  f Change in differential diagnosis  g Change in diagnostic testing  h Other, please specify: \_\_\_\_\_

28. How confident are you that you will be able to make your intended changes?

- a Very confident  b Somewhat confident  c Unsure  d Not confident

Please retain a copy for your records. Please print clearly.

First Name

Last Name

E-Mail

The following is your:  Home Address  Business Address

Business Name

Address

City  State

ZIP

Telephone #  -  -

Fax #

OE Tracker Number

By submitting this answer sheet, I certify that I have read the lesson in its entirety and completed the self-assessment exam personally based on the material presented. I have not obtained the answers to this exam by any fraudulent or improper means.

Signature \_\_\_\_\_ Date \_\_\_\_\_

Lesson 120435

RO-OSC-1120

29. Which of the following do you anticipate will be the primary barrier to implementing these changes?

- a Formulary restrictions  
 b Time constraints  
 c System constraints  
 d Insurance/financial issues  
 e Lack of interprofessional team support  
 f Treatment related adverse events  
 g Patient adherence/compliance  
 h Other, please specify: \_\_\_\_\_

30. Additional comments on this course:

\_\_\_\_\_  
\_\_\_\_\_  
\_\_\_\_\_  
\_\_\_\_\_

Rate the quality of the material provided:

1=Strongly disagree, 2=Somewhat disagree, 3=Neutral, 4=Somewhat agree, 5=Strongly agree

31. The content was evidence-based.

- ① ② ③ ④ ⑤

32. The content was balanced and free of bias.

- ① ② ③ ④ ⑤

33. The presentation was clear and effective.

- ① ② ③ ④ ⑤

# How to Add Ortho-K to Your Toolkit

This valuable service may require thorough education but will provide enormous benefits to your patients and practice. **By Dan Fuller, OD**

Practitioners have been called upon to adopt an unprecedented amount of flexibility due to the uncertainties caused by the COVID-19 pandemic. Business plans that were forward-looking into one-, three- or even five-year periods must now require significant revision. It may seem odd to discuss adding new services to your practice while trying to recover losses to your core business, but it is essential to address both the immediate needs and the growth of your practice. Looking for ways to capture new patients, offer new services to existing patients and grow your practice remain crucial aspects of your business even during a crisis.

In his venerable work *Out of the Crisis*, W. Edwards Deming presented 14 key management points.<sup>1</sup> The first of which is, “Create constancy of purpose toward improvement of product and service, with the aim to become competitive, to stay in

business and to provide jobs.” You can leverage existing resources to add orthokeratology (ortho-K) to your practice without a large capital investment. This article offers both strategic and practical ideas on how to incorporate ortho-K into your business plan.

Setting up a comprehensive myopia management program includes considerations of behavioral changes (e.g., more outdoor time), anti-muscarinic agents (primarily low-dose atropine), soft multifocal contact lens and overnight ortho-K interventions.<sup>2,3</sup>

Ortho-K lenses are sometimes, although rarely, prescribed for use during the day. Our colleagues outside the United States have access to other options, including novel spectacle lens designs, which are projected to become available in the United States in 2022.<sup>4,6</sup> Even if you do not have access to, or choose not to offer, pharmacological or spectacle interventions, you can offer the contact lens options. Regardless, remain informed of

approved and off-label technologies and future developments. If you don’t, your patients or their parents will.

## Program Administration

When dealing with special populations such as pediatric patients, you must obtain informed consent from the parents and assent from the patient, if possible. This process varies across the globe, but informed consent must be provided verbally and in writing with signatures from the responsible parties.<sup>7,8</sup> Copies of these documents should be retained in the patient’s file.

Provide the parent a packet of materials that includes the informed consent document, discussion of the procedure and device prescribed, schedule of visits, discussion of fees and what they cover, payment plans, warranties, how lost or damaged lenses will be replaced and cancellation policies. Also include training materials, a care kit, instructions for lens care and the handling and wearing



schedule. Provide clear guidance on what to do if they experience an adverse event and provide your after-hours contact information.

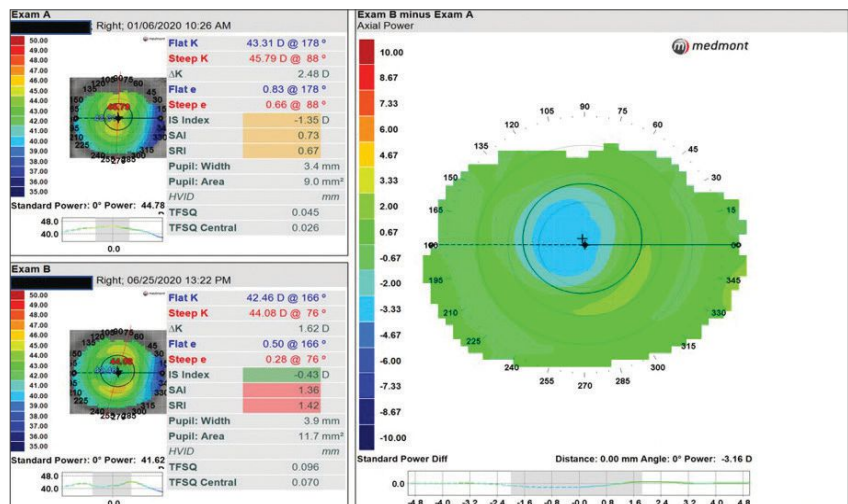
## Indications

Ortho-K lenses are enjoying a resurgence due to the worldwide myopia epidemic. They represent approximately 8% of the rigid contact lens market (0.7% of all contact lens fits) in the United States and 3% of all lens fits worldwide (range <1% to 30%).<sup>9,10</sup> The FDA requires optometrists to complete a certification course for each design before they can offer them in their practice (Table 1).<sup>11</sup> The indications for ortho-K include the temporary reduction of myopia, slowing of myopia progression and as an alternative for soft contact lens wearers experiencing dry eye.<sup>1,11,12</sup>

## Ortho-K Candidates

Above all else, the patient and/or parent needs to be motivated to partner with you in their care over an extended period of time. Ortho-K does not permanently correct myopia, and clinicians must carefully assess patient and parent expectations. Also, the effects regress after cessation of wear at variable rates for individual patients. Elimination or even slowing of myopia progression cannot be guaranteed, and adverse events (though uncommon) do happen. Patients with histories of non-compliance, allergies, preexisting lid or corneal disease may need to be treated to resolution prior to considering a fit.<sup>13-19</sup> The ability of the patient or family to comply with care, hygiene, handling and return visits, requires special consideration prior to embarking on any overnight wear of a contact lens.

None of the currently FDA-approved designs have an age



**Fig. 1. Subtractive axial maps in a successful ortho-K fit show successful reduction of refractive error and a well-centered treatment zone over the pupil.**

restriction. None of the designs approved in the United States possess an indication for myopia control. Outside the United States, the Bloom lens (Menicon) carries this indication.<sup>20</sup> Both adult and pediatric patients who have never worn a lens before may adapt faster than previous soft lens wearers who may be inclined to compare ortho-K designs with their habitual soft lenses.

Patients who have reduced their wearing time due to dryness or discomfort as well as those who wish to temporarily reduce their myopia make great candidates. If the intent is to slow myopia progression, then the earlier you identify onset and progression of myopia, the earlier you can intervene. Research has found a more rapid progression of their myopia in the year prior to onset and a slower rate after onset in children between six and 14 years old.<sup>21</sup>

## Evidence for Efficacy

The Blue Mountains Eye Study from Australia found myopic maculopathy increases with the amount of myopia, with 43% of cases occurring in myopes less than 5.00D.<sup>22</sup> This has led to the

often-quoted statement that there is “no safe amount of myopia.”<sup>23</sup> Any amount of myopia reduction is important, with a 40% decrease in risk of maculopathy for each 1.00D reduction in progression.<sup>24</sup>

Clinicians must monitor axial length changes to accurately track progression since orthokeratology reshapes the corneal surface. The corneal epithelium under the treatment zone thins while the midperipheral area in the reverse curves thickens to create the effect.<sup>25</sup> A change in axial length of 0.1mm roughly equates to 0.20D to 0.25D.<sup>1</sup>

Comparisons of the safety and efficacy of ortho-K across studies is difficult because of variations in inclusion criteria, presence/absence of controls, lack of masking and methodological differences. Nonetheless, a summary of four representative meta-analyses reported remarkably consistent reductions in the progression of axial length in the range of -0.25mm to -0.27mm (Table 2).<sup>1,12,26-29</sup>

## Evidence for Safety

The risks associated with ortho-K are less well understood but are likely similar to those of

**Table 1. Comparison of Indications for Some FDA-approved Ortho-K Lens Designs in the United States**

Product	Manufacturer	Sphere Limit (D)	Cylinder Limit (D)
Corneal Refractive Therapy (CRT)	Paragon Vision Sciences/ Cooper Vision	Up to -6.00	Up to -1.75
Emerald	Euclid Systems	Up to -5.00	Up to -1.50 WTR/-0.75 ATR
*Vision Shaping Treatments (VST)	Bausch + Lomb	-1.00 to -5.00	Up to -1.50

(\*VST includes a family of 15 different designs)

**Table 2. Representative Summary of Effects of Ortho-K Over Time<sup>1,12,26-29</sup>**

Author	Design	Duration (Years)	Sample size (N)	Reduction in Axial Length (mm)
Cho and Cheung (2012)	RCT	2	78	-0.36 ± 0.24
Li et al. (2016)	Meta	2	667	-0.27
Hiraoka et al. (2012)	RCT	5	43	-0.42
Santodomingo-Rubido et al. (2017)	RCT	7	14	-0.13

other designs. Risk factors include overnight wear, use of tap water, and topping off solutions.<sup>12,26</sup>

The majority of published reports come from Asia and ortho-K is more widely used, where conditions of sanitation may vary, and suggest causative organisms encountered are overwhelmingly *Pseudomonas aeruginosa* or *Acanthamoeba*.<sup>17,30-32</sup>

Incidence data on rates of microbial keratitis are elusive but may be similar to overnight soft lens wear—between 19.5 to 25.4 per 10,000 wearers.<sup>12</sup> Adverse events (corneal infiltrative events, including infection) in soft lenses appears to be comparable to adults and may be less in the eight- to 11-year-old age range.<sup>33</sup> It is not clear whether this is true of ortho-K. In a retrospective study of gas permeable (GP) lens wearers who experienced *Acanthamoeba* keratitis, 24% wore ortho-K lenses but no odds ratio could be calculated.<sup>30</sup> Research also shows that *Pseudomonas aeruginosa*

binding to the corneal epithelium increases after overnight ortho-K wear.<sup>34</sup>

### Initial Examination

The initial exam deviates only slightly from your usual standard routine for a contact lens wearer. There are a few additional tests that are important to facilitate the fit and track individual success, such as cycloplegic refraction, axial length, topography or tomography, pupil size and corneal diameter measurements.<sup>35</sup> Many devices are capable of collecting this information, including a number of combination instruments. These contemporary devices can easily upload data to your lab to further assist in fitting. Be consistent when using these devices for each visit because agreement varies significantly between instruments.<sup>36,37</sup>

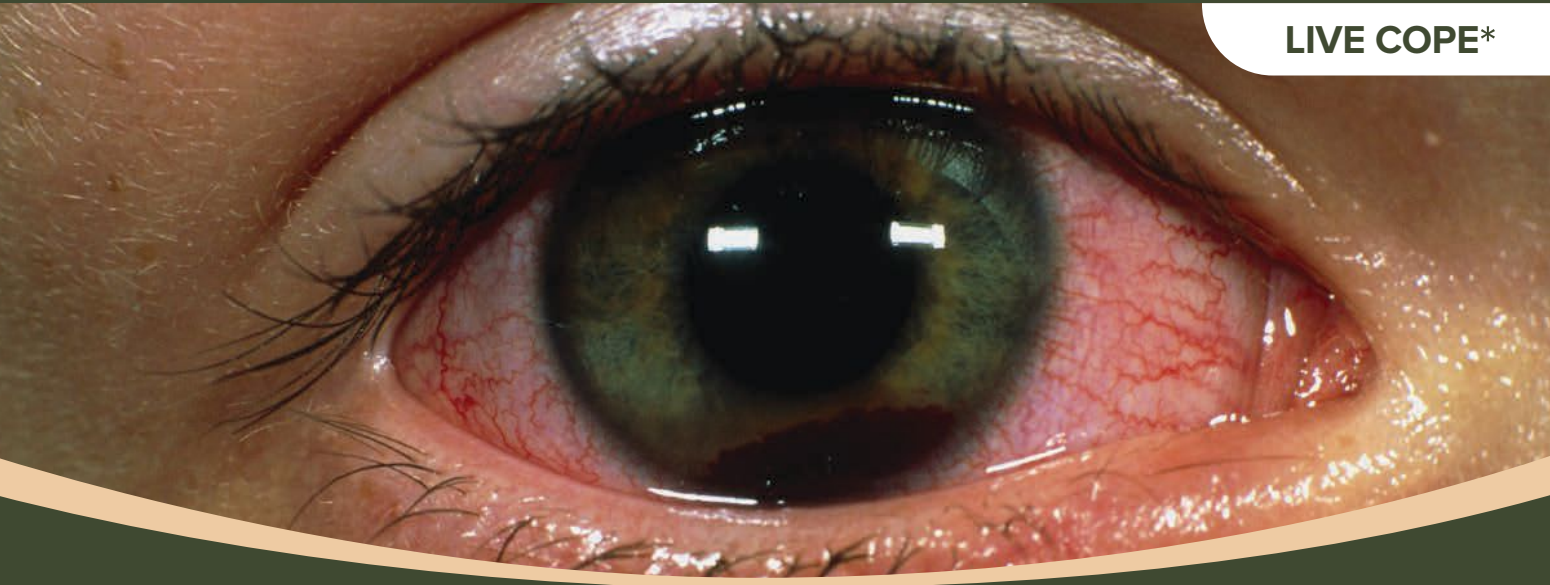
Cycloplegic refraction decreases the likelihood of over-minusing the patient. Some consider this an optional step, but, since a baseline fundus evaluation is important,

it can be easily incorporated into the first visit. Tracking changes in axial length over time is a more reliable measure than changes in refractive error that are influenced by the reshaping of the corneal surface. Assessing pupil size in both ambient and low light conditions helps ensure the treatment zone of the lens will be optimized to reduce risks of flare or glare. Assessing corneal diameter ensures the overall diameter of the lens will not exceed that of the cornea and improve lens centration.

Tomography, such as the Pentacam (Oculus), relies on a rotating Scheimpflug camera and not a reflection of a Placido disc. It is not subject to errors induced by an unstable tear film and measures true corneal height as well as elevation data.<sup>38</sup>

Placido disc topographers generally do not cover as large a region of the cornea as a tomographer, but there are some devices that allow you to stitch or tile together images from different fields of gaze to cover a larger surface area, such as the Medmont E300 (Medmont). This can be important when evaluating whether corneal astigmatism is confined to the central cornea or extends out toward the limbus, improving parameter and design selection. The two types of devices may offer the ability to model contact lens fits without putting a lens on the eye and may even generate simulated fluorescein patterns from the height data.

The ability to create subtractive or comparative maps is an essential feature on both devices. Topographical findings that make ortho-K more challenging include irregular astigmatism, high astigmatism, limbus-to-limbus astigmatism, decentered corneal apex and asymmetries.<sup>39</sup> Topographical attributes that are positive indicators



# Modern Management of Hyphema

TUESDAY, DECEMBER 1, 2020 | 8:00 PM ET (5:00 PM PT)



VIRTUAL EVENT

## SPEAKERS



**Andrew S. Gurwood, OD**  
Professor  
Pennsylvania College of Optometry  
at Salus University  
Philadelphia, PA  
Attending Staff  
Department of Ophthalmology  
Albert Einstein Medical Center  
Philadelphia, PA



**Marc D. Myers, OD**  
Senior Staff Optometrist  
Coatesville Veterans Affairs Medical Center  
Coatesville, PA  
Guest Lecturer, Adjunct Clinical Faculty  
Pennsylvania College of Optometry  
at Salus University  
Philadelphia, PA

\*Earn 1 LIVE COPE Credit for \$24.99

To register visit:

[www.reviewedu.com/hyphema](http://www.reviewedu.com/hyphema)

e-mail: [ReviewMeetings@MedscapeLIVE.com](mailto:ReviewMeetings@MedscapeLIVE.com)



\*Approval pending  
Review Education Group partners with Salus University for those ODs  
who are licensed in states that require university credit.



include well-centered apex near the geometrical center of the cornea, K values between 41.00D and 45.00D, with-the-rule astigmatism <1.50D and average corneal eccentricity between 0.25 and 0.80.<sup>39</sup> Axial maps are useful for comparing patients while obtaining a general overview, tangential maps provide more data on localized shape changes induced by ortho-K, and difference maps will allow you to track changes (Figure 1).<sup>39</sup>

## Fitting

The data you collect helps determine whether to select a diagnostic trial lens, employ a fitting nomogram, submit electronically to the lab or to empirically design the lens using software.<sup>35</sup> All are viable options (Table 3).<sup>40</sup> As you gain more experience, you will likely want more control of the design process and may wish to use design software. Avoid using design software until you gain the deeper understanding of how to manipulate parameters to achieve a desired effect. Trial lenses can expedite the fitting process for anxious parents/patients, where empirically designed lenses can be more customized to topographical features.

You want a well-centered lens, with an aligned area of approximately 4mm in the treatment zone, pooling in the return zone where the reverse curves are 1mm to 2mm wide, then an alignment zone of similar width and finally enough edge lift to create a band of pooling of 0.5mm and ensure adequate tear exchange. The lens should move on the blink but not to the point it moves outside the corneal diameter (Figure 2).<sup>35</sup>

Once the amount of flattening for the myopia + Jessen factor have been incorporated into the base curve, you will seldom need to modify this parameter unless

you determine undertreatment. In that case, you may flatten the base curve or increase the diameter of the treatment zone. More commonly, you will find you may need to modify the reverse curve, or the toricity of the reverse or alignment curves. The reverse curve contributes to decreasing the myopia slightly as you flatten this curve, thereby reducing the sagittal depth and eliminating a central island identified by topography. But mostly the reverse curve improves lens centration by manipulating the sagittal depth of the lens.

A low riding lens leaves a “frowny face” on your topography, and a high riding lens creates a “smiley face.” Modify the reverse curves and/or alignment curves by increasing or decreasing the sagittal depth, respectively. Smaller adjustments may be made by changing the landing zone angle on some lenses. In cases of corneal astigmatism that is limbus-to-limbus, these curves may need to be toric rather than spherical.<sup>35</sup>

Ortho-K for hyperopia and presbyopia (monovision) is an option; however, it’s not as well studied as it is for myopia. Nonetheless, studies with GP designs with base curve radii fit 0.4mm to 0.7mm steeper than flat K have shown

success and reversibility with up to 28 hours of wear.<sup>40</sup> The designs also have an impact on steepening of the treatment zone, flattening in the reverse zone and a positive shift in spherical aberration (as well as other HOAs).<sup>40-43</sup>

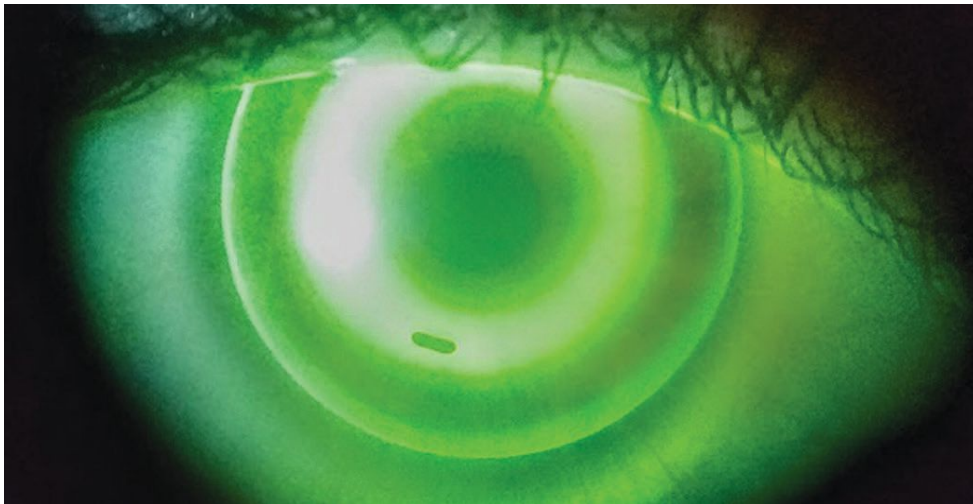
## Follow-up Scheduling

The timing of return visits after dispensing are dictated by the individual needs of the patient. A typical schedule would be the morning after the first overnight wear period, one week and then one, three and six months.<sup>8</sup> Once the desired effect is achieved, six-month intervals are fine. Assess the centration by topography and unaided visual acuities at every visit along with the ocular health, compliance and reinforce education. At one week, you will add a manifest refraction and you should be at or near your target of +0.50D to +0.75D of hyperopia.<sup>37</sup> At six months, include axial length measurements to assess progression.

Continue educating yourself and consider adding this valuable service to your practice. Understanding myopic progression and control should become part of every primary care practice. There are

**Table 3. Summary of Different Fitting Approaches<sup>40</sup>**

Method	Advantage	Disadvantage
Empirical	Easy, no inventory; Good initial success	Dependent on consultation to refine the fit
Diagnostic and trial lenses	Patient gets to experience lens; Can modify fit in real time; Practitioner control	Requires more skill and experience
Software	Precision fitting; Higher initial lens success; customizable for unique cases	Relies on high-quality imaging of topography
Nomogram	Good first lens fit; Decreased chair time; Shortens learning curve	Requires diagnostic skill



**Fig. 2. In this well-centered ortho-K lens at the initial visit, note the small bubble under the return zone inferiorly. These can be ignored and will generally dissipate as the reshaping occurs in the first 24-hour period. You could also instruct the patient to overfill the lens with a viscous artificial tear prior to insertion.**

numerous opportunities to acquire the proper training on ortho-K through continuing education programs at major meetings, dedicated societies and manufacturer online certification courses.

Adding ortho-K to your practice is a win for both patients and the economic health of your practice. It is immensely satisfying to change lives and reduce the risk of future morbidities through early intervention. You will also see how highlighting this service will benefit your practices. ■

*Dr. Fuller is a professor and founding supervisor of the Cornea & Contact Lens—Refractive Surgery residency at The Eye Center at Southern College of Optometry. He is also a Diplomate of Cornea, Contact Lenses and Refractive Technologies for the American Academy of Optometry.*

1. Bullimore MA, Richdale K. Myopia control 2020: Where are we and where are we heading? *Ophthalmic Physiol Opt.* 2020;40(3):254-70.
2. Li FF, Yam JC. Low-concentration atropine eye drops for myopia progression. *Asia Pac J Ophthalmol (Phila).* 2019;8(5):360-5.
3. Walline JJ, Lindsley KB, Vedula SS, et al. Interventions to slow progression of myopia in children. *Cochrane Database Syst Rev.* 2020;1(1):CD004916.
4. Lam CSY, Tang WC, Tse DYY, et al. Defocus incorporated multiple segments (DIMS) spectacle lenses slow myopia progression: a two-year randomised clinical trial. *Br J Ophthalmol.* 2020;104(3):363-8.

5. Bennett T. New myopia-control eyeglasses for children show positive outcomes. *Prim Care Optom News.* 2020;25:5.
6. Bennett T. SightGlass targets global myopia progression with new spectacles. *Prim Care Optom News.* [www.healio.com/news/optometry/2020/07/09/sightglass-targets-global-myopia-progression-with-new-spectacles](http://www.healio.com/news/optometry/2020/07/09/sightglass-targets-global-myopia-progression-with-new-spectacles). July 9, 2020. Accessed October 21, 2020.
7. White P, Cho P. Legal issues in contact lens practice with special reference to the practice of orthokeratology. *Ophthalmic Physiol Opt.* 2003;23(2):151-61.
8. Cho P, Cheung SW, Mountford J, White P. Good clinical practice in orthokeratology. *Cont Lens Anterior Eye.* 2008;31(1):17-28.
9. Nichols JJ, Starcher L. Contact lenses 2019. *CL Spectrum.* 2020;35:18-25.
10. Morgan PB, Efron N, Woods CA, Santodomingo-Rubido J. International survey of orthokeratology contact lens fitting. *Cont Lens Anterior Eye.* 2019;42(4):450-4.
11. FDA. Types of contact lenses. [www.fda.gov/medical-devices/contact-lenses/types-contact-lenses](http://www.fda.gov/medical-devices/contact-lenses/types-contact-lenses). January 16, 2018. Accessed October 21, 2020.
12. Bullimore MA, Johnson LA. Overnight orthokeratology. *Cont Lens Anterior Eye.* 2020;43(4):322-32.
13. Polse KA, Brand RJ, Keener RJ, Schwalbe JS. The Berkeley Orthokeratology Study, part III: safety. *Am J Optom Physiol Opt.* 1983;60(4):321-8.
14. Jun J, Zhiwen B, Feifu W, et al. Level of compliance in orthokeratology. *Eye Contact Lens.* 2018;44(5):330-4.
15. Robertson DM, Cavanagh HD. Non-compliance with contact lens wear and care practices: a comparative analysis. *Optom Vis Sci.* 2011;88(12):1402-8.
16. Szczotka-Flynn LB, Pearlman E, Ghannoum M. Microbial contamination of contact lenses, lens care solutions, and their accessories: A literature review. *Eye Contact Lens.* 2010;36(2):116-29.
17. Van Meter WS, Musch DC, Jacobs DS, et al. Safety of overnight orthokeratology for myopia: a report by the American Academy of Ophthalmology. *Ophthalmology.* 2008;115(12):2301-13.
18. Wang J, Liu L, Boost M, et al. Risk factors associated with contamination of orthokeratology lens cases. *Cont Lens Anterior Eye.* 2020;43(2):178-84.
19. Bui TH, Cavanagh HD, Robertson DM. Patient compliance during contact lens wear: perceptions, awareness and behavior. *Eye Contact Lens.* 2010;36(6):334-9.
20. Menicon. Menicon announces the launch of menicon bloom myopia control management system. [www.menicon.com/corporate/news/view/47](http://www.menicon.com/corporate/news/view/47). May 24, 2019. Accessed October 21, 2020.
21. Mutti DO, Hayes JR, Mitchell GL, et al. Refractive error,

axial length, and relative peripheral refractive error before and after the onset of myopia. *Investig Ophthalmol Vis Sci.* 2007;48(6):2510-9.

22. Fittcroft DI. The complex interactions of retinal, optical and environmental factors in myopia aetiology. *Prog Retin Eye Res.* 2012;31(6):622-60.
23. Fricke TR, Jong M, Naidoo KS, et al. Global prevalence of visual impairment associated with myopic macular degeneration and temporal trends from 2000 through 2050: systematic review, meta-analysis and modelling. *Br J Ophthalmol.* 2018;102(7):855-62.
24. Bullimore MA, Brennan NA. Myopia control: why each diopter matters. *Optom Vis Sci.* 2019;96(6):463-5.
25. Swarbrick HA. Orthokeratology review and update. *Clin Exp Optom.* 2006;89(3):124-43.
26. Cho P, Cheung SW. Retardation of Myopia in Orthokeratology (ROMIO) Study: a two-year randomized clinical trial. *Invest Ophthalmol Vis Sci.* 2012;53:7077.
27. Li SM, Kang MT, Wu SS, et al. Efficacy, safety and acceptability of orthokeratology on slowing axial elongation in myopic children by meta-analysis. *PLoS One.* 2016;41(5):600-8.
28. Hiraoka T, Kakita T, Okamoto F, et al. Long-term effect of overnight orthokeratology on axial length elongation in childhood myopia: a five-year follow-up study. *Invest Ophthalmol Vis Sci.* 2012;53:3913.
29. Santodomingo-Rubido J, Villa-Collar C, Gilmartin B, et al. Long-term efficacy of orthokeratology contact lens wear in controlling the progression of childhood myopia. *Curr Eye Res.* 2017;42:713-20.
30. Cope JR, Collier SA, Schein OD, et al. Acanthamoeba keratitis among rigid gas permeable contact lens wearers in the United States, 2005 through 2011. *Ophthalmology.* 2016;123(7):1435-41.
31. Watt KG, Swarbrick HA. Trends in microbial keratitis associated with orthokeratology. *Eye Contact Lens.* 2007;33(6 pt 2):373-7.
32. Watt K, Swarbrick HA. Microbial keratitis in overnight orthokeratology: review of the first 50 cases. *Eye Contact Lens.* 2005;31(5):201-8.
33. Bullimore MA. The safety of soft contact lenses in children. *Optom Vis Sci.* 2017;94(6):638-46.
34. Ladage PM, Yamamoto N, Robertson DM, et al. *Pseudomonas aeruginosa* corneal binding after 24-hour orthokeratology lens wear. *Eye Contact Lens.* 2004;30(3):173-8.
35. Lipson MJ. Initial fitting. In: Lipson MJ, ed. *Contemporary Orthokeratology*. Vol 1. First. Rochester: Bausch Health; 2019:25-38.
36. Kumar M, Shetty R, Jayadev C, et al. Repeatability and agreement of five imaging systems for measuring anterior segment parameters in healthy eyes. *Indian J Ophthalmol.* 2017;65(4):288-94.
37. Penna RR, de Sanctis U, Catalano M, et al. Placido disk-based topography versus high-resolution rotating Scheimpflug camera for corneal power measurements in keratoconic and post-LASIK eyes: reliability and agreement. *Int J Ophthalmol.* 2017;10(3):453-60.
38. Mejia-Barbosa Y, Malacara-Hernández D. A review of methods for measuring. *Optom Vis Sci.* 2001;78:240-53.
39. Kojima R. Topography. In: Lipson M, ed. *Contemporary Orthokeratology*. Vol 1. First. Rochester: Bausch Health; 2019:39-53.
40. Lipson MJ, Brooks MM, Koffler BH. The role of orthokeratology in myopia control: a review. *Eye Contact Lens.* 2018;44(4):224-30.
41. Charm J, Cho P. High myopia-partial reduction orthokeratology (HM-PRO): study design. *Cont Lens Anterior Eye.* 2013;36(4):164-70.
42. Lu F, Sorbara L, Simpson T, Fonn D. Corneal shape and optical performance after one night of corneal refractive therapy for hyperopia. *Optom Vis Sci.* 2007;84:357-364.
43. Swarbrick HA, Hiew R, Key AI, Peterson S, Tahhan N. Apical clearance rigid contact lenses induce corneal steepening. *Optom Vis Sci.* 2004;81:427-35.



# Heart to Heart

Concurrent keratoconus and systemic disease may, or may not, be connected.

Edited by Joseph P. Shovlin, OD

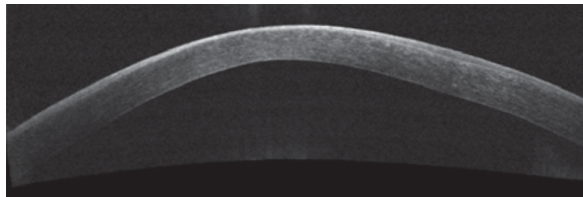
**Q** A keratoconus (KCN) patient of mine just passed away from myocardial infarction. A relative said she read that KCN patients are at a higher risk of cardiac problems. Is this the case or are there too many confounders to draw any conclusions?

**A** “KCN—a progressive ectatic disorder that causes thinning and steepening of the cornea—is a multifactorial disease with environmental, biomechanical and genetic factors,” says Katelyn Lucas, OD, of Price Vision Group in Indianapolis.

Dr. Lucas notes that while many diseases associated with KCN have an increased risk for cardiovascular comorbidities, a direct link between cardiac issues and KCN has not been found. She adds, however, that since KCN prevalence is listed as 1/2000 in some textbooks and between 1% and 5% of patients undergoing screening for refractive surgery show possible signs of KCN, it is not unusual to find KCN patients with almost any disease.<sup>1</sup> Understanding the many risk factors that have been associated with KCN can be beneficial, she suggests.

## Risk Factors

Eye rubbing is highly associated with the progression of KCN due to repetitive mechanical trauma that induces stress on corneal structures, in turn weakening and warping the cornea.<sup>2,3</sup> Dr. Lucas recommends patient education, topical antihistamines and other allergy drops to



Corneal thinning and bulging are characteristic of KCN.

mitigate the effects and help break the cycle of eye rubbing.

KCN is associated with various genetic conditions, including Leber’s congenital amaurosis (LCA) and Down syndrome, according to Dr. Lucas. She says eye rubbing is commonly seen in LCA and is believed to cause KCN in these patients. Patients with Down syndrome are six times more likely to develop KCN and are known to frequently rub their eyes due to atopy or allergy.<sup>4</sup> A genetic variation in Down syndrome may affect collagen fibers and cause alterations in the cornea.<sup>5</sup>

Connective tissue disorders, such as Ehlers-Danlos syndrome (EDS), are linked to KCN, says Dr. Lucas. She notes that classic EDS is a type V collagen disorder, and the cornea is rich in type V collagen, making it a targeted tissue. She adds that brittle cornea syndrome is a type of EDS associated with steeper and thinner corneas that often result in KCN.

Obstructive sleep apnea (OSA) is more prevalent in KCN patients, and high-risk OSA patients are more likely to have more severe KCN.<sup>4</sup> Dr. Lucas recommends screening for OSA in KCN patients due to its increased risk of morbidity and mortality.

## Treatment Options

Most cases of KCN respond well to glasses and contact lenses, and in severe cases, specialty contact lenses provide excellent vision and comfort, Dr. Lucas says.

When the cornea becomes too scarred or distorted for functional vision with contact lenses, however, she says a transplant is needed.

Traditionally, full-thickness transplants are performed for KCN. However, penetrating keratoplasties have a risk of rupture with minor trauma, unpredictable visual recovery and a limited lifetime, as corneal endothelial cells decrease over time, especially in grafted tissue.

Dr. Lucas suggests a deep anterior lamellar keratoplasty to preserve the patient’s own endothelium. This procedure decreases the risk of rejection, lowers the need for long-term steroid use, lasts longer and uses larger-diameter grafts.<sup>6</sup>

According to Dr. Lucas, crosslinking is the only treatment to slow or prevent KCN progression.

KCN is associated with systemic diseases, but there’s no evidence suggesting it’s linked to cardiac issues. ■

1. Nesburn AB, Bahri S, Salz J, et al. Keratoconus detected by videokeratography in candidates for photorefractive keratectomy. *J Refract Surg.* 1995;11(3):194-201.  
 2. Moran S, Gomez L, Zuber K, et al. A case-control study of keratoconus risk factors. *Cornea.* 2020;39(6):697-701.  
 3. Mazharian A, Panthier C, Courtin R, et al. Incorrect sleeping position and eye rubbing in patients with unilateral or highly asymmetric keratoconus: a case-control study. *Cornea.* June 10, 2020. [Epub ahead of print].  
 4. Woodward MA, Blachley TS, Stein JD. The association between sociodemographic factors, common systemic diseases, and keratoconus: an analysis of a nationwide healthcare claims database. *Ophthalmology.* 2016;123(3):457-65.  
 5. Alio JL, Vega-Estrada A, Sanz P, et al. Corneal morphologic characteristics in patients with Down syndrome. *JAMA Ophthalmol.* 2018;136(9):971-8.  
 6. Nariavaty MA, Singh Vijjan K, Yvon C. Deep anterior lamellar keratoplasty: a surgeon’s guide. *J Curr Ophthalmol.* 2018;30(4):297-310.

# The OD's TOP CHOICE

Ranked #1 Eye Care  
Publication In  
**FIVE**  
Critical Readership  
Categories:



Total Readers



Most Read Publication/  
Website Within the Last  
Six Months



Quality Clinical Content  
I Use in My Practice



Average Page Exposures



Websites Visited within  
the Last Six Months

Practitioners rely on RO  
more than any other eye  
care publication



**Review also is number one in readership  
across the following categories:**

- Total Optometrists
- ODs in High-Volume Practices
- Solo Practitioners
- Annual Practice Revenue (\$500k+)
- ODs who Purchase Examination Equipment
- Write Prescriptions (11+ per week)
- Perform Refractions (51+ per week)
- Contact Lens Prescribers
- Years in Practice (1-15 and 15+)
- Among Key Opinion Leaders

***To our readers:* Thank you for  
your loyalty, time and trust.  
We'll keep working hard to earn  
your support.**



# Put a Damper on Flareups

Managing acute dry eye looks different every year with new therapy approvals.

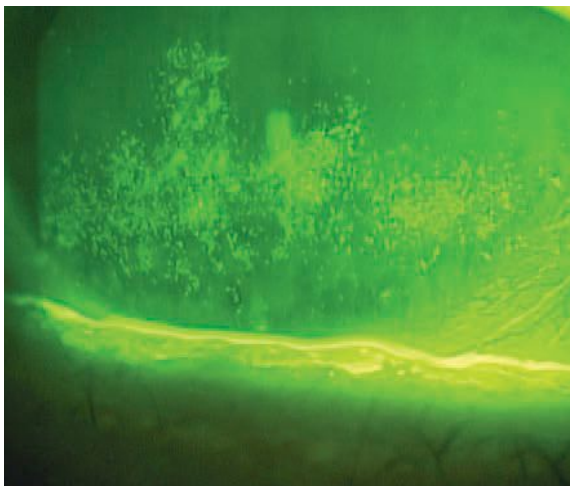
By Paul M. Karpecki, OD

**W**e have a robust selection of therapies that allows us to treat the root cause of most signs and symptoms of dry eye disease. However, despite the countless innovations, most patients still experience occasional rapid-onset flareups that cannot be adequately managed with the patient's usual maintenance therapy. Fortunately, current options can reduce the risk of a flareup and can control one quickly when it does arise—and new approaches to rescue therapy may soon provide patients with on-demand relief.

## Symptoms Come and Go

Although dry eye is a chronic condition, symptoms tend to wax and wane. For example, dry eye can spike during allergy season, when a patient stops using prescription drops or when a systemic drug is prescribed for another condition. Sometimes, symptoms present for no apparent reason whatsoever.

In a recent survey of 503 patients diagnosed with dry eye, 80% to



**Dry eye patients with confluent superficial punctate keratitis may need an arsenal of rescue therapy options.**

90% said they experience flares about six times per year.<sup>1</sup> As primary eye care providers, it's up to us to offer relief for acute presentations as quickly as possible. The longer a flareup persists, the harder it is to control. Flareups can cause significant distress, especially if patients have to wait several days for an appointment.

Patients who present with a dry eye flareup often have red eyes, lid involvement and increased staining. Physiologically, the eye is trying to heal itself by mounting an inflammatory response, but this can take several days and have long-lasting effects on the ocular surface, the tear film, corneal sensitivity and more.

In the meantime, the patient's discomfort often leads to blink alterations, which further exacerbate symptoms and can perceptibly compromise visual function.<sup>2</sup>

## Rescue Therapy

Currently no treatments are no FDA-approved for short-term, rapid relief of episodic dry eye symptoms. As such, we generally rely on a steroid, allergy drop, biologic agents, ointments or other additive treatments to help shorten the episode and roll back symptoms. Just as almost every asthma patient receives an albuterol inhaler, all dry eye patients should have a plan for how to manage exacerbations. Here are a few good options:

### *Over-the-counter (OTC).*

Although most patients experiencing dry eye flares require stronger therapeutics rather than OTC products, clinicians should recommend patients keep effective OTC options on hand. Having artificial tears and antihistamines (for those with a history of allergic conjunctivitis) in the medicine cabinet is a good recommendation. In addition, ocular hygiene supplies, such as a moist heat compress and hypochlorous acid spray, are must-haves. Bruder Healthcare also now packages a three-step hygiene kit that also includes wipes.

Masks and sprays can also offer that extra bump in comfort that patients crave in the midst of a dry eye flareup.

**Neurostimulation.** This new therapy can provide an instant release of one's own tears by stimulating the trigeminal nerve. Our natural

### Common Causes of Flareups

- Treatment discontinuation
- Seasonal allergies
- Environmental allergens
- Systemic disease
- New medications and preservatives (e.g., benzalkonium chloride)
- Dehydration
- Hormonal changes
- Blepharitis biofilm and *Demodex*





“ I didn't realize  
**STARS**  
were little dots that twinkled ”

—Misty L, *RPE65* gene therapy recipient

**WE'RE SEEING  
AMAZING RESULTS.  
AND SO ARE THEY.**

At the Foundation Fighting Blindness our mission is everybody's vision. Our work shines a light on the darkness of inherited retinal diseases (IRDs).

We're the world's leading organization searching for treatments and cures. We need your help to fuel the discovery of innovations that will illuminate the future for so many. We have robust disease information, a national network of local chapters and support groups, local educational events, and our My Retina Tracker® Registry to help keep your patients connected with clinical and research advancements.

Help accelerate our mission  
by donating at [ECPs4Cures.org](https://ECPs4Cures.org).

**FOUNDATION  
FIGHTING  
BLINDNESS**

[FightingBlindness.org](https://FightingBlindness.org)

tears have more than 1,500 proteins, five lipid classes and 20 mucins, as well as growth factors and anti-inflammatory components.<sup>3,4</sup> Stimulating the trigeminal nerve appears to impact all three tear-producing glands, including the goblet cells, meibomian and lacrimal glands.<sup>5-7</sup>

One recent FDA approval, the iTear100 neurostimulator (Olympic Ophthalmics) demonstrated a 22mm change in the Schirmer score when compared with sham with no device-related adverse events.

## In the Pipeline

Still, none of the available acute therapies eliminate flareups from reoccurring. But soon, new options may allow ODs to prescribe a form of rescue therapy for dry eye in much the same way allergists prescribe rescue inhalers for patients who have acute asthma attacks.

Kala has recently received FDA approval for Eysuvis (loteprednol etabonate ophthalmic suspension 0.25%) with launch in the United States expected by the end of this year. Formerly called KPI-121, this formulation uses nanoparticles (approximately 300nm) engineered to penetrate through mucus pores to the ocular surface without being eliminated by the tear film. However, this mechanism more than triples the loteprednol etabonate penetration to the cornea and aqueous humor.

The STRIDE 3 study compared 447 patients in the Eysuvis treatment group and 454 patients receiving the vehicle, each dosed four times a day for two weeks.<sup>8</sup>

Ocular discomfort severity was graded daily by the patient using a visual analog grading scale that ranged from 0mm to 100mm.<sup>8</sup>

The results demonstrated a statistically significant reduction in ocular discomfort severity from baseline to

## The Best Offense is a Good Defense

We should do all we can to minimize the risk of flareups, including regular daily therapy such as cyclosporine or lifitegrast when appropriate. Regular in-office treatments also play a key role in reducing the potential for flareups, including: low-level light therapy for meibomian gland dysfunction (MGD), chalazia, ocular rosacea and hordeola; Blephex for the treatment of the biofilm or blepharitis; and thermal pulsation/expression treatments for evaporative dry eye and MGD.<sup>1</sup>

In cases where signs such as punctate epitheliopathy escalate, initiating a biologic can make a significant difference for a patient. These include applying an amniotic membrane or prescribing autologous serum tears or cytokine extract drops.

1. Stonecipher K, Abell TG, Chotiner B, et al. Combined low level light therapy and intense pulsed light therapy for the treatment of meibomian gland dysfunction. *Clin Ophthalmol*. 2019;13:993-99.

day 15 compared with the controls in both the overall population and a pre-defined subgroup of patients. The subgroup presented with more severe baseline ocular discomfort, defined as patients who scored greater than or equal to 68mm in baseline ocular discomfort.<sup>3</sup>

Statistical significance was also achieved in conjunctival hyperemia at day 15 in the overall population and ocular discomfort severity at day eight in the study population. Significant results were also observed for total corneal staining at day 15.<sup>8</sup>

Eysuvis was well-tolerated, and the most common adverse event was instillation site pain in 2.9% of the Eysuvis patients and 1.5% in the vehicle group. Elevations in intra-ocular pressure were similar between the two groups.<sup>8</sup>

Another potential future option is varenicline (Oyster Point Pharmaceuticals), a nasal spray that involves nicotinic acetylcholine receptors to stimulate the trigeminal nerve, affecting the parasympathetic nervous system. ONSET-2, a phase III clinical trial, was a real-world type study with no placebo run-in and a broad range of dry eye signs and symptoms.<sup>9</sup> Although the study was cut short due to COVID-19, it met the statistical end point of a greater percentage of patients having  $\geq 10$ mm change from baseline

in Schirmer scores. It also showed a statistically significant improvement in dryness symptoms.

Not only do these new treatments bring rescue therapy to the forefront, but they also create a broader awareness about a shifting philosophy in terms of how we manage acute dry eye. Patients should be prepared for the fickle nature of dry eye with exceptional patient education and an arsenal of therapeutic options.

With new options on the way, you can help your patients be fully prepared to manage their next flareup promptly and effectively. ■

*Note: Dr. Karpecki consults for companies with products and services relevant to this topic.*

1. Kala. Patient survey; performed by a third party.
2. Ousler GW III, Abelson MB, Johnston PR, et al. Blink patterns and lid-contact times in dry eye and normal subjects. *Clin Ophthalmol*. 2014;8:869-74.
3. Klenkler B, Sheardown H, Jones L. Growth factors in the tear film: role in tissue maintenance, wound healing, and ocular pathology. *Ocul Surf*. 2007;5(3):228-39.
4. Willcox MD, Argüeso P, Georgiev GA, et al. TFOS DEWS II tear film report. *Ocul Surf*. 2017;15(3):366-403.
5. Dartt DA, McCarthy DM, Mercer HJ, et al. Localization of nerves adjacent to goblet cells in rat conjunctiva. *Curr Eye Research*. 1995;14(11):993-1000.
6. LeDoux MS, Zhou Q, Murphy RB, et al. Parasympathetic innervation of the meibomian glands in rats. *Invest Ophthalmol Vis Sci*. 2001;42:2434-41.
7. Van Der Werf F, Baljet B, Prins M, et al. Innervation of the lacrimal gland in the cynomolgus monkey: a retrograde tracing study. *J Anat*. 1996;188(Pt3):591-601.
8. Oyster Point Pharma announces positive results in ONSET-2 phase 3 trial of OC-01 nasal spray for the treatment of the signs and symptoms of dry eye disease. <https://investors.oysterpointrx.com/news-releases/news-release-details/oyster-point-pharma-announces-positive-results-onset-2-phase-3>. May 11, 2020. Accessed October 22, 2020.
9. Kala Pharmaceuticals announces statistically significant results in STRIDE 3 trial of dry eye disease drug Eysuvis. [eyewire.com/news/articles/kala-pharmaceuticals-announces-statistically-significant-results-in-stride-3-trial-of-dry-eye-disease-drug-eysuvis](https://www.eyewire.com/news/articles/kala-pharmaceuticals-announces-statistically-significant-results-in-stride-3-trial-of-dry-eye-disease-drug-eysuvis). March 20, 2020. Accessed October 22, 2020.

# SAVE THE DATE

 VIRTUAL EVENT



## New Technologies & Treatments in Eye Care

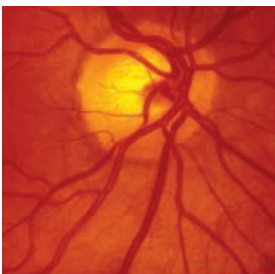CHAIR: Paul M. Karpecki, OD, FAAO

**WINTER | NOVEMBER 13–14, 2020**

EARN UP TO 12\* LIVE COPE CREDITS

Register at [www.ReviewEdu.com/NTT2020](http://www.ReviewEdu.com/NTT2020)

Partially supported by unrestricted educational grants from Alcon, Novartis, Regeneron, and Sun Pharmaceuticals.



The Optometric Retina Society and Review Education Group present

## RETINAUPDATE2020

CHAIR: Mohammad Rafieetary, OD, FAAO

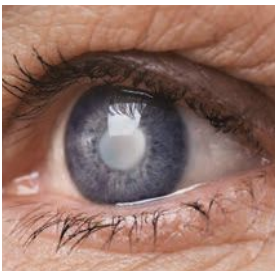CO-CHAIR: Steven Ferrucci, OD, FAAO

**DECEMBER 4–5, 2020**

EARN UP TO 8\* LIVE COPE CREDITS AND 4 ENDURING ONLINE CREDITS

Register at [www.ReviewEdu.com/ORSRetUpdate2020](http://www.ReviewEdu.com/ORSRetUpdate2020)

Partially supported by an unrestricted educational grant from Maculogix.



## Winter Optometric Glaucoma Symposium

CO-CHAIRS: Murray Fingeret, OD, FAAO, and Robert N. Weinreb, MD

**DECEMBER 11–12, 2020**

EARN UP TO 12\* LIVE COPE CREDITS

Register at [www.ReviewEdu.com/OGS2020](http://www.ReviewEdu.com/OGS2020)

Partially supported by unrestricted educational grants from Aerie, Alcon, Bausch & Lomb, and Sun Pharmaceuticals.

For additional information visit:

[www.ReviewEdu.com/Events](http://www.ReviewEdu.com/Events)

e-mail: [ReviewMeetings@MedscapeLIVE.com](mailto:ReviewMeetings@MedscapeLIVE.com)



\*Approval pending

Review Education Group partners with Salus University for those ODs who are licensed in states that require university credit.

Administered by





# A Hazy Shade of Winter

Fundus imaging can help reveal a patient's tumultuous health history.

By Mark Dunbar, OD

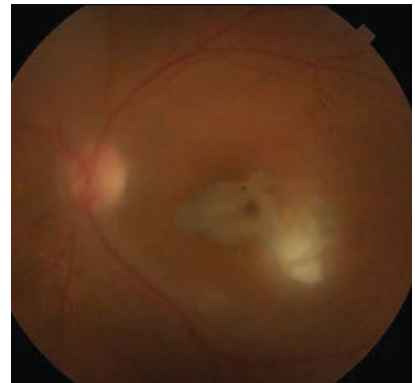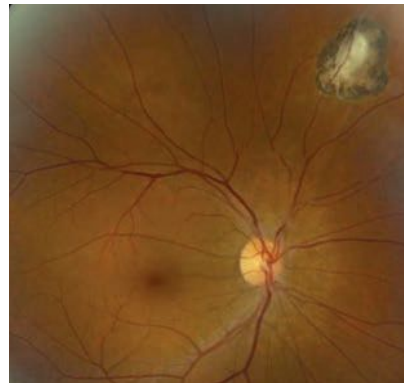A 56-year-old Hispanic female presented with new-onset hazy vision and floaters in the left eye for the past week. She has had similar episodes in that eye before; the last one occurred six years earlier. In fact, she lost central vision in the left eye almost 20 years ago when the problem first started. The right eye was good, and she reported no problems. She reported being in good health and does not take any medications.

Upon examination, her best-corrected visual acuity was 20/20 OD and 20/400 OS with eccentric viewing. Confrontation visual fields were full-to-careful finger counting OU, but she did have a central scotoma in the left eye. Pupils were equal, round and reactive to light, but there was a trace afferent pupillary defect in the left eye. The anterior segment exam was unremarkable, and there was no cell or flare in either eye.

On dilated fundus exam, the posterior pole of the right eye was unremarkable. She did have a significant finding superonasally, which can be seen in the fundus photos provided. The view in the left eye was hazy. Other changes are seen in *Figure 1*.

## Take the Retina Quiz

- How do you account for the hazy view into the left eye?
  - Anterior chamber inflammation
  - Cataract
  - Vitreous cells
  - Just a poor photograph



**Fig. 1.** These are the right and left eyes of our patient. What does the hazy view in the left eye represent?

- What does the white lesion adjacent to the macula represent?
  - Active retinochoroiditis
  - Placoid lesion from syphilis
  - Cotton wool spot
  - Fungal lesion
- What is the correct diagnosis for the fundus lesion?
  - Toxocara canis
  - Toxoplasmosis
  - Active syphilis
  - Histoplasmosis
- What is not a medication used to treat this condition?
  - Clindamycin PO
  - Azithromycin PO
  - Penicillin
  - Primethamine
- Which statement best characterizes her condition?
  - Likely acquired
  - Likely congenital
  - Autoimmune
  - Reactivation

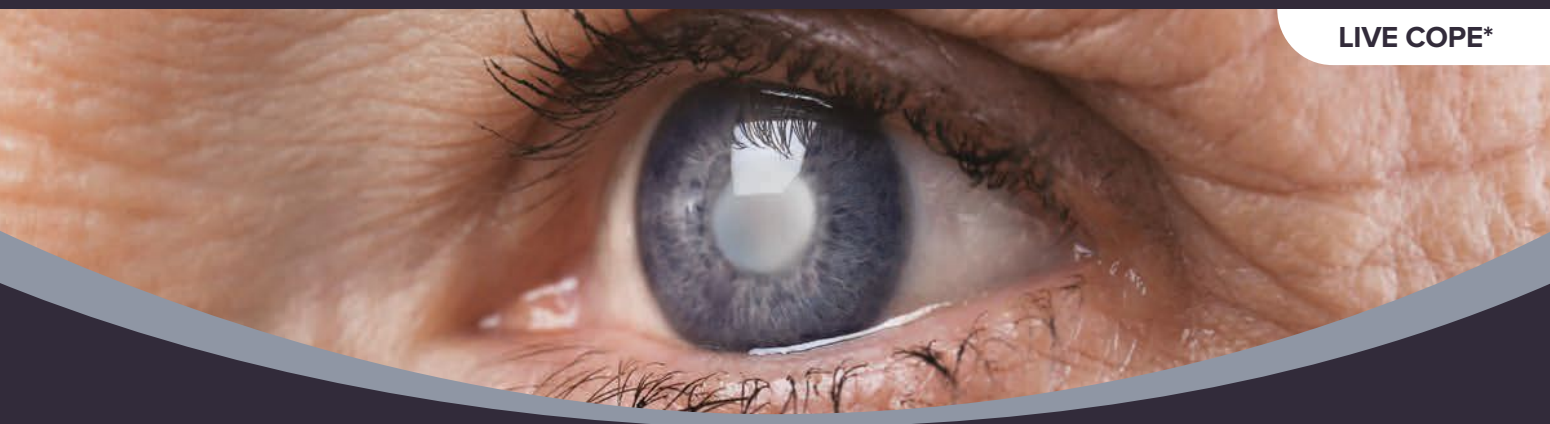*For answers, see page 98.*

## Discussion

The reason we have such a hazy view into the retina of the left eye is because the patient has significant vitreous cells that obscure the view. We can see chorioretinal scarring involving the macula of the left eye, which explains why her acuity is 20/400. The presence of the macula scar in the left eye in addition to the peripheral scar in the right eye should automatically make you suspicious for toxoplasmosis.

Unfortunately, it appears she has reactivation. In addition to her onset of floaters, there is a fluffy white lesion adjacent to the macular scar, which represents an area of active retinochoroiditis. This is classic for reactivation of the toxoplasmosis.

*Toxoplasma gondii* is a widespread parasite that infects almost all mammals and birds across the world. It is estimated that 25% to



WINTER  
**Optometric Glaucoma Symposium**

DECEMBER 11–12, 2020

 VIRTUAL EVENT

**CO-CHAIRS**



**Murray Fingeret, OD, FAAO**

Chief of the Optometry Section  
Brooklyn/St. Albans Campus  
Department of  
Veterans Administration  
New York Harbor  
Health Care System  
Clinical Professor  
SUNY, College of Optometry



**Robert N. Weinreb, MD**

Distinguished Professor and Chair  
Ophthalmology  
Director, Shiley Eye Institute  
Distinguished Professor  
Bioengineering  
Morris Gleich MD Chair of Glaucoma  
Director, Hamilton Glaucoma Center  
University of California San Diego

**OVERVIEW**

The Winter Optometric Glaucoma Symposium, brought to you by Review Education Group and MedscapeLIVE!, comes to you virtually in 2020! This conference is a long-running and trusted program for optometrists managing patients with glaucoma.

**FACULTY**

Nevin W. El-Nimri OD, MS, PhD, FAAO  
Alex Huang, MD, PhD  
Ben Gaddie, OD, FAAO  
Richard Madonna, OD, MA, FAAO

**TOPIC AREAS INCLUDE**

- Glaucoma Patients in the COVID Era
- Glaucoma Therapy
- Innovations in Glaucoma
- Q&A and Case Discussions

**REGISTRATION**

**Super early rate: \$149**  
Rate increases December 4: \$199

\*Earn up to 12 LIVE COPE Credits

To register visit:

[www.ReviewEdu.com/OGS2020](http://www.ReviewEdu.com/OGS2020)

e-mail: [ReviewMeetings@MedscapeLIVE.com](mailto:ReviewMeetings@MedscapeLIVE.com)



\*Approval pending

Supported by unrestricted educational grants from Aerie, Alcon, Bausch & Lomb, and Sun Pharmaceuticals.  
Review Education Group partners with Salus University for those ODs who are licensed in states that require university credit.

Administered by



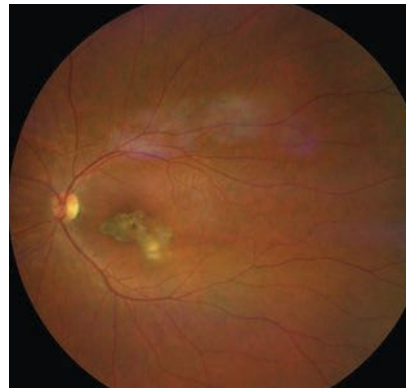
30% of the human population is infected with *Toxoplasma gondii*.<sup>1,2</sup> It is considered to be the most common cause of posterior uveitis and accounts for approximately 90% of focal necrotizing retinitis.

Human infection can occur from a variety of causes, including ingestion of oocysts shed in the feces of cats (from contaminated soils or litter boxes) or ingestion of the tissue cysts (bradyzoites) in infected meat.<sup>1,2</sup> Other forms of exposure include consuming unwashed vegetables and drinking contaminated water or unpasteurized bovine milk. Our patient laughed when we asked about consumption of undercooked meat. She said her family has always eaten their meat well-done—almost like shoe leather.

Congenital transmission of toxoplasmosis is quite common. Intra-uterine transmission occurs in about one-third of pregnancies of women infected with toxoplasmosis.<sup>3</sup> In the United States, congenital toxoplasmosis occurs in about 1/1000 to 10,000 live births.<sup>3</sup> It generally presents in the eye as an inactive choroiretinal scar. The presence of bilateral macular scars is considered to be the hallmark of congenital toxoplasmosis.

Reactivation of a congenital infection can occur. When this happens, reactivation occurs adjacent to an old scar, which was the case with our patient.

In a majority of cases, the diagnosis of toxoplasmosis, congenital or acquired, is based on the clinical presentation, and a serologic work-up is not required. In atypical cases, or when the diagnosis is in question, perform serologic blood studies, such as the *Toxoplasma* ELISA, to confirm the diagnosis. Detection of IgM antibody titers present within the first two weeks of infection and suggest a recently acquired infec-



**Fig. 2.** This patient three months later.

tion. Positive IgG antibodies indicated the patient was exposed to the infection some time in their lifetime. IgG antibodies peak at two months and will be present for life.

## Treatment

Toxoplasmosis retinochoroiditis will generally resolve on its own in four to eight weeks in immunocompetent patients. Patients with peripheral lesions that are not a threat to the macula or optic nerve are often observed without treatment, unless there is a severe vitritis that causes a significant reduction in visual acuity. Treatment is recommended for active lesions that threaten or involve the macula or optic nerve, though many studies have shown there is no significant difference in the visual outcome between treated eyes and observation in immunocompetent patients.

There seems to be no clear consensus among uveitis specialists on treating patients with active disease. The “classic therapy” for treating active toxoplasmosis retinochoroiditis is oral pyrimethamine, (loading dose of 75mg to 100mg during the first day, followed by 25mg to 50mg on subsequent days), sulfadiazine (loading dose of 2g to 4g during the first 24 hours, followed by 1g QID and oral prednisone 40mg to 60mg per day, also referred to as

triple therapy).<sup>4,5</sup> Folinic acid is also given 3mg to 5mg twice a week to avoid developing thrombocytopenia and leucopenia.

Other medications that have been used are clindamycin 30mg PO TID and Bactrim DS DS (sulfamethoxazole-trimethoprim, Roche Pharmaceuticals) PO BID, combined with prednisolone 40mg PO QD. Some uveitis specialists will also give an intravitreal injection of dexamethasone 0.4mg/clindamycin 1mg.<sup>4,5</sup> Azithromycin has also emerged as an alternative treatment for toxoplasmosis. Studies comparing traditional triple therapy with azithromycin have shown no significant difference in results.<sup>6</sup>

When our patient presented with reactivation of her toxoplasmosis, she already had a long and tumultuous history that started in 2000. The initial episode started in her left macula, but it was small, and with treatment, she recovered to 20/50. A toxoplasma ELISA was performed on that initial exam and came back positive.

She was stable until 2013, when she had another reactivation, and that episode robbed her of her central vision. She was stable until 2019, when a third reactivation occurred. *Figure 2* represents how the patient looked three months after treatment. She has remained stable since her last episode. ■

1. Montoya JG, Liesenfeld O. Toxoplasmosis. *Lancet*. 2004;363:1965-76.

2. Stokkermans TJ, Havens SJ. Toxoplasma retinochoroiditis. In: StatPearls [Internet]. Treasure Island, FL: StatPearls Publishing. Updated Jun 27, 2020. [www.ncbi.nlm.nih.gov/books/NBK493182](http://www.ncbi.nlm.nih.gov/books/NBK493182). Accessed October 12, 2020.

3. El Bissati K, Levigne P, Lykins J, et al. Global initiative for congenital toxoplasmosis: an observational and international comparative clinical analysis. *Emerg Microbes Infect*. 2018;27:7(1):165.

4. Harrell M, Carvounis PE. Current treatment of toxoplasma retinochoroiditis: an evidence-based review. *J Ophthalmol*. 2014;2014:273506.

5. Kim SJ, Scott IU, Brown GC, et al. Interventions for toxoplasma retinochoroiditis: a report by the American Academy of Ophthalmology. *Ophthalmology*. 2013;120(2):371-8

6. Bosch-Driessen LH, Verbraak FD, Suttrop-Schulten MS, et al. A prospective, randomized trial of pyrimethamine and azithromycin vs. pyrimethamine and sulfadiazine for the treatment of ocular toxoplasmosis. *Am J Ophthalmol*. 2002;134:34-40.



I was only seeing light flashes early on, but light

**FLASHES**

when you've not seen anything for  
so many years—it was wonderful

—Keith H, retinal prosthesis recipient

**WE'RE SEEING  
AMAZING RESULTS.  
AND SO ARE THEY.**

At the Foundation Fighting Blindness our mission is everybody's vision. Our work shines a light on the darkness of inherited retinal diseases (IRDs).

We're the world's leading organization searching for treatments and cures. We need your help to fuel the discovery of innovations that will illuminate the future for so many. We have robust disease information, a national network of local chapters and support groups, local educational events, and our My Retina Tracker® Registry to help keep your patients connected with clinical and research advancements.

Help accelerate our mission  
by donating at [ECPs4Cures.org](http://ECPs4Cures.org).

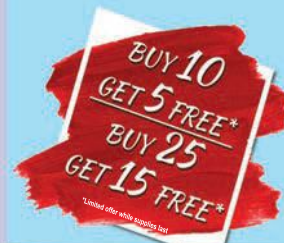**FOUNDATION  
FIGHTING  
BLINDNESS**

[FightingBlindness.org](http://FightingBlindness.org)

Contact Lenses

# Impressions

Color Contact Lens



*Unleash your true color!*

Impressions colored contacts blend naturally with your patients eyes to create a beautiful look. Available in nine dazzling opaque colors of which Brown, Grey, Green, Hazel, Honey, Pure Hazel and True Sapphire are available in RX PL to -8.00. Impressions are fun, hip, fashionable and very competitively priced to help your bottom line. POP materials, posters, and trial kits are available upon request.

Available Exclusively at

  
**NATIONAL LENS**  
1-866-923-5600  
www.national-lens.com  
CALL US FOR ALL MAJOR BRANDS OF CONTACTS



## Targeting Optometrists?

### CLASSIFIED ADVERTISING WORKS

- JOB OPENINGS • CME PROGRAMS
- PRODUCTS & SERVICES • AND MORE...

Contact us today for classified advertising:  
Toll free: **888-498-1460**  
E-mail: **sales@kerhgroup.com**





**Practice For Sale**



Practice Sales • Appraisals • Consulting  
[www.PracticeConsultants.com](http://www.PracticeConsultants.com)

**PRACTICES FOR SALE  
 NATIONWIDE**

Visit us on the Web or call us to learn more about our company and the practices we have available.  
 info@PracticeConsultants.com  
**925-820-6758**

**www.PracticeConsultants.com**

**Optometry-Optical**  
 Busy Practice for Sale  
 Broward County Florida  
 2019 Gross \$906,030.00  
[OptometryPractice4Sale.com](http://OptometryPractice4Sale.com)

**Central Illinois Optometry  
 Practice for Sale**

**30 year practice, gross over  
 \$1,200,000 per year**

135 miles from Chicago, IL,  
 90 miles from Indianapolis, IN

Full service lab, same day  
 service, 2 exam rooms

**Call or text 217-497-2018**

**Do you have  
 CE Programs?**

**CONTACT US TODAY  
 FOR CLASSIFIED  
 ADVERTISING**

Toll free:  
**888-498-1460**  
 E-mail:  
**sales@kerhgroup.com**

**Career Opportunities**


**Staff Optometrist Wanted**

Bard Optical is a family owned full-service retail optometric practice with 22 offices (and growing) throughout Central Illinois. Bard Optical prides itself on having a progressive optometric staff whose foundation is based on one-on-one patient service. We are currently accepting CV/resumes for Optometrists to join our medical model optometric practice that includes extended testing. The practice includes but is not limited to general optometry, contact lenses and geriatric care. Salaried, full-time positions are available with excellent base compensation and incentive programs and benefits. Some part-time opportunities may also be available.

Current positions are available in Bloomington/Normal, Decatur/Forsyth, Peoria, Sterling and Canton as we continue to grow with new and established offices.

Please email your information to [mhall@bardoptical.com](mailto:mhall@bardoptical.com) or call Mick at 309-693-9540 ext 225. Mailing address if more convenient is:  
**Bard Optical**  
 Attn: Mick Hall, Vice President  
 8309 N Knoxville Avenue  
 Peoria, IL 61615

Bard Optical is a proud Associate Member of the Illinois Optometric Association.



**www.bardoptical.com**

**Equipment & Supplies**

**WHY PAY RETAIL?**



Electric power lift table and adjusts from 25" to 50" Tabletop is 20" X 52" Tabletop will accommodate three instruments. Push button switch control. NEW IN BOX. Wholesale Price \$1,195.00 Call 800-522-2275

**Do you have Products and Services for sale?**  
 Contact us today for classified advertising.  
 Toll free: 888-498-1460  
 E-mail: [sales@kerhgroup.com](mailto:sales@kerhgroup.com)

**Continuing Education**

**MEDICAL OPTOMETRISTS**

The American Board of Certification in Medical Optometry (ABCMO) is recognized at Joint Commission (JC) accredited medical facilities as issuing board certification in the specialty of medical optometry and those ABCMO certifies are eligible for credentialing at these facilities as specialists rather than general optometry practitioners.\*

The Joint Commission, the accepted national Gold Standard, reviews and accredits over 21,000 federal, state and local-chartered medical facilities.

**To Be Eligible for ABCMO board certification:**

1. Complete an accredited residency in medical optometry
2. Pass the national Advanced Competence in Medical Optometry Examination
3. Practice in a medical setting for a minimum of two years.†

**www.abcmo.org**



Visit [www.abcmo.org](http://www.abcmo.org) to understand how JC accredited medical facilities credential specialists and why specialty certification can enhance the careers of optometrists who complete residencies in medical optometry.

For Application procedures see [www.abcmo.org](http://www.abcmo.org) or contact [myers.kenj@gmail.com](mailto:myers.kenj@gmail.com)

\* At this time, 127 JC accredited hospitals, clinics and teaching institutions recognize ABCMO specialist certification.  
 † www.jointcommission.org  
 ‡ Waived for two years after residency

**REVIEW**  
 OF OPTOMETRY

Targeting Optometrists?

**CLASSIFIED ADVERTISING WORKS**

- JOB OPENINGS • CME PROGRAMS
- PRODUCTS & SERVICES • AND MORE...

Contact us today for classified advertising:  
 Toll free: 888-498-1460  
 E-mail: [sales@kerhgroup.com](mailto:sales@kerhgroup.com)



# Straight to the Point

Ocular trauma must be managed quickly, or else surgical intervention may be deemed necessary. **By Larae Zimprich, OD, and Richard Mangan, OD**

No optometrist wants to hear the words, “A pencil hit my eye, and now I am in so much pain.” However, everyday accidents do occur, and we have to be prepared when they walk in the door.

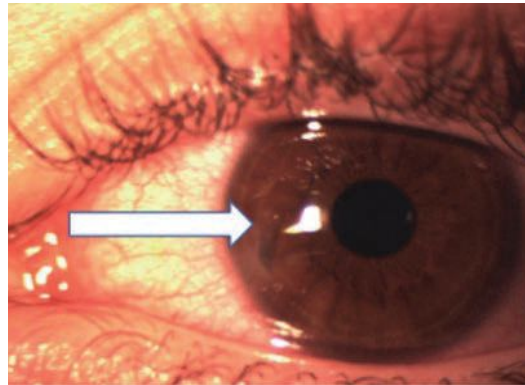
## Case History

A 15-year-old boy was sent to the school nurse after being struck in the left eye by a pencil that was thrown from across the classroom. The boy immediately noted pain, blurred vision and excessive tearing. After being evaluated by the school nurse, he returned to class and finished the school day with only mild irritation in the left eye. Upon waking the next morning, he noted more irritation and worsening of his vision. After a few hours at school, he was sent to the school nurse again for redness and irritation. He was then referred to a local optometrist for evaluation.

## Examination

His vision was 20/200 OS with an intraocular pressure of 3mm Hg and a shallow anterior chamber. The pupil was regular and round, without peaking. There were 2+ cells in the anterior chamber and mild flare. He had a small round, full thickness corneal defect, which was Seidel-positive. An eye shield was then placed over the eye, and he was referred to our clinic.

We were in agreement with the patient’s local optometrist, who diagnosed him with an open globe



**This patient was diagnosed with an open globe injury.**

injury secondary to corneal perforation. We placed the patient on topical moxifloxacin, oral Levaquin (levofloxacin, Johnson & Johnson) due to the amount of time that had passed since the accident and a cycloplegic for the pain. We used timolol—an aqueous suppressant—and a bandage contact lens with the hopes the wound would self-seal.

When the boy returned the next day, the wound was still leaking; therefore, surgical intervention was warranted. One suture was strategically placed to close the wound, and the patient was injected with intracameral moxifloxacin and started on topical steroids. When the patient returned the day after surgery, the vision in his left eye was 20/20, his intraocular pressure was 12mm Hg and he was Seidel-negative. He then began his post-op steroid taper.

## Discussion

The incidence of open globe injuries in the United States is 3.4 per 100,000 people each year, with the vast majority occurring in patients

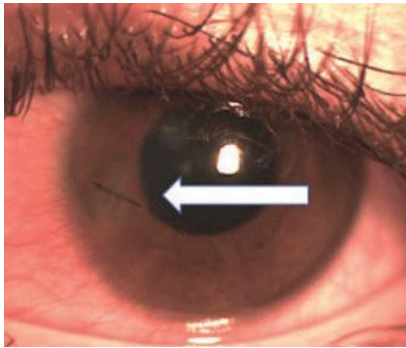
between the ages of 17 and 29 years old and in men.<sup>1</sup> Often the first doctors to see these patients after an injury, ODs should perform a thorough case history, pupil, visual acuity, intraocular pressure and slit lamp assessment. Do not check intraocular pressure with Goldmann tonometry if you suspect a full-thickness laceration.

Signs of open globe injury include penetrating lid injury, bullous subconjunctival hemorrhage, shallow anterior chamber,

blood in the anterior chamber, peaked pupil, iris disinsertion, lens dislocation, vitreous hemorrhage or retinal detachment and loss of red reflex.

It is important to rule out the presence of an intraocular foreign body with imaging. A CT scan of the brain and orbits is considered standard of care if you suspect an intraocular foreign body. A B-scan can also be performed but requires extreme caution to make sure minimal pressure is applied to the eye.

After diagnosing a patient with a ruptured globe, immediately refer them to an ophthalmologist for surgical repair. Open globe injuries should be treated within 12 to 24 hours to decrease endophthalmitis risk.<sup>2</sup> An eye shield should be applied and the patient instructed to not consume any food or drinks in case they have to be placed under general anesthesia during surgical repair. If broad-spectrum antibiotics are available, give a dose until they meet with an ophthalmologist.



**A strategically placed suture can help close a leaking wound.**

## Treatment

The ophthalmologist will determine the treatment plan. However, optometrists hold an important role in diagnosing and managing these patients. A conservative approach for wound leaks may include bandage contact lenses, aqueous suppressants or corneal glue. These therapies allow the cornea to heal itself without surgical repair. If the

wound continues to leak, like it did in this case, surgical repair will probably be necessary.

After surgery, the patient may then be placed on a topical steroid to reduce inflammation. Regardless of which approach is used, the patient will be placed on broad-spectrum oral antibiotics, topical antibiotics and sometimes intracameral or intravitreal antibiotics to prophylactically avoid endophthalmitis.<sup>3</sup> The addition of a topical cycloplegic can help with patient comfort. If the patient is unsure about their immunization history, administer a tetanus shot. Monitor these patients closely, with follow-up visits each day to ensure infection doesn't occur.

## The Ocular Trauma Score

This is used to educate, set expectations and prepare patients and their families following an open globe

injury. Visual acuity has remained one of the strongest predictors of the outcome.<sup>4</sup> Combining the patient's entering visual acuity and additional risk factors reveals the estimated percentages of different visual prognoses. Our patient had a 44% chance of seeing better than 20/40. Thankfully, the odds were in his favor, and he was able to see 20/20 again. ■

*Dr. Zimprich is a residency-trained optometrist at Vance Thompson Vision in Sioux Falls, SD. She specializes in anterior segment surgical care, including cataracts, corneal diseases, glaucoma and refractive surgeries.*

1. Batur M, Seven E, Esmer O, et al. Epidemiology of adult open globe injury. *J Craniofac Surg.* 2016;27(7):1636-41.
2. Blanch RJ, Bishop J, Javidi H, et al. Effect of time to primary repair on final visual outcome after open globe injury. *Br J Ophthalmol.* 2019;103(10):1491-4.
3. Wajda B. *The Wills Eye Manual.* Philadelphia: Lippincott Williams & Wilkins; 2016.
4. Scott R. The Ocular Trauma Score. *Community Eye Health.* 2015;28(91):44-5.

## Advertisers Index

<b>Akorn Pharmaceuticals</b> .....	<b>5</b>
.....(800) 932-5676	
.....www.MyAkornEyeCare.com	
<b>Akorn Pharmaceuticals</b> .....	<b>47</b>
.....www.theratears.com/professionals	
<b>Akorn Pharmaceuticals</b> .....	<b>65</b>
.....(800) 932-5676	
.....www.akorn.com	
<b>Allergan, Inc.</b> .....	<b>Cover Tip</b>
.....(833) 733-7675	
.....www.refreshbrand.com/doc	
<b>Bausch + Lomb</b> .....	<b>2 &amp; 3</b>
.....www.vyzultanow.com	
<b>Bausch + Lomb</b> .....	<b>23</b>
.....(800) 323-0000	
.....www.bausch.com	
<b>Bausch + Lomb</b> .....	<b>43</b>
.....(800) 323-0000	
.....www.LumifyDrops.com/Professional	
<b>Bausch + Lomb</b> .....	<b>99</b>
.....(800) 323-0000	
.....www.BauschInfuse.com	
<b>Bausch + Lomb</b> .....	<b>32 &amp; 33</b>
.....(800) 323-0000	
.....www.bausch.com	

<b>Berkshire Hathaway</b> .....	<b>15</b>
.....www.berxi.com	
<b>Bruder Ophthalmic Products</b> .....	<b>25</b>
.....(888) 827-8337	
.....eyes@bruderophthalmic.com	
.....www.bruder.com	
<b>Eyevance</b> .....	<b>29 &amp; 30</b>
.....(817) 677-6120	
.....www.eyevance.com	
<b>Eyevance</b> .....	<b>57 &amp; 58</b>
.....(817) 677-6120	
.....www.eyevance.com	
<b>Hubble Contacts</b> .....	<b>7</b>
.....www.hubblecontacts.com	
<b>Ivantis, Inc.</b> .....	<b>51 &amp; 52</b>
.....info@ivantisinc.com	
.....www.ivantisinc.com	
<b>Kala Pharmaceuticals</b> .....	<b>100</b>
.....(781) 996-5252	
.....info@kalarx.com	
.....www.kalarx.com	
<b>Keeler Instruments</b> .....	<b>9</b>
.....(800) 523-5620	
.....www.keelerusa.com	
<b>Lacrivera</b> .....	<b>17</b>
.....855-857-0518	
.....www.lacrivera.com	
<b>M&amp;S Technologies</b> .....	<b>19</b>
.....(847) 763-0500	
.....www.mstech-eyes.com	

<b>MacuLogix</b> .....	<b>21</b>
.....(888) 392-6801	
.....www.maculogix.com	
<b>Marco</b> .....	<b>27</b>
.....(800) 874-5274	
.....www.marco.com	
<b>Menicon America</b> .....	<b>11</b>
.....(800) 636-4266	
.....www.meniconamerica.com	
<b>Novartis / My Choice RX</b> .....	<b>12</b>
.....www.MyChoiceRx.com/hcp	
<b>Oculus</b> .....	<b>67</b>
.....(888) 519-5375	
.....ads@oculususa.com	
.....www.oculususa.com/dryeye	
<b>Ocusoft</b> .....	<b>61</b>
.....(800) 233-5469	
.....www.ocusoft.com	
<b>S4OPTIK</b> .....	<b>35 &amp; 37</b>
.....(888) 224-6012	
.....www.s4optik.com	
<b>TelScreen</b> .....	<b>45</b>
.....(502) 515-1806	
.....Wes.Harris@TelScreen.com	
.....www.TelScreen.com	
<b>X-cel Specialty</b> .....	<b>39</b>
.....(800) 241-9312	
.....xcelfinfo@xcelspecialtycontacts.com	
.....www.xcelspecialtycontacts.com	

This advertiser index is published as a convenience and not as part of the advertising contract. Every care will be taken to index correctly. No allowance will be made for errors due to spelling, incorrect page number, or failure to insert.



## An Unexpected Turn

Could the comorbid presentation of ptosis and strabismus in this patient indicate a neurological cause? **By Andrew S. Gurwood, OD**

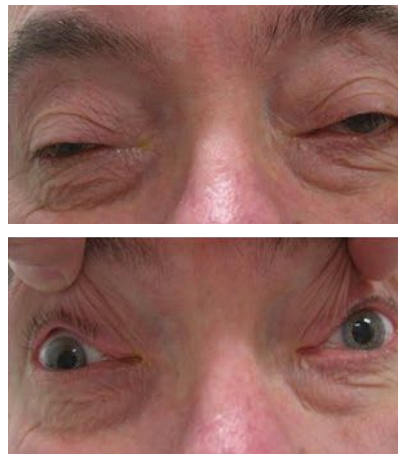### History

A 64-year-old Caucasian male presented to the office requesting a second opinion regarding what he described as a constant right eye turn. He explained that he realized the eye was suffering from reduced vision for approximately two years but could not elaborate on how the vision was lost. His motivation for seeking the correction was that he had recently failed the vision test for driving a school bus.

His ocular history included bilateral upper eyelid ptosis and right exotropia since childhood. He denied a history of double vision. He added that his brother and father have the same upper right eyelid presentation. He reported no systemic illness, no medications and denied allergies of any kind.

### Diagnostic Data

His best-corrected visual acuity measured 20/200 OD and 20/30



**Bilateral upper lid ptosis was plainly evident on physical examination. What might it portend?**

OS at distance and near through spectacles (-6.75 -2.75x050/+2.50, -6.00 -2.50x155/+2.50).

Refraction uncovered anisometropia OD>OS (-10.50 -3.50x60, -6.25 -2.50x50) not improving vision OD and improving vision OS to 20/25 at distance and near. His extraocular motilities were

sluggish in all gazes with decreased adduction ability OD. The pertinent external data is demonstrated in the photographs.

Confrontation fields were full once the lids were lifted. There was no afferent pupillary defect. Biomicroscopy of the anterior segment revealed normal tissues and anatomy with grade II nuclear sclerotic cataracts. Goldmann applanation tonometry measured 15mm Hg OU. The dilated fundus findings were normal peripherally and centrally with normal nerves (no evidence of optic atrophy) and maculae.

### Your Diagnosis

Does the case presented here require any additional tests, history or information? What would be your diagnosis? What is the patient's likely prognosis? To find out, please read the online version of this article at [www.reviewofoptometry.com](http://www.reviewofoptometry.com). ■

### Next Month in the Mag

Coming in December, *Review of Optometry* will present its 26th Annual Surgery Report. Articles in this series will include:

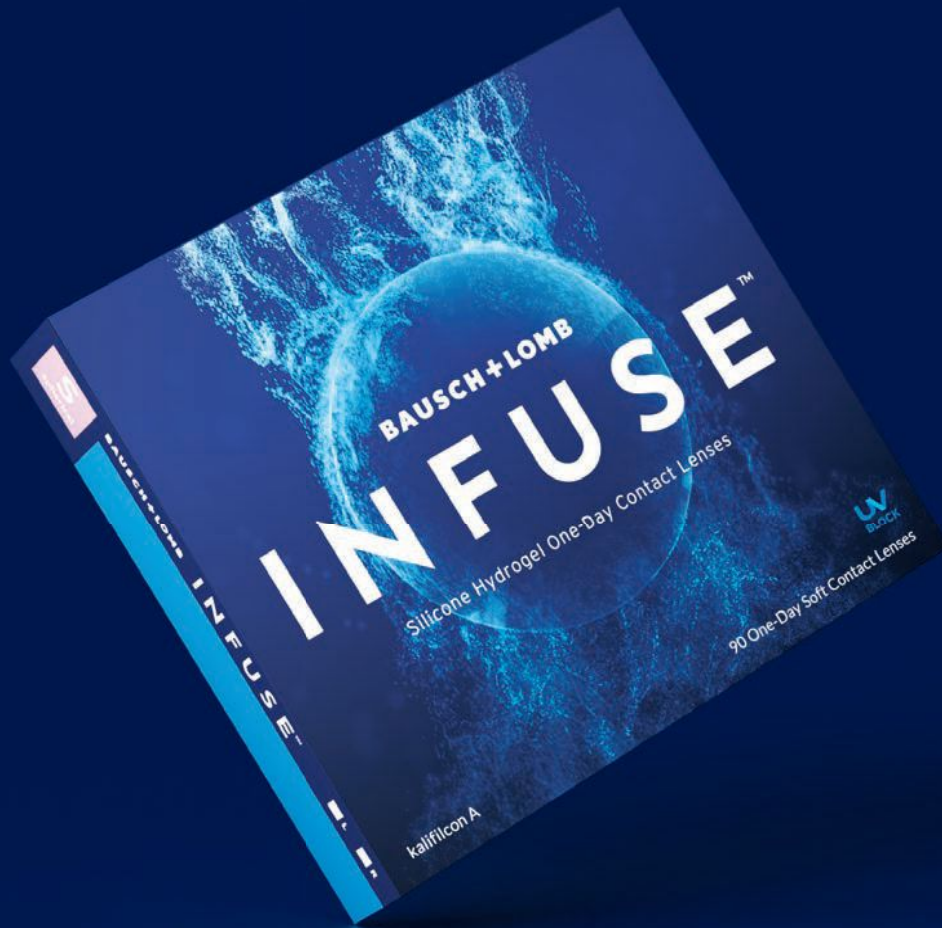- Meet the New Trifocal IOL
- Refractive Surgery in 2020: What's New?
  - Pearls on Post-op Care Regimens
  - MIGS: Indications and Complications

*Also included in December:*

- Annual Income Survey: Tracking 2020's Wild Ride

**Retina Quiz Answers** (from page 90)—Q1: c, Q2: a, Q3: b, Q4: c, Q5: d

REVIEW OF OPTOMETRY (ISSN 0147-7633) IS PUBLISHED MONTHLY, 12 TIMES A YEAR BY JOBSON MEDICAL INFORMATION LLC, 395 HUDSON STREET, 3RD FLOOR FLOOR, NEW YORK, NY 10014. PERIODICALS POSTAGE PAID AT NEW YORK, NY AND ADDITIONAL MAILING OFFICES. POSTMASTER: SEND ADDRESS CHANGES TO REVIEW OF OPTOMETRY, PO BOX 81, CONGERS, NY 10920-0081. SUBSCRIPTION PRICES: US: ONE YEAR \$56; TWO YEARS \$97, CANADA: ONE YEAR \$88, TWO YEARS \$160, INT'L: ONE YEAR \$209, TWO YEARS \$299. FOR SUBSCRIPTION INFORMATION CALL TOLL-FREE (877) 529-1746 (USA); OUTSIDE USA, CALL (845) 267-3065. OR EMAIL US AT REVOPPTOMETRY@CAMBEYWEST.COM. PUBLICATIONS MAIL AGREEMENT NO: 40612608. CANADA RETURNS TO BE SENT TO BLEUCHIP INTERNATIONAL, P.O. BOX 25542, LONDON, ON N6C 6B2.



# INFUSED FOR BALANCE

The only silicone hydrogel daily disposable with a next-generation material infused with ProBalance Technology™ to help maintain ocular surface homeostasis<sup>1</sup>



Next-Generation  
Material



Ocular Surface  
Homeostasis



ProBalance  
Technology™

Find balance at [BauschINFUSE.com](https://www.BauschINFUSE.com)

REFERENCE: 1. Data on file. Bausch & Lomb Incorporated. Rochester, NY.

®/™ are trademarks of Bausch & Lomb Incorporated or its affiliates.  
©2020 Bausch & Lomb Incorporated or its affiliates. INF.0084.USA.20

**BAUSCH+LOMB**

See better. Live better.

**NOW  
APPROVED!** COMING  
SOON

  
**EYSUVIS**<sup>™</sup>  
(loteprednol etabonate  
ophthalmic suspension) 0.25%

  
**kala**  
PHARMACEUTICALS