

# REVIEW<sup>®</sup> OF OPTOMETRY

May 15, 2020

www.reviewofoptometry.com

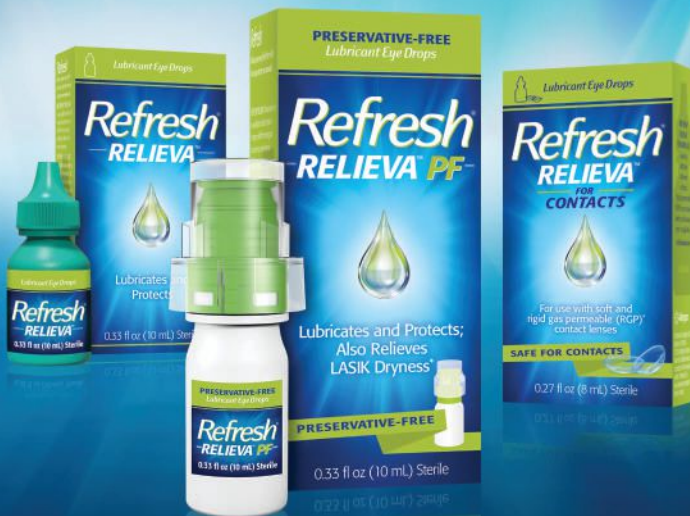## COVID-19's IMPACT

...and How Optometry  
Can Help

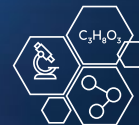
THERE'S RELIEF AND THEN THERE'S

# RELIEVA<sup>TM</sup>

FOR DRY, IRRITATED EYES.



The only family of products  
in the U.S. with CMC, HA  
(inactive ingredient), and  
HydroCell<sup>TM</sup> technology.



[refreshbrand.com/doc](http://refreshbrand.com/doc)



EARN 2 CE CREDITS: Maximizing OCT in the Diagnosis of Glaucoma, p. 76

# REVIEW<sup>®</sup> OF OPTOMETRY

May 15, 2020

[www.reviewofoptometry.com](http://www.reviewofoptometry.com)

## COVID-19's IMPACT

...and How Optometry  
Can Bounce Back

*Its disruptions were swift and seismic,  
but ODs are ready to move on.*

- **Planning for Post-COVID Life, p. 3**
- **Patient Care Morphs During COVID-19, p. 30**
- **20 Tips For Reopening Amid COVID-19, p. 36**



ALSO:


21st Annual Dry Eye Report, *begins p. 42*

Statins and the Eye: What You May Not Know, p. 62

Five Cases You Shouldn't Refer, p. 68

# INTRODUCING VISUAL FIELD SUITE

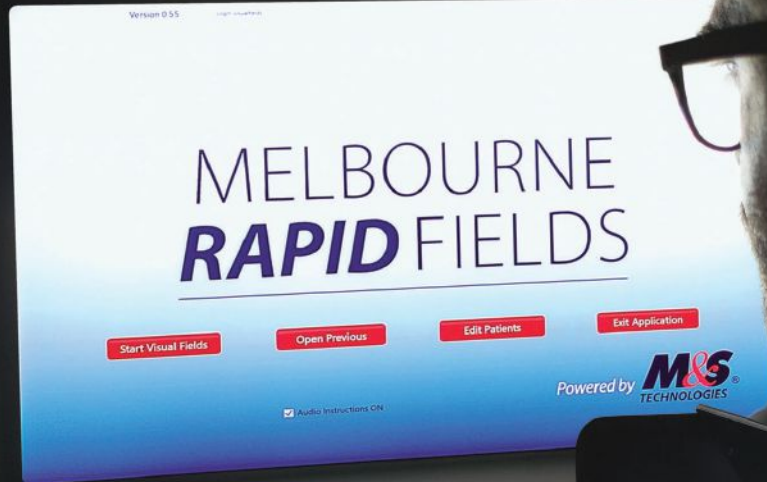M&S | Melbourne Rapid Fields (MRF)



In-Clinic



Web-Based



## Revolutionary Visual Field Testing

**MRF is a simple solution, meticulously designed and calibrated to perform Visual Field tests in-clinic and at home, developed by a name you can trust.**

Optimize your practice with revolutionary Visual Field testing. M&S offers 2 options for state of the art, accurate, reliable testing. The **In-Clinic** testing offers a unique space saving design. The simple user friendly interface allows for reduced test time, progression analysis and low anxiety for the patient.

Our advanced **Web-based** software makes at-home visual field testing a viable alternative to office visits. This offers convenient scheduling for both patient and doctor. Immediate reliable HFA style report is securely transmitted to the doctor. Record patient progression with ease and confidence.

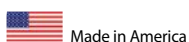
Peer review and published research by leading journals.

**Keep clinics safe. Sanitizes in under 2 minutes.**



The First Choice in Vision Testing Systems

**847-763-0500 mstech-eyes.com**



Powered by:

EyeSimplify™



## IN THE NEWS

A recent study found that pharmacological pupil dilation worsened angle closure in half of untreated acute primary angle closure (APAC) patients with narrow angles. Swept-source OCT captured 360-degree scans of the angles of 106 APAC patients older than age 50 before and one hour after dilation. Angle narrowing was also associated with a shallower anterior chamber and a bigger lens vault.

Narayanaswamy A, Baskaran M, Tun TA, et al. Effect of pharmacological pupil dilatation on angle configuration in untreated primary angle closure suspects: a swept source anterior segment optical coherence tomography study. *J Glaucoma*. March 27, 2020. [Epub ahead of print].

A recent study found that patients with mild cognitive impairment and Alzheimer's disease experienced anatomical and functional retinal changes, including reductions in nerve fiber layer thickness, arterial blood flow, arterial vessel diameter and arteriovenous difference in oxygen saturation. "This indicates alterations in retinal oxygen metabolism in patients with neurodegenerative disease," the researchers concluded in their paper.

Szegedi S, Dal-Bianco P, Stögmann E, et al. Anatomical and functional changes in the retina in patients with Alzheimer's disease and mild cognitive impairment. *Acta Ophthalmologica*. March 25, 2020. [Epub ahead of print].

Researchers recently found that the trajectory of functional decline in eyes treated for wet AMD was greater than what has been reported. After monitoring patients for approximately three years, the team reported a median distance visual acuity (DVA) of 58.0 letters, which decreased by 4.3 letters per year. This rate was not influenced by injection rate after adjusting for key covariates. DVA was similar among patients, regardless of whether they switched between ranibizumab and aflibercept.

Evans RN, Reeves BC, Phillips D, et al. Long-term outcomes of usual care in patients with neovascular age-related macular degeneration in the IVAN trial. *Ophthalmology*. March 27, 2020. [Epub ahead of print].

# Practices Plan for Post-COVID Life

ECPs look to make a return to normalcy an immediate reality. **By Mark De Leon, Associate Editor**

State-mandated shutdowns enacted as the coronavirus spread across the United States have left the eye care profession largely on hiatus since mid-March, but practices are now prepping to reopen, albeit with downscaled services and realistic ambitions for the near term. After restricting services to emergency appointments only, attempting telemedicine consults and using unconventional methods to stay in touch with patients, optometrists have resumed business on their mind but are unsure on how to put that into action.

To track both the sentiment and circumstances of a profession operating in crisis mode, Jobson (publisher of *Review of Optometry*) launched a weekly survey in mid-March. Data through late April show eye care practitioners (ECPs) still reeling—respondents pegged their career-related stress at 7.0 on a 1-10 scale—but ready to rebound.

## Open to Telehealth

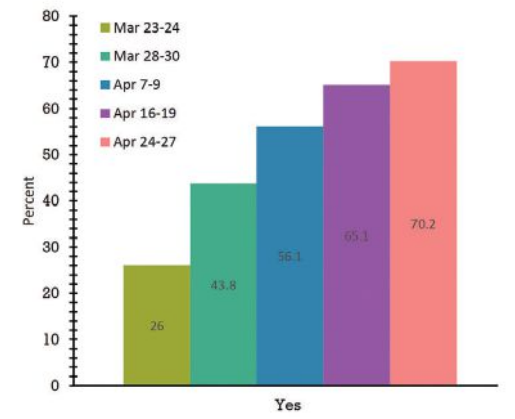
The crisis continues to push doctors to offer telehealth services. According to the most recent Jobson ECP Coronavirus Survey (Wave 7), optometrists are still keeping up with patients while maintaining their

distance, by relying on phone calls (78.6% of respondents) and video or photo consultations (81.6%). This correlates with a similar increase in patients' curiosity in accessing remote services, as 41.4% of respondents reported their patients current express interest, compared with 17.3% at the start of the crisis.

Optometrists have gotten used to billing telehealth consultations as well, as the initial 26% who were comfortable with billing telehealth in mid-March has grown to about 70% of respondents who report having done so in the past two weeks (*Figure 1*). Those doing so are starting to feel more confident with the process, with only 25.2% saying they needed help in mid-April vs. 32.4% one month prior.

(Continued on p. 7)

**Fig. 1. Have You Billed for Telehealth Services in the Last Two Weeks?**



Source: Jobson ECP Coronavirus Survey (Wave 7)

Help your patients with **DIABETIC RETINOPATHY (DR), and**

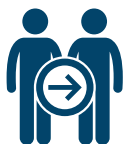# HELP DRIVE PATIENT OUTCOMES

Through early detection, monitoring, and timely referral, you can play a pivotal role in managing your DR patients' vision<sup>1-3</sup>

## IF YOU SEE OR SUSPECT DR:



**Educate your patients** about living with DR and potential treatment options<sup>2,3</sup>



### Refer

DR patients for timely intervention

- According to the AOA, you should refer patients with<sup>2,3</sup>
  - Severe nonproliferative DR (NPDR) within 2 to 4 weeks
  - Proliferative DR (PDR) within 1 week



### Follow up

to ensure they have visited a retina specialist

## INDICATIONS AND IMPORTANT SAFETY INFORMATION

EYLEA® (aflibercept) Injection 2 mg (0.05 mL) is indicated for the treatment of patients with Neovascular (Wet) Age-related Macular Degeneration (AMD), Macular Edema following Retinal Vein Occlusion (RVO), Diabetic Macular Edema (DME), and Diabetic Retinopathy (DR).

## CONTRAINDICATIONS

- EYLEA is contraindicated in patients with ocular or periocular infections, active intraocular inflammation, or known hypersensitivity to aflibercept or to any of the excipients in EYLEA.

## WARNINGS AND PRECAUTIONS

- Intravitreal injections, including those with EYLEA, have been associated with endophthalmitis and retinal detachments. Proper aseptic injection technique must always be used when administering EYLEA. Patients should be instructed to report any symptoms suggestive of endophthalmitis or retinal detachment without delay and should be managed appropriately. Intraocular inflammation has been reported with the use of EYLEA.

**References:** **1.** Early Treatment Diabetic Retinopathy Study Research Group. Fundus photographic risk factors for progression of diabetic retinopathy. ETDRS report number 12. *Ophthalmology*. 1991;98(5 suppl):823-833. **2.** Care of the Patient With Diabetes Mellitus: Quick Reference Guide. American Optometric Association website. <http://bit.ly/2M22OUJ>. Accessed August 7, 2019. **3.** Ferrucci S, Yeh B. Diabetic retinopathy by the numbers. *Rev Optom*. June 15, 2016. <http://bit.ly/2KNNJ4E>. Accessed August 7, 2019.

EYLEA is a registered trademark of Regeneron Pharmaceuticals, Inc.

## REGENERON



# EYLEA<sup>®</sup>

## (aflibercept) Injection

### For Intravitreal Injection

Brought to you by **REGENERON**

Visit [diabeticretinaldisease.com](http://diabeticretinaldisease.com) for additional information and useful patient resources



#### Continue to monitor your patients with DR<sup>2,3</sup>

- The AOA recommends frequent monitoring of patients<sup>2</sup>
  - At least every 6 to 8 months in patients with moderate NPDR and more frequently for patients with greater disease severity<sup>2</sup>

**The more you know** about emerging clinical science about anti-VEGF and other potential therapies for DR, the better you can help inform your patients about how treatment may be able to help

**Refer patients to a retina specialist** who can treat DR<sup>2,3</sup>

## WARNINGS AND PRECAUTIONS (cont'd)

- Acute increases in intraocular pressure have been seen within 60 minutes of intravitreal injection, including with EYLEA. Sustained increases in intraocular pressure have also been reported after repeated intravitreal dosing with VEGF inhibitors. Intraocular pressure and the perfusion of the optic nerve head should be monitored and managed appropriately.
- There is a potential risk of arterial thromboembolic events (ATEs) following intravitreal use of VEGF inhibitors, including EYLEA. ATEs are defined as nonfatal stroke, nonfatal myocardial infarction, or vascular death (including deaths of unknown cause). The incidence of reported thromboembolic events in wet AMD studies during the first year was 1.8% (32 out of 1824) in the combined group of patients treated with EYLEA compared with 1.5% (9 out of 595) in patients treated with ranibizumab; through 96 weeks, the incidence was 3.3% (60 out of 1824) in the EYLEA group compared with 3.2% (19 out of 595) in the ranibizumab group. The incidence in the DME studies from baseline to week 52 was 3.3% (19 out of 578) in the combined group of patients treated with EYLEA compared with 2.8% (8 out of 287) in the control group; from baseline to week 100, the incidence was 6.4% (37 out of 578) in the combined group of patients treated with EYLEA compared with 4.2% (12 out of 287) in the control group. There were no reported thromboembolic events in the patients treated with EYLEA in the first six months of the RVO studies.

## ADVERSE REACTIONS

- Serious adverse reactions related to the injection procedure have occurred in <0.1% of intravitreal injections with EYLEA including endophthalmitis and retinal detachment.
- The most common adverse reactions (≥5%) reported in patients receiving EYLEA were conjunctival hemorrhage, eye pain, cataract, vitreous detachment, vitreous floaters, and intraocular pressure increased.

**Please see Brief Summary of Prescribing Information on the following pages.**





# Meeting New COVID Challenges

(Continued from p. 3)

## Slowly But Surely

A question on ECPs' minds is when they can resume business as usual—as usual as possible, at least. Many continue rescheduling appointments for either May or June.

The latest survey cut to the chase and asked practice owners how many more weeks they thought their businesses could survive with their doors shuttered. Most respondents believed they could tough it out for one or two more months (34.3%), while 30.2% could only plausibly do another three or four weeks. The survey also asked how soon they would expect to be up and running after being allowed to reopen. A resounding 41.2% answered immediately, with 29.9% saying they would open within a week.

### Reality of Layoffs

Another unfortunate impact on businesses is staff downsizing. By late April, about 60% of ECPs in the survey had admitted to letting go or laying off staff, a sizable increase from 40.8% at the end of March. About 15% of respondents said they were recently furloughed or laid off, and 89.6% of them have applied for unemployment.

The federal Coronavirus Aid, Relief and Economic Security (CARES) Act is a relief package looking to make an estimated \$153.5 billion available to the public health sector, another \$377 billion to small businesses and \$500 billion to large corporations. Depending on the practice, optometry may fall into any of those three categories. About 83% of practice owners said they have applied for aid through the relief package.

Snell K. What's inside the senate's \$2 trillion coronavirus aid package. National Public Radio. [www.npr.org/2020/03/26/821457551/whats-inside-the-senate-s-2-trillion-coronavirus-aid-package](http://www.npr.org/2020/03/26/821457551/whats-inside-the-senate-s-2-trillion-coronavirus-aid-package). March 26, 2020. Accessed April 30, 2020.

Currently, 74.5% of respondents would greatly appreciate guidance on reopening, a steady increase from the 48.2% who said the same at the start of the weekly survey series. Almost 58% are now working on a written plan for reopening their practice, and many intend to use phone calls, social media and email to communicate to patients when their practice has re-opened.

When their practices do reopen, 41% of respondents believe they will resume at their normal schedule, while 33.8% believe they'll initially operate with shortened hours and 15.7% expect to put in longer hours to compensate for the additional time needed per patient encounter.

## Safety First

Despite an eagerness to get things back in motion, ECPs understand resuming business necessitates conducting it as safely as possible. Asked what changes they will implement upon returning to routine in-person care, 87.1% said they will reduce the number of people in the office at the same time, 85.4% will change sanitization processes and 83.9% will screen patients for COVID-19 exposure.

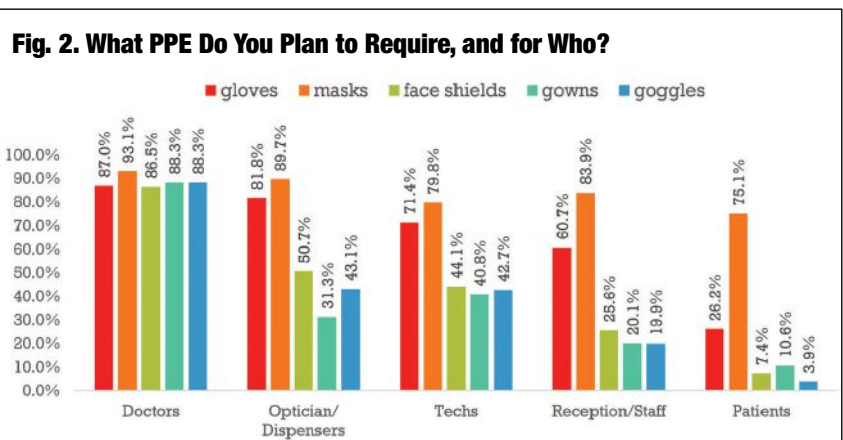
The most recent survey also asked

### On the Road Again

Educational events large and small have been postponed, curtailed or canceled since social distancing policies began in mid-March. The majority of ECPs surveyed feel ready to attend events within driving distance by the fall of this year (25.5%) or sometime in 2021 (25.1%). As for air travel, 33.1% of respondents will feel comfortable going to meetings by plane sometime in 2021. However, respondents to the most recent survey believe that travel both within driving and flying distance will occur most likely sometime in 2021 (31.7% and 38%, respectively).

practitioners what personal protective equipment (PPE) they will implement and maintain for themselves and their colleagues (Figure 2). While the majority of respondents believe they will require all staff members to wear masks and gloves in some capacity, they also intend for doctors to wear masks, gloves, face shields, gowns and goggles. For visiting patients, many practice owners believe they will only require them to wear masks.

Cautiously and with a fair share of anxiety, optometrists and other ECPs nationwide seem ready to interact with patients face to face again.



Source: Jobson ECP Coronavirus Survey (Wave 7)

## FA Detects DR Microaneurysms

Ultra-widefield fluorescein angiography (UWF-FA) may be a more precise method for finding microaneurysms than ultra-widefield color imaging (UWF-CI) when grading diabetic retinopathy (DR) severity, a study in the *British Journal of Ophthalmology* reports. The investigation found UWF-FA was able to detect three to five times more microaneurysms than UWF-CI and identify up to 3.5 more fields affecting DR severity.

The retrospective study included patients with Type 1 or 2 diabetes mellitus who had UWF-FA and UWF-CI done within a two-week timeframe. The investigators manually counted microaneurysms in individual Early Treatment Diabetic Retinopathy Study (ETDRS) and extended ultrawide field zones. The study determined DR severity based on fields with 20 or more microaneurysms. Zero fields were classified

as mild, one to three fields were deemed moderate and four or more were considered severe.

In 193 patients (288 eyes), 2.4% had no DR, 29.9% had mild non-proliferative DR (NPDR), 32.6% had moderate NPDR, 22.9% were classified as having severe NPDR and 12.2% had proliferative DR.

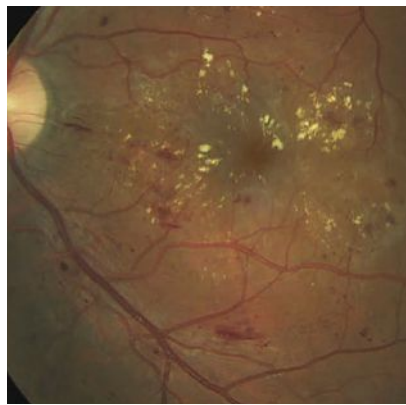


Photo: Erik Hanson, MD

**UWF-FA may detect more scattered microaneurysms, compared with ultrawide field color imaging.**

Overall, UWF-FA microaneurysm counts were 3.5-fold higher than those found in UWF-CI. Specifically, they were 3.2 times higher in ETDRS fields and 5.3 times higher in extended ETDRS fields, in addition to being higher in Type 1 diabetes compared with Type 2.

In 246 NPDR eyes graded with UWF-CI, UWF-FA found 1.6 times to 3.5 times more fields with 20 or more microaneurysms.

The study found fair agreement between imaging modalities, although differences at all DR severity levels limited direct comparison between the modalities, the researchers noted. However, correcting UWF-FA microaneurysm counts substantially improved DR severity agreement between the modalities, they added.

Ashraf M, Sampani K, AbdelAI O, et al. Disparity of microaneurysm count between ultra-wide field color imaging and ultra-wide field fluorescein angiography in eyes with diabetic retinopathy. *Br J Ophthalmol*. February 28, 2020. [Epub ahead of print].

## Ocular Antibiotic Resistance Still Prevalent

Antibiotic therapeutics are used to treat confirmed bacterial cases and, in some cases, mere suspects as well. However, liberal use of them can result in antibiotic resistant strains of bacteria and, eventually, untreatable disease. The research community is on the watch for that eventuality and an update to the well-known Antibiotic Resistance Monitoring in Ocular Microorganisms (ARMOR) study shows that bacteria continue to win the war.

Methicillin resistance and multidrug resistance are prevalent among staphylococci, according to the investigators. They looked into more than 6,000 isolates of

*Staphylococcus aureus*, coagulase-negative staphylococci (CoNS), *Streptococcus pneumoniae*, *Pseudomonas aeruginosa* and *Haemophilus influenzae* collected between 2009 and 2018.

Specifically, the research team note in the study, *S. aureus* and CoNS isolates were most methicillin resistant and more likely to be concurrently resistant to macrolides, fluoroquinolones and aminoglycosides compared with methicillin-susceptible isolates. Multidrug resistance was observed among methicillin-resistant *S. aureus*.

Differences in antibiotic resistance were found among isolates by patient age, with

older patients more likely to have resistance than pediatric patients. However, the study shows, even for pediatric patients, the mean percentage of antibiotic resistance—including methicillin resistance among staphylococcal isolates—was notable.

The study did show that *P. aeruginosa* and *H. influenzae* isolates have low resistance overall.

Although resistance is high, the researchers note that the resistance profiles were mostly unchanged during the 10-year study period.

Asbell P, Sanfilippo C, Sahm D, et al. Trends in antibiotic resistance among ocular microorganisms in the United States from 2009 to 2018. *JAMA Ophthalmol*. April 9, 2020. [Epub ahead of print].



# WORKING TOGETHER to relieve dry eyes

Clinically proven to reduce the signs and symptoms of dry eyes<sup>1</sup>

**47%**  
improvement  
in symptoms

**20%**  
improvement  
in tear breakup time

**67%**  
reduction  
in number of  
glands blocked

**40%**  
improvement  
in meibum quality

Critical **first steps** to treating dry eye symptoms include ocular lubricants, lid hygiene and dietary modifications such as oral fatty acid supplementation.<sup>2</sup>  
-2017 DEWS II Report



**RESTORES**



**CLEANSES**



**NOURISHES**

More than eye drops,  
dry eye therapy™



[theratears.com/professionals](http://theratears.com/professionals)



**References:** 1. Ngo W, Srinivasan S, Houtman D, Jones L. The relief of dry eye signs and symptoms using a combination of lubricants, lid hygiene and ocular nutraceuticals. *J Optom.* 2017 Jan-Mar;10(1):26-33. 2. Jones L, Downie L, Korb D, et al. TFOS DEWS II Management and Therapy Report. *Ocul Surf.* Jul 2017;15:575-628.  
© 2020 Akorn Consumer Health | A Division of Akorn, Inc. | M16-040-01

## Glaucoma Index Finds VF Progression Earlier

Visual field (VF) progression is often a key clue for clinicians to decide on the right course of therapy for their glaucoma patients. A new study in *JAMA Ophthalmology* found one tracker—the glaucoma rate index—was able to detect long-term VF progression earlier than two other methods: pointwise linear regression or guided progression analysis.

The study also found the glaucoma rate index maintained a low rate of false-positive estimates, and agreement among all three tested methods was moderate at best and showed differences, depending on baseline severity.

Researchers looked at the three different measures to detect VF progression in 729 eyes of 567 primary open-angle glaucoma patients.

Patients in the study had six VF tests performed within about three years. A total of 176 subjects (257

eyes) were treated at a tertiary glaucoma center. Additional data was collected from 391 participants (472 eyes) in the Advanced Glaucoma Intervention Study. The data was collected from 1988 to 2004 and analyzed from 2018 to 2019.

The study compared estimates of VF progression using each of the three methods in addition with a subset of patients with likely VF progression and likely VF stability.

Baseline mean deviation was about -6.7 and patients were followed up at around nine years.

The proportion of eyes labeled as progressing was 27.7% in guided progression analysis, 33.5% in pointwise linear regression and highest at 52.9% in the glaucoma rate index. The pairwise difference for glaucoma rate index vs. pointwise linear regression was 20%, 25% for the glaucoma rate index vs. guided progression analysis and 6% for pointwise linear regression vs.

guided progression analysis.

The glaucoma rate index showed the shortest median time to progression at 8.8 years compared with guided progression analysis and pointwise linear regression, which both showed a rate of more than 16 years. The subgroup with likely progression had similar results.

For that subgroup, the proportions of progressing eyes were 73.7% for guided progression analysis, 81.4% for pointwise linear regression and 92.9% for the glaucoma rate index. The pairwise difference for the glaucoma rate index vs. pointwise linear regression was 11.5%, 19.2% for the glaucoma rate index vs. guided progression analysis and 7.7% for pointwise linear regression compared to the guided progression analysis.

Salazar D, Morales E, Rabiolo A, et al. Pointwise methods to measure long-term visual field progression in glaucoma. *JAMA Ophthalmol.* April 2, 2020. [Epub ahead of print].

## OCT Matches Ultrasound in Pre-op Evaluation

Before their patients go in for any surgeries, optometrists should have as complete a picture of their patient's eye health as possible. This includes traumatic cataract patients, who first need to be evaluated for any posterior capsule (PC) defect. Traditionally, this is accomplished using ultrasound biomicroscopy (UBM), but new research is suggesting that swept-source OCT (SS-OCT) works just as well.<sup>1</sup> That's good news for patients, as UBM, while technically noninvasive, can be uncomfortable and requires the eye to be anesthetized.<sup>2</sup>

Researchers looked at 67 eyes

from 67 patients—60 males and seven females, with a mean age of 34 ( $\pm 14$  years). All the patients had a traumatic cataract severe enough to prevent slit lamp evaluation of the PC. They were evaluated under both 50MHz UBM and SS-OCT before surgery. All underwent the same surgical technique.<sup>1</sup>

Evaluation of the patients showed the sensitivity (96.8%), specificity (66.7%) and accuracy (82%) values for SS-OCT. For UBM, the sensitivity, specificity and accuracy values were 82.6%, 57.9% and 71.4% respectively. Positive predictive and negative predictive values for SS-OCT were 75% and 95.2%. For

UBM, they were 70.4% and 73.3% respectively.<sup>1</sup>

Investigators say these numbers show that both imaging techniques are effective. SS-OCT is at least comparable, or superior in some ways, to UBM in detecting preoperative post-traumatic PC rupture. That team recommends preoperative assessment of all traumatic cataracts with SS-OCT as a part of surgical planning.<sup>1</sup> ■

1. Tabatabaei S, Soleimani M, Etesali H, Naderan M. Accuracy of swept source optical coherence tomography and ultrasound biomicroscopy for evaluation of posterior lens capsule in traumatic cataract. *Am J Ophthalmol.* April 2, 2020. [Epub ahead of print].

2. Wills Eye Hospital. [www.willseye.org/treatment/ultrasound](http://www.willseye.org/treatment/ultrasound). Ultrasound. Accessed April 30, 2020.

# Proven Formulation. Exactly.

**ONLY PreserVision® contains the EXACT levels of nutrients** recommended by the National Eye Institute to help reduce the risk of progression of AMD based on the AREDS Studies<sup>\*,†,1</sup>

Patented  
formula



Recommend the most studied eye vitamin brand<sup>§</sup>

For samples, call **1-844-BL-VITES** (1-844-258-4837)

**\*These statements have not been evaluated by the Food and Drug Administration. This product is not intended to diagnose, treat, cure, or prevent any disease.**

<sup>†</sup>For people with moderate to advanced AMD.

<sup>‡</sup>vs original PreserVision AREDS 2 Eye Vitamin Soft Gels.

<sup>§</sup>Based on the AREDS and AREDS2 clinical studies.

AMD=age-related macular degeneration; AREDS=Age-Related Eye Disease Study.

**Reference: 1.** Age-Related Eye Disease Study 2 (AREDS2) Research Group. Lutein + zeaxanthin and omega-3 fatty acids for age-related macular degeneration: the Age-Related Eye Disease Study 2 (AREDS2) randomized clinical trial. *JAMA*. 2013;309(19):2005-2015.

PreserVision is a trademark of Bausch & Lomb Incorporated or its affiliates. AREDS and AREDS2 are registered trademarks of the United States Department of Health and Human Services (HHS).  
© 2020 Bausch & Lomb Incorporated or its affiliates. PN09465 PVN.0096.USA.19

**BAUSCH + LOMB**

# Contents

Review of Optometry  
May 15, 2020

## COVER FOCUS: COVID-19

### 30 Patient Care Morphs During COVID-19

From telemed to ER visits, doctors and hospitals are finding creative ways to take care of those in need.

By Jane Cole, Contributing Editor

### 36 20 Tips For Reopening Amid COVID-19

Here's advice on how you can hit the ground running and thrive in a world with coronavirus.

By Jane Cole, Contributing Editor

## 21st ANNUAL DRY EYE REPORT

### 42 Treat the Front Before the Cut

The surgeon will remove the patient's cataract, but it's your job to make sure the eye is healthy enough for surgery, or else to help get it there. By Thomas Chester, OD

### 48 Diet: Why Dry Eye Hangs in the Balance

What we eat—and don't eat—is impacting our ocular health. Here's what you need to know.

By Katherine Sanford, OD

### 56 Don't Overlook Aqueous-deficient Dry Eye

Familiarize yourself with this subset so that you're better able to detect and manage it if it does present.

By Candice Tolud, OD

## ALSO INSIDE:

### 62 Statins and the Eye: What You Might Not Know

These lipid-altering drugs are changing lives for the better, but the optometrist is responsible for monitoring their many impacts—good and bad—on ocular health. By Richard Zimbalist, OD, Angella Gentry, OD, and Carrie Ho, OD

Earn 2 CE Credits:

### 76 Maximizing OCT in the Diagnosis and Management of Glaucoma

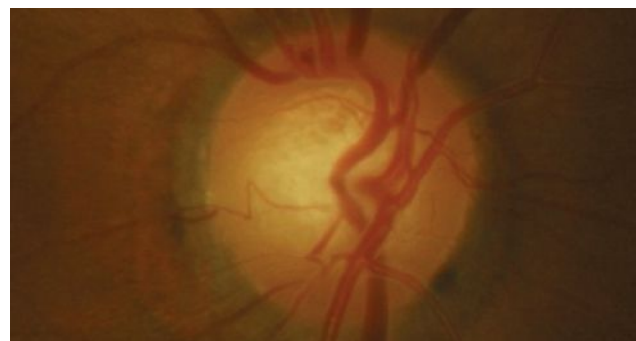
This technology has become an integral part of glaucoma care, and optometrists must understand how to accurately use it.

By Danica Marrelli, OD

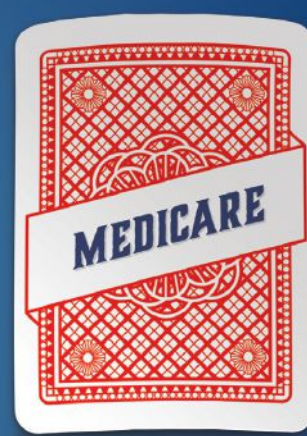
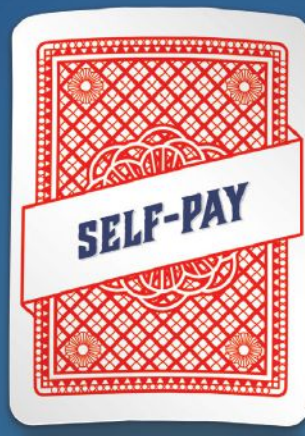### 68 Top Five Cases You Shouldn't Refer

Don't be afraid to keep these patients in your practice; you have the skillset and scope of practice to help them.

By Laine S. Higa, OD



# Is access to eye care prescriptions a guessing game?



**Now EVERY PATIENT wins.**

With MyChoiceRx™, every patient gets the same set price on select branded Novartis medications, regardless of coverage.

 **DUREZOL**®  
(difluprednate ophthalmic emulsion) 0.05%

**ILEVRO**®  
(nepafenac ophthalmic suspension) 0.3%

**TRAVATAN Z**®  
(travoprost ophthalmic solution) 0.004%

Learn more at [MyChoiceRx.com/hcp](https://MyChoiceRx.com/hcp).

Open your camera app and point here to visit [MyChoiceRx.com](https://MyChoiceRx.com).



# Departments

Review of Optometry May 15, 2020

## 3 News Review

## 16 Outlook

Adapt and Overcome  
**JACK PERSICO**

## 18 Through My Eyes

2020: The Year Of COVID-19  
**PAUL M. KARPECKI, OD**

## 20 Chairside

Time Is On My Side  
**MONTGOMERY VICKERS, OD**

## 22 Clinical Quandaries

Slice of Life  
**PAUL C. AJAMIAN, OD**

## 24 Urgent Care

Unmask This Cancer Imposter  
**JIM WILLIAMSON, OD,  
ABBEY KIRK, OD, AND  
RICHARD MANGAN, OD**

## 28 Coding Connection

Ocular Surface Coding Potpourri  
**JOHN RUMPAKIS, OD, MBA**

## 86 Cornea + Contact Lens Q&A

Running Out of Options  
**JOSEPH P. SHOVLIN, OD**

## 88 The Essentials

Track the Hill of Vision  
**BISANT A. LABIB, OD**

## 90 Therapeutic Review

Managing Neovascular Glaucoma  
**JOSEPH W. SOWKA, OD**

## 92 Review of Systems

A Common Denominator  
**CARLO J. PELINO, OD, AND  
JOSEPH J. PIZZIMENTI, OD**

## 94 Retina Quiz

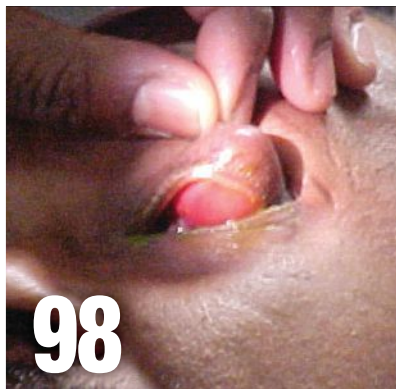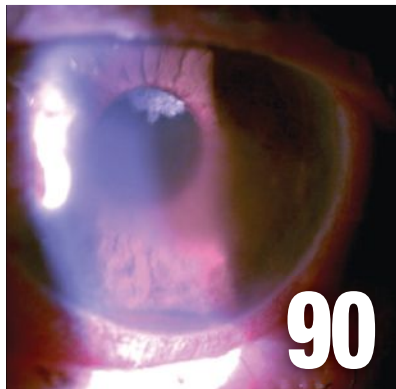
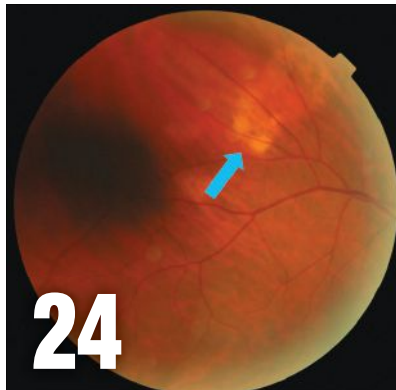
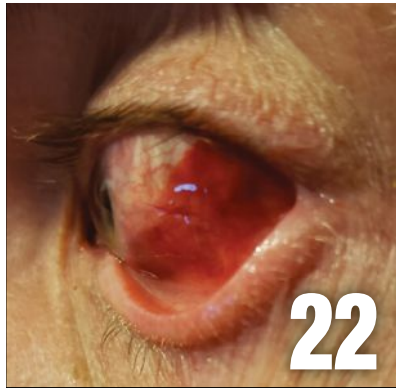
Repairing a Misdiagnosis  
**RAMI ABOUMOURAD, OD, AND  
MARK T. DUNBAR, OD**

## 96 Advertisers Index

## 97 Classifieds

## 98 Diagnostic Quiz

A Bumpy Ride  
**ANDREW S. GURWOOD, OD**



**REVIEW**<sup>®</sup>  
OF OPTOMETRY

### BUSINESS OFFICES

19 CAMPUS BLVD., SUITE 101  
NEWTOWN SQUARE, PA 19073

### CEO, INFORMATION SERVICES GROUP

MARC FERRARA  
(212) 274-7062 • MFERRARA@JOBSON.COM

### PUBLISHER

JAMES HENNE  
(610) 492-1017 • JHENNE@JOBSON.COM

### REGIONAL SALES MANAGER

MICHELE BARRETT  
(610) 492-1014 • MBARRETT@JOBSON.COM

### REGIONAL SALES MANAGER

MICHAEL HOSTER  
(610) 492-1028 • MHOSTER@JOBSON.COM

### VICE PRESIDENT, OPERATIONS

CASEY FOSTER  
(610) 492-1007 • CFOSTER@JOBSON.COM

### VICE PRESIDENT, CLINICAL CONTENT

PAUL M. KARPECKI, OD, FAAO  
PKARPECKI@JOBSON.COM

### PRODUCTION MANAGER

FARRAH APONTE  
(212) 274-7057 • FAPONTE@JOBSON.COM

### SENIOR CIRCULATION MANAGER

HAMILTON MAHER  
(212) 219-7870 • HMAHER@JHIHEALTH.COM

### CLASSIFIED ADVERTISING

(888) 498-1460

### SUBSCRIPTIONS

\$56 A YEAR, \$88 (US) IN CANADA,  
\$209 (US) IN ALL OTHER COUNTRIES.

### SUBSCRIPTION INQUIRIES

(877) 529-1746 (US ONLY)  
OUTSIDE US CALL: (845) 267-3065

### CIRCULATION

PO Box 81  
CONGERS, NY 10920  
TEL: (TOLL FREE): (877) 529-1746  
OUTSIDE US: (845) 267-3065

### CEO, INFORMATION SERVICES GROUP

MARC FERRARA

### SENIOR VICE PRESIDENT, OPERATIONS

JEFF LEVITZ

### VICE PRESIDENT, HUMAN RESOURCES

TAMMY GARCIA

### VICE PRESIDENT, CREATIVE SERVICES & PRODUCTION

MONICA TETTAMANZI

### CORPORATE PRODUCTION DIRECTOR

JOHN ANTHONY CAGGIANO

### VICE PRESIDENT, CIRCULATION

EMELDA BAREA



# Advanced relief for dry eyes

## VeraPlug™ FlexFit™

The **VeraPlug™ FlexFit™** is an advanced solution to the discomfort of dry eye. It is simple to size and insert, comfortable for your patients, and comes with the confidence of our industry leading 30 day retention pledge.



### 30-DAY RETENTION PLEDGE\*

If a VeraPlug™ FlexFit™ is lost within 30 days of insertion, Lacrivera will replace it free of charge.

#### TEMPORARY OCCLUSION


### Vera180™

Synthetic absorbable plugs provide approximately **6 months of treatment** for dry eye syndrome




### Vera90™ Synthetic Inserts

Extended-duration punctal inserts for diagnostic use and post-operative dry eye.



### VeraC7™ Collagen Inserts

Temporary punctal inserts for diagnostic use, providing occlusion for up to 10 days.



#### A FRESH PERSPECTIVE™

[lacrivera.com](http://lacrivera.com) (855) 857-0518

2500 Sandersville Rd • Lexington KY 40511 USA



LACRIVERA®



PRINTED IN USA

FOUNDING EDITOR, FREDERICK BOGER  
1891-1913

EDITORIAL OFFICES  
11 CAMPUS BLVD., SUITE 100  
NEWTOWN SQUARE, PA 19073

SUBSCRIPTION INQUIRIES  
1-877-529-1746

CONTINUING EDUCATION INQUIRIES  
1-800-825-4696

EDITOR-IN-CHIEF • JACK PERSICO  
(610) 492-1006 • JPERSICO@JOBSON.COM

MANAGING EDITOR • REBECCA HEPP  
(610) 492-1005 • RHEPP@JOBSON.COM

SENIOR EDITOR • BILL KEKEVIAN  
(610) 492-1003 • BKEKEVIAN@JOBSON.COM

ASSOCIATE EDITOR • CATHERINE MANTHORP  
(610) 492-1043 • CMANTHORP@JOBSON.COM

ASSOCIATE EDITOR • MARK DE LEON  
(610) 492-1021 • MDELEON@JOBSON.COM

SPECIAL PROJECTS MANAGER • JILL GALLAGHER  
(610) 492-1037 • JGALLAGHER@JOBSON.COM

ART DIRECTOR • JARED ARAUJO  
(610) 492-1032 • JARAUIJO@JOBSON.COM

DIRECTOR OF CE ADMINISTRATION • REGINA COMBS  
(212) 274-7160 • RCOMBS@JOBSON.COM

**EDITORIAL BOARD**

CHIEF CLINICAL EDITOR • PAUL M. KARPECKI, OD

ASSOCIATE CLINICAL EDITORS • JOSEPH P. SHOVLIN, OD;  
ALAN G. KABAT, OD; CHRISTINE W. SINDT, OD

DIRECTOR OPTOMETRIC PROGRAMS • ARTHUR EPSTEIN, OD

CLINICAL & EDUCATION CONFERENCE ADVISOR  
PAUL M. KARPECKI, OD

CASE REPORTS COORDINATOR • ANDREW S. GURWOOD, OD

CLINICAL CODING EDITOR • JOHN RUMPAKIS, OD, MBA

**COLUMNISTS**

CHAIRSIDE • MONTGOMERY VICKERS, OD

CLINICAL QUANDARIES • PAUL C. AJAMIAN, OD

CODING CONNECTION • JOHN RUMPAKIS, OD

CORNEA & CONTACT LENS Q+A • JOSEPH P. SHOVLIN, OD

DIAGNOSTIC QUIZ • ANDREW S. GURWOOD, OD

THE ESSENTIALS • BISANT A. LABIB, OD

FOCUS ON REFRACTION • MARC TAUB, OD;

PAUL HARRIS, OD

GLAUCOMA GRAND ROUNDS • JAMES L. FANELLI, OD

NEURO CLINIC • MICHAEL TROTTINI, OD;

MICHAEL DELGIODICE, OD

OCULAR SURFACE REVIEW • PAUL M. KARPECKI, OD

RETINA QUIZ • MARK T. DUNBAR, OD

REVIEW OF SYSTEMS • CARLO J. PELINO, OD;  
JOSEPH J. PIZZIMENTI, OD

SURGICAL MINUTE • DEREK N. CUNNINGHAM, OD;  
WALTER O. WHITLEY, OD, MBA

THERAPEUTIC REVIEW • JOSEPH W. SOWKA, OD

THROUGH MY EYES • PAUL M. KARPECKI, OD

URGENT CARE • RICHARD B. MANGAN, OD

JOBSON MEDICAL INFORMATION LLC



# Outlook

By Jack Persico, Editor-in-Chief



## Adapt and Overcome

The work of re-engaging with patients while maintaining healthy boundaries is remaking the optometric practice.

In the fall of 2001, a few weeks after the September 11th attacks, President Bush addressed a dumb-founded nation to explain how we'd respond. America would get through it by "the patient accumulation of successes," he said. These would happen on many different fronts—some overt and public, others less so. Some successes would come quickly, others frustratingly late, if ever.

I think everyone, regardless of their political opinions, can agree that was the right way to frame it. Without a nation-state enemy that could be decisively defeated, Americans were told to brace for an unconventional, unpredictable era.

The response to COVID-19 will also follow a tenuous and gradual path. Plans will be provisional, progress will be fitful and daily life will continue to be laden with anxiety.

Such is the unenviable environment optometrists find as many return to their offices this month. No surprise, then, that tensions are running high. Eyecare practitioners (two-thirds of them ODs, the rest mostly opticians) responding to a survey conducted by Jobson rated their stress level when thinking about their businesses at a 7 on a 1-10 scale. Asked how much longer their practices could survive the shutdown, 43% answered just a month or less.

Clearly, the desire to get on with life is compelling. But, when reopening, don't set the bar at "business as usual." Instead, be content with the string of small successes that come as you learn to adapt: working out a disinfecting protocol that's easy to perform a dozen or more times a day,

rejiggering your exam techniques to minimize proximity to patients, mastering the arcana of coding for telemedicine, and so on. There are plenty of new things to master—let these small victories build momentum and motivation. Combined, they begin to solve the inherent paradox optometry practices now face: bringing in enough people to thrive financially, but also *few* enough to keep everyone safe from exposure.

That challenge is upending decades of traditional habits. Among respondents to the Jobson survey, 84% plan to take temperatures of patients, 62% will limit dispensary access and 61% will ask contact lens wearers to do their own insertions. And optometry practices will be awash in personal protective equipment (PPE). Almost nine out of 10 doctors plan to use gloves, masks, face shields, gowns *and* goggles, as well as offer masks and gloves to staff and patients when appropriate.

If there's any silver lining to all that PPE and precaution, maybe it's that more patients—and, dare I say, more ophthalmologists?—will perceive you as a frontline medical professional and not just the place to go to buy a pair of glasses. Your practice is going to look and feel a lot more medical, regardless of how many drug prescriptions you write.

How long these new protocols will be needed is anyone's guess. Until there's a lower rate of transmission, or a vaccine developed and widely available, they seem prudent. For the near term, "back to business" won't mean "back to normal." Just take it one day, and one success, at a time. ■

# FIND YOUR WAY FORWARD

**As you adjust to the changes our industry is facing, you'll find there is also opportunity. Increasing medical revenue and staff efficiency will be paramount.**

Fortunately, our AdaptDx Pro™ can help detect AMD early with your existing patients and transform your medical practice. Our on-board AI technician, Theia™, can expedite patient flow.





# 2020: The Year Of COVID-19

We were all so excited about the year of vision—then, in an instant, everything changed. **By Paul M. Karpecki, OD, Chief Clinical Editor**

**W**ith COVID-19 sending the world into lockdown, the main goal for many is simply survival. Despite high hopes for the year of optometry, 2020 has quickly become the most challenging time the profession has ever faced.

Hopefully the COVID-19 curve will flatten with social distancing, and several potential treatments are in the works. Optometry practices will survive this period and be stronger because of it, but there is no denying the challenges.

## What To Do Now

Back in April, federal crisis relief legislation went into place, including the CARES program, business loans, unemployment and upfront CMS Medicare payments. I commend the AOA on providing timely information and resources on these programs and COVID-19 updates.

Still, to survive, optometry practices must embrace telemedicine. Optometry has one of the best platforms available through EyeCare Live. CMS and other medical insurance companies pay the same for telemedicine visits as in-office visits.

But telemedicine is only successful if you already have a medical model. If you don't, Optometric Medical Solutions (OMS), which specializes in transforming optometry practices into medical eye care practices, is a key resource. Telasight also provides consultative clinical support for those pursuing medical eye care.

A few other tools can help:

- Bausch + Lomb can ship con-

tact lenses, for free, to patients' homes, and it has increased practitioner rebates.

- Imprimis can ship compounded drops to patients.
- Allergan has eliminated copays on all of its ophthalmic drugs. And that's just a sampling.

We can also use this downtime to participate in educational webinars, stay in contact with staff and prepare to return stronger than ever.

## Takeaways

Optometry will find revenue streams beyond seeing patients in the office. Telemedicine will become part of how we practice, although it will require HIPAA-compliant platforms after the pandemic subsides. A virtual visit can't replace the initial exam or glaucoma/retina evaluations, but it could be great for a one-month follow-up for a dry eye patient not on steroids, contact lens and prescription refills and many other follow-up exams.

Home diagnostics will become essential to expanding telehealth. AtHome (iCare) IOP monitoring allows patients to check their own IOP for interim telemedicine visits, and ForeSeeHome (Notal Vision) provides at-home AMD monitoring.

An online contact lens distribution avenue that generates revenue for the practice will be valuable. Companies with sound online distribution channels (e.g., Hubble) are already successfully partnering with some within the optometric profession.

Likewise, recurring sales from over-the-counter products is another

revenue stream. Companies such as Science Based Health, MacuHealth, Pristine and Pharmanex all have excellent products we can provide our patients. Bruder Healthcare initiated a program for dry eye patients during this downturn. 'Storefront' options, such as those offered by Allergan and [myoasis.com](http://myoasis.com), allow you to sell over-the-counter products online that appear to be coming directly from your office or website. While these resources won't replace the revenue from seeing patients, they at least provide some steady income.

Even where you see patients will change. People are staying away from crowded stores and hospitals, which leads to new Rx opportunities such as LeGrandeRx. Patients will be increasingly hesitant to have cataract surgery in a hospital or ambulatory surgery center, and practices that have office-based surgery suites such as iOR Partners may be a safer option.

## Pent-up Demand

The profession must adapt, and the new model will provide eye care differently. For one, ODs should wear surgical masks, even after the pandemic (iOR Value, a division of iOR Partners, sells them at cost to ODs).

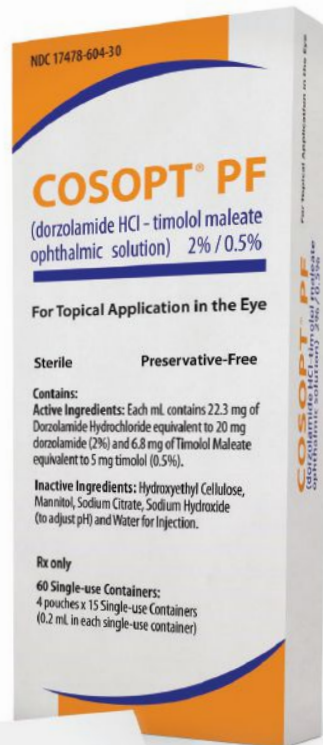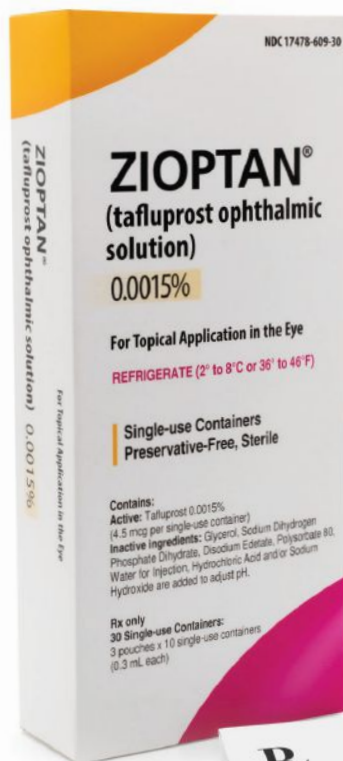The demand for eye care services is currently pent up. By re-positioning our practices, creating new revenue sources and adapting to the changes, optometry won't just survive, it will eventually thrive. ■

*Note: Dr. Karpecki consults for companies with products and services relevant to this topic.*

# 100% PRESERVATIVE FREE

  
**ZIOPTAN**<sup>®</sup>  
(tafluprost ophthalmic  
solution) 0.0015%

[ZIOPTAN.com](http://ZIOPTAN.com)



  
**Cosopt**<sup>®</sup> PF  
(dorzolamide HCl - timolol maleate  
ophthalmic solution) 2% / 0.5%

[COSOPTPF.com](http://COSOPTPF.com)



 AKORN

Cosopt<sup>®</sup> and ZIOPTAN<sup>®</sup> are registered trademarks of Merck Sharp & Dohme Corp and are used under license.

**Santen** ZIOPTAN<sup>®</sup> is licensed by Santen Pharmaceutical Co., Ltd.

©2020 Akorn, Inc. 1925 West Field Court, Suite 200, Lake Forest, IL 60045  
JA009 Rev 01/20

# Time is on My Side

If there's one thing certain about a global pandemic, it is this: Nothing is actually certain, ever. **By Montgomery Vickers, OD**

In mid-April, as I sit here in Lewisville, Texas, more or less on house arrest with my wife as my terrifyingly effective warden, how I spend my time during COVID-19 has been whittled down to just a few things. Four, actually:

1. I start my day with meditation and yoga. By meditation and yoga I mean I spend two hours yawning and complaining about my stiff back while on hold waiting for a very pleasant but hapless IRS agent to come on and tell me, again, that they cannot discuss my deceased mother's missing 2017 tax refund because they haven't received the form I submitted three times. Did I mention I have two separate letters from the IRS thanking me for submitting the forms that have not been received?
2. After my meditation and yoga, I stare at my phone.
3. Once I have completed that critical task, I stare at my computer.
4. Whew! All done and exhausted. Time for either a nap or a Bloody Mary. So far, I haven't chosen a nap. I also am not infected with COVID-19, so my Bloody Mary vaccinations are apparently working. The CDC has not returned my calls.

Now, back to optometry. Remember optometry? After several weeks of a forced furlough from private practice, I actually recall

more details related to my four years playing baritone horn for the "Magnificent 70 Marching Band" at the now-defunct Montgomery High School in Montgomery, West Virginia. Ahh, yes, the Magnificent 70. All 40 of us. No wonder I had trouble with physiological optics at Pennsylvania College of Optometry. Ciphering was not a strong subject in the Fayette County coalfields.

## My Calling, Revealed

In truth, I only know how to be an optometrist. I only know how to help patients. With my two Texas offices closed except for emergency care (it's not my turn to help yet), I miss my patients, my coworkers and my colleagues—the OD business owners who are, no doubt, struggling to keep the offices above water.

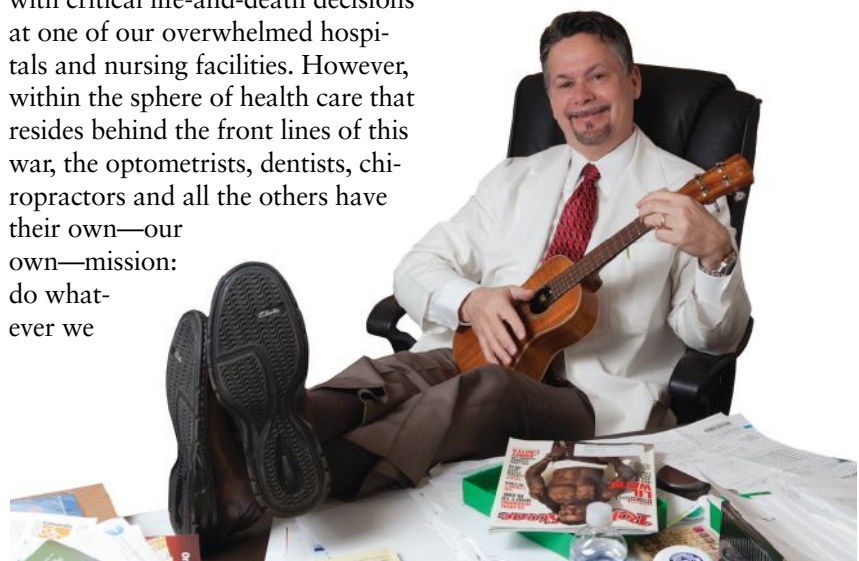
These fine young doctors are not wearing hazmat equipment dealing with critical life-and-death decisions at one of our overwhelmed hospitals and nursing facilities. However, within the sphere of health care that resides behind the front lines of this war, the optometrists, dentists, chiropractors and all the others have their own—our own—mission: do whatever we

can do whenever we can do it, to protect our patients and to be there for them now, in emergencies and, later, when our country will need us to get the whole healthcare system back in gear.

My friends, you have a mission, and it's not loafing around eating too many cookies out of boredom. Be ready. Make sure your practices survive and especially make sure you are ready to thrive again soon. Be hopeful, love on your family members, friends, staff members and colleagues... whether or not they are hiding the cookies from you. It's for your own good.

You should be proud of what you contribute to our country.

And, well, try to laugh as much as you can each day. I'll do my best to help you laugh again with "Chairside" as soon as I get off the phone with the IRS. ■



# LUMIFY<sup>®</sup>

BRIMONIDINE TARTRATE OPHTHALMIC SOLUTION 0.025%  
REDNESS RELIEVER EYE DROPS



Images representative of clinical trial results.<sup>1</sup> Individual results may vary.

- **The first and only OTC eye drop with low dose brimonidine tartrate (0.025%)**
- **Unique method of action<sup>†</sup> with no tachyphylaxis and virtually no rebound redness in clinical trials<sup>1</sup>**
- **Fast acting and long lasting efficacy<sup>1</sup>**

**95%**  
patient  
satisfaction\*



- Works in 1 minute
- Lasts up to 8 hours

Sterile

**Recommend LUMIFY to your patients today!**

Call 1-800-828-9030 to start selling LUMIFY in your office.

\*In Home Use Test, March 2018. n=301 †LUMIFY is a selective  $\alpha_2$ -AR agonist that selectively constricts the venule while maintaining availability of oxygen to surrounding tissue  
<sup>1</sup> McLaurin E, Cavet ME, Gomes PJ, Ciolino JB. Brimonidine ophthalmic solution 0.025% for reduction of ocular redness: A randomized clinical trial. Optom Vis Sci. 2018;95(3):264-271  
LUMIFY is a trademark of Bausch & Lomb Incorporated or its affiliates. © 2019 Bausch & Lomb Incorporated or its affiliates. PN09464 LUM.0193.USA.19

**BAUSCH + LOMB**

Learn more at [LUMIFYDrops.com/Professional](https://LUMIFYDrops.com/Professional)



## Slice of Life

Keep calm when dealing with conjunctival lacerations and be mindful of the extent of the damage. **Edited by Paul C. Ajamian, OD**

**Q** I have a patient who was moving metal sheets and one slipped and caught him in the eye. How do I handle this case?

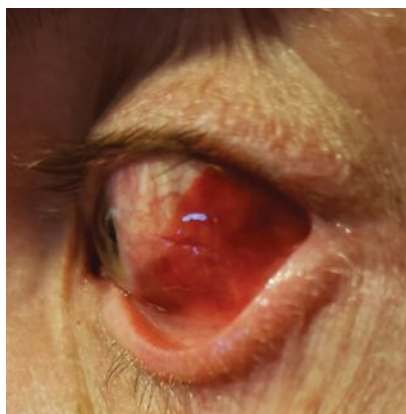
**A** Ocular trauma can be very concerning, and even the smallest abrasion or subconjunctival hemorrhage can be alarming for our patients. “When addressing ocular trauma, our initial goal is to assess the extent of damage,” says Alison Bozung, OD, who is on staff at Bascom Palmer Eye Institute in Miami, specializing in ophthalmic emergencies.

### Examination

Evaluate the eyelids and periocular structures first. Full-thickness eyelid lacerations, for example, can indicate likely globe damage. Next, address the ocular surface including the conjunctiva and cornea. If there is a subconjunctival hemorrhage, closer inspection will often reveal a conjunctival laceration as well.

In dealing with eye injuries, rule out open globes first, according to Dr. Bozung. When assessing a conjunctival laceration, the subconjunctival hemorrhage may limit your view. “Be particularly mindful of the possibility of a scleral rupture in the presence of a complete subconjunctival hemorrhage obscuring the entire sclera,” Dr. Bozung warns.

Most commonly, scleral ruptures from blunt trauma will occur at the limbus or posterior to muscle insertions. If defect depth is not particularly obvious, anesthetize the eye and use a fluorescein strip to paint over the area of concern in order to



**When assessing conjunctival laceration, subconjunctival hemorrhage may limit view of the sclera.**

look for a Seidel sign, as you would with a corneal wound leak. Instilling fluorescein will also highlight any corneal or conjunctival abrasions.

“When the extent of tissue violation anywhere is still unclear, you may want to gently explore the tissue with a cotton-tipped applicator moistened by sterile water or saline,” Dr. Bozung suggests. Be on the lookout for any residual foreign matter. If a deep or non-mobile foreign body is present, or if any uveal tissue is showing, refer this patient to an anterior segment or orbital specialist for further globe exploration and possible CT imaging.

A dilated fundus exam is a critical part of an ocular trauma assessment. Only avoid dilation in very specific circumstances, such as when there is uveal tissue prolapsed through a wound, a foreign body in the anterior chamber or obvious globe disorganization. “Use fundus examination to rule out retinal

breaks or detachment, vitreous hemorrhage and intraocular foreign body,” Dr. Bozung says. In cases that sustain focal trauma to the globe, pay special attention to the corresponding area of the retina. Note changes such as commotio retinae or retinal hemorrhage.

### Treatment

Treating conjunctival lacerations is quite simple in most cases. Often, small lacerations will heal without surgical intervention. Dr. Bozung will typically prescribe a prophylactic broad-spectrum topical antibiotic drop or ointment four times daily until the defect has closed. “Remind patients not to rub their eye and to temporarily discontinue contact lens wear, as this mechanical irritation may impede healing,” she says.

A plastic shield at night is a good way to prevent accidental rubbing or pressure on the traumatized eye. In the case of an extensive conjunctival laceration, consider referral. When surgical repair is indicated, absorbable sutures are typically used. The surgeon typically exercises care to ensure a sterilized wound with properly apposed edges while taking care to avoid capture of subjacent Tenon’s capsule.

“Fortunately, superficial conjunctival lacerations, such as with this patient, are often self-limiting and of minimal consequence,” Dr. Bozung says. “A thorough examination can rule out more dangerous complications of ophthalmic trauma and ensure our patients’ visual health is not compromised.” ■



# The One and Only Indicator of MMP-9 for Dry Eye Inflammation



## InflammaDry®



InflammaDry is the only test that detects elevated levels of MMP-9, a key inflammatory marker for dry eye. This rapid, point-of-care test produces results in 10 minutes allowing patients to be tested and treated in the same office visit. The test is easy to perform, is minimally invasive and requires no additional equipment. InflammaDry utilizes innovative patented technology, CE marked, and CLIA waived.

Quidel is a long-standing leader in the manufacture and sale of rapid, point-of-care diagnostics. Contact your Quidel Account Manager today at **800.874.1517** to learn more about how InflammaDry can help improve the health of your dry eye patients.

[quideleyehealth.com](http://quideleyehealth.com)



# Unmask This Cancer Imposter

This suspicious lesion isn't malignant—but fools most. Here's how to distinguish it.

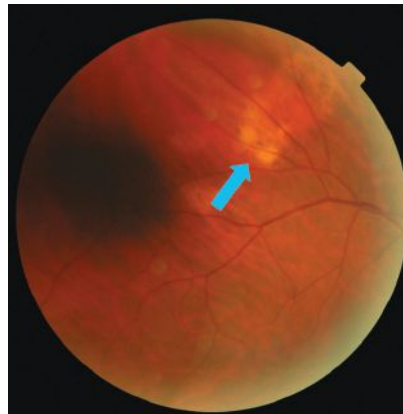
By Jim Williamson, OD, Abbey Kirk, OD, and Richard Mangan, OD

**I**ntraocular malignant neoplasm is one of the most feared diagnoses an OD may have to make. The visual prognosis of this ocular cancer is usually poor, and the potential for systemic involvement is worrisome. However, what may at first glance appear to fit the bill may be an imposter syndrome. Making the correct assessment before sending the patient out for further testing is imperative to distinguish intraocular malignant neoplasms from these other disorders that only masquerade as a malignancy.

Here, we review the case of a 69-year-old Caucasian male who was ultimately diagnosed with sclerochoroidal calcification (SCC). This condition is correctly diagnosed and referred by only 5% of practitioners.<sup>1</sup> Here's how to be among them and avoid superfluous testing and patient anxiety.

## Examination

Our patient presented for follow-up of mild-stage primary open-angle glaucoma, age-related nuclear cataracts and an area of retinal pigment epithelium (RPE) dropout superiorly in the right eye. His medical history included Type 2 diabetes, essential hypertension, hyperlipidemia, coronary artery disease, congestive heart failure, benign prostatic hyperplasia and obstructive sleep apnea. His systemic and ocular medications included Lipitor (atorvastatin, Pfizer) carvedilol, insulin, Vyztula (latanoprost, Bausch + Lomb),



**Fig. 1. The blue arrow in this fundus photo points to a subretinal lesion in the right eye's superior temporal quadrant.**

Cozaar (losartan, Merck), metformin and Flomax (tamsulosin, Boehringer Ingelheim). His social history was positive for tobacco (half a pack of cigarettes per day) and recreational marijuana use.

His best-correct visual acuities were 20/20 OD, OS with +0.75-0.50x120 OD and +0.25-0.50x115 OS and a +2.50 add. Chair skills were unremarkable. Slit lamp biomicroscopy showed a pinguecula OU and NC2 OU as graded by the lens opacities classification system (LOCS) III. A dilated fundus examination revealed a cup-to-disc ratio of 0.70V/0.65H OD and 0.50 OS, along with a yellow subretinal lesion outside the superior temporal arcade (*Figure 1*).

Enhanced-depth imaging optical coherence tomography (EDI-OCT) through the area demonstrated choroidal thinning above the lesion (*Figure 2*). B-scan ultrasonography highlighted an echo-dense placoid

mass with acoustic orbital shadowing (*Figure 3*).

## Discussion

SCC is a deposition of calcium within the sclera. They present as single or multiple, round focal lesions along the superior temporal arcades and are most commonly seen in the elderly as an incidental finding.<sup>2-4</sup> SCCs appear pale yellow, white or orange and can be flat or up to 6mm in height.<sup>5</sup> A 2015 study analyzed 179 eyes of 118 patients with SCC and found the vast majority in Caucasians (98%) with a mean age of 69 and a 60:40 female-to-male ratio.<sup>1</sup> Laterality approached 50% for all categories: unilateral vs. bilateral, and right eye vs. left eye.<sup>1</sup>

The term SCC is actually a misnomer, as the calcification represents a scleral mass. There are four recognized types: Type 1 “flat,” Type 2 “rolling,” Type 3 “rocky-rolling” and Type 4 “table mountain.”<sup>6</sup> “Rocky-rolling” represents the most common type and causes the most thinning of the overlying choroid, which in turn leads to a greater possibility for adjacent retinal pigment epithelium (RPE) and outer retinal changes (*Figure 4*).<sup>6</sup> The hill-like elevation in this patient characterizes a Type 2 “rolling” SCC (*Figure 2*).

## Making the Call

Differentiating SCC from more insidious lesions is key to preventing superfluous testing. Funduscopy alone can diagnose SCC,

# Technology in balance



Health



Vision




Comfort

---

Miru 1 month: a unique family of silicone hydrogel monthly lenses.

---

MeniSilk™ and Nanogloss™ technologies designed to meet the demands of today's contact lens wearer.\*



## Material and surface technologies

### MeniSilk™

- Ultra high Dk/t - 161 @ -3.00D
- Exceptional hydration
- Optimized transparency

### Nanogloss™

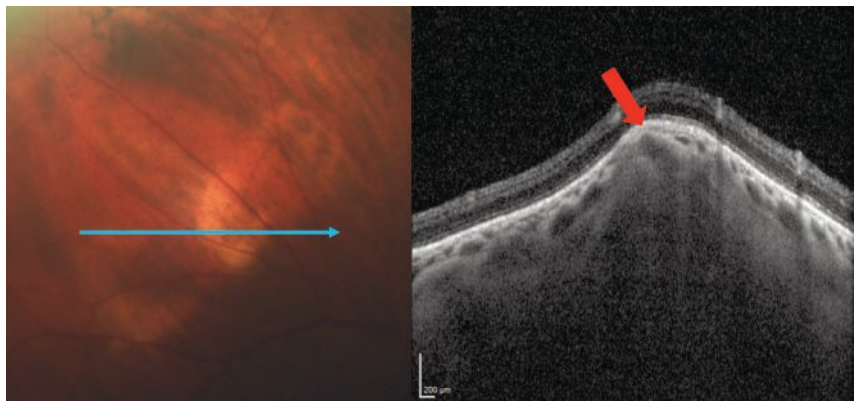
- Super smooth surface
- Resistance to bacteria
- Excellent wettability



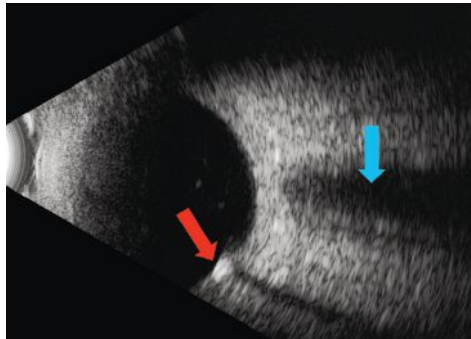
www.meniconamerica.com

\*Menicon data on file April 2016





**Fig. 2.** Above, EDI-OCT imaging through the SCC reveals a Type 2 “rolling” lesion. The red arrow points to an area of choroidal thinning above the lesion.

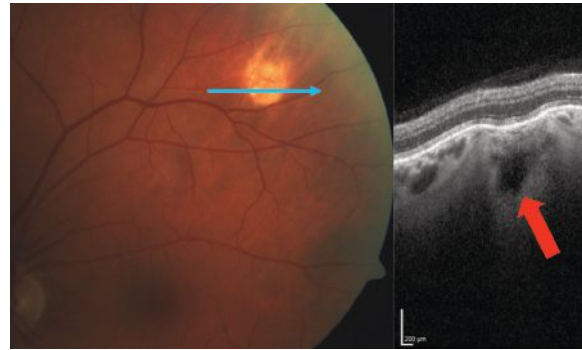


**Fig. 3.** At left, the red arrow shows an echo-dense placoid lesion while, the blue shows acoustic orbital shadowing on this B-scan ultrasound.

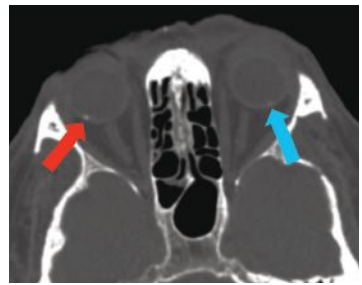
given its characteristic appearance, demographic, and predilection for the superior temporal location. With EDI-OCT, an SCC will appear as a scleral (not choroidal) plaque with secondary compression of the choroid.<sup>3,7</sup> B-scan ultrasonography shows a highly-reflective, echo-dense plaque unlike a choroidal metastasis, which would likely exhibit low-to-medium reflectivity. The majority of SCCs exhibit homogeneous hyperautofluorescence with fundus autofluorescence, and hyperreflectivity on infrared imaging.<sup>7</sup> SCCs also lack vasculature on a fluorescein or indocyanine green angiography. On computed tomography (CT) scans, SCCs appear as highly-attenuated objects similar to bone. The CT scan easily confirmed the right eye SCC in this patient, and surprisingly picked up a subtle one in the left eye, which was not viewed clinically (*Figure 5*). This likely represents a Type 1 “flat” lesion,

which is detectable only with ultrasonography or CT exam.<sup>1</sup> Approximately 80% of SCCs are primary or idiopathic.<sup>1,6</sup> Secondary causes result from hypercalcemia due to hyperparathyroidism, parathyroid adenomas, hypervitaminosis D, calcium pyrophosphate dihydrate deposition, hypomagnesemia, diuretic use, chronic kidney disease and, rarely, renal disorders, including Bartter’s syndrome.<sup>2,5,8</sup> Patients with hyperparathyroidism display the mnemonic “stones, bones, groans, thrones and psychiatric overtones” due to kidney stones, bone pain,

abdominal pain, polyuria and psychiatric symptoms, such as depression, anxiety, insomnia, cognitive dysfunction and possibly coma.<sup>9</sup> Bartter’s syndrome represents a group of inherited primary renal tubular electrolyte transport disorders. Of the three phenotypes, only two—classic Bartter’s and Gitelman’s—are associated with SCC.<sup>8</sup> Both of these closely-related autosomal recessive diseases share the characteristics of renal salt wasting and hypokalemic hypochloremic metabolic alkalosis.<sup>10</sup> A manifestation of Gitelman’s syndrome—which is more common and presents later in childhood or adulthood—includes hypomagnesemia.<sup>11</sup> Magnesium ions increase calcium pyrophosphate dihydrate crystal solubility. Therefore, hypomagnesemia could lead to deposition of those calcium crystals in joints and the sclera.<sup>11</sup> SCCs are usually benign and are similar to a Cogan or senile



**Fig. 4.** Another SCC patient exhibits a Type 3 “rocky-rolling” appearance. The red arrow shows the extensive choroidal thinning above the scleral mass.



**Fig. 5.** This CT scan demonstrates SCC in the right eye (blue arrow) and a subtle one in the left eye (red arrow), which was not visible on clinical exam.

scleral-calcified plaque, which occurs near the horizontal rectus muscle insertions. Some researchers speculate that SCCs may be their counterparts at the oblique muscle insertions where chronic forces induce both primary and secondary calcifications.<sup>5</sup> Rarely, SCCs may lead to a secondary choroidal neovascular membrane (CNV). Researchers recommend periodically monitoring SCC patients for CNV development with a dilated exam and EDI-OCT.<sup>2,9</sup> If a CNV presents, observation may be the best initial course of action, given the more peripheral location to the macula.<sup>12</sup> Intravitreal anti-vascular endothelial growth factor injections or argon laser may also be appropriate.<sup>12</sup>

SCCs can impersonate various intraocular tumors and are frequently misdiagnosed.<sup>2,5,9</sup> Typically, they represent an idiopathic incidental finding, but their discovery does warrant appropriate systemic testing to rule out underlying conditions. This may include a complete metabolic panel, parathyroid and renal function testing.<sup>7</sup> Medications should also be reviewed as diuretics can lead to a loss of metabolic parameters.<sup>1</sup> More importantly, however, is making the right diagnosis and avoiding unnecessary testing. ■


*Dr. Williamson is the residency supervisor at the Memphis VA Medical Center and is an adjunct faculty at multiple optometry schools.*

*Dr. Kirk is a resident at the Memphis VA medical center.*

1. Shields CL, Hasanreisoglu M, Saktanasate J, et al. Sclerochoroidal calcification: clinical features, outcomes, and relationship with hypercalcemia and parathyroid adenoma in 179 eyes. *Retina*. 2015;35:547-54.  
 2. Ali ZC, David VP. Sclerochoroidal calcification associated with hypovitaminosis D. *Can J Ophthalmol*. 2017;52(4):e121-2.  
 3. Honavar S, Shields C, Demirci H, Shields J. Sclerochoroidal calcification: Clinical manifestations and systemic associations. *Arch Ophthalmol*. 2001;119:833-40.

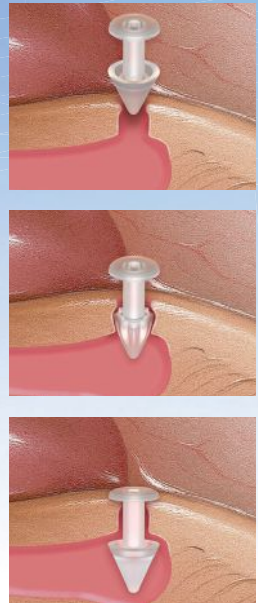
4. Leys A, Stalmans P, Blanckaert J. Sclerochoroidal calcification with choroidal neovascularization. *Arch Ophthalmol*. 2000;118:854-7.  
 5. Wong C, Kawasaki B. Idiopathic sclerochoroidal calcification. *Optom Vis Sci*. 2014;91(2):32-7.  
 6. Hasanreisoglu M, Saktanasate J, Shields P, Shields C. Classification of sclerochoroidal calcification based on enhanced depth imaging optical coherence tomography "mountain-like" features. *Retina*. 2015;35:1407-14.  
 7. Fung A, Arias J, Shields C, Shields J. Sclerochoroidal calcification is primarily a scleral condition based on enhanced depth imaging optical coherence tomography. *JAMA Ophthalmol*. 2013;131(7):960-3.  
 8. Goerlitz-Jessen M, Ali M, Grewal D. Rare complica-

tions of sclerochoroidal calcifications. *JAMA Ophthalmol*. 2019;137(1):111-2.  
 9. Sugarman J, Douglass A, Say E, Shields C. Stones, bones, groans, thrones and psychiatric overtones: Systemic associations of sclerochoroidal calcification. *Oman J Ophthalmol*. 2017;10(1):47-9.  
 10. Fulchiero R, Seo-Mayer P. Barter Syndrome and Gitelman Syndrome. *Pediatr Clin North Am*. 2019;66(1):121-34.  
 11. Bourcier T, Blain P, Massin P, et al. Sclerochoroidal calcification associated with Gitelman syndrome. *Am J Ophthalmol*. 1999;128(6):767-8.  
 12. Bessette AP, Singh AD. Multimodal imaging of choroidal neovascularization associated with sclerochoroidal calcification. *Ocul Oncol Pathol*. 2016;2(4):234-8.



## Proven Occlusion Therapy. Enough Said.


**Collapsible Tip for Superior Retention  
and Improved Patient Comfort**



**Punctal Occlusion is 76.8% effective between 2-4 weeks at treating the symptoms of Dry Eye associated with:**

- Seasonal Allergies.....
- Contact Lens Wear.....
- Aging.....
- Medications.....
- Computer/Cell Phone Use.....
- LASIK/Refractive Surgery.....

Rx



**Lacrimedics**  
(800) 367-8327  
E-mail: [info@lacrimedics.com](mailto:info@lacrimedics.com)  
[www.lacrimedics.com](http://www.lacrimedics.com)

©2020 Lacrimedics, Inc.  
\*<http://www.ncbi.nlm.nih.gov/pubmed/11862081>

PUNCTAL OPENING	SIZE	PART NO.
0.2mm to 0.3mm	X-Small	2003
0.3mm to 0.5mm	Small	2005
0.6mm to 0.8mm	Medium	2008
0.9mm to 1.0mm	Large	2010



# Ocular Surface Coding Potpourri

Keep this compendium handy when treating your dry eye patients.

By John Rumpakis, OD, MBA, Clinical Coding Editor

One of the fastest growing areas of optometry is dry eye. For those of you ready to build a dry eye subspecialty, you also need to know how to code for it, including office visits, procedures and technologies. Here are the basics for coding dry eye visits:

**Office visits.** In general, the E&M codes (992XX) are the most appropriate for dry eye–related visits. The 92012 intermediate ophthalmic code can also be used if the CPT definition is followed. From a telehealth perspective, G2010 (recorded image evaluation and interpretation), G2012 (virtual check-in) and 99421-423 (online digital evaluation) may be appropriate.

**Meibography vs. photography.** In January 2019, meibography was given a new category III code of 0507T, defined as near infrared dual imaging (i.e., simultaneous reflective and transilluminated light) of meibomian glands, unilateral or bilateral, with interpretation and report.

Category III codes, by definition, are rarely covered by third-party carriers and are generally patient-paid.

Anterior segment photography remains the same, CPT 92285, defined as external ocular photography with interpretation and report for documentation of medical progress (e.g., close-up photography, slit lamp photography, gonioscopy, stereo-photography).

Both procedures require proper medical necessity to perform, and interpretation and report.

**Lid procedures.** Numerous new lid procedures are available, each

with their own coding rules.

BlephEx, or mechanical debridement of the eyelids, currently doesn't have a code. Nonetheless, you still have to code it. Just because a specific technology or procedure doesn't have a specific CPT code assigned to it doesn't alleviate the medical record documentation or coding of it. Fortunately, the CPT allows for this situation with unlisted codes. CPT code 92499, unlisted ophthalmological service or procedure, is designed for situations where an ophthalmic procedure is performed but doesn't have its own code. This would be the most appropriate code to use for a BlephEx procedure.

Thermal lid procedures such as iLux (Alcon) would also fall into this category. Some argue that 67999, unlisted procedure-eyelids, would be the proper code; however, the code begins with "67," designating it as a surgical procedure. Because these tools are not surgical in nature, 92499 is the most appropriate.

LipiFlow (Johnson & Johnson Vision Care) and TearCare (Sight Sciences) are different because they have their own category III codes:

- LipiFlow (0207T) – evacuation of meibomian glands, automated, using heat and intermittent pressure, unilateral.
- TearCare (0563T) – evacuation of meibomian glands, using heat delivered through wearable, open-eye eyelid treatment devices and manual gland expression, bilateral.

The definition of each code is unique to the technology.

Intense-pulsed light (e.g., Lumenis) does not have its own CPT code, so 17999, unlisted procedure, skin, mucous membrane and subcutaneous tissue, would be the most appropriate.

Unlisted codes do not have any RVUs attached to them, and no standard coverage or reimbursements exist. Most are patient-paid. If you are submitting an unlisted code, the claim should include a letter of medical necessity, a specific description of the procedure and justification of your charges.

## CLIA-waived POC Tests

Testing osmolarity and MMP-9 is now commonplace for dry eye. Getting your CLIA waiver is easy, as is coding for the tests.

The TearLab osmolarity system is best described using CPT 83861, microfluidic analysis using an integrated collection and analysis device, tear osmolarity. It is a unilateral or single-unit test, so billing one test for each eye is appropriate.

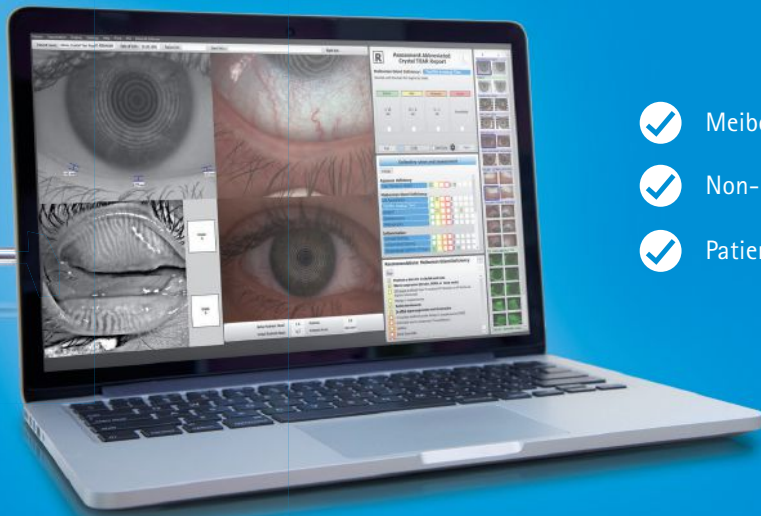InflammaDry (Quidel) is best described using CPT 83516, immunoassay for analyte other than infectious agent antibody or infectious agent antigen, qualitative or semi-quantitative, multiple step method. It also is a unilateral or single-unit test and follows the same billing method for each eye.

If you know the basics for specific procedures using CPT and category III codes, you can protect your practice's finances and compliance. ■

Send your coding questions to [rocodingconnection@gmail.com](mailto:rocodingconnection@gmail.com).

# Searching for Dry Eye?

Find out in 60 seconds



- ✓ Meibography
- ✓ Non-invasive break-up time
- ✓ Patient education and compliance

## OCULUS Keratograph® 5M: More than Meibography

Streamline your dry eye analysis with the baseline data of the tear film quality, quantity, or gland structure. This comprehensive assessment enhances patient care and outcomes.


Contact us today to learn more!



Scan here or visit  
[www.oculususa.com/dryeye](http://www.oculususa.com/dryeye)

Toll free 888-519-5375  
[ads@oculususa.com](mailto:ads@oculususa.com)

 **125 YEARS**  
OCULUS®



# Patient Care Morphs During COVID-19

From telemed to ER visits, doctors and hospitals are finding creative ways to take care of those in need. **By Jane Cole, Contributing Editor**

**C**OVID-19 has everything except essential services on hold, and it has forced a monumental shift in how clinicians provide care. While many ODs made the difficult decision to put their practices on temporary hiatus, some are turning to urgent visits or moving to telehealth to serve their patients without sight-threatening issues.

Other ODs are finding a way to make a difference by offering guidance on how their practices can withstand the current crisis and jump-start their offices once their doors reopen.

## Rising to the Occasion

The coronavirus outbreak has forced nearly every practice in the country to adapt, and what that means for most, including Patrick Vollmer, OD, of the Vita Eye Clinic in Shelby, NC, was to eliminate routine care.

“We felt this was the best recourse despite being considered ‘essential,’” he says.

Dr. Vollmer is keeping his clinic open for emergency visits and for

two cohorts of research patients who are part of his practice’s dry eye clinical trials.

To ensure proper social distancing, he teleconferences with patients in one study group. The other study cohort comes into the office on a “one-in, one-out” basis.

Continuing to see patients who called in for urgent issues—something his practice was designed to handle from day one—fills a critical patient care need and keeps Dr. Vollmer’s practice busy.

Long before the pandemic, Dr. Vollmer had considered moving to a large city an hour away and commuting to his practice, he says, but he’s thankful he decided against it, especially now with the high call volume that has escalated due to the pandemic. Since he only lives a few blocks away from his clinic, Dr. Vollmer can get to his office in a matter of minutes.

On a typical week, he sees between five and 12 research patients and 20 to 25 emergency patients—all of whom present one at a time to reduce patient interactions in the office.

## Turning to Telehealth

A series of federal, state and local COVID-19 mandates caused Kam-biz Silani, OD, to cease all routine eye care at his practice, Beverly Hills Optometry: Advanced Dry Eye Center in Southern California until further notice.

Los Angeles County has been one of the hardest hit counties in the country, with 22,485 confirmed cases as of May 1.<sup>1</sup>

Although his practice significantly reduced in-office services, Dr. Silani and his staff worked to reassure patients they would still be there for them through in-office emergency and telehealth visits.

“Our practice always considered telehealth in our pipeline,” Dr. Silani says. “After COVID-19 hit hard, telehealth quickly became a top priority so we could be available for our patients remotely.”

For his telemedicine platform, Dr. Silani chose [doxy.me](https://doxy.me), which is HIPAA compliant. Although he says FaceTime and Skype are adequate during the COVID-19 pandemic since because of temporary HIPAA leniency, he still found it



beneficial to choose a platform that fit into his practice post-pandemic.

His move to telehealth was relatively smooth and provided patients the option to be seen sooner rather than waiting to reschedule until the practice fully reopened.

Telehealth visits do pose some limitations based on the reason for the patient visit, Dr. Silani says. “We don’t have the ability to perform contact lens evaluations or routine eye care via telehealth visits.” Dr. Silani also encourages patients to come into the office if they have sudden vision loss, onset of floaters/flashes or any eye pain.

What does fall under the practice’s telehealth umbrella are dry eye consults and mild to moderate issues such as styes, red eyes, watery eyes and ocular irritation.

To get the word out about the new telehealth platform, Dr. Silani’s staff shared the news on the practice’s social media platforms and also as an e-mail campaign to reach current patients.

Dr. Silani was quick to hammer out a template for a typical telehealth consult:

- When a patient contacts the practice for an appointment, staff offers the option and benefits of booking a telehealth visit.
- If the patient expresses interest, staff books a virtual appointment.
- Staff sends the patient a consent form highlighting the features, benefits and potential risks of telehealth and collects payment via credit card.
- The doctor and patient engage in the video visit. At the completion, the doctor determines whether the patient needs to be seen for a follow-up (either virtually or in-office), if the patient needs a prescription

### **Finding Purpose in the Chaos**

When Samantha Hornberger, OD, of Bright Family Eyecare in Lawrenceburg, IN, had to temporarily close her office to routine care, she picked up a notebook and pen and started jotting down a plan. Her brainstorm turned into a comprehensive, step-by-step manual called “Office Closure Action Plan: A Plan for COVID-19 Closure” that details what doctors can do to best position themselves in this unprecedented time and how to reboot after the pandemic.

Dr. Hornberger said her brainstorming gave her less anxiety about what was happening. “I thought, if this makes me feel better to have an organized plan, it’s going to make others feel better too.”

Hornberger’s COVID-19 practice roadmap offers immediate and post-pandemic advice for ODs, including how to continue to generate revenue, reaching out to suppliers and vendors about the potential to defer, delay or alter payment arrangements, how to get the word out to the community that you’re still open for emergency visits and tips on sanitizing the office and scheduling and launching a telehealth platform.

Her guide has already become a valuable resource for hundreds in the profession, as more than 700 eye care practitioners have either downloaded it or connected with her on social media, she says.

Dr. Hornberger is currently working on the next update to the manual, which will offer suggestions on how doctors can start envisioning practice changes they’d like to make that would reduce burnout and stress.

“Honestly, there has never been a better time to think about this, because we won’t go back to normal right away. Who knows what normal is even going to look like. There will be a transition period where you can make the changes you want to make even if they aren’t COVID-related.”

In the meantime, Dr. Hornberger encourages her colleagues to persevere and persist, two traits in which she feels the profession already excels. And during this unprecedented time, Dr. Hornberger still suggests trying to find small joys throughout the day. “I fully believe we are going to find good that’s going to come out of this if we look for it.”

Dr. Hornberger’s guide can be found on her website at [themoderneyesite.com](http://themoderneyesite.com).

sent to the pharmacy, or if a referral to a specialist, such as a neuro-ophthalmologist, or a retina, cornea or glaucoma specialist, is warranted.

- Finally, the doctor shares the notes of the visit with the staff to upload into the patient’s chart.

“If eligible for a virtual appointment, patients enjoy the convenience, comfort and safety of this option,” Dr. Silani says. “After the COVID-19 outbreak has ended, we will certainly continue offering this service as an option for our new consults and pre-existing patients.”

Dr. Silani estimates his office is currently conducting three to five

telehealth visits a week, with the hope the number will continue to rise, especially for some out-of-town patients and ones who commute long distances.

Looking to the future, he adds: “Although COVID-19 presents many challenges to eye care practitioners, it is key to adapt and pivot. Use this added, precious time to dabble with new ideas, services, products, update marketing material, create a blog or attend virtual CEs and webinars.”

As New York City became the epicenter of the outbreak in the United States with 42,996 confirmed cases in Brooklyn alone as of May 1, Justin Bazan, OD, of



## A COVID-19 Pandemic Transition In Action

By Rebecca Hepp, Managing Editor

The optometrists, ophthalmologists, technicians and support staff at Emory Eye Center in Atlanta worked overtime to postpone routine care, kickstart telemedicine and prepare to handle COVID-positive consults in the hospital. With more than 120,000 patient encounters annually and five locations, a VA Medical Center, 15 subspecialties and several hospital locations to cover, it's no small feat.

But they had experience with something like this before, and it's given them a leg up on at least one aspect of the changes.

### PPE Surprise

All ODs are trained on personal protective equipment (PPE), but it's a rarely used skill, says Kelsey Moody Mileski, OD, an assistant professor of ophthalmology at Emory Eye Center. In fact, she says getting used to wearing all of the PPE when seeing a patient has been one of the most surprising challenges.

Emory, however, has been ahead of the game when it comes to PPE preparedness, she notes. "Emory Eye Care physicians were involved both during and after the Ebola crisis, and several Emory retinal specialists examined Ebola survivors in both Atlanta and the Democratic Republic of Congo and had experience with the necessary PPE required," she explains. "Due to this, PPE was addressed immediately within the Eye Clinic to begin training even before the closures started."

Her team realized quickly that wearing goggles makes BIO significantly easier than it is with a face shield. Also, having two clinicians on a hospital consult is the best way to handle the situation, Dr. Mileski says. Only one OD has contact with the patient, but the two-man team makes the extra PPE and sterilization steps much easier.

### Scheduling Chess Game

Of course, Ebola never grew to the pandemic we are dealing with now, and it's uncharted territory for other aspects of patient care.

The biggest challenge, Dr. Mileski says, has been culling through the appointments to decide who does—and doesn't—need to be seen. It took a few changes, but they settled on a system that identifies patients as time-sensitive or urgent. The latter patient group is either kept on the schedule or rescheduled for a specific day that the provider is in clinic, she explains.

"The trick is, we don't know when we will be reopening to routine care, so the question is how long can a patient wait, and do we need to be concerned that they may lose vision within that time," she says. "The patient who just needs an IOP check could wait one to two months as long as they have refills of their drops; however, we do not want them to be rescheduled several months later."

Even time-sensitive and urgent patients staying on the calendar need to be rescheduled to different days or times, she admits, to limit the number of patients in the clinic at one time.

"Most of the time, patients are very willing to not come into the

clinic, and if they can have their questions answered over the phone, that's ideal," she says.

One somewhat unexpected scheduling challenge has been the increase in urgent referrals, as Emory Eye Center is one of the only clinics in the area still seeing urgent patients and performing ocular surgeries. Added to that, a significant number of patients present to the emergency room for ocular complaints, or at least they did before the coronavirus hit, Dr. Mileski says. Those numbers have dropped considerably, and patients are now calling the clinic directly.

### Telehealth Pros and Cons

While the move to telehealth has been touted as the go-to intervention during the pandemic, Dr. Mileski says it's a complicated decision. Patients must first have an ocular complaint that is likely easy to identify with a good patient history and external exam. It's also working well for some follow ups, she says.

However, "if they need a pupil check, dilation or a refraction, we have to bring them into the clinic if it's for an urgent complaint or rescheduled if it's routine," she explains.

Another wrinkle: the patients have to be tech savvy enough to use their computer or smartphone for the telemedicine visit—something many older patient struggle with.

### COVID-19 Encounters

In the clinic, staff ask about COVID symptoms when scheduling every appointment and during check-in. Patients who mention suspicious symptoms are asked to not come directly into the eye clinic.

"The goal is to examine them in the hospital or the designated COVID clinics they have now set up," according to Dr. Mileski. "Luckily, the hospital's new COVID-positive clinic now has a teleretinal camera, so it gives us some information that has been helpful."

As for hospital consults, they noticed early in the pandemic that only about 1% of COVID-positive patients develop viral conjunctivitis—and they don't necessarily need an eye care consult for that. "However, just because you are COVID-positive doesn't mean you can't have other ocular issues at the same time that do need to be seen," she emphasized.

Dr. Mileski saw her first COVID-positive inpatient for new-onset floaters. "I started by triaging her over the phone to get her history so when I got to her room I could get straight to the eye exam," she notes. To limit the supplies they had to take into the room, they used a paper eye chart they could just throw it away. The same goes for the eye drops, she adds.

### Make the Most of a Bad Situation

None of this is ideal, but everyone is coming together to make the best of what they have. Most of all, Dr. Mileski is pleasantly surprised by the patient response. "You never know how people will react to the situation [...] and it's been a very positive experience, especially when it's the provider themselves calling," she says. "This is unprecedented; we have never had to deal with anything like this before."

**PASSIONATELY AT WORK  
IN EVERY ASPECT OF EYE HEALTH**

**AKORN** | EYE CARE

At Akorn, eye care is our passion. We are present in all aspects of eye health, from anterior to posterior segments, from diagnosis to treatment to maintenance. Since 1971, we have been building partnerships in the eye care community and supporting you in making a lasting impact in your patients' lives.

**AK-FLUOR**  
(Fluorescein Injection, USP)

**Akten**  
(lidocaine HCl ophthalmic gel) 3.5%

**AzaSITE**  
(azithromycin ophthalmic solution) 1%

**BETIMOL**  
(timolol ophthalmic solution) 0.25%, 0.5%

**CosoptPF**  
(dorzolamide HCl-timolol maleate ophthalmic solution) 2%/0.5%

**ICoGreen**  
(indocyanine green for injection, USP)

**PAREMYD**  
(hydroxyamphetamine hydrobromide and tropicamide ophthalmic solution) 1%/0.25%

**thera tears**  
THE THERAPY FOR YOUR EYES™

**ZIOPTAN**  
(tafluprost ophthalmic solution) 0.0015%

**Akorn Ophthalmic Generics**



Park Slope Eye in Brooklyn, closed his office and headed out of the city to take care of patients through telehealth visits.<sup>1</sup> He coordinated with a local practice to handle emergency referrals and directed his employees to work from home.

“We wanted to provide help to people in need, and telemed and digital communication is the best way we can do that right now. We have always answered a lot of questions and provided advice via email, so it was an easy and natural progression into using a formal telemed platform.”

Still, “the amount we are doing is minuscule compared to our normal in-office flow,” he says.

Dr. Bazan says the learning curve for telehealth is very low. He suggests ODs test drive a few of the popular platforms and they can watch an American Optometric Association telemedicine webinar as a helpful resource if they are considering this option.

### Drive-through Care

Working at the front lines at the Memphis VA Medical Center, Katherine Sanford, OD, easily answered the “all hands on deck” call when her hospital decided to roll out its drive-through lab to promote social distancing while still providing continuity of care for veterans.

“I live in Memphis, so there’s a lot of diabetes, high blood pressure and other chronic conditions that need to be monitored,” she says.

While the hospital had already launched an intensive telemedicine program for primary care visits, the drive-through for blood work was the VA Center’s latest push to take care of patients and ensure their safety during the pandemic.

Although the new lab is phlebotomy based, Dr. Sanford was eager to lend a hand in helping organize

and facilitate the effort when she wasn’t in the clinic, especially since she had some extra time on her hands without routine care visits.

“The majority of patients have appointments for labs,” Dr. Sanford explains. “They can still go inside the hospital to the main lab, but we are funneling every visitor and every employee into one entrance.” In addition to social distancing, the drive-through lab provides convenience for those with ambulatory issues who would otherwise have to navigate through the building until they reach the main lab located on the far end of the hospital, Dr. Sanford says.

Here’s how it works:

A patient pulls up in their car to a station for screening questions. Based on their answers, hospital workers will put a colored strip of paper on their windshield. A red slip indicates a patient may have been exposed to or is exhibiting symptoms of COVID-19 and hospital staff shouldn’t approach the vehicle. In this case, the individual will be redirected to the ER and personnel will be notified so they can take necessary precautions.

Patients who are asymptomatic or who indicate they were not exposed to anyone with symptoms get a green slip of paper, alerting staff that it’s safe to approach them.

The drive-through lab can handle two cars at a time. When the patient reaches one of two bays, they get out of their vehicle and enter a side room of a large tent where a phlebotomist takes their blood

for the specific tests their doctor ordered.

The patient generally returns home where they will have a telemedicine visit with their primary care physician to discuss the lab results and any other issues.

The first day, the lab had 35 patients, but the hospital is anticipating up to 150 per day.

“It’s good to feel like we are providing an extra service for the veterans,” Dr. Sanford says. ■

1. COVID-19 Compiler. <https://covid19.topos.com>. Accessed April 16, 2020.



Photos: Memphis VA Medical Center

**The Memphis VA Medical Center now provides a convenient drive-through lab to help patients get the labwork they need without risking exposure in the hospital.**



“ I didn't realize  
**STARS**  
were little dots that twinkled ”

—Misty L, *RPE65* gene therapy recipient

**WE'RE SEEING  
AMAZING RESULTS.  
AND SO ARE THEY.**

At the Foundation Fighting Blindness our mission is everybody's vision. Our work shines a light on the darkness of inherited retinal diseases (IRDs).

We're the world's leading organization searching for treatments and cures. We need your help to fuel the discovery of innovations that will illuminate the future for so many. We have robust disease information, a national network of local chapters and support groups, local educational events, and our My Retina Tracker® Registry to help keep your patients connected with clinical and research advancements.

Help accelerate our mission  
by donating at [ECPs4Cures.org](https://ECPs4Cures.org).

**FOUNDATION  
FIGHTING  
BLINDNESS**

[FightingBlindness.org](https://FightingBlindness.org)

# 20 Tips For Reopening Amid COVID-19

Here's advice on how you can hit the ground running and thrive in a world with coronavirus. **By Jane Cole, Contributing Editor**

**C**COVID-19's rapid sweep across the country has caused an unprecedented disruption to the profession and forced optometrists to make quick clinical and practice management decisions. Many ODs shuttered their practices temporarily due to COVID-19, while others improvised with urgent appointments only and telehealth. Now that the CDC's nationwide recommendation to postpone routine eye care is no longer in effect, ODs are faced with a new challenge: What should they have in place before reopening?

Almost all eye care practitioners (93%) who responded to the 7th wave of Jobson's Coronavirus ECP Survey expect to reopen their practices once restrictions are lifted, but they also anticipate they'll need to implement changes to continue social distancing and limit the spread of infection.

Here's an array of things you should consider:



**Gone are the days of packed waiting rooms. Instead, clinicians should space out seating and scheduling to minimize patient interactions.**

*(Ed. note: The advice provided here is from anecdotal sources and may not conform to state or federal guidance. Use your own discretion whenever contemplating changes to clinical or business practices.)*

## **1** *Have a plan.*

Somewhat encouragingly, the latest survey of ECPs found more

than half (57.9%) are currently working on a written reopening plan, nearly double the amount who said so just two weeks prior. But *everyone* should be planning, according to practice management consultant Gary Gerber, OD, of the Power Practice. It's critical to have a well-thought out framework that touches on all aspects of the practice and patient care prior to opening your doors again for "routine patient care," he says.

"Many doctors are thinking, 'I'm going to reopen, and it won't be as busy, so I'll just slowly get back into it,'" Dr. Gerber says. "But it's not going to be 'pre-COVID' slower, it's going to be slower

and very different. You have to walk through simulations with your staff prior to reopening." This is not a time to improvise as you go.

Dr. Gerber suggests all doctors do a simulation of the patient's in-office journey prior to reopening. "It's important to do a walk through to determine when and

where you will need PPE or social distancing for different situations. If an optician takes out their tools to bend a nose pad, for example, what are they going to do with that tool? Does the tool get disinfected before they use it again?" It's critical to have everything mapped out before you reopen, he says.

**2 Ignore peer pressure to reopen.** "The biggest gray area I'm hearing from other doctors is when to reopen, when is it safe, when is it advised, and there's no good answer for that," says Samantha Hornberger, OD, of Lawrenceburg, IN. "This was the same situation for many of us when we decided to close."

Because reopening dates are mostly dependent on individual state's stay-at-home orders, rescheduling patients can be a moving target. Most governmental guidance on reopening will be regional, says Brian Chou, OD, of San Diego. But

such guidance may conflict with other considerations, including what public health data suggests, he adds.

There could also be "herd mentality" and pressure to open if other offices do so, Dr. Chou says. That could lead to hastily prepared plans that may end up being counterproductive. Bottom line: getting it right matters more than being fast.

At the time of this writing, Dr. Hornberger had her patients rescheduled starting the first week of May—a date subject to change in these shifting times.

Aaron Neufeld, OD, a private practitioner from Los Altos, CA, and co-founder of ODs on Finance, hopes to reopen his practice in full when the shelter-in-place rule is lifted in his area.

"Our mid-May schedule has already been filling. That being said, there will definitely be changes implemented for the health and safety of our patients and staff, as

well as for public perception."

**3 Rely on experts.** Even if social distancing mandates a six-foot radius between each person, no one should feel alone. Everyone is in the same boat, and support is available from your optometric colleagues and state and national optometric associations. The American Optometric Association (AOA) released much-anticipated guidance on how to reopen during the pandemic (see, "AOA Provides Reopening Checklist"), much of which is reflected here.

**4 Make distancing mandatory.**

A recent article published in the *Journal of Glaucoma* suggests efforts to shorten wait times and lines will be paramount.<sup>1</sup> ODs should rearrange their waiting rooms to reduce capacity and encourage patients to limit the number of people accompanying them.<sup>1</sup> The article also suggests patients in

### **AOA Provides Reopening Checklist**

As mandatory restrictions begin to lift and optometrists prepare to open their doors for routine care, the AOA recently offered guidance on what practices should have in place to reopen.

"The American Optometric Association is committed to helping our members be prepared for the 'new normal' when it's safe to open practices," says AOA President Barbara L. Horn, OD. "Doctors of optometry will be doing things differently in their practices, and the AOA continues to develop helpful guidance supported by the latest information from all federal agencies."


The AOA recommends ODs set their reopen date based on federal, state and local guidance—and have a reopen plan that leaves plenty of time to sanitize the office and all equipment. Here are a few steps from the AOA's "Optometry Practice Reactivation Preparedness Guide" to augment what your colleagues have already suggested:

- **Develop an action plan before opening.** Determine priorities for preparing office space and clinical areas based on suggested guidelines for cleaning and sanitizing the office and dispensary, and how long this process may take.
- **Develop a new system for sterilization of the office, based on available guidelines.**

- **Continue messaging patients.** Reach out to them during this difficult time to see how they are doing through all relevant communications channels (e.g., website, social media, email, direct mail, advertising).
- **Prepare for your staff needs as they assimilate into the new working environment.** Demonstrate consideration for the mental health of the staff and team while reestablishing the new care delivery flow.
- **Contact other medical practices in the area to see when they will be reopening or if they have new protocols in place.**
- **Post signage in the office of the new protocols to ensure maximum safety.**
- **Use AOA resources such as the AOA COVID-19 Hub ([www.aoa.org/coronavirus](http://www.aoa.org/coronavirus)).**

To access the AOA's complete guide, go to [www.aoa.org/documents/covid-19/aoa-guidance-for-re-opening-practices-covid-19.pdf](http://www.aoa.org/documents/covid-19/aoa-guidance-for-re-opening-practices-covid-19.pdf).

Ready for Routine Care? AOA Offers Guidance for Post-COVID-19 Reactivation. [www.aoa.org/news/practice-management/aoa-offers-guidance-for-post-covid-19-reactivation](http://www.aoa.org/news/practice-management/aoa-offers-guidance-for-post-covid-19-reactivation). April 23, 2020.



suburban locations may be asked to wait in their cars until they receive a text message from the office.<sup>1</sup>

“We will likely make changes to avoid having multiple patients in the same area at the same time,” explains Jennifer Stewart, OD, of Norwalk, CT. “This may include decreasing the number of patients on the schedule, staggering how they are scheduled, asking patients to wait in their cars until we are ready and changing patient flow in our office to minimize crowding.”

Letting patients browse about the office will have to stop for a while. Some practices will require patients book an appointment for their dispensaries, in 15-minute increments, with access limited to one individual at a time.

### **5** *Find hands-free options.*

Doctors may want to put into place methods to reduce the amount of surfaces a patient touches, such as leaving the practice front door open (or even installing a motion-activated door), launching cashless payment systems and encouraging patients to fill out registration forms online, Dr. Chou says.

### **6** *When in doubt, reschedule.*

Moving forward, patients won't want to be near anyone who's visibly unwell, COVID-related or not. Dr. Stewart will ask patients who are ill or who have been in contact with someone who is sick to reschedule in two to three weeks.

### **7** *Take temperatures of everyone.*

This goes for both staff and patients. It's not the most reliable screening tool, as asymptomatic individuals can still spread the virus, but it might catch some.

Some medical authorities advise that anyone registering 100.4° or higher should be sent home. Moreover, it has a psychological benefit. Patients will be more at ease knowing that everyone who's currently on the premises or who passed through that day has been screened.

### **8** *Conduct histories by phone.*

Have a staff member call each patient a day or two before their exam to obtain all insurance and registration information, plus a full history. With a lower caseload at the outset, staff may have time to devote to this task. Patients will appreciate it both as a safety measure and a convenience (no one likes filling out forms at the doctor's office).

### **9** *Walk before you run.*

Susan Resnick, OD, who has large contact lens specialty practices in Manhattan and Long Island, has decided to scale down hours and capacity. One doctor will be scheduled at each location from 10am

until 3pm during the first two-to-four weeks. “We don't want our staff travelling in rush hour since they rely on public transportation, and their safety is our first concern,” Dr. Resnick says.

Patients at her practice will be scheduled one per half hour and will alternate between exam rooms.

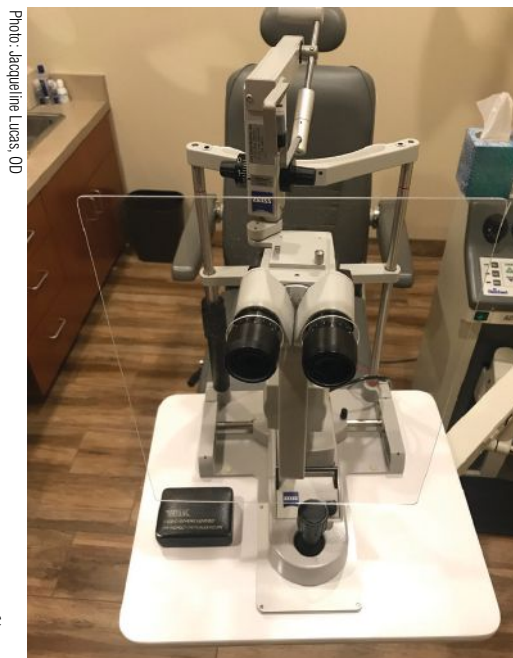Dr. Hornberger believes many doctors will initially schedule at 50% of their previous capacity, which poses a different set of challenges regarding staffing and revenue. Prior to COVID-19, Dr. Hornberger scheduled a half hour for a complete eye exam, but she is now considering allotting an hour for each appointment to allow enough time to clean and disinfect. In addition, her current scheduling protocol is to ask patients if they are in immediate need of contact lenses or glasses, if they have issues such as diabetes or glaucoma or any other immediate reasons why they need to be seen quickly. “If not, we're probably looking at August to schedule those patients.”

### **10** *Install breath shields.*

At the slit lamp, a plexi-glass barrier will be a virtual necessity from now on. Either purchase one or make your own (Learn how here: [www.reviewofoptometry.com/article/how-to-make-your-own-slit-lamp-breath-shield](http://www.reviewofoptometry.com/article/how-to-make-your-own-slit-lamp-breath-shield)). Consider adding a similar barrier at the front desk to separate office staff from patients.

### **11** *Adjust your exam methods.*

Prior to closing for routine care in March, Dr. Resnick had shifted to more “problem-centric” exams to limit touching the patient when possible. For some patients, and when appro-



**If you have the right tools, you can make your own slit lamp breath shield.**



priate, Dr. Resnick skipped certain pretests that weren't critical. Going forward, she says her practice may forego routine visual fields except for glaucoma patients in an effort to be selective in her practice's COVID-19 clinical strategy.

Reusable bottles such as dilating drops and topical anesthetics should be stored in a cabinet, instead of on the counter, to prevent exposure to anything aspirated by you or the patient. You may also want to wear safety goggles during any up-close contact with the patient.

**12 Rethink tonometry.** Clinicians should consider replacing their reusable Goldmann tonometers with other options such as disposable tonometer prisms or single-use protective sleeves.<sup>1</sup> Because pneumotonometers and air-puff tonometry can presumably aerosolize the tear film and any viral particles, clinicians should steer clear of these devices whenever possible.<sup>1</sup>

Dr. Hornberger currently uses an iCare rebound tonometer that allows for a sterile probe for each patient. "You don't have the puff factor, and you don't have to instill eye drops where you have to get close to the patient," she says,

**13 Disinfect—everywhere, every time.**

Because of COVID-19's easy transmission, cleaning and safety precautions will be critical. In Dr. Resnick's practice, every exam room will be completely disinfected before the next patient—a good practice for everyone. In addition, individuals with suspected ocular infections will be put in a special containment area.

"We already have a strict sanitation and sterilization protocol in place and will continue this," adds

Dr. Stewart. "We ask patients to wash hands when they first enter the office and when moving to different rooms. We'll continue to wipe down any patient area, including counters and doorknobs, frequently. In the optical, we'll disinfect frames after patients touch them and minimize browsing."

As part of Dr. Neufeld's reopening plan, his office will implement sterilization processes for exam rooms, reception areas and optical/frames. The latter will include a bin where "used" frames will be placed and then cleaned before being put back on the frame board.

**14 Boost patient confidence.** Patients are expecting you, the healthcare professional, to set an example. "Opening up too early will cast a shadow of social irresponsibility," Dr. Chou explains. "I feel it's more important to communicate with the patient base since uncertainty may lead them astray to subpar online prescription renewal." A patient communication system, such as Eyecare Prime, DemandForce or SolutionReach, will come in handy right about now, he says. (Disclosure: DemandForce is owned by Internet Brands, parent company of the publisher of *Review of Optometry*.)

In addition, COVID-19 likely has patients hypersensitive about disinfection, and any sanitizing activities they see—whether effective or not—will be important, Dr. Chou says. He likens this to restaurants that give straws with a paper wrapper at the top. "It's a visual reinforcement there has been an attempt at sanitation, but the truth is, the wrapper probably does little in actually reducing contamination."

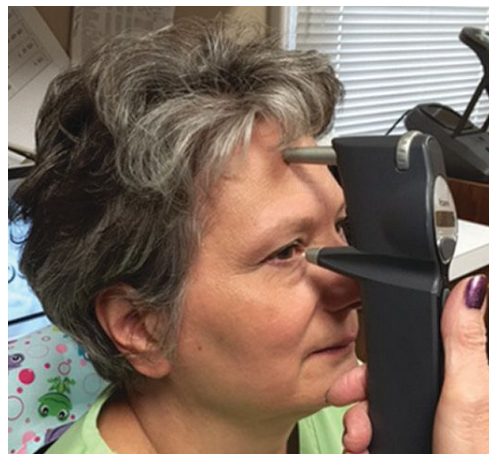

Photo: Nathan Stevens, OD

**Tonometers that provide sterile probes for each patient, such as the iCare seen here, may be a better option for checking IOP.**

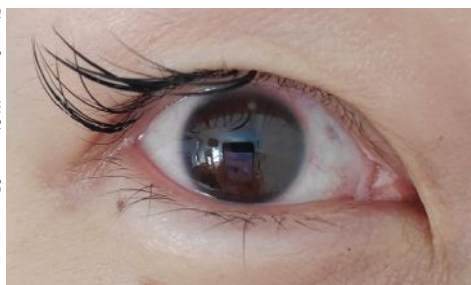If a patient sees you or staff disinfecting—cleaning the slit lamp with alcohol pads or wiping down surfaces in the exam room, for example—it will help reassure the patient far more than if the tech does this behind closed doors, he adds.

**15 Update your wardrobe.** COVID-19 can live on surfaces for hours, so ODs can reduce the chances of contamination for staff and patients by requiring a more sanitary dress code. Dr. Resnick's doctors and staff will now wear scrubs, which will be put in plastic bags after wear and replaced with new scrubs delivered daily. Everyone in her offices will also wear gloves and masks, and she and the other ODs will wear N-95 masks, as they will have longer and closer interactions with the patients.

Most doctors will likely need more PPE than they think, and prior to reopening, practices need to pinpoint reliable, trusted suppliers and alternate suppliers, Dr. Gerber says. Over a three-month period, he estimates practices may need between 1,200 and 8,000 masks, depending on patient volume and number of staff. Doctors



Photo: Suzanne W. Sherman, OD



**Doctors can keep using telehealth for some conditions easily identified with an external exam and a good history. This patient was diagnosed, via telehealth, with a corneal infiltrate due to overnight contact lens wear.**

will also need to determine how often they will need to change masks and ensure they have masks on hand when patients show up to an appointment without one.

**16** *Keep up with telemedicine.* Some doctors turned to telehealth out of necessity and look forward to abandoning it once they reopen. But it's probably here to stay. Take care to master telehealth so you can make it a sustainable part of your practice. This allows you to see more patients than would otherwise be possible, extending the care you provide and adding more to practice revenue.

Does a conjunctivitis patient really need to be in the same physical space as you to make the diagnosis? Most laptop and phone cameras can give you a decent enough view. Moreover, "I can get 90% of the way to the diagnosis from the history alone," noted Elise Brisco, OD, of Los Angeles in a recent webinar on optometric practice in the COVID-19 era.

**17** *Shuffle staffing.* Dr. Gerber suggests the staff you hire for reopening may not be the staff you laid off, since they may have found a different job or decided not to return if they are

worried about safety issues. "Your staff might be waiting to go back to work, but not necessarily for you."

With an initially decreased schedule, revenue flow will be a big consideration in how many staff members to bring back, Dr. Hornberger says. "A lot of doctors like me are in the same boat where we weren't able to get any Paycheck Protection Program funds in the first round. So a big question is, can we even afford to bring staff back if we're not seeing a full patient load?"

Adding to this, many ODs have furloughed staff currently collecting unemployment, which is enhanced by \$600 a week in Federal Pandemic Unemployment Compensation until July 31, 2020.

"This means a decent number of staff are getting paid more than before and not having to work," Dr. Chou says. "So there is an economic disincentive for these staff to return, even though one of the conditions of them accepting unemployment insurance is willingness to accept work." Technically if they don't accept work, they could lose all of their unemployment compensation, he adds.

**18** *Drop cheapskate plans.* With the downtime, some ODs are revisiting their business decisions when it's time to reopen, including vision plans. Dr. Hornberger's practice currently accepts two large vision plans, but since she will be operating on reduced availability and revenue, plans with lower reimbursement rates may be dropped, she says. "If I have reduced availability, the people who really need to be seen are in my chair, and from an economic standpoint, I can't afford to see a

routine, no glasses, no contact lens vision plan reimbursement individual if I'm only seeing one patient an hour."

Still, it might not be advisable to drop vision plans unless a practice's schedule is completely full, Dr. Chou says. "If you are running at full capacity, that's when it makes business sense to pare off the vision plan that is displacing your ability to see higher-value patients."

**19** *Pass along some costs.* Many practices are changing fees when they reopen. For the first time at Dr. Resnick's practice, she'll be charging a nominal no-show cancellation fee. It's justified, she says, because "we're going to be doing concierge, personalized care where patients get a half hour to an hour all to themselves."

And with the increased cost to practices for PPE and sanitation, a modest bump in fees will likely be necessary, Dr. Gerber adds.

**20** *Don't stress.* "Obviously easier said than done; however, stressing out does nothing but add another negative item to deal with on your already overwhelmingly full plate," Dr. Neufeld says. "This pandemic will be over, and life will resume. Look at ways in which you can run your practice in the leanest way possible right now. Slowly we will all be able to ramp up to full speed."

As practices reopen across the country, Dr. Hornberger offers this piece of advice: be flexible. "The reopening plan doesn't have to be perfect at the beginning. We just have to get back to taking care of our patients, and whatever that ends up looking like will be okay." ■

1. Liebmann JM. Ophthalmology and glaucoma practice in the COVID-19 era. *J Glaucoma*. April 14, 2020. [Epub ahead of print].



The Optometric Retina Society & Review Education Group present:

# RETINAUPDATE2020

REGISTRATION OPEN

DECEMBER 4-5 | SCOTTSDALE, AZ

EARN UP TO 12 CE CREDITS\*



**CHAIR**  
Mohammad Rafieetary, OD,  
FAAO



**CO-CHAIR**  
Steven Ferrucci, OD, FAAO

**FAIRMONT SCOTTSDALE PRINCESS**  
7575 East Princess Drive  
Scottsdale, AZ 85255

**A limited number of rooms  
have been reserved**  
at \$279 per night + applicable taxes  
and fees.

Make your reservations with the hotel  
directly at 480-585-4848.

**Mention "Retina Update 2020"**  
for group rate.

#### ORS MISSION STATEMENT

The mission of the Optometric Retina Society (ORS) is to promote the advancement of vitreoretinal knowledge for clinicians, ophthalmic educators, residents, and students. The ORS is dedicated to posterior segment disease prevention, diagnosis, management and co-management.

#### REGISTRATION:

**Early Bird Special:** \$375

**Full Conference after October 9:** \$450

See event website for daily fees.

Three ways to register:

[www.ReviewEdu.com/ORSRetUpdate2020](http://www.ReviewEdu.com/ORSRetUpdate2020)

e-mail: [ReviewMeetings@MedscapeLIVE.com](mailto:ReviewMeetings@MedscapeLIVE.com) or call: 800-999-0975



Review Education Group partners with Salus University for those ODs who are licensed in states that require university credit.



Administered by:



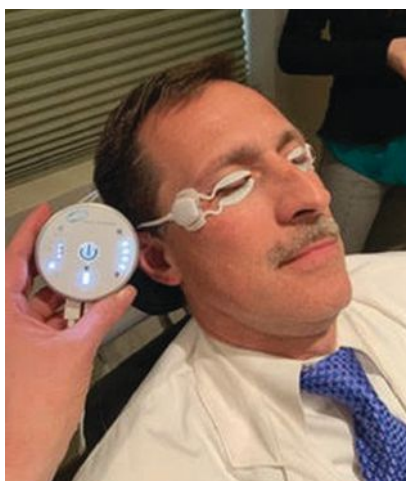21st Annual Dry Eye Report

# Treat the Front Before the Cut

The surgeon will remove the patient's cataract, but it's your job to make sure the eye is healthy enough for surgery, or else to help get it there. **By Thomas Chester, OD**

Ocular surface disease can complicate and, in some cases, impede cataract surgery. At least one study shows 63% of presurgical cataract patients have a decreased tear break-up time (TBUT) of five seconds or less—indicating evaporative dry eye.<sup>1</sup> That same research shows 77% of patients scheduled for surgery had corneal staining.<sup>1</sup> Other research indicates that 87% of cataract patients use artificial tears one month postoperatively.<sup>2</sup>

While dry eye is now a widely diagnosed disease, the number of actual sufferers is likely even greater since many self treat using over-the-counter products or under-report their symptoms. I've heard patients say they believe ocular dryness is simply "typical for my age." However, dry eye disease (DED) can have significant consequences to a patient's lifestyle as well as on various aspects of cataract surgery. As primary care clinicians, optometrists need to take special consider-



**Eyelid warming devices such as the Tearcare system (Sightscience), can help express meibomian glands and prepare the patient for refractive surgery.**

ation of the ocular surface health of every patient planning to undergo cataract surgery. This includes gathering preoperative measurements, and monitoring postoperative refractive outcomes.

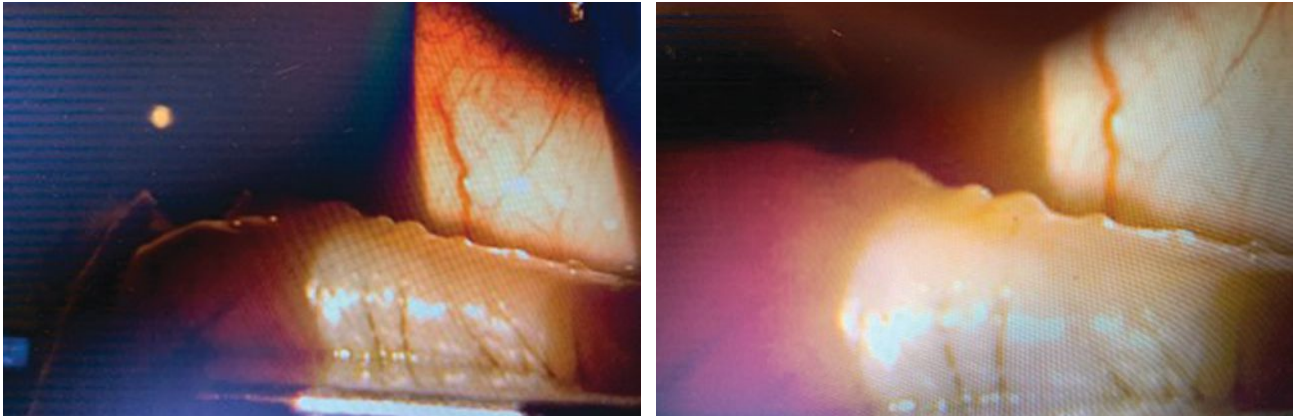
Here, we review how to oversee the health and stability of a cataract

patient's ocular surface, before and after the operation. We will also explain how stabilizing the ocular surface before surgery can impact post-op satisfaction and reduce the chances of possible complications.

## Test All, Despite Symptoms

Patients who are symptomatic will likely be more receptive to discussing how their DED can affect surgery. Generally speaking, these patients may or may not want to have the dry eye treated prior to surgery but patients may not fully understand the impact that a compromised ocular surface can have on their surgical outcomes.

Research clearly shows an impaired ocular surface affects preoperative planning for cataract surgery.<sup>3</sup> Having a poor tear film can potentially alter the corneal surface resulting in reduced repeatability of keratometry readings and diminished accuracy of intraocular lens (IOL) calculations.<sup>3</sup> The study also concluded that diagnosing



**These slit lamp images show a patient undergoing the TearCare procedure. Note the visible material being expressed from the glands.**

and treating dry eye preoperatively results in better visual outcomes.<sup>3</sup> However, many patients present asymptotically. Only approximately 22% of the patients presenting for surgery had been diagnosed with dry eye previously.<sup>1</sup> However, a 2015 study shows dry eye in 54.3% of 400 participants older than 40 years.<sup>4</sup> Additionally, that study shows the prevalence is greatest among participants 71 years or older (67.3%), around the age when many will also be facing potential cataract surgery.<sup>4,5</sup> Of those who reported being completely asymptomatic, 24.1% had dry eye.<sup>4</sup>

Patients with subclinical DED are just as likely to experience surgical complications and return with one or more DED symptoms. So, the importance of dry eye testing using both signs and symptoms for every cataract surgery candidate can't be overstated.

### Create a Testing Protocol

Any discussion about how to treat ocular surgery patients with dry eyes needs to begin with identifying the problem. In our clinic, we stick close to the American Society of Cataract and Refractive Surgery (ASCRS) guidelines.<sup>6</sup> By measuring patient symptoms via SPEED ques-

tionnaires, we are able to determine the patient's perspective of their condition preoperatively. We repeat the questionnaire at each visit (except day one and week one post-op). In our clinic, we flag scores higher than 8 as dry eye suspicious. This step is important because, as we've likely all heard before, "If a patient is diagnosed prior to surgery, it is the patient's problem, if a patient is diagnosed after surgery, it is the doctor's problem."

Other measures of subjective symptoms include the Dry Eye Questionnaire-5 or the Ocular Surface Disease Index. Whichever test you employ, this subjective information is especially valuable when combined with the same results after the procedure. Often, patients present postoperatively with what they perceive is DED caused by their cataract surgery. By referencing a pre-op questionnaire, it frequently reveals that the same symptoms were present before the procedure as well. It can reassure a patient to learn that the surgery did not worsen their dry eye, only that they are now more aware of the symptoms.

Objective tests are also critical in identifying patients, especially those who are asymptomatic. But even if patients are symptomatic, objective

DED tests can reveal much about the current homeostasis of the patient's tear film, so you'll want to incorporate some of the following into your preoperative workup. In our clinic, we have access to both inflammatory marker measurements (Inflammadry, Quidel) and tear osmolarity measurements (Tearlab). When combined with TBUT, osmolarity measurements provide an adequate assessment based on the Tear Film and Ocular Surface Society's DEWS II definition.<sup>7</sup>

Tear hyperosmolarity correlates strongly to tear film instability. A 2017 study shows patients with hyperosmolarity had a greater corneal variability as measured with keratometry readings, resulting in IOL calculation variability as well.<sup>8</sup> With the addition of this purely objective data, a provider can effectively identify a significant number of dry eye patients preoperatively. Other investigative options can include tear film interferometry, tear clearance assessments (i.e., fluorescein clearance test, tear function index, fluorophotometry) and ocular surface damage assessment (i.e., corneal and conjunctival, rose bengal, lissamine green staining, cytology), corneal epithelial cell mapping and lipid layer assessments (i.e., precorneal/meibomian grading).<sup>9</sup>

# Surgical Comanagement

Treatment Protocols <sup>7</sup>		
Minimal	Mild	Moderate
<b>Aqueous deficient</b>		
Education regarding the condition, its management, potential dietary modifications (including water intake), treatment and prognosis	Non-preserved ocular lubricants to minimize preservative-induced toxicity	Autologous/allogeneic serum eye drops
Modification of local environment	Punctal occlusion	Therapeutic contact lens options
Ocular lubricants of various types (if MGD is present, then consider lipid-containing supplements)	Moisture chamber spectacles/goggles	Amniotic membrane grafts
Identification and potential modification/elimination of offending medications	Topical corticosteroid (limited-duration), non-glucocorticoid immunomodulatory drugs (such as cyclosporine) or LFA-1 antagonist drugs (such as lifitegrast)	
<b>Lipid Deficient</b>		
Education regarding the condition, its management, potential dietary modifications (including oral omega-3s), treatment and prognosis	Lid hygiene and warm compresses of various types	Tea tree oil treatment for <i>Demodex</i> (if present)
Modification of local environment	Non-preserved ocular lubricants to minimize preservative-induced toxicity	In-office, physical heating and expression of meibomian glands with TearCare (Sight Sciences), Lipiflow (Johnson & Johnson Vision) or iLux (Alcon)
Ocular lubricants of various types, including more lipid-containing options	Moisture chamber spectacles/goggles	Topical antibiotic or antibiotic/steroid comb applied to the lid margins for anterior blepharitis (if present)
Identification and potential modification/elimination of offending medications	Topical LFA-1 antagonist drugs (such as lifitegrast)	Oral doxycycline (50-100mg po up to bid) or azithromycin (Z-pak)

## Presurgical Treatment

With appropriate identification, optometrists can customize the most appropriate treatment plan for each patient. This can help determine the best procedure as well as the most appropriate IOL for the patient. A patient with significant history of DED may not

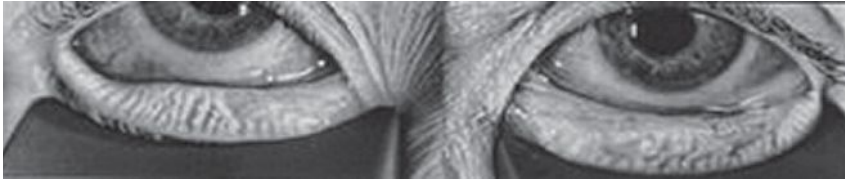be the best candidate for a multifocal lens since these lenses typically require high contrast to maximize the vision. DED identification in premium IOL patients is not only critical for the success of the patient but also for the success of the refractive cataract surgery portion of the practice since many of these

patients are paying out of pocket and bring higher expectations of their surgical results. In attempting to meet the higher expectations of refractive cataract lens patients, providers should have a healthy ocular surface prior to surgery as a priority in their treatment plans.

**Surgical delay.** One way to establish a healthy ocular surface is by stabilizing the ocular tear film while delaying the surgery. Reasons to delay surgery include corneal abnormality (e.g., dellen, superficial punctate keratitis), irregularity in kerotometry (topography) measurements or fluctuating vision.

If delaying the procedure is warranted, it is important to understand what is being monitored so treatment can be appropriate and an endpoint can be achieved. This process can take two to four weeks or longer to improve adequately enough to proceed with surgery. Only upon adequate resolution of the signs and symptoms should the patient proceed. For most patients planning to have standard IOLs implanted, we've found that a 70% resolution of staining is fine as long as the central area is cleared. The same would apply to symptoms—if a patient's symptoms are reduced by 25%, they may be improved enough to proceed, although this is not a hard and fast rule as some contingencies can impact the decision.

Ocular surface issues have an outsized effect on the performance of multifocal IOLs, so if your patient is interested in these high-performance lenses, it is imperative that they achieve a healthy tear film prior to surgery. For example, if a patient with SPK chooses a traditional IOL, they may be counseled as to the effects of the SPK on their vision and it may be treated concomitantly. If the same patient



**This meibography picture demonstrates mild breakdown of the meibomian glands. Classic signs in this image are the lack of parallel meibomian gland structures—whether due to angling or breakdown.**

desires a multifocal IOL, however, their dry eye will more profoundly affect their postoperative vision and should be resolved prior to surgery. Apply the same rationale to epithelial thickness and keratometry measurements with an emphasis on stability. Take these measurements on a serial basis to determine whether or not the surface is stable. TBUT can create irregular dynamic acuity and becomes a much greater concern with multifocal IOLs,

where the patients report transient decreases in vision that are attributable to variations in tear film causing decreased contrast sensitivity.<sup>10</sup>

**Treatment.** As there are different possibilities to treat the ocular surface, much depends on the etiology. If patients lack sufficient tear volume—based on tear meniscus height in conjunction with qualitative analysis of the lipid layer—prescribing a cyclosporine option may be the best option, or punctal occlusion if no

inflammation present. However, if the source is MGD, thermal treatments with expression may be the best option. Doxycycline can also be considered in patients with MGD. If the patient shows significant SPK, loteprednol or lifitegrast may be prescribed or in severe cases an amniotic membrane can be employed. In the least, good hygiene and some form of preservative free artificial tears and/or warm compresses can likely be of help to these patients whether it is used prior to surgery, during the postoperative period (excluding warm compresses during the first week), or for long term maintenance.

When performing the biomicroscopy exam, pay special attention to corneal and conjunctival structures to note any staining. Don't forget to also evaluate the patient's tear

## HEALTHY EYES START HERE

*Now, more than ever, it is important for your patients to practice good ocular hygiene at home.*

The **Bruder Hygienic Eyelid Care Kit** makes it easy to dispense and educate your patients about the importance of a daily lid hygiene routine.

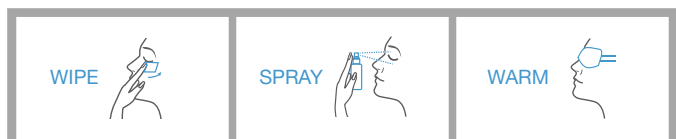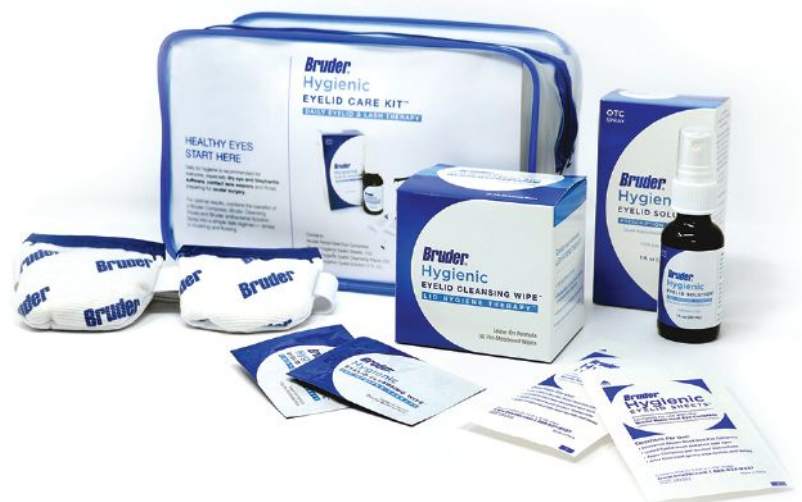Three easy steps—*wipe, spray and warm*—are all that's needed to get patients on the right path.

Watch & Share our Patient Video at  
[bruder.com/kit-video](http://bruder.com/kit-video)

**Bruder** | Better. By Design.

888-827-8337 | [eyes@bruder.com](mailto:eyes@bruder.com)

## PROMOTE AND PRESERVE EYELID HEALTH WITH ONE CONVENIENT KIT



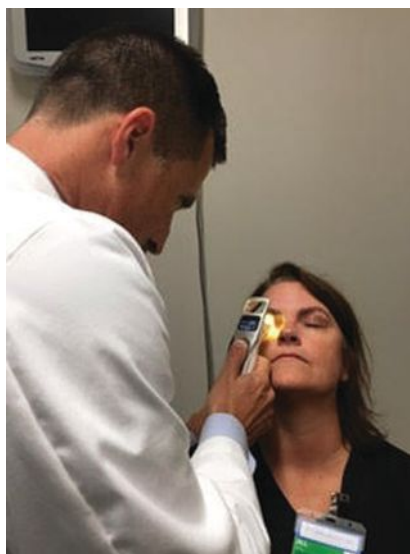TO ORDER, CONTACT YOUR ACCOUNT REPRESENTATIVE AT  
888-827-8337 OR VISIT [ORDER.BRUDER.COM](http://ORDER.BRUDER.COM)

# Surgical Comanagement

meniscus. Additionally, note the lid margin health to determine the state of the glands and the status or potential status of any lid infections or inflammations that could potentially disrupt postoperative healing. Meibomian gland expression can be performed using the Meibomian Gland Evaluator (Johnson & Johnson Vision) to demonstrate gland function. During the clinical exam the provider should also pay special attention to mechanical or structural abnormalities such as poor lid closure, inadequate lid apposition or an irregular lid margin.

## Anterior Healing

During the immediate postoperative period, several complications may arise. These include acute intraocular pressure spikes, endophthalmitis and cystoid macular edema. These can occur with any patient—dry eye or otherwise—following traditional cataract surgery,



**The iLux (Alcon) can be performed in the office to help clear the meibomian glands of patients with dry eye due to meibomian gland dysfunction. This can help set the stage for a successful refractive surgery.**

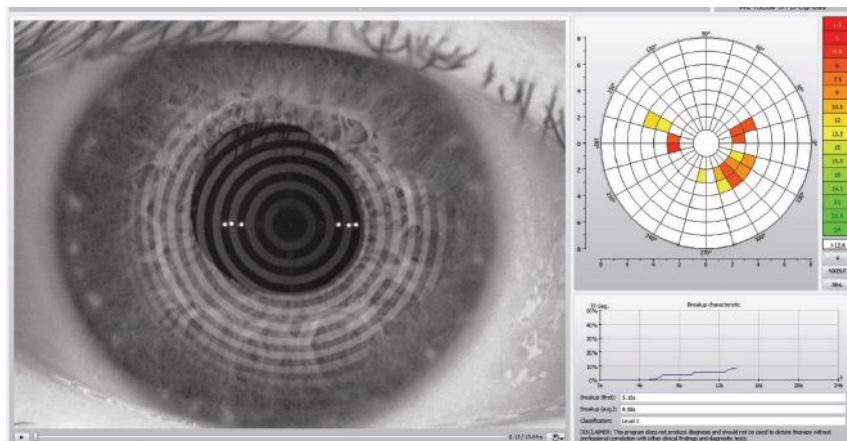


Photo: Dan Fuller, OD

**This Keratograph 5M (Oculus) images is can help establish a patient's tear break-up time, which can help prepare them for surgery.**

laser-assisted cataract surgery or refractive cataract surgery. However, for a patient who was previously diagnosed and treated for DED prior to surgery, the optometrist needs to educate them about their normal healing course. You'll need to explain that the use of topical antibiotics and antiinflammatories and the preservatives located within them can potentially lead to ocular surface agitation, leaving patients with a newly observed or heightened awareness of DED symptoms.<sup>11</sup>

Counsel patients who traditionally use warm compresses to manage posterior blepharitis or use lid scrubs to manage anterior blepharitis to withhold these therapies for a full week, so as not to compromise the new incision and create any increased risk for infection. Stopping these maintenance regimens can lead to a potential backslide or relapse of previously managed DED.<sup>11</sup>

Exposure to light from the operating microscope can also be a contributing factor to the patients dry eye syndrome.<sup>12-14</sup> Optometrists should explain to patients that even the corneal incision can potentially

exacerbate a patient's DED. The incision itself can potentially cut through the nerves that are responsible for innervating the corneal surface and, by doing so, may delay the epithelial wound healing. Discussing this helps the patient understand that, during the initial healing process, they may have reduced tear production, decreased TBUT, decreased mucin production increased inflammation and, ultimately, discomfort.<sup>15</sup> This aspect is relatively temporary and will correct itself with healing.

## Outcomes

It is not uncommon for a patient to have an outstanding surgical procedure, yet be unsatisfied with the outcome.<sup>10</sup> In a 2016 study of patients who were dissatisfied, 57% were due to refractive error and 35% were due to DED. Patients may also confront postoperative discomfort as a result of the previously mentioned postoperative drops, but some might develop discomfort due to a preoperative refractive miscalculation as any residual refractive error can produce eyestrain or create anisometropia between the two eyes.



These patients can have uncorrected 20/20 vision, yet exhibit “20/unhappy” presentation. Since refractive error is closely associated with dry eye, it’s worthwhile to evaluate the ocular surface.<sup>16</sup>

It is imperative to reset expectations during this timeframe. Missed refractive errors can be modified, but it is important to correct the underlying condition that may have caused the error. Likewise, if the post-operative course is expected to be temporary, take measures to address the problem and counsel the patient.

Since dry eye disease can have an influence on ocular surgery before and after the procedure, providers should recognize the condition and treat it appropriately. For some, that treatment means delaying the procedure so the condition can be

minimized or corrected, while for others it may just mean a more thorough education on appropriate expectations. However, all eye care providers should be aware of the impact this condition can have as well as the resulting consequences if they are not dealt with appropriately. ■

*Dr. Chester is a partner at the Cleveland Eye Clinic and is active in training professionals in the perioperative care of the refractive surgery patient, cataract surgery co-management and ocular surface disease management.*

1. Trattler W, Majmudar P, Donnenfeld E, et al. The prospective health assessment of cataract patient (PHACO) study: the effect of dry eye. *Clin Ophthalmol.* 2017;11:1423-30.
2. Roberts CW, Elie ER. Dry eye symptoms following cataract surgery. *Insight* 2007;32(1):14-21.
3. Chuang J, Shih KC, Chan T, Wan KH, Jhanji V, Tong L. Preoperative optimization of ocular surface disease before cataract surgery. *J Cataract Refract Surg.* 2017;43(12):1596-1607.
4. Shah S, Jani H. Prevalence and associated factors of dry eye: our experience in patients above 40 years of age at a

- tertiary care center. *Oman J Ophthalmol.* 2015;8(3):151-6.
5. Kauh C, Blachley T, Lichter P, et al. Geographic variation in the rate and timing of cataract surgery among US communities. *JAMA Ophthalmol.* 2016;134(3):267-76.
6. Starr C, Gupta P, Farid M, et al. An algorithm for the preoperative diagnosis and treatment of ocular surface disorders. *J Cataract Refract Surg.* 2019;45(5):669-84.
7. Craig JP, Nichols KK, Akpek EK, et al. TFOS DEWS II definition and classification report. *Ocul Surf.* 2017;15(3):276-83.
8. Epitropoulos AT, Matossian C, Berdy GJ, et al. Effect of tear osmolarity on repeatability of keratometry for cataract surgery planning. *J Cataract Refract Surg.* 2018; 44(9):1090-6.
9. Kanellopoulos A, Asimellis G. In pursuit of objective dry eye screening clinical techniques. *Eye Vis (Lond).* 2016;3:1
10. Gibbons A, Ali T, Waren D, Donaldson K. Causes and correction of dissatisfaction after implantation of presbyopia-correcting intraocular lenses. *Clin Ophthalmol.* 2016;10:1965-70.
11. Walsh K, Jones L. The use of preservatives in dry eye drops. *Clin Ophthalmol.* 2019;13:1409-25.
12. Sutu C, Fukuoka H, Afshari N. Mechanisms and management of dry eye in cataract surgery patients. *Curr Opin Ophthalmol.* 2016;27:24-30.
13. Cho Y, Kim M. Dry eye after cataract surgery and associated intraoperative risk factors. *Korean J Ophthalmol.* 2009;23:65-73.
14. Li X, Hu L, Hu J, Wang W. Investigation of dry eye disease and analysis of the pathogenic factors in patients after cataract surgery. *Cornea.* 2007;26(9 Suppl 1):S16-S20.
15. Donnenfeld ED, Solomon K, Perry HD. The effect of hinge position on corneal sensation and dry eye after LASIK. *Ophthalmology.* 2003 May; 110(5):1023-30.
16. Dhungel D, Shrestha G. Visual symptoms associated with refractive errors among Thangka artists of Kathmandu valley. *BMC Ophthalmol.* 2017;15:258.

# THE RICK BAY FOUNDATION

*for Excellence in Eyecare Education*

*Support the Education of Future Healthcare & Eyecare Professionals*

Scholarships are awarded to advance the education of students in both **Optometry** and **Ophthalmology**, and are chosen by their school based on qualities that embody Rick’s commitment to the profession, including integrity, compassion, partnership and dedication to the greater good.

Visit [www.rickbayfoundation.org](http://www.rickbayfoundation.org)

*(Contributions are tax-deductible in accordance with section 170 of the Internal Revenue Code.)*



THE RICK BAY FOUNDATION  
*for Excellence in Eyecare Education*

*(The Rick Bay Foundation for Excellence in Eyecare Education is a nonprofit, tax-exempt organization under section 501(c)(3) of the Internal Revenue Code.)*

## 21st Annual Dry Eye Report

# Diet: Why Dry Eye Hangs in the Balance

What we eat—and don't eat—is impacting our ocular health. Here's what you need to know. **By Katherine Sanford, OD**

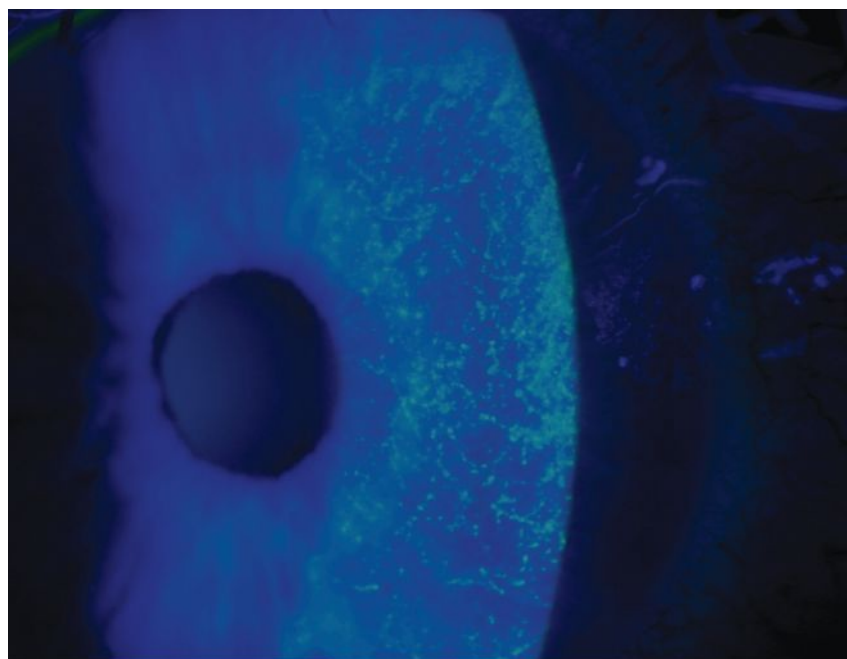
**T**he past 10,000 years have given rise to many changes in our nutritional environment, with enormous implications.

A less varied diet and an increasingly sedentary lifestyle has led to an increased risk of chronic conditions such as atherosclerosis, hypertension, obesity, diabetes and many cancers.<sup>1</sup> Today's Western diet includes too many dietary grains and fatty foods and not enough fruits, vegetables and proteins. As a result, the number of omega-6 fatty acids in our diet are significantly higher while the amount of omega-3 fatty acids continues to decrease.

The connections between omega-3, omega-6 and inflammation are well documented in the medical literature, leaving some to speculate that this nutritional shift plays a role in the pathogenesis of dry eye disease (DED).

### DED in Modern Society

Dry eye's impact on society is significant. Based on the literature, the incidence of DED ranges between 5% and 30% in individuals older



**This slit lamp photo demonstrates sodium fluorescein staining of a patient's eye with punctate keratitis.**

than 50, which, at the upper range, makes it more prevalent in the US population than diabetes, cancer and heart disease combined.<sup>2-4</sup>

The irritation, blurred vision and eye fatigue associated with dry eye lead to a decrease in quality of life by impairing a patient's ability to

read, drive and work on the computer.<sup>5-7</sup> Studies show that when direct costs such as office visits, tear therapies and supplements are combined with indirect costs (e.g., loss of productivity), the yearly impact of DED on the US economy nears \$55 million.<sup>5</sup>

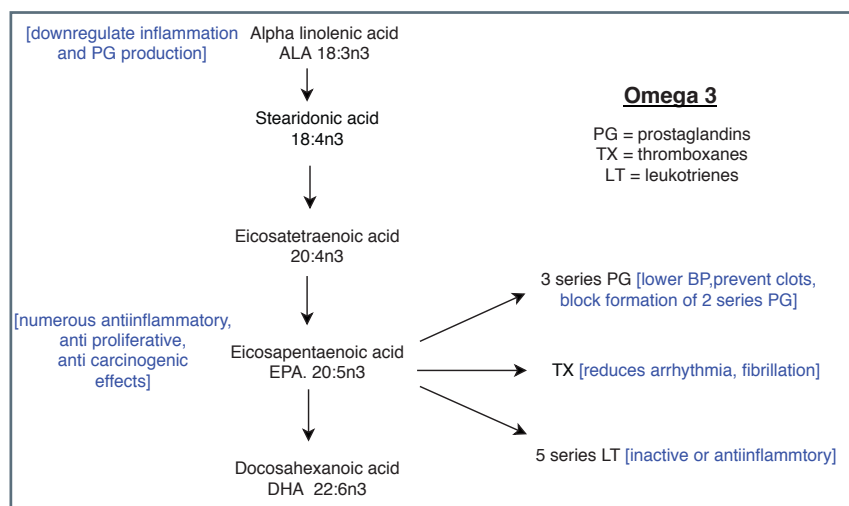
Practitioners have a variety of treatments in their armamentarium to combat this disease, including ophthalmic lubrication, lid and meibomian gland therapy, anti-inflammatory eye drops and punctal plugs.<sup>9</sup> While these treatments can help to manage dry eye, clinicians continue to search for new treatment options with a particular focus on those that address the underlying disease process.<sup>10</sup>

The search for dry eye answers has led researchers to question whether nutrition, specifically the balance of omega-3 and omega-6 fatty acids and their role in inflammation, might hold the key.

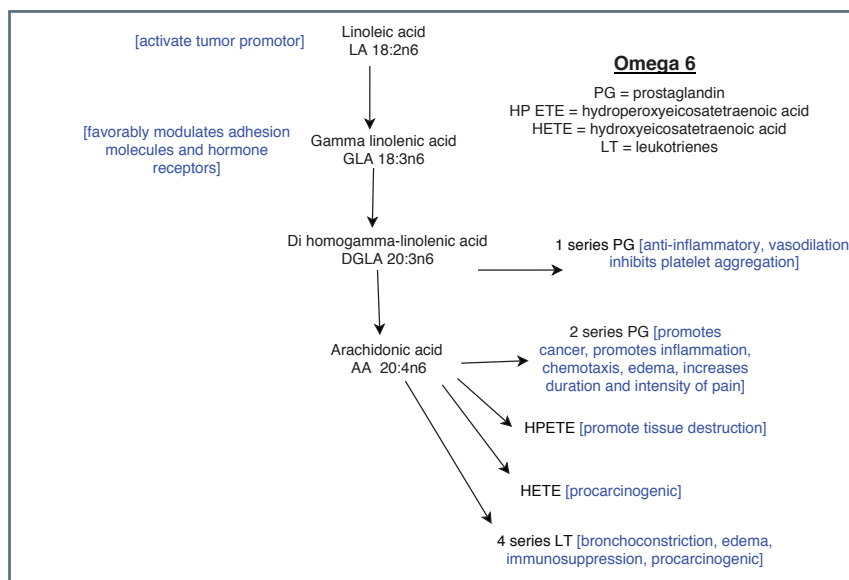
## Fatty Acid Basics

Dietary polyunsaturated fatty acids (PUFAs) consist of two primary categories: omega-6 and omega-3. Omega-3 and omega-6 PUFAs are derivatives of the essential fatty acids (EFAs) alpha-linolenic acid (ALA) and linoleic acid (LA).<sup>11,12</sup> ALA is an omega-3 fatty acid found in flaxseed and chia that is converted by the body to the longer chain PUFA eicosapentaenoic acid (EPA) then docosahexaenoic acid (DHA). Because this process is inefficient in humans, we must obtain EPA and DHA from food sources or supplements.<sup>12-15</sup> DHA and EPA are found naturally in fish and krill oils, as the fish consume microalgae that produce them.<sup>12</sup>

LA is an omega-6 fatty acid found in vegetables oils, nuts, eggs and meat.<sup>20</sup> Once ingested, it is desaturated and elongated to form the longer chain PUFA gamma-linolenic acid (GLA) then arachidonic acid (AA).<sup>15,17</sup> GLA, which is found in black current seed oil and evening primrose oil, exhibits anti-inflammatory properties while AA is pro-inflammatory. GLA increases the amount of dihomogamma-



**These diagrams show the cascade of omega-3 (above) and omega-6 (below) metabolism and eicosanoids. Adapted from Vasquez A.<sup>39</sup>**



linolenic acid (DGLA), which can then be converted to either AA or to 1-series prostaglandins. Omega-3, specifically EPA, competes with the conversion of DGLA to inflammatory AA, thus increasing the production of anti-inflammatory 1-series prostaglandins.

Biochemically, to get the full benefits of increased GLA, you should ensure the patient also has adequate levels of EPA either through their diet or supplementation.<sup>19,20</sup> GLA can provide relief from chronic

inflammatory conditions such as rheumatoid arthritis and improve symptoms in patients with dry eye and Sjögren's.<sup>17-19,21</sup>

Both omega-3 and omega-6 fatty acids form eicosanoids, which are signaling molecules within the body. Eicosanoids from omega-3 are key to the function of the cardiovascular, pulmonary, immune and endocrine systems while omega-6 eicosanoids are mediators of vasoconstriction and platelet aggregation which contribute to inflammation.<sup>12</sup>

A Medscape **LIVE!** CONFERENCE

# 12<sup>th</sup> Annual OPTOMETRIC GLAUCOMA SYMPOSIUM

Join our faculty of renowned ODs and MDs for a highly interactive meeting covering the most up-to-date information in glaucoma care.

Earn up to **12 CE credits\***

## SOUTHWEST

**October 2-3, 2020**

### **Austin Marriot Downtown**

304 East Chavez Street  
Austin, TX 78701  
Phone: 512-457-1111

**Discounted room rate: \$299** plus tax

Please book with the hotel directly at 512-457-1111. Identify yourself as a participant of Southwest Optometric Glaucoma Symposium for group rate. Rooms are limited.

**Early bird registration: \$275**

Full conference after August 7: \$325  
See event website for daily fees.

## THREE WAYS TO REGISTER

**ONLINE:** [www.reviewedu.com/SWOGS2020](http://www.reviewedu.com/SWOGS2020)

**CALL:** 877-451-6514

**EMAIL:** [reviewmeetings@medscapelive.com](mailto:reviewmeetings@medscapelive.com)



Administered by:

**REVIEW**  
EDUCATION GROUP

**COPE**

\*Approval pending

**SALUS**  
UNIVERSITY  
Pennsylvania College of Optometry

Review Education Group partners with Salus University for those ODs who are licensed in states that require university credit.

Earn up to  
**12 CE  
Credits\***

## PROGRAM CO-CHAIRS



### Murray Fingeret, OD, FAAO

Chief of the Optometry Section,  
Brooklyn/St. Albans Campus,  
Department of Veterans Administration  
New York Harbor Health Care System

Clinical Professor,  
SUNY, College of Optometry



### Robert N. Weinreb, MD

Chairman & Distinguished Professor of Ophthalmology  
Director of the Shiley Eye Institute  
Director of the Hamilton Glaucoma Center  
Morris Gleich, M.D. Chair in Glaucoma  
University of California San Diego

# WEST COAST

**December 11-12, 2020**

## Hyatt Regency Huntington Beach

21500 Pacific Coast Highway  
Huntington Beach, CA 92648  
Phone: 714-698-1234

**Discounted room rate: \$239** plus tax

Please book with the hotel directly at 877-803-7534. Identify yourself as a participant of West Coast Optometric Glaucoma Symposium for group rate. Rooms are limited.

**Early bird registration: \$275**

Full conference after October 16: \$325  
See event website for daily fees.

## THREE WAYS TO REGISTER

**ONLINE:** [www.reviewedu.com/WCOGS2020](http://www.reviewedu.com/WCOGS2020)

**CALL:** 877-451-6514

**EMAIL:** [reviewmeetings@medscapelive.com](mailto:reviewmeetings@medscapelive.com)



Administered by:

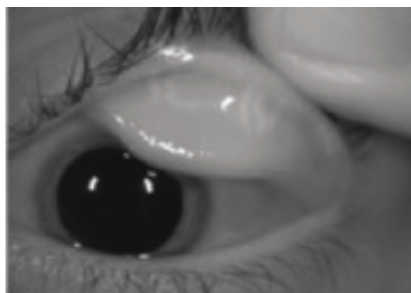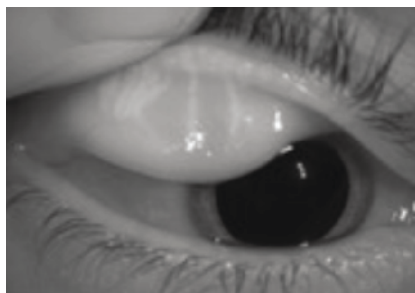**REVIEW**  
EDUCATION GROUP

**COPE**

\*Approval pending

**SALUS**  
UNIVERSITY  
Pennsylvania College of Optometry

## Diet & Dry Eye



**This patient's meibography reveals signs of severe dry eye in a patient with meibomian gland dysfunction.**

Simply stated, omega-3 fatty acids are considered anti-inflammatory while omega-6 fatty acids are primarily pro-inflammatory.<sup>22,23</sup> Though some degree of inflammation is essential to the body's ability to prevent infection and recover from injury, excessive amounts can contribute to chronic disease processes. Research shows that the decline in omega-3 in our tissues allows for its replacement with increased amounts of omega-6.<sup>16</sup> Thus, a diet appropriately balanced in omega-3 and omega-6 fatty acids provides significant health benefits.

There is a beneficial anti-inflammatory shift within the body when the concentration of EPA and DHA is greater than that of AA due to competition in the synthesis of eicosanoids.<sup>12,14</sup> An omega-6 to omega-3 ratio range from 1:1 to 4:1 is considered optimal for the majority of disease process.<sup>1</sup>

### Dietary Shifts

Prior to the agricultural revolution, humans were primarily hunters and gatherers. Lean meat, fish, leafy green vegetables, fruits, berries and honey were readily available, and the human diet had a vast degree of variety.<sup>1</sup> Wild game and plants contributed an appreciable amount of omega-3 to the human diet, creating a 1:1 ratio of omega-6 to omega-3 fatty acids.<sup>1,16,24</sup>

The advent of the agricultural

revolution brought about primarily three dietary changes for which there is no evolutionary precedent in our species.<sup>1</sup>

First, cereal grains entered the human food supply, and quickly become increasingly central to our diet; grains now provide the greatest number of calories in the American diet.<sup>1,16</sup> Cereal grains are high in carbohydrates and omega-6 and are low in omega-3 and antioxidants.<sup>1</sup>

Second, poultry and soybean oil consumption increased exponentially, and soybean oil's contribution to food calories increased 1,000-fold while poultry's contribution increased four-fold. This resulted in a three-fold increase in essential omega-6 but only a two-fold increase in essential omega-3.<sup>16</sup>

Lastly, farmers in the 1950s began to use high-energy grain feed for cattle, which decreased days on feed and improved marbling—or intramuscular fat—in the final product.<sup>11</sup> While there is no significant difference in omega-6 content between the two feeding regimens, grass-fed beef has higher concentrations of omega-3 and has a more favorable omega-6 to omega-3 ratio. Gradually over time, consumers have become accustomed to the flavor profile of grain-feed beef and often prefer it to grass-fed beef.<sup>11</sup>

Together, the increased consumption of cereal grains, advent of the vegetable oil industry and changes

in livestock feed have led to a dramatic increase in the amount of omega-6 in our diet.<sup>1</sup> The ratio of omega-6 to omega-3 in Western diets has now skyrocketed to approximately 15:1.<sup>25</sup>

### The Roots of DED

The Tear Film and Ocular Surface Society's Dry Eye Workshop II defined dry eye as a disease "in which tear film instability and hyper-osmolarity, ocular surface inflammation and damage, and neuro-sensory abnormalities play etiological roles."<sup>5</sup> While numerous risk factors contribute to dry eye, inflammation of the lacrimal gland, ocular surface and meibomian glands is a key contributor.<sup>5,19,25</sup>

When ocular surface inflammation occurs, inflammatory mediators such as prostaglandin E<sub>2</sub> and inflammatory leukotrienes are synthesized from eicosanoids and lead to epithelial cell apoptosis, goblet cell loss and corneal barrier disruption resulting in DED.<sup>14,19,25,26</sup> Omega-3 fatty acids competitively decrease the production of inflammatory mediators and inhibit killer cell activity.<sup>19</sup> Cellular research shows that the efficacy of omega-3 in the context of dry eye may be related to its influence on the composition of lipids produced by meibomian gland epithelial cells in addition to its anti-inflammatory properties.<sup>14,27</sup>

### Where Fatty Acids Fit In

Studies in the 1970s found that deaths due to coronary heart disease were particularly low in Inuit populations that have a diet high in seafood.<sup>11</sup> Researchers discovered that the omega-3 PUFAs in the seafood were responsible for the positive health effects.<sup>11</sup> They also found that a diet high in omega-3 fatty acids has wide-ranging health benefits such as lower serum triglyceride

## SLIT LAMPS

EXCEPTIONAL OPTICS

concentrations, improved cardiac function and lower C-reactive protein and tumor necrosis factor.<sup>13,23,28</sup>

The importance of a balanced omega-6 to omega-3 ratio was first addressed in the 1990s when researchers realized that large amounts of omega-6 in our diet causes the formation of more AA than EPA.<sup>29</sup> The increased AA eicosanoids lead to allergic and inflammatory disorders and continued proliferation of cancer cells.<sup>25</sup>

Although many studies have found a correlation between omega-3 fatty acids and DED, the Women's Health Study in 2005 was the first systematic study to establish the potential protective role of omega-3 fatty acid supplementation in the treatment of DED.<sup>24</sup> Of the approximate 32,000 women included in the study, 4.7% gave self-reports of dry eye. Food frequency questionnaires showed a 68% decrease in self-reported history of dry eye in women who consumed greater than five servings of tuna per week. While the researchers found no correlation between high omega-6 intake and dry eye, they noted that subjects with a high omega-6 to omega-3 ratio (15:1 or greater) were twice as likely to have DED compared with subjects with a lower ratio.<sup>18,24</sup>

Since that study, numerous others have evaluated these fatty acids and DED. One of the first omega-3 dry eye clinical trials in 2011 found that the use of omega-3 supplements resulted in improvements in symptoms and tear production.<sup>30</sup> Other investigations show that patients on omega-3 (EPA/DHA) supplements experience significantly greater improvements in symptoms and signs of dry eye than patients receiving placebo.<sup>10,31-34</sup> Even combinations of omega-3 and the omega-6 GLA can provide

subjective improvement in dry eye symptoms as well as a decrease in corneal inflammatory markers.<sup>19,21</sup> Research shows omega-6 supplements with combined LA and GLA resulted in decreased corneal inflammatory markers, an increase in tear meniscus height and improved symptomatology.<sup>18,19</sup>

Despite the growing body of literature, none of it shows conclusive findings regarding omega fatty acids and dry eye. Comparisons between trials are complicated by the fact that eligibility criteria, supplement content/dosage, placebo content and outcome measures all vary considerably.<sup>9</sup>

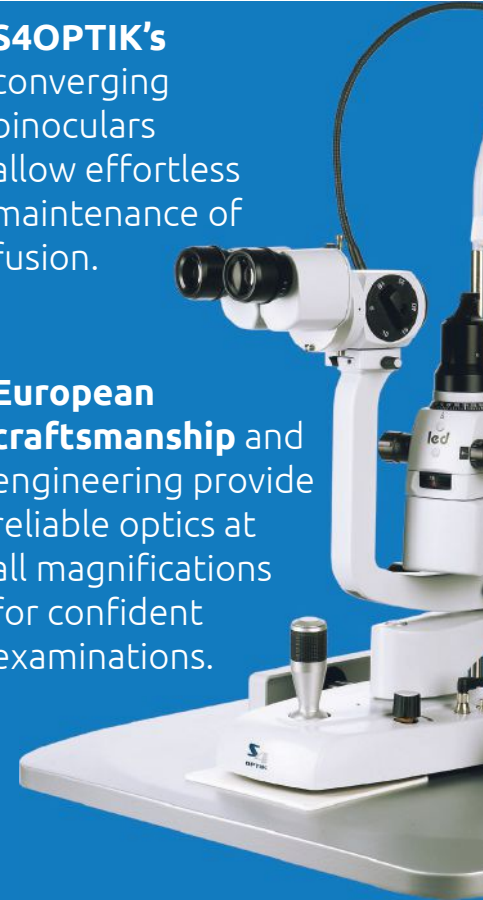Even the American Academy of Ophthalmology remains cautious in its support of omega fatty acid therapy in the treatment of dry eye due to lack of consensus. It's preferred practice patterns state that "education regarding potential dietary modifications (including oral essential fatty acid supplementation) should be included" within the initial treatment of dry eye and that "the use of essential fatty acid supplements for dry eye treatment has been reported to be potentially beneficial." However, it also notes the recent findings from the Dry Eye Assessment and Management (DREAM) study and its failure to support the benefit of oral fatty acids over placebo.<sup>2</sup>

### DREAM Raises Questions

In 2018, the DREAM study research group published findings from a randomized controlled trial conducted at 27 ophthalmologic and optometric clinical centers in the US. In the study, dry eye patients were assigned to either an active supplement containing 3,000mg fish-derived omega-3 EPA/DHA or a placebo of 1,000mg refined olive oil.<sup>9,35</sup> Patients were maintained on

S4OPTIK's converging binoculars allow effortless maintenance of fusion.

European craftsmanship and engineering provide reliable optics at all magnifications for confident examinations.



H-Series

Z-Series



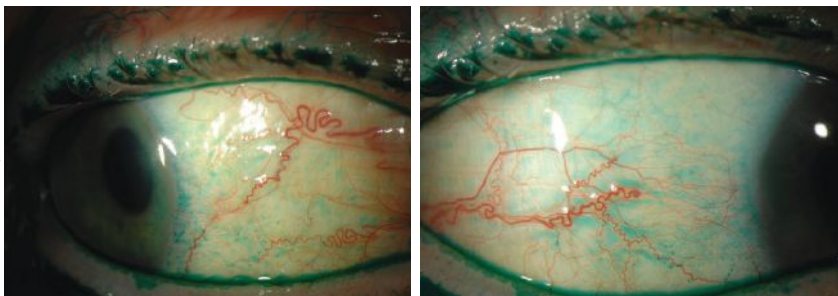
Vertical and compact configurations available.

their assigned supplement for 12 months and their ocular health and symptoms were monitored. The primary outcome was the mean change from baseline in the ocular surface disease index (OSDI) score with secondary outcomes of corneal signs. It is frequently touted as one of the most ‘real-world’ omega supplement studies to date in that patients with inflammatory conditions such as rheumatoid arthritis and Sjögren’s were included and patients could continue certain dry eye treatments.<sup>9</sup>

At the end of 12 months, both DREAM study groups experienced a clinically significant decrease in their OSDI scores compared with baseline, and there was no significant difference between the two groups in signs of DED. The fact that the change in OSDI scores did not differ significantly between the active and placebo supplement groups confounded many in the dry eye world.<sup>9</sup>

Researchers have proposed multiple explanations as to why the DREAM study did not show the benefit of omega-3 over placebo in the treatment of dry eye, including the potential anti-inflammatory effects from the refined olive oil placebo.<sup>35</sup> The lack of GLA in the active supplement could also play a part in the similar efficacy results between the experimental and placebo groups.<sup>17</sup> Finally, the real-world nature of the study is potentially a complicating factor because many patients were already using treatments such as artificial tears and lower dosage omega fatty acid supplements.<sup>35</sup>

Photos: Michelle Hassen, OD



Lissamine green staining on the conjunctiva reveals signs of dry eye.

## Strike a Better Balance

The consumption of omega-6 fatty acids is at an all-time high, and nutritionists are recommending not only an increase in dietary omega-3 but also a decrease in omega-6 intake to more efficiently balance the ratio. The Academy of Nutrition and Dietetics suggests consuming at least 500mg of EPA/DHA per day (200mg more per day for pregnant or lactating females) and the American Heart Association recommends 1,000mg per day for those with coronary heart disease.<sup>36</sup>

**Dietary intake.** The most effective way to increase omega-3 through diet is by consuming non-fried cold-water fatty fish such as salmon, mackerel, tuna or sardines two to four times per week. Marine sources that contain EPA and DHA are preferred over flax, hemp and chia due to the limited conversion of ALA in the human body. Choosing grass-fed over grain-fed meat sources will also increase omega-3 intake.<sup>12,36</sup> Numerous brands of eggs, yogurt, juices and milk are fortified with omega-3 and notably, infant formulas have been fortified with DHA since 2002.<sup>12</sup>

Minimal omega-6 is required for normal metabolic function, and necessary amounts are easily obtained by regular consumption of healthful sources such as olive oil, avocados and nuts (including nut butters). Efforts should be focused on decreasing unhealthy

sources, primarily vegetable oils. Avoiding corn, soybean, peanut and sunflower oils and instead opting for olive oil, coconut oil or butter when cooking is beneficial. Finally, nutritionists recommend limiting the use of products that contain high amounts of vegetable oils and omega-6 such as salad dressing, mayonnaise and margarine.<sup>37</sup> The Institute of Medicine recommends that calories from omega-6 fats should comprise 5% to 10% of your daily caloric intake.

**Supplementation.** Nutritional supplements are certainly beneficial in increasing consumption of essential fatty acids, and myriad options are available to patients. However, dosages and fatty acid sources vary significantly between products, and there is currently no FDA-approved formulation.<sup>31,38</sup>

Algal oil supplements are an excellent source of omega-3 for vegetarians who do not consume fish products and prefer to avoid marine sourced supplements.<sup>37</sup>

Without a clear consensus on the use of omega fatty acids in the management of dry eye, finding the right management path can seem daunting. Eye care providers can begin by discussing diet and nutrition with all of their patients, particularly those suffering from dry eye. Provide information on the recommended daily intakes of omega-3 as well as the dietary

choices patients can make to increase omega-3 and decrease omega-6 to skew the ratio in a more healthful direction. The impact of omega-3 and a balanced



omega-3/omega-6 ratio on systemic inflammatory and chronic conditions is well supported by validated research, and the benefit of making better nutritional choices is clear.

Inflammation plays a prominent role in DED, and it is rational to continue exploring the use of omega fatty acids in its management. But more controlled large-scale studies with standardized outcomes are necessary to clarify exactly what role essential fatty acids and the omega-6/omega-3 ratio play in the treatment and prevention of dry eye. We as practitioners must stay apprised to ensure we are practicing good evidence-based medicine for our patients. ■

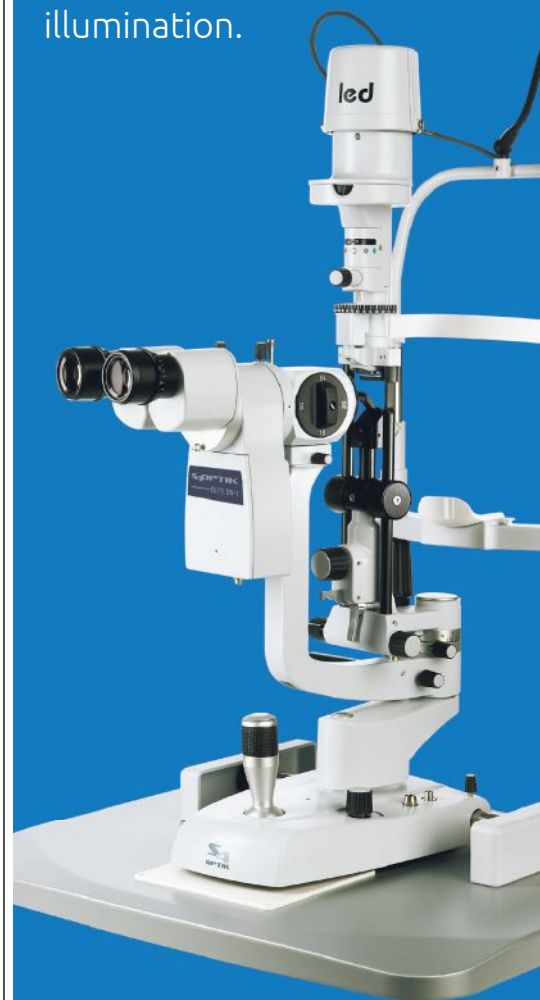*Dr. Sanford is an attending optometrist at the Memphis VA Medical Center.*

1. Simopoulos AP. The importance of the ratio of omega-6/omega-3 essential fatty acids. *Biomed Pharmacother.* 2002;56:365-79.
2. American Academy of Ophthalmology Cornea/External Disease Panel. Preferred practice pattern guidelines: dry eye syndrome. *Academy of Ophthalmology.* November 2018.
3. Paulsen AJ, Cruickshanks KJ, Fisher ME. Dry eye in the beaver dam offspring study: prevalence, risk factors, and health-related quality of life. *Am J Ophthalmol.* 2014;157(4):799-806.
4. Galor A, Feuer W, Lee D. Prevalence and risk factors of dry eye syndrome in a United States Veterans Affairs population. *Am J Ophthalmol.* 2011;152: 377-84.
5. Craig TP, Nichols KK, Akpek EK. TFOS DEWS II definition and classification report. *Ocular Surf.* 2017;15(3):276-83.
6. Stapleton F, Alves M, Bunya VY. TFOS DEWS II epidemiology report. *Ocular Surf.* 2017;15(3):334-65.
7. Wei Y, Asbell P. The core mechanism of dry eye disease (DED) is inflammation. *Eye Contact Lens.* 2014;40(4):248-56.
8. Yu J, Asche CV, Fairchild CJ. The economic burden of dry eye disease in the United States: a decision tree analysis. *Cornea.* 2011;30(4):379-87.
9. Asbell PA, Maguire MG, Pistilli M. n-3 Fatty acid supplementation for the treatment of dry eye disease. *New Eng J Med.* 2018;378:1681-90.
10. Kangari H, Eftekhari MH, Sardari S. Short-term consumption of oral omega-3 and dry eye syndrome. *Ophthalmology.* 2013;120(11):2191-96.
11. Daley CA, Abbott A, Doyle PS. A review of fatty acid profiles and antioxidant content in grass-fed and grain-fed beef. *Nutrition J.* 2010;9:10.
12. National Institutes of Health. Omega-3 fatty acids fact sheet for healthy professionals. <https://ods.od.nih.gov/factsheets/Omega3FattyAcids-HealthProfessional>. October 17, 2019. Accessed march 24, 2020.
13. Chee KM, Gong JX, Rees DM. Fatty acid content of marine oil capsules. *Lipids.* 1990;25(9):523-28.
14. Giannaccare G, Pellegrini M, Sebastiani S. Efficacy of omega-3 fatty acid supplementation for treatment of dry eye disease: a meta-analysis of randomized clinical trials. *Cornea.* 2019;38(5): 565-73.
15. Hom MM, Asbell P, Barry B. Omegas and dry eye: more knowledge, more questions. *Optom Vis Sci.* 2015;92:948-56.
16. Blasblag TL, Hibbeln JR, Ramsden CE. Changes in consumption of omega-3 and omega-6 fatty acids in the United States during the 20th century. *Am J Clin Nutr.* 2011;93:950-62.
17. Silva JR, Burger B, Kuhl CM, Candreva T. Wound healing and omega-6 fatty acids: from inflammation to repair. *Mediators Inflamm.* 2018;2503950. [Epub].
18. Kokke KH, Morris JA, Lawrenson JG. Oral omega-6 essential fatty acid treatment in contact lens associated dry eye. *Cont Lens Ant Eye.* 2008;31:141-46.
19. Sheppard JD, Singh R, McClellan AJ. Long term supplementation with n-6 and n-3 pufas improves moderate to severe keratoconjunctivitis sicca: a randomized double blind clinical trial. *Cornea.* 2013;32(10):1297-1304.
20. Vasquez A. Reducing pain and inflammation naturally. Part II: new insights into fatty acid supplementation and its effect on eicosanoid production and genetic expression. *Nutritional Perspectives: J Counc Nutr Am Chiro Assoc.* 2005;28(1):5-16.
21. Brignole-Baudouin F, Faudouin C, Aragona P. A multicentre, double-masked, randomized, controlled trial assessing the effect of oral supplementation of omega-3 and omega-6 fatty acids on a conjunctival inflammatory marker in dry eye patients. *Acta ophthalmol.* 2011;89:591-97.
22. Calder P. n-3 polyunsaturated fatty acids, inflammation, and inflammatory diseases. *Am J Clin Nutrition.* 2006;83(6):1505-19.
23. DiNicolantonio JJ, O'Keefe JH. Importance of maintaining a low omega-6/omega-3 ratio for reducing inflammation. *Open Heart.* 2018;e000946.
24. Mijlanovic B, Trivedi KA, Dana MR. Relation between dietary n-3 and n-6 fatty acids and clinically diagnosed dry eye syndrome in women. *Am J Clin Nutr.* 2005;82:887-93.
25. Simopoulos AP. Evolutionary aspects of diet, the omega-6/omega-3 ratio and genetic variation: nutritional implication for chronic diseases. *Biomed Pharmacother.* 2006;60:502-07.
26. Russo GL. Dietary n-6 and n-3 polyunsaturated fatty acids: From biochemistry to clinical implications in cardiovascular prevention. *Biochem Pharmacol.* 2009;77:937-46.
27. Liu Y, Kam WR, Sullivan DA. Influence of omega 3 and 6 fatty acids on human meibomian gland epithelial cells. *Cornea.* 2016; 35(8):1122-26.
28. Li K, Huang T, Zheng J. Effect of marine derived n-3 polyunsaturated fatty acids on C-reactive protein, interleukin 6 and tumor necrosis factor alpha: a meta-analysis. *PLoS One* 2014; 9:e88103.
29. Simopoulos AP. Omega 3 fatty acids in health and disease and in growth and development. *Am J Clin Nutr.* 1991;54:438-63.
30. Wojtowicz JC, Butovich I, Uchiyama E. Pilot, prospective, randomized, double masked, placebo controlled clinical trial of an omega-3 supplement for dry eye. *Cornea.* 2011;30(3):308-14.
31. Bhargava R, Kumar P. Oral omega-3 fatty acid treatment for dry eye in contact lens wearers. *Cornea.* 2015;34(4):413-20.
32. Bhargava R, Kumar P, Kumar M. A randomized controlled trial of omega-3 fatty acids in dry eye syndrome. *Int J Ophthalmol.* 2013;6(6):811-16.
33. Deinema LA, Vingrys AJ, Wong CY. A randomized, double masked, placebo-controlled clinical trial of two forms of omega-3 supplements for treating dry eye disease. *Ophthalmology.* 2017;124:43-52.
34. Epiropoulos AT, Donnenfeld ED, Shah ZA. Effect of oral re-esterified omega-3 nutritional supplementation on dry eyes. *Cornea.* 2016;35(9):1185-91.
35. Asbell PA, Maguire MG. Why DREAM should make you think twice about recommending omega-3 supplements. *Ocular Surf.* 2019;17:617-18.
36. Vannice G, Rasmussen H. Position of the academy of nutrition and dietetics: dietary fatty acids for healthy adults. *J Acad Nutr Diet.* 2014;114(1):136-53.
37. Jacobs A. Balancing Act. *Today's Dietitian.* 2013;15(4):38.
38. Rand AL, Asbell PA. Current opinion in ophthalmology nutritional supplements for dry eye syndrome. *Curr Opin Ophthalmol.* 2011;22(4):279-82.
39. Vasquez A. Reducing pain and inflammation naturally. part 1: new insights into fatty acid biochemistry and the influence of diet. *Nutritional Perspectives.* 2004;Oct:5,7-10,12,14.

# S4 OPTIK SLIT LAMPS

## NEW LED Illumination

More than 50,000  
hours of clear, cool  
illumination.



Easier observation of  
minute details.

Color temperature  
maintained through the full  
range of illumination  
adjustment.

# S4 OPTIK

250 Cooper Ave., Suite 100 Tonawanda NY 14150

[www.s4optik.com](http://www.s4optik.com) | 888-224-6012

Sensible equipment. Well made, well priced.

For today's modern office.

21st Annual Dry Eye Report

# Don't Overlook Aqueous-deficient Dry Eye

Familiarize yourself with this subset so that you're better able to detect and manage it if it does present. **By Candice Tolud, OD**

In recent years, diagnosis, management and treatment of dry eye disease (DED) have expanded greatly. Our understanding of what makes an eye “dry” has grown from simply stating that a patient has *dry eye* to understanding the many factors that can contribute to its etiology.

While emerging treatments largely focus on evaporative dry eye (EDE), aqueous deficiency can exist independently or even concurrently in patients who have meibomian gland dysfunction (MGD). Make sure you don't overlook this uncommon but impactful condition while evaluating a patient for dry eye. The following article reviews aqueous-deficient dry eye (ADDE) and corresponding diagnostic and management options.

## Dry Eye Subsets

The Tear Film and Ocular Surface Society (TFOS) defines DED as “a multifactorial disease of the ocular surface characterized by a loss of homeostasis of the tear film and accompanied by ocular symptoms, in which tear film instability and hyperosmolarity, ocular surface inflammation and damage and neurosensory abnormalities play etiological roles.”<sup>1</sup>

The two predominant etiologies, ADDE and EDE, can present as single and separate processes or may overlap with each other. The signs and symptoms of both affect the entire ocular surface, including the tear film, cornea, conjunctiva, eyelids and lacrimal and meibomian glands.<sup>2</sup>

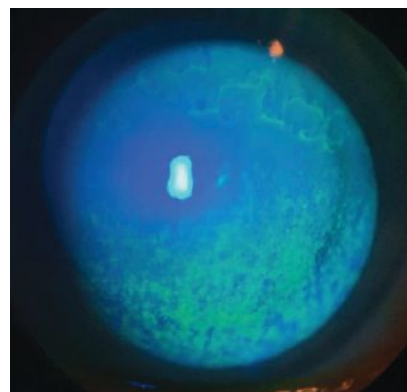
EDE is caused by MGD, and ADDE results from reduced aqueous secretion. EDE, and cases of DED that involve EDE and ADDE, accounts for over 80% of all dry eye cases. Only about 10% of DED is classified as strictly ADDE.<sup>3</sup>

## Aqueous Deficiency

ADDE can be divided into Sjögren's syndrome (SS) and non-SS.<sup>4</sup>

**Sjögren's.** This chronic autoimmune disorder is characterized by immune cell infiltration of the exocrine glands and systemic complications due to autoantibody production.<sup>4</sup> SS predominantly affects women and may be due to an abnormal immune response to environmental or viral triggers in susceptible patients.<sup>4</sup> It mainly targets the lacrimal and salivary glands and can cause gland destruction and signs and symptoms of dry eye and mouth.<sup>4</sup>

Serological testing for SS is geared toward detecting the presence of



**Patients with punctate corneal staining—a common finding in ADDE—can be asymptomatic or have severe pain and decreased vision.**

autoantibodies, specifically anti-SSA and anti-SSB. Earlier stages of SS can be detected through biomarkers for anti-salivary protein-1, anti-carbonic anhydrase and parotid-specific protein.<sup>5,6</sup> You can order these tests, along with other rheumatologic markers, such as anti-nuclear antibodies, rheumatoid factor, erythrocyte sedimentation rate and c-reactive protein.<sup>5</sup> The gold standard for SS diagnosis has long been salivary gland biopsy, but ultrasound imaging is emerging as a potential technique for earlier detection.<sup>5-7</sup>

**Non-Sjögren's.** ADDE without systemic autoimmune features of SS

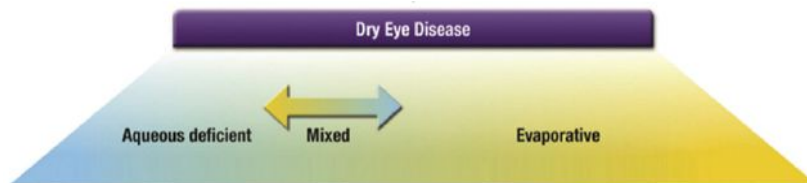could involve congenital or acquired forms of DED.<sup>7</sup> Causes of non-SS dry eye include lacrimal gland ablation, congenital alacrima, triple A syndrome and ocular surface aging. Systemic conditions, such as sarcoidosis and lymphoma, and viral infections, such as hepatitis C and HIV/AIDS, are also potential causes.<sup>7</sup> Direct damage to the lacrimal gland due to radiation therapy of the head/neck, chemical injury or cicatricial changes resulting from graft-vs.-host disease, Stevens-Johnson syndrome, trachoma or ocular pemphigoid may lead to ADDE.<sup>7</sup> Another contributing factor includes decreased corneal sensation, which can be triggered pharmacologically, after refractive surgery or secondary to disease.<sup>7</sup>

Signs and symptoms are similar in non-SS and SS.<sup>4</sup> However, the onset of dry eye is later in non-SS patients. Non-SS patients also tend to be older and have less severe disease with a smaller risk of blindness.<sup>4</sup>

### General Testing

DED testing is the same for all cases. There are three key diagnostic tests the DEWS II recommends in symptomatic patients who have screened positive on patient questionnaires, such as the Dry Eye Questionnaire 5 (score >6) or the Ocular Surface Disease Index (score >13) (OSDI).

**Tear breakup time.** Noninvasive tear breakup time (TBUT) is always recommended over traditional fluorescein TBUT to minimize the dye's impact on tear film stability. However, if fluorescein is used, the test strip should be dry and applied to the outer canthus to decrease any irritation of the ocular surface, and measurements should be taken one to three minutes after instillation.<sup>8</sup> Noninvasive TBUT is measurable with a corneal topographer.<sup>8</sup> A positive test result is a TBUT of less than 10 seconds after the patient blinks.



**DED is on a continuum of pathophysiology and is not a dichotomous disease.**

**Tear hyperosmolarity.** Out of all the available clinical tests, this marker has the highest correlation to DED severity. The DEWS II states that tear osmolarity is the single best metric to diagnose and classify DED.<sup>8</sup> A positive result is any reading greater than 308mOsm/L or a difference of more than eight between eyes. Although the pathophysiology of patients with EDE or ADDE differs, the tear osmolarity and distribution do not.<sup>9</sup>

**Ocular surface staining.** Conjunctival and lid margin damage is best viewed with lissamine green staining, and corneal damage is more visible with fluorescein dye.<sup>8</sup> Rose bengal concentrates on corneal and conjunctival cells that lack mucin and can identify damaged epithelial cells.<sup>9</sup> Staining in either eye confirms a positive result that commonly indicates late-stage DED. Ocular surface staining is defined as more than five corneal or nine conjunctival spots or lid margin staining (lid wiper epitheliopathy) greater than 2mm in length.

While DEWS II suggestions for initial DED testing do not include tear volume, this parameter plays an important role in assessing ocular surface health and homeostasis, particularly in patients with aqueous deficiency.<sup>8</sup> Decreased tear volume may be a key pathogenic mechanism and diagnostic sign of ADDE patients who suffer independently from EDE.<sup>8</sup>

Tear volume can be indirectly evaluated noninvasively via tear meniscus assessment, which can help with DED subclassification.<sup>8</sup> The meniscus is best viewed in the center

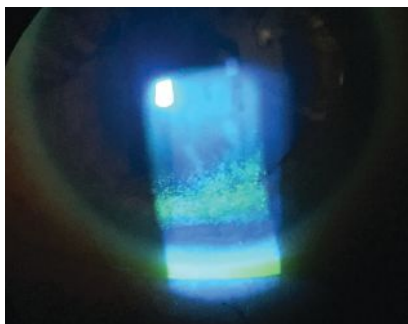
of the lower eyelid shortly after a blink. The simplest way to grade it is to conduct meniscometry at the slit lamp by judging the meniscus height in comparison with the slit lamp beam height, but this method has poor inter-visit repeatability.<sup>8</sup> Digital measurement techniques are emerging and exhibit better reproducibility but are not mainstay at this time.<sup>8</sup>

Perform Schirmer's testing by inserting the paper strip at the temporal one-third of the lower lid margin and measuring the length of wetting after five minutes either with or without anesthesia. A Schirmer's test result >10mm is normal, between 5mm and 10mm is borderline and <5mm is indicative of aqueous deficiency.<sup>8</sup> Conducting the test without an anesthetic is best to confirm severe ADDE, but its variability and invasiveness precludes its use as a routine diagnostic test of tear volume, especially in cases with concurrent EDE where tear quality rather than quantity is predominantly affected.<sup>8</sup> Under these circumstances, testing can stimulate a reflex tearing response on insertion of the testing strip and mask results.<sup>8</sup>

### Treatment Options

Historically, ADDE was treated by prescribing tear replacement products or by conserving tears via punctal plugs.<sup>10</sup> While these methods still play a key role in treating ADDE, recent treatments focus on better stimulating tear production.<sup>10</sup>

Managing dry eye often requires several simultaneous methods of care. Following a patient's signs and



**This patient has extensive punctate epithelial keratitis and decreased TBUT.**

symptoms to gauge the efficacy of their current treatment regimen is key when deciding whether additional therapy is necessary.

**Artificial tears.** These over-the-counter products do not address the pathophysiology of DED but can offer temporary relief.<sup>10</sup> Products vary in osmolarity, viscosity and pH. Higher viscosity agents, such as carboxymethyl cellulose, hyaluronic acid, HP-guar, polyvinyl alcohol and propylene glycol, are typically reserved for overnight use. Viscosity enhancers are beneficial to the ocular surface, as they increase tear film thickness, shield against desiccation, promote tear retention at the ocular surface, protect the ocular surface, maintain physiological corneal thickness, improve goblet cell density and relieve dry eye symptoms. Osmoprotectants, such as trehalose—which can be found in TheraTears Extra (Akorn) and Refresh Optive Mega-3 (Alcon)—can protect corneal cells from desiccation and high osmolarity by fortifying cell membranes.<sup>11,12</sup>

**Topical pharmaceutical agents.** Cyclosporine A is an immunomodulatory drug with anti-inflammatory properties that inhibits the IL-2 activation of lymphocytes.<sup>10</sup> Topical cyclosporine was approved by the FDA for moderate to severe DED and can improve inflammation, tear osmolarity, conjunctival goblet cell density and tear production.<sup>10</sup> It is

available in three preservative-free forms: Restasis (cyclosporine A 0.05%, Allergan), Cequa (cyclosporine A 0.9%, Sun Pharmaceuticals) and Klarity-C (cyclosporine A 0.1%, Imprimis Rx).

Xiidra (lifitegrast, Novartis) is a small-molecule integrin antagonist that binds to cell surface proteins found on leukocytes and blocks the integrin lymphocyte function-associated antigen-1 and cognate ligand intercellular adhesion molecule-1 interactions.<sup>13</sup> *In vitro* studies have shown that Xiidra may inhibit the recruitment of previously activated T-cells, the activation of newly recruited T-cells and the release of pro-inflammatory cytokines, interrupting the perpetual cycle of inflammation that promotes DED.<sup>13</sup>

Often, low-dose topical steroids, such as Lotemax SM (loteprednol etabonate ophthalmic gel 0.38% and 0.5%, Bausch + Lomb), are used as a pretreatment or concomitantly with cyclosporine or lifitegrast earlier on and tapered off after a few weeks. Preservative-free steroids, such as dexamethasone 0.01%—which is currently unavailable in the US—can improve symptoms of chronic ocular surface irritation that were previously unresponsive to preserved topical steroids, such as loteprednol 0.2%, fluorometholone 0.1% and prednisolone 1%.<sup>10</sup>

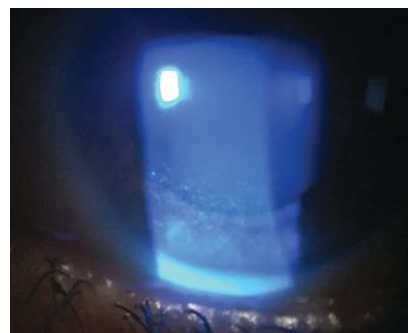
**Biological tear substitutes.** In more advanced cases of DED where topical pharmaceutical agents do not provide adequate relief of severe ocular surface disease, as is the case with many ADDE patients, autologous serum is an effective option. It is derived from the biomarkers in a patient's own blood and contains many biochemical characteristics similar to that of human tears, such as pH level, nutrients, vitamins, albumin, fibronectin and epithelial and nerve growth factors.<sup>10</sup> Autologous

serum, and other blood-derived tear substitutes, can promote corneal epithelial wound healing, inhibit the release of inflammatory cytokines, increase the number of goblet cells and encourage mucin expression.<sup>10</sup>

Specialized compounding pharmacies formulate autologous serum, the concentration of which depends on symptom severity, after the patient's blood is drawn and screened for HIV, hepatitis and other conditions.<sup>10</sup>

Typically kept frozen for up to nine months at -20°C, a defrosted vial is good for about 24 hours after it thaws, as it is non-preserved.<sup>10</sup> A study found that treatment with autologous serum can improve patient symptoms in as soon as 10 days in 60% of patients and two months in 79%.<sup>10</sup> While patient symptoms, TBUT and corneal staining improved, Schirmer's scores remained the same, and ocular surface disease recurred after discontinuation of treatment.<sup>10</sup>

**Punctal occlusion.** ADDE patients benefit from aqueous retention on the ocular surface, and, as such, temporary or permanent punctal occlusion of one or both puncta at the level of the punctal opening or deeper can be an appropriate treatment.<sup>10</sup> Commonly, punctal occlusion is performed via punctal plugs. Absorbable, collagen-based plugs



**The patient improved after four months of treatment with topical lubrications, a tapered course of topical steroids and lifitegrast twice daily.**

# IN THE RACE AGAINST GLAUCOMA, **DURABILITY WINS**

Glaucoma demands outcomes that endure. Results from the largest MIGS pivotal trial to date have shown that the Hydrus<sup>®</sup> Microstent delivers the greatest improvement compared to cataract surgery alone for IOP reduction and medication elimination at 24 months.<sup>1-4,\*</sup>

And now, at 3 years the Hydrus Microstent is the only MIGS device with results from a pivotal trial showing a statistically significant reduction in risk of invasive secondary glaucoma surgeries.<sup>†</sup>

When durability matters, choose the MIGS option that endures—Hydrus Microstent.

**Delivering a new confidence.**



©2020 Ivantis, Inc.  
Ivantis and Hydrus are  
registered trademarks  
of Ivantis, Inc.  
All rights reserved.  
IM-0008 Rev C





**HYDRUS<sup>®</sup>**  
MICROSTENT  
Delivering A New Confidence

**CAUTION: Federal law restricts this device to sale by or on the order of a physician.**  
**INDICATIONS FOR USE:** The Hydrus Microstent is indicated for use in conjunction with cataract surgery for the reduction of intraocular pressure (IOP) in adult patients with mild to moderate primary open-angle glaucoma (POAG).  
**CONTRAINDICATIONS:** The Hydrus Microstent is contraindicated under the following circumstances or conditions: (1) In eyes with angle closure glaucoma; and (2) In eyes with traumatic, malignant, uveitic, or neovascular glaucoma or discernible congenital anomalies of the anterior chamber (AC) angle. **WARNINGS:** Clear media for adequate visualization is required. Conditions such as corneal haze, corneal opacity or other conditions may inhibit gonioscopic view of the intended implant location. Gonioscopy should be performed prior to surgery to exclude congenital anomalies of the angle, peripheral anterior synechiae (PAS), angle closure, rubeosis and any other angle abnormalities that could lead to improper placement of the stent and pose a hazard. **PRECAUTIONS:** The surgeon should monitor the patient postoperatively for proper maintenance of intraocular pressure. The safety and effectiveness of the Hydrus Microstent has not been established as an alternative to the primary treatment of glaucoma with medications, in patients 21 years or younger, eyes with significant prior trauma, or eyes with abnormal anterior segment, eyes with chronic inflammation, eyes with glaucoma associated with vascular disorders, eyes with preexisting pseudophakia, eyes with uveitic glaucoma, eyes with pseudoexfoliative or pigmentary glaucoma, eyes with other secondary open angle glaucoma, eyes that have undergone prior incisional glaucoma surgery or cilioabative procedures, eyes that have undergone argon laser trabeculoplasty (ALT), eyes with unmedicated IOP < 22 mm Hg or > 34 mm Hg, eyes with medicated IOP > 31 mm Hg, eyes requiring > 4 ocular hypotensive medications prior to surgery, in the setting of complicated cataract surgery with iatrogenic injury to the anterior or posterior segment and when implantation is without concomitant cataract surgery with IOL implantation. The safety and effectiveness of use of more than a single Hydrus Microstent has not been established. **ADVERSE EVENTS:** Common post-operative adverse events reported in the randomized pivotal trial included partial or complete device obstruction (7.3%); worsening in visual field MD by > 2.5 dB compared with preoperative (4.3% vs 5.3% for cataract surgery alone); device malposition (1.4%); and BCVA loss of ≥ 2 ETDRS lines ≥ 3 months (1.4% vs 1.6% for cataract surgery alone). For additional adverse event information, please refer to the Instructions for Use. **MRI INFORMATION:** The Hydrus Microstent is MR-Conditional meaning that the device is safe for use in a specified MR environment under specified conditions. **Please see the Instructions for Use for complete product information.**

**References:** 1. Samuelson TW, Chang DF, Marquis R, et al: HORIZON Investigators. A Schlemm canal microstent for intraocular pressure reduction in primary open-angle glaucoma and cataract. *The HORIZON Study. Ophthalmology.* 2019;126:29-37. 2. Vold S, Ahmed II, Craven ER, et al: CyPass Study Group. Two-Year COMPASS Trial Results: Supraciliary Microstenting with Phacolytic Classification in Patients with Open-Angle Glaucoma and Cataracts. *Ophthalmology.* 2016;123(10):2103-2112. 3. US Food and Drug Administration. Summary of Safety and Effectiveness Data (SSED): Glaukos iStent<sup>®</sup> Trabecular Micro-Bypass Stent. US Food and Drug Administration website. [https://www.accessdata.fda.gov/cdrh\\_docs/pdf8/PO80030B.pdf](https://www.accessdata.fda.gov/cdrh_docs/pdf8/PO80030B.pdf). Published June 25, 2012. 4. US Food and Drug Administration. Summary of Safety and Effectiveness Data (SSED): iStent inject Trabecular Micro-Bypass System. US Food and Drug Administration website. [https://www.accessdata.fda.gov/cdrh\\_docs/pdf17/P170043b.pdf](https://www.accessdata.fda.gov/cdrh_docs/pdf17/P170043b.pdf). Published June 21, 2018.

\*Comparison based on results from individual pivotal trials and not head to head comparative studies.

†Data on file - includes trabeculectomy and tube shunt.



©2020 Ivantis, Inc. Ivantis and Hydrus are registered trademarks of Ivantis, Inc. All rights reserved. IM-008 Rev D

## Dry Eye

### Diagnostic Criteria of SS

These American-European Consensus Classification Criteria for SS were published in 2002:<sup>14</sup>

1. Ocular symptoms (at least one of the following): dry eye symptoms for more than three months, artificial tear use more than three times a day, foreign body sensation
2. Ocular signs (at least one of the following): abnormal Schirmer's test results (<5mm of wetting in five minutes without anesthesia), positive vital dye staining (>4)
3. Oral symptoms (at least one of the following): dry mouth symptoms for more than three months, liquid use for comfort while swallowing, recurrent swollen salivary glands
4. Oral signs (at least one of the following): abnormal salivary scintigraphy, abnormal parotid sialography, unstimulated whole salivary flow (≤1.5mL in 15 minutes)
5. Positive autoantibodies: anti-SSA or anti-SSB

In 2012, the American College of Rheumatology proposed simplified diagnostic criteria:<sup>15</sup>

1. Positive autoantibodies (anti-SSA or anti-SSB) or positive RF and ANA titer >1:320
2. Labial salivary gland biopsy exhibiting focal lymphocytic sialadenitis with a focus score of one per 4mm<sup>2</sup>
3. Keratoconjunctivitis sicca with an ocular staining score >3 (assuming the patient is not currently using daily drops for glaucoma and has not had corneal or cosmetic surgery in the last five years)

Any patient suspected of having SS should be referred to rheumatology for further systemic evaluation and treatment.

with absorption rates that vary from one week to six months are the most commonly used. Non-absorbable, or “permanent,” plugs are typically silicone-based. For advanced cases, permanent surgical closure of the puncta via total or partial thermal cauterization, occlusion with a conjunctival flap, punctal suturing or total destruction of the canaliculus can be performed.

Punctal occlusion is most successful when combined with other DED treatments.<sup>10</sup> Occluding the puncta in the presence of ocular surface inflammation is controversial, as there is a concern that occlusion of tear outflow can prolong the presence of pro-inflammatory cytokines on the ocular surface. As such, treating surface inflammation is recommended prior to occlusion.

**Moisture chamber glasses.** These are specially designed to slow tear evaporation by providing a humid environment and minimizing airflow over the ocular surface.<sup>10</sup> They are a potential adjunct to prescribed treatment for increased symptom relief.<sup>10</sup>

**Topical aqueous secretagogues.** Diquas (diquafosol tetrasodium 3% ophthalmic solution, Santen) is a

purinergic P2Y<sub>2</sub> receptor agonist that stimulates water and mucin secretion from conjunctival epithelial and goblet cells and improves tear film stability.<sup>10</sup> It is only approved overseas as of now. Studies have shown topical diquafosol significantly improves corneal and conjunctival staining, TBUT and Schirmer's scores.<sup>10</sup> Topical lacritin, a glycoprotein that stimulates pro-secretory activity in the lacrimal gland, has therapeutic potential in treating ADDE in SS patients with reduced lacritin levels.<sup>10</sup>

**Oral secretagogues.** Oral pilocarpine and cevimeline, both cholinergic agonists, are commercially available to treat SS.<sup>10</sup> While Sjögren's patients who participated in a recent study noticed more improvement in oral vs. ocular dryness with the secretagogues, the drugs did improve ocular surface staining, goblet cell density and TBUT.<sup>10</sup> Cevimeline had a better side effect profile than pilocarpine.<sup>10</sup> However, there was no observed improvement in tear production with either medication.<sup>10</sup>

**Neurostimulation.** Intranasal tear neurostimulation induces normal tear production by stimulating the

nasolacrimal reflex.<sup>10</sup> The nasolacrimal reflex up-regulates tear production following chemical or mechanical stimulation of the nasal mucosa.<sup>10</sup> The TrueTear Intranasal Tear Neurostimulator (Allergan) temporarily increases tear production during neurostimulation in adults. This device consists of a handheld stimulator unit equipped with a disposable two-pronged hydrogel tip and an external charger.<sup>10</sup> It allows self-delivery of minute electrical currents with variable waveform to the anterior ethmoidal nerve, stimulating immediate natural tear production.<sup>10</sup> Preliminary testing shows increased Schirmer's scores and decreased patient symptoms.<sup>10</sup>

### Advanced Strategies

For more advanced or temperamental cases, there are a few options available at your disposal.

**Therapeutic contact lenses.** Bandage lenses can improve ocular comfort, maintain corneal integrity and prolong ocular surface moisturization by reducing the effects of an adverse environment.<sup>10</sup> The availability of silicone hydrogel lenses, along with their high oxygen permeability, has helped promote their use as a therapeutic device in the management of many ocular surface diseases, including DED.<sup>10</sup> Soft lenses are typically used on an extended wear basis. A recent study shows that, in Sjögren's patients, the use of silicone hydrogel lenses used as bandage contact lenses provided significant improvement in visual acuity for up to six weeks after discontinuing wear, OSDI scores, TBUT and corneal staining.<sup>10</sup>

Gas permeable scleral lenses are used in cases of moderate to severe DED and aim to provide a repository of tears and effective protection to the ocular surface.<sup>10</sup> A new solution called Nutrifill (Contamac) contains

essential ions found in tears. Unfortunately, once the neuropathic pain has centralized, a bandage lens may be insufficient for reducing symptoms.<sup>10</sup>

**Amniotic membrane grafts.** These can successfully treat severe DED with persistent epithelial defects or corneal ulceration and scarring. They consist of cryopreserved human amniotic membranes, which contain a wide variety of neuropeptides and neurotransmitters.<sup>10</sup> Grafts are inserted similarly to a scleral lens and typically dissolve in about one week. One study shows symptom improvement for four months in dry eye patients treated with a Prokera Slim (Bio-Tissue) for five days.<sup>10</sup>

**Surgical approaches.** In the most severe cases of DED, surgical intervention may be necessary. Options include tarsorrhaphy, mechanical dacryoreservoirs, gland transplantation and lacrimal gland regeneration.

Tarsorrhaphy is a temporary or permanent surgical procedure that partially or totally closes the eyelids to decrease ocular surface exposure and tear evaporation in cases where all other treatments have failed.<sup>10</sup>

In patients with ADDE and a Schirmer's score less than 2mm who have difficulty maintaining frequent topical lubrication or who have not found relief from less invasive measures, mechanical devices called dacryoreservoirs may be an option.<sup>10</sup> They deliver lubricating or pharmaceutical agents from a reservoir through a silicone catheter that continuously lubricate the ocular surface.<sup>10</sup> While they improve TBUT, corneal staining and conjunctival hyperemia, there is a risk of infection in the reservoir and device that may require its removal.<sup>10</sup>

Transplantation of functioning exocrine tissue from one of the three major salivary glands, typically the submandibular gland, offers lubrication in cases of severe ADDE.<sup>10</sup>

Lacrimal gland regeneration is an emerging treatment option that is exploring several strategies for stem cell expansion and differentiation into lacrimal tissue for organogenesis and engraftment techniques. This method is in its beginning phases.<sup>7</sup>

As our understanding of dry eye continues to expand, so do diagnostic and treatment options that allow us to better serve these patients. While so much of the focus remains on EDE, make sure you have a sufficient understanding of ADDE so you're better able to manage these cases in the chance they do present and work side-by-side with rheumatology for the best results.

*Dr. Tolud completed a residency in ocular disease and practices at Vantage Eye Care, South Jersey Eye Physicians Division, in Columbus, NJ. She also serves as president of the New Jersey chapter of the American Academy of Optometry. ■*

1. Craig JP, Nichols KK, Akpek EK, et al. TFOS DEWS II definition and classification report. *Ocul Surf.* 2017;15(3):276-83.
2. Craig JP, Nelson JD, Azar DT, et al. TFOS DEWS II report executive summary. *Ocul Surf.* 2017;15(4):802-12.
3. Messmer EM. The pathophysiology, diagnosis, and treatment of dry eye disease. *Dtsch Arztebl Int.* 2015;112(5):71-81.
4. Bron AJ, de Paiva CS, Chauhan SK, et al. TFOS DEWS II pathophysiology report. *Ocul Surf.* 2017;15(3):438-510.
5. Hauswirth S. Diagnosing and treating Sjögren's syndrome. *Optometry Times.* August 14, 2016. [Epub ahead of print].
6. Abd-Allah NM, Hassan AA, Omar G, et al. Evaluation of patients with dry eye for the presence of primary or secondary Sjögren's syndrome. *Clin Ophthalmol.* 2019;13:1787-97.
7. Liu CY, Hirayama M, Ali M, et al. Strategies for regenerating the lacrimal gland. *Curr Ophthalmol Rep.* 2017;5(3):193-8.
8. Wolfsfohn JS, Arita R, Chalmers R, et al. TFOS DEWS II diagnostic methodology report. *Ocul Surf.* 2017;15(3):539-74.
9. Beckman KA, Luchs J, Milner MS. Making the diagnosis of Sjögren's syndrome in patients with dry eye. *Clin Ophthalmol.* 2016;10:43-53.
10. Jones L, Downie LE, Korb D, et al. TFOS DEWS II management and therapy report. *Ocul Surf.* 2017;15(3):575-628.
11. McDonald MB, Fumuso PW. Trehalose: a novel treatment for dry eye. [www.healio.com/ophthalmology/cornea-external-disease/news/print/ocular-surgery-news/%7B6d1f0d15-4321-487b-8aa8-56648bdec2d2%7D/trehalose-a-novel-treatment-for-dry-eye?page=3](http://www.healio.com/ophthalmology/cornea-external-disease/news/print/ocular-surgery-news/%7B6d1f0d15-4321-487b-8aa8-56648bdec2d2%7D/trehalose-a-novel-treatment-for-dry-eye?page=3). July 10, 2018. Accessed April 20, 2020.
12. Horton M, Horton M, Reinhard E. Master the maze of artificial tears. *Rev Optom.* 2018;155 (11):48-56.
13. Karcecki P. Say hi to Xiidra. *Rev Optom.* August 15, 2016. [Epub ahead of print].
14. Vitali C, Bombardieri S, Jonsson R, et al. Classification criteria for Sjögren's syndrome: a revised version of the European criteria proposed by the American-European Consensus Group. *Ann Rheum Dis.* 2002;61(6):554-8.
15. Shiboski SC, Shiboski CH, Criswell L, et al. American College of Rheumatology classification criteria for Sjögren's syndrome: a data-driven, expert consensus approach in the Sjögren's International Collaborative Clinical Alliance cohort. *Arthritis Care Res (Hoboken).* 2012;64(4):475-87.

# Statins and the Eye:

## What You Might Not Know

These lipid-altering drugs are changing lives for the better, but the optometrist is responsible for monitoring their many impacts—good and bad—on ocular health.

By Carrie Ho, OD, Angella Gentry, OD, and Richard Zimbalist, OD

**S**tatins are a class of lipid-altering drugs that revolutionized hypercholesterolemia treatment and aid in primary and secondary cardiovascular disease (CVD) prevention. An estimated 38.6 million Americans were on a statin regimen in 2011 and 2012, a nearly 38% increase from 24 million in 2003 and 2004.<sup>1</sup> This rise in use makes statins the most commonly prescribed class of cholesterol-lowering drug. Due to this widespread use, it's vital optometrists understand the possible effects they can have on patients' eyes.

Although many studies into statins and ocular conditions show conflicting results or are of statistical insignificance, some results suggest statins could potentially mitigate various ocular conditions.

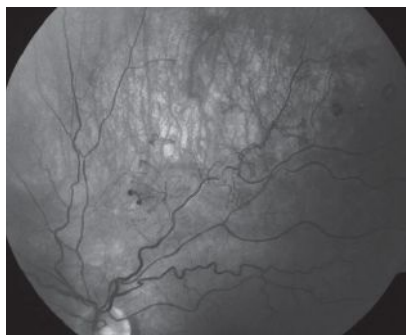
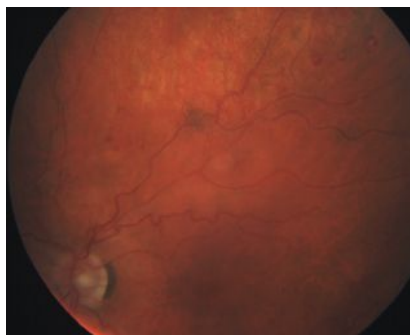
Here, we explain how statins affect different patients' eyes—for better or for worse, and how the OD can oversee these patients and their ocular and visual health.

### Mechanism of Action

Statins are a potent drug for lowering low-density lipoprotein (LDL) cholesterol in the treatment of

hypercholesterolemia and mixed hyperlipidemia. Through inhibition and regression of coronary atherosclerosis, anti-inflammatory properties and atherosclerotic plaque stabilization, statins decrease rates of CVD and mortality.<sup>1</sup>

Available statins include lovastatin, pravastatin, simvastatin, fluvastatin, atorvastatin, rosuvastatin and pitavastatin.<sup>2,3</sup> Statins' beneficial effects result from their capacity to reduce cholesterol biosynthesis and modulate lipid metabolism from inhibition upon 3-hydroxy-3-methylglutaryl-coenzyme A (HMG-CoA) reductase in the liver. HMG-CoA reductase is the enzyme that converts HMG-CoA into mevalonic acid, a cholesterol precursor.<sup>3</sup> Statins are HMG-CoA inhibitors that alter the conformation of the enzyme when they bind to its active site, preventing HMG-CoA reductase from attaining a functional structure. The reduction of cholesterol in hepatocytes leads to the increase of hepatic LDL receptors, ultimately



**This 61-year-old patient's left eye has an ischemic branch retinal vein occlusion with evidence of frank neovascular edema.**



reducing circulating LDLs and its precursors.

Statins also impart a modest benefit in concentrations of triglycerides, high-density lipoproteins (HDL) and very low-density lipoproteins (VLDL).<sup>2</sup> Moreover, statins exert pleiotropic effects such as improvement of endothelial function, enhancing the stability of atherosclerotic plaques, decreasing oxidative stress and inflammation, and inhibiting thrombogenic response.<sup>4</sup>

### Adverse Effects

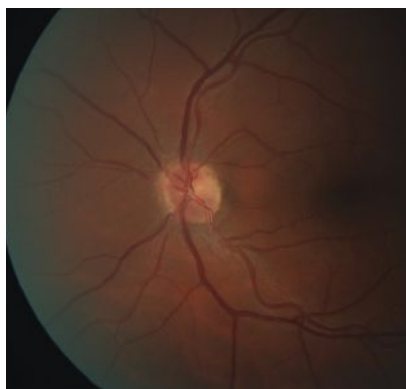
Statins are generally well tolerated, and adverse reactions occur less frequently than with other classes of lipid-lowering agents.<sup>2,3</sup> Liver and muscle toxicity are the most notable adverse effects of statins.<sup>2,3</sup> Although studies have reported conflicting results, statins could have effects on glucose metabolism in non-diabetic patients or affect glycemic control of diabetic patients.<sup>2,3</sup>

Intensive statin therapy may increase the risk of developing diabetes; however, the benefits of statins on cardiovascular events and mortality outweigh the risks. Patients with liver failure, renal insufficiency, hypothyroidism, advanced age and serious infections are more prone to experiencing such adverse reactions.<sup>2,3</sup>

### The Anterior Segment

Adverse effects here range from exacerbation of dry eye to myopathy or possible accelerated cataract development, but positive associations exist as well.

**Ocular surface.** The Blue Mountains Eye Study III survey found that oral statins were associated with an increase in moderate to severe dry eye symptoms, possibly due to the disruption of essential cholesterol synthesis for meibum lipid homeostasis in the meibomian glands.<sup>5</sup>



**This fundus image shows retinal arteriosclerosis in a 45-year-old patient with a total cholesterol of 304, triglycerides of 1,290 and LDL of 129.**

Interestingly, a prospective pilot study with 10 dry eye and blepharitis patients found that topical atorvastatin may be a potential therapy, as demonstrated by improved tear film break up time, blepharitis score and bulbar conjunctival injection.<sup>6</sup> While the mechanism is largely unknown, it may be due to the anti-inflammatory pleotropic effects; larger clinical studies are required to establish the efficacy and safety of topical statin use.

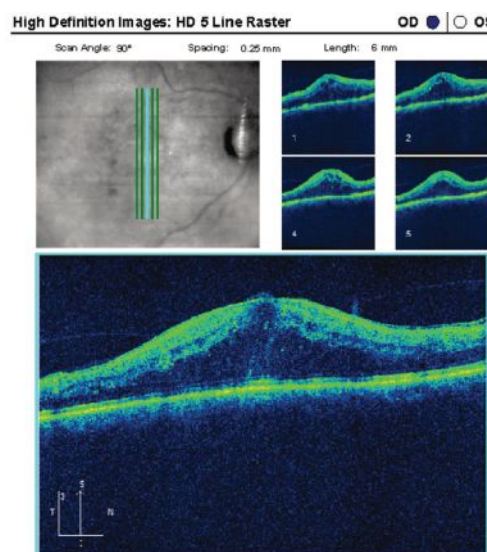
**Orbit.** Myopathies are a rare adverse reaction to statin therapy. Retrospective case reports suggest inflammation of the extraocular or levator muscles as a possible etiology; however, other patient risk factors such as advanced age, hypertension, diabetes and other comorbid cardiovascular conditions cannot be entirely ruled out. Of note, cases of ptosis, blepharoptosis and external ophthalmoplegia associated with statin usage have completely resolved upon discontinuation of statin use.<sup>7-9</sup>

The anti-inflammatory effects of statins may be beneficial in the area of thyroid

eye disease. A recent report shows that oral statins may have the potential to decrease the conversion of Graves' disease to thyroid-associated orbitopathy by 40%.<sup>10,11</sup> A 2018 study of 30 patients shows that statin users tend to have a reduced number of orbital decompressions and strabismus surgeries compared with non-statin users.<sup>11</sup>

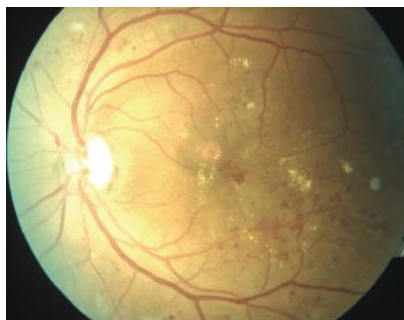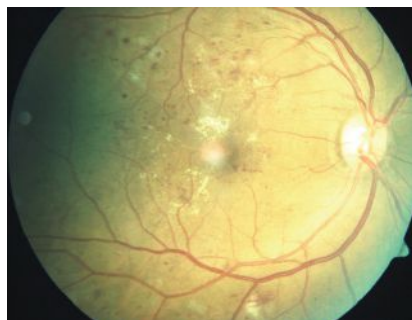**Ocular inflammation/uveitis.** Statins may be beneficial in ocular inflammatory diseases by stabilizing the blood-ocular and blood-retinal barriers (BRB) as well as endothelial cells.<sup>12</sup> Research also shows statins can reduce levels of key inflammatory markers, such as interleukins 6 and 8, TNF-alpha, and C-reactive protein.<sup>12,13</sup> Research from 2015 found statin users were 48% less likely to develop uveitis than non-statin users.<sup>13</sup>

**Cataracts.** Studies on statin use and cataract development have yielded inconsistent and conflicting results. Some reports have found an increased risk of cataracts from



**This 64-year-old patient had a history of poorly controlled insulin-dependent diabetes with significant DME in the right eye. She underwent two aflibercept injections previously. Some research shows statins may also reduce VEGF.**

# Systemic Meds



**This 55-year-old patient with diabetes developed significant bilateral DME over six months. Some patients who take statins are less likely to develop DME.**

statin use, while others showed no association or even a protective effect.<sup>14-16</sup> One possible mechanism may be statins' bidirectional effects on oxidation processes, including a possible mitochondrial effect that may increase the risk of cataracts.<sup>14</sup> High cholesterol is required to maintain transparency of the crystalline lens; some researchers hypothesize that the inhibition of cholesterol biosynthesis by statin medications could prevent proper epithelial cell development within the crystalline lens, increasing the risk of cataract development.<sup>14</sup>

In contrast, a meta-analysis shows a clinically relevant protective effect of statins in preventing cataract formation, with a more pronounced effect in younger patients.<sup>16</sup>

Although the exact mechanism is unknown, statins may help to prevent cataracts through its pleiotropic effects and decreasing by LDLs. In 2017, investigators published research on more than 313,200 cataract cases and concluded that no clear evidence shows that statin use increases the risk of cataract development.<sup>15</sup>

## Posterior Segment

Could statins be protective against glaucoma, diabetic retinopathy or AMD? The jury is still out but some studies are encouraging.

### *Glaucoma/intraocular pressure.*

The current treatment of open-angle glaucoma (OAG) is aimed primarily towards intraocular pressure (IOP) reduction, although clinical challenges often arise when OAG progresses despite adequate IOP control. The search for other treatments, such as statins, is a rising area of interest amongst researchers.

Literature on statins and glaucoma are conflicting in nature. While some studies do not support statins' protective role against OAG, recent research endorses their protective role.<sup>17-22</sup> A large observational study of 136,782 participants reported that higher serum cholesterol levels were associated with a higher risk of primary OAG; five or more years of statin use was associated with a 21% lower risk, and use for 10 years or more had a 40% lower risk.<sup>20</sup> Other studies have found that long-term use of statins is associated with a reduced risk of OAG (independent of the IOP); however, the results did not reach statistical significance.<sup>21</sup>

Researchers have proposed a few hypotheses to explain the mechanism of how statins reduce the risk of OAG. Statins increase aqueous outflow through the upregulation of endothelial nitric oxide synthase resulting in vasodilation and increased retinal and choroidal blood flow, leading to a reduction in

IOP.<sup>20,22</sup> They also inhibit rho-kinase activity, which may increase aqueous outflow and reduce IOP.<sup>20,22</sup> The improved retinal and choroidal perfusion may benefit the health of the optic nerve and the nerve fiber layer. There are also potential neuroprotective effects that may protect retinal ganglion cells.<sup>20,22</sup> Further studies are warranted to confirm statins' potential benefit in OAG management.

*Diabetic retinopathy.* Endothelial dysfunction and inflammatory processes lead to the development of diabetic retinopathy (DR). Statins have vasoprotective actions and are able to penetrate the BRB, reducing endothelial cell dysfunction and ultimately protecting against the sight threatening complications of DR.<sup>23-25</sup> By reducing reactive oxygen species, increasing nitric oxide levels and increasing the number of endothelial progenitor cells, statins have the ability to improve vascular resistance, blood flow velocity and retinal perfusion thereby sustaining the stability of the BRB.<sup>26,27</sup>

In a study that looked at patients with Type 2 diabetes and dyslipidemia, those taking statins had a significantly lower rate of DR, nonproliferative DR, proliferative DR (PDR), vitreous hemorrhage, tractional retinal detachment and diabetic macular edema (DME) than the non-statin group.<sup>28</sup> The study also indicated that statin users also had lower rates of ophthalmic interventions such as retinal laser treatment, intravitreal injection and vitrectomy.<sup>28</sup> Moreover, these researchers reported a decreased risk in DR progression with the use of higher doses and longer duration of statin therapy.<sup>28</sup>

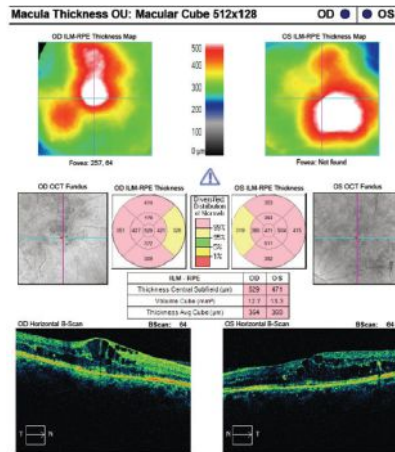
Two large clinical studies show fenofibrate has beneficial effects against DR progression, independent of its lipid-modifying action

in Type 2 diabetics. Although fenofibrate is not classified as a statin medication, it can reduce the frequency of PDR by 30% and the need for laser treatment for DME by 31%.<sup>29</sup> Additionally, one study also noted that the combination of fenofibrate with simvastatin synergistically reduced DR progression rate by 40%, compared with simvastatin treatment alone.<sup>29,30</sup>

**Diabetic macular edema.** Hypercholesterolemia is regarded as a strong risk factor for endothelial dysfunction, which contributes to the development of DME.<sup>31,32</sup> In univariate analysis, the total cholesterol and LDL were significantly higher in patients with clinically significant macular edema and were a risk factor for retinal hard exudate formation.<sup>33-36</sup>

Results from a retrospective study show a noteworthy relationship between serum triglycerides and DME, which corresponds to the findings of the Fenofibrate Intervention and Event Lowering in Diabetes study. Additionally, a recent meta-analysis found that statins protected against the development of DME and progression of DR in patients with Type 2 diabetes.<sup>31,36,37</sup> Large and long-term randomized controlled prospective studies are necessary to obtain a more complete assessment of the effects of statin therapy on DR and DME.

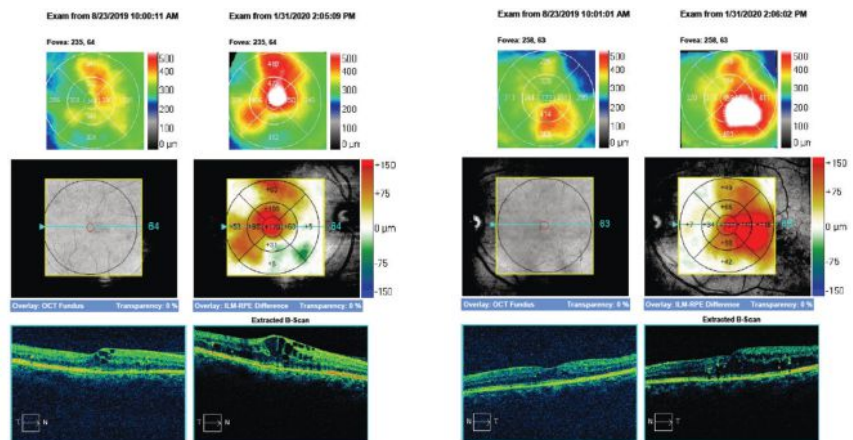
**Vitreotomy for proliferative diabetic retinopathy.** PDR is characterized by retinal neovascularization, contractile scar tissue formation, vitreous hemorrhage, tractional retinal detachment, and neovascular glaucoma. In randomized clinical trials, the use of simvastatin decelerated DR progression and visual acuity loss which may be attributed to the medication's ability to suppress expression and secretion of potent vasoactive, proinflammatory and



**These macular cube analysis images of the same patient from the previous page shows clinically significant macular edema in both eyes.**

tissue remodeling factors.<sup>30,38-41</sup>

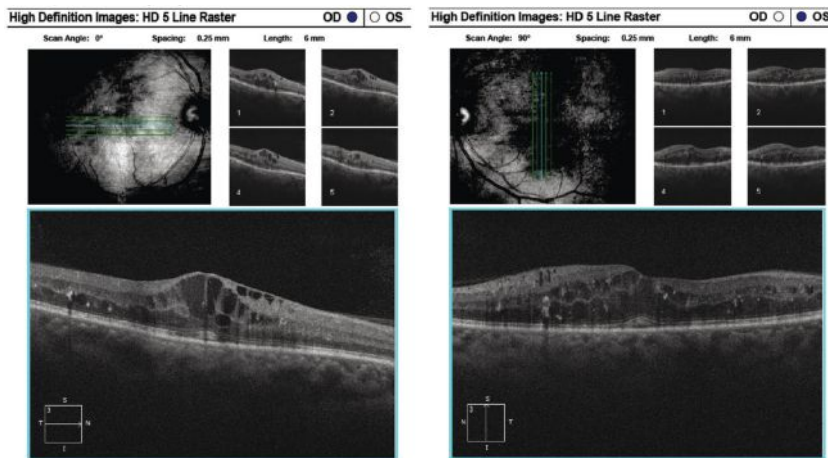
Similarly, a prospective observational study found that diabetic vitrectomy patients with preoperative statin treatment (mainly receiving lipophilic simvastatin or atorvastatin) had a better one-month best-corrected visual acuity improvement and a lower frequency of postoperative complications than those without statin treatment.<sup>42</sup> These studies indicate that statins, particularly simvastatin, appear to contribute to a lower incidence of complications after diabetic vitrectomy.



**Here, the same 55-year old patient's macular cube change analysis of right and left eyes demonstrate the frank progression of DME over the course of six months.**

**Vitreoretinal surgery for rhegmatogenous retinal detachment.** Statin therapy may have a potentially beneficial effect on vitreoretinal (VR) surgery outcomes. Statins exhibit anti-inflammatory, antioxidative, anti-fibroproliferative, and microvasculoprotective effects that contribute to photoreceptor survival, the retinal wound healing process and inflammation related to proliferative vitreoretinopathy (PVR) formation in eyes after surgery for rhegmatogenous retinal detachment (RRD).<sup>43,44</sup> Research shows statins can reduce intravitreal levels of angiotensin-2, vascular endothelial growth factor (VEGF) and matrix metalloproteinase-2, which are factors associated with vascular permeability, inflammation, and fibroproliferation.<sup>45</sup>

According to a Finnish population-based cohort study, the use of simvastatin and atorvastatin was associated with a significantly lower risk of re-vitreotomy in patients whom previously underwent intervention for a RRD.<sup>46</sup> Of note, rosuvastatin also lowered the repeat procedure rate but to a lesser degree than the aforementioned medications.<sup>46</sup> Lipophilicity impacts on the pleiotropic effects of statins



**Here, raster images of the previous patient show center-involved macular edema of the right eye and diffuse edema and retinal thickening of the left eye.**

such as cell function, coagulation and inflammation. Although the pleiotropic effects of statins have been related to the outcomes of re-vitrectomy rates after RDD, additional randomized clinical trials are warranted to further determine the effects of statins on VR surgery outcomes.

**Age-related macular degeneration (AMD).** Recent epidemiologic, genetic and pathological evidence shows AMD and atherosclerosis share several risk factors, leading to the hypothesis that statins may provide protective effects in AMD. There have been several reported mechanisms of how statins may aid in preventing AMD progression.<sup>47</sup> Researchers believe the cholesterol-lowering, antioxidant, anti-inflammatory action, antiproliferative and anti-endothelial dysfunction effect of statins reduce the incidence and progression of AMD.<sup>48-51</sup> Statins may also have the ability to preserve vascular supply to the outer retina and may inhibit secretion of MMP, which is involved in the development of choroidal neovascularization (CNV).<sup>47,52</sup>

Research on statins' effect on AMD has yielded inconsistent and conflicting results. Some studies

report a protective effect in early AMD, while others show an association between their use and AMD development at five years.<sup>53-61</sup>

The heterogeneity of AMD suggests that the effects of statins may vary by stage, reducing the development of drusen at the onset of AMD and having further anti-inflammatory effect on late-disease.<sup>58</sup> Studies also suggest the need for a genetic analysis to understand whether the genotype can influence a response to statins as a therapeutic option.<sup>62</sup> One factor impacting the conflicting results is the lack of standardization of statin dosages or individual lipophilicity for each class of drug.<sup>63</sup>

**Choroidal neovascular membrane.** Elevated intraocular levels of VEGF play an important role in the development of CNV and AMD. Research shows statins reduce plasma levels of VEGF and downregulate transcription factors involved in VEGF expression, thus potentially reducing the incidence and progression of CNV.<sup>51</sup>

Implications of statins on CNV development is not well understood with few relevant trials and observational studies.<sup>59</sup> Interestingly, a large cross-sectional study of 3,090 patients with dry AMD found a

larger proportion of statin users developed a CNV (29.3%) compared to non-statin users (23.3%); these results remained true after adjusting for age, sex, race, and comorbidity status.<sup>64</sup>

**Retinal vein occlusion.** Atherosclerosis, along with cardiovascular risk factors such as hyperlipidemia, diabetes and hypertension, contributes to the pathophysiology of retinal vein occlusion (RVO).<sup>65</sup> Elevated cholesterol levels can change the plasma viscosity and alter platelet function, predisposing the blood to thrombosis and hemostasis.<sup>66</sup> Research shows low-dose simvastatin promotes vascular repair through upregulation of VEGF and NO levels, while higher doses inhibited reparative processes and resulted in cell death due to depletion of intracellular cholesterol and disruption of key structures within the cells, which increases ischemia-induced neovascularization.<sup>67</sup> However, an additional study found no preventive or therapeutic benefit of statins in high-risk patients.<sup>68</sup> Very few studies have explored the role of statins in the management of RVO.

Despite the dearth of randomized trials focusing on statins and their effects on the eye, there is inconsistent evidence regarding their role in various eye conditions. At this time, the literature does not support the recommendation that eye care physicians change their practice patterns or recommend statins solely for improved ocular health. However, statins are medications ODs encounter every day. Optometrists need to be versed in the potential side effects and work to comanage the patient with their primary care doctor, cardiologist or internist. It's prudent to advise patients to discuss their cholesterol levels with their primary care physician. ■

*Drs. Zimbalist and Gentry practice at the Harry S. Truman Memorial Veterans' Hospital in Columbia, Mo.*

*Dr. Ho practices at the Central Texas Veterans Health Care System Austin Outpatient Clinic in Austin, TX.*

- Adedinsawo D, Taka N, Agasthi P, Sachdeva R, et al. Prevalence and Factors Associated With Statin Use Among a Nationally Representative Sample of US Adults: National Health and Nutrition Examination Survey, 2011-2012. *Clinical Cardiology*. 2016;39(9):491-6.
- Rosenson R. Statins: actions, side effects, and administration. UpToDate. [www.uptodate.com/contents/statins-actions-side-effects-and-administration](http://www.uptodate.com/contents/statins-actions-side-effects-and-administration). August 13, 2019. Accessed December 2, 2019.
- Stancu C, Anca S. Statins: mechanism of action and effects. *J Cell Mol Med*. 2001;5(4):378-87.
- Liao J, Laufs U. Pleiotropic effects of statins. *Annu Rev Pharmacol Toxicol*. 2005;45:89-118.
- Ooi K, Lee M, Burlutsky G, et al. Association of dyslipidaemia and oral statin use, and dry eye disease symptoms in the Blue Mountains Eye Study. *Clin Exp Ophthalmol*. 2018;47(2):187-92.
- Ooi K, Wakefield D, Billson F, Watson S. Efficacy and safety of topical atorvastatin for the treatment of dry eye associated with blepharitis: A pilot study. *Ophthalmic Research*. 2015;54(1):26-33.
- Ertas F, Ertas N, Gulec S, et al. Unrecognized side effect of statin treatment: unilateral blepharoptosis. *Ophthalmic Plastic & Reconstructive Surgery*. 2006;22(3):222-4.
- Negveskey G, Kolsky M, Laureno R, Yau T. Reversible atorvastatin-associated external ophthalmoplegia, antiacetylcholine receptor antibodies, and ataxia. *Arch Ophthalmol*. 2000;118(3):427-8.
- Finsterer J, Zuntner G. Rhabdomyolysis from simvastatin triggered by infection and muscle exertion. *South Med J*. 2005;98(8):827-9.
- Stein J, Childers D, Gupta S, et al. Risk factors for developing thyroid-associated ophthalmopathy among individuals with Graves disease. *JAMA Ophthalmol*. 2015;133(3):290.
- Reynolds A, Del Monte M, Archer S. The effect of oral statin therapy on strabismus in patients with thyroid eye disease. *J AAPOS*. 2018;22(5):340-3.
- Yunker J, McGwin G, Read R. Statin use and ocular inflammatory disease risk. *J Ophthalmic Inflamm Infect*. 2013;3(1):8.
- Borkar D, Tham V, Shen E, et al. Association between statin use and uveitis: results from the Pacific ocular inflammation study. *Am J Ophthalmol*. 2015;159(4):707-13.
- Leuschen J, Mortensen E, Frei C, et al. Association of statin use with cataracts: a propensity score-matched analysis. *JAMA Ophthalmol*. 2013;131(11):1427-34.
- Yu S, Chu Y, Li G, et al. Statin use and the risk of cataracts: a systematic review and meta-analysis. *J Am Heart Assoc*. 2017;6(3):e004180.
- Kostis J, Dobrzynski J. Prevention of cataracts by statins: a meta-analysis. *J Cardiovasc Pharmacol Ther*. 2014;19(2):191-200.
- Owen C, Care I, Shah S, et al. Hypotensive medication, statins, and the risk of glaucoma. *Invest Ophthalmol Vis Sci*. 2010;51(7):3524-30.
- Iskedjian M, Walker J, Desjardins O, et al. Effect of selected antihypertensives, antidiabetics, statins and diuretics on adjunctive medical treatment of glaucoma: a population-based study. *Curr Med Res Opin*. 2009;25(8):1879-88.
- Leung D, Li F, Kwong Y, et al. Simvastatin and disease stabilization in normal tension glaucoma: a cohort study. *Ophthalmol*. 2010;117(3):471-6.
- Kang J, Boumenna T, Stein J, et al. Association of statin use and high serum cholesterol levels with risk of primary open angle glaucoma. *JAMA Ophthalmol*. 2019;137(7):756-65.
- Marcus M, Muskens R, Ramdas W, et al. Cholesterol-lowering drugs and incident open-angle glaucoma: a population-based cohort study. *PLoS ONE*. 2012;7(1): e29724.
- Stein J, Newman-Casey P, Talwar N, et al. The relationship between statin use and open-angle glaucoma. *Ophthalmol*. 2012;119(10):2074-81.
- Shchachter M. Chemical, pharmacokinetic and pharmacodynamics properties of statins: an update. *Fund Clin Pharmacol*. 2005;19:117-25.
- Mason R, Walter M, Day C, Jacob R. Intermolecular differences of 3-hydroxy-3-methylglutaryl coenzyme A reductase inhibitors contribute to distinct pharmacologic and pleiotropic actions. *Am J Cardiol*. 2005;96:11F-23F.
- Hilbert T, Poth J, Frede S, et al. Anti-atherogenic effects of statins: Impact on angiotensin-2 release from endothelial cells. *Biochem Pharmacol*. 2013;86:1452-60.
- Fadini G, Baesso I, Albiero M, et al. Technical notes on endothelial progenitor cells: ways to escape from the knowledge plateau. *Atherosclerosis*. 2008;197:496-503.
- Ozkiris A, Erkilic K, Koc A, Mistik S. Effect of atorvastatin on ocular blood flow velocities in patients with diabetic retinopathy. *Br J Ophthalmol*. 2007;91:69-73.
- Kang EY-C, Chen T, Garg S, et al. Association of statin therapy with prevention of vision-threatening diabetic retinopathy. *JAMA Ophthalmol*. 2019;137(4):363-71.
- Keetch A, Mitchell P, Summanan PA, et al. FIELD study investigators. Effect of fenofibrate on the need for laser treatment for diabetic retinopathy (FIELD study): a randomized controlled trial. *Lancet*. 2007;370:1687-97.
- Chew E, Ambrosius W, Davis M, et al. ACCORD Study Group; ACCORD Eye Study Group. Effects of medical therapies on retinopathy progression in Type 2 diabetes. *N Engl J Med*. 2010;363:233-44.
- Rangaswamy S, Penn M, Saidel G, Chisolm G. Exogenous oxidized low-density lipoprotein injures and alters the barrier function of endothelium in rats in vivo. *Circ Res*. 1997;80:37-44.
- Ding J, Wong TY. Current epidemiology of diabetic retinopathy and diabetic macular edema. *Curr Diabetes Rep*. 2012;12:346-54.
- Jew O, Peyman M, Chen T, Visvaraja S. Risk factors for clinically significant macular edema in a multi-ethnic population with Type 2 diabetes. *Int J Ophthalmol*. 2012;5:499-504.
- Chew E, Klein M, Ferris F, et al. Association of elevated serum lipid levels with retinal hard exudate in diabetic retinopathy. Early Treatment Diabetic Retinopathy Study (ETDRS) Report 22. *Arch Ophthalmol*. 1996;114:1079-84.
- Klein B, Moss S, Klein R, Surawicz T. The Wisconsin epidemiologic study of diabetic retinopathy. XIII. Relationship of serum cholesterol to retinopathy and hard exudate. *Ophthalmol*. 1991;98:1261-5.
- Chung Y, Park S, Choi S, et al. Association of statin use and hypertriglyceridemia with diabetic macular edema in patients with type 2 diabetes and diabetic retinopathy. *Cardiovasc Diabetol*. 2017;16(1):4.
- Knickelbein J, Abbott A, Chew F. Fenofibrate and diabetic retinopathy. *Curr Diab Rep*. 2016;16(10):90.
- Sen K, Misra A, Kumar A, Pandey R. Simvastatin retards progression of retinopathy in diabetic patients with hypercholesterolemia. *Diabetes Res Clin Pract*. 2002;56:1-11.
- Lee S, Kim J, Lee H, et al. Simvastatin suppresses expression of angiogenic factors in the retinas of rats with streptozotocin-induced diabetes. *Graefes Arch Clin Exp Ophthalmol*. 2011;249:389-97.
- Miyahara S, Kiryu J, Yamashiro K, et al. Simvastatin inhibits leukocyte accumulation and vascular permeability in the retinas of rats with streptozotocin-induced diabetes. *Am J Pathol*. 2004;164:1697-706.
- Tuominen R, Sahanne S, Loukovaara S. Low intravitreal angiotensin-2 and VEGF levels in vitrectomized diabetic patients with simvastatin treatment. *Acta Ophthalmol*. 2014;92:675-81.
- Tuominen R, Sahanne S, Haukka J, Loukovaara S. Improved outcome after primary vitrectomy in diabetic patients treated with statins. *Eur J Ophthalmol*. 2016;26(2):174-181.
- Koh K. Effects of statins on vascular wall: vasomotor function, inflammation, and plaque stability. *Cardiovasc Res*. 2000;47(4):648-657.
- Takemoto M, Liao JK (2001) Pleiotropic effects of 3-hydroxy-3-methylglutaryl coenzyme A reductase inhibitors. *Arterioscler Thromb Vasc Biol* 21(11):1712-1719.
- Tuominen R, Haukka J, Loukovaara S. Statins in rheumatogenous retinal detachment are associated with low intravitreal angiotensin-2, VEGF and MMP-2 levels, and improved visual acuity gain in vitrectomized patients. *Graefes Arch Clin Exp Ophthalmol*. 2014;253:1685-1693.
- Loukovaara S, Sahanne S, Takala A, Haukka J. Statin use and vitreoretinal surgery: Findings from a Finnish population-based cohort study. *Acta Ophthalmol*. 2018;96:442-451.
- Guymer RH, Chiu AW, Lim L, Baird PN. HMG CoA reductase inhibitors (statins): do they have a role in age-related macular degeneration? *Surv Ophthalmol*. 2005;50(2):194-206.
- Gurne D, Tso M, Edward D, Ripp H. Antiretinal antibodies in serum of patients with age-related macular degeneration. *Ophthalmol*. 1991;98(5):602-7.
- Spaide R, Ho-Spaide W, Browne R, Armstrong D. Characterization of peroxidized lipids in Bruch's membrane. *Retina*. 1999;19(2):141-7.
- Penfold P, Madigan M, Gillies M, Provis J. Immunological and aetiological aspects of macular degeneration. *Progress in Retinal & Eye Research*. 2001;20(3):385-414.
- Dichtl W, Dulak J, Frick M, et al. HMG-CoA reductase inhibitors regulate inflammatory transcription factors in human endothelial and vascular smooth muscle cells. *Arteriosclerosis, Thrombosis, and Vascular Biology*. 2003; 23(1):58-63.
- Friedman E. Update of the vascular model of AMD. *Bri J of Ophthalmol*. 2004;88(2):161-3.
- Barbosa D, Mendes T, Cintron-Colon H, et al. Age-related macular degeneration and protective effect of HMG Co-A reductase inhibitors (statins): results from the National Health and Nutrition Examination Survey 2005-2008. *Eye*. 2014;28:472-80.
- Guymer RH, Baird PN, Varsamidis M, et al. Proof of concept, randomized, placebo-controlled study of the effect of simvastatin on the course of age-related macular degeneration. *PLoS ONE*. 2013;8:e83759.
- Tan JS, Mitchell P, Rochtchina E, Wang JJ. Statins and the long-term risk of incident age-related macular degeneration: the Blue Mountains Eye Study. *Am J Ophthalmol*. 2007;143:685-7.
- Klein R, Klein BE, Tomany SC, et al. Relation of statin use to the 5-year incidence and progression of age-related maculopathy. *Arch Ophthalmol*. 2003;121:1151-5.
- van Leeuwen R, Tomany SC, Wang JJ, et al. Is medication use associated with the incidence of early age-related maculopathy? Pooled findings from 3 continents. *Ophthalmol*. 2004;111:1169-75.
- Vavvas DG, Daniels AB, Kapsala ZG, et al. Regression of some high-risk features of age-related macular degeneration (AMD) in patients receiving intensive statin treatment. *EBioMedicine*. 2016;5:198-203.
- Ma L, Wang Y, Du J, et al. The association between statin use and risk of age-related macular degeneration. *Sci Rep*. 2015;5:18280.
- Maguire MG, Ying GS, McCannel CA, et al. Statin use and the incidence of advanced age-related macular degeneration in the complications of age-related macular degeneration prevention trial. *Ophthalmol*. 2009;116:2381-2385.
- Gehlbach P, Li T, Hatef E. Statins for age-related macular degeneration. *Cochrane Database Syst Rev*. 2016;Cd006927.
- Roizenblatt M, Naranjit N, Maia M, Gehlbach PL. The question of a role for statins in age-related macular degeneration. *Int J Mol Sci*. 2018;19:3688.
- Miller JW, Bagheri S, Vavvas DG. Advances in age-related macular degeneration understanding and therapy. *US Ophthalmic Rev*. 2017;10:119-130.
- Rajeshuni N, Ludwig CA, Moshfeghi DM. The effect of statin exposure on choroidal neovascularization in nonexudative age-related macular degeneration patients. *Eye*. 2019;33:163-165.
- Rehak M, Wiedemann P. Retinal vein thrombosis: pathogenesis and management. *J Thromb Haemost*. 2010;8:1886-94.
- Dodson PM, Galtton DJ, Hamilton AM, Blach RK. Retinal vein occlusion and the prevalence of lipoprotein abnormalities. *Br J Ophthalmol*. 1982;66:161-4.
- Medina RJ, O'Neill CL, Devine AB, et al. The pleiotropic effects of simvastatin on retinal microvascular endothelium has important implications for ischaemic retinopathies. *PLoS ONE*. 2008;3:e2584.
- Matei VM, Xia JY, Nguyen C. Poor outcomes despite aspirin or statin use in high-risk patients with retinal vein occlusion. *Graefes Arch Clin Exp Ophthalmol*. 2017;255:761-6.

# Five Cases

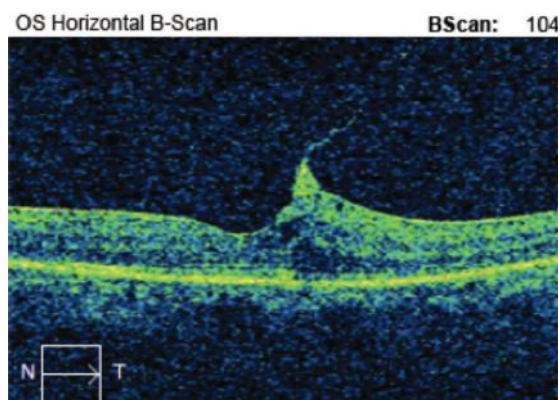
## You Shouldn't Refer

Don't be afraid to keep these patients in your practice; you have the skillset and scope of practice to help them. **By Laine S. Higa, OD**

Ongoing technological advances, new drug formulations and increased scope of practice have all collided to allow optometrists the opportunity to manage difficult cases that were once previously referred to our ophthalmology counterparts. These five disease presentations—vitreomacular adhesion (VMA) and traction (VMT), post-op cystoid macular edema (CME), neurotrophic keratitis (NK), traumatic brain injury (TBI) and glaucoma/ocular hypertension (OHTN)—are commonly evaluated in the optometric setting and can be managed successfully, in most cases, without referral. Case examples help illustrate how optometrists can independently treat and manage each condition.

### VMA and VMT

In adults, the average volume of the vitreous body is 4mL.<sup>1</sup> The vitreous is contained in the posterior chamber of the eye in a cortex that abuts the posterior lens capsule, ciliary



**Case 1. This is the horizontal OCT B-scan of the left eye of an 85-year-old black male patient with VMT who is being monitored. BCVA is 20/50- OS. He reports metamorphopsia on the Amsler grid but denies scotoma. We discussed monitoring vs. surgical consultation, and the patient prefers to self-monitor with Amsler grid. He is being followed every three months with serial macular OCT and dilated fundus exam.**

body, optic nerve and internal limiting membrane (ILM) of the retina. As we age, gel liquefaction occurs within the vitreous body, causing a weakening of the vitreoretinal adhesions posteriorly.<sup>1,2</sup> This biochemical change manifests clinically as a posterior vitreous detachment (PVD) and can be ongoing for decades. A PVD occurs when there is vitreous

separation from the macula and optic nerve.<sup>1</sup>

**Pathophysiology.** VMA is described as a perifoveal vitreous detachment in the presence of persistent foveal attachment observed on ocular coherence tomography (OCT).<sup>1</sup> VMA is a variant of normal given the physiological presence of vitreoretinal adhesion. The observance of VMA with OCT represents a single stage of impending vitreous separation from the retina without underlying abnormalities (i.e., intraretinal cysts).<sup>1</sup> The International Vitreomacular Traction Study Group has subclassified VMA into two types: focal and broad.<sup>1</sup> Focal VMA occurs

when there is less than or equal to 1,500µm of vitreous adhesion overlying the ILM, while broad VMA occurs when the adhesion is greater than 1,500µm.<sup>1</sup> Patients with VMA typically do not report visual symptoms and have the potential for the condition to spontaneously resolve without retinal sequelae.

VMT is the attachment of the vitreous cortex to the ILM in the area of the macula, resulting in anatomic abnormality of the area. Like VMA, there are two types: focal and broad.<sup>1</sup> The condition is focal when the size of the vitreous-ILM adhesion is less than or equal to 1,500 $\mu$ m and broad when the adhesion is greater than 1,500 $\mu$ m.<sup>1</sup>

VMT occurs when there is an imbalance between vitreous liquefaction and the separation of the vitreous cortex from the retina.<sup>3,4</sup> The result of this mismatch is an anomalous PVD—an attachment of the vitreous to the ILM in the macular region. The area of the anomalous PVD has subsequent tractional deformation given the continued vitreous attachment anteriorly.<sup>1</sup>

VMT is more likely to affect females than males and has the highest incidence in the sixth decade of life.<sup>5</sup> The estimated prevalence of VMT is 22.5 cases per 100,000 persons.<sup>6</sup> Unlike VMA, patients with VMT often have visual complaints such as decreased visual acuity (VA), metamorphopsia, blurred vision, micropsia and photopsia.<sup>2,7</sup>

**Management.** Most, if not all, cases of VMA can be monitored conservatively. Given that VMA may be a transient aging change and the vitreous may likely separate from the ILM without issue, referral to a retina specialist is not warranted. Patients with VMA have no underlying changes to the foveal umbo so VA is preserved, except in the setting of other macular and retinal conditions. Conservatively, patients can be given a home Amsler grid to test monocularly on a frequent basis. Patients should be instructed to call the office immediately should they notice changes such as metamorphopsia and scotoma. Follow-up for VMA would be six months to a year with a full dilated fundus examina-

tion and macular OCT.

Management of VMT mirrors that of VMA in cases where the patient is asymptomatic for metamorphopsia and scotoma and VA is 20/60 or better in the affected eye.

Interestingly, a systematic review and meta-analysis of the safety and efficacy of pars plana vitrectomy (PPV) for VMT found a mean improvement in VA to 20/53 postoperatively.<sup>8</sup>

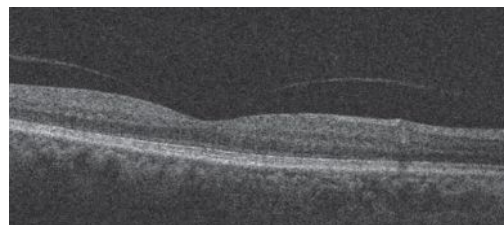
Additionally, a retrospective case series that reviewed the prognostic factors of postoperative intraretinal cystoid spaces (ICS) after primary PPV for VMT found that preoperative ICS was a major risk factor for persistent ICS post-op.<sup>2</sup> Thus, patients with VMT with or without intraretinal cysts with a VA of 20/60 or better can be appropriately managed in the optometric practice. A macular OCT should be done with a dilated fundus exam at three- to six-month intervals to assess for changes in VMT, VA and symptoms.

Prior to the patient leaving, perform an in-office Amsler grid to demonstrate how to use the grid and to note any pre-existing metamorphopsia or scotoma. Should either be present, make note of this and educate the patient that they are to return should they notice any changes from the current findings (*Cases 1 and 2*).

### Post-op CME

In 1953, Irvine-Gass syndrome (IGS) was first reported for CME following cataract surgery, followed by the first fluorescein angiography (FA) diagnosis in 1969.<sup>9,10</sup> IGS typically occurs within 12 weeks with a peak incidence between weeks four and six after cataract surgery.<sup>11</sup>

The diagnosis is made with clini-



**Case 2. Here is a macular OCT of a 64-year-old black female with focal VMA in the right eye. BCVA is 20/20 OD. The patient is asymptomatic for metamorphopsia or scotoma and is being monitored yearly.**

cal exam of the fundus, FA, macular OCT or a combination of all three. With macular OCT imaging, intra-retinal spaces are observed in the area of and around the foveal umbo. Patients with IGS will report decreased VA and contrast sensitivity and metamorphopsia in the affected eye(s). Advancements in cataract removal have dramatically reduced the prevalence of post-op complications, and the prevalence of IGS in those without risk factors is 1% to 2%.<sup>12</sup>

**Pathophysiology.** Surgically induced inflammation is the root etiology of IGS. During surgery, activation of phospholipase A<sub>2</sub> (PLA<sub>2</sub>) propagates the inflammatory pathway by up-regulating arachidonic acid (AA) production. AA production results in eicosanoid (i.e., prostaglandin) and leukotriene synthesis via the cyclooxygenase (COX) and lipoxygenase (LOX) pathways, respectively.<sup>13</sup> These inflammatory mediators, produced in the anterior chamber during cataract surgery, have the potential to migrate posteriorly to the retina.<sup>14</sup> When this occurs, the inflammatory mediators cause vasodilation, vascular permeability and disruption of the blood-retinal barrier.<sup>15</sup>

**Management.** IGS can effectively be treated with a combination of topical corticosteroids and non-steroidal anti-inflammatory

# Referrals

drugs (NSAIDs). Corticosteroids inhibit PLA<sub>2</sub>, down-regulating the production of AA and subsequent substrates for both COX and LOX enzymes.<sup>16</sup> Corticosteroids also have the ability to inhibit vasodilation, decrease vascular permeability and stabilize intracellular and extracellular membranes.<sup>17</sup> NSAIDs work downstream of the inflammatory cascade by inhibiting the COX enzymes, thereby decreasing eicosanoid formation.

Often, patients with IGS will already have these drugs in their arsenal for both pre- and post-operative use. Each drug's formulation will dictate the specific dosing of both the corticosteroid and NSAID. For generic prednisolone and ketorolac, QID dosing of both medications is warranted.

Clinicians can schedule follow-up with VA, intraocular pressure (IOP), fundus examination and macular OCT in two- to four-week intervals until complete resolution is noted. If IGS is persistent past 12 weeks of topical treatment, consider increasing the topical prednisolone to Q1H while awake.

In one clinical trial, there was a statistically significant difference in best-corrected visual acuity (BCVA) and macular thickness 12 weeks after changing the dosing frequency of prednisolone to Q1H while awake.<sup>18</sup> It is important to slowly taper both the corticosteroid and NSAID to prevent the recurrence of intraocular inflammation (*Case 3*).

## Neurotrophic Keratitis

Corneal sensation is important to maintain homeostasis

of the ocular surface by mediating the production of trophic factors that support and maintain the corneal epithelium and corneal nerves.<sup>19</sup> NK is an uncommon corneal disease in which the sensory-mediated reflexes are reduced. The estimated prevalence of NK is 1.6 to 4.2 cases per 10,000 persons.<sup>19,20</sup>

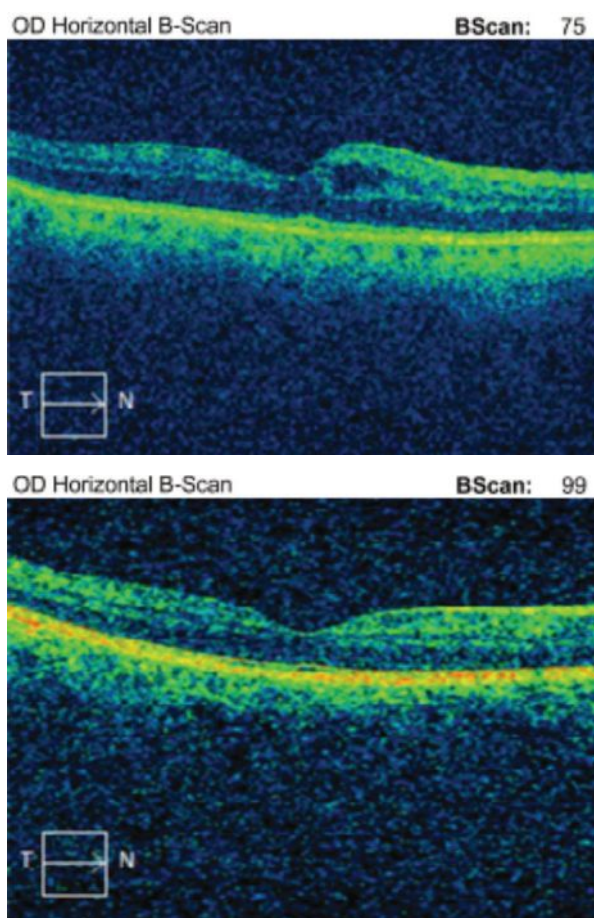
Currently, the disease is classified into three stages. Stage one manifests with punctate epithelial keratitis, epithelial hyperplasia, stromal scarring and corneal neovascularization.<sup>21,22</sup> Stage two is a persistent epithelial defect.<sup>21</sup> The most severe, stage three, is corneal stromal ulceration

that may result in corneal perforation or melting.<sup>21,22</sup> NK can result from past ocular infections (herpes being the most common), chemical corneal burns, ocular surgeries, topical medications, cranial nerve V palsy and select systemic diseases.<sup>22,23</sup>

Diagnosis of NK is confirmed quantitatively or qualitatively with in-office corneal sensitivity testing.

**Pathophysiology.** Corneal epithelial turnover and transparency is due to the highly innervated network of corneal nerves.<sup>24</sup> The human cornea is the most innervated structure in the body—40 times more innervated than tooth pulp and 400 times more innervated than human skin.<sup>25</sup> Corneal stem cell proliferation and differentiation is mediated by the secretion of neurotrophins released by the trigeminal nerve.<sup>24</sup> In cases of NK, decreased amounts of nerve growth factor (NGF), substance P, calcitonin gene-related peptide, neuropeptide Y and acetylcholine are significantly reduced.<sup>24</sup> The reduction of neurotrophins results in both morphological and metabolic epithelial disruptions leading to ocular surface defects and non-healing corneal wounds.<sup>20</sup> Additionally, the ocular surface suffers further desiccative stress from poor tear re-establishment due to reduced blink rates.

**Management.** Treatment and management of NK is dependent on the stage with more aggressive and surgical interventions usually reserved for stage three. Therapy for stage one includes use of artificial tears, most often preservative-free if the drop is used



**Case 3.** Above is the initial macular OCT scan of a 64-year-old black female who developed IGS nine weeks post-op in the right eye. BCVA was 20/40. Below is her macular OCT scan after 11 weeks of difluprednate 0.05% and ketorolac 0.5% therapy in the right eye. Her BCVA resolved to 20/20.



# JOIN US IN GIVING **SIGHT,** **HOPE & OPPORTUNITY**



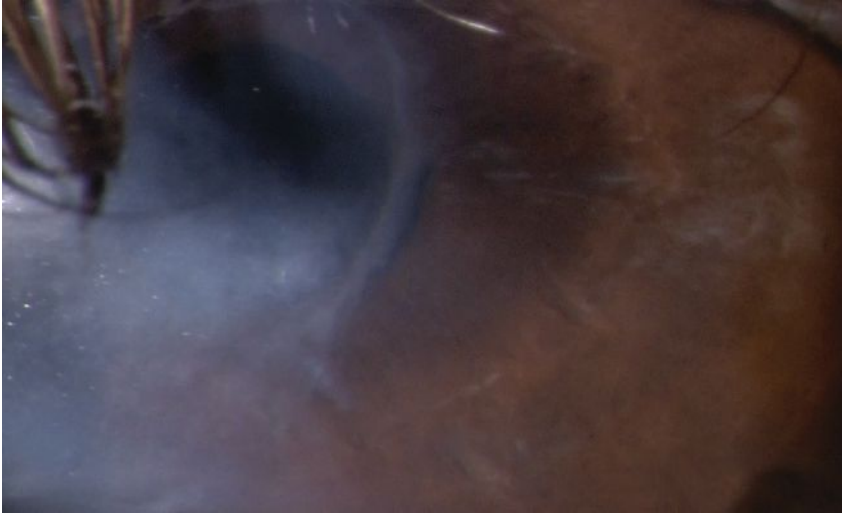
**I Care & Share** engages your patients or customers in your passion to help make eye care accessible to those in need. Your practice or company makes a donation for individual glasses or product sales. We provide you with materials to let your patients or customers know of your efforts to give back. We also make it easy for them to participate.



OPTOMETRY GIVING SIGHT  
**I CARE & SHARE**

THANK YOU FOR YOUR SUPPORT!

To get started, go to Optometry Giving Sight at [www.givingsight.org](http://www.givingsight.org)  
or contact us at: **USA** 303 526 0430 | **CANADA** 403 670 2619  
usa@givingsight.org | canada@givingsight.org



**Case 4. A 78-year-old white male with stage two NK in the left eye was successfully treated with Oxervate over a 56-day treatment course. The patient had a history of herpes zoster with persistent epithelial defects for which he underwent a partial lateral tarsorrhaphy OS. Post-Oxervate therapy, there was full epithelialization, and the tarsorrhaphy was removed 90 days later due to continued corneal health and patient interest. Special thanks to Patrick McMannamon, OD, for the case.**

frequently throughout the day to decrease preservative-induced ocular surface toxicity.

Stage two NK requires the use of corneal or scleral therapeutic contact lenses, amniotic membrane transplantation, topical autologous serum drops and topical recombinant human NGF.<sup>20,24,26</sup> One study found both amniotic membrane treatment and conventional treatment (tarsorrhaphy and a bandage contact lens) were both effective options for refractory neurotrophic corneal ulcers.<sup>27</sup>

Stage three NK often requires surgical intervention to prevent corneal perforation. In 2018, Oxervate (cenegermin-bkbj 0.002%, Dompé), a topical human NGF, was FDA approved for the treatment of NK. In a multicenter, randomized, vehicle-controlled pivotal trial, researchers found that Oxervate had statistically higher rates of corneal healing compared with the vehicle when dosed six times a day over a 56-day period.<sup>26</sup>

The complete healing of the corneal epithelium is paramount in the management of NK to prevent risk of ulceration and perforation. Management and follow up will depend on the stage of the condition and the modality of treatment instituted. For more severe cases of NK, daily follow up may be warranted—at least initially—until complete epithelial healing has occurred (*Case 4*).

## Traumatic Brain Injury

With the increased awareness of the visual sequela after a TBI, optometrists play a key role in the inter-professional management team. Approximately 2.8 million people in the United States sustained a TBI in 2013, most commonly as a result of a fall, being struck by or against an object or a motor vehicle accident.<sup>28</sup> Additionally, with US troops arriving back from the Middle East, an increased prevalence of TBI can be expected from returning active duty service members.

Optometrists are well positioned

to manage the resulting visual impairments for patients with mild TBI (mTBI), a closed head injury with loss of consciousness <30 minutes, a Glasgow Coma Score of 13 or greater, post-traumatic amnesia <24 hours, altered level of awareness <24 hours and normal neural imaging studies.<sup>29</sup> Visual symptoms of mTBI are exacerbated at near with complaints of visual acuity fluctuations, headaches and photophobia with near work.<sup>30</sup> This is not surprising given binocular vision diagnoses of accommodative dysfunction, convergence insufficiency (CI) and saccadic dysfunction have been reported most frequently in the literature.<sup>30,31</sup>

**Management.** Researchers suggest a four-tiered conceptual model for the management of mTBI to address the visual, psychological and neurological sequelae:

- **Tier 1** is the basic optometric visual examination where the patient's refractive, binocular visual system and ocular health are evaluated.<sup>32</sup>
- **Tier 2** is the detection of oculomotor-based vision problems via version, vergence and accommodative evaluation.<sup>32</sup> The abnormalities found dictate whether lenses for distance and near, vision therapy and/or prism are indicated.
- **Tier 3** is non-oculomotor based vision problems.<sup>32</sup> In this tier, the patient's spatial localization, motion sensitivity, photosensitivity, vestibular function, visual fields and visual information processing are evaluated.<sup>32</sup> Treatments for the non-oculomotor vision problems may include prism, yoked prism, tints, binasal occlusion, vision/vestibular therapy and visual information processing and perceptual therapy.<sup>32</sup>

Earn up to  
**18-29 CE**  
Credits\*

A Medscape **LIVE!** CONFERENCE

NEW TECHNOLOGIES  
& TREATMENTS IN  
**2020 EYE CARE**  
**REVIEW**  
EDUCATION GROUP



Join us for our  
**2020 MEETINGS**



» **NEW DATE**

**OCTOBER 30-NOVEMBER 1 - AUSTIN, TX**

Omni Barton Creek

Program Chair: Paul M. Karpecki, OD, FAAO

**REGISTER ONLINE:** [www.ReviewEdu.com/Austin2020](http://www.ReviewEdu.com/Austin2020)



» **NEW DATE**

**NOVEMBER 5-8 - PHILADELPHIA, PA**

Philadelphia Marriott Downtown

Joint Meeting with OCCRS\*\*

Review Program Chair: Paul M. Karpecki, OD, FAAO

OCCRS Program Chair: Tracy Schroeder Swartz, OD, MS, FAAO

**REGISTER ONLINE:** [www.ReviewEdu.com/Philadelphia2020](http://www.ReviewEdu.com/Philadelphia2020)



» **NEW DATE**

**DECEMBER 11-13 - ORLANDO, FL**

Disney's Yacht & Beach Club

Program Chair: Paul M. Karpecki, OD, FAAO

**REGISTER ONLINE:** [www.ReviewEdu.com/Orlando2020](http://www.ReviewEdu.com/Orlando2020)

For the latest information visit:

**[www.ReviewEdu.com/Events](http://www.ReviewEdu.com/Events)**

**e-mail: [ReviewMeetings@MedscapeLIVE.com](mailto:ReviewMeetings@MedscapeLIVE.com) or call: 866-658-1772**

Administered by:

**REVIEW**  
EDUCATION GROUP



\*Approval pending



SALUS UNIVERSITY  
Pennsylvania College of Optometry



\*\*17<sup>th</sup> Annual Education Symposium  
Joint Meeting with NT&T in Eye Care

Review Education Group partners with Salus University for those ODs who are licensed in states that require university credit.  
See [www.reviewedu.com/events](http://www.reviewedu.com/events) for any meeting schedule changes or updates.

- **Tier 4** addresses non-vision based problems.<sup>32</sup> The patient is screened for depression, fatigue, cognitive impairment and behavioral, postural, attention and neurological problems.<sup>32</sup> Based on pertinent concomitant issues, the patient may need evaluation and treatment by psychiatry, psychology, counseling and neurology.<sup>32</sup>

The overall success of the patient may require multiple assessments of the different aspects of the visual system, vision information processing system and inter-collaborative care with other professionals (*Case 5*).<sup>32</sup>

## Glaucoma and Ocular Hypertension

Numerous randomized clinical trials have concluded that lower IOP delays or prevents progression of primary open-angle glaucoma (POAG). The Collaborative Normal Tension Glaucoma Study found slower progression in visual field defects when IOP was lowered by 30% or more.<sup>33</sup> A faster rate of progression was noted in women, patients with migraines and those with disc hemorrhages. Notably, the untreated group was highly variable with some patients not progressing in a five-year period.<sup>33</sup>

In the Ocular Hypertension Treatment Study, researchers found topical ocular hypotensive agents were

effective in delaying or preventing onset of POAG in 50% of patients with elevated IOP when IOP was decreased by 20%.<sup>34</sup>

**Management.** With the plethora of drug classes available, optometrists can individualize therapy based on drug allergies, systemic medications and ocular diseases. Topical drugs can be classified into three categories based on how they lower IOP: by increasing aqueous outflow via the trabecular meshwork or the uveoscleral meshwork and by decreasing aqueous production.

Within the past two years, two new drugs have come to the market as possible first-line or adjunctive agents for the treatment of glaucoma and OHTN. Vyzulta (latanoprostene bunod 0.024%, Bausch + Lomb) is a dual-mechanism drug that increases uveoscleral outflow of aqueous and increases both trabecular meshwork and Schlemm's canal outflow via a nitric oxide metabolite.<sup>35</sup> In a controlled comparison study of Vyzulta and latanoprost 0.05%, researchers found a statistically significant difference in IOP lowering with Vyzulta at days seven, 14 and 28 compared with latanoprost.<sup>35</sup> Vyzulta is dosed one drop at bedtime.

Rhopressa (netarsudil 0.02%, Aerie), another new drug, is a rho kinase inhibitor with three mechanisms to lower IOP: by increasing trabecular meshwork outflow,

decreasing aqueous production and lowering the episcleral venous pressure.<sup>36,37</sup> In two phase three clinical trials, Rhopressa QD significantly lowered IOP from baseline and was found to be non-inferior to timolol.<sup>38</sup>

Additionally, in states where laser procedures are included in the optometric scope of practice, selective laser trabeculoplasty (SLT) is an effective first-line therapy when compared with conventional topical medication intervention.<sup>39</sup> In one study, first-line SLT treatment provided drop-free IOP control for at least three years and was deemed the most cost-effective first-line therapy for POAG and OHTN.<sup>39</sup>

Once a patient is diagnosed with treatable glaucomatous disease, clinicians should initiate a topical medication that is most appropriate for the patient and/or discuss SLT treatment. Follow-up is usually six to eight weeks later to determine medication/SLT efficacy (looking for a 20% to 30% decrease in IOP from highest recorded untreated IOP).

At follow up, clinicians should ensure compliance, as prescribed, and any noted side effects that may alter use and compliance. If the efficacy is unsatisfactory, follow up again six to eight weeks later to confirm poor response to the treatment regimen. Yearly structural and functional testing (visual fields and OCT), gonioscopy and optic nerve head photography are important and augment topical treatment with noted progression. With myriad topical drug classes, combinations and laser treatment options, clinicians can delay or adjust topical treatments to meet target IOP while managing practical drop schedules with the patient (*Case 6*).

If you feel that any presentation is beyond your level of comfort, don't forget about your colleagues who

### Case 5. Treat TBI With Lenses

A 45-year-old Hispanic male, a social worker, presented to the TBI clinic for evaluation of eye strain, eye pain, sensation of increased eye pressure and headaches after hitting his head on a wooden table while trying to plug in his computer. He reported limited ability in reading for a sustained period of time, although his job requires extended computer and near activities.

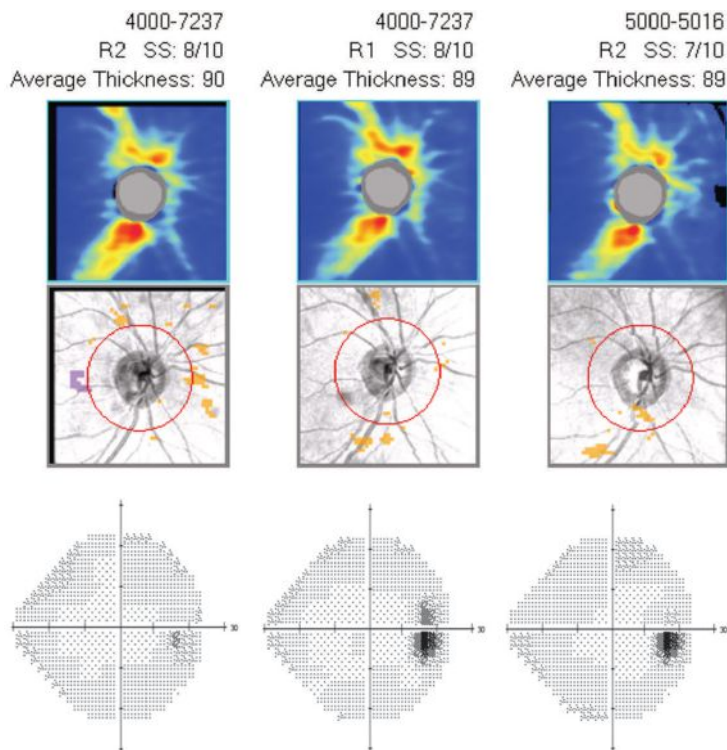
Exam findings were remarkable for CI and accommodative dysfunction in both eyes.

The patient was successfully treated with separate distance and near glasses and reported increased comfort and duration with near tasks.

This case demonstrates a Tier 2 management of mTBI with successful visual comfort with the use of lenses. *Special thanks to Siva Meiyeppen, OD, for the case.*

practice in the various optometric subspecialties who can manage those cases with you. Now more than ever, we are able to provide care to almost all of our patients by implementing the latest technologies and pharmaceuticals to help increase patients' quality of life through vision. ■

*Dr. Higa is an assistant professor at PCO-Salus, where he works with interns and residents. He has a special interest in ocular surface disease and anterior segment inflammation.*



**Case 6. This is the guided progression analysis (optic nerve head OCT) with visual fields (right eye only) of a 43-year-old black male who has been treated with Vyulta for 25 months in both eyes. IOP has decreased 40% and has been consistent at follow ups since initiating the drug. His OCT and visual fields show no change over the 25-month period, indicating successful treatment.**

- Duker JS, Kaiser PK, Binder S, et al. The International Vitreomacular Traction Study Group classification of vitreomacular adhesion, traction, and macular hole. *Ophthalmology*. 2013;120(12):2611-9.
- Coussa RG, Antaki F, Zaguia F, et al. Prognostic factors of postoperative intraretinal cystoid spaces after primary pars plana vitrectomy for vitreomacular traction. *J Curr Ophthalmol*. 2019;31(4):399-405.
- Johnson MW. Posterior vitreous detachment: evolution and complications of its early stages. *Am J Ophthalmol*. 2010;149(3):371-82.
- Sebag J. Anomalous posterior vitreous detachment: a unifying concept in vitreo-retinal disease. *Graefes Arch Clin Exp Ophthalmol*. 2004;42(8):690-8.
- Steel DH, Lotery AJ. Idiopathic vitreomacular traction and macular hole: a comprehensive review of pathophysiology, diagnosis, and treatment. *Eye*. 2013;27(1):S1-21.
- Jackson TL, Nicod E, Simpson A, et al. Symptomatic vitreomacular adhesion. *Retina*. 2013;33(8):1503-11.
- Tadayoni R, Holz FG, Zech C, et al. Assessment of anatomical and functional outcomes with ocriplasma treatment in patients with vitreomacular traction with or without macular holes: results of OVID-1 Trial. *Retina*. 2019;39(12):2341-52.
- Jackson TL, Nicod E, Angelis A, et al. Pars plana vitrectomy for vitreomacular traction syndrome: a systematic review and meta-analysis of safety and efficacy. *Retina*. 2013;33(10):2012-7.
- Irvine SR. A newly defined vitreous syndrome following cataract surgery\*: interpreted according to recent concepts of the structure of the vitreous, The Seventh Francis I. Proctor Lecture. *Am J Ophthalmol*. 1953;36(5):601-19.
- Gass JD, Norton EW. Follow-up study of cystoid macular edema following cataract extraction. *Trans Am Acad Ophthalmol Otolaryngol*. 1969;73(4):665.
- Shoss BL, Tsai LM. Postoperative care in cataract surgery. *Curr Opin Ophthalmol*. 2013;24(1):66-73.
- Chu CJ, Johnston RL, Buscombe C, et al; United Kingdom Pseudophakic Macular Edema Study Group. Risk factors and

- incidence of macular edema after cataract surgery: a database study of 81984 eyes. *Ophthalmology*. 2016;123(2):316-23.
- Ricciotti E, FitzGerald GA. Prostaglandins and inflammation. *Arteriosclerosis, thrombosis, and Vascular Biology*. 2011;31(5):986-1000.
- Ersoy L, Caramoy A, Ristau T, et al. Aqueous flare is increased in patients with clinically significant cystoid macular oedema after cataract surgery. *Br J Ophthalmol*. 2013;97(7):862-5.
- Wielders L, Schouten JSAG, Nuijts RMMA. Prevention and treatment of cystoid macular edema after cataract surgery. *Curr Opin Ophthalmol*. 2018;29(1):48-53.
- Comstock TL, DeCory HH. Advances in corticosteroid therapy for ocular inflammation: loteprednol etabonate. *Internat J Inflamm*. 2012;2012.
- Sheppard JD, Comstock TL, Cavet ME. Impact of the topical ophthalmic corticosteroid loteprednol etabonate on intraocular pressure. *Advances in Therapy*. 2016;33(4):532-52.
- Campochiaro PA, Han YS, Mir TA, et al. Increased frequency of topical steroids provides benefit in patients with recalcitrant postsurgical macular edema. *Am J Ophthalmol*. 2017;178:163-75.
- Mastropasqua L, Massaro Giordano G, Nubile M, Sacchetti M. Understanding the pathogenesis of neurotrophic keratitis: the role of corneal nerves. *J Cell Physiol*. 2017;232(4):717-24.
- Sacchetti M, Lambiase A. Diagnosis and management of neurotrophic keratitis. *Clin Ophthalmol*. 2014;8:571.
- Mackie IA. Neuroparalytic (neurotrophic) keratitis. Presented at the Symposium on Contact Lenses: Transactions of the New Orleans Academy of Ophthalmology. St Louis: Mosby; 1973.
- Semeraro F, Forbice E, Romano V, et al. Neurotrophic keratitis. *Ophthalmologica*. 2014;231(4):191-7.

- Vaidyanathan U, Hopping GC, Liu HY, et al. Persistent corneal epithelial defects: a review article. *Med Hypothesis Discov Innov Ophthalmol*. 2019;8(3):163.
- Di Zazzo A, Coassin M, Varacalli G, et al. Neurotrophic keratopathy: pros and cons of current treatments. *Ocular Surf*. 2019;17(4):619-23.
- Bonini S, Rama P, Olzi D, Lambiase A. Neurotrophic keratitis. *Eye*. 2003;17(8):989-95.
- Pflugfelder SC, Massaro-Giordano M, Perez VL, et al. Topical recombinant human nerve growth factor (cenergin) for neurotrophic keratopathy: a multicenter randomized vehicle-controlled pivotal trial. *Ophthalmology*. 2020;127(1):14-26.
- Khokhar S, Natung T, Sony P, et al. Amniotic membrane transplantation in refractory neurotrophic corneal ulcers: a randomized, controlled clinical trial. *Cornea*. 2005;24(6):654-60.
- Taylor CA, Bell JM, Breiding MJ, Xu L. Traumatic brain injury-related emergency department visits, hospitalizations, and deaths—United States, 2007 and 2013. *MMWR Surveillance Summaries*. 2017;66(9):1.
- Pinchefskey E, Dubrovsky AS, Friedman D, Shevell M. Part I—evaluation of pediatric post-traumatic headaches. *Ped Neurol*. 2015;52(3):263-9.
- Singman E, Quaid P. Vision Disorders in Mild Traumatic Brain Injury. In: Hoffer M, Balaban C, eds. *Neurosensory Disorders in Mild Traumatic Brain Injury*. Philadelphia: Academic Press; 2019:223-244. Academic Press.
- Merezhinskaya N, Mallia RK, Park D, et al. Visual deficits and dysfunctions associated with traumatic brain injury: A systematic review and meta-analysis. *Optom Vis Sci*. 2019;96(8):542-55.
- Ciuffreda KJ, Ludlam DP. Conceptual model of optometric vision care in mild traumatic brain injury. *J Behav Optom*. 2011;22(1):10-3.
- Group CN. Comparison of glaucomatous progression between untreated patients with normal-tension glaucoma and patients with therapeutically reduced intraocular pressures. *Am J Ophthalmol*. 1998;126(4):487-97.
- Kass MA, Heuer DK, Higginbotham EJ, et al. The Ocular Hypertension Treatment Study: a randomized trial determines that topical ocular hypotensive medication delays or prevents the onset of primary open-angle glaucoma. *Arch Ophthalmol*. 2002;120(6):701-13.
- Weinreb RN, Ong T, Storzolini BS, et al. A randomized, controlled comparison of latanoprostene bunod and latanoprost 0.005% in the treatment of ocular hypertension and open angle glaucoma: the VOYAGER study. *Br J Ophthalmol*. 2015;99(6):738-45.
- Wang RF, Williamson JE, Kocpozynski C, Serle JB. Effect of 0.04% AR-13324, a ROCK, and norepinephrine transporter inhibitor, on aqueous humor dynamics in normotensive monkey eyes. *J Glaucoma*. 2015;24(1):51-4.
- Kiel JW, Kocpozynski CC. Effect of AR-13324 on episcleral venous pressure in Dutch belted rabbits. *J Ocul Pharmacol Ther*. 2015;31(3):146-51.
- Serle JB, Katz LJ, McLaurin E, et al. Two phase 3 clinical trials comparing the safety and efficacy of netarsudil to timolol in patients with elevated intraocular pressure: rho kinase elevated IOP treatment trial 1 and 2 (ROCKET-1 and ROCKET-2). *Am J Ophthalmol*. 2018;186:116-27.
- Gazzard G, Konstantakopoulou E, Garway-Heath D, et al. Selective laser trabeculoplasty versus drops for newly diagnosed ocular hypertension and glaucoma: the LiGHT RCT. *Health Technol Assess*. 2019;23(31):1-102.

# MAXIMIZING OCT IN THE DIAGNOSIS AND MANAGEMENT OF GLAUCOMA

This technology has become an integral part of glaucoma care, and optometrists must understand how to accurately use it. **By Danica Marrelli, OD**

**G**laucoma can be defined as a chronic, progressive loss of retinal ganglion cells (RGCs) that results in characteristic structural—optic nerve head (ONH) and retinal nerve fiber layer (RNFL)—damage and corresponding functional (visual field) loss. Historically, clinicians relied on clinical assessment (ophthalmoscopy and fundus photography) of the ONH and RNFL to identify the structural changes. However, detecting glaucomatous changes in optic nerves can be a difficult task and one in which there is poor interobserver agreement.<sup>1-3</sup>

Over the past two decades, objective imaging with optical coherence tomography (OCT) has become increasingly important in the diagnosis of glaucoma. The diagnostic accuracy of all commercially available spectral-domain OCT instruments is similar and improves with increasing severity of the disease.<sup>4,8</sup> This activity discusses the technology and provides a practical approach to analyzing the printouts.

## OCT Scan Protocols

Although differences in scan protocols exist between manufacturers, there are three anatomic regions that

can be imaged that provide important information: the ONH, RNFL and macula.

**Optic nerve head and retinal nerve fiber layer.** The ONH/RNFL scan is presently the most popular scan protocol used in glaucoma diagnostics. The scan provides information about the ONH, including disc size/area, rim area and cup-to-disc ratio. The neuroretinal rim thickness profile is also displayed. The RNFL data typically includes a thickness map, deviation map, RNFL thickness profile and average/global, quadrant and sector/clock hour thicknesses.

**Release Date:** May 15, 2020

**Expiration Date:** May 15, 2023

**Estimated Time to Complete Activity:** 2 hours

**Jointly provided by Postgraduate Institute for Medicine (PIM) and Review Education Group**

**Educational Objectives:** After completing this activity, the participant should be better able to:

- Discuss OCT findings and common concerns with the technology.
- Use OCT to confirm a diagnosis of glaucoma.
- Follow glaucoma patients with serial macular and RNFL scans.
- Avoid common concerns related to OCT technology.

**Target Audience:** This activity is intended for optometrists engaged in the care of patients with glaucoma.

**Accreditation Statement:** In support of improving patient care, this activity has been planned and implemented by the Postgraduate Institute for Medicine and Review Education Group. Postgraduate



Institute for Medicine is jointly accredited by the Accreditation Council for Continuing Medical Education, the Accreditation Council for Pharmacy Education, and the American Nurses Credentialing Center, to provide continuing education for the healthcare team. Postgraduate Institute for Medicine is accredited by COPE to provide continuing education to optometrists.

**Faculty/Editorial Board:** Danica Marrelli, OD, University of Houston College of Optometry.

**Credit Statement:** This course is COPE approved for 2 hours of CE credit. Course ID is **67936-GL**. Check with your local state licensing board to see if this counts toward your CE requirement for relicensure.

### Disclosure Statements:

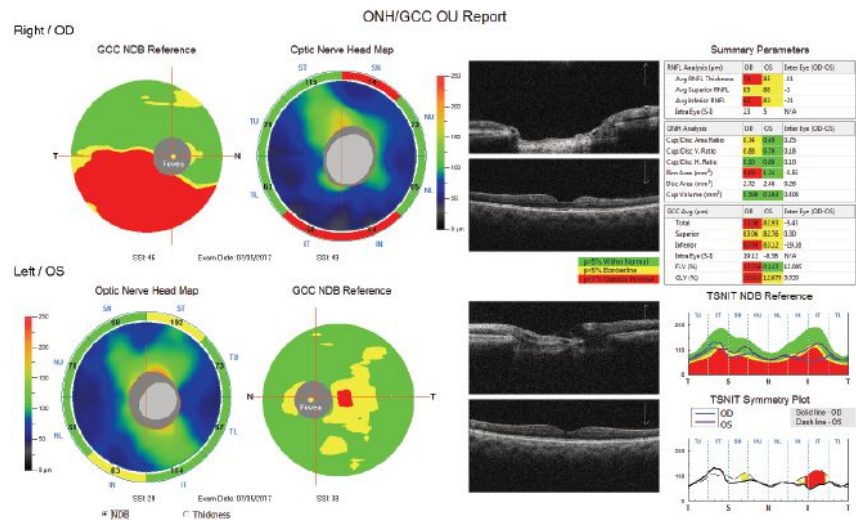
*Dr. Marrelli* has received consulting fees from Aerie, Allergan, Bausch & Lomb, Carl Zeiss Meditec and fees for non-CE/CME services from Aerie, Bausch & Lomb, Carl Zeiss Meditec.

*Managers and Editorial Staff:* The PIM planners and managers have nothing to disclose. The Review Education Group planners, managers and editorial staff have nothing to disclose.

After ensuring that the patient demographic information is correct, the first step when interpreting an ONH/RNFL scan is to ensure that it is high quality without obvious artifacts or acquisition errors. The optic disc should be well-centered within the fixed measuring circle, well illuminated and relatively free of motion artifacts (indicated by discontinuous blood vessel path or irregularly shaped optic nerve). The signal-to-noise ratio (i.e., signal strength) should be high. Since the RNFL thickness is derived from within the defined measuring circle, based on the specific machine used, it is critical that there are no black areas (indicating missing data) within the circle that will affect the average, quadrant or sector thickness measurement. After ensuring good scan quality, the clinician can move on to choosing the scan analysis and interpreting the findings.

A color-coded RNFL thickness map allows a rapid “first glimpse.” In this thickness map, warm colors (reds and oranges) represent areas of thick RNFL and cooler blues represent thinner areas. The normal thickness map will show a symmetrical hourglass or butterfly shape of thick RNFL superiorly and inferiorly correlating with the anatomical location of RNFL bundles.

Looking for symmetry is extremely important in all OCT scans in glaucoma, as asymmetry is a hallmark of early disease (*Figure 1*). A first look at symmetry can take place with the thickness map, looking to see if the thickness appears symmetric between superior and inferior thickness within each eye and between the right and left eye. Diffuse and focal (slit/wedge) RNFL loss may be identifiable as cooler colors on the thickness map. The deviation map will identify areas that are outside normal limits based on the instrument’s reference data-



**Fig. 1. This Optovue OCT scan shows thinning of the inferior RNFL (absence of “warmer” greens/yellows, and more “cool” blue inferior to the disc) and the inferior ganglion cell complex (presence of red areas below the horizontal) in the right eye. On the lower right portion of the printout, the RNFL is plotted against the normative/reference database, where the inferior RNFL of the right eye dips well into the abnormal “red” range. Below that, the symmetry plot color-codes areas of significant asymmetry between the right and left eye.**

base. Yellow pixels are considered “borderline” and represent the thinnest 5% of the reference database (only 5% of normals fall within this range) and red pixels are considered “abnormal” and represent the thinnest 1% of the normative database.

While examining the deviation map, the clinician should look for loss in areas consistent with glaucoma (superior/superotemporal and inferior/inferotemporal). RNFL thickness measurements obtained from the measuring circle are presented on the report as global/average, quadrant and sector/clock hour measurements, with the color-coded indicators of green, yellow and red for the 95%, 5% and 1% thickness percentiles of the reference database, respectively. These color codes are helpful in identifying potential problem areas, but the clinician should avoid diagnosing patients based strictly on the color maps.

Arguably the most important areas to examine on the ONH/RNFL scan are the profile curves.

These provide a visual representation of the optic nerve neuroretinal rim and RNFL thickness in a “TSNIT” pattern: starting with the temporal thickness, moving to superior, nasal, inferior and back to temporal for both rim and RNFL thickness.

Another profile map gaining popularity is the NSTIN curve, which splits the RNFL in the nasal hemifield rather than temporal to allow for better viewing of the susceptible temporal area of loss common in the macula. The neuroretinal rim profile may identify diffuse or focal rim thinning, which should correlate with the clinical examination of the optic nerve. A normal neuroretinal rim profile will usually demonstrate thicker rims inferiorly and superiorly, correlating with the “ISNT Rule” of clinical ONH assessment.

The TSNIT curve of the RNFL should show peaks superiorly and inferiorly; often the superior RNFL will show a “double hump” related to blood vessel positioning. The neuroretinal rim and RNFL profile

curves are overlaid on the reference database color coding. Dips into the yellow/red zones should arouse suspicion but, again, are not diagnostic of disease. When the profile curves of the right and left eye are superimposed, it is easy to identify areas of asymmetry. Depending on the instrument, other parameters such as disc size, rim area and cup-to-disc ratio may also be presented on the ONH/RNFL scan.

**Macula.** The newest area of interest in imaging for glaucoma diagnosis is the macula. It's long been known that glaucomatous damage can occur there.<sup>9</sup> However, these subtle changes cannot be seen on clinical exam. OCT has revolutionized our ability to evaluate and quantify macular thickness. There are several reasons to consider the macula in early glaucoma.

First, the macula is the region of the retina with the highest density of RGCs, the cells impacted by glaucomatous damage. The central 16° of

the retina contains approximately 50% of the RGCs.<sup>10,11</sup> Since glaucoma is a disease of RGCs, it makes sense to look in the area of highest ganglion cell population.

Second, unlike the optic nerve and peripapillary region, where a wide variation of normal exists, the macula is more uniform among patients, and the measurements can be more repeatable. In healthy individuals, there is greater superior/inferior symmetry of the macular thickness than that of the peripapillary RNFL, and in all individuals there is less impact of large blood vessels in the macular area compared with the RNFL. In terms of diagnostic capability, research shows the macular scans that use inner retina segmentation are comparable with RNFL scans.<sup>4</sup>

Much of our understanding of the macula in glaucoma comes from the work of Donald Hood, PhD. In an extensive body of work, his team of researchers has identified the most

likely area of early ganglion cell loss in the macula. This area, termed the “macular vulnerability zone,” is located just inferotemporal to the fovea and is commonly the site of early glaucomatous damage.<sup>12</sup>

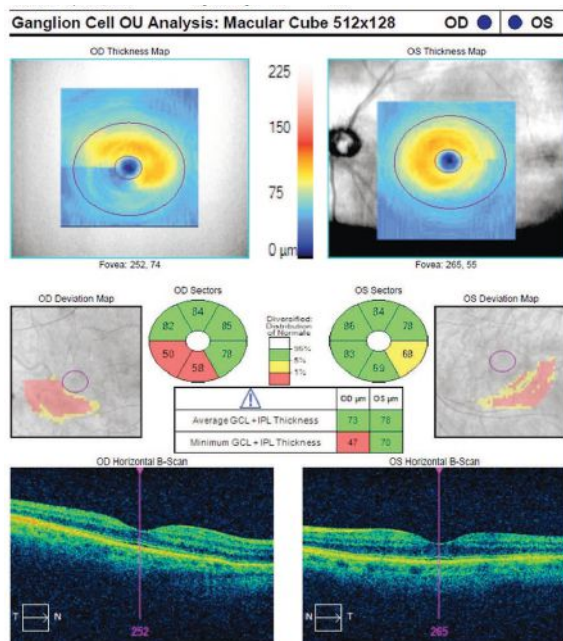
Macular scan protocols for glaucoma vary in terms of what is measured (the entire retinal thickness or only a segment of the inner retina), and if segmented, which layers are included. For example, the ganglion cell complex is a segmentation of the inner retina including the ganglion cell, inner plexiform and RNFL.

The ganglion cell analysis is a segmentation that includes only the ganglion cell and inner plexiform layers (GCIPL). Scans are centered on the fovea and the thickness may be reported as sector, average and minimum. In addition, the Heidelberg Spectralis instrument performs a detailed macular thickness symmetry analysis, comparing superior to inferior within an eye as well as thickness of right eye compared with the left eye.

A macula of normal thickness has a uniform oval appearance on the thickness map. A hallmark of glaucomatous damage to the macula appears as a distinct loss temporal to the fovea along the horizontal raphe, which is easily visible on the thickness map (*Figure 2*). This appearance has been given several nicknames, including the “squeegee sign” (because it looks as if part of the inferior macula has been wiped away) and the “nautilus” (for its similarity to a nautilus shell).

Macular OCT scans have limited usefulness for glaucoma diagnostics in the presence of macular disease, particularly disease that involves the inner retina. Macular edema, epiretinal membranes and age-related macular degeneration all alter the thickness of the macula and the capability of the instrument to segment the various layers. In patients with concomitant macular disease, macular scans are unlikely to be helpful in the diagnosis of glaucoma.<sup>13</sup>

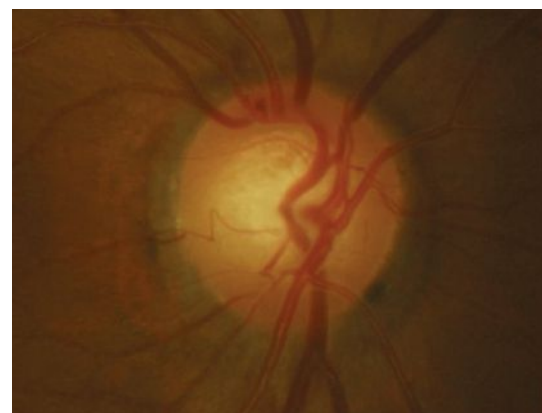
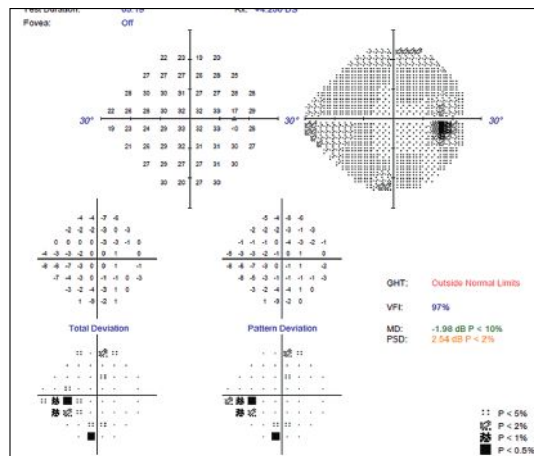
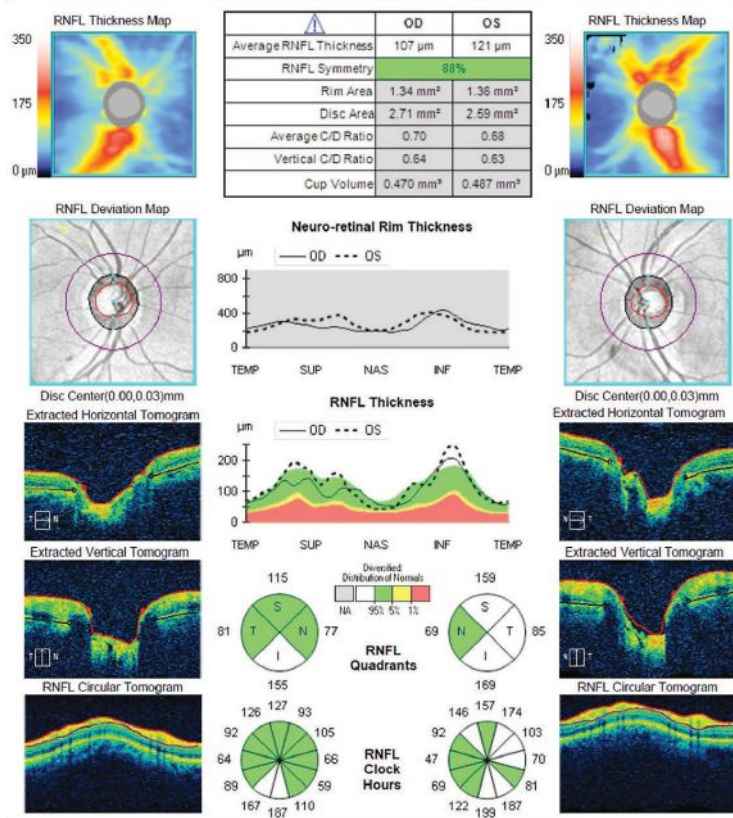
Our new understanding of the importance of macular damage in early glaucoma has necessitated a change in the way we think about perimetry. Conventional visual field testing using either the 24-2 or 30-2 testing strategy may miss or underestimate the functional loss of damage to the macular area. In these test patterns, stimulus spacing of six degrees does not allow for adequate



**Fig. 2.** This macular ganglion cell analysis scan shows the characteristic wedge-shaped loss in the inferior temporal macular vulnerability zone. Note the squeegee sign more pronounced in the right eye.



**ONH and RNFL OU Analysis: Optic Disc Cube 200x200**    OD ●    ● OS



**Fig. 3.** This OCT scan represents a case of green disease. The RNFL deviation map appears clear, and the ONH/RNFL summary table and RNFL quadrant and clock hour analyses are all in the green. However, on careful evaluation of both the thickness maps and the RNFL TSNIT profile, it is clear that the superior RNFL is thinner than the inferior RNFL in the right eye. This asymmetry is characteristic of early glaucoma. This example also shows why correlating the OCT findings with the clinical exam is important. On exam, the patient had a slightly thin superior neuroretinal rim in the right eye, and a small optic disc hemorrhage on the superior rim. In addition, there was a corresponding inferior nasal step visual field defect. Intraocular pressure, while in the statistically normal range, was consistently 3mm Hg to 4mmHg higher in the right eye on each visit.

sampling in the central area with the highest population of retinal ganglion cells.<sup>14-16</sup>

By using a test strategy that includes closer stimulus spacing (for example, the two-degree spacing of the 10-2 or the central points of new 24-2C test pattern), clinicians may be able to improve their ability to detect early functional loss related to the macular damage.<sup>9</sup>

Currently, it's not entirely clear which patients may benefit from central 10° visual field testing. In cases with glaucomatous ganglion cell loss and a normal 24-2 test, the 10° testing may be beneficial.

**The Pitfalls of OCT**

While OCT technology has greatly improved our ability to evaluate the structural loss in glaucoma, it is imperative that clinicians understand its potential pitfalls.

**Normative database.** Each instrument compares scans against a reference database of patients without ocular or systemic disease. OCT instruments provide color-coded reports to alert the clinician that a numeric value falls within or outside of the normal range relative to the reference database. Typically, green represents the top 95% thickness of the reference base and is considered

normal; white represents the very thickest of the normative database and may be normal or may represent abnormally thick RNFL (such as in optic disc swelling). Yellow is considered borderline, representing the thinnest 5% of the database, and red is considered abnormal, representing the thinnest 1% of the database.

These databases are limited in size and with regard to age, ethnicity, optic disc size and refractive error. Because of the limitations of the databases, some patients without disease will fall outside of the normal range. These patients' reports will flag them as red on the printouts.

## Non-glaucomatous Conditions

Glaucoma is not the only condition that can cause RNFL loss. Non-glaucomatous optic neuropathies—including anterior ischemic optic neuropathy (AION) and optic neuritis—and optic disc drusen may produce RNFL loss that is similar to that of glaucoma. The clinical examination of the optic nerve is paramount in differentiating such conditions.

For example, in AION, clinicians would expect optic disc pallor rather than the cupping seen in glaucoma. In some optic neuropathies, including toxic/nutritional and ethambutol-induced optic neuropathy and dominant optic atrophy, temporal RNFL thinning is a feature that can help differentiate the condition from glaucoma.<sup>32,33</sup>

Retinal conditions that affect one hemifield, such as retinal detachment and branch retinal artery and vein occlusions, may also produce superior/inferior asymmetric RNFL loss that mimics that of glaucoma. Again, the clinical examination should provide information to arrive at the appropriate diagnosis, although in the case of a chronic/resolved branch retinal artery occlusion, the clinical examination of the retina may appear quite normal. In this situation, an important OCT feature is atrophy and thinning of the inner retinal layers in the area of the occlusion, which may be seen on raster/line scans through the retina.<sup>34</sup>

The term “red disease” describes these patients who, despite being healthy, are flagged as abnormal on the OCT printout.<sup>17</sup> Red disease is a false positive, and without carefully evaluating the individual components of the scan and considering the scan in the context of the entire clinical picture, these patients may be incorrectly diagnosed and unnecessarily treated for glaucoma.

In a study of 104 normal eyes, researchers found a false positive glaucoma classification in 40.4% of eyes based on ganglion cell analysis and in 30.8% of eyes based on RNFL maps.<sup>18</sup> They found that false positive classification was associated with increased axial length and small optic disc size, a finding supported by other investigators.<sup>19,20</sup> They recommend clinicians carefully evaluate the location and pattern of loss in eyes with abnormal OCT maps.

Likewise, some patients with glaucoma will have scans in which all numeric values fall within the normal range of the reference database. These false negatives,

termed “green disease,” may result in underdiagnosis and a delay in treatment of patients with glaucoma.<sup>21</sup>

In a busy practice, it is easy to become overly reliant on the red/yellow/green color scheme to make a diagnosis of glaucoma. There are two key steps in avoiding red and green disease misdiagnosis.

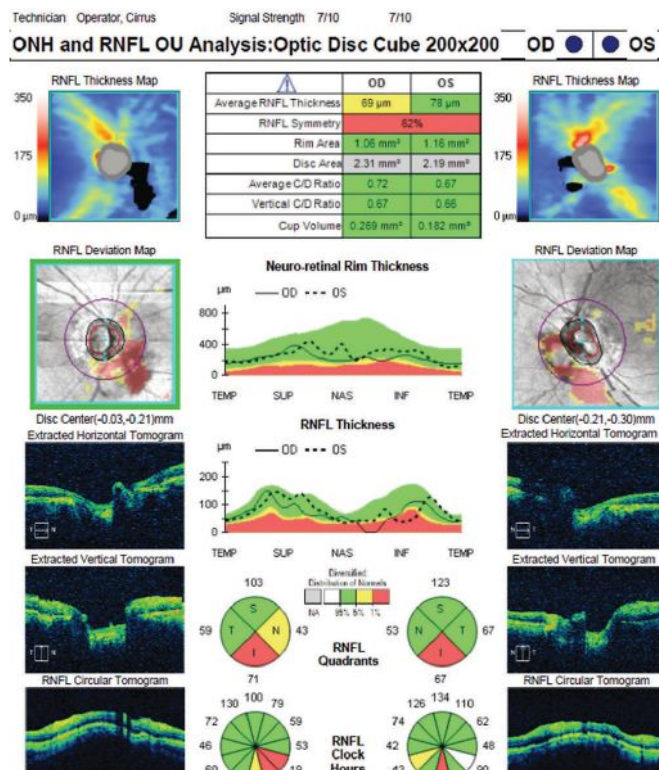
The first is to correlate the OCT findings with other clinical exam findings (*Figure 3*). The OCT should augment, not replace, the doctor’s clinical examination of the optic nerve and RNFL.

The second is to examine the scan for findings consistent with glaucoma: superior/inferior loss of neuroretinal rim and RNFL; sharply demarcated inferotemporal or superotemporal ganglion cell loss in the

macula; and asymmetry between the right and left eyes (often seen easily on the superimposed TSNIT curves).

**Artifacts.** These occur in a surprising number of RNFL and macular scans. Researchers found that 15.2% to 36.1% of RNFL and macular scans in one glaucoma clinic population had artifacts, most of which were evident on the clinical printout.<sup>22</sup> Other authors report up to 90% of scans have artifacts, although not all artifacts will have clinically significant implications, and many are not reproducible on repeat scans.<sup>13,23-25</sup> Recognizing artifacts is critical to accurately interpreting the data.

Artifacts can be classified into three categories: those related to acquisition/technician errors, ocular pathology and software (segmentation) errors.



**Fig. 4.** In this scan, large vitreous floaters in both eyes obscured the signal and created black areas within the measuring circle, which influenced the RNFL thickness measurements. In addition, note the irregular shape of the optic nerve OS and the discontinuous blood vessels in the deviation map of the left eye, indicating a motion artifact.

## Pearls & Pitfalls of OCT Interpretation

### Pearls:

- Ensure the image being interpreted is high-quality, with a well-illuminated scan and an optic nerve or fovea centered within the three-dimensional acquisition window.
- Pay careful attention to profile plots and look for asymmetry that characterizes early glaucoma.
- Correlate OCT findings with clinical examination and other results. Don't let the clinical exam become irrelevant.
- Remember that glaucomatous damage to the macula may occur early. Use both RNFL and macular scans to support a diagnosis of glaucoma. Consider a 10-2 or other central visual field test if there is significant macular damage on OCT.

### Pitfalls:

- Do not rely solely on the red/yellow/green color scheme to interpret the OCT. Not every patient will fit within the reference database parameters. Watch for false positives and false negatives (i.e., red and green disease) that may occur.
- Watch for artifacts. Acquisition errors and segmentation errors are common and can significantly impact the results of OCT. Remember that concurrent macular disease may render the macular scans unusable for glaucoma.
- Remember that there are other conditions that can cause RNFL and ganglion cell loss. High myopia, non-glaucomatous optic neuropathies and retinal disease such as vascular occlusions can mimic glaucoma on an OCT. Again, use OCT to enhance, not replace, the clinical exam.

Technician errors may include truncation of the image, such that not all of the image is included in the acquisition window. These errors will result in areas with near zero thickness and are easily recognized. Remember that the RNFL and GCIPL floor is approximately 45µm, representing residual glial and vascular tissue. Improper circle placement on ONH/RNFL scans is another potential acquisition error, although many instruments now have algorithms that make this less likely.

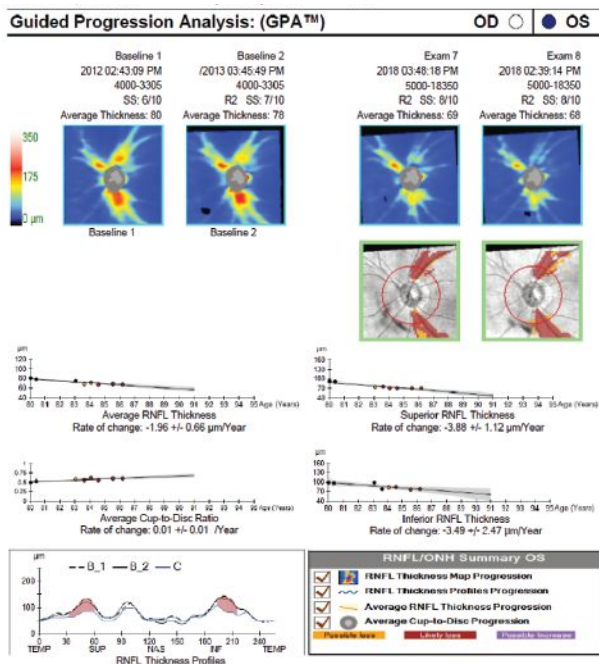
Poor signal-to-noise ratio may be due to media problems such as cataract or dry eye.<sup>26</sup> Pupil dilation and slight movement in the x- (right/left) and y- (superior/inferior) axes may allow the scan to work around central lens opacities. The use of an artificial tear immediately prior to acquisition may minimize the impact of ocular surface dryness. Train technicians to recognize these acquisition errors and to re-scan the patient to minimize their impact on interpretation.

Any ocular pathology that alters retinal thickness

may cause an artifact in a glaucoma scan protocol (*Figure 4*). The most common ocular pathology to cause artifacts is epiretinal membrane. Vitreoretinal interface disorders and epiretinal membrane may alter the thickness of the retina, as well as

diminish the instrument's ability to properly segment the retinal layers. High myopia causes thinning of both the RNFL and ganglion cell layers, and highly myopic eyes may also have anatomic features (including ONH tilting, peripapillary atrophy, myopic staphyloma and temporal RNFL bundle shifting) that may impact structural assessment of the ONH and RNFL.<sup>13,23</sup>

Software-related artifacts are primarily related to improper segmentation of the retinal layers. Poor signal strength related to media opacities and ocular surface disease may hinder the proper segmentation and impact thickness measurements. Vitreous floaters may focally obscure the signal from the retina, resulting in the inability to segment portions of the scan. Asking the patient to move their eye just prior to acquiring the scan may reposition the floaters long enough to work around them. In addition, high myopia is a frequent cause of improper segmentation in RNFL and macular scans.



**Fig. 5.** Here, event analysis shows significant change from baseline indicated by yellow and red pixels in the deviation from baseline maps (green boxes) and on the TSNIT profile. There is also visible thinning over time on the thickness maps, as the average RNFL thickness drops from 80µm to 68µm. Trend analysis shows a significant rate of change in average, superior and inferior RNFL as well as an increase in the cup-to-disc ratio.

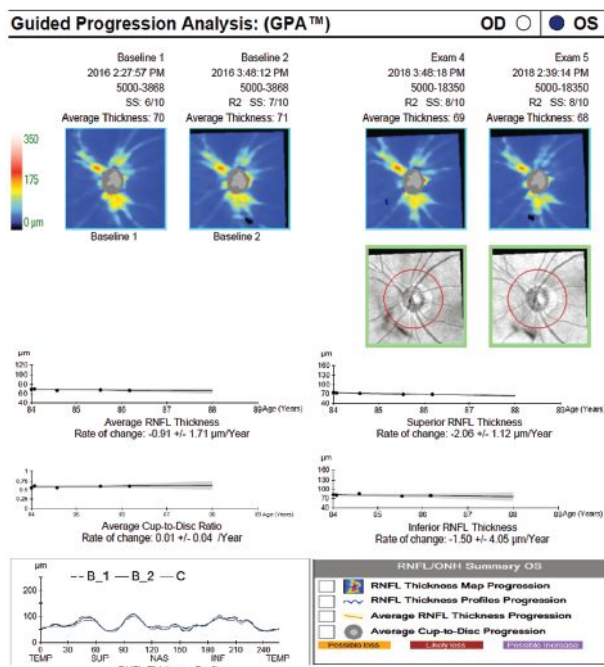
Some instruments allow for manual re-segmentation of improperly segmented scans. Recognition and, when possible, correction of segmentation errors is important for accurate interpretation of the scan.

Artifacts may be a source of red/green disease. Poor signal strength, acquisition errors, vitreous floaters and myopic RNFL thinning may result in a false positive (red or abnormal) findings. Vitreoretinal interface disorders, myelinated nerve fiber layer and optic disc edema may result in false negative (green) findings.

### Detecting Progression

Once a patient is diagnosed with glaucoma, or a glaucoma suspect has entered into a surveillance program for observation, the focus shifts from diagnosis to detecting progression. Structural progression may be detected as progressive RNFL thinning, ONH changes such as rim thinning, progressive inner macular thinning or a combination of all three. Two main strategies exist for detecting progression using OCT: event analysis and trend analysis.

In event analysis, progression is detected when the difference between a baseline and follow-up scan exceeds a predetermined amount, usually the instrument's test-retest variability (*Figure 5*). Clinicians can think of this as a snapshot in time that answers the question, "Has the patient changed significantly from baseline?" Typically, the first time a scan shows progression, it will be flagged in yellow ("possible progression"), and if the same progression is verified on a subsequent exam, the progressing area will be flagged in red ("likely progression").



**Fig. 6.** The patient in *Figure 5* was lost to follow-up and was not using his glaucoma medication. When he returned for care and drop therapy was re-initiated, the baseline was reset to the first two scans following his return. The results of both event and trend analyses show that he has remained relatively stable since re-initiation of therapy.

In general, more emphasis is placed on event analysis when there are fewer follow-up examinations (*Figure 6*). Interestingly, the most common location for progressive RNFL thinning is outside of the standard 3.4mm measuring circle. This means that some RNFL thinning may be identified on the thickness change map but not on the serial analysis of the circumpapillary RNFL thickness measurements, necessitating analysis of the entire scan, not one particular parameter.<sup>27</sup>

Trend analysis provides regression analysis between a given parameter and time. Progression is defined as a significant negative slope of the parameter in question. This slope can be considered a surrogate for the rate of change of the disease. Average and hemifield RNFL thickness measurements, cup-to-disc ratio and inner macula thickness can all be analyzed

this way. Color indicators note when rates of change reach statistical significance.

When analyzing an OCT for progression, clinicians should remember that current OCT progression analysis software does not account for the normal age-related thinning of RNFL and macula. A number of studies have investigated the rate of RNFL loss in both healthy and glaucomatous eyes. One study showed that the average RNFL in healthy subjects changed at a rate of  $-0.48 \text{ m}/\text{year}$ , while the RNFL of glaucoma patients changed at a rate of  $-0.98 \text{ m}/\text{year}$ .<sup>28</sup>

In this study, rates of RNFL change were more rapid than that of GCIPL change. Other researchers found that accounting for age-related loss significantly impacted the percentage of patients determined to be progressing.<sup>29</sup> Research also shows that failure to consider age-related thinning resulted in significant false positive identification of progression.<sup>30</sup>

In addition to age-related loss, clinicians should consider the severity of the disease. The ability of OCT to detect RNFL thinning diminishes in more advanced disease, as the RNFL measurement reaches the floor effect. Inner macular thickness, however, is often more useful for progression detection in advanced disease, as more GCIPL is likely to remain above the measurement floor for a longer period of time.<sup>29</sup>

Finally, a positive correlation exists between signal-to-noise ratio and RNFL thickness, so consider the scan quality (particularly compared with baseline) when evaluating for possible progression.

Always confirm suspected progression with repeat testing. If

progression is confirmed, clinicians still have several decisions to make. First, they must decide if any statistically significant change is clinically relevant. Life expectancy and disease severity may play a role. For example, a change (or rate of change) that is alarming in a younger patient with moderate disease might be less clinically meaningful in an older patient with mild disease.

In addition to the clinical relevance of a change, the optometrist should consider whether the change is consistent with glaucoma or if there is another explanation for the change, such as cataract formation. If the change is deemed glaucomatous, other considerations include the time it took to reach that change (rate of progression), what the intraocular pressure and medication adherence was during that time period and the impact of the next intervention (additional medication, laser or incisional surgery) on the patient's quality of life.

OCT helps detect progression, but clinicians must carefully decide what to do with all the information at their disposal.<sup>31</sup> Finally, if a therapeutic change is warranted due to progression, the clinician must reset the baseline of both structural and functional testing to follow for progression from the point of the therapeutic intervention.

OCT has revolutionized our ability to qualitatively and quantitatively

assess the optic nerve, RNFL and macular changes that occur in glaucoma. It has become indispensable in our decision-making in glaucoma and other diseases. By understanding the technology, its abilities and potential pitfalls, optometrists can be well prepared to use this tool in the diagnosis and management of glaucoma. ■

*Dr. Marrelli is a clinical professor and assistant dean of Clinical Education of the Ocular Diagnostic and Medical Eye Service at the University of Houston College of Optometry.*

- Breusegem C, Fieus S, Stalmans I, et al. Agreement and accuracy of non-expert ophthalmologists in assessing glaucomatous changes in serial stereo optic disc photographs. *Ophthalmology*. 2011;118(4):742-6.
- Azuara-Blanco A, Katz LJ, Spaeth GL, et al. Clinical agreement among glaucoma experts in the detection of glaucomatous changes of the optic disk using simultaneous stereoscopic photographs. *Am J Ophthalmol*. 2003;136(5):949-50.
- Varma R, Steinmann WC, Scott IU. Expert agreement in evaluating the optic disc for glaucoma. *Ophthalmology*. 1992;99(2):215-21.
- Kansal V, Armstrong JJ, Pintwala R, et al. Optical coherence tomography for glaucoma diagnosis: An evidence based meta-analysis. *PLoS One*. 2018;13(1):e0190621.
- Mwanza JC, Durbin MK, Budenz DL, et al. Glaucoma Diagnostic accuracy of ganglion cell-inner plexiform layer thickness: comparison with nerve fiber layer and optic nerve head. *Ophthalmology*. 2012;119(6):1151-8.
- Fallon M, Valero O, Pazos, M, et al. Diagnostic accuracy of imaging devices in glaucoma: a meta-analysis. *Surv Ophthalmol*. 2017;62(4):446-61.
- Oddone F, Lucenteforte E, Michelessi M, et al. Macular versus retinal nerve fiber layer parameters for diagnosing manifest glaucoma: a systematic review of diagnostic accuracy studies. *Ophthalmology*. 2016;123(5):939-49.
- Sullivan-Mee M, Ruegg CC, Pensyl D, et al. Diagnostic precision of retinal nerve fiber layer and macular thickness asymmetry parameters for identifying early primary open-angle glaucoma. *Am J Ophthalmol*. 2013;156(3):567-77.
- Hood DC, Raza AS, de Moraes CG, et al. Glaucomatous damage of the macula. *Prog Retin Eye Res*. 2013;32:1-21.
- Curcio CA, Allen KA. Topography of ganglion cells in human retina. *J Comp Neurol*. 1990;300(1):5-25.
- De Moraes CG, Song C, Liebmann JM, et al. Defining 10-2 visual field progression. *Ophthalmology*. 2014;121(3):741-9.
- Hood DC. Improving our understanding, and detection, of glaucomatous damage: An approach based upon optical coherence tomography (OCT). *Prog Retin Eye Res*. 2017;57:46-75.
- Wong JJ, Chen TC, Shen LG, et al. Macular imaging for glaucoma using spectral-domain optical coherence tomography: a review. *Semin Ophthalmol*. 2012;27(5-6):160-6.
- Hood DC, Raza AS, de Moraes CG, et al. The nature of macular damage in glaucoma as revealed by averaging optical coherence tomography data. *Trans Vis Sci Tech*. 2012;1(1):3.
- Traynis I, De Moraes CG, Raza AS, et al. Prevalence and nature of early glaucomatous defects in the central 10° of the visual field. *JAMA Ophthalmol*. 2014;132(3):291-7.
- Grillo LM, Wang DL, Ramachandran R, et al. The 24-2 visual field test misses central macular damage confirmed by the 10-2 visual field test and optical coherence tomography. *Trans Vis Sci Tech*. 2016;5(2):15.
- Chong GT, Lee RK. Glaucoma versus red disease: imaging and glaucoma diagnosis. *Curr Opin Ophthalmol*. 2012;23(2):79-88.
- Kim KE, Jeoung JW, Park KH, et al. Diagnostic classification of macular ganglion cell and retinal nerve fiber layer analysis differentiation of false positives from glaucoma. *Ophthalmology*. 2015;122(3):502-10.
- Seo S, Lee CE, Jeong JH, et al. Ganglion cell-inner plexiform layer and retinal nerve fiber layer thickness according to myopia and optic disc area: a quantitative and three-dimensional analysis. *BMC Ophthalmol*. 2017;17(1):22.
- Yamashita T, Sakamoto T, Yoshihara N, et al. Correlations between retinal nerve fiber layer thickness and axial length, peripapillary retinal tilt, optic disc size, and retinal artery position in healthy eyes. *J Glaucoma*. 2017;26(1):34-40.
- Sayed MS, Margolis M, Lee RK. Green disease in optical coherence tomography diagnosis of glaucoma. *Curr Opin Ophthalmol*. 2017;28(2):139-53.
- Asrani S, Essaid L, Alder BD, et al. Artifacts in spectral-domain optical coherence tomography measurements in glaucoma. *JAMA Ophthalmol*. 2014;132(4):396-402.
- Awadalla MS, Fitzgerald J, Andrew NH, et al. Prevalence and type of artefact with spectral domain optical coherence tomography macular ganglion cell imaging in glaucoma surveillance. *PLoS One*. 2018;13(12):e0206684.
- Hwang YH, Kim MK, Kim DW. Segmentation errors in macular ganglion cell analysis as determined by optical coherence tomography. *Ophthalmology*. 2016;123(5):950-8.
- Liu Y, Simavli H, Que CJ, et al. Patient characteristics associated with artifacts in Spectralis optical coherence tomography imaging of the retinal nerve fiber layer in glaucoma. *Am J Ophthalmol*. 2015;159(3):565-76.
- Hardin JS, Taibbi G, Nelson SC, et al. Factors affecting Cirrus-HD OCT optic disc scan quality: a review with case examples. *J Ophthalmol*. 2015;74:6150.
- Leung CK. Diagnosing glaucoma progression with optical coherence tomography. *Curr Opin Ophthalmol*. 2014;25(2):104-11.
- Hammel N, Belghith A, Weinreb RN, et al. Comparing the rates of retinal nerve fiber layer and ganglion cell-inner plexiform layer loss in healthy eyes and in glaucoma eyes. *Am J Ophthalmol*. 2017;178:38-50.
- Leung CKS, Ye C, Weinreb RN, et al. Impact of age-related change of retinal nerve fiber layer and macular thickness on evaluation of glaucoma progression. *Ophthalmology*. 2013;120(12):2485-92.
- Wu Z, Saunders LJ, Zangwill LM, et al. Impact of normal aging and progression definitions on the specificity of detecting retinal nerve fiber layer thinning. *Am J Ophthalmol*. 2017;181:106-13.
- Weinreb RN, Garway-Heath DF, Leung C, et al, eds. *World Glaucoma Association Consensus Series 8: Progression of Glaucoma*. Kugler Publications; 2011.
- Rosdahl JA, Asrani S. Glaucoma masqueraders: diagnosis by spectral domain optical coherence tomography. *Saudi J Ophthalmol*. 2012;26(4):433-40.
- Psol J. Neuro-ophthalmic disease and optical coherence tomography: glaucoma look-alikes. *Curr Opin Ophthalmol*. 2011;22(2):124-32.
- Rodrigues IA. Acute and chronic spectral domain optical coherence tomography features of branch retinal artery occlusion. *BMJ Case Rep*. 2013;2013:bcr2013009007.

## OSC QUIZ

**Y**ou can obtain continuing education credit through the Optometric Study Center. Complete the test form and return it with the \$35 fee to: Jobson Healthcare Information, LLC, Attn.: CE Processing, 395 Hudson Street, 3rd Floor New York, New York 10014. To be eligible, please return the card within three years of publication. You can also access the test form and submit your answers and payment via

credit card at *Review Education Group* online, [revieweducationgroup.com](http://revieweducationgroup.com). You must achieve a score of 70 or higher to receive credit. Allow four weeks for processing. For each Optometric Study Center course you pass, you earn 2 hours of credit from Pennsylvania College of Optometry.

Please check with your state licensing board to see if this approval counts toward your CE requirement for relicensure.

- Which of these is not typical of glaucoma?
  - Uniform damage 360° around the optic nerve.
  - Asymmetric damage between superior and inferior poles of the optic nerve.
  - Asymmetric damage between right and left eyes.
  - Visual field defects that correlate to optic nerve damage.

## OSC QUIZ

2. A large optic nerve (large vertical disc diameter) is more likely to have:

- An average cup-to-disc ratio.
- A large cup-to-disc ratio.
- A small cup-to-disc ratio.
- It is impossible to predict.

3. The thickest portion of the optic nerve neuroretinal rim in a healthy/normal individual is usually:

- Temporal.
- Nasal.
- Superior.
- Inferior.

4. In a typical commercial SD-OCT, the green shading of a particular parameter means:

- The patient must be normal.
- The patient is within the top 90% to 95% compared with the normative reference database of the machine.
- The patient definitely does not have glaucoma.
- None of the above.

5. Red disease refers to:

- False positive (identification of a normal patient as abnormal).
- False negative (identification of a glaucomatous patient as normal).
- It depends on the instrument.
- None of the above.

6. Which of the following represents a disease that can impact the interpretation of the retinal nerve fiber layer on an SD-OCT?

- Optic disc drusen.
- Branch retinal vein occlusion.
- Ischemic optic neuropathy.
- All of the above.

7. Which of the following are advantages of macular SD-OCT in the diagnosis of glaucoma over the peripapillary RNFL?

- Less impact from other anatomic components such as blood vessels.
- More uniform anatomy in the macula compared with the peripapillary RNFL.
- Better superior/inferior symmetry and right/left symmetry of the macula compared with the RNFL.
- All of the above.

8. All of these are true about event analysis in looking for progression, except:

- It compares each test with the baseline

test and alerts when there has been a significant change.

- It detects significant change that is greater than the test-retest variability of the instrument.
- It calculates a slope (rate of change).
- It can be used earlier in disease follow-up than trend analysis.

9. Which type of analysis determines a rate of change?

- Event analysis.
- Trend analysis.
- Both event analysis and trend analysis.
- Neither event analysis nor trend analysis.

10. If structural change is suspected on an SD-OCT scan, what is the next step?

- Immediately increase therapy.
- Repeat the scan to confirm or refute the suspected change.
- Confirm the structural change with a functional (visual field) test.
- None of the above.

11. The RNFL is thickest and shows the brightest reflectivity on SD-OCT in which sectors?

- Inferior/superior.
- Nasal/temporal.
- Inferior/nasal.
- Superior/temporal.

12. In patients who show areas of macular ganglion cell loss but don't show RNFL loss, which visual field test may be better able to detect visual field loss?

- 30-2.
- 24-2.
- 10-2.
- 120-point screening.

13. The area of the macula most likely to show ganglion cell loss in glaucoma has been termed "the macular vulnerability zone," which is located:

- Inferior temporal to fovea.
- Inferior nasal to fovea.
- Superior temporal to fovea.
- Superior nasal to fovea.

14. Which statement is true regarding artifacts on an SD-OCT?

- All artifacts have clinically significant impact on the interpretation.
- Technician error is always unavoidable.
- All commercially available instruments

allow for manual re-segmentation of a segmentation error.

d. Artifacts may be a source of red disease.

15. The most common pathology to cause a retinal artifact on an SD-OCT scan is:

- Epi-retinal membrane.
- Choroidal nevus.
- Large optic disc.
- Small optic disc.

16. When should a baseline be reset?

- When a patient has suspected progression on an OCT.
- When therapy is amplified due to confirmed progression.
- Every two years irrespective of progression.
- When the clinician is not happy with the rate of change.

17. When deciding whether or not to amplify therapy after confirming structural progression, which of the following should be considered?

- The time it took for the change to occur in correlation with the patient's demographics.
- The intraocular pressure during the time of progression.
- The impact of the next intervention.
- All of the above.

18. False positive glaucoma classification with SD-OCT has been associated with:

- Increased axial length.
- Large optic disc.
- Hyperopia.
- All of the above.

19. Which of the following is an SD-OCT finding consistent with the diagnosis of glaucoma?

- Asymmetry of RNFL or ganglion cell thickness between right and left eye.
- Asymmetry between superior and inferior RNFL within an eye.
- A sharply demarcated inferotemporal or superotemporal ganglion cell loss.
- All of the above.

20. Which of the following is true regarding progression detection in SD-OCT?

- The OCT instruments factor in age-related loss in their progression software.
- RNFL thinning is more difficult to detect in more advanced disease.

# Examination Answer Sheet

## Maximizing OCT in the Diagnosis and Management of Glaucoma

Valid for credit through May 15, 2023

**Online:** This exam can be taken online at [revieweducationgroup.com](http://revieweducationgroup.com). Upon passing the exam, you can view your results immediately and download a real-time CE certificate. You can also view your test history at any time from the website.

**Directions:** Select one answer for each question in the exam and completely darken the appropriate circle. A minimum score of 70% is required to earn credit.

**Mail to:** Jobson Healthcare Information, LLC, Attn.: CE Processing, 395 Hudson Street, 3rd Floor New York, New York 10014

**Payment:** Remit \$35 with this exam. Make check payable to Jobson Healthcare Information, LLC.

**Credit:** This course is COPE approved for 2 hours of CE credit. Course ID is 67936-GL.

**Jointly provided by Postgraduate Institute for Medicine and Review Education Group.**

**Salus University has sponsored the review and approval of this activity.**

**Processing:** There is a four-week processing time for this exam.

### Answers to CE exam:

1.  A  B  C  D
2.  A  B  C  D
3.  A  B  C  D
4.  A  B  C  D
5.  A  B  C  D
6.  A  B  C  D
7.  A  B  C  D
8.  A  B  C  D
9.  A  B  C  D
10.  A  B  C  D
11.  A  B  C  D
12.  A  B  C  D
13.  A  B  C  D
14.  A  B  C  D
15.  A  B  C  D
16.  A  B  C  D
17.  A  B  C  D
18.  A  B  C  D
19.  A  B  C  D
20.  A  B  C  D

### Post-activity evaluation questions:

Rate how well the activity supported your achievement of these learning objectives:

1=Poor, 2=Fair, 3=Neutral, 4=Good, 5=Excellent

21. Discuss OCT findings and common concerns with the technology.

1  2  3  4  5

22. Use OCT to confirm a diagnosis of glaucoma.

1  2  3  4  5

23. Follow glaucoma patients with serial macular and RNFL scans.

1  2  3  4  5

24. Avoid common concerns related to OCT technology.

1  2  3  4  5

25. Based upon your participation in this activity, do you intend to change your practice behavior? (choose only one of the following options)

A I do plan to implement changes in my practice based on the information presented.

B My current practice has been reinforced by the information presented.

C I need more information before I will change my practice.

26. Thinking about how your participation in this activity will influence your patient care, how many of your patients are likely to benefit? (please use a number):

27. If you plan to change your practice behavior, what type of changes do you plan to implement? (check all that apply)

- a Apply latest guidelines  b Change in pharmaceutical therapy  c Choice of treatment/management approach  
 d Change in current practice for referral  e Change in non-pharmaceutical therapy  f Change in differential diagnosis  g Change in diagnostic testing  h Other, please specify: \_\_\_\_\_

28. How confident are you that you will be able to make your intended changes?

- a Very confident  b Somewhat confident  c Unsure  d Not confident

Please retain a copy for your records. Please print clearly.

First Name

Last Name

E-Mail

The following is your:  Home Address  Business Address

Business Name

Address

City  State

ZIP

Telephone #  -  -

Fax #  -  -

By submitting this answer sheet, I certify that I have read the lesson in its entirety and completed the self-assessment exam personally based on the material presented. I have not obtained the answers to this exam by any fraudulent or improper means.

Signature \_\_\_\_\_ Date \_\_\_\_\_

Lesson 119701

RO-OSC-0520

29. Which of the following do you anticipate will be the primary barrier to implementing these changes?

- a Formulary restrictions  
 b Time constraints  
 c System constraints  
 d Insurance/financial issues  
 e Lack of interprofessional team support  
 f Treatment related adverse events  
 g Patient adherence/compliance  
 h Other, please specify: \_\_\_\_\_

30. Additional comments on this course:

\_\_\_\_\_  
\_\_\_\_\_  
\_\_\_\_\_  
\_\_\_\_\_

Rate the quality of the material provided:

1=Strongly disagree, 2=Somewhat disagree, 3=Neutral, 4=Somewhat agree, 5=Strongly agree

31. The content was evidence-based.

1  2  3  4  5

32. The content was balanced and free of bias.

1  2  3  4  5

33. The presentation was clear and effective.

1  2  3  4  5



# Patient, Heal Thyself

When contact lens wear leads to limbal stem cell deficiency, you may be able to turn to autologous serum tears for help. **Edited by Joseph P. Shovlin, OD**

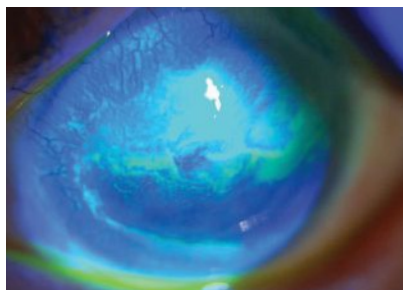
**Q** My patient has had a partial limbal stem cell deficiency (LSCD) following soft contact lens (CL) wear for several decades. I have treated her with a few options with minimal improvement. Should I consider autologous serum tears?

**A** LSCD occurs when there is loss of or damage to LSCs or the microenvironment that promotes their survival, according to Katelyn Lucas, OD, of Price Vision Group in Indianapolis. She notes that LSCs are required for corneal epithelialization to maintain surface integrity and corneal transparency.

## The Breakdown

Dr. Lucas notes that partial/sectoral LSCD occurs when a section of the limbus is involved, typically the superior limbus, and can be managed by improving the ocular surface to provide a livable environment for LSCs. Total/diffuse LSCD typically results in surgery, as no LSCs are present to repopulate the corneal epithelium. Primary causes of LSCD result from congenital or genetic disorders, while secondary causes are due to ocular surface disorders or external factors, including CL wear.<sup>1</sup>

The cause of CL-induced LSCD is likely multifactorial, with potential factors including hypoxia, disinfecting solution, mechanical trauma and dry eye.<sup>2</sup> These cases are easily overlooked, says Dr. Lucas, as they are typically mild and patients are usually asymptomatic. It is estimated that up to 5% of CL wearers develop signs of LSCD, with the



**Superior epitheliopathy extends centripetally in a whorl pattern in LSCD secondary to chemical burn.**

majority being soft CL users.<sup>2</sup> Dr. Lucas recommends conducting a thorough slit lamp exam, as punctate staining may be the only early sign.

Many CL-induced LSCD cases can be reversed with the cessation of CL use, says Dr. Lucas, adding that dry eye therapy can help improve the ocular surface. When conservative therapy is not enough, she suggests considering topical vitamin A, punctal plugs, topical anti-inflammatory meds or autologous serum tears. She warns that severe CL-induced LSCD may require surgical management with autologous or allograft LSC transplantation.

## The Process

Autologous serum tears contain a variety of factors that help epithelial cells with proliferation, differentiation and maturation.<sup>3</sup> Dr. Lucas notes that concentrations range from 20% to 100%, and dosages can be anywhere from BID to hourly depending on severity. When initially prescribing serum tears, she typically starts with a 20% concentration

dosed four to six times daily. If signs and/or symptoms don't improve or the initial presentation is more severe, she advises prescribing a higher concentration.

Long-term use of concentrations above 50% may slow epithelial growth and increase scarring and inflammation due to serum pro-inflammatory factors.<sup>3</sup> Dr. Lucas notes that lower concentrations may be used for years if the patient continues to improve. If LSCD resolves, she recommends discontinuing serum tear use and continuing with conservative therapy to promote a healthy environment for LSCs.

After the patient has blood drawn, Dr. Lucas says they can then take their vials to a compounding pharmacy or a company that partners with local labs. To prevent contamination and degradation, serum tears need to be refrigerated or kept frozen until needed. In diabetes patients, finger-prick autologous blood is a low-cost, accessible alternative.

CL-induced LSCD can be difficult to diagnose due to its subclinical, asymmetric presentation. Clinicians must carefully examine their CL patients, as early intervention can help restore LSC health. When met with challenges in the LSCD management, autologous serum tears are a great tool to treat refractory ocular surface disease. ■

1. Le Q, Xu J, Deng SX. Review: the diagnosis of limbal stem cell deficiency. *Ocul Surf.* 2018;16(1):58-69.  
2. Rossen J, Amram A, Milani B, et al. Contact lens-induced limbal stem cell deficiency. *Ocul Surf.* 2016;14(4):419-34.  
3. Yeh SI, Chu TW, Cheng HC, et al. The use of autologous serum to reverse severe contact lens-induced limbal stem cell deficiency. *Cornea.* January 24, 2020. [Epub ahead of print].



Earn up to  
**19 CE**  
Credits\*

A Medscape **LIVE!** CONFERENCE

NEW TECHNOLOGIES  
& TREATMENTS IN  
**2020 EYE CARE**  
**REVIEW**  
EDUCATION GROUP



# Austin, Texas

October 30 - November 1, 2020  
at the Omni Barton Creek

*Review's* New Technologies & Treatments in Eye Care proudly presents Austin 2020!  
Join us for three days of education detailing the latest ideas and innovations in eye care.

**Register before September 4 for Early Bird discount.**



**PROGRAM CHAIR**  
Paul M. Karpecki, OD, FFAO

**LOCATION:**

**Omni Barton Creek**  
8212 Barton Club Drive  
Austin, TX 78735  
(512) 329-4000

A limited number of rooms have been reserved at the group rate of \$275/night + tax and fees.  
Call the hotel directly at the number above and identify yourself as a participant of "Review's New Tech" for group rate.

**REGISTRATION COST:**

**Early Bird Special: \$420**  
**Full Conference after September 4: \$495**

See event website for daily fees.

**THREE WAYS TO REGISTER:**  
**[www.ReviewEdu.com/Austin2020](http://www.ReviewEdu.com/Austin2020)**

Call: 866-658-1772 or E-mail: [ReviewMeetings@MedscapeLIVE.com](mailto:ReviewMeetings@MedscapeLIVE.com)

Administered by:



\*Approval pending



Pennsylvania College of Optometry

Partially supported by an unrestricted  
educational grant from:

**Novartis**

Review Education Group partners with Salus University for those ODs who are licensed in states that require university credit.



# Track the Hill of Vision

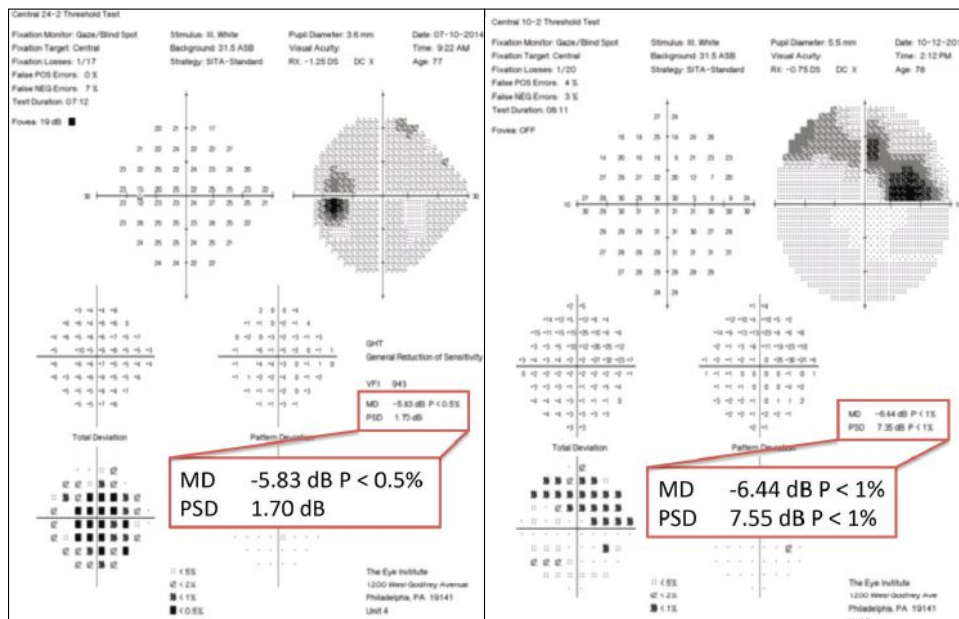
The visual field mean deviation is key when assessing glaucomatous changes.

By Bisant A. Labib, OD

**G**laucoma is a progressive optic neuropathy characterized by retinal nerve fiber layer loss with or without subsequent visual field (VF) damage. Both the diagnosis and management of glaucoma is largely dependent on the patient's VF tests.<sup>1,2</sup> Deciding when to initiate or change treatment is determined by a number of different factors, one of the most important being the interpretation of various aspects of the patient's VF testing. However, interpreting a VF printout can be daunting, with several elements to evaluate and consider. An easy and important index to keep track of is the mean deviation (MD).

## VF Basics

Automated VF perimetry is a standard test that clinicians can use to evaluate the presence and progression of glaucomatous defects, most commonly using the Humphrey



**At left, the 24-2 VF shows one centrally depressed point, which manifests as a larger defect on the 10-2 VF, at right, due to higher resolution and more central field. The MDs are similar but slightly worse on the 10-2 VF due to larger defect detected with higher resolution.**

Field Analyzer. The most common VF test employed for glaucoma patients and glaucoma suspects is the 24-2 test. This measures the central 24 degrees of field, consisting of a total of 54 test points, each separated by six degrees.

In the setting of severe visual loss, or even in cases of early macu-

lar glaucoma, a 10-2 may replace or supplement the 24-2 test. In contrast to the 24-2, the 10-2 test measures the central 10 degrees of fixation with higher resolution, consisting of a total of 68 test points separated by two degrees. Assessing the central 10 degrees of fixation in standard 24-2 testing would be of little value, as it is only represented by 12 overall points.<sup>2</sup>

Before performing any VF interpretation, clinicians must first evaluate the test for accuracy. The three indices that determine reliability are fixation losses, false positives and false negatives. Generally speaking, the arbitrary cutoff values are set at 33% for false negatives and

## Visual Field Index

A similar measurement that is often used in correlation with the MD is the visual field index (VFI). The VFI was developed to better establish changes in glaucoma patients and address the drawbacks of the MD. While the MD is measured as a decibel value, the VFI is a percentage relative to the sensitivity of a reference group of healthy observers.

For example, a healthy patient with no vision loss and a full field would have a VFI of 100%. Unlike the MD, the VFI disregards general reductions in sensitivity associated with cataracts or refractive errors, unless they are associated with pattern deviations outside the normal range.<sup>8</sup>

false positives and 20% for fixation loss.<sup>3</sup> Once clinicians determine that the test is valid, they can use the VF readout for clinical management.

## Mean Deviation

While there are several useful aspects of a VF printout, the MD is one of the most important. The MD is the average, point-wise difference between a given test result and the normal, age-matched reference value.<sup>1</sup> This value is derived from the total deviation plot and indicates the overall depression or elevation of a patient's hill of vision. For example, a patient with a positive MD value will have a better than normal hill of vision (which could occur simply because the patient's VF is better than the normative database, or in a patient with excessively high false positives), whereas a patient with a very low MD will have a decreased hill of vision, indicating pathology.<sup>4</sup>

Identifying if a patient's visual field is truly progressing is a multifactorial process that can be challenging. Many patients may exhibit progressive VF loss in the absence of clear, structural optic nerve changes.<sup>5</sup> In addition, VF results can be inconsistent, making it difficult to discern a clinically significant progression compared with regular test variability.

To help improve visual field testing consistency, clinicians should perform at least six VF tests in the first two years after a patient is diagnosed with glaucoma to establish baseline reliability and rule out rapid progression.

Using MD values can be an important tool in these cases. A rapid rate of progression based only on the MD is established at more than -2dB per year. The less decrease in the MD over time, the better the chance of maintaining

## MD Beyond Glaucoma

The MD, an easily identified value on a standard VF printout, can provide a significant amount of information to aid in the management and treatment of glaucoma patients. It can also help clinicians measure possible progression in other ocular disorders. For example, research shows MD can help clinicians determine visual outcome in patients with papilledema secondary to idiopathic intracranial hypertension—patients with low MD values at initial presentation had a more favorable visual outcome.<sup>9</sup>

Additionally, comparison of MD values between the two eyes can be an excellent predictor of the presence of an afferent pupillary defect (APD).<sup>10</sup> The greater the difference in MD values, the larger the grade of the APD when observed clinically. In the same manner, glaucoma patients who present clinically with an APD will have more asymmetric VF loss.<sup>11</sup>

visual outcome.<sup>1</sup> MD is also a measure used in clinical trials to determine drug efficacy. For example, one study comparing timolol and brimonidine treatments concluded that they were both similarly efficacious by comparing study participants' MD slopes in their VFs over time as an outcome measure.<sup>6</sup>

Reliability of a VF test can also affect the MD value. The greater the percentage of false negatives—which may be increased in glaucoma patients—the lower the MD. Similarly, a trigger-happy patient with high false positives will yield a higher MD.<sup>3</sup> Age is also something worth considering, as research shows an association with increasing age and lower MD values, suggesting more aggressive treatments in elderly patients with VF secondary to glaucoma.<sup>7</sup>

Mean deviation values are present on both the 24-2 and 10-2 analyses. Rates of MD changes in glaucomatous eyes with VF defects on both types of tests are similar in mild to moderate loss. However, the changes in MD in severe glaucoma with advanced VF loss are more significant in the 10-2. This is likely due to the peripheral points of the 24-2 reaching their "floor." Having the inability to detect peripheral worsening will mask the severity of changes occurring centrally. As such, it is more important

to monitor the MD in 10-2 VFs for severe defects.<sup>2</sup>

Mean deviation is a simple measure that can help clinicians efficiently identify visual changes in a number of ocular conditions, the most notable being glaucoma. It should be an integral part of a clinician's assessment when caring for patients with the potential for visual field loss. ■

1. Chauhan BC, Garway-Heath DF, Gofii FJ, et al. Practical recommendations for measuring rates of visual field change in glaucoma. *Br J Ophthalmol*. 2008;92(4):569-73.
2. Rao HL, Begum VU, Khadka D, et al. Comparing glaucoma progression on 24-2 and 10-2 visual field examinations. *PLoS One*. 2015;10(5):e0127233.
3. Tan NYQ, Tham YC, Koh V, et al. The effect of testing reliability on visual field sensitivity in normal eyes: the Singapore Chinese eye study. *Ophthalmology*. 2018;125(1):15-21.
4. Thomas R, George R. Interpreting automated perimetry. *Indian J Ophthalmol*. 2001;49(2):125-40.
5. Anderson AJ. Significant glaucomatous visual field progression in the first two years: what does it mean? *Transl Vis Sci Technol*. 2016;5(6):1. Erratum in: *Transl Vis Sci Technol*. 2017;6(1):10.
6. Yokoyama Y, Kawasaki R, Takahashi H, et al. Effects of brimonidine and timolol on the progression of visual field defects in open-angle glaucoma: a single-center randomized trial. *J Glaucoma*. 2019;28(7):575-83.
7. Bommakanti N, De Moraes CG, Boland MV, et al. Baseline age and mean deviation affect the rate of glaucomatous vision loss. *J Glaucoma*. 2020;29(1):31-38.
8. Mansuri G, Chawala A, Gandhi S, et al. Relationship of a new visual field index, the VFI, with Mean deviation (MD) in 30-2 and 24-2 threshold tests examined by Humphrey field analyzer in POAG patients. *Gujarat Med J*. 2014;69(1):93-95.
9. Mikkilineni S, Trobe JD, Cornblath WT, De Lott L. Visual field mean deviation at diagnosis of idiopathic intracranial hypertension predicts visual outcome. *J Neuroophthalmol*. 2019;39(2):186-90.
10. Bobak SP, Goodwin JA, Guevara RA, et al. Predictors of visual acuity and the relative afferent pupillary defect in optic neuropathy. *Doc Ophthalmol*. 1998;97(1):81-95.
11. Bruckmann A, Gäßler C, Dietzsch J, et al. High correlation between relative afferent pupillary defect (RAPD) and visual field loss in patients with glaucomatous optic neuropathy. *Invest Ophthalmol Vis Sci*. 2011;52(14):5513.



# Managing Neovascular Glaucoma

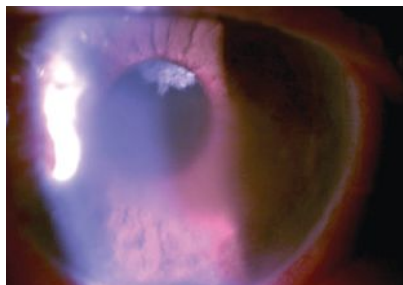
Following a step-wise approach affords the best outcome.

By Joseph W. Sowka, OD

**A**n 82-year-old man presented with a moderately painful left eye for the previous two weeks. He was diabetic and hypertensive and had been diagnosed with open-angle glaucoma in both eyes nearly two years earlier. His right eye was in the advanced stage and he had moderate nonproliferative diabetic retinopathy (DR) in each eye. He was prescribed a prostaglandin analog for glaucoma and reappointed for ongoing care, but was lost to follow-up until now.

At this visit, he was 20/25 OD and bare light perception OS. He was bilaterally pseudophakic with posterior chamber intraocular lenses in each eye. He reported still using latanoprost. He had moderate glaucomatous optic nerve damage in the right eye with a small amount of neovascularization of the disc and DR elsewhere. His intraocular pressures (IOP) were 23mm Hg OD and 62mm Hg OS. His left eye manifested central microcystic corneal edema, florid iris neovascularization and hyphema. Gonioscopically, his right angle was open to at least scleral spur while his left angle was closed with peripheral anterior synechiae (PAS) for 180°, with hyphema and angle neovascularization for the remaining part of the angle. Due to corneal edema, circulating red blood cells in the anterior chamber and a poor dilation, we could not see the left fundus.

Clearly, this was an acutely urgent case of neovascular glaucoma (NVG).



**This patient had pain with vision loss and profound pathological findings such as hyphema, microcystic edema and peripupillary iris neovascularization.**

## Discussion

Patients with NVG typically present with a chronically red, painful eye, which often has significant vision loss. The majority of patients' presenting acuity will be below 20/200.<sup>1-3</sup> They often have significant concurrent vascular disease, such as diabetes, hypertension or giant cell arteritis (GCA)—diabetes is the most common precipitating cause of NVG.<sup>3-8</sup> Patients are also likely to have an antecedent history of a retinal vessel occlusion, carotid artery disease, chronic retinal detachment or advanced DR.<sup>5,8</sup>

These patients will have visible neovascularization of the iris and angle. The patient will typically have significant corneal edema, anterior segment inflammation, anterior chamber cell and flare reaction. They'll usually have elevated IOP, often exceeding 60mm Hg.<sup>1,9,10</sup> Gonioscopically, there will be total or near-total angle closure with massive areas of PAS and neovascularization of the angle. In early cases,

microhyphema may be seen gonioscopically. Funduscopically, there will often be evidence of retinal vessel occlusion (either artery or vein), DR, ocular ischemic syndrome or another condition stimulating retinal ischemia.

Retinal hypoxia induces vascular endothelial growth factor (VEGF) to act upon healthy endothelial cells of viable capillaries to stimulate the formation of a fragile new plexus of vessels (neovascularization).<sup>11-16</sup> In cases of extreme retinal hypoxia—such as ischemic central retinal vein occlusion—very few retinal capillaries are viable. In that instance, researchers theorize that VEGF can diffuse forward to the nearest area of viable capillaries, namely the posterior iris. Neovascularization buds off of the capillaries of the posterior iris, grows along the posterior iris, through the pupil, along the anterior surface of the iris and then into the angle. Once in the angle, the neovascularization, along with attendant fibrovascular support membrane, acts to both physically block the angle as well as bridge the angle and physically pull the iris and cornea into apposition. This blocks the trabecular meshwork with progressive PAS.<sup>17</sup>

## Management

Neovascular glaucoma requires prompt and aggressive therapy that involves IOP and inflammation control as well as management of retinal ischemia and any precipitating conditions. Upon first presenta-

tion, prescribe a strong cycloplegic such as atropine 1% BID as well as a topical steroid such as prednisolone acetate 1% or difluprednate 0.05% QID.<sup>10</sup> The fact that the angle may be closed with PAS does not preclude pharmacologic mydriasis from atropine. Neither does the elevated IOP disqualify steroid use. This will greatly add to patient comfort. Aqueous suppressants in the form of beta blockers, carbonic anhydrase inhibitors and alpha adrenergic agonists may be used to temporarily reduce IOP.<sup>10</sup> However, chronic medical therapy is not indicated for neovascular glaucoma. Aqueous suppressants will temporize IOP and lead to a false sense of security, as the neovascular process will continue with further angle closure.<sup>18</sup>

Management of anterior segment neovascularization and NVG involves eradication of the vessels. This is best accomplished with panretinal photocoagulation (PRP) to destroy ischemic retina, minimize oxygen demand of the eye, and reduce the amount of VEGF being released.<sup>19-22</sup> PRP tends to effectively cause regression and involution of anterior segment neovascularization in approximately 60% of cases.<sup>17</sup> This may also reduce IOP as well as induce vessel regression.

While PRP is the most definitive treatment for the neovascularization causing NVG, the advent and use of antiangiogenic drugs has proven a valuable adjunct. Intravitreal injectable agents such as bevacizumab, ranibizumab and aflibercept have been demonstrated through numerous reports, both controlled studies and case series, to cause prompt and thorough regression of anterior segment neovascularization in NVG.<sup>23-28</sup> Regression can be significant and occur within a period as short as one day following injection.<sup>26</sup> Neovascularization can recur follow-

ing antiangiogenic injection if the causative factor is unaddressed. For that reason, antiangiogenic therapy should only be considered a valuable adjunct along with laser photocoagulation in the management of NVG.<sup>29,30</sup>

Medical therapy following PRP is common, though frequently insufficient to manage the glaucoma. Often, IOP lowering surgical methods are required. Trabeculectomy with antimetabolite adjuncts have effectively managed the elevated IOP in NVG.<sup>5</sup> Often, the use of drainage devices are necessary to optimize surgical outcomes.<sup>31, 32</sup>

This patient's NVG clearly resulted from ischemic retinal disease. He was prescribed atropine 1% BID, prednisolone acetate 1% QID, brinzolamide/brimonidine fixed combination TID in the left eye and latanoprost QHS OU and scheduled for definitive treatment with a retinal specialist. Upon meeting with the retina specialist approximately two weeks later, his eye pain had disappeared, his IOP lowered to 24mm Hg OS and his cornea had cleared enough to allow fundus examination. He still had an iris neovascularization, but the hyphema had cleared. Fundus examination of the right eye revealed end stage glaucomatous atrophy and extensive retinal hemorrhaging. Fluorescein angiography demonstrated poor flow into the left eye and a combined central retinal artery and vein occlusion. He received an anti-VEGF injection and was scheduled for PRP. ■

1. Kuang TM, Liu CJ, Chou CK, et al. Clinical experience in the management of neovascular glaucoma. *J Chin Med Assoc.* 2004;67(3):131-5.
2. Nabili S, Kirkness CM. Trans-scleral diode laser cyclophotocoagulation in the treatment of diabetic neovascular glaucoma. *Eye.* 2004;18(4):352-6.
3. Al-Shamsi HN, Dueker DK, Nowlaty SR, Al-Shahwan SA. Neovascular glaucoma at king khaled eye specialist hospital - etiologic considerations. *Middle East Afr J Ophthalmol.* 2009;16(1):15-9.
4. Lawrence PF, Oderich GS. Ophthalmologic findings as predictors of carotid artery disease. *Vasc Endovascular Surg.* 2002;36(6):415-24.
5. Mandal AK, Majji AB, Mandal SP, et al. Mitomycin-C-aug-

- mented trabeculectomy for neovascular glaucoma. A preliminary report. *Indian J Ophthalmol.* 2002;50(4):287-93.
6. Hamanaka T, Akabane N, Yajima T, et al. Retinal ischemia and angle neovascularization in proliferative diabetic retinopathy. *Am J Ophthalmol.* 2001;132(5):648-58.
7. Chen KJ, Chen SN, Kao LY, et al. Ocular ischemic syndrome. *Chang Gung Med J.* 2001;24(8):483-91.
8. Detry-Morel M. Neovascular glaucoma in the diabetic patient. *Bull Soc Belge Ophtalmol.* 1995;256:133-41.
9. Shazly TA, Latina MA. Neovascular glaucoma: etiology, diagnosis and prognosis. *Semin Ophthalmol.* 2009;24(2):113-21.
10. Löffler KU. Neovascular glaucoma: aetiology, pathogenesis and treatment. *Ophthalmologie.* 2006;103(12):1057-63.
11. Kozawa T, Sone H, Okuda Y, et al. Vascular endothelial growth factor levels in the aqueous and serum in diabetic retinopathy with or without neovascular glaucoma. *Nippon Ganka Gakkai Zasshi.* 1998;102(11):731-8.
12. Pe'er J, Folberg R, Itin A, et al. Vascular endothelial growth factor upregulation in human central retinal vein occlusion. *Ophthalmology.* 1998;105(3):412-6.
13. Tripathi RC, Li J, Tripathi BJ, et al. Increased level of vascular endothelial growth factor in aqueous humor of patients with neovascular glaucoma. *Ophthalmology.* 1998;105(2):232-7.
14. Tolentino MJ, Miller JW, Gragoudas ES, et al. Vascular endothelial growth factor is sufficient to produce iris neovascularization and neovascular glaucoma in a nonhuman primate. *Arch Ophthalmol.* 1996;114(8):964-70.
15. Hu DN, Ritch R, Liebmann J, et al. Vascular endothelial growth factor is increased in aqueous humor of glaucomatous eyes. *J Glaucoma.* 2002;11(5):406-10.
16. Scholl S, Kirchhof J, Augustin AJ. Antivascular endothelial growth factors in anterior segment diseases. *Dev Ophthalmol.* 2010;46:133-9.
17. Hamard P, Baudouin C. Consensus on neovascular glaucoma. *J Fr Ophtalmol.* 2000;23(3):289-94.
18. Sivak-Calloot JA, O'Day DM, Gass JD, et al. Evidence-based recommendations for the diagnosis and treatment of neovascular glaucoma. *Ophthalmology.* 2001;108(10):1767-76.
19. Brooks AM, Gillies WE. The development and management of neovascular glaucoma. *Aust N Z J Ophthalmol.* 1990;18(2):179-85.
20. Cashwell LF, Marks WP. Panretinal photocoagulation in the management of neovascular glaucoma. *South Med J.* 1988;81(11):1364-8.
21. Stefaniotou M, Paschides CA, Psilas K. Panretinal cryopexy for the management of neovascularization of the iris. *Ophthalmologica.* 1995;209(3):141-4.
22. Lee SC, Kim GO, Kim DH, et al. Endoscopic laser photocoagulation for management of neovascular glaucoma. *Yonsei Med J.* 2000;41(4):445-9.
23. Lee SJ, Lee JJ, Kim SY, Kim SD. Intravitreal bevacizumab (Avastin) treatment of neovascular glaucoma in ocular ischemic syndrome. *Korean J Ophthalmol.* 2009;23(2):132-4.
24. Yazdani S, Hendi K, Pakravan M, et al. Intravitreal bevacizumab for neovascular glaucoma: a randomized controlled trial. *J Glaucoma.* 2009;18(8):632-7.
25. Beutel J, Peters S, Lütke M, et al. Bevacizumab as adjuvant for neovascular glaucoma. *Acta Ophthalmol.* 2010;88(1):103-9.
26. Batio lu F, Astam N, Ozmer T. Rapid improvement of retinal and iris neovascularization after a single intravitreal bevacizumab injection in a patient with central retinal vein occlusion and neovascular glaucoma. *Int Ophthalmol.* 2008;28(1):59-61.
27. Katsanos A, Gorgoli K, Mikropoulos DG, et al. Assessing the role of ranibizumab in improving the outcome of glaucoma filtering surgery and neovascular glaucoma. *Expert Opin Biol Ther.* 2018;18(6):719-24.
28. Andrés-Guerrero V, Perucho-González L, García-Feijoo J, et al. Current perspectives on the use of anti-VEGF drugs as adjuvant therapy in glaucoma. *Adv Ther.* 2017;34(2):378-95.
29. Hasanreisoglu M, Weinberger D, Mimouni K, et al. Intravitreal bevacizumab as an adjunct treatment for neovascular glaucoma. *Eur J Ophthalmol.* 2009;19(4):607-12.
30. Ciftci S, Sakalar YB, Unlu K, et al. Intravitreal bevacizumab combined with panretinal photocoagulation in the treatment of open angle neovascular glaucoma. *Eur J Ophthalmol.* 2009;19(6):1028-33.
31. Alkawas AA, Shahien EA, Hussein AM. Management of neovascular glaucoma with panretinal photocoagulation, intravitreal bevacizumab, and subsequent trabeculectomy with mitomycin C. *J Glaucoma.* 2010 Feb 22. [Epub ahead of print]
32. Eid TM, Radwan A, el-Manawy W, el-Hawary I. Intravitreal bevacizumab and aqueous shunting surgery for neovascular glaucoma: safety and efficacy. *Can J Ophthalmol.* 2009;44(4):451-6.



# A Common Denominator

Polycystic ovary syndrome is a hormonal disorder that can have ocular implications.

By **Carlo J. Pelino, OD**, and **Joseph J. Pizzimenti, OD**

**P**olycystic ovary syndrome (PCOS) is a complex condition characterized by menstrual irregularities, androgen excess and ovarian cysts.<sup>1</sup> It is defined as the presence of any two of the following: polycystic ovaries, anovulation or oligoovulation and hyperandrogenism.<sup>2</sup>

## A Triad of Signs

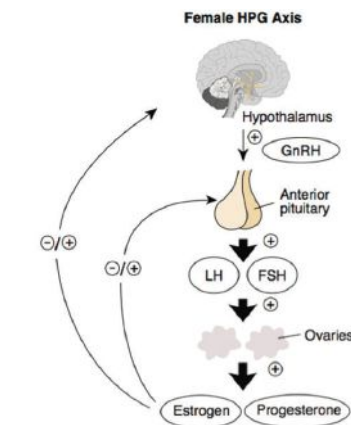
A woman has polycystic ovaries if 20 or more follicles—functional units of ovaries that secrete hormones—are present in at least one ovary. Ultrasonography can detect polycystic ovaries, which typically involve 10 to 12 small follicles spaced close together in a bilateral formation on the peripheral edge of the ovaries.<sup>2,3</sup>

Anovulation occurs when the ovaries do not release an oocyte during the menstrual cycle, precluding ovulation; however, a woman may still menstruate. If ovulation is present but irregular, it's called oligoovulation (fewer than nine menstrual cycles per year).<sup>1,4</sup>

Hyperandrogenism—defined by hirsutism, excess of blood testosterone (T) levels or both—is an endocrine disorder that affects 5% to 10% of women of reproductive age.<sup>5</sup> Clinical manifestations include hirsutism, acne, androgenic alopecia and virilization.<sup>1,4</sup> Many of these patients also tend to have PCOS.

## PCOS Essentials

At least 7% of all adult women have PCOS, with one study estimating this number to be as high as 21%.<sup>6,7</sup> It impacts approximately five mil-



**Fig. 1. The HPG axis runs a feedback loop that could cause PCOS if interrupted.**

lion women of childbearing age in the US alone.<sup>3</sup> Researchers believe PCOS is caused by a disordered feedback loop between the ovaries and the hypothalamic-pituitary-gonadal (HPG) axis (*Figure 1*). This leads to deficits in the release of luteinizing hormone in the presence of follicle-stimulating hormone.<sup>1,2</sup>

The inappropriate gonadotropin secretion seen in PCOS is most likely a result of, rather than a cause of, ovarian dysfunction. Another consistent biochemical feature of PCOS is a raised plasma T level.<sup>8</sup> This causes concomitant insulin resistance and compensatory hyperinsulinemia, increasing glucose intolerance. These patients tend to be overweight; nearly half of all women with PCOS are clinically obese.<sup>9</sup> Many have obstructive sleep apnea (OSA), which adds to the risk of cardiovascular disease.<sup>10</sup> Clinicians should ask OSA patients about excessive daytime somnolence and assess their car-

diovascular risk by evaluating their body-mass index (BMI), fasting lipid and lipoprotein levels and metabolic syndrome risk.<sup>2,3,11</sup>

Women with PCOS have a higher rate of infertility and are at increased risk of pregnancy loss and complications, including gestational diabetes.<sup>1,3</sup> They also have an increased prevalence of coronary artery calcification and thickened carotid intima media, which may be responsible for subclinical atherosclerosis.<sup>1,3</sup>

Approximately 10% of women with PCOS have type 2 diabetes, and 30% to 40% have impaired glucose tolerance by the age of 40.<sup>11</sup> Perform glucose tolerance and glycosylated hemoglobin testing, regardless of a patient's weight.

## Ocular Comorbidities

Estrogen, progesterone and androgen receptors have been found in the cornea, lens, iris, ciliary body, retina, lacrimal glands, meibomian glands and conjunctiva. It is thus incumbent on ODs to identify potential signs of PCOS and its ocular comorbidities.<sup>12</sup> These may include ocular dryness and/or itching, diabetic retinopathy, floppy lid syndrome, central serous chorioretinopathy, keratoconus and anterior ischemic optic neuropathy. Idiopathic intracranial hypertension (IIH), or pseudotumor cerebri, may be another.

IIH initially presents as bilateral optic disc edema of unknown cause (*Figure 2*). It predominantly affects women of childbearing age who are obese. The condition causes chroni-

cally elevated intracranial pressure and papilledema, which may lead to progressive optic atrophy and reduced visual function.<sup>13</sup>

Given that obesity is commonly associated with IIH and PCOS, there may be an association between the two. A study of 38 women with IIH found 15 also had PCOS and 24 were obese.<sup>13</sup> The researchers proposed PCOS-driven obesity facilitates IIH after learning that increased intra-abdominal and cardiac filling pressures associated with obesity may result in a retrograde increase in cerebrospinal fluid pressure.<sup>13</sup> Another study reported that out of 58 women with IIH, nine had PCOS, concluding that the prevalence of PCOS is higher in IIH patients.<sup>14</sup>

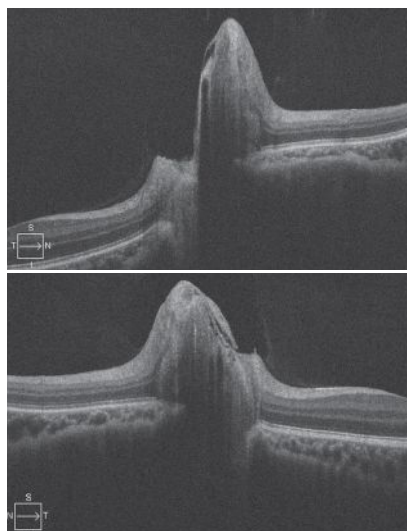
Beyond obesity, PCOS may be associated with IIH through an increased risk of thrombosis. High estrogen levels, common in PCOS and severe obesity, are thrombophilic and may play a role in the development of IIH, particularly in patients with coagulation disorders.<sup>13,14</sup>

## Diagnosis

When PCOS is suspected, first exclude all other disorders that could result in menstrual irregularity and hyperandrogenism, including adrenal or ovarian tumors, thyroid dysfunction, congenital adrenal hyperplasia, hyperprolactinemia, acromegaly and Cushing syndrome.<sup>2,3</sup>

Baseline screening includes:<sup>3,4</sup>

- Thyroid function tests
- Serum prolactin level
- Total and free T levels
- Free androgen index
- 17-hydroxyprogesterone level
- Urinary free cortisol and creatinine levels
- Low-dose dexamethasone suppression test
- Insulin-like growth factor 1 level
- Human chorionic gonadotropin level



**Fig. 2. Bilateral optic disc edema is visible in a patient with IIH, OD on top.**

Ovarian biopsy may histologically confirm PCOS; however, ultrasonography generally supersedes histopathologic analysis. An endometrial biopsy can evaluate for endometrial disease, such as malignancy.<sup>2,3</sup>

## Treatment

Lifestyle changes combined with metformin can help with weight loss, which is recommended to reduce cardiovascular risks and complications associated with diabetes.<sup>2,3</sup>

Pharmacologic treatments are reserved for metabolic derangements, such as anovulation, hirsutism and menstrual irregularities. First-line medical therapy usually consists of an oral contraceptive to regulate menstruation and decrease the risk of endometrial cancer, which is associated with obesity and chronic anovulation (but not necessarily PCOS).<sup>2,3</sup>

If symptoms are not sufficiently alleviated, an androgen-blocking agent may be added. First-line treatments for ovulation induction when fertility is desired are letrozole and clomiphene citrate.<sup>2,3</sup> Clomiphene and metformin can induce ovulation in patients seeking fertility but

should not be used together.<sup>15</sup> Metformin use can be continued into pregnancy and may decrease miscarriage rates.

Medications could include:<sup>1-3</sup>

- Hypoglycemic agents
- Selective estrogen receptor modulators
- Topical hair-removal agents
- Oral contraceptive agents
- Anti-androgens
- Topical acne agents

Surgical management of PCOS aims to restore ovulation. There are two types: laparoscopic ovarian drilling and ovarian wedge resection. Laparoscopic drilling uses electrocautery or a laser to destroy parts of the ovary and trigger ovulation. Wedge resection removes a section of ovary to help regulate menstruation and promote normal ovulation.<sup>1-3</sup>

PCOS is a common, lifelong health condition in women. These patients can develop serious health problems, especially if they are overweight, and must be managed accordingly. Even ODs have a part to play, as ocular comorbidities could be present. ■

1. Carmina E, Lobo RA. Polycystic ovary syndrome (PCOS): arguably the most common endocrinopathy is associated with significant morbidity in women. *J Clin Endocrinol Metab.* 1999;84(6):1897-9.
2. Rotterdam ESHRE/ASRM-Sponsored PCOS Consensus Workshop Group. Revised 2003 consensus on diagnostic criteria and long-term health risks related to polycystic ovary syndrome. *Fertil Steril.* 2004;81(1):19-25.
3. Ndefo UA, Eaton A, Green MR. Polycystic ovary syndrome: a review of treatment options with a focus on pharmacological approaches. *P T.* 2013;38(6):336-55.
4. Vause TDR, Cheung AP, Sierra S, et al. Ovulation induction in polycystic ovary syndrome. *J Obstet Gynaecol Can.* 2010;32(5):495-502.
5. Yildiz BO. Diagnosis of hyperandrogenism: clinical criteria. *Best Pract Res Clin Endocrinol Metab.* 2006;20(2):167-76.
6. Copp T, Jansen J, Doust J, et al. Are expanding disease definitions unnecessarily labelling women with polycystic ovary syndrome? *BMJ.* 2017;358:j3694.
7. Aubuchon M, Legro RS. Polycystic ovary syndrome: current infertility management. *Clin Obstet Gynecol.* 2011;54(4):675-84.
8. Barber TM, Franks S. Genetics of polycystic ovary syndrome. *Front Horm Res.* 2013;40:28-39.
9. Rosenfield RL, Ehrmann DA. The pathogenesis of polycystic ovary syndrome (PCOS): the hypothesis of PCOS as functional ovarian hyperandrogenism revisited. *Endocr Rev.* 2016;37(5):467-520.
10. Tasali E, Van Cauter E, Ehrmann DA. Polycystic ovary syndrome and obstructive sleep apnea. *Sleep Med Clin.* 2008;3(1):37-46.
11. Ehrmann DA, Barnes RB, Rosenfield RL, et al. Prevalence of impaired glucose tolerance and diabetes in women with polycystic ovary syndrome. *Diabetes Care.* 1999;22(1):141-6.
12. Adaye SK, Karaca I, Yildirim S, et al. Anterior segment findings in women with polycystic ovary syndrome. *Turk J Ophthalmol.* 2017;47(1):24-7.
13. Glueck CJ, Iyengar S, Goldenberg N, et al. Idiopathic intracranial hypertension: associations with coagulation disorders and polycystic ovary syndrome. *J Lab Clin Med.* 2003;142(1):35-45.
14. Avisar I, Galon DD, Dania H, et al. The prevalence of polycystic ovary syndrome in women with idiopathic intracranial hypertension. *Scientifica.* July 30, 2012. [Epub ahead of print].
15. Wellberry C. Diagnosis and treatment of polycystic ovary syndrome. *Am Fam Physician.* 2007;76(6):865-76.



# Repairing a Misdiagnosis

A patient averts a crisis related to his worsening cloudy vision.

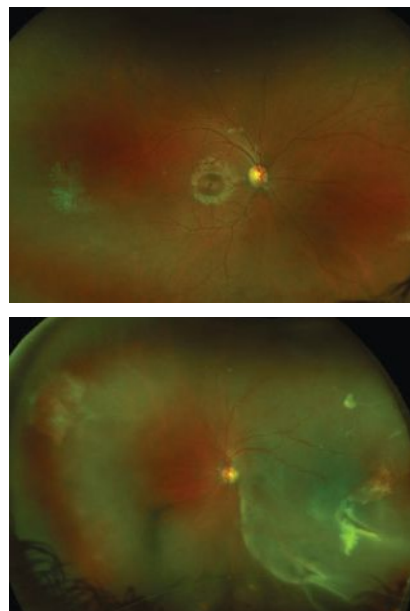
By Rami Aboumourad, OD, and Mark T. Dunbar, OD

A 19-year-old Jamaican male presented with “cloudy vision” in the left eye for nearly two months. He was diagnosed with toxoplasma chorioretinitis in his home country and treated with Bactrim DS (sulfamethoxazole-trimethoprim, Roche Pharmaceuticals), but his symptoms did not improve. Lab tests for toxoplasmosis came back negative, and the patient was referred for a second opinion given the lack of improvement.

On examination, his unaided visual acuity was 20/20 OD and 20/800 OS with no improvement with pinhole. A relative afferent pupillary defect was detected in the left eye. His extraocular motilities were full in both eyes and his left eye had a mild peripheral constriction on confrontation visual fields. The intraocular pressures (IOP) measured 14mm Hg OD and 7mm Hg OS. The anterior segments were unremarkable. Fundus photos and corresponding fluorescein angiograms (FA)—early and late phase—reflect the posterior segments findings (*Figures 1 to 3*).

## Take the Retina Quiz

- How would you characterize the peripheral retinal changes in the right eye?
  - Multiple retinal tears.
  - Choroidal neovascularization.
  - Retinal neovascularization.
  - Retinal capillary angiomas.
- How would you characterize the



**Fig. 1. These ultra-widefield fundus photos show our young patient's right (at top) and left eyes. What do you notice that can explain his blurry vision?**

- peripheral retinal changes in the left eye?
- Rhegmatogenous retinal detachment.
  - Retinal neovascularization.
  - Retinal capillary angiomas.
  - Both a and b.
- Which of the following best describes the FA findings?
    - Early hyperfluorescence with late staining.
    - Early hyperfluorescence with late leakage.
    - Early phase is normal with late pooling.
    - Hyperfluorescence associated with window defect.

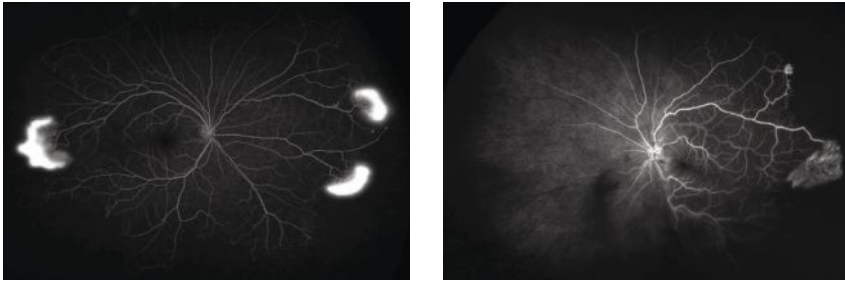
- What is most likely diagnosis consistent with the patient's clinical presentation?
  - Eales' disease.
  - Familial exudative vitreoretinopathy.
  - Proliferative diabetic retinopathy.
  - Proliferative sickle cell retinopathy.
- Based on the Goldberg classification, the patient's left eye would be categorized as:
  - Stage II.
  - Stage III.
  - Stage IV.
  - Stage V.

For answers, see page 98.

## Diagnosis

It was evident that our patient has a large macula-off retinal detachment in the left eye. We were able to see multiple retinal tears, one of which can be seen in the fundus photograph at 4:00. But that's not all. Superior to the retinal tear, he also had an area of active neovascularization in the shape of a sea-fan. The neovascularization was not just in the left eye but also in the peripheral retina of the right eye. The widefield FA in the left eye highlights where we can see hyperfluorescence in the early phase and leakage (via increased hyperfluorescence with blurring of margins) in the late phase (*Figure 2*). The FA in the right eye also shows large areas of capillary nonperfusion





**Fig. 2.** The ultra-widefield FA shows our patient's right eye in mid phase, at left, and left eye in the early phase.

anterior to the areas of neovascularization (*Figure 2*).

Given these findings, we concluded our patient had a traction retinal detachment secondary to proliferative sickle cell retinopathy that evolved into a combined tractional-rhegmatogenous retinal detachment (TRD/RRD).

## Discussion

Sickle cell disease comprises a group of hemoglobinopathies characterized by intravascular hemolysis that ultimately results in defective oxygen transportation.<sup>1,2</sup> Sickle cell disease is the most common inherited blood disorder and affects nearly 100,000 Americans.<sup>2,3</sup> Approximately one in 12 black individuals carry the sickle cell trait and sickle cell disease affects ~1/365-500 African-American births and ~1/16,300 Hispanic-American births.<sup>1-3</sup>

The patient had a known diagnosis of hemoglobin (Hb) SC disease with no prior systemic crises of note. Hemoglobin SC disease is the second most common form of sickle cell disease, but is the most likely to cause sickle cell retinopathy.<sup>1-6</sup> Hemoglobin SS disease is the most common form of sickle cell disease, but is associated with a higher rate of mortality.<sup>2,6,7</sup>

Hemoglobin SC results in hypercoagulability of blood and is more likely to compromise smaller

blood vessels and cause chronic low-grade peripheral ischemia, while Hb SS disease causes larger thrombi that are more likely to affect large blood vessels and cause systemic crises.<sup>1,4,5</sup>

Diagnosis is largely clinical and graded using a universal classification system (See, “*Goldberg Stages of Sickle Cell Retinopathy*”). According to the Goldberg classification, our patient is in Stage III OD and Stage V OS. The hallmark defining feature of Stage III disease is sea-fan neovascular fronds, and the defining feature of Stage V disease is traction retinal detachment.

Proliferative sickle cell retinopathy is unique from other proliferative vitreoretinal diseases in that the neovascular sea-fan lesions can autoinfarct in up to 60% of cases, therefore becoming inactive and no longer pose a threat to vision.<sup>1-7</sup> For that reason, patients with proliferative sickle cell retinopathy are treated on a case-by-case basis and treatment may not be uniformly indicated. If intervention is indicated, options include laser, anti-vascular endothelial growth factor intravitreal injections and surgery (for non-clearing vitreous hemorrhage or retinal detachment). The ultimate goal of treatment is to prevent progression from Stage III to Stages IV or V when possible.

## Goldberg Stages of Sickle Cell Retinopathy<sup>1-6</sup>

- I. Peripheral arterial occlusions** – Can have multiple simultaneous peripheral vascular occlusions and silver-wiring of arterioles.
- II. Peripheral arteriovenous anastomoses (hairpin loops)** – Vascular remodeling at the junction of perfused and nonperfused retina that strives to shunt blood from occluded arterioles to adjacent venules. These lesions do not leak FA.
- III. Neovascular and fibrous proliferations** – Defined by sea-fan lesions that are typically found in the peripheral retina. These lesions do leak on FA.
- IV. Vitreous hemorrhage** – Defined by the presence of vitreous hemorrhage. Typically secondary to vitreous traction and can be focal overlying sea-fan lesions or diffuse. Chronic vitreous hemorrhage can lead to fibroglial membranes and vitreous strands that can induce traction.
- V. Retinal detachment** – Defined by the presence of a TRD, usually secondary to chronic non-clearing vitreous hemorrhage. Can also develop combined TRD/RRD.

Ultra-widefield FA can provide great insight as to whether sea-fan lesions are active or inactive, which can help guide the decision to treat versus observe. Spectral domain OCT and OCT angiography can provide information regarding the foveal architecture and presence of ischemia.<sup>1,2,4</sup>

After a discussion about the risks, benefits and alternatives, the patient was taken into surgery. Panretinal photocoagulation was applied anterior to the sea-fan lesions nasally and temporally in his right eye. The combined TRD/RRD in the left was repaired with the placement of a scleral buckle, pars plana vitrectomy, endoscopic photocoagulation and insertion of silicone oil. The patient had a

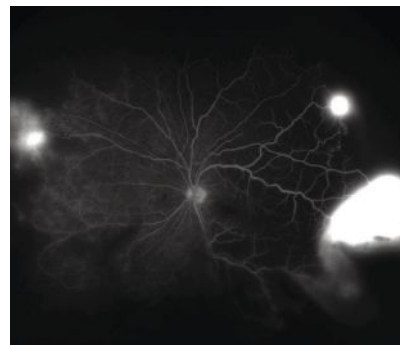
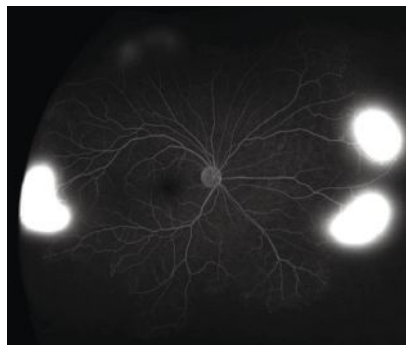
## SC Retinopathy Findings<sup>1-6</sup>

### Nonproliferative

- **Salmon patch hemorrhages** – Pinkish-orange hemorrhages between the retina and internal limiting membrane, typically found in the equatorial retina.
- **Iridescent spots** – Small schisis cavities post-salmon patch hemorrhage or post-arteriolar occlusions that appear with multiple glistening, refractile iridescent spots.
- **Black sunbursts** – Flat areas of hyperpigmentation thought to be secondary to intraretinal hemorrhages tracking into the subretinal space or representative of focal underlying choroidal ischemia or neovascular membrane formation.

### Proliferative

- **Sea-fan lesions** – Neovascular fronds that typically form in the periphery at arteriovenous crossings secondary to peripheral arteriolar occlusions.



**Fig. 3.** These ultra-widefield FA images depict the late phase in both eyes.

good surgical result with reattachment of the retina and excellent regression of the sea-fan lesion in both eye. He continues to be followed closely. ■

*Dr. Aboumourad practices at the Bascom Palmer Eye Institute in Miami. This case came courtesy of Jayanth Sridhar, MD, also of the Bascom Palmer Eye Institute.*

1. Ryan SJ ed. Retina. 5th ed. Philadelphia: Elsevier Saunders; 2013.

2. Akhter M, Latting M, Scott AI. Management of proliferative sickle cell retinopathy. *Eyenet magazine*. [www.aao.org/eyenet/article/proliferative-sickle-cell-retinopathy](http://www.aao.org/eyenet/article/proliferative-sickle-cell-retinopathy). October 2018. Accessed April 17, 2020.

3. Centers for Disease Control and Prevention. Data & statistics on sickle cell disease. [www.cdc.gov/ncbddd/sicklecell/data.html](http://www.cdc.gov/ncbddd/sicklecell/data.html). October 21, 2019. Accessed April 17, 2020.

4. Yanoff M, Duker JS, eds. Ophthalmology. 5th ed. Philadelphia: Elsevier; 2019.

5. Mena F, Khan B, Uzair B, Mena A. Sickle cell retinopathy: improving care with a multidisciplinary approach. *J Multidiscip Healthc*. 2017;10:335-46.

6. Gass J, Agarwal A. Gass' Atlas of Macular Diseases, 5th ed. Philadelphia: Elsevier Saunders; 2012.

7. Platt O, Brambilla D, Rosse W, et al. Mortality in sickle cell disease. Life expectancy and risk factors for early death. *N Engl J Med*. 1994;330(23):1639-44.

## Advertisers Index

Akorn Pharmaceuticals .....	9, 19 & 33
..... (800) 932-5676	
..... www.akorn.com	
Alcon Laboratories .....	100
..... (800) 451-3937	
..... www.alcon.com	
Bausch + Lomb .....	11 & 21
..... (800) 323-0000	
..... www.bausch.com	
Bruder Ophthalmic Products .....	45
..... (888) 827-8337	
..... eyes@bruderophthalmic.com	
..... www.bruderophthalmic.com	
CooperVision .....	99
..... (800) 341-2020	
..... www.coopervision.com	
Ivantis, Inc. ....	59 & 60
..... info@ivantisinc.com	
..... www.ivantisinc.com	
Lacrimedics, Inc. ....	27
..... (800) 367-8327	
..... info@lacrimedicsl.com	
..... www.lacrimedicsl.com	
Lacriversa .....	15
..... www.lacriversa.com	

MacuLogix.....	17
..... (888) 392-6801	
..... www.maculogix.com	
Menicon Ophthalmic.....	25
..... (877) 225-6101	
..... www.meniconamerica.com	
Novartis / My Choice RX.....	13
..... www.mychoicercx.com	
Oculus, Inc. ....	29
..... (888) 284-8004	
..... www.oculususa.com	
Quidel .....	23
..... www.quideleyehealth.com	
Regeneron Pharmaceuticals, Inc.....	6
..... (914) 847-7000	
..... www.regeneron.com	
Regeneron Pharmaceuticals, Inc.....	45
..... (914) 847-7000	
..... www.regeneron.com	
S4OPTIK .....	53 & 55
..... (888) 224-6012	
..... www.s4optik.com	

*This advertiser index is published as a convenience and not as part of the advertising contract. Every care will be taken to index correctly. No allowance will be made for errors due to spelling, incorrect page number, or failure to insert.*

**Career Opportunities**

**Staff Optometrist Wanted**

Bard Optical is a family owned full-service retail optometric practice with 22 offices (and growing) throughout Central Illinois. Bard Optical prides itself on having a progressive optometric staff whose foundation is based on one-on-one patient service. We are currently accepting CV/resumes for Optometrists to join our medical model optometric practice that includes extended testing. The practice includes but is not limited to general optometry, contact lenses and geriatric care. Salaried, full-time positions are available with excellent base compensation and incentive programs and benefits. Some part-time opportunities may also be available.

Current positions are available in Bloomington/Normal, Decatur/Forsyth, Peoria, Sterling and Canton as we continue to grow with new and established offices.

Please email your information to [mhall@bardoptical.com](mailto:mhall@bardoptical.com) or call Mick at 309-693-9540 ext 225. Mailing address if more convenient is:

**Bard Optical**  
Attn: Mick Hall, Vice President  
8309 N Knoxville Avenue  
Peoria, IL 61615

*Bard Optical is a proud Associate Member of the Illinois Optometric Association.*



[www.bardoptical.com](http://www.bardoptical.com)

**Arinella-Williams**

is an Ophthalmology/Optometry Practice in Worcester Massachusetts

We are searching for a skilled Optometrist

This is a full time position. We would consider an extended day four day workweek.

Must be Mass licensed.

We offer a competitive salary, paid vacation, continuing ed reimbursement, health insurance, and a bonus structure is in place

Please contact: Michele Rickert  
[rickertmi@aol.com](mailto:rickertmi@aol.com)

508 853 2020 x 146

**Continuing Education**

**MEDICAL OPTOMETRISTS**

The American Board of Certification in Medical Optometry (ABCMO) is recognized at Joint Commission (JC) accredited medical facilities as issuing board certification in the specialty of medical optometry and those ABCMO certifies are eligible for credentialing at these facilities as specialists rather than general optometry practitioners.\*

The Joint Commission, the accepted national Gold Standard, reviews and accredits over 21,000 federal, state and local-chartered medical facilities.

**To Be Eligible for ABCMO board certification:**

1. Complete an accredited residency in medical optometry
2. Pass the national Advanced Competence in Medical Optometry Examination
3. Practice in a medical setting for a minimum of two years.#

[www.abcmo.org](http://www.abcmo.org)



Visit [www.abcmo.org](http://www.abcmo.org) to understand how JC accredited medical facilities credential specialists and why specialty certification can enhance the careers of optometrists who complete residencies in medical optometry.

For Application procedures see [www.abcmo.org](http://www.abcmo.org) or contact [myers.kenj@gmail.com](mailto:myers.kenj@gmail.com)

\* At this time, 127 JC accredited hospitals, clinics and teaching institutions recognize ABCMO specialist certification.  
# [www.jointcommission.org](http://www.jointcommission.org)  
# Waived for two years after residency

Place Your Ad Here!

Toll free: 888-498-1460

E-mail: [sales@kerhgroup.com](mailto:sales@kerhgroup.com)

**Practice For Sale**



Practice Sales • Appraisals • Consulting  
[www.PracticeConsultants.com](http://www.PracticeConsultants.com)

**PRACTICES FOR SALE  
NATIONWIDE**

Visit us on the Web or call us to learn more about our company and the practices we have available.

[info@PracticeConsultants.com](mailto:info@PracticeConsultants.com)

**925-820-6758**

[www.PracticeConsultants.com](http://www.PracticeConsultants.com)

**Do you have Products and Services for sale?**

CONTACT US TODAY  
FOR CLASSIFIED ADVERTISING  
Toll free: 888-498-1460  
E-mail: [sales@kerhgroup.com](mailto:sales@kerhgroup.com)

**Do you have CE Programs?**

CONTACT US TODAY  
FOR CLASSIFIED  
ADVERTISING

Toll free:  
**888-498-1460**

E-mail:  
[sales@kerhgroup.com](mailto:sales@kerhgroup.com)

**Targeting Optometrists?**

**CLASSIFIED ADVERTISING WORKS**

- JOB OPENINGS • CME PROGRAMS
- PRODUCTS & SERVICES • AND MORE...

Contact us today for classified advertising:

Toll free: 888-498-1460

E-mail: [sales@kerhgroup.com](mailto:sales@kerhgroup.com)



## A Bumpy Ride

A patient is concerned about a progressive growth.

By Andrew S. Gurwood, OD

### History

A 52-year-old black male reported to the office with a chief complaint of a lump in the left eyelid. He explained that the lump had been progressively worsening over the last four months. His systemic and ocular histories were unremarkable and he denied exposure to chemicals or allergies of any kind.

### Diagnostic Data

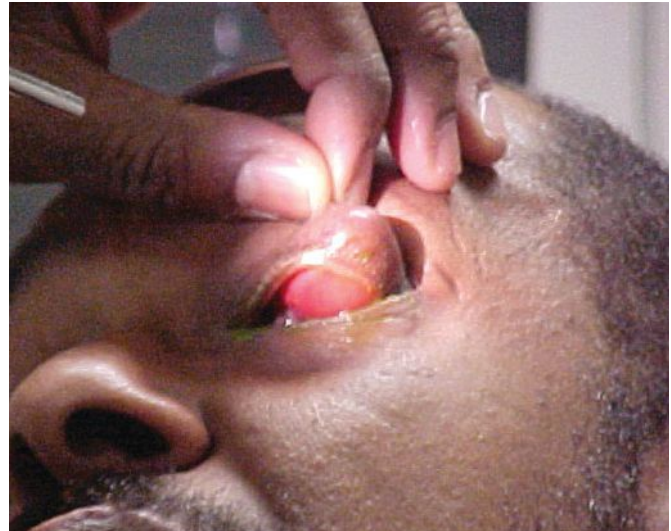His best-corrected entering visual acuities were 20/20 in each eye at distance and near. His external examination was normal with no evidence of afferent pupil defect. The pertinent anterior segment findings are demonstrated in the photograph. Goldmann applanation tonometry measured 15mm Hg OU. Dilated funduscopy was within normal limits, both eyes,

revealing symmetric cup-to-disc ratios measuring 0.3/0.3 OD and 0.3/0.35 OS, respectively, with normal peripheries.

### Your Diagnosis

Does the case presented require any additional tests, history or information? Based

on the information provided, what would be your diagnosis? What is the patient's most likely prognosis?



Can this image of our 52-year-old patient's presentation help you identify his diagnosis?

To find the answers, please visit *Review of Optometry* online at [www.reviewofoptometry.com](http://www.reviewofoptometry.com). ■

**Retina Quiz Answers** (from page 94): 1) c; 2) d; 3) b; 4) d; 5) d.

### Next Month in the Mag

Coming in June, *Review of Optometry* will present its annual retina report.

Topics include:

- *Sizing Up Geographic Atrophy*
- *Setting Patient Expectations for Anti-VEGF Therapy*

- *Is Your Approach to Diabetic Retinopathy Working?*

- *Improve Your Macular Exam*
- *Recognizing Retinitis Pigmentosa*

Also in this issue:

- *Caring for the Pregnant Patient* (Earn 2 CE Credits)
- *The Tools to ID Brain Injury*

REVIEW OF OPTOMETRY (ISSN 0147-7633) IS PUBLISHED MONTHLY, 12 TIMES A YEAR BY JOBSON MEDICAL INFORMATION LLC, 395 HUDSON STREET, 3RD FLOOR FLOOR, NEW YORK, NY 10014. PERIODICALS POSTAGE PAID AT NEW YORK, NY AND ADDITIONAL MAILING OFFICES. POSTMASTER: SEND ADDRESS CHANGES TO REVIEW OF OPTOMETRY, PO BOX 81, CONGERS, NY 10920-0081. SUBSCRIPTION PRICES: US: ONE YEAR \$56; TWO YEARS \$97, CANADA: ONE YEAR \$88, TWO YEARS \$160, INT'L: ONE YEAR \$209, TWO YEARS \$299. FOR SUBSCRIPTION INFORMATION CALL TOLL-FREE (877) 529-1746 (USA); OUTSIDE USA, CALL (845) 267-3065. OR EMAIL US AT REVOPOTOMETRY@CAMBEYWEST.COM. PUBLICATIONS MAIL AGREEMENT NO: 40612608. CANADA RETURNS TO BE SENT TO BLEUCHIP INTERNATIONAL, P.O. BOX 25542, LONDON, ON N6C 6B2.

# Biofinity<sup>®</sup> toric multifocal NOW AVAILABLE.

It's here! Your impression of toric multifocal lenses is about to change. Get the **right fit** the **first time**<sup>1</sup>, all within the proven Biofinity<sup>®</sup> family.



**93% success rate** on initial fitting.<sup>1</sup>



**Over 200,000 unique prescription options**<sup>2</sup> to provide vision correction for **nearly 100%** of astigmatic presbyopes.<sup>3</sup>



**Made-to-order** advantage will give you the utmost accuracy so you can find the right fit, the first time without prescription limitations.<sup>1</sup>



Leverages proven design from the **#1, most prescribed toric lens on the market**.<sup>4</sup>



Two different optical designs (D and N) are optimized for **exceptional vision at all distances**. With 4 different ADD powers, you get a **simplified** and **flexible fitting** for astigmatic presbyopes.

**More options. More opportunities for success.**  
**Learn more at [OnlyBiofinity.com](https://OnlyBiofinity.com) today.**

FROM SPHERE TO SPECIALTY  
*Only Biofinity*<sup>®</sup>

 CooperVision<sup>®</sup>

1. CVI Data on file 2018. Non-dispensing, subject masked, randomized, bilateral, cross-over short-term clinical evaluation. 27 astigmatic, presbyopic soft CL wearers at 2 sites (UK & US) fitted using CVI fit guide  
2. CVI data on file 2019. Based on total number of prescription option combinations manufactured (for sphere, cylinder, axis and add – including D & N combinations). 3. For nearly 100% claim: CVI data on file 2020; Rx coverage database; 42 to 70 years ≥0.75DC 4. CVI data on file, 2019. US industry reports and internal estimates. ©2020 CooperVision. 8823 04/20

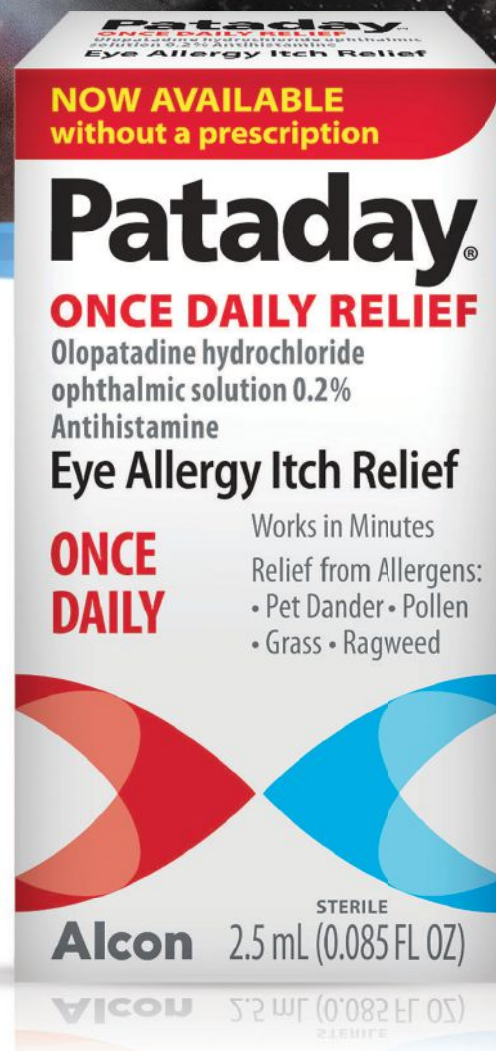ALLERGENS ARE EVERYWHERE

# Pataday is Now Available Without a Prescription

**Encourage your patients to get Pataday**

Once Daily Relief for itchy allergy eyes. It's the same full prescription strength formula you know and trust. Now available directly to your patients.

**One Drop. Once Daily.**



**Alcon**

© 2020 Alcon Inc. 02/20 US-PTD-VLC-2000011

Visit [patadaypro.com](http://patadaypro.com)