

EARN 2 CE CREDITS: *Overcoming Secondary Glaucomas*, p. 74 • *Office Design Contest Winners*, p. 64

# REVIEW<sup>®</sup> OF OPTOMETRY

November 15, 2019

[www.reviewofoptometry.com](http://www.reviewofoptometry.com)



## MAINTAINING EYELID HEALTH

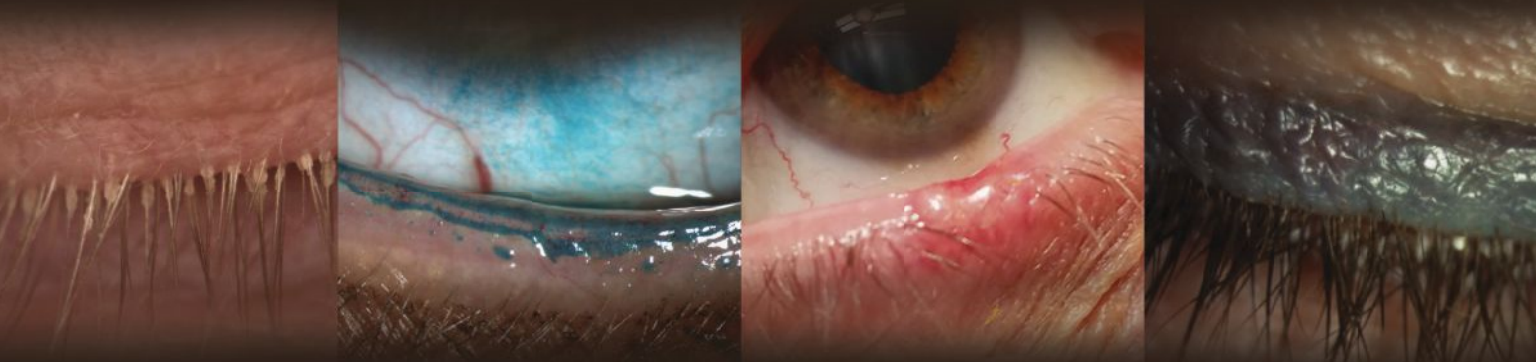
*Practical strategies to  
protect and restore  
proper function.*

*A Close Look at Common Lid Lesions*, p. 38


*At the Crossroads of Allergy, Dry Eye and Lid Disease*, p. 46

*Lashing Out: Dangerous Beauty Trends*, p. 52

*In-office and At-home Lid Maintenance*, p. 58



Only dual-action VYZULTA reduces intraocular pressure (IOP) by targeting the trabecular meshwork with nitric oxide and the uveoscleral pathway with latanoprost acid<sup>1</sup>



  
**VYZULTA**<sup>®</sup>  
(latanoprostene  
bunod ophthalmic  
solution), 0.024%

## EXPAND THE TRABECULAR MESHWORK WITH THE POWER OF NITRIC OXIDE<sup>2-6</sup>

### VYZULTA achieved significant and sustained long-term IOP reductions vs Timolol 0.5% in pivotal trials<sup>7</sup>

$P < 0.001$  vs baseline at all pre-specified visits over 12 months in a pooled analysis of APOLLO and LUNAR clinical trials (N=831)

### VYZULTA demonstrated safety profile in clinical trials

Only 6 out of 811 patients discontinued due to ocular adverse events in APOLLO and LUNAR clinical trials<sup>1,8,9</sup>

Visit [VYZULTANOW.com](http://VYZULTANOW.com) to see our efficacy results

### INDICATION

VYZULTA<sup>®</sup> (latanoprostene bunod ophthalmic solution), 0.024% is indicated for the reduction of intraocular pressure (IOP) in patients with open-angle glaucoma or ocular hypertension.

### IMPORTANT SAFETY INFORMATION

- Increased pigmentation of the iris and periorbital tissue (eyelid) can occur. Iris pigmentation is likely to be permanent
- Gradual changes to eyelashes, including increased length, increased thickness, and number of eyelashes, may occur. These changes are usually reversible upon treatment discontinuation
- Use with caution in patients with a history of intraocular inflammation (iritis/uveitis). VYZULTA should generally not be used in patients with active intraocular inflammation
- Macular edema, including cystoid macular edema, has been reported during treatment with prostaglandin analogs. Use with caution in aphakic patients, in pseudophakic patients with a torn posterior lens capsule, or in patients with known risk factors for macular edema

### IMPORTANT SAFETY INFORMATION cont'd

- There have been reports of bacterial keratitis associated with the use of multiple-dose containers of topical ophthalmic products that were inadvertently contaminated by patients
- Contact lenses should be removed prior to the administration of VYZULTA and may be reinserted 15 minutes after administration
- Most common ocular adverse reactions with incidence  $\geq 2\%$  are conjunctival hyperemia (6%), eye irritation (4%), eye pain (3%), and instillation site pain (2%)

For more information, please see Brief Summary of Prescribing Information on next page.

**References:** 1. VYZULTA Prescribing Information. Bausch & Lomb Incorporated. 2. Cavet ME. *J Ocul Pharmacol Ther.* 2018;34(1):52-60. DOI:10.1089/jop.2016.0188. 3. Wareham LK. *Nitric Oxide.* 2018;77:75-87. DOI:10.1016/j.niox.2018.04.010. 4. Stamer DW. *Curr Opin Ophthalmol.* 2012;23:135-143. DOI:10.1097/ICU.0b013e32834ff23e. 5. Cavet ME. *Invest Ophthalmol Vis Sci.* 2015;56(6):4108-4116. 6. Kaufman PL. *Exp Eye Research.* 2008;86:1-3-17. DOI:10.1016/j.exer.2007.10.007. 7. Weinreb RN. *J Glaucoma.* 2018;27:7-15. 8. Weinreb RN. *Ophthalmology.* 2016;123(5):965-973. 9. Medeiros FA. *Am J Ophthalmol.* 2016;168:250-259.



## BRIEF SUMMARY OF PRESCRIBING INFORMATION

This Brief Summary does not include all the information needed to use VYZULTA safely and effectively. See full Prescribing Information for VYZULTA.

**VYZULTA<sup>®</sup>** (latanoprostene bunod ophthalmic solution), 0.024%, for topical ophthalmic use.

Initial U.S. Approval: 2017

### 1 INDICATIONS AND USAGE

VYZULTA<sup>®</sup> (latanoprostene bunod ophthalmic solution) 0.024% is indicated for the reduction of intraocular pressure (IOP) in patients with open-angle glaucoma or ocular hypertension.

### 4 CONTRAINDICATIONS

None

### 5 WARNINGS AND PRECAUTIONS

#### 5.1 Pigmentation

VYZULTA<sup>®</sup> (latanoprostene bunod ophthalmic solution), 0.024% may cause changes to pigmented tissues. The most frequently reported changes with prostaglandin analogs have been increased pigmentation of the iris and periorbital tissue (eyelid).

Pigmentation is expected to increase as long as latanoprostene bunod ophthalmic solution is administered. The pigmentation change is due to increased melanin content in the melanocytes rather than to an increase in the number of melanocytes. After discontinuation of VYZULTA, pigmentation of the iris is likely to be permanent, while pigmentation of the periorbital tissue and eyelash changes are likely to be reversible in most patients. Patients who receive prostaglandin analogs, including VYZULTA, should be informed of the possibility of increased pigmentation, including permanent changes. The long-term effects of increased pigmentation are not known.

Iris color change may not be noticeable for several months to years. Typically, the brown pigmentation around the pupil spreads concentrically towards the periphery of the iris and the entire iris or parts of the iris become more brownish. Neither nevi nor freckles of the iris appear to be affected by treatment. While treatment with VYZULTA<sup>®</sup> (latanoprostene bunod ophthalmic solution), 0.024% can be continued in patients who develop noticeably increased iris pigmentation, these patients should be examined regularly [see Patient Counseling Information (17) in full Prescribing Information].

#### 5.2 Eyelash Changes

VYZULTA may gradually change eyelashes and vellus hair in the treated eye. These changes include increased length, thickness, and the number of lashes or hairs. Eyelash changes are usually reversible upon discontinuation of treatment.

#### 5.3 Intraocular Inflammation

VYZULTA should be used with caution in patients with a history of intraocular inflammation (iritis/uveitis) and should generally not be used in patients with active intraocular inflammation as it may exacerbate this condition.

#### 5.4 Macular Edema

Macular edema, including cystoid macular edema, has been reported during treatment with prostaglandin analogs. VYZULTA should be used with caution in aphakic patients, in pseudophakic patients with a torn posterior lens capsule, or in patients with known risk factors for macular edema.

#### 5.5 Bacterial Keratitis

There have been reports of bacterial keratitis associated with the use of multiple-dose containers of topical ophthalmic products. These containers had been inadvertently contaminated by patients who, in most cases, had a concurrent corneal disease or a disruption of the ocular epithelial surface.

#### 5.6 Use with Contact Lens

Contact lenses should be removed prior to the administration of VYZULTA because this product contains benzalkonium chloride. Lenses may be reinserted 15 minutes after administration.

### 6 ADVERSE REACTIONS

The following adverse reactions are described in the Warnings and Precautions section: pigmentation (5.1), eyelash changes (5.2), intraocular inflammation (5.3), macular edema (5.4), bacterial keratitis (5.5), use with contact lens (5.6).

#### 6.1 Clinical Trials Experience

Because clinical trials are conducted under widely varying conditions, adverse reaction rates observed in the clinical trials of a drug cannot be directly compared to rates in the clinical trials of another drug and may not reflect the rates observed in practice.

VYZULTA was evaluated in 811 patients in 2 controlled clinical trials of up to 12 months duration. The most common ocular adverse reactions observed in patients treated with latanoprostene bunod were: conjunctival hyperemia (6%), eye irritation (4%), eye pain (3%), and instillation site pain (2%). Approximately 0.6% of patients discontinued therapy due to ocular adverse reactions including ocular hyperemia, conjunctival irritation, eye irritation, eye pain, conjunctival edema, vision blurred, punctate keratitis and foreign body sensation.

### 8 USE IN SPECIFIC POPULATIONS

#### 8.1 Pregnancy

##### Risk Summary

There are no available human data for the use of VYZULTA during pregnancy to inform any drug associated risks.

Latanoprostene bunod has caused miscarriages, abortion, and fetal harm in rabbits. Latanoprostene bunod was shown to be abortifacient and teratogenic when administered intravenously (IV) to pregnant rabbits at exposures  $\geq 0.28$  times the clinical dose. Doses  $\geq 20$   $\mu\text{g}/\text{kg}/\text{day}$  (23 times the clinical dose) produced 100%

embryofetal lethality. Structural abnormalities observed in rabbit fetuses included anomalies of the great vessels and aortic arch vessels, domed head, sternebral and vertebral skeletal anomalies, limb hyperextension and malrotation, abdominal distension and edema. Latanoprostene bunod was not teratogenic in the rat when administered IV at 150 mcg/kg/day (87 times the clinical dose) [see Data].

The background risk of major birth defects and miscarriage for the indicated population is unknown. However, the background risk in the U.S. general population of major birth defects is 2 to 4%, and of miscarriage is 15 to 20%, of clinically recognized pregnancies.

##### Data

##### Animal Data

Embryofetal studies were conducted in pregnant rabbits administered latanoprostene bunod daily by intravenous injection on gestation days 7 through 19, to target the period of organogenesis. The doses administered ranged from 0.24 to 80 mcg/kg/day. Abortion occurred at doses  $\geq 0.24$  mcg/kg/day latanoprostene bunod (0.28 times the clinical dose, on a body surface area basis, assuming 100% absorption). Embryofetal lethality (resorption) was increased in latanoprostene bunod treatment groups, as evidenced by increases in early resorptions at doses  $\geq 0.24$  mcg/kg/day and late resorptions at doses  $\geq 6$  mcg/kg/day (approximately 7 times the clinical dose). No fetuses survived in any rabbit pregnancy at doses of 20 mcg/kg/day (23 times the clinical dose) or greater. Latanoprostene bunod produced structural abnormalities at doses  $\geq 0.24$  mcg/kg/day (0.28 times the clinical dose). Malformations included anomalies of sternum, coarctation of the aorta with pulmonary trunk dilation, retroesophageal subclavian artery with absent brachiocephalic artery, domed head, forepaw hyperextension and hindlimb malrotation, abdominal distension/edema, and missing/fused caudal vertebrae.

An embryofetal study was conducted in pregnant rats administered latanoprostene bunod daily by intravenous injection on gestation days 7 through 17, to target the period of organogenesis. The doses administered ranged from 150 to 1500 mcg/kg/day. Maternal toxicity was produced at 1500 mcg/kg/day (870 times the clinical dose, on a body surface area basis, assuming 100% absorption), as evidenced by reduced maternal weight gain. Embryofetal lethality (resorption and fetal death) and structural anomalies were produced at doses  $\geq 300$  mcg/kg/day (174 times the clinical dose). Malformations included anomalies of the sternum, domed head, forepaw hyperextension and hindlimb malrotation, vertebral anomalies and delayed ossification of distal limb bones. A no observed adverse effect level (NOAEL) was established at 150 mcg/kg/day (87 times the clinical dose) in this study.

#### 8.2 Lactation

##### Risk Summary

There are no data on the presence of VYZULTA in human milk, the effects on the breastfed infant, or the effects on milk production. The developmental and health benefits of breastfeeding should be considered, along with the mother's clinical need for VYZULTA, and any potential adverse effects on the breastfed infant from VYZULTA.

#### 8.4 Pediatric Use

Use in pediatric patients aged 16 years and younger is not recommended because of potential safety concerns related to increased pigmentation following long-term chronic use.

#### 8.5 Geriatric Use

No overall clinical differences in safety or effectiveness have been observed between elderly and other adult patients.

### 13 NONCLINICAL TOXICOLOGY

#### 13.1 Carcinogenesis, Mutagenesis, Impairment of Fertility

Latanoprostene bunod was not mutagenic in bacteria and did not induce micronuclei formation in the *in vivo* rat bone marrow micronucleus assay. Chromosomal aberrations were observed *in vitro* with human lymphocytes in the absence of metabolic activation.

Latanoprostene bunod has not been tested for carcinogenic activity in long-term animal studies. Latanoprost acid is a main metabolite of latanoprostene bunod. Exposure of rats and mice to latanoprost acid, resulting from oral dosing with latanoprost in lifetime rodent bioassays, was not carcinogenic.

Fertility studies have not been conducted with latanoprostene bunod. The potential to impact fertility can be partially characterized by exposure to latanoprost acid, a common metabolite of both latanoprostene bunod and latanoprost. Latanoprost acid has not been found to have any effect on male or female fertility in animal studies.

#### 13.2 Animal Toxicology and/or Pharmacology

A 9-month toxicology study administered topical ocular doses of latanoprostene bunod to one eye of cynomolgus monkeys: control (vehicle only), one drop of 0.024% bid, one drop of 0.04% bid and two drops of 0.04% per dose, bid. The systemic exposures are equivalent to 4.2-fold, 7.9-fold, and 13.5-fold the clinical dose, respectively, on a body surface area basis (assuming 100% absorption). Microscopic evaluation of the lungs after 9 months observed pleural/subpleural chronic fibrosis/inflammation in the 0.04% dose male groups, with increasing incidence and severity compared to controls. Lung toxicity was not observed at the 0.024% dose.

U.S. Patent Numbers: 7,273,946; 7,629,345; 7,910,767; 8,058,467.

VYZULTA is a trademark of Bausch & Lomb Incorporated or its affiliates.

© 2019 Bausch & Lomb Incorporated or its affiliates.

##### Distributed by:

Bausch + Lomb, a division of

Valeant Pharmaceuticals North America LLC

Bridgewater, NJ 08807 USA

Based on 9612402 (Folded), 9612302 (Flat) 6/2018

VYZ.0058.USA.19 Issued: 3/2019

## IN THE NEWS

An evaluation of the use of essential fatty acids in topical ophthalmic preparations for dry eye has revealed that **higher concentrations of fatty acids make tear films less stable**. “In topical applications, the **omega-6 linoleic acid (not omega-3 fatty acid) at low concentrations (20 mol%) can be beneficial** for enhancing tear stability in dry eye patients,” the report concluded.

Mudil P. Evaluation of use of essential fatty acids in topical ophthalmic preparations for dry eye. *Ocul Surf.* October 4, 2019. [Epub ahead of print].

**Eyes with wet AMD may achieve satisfactory long-term visual outcomes** if they receive adequate anti-VEGF treatment. The mean visual acuity in 132 eyes from Australia or New Zealand that completed 10 years of treatment dropped by 0.9 letters from baseline. The research added **that central macular atrophy does not develop universally in eyes on long-term treatment**.

Gillies M, Arnold J, Bhandaria S, et al. Ten-year treatment outcomes of neovascular age-related macular degeneration from two regions. *Am J Ophthalmol.* October 10, 2019. [Epub ahead of print].

Despite being high-risk patients, **very few of those with glaucoma developed visual impairment due to the disease**. Patient data from 1981 to 2017 showed only seven out of 77 (9%) had become bilaterally visually impaired, only two of which had glaucoma to blame. No eyes experienced glaucoma-induced visual impairment or blindness at five years, but incidences rose to 0.22 for visual impairment and 0.17 for blindness at 30 years, respectively.

Oskarsdottir SE, Hejli A, Midlöv P, et al. Lifetime risk of visual impairment due to glaucoma in patients initially followed for elevated intraocular pressure. *Ophthalmology.* October 3, 2019. [Epub ahead of print].

## Despite Vaccination Efforts, HZO On the Rise

Study reported a 3.6% jump in new cases and an increase in middle-aged patients.

By Jane Cole, Contributing Editor

**H**erpes zoster ophthalmicus (HZO) is increasing in the United States, particularly in people who are middle-aged, prompting some to wonder if greater efforts should be made to vaccinate eligible adults 50 and older, researchers from the University of California said.

Their study, published in *Ophthalmology*, found a 3.6% overall increase in HZO cases from 1994 to 2018. Since 2008, HZO has declined in people younger than 21 and older than 60 but increased at a lower rate in middle-aged adults, the investigators said.

The researchers used data from administrative claims and electronic healthcare records. Patients who had no prior history but were given a new code for HZ and HZO were included. The study calculated the incidence rate of HZO by year, 10-year age groups, sex, race and geographic region.

During the 24-year study period, investigators found 633,474 cases of HZ, with 49,745 cases of HZO (7.9%). Additionally, the incidence of HZO increased from 1994 to 2018 by an estimated 1.1 cases per 100,000 persons/years annually. The researchers noted HZO increased in all ages over 10

until 2007. After that, the study reported a decline in individuals younger than 21 and older than 60; a stabilization in individuals 21 to 30; and a slower increase in subjects aged 31 to 60.

The research team also found females and Caucasians were at higher risk of developing HZO.

Looking at geography, HZO rates were highest in the Northeast and lowest in the West, which may be tied to vaccinations, the researchers noted. A 2014 analysis found vaccination rates were the second lowest in the Northeast at 30.3% and highest in the West at 37.4%, they said in their paper.

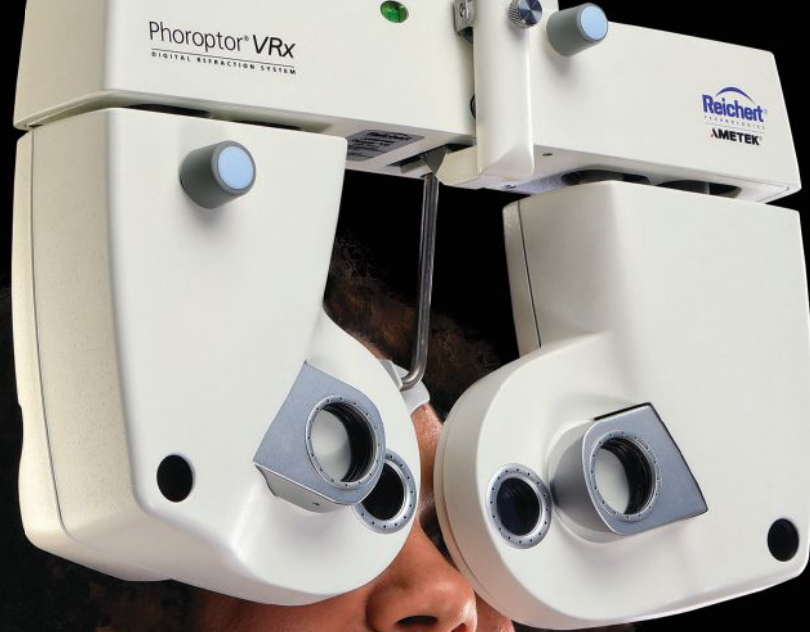More research on earlier vaccination is warranted, the researchers suggested.

“Given the potential shift in HZO burden towards middle-aged individuals, it is crucial for clinicians to support vaccination efforts for individuals 50 years of age and older. These results also raise the question of whether HZ vaccine recommendations should be reevaluated for individuals in younger age groups,” the researchers wrote in their paper.

Kong CL, Thompson RR, Porco TC, et al. Incidence rate of herpes zoster ophthalmicus: a retrospective cohort study from 1994 to 2018. *Ophthalmology.* October 9, 2019. [Epub ahead of print].

NEWS STORIES POST EVERY WEEKDAY MORNING AT [www.reviewofoptometry.com/news](http://www.reviewofoptometry.com/news)





Passionate about patient experience?

“MY PATIENTS CAN DEFINITELY TELL I AM.”







Multitasker **Lisa Genovese, OD**, co-owner of **Insight Eye Care's** multiple locations, talks about using technology to efficiently juggle being a full-time optometrist, a full-time entrepreneur, and a full-time parent. By using the most advanced Phoroptor®, **Phoroptor® VRx**, and the pixel-perfect **ClearChart® 4** Digital Acuity System, she's brought balance to her practice and personal life.



WATCH OUR NEW SERIES AT:  
[PASSIONATEABOUTEYECARE.COM](https://PASSIONATEABOUTEYECARE.COM)

**Reichert**  
TECHNOLOGIES  
PASSIONATE ABOUT EYE CARE

**AMETEK**

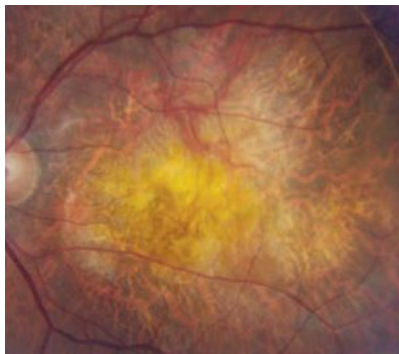
© 2019 AMETEK, Inc. & Reichert, Inc. (11-2019) Phoroptor and ClearChart are registered trademarks of Reichert, Inc. · Phoroptor and ClearChart are designed & assembled in USA      

## Declining Vision Tied to Dosing Intervals

*Wet AMD patients have upped their treatments more than the recommended dosage.*

Researchers from Switzerland and the United States found patients with neovascular age-related macular degeneration (nAMD) experienced a decline in their visual acuity and underwent injection treatments more often over a four-year period. The investigation also reported an increase in the proportion of eyes that received intravitreal anti-VEGF treatments beyond the recommended dosage. All of this may be in an effort to stave off continued visual acuity loss and disease progression, according to the study published in *Ophthalmology Retina*.

The study is the largest electronic medical record (EMR) analysis to evaluate the treatment patterns and long-term visual outcomes in nAMD patients in the United States, the researchers said. It included 98,821 eyes of 78,885 patients who



**Wet AMD eyes undergo injection treatments more often, a study found.**

had anti-VEGF therapy between 2012 and 2015.

In eyes that had a four-year follow-up, the study found visual acuity improved in the first year but declined steadily afterward, with an average of -5.2 ETDRS letters by the fourth year of follow-up. Also, the average number of injections dropped each year of the study

from 7.5 in 2012 to 6.4 in 2015.

By year four, 36.7% of eyes had dosing intervals of eight weeks or less, while 21.2% received treatment at 12 or more weeks. Eyes treated at less than eight weeks increased 40% from year one to year four. For patients treated bilaterally, 32% received the first treatment in the better-seeing eye, and 68% received the first treatment in an eye with vision that was the same or worse than the fellow-eye. This trend was evident across all years studied.

The researchers highlighted the wealth of data contained in EMR databases for evaluating longitudinal treatment patterns and outcomes in patients with nAMD following anti-VEGF therapy.

Khanani AM, Skelly A, Bezlyak V, et al. A retrospective, real-world evidence study of patients with neovascular age-related macular degeneration in the USA. *Ophthalmology Retina*. September 27, 2019. [Epub ahead of print].

## Anti-VEGF Outcomes Neck-and-neck

Researchers investigating the efficacy of ranibizumab and aflibercept in the treatment of neovascular age-related macular degeneration (nAMD) found the two were comparable in terms of visual acuity (VA) outcomes and treatment frequency at the three-year mark.

The retrospective analysis evaluated 965 eyes of 897 patients—469 (499 eyes) treated with ranibizumab and 432 (466 eyes) treated with aflibercept. The mean VA and the type of choroidal neovascular (CNV) lesion at baseline were similar between both groups. After three years of

treatment, the mean VA change was similar between both groups: +1.5 letters for ranibizumab and +1.6 for aflibercept. The mean adjusted change in VA was +0.3 vs. +1.0, respectively.

The researchers added that those who completed three years of therapy received a median of 18 injections regardless of the anti-VEGF used. Even when the CNV was deemed active, the number of clinical visits remained steady between the two agents. A similar proportion of eyes did not complete three years of treatment in each group, although more eyes switched from ranibizumab to

aflibercept than vice-versa.

“These data suggest ranibizumab and aflibercept achieve similar visual outcomes for nAMD in routine clinical practice with the same mean number of injections over a three-year time frame,” the study authors concluded in their paper. “Other issues, such as cost, convenience and availability, may be more useful to guide a patient and physician’s choice of drug rather than the relative efficacy of the currently available drugs.”

Bhandari S, Nguyen V, Arnold J, et al. Treatment outcomes of ranibizumab versus aflibercept for neovascular age-related macular degeneration: data from the Flight Retinal Blindness! Registry. *Ophthalmology*. October 11, 2019. [Epub ahead of print].

Hypochlorous Acid Solution  
**NOW Available Without a Prescription**

**zenoptiq™**  
Hypochlorous Acid Solution

**zenoptiq™**  
0.01% Hypochlorous Acid

Daily Eyelid  
& Eyelash Hygiene  
Solution

Gentle | Soothing | All Natural



3.38oz (100mL)

**zenoptiq™**  
0.0085% Hypochlorous Acid

Daily Eyelid  
& Eyelash Hygiene  
Solution

Gentle | Soothing | All Natural



2.0oz (60.0mL)

## Daily Eyelid & Eyelash Cleanser

- Naturally removes foreign matter
- Nontoxic, nonirritating
- Has been shown in studies to reduce bacteria/microbes
- Formulated to relieve symptoms of MGD, Blepharitis and Dry Eye
- Available in 0.01 % HOCL spray and 0.0085% HOCL gel

LEARN MORE AT  
**zenoptiq.com**



(866) 752-6006 – FocusLaboratories.com

Trademarks: Zenoptiq™ (Paragon BioTech, Inc.) | Copyright © 2018 Paragon BioTech, Inc. All Rights Reserved.



# California Looks to Dim Blue Lights

Legislation aims to shade children from effects of glowing screens.

The impact of blue light on the health of children has pediatrician and California State Senator Richard Pan, MD, seeing red. That's why he led the charge to pass a resolution that outlines research related to the long-term consequences of extended blue light exposure. It also urges consumers to consider taking protective safety measures in reducing exposure to the high-energy blue light seen in common devices such as computer monitors, phones and tablets.

The resolution, SCR 73, or the Blue Light Awareness Resolution, was passed unanimously. Additionally, the state will officially recognize October 10 as World Sight Day.<sup>1</sup> The precise research the state intends to highlight is not yet clear, but a website about

the resolution provides links to a 2011 study, "Computer vision syndrome: a review of ocular causes and potential treatments," published in *Ophthalmic & Physiological Optics*. It also refers to a 2015 article from the *Journal of Adolescent Health* titled "Blue blocker glasses as a countermeasure for alerting effects of evening light-emitting diode screen exposure in male teenagers."<sup>2</sup> The researchers speculate about a number of potential deleterious health effects of blue light overexposure, including sleep disruption, associations with macular degeneration, dry eye and headaches.

There are 80 million electronic devices with digital screens in California alone and many residents use them more than nine hours per day, according to the resolution.

The California legislation was supported by Eyesafe, a Minneapolis-based company that sells blue light-blocking screen protectors. In addition to working with California legislators, the company also partnered with Salus University's Pennsylvania College of Optometry in creating a research project to study the impact of blue light exposure and publishing the newly announced resource *How to Save Your Eyes in the Digital Age: The Handbook for Eye Care and Electronics*.<sup>3</sup>

1. Senate Concurrent Resolution No. 73 Relative to Blue Light Awareness Day. [leginfo.ca.gov/faces/bill-TextClient.xhtml?bill\\_id=201920200SCR73](http://leginfo.ca.gov/faces/bill-TextClient.xhtml?bill_id=201920200SCR73). September 19, 2019. Accessed October 22, 2019.

2. Eyesafe. California blue light resolution scr-73. [eyesafe.com/scr73](http://eyesafe.com/scr73). October 10, 2019. Accessed October 22, 2019.

3. Eyesafe. Salus University partners with eyesafe on blue light and screen time program. [eyesafe.com/salus-university-partners-with-eyesafe-on-blue-light-and-screen-time-program](http://eyesafe.com/salus-university-partners-with-eyesafe-on-blue-light-and-screen-time-program). October 10, 2019. Accessed October 22, 2019.

## Standard CXL Still the Way to Go

Corneal collagen crosslinking (CXL) is quickly becoming an important part of the keratoconus treatment protocol. Despite its success, researchers continue to search for ways to improve the standard Dresden protocol. Even with up to eight different combinations of CXL, the Dresden protocol still provides the best chances of controlling keratoconus progression.

Researchers examined the one-year outcomes for 670 eyes of 461 patients with progressive keratoconus treated with various CXL techniques, including: epi-on or epi-off, conventional 3mW/cm<sup>2</sup> or accelerated 9mW/cm<sup>2</sup> and seven

different riboflavin formulations. Standard CXL served as the reference point for the study.

When comparing all eight combinations, the researchers found the epi-on technique performed significantly worse based on maximum keratometry (Kmax) and mean keratometry (Kmean) readings compared with those who had the standard CXL protocol. Likewise, patients treated with a specific riboflavin formulation called Meran, and those who underwent an accelerated protocol, also experienced worse Kmax and Kmean at the one-year follow-up.

The Meran riboflavin group also had poorer post-op corrected

distance visual acuity; none of the other combinations showed any statistical difference in visual acuity from standard CXL. Although only 2.1% of treated eyes required retreatment, most were in the epi-on group.

Even if the standard protocol is less comfortable and more time-consuming than some of the newer techniques, epi-off CXL combined with a UVA intensity of 3mW/cm<sup>2</sup> is the preferred treatment protocol for patients with progressive keratoconus, the researchers concluded.

Godefrooij DA, Roohé SL, Soeters N, Wisse RPL. The independent effect of various cross-linking treatment modalities on treatment effectiveness in keratoconus. *Cornea*. October 1, 2019. [Epub ahead of print].

# THE *Shape* OF THINGS TO COME

The next generation of amniotic membrane technology is available now. *Shaped* with a convenient tab handle for easy tissue manipulation and simple orientation.

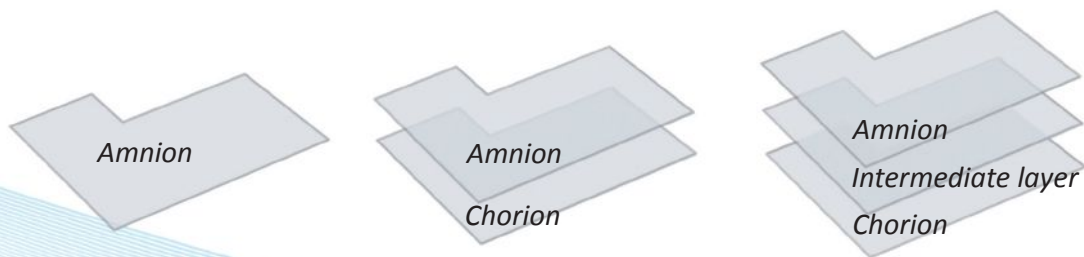


Next generation AmbioDisk®  
office amniotic membrane graft



Next generation Ambio surgical  
amniotic membrane grafts

The new, next-generation Clearify™ process now preserves three layers of amniotic membrane, including the intermediate layer.



Contact Katena at **973-989-1600** for more information on the next generation amniotic membrane products. [www.katena.com](http://www.katena.com)

AmbioDisk, Ambio2 and Ambio5 are registered trademarks.  
©2016 Katena Products Inc. All rights reserved.  
Clearify is a trademark of StimLabs LLC.

KB-Adv-062419-Rev1

 **katena**  
DESIGNED FOR SIGHT®

# Compliance is Cost-effective in Glaucoma

*The lifetime cost was about \$10,000 more for patients who took their meds regularly.*

Glaucoma patients who take their medications on a regular basis enjoy a better quality of life, and a new study shows this benefit comes with a relatively low increase in their lifetime healthcare costs compared with those who aren't compliant with their meds, according to a study in *Ophthalmology*.

A team of researchers conducted a cost-analysis that compared optimal with poor glaucoma medication adherence. They found the total healthcare costs for compliant patients averaged \$62,782 compared with \$52,722 for those who didn't take their medications on a regular basis—or an approximate \$10,000 difference.

The investigation used data from the United Kingdom Glaucoma Treatment Study and included patients who were 40 and older with a full life expectancy. The subjects started out with a mean deviation in the better-seeing eye of  $-1.4 \pm 1.9$  dB and  $-4.3 \pm 3.4$  dB in

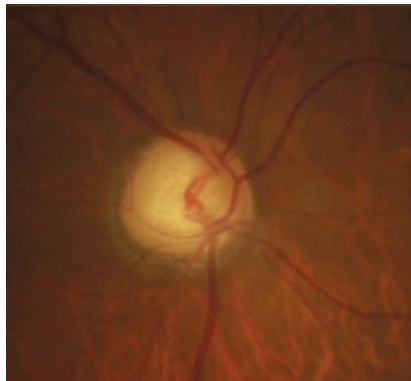


Photo: Justin Cole, OD, and Jared Mazzarella, OD

**Non-adherent patients progressed to single-eye blindness in about 19 years.**

the eye with worse vision.

Participants whose vision deteriorated each year accumulated  $-0.8$  dB loss compared with  $-0.1$  dB loss for those who remained stable. The investigation also used data from the Glaucoma Laser Trial and the Tube vs. Trabeculectomy studies to assign probabilities of worsening disease among treated patients and claims data estimating rates of glaucoma medication adherence over four years to assign

probability of adherence. As patients' mean deviation deteriorated, they transitioned between health states from mild ( $\geq -6$  dB) to moderate ( $< -6$  dB to  $\geq -12$  dB) to severe glaucoma ( $< -12$  dB to  $\geq 23$  dB) to unilateral ( $< -20$  dB) and bilateral blindness. The study calculated the cost of treatment at each health state.

Beginning at an initial glaucoma diagnosis at age 40, patients progressed to single-eye blindness in as early as 19 years among those who were non-adherent and 23 years for those who remained compliant.

The study also noted non-adherent patients had a loss of about 0.34 quality-adjusted-life-years (QALY), which resulted in approximately \$29,600 per QALY gained.

At a conservative estimate of \$50,000 for those who were noncompliant, there is much more room to expand services to improve patient adherence, the researchers suggested.

This is the first study to model the cost-effectiveness of improving glaucoma medication adherence from a societal perspective, the study noted.

“From even a conservative cost-effectiveness standpoint, there is opportunity to allocate more resources to improving adherence while remaining highly cost-effective,” the researchers wrote in their paper. “Therefore, it is imperative to focus on developing cost-effective programs to better support people in taking their glaucoma medications on time, every day.” ■

## Glaucoma Linked to Cognitive Decline

Age-related eye disease may be related to cognitive decline, but the exact relationship remains unexplained within the scientific literature. A new study found that glaucoma patients score lower on cognitive tests, while the same relationship doesn't exist for age-related macular degeneration patients.

This cross-sectional, hospital-based study evaluated 336 adults aged 65 or older. A team measured cognition with six verbal cognitive tests, as well as activity level, visual acuity and visual fields.

Patients with glaucoma scored lower on the digit span forward test, recalling 0.8 fewer digits than those with normal vision. The glaucoma group also scored lower on the digit span backward version and the logical memory test with immediate recall than participants with normal vision. The researchers noted that activity level mediated the relationship between glaucoma and the digit span forward test in a statistically significant manner.

To slow cognitive decline among those with ocular health problems, the team suggested developing cognitive training exercises geared toward people with vision loss.

Varin M, Kergoat MJ, Belleville S, et al. Age-related eye disease and cognitive function: the search for mediators. *Ophthalmology*. October 9, 2019. [Epub ahead of print].

Naranjo A, Arboleda A, Martinez J, et al. Rose bengal photodynamic antimicrobial therapy (RB-PDAT) for patients with progressive infectious keratitis: a pilot clinical study. *Am J Ophthalmol*. September 5, 2019. [Epub ahead of print].





**NEW**  
TO ACUVUE®



## ACUVUE™ RevitaLens MPDS: a solution for your patients

James Cook, Meredith Jansen-Bishop, Chantal Coles-Brennan and David Ruston

### Functions

A multipurpose contact lens solution (MPS) has to perform a delicate balancing act: to deliver effective disinfection against pathogens while being gentle enough to be introduced directly to the eye. Further functions include enhancing on-eye contact lens comfort and wettability, ease of use, and being compatible with a wide range of contact lens materials. Formulating an MPS to meet all of these functions is truly a complex challenge.

### Efficacy

Formulations of MPS vary, and clearly so does their performance in standard testing. Two categories exist. Multipurpose *disinfecting* solutions (MPDS) pass the more rigorous 'stand-alone' test, where numbers of test bacteria and fungi are significantly reduced without any cleaning intervention.<sup>1</sup> In contrast, a MPS solution cannot achieve this level of disinfection under stand-alone conditions, and has to pass a second 'regimen' test that involves a contact lens undergoing the full recommended rub and rinse routine.

**ACUVUE™ RevitaLens MPDS produces exceptional levels of disinfection in the rigorous stand-alone test. These results demonstrate a similar level of performance to hydrogen peroxide systems.<sup>3-5</sup>**

### Real-world challenges

Beyond standard testing, contact lens solutions are further challenged by real-world conditions. These include exposure to a wide range of pathogens, including *Acanthamoeba*, and to wide-spread patient non-compliance of correct cleaning and safe wearing practices such as poor hygiene, incorrect case care and exposure to water.<sup>2</sup> It is also important for a contact lens solution to be able to demonstrate efficacy in these situations.

### Introducing ACUVUE™ RevitaLens MPDS

ACUVUE™ RevitaLens MPDS is a care solution which performs across these key functions. It has been shown to deliver peroxide-quality disinfection with the simplicity and all-day comfort of an advanced multipurpose solution.<sup>3-7</sup> It is also compatible with a wide range of contact lens materials including ACUVUE® Brand Contact Lenses.

### Performance

#### DISINFECTION COMPARABLE TO PEROXIDE SYSTEMS

ACUVUE™ RevitaLens MPDS produces exceptional levels of disinfection in the rigorous stand-alone test. These results demonstrate a similar level of performance to hydrogen peroxide systems,<sup>3-5</sup> and enable the solution to be categorised as a multipurpose **disinfecting** solution (MPDS). ACUVUE™ RevitaLens MPDS also provides greater than 99.9% kill-rate against both active and cyst forms of *Acanthamoeba*.<sup>3,8</sup>

#### DELIVERS ALL-DAY COMFORT

After one month of use, ninety percent of wearers agreed that ACUVUE™ RevitaLens MPDS was effective in keeping their contact lenses feeling comfortable. More than 9 in 10 (94%) agreed that it also was effective in keeping their contact lenses feeling clean.<sup>6</sup>

#### COMPATIBLE WITH A WIDE-RANGE OF LEADING CONTACT LENSES

Use of ACUVUE™ RevitaLens MPDS resulted in positive comfort scores and all-day comfort across two studies with ACUVUE® Brand Contact Lenses.<sup>7,9</sup> All day comfort has also been demonstrated with other leading reusable brand contact lenses.<sup>7</sup>

### Summary

For a typical patient, wearing reusable contact lenses and leading a busy life, ACUVUE™ RevitaLens MPDS delivers a safe, simple and comfortable option. Truly a solution for your patients.

**Mr. James Cook** is Senior Manager Product Development, **Dr. Meredith Jansen-Bishop** is Senior Principal Research Optometrist, **Dr. Chantal Coles-Brennan** is Principal Research Optometrist and **Mr. David Ruston** is Director of Global Professional Education and Development at Johnson and Johnson Vision Care Inc.

**References:** 1. ISO 14729:2001. Ophthalmic optics - Contact lens care products - Microbiological requirements and test methods for products and regimens for hygienic management of contact lenses. 2001 Available at: <https://www.iso.org/standard/25382.html>. 2. Morgan PB, Efron N, Toshida H, et al. An international analysis of contact lens compliance. *Contact Lens & Anterior Eye* 2011;34:223-8. 3. Nikolic M, Kilvington S, Brady N, et al. *Comparative Efficacy Of New Contact Lens Care Solutions Against Bacteria, Fungi And Acanthamoeba*. *Investigative Ophthalmology & Visual Science* 2011;52:5837. 4. Kilvington S, Powell CH, Lam A, et al. Antimicrobial efficacy of multi-purpose contact lens disinfectant solutions following evaporation. *Contact Lens & Anterior Eye* 2011;34:183-7. 5. Heaselgrave W, Kilvington S, Lonnen J. *Efficacy of contact lens care solutions against clinical microorganisms*. *Contact Lens and Anterior Eye* 2011;34:S30. 6. Owen JP. *Global RevitaLens Experience and Acceptance Trial (GREAT)*. Multi-center, open-label, non-comparative study. 2979 soft CL wearers Europe and US. MPS users. 1 month wear with Revitalens. 94% very effective, more effective, somewhat effective (T3B very effective/more effective/somewhat effective) in keeping their contact lenses feeling clean. IOVS March 2012, Vol 53, 4720; 2012. 7. JJV Data on File 2018. ACUVUE™ RevitaLens Multipurpose Disinfecting Solution Packaging Claims. 8. Kilvington S, Huang L, Kao E, et al. *Development of a new contact lens multipurpose solution: Comparative analysis of microbiological, biological and clinical performance*. *Journal of Optometry* 2010;3:134-42. 9. Berntsen DA, Hickson-Curran SB, Jones LW, et al. *Subjective Comfort and Physiology with Modern Contact Lens Care Products*. *Optometry and Vision Science* 2016;93:809-19.

ACUVUE™ RevitaLens MPDS is indicated for the care of soft (hydrophilic) contact lenses, including silicone hydrogel lenses. Use this product as directed on the product carton to disinfect, clean, rinse, store, remove protein, and condition contact lenses. Do not use this product if allergic to any ingredient in ACUVUE™ RevitaLens MPDS. Problems with contact lenses and lens care products could result in corneal infection and/or ulcers and lead to loss of vision. It is essential that patients follow the directions and labeling instructions for proper use of lenses and lens care products, including the lens case.

ACUVUE™ RevitaLens is a trademark of Johnson & Johnson Vision Care, Inc.

© Johnson & Johnson Vision Care, Inc. 2019 PP2019AVRL4059

**Johnson & Johnson** VISION

# Keeler

# Complimentary

# FREE AIR

## Free air with the TonoCare

Easy-to-use, intuitive controls for quick learning.



[calcoastophthalmic.com](http://calcoastophthalmic.com)



[deviceoptical.com](http://deviceoptical.com)

LOMBART

[lombartinstrument.com](http://lombartinstrument.com)

INNOVA

[innovamed.com](http://innovamed.com)

THE TONOCARE CAN BE PURCHASED ON OUR WEBSITE OR THROUGH ANY OF OUR PARTNERS LISTED ABOVE.

# Keeler

[www.keelerusa.com](http://www.keelerusa.com) • 3222 Phoenixville Pike - Bldg. #50 • Malvern, PA 19355  
Tel No: 1-610-353-4350 • Toll Free: 1-800-523-5620 • Fax: 1-610-353-7814

  
A Halma company

# Contents

Review of Optometry November 15, 2019

## PROMOTING EYELID HEALTH

### 38 A Close Look at Common Lid Lesions

Although benign most of the time, eyelid and periorbital lesions require careful diagnosis. These pearls can help you differentiate several you are likely to see. **By Sara Weidmayer, OD, and Molly McGinty-Tauren, OD**

### 46 At the Crossroads of Allergy, Dry Eye and Lid Disease

Any of these ocular surface issues can set off inflammation. Here's how to get to the root of the problem. **By Jennifer S. Harthan OD, and Clare Halleran, OD**

### 52 Lashing Out: Dangerous Beauty Trends

If patients aren't mindful of the steps they are taking to modify their ocular features, they may end up doing more harm than good. **By Tracy Doll, OD**

### 58 In-Office and At-Home Lid Maintenance

Keeping dry eye at bay can require patients and ODs to adopt a new hygiene regimen. Here are some options. **By Whitney Hauser, OD**

### 64 The Optometry Office Reimagined

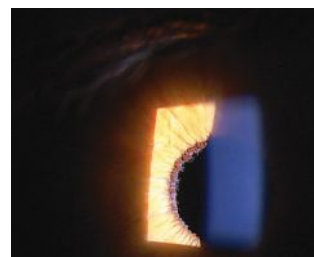
These new spaces emphasize patient comfort as much as they do state-of-the-art technology and exceptional clinical care. **By RO Staff**



Earn 2 CE Credits:

### 74 Overcoming Secondary Glaucomas

A proper understanding of these conditions is paramount in providing swift and appropriate care. **By Michael Cymbor, OD, and Jenae Stiles, OD**

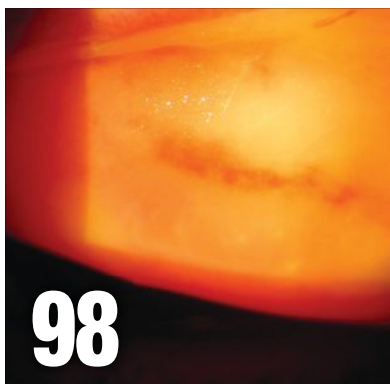
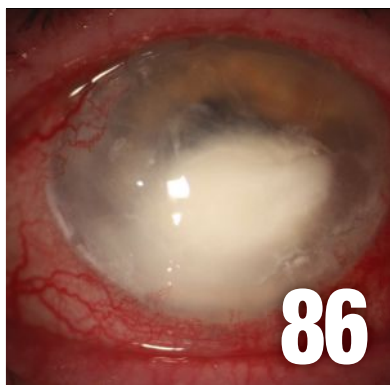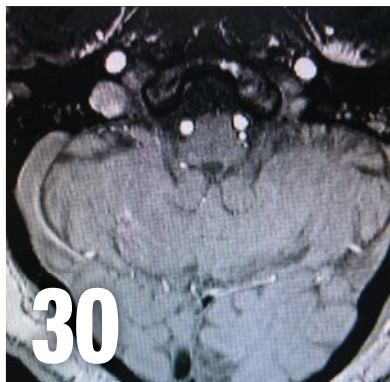
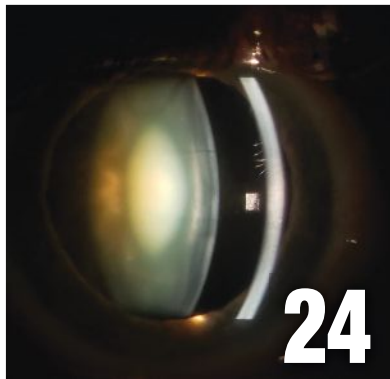




# Departments

Review of Optometry November 15, 2019

- 4 News Review**
- 18 Outlook**  
A Tale of Two Academies  
**JACK PERSICO**
- 20 Through My Eyes**  
Eyelids: Assess and Express  
**PAUL M. KARPECKI, OD**
- 22 Chairside**  
Optometry, Shakespearean Style  
**MONTGOMERY VICKERS, OD**
- 24 Clinical Quandaries**  
The Undercover Cataract  
**PAUL C. AJAMIAN, OD**
- 26 The Essentials**  
The Who and Why of MRI  
**BISANT A. LABIB, OD**
- 30 Neuro Clinic**  
Be a Neuroanatomy Detective  
**MICHAEL TROTTINI, OD,  
MICHAEL DELGIODICE, OD, AND  
AMANDA ALHOUT, BS**
- 34 Coding Connection**  
Coding in More Ways Than One  
**JOHN RUMPAKIS, OD, MBA**
- 85 Cornea + Contact Lens Q&A**  
Proceed With Caution  
**JOSEPH P. SHOVLIN, OD**
- 86 Urgent Care**  
Find Infectious Keratitis's Root  
**DELANEY KENT, OD, AND  
RICHARD MANGAN, OD**
- 88 Review of Systems**  
Common Tumor, Unlikely Location  
**CARLO J. PELINO, OD, AND  
JOSEPH J. PIZZIMENTI, OD**
- 90 Therapeutic Review**  
Deliver Us From Noncompliance  
**JOSEPH W. SOWKA, OD**
- 94 Retina Quiz**  
In Too Deep  
**MARK T. DUNBAR, OD**
- 93 Meetings & Conferences**
- 93 Advertisers Index**
- 96 Classifieds**
- 98 Diagnostic Quiz**  
Can't Get the Red Out  
**ANDREW S. GURWOOD, OD**



## REVIEW<sup>®</sup> OF OPTOMETRY

### BUSINESS OFFICES

11 CAMPUS BLVD., SUITE 100  
NEWTOWN SQUARE, PA 19073

### CEO, INFORMATION SERVICES GROUP

MARC FERRARA  
(212) 274-7062 • MFERRARA@JOBSON.COM

### PUBLISHER

JAMES HENNE  
(610) 492-1017 • JHENNE@JOBSON.COM

### REGIONAL SALES MANAGER

MICHELE BARRETT  
(610) 492-1014 • MBARRETT@JOBSON.COM

### REGIONAL SALES MANAGER

MICHAEL HOSTER  
(610) 492-1028 • MHOSTER@JOBSON.COM

### VICE PRESIDENT, OPERATIONS

CASEY FOSTER  
(610) 492-1007 • CFOSTER@JOBSON.COM

### VICE PRESIDENT, CLINICAL CONTENT

PAUL M. KARPECKI, OD, FFAO  
PKARPECKI@JOBSON.COM

### PRODUCTION MANAGER

SCOTT TOBIN  
(610) 492-1011 • STOBIN@JOBSON.COM

### SENIOR CIRCULATION MANAGER

HAMILTON MAHER  
(212) 219-7870 • HMAHER@JHIHEALTH.COM

### CLASSIFIED ADVERTISING

(888) 498-1460

### SUBSCRIPTIONS

\$56 A YEAR, \$88 (US) IN CANADA,  
\$209 (US) IN ALL OTHER COUNTRIES.

### SUBSCRIPTION INQUIRIES

(877) 529-1746 (US ONLY)  
OUTSIDE US CALL: (845) 267-3065

### CIRCULATION

PO Box 81  
CONGERS, NY 10920  
TEL: (TOLL FREE): (877) 529-1746  
OUTSIDE US: (845) 267-3065

CEO, INFORMATION SERVICES GROUP  
MARC FERRARA

SENIOR VICE PRESIDENT, OPERATIONS  
JEFF LEVITZ

VICE PRESIDENT, HUMAN RESOURCES  
TAMMY GARCIA

VICE PRESIDENT, CREATIVE SERVICES & PRODUCTION  
MONICA TETTAMANZI

CORPORATE PRODUCTION DIRECTOR  
JOHN ANTHONY CAGGIANO

VICE PRESIDENT, CIRCULATION  
EMELDA BAREA



# THERE'S NO SWITCHING THIS

Xiidra is the only lymphocyte function-associated antigen-1 (LFA-1) antagonist treatment for Dry Eye Disease<sup>1,2</sup>

Xiidra, the first in a class of LFA-1 antagonists for Dry Eye Disease, is a prescription eye drop FDA-approved to treat both signs and symptoms of the disease.<sup>1,3</sup>

There's no substitute.<sup>2,4</sup>  
Check out patient resources,  
insurance coverage, and  
more at **Xiidra-ECP.com**

#### References:

1. Xiidra [Prescribing Information]. Lexington, MA: Shire US.
2. TFOS DEWS II Research Subcommittee. Report of the Research Subcommittee of the Tear Film & Ocular Surface Society Dry Eye WorkShop II (2017). *Ocul Surf.* 2017;15(3):269-649.
3. FDA approves new medication for dry eye disease. FDA News Release. July 2016. <http://www.fda.gov/newsevents/newsroom/pressannouncements/ucm510720.htm>. Accessed July 12, 2016.
4. Food and Drug Administration. Electronic Orange Book. <http://www.fda.gov/downloads/Drugs/DevelopmentApprovalProcess/UCM071436.pdf>. Accessed June 26, 2018.

#### Indication

Xiidra® (lifitegrast ophthalmic solution) 5% is indicated for the treatment of signs and symptoms of dry eye disease (DED).

#### Important Safety Information

Xiidra is contraindicated in patients with known hypersensitivity to lifitegrast or to any of the other ingredients.

In clinical trials, the most common adverse reactions reported in 5-25% of patients were instillation site irritation, dysgeusia and reduced visual acuity. Other adverse reactions reported in 1% to 5% of the patients were blurred vision, conjunctival hyperemia, eye irritation, headache, increased lacrimation, eye discharge, eye discomfort, eye pruritus and sinusitis.

To avoid the potential for eye injury or contamination of the solution, patients should not touch the tip of the single-use container to their eye or to any surface.

Contact lenses should be removed prior to the administration of Xiidra and may be reinserted 15 minutes following administration.

Safety and efficacy in pediatric patients below the age of 17 years have not been established.

For additional safety information, see accompanying Brief Summary of Safety Information on the adjacent page and Full Prescribing Information on Xiidra-ECP.com.

©2018 Shire US Inc., Lexington, MA 02421. 1-800-828-2088. All rights reserved. SHIRE and the Shire Logo are trademarks or registered trademarks of Shire Pharmaceutical Holdings Ireland Limited or its affiliates. Marks designated ® and ™ are owned by Shire or an affiliated company. S41341 07/18





## BRIEF SUMMARY:

Consult the Full Prescribing Information for complete product information.

## INDICATIONS AND USAGE

Xiidra® (lifitegrast ophthalmic solution) 5% is indicated for the treatment of the signs and symptoms of dry eye disease (DED).

## DOSAGE AND ADMINISTRATION

Instill one drop of Xiidra twice daily (approximately 12 hours apart) into each eye using a single-use container. Discard the single-use container immediately after using in each eye. Contact lenses should be removed prior to the administration of Xiidra and may be reinserted 15 minutes following administration.

## CONTRAINDICATIONS

Xiidra is contraindicated in patients with known hypersensitivity to lifitegrast or to any of the other ingredients in the formulation.

## ADVERSE REACTIONS

### Clinical Trials Experience

Because clinical studies are conducted under widely varying conditions, adverse reaction rates observed in clinical studies of a drug cannot be directly compared to rates in the clinical trials of another drug and may not reflect the rates observed in practice. In five clinical studies of dry eye disease conducted with lifitegrast ophthalmic solution, 1401 patients received at least 1 dose of lifitegrast (1287 of which received lifitegrast 5%). The majority of patients (84%) had  $\leq 3$  months of treatment exposure. 170 patients were exposed to lifitegrast for approximately 12 months. The majority of the treated patients were female (77%). The most common adverse reactions reported in 5-25 % of patients were instillation site irritation, dysgeusia and reduced visual acuity. Other adverse reactions reported in 1% to 5% of the patients were blurred vision, conjunctival hyperemia, eye irritation, headache, increased lacrimation, eye discharge, eye discomfort, eye pruritus and sinusitis.

### Postmarketing Experience

The following adverse reactions have been identified during postapproval use of Xiidra. Because these reactions are reported voluntarily from a population of uncertain size, it is not always possible to reliably estimate their frequency or establish a causal relationship to drug exposure.

Rare cases of hypersensitivity, including anaphylactic reaction, bronchospasm, respiratory distress, pharyngeal edema, swollen tongue, and urticaria have been reported. Eye swelling and rash have been reported.

## USE IN SPECIFIC POPULATIONS

### Pregnancy

There are no available data on Xiidra use in pregnant women to inform any drug associated risks. Intravenous (IV) administration of lifitegrast to pregnant rats, from pre-mating through gestation day 17, did not produce teratogenicity at clinically relevant systemic exposures. Intravenous administration of lifitegrast to pregnant rabbits during organogenesis produced an increased incidence of omphalocele at the lowest dose

tested, 3 mg/kg/day (400-fold the human plasma exposure at the recommended human ophthalmic dose [RHOD], based on the area under the curve [AUC] level). Since human systemic exposure to lifitegrast following ocular administration of Xiidra at the RHOD is low, the applicability of animal findings to the risk of Xiidra use in humans during pregnancy is unclear.

### Animal Data

Lifitegrast administered daily by intravenous (IV) injection to rats, from pre-mating through gestation day 17, caused an increase in mean preimplantation loss and an increased incidence of several minor skeletal anomalies at 30 mg /kg /day, representing 5,400-fold the human plasma exposure at the RHOD of Xiidra, based on AUC. No teratogenicity was observed in the rat at 10 mg /kg /day (460-fold the human plasma exposure at the RHOD, based on AUC ). In the rabbit, an increased incidence of omphalocele was observed at the lowest dose tested, 3 mg /kg /day (400-fold the human plasma exposure at the RHOD, based on AUC), when administered by IV injection daily from gestation days 7 through 19. A fetal No Observed Adverse Effect Level (NOAEL) was not identified in the rabbit.

### Lactation

There are no data on the presence of lifitegrast in human milk, the effects on the breastfed infant, or the effects on milk production. However, systemic exposure to lifitegrast from ocular administration is low. The developmental and health benefits of breastfeeding should be considered, along with the mother's clinical need for Xiidra and any potential adverse effects on the breastfed child from Xiidra.

### Pediatric Use

Safety and efficacy in pediatric patients below the age of 17 years have not been established.

### Geriatric Use

No overall differences in safety or effectiveness have been observed between elderly and younger adult patients.

## NONCLINICAL TOXICOLOGY

### Carcinogenesis, Mutagenesis, Impairment of Fertility

**Carcinogenesis:** Animal studies have not been conducted to determine the carcinogenic potential of lifitegrast.

**Mutagenesis:** Lifitegrast was not mutagenic in the *in vitro* Ames assay. Lifitegrast was not clastogenic in the *in vivo* mouse micronucleus assay. In an *in vitro* chromosomal aberration assay using mammalian cells (Chinese hamster ovary cells), lifitegrast was positive at the highest concentration tested, without metabolic activation.

**Impairment of fertility:** Lifitegrast administered at intravenous (IV) doses of up to 30 mg/kg/day (5400-fold the human plasma exposure at the recommended human ophthalmic dose (RHOD) of lifitegrast ophthalmic solution, 5%) had no effect on fertility and reproductive performance in male and female treated rats.



Manufactured for: Shire US Inc., 300 Shire Way, Lexington, MA 02421. For more information, go to [www.Xiidra.com](http://www.Xiidra.com) or call 1-800-828-2088. Marks designated ® and ™ are owned by Shire or an affiliated company. ©2018 Shire US Inc. SHIRE and the Shire Logo are trademarks or registered trademarks of Shire Pharmaceutical Holdings Ireland Limited or its affiliates. Patented: please see <https://www.shire.com/legal-notice/product-patents> Last Modified: 01/2018 533769





Give the  
Gift of Sight  
for the  
Holidays!

Your support can make the difference between a life of opportunity or one of poverty.

**JOIN WITH OUR MAJOR PARTNERS**

CooperVision, Vision Source, VSP Global, Bausch & Lomb, PECAA, Essilor of America, ABB Optical Group, iCare Health Solutions, Carl Zeiss Vision, EyePromise, Healthy Vision Association, GPLI, Alcon Foundation, De Rigo REM, VisionWeb, Texas State Optical, Jobson Optical Group, PentaVision, First Media Vision Group, Invision.



OPTOMETRY  
**GIVINGSIGHT**

1019 8th St., #304, Golden, CO 80401  
**303 526-0430**

Donate now TO OPTOMETRY GIVING SIGHT AT [givingsight.org](http://givingsight.org)



PRINTED IN USA

FOUNDING EDITOR, FREDERICK BOGER  
1891-1913

EDITORIAL OFFICES  
11 CAMPUS BLVD., SUITE 100  
NEWTOWN SQUARE, PA 19073

SUBSCRIPTION INQUIRIES  
1-877-529-1746

CONTINUING EDUCATION INQUIRIES  
1-800-825-4696

EDITOR-IN-CHIEF • JACK PERSICO  
(610) 492-1006 • JPERSICO@JOBSON.COM

MANAGING EDITOR • REBECCA HEPP  
(610) 492-1005 • RHEPP@JOBSON.COM

SENIOR EDITOR • BILL KEKEVIAN  
(610) 492-1003 • BKEKEVIAN@JOBSON.COM

ASSOCIATE EDITOR • CATHERINE MANTHORP  
(610) 492-1043 • CMANTHORP@JOBSON.COM

ASSOCIATE EDITOR • MARK DE LEON  
(610) 492-1021 • MDELEON@JOBSON.COM

SPECIAL PROJECTS MANAGER • JILL HOFFMAN  
(610) 492-1037 • JHOFFMAN@JOBSON.COM

ART DIRECTOR • JARED ARAUJO  
(610) 492-1032 • JARAUJO@JOBSON.COM

DIRECTOR OF CE ADMINISTRATION • REGINA COMBS  
(212) 274-7160 • RCOMBS@JOBSON.COM

#### EDITORIAL BOARD

CHIEF CLINICAL EDITOR • PAUL M. KARPECKI, OD

ASSOCIATE CLINICAL EDITORS • JOSEPH P. SHOVLIN, OD;  
ALAN G. KABAT, OD; CHRISTINE W. SINDT, OD

DIRECTOR OPTOMETRIC PROGRAMS • ARTHUR EPSTEIN, OD

CLINICAL & EDUCATION CONFERENCE ADVISOR  
PAUL M. KARPECKI, OD

CASE REPORTS COORDINATOR • ANDREW S. GURWOOD, OD

CLINICAL CODING EDITOR • JOHN RUMPAKIS, OD, MBA

CONSULTING EDITOR • FRANK FONTANA, OD

#### COLUMNISTS

CHAIRSIDE • MONTGOMERY VICKERS, OD

CLINICAL QUANDARIES • PAUL C. AJAMIAN, OD

CODING CONNECTION • JOHN RUMPAKIS, OD

CORNEA & CONTACT LENS Q+A • JOSEPH P. SHOVLIN, OD

DIAGNOSTIC QUIZ • ANDREW S. GURWOOD, OD

THE ESSENTIALS • BISANT A. LABIB, OD

FOCUS ON REFRACTION • MARC TAUB, OD;

PAUL HARRIS, OD

GLAUCOMA GRAND ROUNDS • JAMES L. FANELLI, OD

NEURO CLINIC • MICHAEL TROTTINI, OD;

MICHAEL DELGIODICE, OD

OCULAR SURFACE REVIEW • PAUL M. KARPECKI, OD

RETINA DILEMMAS • DIANA L. SHECHTMAN, OD;

JAY M. HAYNE, OD

RETINA QUIZ • MARK T. DUNBAR, OD

REVIEW OF SYSTEMS • CARLO J. PELINO, OD;

JOSEPH J. PIZZIMENTI, OD

SURGICAL MINUTE • DEREK N. CUNNINGHAM, OD;

WALTER O. WHITLEY, OD, MBA

THERAPEUTIC REVIEW • JOSEPH W. SOWKA, OD

THROUGH MY EYES • PAUL M. KARPECKI, OD

URGENT CARE • RICHARD B. MANGAN, OD

JOBSON MEDICAL INFORMATION LLC



## Outlook

By Jack Persico, Editor-in-Chief



# A Tale of Two Academies

Dueling conferences present optometry as both savior and pariah. Neither paints a complete picture.

Last month I had the good fortune of attending both Annual Academy meetings in eye care, the Academy of Ophthalmology in San Francisco and then, a week later, the Academy of Optometry in Orlando. It's perhaps fitting that the conferences happened in opposite corners of America because the views of optometry presented at each were just as far apart.

Up in San Francisco, optometrists were portrayed as greedy opportunists reaching beyond their skill set to recklessly expand their scope of practice, endangering the populace as a result. Most of the major sessions ended with the speaker imploring the attendees to donate to the Academy of Ophthalmology's political action committee for the express purpose of fighting the progress of optometry legislatively.

This wasn't just an occasional cheap shot here and there: it was built into the meeting's program to close the talks with an anti-optometry diatribe and a passing of the collection plate.

Down in Orlando the following week, representatives of the World Health Organization headlined the plenary session to highlight the vital role optometry must play in combating eye health deficiencies around the globe and to fire up the troops. The WHO had just released a comprehensive report detailing shortcomings in the delivery of eye care and the ensuing misery of the one billion or so people who hang in the balance.

In Orlando at least, optometry's rise was presented as not just welcome but necessary—in fact, long overdue.

Concerning optometry's place in the world, the message from these back-to-back meetings was clear: It was the best of times, it was the worst of times.

Neither, of course, is true.

Optometry isn't the boogeyman I heard about in San Francisco. Data on clinical outcomes in states with scope expansion laws consistently show optometric care is safe, reliable and cost effective. The ODs who take on newer procedures like lasers and injections do so with a humility and respect for the gravity of their responsibilities.

And perhaps optometry's not quite the savior touted in Orlando either. Optometric capabilities vary plenty throughout the US—and wildly in Europe. Public confusion over such a hodge-podge profession is understandable. Not all optometrists have taken on some of the clinical responsibilities open to them in disease diagnosis and management. International differences are so vast that it's hardly even fair to call it the same profession overseas.

That the medical lobby seizes on this heterogeneity and seeks to turn it to its own advantage comes off as petty, not pious. What's needed is cooperation and education—not demonization. Many individual ODs and MDs work great together, for mutual benefit and without acrimony. Would that it were so simple for the rest to follow their examples. ■

# Technology in balance



Health



Vision




Comfort

---

Miru 1 month: a unique family of silicone hydrogel monthly lenses.

---

MeniSilk™ and Nanogloss™ technologies designed to meet the demands of today's contact lens wearer.\*



## Material and surface technologies

### MeniSilk™

- Ultra high Dk/t - 161 @ -3.00D
- Exceptional hydration
- Optimized transparency

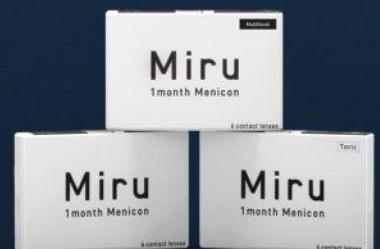### Nanogloss™

- Super smooth surface
- Resistance to bacteria
- Excellent wettability



[www.meniconamerica.com](http://www.meniconamerica.com)

\*Menicon data on file April 2016







# Eyelids: Assess and Express

Optometrists should embrace MGD therapies and lid lesion exams to care for a vast number of patients. **By Paul M. Karpecki, OD, Chief Clinical Editor**

We always thought of dry eye disease (DED) as a condition of the cornea and conjunctiva; today we know that, for about 86% of cases, DED begins with the eyelids.<sup>1</sup> Meibomian gland dysfunction (MGD) affects 96% of glaucoma patients on prostaglandin analogs, almost 60% of contact lens wearers and 85% of people who use digital devices.<sup>2-4</sup> Despite these numbers, not nearly enough optometrists are treating this precursor to DED at an early stage.<sup>5</sup>

This must start with diagnosis. Clinicians only need to take two steps to prepare themselves: buy a meibomian gland expressor and learn to spot early biofilm and blepharitis. This will add about 20 seconds to your exam, but it will generate a multitude of patients for the practice who need ongoing care.

## Cosmetics and DED

Numerous agents have been banned from human use because they cause cancer. One such example is formaldehyde, although more than 20% of current makeup products contain formaldehyde or formaldehyde-releasing chemicals. Additionally, this is just one of many harmful ingredients people apply to their eyelids, lashes and adnexa almost daily. Lash extensions and other additives to the eyelids and lashes create the perfect environment for *Demodex* and bacteria to colonize. Patients frequently ask about the risks of makeup and ocular surface diseases, and we must provide the proper education.

## In-office Procedures

It's time to consider adding in-office, patient-pay options, given the success patients are experiencing with these technologies. Blepharitis caused by bacteria or *Demodex* requires an in-office procedure, as does almost all cases of evaporative DED where biofilm components exist. An in-office blepharoexfoliation will significantly help these patients.

Other beneficial procedures for ocular surface disease include intense pulsed light (IPL) therapy and thermal expression and pulsation, the latter of which now has four different equipment options. The first and perhaps longest lasting option is a LipiFlow (Johnson & Johnson Vision). Research shows the effects of one treatment typically lasts three years.<sup>6</sup> While beneficial for all patients with MGD, it's a must for those with more than 70% gland loss to keep what few glands they have left. New in-office MGD therapies that combine heat and gland expression include the iLux (Alcon), TearCare (Sight Sciences) and the Thermal 1-Touch (OcuSoft).

Finally, IPL is an excellent therapy for patients with evaporative DED, ocular rosacea or MGD with telangiectatic vessels along the lower eyelid, which bring inflammatory mediators to the eye and lid margin. A series of IPL treatments can treat these blood vessels and help improve MGD and evaporative DED symptoms. The newest IPL devices no longer require coupling gel and are vastly more comfortable during treatment.

## Lumps and Bumps

Clinicians should always be on the lookout for eyelid lesions, considering the most likely locations of basal cell carcinomas—the most common cancerous lesions—match the pattern of eyeglasses. These include the eyelids where the lenses would be, the nose pad area and behind the ears where the temples are. This is an easy way to remember the most frequent locations for the presentation. Other less common lesions, such as squamous cell carcinoma, malignant melanoma and sebaceous gland carcinoma, are also in our wheelhouse and should be suspected when lesions change or conditions such as blepharitis worsen even after treatment.

Optometry's role in caring for ocular surface disease and lid lesions is critical from diagnosis to treatment. In fact, it's an area of medical eyecare we should own. These conditions, moreso than any others, provide an enormous opportunity for us to help more people. Incorporating better care can't hurt our practices either. ■

*Note: Dr. Karpecki consults for companies with products and services relevant to this topic.*

1. Lemp MA, Crews LA, Bron AJ, et al. Distribution of aqueous-deficient and evaporative dry eye in a clinic-based patient cohort: a retrospective study. *Cornea*. 2012;31(5):472-8.
2. Mogan MC, Uzunosmanoglu E, Kocabeyoglu S, et al. The association of chronic topical prostaglandin analog use with meibomian gland dysfunction. *J Glaucoma*. 2016;25(9):770-4.
3. Machalinska A, Zakrzewska A, Adamek B, et al. Comparison of morphological and functional meibomian gland characteristics between daily contact lens wearers and nonwearers. *Cornea*. 2015;34(9):1098-104.
4. Wu H. The severity of the dry eye conditions in visual display terminal workers. *PLoS One*. 2014;9(8):e105575.
5. Steinberg D, et al. *Equity Research Americans*. 2017:1-38
6. Greiner JV. Long-term (3 year) effects of a single thermal pulsation system treatment on meibomian gland function and dry eye symptoms. *Eye Contact Lens*. 2016;42(2):99-107.

# www.katena.com DID YOU MISS THESE FLASH SALES?

## DON'T MISS ANOTHER!

**Gonio Prism**  
~~\$79.99~~  
09/19/2019

**MIGS Surgical Gonio Prism**  
(Single-Use)  
**One Day Sale**

**One Day Sale**  
Promo Code  
**"ANGLE"**

**Sale Price**  
**\$79.99**  
list price \$195.00  
(per box of 10 lenses)

These lenses provide exceptionally clear direct viewing (no mirror) of the angle during glaucoma surgery.

Each single use lens comes in a sterile pouch and is supplied in a box of 10.

K30-1400 for left hand dominant surgeons  
K30-1405 for right hand dominant surgeons



**katena**

**Amniotic Membrane**  
~~\$299.00~~  
09/03/2019

AMBIODisk AMBIO2 AMBIO3

**AMNIOTIC MEMBRANE 1 DAY ONLY**  
**ONLY ON KATENA.COM**

USE PROMO CODE  
**"AMBIO"**

The next generation amniotic membrane technologies is available now. Shipped with a convenient tool handle for easy precise manipulation and sterile presentation.

**Amniotic membrane for surgical and in-office applications**

**\$299.00** per pair  
per pair  
per quantity

Discount only available off of list price.

Offer valid 09/03/2019 only and orders placed on www.katena.com. Must have USA shipping address. Don't have an account? Create one today! www.katena.com/customer/create/

**katena**

**Gold Eyelid Weights**  
**20% off**  
08/28/2019

**20% OFF**  
**ALL GOLD EYELID WEIGHTS**  
**ONLY ON KATENA.COM**

**One Day Sale**  
Promo Code  
**"GOLD"**

**LABTICIAN LID LOAD WEIGHTS**

Part #	Size	List Price
SLP06	0.6 gram	\$250
SLP08	0.8 gram	\$250
SLP10	1.0 gram	\$250
SLP12	1.2 gram	\$275
SLP14	1.4 gram	\$250
SLP16	1.6 gram	\$250
SLP18	1.8 gram	\$250
SLP20	2.0 gram	\$250

Offer available only on orders placed on www.katena.com. Discount only available off of list price. Must have USA shipping address. Don't have an account? Create one today! www.katena.com/customer/create/

**katena**



Create an account and receive news and promotional offers

**katena**  
DESIGNED FOR SIGHT®

800.225.1195 • info@katena.com • www.katena.com

KW-Adv-013119-Rev0

# Optometry, Shakespearean Style

The bard's words still apply to our daily nuisances, don't you think?

By Montgomery Vickers, OD

Not many people know this fun fact: William Shakespeare was the first optometric author. If you went to Pennsylvania College of Optometry in the 1970s, then you already knew this. If you went somewhere else, I've heard other teachers say it was some guy named Hemingway or something. It's time I set the record straight.

Shakespeare's original writings were peppered with optometric references. I have to admit, though, that he had to change some words in his final drafts to keep his editors and Queen Elizabeth I off his back. (That's the same Queen Elizabeth who is still in charge, right?) Here's what he really wanted to say:

- What's in a name? An infection by any other name would smell as sweet.
- Good night, good night! Teaching contact lens insertion is such sweet sorrow.
- To thine own self be true, unless you feel like you have to accept a crappy vision plan.
- All that glitters is not asteroid hyalosis.
- What a piece of work is man, that he loses half his vision on Friday and calls you at home the next Wednesday night.
- Brevity is the soul of pretesting.
- The lady doth no-show too much, methinks.
- Now is the winter of our tri-

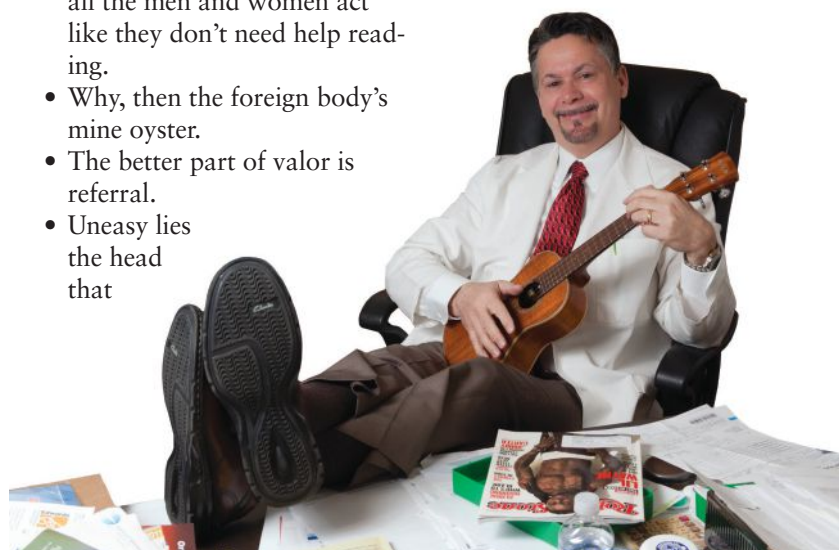geminal dysphoria.

- Alexa, if music be the food of love, play "Doctor, My Eyes" by Jackson Browne.
- What is hyperemic is prologue.
- Neither a borrower nor a pterygium be.
- For my part, that eyelid bump was Greek to me.
- God hath given you one face, and decent glasses can give you another, thank goodness.
- Ambition should be made of better recalls.
- To see or not to see, that is the question.
- Though this be madness, I still plan to visit my legislator.
- And it must follow, as the night the day, thou canst not diagnose when there are false positives for any man.
- All the world is a stage, and all the men and women act like they don't need help reading.
- Why, then the foreign body's mine oyster.
- The better part of valor is referral.
- Uneasy lies the head that

wears the indirect.

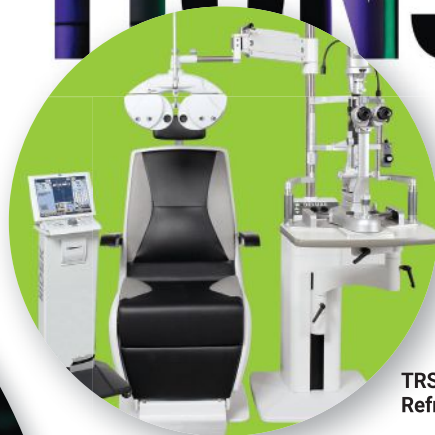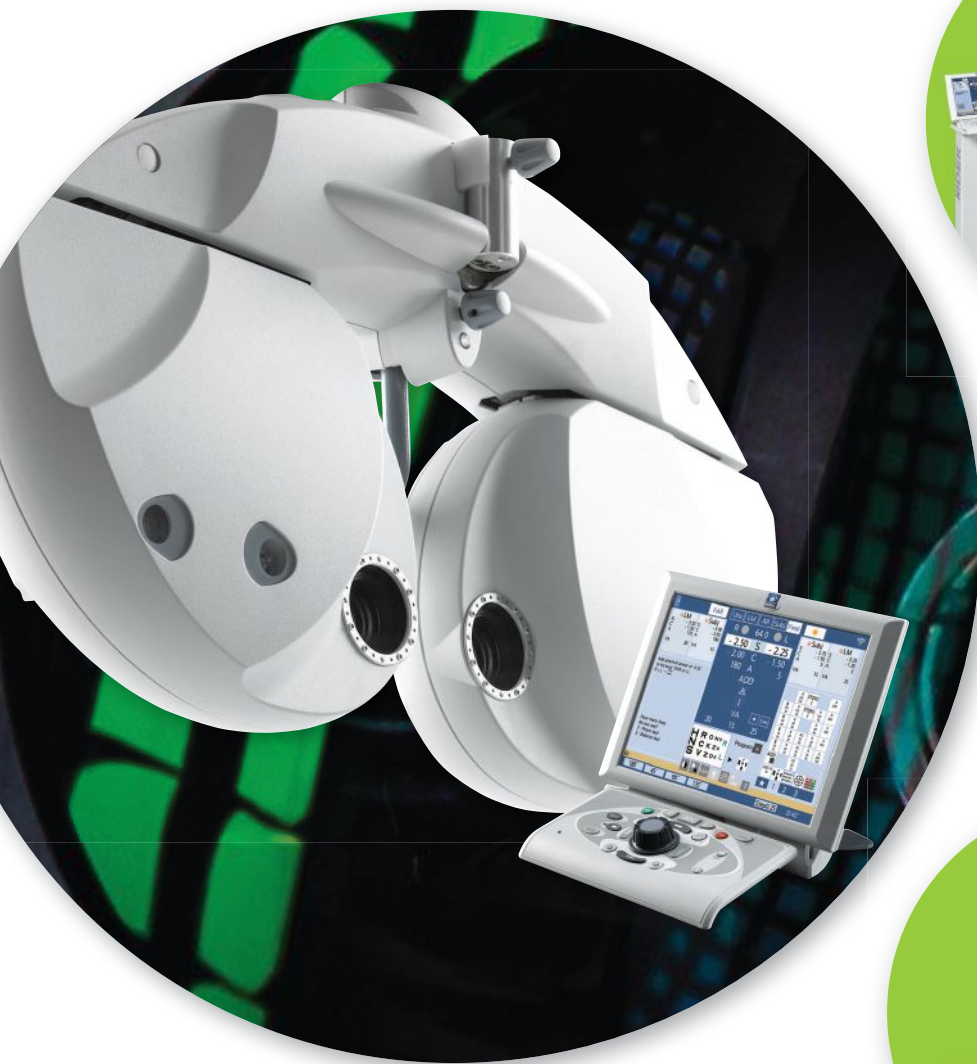
- Friends, Romans, countrymen, do these frames hurt your ears?
- Beware the ideas of sales reps.
- Double, double, toil and trouble. I'll be home late for dinner.
- A CE course, a CE course, my kingdom for a course!
- The course of true private practice never did run smooth.
- The first thing we do, let's kill all the lawyers. (Okay, good ol' Willie didn't have to change that one.)

Shakespeare knew us so well. Maybe he knew us better than we know ourselves. My advice? Speak like Shakespeare wrote, to every patient. You won't keep many, but those who remaineth shall remaineth forever and a day. ■

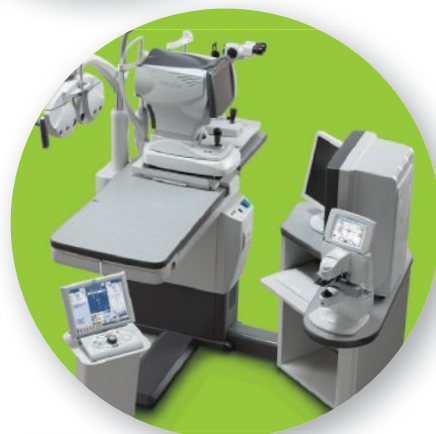



# 1 NEW STANDARD 3 EXAM OPTIONS



TRS-6100 Total  
Refraction System



EPIC-6100  
Refraction Workstation



TS-610 Tabletop  
Refraction System

## Do it Right. Contact Marco First

The BRAND NEW TRS-6100 is the newest technology in a line of refraction systems that enhances practice workflow and increases efficiency while maximizing patient comfort. The streamlined design and user-friendly controls allow precise and rapid examinations, even while performing a fully comprehensive subjective refraction. Enhanced data functions allow seamless digital communication for various network structures, and Wavefront maps can be incorporated into the refractive process to enhance diagnostics and patient education. **This NEW TRS-6100 Refraction Standard is available in three formats to fit your specific practice needs.**

It's what we do. [marco.com](http://marco.com) 800.874.5274





# The Undercover Cataract

Keep it simple, and take the entire exam into consideration when evaluating nuclear sclerosis. **Edited by Paul C. Ajamian, OD**

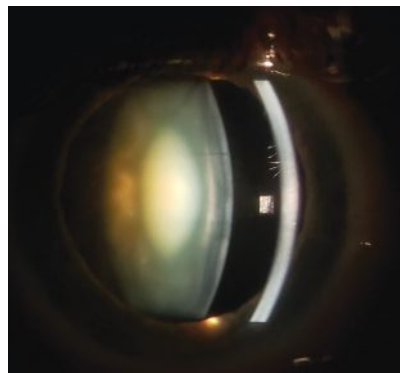
**Q** I have a 47-year-old patient who has noticed a rapid decline in vision in his right eye since beginning chemotherapy with Sprycel (dasatinib, Bristol-Myers Squibb) for leukemia. Best-corrected acuity is 20/50 OD with some nuclear sclerosis, but my view of the fundus is crystal clear. What else could it be?

**A** Even when you have found nuclear sclerosis to be the cause of the patient's vision loss, don't underestimate it. "Milky nuclear sclerosis has a way of hiding in plain sight," says Heather Purman, OD, of Omni Eye Services of Atlanta. Without any yellowing or brunescence, the cataract has the appearance of a white lens within a lens and is often unilateral. "Most of us were taught that our view into the eye is associated with the patients view out when it comes to cataracts, but not with milky nuclear sclerosis," Dr. Purman says.

## Avoid Over-referrals

Other findings to look for with milky nuclear sclerosis are myopic shift, bowing of the light beam on fundus exam and a dark reflex centrally on retinoscopy. In a similar case, a 44-year-old patient presented with decreased vision in his right eye that happened rapidly, with a medical history of trauma to the right side of his head. Initially Dr. Purman thought it could be a traumatic cataract, but upon further examination, the patient had a six diopter myopic shift OD and best-corrected acuity of 20/100 OD and 20/20 OS.

On slit lamp exam, the patient



**A sudden, large unilateral myopic shift could suggest milky nuclear sclerosis.**

had 4+ milky nuclear sclerosis OD and a clear lens OS. The fundus exam was unremarkable, and the patient was referred for removal of the cataract. At the one day post-op visit, the patient was 20/25 and very happy. "Thanks to a thorough exam, this patient was able to have surgery right away without being sent on a wild goose chase for unexplained vision loss," Dr. Purman says.

"When patients come in with a remarkable health history, it is easy to be led down the wrong path and overlook the simplest causes, thinking something more complicated is the culprit," Dr. Purman says. "This has often led to multiple unnecessary referrals to retina specialists, neuro-ophthalmologists and costly hospital visits for MRIs, all before seeing a cataract surgeon for the treatment they need."

While it is necessary to find the cause of unexplained vision loss, it's equally as important to take the entire exam into consideration before forming a diagnosis. Carefully

examining the cornea, lens, macula and nerve when decreased vision occurs can help catch these changes before referring to another doctor.

Retina is a common first referral for these patients—to look for an occult macular change that is not seen on a dilated fundus exam. These patients will be given a clean bill of retinal health but may continue down the referral chain. When we don't look for milky nuclear sclerosis, it will continue to hide right in front of us. "Any time a patient comes in with a large unilateral myopic shift that comes on suddenly, milky nuclear sclerosis is on my differential list," says Dr. Purman.

## An Integral Resource

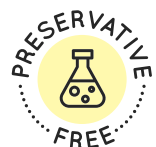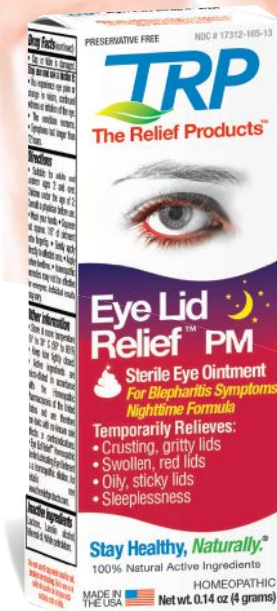The most common treatment for milky nuclear sclerosis patients is cataract surgery. Because this patient population tends to be younger, most still have accommodation left and would benefit from a discussion on monovision, toric lenses, multifocals, or a trifocal intraocular lens.

Educating your patients about these lens options beforehand is a great way to not only ensure a happy patient post-op but also positions you as the key information source for all things eye-related.

"In most cases, we have spent years with the patient and know their lifestyle goals, personality type and vision needs," Dr. Purman says. "We should be an integral part of the decision process and refer to surgeons who will respect our wishes and whose skills will provide the best outcomes." ■



**NEW!**  
 Eye Lid Relief® PM  
 for Lid Scrub  
 Patients!



2014 - 2019  
 WOMEN'S CHOICE AWARD™



**NEW Eye Lid Relief® offers soothing nighttime relief for Blepharitis symptoms.**

The Relief Products™ introduces Eye Lid Relief® PM, a preservative-free, homeopathic ointment for the treatment of Blepharitis symptoms and other eye lid conditions. Eye Lid Relief® PM combines a unique blend of medicinal and inactive ingredients to gently alleviate symptoms such as red, swollen lids, crusting, gritty lids, oily, sticky lids, and sleeplessness. Eye Lid Relief® works best when used as a companion product to an eyelid cleanser pad. Scrub, then heal, with Eye Lid Relief® PM Ointment. Available now at your local Walgreens.

**The Relief Products™** is a family-run business driven by its mission to help you **Stay Healthy, Naturally®**. All of our products use 100% natural active ingredients and offer no known side effects or interactions with other medications. Additionally, we have received 5 Women's Choice Awards for 2019, as well as the 2019 DSN Retail Excellence Award in the Natural Products category.

Recommend The Relief Products™ with confidence knowing our award-winning products are safe, effective, and affordable.

**TRP Stay Healthy, Naturally.®**  
 Get Relief for Your Patients at: [info@trpcompany.com](mailto:info@trpcompany.com) or Call: 888-969-6855

MADE IN THE USA



The Relief Products™ FDA Disclaimer: Claims based on traditional homeopathic practice, not accepted medical evidence. Not FDA evaluated.





# The Who and Why of MRI

Diffusion-weighted imaging can be crucial to confirm a number of ophthalmic disorders.

By Bisant A. Labib, OD

The use of radiologic studies in the ophthalmic setting is becoming increasingly more common, especially for neuro-ophthalmic disorders. Many eye care providers now routinely order various types of neuroimaging studies that provide valuable and detailed information on neural visual pathways not easily obtained through clinical examination alone.

The most commonly ordered diagnostic test is magnetic resonance imaging (MRI) because it allows imaging of the orbital apex and optic nerve despite the dense bone surrounding these areas.<sup>1</sup>

## Imaging Basics

The most common indications for neuroimaging are vision or visual field loss, pupil abnormalities, ptosis, proptosis, diplopia or ophthalmoplegia, nystagmus and certain optic disc abnormalities. MRI studies are based on the signal detection of the interaction between hydrogen molecules within a magnetic field.

When an MRI is ordered, both T1 and T2 studies are performed routinely for the imaging of the brain and orbits. Studies that are weighted towards T1 are best for the observation of normal anatomy, while T2 studies better distinguish pathology by enhancing the signaling differences and contrast in various tissues. In T1 images, fluids such as cerebrospinal fluid (CSF) and vitreous appear dark, or hypointense, whereas in T2-weighted images, fluids appear

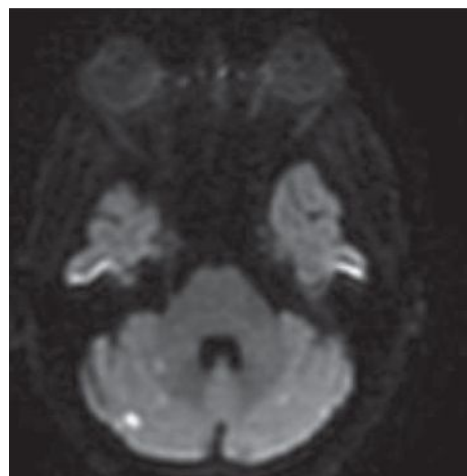
bright. For example, when viewing the CSF within the optic nerve sheath in suspected papilledema, a T2 image offers better contrast because it will appear hyperintense.

MRI studies also include the use of contrast material, gadolinium, as well as specialized sequences such as fluid attenuation inversion recovery (FLAIR), fat suppression MRIs, gradient echo, magnetic resonance angiography and magnetic resonance spectroscopy (MRS) (*Table 1*). The different uses and sequences of MRI alone are vast, but the focus of this article will be on diffusion-weighted imaging (DWI) studies and their application in ophthalmic practice.<sup>2</sup>

## DWI Drilldown

This sequence is obtained in most routine MRI brain examinations. DWI MRI works by detecting the free diffusion of water molecules. In a normal, healthy brain, there is free diffusion of water molecules along a concentration gradient, from regions of higher concentration to regions of lower concentration. A number of disease processes may impair this free motion, resulting in areas of restricted diffusion that appear “bright” on DWI.<sup>3</sup>

Although the details and the physical properties of the technique are complex, there are generally two equal but opposite gradient pulses applied to the tissue in question: if




DWI of the brain reflecting areas of hyperintensity that correlate with lesions of acute infarct.

there is no free movement of water (i.e., restricted diffusion), the effects of the dephasing gradient and the equal but opposite rephrasing gradient cancel each other out, producing a hyperintense signal on DWI; if there is normal, free movement as in healthy tissue, the effects of the dephasing and rephrasing gradients do not cancel each other out and the tissue will produce an isointense signal on DWI.<sup>3,4</sup>

## Clinical Applications

Restricted diffusion occurs in cytotoxic damage from ischemia, inflammation, trauma or tumor. Most commonly, the DWI sequence is used in the diagnosis and assessment of acute ischemic stroke.<sup>5</sup> As vision and visual field loss can be the initial presenting sign of a cerebral infarct, clinicians should be familiar with

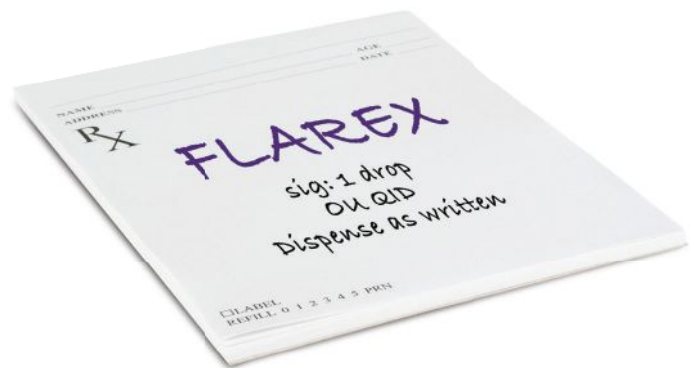

# PRECISION POTENCY

**FLAREX® provides the precise level of potency  
when treating ocular surface inflammation<sup>1,2</sup>**

By balancing efficacy and safety, you can tailor treatment to meet the exact needs of your patients<sup>1</sup>

- **Superior efficacy** vs FML® (fluorometholone ophthalmic suspension, USP) 0.1%\*<sup>2,a</sup>
- **Similar efficacy** to prednisolone acetate 1.0%<sup>2,a</sup>
- **No differences** in adverse reactions vs FML\* and prednisolone acetate 1.0%<sup>2,a</sup>
- The **lowest-cost branded** corticosteroid<sup>3,b</sup>
- **No generic equivalent**—prescribe **FLAREX** by name<sup>4</sup>



Learn more at [MyFlarex.com](https://www.MyFlarex.com)

## INDICATIONS AND USAGE

FLAREX® (fluorometholone acetate ophthalmic suspension) is indicated for use in the treatment of steroid-responsive inflammatory conditions of the palpebral and bulbar conjunctiva, cornea, and anterior segment of the eye.

## IMPORTANT SAFETY INFORMATION

### CONTRAINDICATIONS

Contraindicated in acute superficial herpes simplex keratitis, vaccinia, varicella, and most other viral diseases of the cornea and conjunctiva; mycobacterial infection of the eye; fungal diseases; acute purulent untreated infections, which like other diseases caused by microorganisms, may be masked or enhanced by the presence of the steroid; and in those persons who have known hypersensitivity to any component of this preparation.

**Please see brief summary of Full Prescribing Information on the adjacent page.**

<sup>1</sup>**STUDY DESIGN:** The efficacy and safety of FLAREX (n=41) vs FML\* (n=37) were evaluated in a randomized, double-blind clinical trial in 78 patients with ocular surface inflammation (eg, conjunctivitis, episcleritis, scleritis) in one or both eyes. In a separate randomized, double-blind clinical trial in 82 patients with ocular surface inflammation in one or both eyes, the efficacy and safety of FLAREX (n=37) vs prednisolone acetate 1.0% (n=45) were evaluated. In these studies, patients administered either FLAREX or FML\*/prednisolone acetate 1.0% every 2 hours for the first 2 days and then every 4 hours thereafter, with signs and symptoms of inflammation assessed at Days 1, 3, 8, and 13. At each visit, investigators determined if symptoms in the involved eye were resolved (cured), improved, unchanged, or worsened. If a patient was rated as cured before the end of the study, steroid drops were discontinued and the patient was considered to have completed the trial.<sup>2</sup>

<sup>b</sup>Cost information based on Wholesale Acquisition Cost (WAC), 2019 data.



© 2019 EyeVance Pharmaceuticals LLC. All rights reserved.  
FLAREX® is a registered trademark of Alcon Research, Ltd.  
\*All other trademarks are the property of their respective owners.  
FLA-09-19-AD-42

**Flarex®**  
(fluorometholone acetate  
ophthalmic suspension) 0.1%

## FLAREX® (fluorometholone acetate ophthalmic suspension) 0.1% Brief Summary

### INDICATIONS AND USAGE

FLAREX (fluorometholone acetate ophthalmic suspension) is indicated for use in the treatment of steroid-responsive inflammatory conditions of the palpebral and bulbar conjunctiva, cornea, and anterior segment of the eye.

### DOSAGE AND ADMINISTRATION

**Shake Well Before Using.** One to two drops instilled into the conjunctival sac(s) four times daily. During the initial 24 to 48 hours, the dosage may be safely increased to two drops every two hours. If no improvement after two weeks, consult physician. Care should be taken not to discontinue therapy prematurely.

### CONTRAINDICATIONS

Contraindicated in acute superficial herpes simplex keratitis, vaccinia, varicella, and most other viral diseases of the cornea and conjunctiva; mycobacterial infection of the eye; fungal diseases; acute purulent untreated infections, which like other diseases caused by microorganisms, may be masked or enhanced by the presence of the steroid; and in those persons who have known hypersensitivity to any component of this preparation.

### WARNINGS AND PRECAUTIONS

#### Topical Ophthalmic Use Only

For topical ophthalmic use only. Not for injection.

#### Intraocular Pressure Increase

Prolonged use may result in glaucoma, damage to the optic nerve, and defects in visual acuity and visual field. It is advisable that the intraocular pressure be checked frequently.

#### Cataracts

Use of corticosteroids may result in cataract formation.

#### Delayed Healing

Topical ophthalmic corticosteroids may slow corneal wound healing. In those diseases causing thinning of the cornea or sclera, perforation has been known to occur with chronic use of topical steroids.

#### Viral Infections

Use in the treatment of herpes simplex infection requires great caution.

#### Bacterial Infections

Use of corticosteroids may suppress the host response and thus aid in the establishment of secondary ocular infections. Acute purulent infections of the eye may be masked or exacerbated by the presence of steroid medication.

#### Fungal Infections

Fungal infections of the cornea are particularly prone to develop coincidentally with long-term local steroid application. Fungus invasion must be considered in any persistent corneal ulceration where a steroid has been used or is in use.

#### Contamination

Do not touch dropper tip to any surface, as this may contaminate the suspension.

#### Contact Lens Wear

Contact lenses should be removed during instillation of FLAREX but may be reinserted after 15 minutes.

#### Temporarily Blurred Vision

Vision may be temporarily blurred following dosing with FLAREX. Care should be exercised in operating machinery or driving a motor vehicle.

### ADVERSE REACTIONS

#### Clinical Trials Experience

Glaucoma with optic nerve damage, visual acuity and field defects, cataract formation, secondary ocular infection following suppression of host response, and perforation of the globe may occur.

### Postmarketing Experience

The following reaction has been identified during postmarketing use of FLAREX in clinical practice. Because reactions are reported voluntarily from a population of unknown size, estimates of frequency cannot be made. The reaction, which has been chosen for inclusion due to either its seriousness, frequency of reporting, possible causal connection to FLAREX, or a combination of these factors, includes dysgeusia.

### USE IN SPECIFIC POPULATIONS

#### Pregnancy

Fluorometholone has been shown to be embryocidal and teratogenic in rabbits when administered at low multiples of the human ocular dose. Fluorometholone was applied ocularly to rabbits daily on days 6-18 of gestation, and dose-related fetal loss and fetal abnormalities including cleft palate, deformed rib cage, anomalous limbs, and neural abnormalities, such as encephalocele, craniorachischisis, and spina bifida, were observed. There are no adequate and well-controlled studies of fluorometholone in pregnant women, and it is not known whether fluorometholone can cause fetal harm when administered to a pregnant woman. Fluorometholone should be used during pregnancy only if the potential benefit justifies the potential risk to the fetus.

#### Lactation

Systemically administered corticosteroids appear in human milk and could suppress growth, interfere with endogenous corticosteroid production, or cause other untoward effects. It is not known whether topical administration of corticosteroids could result in sufficient systemic absorption to produce detectable quantities in human milk. Because many drugs are excreted in human milk, caution should be exercised when FLAREX is administered to a nursing woman.

#### Pediatric Use

Safety and effectiveness in pediatric patients have not been established.

#### Geriatric Use

No overall differences in safety or effectiveness have been observed between elderly and younger patients.

### NONCLINICAL TOXICOLOGY

#### Carcinogenesis, Mutagenesis, Impairment of Fertility

No studies have been conducted in animals or in humans to evaluate the possibility of these effects with fluorometholone.

### PATIENT COUNSELING INFORMATION

#### Risk of Contamination

Do not touch dropper tip to any surface, as this may contaminate the suspension.

#### Use with Contact Lenses

The preservative in FLAREX, benzalkonium chloride, may be absorbed by soft contact lenses. Contact lenses should be removed during instillation of FLAREX but may be reinserted 15 minutes after instillation.

#### Temporarily Blurred Vision

Patients should be advised that their vision may be temporarily blurred following dosing with FLAREX. Care should be exercised in operating machinery or driving a motor vehicle.

#### Rx Only

**Distributed by:** Eyevance Pharmaceuticals LLC, Fort Worth, TX 76102

**References:** 1. FLAREX [package insert]. Fort Worth, TX: Alcon Laboratories, Inc; 2017. 2. Leibowitz HM, Hyndiuk RA, Lindsey C, et al. Fluorometholone acetate: clinical evaluation in the treatment of external ocular inflammation. *Ann Ophthalmol.* 1984;16(12):1110-1115. 3. Data on file. Fort Worth, TX: Eyevance Pharmaceuticals LLC. 4. US Department of Health and Human Services, Food and Drug Administration. *Approved drug products with therapeutic equivalence evaluations.* (Orange Book). 38th ed. Washington, DC: US Department of Health and Human Services, Food and Drug Administration; 2018.





this imaging modality and be able to order and understand its basic principles, as this is often required in emergent cases. The DWI can identify acute infarct as early as three to five minutes following the onset of clinical symptoms and remains positive for up to 14 days.<sup>5-7</sup> This makes it a crucial tool to determine if thrombolytic therapy should be administered, where timeliness is an essential factor in stroke treatment.<sup>5</sup>

Acute strokes appear as high signal, bright lesions on DWI. These areas correspond with a hypoperfused brain. As such, when this area regains perfusion, DWI abnormalities may reverse. This is referred to as *pseudonormalization* because the disappearance of the DWI signal does not imply a return of normal cellular function—that will remain abnormal on conventional MRI. Therefore, chronic infarcts will appear hypo or isointense on DWI.<sup>5</sup>

### Additional Ophthalmic Uses

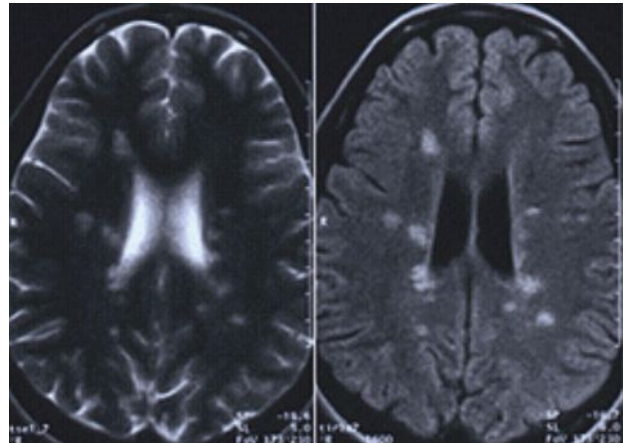
The utility of DWI in acute stroke diagnosis and management is well studied and understood. In addition to these cases, DWI can be useful in other areas of ocular disease. Specifically, DWI is helpful in distinguishing an arachnoid cyst from an epidermoid tumor. Normally, these lesions have similar features on T1 and T2 MRIs. However, arachnoid

cysts contain cerebrospinal fluid, whereas epidermoid tumors are solid masses. This results in a higher DWI signal on solid tumors, where water mobility is low or more restricted.<sup>2,5</sup>

Cerebral abscesses are also readily identified on DWI because there are often central areas of cellular necrosis, cysts or both. These areas restrict water movement and result in bright signals on DWI. Additionally, blood products that may be subtle on conventional MRI contribute to low signal intensity on DWI, aiding in its identification.<sup>5</sup>

Acute white matter changes in multiple sclerosis (MS) also appear on DWI. While they will also arise on conventional MRI and FLAIR, the DWI is particularly helpful in dating MS plaques, which is useful when evaluating responses to therapy.<sup>5</sup>

Finally, in cases of central retinal artery occlusion (CRAO), DWI studies reveal multiple areas of restricted diffusion in affected reti-



**This patient's MRI reveals classic white matter lesions perpendicular to the lateral ventricles, consistent with MS.**

nas, suggestive of infarct.<sup>8</sup> One study also found a correlation between the severity of papilledema and optic nerve hyperintensity on DWI in patients with idiopathic intracranial hypertension (IIH). These findings suggest a possible surrogate marker for the identification and severity of papilledema secondary to IIH.<sup>9</sup>

DWI is an essential tool in the evaluation of a patient presenting emergently with acute vision loss. Clinicians must understand the principles of this unique sequence to apply it in practice—and properly identify everything from stroke and tumors to MS and CRAO. ■

**Table 1. Brief Summary of Different MRI Sequences**

MRI Sequence	General Use
T1 "fat suppression"	Visualization of orbit
FLAIR	Demyelinating disease
Gradient echo	Hemorrhage in patients with underlying vascular malformations, intracerebral hemorrhage and traumatic brain injury
MRI with contrast (gadolinium)	Identification of areas where there is breakdown of the blood-brain barrier
MRS	Diagnosis and evaluation of treatment response of brain tumors
DWI	Hyperacute ischemic lesions, areas of cytotoxic edema

- Kakaria AK. Imaging in neuro-ophthalmology: An overview. *Oman J Ophthalmol.* 2009;2(2):57-61
- Lee AG, Brazis PW, Garrity JA, White M. Imaging for neuro-ophthalmic and orbital disease. *Am J Ophthalmol.* 2004;138(5):852-62.
- Schaefer PW, Grant PE, Gonzalez RG. Diffusion-weighted MR imaging of the brain. *Radiology.* 2000;217(2):331-45.
- Bammer R. Basic principles of diffusion-weighted imaging. *European J Radiol.* 2003;45(3):169-84.
- Mukherji SK, Chenevert TL, Castillo M. Diffusion-weighted magnetic resonance imaging. *J Neuro-Ophthalmol.* 2002;22(2):118-22.
- Allen LM, Hasso AN, Handwerker J, Farid H. Sequence-specific MR imaging findings that are useful in dating ischemic stroke. *Radiographics.* 2012;32(5):1285-97.
- Reith W, Hasegawa Y, Latour LL, et al. Multislice diffusion mapping for 3-D evolution of cerebral ischemia in a rat stroke. *Neurology.* 1995;45(1):172-7.
- Alsinaidi O, Shaikh AG. Diffusion-weighted magnetic resonance imaging in acute retinal pathology. *Neuro-Ophthalmology.* 2018;42(3):191-93.
- Salvay DM, Padhye LV, Huecker JB, et al. Correlation between papilledema grade and diffusion-weighted magnetic resonance imaging in idiopathic intracranial hypertension. *J Neuro-Ophthalmol.* 2014;34(4):331-5.



# Be a Neuroanatomy Detective

Ischemic stroke might be hidden behind common eye complaints.

By Michael Trottni, OD, Michael DelGiodice, OD, PhD, and Amanda Alhout, BS

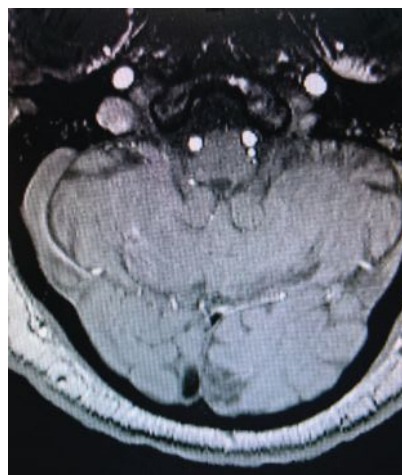
A 54-year-old Caucasian male was referred from his primary care physician for pain, redness and photophobia in the left eye for one month, which had been refractory to palliative therapy with artificial tears and warm compresses. Additional history questions revealed transient symptoms of vertigo, right arm weakness and left facial numbness, also for one month. He denied pain, hearing or weight loss, and his gait was unaffected. Past ocular, social and family histories were unremarkable.

## Evaluation and Diagnosis

Best-corrected visual acuity measured 20/20 OD and 20/50 OS. Confrontation field testing revealed a questionable right hemianopia. Subsequently, a formal HVF 30-2 revealed an incongruous right hemianopia. Extraocular muscle testing revealed a left abduction deficit that was neutralized with six prism diopters (base out).

Sensory testing of the face revealed hypoesthesia confined to the left cheek. Saccades were normal in magnitude and velocity in right gaze but equally diminished in left gaze. Examination of the left eye showed diffuse conjunctival hyperemia without discharge and grade 4 punctate epithelial erosions without infiltrates or dendrites. The lens showed mild nuclear sclerotic changes in each eye.

Reduced sensation of the left cheek is most indicative of maxillary division (V2) involvement of the trigeminal nerve—cranial nerve (CN



**Ischemic stroke within the left occipital cortex can lead to a right hemianopia.**

V. This prompted us to evaluate the ophthalmic division (V1) of CN V. Reduced facial and corneal sensation indicated CN V involvement, whereas reduced basal tear secretion identified motor involvement of the facial nerve (CN VII).

The symptoms and signs of right arm weakness, vertigo, right hemianopia, left abduction deficit, reduced sensory innervation of V1 and V2 and lacrimal gland dysfunction led us to a diagnosis of presumed polyneuropathy. Subsequently, an emergent referral was made to the emergency department for combined MRI/MRA with special attention to the brainstem. MRI was ordered to assess for soft tissue changes associated with stroke or tumor, while MRA allows for direct visualization of blood flow. A combined MRI/MRA is most useful when evaluating for potential vascu-

lar pathology (i.e., stroke, aneurysm or arteriovenous malformation).

Results of neuroimaging indicated (non-acute) brainstem infarction involving the left lower lateral pons including the sixth, seventh and eighth nerve nuclei, the posterior limb of the left internal capsule and the left occipital cortex. Additionally, there were moderate white matter lesions dispersed throughout both hemispheres due to chronic microvascular disease.

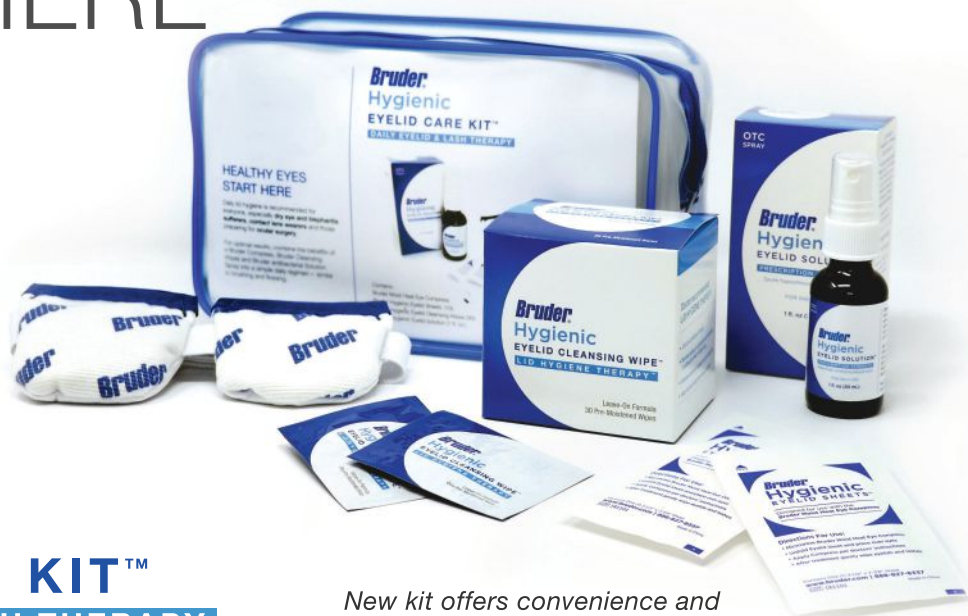Subsequently, the patient was scheduled for consultations in the cardiology and neurology departments. His medications for diabetes, hypertension and cholesterol were changed and he was placed on a blood thinner. He was eventually discharged and prescribed physical therapy. Additionally, we treated the keratopathy with a combination of Prokera (amniotic membrane, Bio-Tissue), punctal occlusion and Restasis (cyclosporine A 0.05%, Allergan) BID. Over the next several months, the left abduction deficit resolved, his right arm regained strength and there was a dramatic improvement in keratopathy with his best-corrected vision improving to 20/20 OS.

## Discussion

Ischemic infarction accounts for 80% to 90% of all strokes, with the remaining 10% to 20% due to hemorrhagic stroke.<sup>1,2</sup> Of the ischemic strokes, 25% involve the posterior circulation.<sup>1,2</sup> Of these, 60% and 40% occur in the brainstem and

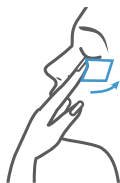# HEALTHY EYES START HERE

Introducing  
**Bruder**  
**Hygienic**  
**EYELID CARE KIT™**  
**DAILY EYELID & LASH THERAPY**

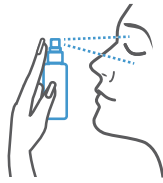

New kit offers convenience and improves patient compliance.

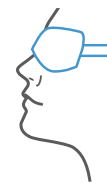WIPE



SPRAY



WARM



## PROMOTE AND PRESERVE EYELID HEALTH FOR ALL YOUR PATIENTS IN 3 EASY STEPS

Daily lid hygiene is recommended for everyone, *especially* **dry eye and blepharitis sufferers, contact lens wearers** and those **preparing for ocular surgery**. The good news is that a simple routine can solve or prevent problems, including dry eye, discomfort and contact lens drop out.

Three easy steps—*wipe, spray and warm*—are all that's needed to get patients on the right path.

The kit brings key lid hygiene components together in one convenient package: Patients receive the **#1 Doctor Recommended Bruder Moist Heat Eye Compress**, along with **Bruder Hygienic Eyelid Cleansing Wipes™** and **Bruder Hygienic Eyelid Solution™** (0.02% pure hypochlorous acid spray) and **Bruder Hygienic Eyelid Sheets™**.

Recommend a simple but comprehensive approach to ocular comfort and wellness with the Bruder Family of Hygiene products. It's easier now than ever before with the **Bruder Hygienic Eyelid Care Kit**.

VISIT [ORDER.BRUDER.COM](http://ORDER.BRUDER.COM) TO PURCHASE OR CALL 888-827-8337

**Bruder** | Better. By Design.

©2019 Bruder Healthcare Company. Alpharetta, GA 30004.

Learn more about Bruder products at  
[www.bruder.com](http://www.bruder.com)



cerebellum, respectively.<sup>1,2</sup> Brainstem infarctions are classified according to three main groups representing the site of infarction: mesencephalon, pons and medulla. Each of the three anatomic locations are further subdivided into anteromedial, anterolateral, lateral and posterior segments.<sup>3</sup>

In our patient, ischemic infarction occurred within the left lower lateral pons, left posterior limb of the internal capsule and the left occipital cortex.

Clinicians should conduct a short but efficient neuro exam in the office to assess for multiple cranial nerve involvement. Assess the sensory component of the ophthalmic division of CN V by gently touching a small bundle of cotton swabs to each cornea to compare sensation and evaluate the corneal reflex.

Similarly, use a pinprick to test sensation of both the maxillary and mandibular divisions. A physical evaluation of the motor functions of CN VII includes asking the patient to smile, close their eyes and wrinkle their forehead.

Test limb strength, gait and balance by simply applying force to the arms and legs while comparing their individualized resistance. Ask the patient to attempt to walk in a straight line and carefully instruct them to lift one leg off the ground while standing in position. Keep a low threshold when distinguishing normal from abnormal and practice performing these tests on unaffected patients.

The following describes the association between the neuroanatomy involved and the symptoms our patient presented with:<sup>4</sup>

1. left internal capsule (subcortex): weakness of the right arm and hand
2. left occipital cortex: right hemianopia

3. CN VI: left abduction deficit
4. V1, V2 and spinal trigeminal nucleus: loss of pain sensation from the cornea and face, respectively
5. facial nerve: reduced basal tear secretion
6. vestibular nuclei: vertigo

The internal capsule allows for communication between the cerebral cortex and the brain stem regarding motor and sensory activity from the arm, leg, trunk and face. The internal capsule consists of three parts: genu, anterior limb and posterior limb.

In our patient, ischemic infarction of the left posterior limb of the internal capsule resulted in contralateral hemiparesis and reduced sensation in the right arm and hand.<sup>4</sup>

### Confirming a Stroke

Signs and symptoms of internal capsular stroke may include a combination of the following: weakness of the face, arm or leg; upper motor neuron signs including hyperreflexia, Babinski sign, clonus and spasticity; and mixed sensorimotor, which involves motor fibers from the arm, trunk and legs and sensory fibers that leads to contralateral weakness and contralateral sensory loss.<sup>4</sup> Lastly, the occipital cortex houses the visual cortex—the visual processing center. In our patient, ischemic infarction within the left occipital cortex resulted in an incongruous right hemianopia.

Ocular complications included left abduction deficit, severe keratopathy and incongruous hemianopia. An abduction deficit could be managed with observation, vision therapy or prism. In this case we felt the keratopathy was severe enough to warrant immediate application of an amniotic membrane such as Prokera, a cryopreserved amniotic membrane that

contains nerve growth factor, which was found to accelerate healing and re-epithelialization of the ocular surface as well as stimulate corneal nerve regeneration.<sup>5</sup>

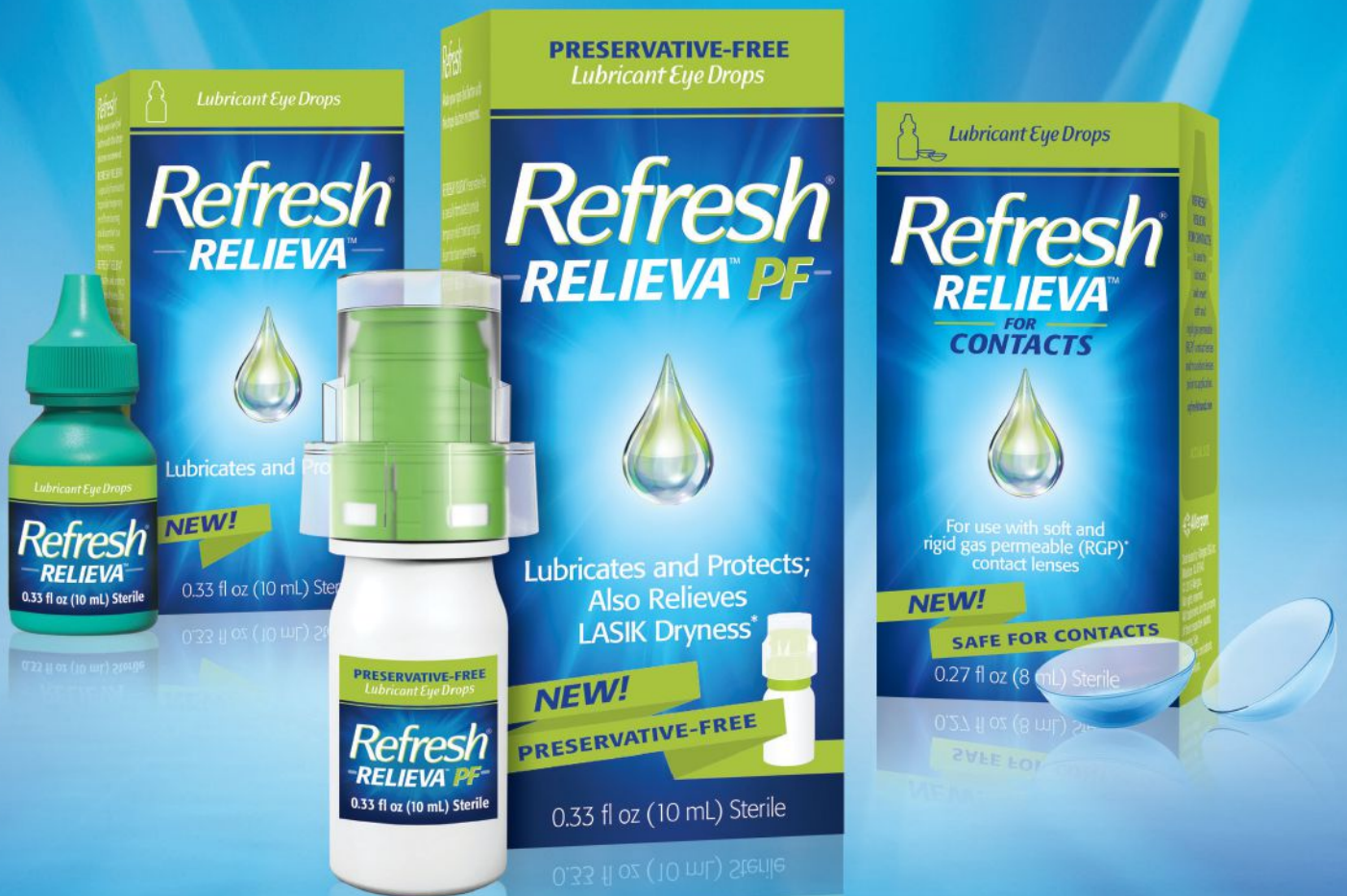In addition, we prescribed Restasis to reduce secondary inflammatory from neurotrophic disease. We performed punctal occlusion, after reducing inflammation, in order to increase the tear lake. Because the visual field defect was not causing a noticeable problem in our patient, we conservatively managed this with observation and periodic visual field testing. However, if the defect were robust enough to cause awareness of the field loss, we could have prescribed yoked prism with or without occupational therapy.

Interestingly enough, our patient's chief complaint was a red, painful eye, albeit he presented with more concerning clinical findings that led to the diagnosis of brain stem infarct. Because dry eye complaints are so frequent, it is prudent to consider alternative diagnoses if there is considerable inter-ocular asymmetry, as was observed in our patient.

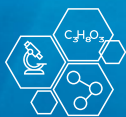
The combination of ocular and neurological signs and symptoms were clues to investigate for a neurologic process. A good understanding of anatomy and pathophysiology allowed us to better understand the mechanism underlying the presenting symptoms, which then led to additional CN testing and appropriate neuroimaging studies. ■

1. Bamford J, Sandercock P, Dennis M, et al. Classification and natural history of clinically identifiable subtypes of cerebral infarction. *Lancet*. 1991;337(8756):1521-6.
2. Bogousslavsky J, Regli F, Maeder P, et al. The etiology of posterior circulation infarcts: a prospective study using magnetic resonance imaging and magnetic resonance angiography. *Neurology*. 1993;43(8):1528-33.
3. Burger KM, Tuhir S, Naidich TP. Brainstem vascular stroke anatomy. *Neuroimag Clin N Am*. 2005;15(2):297-324.
4. Campbell WW. *DeJong's The Neurologic Examination*. 7th ed. Philadelphia, PA: Lippincott, Williams & Wilkins. 2012:338.
5. John T, Tighe S, Sheha H, et al. Corneal nerve regeneration after self-retained cryopreserved amniotic membrane in dry eye disease. *J Ophthalmol*. 2017; 6404918.

# THERE'S RELIEF AND THEN THERE'S RELIEVA™



THE ONLY FAMILY OF PRODUCTS IN THE U.S. WITH  
CMC, HA<sup>†</sup>, AND HYDROCELL™ TECHNOLOGY.



Welcome to REFRESH® RELIEVA™—the innovative family of products specially formulated to relieve discomfort due to eye dryness and prevent further irritation. We do it with HydroCell™ technology—our proprietary NaCl-free, glycerin-based solution that enables hydration and maintains the volume of cells on the ocular surface.

<sup>†</sup>HA is an inactive ingredient.

[refreshbrand.com/doc](http://refreshbrand.com/doc)



# Coding in More Ways Than One

When a patient has more than one condition concurrently, the medical record can get messy. Here's how to stay on track. **By John Rumpakis, OD, MBA, Clinical Coding Editor**

Optometrists are well-equipped to diagnose and manage almost any ocular condition that walks through the door, whether simple or complex. However, in the midst of working through the differential diagnosis, it can be easy to forget to handle all of the issues affecting the patient. Often, we make a primary diagnosis, construct a treatment plan and move on—not thinking twice about any possible concomitant conditions. It's not unusual to deal with a patient whose allergic response is elevated due to a compromised ocular surface and whose contact lens wearing time is reduced or quality of vision is affected—all on the same visit.

## Document Everything

A good example of this is the concurrent presentation of ocular allergies and ocular surface disease (OSD). The symptoms of each can mask one another, confounding the proper diagnosis, treatment and documentation. Moreover, many of these patients are also contact lens wearers, further complicating the already muddled coding picture.

If your patient presents with a primary complaint associated with either of these two conditions, it is critical to note these issues in the “reason for visit” or “chief complaint” section of the medical record. Once you have completed a thorough systemic and ocular case history, your anterior segment exam notes should reflect your current exam and lid eversion findings and

contact lens wear habits, as well as the patient's lens care products.

Order your diagnoses based on the patient's chief complaint and physical findings. Don't be afraid to map multiple diagnoses to the office visit for appropriate coverage.

The first component of scoring the medical management portion of your E/M visit is tabulating the number of diagnoses and number of treatment options. Here, don't short-change yourself by excluding anything, as these factors will also play a role in the remaining sections of the medical decision-making based on additional testing, consultation with other physicians, the acute or chronic aspect of the disease and what was prescribed, if anything.

After the assessment, your plan should clearly state the what, why and when of ongoing care. Be clear and descriptive for each of the conditions diagnosed. For example, use direct statements such as: “patient to RTC in one week for further diagnostic evaluation and follow-up for ocular surface disease and allergic conjunctivitis and potential change of contact lens modality.”

Done properly, this can then be transposed as the patient's reason for return visit: “patient returning per doctor-directed orders for further diagnostic evaluation and follow-up for ocular surface disease and allergic conjunctivitis and potential change of contact lens modality. Additional symptoms noted since last visit include...”

Greater specificity in the medi-

cal record leads to a more clinically appropriate case history, level of physical exam, medical decision making and, ultimately, a more accurate code for the encounter. It also helps you to establish medical necessity for point-of-care clinical lab tests such as osmolarity (CPT 83861) or inflammation (CPT 83516) at the first visit so they can be done prior to the physician seeing the patient on the follow-up. The same goes for any other necessary special ophthalmic procedures.

Keep in mind that the follow-up schedule may differ for each condition based on the individual. You may follow the dry eye every three to four months, but ocular allergy only every six. Just be sure to note the appropriate frequency of follow-up visits in the record.

Recording appropriate detail during the entire annual episode of care allows you to ultimately code your procedures and diagnoses properly and map out a clinically relevant and defensible care plan. Don't forget that concomitant conditions can—and often do—occur in different anatomical regions. You can follow a glaucoma patient who has dry eye and is a contact lens wearer in the very same fashion.

Your meticulous medical record is where you sort all of this out to ensure the patient is properly managed and you are billing and coding correctly. ■

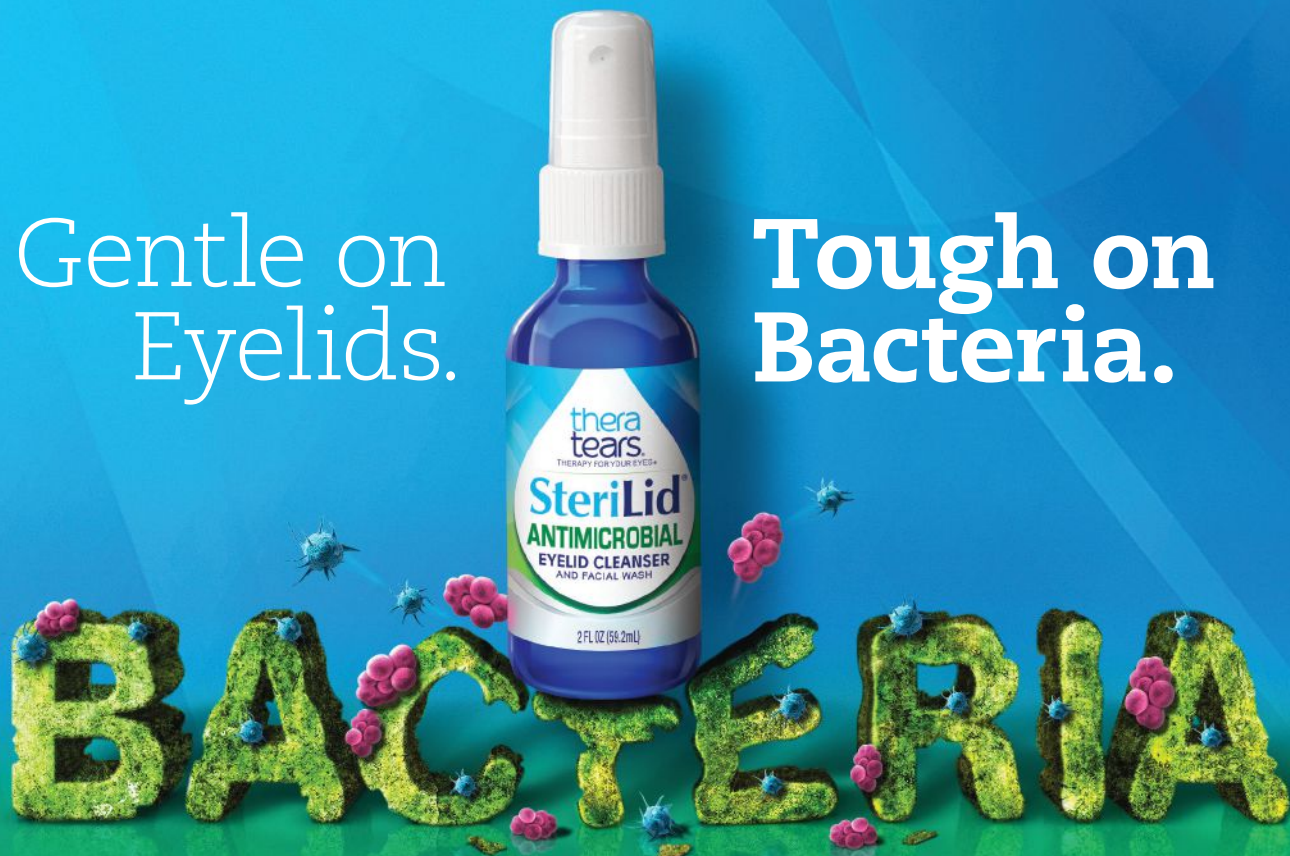Send your coding questions to [rocodingconnection@gmail.com](mailto:rocodingconnection@gmail.com).



new!

Gentle on  
Eyelids.

Tough on  
Bacteria.



RECOMMEND  
THE FIRST FDA-ACCEPTED  
**ANTIMICROBIAL**  
EYELID CLEANSER

- ✓ Advanced Hypochlorous Acid (0.01%) formula for superior cleansing
- ✓ Cleanses away bacteria and irritants
- ✓ pH balanced formula is gentle on eyelids
- ✓ Effective daily eyelid and eyelash hygiene
- ✓ No rinse - soap free



Now available without a prescription at Walgreens, CVS Pharmacy®, Amazon, Rite Aid, and other retailers nationwide

Visit [theratears.com](http://theratears.com) to learn more



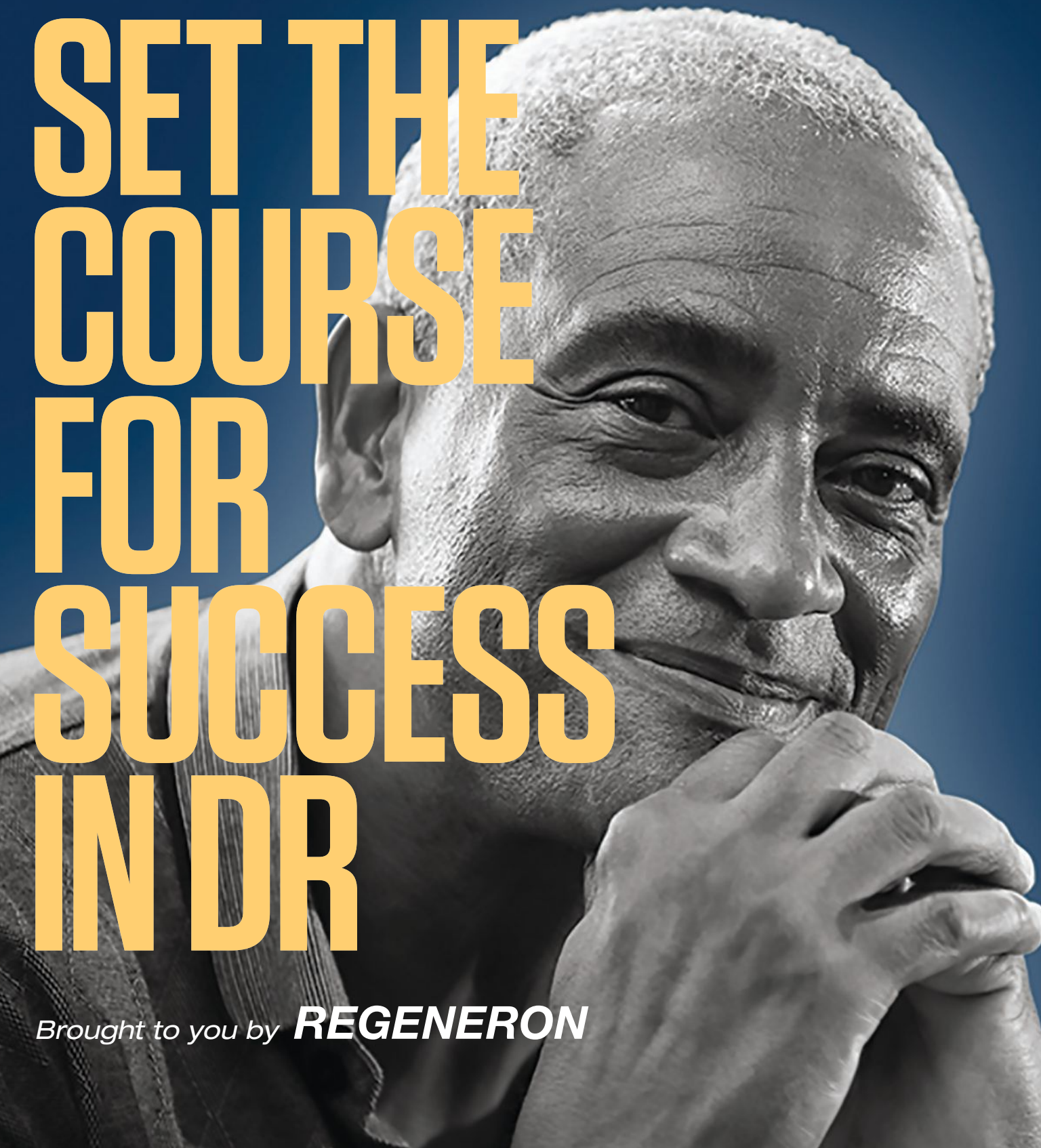
Reference: 1. Results from an in vitro laboratory study. TheraTears® SteriLid® Antimicrobial Eyelid Cleanser and Facial Wash showed efficacy in reduction of colony forming units for eight common eyelid organisms. Data was captured at 30 and 60 seconds.

M18-069-00

PUT YOUR PATIENTS WITH  
**DIABETIC RETINOPATHY (DR)**  
ON THE PATH TOWARD  
MANAGING THEIR DISEASE AND

**SET THE  
COURSE  
FOR  
SUCCESS  
IN DR**

Brought to you by **REGENERON**





# DIABETIC RETINOPATHY: A GROWING PROBLEM THAT YOU CAN HELP MANAGE<sup>1-4</sup>

Through early detection, monitoring, and timely referral, you play a pivotal role in managing your DR patients' vision<sup>2-4</sup>

## If you see or suspect DR:



Educate your patients about the severity of DR, especially when left untreated<sup>3,4</sup>

- Your early and frequent discussions about disease progression, treatment options, and referral will empower patients, which could help them avoid significant vision loss<sup>3,4</sup>



According to the AOA, you should refer patients with<sup>3</sup>:

- Severe nonproliferative DR (NPDR) within 2 to 4 weeks
- Proliferative DR (PDR) within 2 to 4 weeks
- High-risk PDR with or without macular edema within 24 to 48 hours



Ensure patients have followed up with a retina specialist who can treat DR



Monitor your patients with DR<sup>3,4</sup>

The AOA recommends frequent monitoring of patients<sup>3</sup>

- At least every 6 to 8 months in patients with moderate NPDR and more frequently for patients with greater disease severity<sup>3</sup>

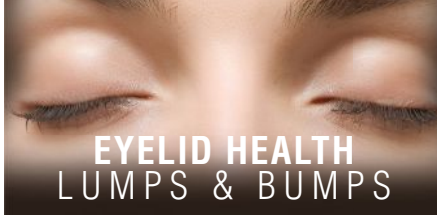## Refer patients to a specialist who can treat DR<sup>3,4</sup>

*Regeneron is committed to helping you partner with your patients for comprehensive care of DR, as well as for care of other retinal diseases.*

AOA = American Optometric Association.

**References:** **1.** Diabetic Retinopathy. Centers for Disease Control and Prevention website. <http://bit.ly/2BKTVCTS>. Accessed August 7, 2019. **2.** Early Treatment Diabetic Retinopathy Study Research Group. Fundus photographic risk factors for progression of diabetic retinopathy. ETDRS report number 12. *Ophthalmology*. 1991;98(5 suppl):823-833. **3.** Care of the Patient With Diabetes Mellitus: Quick Reference Guide. American Optometric Association website. <http://bit.ly/2M22OUJ>. Accessed August 7, 2019. **4.** Ferrucci S, Yeh B. Diabetic retinopathy by the numbers. *Rev Optom*. June 15, 2016. <http://bit.ly/2KNNJ4E>. Accessed August 7, 2019.





# A Close Look at Common LID LESIONS

Although benign most of the time, eyelid and periorbital lesions require careful diagnosis. These pearls can help you differentiate several you are likely to see.

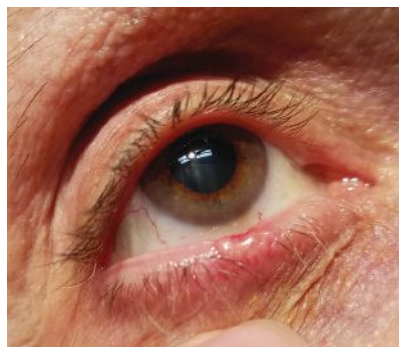
By Sara Weidmayer, OD, and Molly McGinty-Tauren, OD

**M**any eyelid lesions are so commonplace in clinical practice that the finding is dismissed, but some raise suspicion and a few generate concern for malignancy—particularly lesions that have changed in size, shape or color; are itchy or have ulceration, scabbing or bleeding, or with other concerning clinical features. Differentiating benign from pre-malignant or malignant is crucial to help guide appropriate management and referral.

Here's a look at many of the frequently observed eyelid and periorbital lesions along the benign to malignant spectrum.

## Benign Lesions

The location of many benign and pre-malignant eyelid lesions, such as seborrheic keratosis (SK), actinic keratosis (AK) and Bowen's disease, is related to chronic and direct sun exposure—making their occurrence most typical on the lower eyelids.<sup>1,2</sup> Many of these lesions are only of cosmetic concern, though in some



**Basal cell carcinoma of the lower eyelid margin. Note the ulceration of the superior aspect, the lesion's pearly elevated margins and madarosis.**

cases they can induce astigmatism or eyelid disfigurement that requires intervention.

**Chalazia.** These are firm, well-defined nodules in the subcutaneous eyelid tissue, within the tarsal plate. They typically form as chronic sequelae to an acute meibomian gland hordeolum. Chalazia are comprised of consolidated lipogranulomatous tissue.<sup>3</sup> They may present with acute inflammation but more often are non-tender

and a cosmetic aggravation.<sup>4</sup> They tend to be found in patients with concomitant blepharitis and meibomian gland dysfunction (MGD).

Frequent warm compresses and gentle massage over the lesion may lead to improvement or resolution, though resolution is less likely if the chalazion has been present for two months or more.<sup>4</sup> The additional use of antibiotic or antibiotic/steroid solutions or ointments can also be effective, but does not appear to improve resolution outcomes or overall lesion size compared with warm compresses alone.<sup>4</sup> If unresolved, intralesional steroid injection or incision and curettage are the next therapeutic steps.

In cases of locally recurrent chalazion, be on high alert for sebaceous cell carcinoma (SCC), particularly in older patients.

**Epidermal inclusion cysts.** These are common cutaneous lesions, often referred to as epidermoid, epidermal, inclusion or keratin cysts.<sup>5</sup> They contain keratinized squamous epithelium and lipids, which may

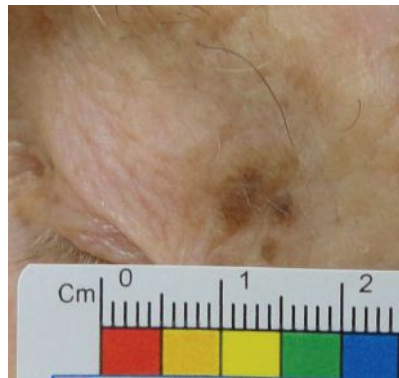
be odorous if ruptured. They are dome-shaped and creamy- or skin-colored and often have a superficial central keratin plug. These cysts may form directly within a hair follicle if its orifice becomes obstructed, or may form secondary to dermal trauma or acne, whereby the epithelium implants into the dermis.<sup>5</sup> Epidermal inclusion cysts mostly remain quiescent, but in some cases can grow and become inflamed, infected or rupture.<sup>5</sup> Rarely, case reports have described their development into SCC, but its documented occurrence is so rare that monitoring or biopsy are not necessary.<sup>6</sup>

Surgical excision of the cyst with its walls is the definitive treatment, though observation is acceptable in asymptomatic cases.<sup>5</sup>

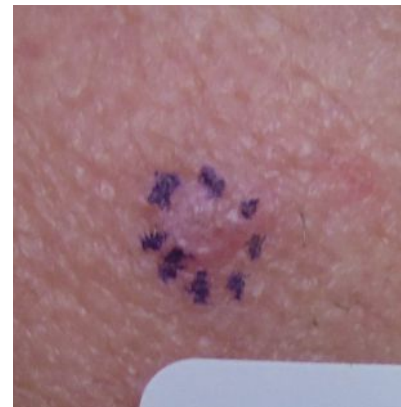**Hidrocystoma.** Apocrine and eccrine sweat glands are found along the eyelid margins and in the pretarsal and preseptal skin, respectively.<sup>7</sup> Hidrocystomas, which develop in these glands, are fluid-filled solitary cystic elevations that are translucent or may have a bluish hue.<sup>2</sup>

Traditional treatment involves incision and drainage; however, improvement tends only to be temporary, as the cysts often re-fill within two to six weeks.<sup>8</sup> Electrodesiccation of the walls of the cyst and cautery may help delay recurrence, but the cysts can remain untreated if they are not bothersome to the patient.<sup>8,9</sup>

**Seborrheic keratosis.** This is the most common benign tumor and is frequently seen on the face, particularly in elderly patients. These epithelial proliferations are typically darkly pigmented, slightly raised and well-defined with a scaly texture of ridges and fissures that often appear as if they are “stuck on” the skin. They do not transform into



**Melanoma *in situ* of the lateral upper eyelid. Note the lesion’s asymmetry and irregular borders, satellite lesions and variable pigmentation.**



**Squamous cell carcinoma of the cheek. Note the raised margins and scaly surface.**

malignancy but can be removed as needed with cryotherapy, curettage or ablative laser.<sup>10</sup>

### Pre-malignant Lesions

For pre-malignant lesions, the commonly used term *in situ* refers to a group of abnormal cells confined to the epidermal layer but not breaching the basement membrane. A breach would be considered invasive carcinoma.<sup>11</sup> Identifying and properly managing or referring these lesions may be critical to the patient’s long-term outcomes.

**Nevi.** Melanocytic nevi are quite common and are often referred to as moles.<sup>2</sup> Junctional nevi may be present at birth or may develop before early adulthood. These are pigmented, flat macules that grow over time into the common compound (epidermal and dermal) or intradermal nevus.<sup>2</sup> Excision or shave is optional if they are troublesome to the patient. Nevi are dynamic and grow over time, but clinicians should monitor them for atypical features that would warrant referral to evaluate for melanoma (Table 1).

**Actinic keratosis.** Also known as solar keratosis, this is a

clinical sign of photo-aging—sun-related skin damage to exposed areas.<sup>11,12</sup> These lesions demonstrate intraepithelial keratinocytic dysplasia and are *in situ* SCC, precursors of invasive SCC.<sup>11</sup> AK usually appears as pink, but possibly tan or red, pustules or plaques, which may become scaly with time; hypertrophy or bleeding should increase suspicion for SCC.<sup>13</sup> Because the clinical features of AK are fairly nonspecific with broad differentials, clinicians should refer for biopsy when they present in high-risk anatomical locations or in high-risk patients, such as those with a history of skin cancer or immunosuppression.<sup>13</sup> Anatomic locations considered higher risk for

**Table 1. The ABCDEs of Melanoma**

Signs concerning for malignant transformation of a nevus into melanoma
<b>A</b> symmetry: if any two halves of a lesion are not symmetric
<b>B</b> orders: irregular borders or development of satellite pigmentation
<b>C</b> olor: uneven color or changes in color (especially white, gray, red or blue)
<b>D</b> iameter: enlarging size or >6mm diameter
<b>E</b> levation
Other concerning changes include ulceration, scaling, discharge or bleeding



## EYELID HEALTH LUMPS & BUMPS

### Evaluation Pearls

Because 15% to 20% of periocular lesions are malignant, comprehensive eye examinations should include questioning regarding prior skin cancers and the extent of UV exposure.<sup>19,20</sup> Clinicians should document objective findings such as skin type, lesion size, changes to pre-existing lesions, ulceration, pigmentation, madarosis, induration, symptoms such as itching or bleeding and changes to eyelid architecture and function. Cervical, preauricular, parotid and submandibular lymph nodes should be palpated for firmness and tenderness.<sup>34</sup> Clinicians should photograph all suspicious lesions and refer patients to dermatology, tele-dermatology or oculoplastics for evaluation. If a full eyelid examination reveals any signs of orbital invasion such as strabismus, hyper- or hypo-globus, extraocular muscle dysfunction and proptosis, clinicians should evaluate these patients with neuroimaging.<sup>22</sup>

carcinoma due to chronic sun exposure include the eyelids and periorbital region, the dorsal hands, legs, forearms, ears and lips; most SCC in these regions arise from AK.<sup>12</sup> They are not often solitary but more frequently develop as a cluster of lesions; AKs are rarely found on the eyelids and periorbital regions but should raise high suspicion for malignancy when they do.<sup>12</sup>

Around 25% of AK lesions may spontaneously regress over their inaugural year without intervention, though many later recur locally, and the rate of malignant transformation from AK to invasive SCC is estimated at 0.1% to 10%.<sup>12,14</sup>

Definitive treatment with excisional biopsy with permanent pathology or frozen sections is frequently used for AK around the eye; in some cases, Mohs micrographic surgery is needed, and several other treatment options exist such as topical chemotherapy or cryotherapy.<sup>15</sup>

Mohs is a microscopically controlled excisional surgery that involves removing a lesion with a small amount of its surrounding tissue in tangential sections, evaluating the tissue's margins microscopically for cell content, then progressively enlarging the excised area until all margins contain only normal, cancer-free tissue. The tissue is processed into stained frozen

sections for microscopic evaluation of each plane's content to decipher whether further micro-excision is needed. The goal of this surgery is to fully remove the lesion of concern, ensuring clear margins to reduce the rate of local recurrence but minimizing healthy tissue loss. Following excision, primary wound closure, second-intention healing or reconstruction ensues.<sup>16</sup>

**Keratoacanthoma.** This unusual lesion grows rapidly over weeks in a dome shape, remains stable for a few weeks, then involutes to include a keratin-filled center, creating its characteristic crater-like appearance. The lesion is fleshy with telangiectatic surface vessels and possibly erythema at its margins. It is also a squamoproliferative process, which can ultimately result in invasive SCC. Keratoacanthoma is atypical in the periorbital area, despite it being most commonly found in other highly sun-exposed regions; it

is found more typically in males in their 40s to 60s.<sup>17</sup>

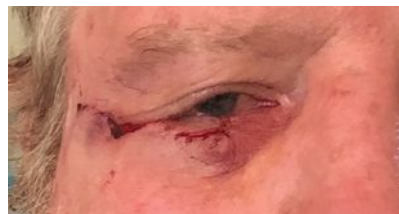Keratoacanthoma can fully regress without any intervention.<sup>18</sup> However, while keratoacanthoma's clinical appearance seems unique, it is not clinically pathognomonic, and histology is necessary to definitively rule out invasive SCC.<sup>17</sup> Full excision with margin control, recommended for all periorbital lesions suspected to be keratoacanthoma, provides a low recurrence rate.<sup>17</sup> Even if not found to be SCC, excision will prevent local tissue destruction.

### Malignant Lesions

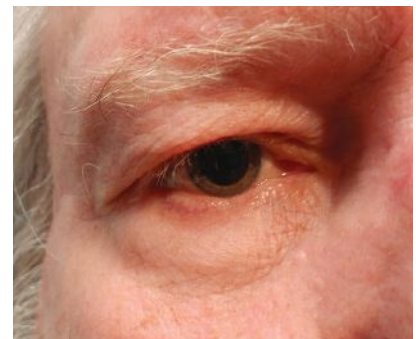
Eyelid malignancies carry a considerable risk of globe and vision impairment, given that eyelid and periocular tissue destruction can impair the tear drainage apparatus, eyelid position, muscular function and local glandular secretions. This is true for both the lesion itself and after its excision and repair. Ultraviolet (UV) exposure is the principal risk factor for all of the following eyelid malignancies.

#### **Basal cell carcinoma (BCC).**

This accounts for 90% to 95% of eyelid malignancies, making them the most frequently encountered.<sup>19</sup> Eighty percent of BCCs occur on the head and neck, with 20% of these being periocular.<sup>20</sup> BCCs within the periocular area are most commonly located on the lower



**This patient had BCC of the lower eyelid. Above is the immediate post-op s/p Mohs micrographic surgery with Tenzel closure. At right is one year post-op.**





# FIVE OF A KIND BEATS ANY DEALER'S HAND.

CONSULT LOMBART AND GET *YOUR* WINNING HAND.



- ✓ BROAD PORTFOLIO OF  
NEW AND PRE-OWNED
- ✓ DEDICATED, KNOWLEDGEABLE  
TECHNOLOGY DIRECTORS
- ✓ ONGOING TRAINING FROM OUR  
CLINICAL SUPPORT TEAM
- ✓ CONSULTATIVE APPROACH  
TO HELP YOU FIND  
THE RIGHT SOLUTION

**LOMBART**  
YOUR OPHTHALMIC PARTNER

Lombart Instrument is the nation's largest distributor of ophthalmic instruments, services, and supplies. Since our founding in 1979, we have been dedicated to creating long-lasting partnerships and serving our customers: optometry and ophthalmology practices, universities, hospitals, and the US government. It is because of the effort of our incredible staff that we have been the industry leader since 1987, and we work hard every day to provide the highest quality service to our customers.

**800.LOMBART**  
LOMBARTINSTRUMENT.COM

CONTACT YOUR LOMBART REPRESENTATIVE TO SEE  
WHICH OCT BEST FITS *YOUR* PRACTICE.



## EYELID HEALTH LUMPS & BUMPS

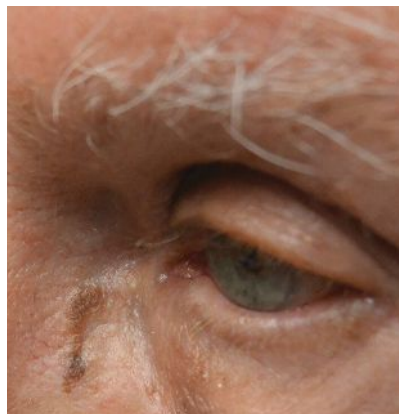eyelid (50% to 60%), followed by the medial canthus (25% to 30%).<sup>19</sup> They can also be found on the upper lids and lateral canthus.<sup>21</sup> Risk factors for BCC include advancing age, UV exposure (particularly during adolescent years), immune suppression, fair skin with red or blonde hair and blue eyes and smoking.<sup>20-22</sup> BCC has no sex predilection.<sup>23</sup> BCC rarely metastasizes but can be locally invasive.

BCC is subdivided into types, each with its own distinguishing features. The nodular subtype is the most common, representing anywhere between 43% and 77% of presentations.<sup>20</sup> These tend to present as painless nodular lesions, but may cause symptoms of itching or bleeding.<sup>20</sup> These lesions can be white with pearly raised edges, telangiectatic vessels and central ulcerations, which are expected with increasing size.<sup>20,24</sup> Growth is slow and insidious and can cause madarosis if at the lash line.<sup>20</sup>

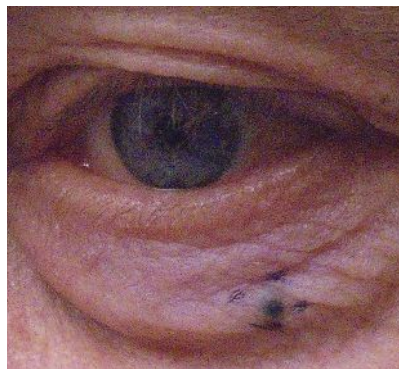Rodent ulcers, a variant of the nodular subtype, are described as solid, circumscribed and often scab.<sup>21</sup>

The morpheaform subtype of BCC is more aggressive and presents as solitary, pale, flesh- or yellow-colored with poorly defined margins.<sup>20</sup> These lesions can be located in the medial canthus. Because of the morpheaform nature, a greater likelihood for incomplete resection and recurrence exists and therefore recurrence.<sup>21</sup>

For all variants of BCC, complete excision with Mohs is expected 99% of the time with recurrence rates of up to 3% overall; the five-year local recurrence rate after Mohs for primary BCC is 1% and 5.6% for recurrent BCC.<sup>19,25-27</sup> Comparatively, standard excisions (non-Mohs) are incomplete for up to a quarter of periocular BCC with



**Seborrheic keratosis of the nasal sidewall is less scaly and ridged than often seen, and could be mistaken for melanoma.**



**Nodular melanoma of the lower eyelid.**

recurrence rates as high as 30% to 50%.<sup>20,25</sup> Because up to 18% recur at five years, long-term monitoring post-excision is advised.<sup>25</sup>

**Squamous cell carcinoma.** This is the second most common eyelid malignancy comprising 3.4% to 12.6%.<sup>20</sup> SCCs occur two to three times more frequently in men than women with a median age of onset in the sixth and seventh decades.<sup>22</sup> As with BCC, SCC are commonly found on the lower lids and medial canthi.<sup>21</sup> Risk factors include UV exposure, fair complexions, immune suppression, high fat diets, chemical exposures, smoking and human papilloma virus (HPV).<sup>20</sup>

SCC can arise *de novo* or from AK, Bowen's disease, keratoacan-

thoma or post-radiation treatment exposure.<sup>19</sup> Bowen's disease is SCC *in situ*, which histologically shows full thickness epidermal squamous cell dysplasia.<sup>28</sup> It is a superficial skin cancer in an early stage but may progress to invasive SCC in 3% to 5% of cases.<sup>29</sup>

SCC presents similarly to BCC. Their natural course generally begins as a painless, small raised keratin patch, which slowly transforms to a papillomatous lesion and then to a larger ulcerated lesion.<sup>22</sup> These are commonly misdiagnosed as chronic anterior blepharitis.<sup>20</sup>

SCCs tend to be invasive and patients are at risk for metastasis through direct extension of cancerous cells into surrounding tissue or through the lymphatic system.<sup>19</sup> Overall, SCC comprises greater than 20% of non-melanoma skin cancers (NMSC) and account for the most metastatic disease and mortality from NMSC.<sup>13</sup> The risk for tissue destruction is significant.

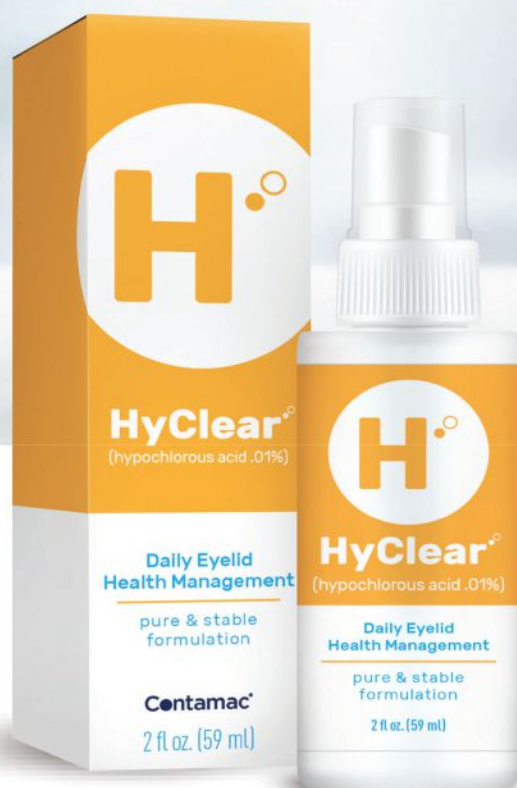Reported recurrence rates are similar to that of BCC at 2.4% to 36.9% at five years, with the extremes of the range relating to Mohs versus standard excision.<sup>20</sup> The five-year recurrence after Mohs for recurrent SSC is 10%. For primary SCC that is well differentiated without metastasis, the recurrence rate after Mohs is 2% to 3%.<sup>30</sup>

**Sebaceous cell carcinoma.** This accounts for only 5% of eyelid neoplasms, although the incidence is higher for Asians than Caucasians.<sup>24</sup> These lesions arise from meibomian and zeiss glands and are more likely to occur on the upper eyelid due to the preponderance of glandular ducts in this region.<sup>21</sup> Female patients and those in their late 50s to early 70s are at increased risk.<sup>20</sup> Sebaceous cell carcinomas present as painless solitary nodules or a diffuse thickening with

# HyClear<sup>®</sup>

## The ONLY Balanced Analytic Hypochlorous Acid™

for Essential Daily Eyelid Health Management



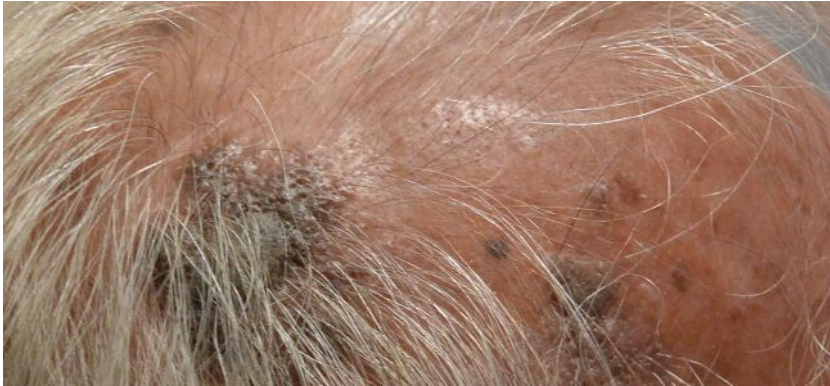Introducing the next generation of hypochlorous acid for essential daily eyelid health management. With a broad-spectrum of antimicrobial activity from the pure hypochlorous acid .01%, HyClear kills most ocular pathogens in 15 seconds\*.

HyClear is an exclusive brand for Optometrists and Ophthalmologists for sale directly to their patients. It will provide a safe, easy to use treatment for eyelid hygiene without the high cost or hassle of being a prescription product.

Visit [getHyClear.com](http://getHyClear.com)  
and create an account today!

\*In solution.





Typical appearance of SK, seen here on the scalp.

erythema.<sup>21</sup> Madarosis will often occur if the lesion's source is a zeiss gland. The lesions can be yellow due to the lipid content within the neoplastic cells.<sup>19</sup> Although a rare presentation, sebaceous cell lesions can ulcerate and mimic BCC.<sup>24</sup>

Differentials include recurrent chalazion, blepharoconjunctivitis, BCC or SCC. These lesions are misdiagnosed, clinically and pathologically, up to two-thirds of the time, which can delay appropriate treatment by as much as one to two years.<sup>20,22</sup>

Hallmark features of this malignancy are pagetoid spread (26% to 47% of the time) and aggressive local extension.<sup>22</sup> Pagetoid spread is defined as intraepithelial growth that often extends over the conjunctiva.<sup>19</sup> Conjunctival involvement presents as injection with or without papillary reaction.<sup>20</sup> Therefore, clinicians should suspect sebaceous cell carcinoma in cases

of un-resolving unilateral blepharoconjunctivitis. Recurrence rates differ based upon the presence of pagetoid spread—36% with vs. 7% without—implying that epithelial involvement greatly affects prognosis.<sup>19</sup> Lymph involvement ensues through perineural infiltration and invasion. Metastasis to lymph nodes and distal organs occurs in 8% to 18% and 3% to 8% of cases, respectively.<sup>22</sup>

**Malignant melanoma.** These account for fewer than 1% of eyelid malignancies.<sup>21</sup> The lesions arise *de novo* or from pre-malignancies such as congenital nevi, dysplastic nevi or lentigo maligna (melanoma *in situ*, also known as Hutchinson's freckle).<sup>20</sup> Eyelid melanomas can present with or without pigment, complicating accurate diagnosis. Therefore, clinicians should consider the ABCDEs of melanoma (Table 1). Sun exposure to fair skin puts patients at greatest risk, with

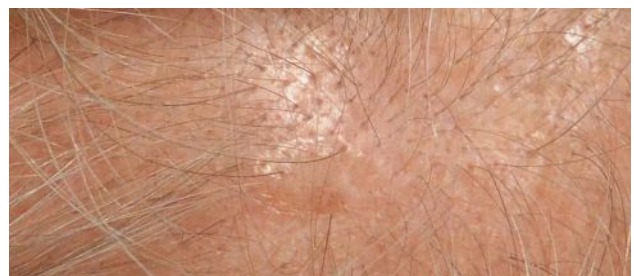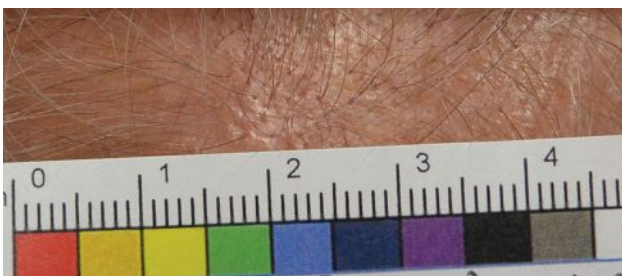**Table 2. AEIOU Findings Consistent with Merkel Cell Carcinoma<sup>35</sup>**

Asymptomatic
Expands rapidly
Immune suppression
Older than 50 years
UV exposure to fair skin

the lower eyelid being the most common location.<sup>31</sup> Superficial spreading lesions have a better prognosis than the nodular type.<sup>32</sup> Because eyelid melanoma's behavior is consistent with cutaneous melanomas, a significant risk of lymph node metastasis exists.<sup>3</sup>

**Merkel cell carcinoma (MCC).** This is another rare eyelid malignancy that originates from neuroendocrine cells.<sup>20</sup> Females are more apt to be affected in their 70s and 80s.<sup>19</sup> Risk factors include sun exposure, immune suppression and polyomavirus. MCCs are solitary nodules with or without telangiectatic vessels. The nodules are painless and appear purple or reddish in color.<sup>20</sup> Additional signs may include ulceration and madarosis. The mnemonic "AEIOU" can help to recall features consistent with MCC (Table 2).<sup>35</sup>

Differential diagnoses for MCC include chalazion, keratoacanthoma, SCC, BCC and sebaceous cell carcinoma.<sup>34</sup> These lesions grow rapidly over weeks to months, and two-thirds of Merkel cell tumors



This patient with actinic keratosis of the scalp has a subtle lesion that is pinkish-tan and slightly elevated.

## Treatment Pearls

Incisional or excisional biopsies are indicated for most eyelid malignancies, with excisional reserved for the more aggressive forms. Considerations for skip lesions and pagetoid spread associated with sebaceous cell carcinoma may require full thickness or map biopsies.<sup>20</sup> Varying risks of metastasis to lymph nodes with all eyelid malignancies (except BCC) warrant sentinel lymph node biopsies, although some surgeons dispute this, citing little to no patient survival benefit.<sup>20</sup> Prior to determining treatment, the lesion's histologic diagnosis should be established (generally with permanent paraffin-embedded sections).

The standard surgical treatment for BCC, SCC and sebaceous cell is Mohs with intraoperative frozen sections.<sup>19,20,34</sup> Mohs is also used for many non-melanoma tumors and in situations where lesions may have aggressive growth patterns or when tissue conservation is critical.<sup>16</sup> Its use for Merkel cell and melanoma is controversial.<sup>16</sup>

The absence of subcutaneous fat in the eyelid complicates surgical reconstruction concerns. The delicacy of the periorbital area frequently requires an interdisciplinary approach that includes both a Mohs surgeon and oculo or facial plastic surgeon.<sup>25</sup>

Adjunct therapies to Mohs include topical chemotherapy for BCC lesions for which surgical excision is not appropriate or those with unclear margins.<sup>20</sup> Cryotherapy or topical chemotherapy are options for sebaceous cell lesions with pagetoid spread.<sup>24</sup> Radiotherapy, an adjunct therapy for MCC, can lower the rates of recurrence.<sup>19</sup> Photodynamic therapy with topical 5-aminolevulinic acid is a non-surgical alternative for SCC.<sup>19</sup>

A better understanding of genetic pathways for mutation has led to targeted immunotherapies. BCC studies have used medications such as vismodegib and imiquimod. Imiquimod may also have applications in the treatment of melanoma.<sup>20</sup> Epidermal growth factor receptor inhibitors are under investigation for SCC.<sup>20</sup> These promising treatments are likely to have less systemic toxicity.

When comanaging these post-op patients, optometrists are likely to encounter complications ranging from ptosis and trichiasis to ectropion and corneal ulcers.<sup>20</sup> Patients must be followed for signs of recurrence.

metastasize to the lymph nodes either at diagnosis or within 18 months.<sup>19,20</sup> Research suggests 21% of cases recur.<sup>35</sup>

Optometrists play a critical role in detecting and clinically deciphering between benign and concerning periocular lesions. Clinicians should be familiar with each lesion's typical features, risk factors, referral timeline, general treatments and outcomes to providing high quality patient care. ■

*Dr. Weidmayer practices at the VA Ann Arbor Healthcare System in Ann Arbor, MI.*

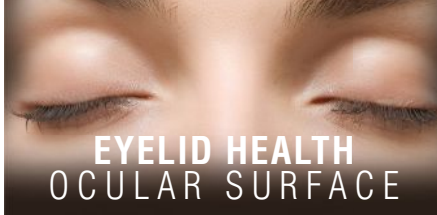*Dr. McGinty-Tauren practices at the Battle Creek VA Medical Center in Battle Creek, MI.*

*Contents in this publication do not necessarily represent the views of the U.S. Department of Veterans Affairs or the United States Government.*

1. Yu S-S, Zhao Y, Zhao H, et al. A retrospective study of 2228 cases with eyelid tumors. *Int J Ophthalmol*. 2018;11(11):1835-41.  
2. Baek SH, Chi MJ. Clinical analysis of benign eyelid and conjunctival tumors. *Ophthalmologica*. 2006;220:43-51.  
3. Suimon Y, Kase S, Ishijima K, et al. Clinicopathological features of cystic lesions in the eyelid. *Biomed Rep*. 2019;10(2):92-96.

4. Wu AY, Gervasio KA, Gergoudis KN, et al. Conservative therapy for chalazia: is it really effective? *Acta Ophthalmol*. 2018;96:e503-e509.  
5. Weir CB, St. Hilaire NJ. Epidermal inclusion cyst. *StatPearls [Internet]*. Treasure Island (FL): StatPearls Publishing; 2018.  
6. López-Ríos F, Rodríguez-Peraltó JL, Castaño E, Benito A. Squamous cell carcinoma arising in a cutaneous epidermal cyst: case report and literature review. *Am J Dermatopathol*. 1999;21(2):174-77.  
7. Singh AD, McCloskey L, Parsons MA, et al. Eccrine hidrocystoma of the eyelid. *Eye (Lond)*. 2005;19(1):77-9.  
8. Osaki TH, Osaki MH, Osaki T, Viana GA. A minimally invasive approach for apocrine hidrocystomas of the eyelid. *Dermatol Surg*. 2016;42(1):134-6.  
9. Gupta S, Handa U, Handa S, Mohan H. The efficacy of electrosurgery and excision in treating patients with multiple apocrine hidrocystomas. *Dermatol Surg*. 2001;27(4):382-4.  
10. Wollina U. Seborrhic keratoses - the most common benign skin tumor of humans. Clinical presentation and an update on pathogenesis and treatment options. *Open Access Maced J Med Sci*. 2018;6(11):2270-75.  
11. Werner RN, Sammain A, Erdmann R, et al. The natural history of actinic keratosis: a systematic review. *Br J Dermatol*. 2013;169(3):502-18.  
12. Richard MA, Amici JM, Basset-Seguín N, et al. Management of actinic keratosis at specific body sites in patients at high risk of carcinoma lesions: expert consensus from the AKTeam of expert clinicians. *J Eur Acad Dermatol Venereol*. 2017;32(3):339-46.  
13. Venna SS, Lee D, Stadecker MJ, et al. Clinical recognition of actinic keratoses in a high-risk population: How good are we? *Arch Dermatol*. 2005;141(4):507-9.  
14. Marks R, Foley P, Goodman G, et al. Spontaneous remission of solar keratoses: the case for conservative management. *Br J Dermatol*. 1986;115(6):649-55.  
15. Lagler CNP, Freitag SK. Management of periocular actinic keratosis: a review of practice patterns among ophthalmic plastic surgeons. *Ophthalmic Plastic and Reconstructive Surgery*. 2012;28(4):277-81.  
16. Finley EM. The principles of Mohs micrographic surgery for cutaneous neoplasia. *Ochsner J*. 2003;5(2):22-33.  
17. Leibovitch I, Huilgol SC, James CL, et al. Periocular keratoacanthoma: can we always rely on the clinical diagnosis? *Br J Ophthalmol*. 2005;89(9):1201-4.  
18. Griffiths RW. Keratoacanthoma observed. *Br J Plast Surg*. 2004;57(6):485-501.  
19. Bernardini F. Management of malignant and benign eyelid lesions. *Curr Opin Ophthalmol*. 2006;17:480-84.  
20. Silverman N, Shinder R. What's new in eyelid tumors. *Asia-Pac J Ophthalmol*. 2017;6(2):143-152.

21. Pe'er J. Pathology of eyelid tumors. *Indian J Ophthalmol*. 2016;64(3):177-90.  
22. Yin V, Merritt H, Sniogowski M, Esmaeli B. Eyelid and ocular surface carcinoma: Diagnosis and management. *Clinics in Dermatology*. 2015;33:159-69.  
23. Cook B, Bartley G. Epidemiologic characteristics and clinical course of patients with malignant eyelid tumors in an incidence cohort in Olmsted County, Minnesota. *Ophthalmology*. 1999;106(4):746-50.  
24. Ling M, Silkiss R. Diagnosis and management of sebaceous carcinoma of the eyelid. *Ophthalmic Pearls*. *Oncology*.  
25. Weesie F, Naus N, Hollestein L, et al. Recurrence of periocular basal cell carcinoma and squamous cell carcinoma after Mohs micrographic surgery: a retrospective cohort study. *Br J Dermatol*. 2019;180(5):1176-82.  
26. Rowe DE, Carroll RJ, Day CL Jr. Long-term recurrence rates in previously untreated (primary) basal cell carcinoma: implications for patient follow-up. *J Dermatol Surg Oncol*. 1989;15(3):315-28.  
27. Rowe DE, Carroll RJ, Day CL Jr. Mohs surgery is the treatment of choice for recurrent (previously treated) basal cell carcinoma. *J Dermatol Surg Oncol*. 1989;15(4):424-31.  
28. Neubert T, Lehmann P. Bowen's disease - a review of newer treatment options. *Ther Clin Risk Manag*. 2008;4(5):1085-95.  
29. Kao GF. Carcinoma arising in Bowen's disease. *Arch Dermatol*. 1986;122(10):1124-6.  
30. Rowe DE, Carroll RJ, Day CL Jr. Prognostic factors for local recurrence, metastasis, and survival rates in squamous cell carcinoma of the skin, ear, and lip. Implications for treatment modality selection. *J Am Acad Dermatol*. 1992;26(6):976-90.  
31. Chan F, O'Donnell B, Whitehead K, et al. Treatment and outcomes of malignant melanoma of the eyelid. *Ophthalmology*. 2007;114(1):187-92.  
32. Garner A, Koornmeef L, Levene A, Collin J. Malignant melanoma of the eyelid skin: histopathology and behavior. *Br J Ophthalmol*. 1985;69(3):180-86.  
33. Shields C, Shields J. Ocular melanoma: relatively rare but requiring respect. *Clinics in Dermatology*. 2009;27(1):122-33.  
34. Huang D, Silkiss R. Diagnosis and management of Merkel cell carcinoma of the eyelid. *Eyenet*. 2015 Jan:37-39.  
35. Heath M, Jaimes N, Lemos B, et al. Clinical characteristics of Merkel cell carcinoma at diagnosis in 195 patients: the AEIOU features. *J Am Acad Dermatol*. 2008;58(3):375-81.



# At the Crossroads of Allergy, Dry Eye and Lid Disease

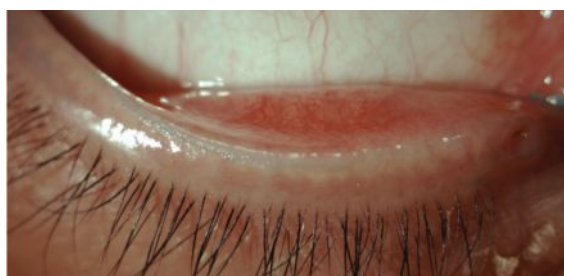Any of these ocular surface issues can set off inflammation. Here's how to get to the root of the problem. **By Clare Halleran, OD, and Jennifer S. Harthan, OD**

**T**he Tear Film and Ocular Surface Society (TFOS) delivered a landmark manuscript when it issued its second Dry Eye Workshop (DEWS II) report in 2017. That research highlighted the relationship between the intricately connected structures of the ocular surface.

The take-home point is that there rarely is just one structure affected when tear homeostasis is disrupted. Dry eye states, for instance, worsen allergic reactions, and those allergic reactions cause more inflammation, which in turn, worsens ocular dryness. Inflammation is both the cause and effect of dry eye states. It's a vicious cycle.

TFOS's original DEWS report, published in 2007, defined the lacrimal functional unit (LFU) as an integrated system comprised of the lacrimal glands, the ocular surface, the eyelids and the sensory/motor nerves that connect them all.<sup>1</sup>

This article reviews the key areas of the LFU and how they are altered when ocular allergy and dry eye emerge.



**Fig. 1.** This patient's line of Marx is visible thanks to vital dye staining.

## The Value of Healthy Lids

In general, when patients experience problems with their eyelids, they are often gradual and likely developed before obvious symptoms were noticed. The lids, and subsequently the palpebral conjunctiva, are two areas that optometrists must investigate extensively.

The eyelids contain three glands—Zeis, Moll, meibomian—that come together to create the lipid layer, comprised of low polarity (wax and cholesterol esters) and high polarity lipids (triglycerides, free fatty acids and phospholipids). The main function of these lipids is to create a uniform, protective top layer of the tear film.<sup>2</sup> While

small—only 3 $\mu$ L thick—the tear film creates lubrication, as well as antimicrobial protection, nutrition, maintenance of corneal transparency and surface stem cell population. It's vital for the removal of debris and the preservation of the quality of the

image projected to the retina.<sup>2-4</sup>

Blinking occurs approximately once every three to four seconds in most patients. However, research shows digital devices are reducing blink rates to 4.5 per minute.<sup>5</sup>

This is one lifestyle factor that can cause the LFU to dysfunction, setting off the vicious dry eye cycle. A normal functioning eye would flush away inflammatory mediators that suppress T-cell activation and inhibit complement-mediated tissue damage by blinking and tear drainage from the ocular surface. With fewer blinks, the patient may be at risk for meibomian gland atrophy and ultimately chronic ocular surface disease.<sup>6</sup>



## LFU Examination

Evaluating the external eyelid begins during initial observation. This exam requires optometrists to observe lid positioning, blink rates and lid closure before putting their patient in front of a slit lamp. These evaluations are especially important in geriatric patients, as their orbicularis muscle may lose tension and lagophthalmos and lid congruity conditions may be present. Observing the eyelid margins may lead to additional causes for a patient's symptomatology.

Lid wiper epitheliopathy can be a contributing factor to many debilitating symptoms.<sup>7</sup> A patient who presents with a normal appearing blink rate and function but is symptomatic of dry eye or contact lens discomfort warrants an evaluation of this structure. The lid wiper is the anatomical area of the palpebral marginal conjunctiva in the upper and lower lids that is in contact with the globe. In the upper lid, it extends from the crest of the sharp posterior (inner) lid border (the mucocutaneous junction) to the subtarsal fold superiorly, and from the medial upper punctum to the lateral canthus horizontally in the lower lid.<sup>7</sup> Lid eversion is a simple, useful diagnostic assessment for any patient presenting with symptoms of dry eye or contact lens discomfort.

Lid wiper epitheliopathy is also associated with decreased tear film stability, contact lens wear and lid-parallel conjunctival folds.<sup>8</sup> It's best observed with vital dye staining—in particular, lissamine green, which can unveil significant dryness secondary to frictional and mechanical forces (such as contact lens wear).<sup>9</sup>

The mucocutaneous junction, also known as the line of Marx (LOM), runs parallel to and away from the orifices of the meibomian glands along the conjunctival border in

normal patients and becomes anteriorly displaced to the orifices with increasing irregularity.<sup>10</sup> Researchers still aren't sure whether meibomian gland dysfunction (MGD) is caused by this anterior displacement of the LOM or if MGD precedes its displacement.

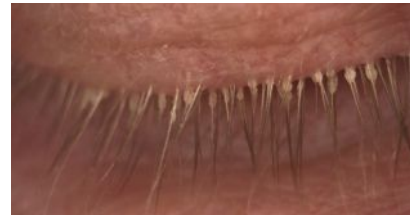It is possible to view the superior LOM without lid eversion but research shows lissamine green is the best way to observe keratinized debris (*Figure 1*).<sup>11</sup>

Debridement of LOM is a clinically significant method for improving symptoms.<sup>12</sup> It also provides meibomian gland production in some severe dry eye patients.<sup>12</sup> The mechanical debridement of the LOM and the lid margin removes keratin from the meibomian gland orifices that can obstruct lipid expression to the ocular surface.<sup>13</sup> This technique can provide its own statistically significant symptom relief and improve meibomian gland function.<sup>14</sup>

Carefully evaluating the base of the lashes on slit lamp examination can help expose an abundance of *Demodex folliculorum* or *Demodex brevis*.<sup>15</sup> Run amok, these mites can both create eyelid inflammation (blepharitis) and inflame rosacea that, in turn, affect the meibomian glands' ability to secrete meibum—another vicious cycle.<sup>16,17</sup>

Research presented at ARVO in 2017 demonstrated that cylindrical dandruff was pathognomonic for the presence of *Demodex* (*Figure 2*).<sup>17,18</sup> Additionally, patients with more lid laxity also had higher incidence of *Demodex*.<sup>17,18</sup> Treatments include tea tree oil and examination for clinical sign of these mites should be done during a general examination.

Many chemicals used in cosmetics affects the ocular surface. In fact, oil-based makeup can provide suste-



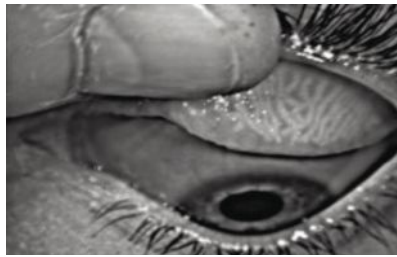
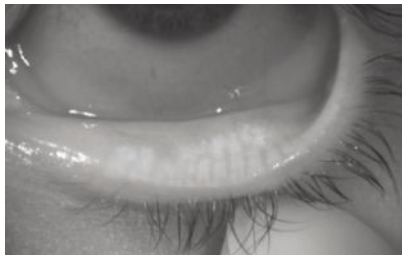**Fig. 2. This patient's lashes show cylindrical dandruff secondary to the presence of *Demodex*.**

nance for *Demodex*, so ODs should advise patients regarding daily cosmetic hygiene practices and consistent removal of cosmetics. Those with a *Demodex* diagnosis should avoid oil-based make-up products. Even those without *Demodex*-related issues who do not remove make-up products report more complaints of dry eyes than those who do remove those products.<sup>20</sup>

## Meibomian Gland Dysfunction

Research suggests MGD is the most frequent cause of DED.<sup>21</sup> Diagnosing MGD requires a combination of collecting patient symptoms—such as burning, itching, irritation, foreign body sensation and dryness—and diagnostic imaging—such as meibography, tear break-up time, the Korb Meibomian Gland Evaluator (Johnson & Johnson Vision) and Schirmer testing (*Figure 3*).<sup>22</sup>

MGD and DED are not mutually exclusive. MGD may result, as discussed, from eyelid inflammation, but it can also arise from conjunctival inflammation, corneal damage, tear film instability, microbiological changes associated with DED or any combination of those.<sup>21</sup> Gland dropout, blockage and inflammation can all cause stasis. Over time, this leads to chronic proliferation of bacteria and can provide an environment *Demodex*, ultimately increasing lid and conjunctival inflammation, thus perpetuating the chronic inflammatory cycle of DED.<sup>21,23,24</sup>



**Fig. 3.** These meibography images of an upper and lower lid demonstrate atrophy, truncation and tortuosity of the meibomian glands.

### Allergy

Ocular allergy can significantly alter the DED cycle by initiating an inflammatory response in the ocular surface, which in turn leads to tear film instability.<sup>25</sup> The DEWS II includes allergic conjunctivitis among DED's likeliest risk factors.<sup>25</sup>

Ocular allergy is typically classified into two main categories: common keratoconjunctivitis (seasonal and perennial) and rarer keratoconjunctivitis (vernal and atopic). Seasonal and perennial conjunctivitis are immunoglobulin E (IgE)-mediated hypersensitivity responses, typically presenting with mild-to-moderate signs and symptoms of ocular allergy. Allergic conjunctivitis can be distinguished from *Demodex* based on the location of the itch. In allergy, it is directed toward the conjunctiva, whereas *Demodex* itching is experienced along the lid.

Vernal and atopic keratoconjunctivitis are T-helper-mediated responses, often presenting with more complex, severe chronic inflammatory responses.

Several studies show an association between ocular allergy and reduced tear break-up-time (TBUT).<sup>25,28-31</sup> A 2017 study demonstrates how patients with ocular allergy develop morphological changes to their meibomian glands, which could be attributed to either ocular inflammation or damage from scratching and eye-rubbing, or both.<sup>32</sup>

The DEWS II research includes tear osmolarity in its diagnostic protocol, as it is a core mechanism of dry eye disease.<sup>23</sup> One study looked at osmolarity in patients with allergic rhinoconjunctivitis, finding values of 318mOsm/l to 324mOsm/l.<sup>34-36</sup> Another study found increased levels of inflammatory markers matrix metalloproteinase-1, -2 and -9 in patients with vernal keratoconjunctivitis, which is significant, as increased levels of MMP-9 can lead to increased ocular surface staining and increased symptoms of dry eye disease.<sup>34-36</sup>

Neurosensory abnormalities also play a key role in ocular surface disease.<sup>37</sup> Hyperosmolarity of the tear film and ocular surface inflammation—both of which can result from allergic reactions—can change corneal sensory receptors by inducing peripheral sensitization and even nerve damage. Symptoms of ocular allergy and DED frequently overlap and are mediated by corneal sensory innervation. DED and ocular allergy are not mutually exclusive, and ODs must take care to examine the entire ocular surface to ensure patients receive appropriate integrated management.

### Right on Target

The symptomology of a patient's dry eye does not always match their clinical signs. This makes clinical management difficult. However, as we begin to understand the disease

further, this discrepancy is becoming less of an issue. Many practitioners have incorporated protocols to help develop more specific diagnoses and more targeted management of DED.

Diagnostic dyes such as sodium fluorescein, lissamine green dye and rose bengal are among the most common ways to observe signs of dry eye damage. In 2016, investigators noted that clinical dyes used as a means to determine the absence of tear abnormalities could produce a false negative in many cases ruled as 'symptoms not matching clinical signs'.<sup>37</sup> The research argued that a single instillation of a dye may not be sufficient to elicit evidence of ocular surface or lid wiper epitheliopathy associated with desiccation.<sup>37</sup> A second instillation may possibly show clinical evidence.<sup>37</sup> The concentration and volume of the dye per manufactured strip could also play a factor in results.<sup>37</sup>

Many practitioners have adopted point-of-care testing to assist with DED diagnosis and monitoring. Hyperosmolarity has been described as a primary marker of tear film integrity and is often higher in patients diagnosed with DED.<sup>38</sup> Measurement of tear osmolarity has a high-positive predictive value and should not be used as a standalone test. An unstable tear film will cause osmolarity readings to fluctuate, indicating the patient may need a change in management. MMP-9 immunoassay measurement provides information regarding the presence of inflammation on the ocular surface. Inflammation may be present before the clinical signs of dry eye, contributing to increased corneal desquamation and corneal surface irregularity. Point-of-care testing assists with the management of the patient, helping the practitioner quantify and monitor the patients response to therapies.



# nurture THEIR EYES



Take a fresh approach to treating dry eye symptoms with FRESHKOTE® Preservative Free (PF)

**Patented polymer blend** of polyvinyl alcohol and povidone supports all layers of the tear film<sup>1,2</sup>

**Triple-acting formula** reduces evaporation and increases stability of the tear film while high oncotic pressure draws excess water from epithelial cells<sup>1,3</sup>

**Compatible for use with contact lenses<sup>4</sup>**

**State-of-the-art multidose bottle** provides more than a month's worth of preservative-free drops when dosed 4 times a day<sup>5</sup>

RECOMMEND SOOTHING RELIEF

Visit [FRESHKOTE<sup>PF</sup>.com](https://www.freshkotePF.com) to learn more

FRESHKOTE®  
Preservative Free  
LUBRICANT EYE DROPS

References: 1. Holly FJ. Lacrophilic ophthalmic demulcents. *US Ophthalmic Rev.* 2007;3:38-41. 2. FRESHKOTE PF Drug Facts. Eyevance Pharmaceuticals LLC; 2018. 3. Holly FJ. *Colloidal Osmosis — Oncotic Pressure*. Grapevine, TX: Dry Eye Institute; 2006. 4. Fuller DG, Connor CG. Safety and efficacy of FreshKote® used as a rewetting agent in Lotrafilcon-A® contact lens wearers. Poster presented at: American Academy of Optometry Annual Meeting; November 17-20, 2010; San Francisco, CA. 5. Nemer. Novelia®. <https://nemer.net/products/ophthalmic-novelie-eyedropper/>. Accessed March 14, 2019.



© 2019 Eyevance Pharmaceuticals LLC. All rights reserved.  
FRESHKOTE® is a registered trademark of Eyevance Pharmaceuticals LLC.  
Novelia® is a registered trademark of Nemer Development.  
FPF-10-19-AD-28





## EYELID HEALTH OCULAR SURFACE

Meibomian gland evaluation through expression and meibography has become an essential part of the clinical examination. However, a common concern with meibography is how to appropriately use the information gathered to help classify a patient's level of MGD. Heiko Pult's grading scale was determined to be the most agreeable between grading clinicians and has been used to grade meibomian gland atrophy (MGA) in multiple research papers and posters.<sup>30</sup>

### Lifestyle

Environment and geographic location may contribute factors to ocular surface disease. Temperature, humidity and pollen counts can affect the signs and symptoms of dry eye. Expectedly, as humidity levels increased, symptomology decreased. However, in times of higher temperature without humidity symptoms of dry eye increased. In addition, as pollen counts elevated, symptoms increased, more lower lid staining was recorded and non-invasive tear break up time decreased.<sup>40,41</sup> The use of digital devices is growing and with increased use, eye care practitioners have noted higher prevalence of dry eye signs and symptoms among all age groups, including children. The potential adverse effect of this increased digital use may interfere with work and school performance, productivity and quality of life.

A study presented at ARVO in 2016 demonstrated that, regardless of age, patients are using an increased number of digital devices for multiple hours throughout the day contributing to dry eye symptoms and vision fluctuation.<sup>42</sup>

The ocular surface is complex and complaints of ocular discomfort are often not exclusive to one disease

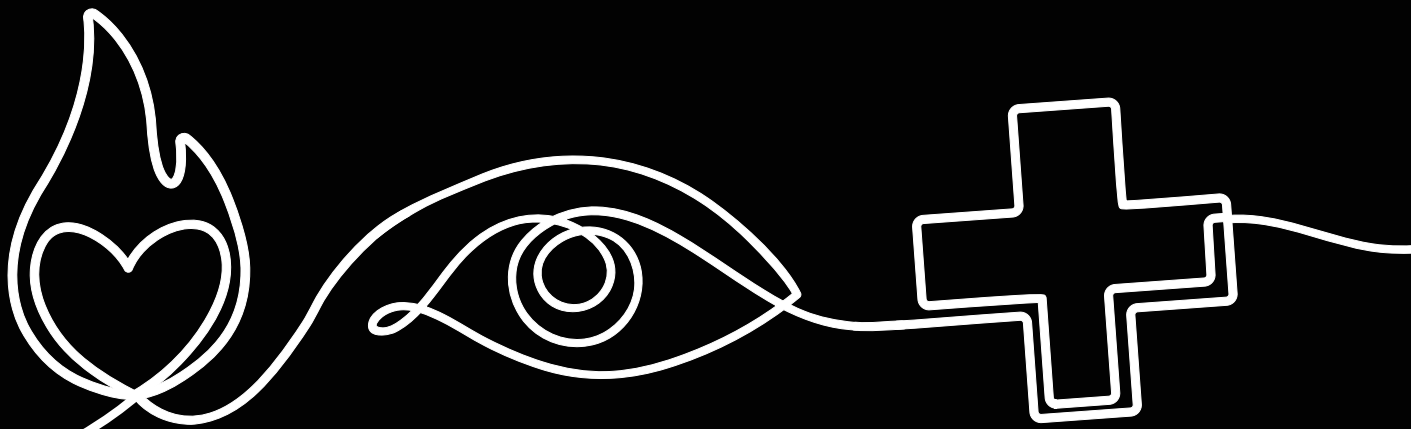
process. Advancements in anterior diagnostic testing have furthered our understanding of how changes to the structures of the anterior eye contribute to ocular surface disease processes. Optometrists are in a unique position to make a true difference in our patient's lives and there is much every practitioner can do to make a positive difference to the health our patient's eye. By reminding ourselves how eyelid morphology, allergic processes and dry eye progression are connected, careful examination of every patient will lead to more preventative and customized management. ■

*Dr Halleran is a private practice owner in Clarenville Newfoundland Canada and serves as an adjunct clinical instructor for Waterloo School of Optometry.*

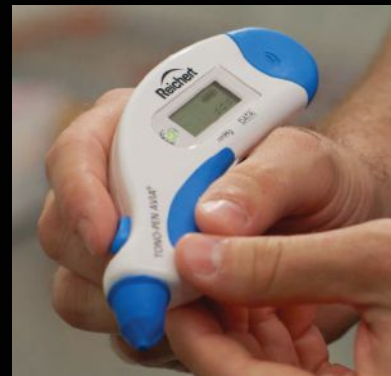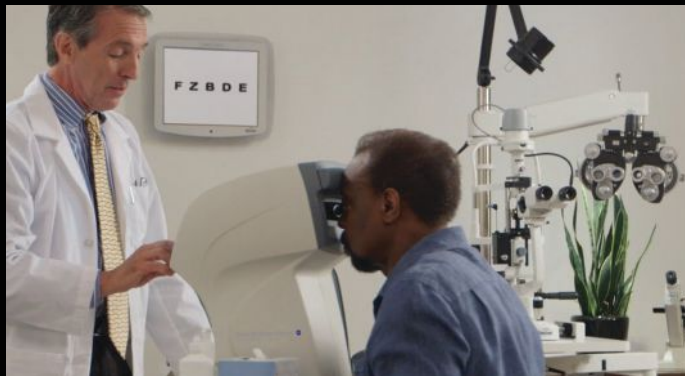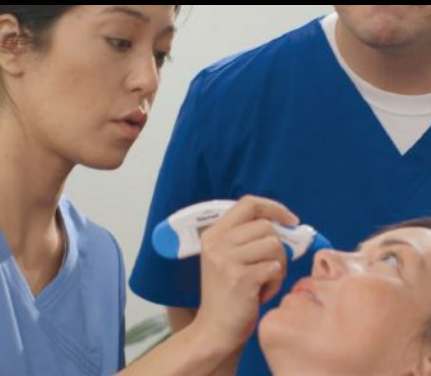*Dr. Harthan is a professor at the Illinois College of Optometry and chief of the Cornea Center for Clinical Excellence at the Illinois Eye Institute.*

1. International Dry Eye Workshop. The definition and classification of dry eye disease: report of the Definition and Classification Subcommittee of the International Dry Eye Workshop. *Ocul Surf.* 2007;5(2):75-92.
2. Green-Church K, Butovich I, Wilcox M, et al. The international workshop on meibomian gland dysfunction: report of the subcommittee on tear film lipids and lipid-protein interactions in health and disease. *Invest Ophthalmol Vis Sci.* 2011;52(4):1979-93.
3. Sridhar M. Anatomy of cornea and ocular surface. *Indian J Ophthalmol.* 2018;66(2):190-4.
4. Gulati S, Jain S. Ocular pharmacology of tear film, dry eye and allergic conjunctivitis. *Handb Exp Pharmacol.* 2017;242:97-118.
5. Bentivoglio A, Bressman S, Cassetta E, et al. Analysis of blink rate patterns in normal subjects. *Mov Disord.* 1997;12(6):1028-34.
6. Schaumberg D, Sullivan D, Buring J, Dana M. Prevalence of dry eye syndrome among US women. *Am J Ophthalmol.* 2003;136(2):318-26.
7. Korb D, Greiner J, Herman J, et al. Lid-wiper epitheliopathy and dry-eye symptoms in contact lens wearers. *CLAO J.* 2002;28(4):211-6.
8. Li W, Yeh T, Leung T, et al. The relationship of lid wiper epitheliopathy to ocular surface signs and symptoms. 2018;59(5):1878-87.
9. Efron N, Brennan N, Morgan P, Wilson T. Lid wiper epitheliopathy. *Prog Retin Eye Res.* 2016;53(7):140-74.
10. Jester J, Parfitt G, Brown D, et al. Meibomian gland dysfunction: hyperkeratinization or atrophy? *BMC Ophthalmol.* 2015;15 Suppl 1:156.
11. Korb D, Blackie C. Marx's line of the upper lid is visible in upgaze without lid eversion. *Eye Contact Lens.* 2010;36(3):149-51.
12. Ngo W, Srinivasan S, Schulze M, Jones L, et al. Repeatability of grading meibomian gland dropout using two infrared systems. *Optom Vis Sci.* 2014;91(6):658-67.
13. Zarei-Ghanavati S, Heravian Shandiz J, Abrishami M, Karimpour M. Comparison of mechanical debridement and trans-epithelial myopic photorefractive keratotomy: A contra-

14. lateral eye study. 2019;31(2):135-41.
14. Korb DR, Blackie CA. Debridement-scaling: A new procedure that increases meibomian gland function and reduces dry eye symptoms. *Cornea.* 2013;32(12):1554-7.
15. Jarmuda S, O'Reilly N, Zaba R, et al. Potential role of *Demodex* mites and bacteria in the induction of rosacea. *J Med Microbiol.* 2012;61:1504-10.
16. Fromstein S, Harthan J, Patel J, Opitz D. *Demodex* blepharitis: clinical perspectives. *Clin Optom (Auckl).* 2018;10:57-63.
17. Hom M, Mastrotta K, Schachter S. *Demodex*. *Optom Vis Sci.* 2013;90(7):e198-205.
18. Halleran C, O'Dell L, Harthan J et al. An evaluation of the presence of *Demodex* and its influence on meibomian gland structure. *Invest Ophthalmol Vis Sci.* 2017;58:ARVO.
19. Rather P, Hassan I. Human *Demodex* Mite: The Versatile Mite of Dermatological Importance. *Indian J Dermatol.* 2014;59(1):60-6.
20. O'Dell L, Periman L, Sullivan A, et al. An evaluation of cosmetic wear habits correlated to ocular surface disease symptoms. *Invest Ophthalmol Vis Sci.* 2017;58:ARVO E-Abstract:495-A0420.
21. Baudouin C, Messner E, Aragona P, et al. Revisiting the vicious circle of dry eye disease: a focus on the pathophysiology of meibomian gland dysfunction. *Br J Ophthalmol.* 2016;100(3):300-6.
22. What is meibomian gland dysfunction? WebMD. [www.webmd.com/eye-health/meibomian-gland-dysfunction#2-6](http://www.webmd.com/eye-health/meibomian-gland-dysfunction#2-6). Accessed October 1, 2019.
23. Kosik-Bogacka D, Lanocha N, Lanocha A, et al. Role of *Demodex folliculorum* in the pathogenesis of blepharitis. *Acta Ophthalmol.* 2012;90(7):e579.
24. Murillo N, Aubert J, Raoult D. Microbiota of *Demodex* mites from rosacea patients and controls. *Microb Pathog.* 2014;71-72:37-40.
25. Villani E, Mantelli F, Nucci P. *In-vivo* confocal microscopy of the ocular surface: ocular allergy and dry eye. *Curr Opin Allergy Clin Immunol.* 2013;13(5):569-76.
26. Leonardi A, Motterle L, Bortolotti M. Allergy and the eye. *Clin Exp Immunol.* 2008;153(Suppl 1):17-21.
27. Kabat A, Sowka J. If it itches, it's allergy...right? *Rev Optom.* 2011;147(6):107-8.
28. Villani E, Strologo M, Pichi F, et al. Dry eye in vernal keratoconjunctivitis: A cross-sectional comparative study. *Medicine (Baltimore).* 2015;94(42):e1648.
29. Chen L, Pi L, Fang J, et al. High incidence of dry eye in young children with allergic conjunctivitis in Southwest China. *Acta Ophthalmol.* 2016;94(8):e727-30.
30. Akil H, Celik F, Ulas F, Kara IS. Dry eye syndrome and allergic conjunctivitis in the pediatric population. *Middle East Afr J Ophthalmol.* 2015;22(4):467-71.
31. Kim T, Moon N. Clinical correlations of dry eye syndrome and allergic conjunctivitis in Korean children. *J Pediatr Ophthalmol Strabismus.* 2013;50(2):124-7.
32. Mizoguchi S, Iwanishi H, Arita R, et al. Ocular surface inflammation impairs structure and function of meibomian gland. *Exp Eye Res.* 2017;163:78-84.
33. Wolffsohn J, Arita R, Chalmers R, et al. TFOS DEWS II Diagnostic Methodology report. *Ocul Surf.* 2017;15(3):539-74.
34. Leonardi A, Brun P, Abatangelo G, et al. Tear levels and activity of matrix metalloproteinase (MMP)-1 and MMP-9 in vernal keratoconjunctivitis. *Invest Ophthalmol Vis Sci.* 2003;44(7):3052-8.
35. Kumagai N, Yamamoto K, Fukuda K, et al. Active matrix metalloproteinases in the tear fluid of individuals with vernal keratoconjunctivitis. *J Allergy Clin Immunol.* 2002;110(3):489-91.
36. Villani E, Rabbio G, Nucci P. Ocular allergy as a risk factor for dry eye in adults and children. *Curr Opin Allergy Clin Immunol.* 2018;18(5):398-403.
37. McMonnies C. The potential role of neuropathic mechanisms in dry eye syndromes. *J Optom.* 2017;10(1):5-13.
38. Messmer E, Bulgen M, Kampik A. Hyperosmolality of the tear film in dry eye syndrome. *Dev Ophthalmol.* 2010;45:129-138.
39. Halleran C, Kwan J, Hom M, Harthan J. Agreement in reading centre grading of meibomian gland tortuosity and tortuosity. Poster presented at the American Academy of Optometry. November 2016;Anaheim CA.
40. Harthan J, Hom M, O'Dell L, Halleran C. Impact of humidity levels, temperature, breathing and heat indices on dry eye symptom scores. Poster presented at the American Academy of Optometry. October 2017;Chicago, IL.
41. Halleran C, Kwan J, Hipolito K, Harthan J, Hom MM. The role of pollen counts on the Signs and symptoms of ocular surface disease. Poster presented at the American Academy of Optometry. October 2017;Chicago, IL.
42. Schachter A, Schachter S, Kwan J, et al. Impact of digital device use on dry eye symptoms. Poster presented at the American Academy of Optometry. November 2016;Anaheim CA.



Passionate about glaucoma care?



## FROM CORNEAL HYSTERESIS TO IOP, SO ARE WE.

Only **Ocular Response Analyzer® G3** measures **Corneal Hysteresis** and **Corneal Compensated IOP (IOPcc)** using patented technology to assess the unique corneal biomechanical properties of your patient. Corneal Hysteresis has shown to be an independent risk factor and more predictive of glaucoma development and progression than CCT or IOP<sup>1-3</sup>. Using biomechanics, IOPcc is less influenced by corneal properties than Goldmann applanation tonometry<sup>4</sup>.

Only **Tono-Pen AVIA®** continues to advance handheld tonometry with the all-new **Quick-Tap™** measurement mode. The same ready-to-use, calibration-free, and accurate operation, now with more confidence in fewer measurements. Trusted by clinicians for over 30 years. We share your passion for improving glaucoma care.

VISIT US AT [REICHERT.COM/GLAUCOMACARE](https://www.reichert.com/glaucomacare)



**AMETEK®** © 2019 AMETEK, Inc. & Reichert, Inc. (10-2019) - Ocular Response Analyzer and Tono-Pen are registered trademarks of Reichert, Inc. - Designed & assembled in USA

References: 1. Medeiros FA, Meira-Freitas D, Lisboa R, Kuang TM, Zangwill LM, Weinreb RN. Corneal hysteresis as a risk factor for glaucoma progression: a prospective longitudinal study. *Ophthalmology*. 2013 Aug;120(8):1533-40. 2. De Moraes CV, Hill V, Tello C, Liebmann JM, Ritch R. Lower corneal hysteresis is associated with more rapid glaucomatous visual field progression. *J Glaucoma*. 2012 Apr-May;21(4):209-13. 3. Susanna CN, Diniz-Filho A, Daga FB, Susanna BN, Zhu F, Ogata NG, Medeiros FA. Am J Ophthalmol. A Prospective Longitudinal Study to Investigate Corneal Hysteresis as a Risk Factor for Predicting Development of Glaucoma. 2018 Mar;187:148-152. doi: 10.1016/j.ajo.2017.12.018. 4. Felipe A, Medeiros, MD and Robert N. Weinreb, MD. Evaluation of the Influence of Corneal Biomechanical Properties on Intraocular Pressure Measurements Using the Ocular Response Analyzer. *J Glaucoma* 2006;15:364-370.

# Lashing Out: Dangerous Beauty Trends

If patients aren't mindful of the steps they are taking to modify their ocular appearance, they may end up doing more harm than good.

By Tracy Doll, OD

The eyes are one of the biggest markers of facial attractiveness, and everyone has taken notice. The beauty industry is more than happy to aid consumers in enhancing their eyes.<sup>1,2</sup> Salon and at-home eyelash augmentation procedures are projected to continue expanding and growing in popularity in the market, and false eyelashes alone are expected to bring in almost two billion dollars by the end of 2024.<sup>3,4</sup>

The quest for longer, thicker and darker eyelashes and eyes that appear larger, however, does not come without risk. This is a risk many patients don't mind taking, as they are often unwilling to give up their beauty regimen. In a study of 1,292 women, 44% of participants reported experiencing negative feelings when they weren't able to wear make-up.<sup>5</sup> Even knowing the risks might not be enough for patients to discontinue eye-enhancing procedures. Educating patients about healthier practices and alternatives could be the next best option.

## False Eyelashes

These are categorized as strip lashes, individual flare lashes and single individual lashes, and are made from real hair or synthetic material. These lashes are applied



Fig. 1. Magnetic lashes with added mascara.

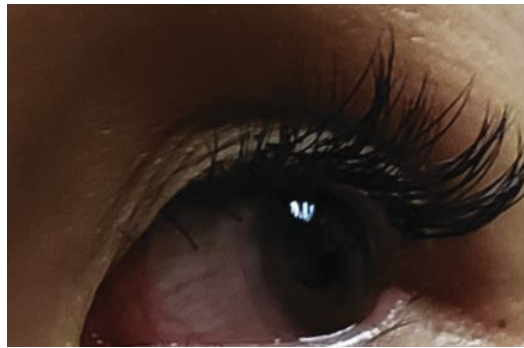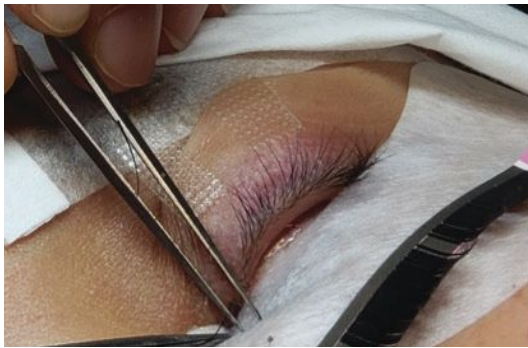at the lid margin above the existing lashes with glue, which often contains harsh ingredients with allergenic properties, including formaldehyde and latex. False lashes are associated with allergic contact dermatitis, blepharoconjunctivitis and abrasions secondary to application, removal and lash-fall.<sup>6</sup>

A newer false eyelash alternative created to avoid glues is the magnetic false eyelash (*Figure 1*). These lashes can be applied in two ways—either small magnets sandwich a patient's real lashes between a set of

upper and lower false lashes or the magnetic false lashes attach above the lash line to a thick line of metallic-based eyeliner. Risks include application abrasion, lash-fall due to the weight of the magnets and metal allergies in the case of the eyeliner version.

If patients choose to use false eyelashes, recommend that they use glues that do not contain formaldehyde, choose lashes of a natural length—1/3 the eye width to facilitate the best ocular health by maintaining proper aerodynamic flow and avoiding funneling air and debris into the ocular surface—and use partial strips instead of ones that extend the full lash line to avoid using more material than necessary.<sup>7</sup> Patients should take breaks in false lash wear or reserve them for special occasions.





**Fig. 2.** During (left) and after (right) an eyelash extension procedure. Note this patient's ocular irritation post-application.

Placing a small amount of glue or metallic eyeliner on the inside of the wrist for a “patch test” could alert patients to potential allergies before contact dermatitis occurs on their eyelid.

Lash and lid procedures were created to enhance and rarely replace make-up. Mascara is often used in conjunction with false eyelashes to help “blend” them with the real ones. The addition of ocular cosmetics further increases the risk of irritation, allergic reaction and infection. Eye cosmetics themselves can contain allergenic and toxic additives.<sup>8-21</sup> The non-profit Environmental Working Group has a free online database that rates more than 70,000 cosmetics and ingredients in terms of safety for doctors and patients alike to learn more about different products.<sup>22</sup>

### Eyelash Extensions

This approach differs from false eyelashes in their application. Extensions are applied by gluing a single hair or synthetic lash to an existing anatomic eyelash (*Figure 2*). This is a long process and takes a trained esthetician between one and three hours to apply 50 to 200 lash extensions individually with forceps. The glues involved with application contain the same allergenic ingredients as false lashes, sometimes in even stronger concentrations.<sup>23,24</sup> Post-application ocular irritation is common.

Most professional estheticians recommend re-doing or “filling” extensions every two to four weeks to replace lashes that have fallen as part of the natural lifecycle of an eyelash—four to 11 months depending on ocular health—and achieve the best look.<sup>24</sup> In order to “fill” extensions, old extensions must first be removed. Removal is often achieved by using ocular-irritating glue solvents combined with fragrances. Even in the best case scenario, some

of the remover will make its way to the ocular surface, as it would with traditional eye makeup remover.<sup>25</sup> A closed eye is not an air- or water-tight seal. Hygiene may become an issue, as these lashes are meant to be worn for weeks at a time. Extensions have the same potential complications as false eyelashes, with added infective risks of chalazia/hordeola and blepharitis.<sup>6</sup>

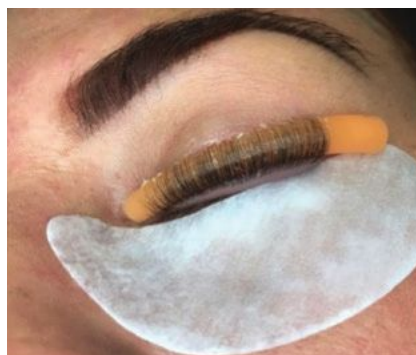Safer practices for eyelash extensions include using glues that do not contain formaldehyde and removers that are oil-based. Patients need to practice lid hygiene and understand that extensions are not like jeans that you don't wash in an effort to protect the look. Over-the-counter (OTC) hypochlorous acid is a cleaning option that will not dissolve the glues. More natural lash lengths are also preferable.

Should you encounter a patient with “extensions gone wrong,” you can remove the extensions quite easily in-office. Start by clearing the lid margins of excess infective debris with an oil-based tea-tree lid cleanser. Next, generously apply a non-irritating oil, such as argan, jojoba, fractionated coconut and macadamia nut, to the lid margin. Have the patient close their eyes for five minutes under a heated micro-bead eye mask. The combination of heat and oil will loosen the glue bonds. You can then use a little mechanical action and jeweler's forceps to remove the extensions.

If you aren't able to remove the extensions with these materials, you can obtain online the same lash solvents used by salons. Exercise proper infection and inflammation control with topical steroids and antibiotics as needed and amniotic membranes for corneal involvement.

### Eyelash Perming

Sometimes known as a “lash-lift,” lash perming is a trend that may



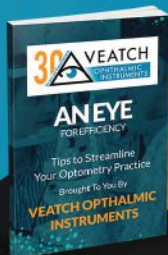
**Fig. 3.** Eyelash perming procedure.



## Veatch Digital Refraction

*The future is NOW,  
the ophthalmic industry  
is going digital & for good reason.*

- Greater Efficiency & Accuracy
- Large Return on Investment
- Increased Capability
- Wireless Connectivity
- Full Integration



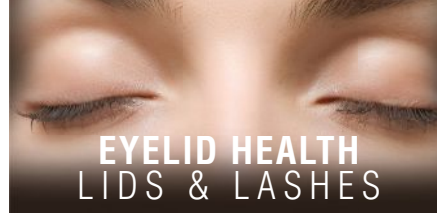**Download FREE**

Whitepaper: An Eye for Efficiency  
[www.voi2020.com/eye](http://www.voi2020.com/eye)

### Contact Us Today

Veatch Ophthalmic Instruments

[www.VOI2020.com](http://www.VOI2020.com) | 800.447.7511



be a bit harder to detect, as there are no false lash materials involved (*Figure 3*). The only way to know if a patient has undergone a lash-lift is via their case history. The goal with a lash-lift is for the natural eyelashes to curl up and outward.

During this procedure, the eyelashes are wrapped around a metallic or plastic rod that either is coated in adhesive or comes with an adhesive for the patient/ esthetician to paint on the rod. Some kits use plastic “clips” to keep the lashes in place. Then, perming and neutralizer solutions containing highly ocular toxic active ingredients—hydrogen peroxide and thioglycolic acid—and other irritating additives are applied (*Table 1*).<sup>22</sup> The entire process takes 10 to 15 minutes.

Patients should avoid lash lifting due to the potential risks. However, if a patient is adamant about attempting a lash-lift, only a highly trained professional esthetician should perform this procedure to mitigate the amount of perming and neutralizing solutions on the ocular surface.

The main risk involved in lash lifting is toxic keratoconjunctivitis, and allergic reactions to perming solutions and adhesives are known to occur.<sup>22</sup> Patients should see their eye doctor immediately if significant irritation ensues. As water deactivates perming solutions, the patient will likely have been told not to get their lashes wet for 24 hours.<sup>26,27</sup> If a patient presents with a reaction within 24 hours, you can flush the ocular surface and lashes. Unfortunately, after that time, these allergens will stick around for the natural lifecycle of an eyelash.<sup>24</sup> Patients who experience a “lash-lift gone wrong” will likely need to be treated similarly to patients with basic, mild chemical burns with topical steroids, antibiotics and amniotic membranes.

### Eyelash Tinting

In this cosmetic procedure, permanent dyes are applied to darken the eyelashes. Similar to lash perming, the lashes are wrapped around a sticky plastic or metal rod and permanent dye is applied and allowed to set. Ocular toxic and allergenic ingredients commonly found in lash tinting products include hydrogen peroxide, dyes and fragrances. The main risk associated with the procedure is an allergic reaction.<sup>28</sup> Again, these allergens will persist for the natural lifecycle of an eyelash.<sup>24</sup>

Stripping the dye out comes with the risk of permanent damage to the follicle. The best option here is anti-inflammatory control with topical steroids until the lash lifecycle has turned over. Like lash lifting, lash tinting should be avoided, but if a patient is adamant about proceeding, only a highly trained esthetician

**Table 1. Allergic and Toxic Ingredients in Cosmetic Procedures<sup>22,40-42</sup>**

Cosmetic Procedure	Ingredients Causing Allergy or Ocular Surface Toxicity
False Eyelash and Eyelash Extension Glues	Preservatives: formaldehyde Opacifying agent/film-formers: latex Fragrances: phenoxyethanol, fragrance* Pigments: iron oxides
False Eyelash Metallic Eyeliners	Pigments: iron oxides
Eyelash Extension Removers	Solvents: 4-methyl-1, 3-dioxolan-2-one, 2-methoxyethanol, propylene carbonate, ethyl acetate Fragrances: phenoxyethanol, fragrance*
Eyelash Perming Solutions	Agents: hydrogen peroxide, thioglycolic acid, sodium bromate Fragrances: limonene, fragrance* Preservatives/solvents: benzyl benzoate, benzyl alcohol, methylparabens
Eyelash Tinting Dyes	Agents: hydrogen peroxide, p-phenylenediamine, m-aminophenol, resorcinol Fragrances: phenoxyethanol, lilyal (butylphenyl methylpropional), fragrance*
Eyelash Serums	Synthetic prostaglandins: ethylcloprostenolomide, methylamido dihydro noralaprostal, 17-phenyl trinor, prostaglandin E serinol amide Preservatives: formaldehyde derivatives, methylparabens Fragrances: fragrance*
Tattooed Eyeliner Inks	Black pigments: iron oxide, carbon nanoparticles, aluminum silicate White pigments: lead carbonate, titanium dioxide, barium sulfate

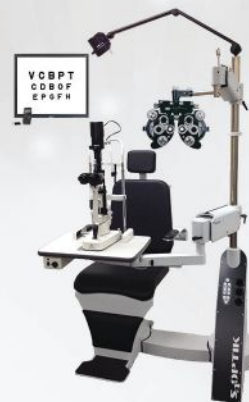\*Fragrances are considered proprietary, so exact ingredients and their risks do not need to be listed and, therefore, are unknown.

who is willing to “patch test” prior to the tint should perform the procedure. Lash tinting is often combined with lash lifting, so the risks are twofold, and extra caution should be taken.

While eyelash extensions, perming and tinting are all highly recommended to be done by a licensed esthetician, all the products necessary for patients to self-administer are available online and don’t require a medical or esthetician license. With these lash procedures costing hundreds of dollars, the number of home attempts is high, as is the risk for mistakes.

### Eyelash Serums

When Latisse (bimatoprost 0.03%, Allergan) was first approved by the FDA in 2008, it changed the pharmaceutical and cosmetic industries.<sup>29</sup> The crucial side effect of darker and thicker eyelashes when this prostaglandin analog was used for glaucoma did not go unnoticed. Daily application along the lash line targets the anagen phase of the eyelash growth cycle, causing longer, thicker and more melanin deposition in the eyelash. This prostaglandin analog may also increase

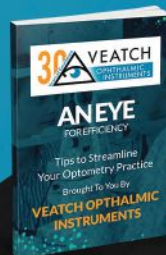


## Exam Lane Packages

Opening a new practice?  
Looking to upgrade your equipment?  
Veatch exam lanes are an investment in your patients, your equipment & your business.

## Bundled Packages: Save Time & Money

- Visual acuity system
- Manual or Digital Refractor
- Exam chair & stand

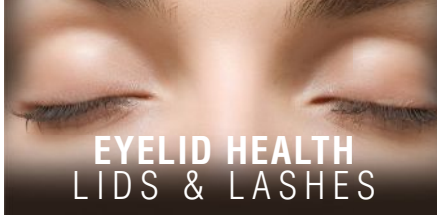

**Download FREE**  
Whitepaper: An Eye for Efficiency  
[www.vei2020.com/eye](http://www.vei2020.com/eye)

### Contact Us Today

Veatch Ophthalmic Instruments  
[www.VOI2020.com](http://www.VOI2020.com) | 800.447.7511





the number of eyelashes in the follicle, cause skin and iris pigmentation, conjunctival hyperemia, pruritus (itching) and lash-loss and lower intraocular pressure.<sup>29</sup>

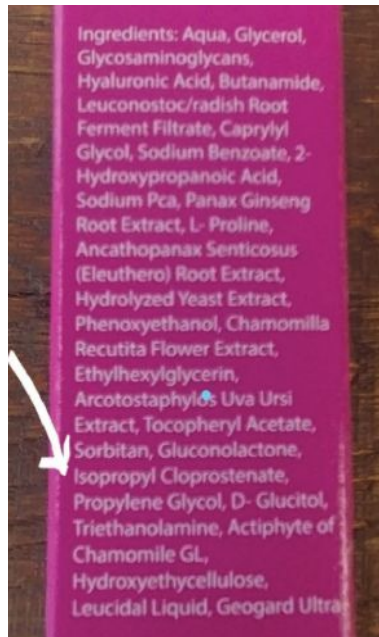OTC eyelash serums have risen in popularity in the beauty industry to compete with Latisse. These OTC options can contain synthetic prostaglandins with identical side effects to the pharmaceutical option. Unlike pharma companies, cosmetic companies are not required to list these potential side effects in their packaging. Synthetic prostaglandins can be difficult to spot unless you are familiar with their common names. The key is to look for “prost” as an indicator of a potential synthetic prostaglandin ingredient (Figure 4). Some OTC lash serums that do not contain synthetic prostaglandins include polypeptide and lipopeptide formulations of amino acids that support eyelash growth.<sup>30,31</sup>

Even the lipopeptide and polypeptide versions do not necessarily come without risk and may contain other irritating ingredients, so it is important to read the ingredient list.

The healthiest practice for using eyelash serums is to advise patients to choose options that do not include prostaglandins. Any patient using a prostaglandin lash serum should be followed regularly to monitor ocular health. Patients with chronic ocular inflammatory conditions, including dry eye disease, should avoid prostaglandin lash serums.

### Tattooed Eyeliner

Often referred to as “permanent makeup,” this is a misnomer, as tattooed eyeliner does not last forever. Most tattoos require touch-ups over time as the ink fades. Black eyeliner fades to a bluish tinge, making it easy to



**Fig. 4. One of the most common synthetic prostaglandins is isopropyl cloprostenate.**

detect, and the ink does not always stay contained in the target location, leading to pigment spreading (Figure 5).

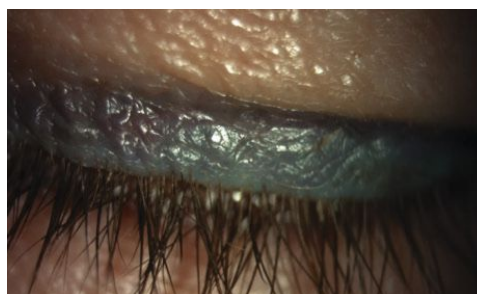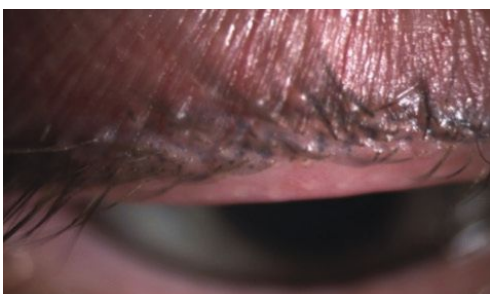The ink used in tattooing is not regulated or necessarily consistent between professional tattoo artists. Black, white and colored inks contain metallic ingredients, which can be allergy-inducing. In addition, tattooing can cause bruising, swelling, infections, scarring, granuloma formation, photo-toxicity and lamellar keratitis.<sup>8,9,32-39</sup>

A study examining the association between tattoos and meibomian gland dysfunction (MGD) found that tattooed patients demonstrated reduced tear break-up time, loss of meibomian gland architecture and increased corneal staining.<sup>32</sup> The impact of the concussive damage and chemical toxicity is also theorized to be contributory to MGD. Permanent makeup on the

eyelid should be avoided, as this is not a procedure that can be reversed.

As eye care practitioners, we are well poised to recognize the complications stemming from dangerous beauty trends involving the ocular surface and adnexa. With the cosmetic industry doing everything it can to promote the growth of eyelash and lid enhancement, we need to educate patients about healthier practices and alternatives to strike a better balance between health and beauty. ■

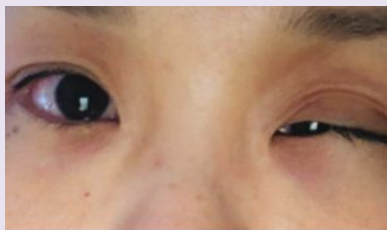*Dr. Doll is an assistant professor of optometry and the coordinator at Pacific Dry Eye Solutions, a dry eye center of excellence within the Pacific University College of Optometry. She coordinates clinical and didactic ocular surface dryness education, including a course devoted to advanced ocular surface dryness disease clinical techniques, and lectures nationally on ocular surface dryness.*



**Fig. 5. Pigment fade (left) and spread (right), with the tattooed eyeliner extending upward further than the thin line originally applied, of permanent makeup. Both patients have dry eye with MGD.**

## Case Example: The DIY Lift

A 35-year-old Asian female presented with the chief concern of a bilateral eye infection secondary to use of an expired lash perming kit four days prior. She reported bilateral dull-to-sharp eye pain, photophobia, eye and lid redness and mucus discharge that glues her left eye shut overnight. She visited her primary care provider two days ago and was prescribed a topical sulfa-based antibiotic. The antibiotics and artificial tears she was

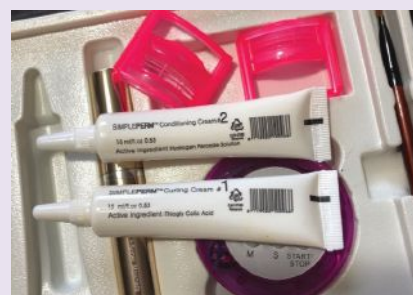

**This patient presented with discharge gluing half her eye shut.**

using every hour did not reduce her symptoms. External examination demonstrated scaly, 2+ edema and erythema of the lid margins. Once the mucus was loosened and removed with an oil-based tea-tree lid scrub, a 3+ diffuse keratitis and accompanying conjunctivitis was evident. The patient had brought her lash perming kit along for inspection. The kit included two tubes—one was a curling cream containing thioglycolic acid, and the other was a conditioning cream containing hydrogen peroxide—both of which had expired eight months prior to the patient's purchase and use. She confirmed that while attempting to perm her own eyelashes, she had gotten the contents of both tubes in her eyes.

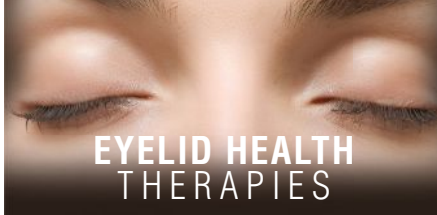The active ingredients in the lash perming kit were still active, leading to a bilateral toxic keratoconjunctivitis and allergic contact dermatitis. The patient was immediately placed on topical steroids (pred acetate 1%) TID and instructed to use gentle lid scrubs with hypochlorous acid. She declined a cryopreserved amniotic membrane and was told to avoid all eye cosmetics for the next three days until she could be seen for a follow-up.

Within one week, the patient's corneal staining decreased and her eyelid edema resolved. She still had some mild scaling of the eyelid skin. She began a steroid taper and was urged to continue daily hypochlorous acid lid scrubs and stay makeup-free for the next week. We discussed non-prostaglandin eyelash serums to condition her natural lashes as an alternative to lash perming.



**Lash perm kit ingredients.**

- Mulhern R, Fieldman G, Hussey T, et al. Do cosmetics enhance female Caucasian facial attractiveness? *Int J Cosmet Sci.* 2003;25(4):199-205.
- McCurdy JA Jr. Beautiful eyes: characteristics and application to aesthetic surgery. *Facial Plast Surg.* 2006;22(3):204-14.
- Crawford SK. ABC News. How false eyelashes have become a must-have, everyday accessory and a booming market. [abcnews.go.com/Lifestyle/false-eyelashes-everyday-accessory-booming-market/story?id=55019597](http://abcnews.go.com/Lifestyle/false-eyelashes-everyday-accessory-booming-market/story?id=55019597). May 8, 2018. Accessed September 17, 2019.
- Market Research Future. False eyelashes market research report-global forecast till 2024. [www.marketresearchfuture.com/reports/false-eyelashes-market-2921](http://www.marketresearchfuture.com/reports/false-eyelashes-market-2921). July 2019. Accessed September 17, 2019.
- Cision PR Newswire. New survey results indicate there's more to makeup use than meets the eye. [www.prnswire.com/news-releases/new-survey-results-indicate-theres-more-to-makeup-use-than-meets-the-eye-140012233.html](http://www.prnswire.com/news-releases/new-survey-results-indicate-theres-more-to-makeup-use-than-meets-the-eye-140012233.html). February 22, 2012. Accessed September 17, 2019.
- Amano Y, Sugimoto Y, Sugita M. Ocular disorders due to eyelash extensions. *Cornea.* 2012;31(2):121-5.
- Amador GJ, Mao W, DeMercurio P, et al. Eyelashes divert airflow to protect the eye. *J R Soc Interface.* 2015;12(105):20141294.
- Adams RM, Maibach HI. A five-year study of cosmetic reactions. *J Am Acad Dermatol.* 1985;13(6):1062-9.
- Meynadier JM, Meynadier J, Mark Y. True cosmetic-induced dermatitis. In: Baran R, Maibach HI, 1st ed. *Textbook of Cosmetic Dermatology*. London, UK, Martin Dunitz, 1994:551-6.
- Dawson NL, Reinhardt DJ. Microbial flora of in-use, display eye shadow testers and bacterial challenges of unused eye shadows. *Appl Environ Microbiol.* 1981;42(2):297-302.
- Pack LD, Wickham MG, Enloe RA, et al. Microbial contamination associated with mascara use. *Optometry.* 2008;79(10):587-93.
- Wilson LA, Julian AJ, Ahearn DG. The survival and growth of microorganisms in mascara during use. *Am J Ophthalmol.* 1975;79(4):596-601.
- Lundov MD, Moesby L, Zachariae C, et al. Contamination versus preservation of cosmetics: a review on legislation, usage, infections, and contact allergy. *Contact Dermatitis.* 2009;60(2):70-8.
- Steinberg DC. 2010 frequency of preservative use. *Cosmetics & Toiletries.* 2010;125:46-51.
- De Groot AC, Flytholm MA, Lensen G, et al. Formaldehyde-releasers: relationship to formaldehyde contact allergy. Contact allergy to formaldehyde and inventory of formaldehyde-releasers. *Contact Dermatitis.* 2009;61(2):63-85.
- Draelos ZD. Special considerations in eye cosmetics. *Clin Dermatol.* 2001;19(4):424-30.
- Orecchini AM. Eye make-up. In: Baran R, Maibach HI, eds. *Cosmetic Dermatology*. London, UK, Martin Dunitz, 1994:143-9.
- Hunter M, Bhola R, Yappert MC, et al. Pilot study of the influence of eyeliner cosmetics on the molecular structure of human meibum. *Ophthalmic Res.* 2015;53(3):131-5.
- Lodén M, Wessman C. Mascaras may cause irritant contact dermatitis. *Int J Cosmet Sci.* 2002;24(5):281-5.
- Draelos ZD. Eyelash cosmetics. In: *Cosmetics in Dermatology*. New York, NY, Churchill Livingstone, 1995:41-52.
- O'Donoghue MN. Eye cosmetics. *Dermatol Clin.* 2000;18:633-9.
- EWG's Skin Deep Cosmetics Database. [www.ewg.org/skindeep](http://www.ewg.org/skindeep). September 17, 2019.
- Winks Eyelash Boutique. The truth about unlimited lash sets. [winksboutique.com/how-many-lashes-are-in-a-full-set-of-extensions](http://winksboutique.com/how-many-lashes-are-in-a-full-set-of-extensions). February 19, 2018. Accessed September 17, 2019.
- Aumond S, Bitton E. The eyelash follicle features and anomalies: a review. *J Optom.* 2018;11(4):211-22.
- Debbasch C, Ebenhahn C, Dami N, et al. Eye irritation of low-irritant cosmetic formulations: correlation of in vitro results with clinical data and product composition. *Food Chem Toxicol.* 2005;43(1):155-65.
- Rodulfo K. Elle. Everything you need to know about lash lifts (and why they're better than lash extensions). [www.elle.com/beauty/makeup-skin-care/a19409536/what-is-lash-lift](http://www.elle.com/beauty/makeup-skin-care/a19409536/what-is-lash-lift). March 13, 2018. Accessed September 17, 2019.
- Mychaskiw M. This treatment gives you mega lashes without extensions. InStyle. [www.instyle.com/beauty/lash-lift-treatment-curling-eyelashes](http://www.instyle.com/beauty/lash-lift-treatment-curling-eyelashes). October 6, 2017. Accessed September 17, 2019.
- Vogel TA, Coenraads PJ, Schuttelaar, MLA. Allergic contact dermatitis presenting as severe and persistent blepharokeratoconjunctivitis and centropalpebral oedema after dyeing of eyelashes. *Contact Dermatitis.* 2014;71(5):304-6.
- Allergan. Latisse (bimatoprost ophthalmic solution) 0.03% package insert. [www.allergan.com/assets/pdf/latisse\\_pi.pdf](http://www.allergan.com/assets/pdf/latisse_pi.pdf). July 2017. Accessed September 17, 2019.
- Pyo HK, Yoo HG, Won CH, et al. The effect of tripeptide-copper complex on human hair growth in vitro. *Arch Pharm Res.* 2007;30(7):834-9.
- Iwabuchi T, Takeda S, Yamanishi H, et al. The topical penta-peptide Gly-Pro-Ile-Gly-Ser increases the proportion of thick hair in Japanese men with androgenetic alopecia. *J Cosmet Dermatol.* 2016;15(2):176-84.
- Lee YB, Kim JY, Hyon JY, et al. Eyelid tattooing induces meibomian gland loss and tear film instability. *Cornea.* 2015;34(7):750-5.
- Bee CR, Steele EA, White KP, et al. Tattoo granuloma of the eyelid mimicking carcinoma. *Ophthalmic Plast Reconstr Surg.* 2014;30(1):e15-7.
- Peters NT, Conn H, Côté MA. Extensive lower eyelid pigment spread after blepharopigmentation. *Ophthalmic Plast Reconstr Surg.* 1999;15(6):445-7.
- Hurwitz JJ, Brownstein S, Mishkin SK. Histopathological findings in blepharopigmentation (eyelid tattoo). *Can J Ophthalmol.* 1988;23(6):267-9.
- Goldman A, Wollina U. Severe unexpected adverse effects after permanent eye makeup and their management by Q-switched Nd:YAG laser. *Clin Interv Aging.* 2014;9:1305-9.
- ThoughtCo. Helmenstine AM. Tattoo ink chemistry. [www.thoughtco.com/tattoo-ink-chemistry-606170](http://www.thoughtco.com/tattoo-ink-chemistry-606170). September 13, 2019. Accessed September 17, 2019.
- Lu CW, Liu XF, Zhou DD, et al. Bilateral diffuse lamellar keratitis triggered by permanent eyeliner tattoo treatment: a case report. *Exp Ther Med.* 2017;14(1):283-5.
- Schwarze HP, Giordano-Labadie F, Loche F, et al. Delayed-hypersensitivity granulomatous reaction induced by blepharopigmentation with aluminum-silicate. *J Am Acad Dermatol.* 2000;42(5 Pt 2):888-91.
- Hazard. 2-Methoxyethanol. [hazard.com/msds/mf/baker/baker/files/m2327.htm](http://hazard.com/msds/mf/baker/baker/files/m2327.htm). Accessed September 17, 2019.
- PubChem. (S)-4-Methyl-1,3-dioxolan-2-one. [pubchem.ncbi.nlm.nih.gov/compound/S\\_-4-Methyl-1\\_3-dioxolan-2-one](http://pubchem.ncbi.nlm.nih.gov/compound/S_-4-Methyl-1_3-dioxolan-2-one). Accessed September 17, 2019.
- Toxnet. Hazardous substance data bank (HSDB). [toxnet.nlm.nih.gov/newtoxnet/hsdb.htm](http://toxnet.nlm.nih.gov/newtoxnet/hsdb.htm). Accessed September 17, 2019.



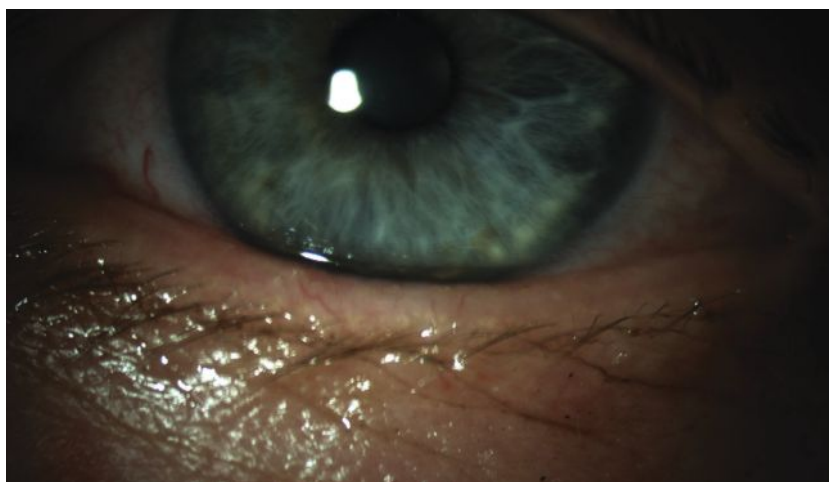
# In-Office and At-Home Lid Maintenance

Keeping dry eye at bay can require patients and ODs to adopt a new hygiene regimen. Here are some options. **By Whitney Hauser, OD**

**D**ry eye disease (DED) can be frustrating for both the patient, living with pain, and the optometrist, who has to dig for the precise pathogenesis of their patient's symptoms to best target treatment. That diagnostic process can be costly and time-consuming. Every day the patient spends with burning dry eyes is a day they consider seeing a different optometrist. That's why it's vital to have an armamentarium replete with the most up-to-date technologies and techniques to deliver the relief your patients are seeking.

Luckily, optometrists—with a dose of patient cooperation—can handle most of these cases thanks to their clinical acumen as well as several innovative in-office procedures and at-home therapies that patients can be taught to apply. These therapies can be particularly accessible when DED is connected to an underlying disease.

The process begins with a clinical evaluation of the patient to help identify the precise lid disease causing their dryness. Second, the



**Telangiectasias can be evidence of inflammation at the lid margin.**

doctor must decide on a treatment protocol to address that underlying issue. Finally, the doctor should educate the patient on an effective management plan that makes use of the technologies and products available to them.

This article provides a guide through those three steps with a focus on lid disease treatment options that the OD can provide in-office, or that a patient can bring home to manage their own condition with optometric oversight.

## Identification

Any suspicion of lid disease is a good reason to evaluate the patient at the slit lamp. Note the apposition of the eyelid to the globe, presence or absence of lid debris and telangiectasias. Additionally, expressing the meibomian glands demonstrates the quality and quantity of the meibum being secreted.

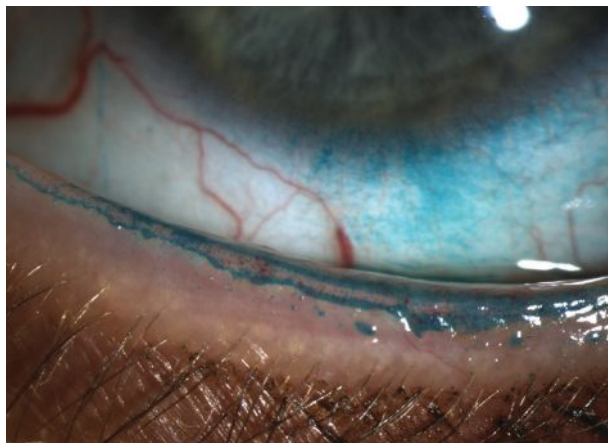
Eyelid laxity can occur due to aging, eye rubbing, hyperelasticity, inflammation or blepharochalasis.<sup>1</sup> Patients may experience symptoms



such as foreign body sensation, photophobia or irritation. Poor lid apposition may cause lagophthalmos with resultant inferior corneal superficial punctate keratitis. Additionally, an increase in lid laxity can negatively affect blink performance, which is critical for providing and distributing meibum into the tear film. Laxity can easily be evaluated by the “snap” test. In this examination technique, the patient’s lid is lowered and quickly released under the slit lamp. The speed of recovery, or rebound, is noted and subjectively compared with normal.<sup>2</sup>

Also, be sure to note any lid debris residing at or near the lash margin. Blepharitis, demodicosis and hyperkeratinization are common findings and contributors to dry eye complaints. Research reports that more than 40% of patients in a primary eye care setting have blepharitis.<sup>3</sup> Additionally, more than 35% of chronic blepharitis is associated with keratoconjunctivitis sicca (KCS) and meibomian gland dysfunction (MGD).<sup>4</sup> Direct bacterial infection, often led by *Staphylococcus epidermidis*, results in an increase in exotoxins and subsequent release of proinflammatory cytokines into the tear film.<sup>5</sup>

*Demodex* mites, the most common ectoparasites on human skin, can also be observed at the lid margin. The risk of demodicosis increases with age and is seen more frequently in patients with concurrent skin conditions such as rosacea.<sup>6</sup> The presence of *Demodex* mites results in pathognomonic cylindrical dandruff at the base of lashes, follicular distention and



**Lissamine green instilled in the eye reveals a line of Marx that transects the meibomian gland orifice.**

misdirected or broken lashes.<sup>6</sup>

Telangiectasias and lid margin erythema are among the most common findings for ocular rosacea.<sup>7</sup> Identification of this condition’s findings may precede those of dermatological rosacea in approximately 20% of cases.<sup>7</sup> Patients may also exhibit signs such as lid swelling, blepharitis and MGD with more serious cases having potential for corneal neovascularization and thinning.<sup>8</sup>

Expressability of meibum is an essential component of a complete anterior segment examination and is easily observable at the slit lamp. Digital pressure can be applied to release oil to the surface of the lid margin or a meibomian gland evaluator can be employed to provide uniform and consistent pressure to the lids. Quality and quantity of secretions can be recorded and monitored during therapy for improvement.

### Mechanical Treatments

Lid debridement, or scaling, of the hyperkeratinized lid margin removes obstructive cells limiting meibum expression and contributing to gland obstruction. Instillation of lissamine

green dye highlights the line of Marx (LOM), or mucocutaneous junction. In normal patients, the LOM naturally resides posterior to the meibomian glands but may move anteriorly in patients with MGD. Removing the layer of keratin can be beneficial.<sup>9</sup>

Microblepharoexfoliation can be performed using the BlephEx (BlephEx) or AB Max (Myco Industries) devices to mechanically remove

biofilm, a potential contributor to DED, plus eyelid scurf and debris.<sup>10</sup> The BlephEx procedure takes approximately six to eight minutes to complete all four lids and is well-tolerated by patients. The micro-sponge disposable tip removes debris from the eyelid surface and simultaneously exfoliates the lid margin. The AB Max device offers similar functionality plus a pulse mode designed to address hard-to-remove debris while gently massaging the lid margins, the manufacturer says.

### Treat with Heat

Thermal treatments for MGD can be implemented in-office and, now, at-home as well. The fundamental principle behind each option is to provide a heat source to loosen the lipid-based meibum and make it more fluid for better incorporation into the tear film.

The most traditional device to deliver thermal therapy is a warming mask. These are highly accessible to patients, offer a great entry point into dry eye care for the newly diagnosed and are at an affordable price point. However, studies show not all warm compresses to be equally efficacious due to their

Earn up to  
**12 CE**  
Credits\*

# 2019 WEST COAST OPTOMETRIC GLAUCOMA SYMPOSIUM DECEMBER 13-14



## Registration Open!

Join our faculty of renowned ODs, MDs, and PhDs for a highly interactive meeting covering the most up-to-date information in glaucoma care.  
Earn up to 12\* CE credits!

### HYATT REGENCY HUNTINGTON BEACH

21500 Pacific Coast Highway  
Huntington, CA 92648

Discounted room rate **\$239/night** + tax.  
Please call the hotel directly at  
877-803-7534 and mention  
WCOGS for group rate. Rooms limited.

### MEETING CO-CHAIRS

Murray Fingeret, OD, FAAO

Robert N. Weinreb, MD



## 3 WAYS TO REGISTER:

Online: [www.reviewsce.com/WCOGS2019](http://www.reviewsce.com/WCOGS2019)

E-mail: [reviewmeetings@jhihealth.com](mailto:reviewmeetings@jhihealth.com)

Call: 877-451-6514

Administered by:



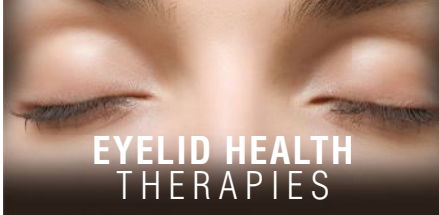\*Approval pending



Partially supported by unrestricted educational grants from:

Bausch & Lomb	Aerie
Sun Pharmaceuticals	Allergan
Carl Zeiss Meditec	Alcon

Review Education Group partners with Salus University for those ODs who are licensed in states that require university credit.  
See event website for complete details.



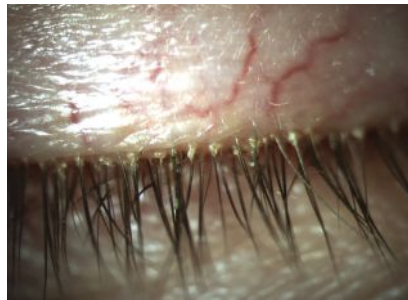## EYELID HEALTH THERAPIES

inability to maintain a consistent temperature at 45°C (113°F) at the outer lid surface.<sup>11,12</sup> This temperature is required to provide therapeutic heat to the meibomian glands.<sup>11,12</sup> While warming masks can be recommended as an at-home option, their use can also be paired with in-office manual meibomian gland expression to provide greater release of impacted meibum relative to lid massage alone.

LipiFlow (Johnson & Johnson Vision) also offers an in-office thermal treatment. This closed-eye thermal device enables a hands-free 12-minute procedure that directly applies heat to the inside of the lid where the meibomian glands reside. Research shows a single LipiFlow treatment can provide lasting relief from signs and symptoms of evaporative DED for up to 12 months.<sup>13</sup>

In one study, 30 patients received the procedure and were evaluated at one month and one year.<sup>14</sup> Eighteen returned for post-procedure evaluation at 12 months. At the visit, dry eye symptoms were scored and tear break-up time (TBUT) and meibomian gland function were measured. Patient symptoms and gland function continued to show significant improvement from baseline. However, the improvement in TBUT at one month was not maintained at the one-year follow up. LipiFlow improved dry eye symptom scores for 86% of treatment group subjects who received only one LipiFlow treatment and a sustained mean improvement in symptom score was noted from baseline.<sup>14</sup>

The iLux (Alcon) handheld device is a thermal treatment designed to allow the practitioner to visualize the meibomian glands through a magnifier during targeted expression. The operator actively controls the amount of heat and pressure



**Pathognomonic cylindrical dandruff at the base of the lash due to demodexosis.**

during the treatment. Each treatment takes approximately 10 minutes (treating two zones/both eyes). It's important to note the meibum may begin to melt within the gland and begin to release onto the lid margin prior to lid compression. Efficacy of the device was evaluated in a multi-center clinical trial with 142 subjects. The study found the iLux device provided efficacy for DED patients and showed non-inferiority to the predicate thermal device, LipiFlow.<sup>15</sup>

Another device, TearCare (Sight Sciences), uses adjustable thermal energy applied externally to the inferior and superior eyelids via adhesive strips. This thermal treatment takes 15 minutes to complete and is immediately followed by manual expression of the meibomian glands by the eye care provider. A hub controls temperature and is adjustable for patient comfort as needed. In addition, the instrument is portable in case you have multiple locations or need to move a patient from different rooms. As a safety feature, software within the hub continually monitors the thermal energy applied.

TearCare allows patients to keep their eyes open during the procedure, which may make them more comfortable and can encourage movement of melted meibum during the process.<sup>16</sup>

# S4OPTIK

## LCD Visual Acuity System VA-1



### Comprehensive Visual Acuity Solution

- Multiple optotype selections
- All acuity slides presented with ETDRS Spacing
- Contrast sensitivity testing
- Crowding bars (for pediatrics)
- Multimedia system and more!



# S4OPTIK

250 Cooper Ave., Suite 100 Tonawanda NY 14150

[www.s4optik.com](http://www.s4optik.com) | 888-224-6012

Sensible equipment. Well made, well priced.

For today's modern office.





## EYELID HEALTH THERAPIES

Pilot data from a single-center study shows improvement in subjects treated with TearCare relative to those treated with warm compress.<sup>16</sup> Both signs and symptoms as measured by TBUT and Ocular Surface Disease Index (OSDI) significantly improved from baseline.<sup>16</sup>

### A Bright Idea

Intense pulsed light (IPL) uses a non-laser high-intensity light source, or flashlamp, to create a broad wavelength of non-coherent light. The light pulse passes through a xenon gas-filled chamber with the energy pulse directed through a sapphire or quartz block. The operator controls the duration, intensity and spectral distribution of the pulse. While the mechanism of action of IPL has not been fully elucidated, studies show a reduction in cytokines in the tear film as compared with baseline values after IPL treatment.<sup>17,18</sup> IL-17A and IL-6 showed statistically significant decreases post-procedure.<sup>17</sup>

More than 85% of patients with skin and eyelid inflammation also suffer from inflammatory ocular conditions.<sup>18</sup> Patient selection for IPL procedures—such as those performed with the The M22 Optima (Lumenis)—is critical for safe and efficacious treatment. First, patients complete a skin survey to determine their skin type based on the Fitzpatrick Skin Scale, a six-point grading system used to determine the amount of pigment your skin has and your skin's reaction to sun exposure. The patient should be counseled prior to treatment about potential adverse events and evaluation of their current medications. Before the procedure starts, a coupling gel is applied to the area to be treated.

A recent multi-center study with 40 enrolled subjects who under-

went four treatment sessions three weeks apart found significant improvement in both the signs and symptoms of dry eye disease including TBUT, meibomian gland score and SPEED score.<sup>19</sup>

Eye-Light (Topcon) also offers IPL, as well as low-level light therapy (LLLT), which combines light modulation with optimized power energy (OPE). The unit treats both inferior and superior eyelids simul-

taneously without the need for a coupling gel. Instead, the Eye-Light has an internal cooling feature. The patient's treatment parameters are managed by the unit's software. The OPE uses a xenon flashtube to create a pulse with a 600nm wavelength and is applied to the periorbital area. The LLLT is delivered through a facemask containing an LED matrix designed to heat the upper and lower lids.

### Five Warming Mask Options

In the old days, patients were advised to devise their own warm compress by filling a damp sock with rice and warm it in the microwave. However, these homespun remedies can have a lot of variability. Some patients were advised to use other various household items—including hard-boiled eggs—and temperature and compression times. Some of these methods heated the lid, but sapped it of moisture, the exact opposite of the intended outcome. Today, the market offers several well-researched items specifically designed for lid therapies.

**1. Bruder Moist Heat Eye Compress (Bruder):** The company's MediBeads technology stores water molecules that are continuously absorbed from the air. When microwaved, the absorbed water is released as a moist heat. The company notes a significant increase in TBUT after using the product.<sup>1</sup>

**2. Eye Doctor Click and Go, and Eye Doctor Plus Moist Heat Compress (The Dry Eye Doctor):** This company offers a deep roster of products related to dry eye. The instant mask doesn't require an oven or microwave to heat up. It's activated by clicking a disk inside the compress to generate the heat and stays warm for approximately 20 minutes. Eye Doctor Plus Moist Heat Compress does require oven or microwave heat, but can also be cooled in a freezer to help relieve allergies or headaches.<sup>2</sup>

**3. EyeEco** boasts a product line designed to treat different stages of dry eye and can be heated to specific temperatures. Its **Dry Eye Relief Mask** is for mild dry eye and heats to 104°. Its **Tranquileyes Advanced** heats to 110° and provides moist-heat for 12 to 15 minutes for moderate DED. Finally, the **Tranquileyes XL Advanced** for severe patients heats to 102° to 110° and provides moist heat for 20 to 25 minutes.<sup>3</sup>

**4. TheraPearl eye mask (Bausch + Lomb):** This microwavable option can be used as a 20-minute warm compress for DED patients or stored in a freezer and used as a cold compress.<sup>4</sup>

**5. Thermal-1 Touch (OcuSoft)** is a portable heated eye pad worn like a pair of glasses by the patient. The heat applied to the eyelids is a pre-set and controlled temperature with adjustable bridge and temples. The treatment takes between five and 10 minutes to complete twice daily at home.<sup>5</sup>

1. Bruder. Moist heat: how it works. [www.bruder.com/moist-heat-eye-compress/how-it-works](http://www.bruder.com/moist-heat-eye-compress/how-it-works). 2017. Accessed October 17, 2019.

2. The Dry Eye Doctor [thedryeyedoctor.net](http://thedryeyedoctor.net). Accessed October 17, 2019.

3. Eyeeco. Controlled moist-heat relieves dry eye. [www.eyeeeco.com/docs/Research-Moist-Heat-Performance-Charts.pdf](http://www.eyeeeco.com/docs/Research-Moist-Heat-Performance-Charts.pdf). May 29, 2018. Accessed October 17, 2019.

4. Bausch + Lomb. Therapearl Eye Mask. [www.bausch.com/our-products/dry-eye-products/dry-eye-products/therapearl-eye-mask](http://www.bausch.com/our-products/dry-eye-products/dry-eye-products/therapearl-eye-mask). Accessed October 17, 2019.

5. Ocusoft. Ocusoft Inc. acquires digital heat's eyelid warming device. [www.prnewswire.com/news-releases/ocusoft-inc-acquires-digital-heats-eyelid-warming-device-300875782.html](http://www.prnewswire.com/news-releases/ocusoft-inc-acquires-digital-heats-eyelid-warming-device-300875782.html). June 27, 2019. Accessed October 17, 2019.

## SLIT LAMPS

EXCEPTIONAL OPTICS

## Maintenance

In-office treatment effectively hits a “reset button” for patients. However, maintaining that initial success and protecting the patient’s financial investment is essential for long-term patient satisfaction. Achieving this necessitates the use of at-home hygiene products.

One such lid-cleansing formulation, Zocushield (Okra), is composed of an okra polysaccharide complex. The gel is digitally applied by the patient in a gentle, circular fashion along the lids and lashes. The product also has an in-office companion, the Zest treatment, which incorporates Zocushield gel as part of a treatment kit.

NuLids (NuSight Medical) is a compact, cordless, at-home lid cleaning device. A sterile, disposable tip is attached to the end of the unit and a lubricating gel is added as an interface. The tip gently vibrates and is placed at the edge of each eyelid for approximately 30 seconds. A pilot study into the device enrolled 37 patients and found improvement in both signs and symptoms of DED.<sup>20</sup> Notably, after 30 days of treatment, TBUT increased and OSDI decreased.<sup>20</sup> While the device is held near the eye, risk of adverse events were deemed low.<sup>20</sup>

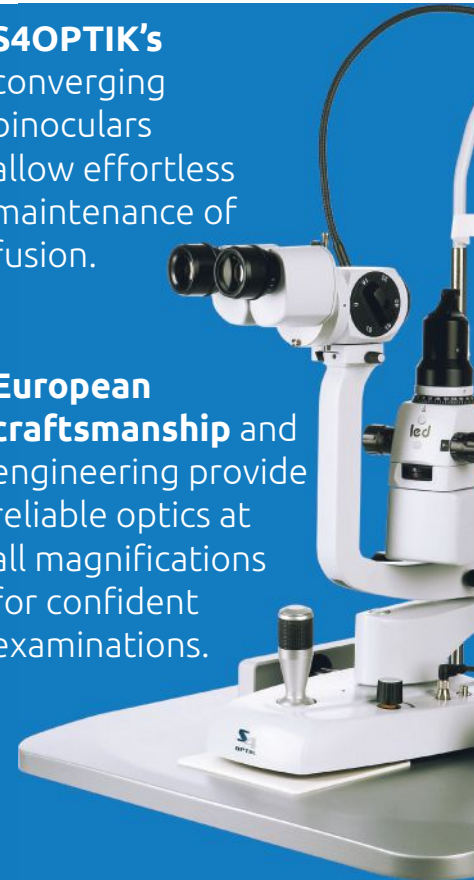Combining consistent at-home hygiene with demonstrably effective in-office procedures can help keep patients’ ocular surface rich in tears and their meibomian glands clear and active, limiting both signs and symptoms of dry eye. Successful management of DED must include evaluation, treatment and continued maintenance of the lids—today’s technologies are making it easier than ever to accomplish those goals. ■

*Dr. Hauser is the director of clinical affairs for Keplr Vision. She also practices clinical care at The Eye Specialty Group in Memphis, TN and is the founder of Dry Eye Coach.*

1. Chhadva P, McClellan A, Alabiad C. The impact of eyelid laxity on symptoms and signs of dry eye disease. *Cornea*. 2016 Apr; 35(4): 531–535.
2. Bashour M. Lower lid ectropion blepharoplasty workup. *Medscape*. [medscape.com/article/1281565-workup?src=refgatesrc1](https://www.medscape.com/article/1281565-workup?src=refgatesrc1). December 22, 2015. Accessed October 14, 2019.
3. Lemp M, Nichols K. Blepharitis in the United States 2009: a survey-based perspective on prevalence and treatment. *Ocul Surf*. 2009;7(2 Suppl):S1–14.
4. Nelson J, Shimazaki J, Benitez-del Castillo J, et al. The international workshop on meibomian gland dysfunction: report of the definition and classification subcommittee. *Invest Ophthalmol Vis Sci*. 2001;52(4):1930–1937.
5. Putnam C. Diagnosis and management of blepharitis: an optometrist’s perspective. *Clin Optom (Auckl)*. 2016; 8: 71–78.
6. Liu J, Sheha H, Tseng S. Pathogenic role of Demodex mites in blepharitis. *Curr Opin Allergy Clin Immunol*. 2010;10(5):505–10.
7. National Rosacea Society. Ocular rosacea: what your eyes may be trying to tell you. [www.rosacea.org/blog/2015/january/ocular-rosacea-what-your-eyes-may-be-trying-to-tell-you](http://www.rosacea.org/blog/2015/january/ocular-rosacea-what-your-eyes-may-be-trying-to-tell-you). January 20, 2015. Accessed October 14, 2019.
8. López-Valverde G, Garcia-Martin E, Larrosa-Povés J, et al. Therapeutical management for ocular rosacea. *Case Rep Ophthalmol*. 2016;7:237–42.
9. Korb D, Blackie C. Debridement-scaling: a new procedure that increases Meibomian gland function and reduces dry eye symptoms. *Cornea*. 2013;32(12):1554–7.
10. Rynerson J, Perry H. DEBS – a unification theory for dry eye and blepharitis. *Clin Ophthalmol*. 2016;10:2455–67.
11. Blackie C, Solomon J, Greiner J, et al. Inner eyelid surface temperatures as a function of warm compress methodology. *Opt Vis Sci*. 2008;85(8):675–83.
12. Murakami DK, Blackie C, Korb D. All warm compresses are not equally efficacious. *Optom Vis Sci*. 2015;92(9):e327–33.
13. Greiner J. Long-term (12-month) improvement in meibomian gland function and reduced dry eye symptoms with a single thermal pulsation treatment. *Clin Exp Ophthalmol*. 2013;41(6):524–30.
14. Blackie C, Coleman C, Holland E. The sustained effect (12 months) of a single-dose vectored thermal pulsation procedure for meibomian gland dysfunction and evaporative dry eye. *Clin Ophthalmol*. 2016;10:1385–96.
15. Tear Film Innovations. Randomized Comparison between iLux and LipiFlow in the treatment of meibomian gland dysfunction. [clinicaltrials.gov/ProvidedDocs/32/NCT03055832/Prot\\_SAP\\_000.pdf](https://clinicaltrials.gov/ProvidedDocs/32/NCT03055832/Prot_SAP_000.pdf). April 3, 2019. Accessed October 14, 2019.
16. Badawi D. A novel system, TearCare, for the treatment of the signs and symptoms of dry eye disease. *Clin Ophthalmol*. 2018;12:683–94.
17. Liu R, Rong B, Tu P, et al. Analysis of Cytokine Levels in Tears and Clinical Correlations After Intense Pulsed Light Treating Meibomian Gland Dysfunction. *Am J Ophthalmol*. 2017;183(11):81–90.
18. Viso E, Millán AC, Rodríguez-Ares MT. Rosacea-associated meibomian gland dysfunction—an epidemiological perspective. *Eur Ophthalmol Rev*. 2014;8(1):13–16.
19. Dell S, Gaster R, Barbarino S, Cunningham D. Prospective evaluation of intense pulsed light and meibomian gland expression efficacy on relieving signs and symptoms of dry eye disease due to meibomian gland dysfunction. *Clin Ophthalmol*. 2017;11:817–27.
20. Schanzlin D, Olkowski J, Coble J, et al. Efficacy of self-administration of a personal mechanical eyelid device for the treatment of dry eye disease, blepharitis and meibomian gland disease. NuSight Medical. [eastvisionexpo.com/novadocuments/548696?v=636848314252030000](https://www.eastvisionexpo.com/novadocuments/548696?v=636848314252030000). Accessed October 14, 2019.

S4OPTIK’s converging binoculars allow effortless maintenance of fusion.

European craftsmanship and engineering provide reliable optics at all magnifications for confident examinations.



H-Series

Z-Series



Vertical and compact configurations available.

S4OPTIK

www.s4optik.com | 888.224.6012

Sensible equipment. Well made, well priced.

For today’s modern office.

# THE OPTOMETRY OFFICE REIMAGINED

These new spaces emphasize patient comfort as much as they do state-of-the-art technology and exceptional clinical care. **By RO Staff**

Optometrists have added a lot to their toolbox in recent years, with new high-tech diagnostic instruments, integrated electronic health records (EHR) and advanced therapies. While all of this has, without a doubt, improved eye care, it's also put a strain on practices operating out of smaller spaces never meant to house all of these innovations. Some optometrists make do with the space they have, squeezing in the new exam lane, OCT or widefield imaging device wherever they can. Others take the plunge and upgrade their digs, aiming to revolutionize both the patient and staff experience.

"We feel that we have completely broken the mold and reinvented the exam process by creating an open-space testing environment," says this year's

Office Design Contest winner Scot Morris, OD, of Eye Consultants of Colorado in Conifer, CO. "By fusing state-of-the-art technology and amazing staff with an inviting ambiance, we have created a truly unique eye health visit."

Like Dr. Morris, all of this year's design contest participants focused on the patient experience while seamlessly integrating top-of-the-line technology. Fireplaces, barn doors, gold-accented restrooms and open spaces are just some of the features wowing patients. But these practice owners also took care of their employees, ensuring a stress- and bottleneck-free work environment. Take a look at the three optometry practices that hit it out of the park this year with top-notch tech, function and aesthetics.

## MEET THE JUDGES

In 2017, these three practices went above and beyond with their own office renovations. This year, they provided expert feedback to help us wade through all of the exceptional office designs to pick the cream of the crop.

### Swell Vision Center in Leland, NC

*This office blended rustic and modern concepts to create a simple, elegant experience with privacy when you need it—and open space when you don't.*



### Benjamin Crawford, OD, of Accurate Vision Clinic in Anchorage, AK

*The industrial-chic feel of this space boasts everything but clutter, with wireless transfer of pretesting data and seamless patient flow. The inviting design begs patients to stay and browse.*



### William L. Tantum, OD, of Blount County Eye Center in Maryville, TN

*This super-sized practice provides everything from a drive-thru optical dispensing window to an open-concept lab that gives patients a behind-the-scenes look at "how the magic of optical happens."*







# Winner

*Eye Consultants of Colorado, Conifer, CO*  
 Scot Morris, OD

“Warm,” “cozy” and “inviting” were the first thoughts our judges had about this practice. And at an elevation of 9,000ft., it’s no wonder the “mountain chalet ambiance” works for them, according to judge Benjamin Crawford, OD, of Accurate Vision Clinic in Anchorage, AK. The judges were ready to “grab a seat next to the fire with a hot chocolate and enjoy a good book” at the sight of the office’s exposed beams, barn doors, fireplace and custom scented candles.

While Dr. Morris decided to keep the business operations out of sight, the same isn’t true of the latest diagnostic equipment. In fact, the new open concept puts the ultra-widefield imaging, OCT and visual field testing devices on display.

“We took our advanced equipment out from behind the walls and featured our technology in what we call ‘The Runway,’” Dr. Morris explains.





# OFFICE DESIGN CONTEST

All of the information is seamlessly integrated into the EHR, and staff can use the command center's multiple screens to follow in-progress exams or access the data using their tablets on the go.

"Having no business operations in plain view, really lessens clutter and opens up the whole office," Dr. Crawford notes. "I love the idea of 'The Runway' and showing off all of the state-of-the-art equipment instead of tucking it away in a separate room." The judges also loved the addition of a face and eye med spa.

From the beginning of the patient experience, high-tech is blended with a personal touch. Patients are greeted by a staff member upon their arrival and never encounter a front desk. They can then interact with an augmented intelligence app that streamlines their differential diagnosis with just eight questions, a proprietary cityscape acuity chart and personalized video-based education.


"It seems incredibly patient-focused, and you can tell the experience matters a lot to them," says judge William L. Tantum, OD, of Blount County Eye Center in Maryville, TN.

When it comes time to pick frames, patients enjoy an equally unique optical experience.

"We created customized displays incorporating local designs to create a truly stunning and rustic feel at a fraction of the price of outdated display racks," Dr. Morris says. "We also use both virtual try-on technology and computer-guided measurements to create a uniquely comfortable yet high-tech shopping and purchasing experience."

The new approach is quickly paying off, too.

"Due to our greater exposure, high-tech environment and ski lodge feel, we are seeing a record increase of 40% in new patients both in the form of walk-ins, call-ins and referrals from existing patients," Dr. Morris says.



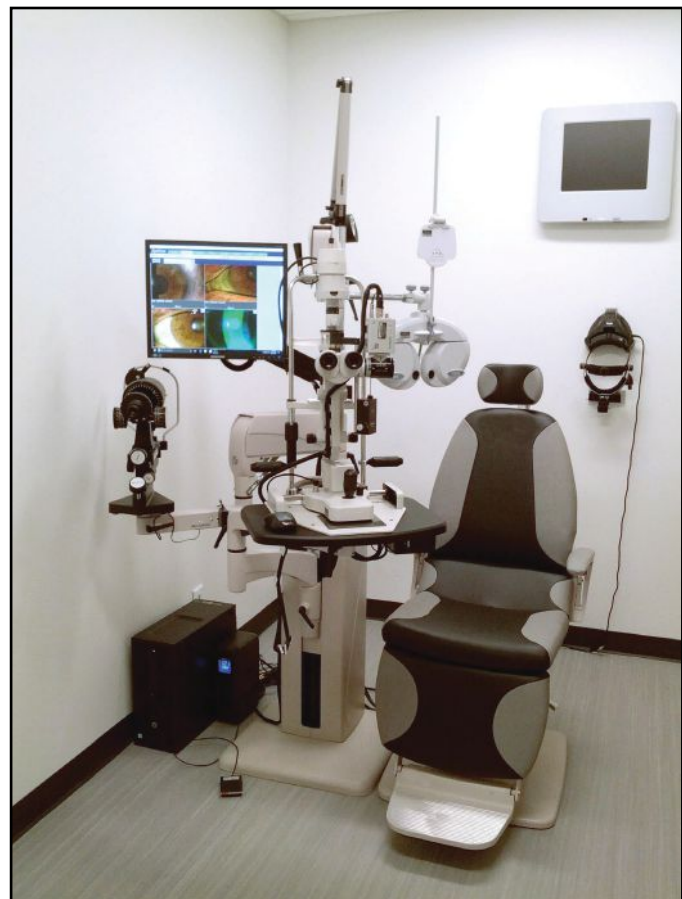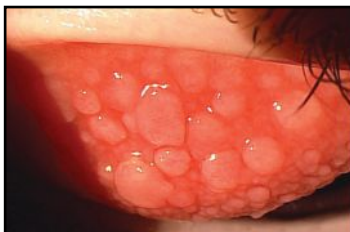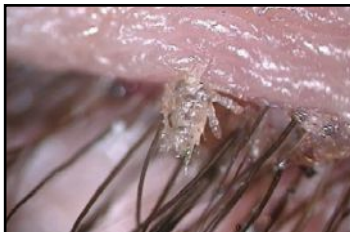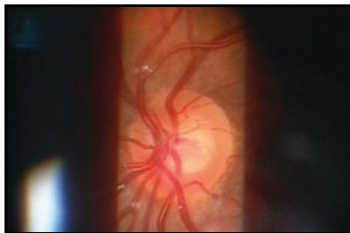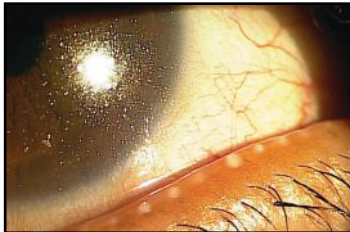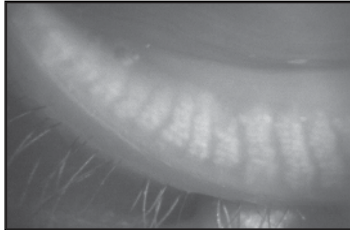
**I'm still loving the imaging system. Compliance has been great now that patients can see their eye problems.**

**Brittney McWilliams, O.D., Evansville, IN**

Concisely communicate your diagnosis & treatment plan using an **EyeRes Digital Imaging System**.

**EyeRes**<sup>TM</sup>

**Digital Imaging Systems**



Promote optimal health & wellness outcomes with your patients.

**TelScreen**





# 1st Runner Up

*Personaley3s Vision Care, Flower Mound, TX*  
Kumar Patel, OD





Our first runner up, Personaley Vision Care, also prioritized an open concept design but took a modern, minimalist approach.

“I love the clean lines and open space of this modern office,” says Dr. Crawford. “The unique optical displays integrate seamlessly with the design.”

The office was designed so patients enter and exit based on the progress of their appointment, according to practice owner Kumar Patel, OD, and office manager/designer Trusha Patel. Moving through the 2,267sq.ft. gives them the full optometric experience, they say.

Dr. Patel made his \$360,000 budget go a long way. This practice packs quite a punch with high ceilings, exposed ductwork and custom lighting.

“The lighting of this office with the large open windows is really what sold us,” according to judge Craig Scibal, OD, of Swell Vision Center in Leland, NC. “Also, tough to beat that city view with the exposed brick.”

The judges were also wowed by the attention to detail everywhere, including the bathroom.

“Likely one of the coolest bathrooms you’ll ever see with the patterned gold backsplash and classic clean subway tile,” admits Dr. Scibal. “I’m sure patients come out of there saying, ‘Wow!’” adds Dr. Crawford.

The office’s natural lighting harmonizes with the calming color palette. “The use of blue and yellow colors was very important because they give patients the sense of calm and friendliness,” Dr. Patel says. “It helps them open up more and relax during their appointment.”

The effort wasn’t lost on the judges. “The subtle blue colors throughout the office seem to promote tranquil-



ity and a zen-like vibe,” Dr. Scibal says. “The pops of color with the doors and furniture is great.”

When it comes to the equipment, Dr. Patel made sure it complemented, rather than disrupted, the open feel. Ethernet ports were added throughout the space to make installing and moving optometric equipment a breeze. This also gives him the flexibility to add new equipment whenever he wants without over-crowding the space.

“It seems like no detail of the design was overlooked,” Dr. Crawford says. “If I had one word to describe this office, it would be fresh.”







## 2nd Runner Up

Spring Hill Eyecare, Spring Hill, TN  
Rob Szeliga, OD



“If I had one word to describe this office, it would be homegrown,” says Dr. Crawford. Preserving history and small-town charm was key for this practice, which grew from one lane and 1,200sq.ft. in 2005 to four lanes and 2,400sq.ft. in 2008. This new building now boasts 10 lanes and 8,300sq.ft.

The practice’s new location was first home to a farmhouse built in 1870, and taking down the historical landmark presented a significant challenge. “Without the proper approach, this would not go over well in a growing community that is quickly losing its small-town charm,” practice owner Rob Szeliga, OD, explains.





He ensured the locals that the practice would repurpose as much of the farmhouse as possible, and the office is now home to eight of the original fireplace mantles, all of the doors and much of the original barnwood and beadboard. The farmhouse's wavy glass windows decorate the pretesting and special testing rooms, and the clinic displays many artifacts recovered from the farmhouse, such as books, train tickets and letters. Even if it didn't come from the farmhouse, it's still local, according to Dr. Morris. The three other fireplace mantles were salvaged from another nearby home and the town's antique store.



"I love the fact that they incorporated aspects of the old farmhouse to give the office its rustic charm," says Dr. Crawford. "Having that local connection to the community speaks volumes to patients. It shows the respect and lasting commitment that the doctors have to serving their community."

Added to the hometown charm, the new office boasts everything a patient could ask for: large parking lot, reception area with a coffee bar, spacious optical room, an open pretesting area, dedicated dry eye room, sports vision/vision therapy suite and two special testing rooms.

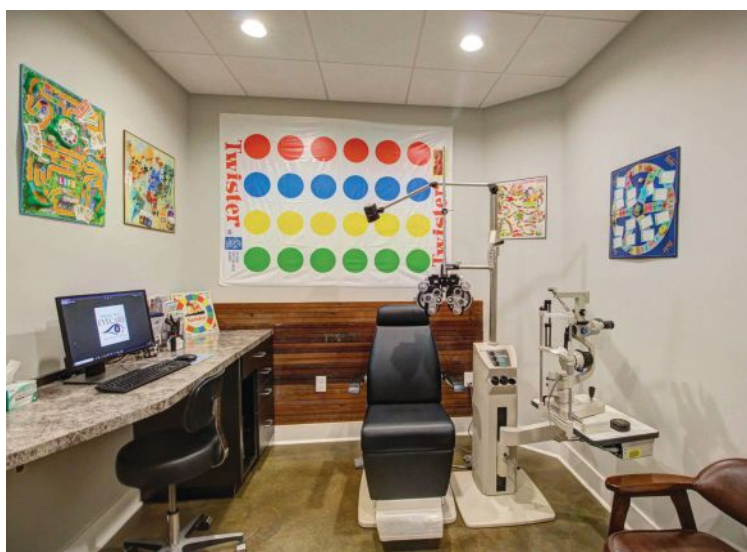
"Each room looks like an adventure," says Dr. Tantum. "Very open and well lit. Very patient-focused."

The renovation didn't ignore staff needs either. A team lounge, two tech stations and separate offices for the office manager and associate doctors give everyone the space they need.

More space also meant room for more gadgets and gizmos. Dr. Szeliga added new treatment devices and a massage chair in the dry eye room. Exams now include automated phoropters, eye tracking technology, dark adaptation testing and neurolens (eyeBrain Medical) technology for those who need it.

Perhaps the best emblem of this practice's commitment to patient care is the farmhouse's cornerstone, now part of the eyewear gallery.

"Forming a hand-cut stone like this is like a symbol of our practice—I opened it cold right out of school years ago," says Dr. Szeliga. "Although trends and technology are constantly changing in optometry, creating a strong foundation built on superior patient experience will hopefully stand the test of time." ■



Earn up to  
**17 CE  
Credits\***

ANNUAL • EST. 1976

# WINTER OPHTHALMIC CONFERENCE

A REVIEW MEETING OF CLINICAL EXCELLENCE

THE LONGEST  
RUNNING WINTER  
CE MEETING  
IN EYE CARE!

Early Bird Discount!

**\$545**

Must register before  
12/1/2019

**FEBRUARY 14-17, 2020**

**ASPEN, COLORADO**

**Westin Snowmass Conference Center**

The meeting features relevant topics in  
glaucoma, dry eye, external disease and retina.

**[www.SkiVision.com](http://www.SkiVision.com)**

Administered by:  
**REVIEW**  
EDUCATION GROUP

**cove**  
\*Approval pending

Medscape  
**LIVE!**

**SALUS**  
UNIVERSITY  
Pennsylvania College of Optometry

Review Education Group partners with Salus University for those ODs who are licensed in states that require university credit.  
See event website for complete details.







# OVERCOMING SECONDARY GLAUCOMAS

A proper understanding of these conditions is paramount in providing swift and appropriate care. **By Michael Cymbor, OD, and Jenae Stiles, OD**

In optometry school, we were taught that glaucoma converts and progresses over years and years. “Monitor” is the mantra. But sometimes, glaucoma isn’t a slow and steady disease.

Secondary glaucoma refers to any form of glaucoma in which there is an identifiable cause. The primary purpose of this article is to highlight the aggressive nature of two secondary glaucomas—exfoliation glaucoma (XFG) and, to a lesser extent, pigmentary glaucoma (PG)—as

their aggressiveness is often underappreciated. Other secondary glaucomas—including uveitic, traumatic and lens-induced are also discussed.

## Exfoliation Syndrome

Exfoliation syndrome (XFS) may cause an extremely aggressive form of glaucoma. The severity of exfoliative glaucoma (XFG) may be overlooked due to the relatively slower progression of primary open-angle glaucoma (POAG). With failure to diagnose/delayed diagnosis being

the most common reason for malpractice among all physicians, it is imperative that a timely diagnosis be made to tailor treatment.<sup>1</sup>

XFS was first described in 1917 and was termed pseudoexfoliation in 1953 when pseudocapsular deposits were found on histological sections of three eyes with clinical exfoliation.<sup>2,3</sup> The term *exfoliation* described changes to the lens from capsular delamination due to high amounts of infrared radiation, commonly found on the natural lenses of

**Release Date:** November 15, 2019

**Expiration Date:** November 15, 2022

**Estimated Time to Complete Activity:** 2 hours

**Jointly provided by Postgraduate Institute for Medicine (PIM) and Review Education Group**

**Educational Objectives:** After completing this activity, the participant should be better able to:

- Describe the fundamental differences between primary and secondary glaucoma.
- Identify the presentation of various forms of secondary glaucomas.
- Perform the necessary elements of the patient history, ocular examination/vision testing as well as diagnostic testing and/or imaging, and any other ocular or systemic evaluation required to diagnose secondary glaucomas.
- Provide, or otherwise obtain, the ocular and systemic treatment that the patient requires.

**Target Audience:** This activity is intended for optometrists engaged in the care of patients with secondary glaucomas.



**Accreditation Statement:** In support of improving patient care, this activity has been planned and implemented by the Postgraduate Institute for Medicine and Review Education Group. Postgraduate Institute for Medicine is jointly accredited by the Accreditation Council for Continuing Medical Education, the Accreditation Council for Pharmacy Education, and the American Nurses Credentialing Center, to provide continuing education for the healthcare team. Postgraduate Institute for Medicine is accredited by COPE to provide continuing education to optometrists.

**Faculty/Editorial Board:** Michael Cymbor, OD, and Jenae Stiles, OD.  
**Credit Statement:** This course is COPE approved for 2 hours of CE credit. Course ID is **65237-GL**. Check with your local state licensing board to see if this counts toward your CE requirement for relicensure.

### Disclosure Statements:

*Dr. Stiles* has nothing to disclose.

*Dr. Cymbor* has fees from non-CME/CE services from Optovue.

**Managers and Editorial Staff:** The PIM planners and managers have nothing to disclose. The Review Education Group planners, managers and editorial staff have nothing to disclose.

unprotected steel foundry workers.

A return to the original nomenclature coined in 1917 is now occurring. Due to the current rarity of true exfoliation, the term *pseudoexfoliation* is being replaced by *exfoliation*. Both terms are currently found in the literature. For simplicity, we will use XFS and XFG in this article.

XFS affects 70 million people worldwide, with an emphasis on those of European descent.<sup>4</sup> At one time, XFS was considered solely a Scandinavian disease, but now prevalence patterns vary greatly. Studies report that it affects approximately 20% to 25% of those older than age 60 in Iceland and Finland, with virtually no signs of XFS found among the Eskimo population and very low prevalence reported in the Japanese.<sup>5</sup>

The systemic disease process of XFS has been linked with dementia, hearing loss, cerebrovascular, cardiovascular and kidney disease.<sup>6</sup> Literature supports the increasing prevalence of XFS with age but not necessarily gender.<sup>7</sup>

XFS is characterized by fibrillar deposits in virtually all tissues within the anterior segment and some tissues within the posterior segment. These deposits are caused by an imbalance of enzymes called matrix metalloproteinases (MMPs).<sup>8</sup> This systemic extracellular matrix disorder is thought to be triggered

### Patient with XFS Nearly Lost to Follow Up

A 71-year-old white female presented to the office in 2013 for a comprehensive eye examination. She complained of changes in her distance vision. Her IOP by non-contact tonometry (NCT) was 17mm Hg OD and 15mm Hg OS.

On exam, the optometrist noted XFS material deposited on the left pupillary margin along with a classic bull's eye pattern on the left lens on dilated fundus exam (*Figure 1*). The cup-to-disc ratio was noted to be 0.4/0.5 OD and OS. Optical coherence tomography (OCT) was performed the same day, which showed a thick retinal nerve fiber layer (RNFL) OU with a relatively thick ganglion cell complex (GCC) (*Figure 2*).

The patient was diagnosed with exfoliation syndrome OS and educated on the serious nature of the diagnosis. She was scheduled for a complete glaucoma work-up in one month.

The patient did not show for the follow-up visit and was not seen again until 2015. That exam again showed the bull's eye capsular pattern OS with IOPs of 19mm Hg OD and 18mm Hg OS by NCT. The cup-to-disc ratio was again graded at 0.4/0.5 OD and OS. The patient was again educated on the serious nature of the diagnosis and was scheduled for a glaucoma work-up in two weeks. Again, the patient never showed, but a concerted effort (which included phone calls, letters and a certified letter) was made to encourage the patient to return to the office. Unfortunately, the patient did not return again until 2017.

At this visit in 2017, IOPs measured 15mm Hg OD and OS by NCT. OCT revealed significant RNFL and GCC thinning OS, and her cup-to-disc ratio was now graded at 0.5/0.65 OD and OS (*Figure 3*). She was diagnosed with exfoliation glaucoma OS. She was also diagnosed with grade 2 nuclear sclerotic cataracts OU.

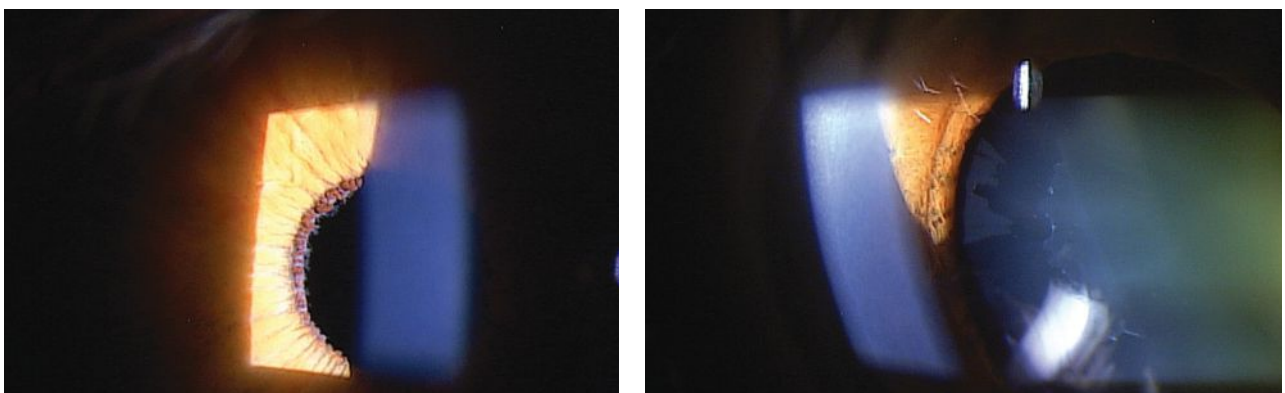
The optometrist started the patient on one drop of Lumigan (bimatoprost, Allergan) every night OU and referred her to the Glaucoma Institute of State College. Glaucomatous visual field testing showed a small depression OD and a significant reduction OS (*Figure 4*). Treated pre-dilation IOPs measured 10.6mm Hg OD and 17.1mm Hg OS by Ocular Response Analyzer (ORA). Post-dilation IOPs measured 12.1mm Hg OD and 31.3mm Hg OS by ORA.

At this time, she is scheduled for cataract surgery and Kahook Dual Blade goniotomy OU.

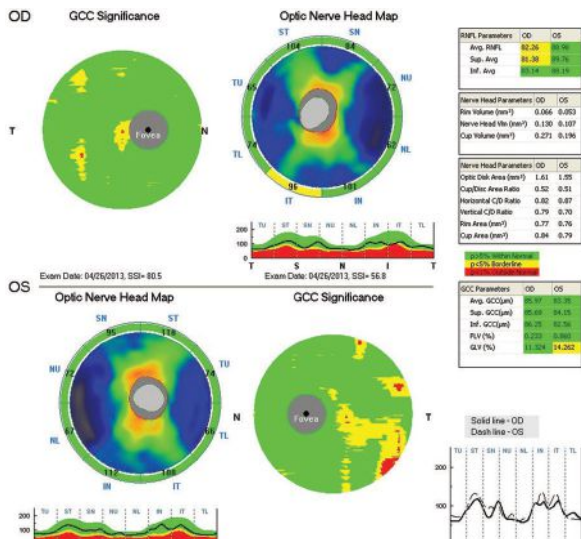
by both genetic and environmental factors, causing irregular cellular degeneration, abnormal lysosomes and mitochondria and disorganized microtubules essential for maintaining cellular integrity.<sup>9</sup>

While several genes are implicated in XFS, the strongest association

is linked to the *lysyl-oxidase-like 1 (LOXL1)* gene.<sup>10</sup> *LOXL1* controls a key enzyme in extracellular matrix formation. This gene is essential for the covalent crosslinking of collagen and elastin in connective tissue.<sup>11</sup> *LOXL1* expression and XFS pathogenesis can be influenced by



**Fig. 1.** At left, XFS material deposited on the pupillary margin of a 71-year-old patient diagnosed with XFS. At right, note the classic XFS pattern deposited on the anterior lens capsule.



**Fig. 2. RNFL and GCC OCT imaging at presentation in 2013 shows a thick RNFL OU and relatively thick GCC OU.**

UVB exposure, oxidative stress and hypoxia, among several other environmental factors.<sup>12</sup> Higher latitude, high caffeine intake and low dietary folate consumption are also associated with increased risk of XFS.<sup>13</sup>

Approximately 30% to 50% of patients with XFS develop glaucoma, and this aggressive ocular disease is the most common identifiable form of secondary open-angle glaucoma, mostly affecting those in the seventh and eighth decade of life.<sup>14</sup> XFG accounts for 20% of all glaucoma cases worldwide and is also associated with pathology of several other ocular structures.

Because of the relatively high risk of XFS converting to XFG, we recommend following all XFS patients at six-month intervals.

**Ocular Targets**

The more commonly recognized ocular targets include the lens capsule, lens zonules, iris and the angle.

XFS weakens the lens capsule, resulting in the classic bull’s eye pattern on the lens, which is caused by the mechanical rubbing against the pupillary frill, and best visualized upon dilation.<sup>15</sup> A careful inspection

of the pupillary frill will reveal whitish fibers that can be visualized even if the patient is pseudophakic. This mechanical friction releases iris pigment with resultant iris transillumination defects that occur closer to the pupillary margin, in contrast to pigmentary glaucoma in which transillumination defects occur in the mid-periphery.

XFS fibers can be found on the zonules, which can

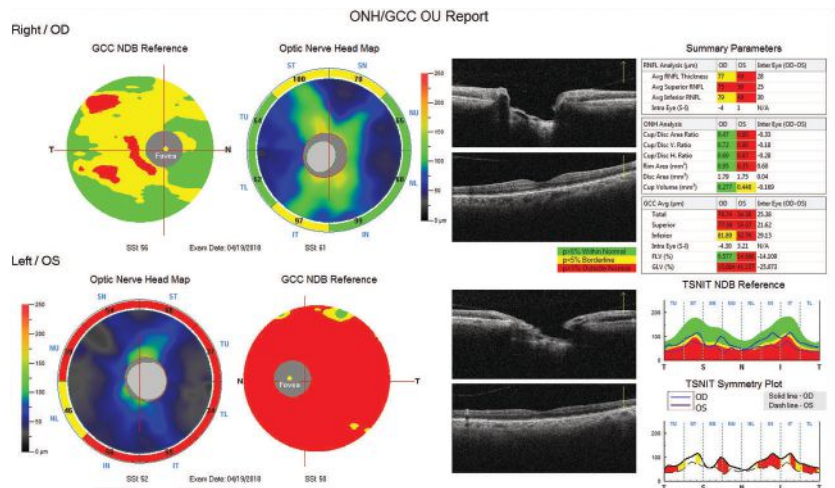
be visualized in a fully-dilated pupil or during dilated gonioscopy. XFS fibers on the zonules usually indicate zonular weakness. Direct signs of zonular weakness include subluxation of the lens, zonular dialysis and phacodonesis.<sup>16</sup> A shallow anterior chamber depth, due to the forward shift of the lens, can be an indirect clue of zonular weakness.<sup>17</sup> Zonular weakness may cause the lens to move either anteriorly or posteriorly, causing refractive asymmetry. Pupil asymmetry can also be indirect sign

of this complication.

Zonular weakness can present challenges during cataract surgery, especially with initiation of the capsulorhexis, as too much zonular tugging may cause the fragile zonules to break.<sup>18</sup> It is important to communicate the presence of exfoliation to the surgeon during the referral to ensure they take extra surgical caution.

In addition to fiber buildup on the pupillary frill, the iris may have endothelial cell loss that may include damage to the dilator muscle. This can result in asymmetric pupil dilation during the comprehensive eye exam. Iris angiography in XFS patients has shown nonperfusion and, as mentioned, transillumination defects at the pupillary margin are common.<sup>19</sup>

The angle will show increased pigment in the anterior trabecular meshwork that is more irregular than pigment dispersion syndrome. The trabecular meshwork pigmentation has a “brown sugar” appearance. Pigment on Schwalbe’s line may occur and is known as Sampaolesi’s line. XFS fibers can clog the angle and arise both from the iris-lens capsule interaction as well as angle cells themselves.<sup>20</sup> Eventually, the trabecular meshwork and Schlemm’s



**Fig. 3. RNFL and GCC OCT at follow up in 2017 shows significant RNFL and GCC thinning of the left eye.**



canal become disorganized, leading to abnormal function. Zonular weakness can also lead to a narrow angle due to forward displacement of the lens.<sup>21</sup>

There are several ocular targets for exfoliation material—including the lamina cribrosa, corneal endothelium and ciliary body—that are less commonly recognized because they are more subtle or more difficult to analyze.

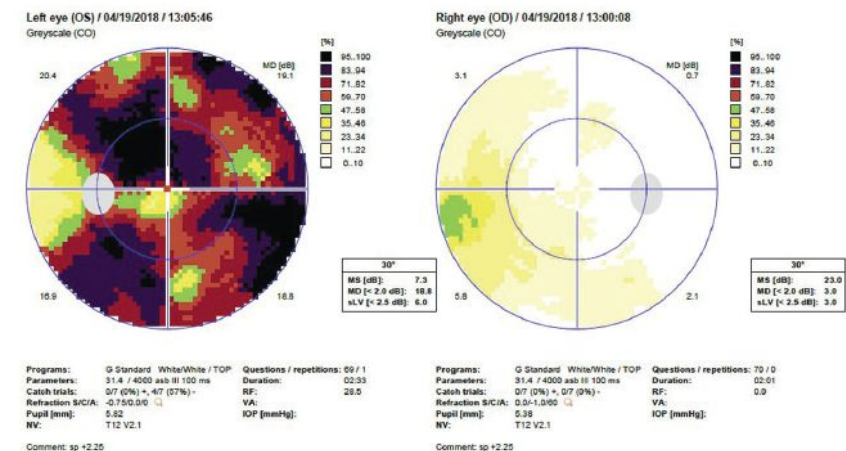
The lamina cribrosa is the sieve-like, load-bearing connective tissue that separates two very different pressure environments, namely the intraocular pressure (IOP) and the cerebrospinal fluid pressure. As the *LOXL1* gene is responsible for connective tissue maintenance, XFG displays a thinner lamina cribrosa compared with POAG eyes.<sup>22</sup> This weakened integrity may crimp axons and blood vessels running through it, contributing to the more rapid progression of the disease.

XFS deposits and pigment cells build up on the corneal endothelium, causing stress to these cells and early cell death.<sup>23</sup> There is an increased risk of corneal decompensation, especially with IOP fluctuations from a shallow anterior angle. Pre- and postoperative cataract surgical care should include endothelial cell counts. XFS fibers may build up on the ciliary body, giving it the appearance of newly fallen snow. This can lead to the aberrant insertion of the zonules into this muscular structure, contributing to zonular weakness.<sup>23</sup>

Exfoliation may be apparent in many, if not most, of the ocular structures mentioned above but may not necessarily be found in all.

### Systemic Targets

As experts of the eye, optometrists must consider not only the ocular effects of XFS/XFG, but also the systemic complications that are common with this syndrome. In reality,



**Fig. 4. A GTOP visual field completed in 2017 shows a small depression of the right eye and significant reduction of the left eye.**

the ocular changes we see are the manifestation of a systemic disease, and we must remember that the clinical course of XFS/XFG may involve alerting the primary care physician of its existence and any systemic correlations. It may also involve referrals to other specialists for complete care.

XFS fibers have been found in the heart and in the small blood vessels supplying the heart.<sup>24</sup> The Blue Mountains Eye Study suggested that a combined history of angina, myocardial infarction and stroke are significantly associated with the presence of XFS.<sup>25</sup> Myocardial ischemia and aortic aneurysms are also associated with XFS and XFG.<sup>24</sup> This material can also deposit in the lungs. Due to the age of these patients at presentation, there is a significant probability that a cardiologist has already been involved in their care, but consider a referral to this specialty if care has not been established.

When considering any pathologic process affecting the small blood vessels, do not overlook the kidneys. A significant association with XFS and renal artery stenosis exists.<sup>26</sup>

While affecting the small blood vessels in the brain, XFS fibers can also deposit on the meninges.<sup>27</sup> Several studies show a higher frequency

of Alzheimer-related dementia in patients with XFS.<sup>28</sup> The severity and prevalence of sensorineural hearing loss in patients with XFS is increased, lending the need to consider audiologic testing to improve the quality of life of these patients.<sup>29</sup>

### Current Treatment Strategies

Prostaglandins are effective first-line therapy for treating XFG. Pilocarpine 2% at night can successfully reduce lens-iris interaction (which reduces exfoliation fiber migration to the trabecular meshwork), but it can cause posterior synechiae and exacerbate preexisting anterior subluxation of the lens due to zonular weakness.<sup>21</sup> A 2009 study showed that latanoprost and pilocarpine 2% was more effective than aqueous suppressants. Researchers have speculated that aqueous suppressants may actually allow more fibers to accumulate in the trabecular meshwork, leading to worsening of function over time.<sup>30</sup> Further study is needed in this area.

If medical therapy fails or a patient is not compliant, consider surgical options. Selective laser trabeculoplasty (SLT) and argon laser trabeculoplasty (ALT) are both effective treatments for XFG.<sup>31</sup> Patients with XFG tend to experience more fluctuation of IOP and require a

### Arthritis Confounds Diagnosis

A 44-year-old white male came to the office complaining of pain in his right eye. We last saw him years ago for bilateral uveitis that was controlled with topical steroids. At that time, we referred him to a rheumatologist who found no systemic etiology, but he did not return for subsequent eye care. He reported that his rheumatologist switched him from CellCept (mycophenolate mofetil, Genentech) to Humira (adalimumab, AbbVie).

At his current visit, his best-corrected visual acuity was 20/30 OD and OS. Biomicroscopy revealed bilateral keratic precipitates with grade 2 cells OD and grade 1 cells OS. Intraocular pressures were 42mm Hg OD and 35mm Hg OS. OCT revealed inferotemporal thinning of the RNFL and the GCC OD while OS was normal.

We diagnosed him with uveitic glaucoma OD and started him on 1% Pred Forte (prednisolone acetate, Allergan) 6x/day along with Cosopt (dorzolamide/timolol, Akorn) and brimonidine, both OU. We tapered his Pred Forte over several weeks. He is currently on brimonidine BID OU and his IOP is controlled in the low teens.

greater reduction of mean 24-hour IOP than those with POAG, leading to initiation of combination therapy much sooner.<sup>32</sup> SLT/ALT causes more inflammation in XFG patients than in POAG patients, so those with XFG must be monitored more closely for IOP spikes in the postoperative period. Overall, XFG patients must be monitored more frequently than POAG patients, with consideration of surgical options sooner.

Cataract surgery must also be approached with more caution in XFG patients. While cataract removal may reduce XFS fibers in the trabecular meshwork, weak zonules may pose several potential complications for the surgeon and result in a smaller

capsulorhexis. This smaller opening can lead to an increased risk of phimosis (i.e., the centripetal fibrosis and contraction of the capsulorhexis after cataract extraction). There is also an increased risk of capsular and zonular tear.<sup>33</sup> As with laser procedures, increased risk of IOP spike and increased inflammation during the postoperative period is possible. Topical steroids may need to be used for a longer period of time in these patients, as prolonged inflammation is common.<sup>34</sup>

Another consideration for patients with XFG is the role of minimally invasive glaucoma surgery (MIGS), although very little data is available. One study showed that Trabectome (MicroSurgical Technology) surgery is as effective in XFG patients as it is in POAG patients with low preoperative IOP, thin central corneal thickness and no history of SLT.<sup>35</sup> Another study found that Trabectome surgery showed an overall greater IOP reduction to the mid-teens in XFG compared with POAG.<sup>36</sup> As with all XFG treatments, the effects may diminish sooner than other types of glaucoma, resulting in a rapid IOP rise. Trabeculectomy and tubes have also been found to be as effective in XFG management as in POAG.<sup>37</sup>

Due to the genetic etiology contributing to the systemic disease of XFS, gene therapy is on the horizon for possible treatment modalities. Two single nucleotide polymorphisms (SNPs) on the *LOXL1* gene account for nearly all XFS.<sup>30</sup>

Although not everyone with these SNPs will develop XFG, gene transfer by intraocular injection could be a viable option. This would represent the first treatment for glaucoma whose primary goal is to alter gene expression and not primarily decrease IOP. More study is needed on this exciting technology.

### Pigmentary Glaucoma

Pigment dispersion syndrome (PDS) is a degeneration of the iris caused by the physical contact of lens zonules against the posterior iris surface, resulting in a mechanical liberation of pigment. This pigment in the anterior chamber of the eye can obstruct the trabecular meshwork drainage system, eventually leading to increased IOP and pigmentary glaucoma.

Potential ocular signs include mid-peripheral iris transillumination defects, corneal endothelial pigment and heavy pigmentation of the trabecular meshwork.

PDS has an estimated prevalence of up to 2.45% in the United States, with a higher incidence in men than in women.<sup>38</sup> Men with PDS typically present in the third decade of life and women in the fourth decade. Myopia and white race are also risk factors for PDS. Genetic studies have determined a possible autosomal dominant inheritance pattern.<sup>39</sup>

A burn-out period can occur once the crystalline lens in the eye thickens with age, adjusting the zonular-iris contact area and preventing further pigment liberation.<sup>40</sup> The probability of development of PG from PDS is approximately 15% at 15 years, with young myopic men most likely to develop PG.<sup>41</sup>

Once a diagnosis of PG has been made, treatment is similar to that of POAG, with therapy

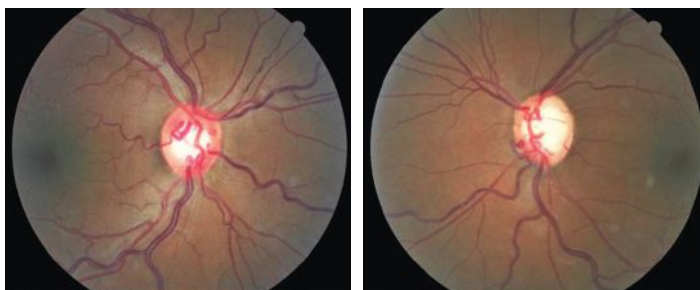


Fig. 5. Asymmetric cupping in a PG patient with hypertensive retinopathy.

targeted at lowering IOP through topical treatment, laser or surgical procedures.

### Other Secondary Glaucomas

In *uveitic glaucoma*, which affects up to 20% of patients with uveitis, the increase in IOP can be due to open-angle or closed-angle mechanisms.<sup>42</sup> Further complicating this situation, the common treatment for uveitis involves topical corticosteroids, which can induce increased outflow resistance.

The onset with uveitis can be rapid via trabecular meshwork inflammation or chronic due to fibroblastic infiltration with subsequent scar tissue formation obstructing the anterior chamber angle. The patient can present with high IOP from these mechanisms or low IOP due to decreased aqueous production by the inflamed ciliary body. Keratic precipitates, band keratopathy, nodules, peripheral anterior synechiae (diagnosed by gonioscopy), posterior synechiae and eventual neovascularization of the angle can be noted, along with the typical cell and flare of uveitis.

Treatment is aimed at discovering the underlying cause of uveitis and lowering the acutely raised IOP (if present) to prevent further optic nerve head (ONH) damage. Topical IOP-lowering agents should be considered first. While prostaglandins can be used, proceed with caution due to their role in the inflammatory pathway.<sup>43</sup>

If IOP remains uncontrolled with topical treatment, surgical intervention (drainage implant or trabeculectomy) is needed.<sup>44</sup> A recent study suggests Kahook Dual Blade (New World Medical) goniotomy might be helpful in managing these patients.<sup>45</sup>

*Traumatic glaucoma* often occurs due to recession of the anterior chamber angle after trauma. Angle recession is relatively common, with

### Optic Nerve Pathology in Chronic Angle-Closure Glaucoma

A 61-year-old white female was referred with a diagnosis of chronic angle-closure glaucoma, OD>OS. She had bilateral peripheral iridotomies a year prior. She was being medicated with Lumigan ((bimatoprost ophthalmic solution, Allergan) QHS OU.

Her IOPs were 25mm Hg OD and 21mm Hg OS. OCT revealed severe thinning of GCC and RNFL OD with minimal thinning OS. Visual fields were severely reduced OD and unremarkable OS. The right optic nerve exhibited significant cupping. Scheimpflug imaging revealed an anterior chamber depth of 2.35mm in the right eye with an angle opening distance at 700 $\mu$ m of 0.32 and 0.44 while the left eye was 2.39mm and 0.39 and 0.51, respectively (Figure 6).

We added Combigan (brimonidine/timolol, Allergan) BID OU and scheduled her for cataract surgery plus Kahook Dual Blade goniotomy.

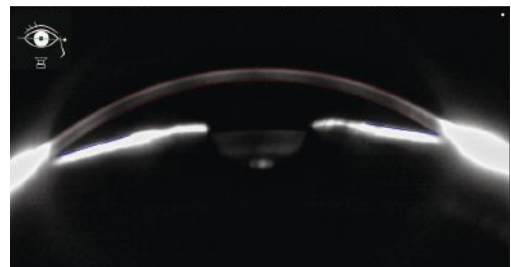
reports of it developing in up to 60% of eyes after non-penetrating or concussive trauma.<sup>46</sup>

Glaucoma can develop years or even decades after the initial injury. About 6.6% of eyes will develop glaucoma post trauma, which occurs more frequently in ocular contusions than in perforating injuries.<sup>47</sup>

Blunt force can cause an aqueous displacement, which eventually leads to tearing of the ciliary body muscles by traction on the iris root. Fibrotic tissue can then grow over the area of insult, leading to decreased outflow.<sup>48</sup>

While several factors can contribute to glaucoma developing in an angle recessed eye, increased degrees of recession (greater than 180 degrees) make glaucoma more likely. Other factors significantly associated with glaucoma following closed globe injury include increased pigmentation within the angle, elevated baseline IOP, hyphema and lens displacement.<sup>49</sup>

Gonioscopy is essential for examining the anterior chamber in search of areas of widening of the ciliary body band. Treatment is aimed at decreasing the elevated IOP to prevent ONH damage, and the clinical course can vary significantly depending on initial trauma. Topical IOP-lowering medications that suppress aqueous are preferred due to the



**Fig. 6. This Scheimpflug anterior segment image shows narrow angles in a chronic angle closure patient.**

likely compromise of the trabecular meshwork outflow pathway.<sup>50</sup>

*Lens-induced glaucoma*—both open-angle and closed-angle—can occur via several mechanisms. In phacolytic glaucoma, a rise in IOP with potential ONH damage can occur due to leakage of lens proteins of a mature cataract, causing an inflammatory reaction that leads to trabecular meshwork obstruction in an open angle.<sup>51</sup> Closed-angle lens-induced glaucoma can occur when the swollen and hardened lens causes angle closure by proximity or lens dislocation (i.e., phacomorphic glaucoma).<sup>52</sup>

Removal of a hypermature cataract can pose several risks, including lens-particle glaucoma where capsular disruption leads to leakage of lens particles into the anterior chamber, altering normal aqueous outflow.<sup>53</sup>

While lens-induced glaucoma may not be common in industrialized nations, it poses a significant risk in developing countries. This secondary



## Old Trauma Linked to Recent Rise in IOP

A 56-year-old white male was referred to the Glaucoma Institute of State College because of increasing IOP OS. He had a history of blunt trauma to the left eye 25 years prior. His IOP began to rise about five years before referral. He was taking Cosopt BID OS.

His IOPs that day were 21mm Hg OD and 22mm Hg OS. Pachymetry measurements were 548 $\mu$ m OD and 578 $\mu$ m OS, and corneal hysteresis was 14.1mm Hg OD and 13.2mm Hg OS. His maximum IOPs were 21mm Hg OD and 42mm Hg OS. OCTs and visual fields showed progression OS. Gonioscopy revealed mild angle recession OS. He had visually significant cataracts.

Cataract extraction OU with Kahook Dual Blade goniotomy OS was performed. His IOP is currently controlled in the low teens OU on 0.5% timolol QAM OS. His optic nerves and visual fields have been stable over the last two years.

developing countries. This secondary glaucoma affects up to an estimated 2.28 million in India, where the incidence of cataract cases far exceeds the total number of surgeries.<sup>54</sup>

Depending on the type of lens-induced glaucoma, several clinical findings may be observed. In phacolytic and lens-particle glaucoma, inflammation and white particles may be present in the anterior chamber along with corneal edema and synechiae. In phacomorphic glaucoma, a hypermature cataract is observed along with a closed angle and possible cell and flare.

Short-term treatment of this secondary glaucoma involves lowering the acutely raised IOP by topical medication (IOP-lowering medication and corticosteroids if inflammation is involved), with removal of the lens being the definitive treatment.

As optometrists continue to provide more glaucoma care, a proper understanding of the secondary glaucomas is paramount.

We have been trained to think that glaucoma is a long and slow process. But exfoliation glaucoma and pigmentary glaucoma can be aggressive. Aggressive glaucoma demands aggressive therapy. ■

*Dr. Cymbor is a partner at Nit-tany Eye Associates in State College, PA. He is co-director of the Glaucoma Institute of State College and a member of the Optometric Glaucoma Society.*

## Dr. Stiles is a Captain in the US Army and currently practicing in the Midwest.

- Wallace E, Lowry J, Smith SM, Fahey T. The epidemiology of malpractice claims in primary care: a systematic review. *BMJ Open*. 2013;3(7):2.
- Tarkkanen A, Kivela T, John G, Lindberg and the discovery of exfoliation syndrome. *Acta Ophthalmol Scand*. 2002;80(2):151-4.
- Tarkkanen A. Exfoliation Syndrome: A Historical Perspective. *J Glaucoma*. 2018;27(Suppl 1):S1-S3.
- Nazarali S, Damji F, Damji KF. What have we learned about exfoliation syndrome since its discovery by John Lindberg 100 years ago? *Br J Ophthalmol*. 2018;102(10):1342-50.
- Amarsson AM. Epidemiology of exfoliation syndrome in the Reykjavik Eye Study. *Acta Ophthalmol*. 2009;87(Thesis 3):1-17.
- Katsi V, Pavlidis AN, Kallistratos MS, et al. Cardiovascular repercussions of the pseudoexfoliation syndrome. *N Am J Med Sci*. 2013;5(8):454-9.
- Yildirim N, Yasar E, Gursoy H, Colak E. Prevalence of pseudoexfoliation syndrome and its association with ocular and systemic diseases in Eskisehir, Turkey. *Int J Ophthalmol*. 2017;10(1):128-34.
- De Groef L, Van Hove I, Dekeyser E, et al. MMPs in the trabecular meshwork: promising targets for future glaucoma therapies? *Invest Ophthalmol Vis Sci*. 2013;54(12):7756-63.
- Ritch R. Systemic Associations of Exfoliation Syndrome. *Asia Pac J Ophthalmol (Phila)*. 2016 Jan-Feb;5(1):45-50.
- Challa P. Genetics of pseudoexfoliation syndrome. *Curr Opin Ophthalmol*. 2009;20(2):88-91.
- Genetics Home Reference. LOXL1 gene. NIH US National Library of Medicine. <https://ghr.nlm.nih.gov/gene/LOXL1>. Accessed October 25, 2019.
- Wiggs JL, Pasquale LR. Expression and regulation of LOXL1 and elastin-related genes in eyes with exfoliation syndrome. *J Glaucoma*. 2014;23(8 Suppl 1):S62-3.
- Dewundara S, Pasquale LR. Exfoliation syndrome: a disease with an environmental component. *Curr Opin Ophthalmol*. 2015;26(2):78-81.
- Khawaja A. Pseudoexfoliative Glaucoma. EyeWiki. [http://eyewiki.aao.org/Pseudoexfoliative\\_Glaucoma](http://eyewiki.aao.org/Pseudoexfoliative_Glaucoma). Updated September 20, 2019. Accessed October 25, 2019.
- Plateroti P, Plateroti AM, Abdolrahimzadeh S, Scuderi G. Pseudoexfoliation syndrome and pseudoexfoliation glaucoma: a review of the literature with updates on surgical management. *J Ophthalmol*. 2015;2015:370371.
- Yaguchi S, Yaguchi S, Yagi-Yaguchi Y, et al. Objective classification of zonular weakness based on lens movement at the start of capsulorhexis. *PLoS One*. 2017;12(4):e0176169.
- Fontana L, Coassin M, Iovieno A, et al. Cataract surgery in patients with pseudoexfoliation syndrome: current updates. *Clin Ophthalmol*. 2017;11:1377-83.
- Calafati J, Tam DY, Ahmed IK. Pseudoexfoliation syndrome in cataract surgery. *EyeNet*. 2009;2009:37-9.
- Fingert JH, Burden JH, Wang K, et al. Circumferential iris trans-illumination defects in exfoliation syndrome. *J Glaucoma*. 2013;22(7):555-8.
- Rasmussen CA, Kaufman PL, Duehr PA, Barány EH. The trabecular meshwork in normal eyes and in exfoliation glaucoma. *J Glaucoma*. 2014;23(8 Suppl 1):S15-9.
- Desai MA, Lee RK. The medical and surgical management of pseudoexfoliation glaucoma. *Int Ophthalmol Clin*. 2008;48(4):95-113.
- Kim S, Sung KR, Lee JR, Lee KS. Evaluation of lamina cribrosa in pseudoexfoliation syndrome using spectral-domain optical coherence tomography enhanced depth imaging. *Ophthalmology*. 2013;120(9):1798-803.
- Tomaszewski BT, Zaleska R, Mariak Z. Evaluation of the endothelial cell density and the central corneal thickness in pseudoexfoliation syndrome and pseudoexfoliation glaucoma. *J Ophthalmol*. 2014;2014:123683.
- Andrikopoulos GK, Alexopoulos DK, Gartaganis SP. Pseudoexfoliation syndrome and cardiovascular diseases. *World J Cardiol*. 2014;6(8):847-54.
- Mitchell P, Wang JJ, Smith W. Association of pseudoexfoliation syndrome with increased vascular risk. *Am J Ophthalmol*. 1997;124(5):685-7.
- Gonen KA, Gonen T, Gurnus B. Renal artery stenosis and abdominal aorta aneurysm in patients with pseudoexfoliation syndrome. *Eye (Lond)*. 2013;27(6):735-41.
- Schlötzer-Schrehardt UM, Koca MR, Naumann GO, Volkholz H. Pseudoexfoliation syndrome ocular manifestation of a systemic disorder? *Arch Ophthalmol*. 1992;110(12):1752-6.
- Cumurcu T, Dorak F, Cumurcu BE, et al. Is there any relation between pseudoexfoliation syndrome and Alzheimer's type dementia? *Semin Ophthalmol*. 2013;28(4):224-9.
- Elshafei AM, El-Badry MM. Association between pseudoexfoliation syndrome and sensorineural hearing loss. *J Egypt Ophthalmol Soc*. 2015;108(2):92.
- Angellilli A, Ritch R. Directed therapy: An approach to the improved treatment of exfoliation syndrome. *Middle East Afr J Ophthalmol*. 2009;16(1):35-40.
- Hodge WG, Damji KF, Rock W, et al. SLT vs ALT in patients with pseudoexfoliation syndrome. *Invest Ophthalmol Vis Sci*. 2003;44(13):2183.
- Holló G, Katsanos A, Konstas AG. Management of exfoliative glaucoma: challenges and solutions. *Clin Ophthalmol*. 2015 May;9:907-19.
- Mohammadpour M, Erfanian R, Karimi N. Capsulorhexis: pearls and pitfalls. *Saudi J Ophthalmol*. 2012;26(1):33-40.
- Sangal N, Chen TC. Cataract surgery in pseudoexfoliation syndrome. *Semin Ophthalmol*. 2014;29(5-6):403-8.
- Tojo N, Abe S, Hayashi A. Factors that influence of trabectome surgery for glaucoma patients. *J Glaucoma*. 2017;26(9):835-44.
- Ting JL, Damji KF, Stiles MC; Trabectome Study Group. Ab interno trabectectomy: outcomes in exfoliation versus primary open-angle glaucoma. *J Cataract Refract Surg*. 2012;38(2):315-23.
- Peltili Gürlü V, Güçlü H, Özal A, et al. Comparison of long-term results of trabectectomy to treat pseudoexfoliative glaucoma and primary open angle glaucoma. *Int J Ophthalmol*. 2018;11(1):66-70.
- Lahola-Chomiak AA, Walter MA. Molecular Genetics of Pigment Dispersion Syndrome and Pigmentary Glaucoma: New Insights into Mechanisms. *J Ophthalmol*. 2018;2018:5926906.
- Ramulu PM. Pigmentary glaucoma and Pigment Dispersion Syndrome. EyeWiki. [http://eyewiki.aao.org/Pigmentary\\_glaucoma\\_and\\_Pigment\\_Dispersion\\_Syndrome](http://eyewiki.aao.org/Pigmentary_glaucoma_and_Pigment_Dispersion_Syndrome). Updated June 11, 2019. Accessed October 25, 2019.
- Hager J, Alward W. Pigmentary Glaucoma: 24-year-old male with episodic halos around lights and blurry vision. *EyeRounds.org*. <http://webeve.ophth.uiowa.edu/eyeforum/cases/184-pigmentary-glaucoma.htm>. February 2, 2014. Accessed October 25, 2019.
- Siddiqui Y, Ten Hulzen RD, Cameron JD, et al. What is the risk of developing pigmentary glaucoma from pigment dispersion syndrome? *Am J Ophthalmol*. 2003;135(6):794-9.
- Eliassi-Rad B, Francis A. Uveitic Glaucoma. EyeWiki. [https://eyewiki.aao.org/Uveitic\\_Glaucoma](https://eyewiki.aao.org/Uveitic_Glaucoma). June 21, 2019. Accessed October 25, 2019.
- Taylor SR, Gurbaxani A, Salim A, Lightman S. Topical prostaglandin analogues and conjunctival inflammation in uveitic glaucoma. *Open Ophthalmol J*. 2012;6:75-8.
- Kwon HJ, Kong YX, Tao LW, et al. Surgical outcomes of trabectectomy and glaucoma drainage implant for uveitic glaucoma and relationship with uveitis activity. *Clin Exp Ophthalmol*. 2017;45(5):472-480.
- Miller VJ, Young CE, SooHoo JR, et al. Efficacy of Goniotomy with Kahook Dual Blade in Patients with Uveitis-associated Ocular Hypertension. *J Glaucoma*. 2019;28(8):744-748.
- Herschler J. Trabecular damage due to blunt anterior segment injury and its relationship to traumatic glaucoma. *Trans Sect Ophthalmol Am Acad Ophthalmol Otolaryngol*. 1977;83(2):239-48.
- Stani R, Stani R. Traumatic glaucoma. *Coil Antropol*. 2001;25(Suppl):101-4.
- Brenner J. Angle Recession Glaucoma. EyeWiki. [https://eyewiki.aao.org/Angle\\_Recession\\_Glaucoma](https://eyewiki.aao.org/Angle_Recession_Glaucoma). Updated August 30, 2019. Accessed October 25, 2019.
- Shiota R, Sood NN, Agarwal HC. Traumatic glaucoma. *Acta Ophthalmol Scand*. 1995;73(3):252-4.
- Clement CI, Goldberg I. The management of complicated glaucoma. *Indian J Ophthalmol*. 2011;59(Suppl):S141-7.
- Dhingra D, Grover S, Kapadia G, et al. Phacolytic glaucoma: A nearly forgotten entity. *European Eur J Ophthalmol*. 2019;1120672119841972.
- Mehta S, Hooda A, Mehta M. A study of clinical profile of phacomorphic glaucoma and its management outcome. *Paripex-Indian J Res*. 2019;8(3):13-14.
- Luna G, Eliassi-Rad B. Lens Induced Glaucomas. EyeWiki. [https://eyewiki.aao.org/Lens\\_Induced\\_Glaucomas](https://eyewiki.aao.org/Lens_Induced_Glaucomas). Updated June 21, 2019. Accessed October 25, 2019.
- Peram V, Atti S, Paspula R, et al. Clinical types, IOP control and visual outcome in lens induced glaucoma. *J Evol Med Dent Sci*. 2015 Nov 16;4(92):15798-801.

## OSC QUIZ

**Y**ou can obtain continuing education credit through the Optometric Study Center. Complete the test form and return it with the \$35 fee to: Jobson Healthcare Information, LLC, Attn.: CE Processing, 395 Hudson Street, 3rd Floor New York, New York 10014. To be eligible, please return the card within three years of publication. You can also access the test form and submit your answers and payment via credit card at *Review Education Group* online, [www.reviewscce.com](http://www.reviewscce.com).

You must achieve a score of 70 or higher to receive credit. Allow four weeks for processing. For each Optometric Study Center course you pass, you earn 2 hours of credit from Pennsylvania College of Optometry.

Please check with your state licensing board to see if this approval counts toward your CE requirement for relicensure.

- Worldwide, exfoliation affects:
  - 10 billion people.
  - 50 million people.
  - 70 million people.
  - 111 million people.
- What percentage of patients with exfoliation syndrome develop glaucoma?
  - 5% to 8%.
  - 20% to 25%.
  - 30% to 50%.
  - 90% to 100%.
- Exfoliation has been linked with which of the following diseases?
  - Dementia.
  - Cardiovascular disease.
  - Kidney disease.
  - All of the above.
- Exfoliation deposits are caused by an imbalance of:
  - Peptides.
  - Glutamate.
  - Matrix metalloproteinases.
  - Tricarboxylic acid.
- Which gene has the strongest association with exfoliation?
  - LOXL1.
  - LOXL3.
  - LOXL5.
  - LOXL9.
- Which of the following is associated with a higher risk of exfoliation?
  - High caffeine intake.
  - High NSAID intake.
  - Deodorants containing aluminum.
  - Consuming red M&Ms.
- Which of the following is a sign of zonular weakness caused by exfoliation?
  - Shallow anterior chamber.
  - Phacodonesis.
  - Plateau iris.
  - a and b.
- In a patient with exfoliation, the appearance of the trabecular meshwork during gonioscopy resembles:
  - Newly fallen snow.
  - Brown sugar.
  - Seidel's sign.
  - T sign.
- Exfoliation may raise the risk of which of the following complications?
  - Cystoid macular edema.
  - Vitreous hemorrhage.
  - Corneal decompensation.
  - Corneal verticillata.
- Which of the following is an effective treatment for exfoliation glaucoma?
  - Lutein and zeaxanthin.
  - Prostaglandins.
  - Selective laser trabeculoplasty.
  - b and c.
- Which of the following is not commonly found in pigment dispersion syndrome and pigmentary glaucoma?
  - Mid-peripheral iris transillumination defects.
  - Bull's eye pattern on anterior lens surface.
  - Corneal endothelial pigment deposition.
  - Heavy pigmentation of the trabecular meshwork.
- All of the following are true about pigment dispersion syndrome, *except*:
  - Favors the male population.
  - Genetic studies show a possible autosomal dominance inheritance pattern.
  - Hyperopia is a risk factor.
  - A burn-out period can occur once the lens begins to thicken with age.
- Which of the following treatment options should be considered in pigmentary glaucoma?
  - Topical treatment.
  - Selective laser trabeculoplasty.
  - Trabeculectomy.
  - All of the above.
- Which class of topical ocular medication can further complicate the treatment of uveitic glaucoma?
  - Corticosteroids.
  - NSAIDs.
  - Aminoglycosides.
  - Beta blockers.
- Which of the following is true of uveitic glaucoma?
  - The patient always presents with raised IOP.
  - Uveitic glaucoma only occurs due to closed-angle mechanisms.
  - Identifying the underlying cause of uveitis is the focus of treatment.
  - Uveitic glaucoma only occurs within the first three months of the initial episode.
- All of the following factors are associated with an increased risk of traumatic glaucoma following closed globe injury, *except*:
  - Increased pigmentation within the angle.
  - Elevated baseline IOP.
  - Hyphema.
  - Presence of corneal epithelial defect.
- Which procedure is imperative when ruling out traumatic glaucoma?
  - Gonioscopy.
  - Corneal endothelial cell count.
  - Red cap desaturation test.
  - Ishihara color vision testing.
- Which of the following lens-induced glaucoma mechanisms occur due to leakage of lens particles into the anterior chamber during cataract surgery?
  - Lens-particle.
  - Phacomorphic.
  - Phacolytic.
  - Subluxation.
- Which of the following is true regarding lens-induced glaucoma?
  - It poses a significant risk to vision in developing nations.
  - Inflammatory processes are never involved.
  - Topical medication should not be considered to lower IOP.
  - It occurs via one mechanism.
- Which of the following is considered the definitive treatment for lens-induced glaucoma?
  - Topical prostaglandins.
  - Trabeculectomy.
  - Lens removal.
  - Peripheral iridotomy.

# Examination Answer Sheet

## Overcoming Secondary Glaucomas

Valid for credit through November 15, 2022

**Online:** This exam can be taken online at [www.reviewsce.com](http://www.reviewsce.com). Upon passing the exam, you can view your results immediately and download a real-time CE certificate. You can also view your test history at any time from the website.

**Directions:** Select one answer for each question in the exam and completely darken the appropriate circle. A minimum score of 70% is required to earn credit.

**Mail to:** Jobson Healthcare Information, LLC, Attn.: CE Processing, 395 Hudson Street, 3rd Floor New York, New York 10014

**Payment:** Remit \$35 with this exam. Make check payable to Jobson Healthcare Information, LLC.

**Credit:** This course is COPE approved for 2 hours of CE credit. Course ID is 65237-GL.

**Jointly provided by Postgraduate Institute for Medicine and Review Education Group.**

**Salus University has sponsored the review and approval of this activity.**

**Processing:** There is a four-week processing time for this exam.

**Answers to CE exam:**

1. (A) (B) (C) (D)
2. (A) (B) (C) (D)
3. (A) (B) (C) (D)
4. (A) (B) (C) (D)
5. (A) (B) (C) (D)
6. (A) (B) (C) (D)
7. (A) (B) (C) (D)
8. (A) (B) (C) (D)
9. (A) (B) (C) (D)
10. (A) (B) (C) (D)
11. (A) (B) (C) (D)
12. (A) (B) (C) (D)
13. (A) (B) (C) (D)
14. (A) (B) (C) (D)
15. (A) (B) (C) (D)
16. (A) (B) (C) (D)
17. (A) (B) (C) (D)
18. (A) (B) (C) (D)
19. (A) (B) (C) (D)
20. (A) (B) (C) (D)

**Post-activity evaluation questions:**

Rate how well the activity supported your achievement of these learning objectives:

1=Poor, 2=Fair, 3=Neutral, 4=Good, 5=Excellent

21. Describe the fundamental differences between primary and secondary glaucoma. ① ② ③ ④ ⑤
22. Identify the presentation of various forms of secondary glaucomas. ① ② ③ ④ ⑤
23. Perform the necessary elements of the patient history, ocular examination/vision testing as well as diagnostic testing and/or imaging, and any other ocular or systemic evaluation required to diagnose secondary glaucomas. ① ② ③ ④ ⑤
24. Provide, or otherwise obtain, the ocular and systemic treatment that the patient requires. ① ② ③ ④ ⑤
25. Based upon your participation in this activity, do you intend to change your practice behavior? (choose only one of the following options)
  - (A) I do plan to implement changes in my practice based on the information presented.
  - (B) My current practice has been reinforced by the information presented.
  - (C) I need more information before I will change my practice.
26. Thinking about how your participation in this activity will influence your patient care, how many of your patients are likely to benefit? (please use a number):

27. If you plan to change your practice behavior, what type of changes do you plan to implement? (check all that apply)

- (a) Apply latest guidelines (b) Change in pharmaceutical therapy (c) Choice of treatment/management approach
- (d) Change in current practice for referral (e) Change in non-pharmaceutical therapy (f) Change in differential diagnosis (g) Change in diagnostic testing (h) Other, please specify: \_\_\_\_\_

28. How confident are you that you will be able to make your intended changes?

- (a) Very confident (b) Somewhat confident (c) Unsure (d) Not confident

Please retain a copy for your records. Please print clearly.

First Name

Last Name

E-Mail

The following is your:  Home Address  Business Address

Business Name

Address

City  State

ZIP

Telephone #  -  -

Fax #  -  -

By submitting this answer sheet, I certify that I have read the lesson in its entirety and completed the self-assessment exam personally based on the material presented. I have not obtained the answers to this exam by any fraudulent or improper means.

Signature \_\_\_\_\_ Date \_\_\_\_\_

Lesson 118894

RO-OSC-1119

29. Which of the following do you anticipate will be the primary barrier to implementing these changes?

- (a) Formulary restrictions
- (b) Time constraints
- (c) System constraints
- (d) Insurance/financial issues
- (e) Lack of interprofessional team support
- (f) Treatment related adverse events
- (g) Patient adherence/compliance
- (h) Other, please specify: \_\_\_\_\_

30. Additional comments on this course:

\_\_\_\_\_

\_\_\_\_\_

\_\_\_\_\_

\_\_\_\_\_

Rate the quality of the material provided:

1=Strongly disagree, 2=Somewhat disagree, 3=Neutral, 4=Somewhat agree, 5=Strongly agree

31. The content was evidence-based.

- ① ② ③ ④ ⑤

32. The content was balanced and free of bias.

- ① ② ③ ④ ⑤

33. The presentation was clear and effective.

- ① ② ③ ④ ⑤



A large, stylized graphic of the number '20/20' is the central focus. The '20' is rendered in a vibrant magenta color, while the '/20' is in a bright blue. The numbers are set against a background of a dense, colorful grid of lines that create a 3D, tunnel-like effect. The grid lines transition through a spectrum of colors including yellow, green, cyan, and blue. A thin vertical line with small circles at the top and bottom bisects the graphic.

**SECO 20/20**

WHERE SIGHT MEETS VISION™  
**MARCH 4-8 | ATLANTA, GA**

A  
**PERFECT  
VIEW**  
OF WHAT'S AHEAD

Forget hindsight—this year, it's foresight that's 20/20. Get a first look at the research, technology and techniques that are evolving patient care and propelling the optometric profession forward. Whether you're looking for the latest in clinical advancements or considering a paperless practice, you'll find the speakers, education, solutions and connections you need to stay on the cutting edge.

**REGISTER TODAY**

[attendseco.com](https://attendseco.com) | [#SECO2020](https://twitter.com/SECO2020)

**think**about  
your**eyes**.com

Brought to you by the AOA  
AMERICAN OPTOMETRIC ASSOCIATION

There's an entire network of your peers and partners working to improve the health of the optical industry and spread the word about the importance of annual comprehensive eye exams.



**3.95 Million** Eye Exams

**24,000+** Eye Care Professionals

**18** Industry Supporters

**ARE YOU IN?**



FIND OUT HERE:

[thevisioncouncil.org/AreYouIn](http://thevisioncouncil.org/AreYouIn)

**Alcon**  
a Novartis company

  
essilor

*Johnson & Johnson* VISION

**LXOTICA**

 AMERICAN OPTOMETRIC ASSOCIATION

 THEVISIONCOUNCIL

**ALL ABOUT VISION!**

 Compliance Group

 ESCHENBACH

**FVMG**  
FIRST VISION MEDIA GROUP

**GUNNAR**

**HILCOVISION**  
Creating Better Optical Solutions since 1982

*Jobson*  
Optical Group



  
Optelec  
a VEO COMPANY

  
SHAMIR

specialeyes 

Transitions  
Light intelligent lenses

**VISION EXPO**

  
WALMAN

**WestGroup**



# Proceed With Caution

Dupixent is worth prescribing to eczema patients, but be on the lookout for associated ocular surface problems and know how to react if they present.

Edited by Joseph P. Shovlin, OD

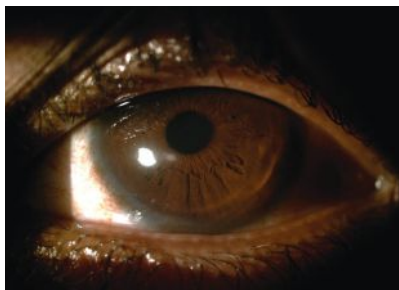**Q** I have a keratoconus patient with severe eczema who may start Dupixent (dupilumab, Sanofi and Regeneron). However, the drug is associated with ocular surface problems. Should his dermatologist prescribe it to him despite the risks? If so, what does the management process look like and how are the ocular side effects best treated?

**A** Dupixent is a monoclonal antibody that inhibits IL-4 and IL-13 signaling, targeting inflammation in cases of atopic dermatitis (AD), or eczema.<sup>1</sup> Patients with AD are predisposed to conjunctivitis and keratoconus.<sup>2,3</sup>

“Dupixent has fairly typical potential side effects relative to the injection itself,” says Jim Thimons, OD, medical director and founding partner of Ophthalmic Consultants of Connecticut. Dr. Thimons notes that the main issue that must be on every OD’s radar is ocular side effects (conjunctivitis and keratitis).

## Conjunctival Obstacles

Surajit Saha, MD, a cornea, cataract and refractive surgeon of OCLI in New York, says the pathogenesis of conjunctivitis in AD patients receiving dupilumab has not yet been established. He notes that one hypothesis contends that blocking IL-4 and IL-13 from binding to their receptors leads to increased activity of ligands involved in atopic keratoconjunctivitis.



Severe keratoconus without scarring.

Dr. Thimons says ocular surface problems usually clear up well with topical steroid therapy. Treatment with fluorometholone 0.1% eye drops or tacrolimus 0.03% eye ointment is generally successful.<sup>4</sup> A study evaluating AD patients treated with dupilumab found that mild, non-specific conjunctivitis with evaporative dry eye can be treated with warm compresses and preservative-free artificial tears.<sup>5</sup> Dr. Saha adds that severe follicular conjunctivitis, on the other hand, can be managed with dexamethasone eye drops and artificial tears. He notes that discontinuing dupilumab is rarely necessary to facilitate the resolution of conjunctivitis.

“The response on the conjunctivitis side has been relatively mild and easily managed, so discontinuation of the drug isn’t usually necessary,” according to Dr. Thimons. He adds that severe eczema patients have very few treatment options available to them, so Dupixent is usually always worth trying.

## Drug Management

Dr. Saha notes that Dupixent is indicated for patients at least 12 years old with moderate to severe AD who are not getting adequate control of their disease with topical medications. He says some of these patients may have preexisting conjunctivitis, keratoconus or dry eye.

Dr. Thimons recommends documenting the appearance of lid tissue prior to initiating Dupixent, observing and intervening if necessary.

For comanaging, Dr. Saha advises consultation with an eye care provider prior to starting a patient on Dupixent to optimize the ocular surface. If the patient has keratoconus, he suggests referring them to a cornea specialist. If the patient develops an ocular surface disease, the prescribing physician should coordinate with an eye doctor.

“In general, Dupixent can be continued while the ocular surface disease is usually successfully treated with topical corticosteroids and artificial tears,” Dr. Saha concludes. ■

1. Dupixent. [www.dupixenthcp.com/](http://www.dupixenthcp.com/). Accessed October 15, 2019.
2. CA Maguire, E Hollick, R Morris-Jones. Keratoconus: an important ophthalmological complication of atopic dermatitis. *J Am Acad Dermatol*. 2017;76(6):AB421.
3. Thyssen JP, de Bruin-Weller MS, Paller AS, et al. Conjunctivitis in atopic dermatitis patients with and without dupilumab therapy—international eczema council survey and opinion. *J Eur Acad Dermatol Venereol*. 2019;33(7):1224-31.
4. Wollenberg A, Ariens L, Thurau S, et al. Conjunctivitis occurring in atopic dermatitis patients treated with dupilumab—clinical characteristics and treatment. *J Allergy Clin Immunol Pract*. 2018;6(5):1778-80.
5. Maudinet A, Law-Koune S, Duretz C, et al. Ocular surface diseases induced by dupilumab in severe atopic dermatitis. *Ophthalmol Ther*. 2019;8(3):485-90.





# Find Infectious Keratitis's Root

Treatment is dependent upon the cause of the issue. It's on you to identify it.

By Delaney Kent, OD, and Richard Mangan, OD

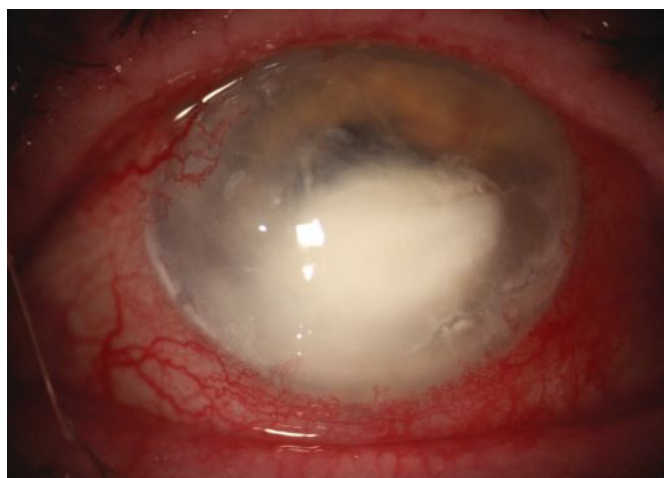**I**nfectious keratitis—a common cause of visual impairment—occurs when the cornea's integrity is compromised by a bacteria, fungus, virus or parasite. In the United States and other developed countries, these infections are typically associated with contact lens use or poor lid hygiene.<sup>1</sup> Ocular trauma involving vegetative or organic matter is more common in underdeveloped areas.<sup>1-3</sup> Identifying the causative microorganism in a case of infectious keratitis is essential for initiating the most efficacious topical treatment and eventual resolution of the infection.

Here we review the differential diagnoses of the different kinds of infectious keratitis and treatment options through a real-world case example.

## Patient History

A 51-year-old Caucasian female presented with a painful, photophobic right eye. She had a history of extended soft contact lens wear and denied any previous incidence of trauma. One week prior, an optometrist had diagnosed her with a corneal ulcer of unknown etiology and initiated treatment with Tobradex ST (tobramycin and dexamethasone, Eyevance). After an exacerbation of symptoms and a second local opinion, the patient was referred to our clinic for further evaluation.

At her initial visit, her best-corrected visual acuities (BCVA) were 20/50 OD and 20/25 OS. Slit lamp examination of the right



This image shows a bacterial ulcer caused by the gram-negative rod *Serratia marcescens*.

eye revealed a 1.5mm by 1.5mm epithelial defect overlying a similarly sized infiltrate. The anterior chamber contained few rare cells, but no hypopyon was noted. Pupils, extraocular motility and intraocular pressures (IOP) were normal. Clinical examination of the left eye was unremarkable.

We diagnosed the patient with a presumed bacterial central corneal ulcer and determined it was likely related to soft contact lens wear based on the patient's case history. We decided to hold off on culturing because the ulcer had already been treated with antibiotics. At her initial visit with us, the patient was using Vigamox (moxifloxacin, Novartis) four times a day in her right eye. We increased her dosage to once every hour around the clock and expressed the importance of monitoring the condition closely over the next few days.

On follow up, the BCVA of her right eye had reduced to 20/500.

Slit lamp examination of the right eye showed that the infiltrate had nearly doubled in size with the overlying epithelial defect measuring 3mm by 3mm. Diffuse corneal edema was now surrounding the central lesion. We performed a corneal culture and prescribed fortified tobramycin along with fortified cefazolin to be alternated every hour around the clock. The patient was asked to return in 24 hours.

## Searching for a Cause

Being the most common etiology of infectious keratitis, bacterial ulcers are most often related to contact lens use.<sup>1,3</sup> These ulcers typically present with well-defined, dense infiltrates that coincide with similarly sized epithelial defects. Extensive conjunctival injection, mucopurulent discharge and an anterior chamber reaction are common signs.

On the contrary, fungal keratitis typically presents with a feather-like

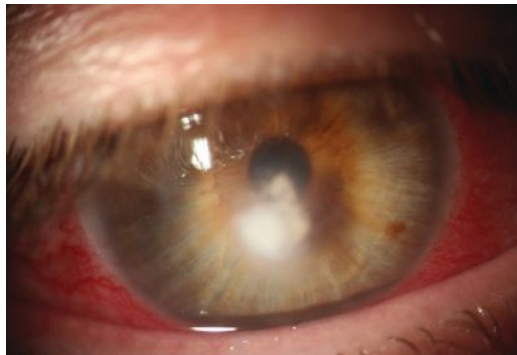
infiltrate with poorly defined borders. These infiltrates may have overlying epithelial defects; however, it is not uncommon for fungal infections to have closed or even heaped epithelium overlying the infiltrate. Satellite lesions located around the main lesion are also a good indication of possible fungal etiology.<sup>2</sup>

For our patient, the case history did not align with a typical fungal onset. A clinical red flag occurred when her condition remained unresponsive to aggressive, broad-spectrum antimicrobial treatment alone. The culture results confirmed some type of fungal etiology, but the exact microorganism could not be identified at first. Due to the patient's location, she was unable to locally fill a prescription for Natacyn (natamycin, Eyevance), so we started fortified voriconazole therapy as an alternative.

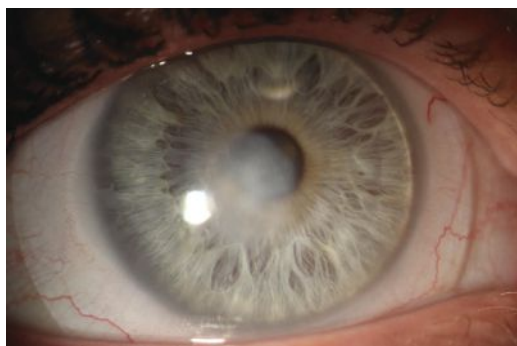### Diagnostic Techniques

Corneal culture should be performed when the infected area is large (>1mm to 2mm), centrally located and worsens after initial treatment. Sabouraud's agar and fungal smear microscope slides are best at demonstrating fungal growth, while blood and chocolate agar are typically used for bacteria. Gram stains are also helpful in determining bacterial causes.

Avoiding the eyelids and eyelashes while performing a culture will decrease the risk of potential contamination. If the epithelium is closed, debridement is recommended to access the infiltrative area where active invasion is occurring.<sup>1-5</sup> Research shows that infectious keratitis should be treated as bacterial until a fungal etiology can



**The feather-like borders of this lesion are indicative of a fungal ulcer.**



**This cornea shows a central depressed opacity after the resolution of a fungal ulcer. Note the scleral lens.**

be confirmed.<sup>2,3</sup> Primary reasoning supporting this approach is due to the high toxicity of topical antifungal agents to the cornea.

Currently, the only topical antifungal commercially available is Natacyn. Any other topical antifungal must be made by a compounding pharmacy. Sometimes geographic location, cost and limited resources make obtaining appropriate medications challenging.

Knowing the type of microorganism that caused the infection is critical in prescribing the most effective treatment.<sup>3</sup> According to the Mycotic Ulcer Treatment Trial (MUTT) I, natamycin was more efficacious in treating filamentous fungal keratitis, particularly *Fusarium*, over topical voriconazole.<sup>6</sup> Amphotericin B is another compounded alternative treatment that is beneficial in treating kera-

titis caused by *Candida*.<sup>5</sup> Oral antifungals like voriconazole may be added as adjunctive therapy; however, the MUTT II trial determined that it is not a superior alternative for faster resolution.<sup>7</sup>

After four months of topical antifungal treatment, copious artificial tears and a lot of patience, our patient's fungal infection resolved. On final examination, a large depressed central corneal opacity remained. After a specialty contact lens fitting, our patient's BCVA was 20/20 with her scleral lens and she was pleased with her vision. Although infectious keratitis seems daunting at first, careful case history and proper corneal culturing are the most simple and important aspects to guide the management of infectious keratitis. ■

*Dr. Delaney Kent completed a residency in refractive surgery and ocular disease at Vance Thompson Vision in South Dakota. She currently practices at Chu Vision Institute in Bloomington, MN.*

1. Austin A, Lietman T, Rose-Nussbaumer J. Update on the management of infectious keratitis. *Ophthalmol*. 2017;124(11):1678-89.
2. Tanure MA, Cohen EJ, Sudesh S, et al. Spectrum of fungal keratitis at Wills Eye Hospital, Philadelphia, Pennsylvania. *Cornea*. 2000;19:307-12.
3. Ray KJ, Prajna L, Srinivasan M, et al. Fluoroquinolone treatment and susceptibility of isolates from bacterial keratitis. *JAMA Ophthalmol*. 2013;131(3):310-3.
4. Alfonso EC, Rosa RH. Fungal keratitis. In: Krachmer JH, Mannis MJ, Holland EJ, eds. *Cornea and external diseases: clinical diagnosis and management*. St Louis: Mosby, 1997:1253-66.
5. O'Day, D.M., Head, W.S., Robinson, R.D., and Clanton, J.A. Corneal penetration of topical amphotericin B and natamycin. *Curr Eye Res*. 1986;5:877-82.
6. Prajna NV, Krishnan T, Mascarenhas J, et al. The mycotic ulcer treatment trial: a randomized trial comparing natamycin vs. voriconazole. *JAMA Ophthalmol*. 2013;131:422-9.
7. Prajna NV, Krishnan T, Rajaraman R, et al. Adjunctive Oral Voriconazole Treatment of Fusarium Keratitis: A Secondary Analysis From the Mycotic Ulcer Treatment Trial II. *JAMA Ophthalmol*. 2017;135(6):520-5.
8. Deorukhkar S, Katiyar R, Saini S. Epidemiological features and laboratory results of bacterial and fungal keratitis: a five year study at a rural tertiary-care hospital in western Maharashtra, India. *Singapore Med J*. 2012;53:264-67.



# Common Tumor, Unlikely Location

Lymphoma may present anywhere in the body but is rare in the eye.

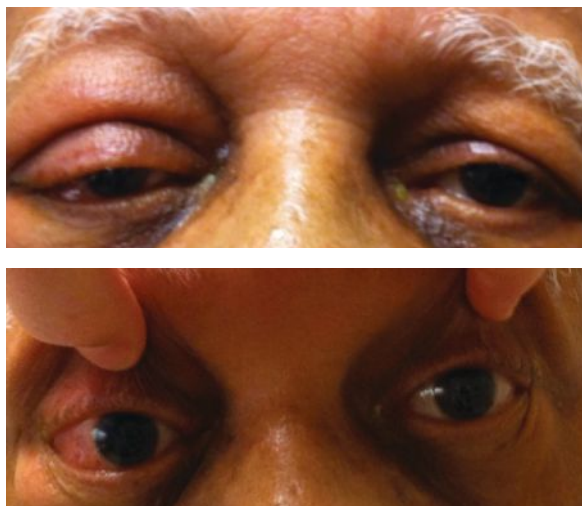
By Carlo J. Pelino, OD, and Joseph J. Pizzimenti, OD

A 69-year-old African-American male presented emergently with painless, marked swelling and redness of the right eye (*Figure 1*). His history was positive for long-standing hypertension and non-Hodgkin's lymphoma (NHL), which he said has been in remission for eight years.

The patient's pinhole visual acuities measured 20/30 OD and 20/30 OS. No afferent pupillary defect was present. Extraocular movement was limited in the right eye, which appeared proptotic (*Figure 2*). Exophthalmometer findings measured 25mm OD and 21mm OS with a base of 110mm. Given these findings, his differential diagnosis included:

- Orbital tumor
- Idiopathic orbital inflammatory pseudotumor
- Thyroid eye disease
- Preseptal/orbital cellulitis
- Orbital mucocele
- Dacryoadenitis

We immediately ordered blood work to test blood urea nitrogen and creatinine followed by an MRI of the brain and orbits with contrast. The MRI revealed a thickened mass located in the right lacrimal gland. The patient underwent an anterior orbitotomy and a biopsy of the mass, which revealed a malignant neoplasm consistent with mature B-cell lymphoma.



**Fig. 1.** This patient has marked chemosis and hyperemia in his proptotic right eye.

## Discussion

Lymphocytes—white blood cells—are one of the body's main types of immune cells. They are produced in the bone marrow and found in blood and lymph tissue. The two most common kinds are B-lymphocytes (B-cells) and T-lymphocytes (T-cells). B-cells make antibodies, and T-cells kill tumor cells and control immune responses.<sup>1</sup>

Malignant lymphomas are neoplasms derived from clonal (i.e., unicellular in origin) proliferations of lymphocytes. More than 70 different types of lymphoma exist, ranging from indolent (slow growing) to highly aggressive.<sup>1</sup> Lymphoma may be primary or secondary to systemic disease.<sup>1,2</sup> While lymphoma can have sight-threatening implications, it is often treatable when caught early and treated aggressively.

## Neoplastic Disease Refresher

The American Cancer Society defines cancer (or carcinoma) as a group of diseases characterized by uncontrolled cell growth and abnormal cell spread.<sup>3</sup> Cancer has the capacity to invade surrounding normal tissue, metastasize and kill the host. Neoplasia is the process of abnormal growth that starts from a single altered cell.<sup>4</sup>

Uncontrolled proliferation happens when genes controlling cellular growth no longer function properly.

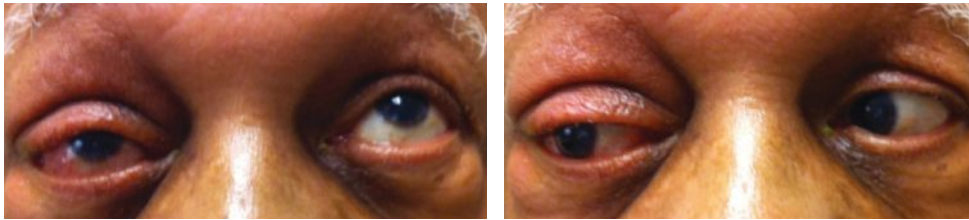
The lymphocytes then grow uncontrollably, multiply abnormally or live longer than they should.<sup>2,6</sup> This is when lymphoma occurs.

Benign neoplasms cannot spread by invasion or metastasis—they only grow locally. Malignant neoplasms, on the other hand, can.<sup>4,5</sup> These cells must first develop the capacity to cause invasive destruction before they can metastasize.<sup>5,6</sup> By definition, the term *cancer* applies only to malignant tumors.

## Lymphoma and the Eye

Lymphoma is categorized as either NHL or Hodgkin's lymphoma (HL). In the United States, the lifetime risks of NHL and HL are 2.1% and 0.2%, respectively.<sup>1,2</sup> B cell lymphoma is far more common than T-cell lymphoma and accounts for about 80% of all NHL cases.<sup>2</sup> Lymphomas involving the eye can





**Fig. 2.** Here, you can see our patient's slight limitation on extraocular movement.

be divided into three broad groups: uveal, vitreoretinal and ocular adnexal.<sup>2,7</sup> Each type differs in its clinical presentation, diagnosis, treatment and outcome.

A lymphoma located inside the eye that does not involve extraocular tissue is termed intraocular. Almost all intraocular lymphomas are of the NHL type, and the vast majority are of B-cell origin. Intraocular lymphoma has two distinct forms: one that arises inside the central nervous system (CNS), including the retina, and one that arises outside the CNS, with intraocular metastasis.<sup>2,7</sup> The former, also called primary CNS lymphoma (PCNSL), is far more prevalent than the latter and is well documented.<sup>2</sup> PCNSL involves the retina, vitreous or optic nerve head. Ocular symptoms include blurred vision, floaters and decreased visual acuity. Primary intraocular lymphoma, a subset of PCNSL, may present with or without simultaneous CNS involvement.<sup>2,7</sup>

Ocular adnexal lymphomas may present on or within the lids, conjunctiva, orbit, lacrimal gland or lacrimal sac. Lymphoma is the most prevalent orbital neoplasm in adults aged 60 or older.<sup>8</sup> Lacrimal gland lymphoma is relatively rare, representing 7% to 26% of all ocular adnexal lymphomas.<sup>2,7,9</sup>

## Diagnosis and Management

As our case highlights, the list of differential diagnoses for an orbital mass lesion is long. Orbital neoplasms are categorized based on

location and histologic type. Optometrists must provide a thorough ophthalmic evaluation for patients with suspicious presentations, including appropriate serologic and radiologic testing, to narrow down the diagnosis. Neuroimaging features of these lesions often reflect their tissue composition. Comanagement with oculoplastics (for biopsies) and oncology is prudent.

The reported case is unusual in that the lymphoma developed in the lacrimal gland after a period of NHL remission. Researchers have documented orbital and adnexal NHL in relapses of previously diagnosed lymphomas.<sup>2,7,9,10</sup>

Although the orbit is rarely a secondary site of lymphoma dissemination, clinicians should immediately investigate if a patient with an established NHL diagnosis develops ophthalmic or orbital symptoms. The typical presentation of adnexal lymphoproliferative disease with orbital involvement includes a painless, palpable mass lesion, swelling, ptosis, proptosis, diplopia or a lid edema. Adnexal structure involvement in systemic NHL may occur at any time during the course of the disease, including as a relapse site.<sup>2,9</sup>

Based on the neuroimaging, incisional biopsy of the involved structures should be performed to reveal the tumor type through pathology testing. In our patient's case, the lacrimal gland was the site biopsied. In addition, serology and molecular testing for certain genes and proteins may help determine disease extent.

Liver, pulmonary and kidney function testing, along with echocardiography, should also be obtained to investigate for lymphoma at other sites and to determine the patient's status for treatment options.<sup>2,7,9</sup>

Local radiation may be pursued, with close monitoring for gradual resolution of signs and symptoms. Systemic chemotherapy or immunotherapy in combination with local radiation can achieve good results in secondary orbital NHL.<sup>2,9</sup> Treatment options for intraocular lymphoma include ocular radiotherapy and intraocular chemotherapy.

In this case, we prescribed a non-preserved tear supplement every four hours and a gel formulation before bed to protect the ocular surface. We referred him for treatment, which will likely include systemic chemotherapy or immunotherapy in combination with local radiation.

More than half of NHL patients are 65 or older when they are diagnosed.<sup>11</sup> As the population continues to live longer, we will likely see an increase in such cases, stressing the importance of early intervention and appropriate management. ■

1. Swerdlow SH, Campo E, Harris NL, et al., eds. WHO Classification of Tumours of Haematopoietic and Lymphoid Tissues, Revised. 4th ed. International Agency for Research on Cancer; Lyon: 2017.
2. Couceiro R, Proença H, Pinto F, et al. Non-Hodgkin lymphoma with relapses in the lacrimal glands. *GMS Ophthalmol Cases*. 2015;5:Doc04.
3. American Cancer Society. What is cancer? [www.cancer.org/cancer/cancer-basics/what-is-cancer.html](http://www.cancer.org/cancer/cancer-basics/what-is-cancer.html). Accessed October 8, 2019.
4. National Cancer Institute. Cancer as a disease. [training.seer.cancer.gov/disease](http://training.seer.cancer.gov/disease). Accessed October 8, 2019.
5. Cornett PA, Dea TO. Cancer. In: SJ McPhee, MA Papadakis, eds. 2010 Current Medical Diagnosis and Treatment. 49th ed. New York: McGraw Hill Medical; 2009:1450-1511.
6. Weinberg RA. The Biology of Cancer. New York: Garland Science; 2006:ch.1-5.5.
7. Farmer JP, Lamba M, Lamba WR, et al. Lymphoproliferative lesions of the lacrimal gland: clinicopathological, immunohistochemical and molecular genetic analysis. *Can J Ophthalmol*. 2005;40(2):151-60.
8. Tailor TD, Gupta D, Dalley RW, et al. Orbital neoplasms in adults: clinical, radiologic, and pathologic review. *Radiographics*. 2013 Oct;33(6):1739-58.
9. Tang LJ, Gu CL, Zhang P. Intraocular lymphoma. *Int J Ophthalmol*. 2017;10(8):1301-7.
10. Shields JA, Shields CL, Scartozzi R. Survey of 1264 patients with orbital tumors and simulating lesions: the 2002 Montgomery Lecture, part 1. *Ophthalmology*. 2004;111(5):997-1008.
11. Chihara D, Nastoupil LJ, Williams JN, et al. New insights into the epidemiology of non-Hodgkin lymphoma and implications for therapy. *Expert Rev Anticancer Ther*. 2015;15(5):531-44.



# Deliver Us From Noncompliance

Impending options can change how medicines are instilled.

By Joseph W. Sowka, OD

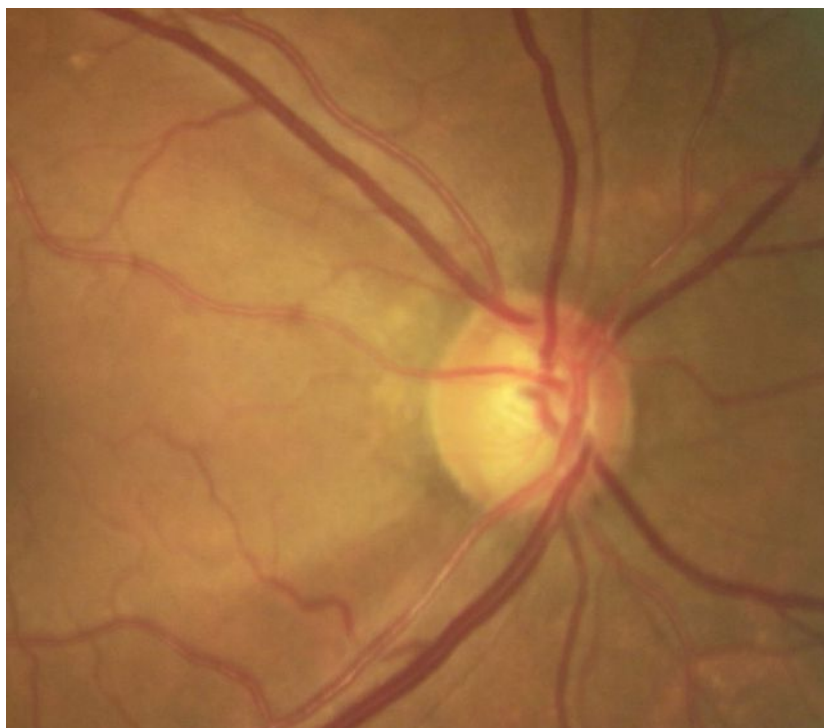
**E**ye care has had forms of sustained release since 1974, when Ocusert (Alza) was introduced.<sup>1</sup> Ocusert was a pilocarpine-impregnated wafer that was placed in the lower cul-de-sac for sustained delivery of medication, bypassing the four-times-a-day dosing required for therapeutic efficacy.<sup>1</sup> It didn't really catch on due to poor tolerability, but it was never established if the vehicle or the drug (or both) led to patients' dislike.

But the promise of sustained-release delivery didn't fade. In 1996, Vitrasert (ganciclovir, Auritec), an intravitreal ganciclovir depot for cytomegalovirus retinitis, was developed.<sup>2</sup> Then, between 2005 and 2011, new products such as Retisert (fluocinolone, Bausch + Lomb), Ozurdex (dexamethasone, Allergan) and Iluvien (fluocinolone, Alimera) entered the fray.<sup>3</sup>

Perhaps buoyed by their successes, a new era in non-traditional delivery systems were launched. Here, we look at some new and yet-to-be released sustained-release delivery systems.

## Enter Dextenza

Recently approved for commercial use, Dextenza (dexamethasone, Ocular Therapeutix) is a sustained release intracanalicular dexamethasone insert for use following cataract surgery.<sup>4</sup> It is a preservative-free, resorbable hydrogel intracanalicular insert that delivers



**Sustained-release medications for glaucoma could help ensure compliance and, ultimately, reduce IOP without the hassle of drops.**

0.4mg of dexamethasone to the eye's surface without the need for additional drops, and it's designed to treat post-surgical ocular inflammation, as well as pain, for up to 30 days with a single administration.<sup>4</sup> In addition to treating ocular pain following ophthalmic surgery, it is now also approved for postoperative inflammation control.

In a multicenter randomized study, 438 patients with planned clear corneal cataract surgery were randomized to receive either a dexamethasone insert or placebo

implant.<sup>5</sup> The implants were placed in the canaliculus of the eye immediately after surgery. The primary efficacy endpoints were complete absence of anterior chamber cells on day 14 and complete absence of pain by day eight.<sup>5</sup>

Significantly more patients had an absence of anterior chamber cells in the dexamethasone insert arm compared with placebo on day 14 of this study.<sup>5</sup>

Additionally, significantly more patients had an absence of ocular pain in the dexamethasone insert arm compared with placebo.<sup>5</sup>

The insert provides a sustained and tapered delivery of drug to the ocular surface over 30 days after a one-time insertion, which reduces the risk of improper corticosteroid tapering and unwanted peaks and troughs in drug concentration.

The amount of corticosteroid contained in the insert actually represents a fraction of the total dose of corticosteroid delivered in a typical topical monthly course, which might minimize deleterious side effects while maintaining sufficient therapeutic concentrations because of its direct proximity to the ocular surface.<sup>6</sup>

Over time, the insert softens and is cleared through the inferior nasolacrimal canaliculus. If necessary, however, the insert can be clinician-expressed. In addition, the insert is manufactured preservative-free to eliminate ocular surface toxicity.<sup>5</sup>

### Coming Closer?

The same manufacturer is also working on an intracanalicular implant intended for insertion into the canaliculus to deliver travoprost to the ocular surface for up to 90 days without preservatives. The goal of this device, OTX-TP (Ocular Therapeutix), is to deliver a continuous steady release of travoprost throughout the treatment period, removing issues of patient non-adherence to topical glaucoma therapy.

An initial prospective study found the sustained-release OTX-TP was able to reduce intraocular pressure (IOP) by 24% by day 10 and 15.6% by day 30.<sup>7</sup> At 10 days, all plugs were still present; at 30 days, plug retention had declined to 42%.<sup>7</sup> The study concluded that the travoprost intracanalicular implant was a non-invasive, well-tolerated potential ocular hypoten-

sive therapy for glaucoma patients with a history of poor compliance.<sup>7</sup>

A recently completed Phase III clinical trial included 554 subjects with open-angle glaucoma or ocular hypertension.<sup>8</sup> The primary efficacy endpoint was to demonstrate a statistically superior mean reduction of IOP from baseline for OTX-TP treated subjects, compared with placebo, at nine different time points.<sup>8</sup>

While IOP reduction was noted in all time points, the trial did not achieve its primary endpoint of statistically significant superiority in reduction at all nine time points—but only in eight out of nine were statistically significant.<sup>8</sup> The sole time point where the performance of the OTX-TP implant was not statistically superior to a placebo implant was at 8am on week 12.<sup>8</sup>

In the study, IOP reductions from baseline for OTX-TP treated subjects ranged from 3.27mm Hg to 5.72mm Hg across the nine time points with higher levels of IOP reduction seen at the earlier time points in this trial.<sup>8</sup>

The trial also showed that the implant was well-tolerated and no serious adverse events were observed.

The most common ocular adverse events were dacryocanalculitis (approximately 7% in OTX-TP vs. 3% in placebo) and lacrimal structure disorder (approximately 6% in OTX-TP vs. 4% in placebo).<sup>8</sup>

### Another Phase III Trial

The FDA has recently accepted a new drug application (NDA) for Bimatoprost Sustained-Release (Allergan).<sup>9</sup> This product is a biodegradable intracameral implant designed to reduce IOP in patients with primary open-angle glaucoma or ocular hypertension. In the two

Phase III studies, patients were randomized to receive bimatoprost SR administered on day one, week 16 and week 32 or timolol twice a day for up to 20 months, as well as placebo implants. Bimatoprost SR reduced IOP by 30% over 12 weeks, achieving non-inferiority to timolol.<sup>9</sup>

In addition, more than 80% of patients remained treatment free and maintained IOP control for at least 12 months following three treatments with bimatoprost SR.<sup>9</sup>

Eye care offers several routes of drug administration. The familiar categorization—topical, oral, intracameral, intravitreal—is set to undergo a shake-up as new concepts are tried. Even drug-eluting contact lenses and refillable intravitreal drug depots are being studied. With new approvals, NDAs and ongoing research and development, sustained delivery may become a more significant route in the near future. ■

1. Worthen DM, Zimmerman TJ, Wind CA. An evaluation of the pilocarpine Ocusert. *Invest Ophthalmol.* 1974 Apr;13(4):296-9.
2. Vitrasert. Auritec Pharmaceuticals, Inc. [www.auritecpharma.com/Vitrasert-retisert/](http://www.auritecpharma.com/Vitrasert-retisert/). 2016. Accessed October 1, 2019.
3. de Oliveira Dias J, Nunes R, Goldhardt R. New drugs and new posterior delivery methods in CME. *Curr Ophthalmol Rep.* 2017;5(2):160-8.
4. Stewart J. Dextenza Approval History. [www.drugs.com/history/dextenza.html](http://www.drugs.com/history/dextenza.html). June 24, 2019. Accessed October 1, 2019.
5. Tyson SL, Bafna S, Gira JP, et al. Dextenza Study Group. Multicenter randomized phase 3 study of a sustained-release intracanalicular dexamethasone insert for treatment of ocular inflammation and pain after cataract surgery. *J Cataract Refract Surg.* 2019;45(2):204-12.
6. Blizzard C, Desai A, Driscoll A. Pharmacokinetic studies of sustained-release depot of dexamethasone in beagle dogs. *J Ocul Pharmacol Ther.* 2016;32(9):595-600.
7. Perera SA, Ting DS, Nongpiur ME, et al. Feasibility study of sustained-release travoprost punctum plug for intraocular pressure reduction in an Asian population. *Clin Ophthalmol.* 2016;10:757-64.
8. OTX-16-002: A Phase 3 study evaluating the safety and efficacy of OTX-TP in subjects with open-angle glaucoma and ocular hypertension. [clinicaltrials.gov/ct2/show/NCT02914509](https://clinicaltrials.gov/ct2/show/NCT02914509). August 29, 2019. Accessed September 30, 2019.
9. Allergan. U.S. FDA accepts Allergan's new drug application for bimatoprost sustained-release in patients with open-angle glaucoma or ocular hypertension. Allergan News. [www.allergan.com/news/news/thomson-reuters/u-s-fda-accepts-allergan-s-new-drug-application-fo.aspx](http://www.allergan.com/news/news/thomson-reuters/u-s-fda-accepts-allergan-s-new-drug-application-fo.aspx). July 17, 2019. Accessed September 30, 2019.



Earn up to  
**18-28 CE**  
Credits\*

Join us for our  
**2020 MEETINGS**



**FEBRUARY 14-17, 2020 - ASPEN, CO**

**Annual Winter Ophthalmic Conference**

Westin Snowmass Conference Center

Program Co-chairs: Murray Fingeret, OD, FAAO and Leo P. Semes, OD, FACMO, FAAO

**REGISTER ONLINE:** [www.skivision.com](http://www.skivision.com)



**APRIL 16-19, 2020 - AUSTIN, TX**

Omni Barton Creek

Joint Meeting with OCCRS\*\*

Program Chair: Paul M. Karpecki, OD, FAAO

**REGISTER ONLINE:** [www.reviewsce.com/austin2020](http://www.reviewsce.com/austin2020)



**MAY 29-31, 2020 - SAN DIEGO, CA**

Manchester Grand Hyatt

Program Chair: Paul M. Karpecki, OD, FAAO

**REGISTER ONLINE:** [www.reviewsce.com/sandiego2020](http://www.reviewsce.com/sandiego2020)



**JUNE 5-7, 2020 - ORLANDO, FL**

Disney Yacht & Beach Club

Program Chair: Paul M. Karpecki, OD, FAAO

**REGISTER ONLINE:** [www.reviewsce.com/orlando2020](http://www.reviewsce.com/orlando2020)



**NOVEMBER 6-8, 2020 - PHILADELPHIA, PA**

Philadelphia Marriott Downtown

Program Chair: Paul M. Karpecki, OD, FAAO

**REGISTER ONLINE:** [www.reviewsce.com/philadelphia2020](http://www.reviewsce.com/philadelphia2020)

Visit our website for the latest information: [www.reviewsce.com/events](http://www.reviewsce.com/events)  
e-mail: [reviewmeetings@jhihealth.com](mailto:reviewmeetings@jhihealth.com) or call: 866-658-1772

Administered by:

**REVIEW**  
EDUCATION GROUP

Medscape  
**LIVE!**

**COPE**

\*Approval pending

**SALUS**  
UNIVERSITY  
Pennsylvania College of Optometry

**OCCRS**  
OPTOMETRIC CLINICAL, CONTACT  
AND REFRACTIVE SOCIETY

\*\*17<sup>th</sup> Annual Education Symposium  
Joint Meeting with NT&T in Eye Care

# Meetings + Conferences

## December 2019

- **5-8.** *Optometric Management Symposium.* Disney's Yacht & Beach Club, Orlando, FL. Hosted by: PentaVision Media, *Optometric Management.* Key faculty: Greg Caldwell, April Jasper, Joseph Sowka. CE hours: 45 total, 25 per OD. For more information, email Maureen Trusky at [maureen.trusky@pentavisionmedia.com](mailto:maureen.trusky@pentavisionmedia.com) or go to [www.omconference.com](http://www.omconference.com).
- **6-7.** *Annual Tulsa Winter Weekend.* Renaissance Tulsa, Tulsa, OK. Hosted by: Oklahoma College of Optometry. Key faculty: Nathan Lighthizer, Blair Lonsberry. CE hours: 19. For more information, email Callie McAtee at [mcateec@nsuok.edu](mailto:mcateec@nsuok.edu), call 918-316-3602 or go to [optometry.nsuok.edu/Continuing-Education/Schedule-of-Events/5th-Annual-Tulsa-Winter-Weekend](http://optometry.nsuok.edu/Continuing-Education/Schedule-of-Events/5th-Annual-Tulsa-Winter-Weekend).
- **6-7.** *Retina Update.* Fairmont Scottsdale Princess, Scottsdale, AZ. Hosted by: Optometric Retina Society and REG. Key faculty: Mohammad Rafeetary, Steven Ferrucci. CE hours: 12. For more information, go to [www.reviewsce.com/orsretupdate2019](http://www.reviewsce.com/orsretupdate2019).
- **7-8.** *Cornea, Contact Lens & Contemporary Vision Care Symposium.* The Westin Hotel, Memorial City, Houston, TX. Hosted by: University of Houston College of Optometry. Key faculty: Jan P.G. Bergmans. CE hours: 16. For more information, email UHCO Continuing Education at [optce@central.uh.edu](mailto:optce@central.uh.edu), call 713-743-1900 or go to [ce.opt.uh.edu/live](http://ce.opt.uh.edu/live).
- **7-8.** *Malinovsky Ocular Disease Weekend.* Rawles Hall, Bloomington, IN. Hosted by: Indiana University School of Optometry. CE hours: 16. For more information, email Cheryl Oldfield at [coldfiel@indiana.edu](mailto:coldfiel@indiana.edu), call 812-856-3502 or go to [expand.iu.edu/browse/iuso-ce](http://expand.iu.edu/browse/iuso-ce).
- **8.** *Contemporary Topics in Optometry.* MBKU Hopping Academic Center, Fullerton, CA. Hosted by: Marshall B. Ketchum University Southern California College of Optometry. Key faculty: Vin Dang, Rachelle Lin, Tomi Luan, Patrick Yoshinaga, Lisa Wahl, Judy Tong. CE hours: 8. For more information, email Bonnie Dellatorre and Antoinette Smith at [ce@ketchum.edu](mailto:ce@ketchum.edu), call 714-449-7495 or go to [ketchum.edu/ce](http://ketchum.edu/ce).
- **13-14.** *West Coast Optometric Glaucoma Symposium.* Hyatt Regency Huntington Beach, Huntington Beach, CA. Hosted by: REG. Key faculty: Murray Fingeret, Robert N. Weinreb. CE hours: 12. For more information, go to [www.reviewsce.com/wcogs2019](http://www.reviewsce.com/wcogs2019).
- **22-29.** *Modern Management of Ocular Disease Cruise.* Royal Caribbean's Allure of the Seas, round trip from Fort Lauderdale, FL. Hosted by: Dr. Travel Seminars. Key faculty: Edward L. Paul, Jr. CE hours: 16. For more information, email at [info@drtravel.com](mailto:info@drtravel.com), call 800-436-1028 or go to [www.drtravel.com](http://www.drtravel.com).

### To list your meeting, please send the details to:

Mark De Leon, Associate Editor

Email: [mdeleon@jobson.com](mailto:mdeleon@jobson.com)

Phone: (610) 492-1021

# Advertisers Index

- Akorn Consumer Health** ..... 35  
 Phone ..... (800) 579-8327  
[www.akornconsumerhealth.com](http://www.akornconsumerhealth.com)
- Alcon Laboratories** ..... 100  
 Phone ..... (800) 451-3937  
 Fax ..... (817) 551-4352
- Allergan, Inc.** ..... 33  
 Phone ..... (800) 347-4500
- Bausch + Lomb** ..... 2, 3, 99  
 Phone ..... (800) 323-0000  
 Fax ..... (813) 975-7762
- Bruder Ophthalmic Products.**  
**31**  
 Phone ..... (888) 827-8337  
[eyes@bruderophthalmic.com](mailto:eyes@bruderophthalmic.com)
- Contamac** ..... 43  
[www.contamac.com](http://www.contamac.com)
- Eyevance Pharmaceuticals** ....  
 ..... 27, 28, 49  
 Phone ..... (817) 677-6120  
[www.eyevance.com](http://www.eyevance.com)
- Focus Laboratories, Inc.** ..... 7  
 Phone ..... (866) 752-6006  
 Fax ..... (501) 753-6021  
[www.focuslaboratories.com](http://www.focuslaboratories.com)
- Johnson & Johnson Vision** 11  
 Phone ..... (904) 443-1000  
[www.jjvision.com](http://www.jjvision.com)
- Katena** ..... 9, 21  
 Phone ..... (800) 225-1195  
[www.katena.com](http://www.katena.com)
- Keeler Instruments** ..... 12  
 Phone ..... (800) 523-5620  
 Fax ..... (610) 353-7814
- Lombart Instruments** ..... 41  
 Phone ..... (800) 446-8092  
 Fax ..... (757) 855-1232
- Marco Ophthalmic** ..... 23  
 Phone ..... (800) 874-5274  
[www.marco.com](http://www.marco.com)
- Menicon** ..... 19  
 Phone ..... (800) MENICON  
 ..... information@menicon.com  
 ..... www.meniconamerica.com
- Regeneron Pharmaceuticals, Inc.** ..... 36-37  
 Phone ..... (914) 847-7000  
[www.regeneron.com](http://www.regeneron.com)
- Reichert Technologies** .... 5, 51  
 Phone ..... (888) 849-8955  
 Fax ..... (716) 686-4545  
[www.reichert.com](http://www.reichert.com)
- S4OPTIK** ..... 61, 63  
 Phone ..... (888) 224-6012
- Shire Ophthalmics** ..... 15, 16  
[www.shire.com](http://www.shire.com)
- TelScreen** ..... 67  
[www.TelScreen.com](http://www.TelScreen.com)  
 ..... DryEye@TelScreen.com
- TRP Company, Inc.** ..... 25  
 Phone ..... (888) 969-6855  
 ..... info@thereliefproducts.com  
 ..... www.thereliefproducts.com
- Veatch** ..... 54, 55  
 Phone ..... (800) 447-7511  
 Fax ..... (602) 838-4934

*This advertiser index is published as a convenience and not as part of the advertising contract. Every care will be taken to index correctly. No allowance will be made for errors due to spelling, incorrect page number or failure to insert.*



# In Too Deep

Can imaging various retinal and choroidal layers help uncover the origin of this patient's blurred and distorted vision? **By Mark T. Dunbar, OD**

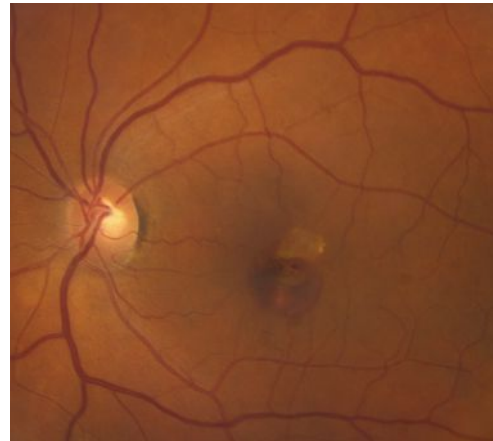**A** 71-year-old Hispanic female presented with blurry and distorted vision in her left eye for the past month. She had been seen 14 months earlier, and at that time her vision was 20/20. She has been moderately hyperopic all her life and felt like she always saw well with her glasses. The blur and distortion in the left eye represented a recent change. She suffers from dry eye and had been using artificial tears and Restasis (cyclosporine, Allergan) with moderate relief of her symptoms.

Her medical history is significant for hypertension, and she takes atenolol and hydrochlorothiazide.

## Evaluation

On examination, her best-corrected visual acuity was 20/20 OD and 20/70 OS. Her manifest refraction was +8.00 -3.00 x 070 OD and +6.25 -1.25 x 090 OS. Her confrontation visual fields were full-to-careful finger counting. Her ocular motility testing was normal and the pupils were equally round and reactive to light without an afferent pupillary defect. The anterior segment was significant for trace nuclear sclerotic cataracts in both eyes. Tensions by Tonopen (Reichert) measured 16mm Hg OU.

On dilated fundus exam, the vitreous was clear. The optic nerves were healthy with small cups and good rim perfusion in both eyes. The macula, vessels and periphery of the right eye were all normal.



**Fig 1.** This fundus photo shows our patient's left eye. How do you account for the hemorrhage?

In the left, obvious changes in the macula were visible (*Figure 1*). Spectral-domain OCT (SD-OCT) and OCT angiography (OCT-A) scans were also obtained (*Figures 2 and 3*).

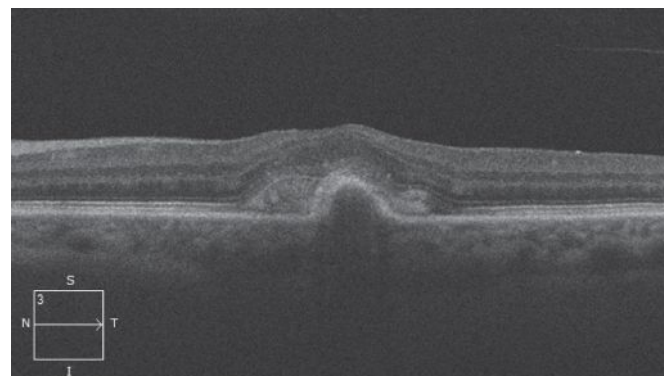
## Take the Retina Quiz

1. What is responsible for the macular changes in the left eye?
  - a. Subretinal hemorrhage.
  - b. Suprachoroidal hemorrhage.
  - c. Choroidal neovascularization.
  - d. Polypoidal choroidal vessels.

2. What is the etiology?
  - a. Macular degeneration.
  - b. Myopic degeneration.
  - c. Idiopathic.
  - d. Pachychoroidal neovascularization.
3. How should this patient be managed?
  - a. Pars plana vitrectomy.
  - b. Anti-VEGF injections.
  - c. Photodynamic therapy.
  - d. Focal laser photocoagulation.
4. What additional testing would be helpful for this patient?
  - a. Visual field.
  - b. Ultrasound.
  - c. A-scan.
  - d. Enhanced-depth imaging OCT.

## Diagnosis

The obvious subretinal hemorrhage in the macula of the left eye



**Fig. 2.** This OCT scan shows us what's beneath the patient's macula.



is due to choroidal neovascularization (CNV). The SD-OCT shows loss of the foveal depression and a serous pigment epithelial detachment (PED) involving the macula. Adjacent to the PED and above the retinal pigment epithelium (RPE) is a high reflective area that represents the CNV. This is a Type 2 CNV because it is growing above the RPE.

Part of the CNV can be visualized on the deep slice of the OCT-A scan. If we had a slightly deeper cut we would have been able to distinguish even more. The *en face* images show a large area of hyperfluorescence. The deeper avascular slice was essentially normal, which is consistent with the clinical presentation. Interestingly, no subretinal or intraretinal fluid is present.

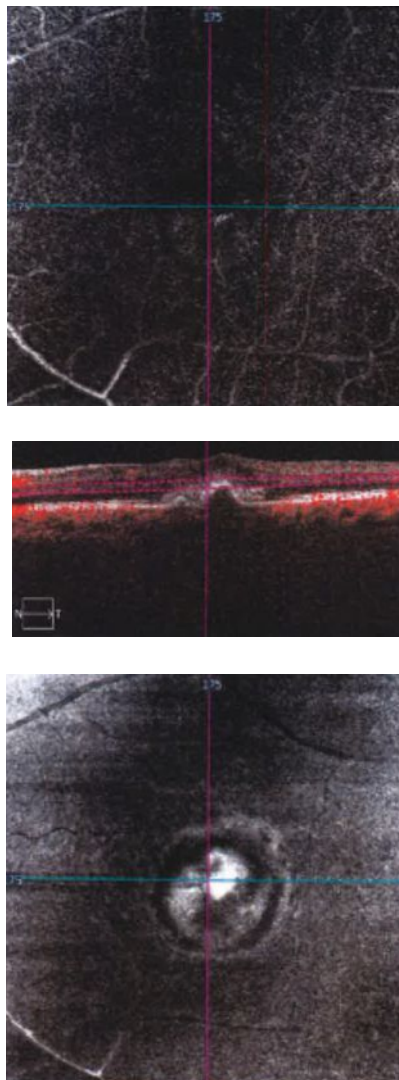
Why did she develop this? The most common causes of CNV is macular degeneration, histoplasmosis and pathologic myopia. Other predisposing causes include angioid streaks, trauma and inflammation, among others. When no apparent cause can be detected, we assume the condition is idiopathic.

In our patient, no drusen or RPE mottling was noted in either eye, so that eliminates age-related macular degeneration as a cause—even though she fits the age demographic.

Of interest, she has had a longstanding circular area of RPE atrophy, like a scar, that can be seen superior to the macula that has been present for many years. This is probably the access point for developing the CNV.

## Discussion

CNV commonly grows adjacent to chorioretinal scars, which them-



**Fig 3.** This “deep slice” OCT-A shows an *en face* view of through the patient’s macula.

selves develop following toxoplasmosis, laser photocoagulation and end-stage macular telangiectasia, among others. Any of these can result in a break in Bruch’s membrane, which sets the stage for CNV.

Our patient’s longstanding area of RPE atrophy above the fovea was seen in the fundus photograph, but it hadn’t resulted in any problems until the CNV developed.

Another possible cause of CNV

is pachychoroid, which is characterized by choroidal thickening and RPE changes. Choroidal thickness varies with age, ethnicity and axial length. The normal choroidal thickness is between 191 $\mu$ m and 354 $\mu$ m. Patients with a choroidal thicknesses greater than 390 $\mu$ m have a pachychoroid.<sup>1-2</sup>

A spectrum of conditions are associated with this finding, including pachychoroid pigment epitheliopathy (PPE), central serous chorioretinopathy (CSCR), pachychoroid neovascularopathy (PNV) and polypoidal choroidal vasculopathy (PCV). PPE is considered the precursor to CSCR.<sup>1-2</sup>

Each of these conditions may progress to the development of neovascularization below the RPE as well as polypoidal choroidal vessels as seen with PCV. These patients may present with pigmentary changes, idiopathic serous PEDs and even hemorrhagic PEDs in more advanced cases.

Many patients who were once considered to have idiopathic CNV are now recognized as having PPE. Advances in OCT/OCT-A imaging including enhanced-depth imaging OCT, hasve led to a much better understanding of these diseases as well as more accuracy in making the diagnosis.

Our patient was referred to a retina specialist where she ultimately received five anti-VEGF injections over 10 months. The hemorrhage resolved and her foveal contour and architecture returned to normal. On last exam, her vision had improved to 20/40. She continues to be followed closely. ■

1. Yap J, Mandelcorn ED. Pachychoroid spectrum: a closure look. *Retina Specialist*. 2018;4(3):44-7.
2. Dolz-Marco R, Dansingani K, Freund K. The pachychoroid clinical spectrum. A new risk and disease modifier in macular disorders. *Retina Today*. May/June 2016;14(4):57-60.

Merchandise Offered

# National Lens

America's Leading Discount Lens Distributer

1-866-923-5600 Phone

1-866-923-5601 Fax

www.national-lens.com

2019		LOW 1 to 5	LOWER 6 - 10	LOWEST 11 & OVER	2019		LOW 1 to 5	LOWER 6 - 10	LOWEST 11 & OVER		
Color	Impressions Color - Available in Rx!	23.95	22.95	21.95							
	Avaira Vitality - 6 PACK	19.95	19.25	19.00							
Johnson & Johnson	Acuvue 1-Day Acuvue Moist - 30 PACK	19.95	19.75	19.50							
	Acuvue 1-Day Acuvue Moist - 90 PACK	44.95	43.95	43.00							
	Acuvue Oasys 1-Day - 90 PACK	65.00	64.00	63.00							
	Acuvue 1-Day Acuvue TruEye - 90 PACK	62.00	61.00	60.00							
	Acuvue 1-Day Moist for Astigmatism - 30 PACK	24.00	23.00	22.00							
	Acuvue 2 - 6 PACK	19.50	18.50	17.50							
	Acuvue Oasys with Hydraclear Plus - 6 PACK	21.50	20.95	19.95							
	Acuvue Oasys with Hydraclear Plus - 24 PACK	66.00	65.00	64.00							
	Acuvue Oasys for Astigmatism - 6 PACK	26.50	26.00	25.00							
	Acuvue Vita - 6 PACK	35.50	35.00	34.50							
	Acuvue Oasys for Presbyopia (limited avail.) - 6 PACK	29.95	28.95	27.95							
	Air Optix Aqua / Air Optix Hydraglyde - 6 PACK	27.75	26.95	25.95							
Alcon	Air Optix Aqua Multifocal - 6 PACK	46.95	45.95	44.95							
	Air Optix for Astigmatism - 6 PACK	38.50	37.95	36.95							
	Air Optix Night & Day Aqua - 6 PACK	44.25	42.95	41.95							
	Freshlook Colorblends - 2 PACK	13.25	12.95	11.95							
	Dailies Aqua Comfort Plus - 90 PACK	37.95	36.95	36.00							
	Dailies Total1 - 30 PACK	26.00	25.75	25.50							
	Dailies Total1 - 90 PACK	68.00	67.00	66.00							
	Focus Dailies - 90 PACK	38.00	37.50	37.00							
						CooperVision					
							Biofinity - 6 PACK	26.50	26.00	25.50	
					Biofinity Energys - 6 PACK		33.00	32.50	32.25		
					Biofinity Multifocal D/N - 6 PACK		47.50	47.00	46.50		
					Biofinity Toric - 6 PACK		37.00	36.75	36.25		
					Biomedics 55 Evolution & Premier - 6 PACK		18.00	17.00	16.50		
					Clariti 1 Day - 90 PACK		42.00	41.00	40.50		
					Frequency 55 Aspheric - 6 PACK		19.95	18.95	17.95		
					MyDay - 90 PACK		56.50	53.95	52.25		
					Proclear 8.6 - 6 PACK		24.95	22.95	21.95		
					Proclear 8.2 - 6 PACK	26.95	25.95	24.95			
					Proclear 1-Day - 90 PACK	44.50	41.00	40.50			
					Bausch & Lomb						
						Biotrue Oneday - 90 PACK	44.00	42.95	42.50		
						PureVision 2 HD - 6 PACK	27.50	26.95	25.95		
						Soflens Daily Disposables - 90 PACK	35.50	34.50	31.95		
						Soflens 38 - 6 PACK	17.00	16.00	15.50		
						Ultra - 6 PACK	33.95	32.95	30.50		
					Ultra Presbyopia - 6 PACK	40.95	39.95	38.95			

We'll Meet or Beat Any Competitors Prices on Any Stock Lens • Free Standard Shipping (when available) • Same Day Shipping • We Do Not Backorder Lenses



## Targeting Optometrists?

### CLASSIFIED ADVERTISING WORKS

- JOB OPENINGS
- CME PROGRAMS
- PRODUCTS & SERVICES
- AND MORE...

Contact us today for classified advertising:

Toll free: 888-498-1460

E-mail: sales@kerhgroup.com



**Continuing Education**

**MEDICAL OPTOMETRISTS**

The American Board of Certification in Medical Optometry (ABCMO) is recognized at Joint Commission (JC) accredited medical facilities as issuing board certification in the specialty of medical optometry and those ABCMO certifies are eligible for credentialing at these facilities as specialists rather than general optometry practitioners.<sup>^</sup>

The Joint Commission, the accepted national Gold Standard, reviews and accredits over 21,000 federal, state and local-chartered medical facilities.

**To Be Eligible for ABCMO board certification:**

1. Complete an accredited residency in medical optometry
2. Pass the national Advanced Competence in Medical Optometry Examination
3. Practice in a medical setting for a minimum of two years.<sup>^</sup>

[www.abcmo.org](http://www.abcmo.org)



Visit [www.abcmo.org](http://www.abcmo.org) to understand how JC accredited medical facilities credential specialists and why specialty certification can enhance the careers of optometrists who complete residencies in medical optometry.

For Application procedures see [www.abcmo.org](http://www.abcmo.org) or contact [myers.kenj@gmail.com](mailto:myers.kenj@gmail.com)

<sup>^</sup> At this time, 127 JC accredited hospitals, clinics and teaching institutions recognize ABCMO specialist certification.  
<sup>^</sup> [www.jointcommission.org](http://www.jointcommission.org)  
<sup>^</sup> Waived for two years after residency

**Practice For Sale**



Practice Sales • Appraisals • Consulting  
[www.PracticeConsultants.com](http://www.PracticeConsultants.com)

**PRACTICES FOR SALE  
 NATIONWIDE**

Visit us on the Web or call us to learn more about our company and the practices we have available.

[info@PracticeConsultants.com](mailto:info@PracticeConsultants.com)

**925-820-6758**

[www.PracticeConsultants.com](http://www.PracticeConsultants.com)

**PRACTICE SALES  
 & APPRAISAL**

Expert Services for:

- Buying or Selling a Practice**
- Practice Appraisal**
- Practice Financing**
- Partner Buy-in or Buy-out**

Call for a Free Consultation

**(800) 416-2055**

[www.TransitionConsultants.com](http://www.TransitionConsultants.com)

**Career Opportunities**

**Staff Optometrist Wanted**

Bard Optical is a family owned full-service retail optometric practice with 22 offices (and growing) throughout Central Illinois. Bard Optical prides itself on having a progressive optometric staff whose foundation is based on one-on-one patient service. We are currently accepting CV/resumes for Optometrists to join our medical model optometric practice that includes extended testing. The practice includes but is not limited to general optometry, contact lenses and geriatric care. Salaried, full-time positions are available with excellent base compensation and incentive programs and benefits. Some part-time opportunities may also be available.

Current positions are available in Bloomington/Normal, Decatur/Forsyth, Peoria, Sterling and Canton as we continue to grow with new and established offices.

Please email your information to [mhall@bardoptical.com](mailto:mhall@bardoptical.com) or call Mick at 309-693-9540 ext 225. Mailing address if more convenient is:

**Bard Optical**  
 Attn: Mick Hall, Vice President  
 8309 N Knoxville Avenue  
 Peoria, IL 61615

*Bard Optical is a proud Associate Member of the Illinois Optometric Association.*



[www.bardoptical.com](http://www.bardoptical.com)

**Do you have Products and Services for sale?**

**CONTACT US TODAY  
 FOR CLASSIFIED ADVERTISING**  
 Toll free: 888-498-1460  
 E-mail: [sales@kerhgroup.com](mailto:sales@kerhgroup.com)

Do you have Products and Services for sale?

**CLASSIFIED  
 ADVERTISING WORKS**

- **JOB OPENINGS**
- **CME PROGRAMS**
- **PRODUCTS**
- **AND MORE...**

Contact us today for classified advertising:  
 Toll free: 888-498-1460  
 E-mail: [sales@kerhgroup.com](mailto:sales@kerhgroup.com)





**Targeting Optometrists?**

**CLASSIFIED ADVERTISING WORKS**

- **JOB OPENINGS** • **CME PROGRAMS**
- **PRODUCTS & SERVICES** • **AND MORE...**

Contact us today for classified advertising:  
 Toll free: 888-498-1460  
 E-mail: [sales@kerhgroup.com](mailto:sales@kerhgroup.com)








## Can't Get the Red Out

By Andrew S. Gurwood, OD

### History

A 27-year-old Caucasian male reported to the office with a chief complaint of “pink eye.” He explained that his eyes became red following a cold two weeks earlier and that Visine (tetrahydrozoline, Johnson & Johnson) made them less red but didn't stop the discharge.

His systemic and ocular histories were unremarkable and he denied exposure to chemicals or allergens of any kind.

### Diagnostic Data

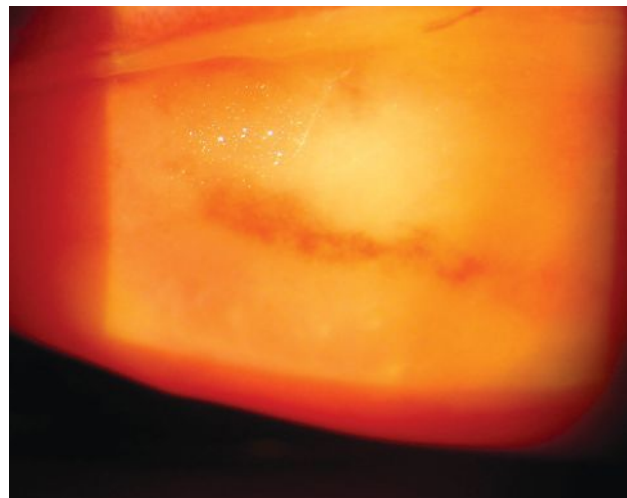
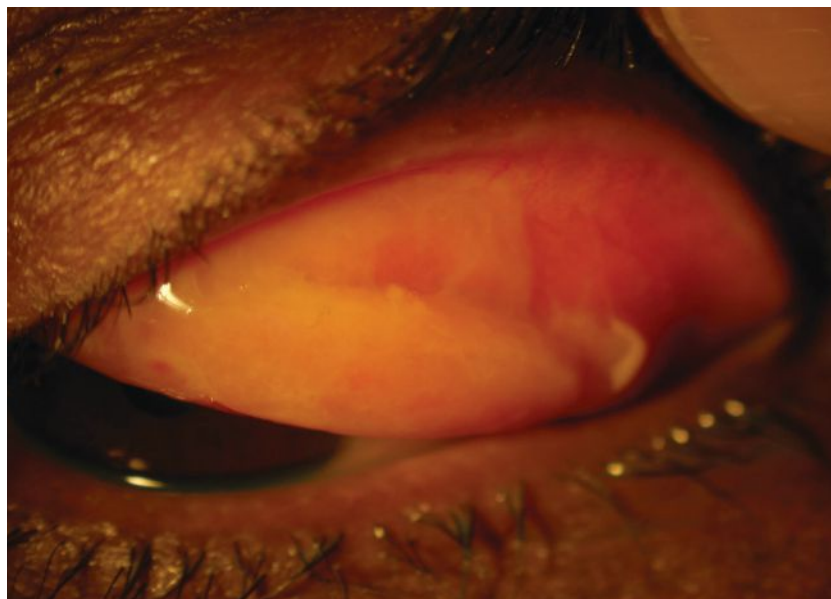
His best-corrected entering visual acuities were 20/20 OU at distance and near. His external examination was normal with no evidence of afferent pupillary defect.

The biomicroscopic examination of the anterior segment is demonstrated in the photographs. Goldmann applanation tonometry measured 15mm Hg OU.

The dilated fundus findings were normal peripherally and centrally with normal nerves and maculae.

### Your Diagnosis

Does the case presented require any additional tests, history or information? Based on the information provided, what would be your diagnosis? What is the patient's likely prognosis? To find out, please visit us at [www.reviewofoptometry.com](http://www.reviewofoptometry.com). ■

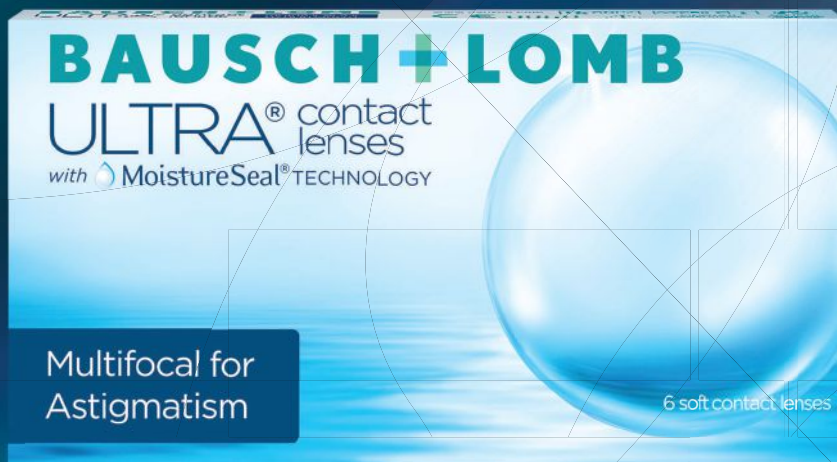

**This 27-year-old patient's persistent reddening and discharge was coupled with this finding, seen upon everting the eyelid. Can you identify the underlying condition causing his distress?**

**Retina Quiz Answers** (from page 94): 1) c; 2) c; 3) b; 4) d.

REVIEW OF OPTOMETRY (ISSN 0147-7633) IS PUBLISHED MONTHLY, 12 TIMES A YEAR BY JOBSON MEDICAL INFORMATION LLC, 395 HUDSON STREET, 3RD FLOOR NEW YORK, NEW YORK 10014. PERIODICALS POSTAGE PAID AT NEW YORK, NY AND ADDITIONAL MAILING OFFICES. POSTMASTER: SEND ADDRESS CHANGES TO REVIEW OF OPTOMETRY, PO BOX 81, CONGERS, NY 10920-0081. SUBSCRIPTION PRICES: US: ONE YEAR \$56; TWO YEARS \$97, CANADA: ONE YEAR \$88, TWO YEARS \$160, INT'L: ONE YEAR \$209, TWO YEARS \$299. FOR SUBSCRIPTION INFORMATION CALL TOLL-FREE (877) 529-1746 (USA); OUTSIDE USA, CALL (845) 267-3065. OR EMAIL US AT REVOPMETRY@CAMBEYWEST.COM. PUBLICATIONS MAIL AGREEMENT NO: 40612608. CANADA RETURNS TO BE SENT TO BLEUCHIP INTERNATIONAL, P.O. BOX 25542, LONDON, ON N6C 6B2.

# REACHING NEW LIMITS



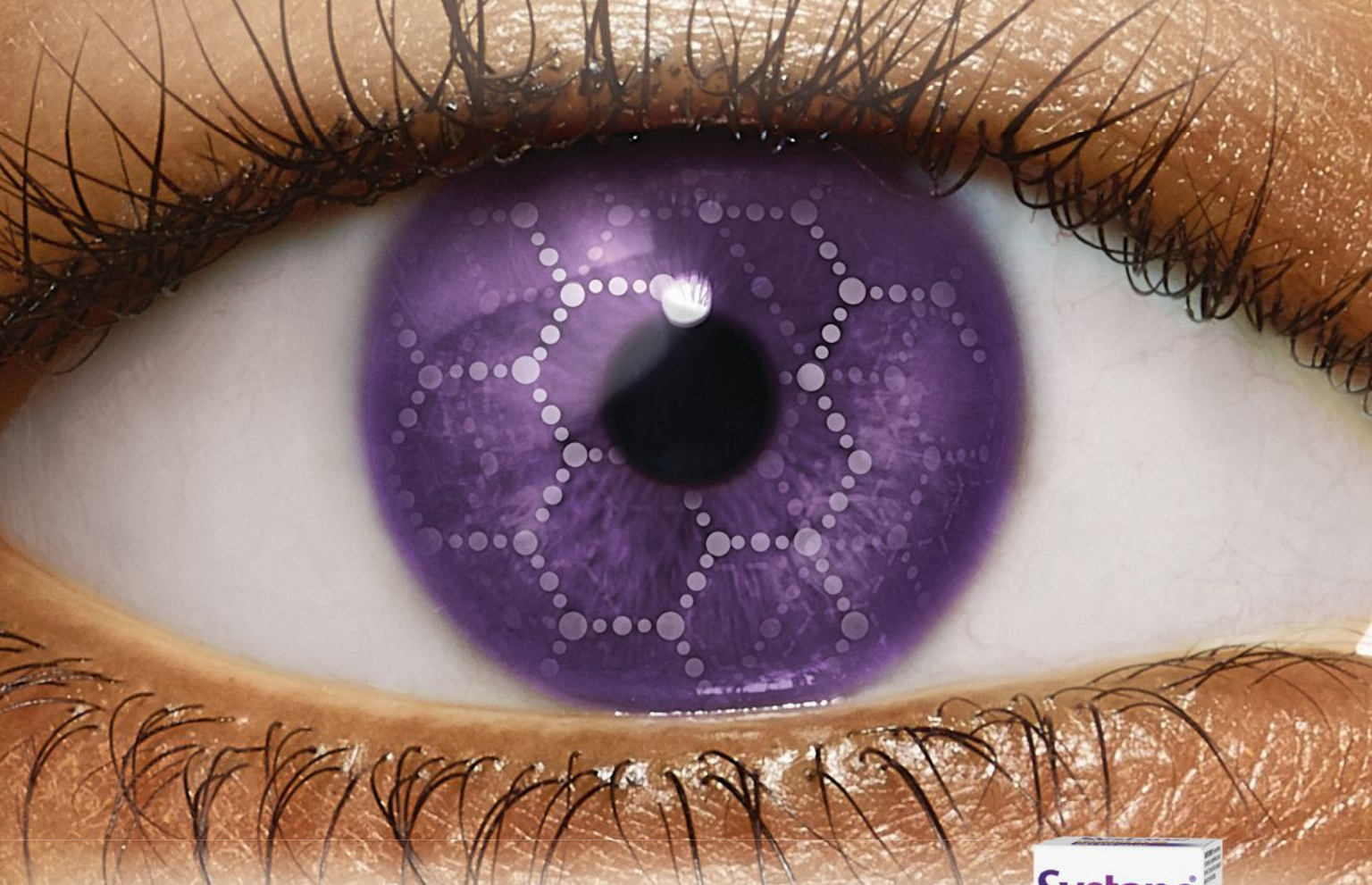## **Bausch + Lomb ULTRA® Multifocal for Astigmatism**

is the first and only lens of its kind available as a standard offering. This advanced lens combines the seamless transitions presbyopic patients want with the lens stability their astigmatism needs.

**OpticAlign® Design**  
for reliable stability

**3-Zone Progressive™ Design**  
for seamless transitions





# SYSTANE® COMPLETE: OUR MOST ADVANCED SOLUTION. ONE SIMPLE CHOICE.

Our most innovative drop supports all layers of the tear film and is designed to provide symptom relief for **every major type of dry eye**.<sup>1-9</sup>

- Evaporative Dry Eye**
- Aqueous-deficient Dry Eye**
- Mixed Dry Eye**



**The Relief is Real™**



**Advanced, lipid nano-droplet technology** rapidly delivers the lubricant across the ocular surface — resulting in **better coverage\*** to provide **fast-acting hydration, tear evaporation protection, and long-lasting relief**.<sup>1,5-6,8-10</sup>

**VISIT SYSTANE.COM TO LEARN MORE!**

\*Compared to SYSTANE® BALANCE Lubricant Eye Drops.

**References:** **1.** Korb D, Blackie C, Meadows D, Christensen M, Tudor M. Evaluation of extended tear stability by two emulsion based artificial tears. Poster presented at: 6th International Conference of the Tear Film and Ocular Surface: Basic Science and Clinical Relevance; September 22-25, 2010; Florence, Italy. **2.** Moon SW, Hwang JH, Chung SH, Nam KH. The impact of artificial tears containing hydroxypropyl guar on mucous layer. *Cornea*. 2010;29(12):1430-1435. **3.** Davitt WF, Bloomenstein M, Christensen M, Martin AE. Efficacy in patients with dry eye after treatment with a new lubricant eye drop formulation. *J Ocul Pharmacol Ther*. 2010;26(4):347-353. **4.** Willcox MDP, Argueso P, Georgiev GA, et al. TFOS DEWS II tear film report. *Ocul Surf*. 2017;15:366-403. **5.** Ketelson H, Rangarajan R. Pre-clinical evaluation of a novel phospholipid nanoemulsion based lubricant eye drop. Invest Ophthalmol Vis Sci. 2017;58:3929. **6.** Ogundele A, Ketelson H, et al. Preclinical evaluation of a novel hydroxypropyl-guar phospholipid nanoemulsion lubricant eye drop for dry eye disease. Poster presented at: The 36th World Ophthalmology Congress (WOC); June 16-19, 2018; Barcelona, Spain. **7.** Craig J, Nichols K, Akpek E, et al. TFOS DEWS II definition and classification report. *Ocul Surf*. 2017;15:276-283. **8.** Lane S, Paugh J, et al. An Evaluation of the in vivo Retention Time of a Novel Artificial Tear as Compared to a Placebo Control. Invest Ophthalmol Vis Sci. 2009;50(13):4679. **9.** Benelli U. Systane® lubricant eye drops in the management of ocular dryness. *Clin Ophthalmol*. 2011;5:783-790. **10.** Torkildsen G. The effects of lubricant eye drops on visual function as measured by the Inter-blink interval Visual Acuity Decay test. *Clin Ophthalmol*. 2009;3:501-506.