

2019 CLINICAL GUIDE TO **OPHTHALMIC DRUGS**

23rd Edition

Expert advice to
help you eradicate
eye disease.



Ron Melton, OD



Randall Thomas, OD, MPH

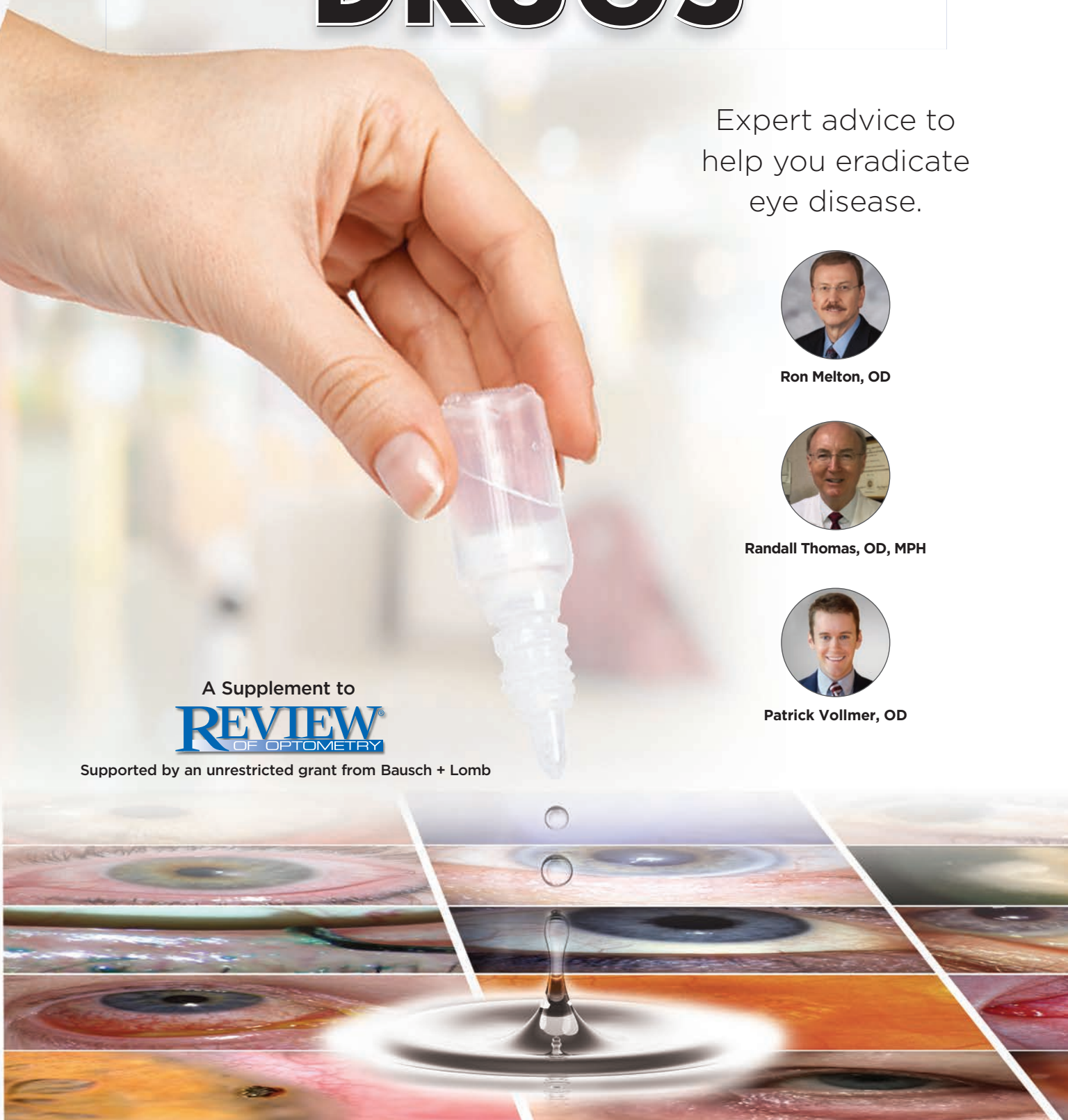

Patrick Vollmer, OD

A Supplement to

REVIEW
OF OPTOMETRY

Supported by an unrestricted grant from Bausch + Lomb



DEAR OPTOMETRIC COLLEAGUES:

Welcome to the 2019 edition of our annual *Clinical Guide to Ophthalmic Drugs*. In these pages, we offer you our collective clinical wisdom, gleaned from over 75 years of combined experience, and the latest information on developments in ocular therapies and care to help you in your daily practice.

Though advancements are always welcome, technology is a two-edged sword that can truly cut both ways. For example, refraction can now be performed by any number of scanning devices. And in many parts of the world, automated refraction is the only way to provide people with corrective lenses. 3D printers can now produce eyeglasses. Even more strikingly, eye drop technology will soon be available to dampen the onset and degree of presbyopia. We all know such advances will only continue.

What we are getting at here is our strong admonition to begin diversifying your practice to embrace more medical eye care services. This is especially important for younger clinicians, since refractive-centric practices are already at risk of being replaced by technology. The time to plan ahead is now.

Turning to the state of advancing therapies, the drug pipeline has been influenced by the patent expiration of Restasis and the advent of numerous generics. Yet another new glaucoma drug was approved, as well as a non-BAK-preserved formulation of latanoprost. We now have a medicine specifically indicated to help patients with neurotrophic keratitis. And a micro-particle delivery system for loteprednol was approved for BID administration, in addition to a newer 0.38% Lotemax SM available for TID, both of which are indicated for postoperative care. Soothe XP is now offered in preservative-free unit-dose packages, AREDS2 vitamin supplements now come in chewable tablets, and a new supplement containing lutein and zeaxanthin is formulated to help guard against blue light macular phototrauma.

This year, as in past years, we will help you to better understand how to use available ophthalmic medicines as well as discuss these newer medications. And we will continue to emphasize the increasingly important role of systemic medications in the care of patients who present to optometrists.

Medical care may be a science, but it's also an art. No treatment is foolproof and methods vary among practitioners. We are pleased to share our approaches and their rationales with you each year. As always, our goal is to help you better serve and care for patients. Remember to care for them as you would like to be cared for yourself.

With our best wishes,



Randall K. Thomas,
OD, MPH, FAAO



Ron Melton,
OD, FAAO



Patrick M. Vollmer,
OD, FAAO

Disclosure: Drs. Melton and Thomas are consultants to, but have no financial interests in, the following companies: Bausch + Lomb/Valeant and Icare. Dr. Vollmer has no financial interests in any company.

Supported by an
unrestricted grant from
Bausch + Lomb

CONTENTS

Thoughts from the Chair.....	3
Glaucoma Care.....	5
Corticosteroids.....	14
Antibiotics.....	23
Combination Drugs.....	28
Ocular Surface Care.....	32
Allergy Drugs.....	38
Shingles Therapy.....	42
Vision Insights.....	45
Practice Management.....	48



A PEER-REVIEWED
SUPPLEMENT

Note: The authors present unapproved and "off-label" uses of specific drugs in this guide.

Persistence Pays Off

The need to diversify your practice to include medical eye care is becoming apparent. Here's how I broke into the local referral network.

By Patrick Vollmer, OD, FAAO

I purchased my practice in October 2016, shortly after completing my residency. Like most new grads, I was eager to make an immediate impact in my newly discovered community. Patients were going to line up at my door, recommend my services to their family and friends and, perhaps most importantly, surrounding healthcare professionals would refer me all their complex eye cases. I was going to be swamped in no time.

But that didn't happen... at least not right away. One month into practice, I realized patients were not just going to spontaneously show up at my door and I wasn't going to be seeing emergency cases frantically sent over by other providers. I was new to my community—an outsider—and no one knew me. This was a discovery I met with early frustration.

Just as a financial advisor will encourage you to diversify your investment portfolio, I knew at the outset I had to diversify my services. Funding a practice strictly through retail alone is not infallible, and I had too much at stake. Additionally, I had studied extensively under my coauthors, who manage high-level acute and chronic ocular disease every day, and I understood the impor-



Dr. Vollmer's emphasis on emergency care helped his practice establish an identity as a vital local resource.

tance of offering these kinds of important medical services. But I can assure you that succeeding in medical eye care did not happen overnight, even to a recent grad who was both well-trained for and enthusiastic about that role.

The first time I met with the medical community was at a local Urgent Care. I waited patiently for the attending physician to finish examining his patient so I could

THE VIRTUES OF 24/7 EMERGENCY CARE

I don't personally subscribe to the idea that optimum patient care is a 9-to-5 endeavor. My clinic offers around-the-clock emergency services on nights and weekends. Ironically, about 80% of all these emergency cases are not my existing patients, but rather patients who weren't able to locate other optometrists during their distress.

I've found this to be a tremendous practice builder. Patients really appreciate your willingness to extend your hours outside of normative realms. The number of true eye "specialists" is severely diminished outside of regular business hours. By making yourself available, you will be tapping into a market that demands your attentive expertise.

At the conclusion of every exam, I say, "If you ever have an eye emergency, let me know first." This quick comment takes three seconds. Its impact is immeasurable.

talk with him about the services I could offer. When I met him, my attempts to convey my skills and abilities were dampened by his condescending remarks, including: “Are you old enough to be a doctor?” “I thought you guys just prescribe glasses.” “Optometrists can treat pink eye?” (Ha.) The meeting finished in my humiliation.

But I came back to him next week. And the next week. And the week after that. I did this at all of the local Urgent Care clinics and medical practices, where I continued to be met with the same initial responses. Despite my most sincere efforts to explain my potential role within their clinics, I typically would leave each one feeling slightly more admonished than the last.

Then one day, I was finishing up work at my desk, and I got a call. It was the doctor I met with the first day. “Yes, I have a patient here who is not getting better on the drops I prescribed. Can you see her?” This initial call was followed by others later that week. The frequency and complexity of the referred cases began to accelerate with each successful outcome.

I was beginning to establish myself in the community as a doctor who would treat ocular emergencies. With each case, I would examine the patient and send a one-page report back to the referring provider detailing my findings with a recommended course of action. This brief summary showcased the wide array of treatments I could provide and brought the referring practitioner closure that their patient was in good hands.

Now, just over two years later, it’s no longer novel to be providing care not only to the patients of these physicians, but also to the physicians’ families and to the physicians themselves. I am amicably greeted when I go to visit them now, and they know they can count on me to take care of their needs. I’m grateful that I wasn’t just handed this privilege when I first started out. Professional development, networking and reputation-building take time. This is how it’s supposed to be. ■

HOW I BECAME A RELUCTANT INTERNET STAR

To give you an idea of the inroads one new optometrist can have in a community, my recent case—referred to me from a local Urgent Care—went viral on social media and was covered on news outlets from *Newsweek* to the *Daily Mail*.

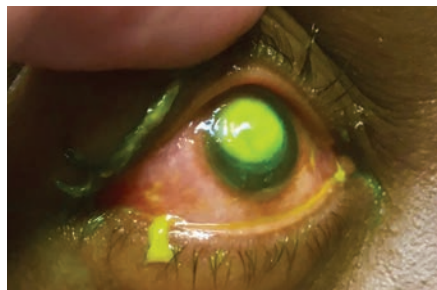When I first posted pictures April 28 of a *Pseudomonas* ulcer, directly caused by a patient sleeping in contact lenses, I had no idea that more than 30 million people would see it in the first three days. But I’m thrilled the case is raising awareness on this important issue and, hopefully, helping to correct unhealthy patient behaviors when it comes to contact lens wear.

I started the patient on fortified antibiotic drops around the clock and recently added steroids to reduce permanent scarring. While this patient’s eye continues to drastically improve from baseline, she will likely exhibit some form of residual vision loss even after treatment.

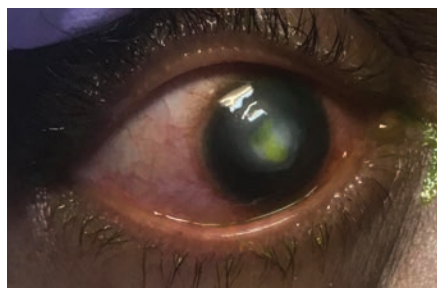This problem is not new. This is the fourth case of cultured *Pseudomonas* I’ve treated in my clinic—remember, I’ve been practicing for less than three years—and I constantly hear from patients, “I sleep in my contacts all the time and I’ve never had a problem.”

Disturbingly, the adoption—and increasingly popular overnight use (or misuse)—of soft extended-wear contact lenses as a convenient method for correction of routine refractive errors has been associated with a dramatic increase in cases of microbial keratitis in eyes not otherwise predisposed to this condition.

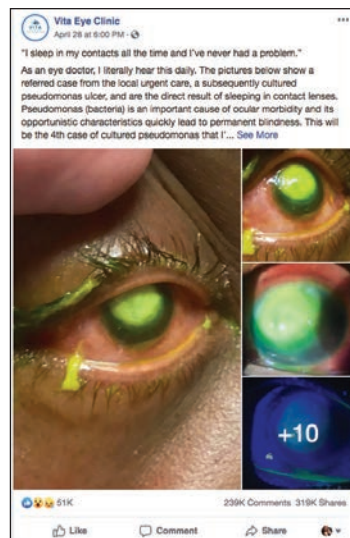I never recommend sleeping in soft contact lenses. The risks outweigh the benefits every time. It takes seconds to remove your contacts but risks a potential lifetime of irreversible damage if you don’t.



The patient’s ulcer grew from a “small ulcer” noted at Urgent Care to this—in just 36 hours.



Around-the-clock fortified antibiotic drops and steroids have helped the patient considerably. But she will likely have permanent vision loss of some kind.



A MESSAGE FROM DRs. MELTON AND THOMAS

We are most happy to recommend Dr. Vollmer as a lecturer for optometric continuing medical education programs. He has developed a series of clinical case presentations that perfectly represents the pinnacle of optometric patient care. He can be contacted at: patrickvollmer23@gmail.com.

DETECT AND PROTECT THE OPTIC NERVE

With glaucoma, proper diagnosis and careful follow-up are crucial to protecting against optic neuropathy. Be sure to “look before you leap” into medical therapy.

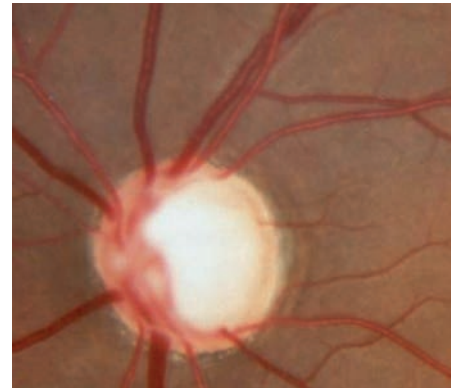
Glaucoma management has become a hot topic in optometry these days with the recent approval of several new drugs to reduce IOP. Yet, we shouldn't lose sight of the ultimate goal when managing glaucoma patients: protecting the optic nerve.

In fact, critical observation of the optic nerve is far more important than measuring IOP. Many patients who have statistically normal IOPs experience glaucomatous optic neuropathy—or perhaps they *do* have elevated pressures but these episodes occur outside of normal office hours. We would miss diagnosing these patients if IOP was our only driving force to pursue a more detailed glaucoma workup.

The final common pathway of all forms of glaucoma is optic nerve head atrophy as evidenced by progressive cupping with concurrent thinning of the neuroretinal rim tissue. Especially in older patients with normal-tension glaucoma, such cupping can be quite elusive, as in the case of a shallow cup with very thin rim tissue. It takes attentive study of these types of optic nerve heads to detect subtle advanced cupping.

So, how can eye doctors make sure they don't miss glaucoma? The key is a comprehensive patient evaluation. Here is our usual workup:

1. We begin with a detailed family history, especially if there are siblings with glaucoma. While glaucoma is not inherited per se, it does tend to run in



This optic nerve sustained severe loss of neural tissue, thus showing a C/D ratio of 0.8.

families. We look at the patient's overall health status and medications they are taking. It is important to know that oral beta-blockers have a slightly protective effect, whereas calcium channel blockers such as Norvasc (amlodipine besylate, Pfizer) can be significantly detrimental.

2. We then measure IOP, corneal thickness and the retinal nerve fiber layer, followed by a 24-2 SITA fast visual field and a four-mirror gonioscopic evaluation.

3. Most importantly, we attentively study the optic nerve head. This last step isn't as easy as it sounds. A recent report found “there is little consistency in the way clinicians are taught how to identify the disc and rim margins,” and disc examination is variable between clinicians.¹ The study found fellowship-trained glaucoma specialists show substantial differences in

TOPICAL GLAUCOMA DRUGS				
BRAND NAME	GENERIC NAME	MANUFACTURER	CONCENTRATION	BOTTLE SIZE
Beta Blockers				
Betagan	levobunolol hydrochloride	Allergan and generic	0.25% 0.5%	5ml, 10ml 5ml, 10ml, 15ml
Betimol	timolol hemihydrate	Akorn	0.25% 0.5%	5ml 5ml, 10ml, 15ml
Betoptic-S	betaxolol hydrochloride	Novartis	0.25%	5ml, 10ml, 15ml
Istalol	timolol maleate	Bausch + Lomb	0.5%	2.5ml, 5ml
Timoptic	timolol maleate	Bausch Health and generic	0.25% 0.5%	5ml, 10ml, 15ml 5ml, 10ml, 15ml
Timoptic (preservative-free)	timolol maleate	Bausch Health	0.25% 0.5%	unit-dose unit-dose
Timoptic-XE	timolol maleate	Bausch Health	0.25%	2.5ml, 5ml
Prostaglandin Analogs				
Bimatoprost	bimatoprost	generic	0.03%	2.5ml, 5ml, 7.5ml
Lumigan	bimatoprost	Allergan	0.01%	2.5ml, 5ml, 7.5ml
Travatan Z	travoprost	Novartis	0.004%	2.5ml, 5ml
Travoprost	travoprost	generic	0.004%	2.5ml, 5ml
Vyzulta	latanoprostene bunod	Bausch + Lomb	0.024%	2.5ml, 5ml
Xalatan	latanoprost	Pfizer, + generic	0.005%	2.5ml
Xelpros	latanoprost ophthalmic emulsion	Sun Ophthalmics	0.005%	5ml
Zioptan	tafluprost	Akorn	0.0015%	unit-dose
Alpha Agonists				
Alphagan P	brimonidine	Allergan	0.1%, 0.15%	5ml, 10ml, 15ml
Brimonidine	brimonidine	generic	0.15%, 0.2%	5ml, 10ml, 15ml
Carbonic Anhydrase Inhibitors				
Azopt	brinzolamide suspension	Novartis	1%	5ml, 10ml, 15ml
Trusopt	dorzolamide	Merck and generic	2%	5ml, 10ml
Rho Kinase Inhibitors				
Rhopressa	netarsudil	Aerie Pharmaceuticals	0.02%	2.5ml
Combination Glaucoma Medications				
Combigan	brimonidine/timolol	Allergan	0.2%/0.5%	5ml, 10ml
Cosopt	dorzolamide/timolol	Akorn and generic	2%/0.5%	5ml, 10ml
Cosopt PF	dorzolamide/timolol	Akorn	2%/0.5%	unit-dose
Rocklatan	netarsudil and latanoprost	Aerie Pharmaceuticals	0.02%, 0.005%	2.5ml
Simbrinza	brinzolamide/brimonidine suspension	Novartis	1%/0.2%	8ml

their optic nerve head tissue estimates in glaucomatous or at-risk eyes.

The takeaway here is that critical assessment of the micro-neuroanatomy of the optic nerve head is truly subjective, and all eye doctors struggle with detailed assessment. We look back through our own records and are dismayed at the inconsistency of our quantitative grading and tissue characterization. It's oddly reassuring that such inconsistency occurs at all levels of clinical expertise.

Luckily, numerous tests and clinical parameters exist to help us follow glaucoma patients, so being a little irregular with a single observation carries no meaningful impact to quality of life concerns.

Once these steps are complete, we can assess risk and decide whether to follow the patient, the frequency of follow-up and whether to initiate therapy. If therapy is initiated, we always do a monocular therapeutic trial. Most importantly, we spend time

explaining the situation to the patient and thoroughly answer all of their questions. If we read skepticism on the patient's face (which is very rare), we suggest getting a second opinion, and we recommend several glaucoma subspecialists in the area. This further assures the patient that we do, indeed, know what we're talking about.

Whether the patient's IOP is high or normal, the ultimate goal is to reduce it to a target range you feel is safe for that individual.



TODAY'S PERSPECTIVE ON RHO-KINASE INHIBITORS

An exhaustive “translational science review” on this topic was published in the November 2018 issue of *Ophthalmology*, with several observations worthy of sharing:

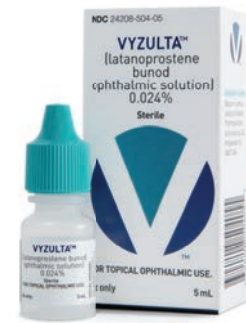- Under normal physiological conditions, about 15% of aqueous humor exits via the uveoscleral pathway. Prostaglandins greatly shift aqueous outflow through the uveoscleral tissues.
- “Brimonidine may lower IOP, in part, by stimulating prostaglandin release.”
- “Approximately 40% to 50% of patients require two or more medications to adequately lower intraocular pressure.”
- Current commonly used glaucoma medications adjunctive to prostaglandins reduce IOP by 1.5mm Hg to 3mm Hg. In keeping with this trend, “Netarsudil lowers IOP approximately an additional 2mm Hg when added to a prostaglandin [...] however, the incidence of adverse events is higher.”
- “Rho-kinase inhibitors have a variety of effects. They can increase blood flow by causing vascular smooth muscle relaxation leading to vasodilation. On the ocular surface, this can lead to conjunctival hyperemia.” Such action also causes smooth muscle cell relaxation in the trabecular meshwork.
- Conjunctival hyperemia was observed in about 50% of patients and the “incidence and severity remained stable through the three-month study period.”
- Paralimbal subconjunctival hemorrhages were seen in about 14% of patients, and about 10% developed corneal verticillata—neither of which have any clinically significant bearing. These conditions resolved after drug discontinuation.
- “It is notable that a large proportion of patients withdrew from clinical trials because of adverse events, raising some questions about the ease with which these agents can be used in clinical practice.”
- “Although these agents have been shown to be effective in lowering intraocular pressure, both as monotherapy and adjunctively with beta-blockers and prostaglandin analogues, their side effect profile raises serious concerns about the likelihood of their acceptance by patients.”

As we earnestly strive to share clinical knowledge with our colleagues to enhance patient care, we also want to share our perspectives. First, if an adjunctive medicine to a prostaglandin is needed, it is abundantly evident that timolol is the drug of choice because of its dosing regimen, cost and efficacy.

Perhaps even more importantly, and in acknowledgement of the reality that adding any adjunctive medicine adds further expense and complexity to the regimen, target-range IOP might be achieved by simply switching from a standard prostaglandin to Vyzulta, which has been shown to further reduce IOP.

Do not let us persuade you here; instead, we invite you to think along with us as we ponder how to best serve our patients based on medical literature and our many combined decades of caring for patients with glaucoma.

Tanna AP, Johnson M. Rho kinase inhibitors as a novel treatment for glaucoma and ocular hypertension. *Ophthalmology*. 2018;125(11):1741-56.



THERAPEUTIC TOOLBOX

Now, let’s turn our attention to the therapeutic armamentarium available to us to reduce IOP.

If the patient has established glaucoma as evidenced by visual field defects that correspond to your observation of the optic nerve head, the IOP needs to be reduced generally into the low- to mid-teens. Here we usually initiate prostaglandin therapy; our newest option in this category is Vyzulta (latanoprostene bunod 0.024% ophthalmic solution, Bausch + Lomb), which we have found to be most effective at reducing IOP.

If, on the other hand, the optic nerve is healthy but the IOP is perhaps 28mm Hg, and we want to decrease the IOP into the low 20s, we might select a beta-blocker for both efficacy and cost; however, in most instances, we simply follow the patient without therapy every six months and repeat testing annually. Don’t be in a hurry to treat. Glaucoma, on average, progresses at about 3% per year, so no rush—rather, timely attentiveness and follow-up are the keys.

Daily dosing options. The prostaglandins have been the drug of choice for initial therapy since 1996, when latanoprost first came to market under the brand name Xalatan (Pfizer). While there are now several prostaglandins to choose from, they all work about the same, with the exception of Vyzulta (see, “Vyzulta: A One-Two Punch to IOP”).



VYZULTA: A ONE-TWO PUNCH TO IOP

While VyZulta is primarily a prostaglandin, it has a secondary effect on trabecular outflow beyond its enhancement of uveoscleral outflow. This is a single molecule that is cleaved by intrinsic esterases to also release nitric oxide, which is the biochemical stimulant of trabecular meshwork outflow.

This secondary effect is what separates this medicine from the other prostaglandins. VyZulta reduced IOP anywhere between 7.5mm Hg and 9.1mm Hg in Phase III studies.¹⁻³ In preapproval studies, VyZulta decreased IOP an average of 1.23mm Hg beyond that of latanoprost.¹⁻³ The significance here is that several independent studies have established that every millimeter reduction in IOP results in a 10% decrease in the risk of glaucoma progression.⁴⁻⁶

As a prostaglandin, VyZulta performs maximally when instilled in the evening and, as with latanoprost, is stored under refrigeration at pharmacies. However, VyZulta can be kept at room temperature for up to two months once it has been dispensed to the patient. It shares a high tolerability profile with latanoprost and its 0.2% benzalkonium chloride preservative. Further distinguishing VyZulta, it comes in both a 2.5mL and a 5mL bottle.

We know that about half of all glaucoma patients end up requiring a second eye drop as they age to further decrease IOP. By using VyZulta with its dual effect, our hope is that we can push the need to add a second drop further down the road. Any time we can decrease therapeutic complexity, it enhances adherence and intraocular pressure control.

As with all branded products, coupons greatly reduce the cost to the patient. Also, many new drugs require prior authorization, so Bausch + Lomb has contracted with a company (parxsolutions.com) to help streamline this encumbrance.

1. Weinreb RN, Sforzolini S, Vittitow J, Liebmann J. Latanoprostene bunod 0.024% versus timolol maleate 0.5% in subjects with open-angle glaucoma or ocular hypertension: The APOLLO study. *Ophthalmology*. 2016;123(5):965-73.
2. Medeiros FA, Martin KR, Peace J, et al. Comparison of latanoprostene bunod 0.024% and timolol maleate 0.5% in open-angle glaucoma or ocular hypertension: the LUNAR study. *Am J Ophthalmol*. 2016;168:250-59.
3. Kawase K, Vittitow JL, Weinreb RN, et al. Long-term safety and efficacy of latanoprostene bunod 0.024% in Japanese subjects with open-angle glaucoma or ocular hypertension: the JUPITER study. *Adv Ther*. 2016;33(9):1612-27.
4. Heijl A. Glaucoma Treatment: by the highest level of evidence. *Lancet*. 2015;385(9975):1264-6.
5. Leske MC, Heijl A, Hussein M, et al. Factors for glaucoma progression and the effect of the treatment. *Arch Ophthalmol*. 2003;121(1):48-56.
6. Bengtsson B, Leske MC, Hyman L, et al. Fluctuation of intraocular pressure and glaucoma progression in the early manifest glaucoma trial. *Ophthalmology*. 2007;114(2):205-9.

Recently, Xelpros (latanoprost 0.005% ophthalmic emulsion, Sun Pharmaceuticals) became our only version of latanoprost not preserved with benzalkonium chloride—it uses 0.47% potassium sorbate instead. No refrigeration is required for long-term storage, and, as with the original latanoprost, it is dosed once daily in the evening. However, be aware that you can't just "prescribe" Xelpros, as it's not available in retail pharmacies. This medication can only be ordered through the manufacturer's two contracted pharmacies via XelprosXpress.

If we are unable to achieve the target range IOP with a prostaglandin,

we almost always add a beta-blocker, usually timolol, for three reasons: (1) it is inexpensive, (2) it is administered once daily and (3) it has good efficacy. Nonselective beta-blockers such as timolol reduce IOP about 25%, which is not that much less than the 30% to 35% reduction seen with the prostaglandin class.

Systemic beta-blockers are always among the top 10 most prescribed medicines in the United States because they are prescribed for a wide variety of heart conditions. Beta-blockers are quite safe, with the significant exception of their use in

the setting of clinically expressed asthma. Always inquire about a history of asthma prior to prescribing any topical beta-blocker.

Timolol has a long half-life, which is why it can be used once daily. Timolol is ineffective during the nocturnal sleep cycle, so it requires morning administration. We use the 0.25% formulation for patients with lightly pigmented irides (usually Caucasians) and the 0.5% for patients with darkly pigmented irides since melanin pigments tend to absorb some of this medicine.

Of our numerous glaucoma patients, 80% to 85% use a prostaglandin drop alone, timolol alone or a combination of the two.

Another relatively new once-daily glaucoma medication is Rhopressa (netarsudil 0.02%, Aerie Pharmaceuticals), which works exclusively at the trabecular meshwork to enhance aqueous outflow. Pilocarpine, a parasympathomimetic, also potentiates aqueous outflow, but through a different mechanism; it causes contraction of the longitudinal muscles of the ciliary body, mechanically opening the porous trabecular tissues. Because of its QID frequency of administration, accommodative spasm, brow ache and miosis, pilocarpine quickly fell out of favor once beta-blockers came to market in 1978.

Rhopressa works through a rho-kinase (ROCK)-mediated chemical system that reduces IOP on average about 4mm Hg to 5mm Hg and is used once daily, usually in the evening, as with the prostaglandins. The Achilles heel of Rhopressa is its proclivity to cause significant conjunctival hyperemia, which is likely to limit its acceptability for many patients. Rhopressa can cause an amiodarone-like verticillata deposition in the cornea, although this has no clinical significance. Further, some patients may experience some subtle paralimbal, splotchy and transient subconjunctival hemorrhages, also with no known clinical significant.



THE CASE FOR PILOCARPINE

A 49-year-old female has long been treated for open-angle ocular hypertension (baseline IOPs in the high 30s) with a prostaglandin and Combigan. She had 0.5 cups and healthy optic nerves when she became our patient. Her IOPs have been maintained in the low 20s during these past years. All testing is normal. Now she and her husband are trying in vitro fertilization to have a child. We wanted to see if her glaucoma medicines could be stopped during her anticipated pregnancy, so we performed a standard discontinuation trial. The patient returned in about two weeks complaining that her eyes were uncomfortable, and we found that her non-treated IOPs were in the low 60s.

While we needed to avoid a prostaglandin during pregnancy because of the rare possibility of uterine contractions, she desperately needed something. We consulted three different glaucoma subspecialists, all of whom had nothing to offer and sent the patient back to us. We then telephone consulted with a university medical center glaucoma specialist who had an idea: he recommended we restart the patient on Combigan and try 1% pilocarpine QID, since these three drugs are relatively safe. We also inserted punctal plugs in her lower eyelids to further minimize any systemic absorption. This approach brought our patient's IOPs into the mid to upper 20s during the course of her successful pregnancy, and she tolerated the pilocarpine well.

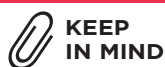Now at age 51, the patient has a healthy two-year-old and is back on a prostaglandin along with Combigan. Although the pilocarpine was a successful treatment avenue, it required QID dosing, and it is much simpler for her to use the once-daily prostaglandin.

Clinicians should also consider pilocarpine for the patient with advanced glaucoma who is on maximum medical therapy (a prostaglandin with one of the four combination drugs). Of the typical glaucoma medication classes, only prostaglandins provide a clinically significant nocturnal effect on IOP reduction. Adding 1% or 2% pilocarpine at bedtime may further reduce IOP during the night, when IOP has been documented to be highest.

Although Rhopressa could be used as initial monotherapy, its role as adjunctive therapy to a prostaglandin remains ill-defined.

Rocklatan (Aerie)—a combination of netarsudil 0.02% and latanoprost 0.005%—gained approval in March 2019 and is the newest once-daily medication that capitalizes on both the trabecular meshwork and uveoscleral outflow pathways to lower IOP. We are strongly philosophically opposed to all combination glaucoma medicines as first-line therapy because IOP may well be achieved with one-agent drugs. However, to give Rocklatan its due, clinical trials found that more than 60% of patients taking the drug achieved an IOP reduction of 30% or more, a frequency that was nearly twice that achieved by participants taking latanoprost alone.²

But remember that cost is a major deterrent to patient adherence with their glaucoma medications. We ask all of our colleagues to not immediately jump at the possibility of a new combination medicine; rather, be patient-centric in your decision-making and prescribing. In most cases, we would first try generic latanoprost to see if it achieves a target IOP range. If the latanoprost comes close to target but does not quite reach it, then we



GLAUCOMA PEARLS AND PONDERINGS

- Most patients can tolerate an IOP of 30mm Hg for many years and may never require treatment—although they merit close follow-up.
- Because early therapeutic intervention only provides modest benefits, not rushing into treatment may be best for most patients.
- Most (but not all) cases of glaucoma progress quite slowly, at about 3% per year.
- We all lose about 5,000 optic nerve fibers annually as a natural course of aging. Since we start with about 1.2 million optic nerve fibers, this is rarely a concern.
- Never believe an initial visual field result unless it appropriately correlates with your clinical assessment and a nerve fiber layer analysis study of the optic nerve head. If the visual field correlates with the optic nerve anatomy, it is likely valid. If any ambiguity exists, simply repeat the field in a few months.
- Physiological cupping is almost always round, whereas glaucomatous optic neuropathic cupping typically manifests as a somewhat vertically elongated cup. This can be quite helpful when trying to appreciate and differentiate whether the cupping of the optic nerve is physiologic or pathologic.
- Retinal nerve fiber layer hemorrhages occur in most (if not all) glaucoma patients and are transient. These hemorrhages, when seen, do not alter our therapy.
- Short-wavelength automated perimetry and frequency-doubling technology (FDT) protocols are no more useful than standard white-on-white visual field testing. We have not found FDT to be superior to standard field testing.
- Nearly 10% of patients with glaucoma or ocular hypertension have no idea why they are taking eye drops. A recent study found “poor communication and patient disease understanding persists in this setting.”¹
- Take ample time to converse with glaucoma and glaucoma suspect patients to educate and encourage them. Such conversations greatly enhance patient compliance.

1. Lowry EA, Mansberger SL. Characteristics of patients receiving treatment who deny a diagnosis glaucoma or elevated intraocular pressure in the United States. *J Glaucoma*. 2018 Nov;27(11):1029-1031

might try Vyulta or add timolol. Of course, all of this rhetoric could go out the window if manufacturers provided coupons to make these drugs more cost-effective.

Twice-daily dosing options. The two other commonly used classes of drugs, alpha-adrenergic receptor agonists and carbonic anhydrase inhibitors, do not have once-daily dosing.

If we cannot, or choose not to, use one of the once-daily drugs, we generally do a therapeutic trial of brimonidine 0.2%, originally known as Alphagan (Allergan) until Alphagan-P (Allergan), a 0.15% formulation hit the market. This is still significantly more expensive than the generic 0.2% formulation, and all three concentrations work similarly. A significant minority of patients will ultimately develop an allergy to brimonidine, as evidenced by a follicular tarsal conjunctivitis and, usually, a low-grade red eye. These symptoms often require discontinuation of this class of drugs.

Brimonidine is FDA-approved for TID administration because it has about eight hours of efficacy. We almost always prescribe brimonidine twice daily, usually to be used shortly after awakening and then again about eight hours later. Brimonidine does little or nothing during the sleep cycle and should not be used near bedtime. Patients often struggle to remember the afternoon drop (of any medicine), so suggest that your patients set a cell phone timer to remind them.

Because of cost, we almost always prescribe the 0.2% concentration of brimonidine. Combigan (Allergan) is a combination drop of 0.2% brimonidine with 0.5% timolol.

The last commonly used class of glaucoma medicine is the carbonic anhydrase inhibitors. Dorzolamide is a generic 2% solution, while Azopt (brinzolamide, Novartis) comes as a 1% ophthalmic suspension. Since these two drops are clinically equivalent, we prefer the generic solution of dorzolamide. Only rarely do either of these drops exert a robust response,



FROM THE LITERATURE

FAMILY HISTORY IN AN AFRICAN-AMERICAN COHORT

We all need to be particularly attentive to our patients with African and Caribbean heritage for myriad reasons. If you have diagnosed your patient with glaucoma and they fall into one of these cohorts, aggressively pursue ocular examinations for the families of these patients, with the ultimate goal of catching undiagnosed glaucoma as soon as possible. A study in the *American Journal of Ophthalmology* drives home this point:

- “Multiple epidemiological studies have confirmed that African-Americans are disproportionately affected by primary open-angle glaucoma and present earlier with more severe and rapidly progressive disease.”
- “Siblings of affected patients are at greatest risk of developing primary open-angle glaucoma, compared to parents or children.”
- Positive family history in a first-degree relative was associated with a 3.4 times greater risk of developing glaucoma.

O'Brien JM, Salowe RJ, Fertig R, et al. Family history in the primary open-angle African American glaucoma genetics study cohort. *Am J Ophthalmol.* 2018 Aug;192:239-47.

and they generally decrease IOP about 15%. Like brimonidine, the topical carbonic anhydrase inhibitors are FDA-approved for TID administration, but most prescribe twice daily use. While these drugs have some effect overnight, they are not as effective nocturnally as the prostaglandins, and their modest nocturnal performance precludes them from being top-tier performers.

Cosopt (Akorn) is a combination of dorzolamide with 0.5% timolol, but most simply prescribe a generic dorzolamide-timolol. Clinicians now have a generic form of the preservative-free, unit-dose Cosopt formulation to prescribe when a preservative-free formulation is necessary.

Azopt is also available in a combination but with brimonidine, not a beta-blocker, making it a reasonable choice for patients with asthma who truly need both ingredient drugs. This brand name-protected combination ophthalmic suspension, Simbrinza (Novartis), is relatively expensive and can intelligently be prescribed only if monocular therapeutic trials of each ingredient drug show meaningfully efficacy, and it is affordable to the patient. Otherwise, we must prescribe both individual generic drops. While

KIDS WITH LARGE OPTIC NERVES

We all see young people with large and impressive optic nerve head cupping, and it does give us pause. However, juvenile glaucoma is almost invariably accompanied by significantly increased IOP, and most suspicious-appearing optic nerves have IOPs within normal limits, unless they have thickened corneas.

The key to managing these patients is examining the parents and other siblings. Anatomic features are inherited, and central corneal thickness is the most heritable aspect of ocular anatomy. Thus, measuring the parents' corneal thicknesses can help you understand the patient's inherited ocular anatomy. To be safe, also obtain a retinal nerve fiber layer analysis and take baseline photos on the patient. Once we establish that the young person likely has large physiological cups, we typically follow the child annually.

both are relatively inexpensive, the patient must wait at least five minutes between each instillation. This is certainly suboptimal compared with one

GLAUCOMA MEDS AND CATARACT SURGERY: Q&A

Q. *Should patients on anticoagulation medicines who are contemplating intraocular surgery be advised to stop these medicines during the perioperative period?*

A. There is no increased risk of intraocular hemorrhage associated with antiplatelet therapy. However, newer anticoagulants may decrease the risk of bleeding compared with warfarin.

Q. *Should patients taking a topical prostaglandin be advised to stop one of these medicines during the perioperative period, since these medicines have a warning regarding cystoid macular edema?*

A. Our broad observation of expert behavior shows that cataract surgeons do not alter patients' glaucoma therapy based on cataract surgery.

bottle containing both drugs, but the less expensive two drugs may be essential for cost-sensitive patients.

THERAPEUTIC TIMING

The actual time of treatment initiation for IOP control is relatively straightforward; the ultimate challenge, however, is knowing the optimal time to start therapeutic intervention. Equally good doctors have different thresholds for therapeutic initiation. The good news is that, with rare exception, glaucoma is a slow pathological process and there is rarely a need to rush into therapy. Attentively following patients every four to six months is reasonable and can allow more thoughtful, deliberate decision-making when the time comes to start treatment.

We generally see patients every three months initially and extend those visits out to every four months as we become comfortable with therapeutic success and the patient's understanding of their medications and the need for timely follow-up. Ultimately, in many cases, we end up seeing them every six months. We generally repeat retinal nerve fiber layer measurement, perform visual field assessments and perform a dilated examination annually. Since it is possible to obtain stereoscopic biomicroscopic condensing lens-enabled views of the optic nerve head through a 3mm or larger pupil, we do a quick ophthalmoscopic assessment between the annual dilated examinations.

But clinicians must remember that

people are not the best of patients. They often quit taking their eye drops and, on occasion, no-show for scheduled exams. Clinicians must develop an in-office system to track these patients so that if they skip follow-ups, you will know. This should prompt a telephone call to the patient in an effort to reschedule. Good patient education by the optometrist goes a long way to ensuring good patient cooperation and care.



FROM THE
LITERATURE

PERSPECTIVE ON OCULAR HYPERTENSION TREATMENT STUDY

A recent journal article enumerated five key take-home points from the landmark OHTS study:

- Approximately 5% of Americans over the age of 40 have ocular hypertension.
- Screening tests include retinal nerve fiber layer assessment and visual field testing.
- One study found the observation group developed POAG in an average of six years compared with 8.7 years in the medication group.
- "There is little absolute benefit of early treatment in low-risk ocular hypertensive patients. Most ocular hypertensive patients fall into this group and probably can be followed less frequently without treatment."
- The authors identified five factors—age, IOP, central corneal thickness, vertical cup-to-disc-ratio and visual fields—that all merit our attention.
- We would like to add a sixth "key factor" to this list: measuring the status of the retinal nerve fiber layer. If clinicians are keenly attentive to these six factors, it is our opinion that glaucoma would never be missed. Although true glaucoma is a progressive optic neuropathy, it usually takes a few years for conversion from ocular hypertension to glaucoma. There is rarely a need for rushing to therapy; even with traditional therapy, conversion occurs, but it does extend the time of conversion by about two-and-a-half to three years. At that point, therapy must be modified to achieve further IOP reduction.

Gordon MO, Kass MA. What we have learned from the Ocular Hypertension Treatment Study. *Am J Ophthalmol.* 2018;189:24-27.

One thing is for sure: there is a huge population of undiagnosed glaucoma. The potential is there for an enormous public health benefit if optometrists are vigilant in diagnostic attentiveness and enthusiastically embrace the clinical care of these patients, or send them to an optometric colleague who will.

NORMAL-TENSION GLAUCOMA: A FRESH PERSPECTIVE

Patients with statistically normal IOPs who still show signs of glaucomatous optic neuropathy are more common than you might think. In fact, normal-tension glaucoma (NTG) is now thought to account for 20% to 40% of all open-angle glaucoma patients, and prevalence is considerably higher in patients of Japanese descent. Based on the Collaborative Normal-Tension Glaucoma Study (CNTGS), we know that 80% of treated patients and 60% of untreated patients progress within three years; at five years, 80% and 40% do not progress, respectively.³



OBSERVATIONS FROM THE “KING OF GLAUCOMA”

Dr. Harry Quigley of Johns Hopkins is, in our opinion, the ultimate authority in glaucoma, so when he speaks, we listen. From his November/December 2018 *Glaucoma Today* article, we share these insights. The publication may be non-peer reviewed, but Dr. Quigley is an expert of the highest order:

- “For the first two to three years of care, we do not truly know whether the patient’s visual field or OCT is stable or getting worse, so we use an intraocular pressure reduction goal that is individualized for each patient.” This observation is why we cannot judge progression based on a single visual field. With exceedingly rare exception, glaucoma progresses slowly, such that true progression takes a minimum of two to three years to reliably show itself.
- Regarding the determination of baseline IOP (on a patient you might inherit from another practitioner), “take the patient briefly off any drop treatment that he or she may have been prescribed for a couple of visits, reassuring the patient that damage will not progress in a week’s washout.” We often inherit patients from all over the United States who are currently treated for glaucoma. In most cases, depending on their stage of progression, we ask them to stop their drops for two weeks, and then we recheck their IOP.

Over the decades, we have seen that about a third of these patients are being treated for a disease they do not have. That is, their on-treatment and off-treatment IOPs are the same. It may be that some of these people do indeed have glaucomatous optic neuropathy but are on an ineffective treatment, or it may be that they are simply not using the previously prescribed eyedrops as they should be; thus, a heartfelt, person-to-person conversation regarding proper use of any medication may be the most critical aspect of their care. Assuming proper use but non-response to the previous medicine, a new treatment regimen can be intelligently attempted as a therapeutic monocular trial.

- “If the patient’s target IOP is 15mm Hg, and IOP at this visit is 18mm Hg, should one change the target or add more drops? Neither. Instead, try to assess whether the patient is adherent with the prescribed treatment. At least half the time, with improved adherence, the patient regains the target. For a patient who is achieving his or her target IOP, and yet is having confirmed worse visual field, improved adherence is still a likely solution. If it is not, a lower target and closer OCT and visual field follow-up are needed.”
- “With every patient, a balance must be achieved between the benefits of IOP reduction and the burdens of therapy. Setting a target IOP can help codify our best estimate for where this balance lies, but it requires evaluation of multiple factors in addition to IOP and the recognition that the target may have to be adjusted based on the clinical course of each patient.”
- It is our duty to have meaningful conversations with our patients and to form a team-based relationship to ensure optimum therapy.

Sit AJ, Quigley HA. Target IOP: to set or not to set? *Glaucoma Today*. 2018;16(6):42-45.

Because the odds of progression are about 50/50, we need to attentively follow these patients and therapeutically intervene if there is any evidence of progression.

Several discoveries have updated our understanding of this condition

since the CNTGS. For example, recent data suggests about 10% of patients continue to progress, even with ideal IOP reduction. In those uncommon cases, we must redouble our efforts to aggressively decrease IOP.

In addition, research suggests large

diurnal IOP fluctuations lead to misdiagnosis of NTG because clinicians miss the peaks of elevated IOP in a large number of patients with progressive primary open-angle glaucoma (POAG).⁴ One study found 80% of medically controlled NTG patients had prolonged nocturnal IOP spikes, and 96% of NTG patients had more IOP variability than healthy patients. Such a discovery is key for making treatment decisions, considering progression is strongly associated with IOP amplitude.⁴

The same study found NTG patients with a baseline IOP of less than 15mm Hg had significantly increased IOP at bedtime, and progressing patients with IOPs at target levels had mean peak IOP well above target at night. The researchers concluded that increased nocturnal IOP could be a risk factor for progression in NTG.⁴

New technology such as 24-hour monitoring may one day help correct this error by documenting IOP spikes above target levels. While in-office monitoring is impractical, at-home IOP-monitoring devices, such as the Icare Home tonometer, could be useful tools to measure diurnal IOP and help us fine-tune our understanding of the patient’s IOP profile.

For reasons that are not yet understood, there is agreement that disruptive blood flow to the optic nerve describes the pathophysiology.⁵ Vasospasm is thought to play a role in some patients having disorders such as migraine and Raynaud’s disease. Subnormal nocturnal blood pressure can add further insult, which is why obstructive sleep apnea syndrome needs to be addressed in some of these patients. Sleep studies may be key to search for this common comorbid condition. Clinicians should be careful to prescribe systemic beta-blockers and especially calcium channel blockers for morning administration to avoid potentially damaging an already subnormal decrease in nocturnal blood pressure.

Research suggests both brimonidine and timolol may exhibit some degree



GLAUCOMA AND EXERCISE

Often, patients ask if there is anything they can do to help their glaucoma. We have historically reiterated to these patients, “just be faithful to taking your eye drops!” Although we have known for years that consistent exercise can be helpful in the setting of glaucoma, the degree of benefit demonstrated in a recent study was surprising.¹ Still, getting patients to make lifestyle changes is a formidable challenge—think of discussing weight loss benefits with patients with diabetes or idiopathic intracranial hypertension, and the benefit of smoking cessation for patients with age-related macular degeneration.

Whether they take our evidence-based advice or not, we must share this knowledge with our patients and do our best to encourage them to modify their lifestyles.

- Recommend 150 minutes of moderate-intensity aerobic exercise and two days of resistance exercise each week.²
- Such exercise may reduce glaucoma risk by as much as 40% to 50%.²
- Promote that physical activity can help to prevent glaucoma, in addition to other chronic diseases.
- “The magnitude of a 40% to 50% reduced risk of developing glaucoma by being active and fit is surprising, and may be one of the strongest factors in glaucoma prevention, besides aging.”²

1. Meier NF, Lee DC, Sui X, Blair SN. Physical activity, cardiorespiratory fitness, and incident glaucoma. *Med Sci Sports Exerc.* 2018;50(11):2253-58.

2. Crist C. Staying fit might cut glaucoma risk. *Reuters Health News.* www.reuters.com/article/us-health-glaucoma-fitness/staying-fit-might-cut-glaucoma-risk-idUSKBNL21JZ. August 17, 2018. Accessed March 27, 2019.

of neuroprotection, but this quantitative component requires further investigation.⁵

Regarding therapy, the CNTGS found a prostaglandin combined with timolol was the most effective in lowering IOP in NTG. But remember, this study was done prior to the availability of Vyulta, Rhopressa and Rocklatan,

so the role of these newer medications is not yet fully understood. If progression endures, even with a 30% reduction in IOP, additional topical eye drops may be required to drive the IOP lower, even into the low teens. For patients with sufficient angle pigmentation (as determined by attentive gonioscopy), consider referring for—or

even performing, if your state allows—laser trabeculoplasty, which can reduce IOP about 20%. Various surgical procedures may help reach the target IOP if these primary interventions fail.⁴

But the best intervention is actually making the right diagnosis by performing diurnal curves and documenting IOP peaks. This will make sure your patient truly has NTG and not just “missed” higher IOP readings. A device such as the Icare Home tonometer can help to make this determination.

Once you properly diagnose NTG and document compelling evidence of progressive optic neuropathy (as evidenced by true progression of visual fields and nerve fiber layer diminution), then aggressive IOP lowering is standard of care. ■

1. Hong SW, Koenigsmana H, Ren R, et al. Glaucoma Specialist Optic Disc Margin, Rim Margin, and Rim Width Discordance in Glaucoma and Glaucoma Suspect Eyes. *Am J Ophthalmol.* 2018;192(8):65-76.

2. Brubaker J, Teymoorian S, Lewis R, et al. Once-daily fixed-dose combination of netarsudil 0.02% and latanoprost 0.005% in ocular hypertension/open-angle glaucoma: 12-month data from MERCURY-1. Presented at the 28th Meeting of the American Glaucoma Society, March 1-4, 2018; New York, NY.

3. Collaborative Normal-Tension Glaucoma Study Group. The effectiveness of intraocular pressure reduction in the treatment of normal-tension glaucoma. *Am J Ophthalmol.* 1998;126:498-505.

4. Razeghinejad MR, Lee D. Managing Normal-Tension Glaucoma by Lowering the Intraocular Pressure. *Surv Ophthalmol.* 2019;64(1):101-16.

5. Adegate J, Rahmatnejad K, Waisbourd M, Katz LJ. Intraocular pressure - independent management of normal-tension glaucoma. *Surv Ophthalmol.* 2019;64(1):101-10.



A FINER POINT OF GLAUCOMA PATIENT CARE

In patients with advanced asymmetric cupping, is there anything the patient can do, other than adhere to their medical therapy? Probably. A recent study shows patients' habitual sleeping positions may be exacerbating their optic neuropathies, which potentially impacts IOP.¹ When patients sleep with their face pressed into the pillow on one side, IOP can increase on that side from direct physical/mechanical pressure. Even if their eye is not directly pressed into the pillow, just having the more pathologic optic nerve in a downward position can result in increased IOP in that eye compared with the upward facing eye.

Wearing a Fox shield during sleep may mitigate the increase induced by direct pillow pressure. Clinicians should educate patients about trying to sleep with their more advanced glaucomatous eye in the upward position; sleeping on their back with their head elevated may offer an advantage as well.

These are, admittedly, fine points, but in the setting of advanced or advancing disease, every effort to protect against further progression is worthwhile.

Meurs I, Thepass G, Stuij A, et al. Is a pillow a risk factor in glaucoma. *Acta Ophthalmologica.* 2018;96(8):795-99.

FLEX YOUR THERAPEUTIC MUSCLE WITH CORTICOSTEROIDS

When ocular inflammation is present, only one class of drugs can provide unparalleled relief for patients. Don't hesitate to use it.

In this 23rd issue of the *Clinical Guide to Ophthalmic Drugs*, our thoughts on the virtues of corticosteroid usage for eye inflammation remain unwavering.

When inflammation is present, these drugs continue to be the most powerful and effective agents optometrists can prescribe in patient care. Their applications should be well integrated into our clinics—aggressively prescribing them when indicated will prevent further damage.

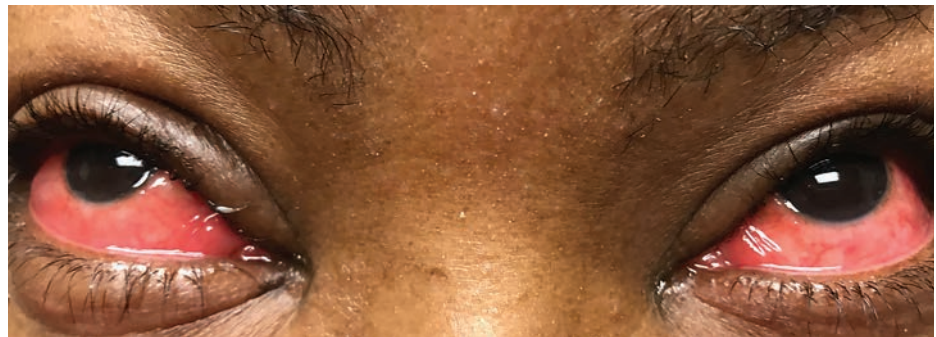When dosed properly, steroids work expediently and effectively. The three authors of this guide have collectively encountered many thousands of patients in our clinics, many of whom have presented with ocular inflammation. Nearly all were treated with steroids, and not one got patient worse on the regimen, to our knowledge. In fact, in more than 75 years of combined practice, we have yet to encounter a patient whose inflammation did not drastically improve on topical and/or oral corticosteroids.

However, an unfortunate stigma sur-

rounds steroids, possibly due to uncertainty on the part of the prescriber regarding side effects. These notions must be countered with accurate findings that demonstrate the overwhelming advantages of these drugs—and the detriment to the patient of not using them expediently when indicated.

For example, we see cases of acute red eyes weekly. Since up to 80% of conjunctivitis presentations are viral in nature, with secondary inflammation, prescribing antibiotic monotherapy for acute red eye runs the risk of subjecting the eye to further damage from prolonged untreated inflammation.¹ It also increases the antibiotic resistance profile for the patient (a significant concern in medicine). This is all the more inadvisable given that only a minority of patients with acute red eye will benefit from antibiotics to any degree, based on our years of experience.

Outside the realm of eye care, patients who seek red eye evaluation and treatment



This patient with epidemic keratoconjunctivitis was treated successfully with a betadine wash and Lotemax.

QUOTABLE

“Most cases of acute conjunctivitis are nonbacterial in origin, and even among those with a bacterial cause, antibiotics have only a modest benefit in reducing symptom duration. The complications of acute conjunctivitis are so rare that there is no evidence from systematic reviews that antibiotics reduce rates of complications.”

Keen M, Thompson M. Treatment of acute conjunctivitis in the United States and evidence of antibiotic overuse: isolated issue or a systematic problem? *Ophthalmology*. 2017;124(8):1096-8.

from other medical entities (e.g., urgent care clinics, emergency departments, primary care) likely will also encounter a reluctance to prescribe steroids for acute red eye. Since conjunctivitis presents in various forms (viral, allergic, bacterial or nonspecific), the untrained professional might not accurately segregate the diseases or understand the importance of steroids to controlling inflammation in this setting.

At the same time, many physicians and medical professionals tend to overprescribe antibiotics, given their well-known safety profiles. This mindset to “play it safe” actually can do more harm than good. Inflammation does not go into clinical remission with antibiotics alone and habitually delays patient recovery. Thus, in the setting of acute red eyes, we unhesitatingly prescribe topical ophthalmic steroids, either as monotherapy or in combination with antibiotics. By the same token, it’s essential to rule out herpetic etiology—the main contraindication to topical steroids.

To be clear, improper use of corticosteroids can have unwanted and damaging results for your patient under rare circumstances. While there are plenty of indications for the use of topical steroids, one contraindication exists: epithelial herpetic infection.

And when the diagnosis is uncertain, you should use caution. For example, the clinical presentation of an *Acanthamoeba* or fungal keratitis can

make it difficult to diagnose in the early stages. The use of a corticosteroid—even if it is a combination antibiotic/steroid—could worsen the condition.

In every case of prescribing steroids, make sure to see the patient back for timely follow-up to evaluate the progress of the therapy.

NEED FOR FOLLOW-UP

In all cases, proper follow-up is paramount. Patient education and open discussions minimize misconceptions and concerns about a given disease or therapy, and strengthen the doctor-patient trust. This, in turn, reduces the likelihood of patients seeking unwarranted second opinions that can lead to a delay in care.

Acute conjunctivitis rarely presents in textbook fashion. More often than not, the eye will just show signs of nonspecific inflammation. While this shouldn’t discourage your willingness

to treat with topical steroids, having the patient return to you in a timely manner will reveal ineffective treatments or misdiagnosed conditions. That way you can quickly alter the therapy if necessary.

If you have nagging concerns from the start, call the patient in a couple of days to check on the patient’s progress. Patients love having their doctors call to check on them.

As one example, let’s say you examine a patient with typical lesions that could be Thygeson’s superficial punctate keratopathy (SPK) or herpetic eye disease. Since most red eyes are inflammatory in nature, we are inclined to initiate therapy with a steroid. However, in the uncertainty of the diagnosis, we would tell the patient something like this: “This medicine should help your eye get better quickly but, at this time, the diagnosis of your condition is not completely clear, and there is a chance your eye could worsen on this drug. It is important that you let me see you again in a couple of days. I will be glad to work you in anytime.” As previously mentioned, this truly caring conversation is key to optimal patient care and rapport.

All of this falls under the heading of “patient management” and goes well beyond mere disease management. Trying to solely manage disease without also managing the patient often results in frustration for both doctor and patient. (This not only applies

THREE REASONS WHY ANTIBIOTICS ARE OVERPRESCRIBED IN EYE CARE

During our many years in clinical eye care practice, we have identified the following reasons why some doctors overprescribe antibiotic agents:

1. Some optometrists neglect to stay informed about the latest research and become therapeutically complacent.
2. Clinically differentiating between various types of conjunctivitis can be challenging. This leads providers to prescribe antibiotics “just in case” there is an underlying infection.
3. The patient perception that antibiotics are a harmless cure-all for their ailments leads many patients to frequently request prescriptions “to be safe.” Providers often submit to these unfounded petitions to maintain or improve patient satisfaction.

to corticosteroid treatment but also to the management of any eye condition.)

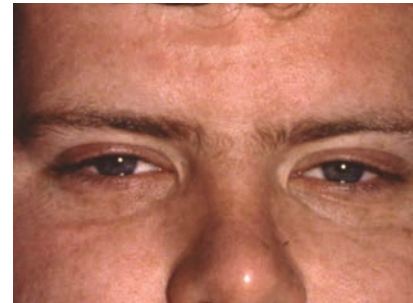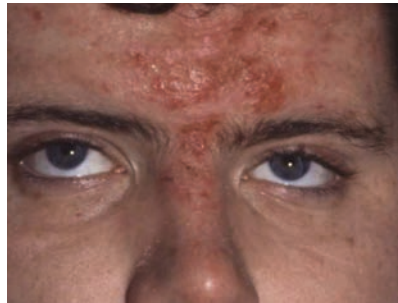MAXIMUM EFFICACY STEROIDS

Another common pitfall by optometrists is to hesitantly prescribe steroids to “test the waters”—an approach that neither leads to symptomatic relief nor expedites disease remission. In our experience, “hammering” inflammation with corticosteroids at initial presentation quickly suppresses the inflammatory cascade, after which an appropriate tapering schedule can be executed if indicated.

Clinically, we have found the two most efficacious topical ophthalmic steroids over the last several years to be Durezol emulsion (difluprednate 0.05%, Novartis) and Pred Forte (prednisolone acetate 1%, Allergan).

Durezol. Often employed as a heavyweight of topical corticosteroids, Durezol is usually looked upon favorably when moderate to severe inflammation needs to be rapidly suppressed. This drug is manufactured as an emulsion and does not need to be shaken before use.

The drug has a long history of use in severe or non-resolving iritis and is gaining recognition as a popular



As vital as topical steroids are to clinical practice, optometrists must remember that oral steroids should also be readily used, not feared—at least for short-term use (less than a week). Further, after a single week of prednisone therapy, it can just be stopped, not tapered. Take this patient, for example. An office accountant for a fiberglass factory, he would occasionally visit the actual plant. He presented with these facial and ocular symptoms (at left), showing an obvious allergy to the plant’s environmental assaults. With 40mg of oral prednisone, his symptoms improved significantly in three days. He was educated on the need to wear adequate face protection whenever he visits the factory.

A NEW TWIST TO LOTEPREDNOL

Remember when Patanol (olopatadine, Novartis) went from 0.1% to 0.2%? It also switched from twice- to once-daily usage. We find that when a product’s concentration doubles, we can use it about half as frequently.

Kala Pharmaceuticals has doubled the traditional concentration of loteprednol 0.5% to 1%. And the FDA approved its Inveltys ophthalmic suspension as a twice-daily drug with a sole indication of treating postoperative inflammation and pain following ocular surgery. To enable the twice-daily dosing, Kala also uses a micro-particle technology to enhance its ocular surface residency time and potential penetration.⁸ We envision Inveltys joining Lotemax SM and Alrex in the care of patients with dry eye disease.

TOPICAL CORTICOSTEROID DRUGS				
BRAND NAME	GENERIC NAME	MANUFACTURER	PREPARATION	BOTTLE/TUBE
Maximum Strength Steroids				
Durezol	difluprednate 0.05%	Alcon	emulsion	5ml
Lotemax SM	loteprednol etabonate 0.38%	Bausch + Lomb	gel drops	5g
Lotemax gel	loteprednol etabonate 0.5%	Bausch + Lomb	gel drops	5g
Lotemax ointment	loteprednol etabonate 0.5%	Bausch + Lomb	ointment	3.5g
Inveltys	loteprednol etabonate 1%	Kala Pharmaceuticals	suspension	5ml
Pred Forte	prednisolone acetate 1%	Allergan and generic	suspension	5ml, 10ml, 15ml
generic prednisolone sodium phosphate	prednisolone sodium phosphate 1%	generic	solution	5ml, 10ml, 15ml
Maxidex	dexamethasone 0.1%	Novartis	suspension	5ml
Vexol	rimexolone 1%	Novartis	suspension	5ml, 10ml
Moderate and Lesser Strength Steroids				
Alrex	loteprednol etabonate 0.2%	Bausch + Lomb	suspension	5ml, 10ml
Flarex	fluorometholone acetate 0.1%	EyeVance Pharmaceuticals	suspension	5ml, 10ml
FML	fluorometholone alcohol 0.1%	Allergan and generic	suspension	5ml, 10ml, 15ml
FML ointment	fluorometholone alcohol 0.1%	Allergan	ointment	3.5g
Pred Mild	prednisolone acetate 0.12%	Allergan	suspension	5ml, 10ml

postoperative medication. Clinically, we prefer Durezol over Pred Forte for several reasons: We have found it to be more effective, it does not need to be shaken prior to instillation and it does not need to be dosed as often, which increases patient compliance.

The glucocorticoid binding affinity of Durezol's active metabolite difluprednate was found to be 56 times stronger than prednisolone.² In addition, the drug's structural modifications enable difluprednate, a derivative of prednisolone, to have a more consistent potency than prednisolone.

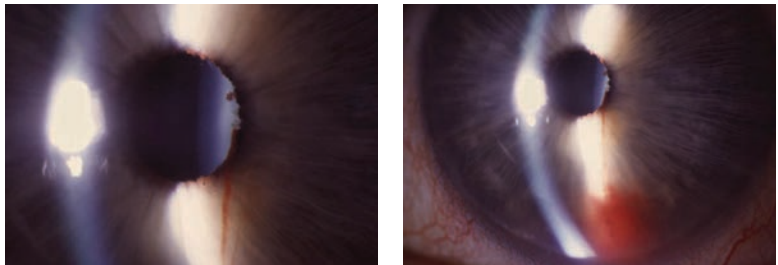
As a general rule, the more efficacious the drug, the more potential for adverse side effects. Durezol is no exception, as it can be associated with elevated intraocular pressure (IOP). Thus, best practices must be engaged, with frequent follow-ups to monitor the patient's condition and check IOP.

Pred Forte. While not as clinically

IRIS MICROHEMANGIOMAS

Also known as iris vascular tufts, these presentations are usually discovered following spontaneous hyphema. They can be unilateral or bilateral, and are almost always found at the pupillary border. Iris microhemangiomas has no known systemic associations, but can occasionally present with transiently elevated IOP. The natural course is benign and they often resolve spontaneously in about a week; thus, observation is typically the best form of initial management.¹ If treatment is necessary, cycloplegia and steroids are an option, as is argon laser.

1. Williams BK Jr, Di Nicola M, Ferenczy S, et al. Iris microhemangiomas: clinical, fluorescein angiography, and optical coherence tomography angiography features in 14 consecutive patients. *Am J Ophthalmol.* 2018;196:18-25.



This patient presented with a concern that their eye was bleeding. Note the iris vascular tufts at the pupillary border.

TIPS FOR TAPERING

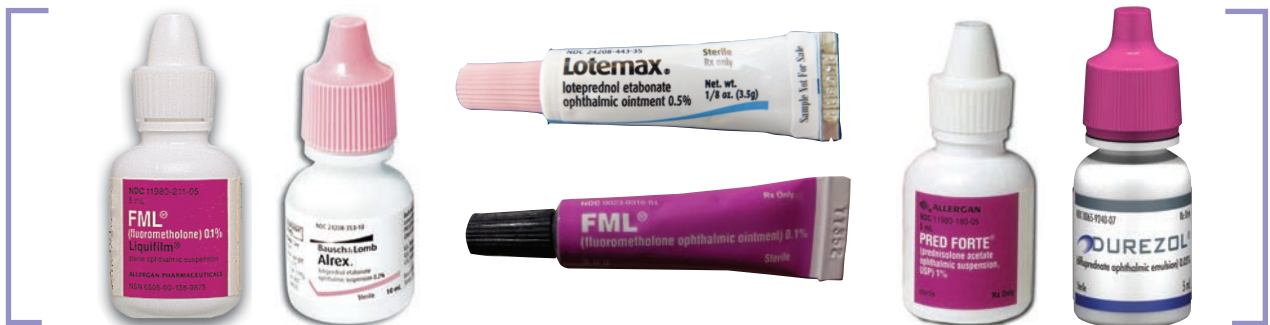Ever had a challenge tapering a patient off of a topical corticosteroid? Steroids are wonderful for short-term therapy but carry intrinsic risks when used long-term.

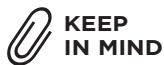Here are a few thoughts: You can usually get a patient's uveitis down to two or three times a day, or even once daily, before a relapse occurs. If a relapse does happen, increase the dosage frequency and try a longer, slower taper.

In addition, try adding a topical NSAID such as Prolensa (bromfenac, Bausch + Lomb) once daily, or generic diclofenac or ketorolac QID as you begin the next step-down off the corticosteroid. This may offer enough supplemental anti-inflammatory support to enable the continuation of the steroid taper. Or, try the oral NSAID route: Celebrex (celecoxib, Pfizer) 100mg per day for a few weeks as needed.

In some cases, long-term steroid use can be indicated. Certain patients with corneal transplants, stromal immune corneal disease, chronic uveitis or recalcitrant dry eye disease might be kept on low-dose steroids for life.

While older ketone-based steroids were frequently used for long-term therapy in the past, we recommend ester-based loteprednol SM 0.38% or 0.5% gel off-label once daily for these protracted dosing schedules. Though ketone-based steroids appear to work well in this low-dose approach, it stands to reason that loteprednol is preferable because of its enhanced safety profile as an ester-based steroid. Some patients require one drop of steroid daily to maintain control of their conditions.





RELATIVE CLINICAL EFFICACY OF TOPICAL STEROIDS

Here, based on our combined clinical experience and comparative information we have available, we rate the relative efficacy of topical steroids, starting with the most efficacious:

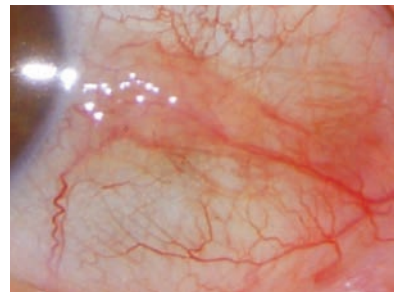
1. Difluprednate 0.05%
2. Prednisolone acetate 1%
3. Loteprednol 0.38% or 0.5%
4. Rimexolone 1%
5. Fluorometholone acetate 0.1%
6. Dexamethasone 0.1%
7. Fluorometholone alcohol 0.1%
8. Loteprednol 0.2%
9. Prednisolone 0.125%
10. Hydrocortisone 1%

effective as Durezol, prednisolone acetate 1% (not to be confused with prednisolone sodium phosphate 1%, a solution form of prednisolone) possesses impressive anti-inflammatory efficacy. Its widespread use in ocular inflammatory conditions is most notably embraced postoperatively as well as for anterior uveitis cases. Unlike Durezol, this drop is a suspension and must be vigorously shaken before instillation.

Some pharmacists will dispense generic prednisolone acetate, even when you specifically indicate “dispense as written” on the prescription. The generic options, although less expensive, are considerably less effective.³ When our patient requires maximum efficacy, Durezol is our drug of choice.

HIGH EFFICACY STEROIDS

Next in clinical efficacy are Lotemax SM and Lotemax Gel (loteprednol 0.38% and 0.5%, Bausch + Lomb), generic prednisolone sodium phos-



This inflamed pingueculum should be treated with a topical steroid. Once the inflammation is under control, the ocular surface must be kept properly lubricated to prevent further inflammatory expression.

phate 1% solution (original brand name Inflammase Forte) and generic prednisolone acetate 1%. Dexamethasone, either as a solution or suspension form, is also in this category. Of note, we have found that generic prednisolone sodium phosphate 1% solution does not penetrate transcorneally

THE LOTEPIREDNOL MOLECULE AND ITS NEW ITERATIONS

In 1998, the landscape of corticosteroid medicines was remarkably enhanced with the advent of a novel, retro-metabolically designed ester-based molecule—loteprednol. The initial suspension formulation had numerous clinical indications to include the treatment of steroid-responsive inflammatory conditions of the palpebral and bulbar conjunctiva, cornea and anterior segment of the globe, such as allergic conjunctivitis, acne, rosacea, superficial punctate keratitis, herpes zoster keratitis, iritis, cyclitis and selected infective conjunctivides “when the inherent hazard of steroid use is accepted to obtain an advisable diminution in edema and inflammation.”⁷

Since 1998, the loteprednol formulations have seen several additions, modifications and enhancements. Alex is a 0.2% concentration indicated for “the temporary relief of the signs and symptoms of seasonal allergic conjunctivitis.” Of course, the Lotemax 0.5% suspension could easily be used for this same clinical condition, as it offers a broad array of indications.

Though Lotemax ophthalmic ointment’s indication is for postoperative inflammation and pain, we have used it extensively for numerous off-label indications. These include dry eye, allergy, corneal transplant protection, blepharitis, giant papillary conjunctivitis, chronic uveitis,

stromal-immune herpetic keratitis, Thygeson’s SPK, recurrent corneal erosions, contact dermatitis, to supplement steroid eye drop therapy; acute, advanced uveitis or episcleritis; following Betadine epidemic keratoconjunctivitis treatment and for numerous other inflammatory conditions. Lotemax ophthalmic ointment is the only preservative-free corticosteroid available.

In 2012, Lotemax gel came to market and was formulated as an emulsion with no shaking required. Today, we have two improvements to the loteprednol molecule delivery systems: a 1% ophthalmic suspension (Inveltys, Kala Pharmaceuticals) and a 0.38% Lotemax SM ophthalmic gel drop. All are only indicated to treat postoperative inflammation and pain but widely used off-label for other purposes.

Clinicians can use any of these loteprednol formulations on-label or off-label, as long as they enlist them prudently and in a scientifically sound manner. For our part, we would use any of these products to treat mild to moderate inflammatory conditions of the ocular surface, most notably dry eye disease. The consensus of peer-reviewed professional literature supports this patient-centric use. In any and all clinical situations, our prime concern is how to best care for our patients; frequently, this means employing off-label applications.

STEROIDS vs. CONTACTS: WHICH IS THE GREATER DANGER TO PUBLIC HEALTH?

Anyone who gives this question any thought would have to conclude that contact lenses represent a far greater risk to public health than topical or even oral steroids. To be fair, it might not be the actual lenses but patient misuse of these devices that represent the threat. Nonetheless, to be intellectually honest, the two really cannot be separated.

Every year, there are numerous cases of microbial keratitis in the United States, as well as many deaths attributable to opioid abuse and motor vehicle fatalities. Using motor vehicles is a necessity for most of us; however, for the most part, wearing contact lenses is an option. Based on this data alone, a rational argument could be put forward to ban the use of these potentially dangerous devices.

In one retrospective cohort and trend study, researchers evaluated the laboratory results and prognostic factors of poor clinical outcomes in microbial keratitis cases over 15 years at Saint Louis University and found that *Pseudomonas aeruginosa* and other organisms were commonly recovered from microbial keratitis cases with a disproportionately high incidence, and seemed to be related to the number of contact lens-related keratitis cases.¹

They wrote, "We hypothesize that we are seeing more contact lens-related cases owing to the presence of a growing population in the St. Louis area that use and abuse contact lenses. An epidemiological analysis of our contact lens-related cases mirrors the findings of a Centers for Disease Control and Prevention report regarding the relative young age and female preponderance of contact lens wearers and their high prevalence of reported misuse of contact lenses, which predisposes them to eye infections."

The purpose of this commentary is not to denigrate contact lenses, which are a wonderful vision correction technology. Rather, we are trying to make the point that any technology has its risks when applied in the wrong manner or subjected to unsafe circumstances. Optometrists don't hesitate to prescribe contact lenses—so why all the anxiety about steroids? We encourage eye doctors to consider using topical and oral corticosteroids whenever warranted, to take advantage of their potentially significant benefits for patient care.

1. Hsu HY, Ernst B, Schmidt EJ, et al. Laboratory results, epidemiological features, and outcome analysis of microbial keratitis; a fifteen-year review from St Louis. *Am J Ophthalmol.* 2019;198(2):54-62.

as effectively as the acetate moiety.

Lotemax SM 0.38% and 0.5% gel drops. The newest version of loteprednol uses submicron (SM) particles to enhance drug dissolution in the tears, which doubles penetration transcorneally compared with Lotemax 0.5% gel drops. This variation also enables greater adherence to the ocular surface. The FDA approved the drug for the treatment of postoperative inflammation and pain following ocular surgery, but numerous off-label uses exist for such an enhanced formulation.

Neither the original nor latest formulation require shaking due to a gel-to-liquid delivery system. Lotemax SM 0.38% is approved for TID dosing, while the 0.5% version is approved for QID dosing. Of course, in the setting of more severe ocular inflammation, a more aggressive dosing schedule would be indicated. Both are preserved with a very low-dose BAK (0.003%). For perspective, latanoprost contains 0.02% BAK, and is well tolerated.

Lotemax SM and Lotemax gel are non-settling eye drops that don't require shaking before instillation. Though labeled as gels, once on the ocular surface, the drugs become a viscous liquid.

We often prefer Lotemax SM or gel as an off-label treatment for many of our dry eye patients. We also use it to treat a number of chronic, recurrent inflammatory conditions such as stromal herpes simplex keratitis, Thy-

geson's SPK, chronic uveitis, inflamed pinguecula and pterygia.

While we have found that loteprednol is not quite as efficacious as prednisolone and Durezol, its ester-based derivatives correlate to fewer unwanted side effects (e.g., subcapsular cataracts and elevated IOP). In Phase III studies, for instance, only two out of 409 patients on Lotemax gel (0.5%) had an IOP increase greater than 10mm Hg after 18 days of treatment.⁴

INJECTABLE STEROIDS FOR POST-OP CARE & BEYOND

Some injectable drugs have been approved for postoperative use after ocular surgeries and diabetic retinopathy. Optometrists involved in surgical comanagement should be aware of these new agents.

- Yutiq (fluocinolone acetonide intravitreal implant 0.18 mg, EyePoint Pharmaceuticals) treats chronic noninfectious uveitis affecting the posterior segment of the eye.
- Dexycu (dexamethasone 9% intraocular suspension, EyePoint Pharmaceuticals) is approved as a single-dose, sustained-release steroid injection to treat inflammation associated with cataract surgery.
- Dextenza (dexamethasone ophthalmic intracanalicular insert 0.4mg, Ocular Therapeutix) treats postoperative pain up to 30 days as a single treatment.

And loteprednol 0.5% suspension, when used for postoperative cataract surgery inflammation, was shown to be nearly as effective as prednisolone acetate, with less effect on IOP.⁵

Prednisolone sodium phosphate 1%. Although generic, this drug remains a viable option when an inexpensive, potent steroid is needed. Unlike many other topical steroids, the drop is prepared as a solution, not a suspension, and doesn't need to be shaken before instillation. It remains an excellent choice for older patients with arthropathies that make shaking a bottle challenging. It's also well-suited for soft contact lens wearers because it won't precipitate on the lens to the same extent as suspensions.

Prednisolone acetate 1%. Generic prednisolone acetate suspension is relatively inexpensive and is a reasonable choice for mild to moderate acute inflammatory conditions. However, it's not preferred in the setting of advanced iritis and episcleritis. Make sure you indicate "brand name necessary" when prescribing for clinical situations that are potentially vision threatening. We recommend just prescribing Durezol to bypass the bureaucratic hassle of battling with the pharmacy or insurance company.

MODERATE EFFICACY STEROIDS

The two most common topical steroids in this category are fluorometholone 0.1% suspension and Alex suspension (loteprednol 0.2%, Bausch + Lomb), both of which must be shaken prior to instillation.

Fluorometholone 0.1%. Two derivatives of fluorometholone 0.1% suspension are available: alcohol (FML, Allergan and generic) and acetate (Flarex, Eyeavance Pharmaceuticals and generic). Be advised that the acetate moiety gives the fluorometholone molecule additional anti-inflammatory effectiveness over the alcohol moiety.⁶ Because fluorometholone alcohol is available generically, it's relatively inexpensive. Though fluoro-

metholone has less chance of raising IOP than other ketone steroids, we are not as comfortable using it long-term as we are using ester-based loteprednol.

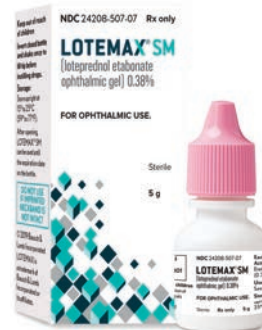Since you should use the lowest effective dose in all cases, we do not recommend FML Forte (fluorometholone 0.25% ophthalmic suspension) because the fluorometholone 0.1% concentration represents the top of the dose response curve—meaning that 0.25% is no more efficacious than 0.1%.

Alex. Another ester-based steroid, Alex (loteprednol 0.2%) is an excellent off-label treatment in cases of Thygeson's SPK, ocular allergy and maintenance therapy (if needed) for DED. Because Alex is slightly less efficacious than its "bigger brothers" Lotemax SM 0.38% and Lotemax gel 0.5%, it theoretically has a safer therapeutic profile for extended use. We often use Alex for patients presenting with allergic eye disease whose itching is accompanied by any signs of conjunctival injection, chemosis or eyelid

LOTEMAX GEL VS. LOTEMAX OINTMENT

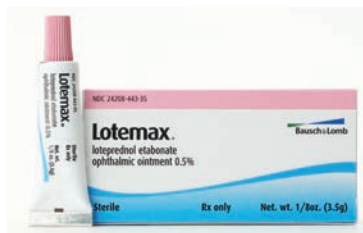Patients, practitioners and pharmacists may mix up these two medicines, so let's set the record straight.

• **Lotemax SM and Lotemax gel.**¹ Though called a gel, this comes in a dropper bottle, like a solution. However, inside the bottle it is indeed a highly viscous, semisolid gel formulation. But, through a process called adaptive viscosity, it becomes a liquid when squeezed out of the dropper. And upon instillation in the eye (no shaking is necessary), the formulation loses its gel structure altogether as the polycarbophil polymer interacts with the electrolytes in tears. Still, the drop is rather thick upon instillation and will cause a moment of initial blur until the gel fully converts into a liquid. We advise patients to allow the drop to spread out on the ocular surface for four to five seconds before blinking, so that the initial blink does not displace the drop onto the eyelid.



Because of the nature of this unique gel, the steroid does not settle out of the vehicle, so it does not require shaking. (It is best to tip the bottle back and forth once to make sure the drug enters the tip of the dropper prior to instillation, but no actual shaking is necessary.) Also, unlike suspensions, this delivery system provides a perfectly uniform dose at every instillation.¹

• **Lotemax ointment.**² This preparation comes in a 3.5g tube and contains inactive ingredients of white petrolatum and mineral oil. Because it is an ester-based corticosteroid and also because it is a preservative-free preparation, it may provide a slight safety advantage over fluorometholone ointment. Lotemax ointment is indicated for the treatment of postoperative inflammation and pain, but is also applicable in many other cases in which an ointment is useful for suppression of inflammation.²



1. Marlowe ZT, Davio SR. Dose uniformity of loteprednol etabonate ophthalmic gel (0.5%) compared with branded and generic prednisolone acetate ophthalmic suspension (1%). *Clin Ophthalmol.* 2014;8:23-9.

2. Comstock TL, Paterno MR, Singh A, et al. Safety and efficacy of loteprednol etabonate ophthalmic ointment 0.5% for the treatment of inflammation and pain following cataract surgery. *Clin Ophthalmol.* 2011;5:177-86.

OPHTHALMIC MYTHS ON STEROID USE

Myth: Never use a topical steroid if a significant epithelial defect is present.

Our Take: Corneal infiltrates are common presentations, especially in contact lens wearers. If these leukocytic infiltrates remain in the anterior stroma long enough, the overlying epithelial cells can succumb to inflammatory activity just beneath them. The epithelial defect results from subjacent inflammation. Topical corticosteroid suppression of the stroma (AKA subepithelial inflammation) rapidly enables the corneal epithelium to repopulate. Without use of topical steroids, the epithelial defect would endure for many days until innate resolution occurred. Our consistent observation has been that round or oval defects at or near the limbus are involved in inflammatory processes due to the anatomic proximity of abundant humeral immunity (antibodies) and cellular immunity (leukocytes) at the highly vascularized limbus.

Myth: Steroids can cause IOP to rise.

Our Take: While technically true, the application of topical steroids in an appropriate manner can help reduce this potential side effect. As one example, the trabecular tissue can become inflamed as a result of shingles and other anterior segment inflammatory disorders. Rarely is there a need to use anti-hypertensive medications in these situations; rather, a topical steroid often can suppress tissue inflammation, helping the IOP to renormalize.

Myth: Never use a steroid in combination with an antibiotic when treating bacterial conjunctivitis because the steroid will impede bacterial eradication and slow healing.

Our Take: This is a purely academic concept that holds no practical application. We almost always treat bacterial conjunctivitis with an antibiotic-steroid combination, since this allows us to do three things: kill the bacteria, suppress the secondary inflammation and get our patients looking and feeling better more quickly.

Myth: Be very careful with steroids; they can be dangerous.

Our Take: In all of our years of combined clinical practice, we have never found this to be the case. There are situations in which steroids could potentially worsen a patient's condition, such as with epithelial herpes simplex disease, but such a condition is nearly impossible to miss with attentive care.

To explain further, since herpes simplex viral epithelial keratitis is a unilateral condition, any unilateral red eye must prompt the clinicians to consider the potential diagnosis of herpes simplex keratitis. In every case, instill fluorescein dye to examine the integrity of the corneal epithelium. If it is pristine yet the differential diagnosis remains elusive, then prescribe a steroid because most acute red eye cases are inflammatory in nature. It is possible (though exceedingly rare) that herpes viral conjunctivitis could precede corneal disease. So in that case, prescribing a steroid might lead to corneal dendrites. This is not even a serious problem. At this point, simply stop the steroid (no need to taper) and start an oral antiviral medication; the patient will improve.

No doctor is perfect, and occasional misadventures do occur; thankfully, they can almost always be remedied fairly easily with a little clinical know-how.

Myth: Never use steroids in the setting of adenoviral infection, as they prolong ultimate healing.

Our Take: This might be academically true, but who cares? By using a steroid, the patient is going to feel much better during the course of the disease. Although it might take a few more hours to get better, the patient will be much less miserable while the tissues heal.

Myth: If you're not sure of the diagnosis, use an antibiotic for a few days initially and then see the patient back to reevaluate.

Our Take: Our many decades of experience lead us to one simple observation, although it runs contrary to conventional wisdom: "When in doubt, consider a steroid." If you are concerned or unsure about a particular patient, get the patient's phone number and call in a day or two to see how the individual is doing. This shows that you care, and you'll feel better knowing that your patient is feeling better.

swelling. We typically dose Alrex (or Lotemax) QID for one week, then BID for one to four weeks.

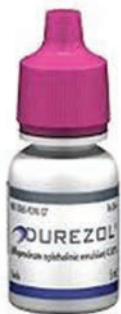It's important to be aware of ste-

roids' various delivery systems (suspensions, solutions, emulsions, gels and ointments) in addition to knowing their clinical efficacy.

STEROID OINTMENTS

Ophthalmic ointments enjoy a wide array of clinical indications. Three steroids meriting frequent clinical use are:

Lotemax ointment. The only ester-based steroid ointment available, Lotemax ophthalmic ointment (loteprednol 0.5%, Bausch + Lomb) is indicated for postoperative inflammation and pain but has many off-label clinical applications. Some examples are dry eye, allergy, corneal transplant protection, blepharitis, giant papillary conjunctivitis, chronic uveitis, stromal immune herpetic keratitis, Thygeson's SPK, recurrent corneal erosion, steroid eye drop therapy augmentation in acute advanced uveitis or episcleritis, contact dermatitis and other inflammatory conditions. Lotemax ointment is ideally suited for

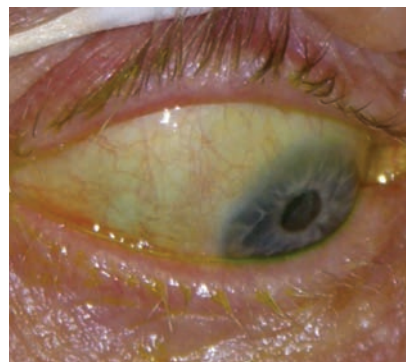
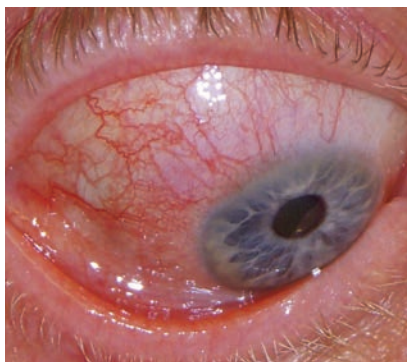


patients who complain of sandy and gritty eyes upon awakening.

FML ointment. Used similarly to Lotemax ointment, FML ophthalmic ointment (fluorometholone 0.1%, Allergan) is indicated for inflammation of the palpebral and bulbar conjunctiva, cornea, anterior segment of the globe as well as the off-label uses mentioned previously. Just make sure to keep a closer watch for steroid-related adverse effects since it is a ketone formulation.

Triamcinolone 0.1% cream. A dermatological preparation that works well for periocular dermatitis conditions, triamcinolone 0.1% cream, became generic long ago. It has been our favorite medication for many years to treat contact blepharodermatitis. It comes in 15g and 30g tubes, each costing about \$10 in most markets.

Be sure to tell the patient that the statement, "Not for Ophthalmic Use" is on the side of the tube, but that the medication is perfectly fine to use as prescribed. We explain to patients that triamcinolone (Kenalog) is frequently used by retina subspecialists for FDA-approved injection into the eye, so if some of the triamcinolone cream gets into the patient's eyes, it's nothing to be concerned about.



This patient presented with considerable ocular surface inflammation; after four days of topical steroid therapy, she has much improved.

Corticosteroids are the most essential and highly prescribed medicines in the treatment of ocular inflammation of any stripe. Their widespread use confirms that ocular inflammation is the most common clinical manifestation in eye care. It is imperative that optometrists embrace this reality and become comfortable using these essential drugs to care for patients with inflammatory eye disease. ■

1. Azari AA, Barney NP. Conjunctivitis: A systematic review of diagnosis and treatment. *JAMA*. 2013;310(16):1721-9.
2. Donnenfeld ED. Difluprednate for the prevention of ocular inflammation postsurgery: an update. *Clin Ophthalmol*. 2011;5:811-6.
3. Roberts CW, Nelson PL. Comparative analysis

- of prednisolone acetate suspensions. *J Ocul Pharmacol Ther*. 2007;23(2):182-7.
4. FDA Center for Drug Evaluation and Research. Deputy Division Director Review for NDA 202-872. 2012 Sep 27. www.accessdata.fda.gov/drugsatfda_docs/nda/2012/202872Orig1s000MedR.pdf. Accessed March 21, 2019.
5. Lane SS, Holland EJ. Loteprednol etabonate 0.5% versus prednisolone acetate 1.0% for the treatment of inflammation after cataract surgery. *J Cataract Refract Surg*. 2013;39(2):168-73.
6. Leibowitz HM, Hyndiuk RA, Lindsey C, Rosenthal AL. Fluorometholone acetate: clinical evaluation in the treatment of external ocular inflammation. *Ann Ophthalmol*. 1984;16(12):1110-5.
7. Bausch + Lomb announces successful results from phase 3 study of sub-micron loteprednol etabonate ophthalmic gel, 0.38%. www.prnewswire.com/news-releases/bausch-lomb-announces-successful-results-from-phase-3-study-of-sub-micron-loteprednol-etabonate-ophthalmic-gel-038-277195951.html. Accessed April 2, 2019.
8. Kala Pharmaceuticals. MPP Platform. <https://kalarx.com/technology/mpp-platform>. Accessed April 2, 2019.

DO STEROIDS CAUSE GLAUCOMA?

The short answer is "no," but let us explain. Traditional ketone steroids, especially dexamethasone, prednisolone and difluprednate, have a propensity to elevate IOP; ester-based steroids much less so. However, increased IOP and ocular hypertension are not synonymous with glaucoma.

Most of us have seen patients whose IOPs increased during the course of treatment. This is an uncommon side effect of steroids but one that is well known. So, how then is glaucoma avoided? We apply the following rules in our practice:

- First, never prescribe more than one bottle of a steroid drop (at least initially) to control the patient's access and exposure to the drug.
- Second, schedule all patients who are prescribed a steroid a follow-up visit in less than a month, or sooner if the optic nerve head of the patient appears glaucomatous.

If you determine that a patient is a "steroid responder," you will need to more closely monitor that patient in the future if steroids are prescribed. While such increased IOPs do occur in certain patients, we find that proper patient management means they are less common and less elevated when they do occur. But for ocular hypertension to evolve to glaucoma reflects inattentive and poorly managed care.

PRUDENT PRESCRIBING OF ANTIBIOTICS

Clinicians have a robust list of topical and systemic options to choose from. Consider these clinical tips to help you prescribe them judiciously.

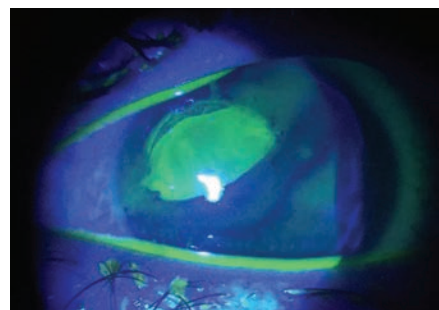
Antibiotics have been a medical mainstay since the 1940s. Unfortunately, their utility has led to over-use across many disciplines and, thus, growing resistance. Antibiotics that were once highly effective are no longer providing the same clinical benefit, contributing to as many as two million bacterial and fungal illnesses, and 23,000 deaths, yearly.¹ Given these unprecedented statistics, it's in the clinician's best interest to prescribe these medications, both topical and systemic, with discretion.

CONFIRM THE ETIOLOGY

If you are contemplating prescribing antibiotics for acute red eyes, consider this: The epidemiology for conjunctivitis is viral for more than 80% of documented cases, and it's usually self-limiting.² Thus, only one in five patients at most will benefit from an antibiotic.

Even when indicated, topical antibiotics only provide moderate benefit. You are better off prescribing a topical corticosteroid in many cases, as long as you first use fluorescein dye to rule out herpetic keratitis in a unilateral red eye.

In fact, when we encounter a red eye and are unsure of its etiology, we always prescribe either a topical steroid or steroid-antibiotic combination drug, since such acute red eyes are almost always inflammatory in nature. Early epidemic keratoconjunctivitis may also be unilateral until it involves the fellow eye.



A cat scratch to the eye required treatment with an antibiotic ointment and a pressure patch or bandage contact lens.

While the AdenoPlus (Quidel) point-of-care test can help achieve a definitive diagnosis if you suspect an adenoviral etiology, simply looking closely at the signs and symptoms can go a long way toward making the diagnosis. For one, infected eyes have discharge: mucopurulent if it's bacterial, serous/watery if it is viral and mucoid if it's chlamydia. If no discharge exists, the eye is not externally infected. Also, sectoral bulbar conjunctival injection is almost always inflammatory (think episcleritis). An exception here is early or moderate bacterial conjunctivitis, in which the superior tissues are relatively spared compared with the inferior (gravitational pull leads to increased bacterial populations inferiorly).

TOPICAL OPTIONS

If we do confirm bacterial conjunctivitis, we almost always prescribe an antibiotic-

TOPICAL ANTIBIOTIC DRUGS					
BRAND NAME	GENERIC NAME	MANUFACTURER	PREPARATION	PEDIATRIC USE	BOTTLE/TUBE
Fluoroquinolones					
Besivance	besifloxacin 0.6%	Bausch + Lomb	suspension	≥ 1 yr.	5ml
Ciloxan	ciprofloxacin 0.3%	Novartis and generic	sol./oint.	≥ 1 yr./ ≥ 2 yrs.	5ml, 10ml/3.5g
Moxeza	moxifloxacin 0.5%	Novartis	solution	≥ 4 mos.	3ml
Ocuflox	ofloxacin 0.3%	Allergan and generic	solution	≥ 1 yr.	5ml, 10ml
Vigamox	moxifloxacin 0.5%	Novartis	solution	≥ 1 yr.	3ml
Zymaxid	gatifloxacin 0.5%	Allergan and generic	solution	≥ 1 yr.	2.5ml
Aminoglycosides					
Tobrex	tobramycin 0.3%	Novartis and generic	sol./oint.	≥ 2 mos.	5ml/3.5g
Garamycin	gentamicin 0.3%	Perrigo and generic	sol./oint.	N/A	5ml/3.5g
Polymyxin B Combinations					
Polytrim	polymyxin B/trimethoprim	Allergan and generic	solution	≥ 2 mos.	10ml
Polysporin	polymyxin B/bacitracin	generic	ointment	N/A	3.5g
Neosporin	polymyxin B/neomycin/ gramicidin	generic	solution	N/A	10ml
	polymyxin B/neomycin/ bacitracin	generic	ointment	N/A	3.5g
Other Antibiotics					
AzaSite	azithromycin 1%	Akorn	solution	≥ 1 yr.	2.5ml
Ilotycin	erythromycin 0.5%	Perrigo and generic	ointment	≥ 2 mos.	3.5g
Bacitracin	bacitracin 500u/g	Perrigo	ointment	N/A	3.5g

steroid combination suspension such as Zylet (loteprednol 0.5%, tobramycin 0.3%, Bausch + Lomb), Tobradex (tobramycin/dexamethasone, Novartis) or Maxitrol (dexamethasone/neomycin/polymyxin B, Novartis). Combination therapy accomplishes two goals: it eradicates the bacteria and concurrently suppresses the secondary conjunctival hyperemia. A topical antibiotic alone only addresses one component of the condition: bacterial eradication. Although this treatment method will ultimately yield a white eye, we have found that it takes a few more days to achieve renormalization than with a combination drug.

When the cornea becomes bacterially infected, the bar is set significantly higher and a broad-spectrum antibiotic is your best option. The stage or grade and location dictate one of two options: if central in location, fortification with vancomycin (for gram-

CHALAZIA UP CLOSE

Remember, chalazia represent noninfectious accumulations of granulomatous scar tissue that forms when meibomian gland infections (internal hordeola) are untreated or undertreated. Both acute infections and secondary chalazia can be ameliorated with aggressive use of warm soaks. We advise patients to apply these for approximately 10 minutes, four to six times a day, and to keep the heat level up throughout the treatment. Patients can use any number of methods to accomplish this, including rewetting a clean washcloth, using a microwave to gently heat a sock filled with dry rice, a warm boiled egg in a stocking, or any number of commercially available heat application devices.

positive infections) and tobramycin (for gram-negative infections) is usually the norm. For less expressed, true infections (not a sterile infiltrate), and non-centrally located foci, Besivance (besifloxacin ophthalmic suspension, Bausch + Lomb) is a good option. For any corneal infection, we always prescribe either Polysporin or Neosporin ophthalmic ointment at bedtime. Here is a quick look at all of the topical antibiotics at your disposal:

Bacitracin. This ointment is strictly

a gram-positive antibiotic often prescribed for *Staph.* blepharitis. After applying warm compresses and lid scrubs, bacitracin can be applied to the lid margins before bedtime for four to six days. However, because tissue inflammation accompanies *Staph.* blepharitis, we usually choose an antibiotic-steroid combination ointment such as generic Maxitrol.

Aminoglycosides. These have fallen out of favor since the advent of fluoroquinolones. In addition, there is mini-

MIC₉₀ COMPARISONS FOR ARMOR SURVEILLANCE STUDY ISOLATES

	<i>S. aureus</i> (n=1,695)	MRSA (n=621)		CoNS* (n=1,475)	MRCoNS (n=717)
Besifloxacin	1	2	Besifloxacin	2	4
Vancomycin	1	1	Vancomycin	2	2
Trimethoprim	4	2	Clindamycin	>2	>16
Clindamycin	>2	>2	Oxacillin	>2	>2
Oxacillin	>2	>4	Gatifloxacin	16	32
Moxifloxacin	4	16	Tobramycin	8	32
Gatifloxacin	8	16	Chloramphenicol	8	8
Chloramphenicol	8	16	Ofloxacin	>8	16
Ofloxacin	>8	>8	Moxifloxacin	16	32
Levofloxacin	32	128	Ciprofloxacin	64	64
Ciprofloxacin	128	256	Levofloxacin	128	128
Tobramycin	128	256	Trimethoprim	>128	256
Azithromycin	>512	>512	Azithromycin	>512	>512

*CoNS = coagulase-negative *Staph.* species, of which the majority are *Staph. epidermidis*.
Thomas RK, et al. Clin Optom. 2019;11:15-26.

mal risk of a type IV hypersensitivity reaction. Neomycin, itself is broad-spectrum, does not cover *Pseudomonas* and is always packaged with polymyxin B or another antibiotic effective against gram-negative organisms.

Polymyxin B Combinations. These can extend the total antibiotic coverage achieved. Generic Polytrim (polymyxin B/trimethoprim) is an effective combination antibiotic available in solution form. Polymyxin B is active

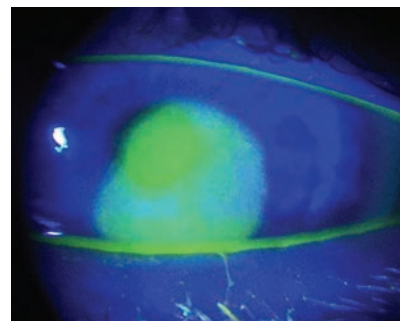
FROM THE LITERATURE

ADDITIONAL WARNINGS REGARDING ORAL FLUOROQUINOLONES

Although these have been in common use for many years now, their full clinical profile continues to change. Here's the latest from the CDC:

- "During the past ten years, the FDA has issued several warnings about potentially disabling adverse effects associated with their use, beginning with tendinopathy and tendon rupture. In July, 2018, the FDA strengthened its warning that fluoroquinolones can affect glucose homeostasis adversely, particularly in elders and patients with diabetes who take oral hypoglycemic agents."
- "Now, in its most recent update, the FDA has highlighted another recognized, much less common yet more serious adverse effect of fluoroquinolones—aortic rupture and tearing. Fluoroquinolones up-regulate cellular matrix metalloproteinases, resulting in fewer collagen fibrils of types I and III collagen, which comprise the majority of collagen in both Achilles tendons and the aorta, serving as a likely mechanism for those adverse events. Recently published studies demonstrated similar excess risks for aortic dissection and Achilles tendon rupture with fluoroquinolones, at about 2.5 to 3-folded compared with controlled populations." (About half of these aortic ruptures occurred within the first three weeks of fluoroquinolone therapy.)

U.S. Food and Drug Administration. Drug Safety Communication: FDA warns about increased risk of ruptures or tears in the aorta blood vessel with fluoroquinolone antibiotics in certain patients. www.fda.gov/DrugSafety/ucm628753.htm. December 20, 2018. Accessed April 2, 2019.



This *Pseudomonas* ulcer required treatment with Besivance and cycloplegics.

only against gram-negative bacteria. Trimethoprim is broad-spectrum against many gram-positive and some gram-negative bacteria. Polysporin combines polymyxin B with bacitracin and is only available as an ophthalmic ointment.

The pairing of polymyxin B's gram-negative and bacitracin's gram-positive action makes this an excellent, nontoxic, broad-spectrum antibiotic. Neosporin is a triple-antibiotic of neomycin, bacitracin and polymyxin B (the solution contains gramicidin, not bacitracin). We rarely use Neosporin in eye drop form because there are so many other options.

Fluoroquinolones. Besivance is the only topical ophthalmic antibiotic that comes as a suspension. As with all fluoroquinolones, Besivance provides activity against DNA gyrase and topoisomerase IV. Its broad-spectrum coverage combats gram-positive, gram-negative (including *Pseudomonas*) and anaerobic organisms, as well as methicillin-resistant *Staphylococcus aureus* (MRSA) and methicillin-resistant *Staphylococcus epidermidis* (MRSE). Ciprofloxacin, a second-generation fluoroquinolone, is the drug of choice against the gram-negative *Pseudomonas* species and remains close in efficacy to the fourth-generation fluoroquinolones. A second-generation fluoroquinolone, ofloxacin, is rarely used. However, because the drug is generic, it remains



FROM THE
LITERATURE

ANTIBIOTIC USE IN URGENT CARE CENTERS

Over the decades from a public health/patient-centric perspective, we have realized that all eye care needs to be provided by an eye doctor. A recent article in *JAMA Internal Medicine* highlights just how different care can be in, say, an urgent care center.¹ Here are some enlightening comments regarding the research:²

- “Patients with viral upper respiratory infections were treated with unnecessary antibiotics almost half the time.”
- “Despite proven harms of unnecessary antibiotic use, the battle to limit unnecessary prescriptions rages on.”
- “Likelihood of antibiotic prescription use was uniformly higher in urgent care centers than hospital-associated emergency departments (25%) or medical offices (17%).”
- “The booming market in urgent care centers has opened another gigantic front in the antibiotic wars.”

1. Palms DL, Hicks LA, Bartoces M, et al. Comparison of antibiotic prescribing in retail clinics, urgent care centers, emergency departments, and traditional ambulatory care settings in the United States. *JAMA Intern Med.* 2018;178(9):1267-69.

2. Zuger A. Antibiotic misuse is rife in urgent care centers. *NEJM Journal Watch.* July 26, 2018. www.iwatch.org/na47163/2018/07/26/antibiotic-misuse-rife-urgent-care-centers. Accessed April 2, 2019.

a reasonable, inexpensive option for bacterial conjunctivitis. Two popular fourth-generation fluoroquinolones—topical moxifloxacin 0.5%, available as Moxeza (Novartis) and Vigamox (Novartis)—function similarly. Of clinical note, Vigamox and Moxeza are the only preservative-free ophthalmic fluoroquinolone antibiotics, thus

minimizing the potential for a toxic or allergic response (although such is exceedingly rare). Gatifloxacin, a fairly effective fourth-generation fluoroquinolone, is FDA-approved to treat bacterial conjunctivitis. While useful and generically available, all fourth-generation fluoroquinolones are exhibiting increasing bacterial resistance.

Although topical antibiotics have a role in contemporary eye care, when they are needed, clinicians should use recent data, such as that from the ARMOR study (*see table on adjacent page*), to guide prescribing.³

SYSTEMIC OPTIONS

We prescribe significantly more oral antibiotics than topicals simply because we see more eyelid infections (internal hordeola and styes) than bacterial or corneal infections. While many oral antibiotics exist, we almost always prefer one of three oral options:

Cephalosporins. For most acute infectious eyelid presentations, we recommend patients use warm soaks alone to affect a clinical cure. When the presentation is more advanced, we prescribe an oral antibiotic—almost always cephalexin (originally branded as Keflex) 500mg BID for one week.

This first-generation cephalosporin provides excellent coverage against gram-positive organisms, most commonly *Staph. aureus* or *Staph. epidermidis*. Three advanced-generation cephalosporins exist, each of which have distinct differences in their mo-

ALLERGIC TO PENICILLIN?

Patients giving a history of penicillin allergy usually aren't truly allergic—the scientific literature has robustly refuted the myth that this allergy is commonplace. Another effort to temper this myth was published in the November 2018 *Journal of the American Medical Association*. Here are some key takeaways from this article:

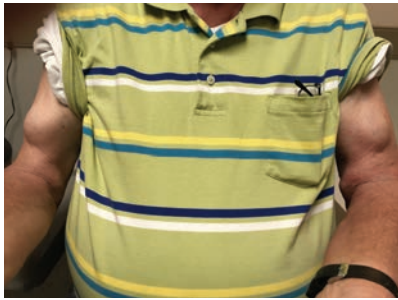- “As few as 10% of people who report they are allergic to the topical antibiotic really are.” (*Remember, cephalosporins such as cephalexin share a beta-lactam ring structure similar to penicillin, meaning a cross-reactivity between these two structurally similar antibiotics is possible. If a patient has truly had an anaphylactic reaction to a penicillin, we generally do not prescribe a cephalosporin. That being said...*)
- “In one retrospective study that included more than 65,000 patients with a history of penicillin allergy who received more than 127,000 courses of cephalosporins (which are beta-lactam antibiotics like penicillin), only three cases of anaphylaxis were associated with the drugs. That was not statistically different from anaphylaxis rates in non-penicillin-allergic patients who

received cephalosporins.”

- “Even those who have experienced a true allergic reaction [to penicillin] have about an 80% chance of losing their sensitivity to penicillin within ten years.”
- “Beta-lactam drugs appear to have benefits not exhibited by other antimicrobial classes. They do more than kill bacteria directly; they are also boosting the activities of our body's immune system.”
- “There is now underway a large national effort to do ‘oral challenge’ testing in many primary, and allergists’ offices so that such patients inaccurately reporting a penicillin allergy can be accurately determined. This is allowing large numbers of people to be ‘de-labeled’ as penicillin-allergic, which in turn allows them to be more appropriately treated when the need arises.”

Despite our personal widespread use of cephalexin, we have never had any untoward experiences prescribing it. Oddly enough, its high volume use has yet to result in increasing resistance.

Rubin R. Overdiagnosis of penicillin allergy leads to costly, inappropriate treatment. *JAMA.* 2018;320(18):1846-48.



This patient was treated with an oral fluoroquinolone a few years ago and suffered extensive tendon rupture, such that his bicep lifting capacity was profoundly limited. This is an example of why clinicians rarely prescribe this class of oral medicine.

lecular side chains: *cefuroxime* (Cef-tin), *cefprozime* (Vantin) and *cef-dinir* (Omnicef).⁴ These can be used on the rare occasion of a true and severe history of penicillin allergy.

Trimethoprim with sulfamethoxazole. Since cephalosporin antibiotics are closely related to the penicillins, we generally avoid their use in patients who have a history of an anaphylactic reaction (see “Allergic to Penicillin?”). In these cases we generally default to another drug class altogether.

Most often, we prescribe trimethoprim with sulfamethoxazole (brand names of Septra or Bactrim). We write the prescription for either of the brand names and include “generic substitution permitted.” The common dosage is two double-strength tablets/capsules taken BID for one week.

If a patient is also allergic to sulfa drugs, we consider doxycycline 100mg BID for one week.

Fluoroquinolones. We avoid prescribing any oral fluoroquinolone unless truly it is necessary because of the rare possibility of tendon rupture with this class of drug, which can be devastating when it happens.

Luckily, tendon rupture does not occur with use of topical ophthalmic fluoroquinolones.

PRESCRIBING PEARLS

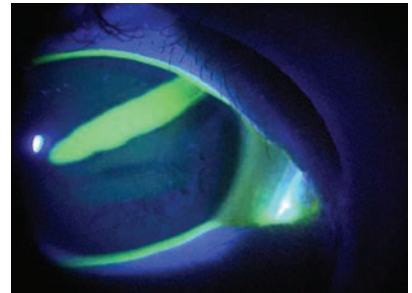
- Some female patients are prone to vaginal yeast infections concurrent with oral antibiotic use; most women know how to treat these, so just have this conversation with them prior to prescribing.

- These antibiotics are usually taken with meals, and we encourage our patients to do so to minimize any potential gastrointestinal issues. Only rarely would patients need to concurrently use a probiotic.

- For pregnant patients or children younger than 18, we always consult their obstetrician or pediatrician to gain their advice on drug selection and dosing. With children in particular, we never hesitate to call a pediatrician or pharmacist for help to ensure we are prescribing the right antibiotic—at the right dose—for each patient.

- A quick note on penicillin: Because most gram-positive bacteria produce penicillinase, which diminishes the medication’s efficacy, we do not prescribe penicillin, unless it is Augmentin (GlaxoSmithKline), which contains amoxicillin, a synthetic penicillin, with clavulanic acid. The clavulanic acid protects the amoxicillin from the degrading effects of penicillinase, enabling the amoxicillin to effectively eradicate gram-positive pathogens. The most common dosage is 875mg BID for one week. For smaller patients, we consider prescribing 500mg BID. While a 1,000mg formulation exists, we have yet to find a need to prescribe it.

- Chlamydial infections are most al-



This three-year-old had a deep corneal abrasion from a metal coat hanger. We treated with antibiotic ointment and pressure patch.

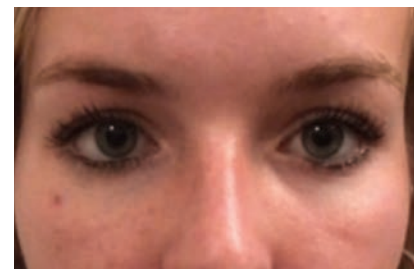
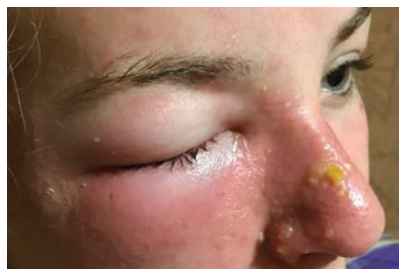ways sexually transmitted and can be present with a low-grade red eye and a mucoid discharge in the setting of giant follicles in the inferior fornical conjunctiva. A tedious and often awkward history helps to confirm your clinical findings, as can a chlamydia culture, which must be refrigerated and discarded and replaced as needed. The drug of choice for these infections is 1,000mg of oral azithromycin taken as one single dose with either 250mg or 500mg capsules or tablets. ■

1. Centers for Disease Control and Prevention. Antibiotic resistance threats in the United States, 2013. www.cdc.gov/drugresistance/threat-report-2013. Accessed April 2, 2019.

2. Keen M. Treatment of acute conjunctivitis in the United States and evidence of antibiotic overuse: isolated issue or a systematic problem? *Ophthalmology*. 2017;124(8):1096-98.

3. Asbell PA, Sanfilippo CM, Pillar CM, et al. Antibiotic resistance among ocular pathogens in the United States: five-year results from the antibiotic resistance monitoring in ocular microorganisms (ARMOR) surveillance study. *JAMA Ophthalmol*. 2015;133(12):1445-54.

4. Pichichero ME, Casey JR. Safe use of selected cephalosporins in penicillin-allergic patients: a meta-analysis. *Otolaryngol Head Neck Surg*. 2007 Mar;136(3):340-7.



A local MD misdiagnosed this patient’s periorbital bullous impetigo as shingles. Treatment with Augmentin 875mg BID for 10 days did the trick.

COMBINATION ANTIBIOTIC-CORTICOSTEROID OPTIONS

Used in the right way, these drugs pack a clinical one-two punch to address specific conditions.

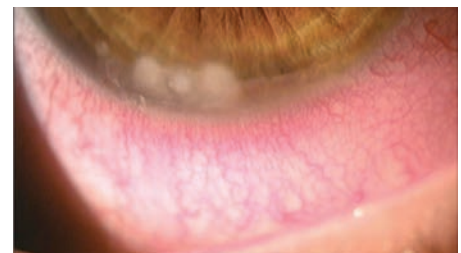Data show eye doctors are far more likely to prescribe combination antibiotic-steroid therapy for acute conjunctivitis than those outside of eye care. In one study of acute conjunctivitis, as many as 30% of those who saw an optometrist, and 23% who saw an ophthalmologist, filled a combination antibiotic-corticosteroid prescription, compared with just 8% of those seen by an urgent care physician, internist, pediatrician or family practitioner.¹

Considering most acute red eye is inflammatory in nature, we are surprised the rate is no higher than 30%—but it's informative that optometrists were slightly more inclined to embrace such therapy than ophthalmologists. Non-eye doctors have been specifically trained to avoid the use of these types of medicines and instead refer to eye doctors, who should be quite comfortable with the safety and enormous benefits of corticosteroids.

COMBINATION CONSIDERATIONS

There are several factors to consider when contemplating prescribing an antibiotic/steroid combination medication. Let's take a closer look at each:

1 *Is there a need for an antibiotic, or would steroid monotherapy be more appropriate?* An antibiotic is indicated only when there are obvious signs of infection, such as mucopurulent discharge. Many



A classic leukocytic infiltrative response from an unknown immunogenic stimulus. Use an antibiotic/corticosteroid every two hours for two days, then every four hours for four more days to re-normalize the inflamed tissues.

times, such discharge may not be grossly visible (even at the slit lamp), so a high-magnification look at the lacrimal lake may be required to thoroughly search for subtle microparticulate debris.

This close examination is performed in a manner similar to that used when one is evaluating for anterior chamber cells and flare: have the room relatively dark, and use high magnification. In addition, use your thumb or finger to raise the lower eyelid a few millimeters, which raises the lacrimal lake high enough so that the iris (not the bulbar conjunctiva and sclera) is the background for your viewing. It is easier to see whitish debris against the darker background of the iris. If no evidence of active infection exists, there is no need for an antibiotic.

2 *Is the condition primarily infectious with secondary inflammation, or is*

TOPICAL STEROID/ANTIBIOTIC COMBINATION DRUGS

BRAND NAME	MANUFACTURER	STEROID	ANTIBIOTIC	PREPARATION	BOTTLE/TUBE
Blephamide*	Allergan	prednisolone acetate 0.2%	sodium sulfacetamide 10%	susp./ung.	5ml, 10ml, 3.5g
Cortisporin*	Monarch	hydrocortisone 1%	neomycin 0.35% polymyxin B 10,000u/ml	suspension	7.5ml
Maxitrol*	Novartis	dexamethasone 0.1%	neomycin 0.35% polymyxin B 10,000u/ml	susp./oint.	5ml/3.5g
Pred-G	Allergan	prednisolone acetate 1%	gentamicin 0.3%	susp./oint.	10ml, 3.5g
TobraDex*	Novartis	dexamethasone 0.1%	tobramycin 0.3%	susp./oint.	5ml/3.5g
TobraDex ST	Novartis	dexamethasone 0.05%	tobramycin 0.3%	suspension	2.5ml, 5ml, 10ml
Zylet	Bausch + Lomb	loteprednol 0.5%	tobramycin 0.3%	suspension	5ml, 10ml

HISTORICAL PREGNANCY CATEGORY: All drugs listed above are “historically” Category C *also available generically

the condition primarily inflammatory with a perceived, rational need for bacterial prophylaxis? This determination is almost exclusively predicated on the integrity of the corneal epithelium. Superficial punctate keratitis (SPK, also called punctate epithelial erosion) does not require antibiotic protection. We all see patients with SPK practically every day, but do not prescribe an antibiotic because these epithelial defects are not predisposed to opportunistic bacterial infection. For the most part, if there is no significant breach in epithelial integrity, antibiotic prophylaxis is not needed. However, if significant epithelial compromise exists, a prophylactic antibiotic may be of value.

Most clinically significant bacterial infections cause substantial secondary conjunctival inflammation. This is why we treat most bacterial conjunctival entities with a combination medicine—to kill the bacteria while concurrently suppressing the secondary inflammation to help normalize tissues as rapidly as possible.

3. Does the patient have any known allergies to medicines? This is critically important. Always, without exception, inquire about any known allergies prior to prescribing any medication, topically or orally.

4. Which antibiotic has the highest probability of being clinically effective? For this question, we must know the expected spectrum of antimicrobial activity of each drug and the likely type of bacterial pathogen. For example, the macrolides erythromycin and azithromycin have limited effectiveness when used topically. There is increasing resistance to the fourth-generation fluoroquinolones. However, drugs such as Polytrim (trimethoprim with polymyxin B), besifloxacin, the aminoglycosides and bacitracin with polymyxin B all show coverage against common bacterial pathogens. Although aggressive marketing and common practice patterns can confuse the conversation, keeping current with the literature will enable you to separate science from “spin.”

5. Is the condition acute or chronic? Generally speaking, most conditions that evolve quickly are acute, while conditions, such as blepharitis, rosacea blepharitis and meibomian gland disease, are most often chronic and will require a more protracted use of medication. For such chronic conditions, we typically prescribe Zylet because of the enhanced safety profile of loteprednol.

For example, we commonly pre-

scribe generic Maxitrol (dexamethasone, neomycin and polymyxin B) for acute bacterial infections but would never use it for conditions that may require more than a week of treatment. Why? The neomycin (on very rare occasions) can cause a type IV hypersensitivity/allergic reaction, and the dexamethasone has the greatest propensity to increase intraocular pressure.

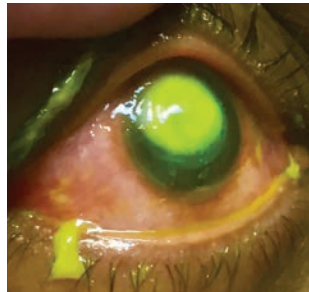
When indicated, though, generic Maxitrol is highly effective and inexpensive. Thus, we frequently prescribe it, usually with a dosing regimen of every two hours for two days and then QID for four more days.

6. Is the corticosteroid component ketone-based or ester-based? For chronic care of a condition such as staphylococcal blepharitis, we would prescribe Zylet (loteprednol 0.5% and tobramycin 0.3%, Bausch + Lomb). Why? The tobramycin is effective against gram-positive species, and the ester-based loteprednol has a much enhanced safety profile than ketone-based corticosteroids.

We typically prescribe Zylet QID for two weeks, then BID for a month, along with eyelid hygiene, of course. Thankfully, with a coupon, this optimum medicine can be obtained for about \$35 with commercial insurance.

DIFFERENTIAL DIAGNOSIS: INFECTIOUS CORNEAL ULCERS vs. STERILE LEUKOCYTIC INFILTRATES**Ulcers—Bacterial Corneal Infection**

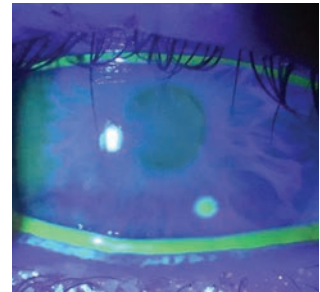
- Rare
- Usually painful
- Tend to be central
- 1:1 staining defect to lesion ratio
- Cells in anterior chamber
- Generalized conjunctival injection
- Usually solitary
- Possible tear lake debris



TREATMENT: besifloxacin or fortified vancomycin and tobramycin administered frequently until it is evident that the lesion is no longer progressing. We would also use an antibiotic ointment at night such as ophthalmic Neosporin or Polysporin. Once the antibiotic has “turned the cornea,” we blend in loteprednol in an effort to minimize any scarring.

Infiltrates—Sterile Leukocytic Infiltration

- Common
- Mild pain
- Tend to be peripheral
- Staining defect size is relatively small (compared with that of an anterior stromal infiltrate)
- No (or few) cells in the anterior chamber
- Sector skewed injection pattern
- Can be multiple lesions
- Clear tear lake



TREATMENT: antibiotic-steroid combination, usually every two hours (while patient is awake) for two days, then QID for four more days.

1. Shekhawat NS, Shtein RM, Blachley TS, Stein JD. Antibiotic prescription fills for acute conjunctivitis among enrollees in a large United States managed control network. *Ophthalmology*. 2017;124(8):1099-1107.

2. Abelson MB, Plumer A. Marginal infiltrates: A mysterious malady. *Rev Ophthalmol*. 2005;12(1):66-8.

We rarely prescribe generic TobraDex (tobramycin and dexamethasone, Novartis) because of its expense.

COMBINATION COMPONENTS

Now that we’ve established the basic principles of drug selection, let’s turn our attention to the specific combination drugs available, best discussed based first on the corticosteroid component.

There are four corticosteroids used in topical combination medicines: prednisolone, hydrocortisone, dexamethasone and loteprednol. Let’s discuss these in the general order that they came to market.

Prednisolone. Sodium sulfacetamide 10% with 0.2% prednisolone acetate ophthalmic suspension (the ointment is 0.25% prednisolone acetate) is available generically but is best known by its original brand name, Blephamide (Allergan). It comes in 5ml, 10ml and 15ml. It also comes in 15% and 30% concentrations of sodium sulfacetamide, but we never use

these two strengths because of a stinging effect. In addition, it is rarely used in contemporary eye care because of sodium sulfacetamide’s poor action against many *Staph.* species and the relatively low concentration of prednisolone.

Hydrocortisone 1%. Years ago, a combination of neomycin, bacitracin (or gramicidin), polymyxin B and hydrocortisone 1% was rather popular among primary care physicians. The antibiotic combination punch was awesome, but the hydrocortisone was inadequately therapeutic. In fact, the corticosteroid component was so weak that on the rare occasion of a neomycin reaction, it could not mask the type IV hypersensitivity and allowed the problematic neomycin reaction to manifest clinically.

This four-ingredient combination drug was originally known by the brand name Cortisporin (Pfizer) and included numerous generics, but the drug is rarely used today.

Dexamethasone. Back in the 1970s and ’80s, the “superstar” of the com-

bination drugs was Maxitrol (Novartis). It contains neomycin, polymyxin B and dexamethasone 0.1%. Neomycin is itself a broad-spectrum antibiotic, with the exception of *Pseudomonas* species. But because polymyxin B is highly anti-pseudomonal, it is used in many combination products to shore up activity in the gram-negative spectrum. Dexamethasone 0.1% is a highly effective suppressor of inflammation—so much so that if a neomycin sensitivity reaction (again, which is rare) occurs, the dexamethasone is able to mask it and ensure overall therapeutic success, thereby elevating Maxitrol to superstar status.

As we’ve emphasized several times, neomycin reactions generally are not a big deal clinically—yet drug developers are always looking for improvement. This undoubtedly was the reason for the birth of TobraDex (dexamethasone 0.1% and tobramycin 0.3%, Novartis), the blockbuster combo drug of the 1990s, now limited by its cost. Keep in mind that when the market leader’s patent protection runs

COMMON BRANDED ANTI-INFECTIVE/ ANTI-INFLAMMATORY COMBINATIONS

Prednisone

Blephamide
Pred-G

Hydrocortisone

Cortisporin

Dexamethasone

Maxitrol
TobraDex
TobraDex ST

Loteprednol

Zylet

out and generic drug companies are gearing up to jump on the manufacturing wagon, a “new and improved” version of the old drug often rolls out.

Pred-G and TobraDex. Pred-G (prednisolone acetate 1% and gentamicin 0.3%, Allergan) came to market prior to the introduction of TobraDex. But the preparation stung so much that when the more comfortable and tolerable TobraDex arrived, the latter quickly gained favor.

Tobramycin. This stand-alone, broad-spectrum antibiotic only causes any clinically significant toxic or allergic reaction in exceedingly rare cases.

However, there’s an inherent problem with dexamethasone. While a good suppressor of inflammation, it possesses significant potential to increase intraocular pressure, which limits the duration for which it can be used safely. We always try to restrict

use of dexamethasone to less than two weeks.

Loteprednol. The most recent entry into the combination category solves, or most certainly reduces, the possibility of increased intraocular pressure associated with all classes of corticosteroids. Now with Zylet, we finally have a combination drug that is both effective and safe to extend the range of clinical use beyond seven to 10 days. This makes Zylet an ideal choice for treating chronic conditions such as staphylococcal blepharitis. With the availability of coupons, this state-of-the-art combination drop is available for \$35 for most commercially insured patients.

A QUICKER RECOVERY

Over the decades, we have witnessed the use of a combination drug when all that was needed was a corticoste-

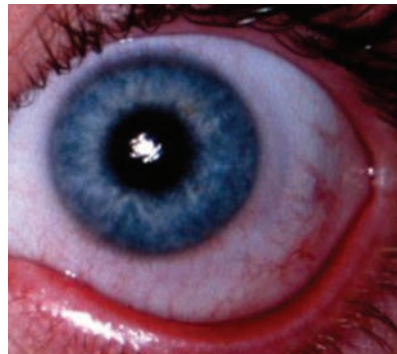
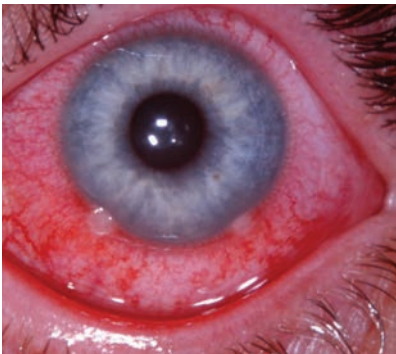
roid. The main reasons this occurs may be because of: (1) uncertainty of the diagnosis and a “shotgun” prescribing approach and (2) the irrational fear of the expression of opportunistic pathogenic bacterial superinfection.

Recognizing two characteristics may help make prescribing more precise: First, a skilled clinician who takes a complete history and performs a careful slit lamp examination can make highly accurate diagnoses. Second, opportunistic bacterial infection is just plain rare.

Because corneal infections can be devastating, we come to the defense of the “shotgun” approach to corneal infiltrates. In our vast clinical experience, though, we have never seen a “corneal infiltrate” turn out to be the beginning of an actual bacterial ulcer—but surely it can happen (probably depending upon the time of presentation and virulence of the bacterial species). Thus, we agree with the succinct and accurate guidance of ocular pharmacology expert Mark Abelson, MD:²

“Left untreated, marginal infiltrates generally disappear within a week or two. Ocular steroids have been shown to be the best and only recognized drug therapy for sterile marginal infiltrates, and their application will shorten the course of inflammation, regardless of causative origin. For many patients, a quicker recovery from symptoms such as redness, tearing, and discomfort is important for improving their quality of life. Steroids are often prescribed in conjunction with an antibiotic in order to decrease the chance of developing a secondary infection or corneal ulcer to protect against misdiagnosis.”

In closing, the combination agent we prescribe most is generic Maxitrol. This is our choice for two simple reasons: it works well clinically and is inexpensive. However, when therapeutic intervention is needed beyond two weeks, we prescribe Zylet because of the safety profile of loteprednol. ■



This classic presentation of phlyctenular keratoconjunctivitis (PKC) represents a hypersensitivity response to staphylococcal exotoxins (at left). A combination antibiotic (to reduce staph populations)-steroid (to suppress the secondary inflammatory reaction) is ideal to help restore these ocular tissues. We typically prescribe one drop Q2H for two days, and then QID for four more days. The image on the right is after three days of treatment.

OCULAR SURFACE PEARLS: DRY EYE AND BEYOND

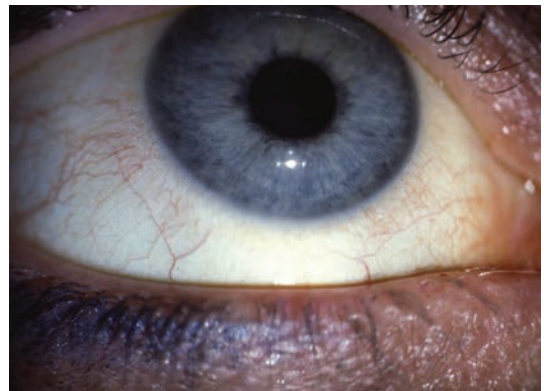Research and the latest therapies to address a variety of ocular surface conditions are constantly evolving. Read our take on what's new and what hasn't changed.

Caring for the ocular surface, already a complex endeavor, has become even more complex with significant changes to our diagnostic differentials and therapeutic armamentarium. Commonly prescribed drugs have lost their patent protection, paving the way for generics. New research has brought thinking on omega-3 supplements into question and improved diagnostics have raised previously ignored conditions to the surface. While no summary can adequately address every relevant topic, a brief look at these trends can keep your practice up to date and prepare you to care for any number of ocular surface complaints.

Let's first recap highlights of our treatment approach before expanding into other important ocular surface considerations that may be overlooked in the diagnostic evaluation.

OUR DRY EYE APPROACH

We all know that a healthy tear film requires proper functioning of the meibomian glands, lacrimal glands and conjunctival goblet cells. Of these, the first group is by far the most impactful. Meibomian gland dysfunction (MGD) is the culprit in most cases of dry eye disease (DED), steering us to the eyelids as one of the chief areas of assessment and intervention. Clinicians have the best chance to institute long-term improvement in their DED patients by maintaining proper eyelid health



As can be readily seen, this patient has a scant lacrimal lake.

and function, all the more important in an era when people stare at various digital screens too long and blink insufficiently.

Some patients can be managed for a time with over-the-counter tear supplements for as-needed symptomatic relief. Again recognizing the influence of MGD on symptoms, we tend to prioritize lipid-based artificial tears as we have found they best stabilize the tear film.

But to give patients lasting improvement, we need to address the effects of inflammation. We feel a topical steroid, most notably loteprednol, is the most clinically effective and cost-effective initial approach to suppressing the ocular surface inflammation associated with DED.

Loteprednol. Our favorite “wonder drug” is now available in six formulations:

- The original 0.5% suspension
- The 0.5% ointment

- Alrex (0.2% suspension, Bausch + Lomb)
- Lotemax 0.5% gel drops (Bausch + Lomb)
- Lotemax SM 0.38% gel drop (Bausch + Lomb)
- Inveltys 1% loteprednol suspension (Kala)

For DED in particular and ocular surface disease generally, we feel all of these products perform similarly. In addition, all of them, except the original suspension (which enjoys a litany of indications) and Alrex (approved for treating signs and symptoms of allergic conjunctivitis), are approved for postoperative care. For additional details on loteprednol, especially the newer formulations Lotemax SM and Inveltys, please see the Corticosteroids section on page 14.

Cyclosporine. Because of the patent expiration of Restasis (Allergan), several new cyclosporine options are now available, including a preservative-free ophthalmic solution at 0.09% concentration (Cequa, Sun Pharmaceutical) and Klarity-C (Imprimis), a compounded ophthalmic emulsion that contains cyclosporine 0.1% and chondroitin sulfate.

Lifitegrast. This anti-inflammatory (Xiidra, Novartis) selectively targets certain proteins on the surface of leukocytes (LFA-1 and ICAM-1) to interfere with recruitment of T-cells in patients with DED.

PERSPECTIVE ON THE DREAM STUDY

For years, most eye doctors have recommended omega-3 fatty acids in the comprehensive care of patients with DED. Then came along the DREAM study, which found no benefit beyond its olive oil placebo group, which the authors firmly claim possesses no clinically significant activity. Nonetheless, the vast majority of ODs still support the use of fish or flaxseed oil in their DED treatment regimen, and with good cause.

Beyond the DREAM study, other peer-reviewed literature shows posi-

tive effects of the supplement for dry eye. The Women's Health study found each gram of oral long-chain omega-3 essential fatty acids consumed each day led to a 30% reduction in the risk of DED.¹ A more recent randomized, double-masked, placebo-controlled clinical trial found a moderate dose of omega-3 fatty acids—about 1,000mg of EPA and about 500mg of DHA per day—can reduce tear osmolarity and increase tear stability in patients with DED.² Ultimately, the study found three interesting things: (1) the omega-3s provided significant improvements in tear film stability; (2) onset of benefits, including hyperemia, happened within 30 to 60 days; and (3) krill oil appears to be a touch more effective than fish oil.

A 2018 literature review of ocular rosacea therapies more specifically cited two well-designed studies that showed improvements in subjective symptoms and objective signs of MGD with omega-3 fatty acids. Managing both DED and MGD are crucial factors in ocular rosacea.³

With results like these, it's no wonder the DREAM study has us all scratching our heads. Ultimately, the preponderance of the literature finds value in such supplementation, and we will continue to use them for our own dry eyes, as well as those of our patients.

NEUROTROPHIC KERATITIS

Because sensory innervation is required to maintain epithelial integrity, any condition or surgical procedure that harms trigeminal innervation to these tissues can cause neurotrophic keratopathy.

The most common situations that lead to such epithelial compromise are herpes simplex keratitis, herpes zoster ophthalmicus and any

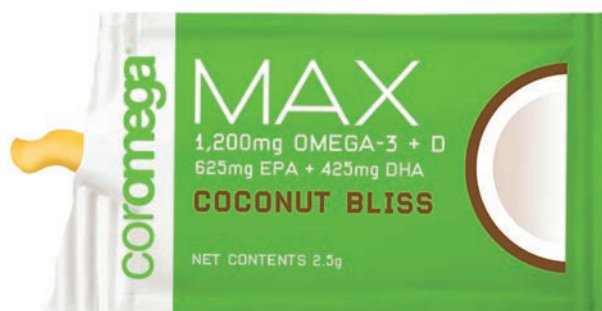IS BAK REALLY THAT BAD?

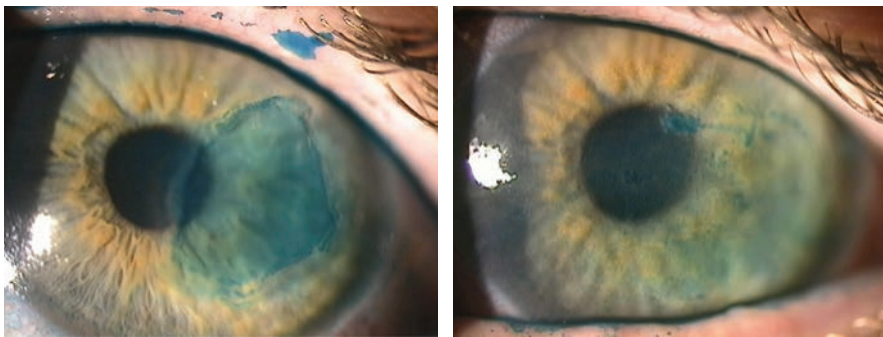
Let's start by gaining some perspective. The original 0.03% Lumigan (Allergan) was not well-tolerated until the manufacturer reformulated it to a 0.01% concentration. Paradoxically, this nicely enhanced reformulation contains four times the concentration of benzalkonium chloride (BAK). Latanoprost also has a relatively high concentration of BAK (0.2%), yet it remains quite tolerable.

Thus, the existence of BAK in the formulation may not be the problem, so much as the amount the ocular surface is exposed to. If a patient is using a preserved over-the-counter artificial tear, another preserved topical eye drop and they have advanced DED as evidenced by superficial punctate keratopathy, we should consider a preservative-free product to avoid overly exposing the ocular epithelial tissues to more toxic levels of BAK. Until then, clinicians may not need to worry so much about the possible effects of BAK. The old adage of "moderation in everything" holds true here as well.

surgical procedure where the ophthalmic division of the trigeminal nerve is damaged.

The epithelium tries to mitotically repopulate these epithelial defects, but because of complex neurochemical compromise, non-healing defects sometimes endure, evident from the classic rolled edges. Remember: bacterial ulcers always have subepithelial (anterior stromal) whitish lesions,





This is a classic case of neurotrophic keratopathy (at left). The patient had neurosurgery two days prior, during which her nasociliary nerve was cut. After intensive topical treatment for several weeks with preservative-free, lipid-based artificial tears by day and preservative-free ointment at bedtime, her epithelium finally healed (at right). We certainly hope Oxervate can fast-forward the healing process for other patients with this condition.

but only the epithelium is involved in neurotrophic keratitis. Traditionally, we have used preservative-free artificial tears and therapeutic soft contact lens with gentle antibiotic cover. In August 2018, a new medicine, Oxervate (cenegermin 0.002%, Dompé), was FDA-approved to help enhance re-epithelialization of non-healing epithelial defects, associated with neurotrophic keratopathy. Oxervate is a human nerve growth factor solution with an intricate formulation and administration protocol. It is instilled six times a day at two-hour intervals for eight weeks.⁴ In the Phase III studies, 70% of patients had complete healing in eight weeks.⁵

While this wonderful new medicine is highly welcomed, it will likely remain a tool for cornea subspecial-

ists and cutting-edge optometrists and ophthalmologists. We will have a better understanding of Oxervate's clinical utility once it has been in use for a year or two, but we are excited that there is now a medicine available to help treat patients with this challenging corneal pathology.

ADD CCH TO YOUR DIFFERENTIALS

For decades, superior limbic keratoconjunctivitis and chlamydia conjunctivitis have been cited as the two most commonly missed anterior segment conditions. It seems we should add a third clinical condition to the list: conjunctivochalasis (CCH).⁶

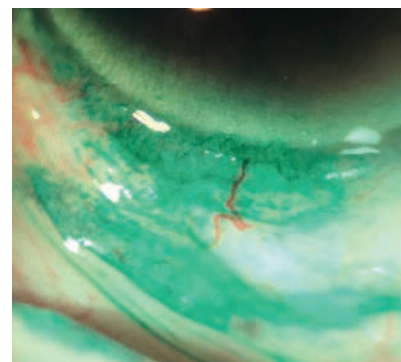
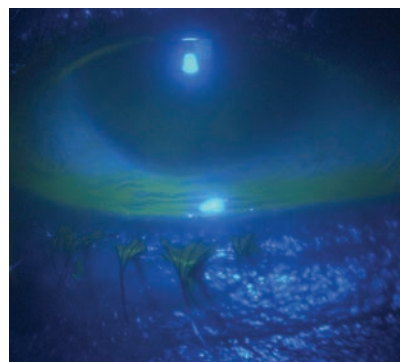
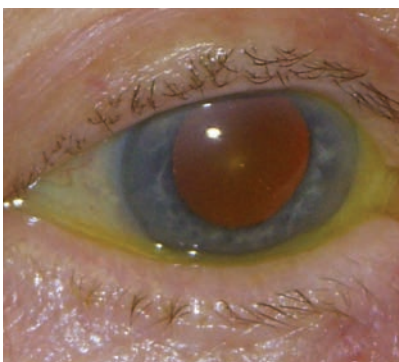
This common—yet commonly missed—chronic clinical condition is characterized by loose, redundant,

non-edematous conjunctival folds, typically in the inferior bulbar conjunctiva of both eyes overlying the inferior eyelid margin. The condition often causes irritation and discomfort, commonly in older patients.

A complex cascade of disruptions lead to CCH, most of which begin with the normal aging process. Patients' subconjunctival connective tissue erodes as they age, predisposing them to reduced attachment of the bulbar conjunctiva to the sclera, and thus conjunctival laxity. The resulting chronic mechanical friction during blinking and eye movements

triggers conjunctival epithelium and vascular endothelium inflammatory responses, which play into the CCH pathogenesis by degrading extracellular matrix via matrix metalloproteinases. This circles back to more conjunctival laxity, beginning a vicious cycle of conjunctival redundancy, friction, inflammation and extracellular matrix degradation.

Further delayed tear clearance can exacerbate this entire pathophysiological process and may be caused by anatomical obstruction of the punctum by redundant conjunctival folds—another cycle characterized by redundant delayed tear clearance leading to ocular surface inflammation and the generation of more matrix metalloproteinases, which degrades the conjunctival matrix and Tenon's capsule,



The conjunctival folds and their obliteration of the tear lake are more easily identifiable conjunctivochalasis with dye. Left: no dye; middle: blue fluorescein dye; right: green dye (latter image: Nicholas Leonard).

ANTIVIRAL INSIGHT INTO POVIDONE-IODINE (BETADINE)

While iodine has been recognized as an effective bactericide since the 1800s, only since the 1980s has Betadine (povidone-iodine, Avrio Health) come into widespread use as standard of care in preventing endophthalmitis following intraocular surgery or intravitreal injection. In fact, there is little to nothing to be gained by using a topical antibiotic above and beyond that of Betadine for sterilizing the ocular surface.

Povidone-iodine has a wide spectrum of antimicrobial activity, including efficacy against a variety of bacteria, fungi, protozoa and viruses, which is why we have long advocated for its use in treating acute infectious adenoviral conjunctivitis. Because povidone is hydrophilic and adheres to cell membranes, it acts as a carrier to transfer iodine to the target cell—a crucial event of antimicrobial action.¹ At the same time free iodine iodinates and oxidizes proteins, enzymes and other molecules essential for biological viability, povidone-iodine inactivates bacterial exo- and endotoxins, tissue-destroying enzymes and microbial-induced cytokines. Betadine is also bactericidal against drug-resistant bacteria.¹

While 5% Betadine is common for pre-op ocular prophylaxis, the surgical staff uses a 10% concentration to scrub in prior to entering the operating room. Even dilute solutions, such as 0.1%, have been shown to have a fast



killing time, possibly due to an increase in free iodine, the availability of which peaks around 0.1% to 1%.^{2,3} Despite this, for the ocular surface, research shows the 5% povidone-iodine more effectively reduces the bacterial load compared with the 1% concentration.³ Investigators have realized that organic substances in the operative field can inhibit Betadine's bactericidal activity; thus, supplying more total iodine with higher concentrations is helpful.⁴

In addition, such apparent discrepancies might be found in comparing *in vitro* and *in vivo* applications. The bottom line is that all common-use concentrations are antimicrobial in 60 to 90 seconds—an incredibly efficient clinical effect.

The toxicity of povidone-iodine is related to its concentration and duration of exposure. We do know that 5% Betadine can cause considerable short-term stinging, even

with the use of topical proparacaine, so one could consider diluting the 5% Betadine at a ratio of 5:1 (to achieve a 1% concentration) to provide good antimicrobial effect while minimizing patient discomfort when treating epidemic keratoconjunctivitis.

Another approach to maximizing efficacy while minimizing toxicity is frequent application of lower-concentration Betadine. Researchers are currently investigating a combination of 0.6% povidone-iodine with 0.1% dexamethasone, which might prove useful (we have never used this strategy). Only time will tell how such a drug might play out in widespread clinical use.

OUR OFF-LABEL BETADINE PROTOCOL FOR EKC:

- Anesthetize the eye with proparacaine
- Instill one or two drops of an NSAID
- Instill several drops of Betadine 5% and then have the patient close their eye
- Swab or rub excess liquid over the eyelid margin
- After one minute, irrigate the eye with sterile saline
- Instill one or two drops of an NSAID
- Rx steroid QID for four days

1. Koener JC, George MJ, Meyer DR, et al. Povidone-iodine concentration and dosing in cataract surgery. *Surv Ophthalmol.* 2018;63(6):862-68.

2. Peden MC, Hammer ME, Suñer JJ. Dilute povidone-iodine prophylaxis maintains safety while improving patient comfort after intravitreal injections. *Retina.* August 23, 2018. [Epub ahead of print].

3. Pepose JS, Ahuja A, Liu W, et al. Randomized, controlled, phase 2 trial of povidone-iodine/dexamethasone ophthalmic suspension for treatment of adenoviral conjunctivitis. *Am J Ophthalmol.* 2018 Oct;194:7-15.

4. Cinal A. Correspondence: Randomized, controlled, phase 2 trial of povidone-iodine/dexamethasone ophthalmic suspension for treatment of adenoviral conjunctivitis. *Am J Ophthalmol.* 2019 Jan;197:184.

causing CCH progression.

Risk factors include increasing age, Asian descent and hyperopia. Severity, judged by the number and height of folds, also increases with age.

As for CCH's clinical presentation, it is often asymptomatic but can also present with symptoms related to tear film instability, delayed tear clearance, ocular surface inflammation and me-

chanical compression of the redundant conjunctiva during eyelid blinking. No wonder DED and epiphora symptoms are often seen in conjunction with CCH. In fact, CCH often coexists with DED, but also causes dry eye symptoms and an unstable tear film. DED, in turn, can induce or exacerbate CCH because of increased ocular surface friction and inflamma-

tion. Some patients may experience subconjunctival hemorrhage, usually in the inferior conjunctiva, due to the increased mechanical friction.

Given this presentation, clinicians should consider CCH in any patient—especially as they age—with ocular surface irritation and symptoms of DED or lacrimal drainage obstruction, particularly if the patient

doesn't respond to appropriate DED treatments such as loteprednol and lipid-based artificial tears. The diagnosis is complicated by the condition's nonspecific symptoms and its preponderance for coexisting with other ocular surface disorders such as DED, MGD, floppy eyelid syndrome and blepharitis. One diagnostic pearl is that down-gaze during reading or computer usage or vigorous blinking may exacerbate CCH symptoms in particular.

Also, don't forget about the possible presence of a recurrent subconjunctival hemorrhage, which may indicate CCH. In addition, patients who present with both DED and epiphora may have CCH. Clinicians can use the slit lamp examination (which will reveal redundant conjunctival folds that move with blinking) and vital dye staining to confirm a CCH diagnosis.

Topical medical management with lipid-based ocular lubricants may be

successful in most all cases, as it can improve tear film function and reduce mechanical friction and suppress ocular surface inflammation. However, we have found that only steroids suppress inflammation.

In addition to ocular lubricants, two drug classes are known to inhibit the extracellular matrix metalloproteinases involved in the CCH cascade: tetracyclines (doxycycline at 50mg per day for three to six months is common) and corticosteroids. Loteprednol is a mainstay because of its enhanced safety profile. For CCH, we typically prescribe loteprednol four times daily for two weeks, then twice daily for another two to four weeks. We have found that topical corticosteroids provide more than an 80% subjective and objective improvement and resolution of delayed tear film clearing.

Should medical therapy not meet therapeutic goals, conjunctival cauter-

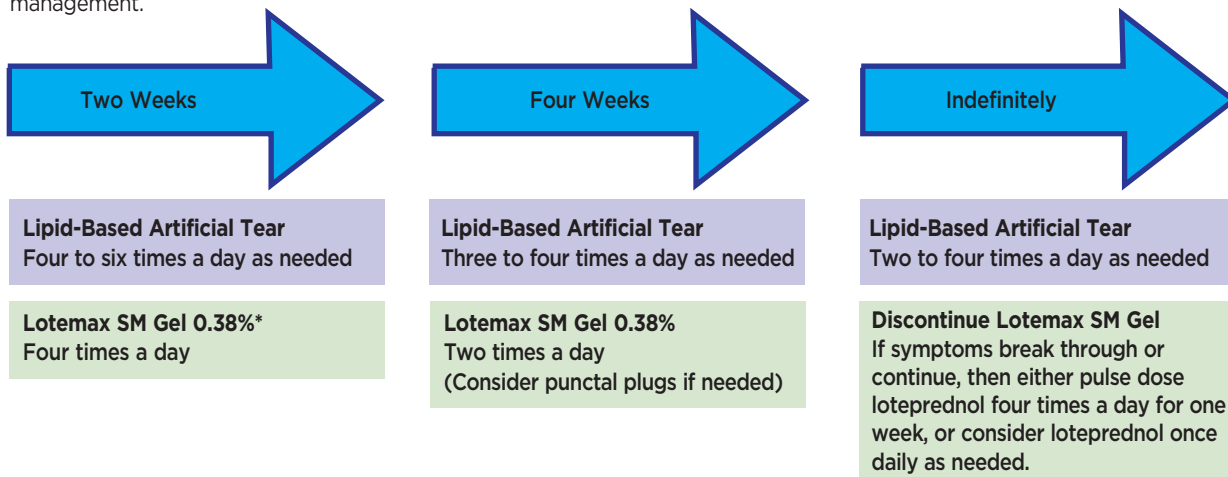
ization can help shrink the redundant bulbar and forniceal conjunctival tissues. If this also fails, surgical resection can be performed.

Although CCH is a common cause of ocular surface irritation, it is often overlooked in clinical practice. Now that you are armed with more information about this condition, we hope it enhances your patient care. ■

1. Miljanovic B, Trivedi KA, Dana MR, et al. Relation between dietary n-3 and n-6 fatty acids and clinically diagnosed dry eye syndrome in women. *Am J Nutr.* 2005;82:887-93.
2. Deinema LA, Vingrys AJ, Wong CY, et al. A randomized, double-masked, placebo-controlled clinical trial of two forms of omega-3 supplements for treating dry eye disease. *Ophthalmology.* 2017 Jan;124(1):43-52.
3. Wladis EJ, Adam AP. Treatment of ocular rosacea. *Surv Ophthalmol.* 2018;63(3):340-46.
4. FDA. Oxervate Prescribing Information. www.accessdata.fda.gov/drugsatfda_docs/label/2018/761094s000lbl.pdf. Accessed March 29, 2019.
5. US Food and Drug Administration. FDA approves first drug for neurotrophic keratitis, a rare eye disease. www.fda.gov/NewsEvents/Newsroom/PressAnnouncements/ucm618047.htm. Accessed March 29, 2019.
6. Marmalidou A, Kheirkhah A, Dana R. Conjunctivochalasis: a systematic review. *Surv Ophthalmol.* 2018;63(4):554-64.

OUR DRY EYE MANAGEMENT ALGORITHM

All therapy—dry eye included—should be individualized to the patient. That said, here is our usual approach to dry eye management.



The risk of increased IOP with loteprednol is uncommon at high dosage and rare at low dosage.
Our experience has been that if an increase in IOP is going to occur, it will do so at the initial one-month follow up, and not later.

Omega-3 essential fatty acids (derived from fish and/or flaxseed oil) can be initiated at any stage

*Alternatively, instill loteprednol ointment daily at bedtime for three weeks, then M-W-F for three weeks. Loteprednol therapy for inflammation due to dry eye disease is considered an "off-label" use.

SEPARATE SCIENCE FROM SALESMANSHIP

The early days of patent medicines were tarnished by now infamous snake oil salesmen who trumped up 'evidence' that their homemade remedies worked wonders. The creation of the FDA took a lot of that chicanery out of medicine, but certainly not all. And it isn't just patients who are vulnerable to aggressive marketing claims—doctors are too.

A recent editorial in *Ophthalmology* uses dry eye as a cautionary tale, imploring doctors to critically evaluate primary research themselves and cast a skeptical eye at claims coming from companies or consultants with a vested interest.¹ The authors question how we can trust popular interpretations of study data—often repeated at the podium or in marketing—where researchers “use statistical tricks and multiple comparisons” to create an impression of efficacy that may not be borne out by the data.

Even when studies demonstrate apparent statistical significance, this doesn't always translate to clinical significance. The authors point out that the concentrations of 0.05% and 0.1% cyclosporin were only minimally superior to placebo and that “there is no clear dose response effect in this outcome variable or any of the primary outcome variables in this study.”

The authors touch on several key points, including the power of the placebo effect and the ability of “one teaspoon of olive oil to treat dry eyes.” Such was the placebo used in the DREAM study. It can be a challenge to truly understand why a patient improves with any given treatment, the authors explain, noting that it could be attributed to one of three reasons: regression to the mean, placebo effect or true treatment effect.

The first possible explanation, regression to the mean, simply means that extreme measurements, when repeated, often return to a more conventional level. Patients selected for dry eye trials because of their higher-than-average symptomatic scores can have lower scores when retested, even

without intervention, simply because the condition itself is highly variable. It's easy to falsely read regression to the mean as efficacy, these authors caution.

Regarding the second explanation, while most of us are aware of the placebo effect, fewer doctors understand the underlying mechanisms. Research in low back pain patients treated with opioids or placebo shows similar brain activity changes in both groups, illustrating that the placebo effect has a true biological basis. In addition, the patient's expectation of improvement directly correlated with the actual amount of improvement with the placebo effect.

The third possibility is of course that the prescribed therapy did as intended and improved the patient's physical circumstances by addressing the cause of the pathophysiology. Too often, the editorial argues, we assume this effect is present because we want to believe it or we have been conditioned by marketing to think that. We should keep this in mind every time we are faced with the decision to incorporate new drugs into our treatment routines.

The editorial goes on to caution against overzealous prescribing of expensive drugs, noting that “eye care providers prescribe more brand-name medicines than any other medical provider.”

Our bottom line: doctors are susceptible to slick marketing efforts that present weak data in a more favorable light than the studies themselves show. To ward off undue influence, which speaks poorly of our professionalism, we must engage in detailed, objective review of the literature, the authors state. This is why we implore our colleagues to subscribe to a variety of professional journals. *Ophthalmology*, *American Journal of Ophthalmology* and *JAMA-Ophthalmology* are all excellent resources that can protect us from aggressive sales tactics under the guise of education.

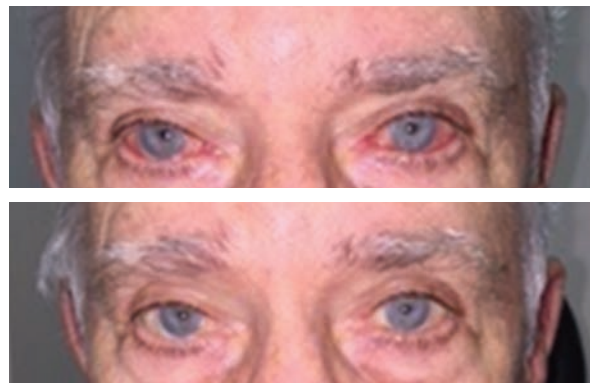
1. Seitzman GD, Lietman TM. Dry Eye Research—Still Regressing? *Ophthalmology*. 2019;126(2):192-94.

AESTHETIC INTERVENTIONS

We tend to focus on keeping patients healthy and free of symptoms of discomfort, but many are affected by the cosmetic appearance of their eye and we shouldn't brush off these concerns as unimportant. Somewhat oddly, two pharmaceutical agents originally used in glaucoma have now been modified and repurposed to help improve the appearance of the eye.

Latisse. Initially billed as an eyelash enhancer or treatment for hypotrichosis, this 0.03% bimatoprost formulation (Allergan) product recently lost patent protection. Clinicians may soon have access to new generic renditions that may be useful if significantly less expensive than the branded version.

Lumify. This brimonidine 0.025% formulation by Bausch + Lomb is an alpha-2 receptor agonist vasoconstrictor indicated for red eye relief. Launched last year to much fanfare, it competes most directly with Visine, a tetrahydrozoline decongestant. Lumify is more sparing



Here, just 20 seconds after instilling Lumify, this patient's eyes appear whiter.

of the ocular surface, as it does not cause the rebound hyperemia associated with tetrahydrozoline.

RAISE THE BAR ON MANAGING OCULAR ALLERGIES

Asking the right questions can prompt patients to disclose clues that they are burdened by this common ocular condition.

Ocular allergies continue to be one of the most common conditions seen in our offices and clinics. Nearly one-third of the American population is affected by allergic disease, with an estimated 40% to 80% of these individuals manifesting ocular involvement.¹ And while allergic eye disease has been shown to strongly impact a patient's quality of life, paradoxically, many patients with allergies fail to report their ocular symptoms.

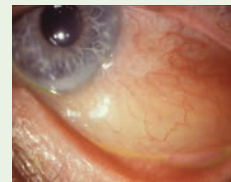Moreover, allergic eye disease is often included as a component of the diagnoses of allergic rhinitis or sinusitis, according to the American Academy of Allergy, Asthma and Immunology. As a result, sinus inflammation is routinely diagnosed, treated and managed, while ocular allergies are not.

So we are left to ask ourselves: How effectively are we diagnosing and treating this disease?

Allergic conjunctivitis begins when the immune system identifies an aeroallergen on the conjunctiva. In response, the immune system overreacts and produces antibodies called immunoglobulin E (IgE) that quickly bind to mast cells. This in turn releases chemical mediators such as histamine that initiate a cascade of local inflammation (e.g., itching, redness, tearing)—a process known as mast cell degranulation. This response to the allergen produces local itching and tearing, resulting in eye rubbing. Unfortunately, in most instances it only accelerates and aggravates the in-

Itchy Eyes Are Often Dry Eyes

Most patients with "itchy eyes" (consistent with allergic conjunctivitis) also have dry eyes and redness. Specifically, the odds of patients with "itchy eyes" who also have dry eyes are 2.11 times that of patients with non-itchy eyes.¹ The odds of these patients also experiencing redness are 7.34 times that of patients with non-itchy eyes.¹



This patient presented with an acute allergic response of itching, conjunctival injection and chemosis.

These results suggest that some symptomatic patients concomitantly have features of allergic conjunctivitis and dry eye syndrome.

1. Hom MM, Nguyen AL, Bielory L. Allergic conjunctivitis and dry eye syndrome. *Ann Allergy Asthma Immunol.* 2012;108(3):163-6.

flammatory process.

Allergic eye disease, an immune-mediated response (IgE antibodies) and type I hypersensitivity reaction, can be subdivided into three phases: sensitization, an early phase and a late phase. While the early-phase reaction can be mildly symptomatic, the late phase can yield keratitis, limbal infiltrates and potentially sight-threatening corneal shield ulcers (e.g., vernal keratoconjunctivitis).

OPTOMETRISTS AND ALLERGISTS: A POWERFUL TEAM APPROACH

In a recent conversation, Phil Lieberman, MD, a clinical professor in the Departments of Internal Medicine and Pediatrics, Divisions of Allergy and Immunology, at the University of Tennessee College of Medicine, discussed the profound burden allergic eye disease can have on a patient's quality of life.

He noted that the two most prevalent allergens are pollen and animal dander, which cycle throughout varying seasons. In the spring, grass and tree pollen aeroallergens are common; in the fall, ragweed is more predominant. Additionally, indoor pets can prompt allergic eye disease.

Dr. Lieberman stated, "The symptoms of allergic eye disease are usually three in number: itching (paramount), redness and tearing. Without itching, the patient probably does not have allergic eye disease."

Allergists suggest that patients suffering from chronic and cyclical symptoms caused by allergic disease be tested to identify the offender(s). Treatment is delivered through medicine, environmental control (avoidance), allergy injections and sublingual drops.

The next time your patient presents with a longstanding history of allergic patterns, consider the role of an allergist to further assist your management.

"Do Your Eyes Itch or Burn?"

• **Itching:** If itching is the patient's primary concern, determine if it's an isolated symptom or if it's associated with parallel signs of inflammation, and then treat accordingly. Remember:

Symptoms only: Use cold, tears, and oral or topical an antihistamine/mast cell stabilizer.

Symptoms and signs: Use the same strategy with the addition of a steroid such as Lotemax, Alex or FML.

• **Burning:** If burning is the main symptom, a full dry eye workup is in order. Be sure to consider dry eye as the foundational condition, and treat accordingly.

Be aware that both of these symptoms can exist concomitantly. Due to the prevalence of dry eye across all ages, recognize and also treat this disease whether or not it is affiliated with allergic eye disease.

For seasonal allergic conjunctivitis, the treatment protocol is straightforward: cold compresses, lubrication, oral and topical antihistamines/mast

cell stabilizers and/or corticosteroids. Perennial allergic conjunctivitis follows a more indolent course, often requiring persistent care by the attending doctor, although treatment options are essentially the same as for the seasonal variety.

Itching is the definitive hallmark of ocular allergy. Always ask your patient: "Is itching or burning your main symptom?" Typically, their response can guide your next step. If the patient remarks that itching is the main symptom, allergic etiology is confirmed. In cases where your patient is unable to decide which symptom distresses them the most, consider treating with a topical ester-based steroid drop (e.g., Alex, loteprednol etabonate 0.2% or Lotemax SM loteprednol etabonate 0.38%), which typically solves both complaints. Anytime a patient is prescribed topical steroids, intraocular pressure should be done at the two- to four-week follow-up visit.

If patients report itching as their predominant symptom, therapy is directed toward one of two paths, discussed below.

SYMPTOMS ONLY

Ocular allergies can be easily overlooked, so begin by carefully evaluat-

An Update on Prevalence

According to published findings from a series of studies conducted by the International Study of Asthma and Allergies in Childhood (ISAAC) starting two decades ago, allergic conjunctivitis has shown a worldwide trend in increasing prevalence.¹ This upsurge has been attributed to climate changes, pollution, increased pollen and a heightened immunological sensitivity in response to environmental changes, among other factors.² About 40% of patients who suffer from allergies reportedly experience some form of ocular symptomology (i.e., itching, chemosis and redness).³

Of equal significance are the documented negative impacts of ocular allergies on patient quality of life, confirming the importance of early therapeutic intervention.

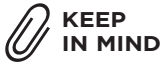1. Worldwide variation in prevalence of symptoms of asthma, allergic rhinoconjunctivitis, and atopic eczema: ISAAC. The International Study of Asthma and Allergies in Childhood (ISAAC) Steering Committee. *Lancet*. 1998 Apr;351(9111):1225-32.

2. D'Amato G, Holgate ST, Pawankar R, et al. Meteorological conditions, climate change, new emerging factors, and asthma and related allergic disorders. A statement of the World Allergy Organization. *World Allergy Organ J*. 2015; 8(1):1-52.

3. Singh K, Axelrod S, Bielory L. The epidemiology of ocular and nasal allergy in the United States, 1988-1994. *World Allergy Organ J*. 2015;8(1):25.

ing the palpebral and bulbar conjunctivas. If the anterior segment shows minimal or unremarkable signs of an allergic conjunctivitis (e.g., conjunctival chemosis, conjunctival injection, lid edema and/or papillae), treating with a combination antihistamine/mast cell stabilizer remains the ideal clinical choice. There are currently seven drugs in this class to choose from:

- *Alcaftadine* (Lastacaft, Allergan)
- *Azelastine* (Optivar, Meda Pharmaceuticals; generic available)
- *Bepotastine* (Bepreve, Bausch + Lomb)



TYPES OF ALLERGIC CONJUNCTIVITIS

1. Acute Allergic Conjunctivitis: Subcategories are seasonal allergic conjunctivitis (allergens include: ragweed, pollen, grass, etc.) and perennial allergic conjunctivitis (allergens include: dander, foods, molds, etc.).

2. Giant Papillary Conjunctivitis (GPC): More mechanical in nature than a true allergic response.

3. Vernal Keratoconjunctivitis (VKC): Involves type I and IV hypersensitivity reactions; presents with severe itching; symptoms are exacerbated in the spring.

4. Atopic Keratoconjunctivitis (AKC): Uncommon; associated with asthma, hay fever and eczema.

- *Epinastine* (Elestat, Allergan; generic available)
- *Ketotifen* (Zaditor, Alcon; Alaway, Bausch + Lomb; many generics available. This drop is OTC.)
- *Olopatadine* (Pazeo/Pataday/Patanol, Novartis) and generic 0.1% olopatadine
- *Cetirizine* (Zerviate, Eyevance Pharmaceuticals)

Of these, most are rated the historical pregnancy category C, except Lastacaft (category B) and Zerviate, in which “no adequate or well-controlled studies” were conducted in pregnant women, per the drug’s prescribing information. Notwithstanding fine differences, all of the antihistamine subtype 1 receptor blockers nicely suppress ocular itching. In

addition, all are dosed initially BID, with the exception of Pazeo, Pataday and Lastacaft, which are dosed QD.

After two weeks of BID therapy, consider reducing instillation to QD or as needed dosing for maintenance dosing. As with any treatment, the lowest effective dose is always desired. In our experience, once inflammation is firmly brought under control, less pharmaceutical intervention is needed to maintain control. Then again, some patients still require a second additional drop later in the afternoon.

When symptoms cannot be managed by the OTC medications listed above, a 5ml bottle of Alrex and Bepreve should only require \$10 copays for the first Rx and refills (for most eligible commercially insured patients) through the Bausch + Lomb Access program at Walgreens and other participating independent pharmacies during allergy season (between March 1, 2019 and Oct. 31, 2019). Also consider consulting

OCULAR ALLERGY MEDICINES

BRAND NAME	GENERIC NAME	MANUFACTURER	PEDIATRIC USE	BOTTLE SIZE(S)	DOSING
Acute Care Products					
Acular LS	ketorolac tromethamine 0.4%	Allergan and generic	3 yrs	5ml, 10ml	QID
Alaway (OTC)	ketotifen fumarate 0.035%	Bausch + Lomb	3 yrs	10ml	BID
Alrex	loteprednol etabonate 0.2%	Bausch + Lomb	12 yrs	5ml, 10ml	QID
Bepreve	bepotastine besilate 1.5%	Bausch + Lomb	2 yrs	5ml, 10ml	BID
Elestat	epinastine HCl 0.05%	Allergan and generic	3 yrs	5ml	BID
Emadine	emedastine difumarate 0.05%	Novartis and generic	3 yrs	5ml	QID
Lastacaft	alcaftadine 0.25%	Allergan and generic	2 yrs	3ml	QD
Optivar	azelastine hydrochloride 0.05%	Meda and generic	3 yrs	6ml	BID
Pataday	olopatadine hydrochloride 0.2%	Novartis	3 yrs	2.5ml	QD
Patanol	olopatadine hydrochloride 0.1%	Novartis and generic	3 yrs	5ml	BID
Pazeo	olopatadine hydrochloride 0.7%	Novartis	2 yrs	2.5ml	QD
Zaditor (OTC)	ketotifen fumarate 0.035%	Novartis and generic	3 yrs	5ml	BID
Zerviate	cetirizine 0.24%	Eyevance Pharmaceuticals	2 yrs	5ml, 10ml	BID
Chronic Care Products					
Alocril	nedocromil sodium 2%	Allergan and generic	3 yrs	5ml	BID
Alomide	lodoxamide tromethamine 0.1%	Alcon	2 yrs	10ml	QID
Crolom	cromolyn sodium 4%	Bausch + Lomb and generic	4 yrs	10ml	QID

TOPICAL ANTIHISTAMINE DOSING: TWO ARE BETTER THAN ONE

Prescribing pure mast cell stabilizing drugs is no longer considered to be a best practice for treating ocular allergies, according to Mark Abelson, MD, a world-renowned ocular allergist at Harvard Medical School. Dr. Abelson told us that pure mast cell stabilizing drugs have little clinical use, as their lag period and mandatory chronic dosing severely limits their applicability. Rather, topical combination antihistamine/mast cell stabilizers offer patients nearly instantaneous relief due to the rapid onset of action. Also compelling is their affordability; the cost of an OTC topical combination antihistamine/mast cell stabilizer is similar to a pure mast cell stabilizer.

For patients who have symptomatic disease, one drop in the morning may suffice for lasting improvement

throughout the day. However, a subset of patients may need a second drop later in the afternoon. Which is correct? In the end, either is appropriate, as patient care is not a one-size-fits-all, but rather a tailored approach to find symptomatic relief. (Remind your patients that transient burning and stinging upon instillation is common.)

Patients with severe allergy expression will need slightly more involved therapy. In addition to an antihistamine/mast cell stabilizer BID, we turn to an ester-based corticosteroid such as Alrex (loteprednol 0.2%, Bausch + Lomb) or off-label use of Lotemax SM (loteprednol 0.38%, Bausch + Lomb) QID initially along with cold compresses.

Once the inflammation has settled down, the steroid may be discontinued, and the patient can remain on the antihistamine/mast cell stabilizer once or twice daily as needed.

www.goodrx.com to find the best pricing in your area.

SYMPTOMS AND SIGNS

Whenever possible, therapy for ocular allergies should be prophylactic. For patients who encounter the same allergic complications yearly, therapy should be initiated prior to symptomatic inflammation, be sufficient enough to suppress the patient's signs and symptoms, and be continued for a long enough period to prevent conversion into a chronic disease. The basis of treating any allergic eye disease remains the same: quell the inflammation early to help avoid potential late complications.

In patients who present with symptoms of allergy as well as classical anterior segment findings, a topical ester-based corticosteroid is our preferred therapeutic option. Don't hesitate to employ Alrex (loteprednol 0.2%, Bausch + Lomb) or off-label Lotemax SM (loteprednol 0.38%, Bausch + Lomb). Topical prednisolone acetate (Pred Forte and Mild, Allergan) and prednisolone sodium phosphate (Inflamase Forte and Mild, Novartis) are additional options.

Also, the ketone-based steroid FML ophthalmic suspension (fluorometholone 0.1%, Allergan and generic) is a viable option, though we have found it has a higher propensity to increase IOP compared with its ester-based

counterparts. (Also note: FML, though generic, is often more expensive than the varying concentrations of loteprednol once a Bausch + Lomb coupon has been applied.)

The frequency of instillation of steroidal preparations should be tailored to the severity of the patient's signs and symptoms. Typically, we prescribe a steroid drop Q2H for two days, then QID for one week, followed by BID for one more week to manage most cases. Once the signs of allergic eye disease are subdued, consider switching your patient to an antihistamine/mast cell stabilizer for ongoing symptomatic regulation.

AN EQUAL-OPPORTUNITY DISEASE

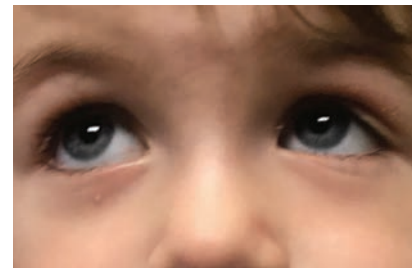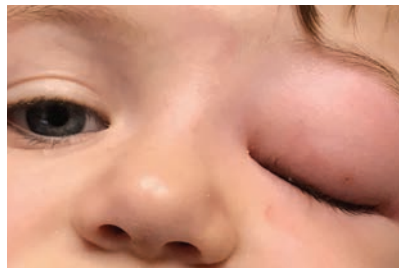While originally considered to be a "disease of affluence," allergic conjunctivitis is now clearly recognized in many corners of the world, with

increasing prevalence in countries experiencing sustained growth and developing urban populations.² Doctors should keep in mind that ocular allergies, while not life-threatening, yield persistent, uncomfortable symptoms that negatively impact the patient's productivity and quality of life.

Also remember that allergy is an expression of inflammation. In addition to the therapeutic strategies listed above, don't forget to discuss palliative options with patients such as daily cold compresses to the inflamed eye. Suggesting that your patients place their allergy drops in the refrigerator until it's time to instill the drops can provide added relief. ■

1. Kari O, Saari KM. Diagnostics and new developments in the treatment of ocular allergies. *Curr Allergy Asthma Rep.* 2012;12(3):232-9.

2. Gomes PJ. Trends in prevalence and treatment of ocular allergy. *Curr Opin Allergy Clin Immunol.* 2014;14(5):451-6.



This child's mosquito bite was mistaken as preseptal cellulitis by Urgent Care. We treated him with Benadryl, steroid drops and cold compresses. The right image is four days later.

ARM YOURSELF FOR A SHINGLES ONSLAUGHT

Until the adult population is fully vaccinated against varicella zoster, more patients will need our help with this condition. With prompt attention, you can hasten recovery from this often painful and distressing experience.

One day, shingles—a latent secondary expression of the varicella zoster virus—will be exceedingly rare. The advent of the chickenpox vaccine (Varivax, Merck) is creating generations of patients who will never have shingles because they will never contract chicken pox.

However, until all children are fully immunized with the chickenpox vaccine—which will take another 20 to 30 years, at least—there will be a significant uptick of adult shingles. This is because, before the vaccine's release, the spread of childhood chickenpox within the community passively fostered adult immunity through contact with the virus during the course of daily living. Without these sporadic immunity-bolstering experiences, unvaccinated adults are more vulnerable to shingles later in life. As our population ages, eye doctors need to be prepared to meet the needs of this coming wave of shingles.

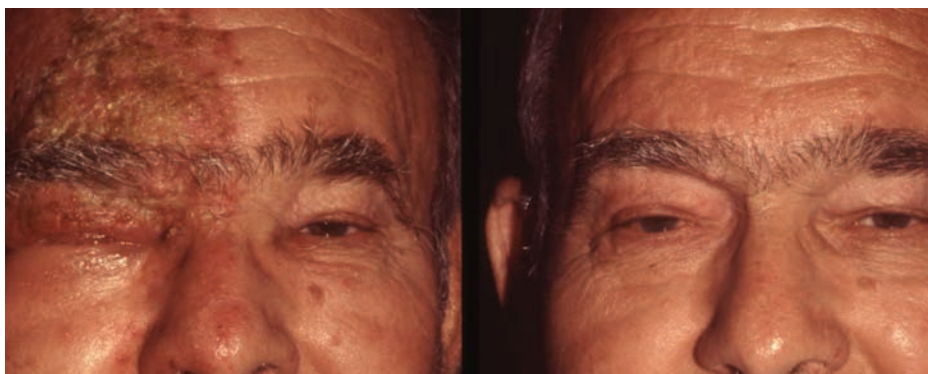A SKIN AND EYE DISEASE

The diagnosis is usually straightforward. A minority of patients will develop skin pain days or weeks before developing the vesicular eruptions associated with shingles. Zoster disease is most commonly expressed in the trunk of the body; the second most common site is the first (ophthalmic) division of the trigeminal nerve distribution, which involves the forehead and upper eyelid. The globe becomes involved in about half of these first trigeminal nerve expressions, and the disease affects both the skin and the globe.

When shingles presents as an uncomplicated skin disease, as evidenced by pain, erythema and vesicular expression, the treatment is an oral antiviral for seven to 10 days with one of three options:

- Acyclovir 800mg five times daily
- Valacyclovir 1000mg TID
- Famciclovir 500mg TID

These drugs nicely subdue a varicella outbreak in most patients, particularly



HZO patient before (left) and after treatment.

SHINGLES VACCINE UPDATE

Having shingles is far more effective in preventing further outbreaks than the vaccines. Zostavax (live zoster vaccine, Merck)—which only reduces the disease burden by about 50%—has now been relegated to history with the advent of the newer and much more effective Shingrix. The Zostavax vaccine is highly recommended for those older than age 60. The downside of the vaccine is that it only provides relative immunity for about eight years, so repeat vaccination may be necessary.

Shingrix (recombinant zoster vaccine, GlaxoSmithKline) was FDA approved in 2017 for immunocompetent patients ages 50 and older. Studies demonstrate it is 97% effective for patients between the ages of 50 and 69 and remains effective, at 91%, in those aged 70 or older. In addition, researchers note Shingrix is more cost-effective than Zostavax.

Although patients often ask if they should get the vaccine if they have already had a bout of shingles, we have no definitive answer. Some advocate that patients should receive the vaccination, whether or not they have already had shingles, simply because the condition could recur. However, having shingles powerfully boosts the immune system, which is why shingles is often a one-and-done event. We believe a patient older than age 50 who develops shingles likely would not benefit from the vaccine any more than natural history. Further, cataract surgery can increase the risk of a repeat bout of shingles, so a patient should generally wait a year or so after having shingles to get cataract surgery.

Jeng BH. Herpes zoster eye disease: new ways to combat an old foe? *Ophthalmology*. 2018; 125(11):1671-74.

patients who present within the first 72 hours of the outbreak. Antiviral medicines work best during the early replicative phase of the infection. This does not mean that after three days, the opportunity for medical intervention has passed—just that there is decreasing clinical efficacy with each day of delayed care. With more virulent expressions, especially in older patients, concurrent therapy with oral prednisone (usually 40mg to 60mg/day for a week) can help decrease the pain and inflammation, and it may dampen the expression of post-herpetic neuralgia.

Globe. When the globe is involved

concurrently with the skin, it is commonly an inflammatory keratitis, uveitis or both. Uveitic involvement will manifest as inflammatory cells in the anterior chamber; corneal involvement will manifest as stromal inflammation. Occasionally, even the trabecular tissues become inflamed, resulting in increased intraocular pressure. Conjunctival injection, of varying degree, accompanies these inflammatory expressions. Such ocular involvement requires proper (usually aggressive)

QUOTABLE

For our shingles patients, we occasionally have a brief chat with the patient's primary care physician first to be sure there are no contraindications to any of these medications. Always remember, excellent patient care often requires a team approach. Never hesitate to make a call, but take care of the patient yourself.

Herpes Zoster Regimen Options:

Acyclovir 800mg 5x/day for seven to 10 days

Valacyclovir 1000mg TID for seven to 10 days

Famciclovir 500mg TID for seven to 10 days

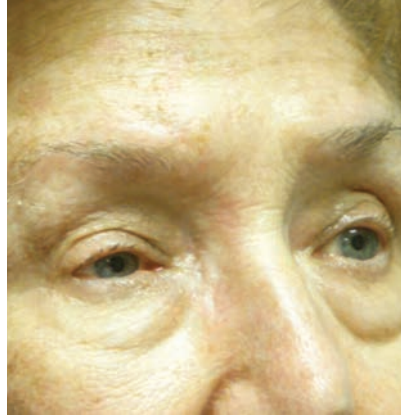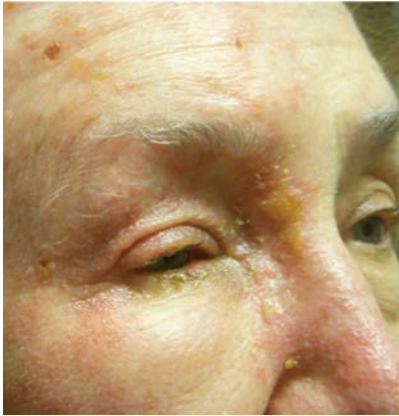treatment with cycloplegia and topical steroids. We prescribe homatropine 5% for use BID to QID, along with Durezol (difluprednate ophthalmic emulsion, Novartis), prednisolone acetate or loteprednol until the inflammation is well controlled. Only then begin a taper. If the patient is older or has a severe presentation, we commonly prescribe 40mg to 60mg of oral prednisone for five to seven days (without taper) in addition to the steroid drop and antiviral to help control the concurrent inflammation and pain.

All of the oral antivirals are FDA Category B, and clinicians must reduce the dosage for patients with renal disease. If your patient has impaired kidney function, call their nephrologist or internist to learn the creatinine clearance rate or glomerular filtration rate. This will help you, a pharmacist or an app calculate the proper dosage. While we have never encountered this unusual circumstance, we are well prepared if we do.

For our shingles patients, we occasionally have a brief chat with the patient's primary care physician first to be sure there are no contraindications to any of these medications. Always remember, excellent patient care often requires a team approach. Never hesitate to make a call, but take care of the patient yourself.

CLINICAL CHALLENGE

Diagnosis can be tricky for a patient, often older and Caucasian, who presents with new-onset headache and skin



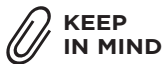This patient presented with second-division shingles. In addition to standard oral antiviral treatment, such patients may well benefit from oral prednisone to help control inflammation and pain.

pain, but no vesicles on the face over the distribution of the ophthalmic division of the trigeminal nerve. It could be giant cell arteritis (GCA) or early-onset shingles. For this patient, we would order an erythrocyte sedimentation

rate, C-reactive protein and a complete blood count to look for elevated platelets (thrombocytosis). These three markers tend to be significantly elevated in the setting of GCA. Then we prescribe an oral antiviral to be filled

only if the patient develops dermatologic vesicles over the next few days. Lab results are often available in a day or two. If the lab results are positive for GCA, we prescribe 80mg to 100mg of oral prednisolone that day and schedule the patient to undergo a temporal artery biopsy in the next few days with an oculoplastic subspecialist, general surgeon or otolaryngologist. Be sure to keep the patient's primary care physician up-to-date on the diagnosis and management using a succinct letter—never just send a copy of the voluminous electronic medical record.

As shingles can be devastatingly painful, it is satisfying to provide effective acute care to those who are suffering. The diagnosis is almost always clearly evident, and the medical intervention is straightforward in most cases. We should be experts in treating this disease, as we are likely to see more cases in the coming years. ■

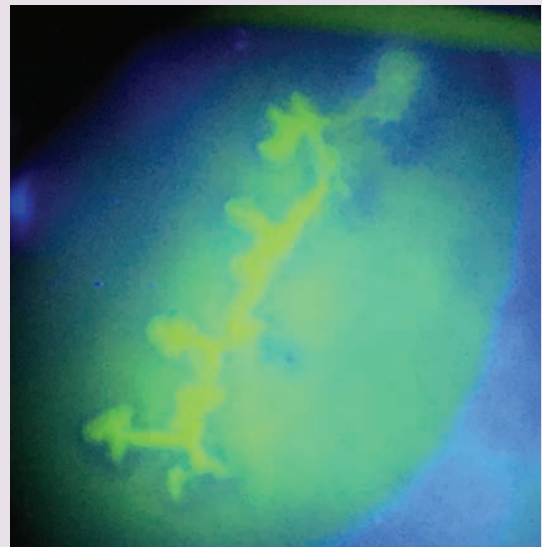


**KEEP
IN MIND**

ORAL ANTIVIRAL PRESCRIBING PEARLS

While these drugs are the workhorses in treating herpes simplex viral keratitis and shingles, clinicians should keep these clinically relevant finer points in mind when prescribing antivirals:

- For patients who are lactose intolerant, we prescribe valacyclovir. We all need to think about asking about lactose intolerance prior to prescribing.
- For patients older than age 65, famciclovir is preferred because research shows both acyclovir and valacyclovir have an increased risk of central nervous system reactions such as agitation, hallucinations, confusion and encephalopathy.¹ In addition, they pose an increased risk of renal failure for older patients compared with those younger than 65.¹
- Since the herpes simplex virus is easier to kill than the herpes zoster (varicella) virus, the dosage for simplex is generally half of that used to treat shingles: acyclovir, 400mg; valacyclovir, 500mg; and famciclovir 250mg—all for the same duration.
- Acyclovir has a liquid formulation ideal for children and patients with dysphagia (difficulty swallowing); this is dosed at 200mg/5mL (5mL is one teaspoon).
- Don't forget that oral antivirals are the drugs of choice to treat epithelial herpes simplex keratitis, not the toxic (and more expensive) topical drugs.
- The main side effect of the antivirals is occasional nausea, so patients should take them with meals.



This presentation of HSK was mistaken as an abrasion at the ER. The patient simply needed treatment with an oral antiviral only.

1. White ML, Chodosh J. Herpes simplex virus keratitis: a treatment guideline - 2014. American Academy of Ophthalmology. www.aao.org/clinical-statement/herpes-simplex-virus-keratitis-treatment-guideline. June 2014. Accessed April 4, 2019.

PRESERVING VISION ACROSS THE LIFECYCLE

New research on everything from myopia to AMD is helping us protect our patient's vision—from birth to 101.

Young or old, all of our patients may need us to step in to help preserve their vision quality at some point in their lives. Two conditions that affect opposite ends of the lifecycle spectrum have been under the microscope of late, and new data is giving us different strategies to better help these patients. Let's take a look at the latest literature on myopia control and nutrition for retinal health.

LOW-DOSE ATROPINE FOR MYOPIA CONTROL

Over the decades, researchers and clinicians alike have tested myriad approaches to slowing the progression of myopia, yet none are optimal. While patients need to embrace simple lifestyle adjustments such as increasing time spent outside and reducing screen time, clinical intervention is a

must for many patients. But what that intervention looks like is still up for debate. Based on our experience and that of our colleagues, it appears that low-dose atropine may be the best pharmacological therapy. However, researchers continue to debate the best therapeutic regimen for optimal myopia control with atropine.

A June 2018 article published in *Eye* provides robust coverage of the various therapeutic options, and it is worth taking a close look at its conclusions:¹

- “Myopia is the most common eye disorder worldwide, but it is often misregarded as merely a refractive error that simply can be corrected by spectacles, contact lenses, or refractive surgery.”

- “...delaying myopia onset and retarding myopia progression in school-aged children is potentially the key to reduce high myopia later in life.”

QUOTABLE

“It is now thought that because of the rapid increase in the prevalence of myopia in under one generation, environmental factors perhaps played a greater role in its development than our genes. Environmental risk factors include urbanization, higher educational attainment, higher IQ, but more important has been two consistent risk factors: increased near-work activity and reduced outdoor activity.”

Dirani M, Crowston JG, Wong TY, et al. “From reading books to increased smart device screen time.” *Br J Ophthalmol.* 2019;103(1):1-2.

- “To date, atropine is the only medication that has been demonstrated to be consistently effective in slowing myopic progression. Once myopia has developed in a child, the rate of progression is estimated to be around -1D per year in East Asians and around -0.5D per year in Caucasians. [...] Therefore, intervention to prevent myopia progression early on in myopic children is urgent and important.”

- “Starting treatment with the lowest concentration, such as 0.01% atropine, would be preferable as this is associated with the least side effects. The dosing frequency is once daily at bedtime [...] During the period of atropine treatment, the appropriate distance glasses should be prescribed if the child has difficulty in far vision...”

- “For optimal results, the motivation of parent[s] and children is important, and long-term compliance and adherence with atropine treatment cannot be over-emphasized.”

The author notes that rigorous studies comparing different concentrations of atropine have found the 0.01% is most effective with minimal rebound upon treatment completion. While photophobia is the most frequent side effect in higher concentrations (i.e., 1% and 0.5%), participants using 0.1% and 0.01% rarely complained of photophobia. This rarity also held true for the development of atropine allergy in these lower concentrations. In the 0.01% group, only 2% of patients stopped treatment due to side effects.¹

The researchers also recommend patients remove their myopia-correction eyeglasses during near tasks or wear multifocal glasses, along with generous outdoor activities. During those outdoor activities, they can wear a hat, photochromic glasses or sunglasses to alleviate symptoms of photophobia.¹

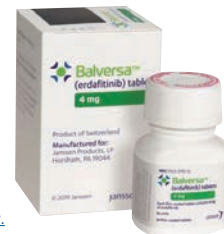Although the optimal length of treatment is unknown, some recommend halting treatment for one year to assess the rate of progression after the initial two years of treatment. Those who progress after stopping treatment can restart the therapy.¹

THE CONNECTION BETWEEN OPTOMETRY AND UROLOGY

Eye doctors and urologists generally have little in common, and you can judge whether that’s a good thing. However, a new drug has just been approved for the treatment of adult patients with locally advanced or metastatic urothelial carcinoma.

Balversa (erdafitinib) tablets carry serious ocular side effects including inflamed eyes, inflamed cornea and disorders of the retina such as central serous retinopathy/retinal pigmented epithelial detachment.¹ It is recommended that these patients have monthly eye examinations during the first four months of treatment, every three months afterwards and at any time for visual symptoms. Beyond a vision assessment and dilated fundus examination, always perform optical coherence tomography imaging at each visit.

Here is an opportunity for optometrists to establish a relationship with area urologists and perhaps oncologists to let them know you are available to consult with them on Balversa. This is similar to our relationship with rheumatologists regarding Plaquenil (hydroxychloroquine) screenings.



1. FDA approves first targeted therapy for metastatic bladder cancer. www.fda.gov/NewsEvents/Newsroom/PressAnnouncements/ucm635906.htm. April 12, 2019. Accessed April 16, 2019.

Another, more recent study evaluated three concentrations of atropine—0.05%, 0.025% and 0.01%—and provides more details on the benefits of these differing atropine treatment regimens:²

- “After 1 year, there was a reduction of 67%, 43%, and 27% in the mean SE [spherical equivalent] progression and 51%, 29%, and 12% in AL [axial length] elongation in the 0.05%, 0.025%, and 0.01% atropine groups, respectively, when compared with the placebo group. Of note, the difference in axial elongation between the 0.01% atropine and placebo groups was not significant. All 3 concentrations of atropine were well tolerated by the children in pupil dilation, accommodation loss, near vision, and best-corrected distant vision. There was no reported treatment-related adverse event.”

- “Although we confirmed that atropine 0.05% is better than 0.025% over a 1-year period, it is important to compare their efficacies after 2 years to determine the long-term optimal concentration. [...] There is also the question of whether atropine could be discontinued once the myopia progression was under control.”

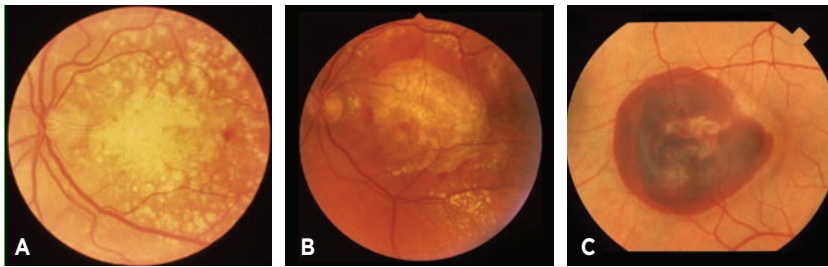
- “The anti-myopia mechanisms of atropine are not fully understood.”

These two groups of researchers come to slightly different conclusions, perfectly reflecting the embryonic state of pharmacological dampening of myopia progression. We think the key to widespread use of this yet-to-be-perfected approach is to partner with a clinician well-versed in using this therapeutic approach.

While these study results are promising, getting parents and children onboard—and keeping them onboard for several years—may be the limiting factor in the ultimate success of low-dose atropine. We urge you to identify and communicate with pediatric experts before embarking on this pharmacological approach to myopia control.

NUTRITION AND THE RETINA: STAVING OFF AMD

The ravages of age are inevitable for many of our senior patients, especially those who have not taken reasonable care of themselves. One of the more prevalent ravages is age-related macular degeneration (AMD). A recent population-based study, published in the February 2019 issue of *American Journal of Ophthalmology*, highlights



(A) Large confluent soft drusen represent advanced dry degenerative changes. Hopefully this and the subsequent events could be prevented, delayed or minimized with appropriate vitamin-mineral supplementation. **(B)** Large disciform scar after resorption of blood resulting from hemorrhagic (wet) AMD. **(C)** A fresh sub-RPE and sub-sensory retinal hemorrhage.

many nutritional changes patients can take to help ward off retinal changes.³ For one, research shows lutein, zeaxanthin, zinc, vitamins C and E, and the polyunsaturated omega-3 fatty acids, can all reduce the risk of developing AMD. Trials that evaluate high-dose supplementation of these nutrients, as well as reports on dietary intake provide significant evidence of their beneficial effects. Patients who adhere to a diet that combines many of these beneficial nutrients may be more protected against AMD than patients who do not. “A possible explanation is that the bioavailability and nutritional value of a nutrient depends on the concomitant uptake of other nutrients,” according to the study authors.³

Countries that have established dietary guidelines generally recommend one to two portions of fish per week, 200g to 250g of vegetables each day and 200g of fruit daily. The study found this diet provided a 42% reduction in the risk of AMD. Just eating particularly fatty fish twice a week reduced the risk by 24%.³

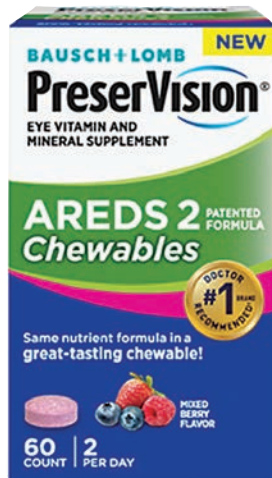
When it comes to nutrition and AMD, the carotenoids lutein and zeaxanthin are often the first to come to mind for clinicians, mostly because they

are important components of macular pigment and help to maintain the retina’s integrity. Lutein and zeaxanthin concentrate in the macula and can filter blue light, halt reactive oxygen species, and reduce light-induced oxidative damage and inflammation. They can also protect neural membranes. Despite this, the study found no significant association with incident AMD for the food categories of vegetables and fruit.

The researchers concluded that no clear evidence existed that the dietary intake of lutein and zeaxanthin lowered the risk of AMD. Dietary intake of beta-carotene, however, showed a reduced risk of AMD, especially for those with high genetic risk.

At the end of the day, the study confirmed what other researchers have already reported: a diet that combines various food groups influences the bioavailability and nutritional value of each individual nutrient. Combining foods led to better performance than each food group individually.

Clinicians can be confident that the literature supports a recommended diet that consists of a large variety of vegetables, fruit and fish will benefit patients at risk for AMD. The study author concluded that clinicians should counsel all patients at risk of AMD



about the benefits of a healthy overall lifestyle that includes a healthy diet, regular exercise and no smoking.

The problem with this recommendation, however well-intentioned, is that humans, by and large, make lousy patients. We are often undisciplined and tend to make poor decisions. To help our patients maintain central vision, despite themselves, we commonly recommend oral supplementation of vitamins and minerals with either the traditional AREDS2 product or the new chewable form. ■

1. Wu P-C, Chuang M-N, Choi J, et al. Update in myopia and treatment strategy of atropine use in myopia control. *Eye*. 2019;33:3-13.
2. Yam JC, Jiang Y, Tang SM, et al. Low-concentration atropine for myopia progression (LAMP) study. *Ophthalmology*. 2019;126(1):113-24.
3. de Koning-Backus APM, Buitendijk GHS, Kieft-de Jong JC, et al. Intake of vegetables, fruit, and fish is beneficial for age-related macular degeneration. *Am J Ophthalmol*. 2019;198(2):70-79.



FISH OIL & EPA-DHA

Fish oils come in different qualities and their essential fatty acid constituents of eicosapentaenoic acid (EPA) and (docosahexaenoic acid) DHA can vary. As a general guideline, the milligram contents of these compounds must add up to roughly 850mg to have a meaningful effect. These two compounds are concentrated in the outer layers of the photoreceptors and are thought to absorb harmful wavelengths of blue light. Because lutein and zeaxanthin are supplements, you would need to know the dietary and nutritional intake of each patient to properly quantify the precise amount of supplementation necessary. This reality is often lost in the conversation regarding appropriate supplemental recommendations.

Pizzimenti J, Capogna L. Choroid Chronicles. Talk presented at the Optometric Retina Society EyeSki Conference. Park City, UT. Feb 23, 2015.

A NEW WORLD OF OPTOMETRY

Optometrists must accept the reality of encroaching threats from online refractive services and technology advancements and find ways to expand—and diversify—their eye care practices.

Progression of technology can cut like a two-edged sword. We have all seen the rapid evolution of autorefractors; they have achieved remarkably excellent accuracy. Now this diagnostic technology is available online in a rudimentary form and will likely only become more sophisticated. It's conceivable that the day will soon be upon us when refraction can be achieved via the camera function on a phone or tablet, or even in a mall kiosk!

Though we would all agree that refraction is best handled by a well-trained eye doctor, many patients are satisfied with a good-enough refraction online. Many “consumer advocates” are sure to enthusiastically embrace these cheap and workable online technologies, while pub-

lic health-oriented stakeholders should find such approaches deplorable.

Ironically, while some retail-based optometrists are refraction-centric practitioners, they tend to not be AOA members. Why is this ironic? Because the AOA is our profession's frontline advocate, and we all need to become members. This is especially true of younger optometrists who perform refraction as the centerpiece of their practices.

In addition to the threat from online refractive technology, numerous online retail sites are offering eyeglasses, and 3-D printers can now print eyeglasses from a “phantom model.”

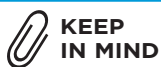A study published in the May 16, 2018, issue of *Clinical and Experimental Optometry* noted the ability of 3-D printing technology to fabricate and

THE ‘MODEL’ MISNOMER

The term “medical model” is ill-conceived and poorly reflects the modus operandi of comprehensive optometric care. Perhaps this term is intended to indicate an interest in expanding one's practice to begin to more aggressively manage medically oriented patient presentations. However, in our eyes, this simply reflects the need to become more comprehensive and refer less—not a monumental shift, and certainly not one meriting a special moniker.

A more accurate name might be “comprehensive optometry,” signifying that the comprehensive optometrist provides all of the care needed for the vast majority of patients who present. This, of course, would include medical eye care in addition to contact lens care, low vision, orthodox orthoptics, refractive correction services and more.

Medical eye care for most ODs, especially those in rural areas, is and probably always has been a significant part of daily practice. Comprehensive care includes all aspects of medical eye care, but to attempt to isolate a mode of practice as a medical model actually misrepresents what progressive, contemporary optometrists do every day. Enough said.



WHEN THE PHARMACY OR PATIENT REJECTS YOUR Rx

Too often, we get calls from pharmacies to inform us that Drug Y prescribed for a patient is not on the insurance formulary, and they recommend Drug Z be substituted. At other times, the medicine that would best serve the patient's needs is quite expensive, so the patient rejects the prescription at the pharmacy due to the cost, which prompts yet another call back to the prescribing doctor. We, and no doubt you, are sick of this absurd interference in the care of our patients.

Here is an example of the maddening scenario we all encounter with growing frequency: We saw a young woman with chronic, recurrent, bilateral anterior uveitis whose condition was concurrently managed by her rheumatologist, who had placed her on increasingly high doses of methotrexate because we were unable to subdue the uveitis with topical steroids. We prescribed Durezol, the best drug for her, only to get pushback from the pharmacy informing us that Durezol wasn't on her formulary. They recommended generic prednisolone acetate.

We had no choice but to acquiesce, even though in our clinical experience, the substitute drug would likely require a longer time to gain control of the condition. After weeks of chronic recurrence, we finally provided her with samples of Durezol and, as we expected, this quickly suppressed her uveitis. Once controlled, we had to switch her back to the generic prednisolone acetate because we had no more samples available for her.

Since we don't seem to have leverage to remove all this "red tape," here are some "Plan Bs" that we use to maneuver through and around some of this bureaucracy to provide optimum care for our patients:

Problem: When a brand-name prostaglandin is prescribed and denied and generic latanoprost is recommended: For most patients, this would be fine, but we have anecdotally found some generic varieties of latanoprost to perform less well than others.

Plan B: Keep and offer coupons for brand-name, preferred drugs. These can be helpful to some patients.

Problem: You prescribe Combigan only to be told it is not on the patient's formulary, or the patient is paying cash for the medicine and the cost is prohibitive.

Plan B: In either case, a viable option is to prescribe the two generic ingredient drugs. In this instance, we would prescribe timolol 0.25% or 0.5% QAM, and brimonidine 0.2% QAM. Clearly instruct the patient to wait 10 minutes between the use of these two drops. We prescribe a second drop of brimonidine 0.2% to be used around 4pm to 5pm. (Brimonidine only works for about eight hours, thus the need for the second, late-afternoon drop.) Optimally, timolol is used only once daily in the morning.

Problem: You prescribe Simbrinza ophthalmic suspension and are told it is not on the patient's formulary, or that the patient can't afford the cost.

Plan B: Default to brimonidine 0.2% and dorzolamide

2% to be used first thing in the morning (be sure to instruct the patient to always wait a few minutes between instillation of the two drops) and then second instillations around 4pm to 5pm. Of note, while brinzolamide is in Simbrinza, when prescribing an individual carbonic anhydrase inhibitor, we default to the generic dorzolamide because it is less expensive and is a solution, thus it requires no shaking before instillation.

Problem: You prescribe Lotemax SM drops off label for a patient with dry eye disease, only to be told that it is either too expensive or not on the formulary.

Plan B: Try coupons, or default to generic fluorometholone 0.1%. While this medicine is relatively safe, it is not as safe as loteprednol. Be sure to advise the patient that the fluorometholone must be shaken before each instillation.

Problem: You prescribe Zylet or generic TobraDex for staphylococcal blepharitis, only to be told that it is too expensive or not on the patient's formulary.

Plan B: Offer coupons if they are available, or default to generic Maxitrol if it will be used for less than two weeks. Be aware that there is a slight potential for neomycin allergic reaction or increased intraocular pressure from the dexamethasone, which may occasionally be bothersome. Zylet, generic TobraDex and generic Maxitrol are all suspensions and must be shaken before each use.

Problem: You prescribe prednisolone acetate for an episcleritis, but the patient is dismayed by its high price.

Plan B: Consider generic Maxitrol, ignoring the antibiotic component; it is a cheap way to get access to a decent steroid when push comes to shove. Another option is generic prednisolone sodium phosphate, which works well for ocular surface conditions and requires no shaking.

Problem: You Rx Lotemax ointment or FML ophthalmic ointment, but the expense is a concern for the patient.

Plan B: Try generic Blephamide ointment or Maxitrol ointment, ignoring the antibiotic components of these drugs. If you're treating contact blepharodermatitis, go with triamcinolone 0.1% cream, proactively explaining to the patient that the tube will state "not for ophthalmic use," but that it's completely safe to use the drug, as this is a bureaucratic statement, not a clinically relevant one. Note: Kenalog (triamcinolone) is commonly injected intravitreally, and we've never seen a problem with use of triamcinolone cream, even if some gets in the eyes.

Prescribing has never been so fraught with barriers and inconveniences. It's like playing chess: One must be fully aware of all potential moves of the adversary (in this case, the insurance companies) at all times and be ready with an effective countermove. This often requires thinking outside the box, and you must have a comprehensive knowledge of all available drugs. Sometimes, after a point-counterpoint with a pharmacist, we finally just say, "tell me what you have," and work from there to find a medicine that is either affordable or on the patient's formulary.

ONE OPHTHALMOLOGIST'S TAKE ON EYE CARE'S FUTURE

In this Q&A, excerpted from a July 2018 interview in *The Ophthalmologist*, Bonnie An Henderson, MD, partner at Ophthalmic Consultants of Boston and clinical professor at Tufts University School of Medicine Boston, discussed the future of ophthalmology.

Q. How do you think ophthalmology will change in the coming years?

A. “Technological advances seem to evolve more rapidly in ophthalmology than in other industries... Hopefully, future advances will allow patients to be less dependent on eyedrops for glaucoma, less dependent on corrective spectacles, and medical therapies will decrease visual morbidity from age-related diseases and endocrine disorders.”

Q. What's exciting you right now?

A. “The focus on presbyopia correction. Not only because of the explosion of new IOLs, but also the new medical developments to prevent lens hardening. This field is in its infancy and will continue to grow over the next few decades.”

Attentive ODs should be keenly aware of the changing landscape of eye care delivery. Those who embrace the vast majority of patient presentations (and cease senseless referrals) are poised to do well in the face of these changes. On the other hand, refraction-centric practices will be significantly adversely affected.

Year of the Woman. Sitting Down With... Bonnie An Henderson, Partner at Ophthalmic Consultants of Boston, and Clinical Professor at Tufts University School of Medicine Boston, MA, USA. Excerpted from *The Ophthalmologist*. <https://theophthalmologist.com/subspecialties/year-of-the-woman>. July 25, 2018. Accessed April 3, 2019.

FDA DRUG APPROVAL & OFF-LABEL USE

We are noticing that newly approved antibiotics have a sole indication for bacterial conjunctivitis and that new steroids have a sole indication for postoperative care. Why is this? Getting drugs approved is an expensive, bureaucratic exercise, so drug companies have a financial incentive to find the shortest, least expensive way to get their product to market. This process has little to nothing to do with the product's ultimate clinical use. This partly explains why a lot of what we do in clinical practice is “off-label.”

What we need is a team of experts to objectively assess all drugs guided by rigorous scientific standards. This would provide all clinicians with vastly enhanced guidance on the proper, intelligent use of medicines in the care of our patients. Until such a dream becomes reality, we will all have to become more and more comfortable prescribing “off-label,” which is an extremely common, routine practice.

manufacture eye glasses weighing 7 grams (25 ounces) in 14 hours at a cost of \$113.90.¹ The researchers wrote, “The 3-D printed spectacles fitted precisely onto the face and were considered to provide a superior outcome compared with conventional spectacles. Optical alignment, good comfort and acceptable cosmesis were achieved. One month after fitting, the 3-D printed spectacles did not require further changes.” We all know this technology is only going to improve.

And in the medical realm, eye drops are in development that might potentially delay presbyopia for years. Such medical advances are only going to continue.

While online refraction is here to stay, we all know such a service fails to screen for glaucoma and other potentially vision-threatening, asymptomatic eye conditions. Regardless of how this online evaluation and other technological/clinical developments play out, it's vital that optometrists continue to evolve as broad-based, comprehensive medical eye doctors. Not only is this crucial to meeting an underserved segment of patient need, but technology cannot replace sound clinical reasoning and judgment. In addition, the decrease in matriculating ophthalmologists from residencies each year leaves a

TECHNOLOGY TO AID YOUR PRACTICE

Services such as CoverMyMeds and PARx Solutions partner with electronic health records (EHRs), health care providers, payers and pharmacies to initiate, transmit and track the status of electronic prior authorization (PA) requests within the clinical workflow, helping patients to more quickly receive the medications they need for therapy.

void where optometry could (and should) become the main provider of medical eye care.

From a public health perspective and for professional survival, we need to begin today to stop needless referrals to surgeons for medical care that we can provide. If you do not provide, for example, glaucoma care, then have an optometric colleague care for these patients. As a profession, we refer out untold millions of dollars each year that should be staying in our offices. Financial advisors urge portfolio diversification, and we urge you in like manner to diversify your patient base. We think this is absolutely critical for enhanced medical care of our patients and for the viability of our profession. ■

1. Ayyildiz O. Customised spectacles using 3-D printing technology. *Clin Exp Optom*. 2018;101(6):747-51.

EQUIPPING THE EXAMINATION ROOM

To provide high-quality comprehensive care, optometrists need to equip the exam room with the right tools. We catalogued our medical inventory and determined most of the following items to be absolutely essential and highly recommended for the office. (Note that we do not list slit lamps, trial lenses or the basic instrumentation all offices have.)

- Dilating drops:** • Paremyd; 1% and 0.5% tropicamide; 2.5% and 10% phenylephrine
- Anesthetics:** • 0.5% proparacaine, and a combination of 0.25% sodium fluorescein with a topical anesthetic (e.g., Fluress)
- Cycloplegics:** • Cyclopentolate 1%, and homatropine 5%
- Ointments:** • A combination antibiotic/steroid, such as generic Maxitrol, and an antibiotic, such as Polysporin or a generic equivalent
- Medications:** • Acetazolamide (Diamox) 250mg tablets (for acute angle closure)
• Pilocarpine 2% (for acute angle closure)
• Timolol, brimonidine and prostaglandin samples
• Lipid-based artificial tear samples
• Steroid and antibiotic samples
• Betadine 5% ophthalmic prep solution (for treating acute EKC)
- Supplies:** • Fluorescein and lissamine green strips
• Sterile irrigating solution
• Bandage-therapeutic soft contact lenses
• Oval eye patches
• One-inch hypoallergenic surgical tape for patching (e.g., Micropore)
• Sterile and non-sterile cotton swabs
• Mini-tip culturette swab kits (to collect for bacterial culturing)
• Alger brush and 25-gauge, 5/8-inch needles (for foreign body removal and/or rust ring fragmentation)
• Alcohol prep pads
• Post-mydriatic sunglasses (adult and child sizes) with temples and drop-in
• Anterior stromal puncture needles with syringe handles
• Syringe barrels (two or three of these universal plastic barrels for use as holders for straight or ASP needles)
- Instruments:** • AdenoPlus (EKC in-office detector)
• Blood glucose monitor
• Humphrey field analyzer
• Optical coherence tomography device
• Meibography device
• Icare tonometer (and Icare Home tonometer)
• Stainless-steel instrument tray containing: sharp-tipped jewelers forceps; golf club spud; Shahinian cannula for lacrimal irrigation; #2 Desmarres lid retractor to facilitate double eversion; Simpson lacrimal dilator; sharp-tipped small iris scissors; epilation forceps; curved, toothed forceps; EOS 28 needles (e.g., Bausch + Lomb) and gouge spud (for foreign body and concretion removal)
• 4-mirror and 3-mirror gonio lenses
• Plano and convex handheld mirror
• Exophthalmometer
• BIO 20D or similar condensing lens
• Scleral depressor (e.g., Wilder), mainly to facilitate eyelid eversion
• 90D (or equivalent) condensing lens to enable slit-lamp ophthalmoscopy
• Magnifying loupes for inserting punctal plugs and other procedures
• Stethoscope
• Sphygmomanometer and/or wrist cuff automatic blood pressure device
• Assorted patient education materials

