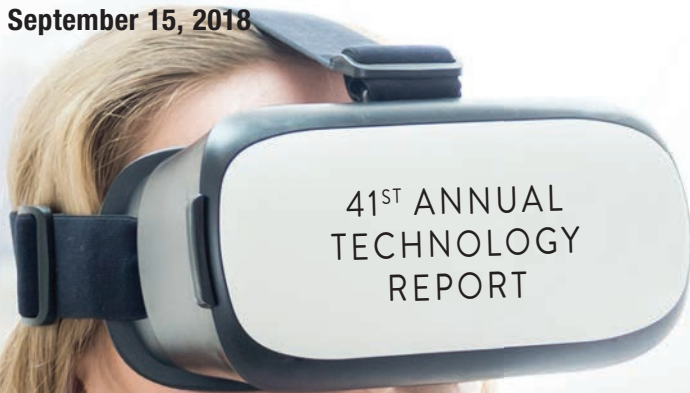

The Day I Became My Own Patient—a final *Therapeutic Review* column from Dr. Kabat, page 122

REVIEW[®] OF OPTOMETRY

September 15, 2018

www.reviewofoptometry.com



Reality Check: Protecting Ocular Health from Headset Hazards

Page 52

Retool Your Office Tech
to Boost Efficiency

Page 30

OCT-A for AMD,
Diabetes and Beyond

Page 40

ALSO:

Why Refer When You Can Retain?, page 62

Master Pediatric Spectacle Wear Challenges, page 70

How Drug Abuse Affects the Eye, page 80

EARN 2 CE CREDITS

Slaying the Giant Cell Arteritis, page 91

COMING SOON

AIR OPTIX® PLUS HYDRAGLYDE® MULTIFOCAL CONTACT LENSES

DISCOVER THE DIFFERENCE



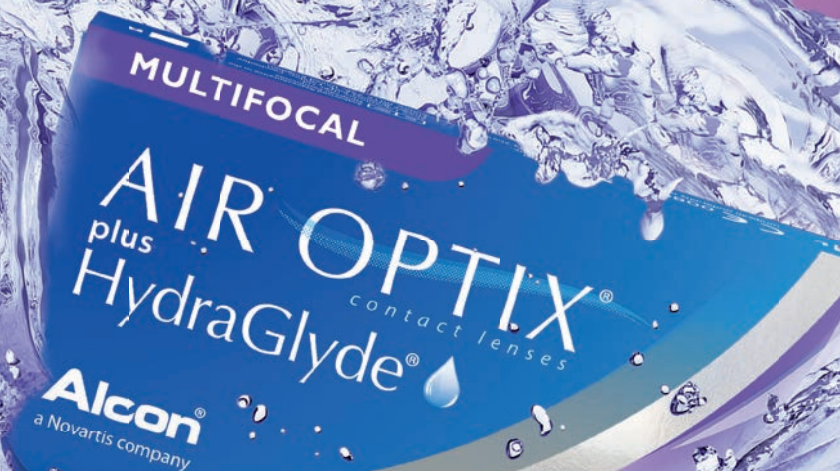Excellent Deposit Protection^{1,2}



Lasting Lens Surface Moisture^{3,4}



Seamless Vision At All Distances^{5,6†}



†Based on the Alcon Precision Profile® Design, as incorporated in AIR OPTIX® AQUA Multifocal lenses.

References: 1. Nash WL, Gabriel M, Mowrey-McKee M. A comparison of various silicone hydrogel lenses; lipid and protein deposition as a result of daily wear. *Optom Vis Sci.* 2010;87:E-abstract 105110. 2. Nash WL, Gabriel MM. Ex vivo analysis of cholesterol deposition for commercially available silicone hydrogel contact lenses using a fluorometric enzymatic assay. *Eye Contact Lens.* 2014;40(5):277-282. 3. In vitro study over 16 hours to measure wetting substantivity, Alcon data on file, 2015. 4. Muya L, Lemp J, Kern JR, Sentell KB, Lane J, Perry SS. Impact of packaging saline wetting agents on wetting substantivity and lubricity. *Invest Ophthalmol Vis Sci.* 2016;57:E-abstract 1463. 5. Alcon data on file, 2013. 6. Lemp J, Kern J. Alcon multifocal contact lenses for presbyopia correction. Presented at the Canadian Association of Optometrists Congress, June 28-30, 2017; Ottawa, ON.

Important information for AIR OPTIX® plus HydraGlyde® Multifocal (lotrafilcon B) contact lenses: For daily wear or extended wear up to 6 nights for near/far-sightedness, presbyopia and/or astigmatism. Risk of serious eye problems (i.e., corneal ulcer) is greater for extended wear. In rare cases, loss of vision may result. Side effects like discomfort, mild burning or stinging may occur.

Alcon A Novartis
Division

See product instructions for complete wear, care and safety information. **Rx only**

© 2018 Novartis 06/18 US-AOHH-18-E-1269

IN THE NEWS

A new study suggests **central corneal thickness (CCT) increases as diabetic peripheral neuropathy (DPN) becomes more severe** in patients with diabetes because of an increase in stromal thickness. The study evaluated nine controls, 16 patients with mild DPN and nine with severe DPN. Data showed CCT was lowest in the control group and highest in those with severe DPN; stromal thickness also increased as DPN progressed.

Kumar N, Pop-Busui R, Musch DC, et al. Central corneal thickness increase due to stromal thickening with diabetic peripheral neuropathy severity. *Cornea*. 2018;37(9):1138-42.

The **oxidative stress and apoptosis seen in glaucoma patients may be linked to elevated levels of serum bile acids (SBA)**, according to researchers. A new study found a statistically significant difference between the SBA level in those with and those without primary open-angle glaucoma (POAG)—with the median measurement of 13.4ng/mL found in POAG patients and only 3.10ng/mL in non-POAG patients. The investigators speculate that the connection may lie in SBA's clinical pathways.

Mridula J, Vijaya P, Gnananaharan J, Kamath S. Serum bile acids in patients with primary open-angle glaucoma. *J Glaucoma*. 2018;27(8):687-90.

Researchers recently found that people with glaucoma, age-related macular degeneration (AMD) or diabetic retinopathy (DR) have a **higher risk of developing Alzheimer's disease (AD)**. The study found a 46% higher AD risk in participants with recent glaucoma, a 50% higher risk in participants with established AMD and a 67% and 50% increased risk in participants with recent and established DR, respectively.

Lee CS, Larson EB, Gibbons LE, et al. Associations between recent and established ophthalmic conditions and risk of Alzheimer's disease. *Alzheimer's & Dementia*. August 8, 2018. [Epub ahead of print].

Glaucoma's Origins: The Immune System?

The sight-threatening disease's roots are unknown, but researchers may have uncovered a telling detail.

By Bill Kekevan, Senior Editor

Celiac disease, lupus and multiple sclerosis are all conditions that turn the body's immune system on itself, attacking its own nerves, tissues or other structures. Thanks to an unintentional discovery, glaucoma may soon be listed among their ranks.¹

The condition is the second leading cause of blindness in the world and yet its only known modifiable risk factor is elevated intraocular pressure (IOP).² That could all change if this hypothesis plays out. Although the new concept is still in an early stage of research, a team of investigators from Massachusetts Institute of Technology (MIT) and Massachusetts Eye and Ear is speculating that glaucoma be filed under the autoimmune banner.

Blocking this autoimmune activity, they feel, could be the key to treatment and perhaps even prevention.¹

Using mice deficient in T-cells, B-cells or both and a process called adoptive cell transfer, the investigators have uncovered "compelling evidence that glaucomatous neurodegeneration is mediated in part by T-cells that are pre-sensitized by exposure to commensal microflora," the report reads.

The researchers found that, in mice with glaucomatous damage,

T-cells infiltrated the retina when IOP rose. Once these cells breach the blood-retina barrier, they target heat shock proteins, which help cells respond to stress or injury. The researchers suspect the T-cells attack the proteins because they perceive them as a threat due to prior exposure to bacterial heat shock proteins—the researchers could not induce glaucoma in mice never exposed to bacteria.^{1,3}

The team looked at T-cell activity in human patients with glaucoma as well and found they have five times the normal level of T-cells specific to heat shock proteins, suggesting that the same phenomenon may also contribute to the disease in humans, according to an MIT release.³

"This is the first report that, to our knowledge, describes an unexpected link and the sequential roles of elevated IOP, intact commensal microflora and activation of T-cell responses in the pathogenesis of glaucoma," the researchers stated in the MIT release.¹

1. Chen H, Cho K, Shen C, et al. Commensal microflora-induced T cell responses mediate progressive neurodegeneration in glaucoma. *Nature Communications*. 2018;9:3209.
2. Bulletin of the World Health Organization. World Health Organization. Glaucoma is second leading cause of blindness globally. www.who.int/bulletin/volumes/82/11/feature1104/en. November 1, 2004. Accessed August 21, 2018.
3. Trafton A. Study suggests glaucoma may be an autoimmune disease. MIT News Office. <http://news.mit.edu/2018/glaucoma-autoimmune-disease-0810>. August 10, 2018. Accessed August 21, 2018.

NEWS STORIES POST EVERY WEEKDAY MORNING AT www.reviewofoptometry.com/news

AI Muscles in on Eye Care

Researchers in the United Kingdom recently unveiled an artificial intelligence (AI) system that can correctly refer at least 50 retinal conditions in 94% of cases—stats that match or even exceed experts in the field.¹

The collaboration between Moorfields Eye Hospital NHS Foundation Trust, UK-based Google DeepMind, University

College London and Southampton University published their findings in *Nature Medicine* August 13th, making waves in the eye care community.²

Because the volume and complexity of diagnostic imaging is exploding beyond what experts can manage, the team sought an AI solution to ensure patients in need are seen in a timely manner. Their program, built on a deep learning architecture, analyzed 14,884 three-dimensional optical coherence tomography (OCT) scans as training—and then proceeded to provide referral recommendations on a range of sight-threatening retinal diseases. After experts analyzed the same OCT scans and made their own referral decisions, they found the program showed a 94% accuracy rate.

The system's ability to train properly with so few scans removes

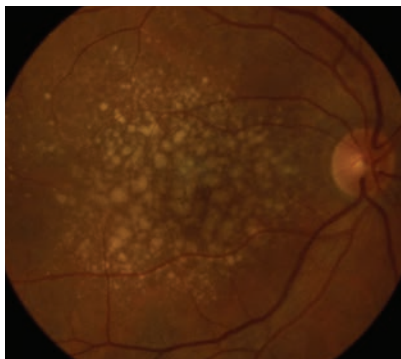
a major barrier to implementation, according to the researchers: it doesn't need "prohibitive training data requirements across multiple pathologies." But that's not the only barrier this system destroys. The deep learning architecture it's based on uses OCT tissue segmentations that act as device-independent representations, meaning "referral accuracy is maintained when using tissue segmentations from a different type of device," the study says.²

With these stumbling blocks out of the way, the team plans to move forward with clinical trials, in the hopes of launching the system in as many as 30 UK hospitals within three years.¹

1. Matthews S. Eye care revolution: AI programme with 94% accuracy can now spot diseases that cause blindness (and it's as good as the world's top consultants). Daily Mail. www.dailymail.co.uk/health/article-6056259/AI-programme-spot-diseases-worlds-consultants.html. August 13, 2018. Accessed August 14, 2018.

2. De Fauw J, Ledsam JR, Romera-Paredes B, et al. Clinically applicable deep learning for diagnosis and referral in retinal disease. *Nature Medicine*. August 13, 2018. [Epub].

Photo: Jay M. Heyrle, OD



AI may soon help clinicians detect patients such as this one with early AMD.

Rethink Your Use of Lea Symbols

Lea symbol charts are useful in visual acuity assessment in children, but different test designs can lead to discrepancies in measured visual acuity as a result of differential effects of crowding, a new study finds.

The study compared habitual visual acuity in a sample of young children using two versions of the single Lea symbol charts with different crowding features.

Researchers measured monocular habitual visual acuity in a sample of 77 young children ages four to six using crowded Lea symbol charts with either flanking bars separated from the central symbol by 0.5

optotype width or flanking Lea optotypes separated from the central symbol by 1.0 optotype width.

Lea symbols with flanking optotypes resulted in higher visual acuity than the Lea symbols with flanking bars, believed to be a result of differences in the crowding effect. The logarithm of the minimum angle of resolution measured using the two chart versions with different flankers and flanker-target separations differed, on average, by a small amount (about 1.5 optotypes). The study notes that this difference is unlikely to be clinically significant.

Researchers expected their results to show the opposite effect, where

the Lea symbols with flanking optotypes resulted in lower acuity values, not higher than the Lea symbols with flanking bars.

The study concludes that flanker-target separation may be more important in determining the amount of crowding and may override the effect of flanker type when using single flanked optotypes for testing visual acuity in children. Still, the researchers recommend using the Lea symbols with flanking bars because of the closer flanker-target separation.

Sailoganathan A, Rou LX, Buja KA, Siderov J. Assessment of visual acuity in children using crowded Lea symbol charts. *Optom Vis Sci*. 2018;95(8):643-7.

Technology in balance



Health




Vision



Comfort

Miru 1 month: a unique family of silicone hydrogel monthly lenses.

MeniSilk™ and Nanogloss™ technologies designed to meet the demands of today's contact lens wearer.*



Material and surface technologies

MeniSilk™

- Ultra high Dk/t - 161 @ -3.00D
- Exceptional hydration
- Optimized transparency

Nanogloss™

- Super smooth surface
- Resistance to bacteria
- Excellent wettability



www.meniconamerica.com

*Menicon data on file April 2016



The Future of AMD Therapy: a Drop?

Eye drops may one day be an option for age-related macular degeneration (AMD) treatment, according to a new study.

Though previous efforts at topical AMD therapy have met with little success, researchers have developed a topical delivery of ranibizumab and bevacizumab that, at least in an animal model, provides the same outcome as injected therapy.

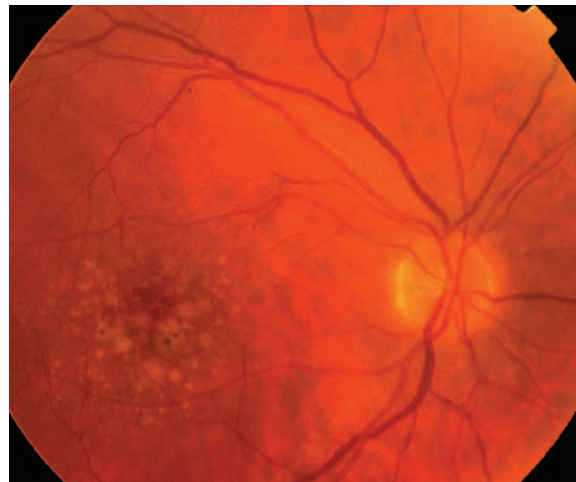
The recent study investigated cell-penetrating peptides (CPP) as ocular drug delivery vehicles. Researchers used drops with CPP-mediated topical delivery to transport anti-vascular endothelial growth factor (anti-VEGF) therapy into the posterior segment of rabbit and pig eyes. They also tested the CPP and anti-VEGF mix's efficacy using disease models in rodents with pre-established models of neovascularization.

In rabbits, the CPP+bevacizumab drop delivered $4.0 \pm 2.3 \mu\text{g}/\text{retina}$ at 24 hours—significantly higher

than controls. This increased over three days to $83.31 \pm 39.72 \mu\text{g}/\text{retina}$ and cleared from the retina over seven days. In the pig's eyes, the CPP+ranibizumab eye drop delivered $1.7 \pm 0.4 \mu\text{g}/\text{mL}$ and the CPP+bevacizumab eye drop delivered $1.1 \pm 0.3 \mu\text{g}/\text{mL}$, all significantly higher levels than either CPP, saline, ranibizumab or bevacizumab drops alone.

Subjects that had an anti-VEGF intravitreal injection and those receiving CPP+anti-VEGF eye drops had significantly lower areas of neovascularization than the negative control eyes.

The researchers note that eye drops could deliver anti-VEGF treatment to the posterior segment



AMD patients such as this one may one day be able to use eye drops instead of injections to stave off further damage.

without causing patients distress or possible side effects such as retinal tearing. In addition, by removing the need for injections, patients could take ownership of their treatment program.

“This study is encouraging in that it shows the potential for feasibility of a topical treatment, which if efficacious would be much better for patients, as their overall treatment burden would be decreased,” explains Jeffrey D. Gerson, OD, of Grin Eye Care in Olathe, KS.

But as promising as these results may be, Dr. Gerson warns against over-enthusiasm for a few reasons. “The results in this study were produced in animals—this was not a human study.” In addition, “previous topical drugs in trials even in humans that originally looked to be on the road to approval ultimately failed in trials.”

De Cogan F, Lynch A, Berwick M, et al. Topical treatment for AMD: Non-invasive delivery and efficacy of ranibizumab and bevacizumab in rabbit and porcine eyes. *Invest Ophthalmol Vis Sci.* 2018;59:1439.

2018 Income in Review

It's that time of year again! *We at Review want to hear about how your income is doing in 2018 for our annual income survey.*

If you haven't done so already, please take a few moments to respond to this very important survey. In our December issue, we will have crunched the numbers and will let you know how ODs across the country are doing, income-wise.

Here's an incentive for sharing your thoughts with us: By completing the survey, you'll have a chance to win a **\$100 American Express Gift Card.**

You can respond anonymously. All personal and financial information is confidential and used for no other purpose than this survey. It only takes a few minutes, since there are only about 20 questions.

To take the survey, visit www.surveymonkey.com/r/9QPBG6T, or scan the QR code.



THE JOURNEY TO **IMPROVED VISION** STARTS WITH *YOU*

Successful cataract surgery often depends on strong collaboration between patients, optometrists, and surgeons. **Alcon is here to support YOU** in building those partnerships.

Alcon Surgical Offerings

- The AcrySof® family of IOLs has been implanted over **100 MILLION TIMES**¹ – more than any other brand – and provides exceptional quality, clarity, and stability.²⁻⁴
- Our full range of products helps you meet each individual's needs, including astigmatic and presbyopic patients.
- We provide resources to support collaborative care between the optometrist and ophthalmologist.

Visit myalcon.com/cataractresources to order resources for your patients and your practice.

Alcon A Novartis
Division

 AcrySof® IQ IOL Family

References: 1. Alcon sales data on file. 2. Wirtitsch MG, Findl O, Menapace R, et al. Effect of haptic design on change in axial position after cataract surgery. *J Cataract Refract Surg.* 2004;30(1):45-51. 3. Visser N, Bauer NJ, Nuijts RM. Toric intraocular lenses: Historical overview, patient selection, IOL calculation, surgical techniques, clinical outcomes, and complications. *J Cataract Refract Surg.* 2013;39(4):624-637. 4. Potvin R, Kramer BA, Hardten DR, Berdahl JP. Toric intraocular lens orientation and residual refractive astigmatism: An analysis. *Clin Ophthalmol.* 2016;10:1829-1836.

© 2018 Novartis 04/18 US-ODE-18-E-0547a

AcrySof® Family of Single-Piece IOLs Important Product Information

(AcrySof® UV, AcrySof® IQ, AcrySof® IQ Toric, AcrySof® IQ ReSTOR®, and AcrySof® IQ ReSTOR® Toric IOLs)

CAUTION: Federal law restricts these devices to sale by or on the order of a physician. **INDICATION:**

The family of AcrySof® single-piece intraocular lenses (IOLs) includes AcrySof® UV-absorbing IOLs ("AcrySof® UV"), AcrySof® IQ, AcrySof® IQ Toric and AcrySof® IQ ReSTOR® and AcrySof® IQ ReSTOR® Toric IOLs. Each of these IOLs is indicated for visual correction of aphakia in adult patients following cataract surgery. In addition, the AcrySof Toric IOLs are indicated to correct pre-existing corneal astigmatism at the time of cataract surgery. The AcrySof IQ ReSTOR IOLs are for cataract patients with or without presbyopia, who desire increased spectacle independence with a multifocal vision. All of these IOLs are intended for placement in the capsular bag. **WARNINGS/PRECAUTIONS:**

General cautions for all AcrySof® and AcrySof® UV IOLs: Careful preoperative evaluation and sound clinical judgment should be used by the surgeon to decide the risk/benefit ratio before implanting any IOL in a patient with any of the conditions described in the Directions for Use that accompany each IOL. Caution should be used prior to lens encapsulation to avoid lens decentration or dislocation. Viscoelastic should be removed from the eye at the close of surgery. **Additional Cautions associated with AcrySof® IQ ReSTOR® IOLs:**

Some patients may experience visual disturbances and/or discomfort due to multifocality, especially under dim light conditions. A reduction in contrast sensitivity may occur in low light conditions. Visual symptoms may be significant enough that the patient will request explant of the multifocal IOL. Spectacle independence rates vary with all multifocal IOLs; as such, some patients may need glasses when reading small print or looking at small objects. Clinical studies indicate that posterior capsule opacification (PCO), when present, may develop earlier into clinically significant PCO with multifocal IOLs. **Additional Cautions associated with AcrySof® IQ Toric, AcrySof® UV Toric and ReSTOR® Toric IOLs:** Optical theory suggests that, high astigmatic patients (i.e. > 2.5 D) may experience spatial distortions. Possible toric IOL related factors may include residual cylindrical error or axis misalignments. Toric IOLs should not be implanted if the posterior capsule is ruptured, if the zonules are damaged, or if a primary posterior capsulotomy is planned. Rotation can reduce astigmatic correction; if necessary lens repositioning should occur as early as possible prior to lens encapsulation. Prior to surgery, physicians should provide prospective patients with a copy of the appropriate Patient Information Brochure available from Alcon informing them of possible risks and benefits associated with the AcrySof® IQ Toric, AcrySof® IQ ReSTOR® and AcrySof® IQ ReSTOR® Toric IOLs. Do not resterilize. Do not store at temperatures over 45° C. Use only sterile irrigating solutions to rinse or soak IOLs. **ATTENTION:** Refer to the Directions for Use labeling for the specific IOL for a complete list of indications, warnings and precautions.

News Review

Oxidative Stress May Contribute to KCN

Researchers in Iran recently discovered low serum levels of certain antioxidants in patients with keratoconus (KCN), pointing to a possible new therapy to help ward off early progression.

After assessing serum levels of zinc (Zn), calcium, magnesium, iron, copper (Cu) and selenium (Se) in 50 patients with advanced KCN and 50 healthy controls, the researchers noted lower zinc, copper and selenium in the KCN group. No statistical difference existed between groups for calcium, magnesium or iron.

The study further explains that copper deficiency is known to cause oxidative stress in tissues and abnormal collagen synthesis; zinc deficiency also impairs the breakdown of collagen and induces oxidative stress in tissues; "these changes can be the underlying pathology involved in loss of corneal rigidity, thinning and formation of a cone due to the weakened tissue being unable to withstand intraocular pressure forces that finally result in KCN," the study says.

This was the first investigation to report systemic selenium levels—and low ones at that—in patients with advanced KCN, the researchers said. Selenium deficiency plays a role in the etiology of autoimmune diseases such as thyroid dysfunction and various infections. In addition, other studies have suggested that "selenium–lactoferrin eye drops regulate oxidative stress in the corneal epithelium and are recommended for treatment of dry eye," according to the study.

"These results suggest the possible role of antioxidant activity of Zn, Cu and Se in the etiology of advanced KCN, which then suggests the possibility of treatment of KCN by supplementation with these trace elements," the researchers conclude. "If such treatment could slow the progression of KCN, then the need for keratoplasty might be reduced."


Bamdad S, Owji N, Bolkheir A, et al. Association between advanced keratoconus and serum levels of zinc, calcium, magnesium, iron, copper, and selenium. *Cornea*. June 07, 2018. [Epub ahead of print].

What's Behind Infection?

Researchers recently discovered a unique microbiome in human limbal and forniceal tissue that differs from the structure and composition of the ocular surface microbiome as a whole. The team obtained conjunctival tissue from 23 patients undergoing pterygium surgery and found a significant difference in bacterial community structure between the conjunctival surface and limbal and forniceal tissue, but no difference between the limbus and fornix. Limbal and forniceal samples were dominated by *Pseudomonas* (79.9%), which was found in low relative abundances on the conjunctival surface (6.3%).

Ozkan J, Coroneo M, Willcox M, et al. Identification and visualization of a distinct microbiome in ocular surface conjunctival tissue. *Invest Ophthalmol Vis Sci*. 2018;59(10):4268-76.





BVI

Parasol® and Extend® Punctal Occlusion

New Juvenile Glaucoma Plan

Childhood glaucoma is rare but devastating, given its lifelong impact. As with most diseases, early diagnosis is key to developing a targeted treatment protocol and preserving visual function as much as possible. That's why it's so important for the Childhood Glaucoma Research Network (CGRN) to give doctors precise and accurate guidance on diagnosis.

A new classification system CGRN developed aims to do just that by unifying the nomenclature "through a logical and systematically approachable path." It's available at www.gl-foundation.org/wp-content/uploads/2012/04/cgrn-classificationsystemlaminatedcard.pptx.pdf.

This new system recognizes that, for some, a glaucoma diagnosis may be suspected, but not confirmed. It categorizes patients as follows:

- Glaucoma following cataract surgery or clear lens extraction.
- Glaucoma associated with nonacquired systemic disease or syndrome.
- Glaucoma associated with non-acquired ocular anomalies.
- Glaucoma associated with acquired conditions.
- Primary congenital glaucoma.
- Juvenile open-angle glaucoma.

The system has already met with approval, as it reached a consensus agreement at the Ninth World Glaucoma Association Consensus and has been adopted by the American Academy of Ophthalmology. ■

Thau A, Lloyd M, Freedman S, et al. New classification system for pediatric glaucoma: implications for clinical care and a research registry. *Curr Opin Ophthalmol*. July 19, 2018. [Epub ahead of print].

Products for Every Stage of your Patient's Dry Eye Care




Parasol®

Permanent



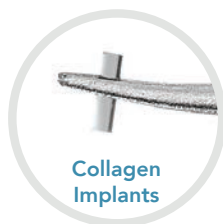
EXTEND180®

Long-Term



EXTEND®

Mid-term



Collagen Implants

Short-Term



Micro Flow™

Partial



Call your local sales rep or customer service at **1-866-906-8080**

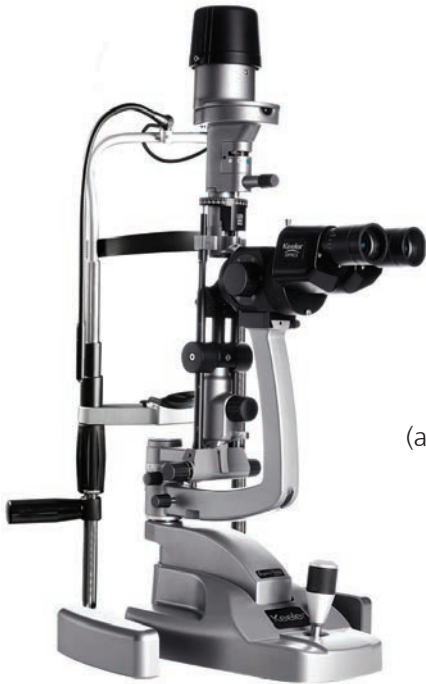For information on all BVI products, visit bvimedical.com

BVI, BVI Logo and all other trademarks (unless noted otherwise) are property of Beaver-Visitec International ("BVI") © 2018 BVI

The Keeler³ Trade In Program

Buy 3 // Trade 3 // Get 1 Free

The Power of 3. Purchase any 3 Keeler Slit Lamps and trade in 3 of your old Slit Lamps and we'll send you a 4th Keeler Slit Lamp absolutely free of charge.



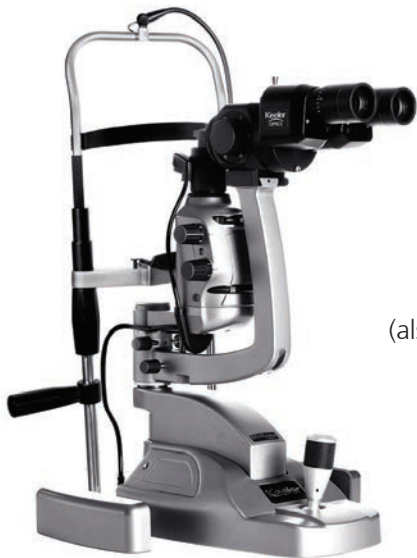KSL-H

(also in Digital Ready)



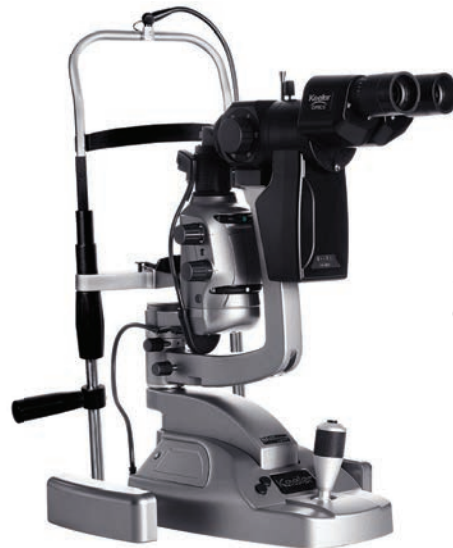KSL-H-D

(full Digital)



KSL-Z

(also in Digital Ready)



KSL-H-D

(full Digital)

Keeler
OPTICS

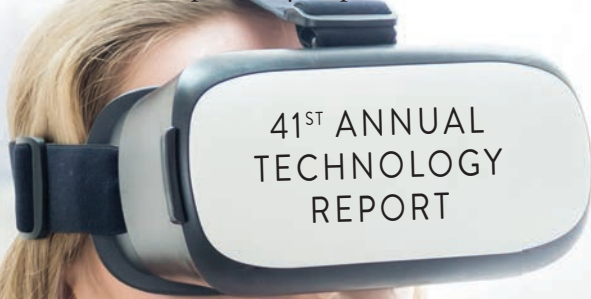Keeler Instruments, Inc. • 3222 Phoenixville Pike, bldg. 50 • Malvern, PA 19355
Tel: (800) 523-5620 • Fax: (610) 353-7814 • email: keeler@keelerusa.com

Offer valid until December 31, 2018.

Contact Keeler or one of our authorized dealers for more information.

Contents

Review of Optometry September 15, 2018



30 Retool Your Office Tech to Boost Efficiency

These tips can help you get more out of EHR, patient communication tools and new diagnostic devices.

BY BRIAN CHOU, OD

40 OCT-A for AMD, Diabetes and Beyond

Imaging retinal and choroidal bloodflow can have a significant impact on how you diagnose and treat any number of ocular conditions.

BY STEVEN FERRUCCI, OD, AND JAY M. HAYNIE, OD

52 Reality Check: Protecting Ocular Health from Headset Hazards

Devices are expanding your patients' visual landscapes. What are they doing to their eyes?

BY JEROME LEGERTON, OD, MS, LIZ SEGRE, AND JAY MARSH, MSME

Why Refer When You Can Retain?

Adding a specialty focus elevates your practice and dramatically improves your patients' lives.

BY CATHERINE MANTHORP, ASSOCIATE EDITOR • PAGE 62

Master Pediatric Spectacle Wear Challenges

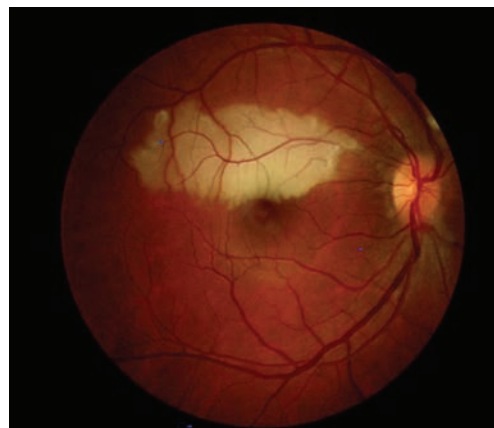Uncooperative kids, anxious parents and unusual clinical challenges raise the stakes. Here's how to succeed.

BY SARAH GALT, OD, KATHERINE WEISE, OD, MBA, AND CATHY BALDWIN, LDO • PAGE 70

How Drug Abuse Affects the Eye

Drug use can be identified from a set of ocular sequelae. Learn to recognize the signs and how to respond with this guide.

BY NICHOLAS KARBACH, OD, NATALIA KOBRENKO, OD, MARC MYERS, OD, AND ANDREW S. GURWOOD, OD • PAGE 80

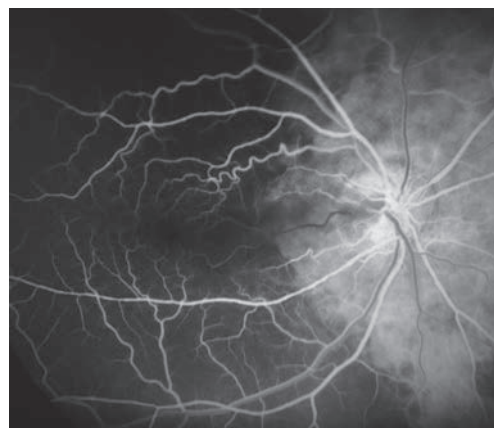

Earn 2 CE Credit:

Slaying the Giant Cell Arteritis

Uncover the symptoms of this deadly condition and know how to help manage the patient.

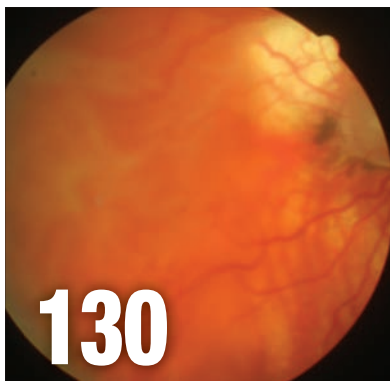
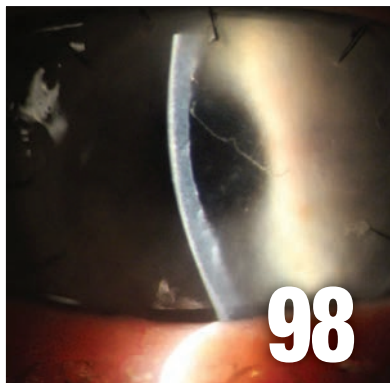
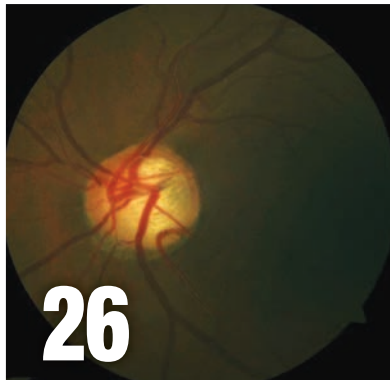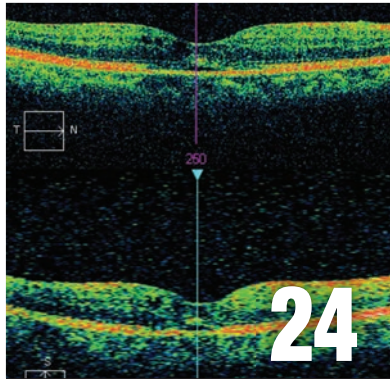
BY TRENTON CLEGHEN, OD • PAGE 91



Departments

Review of Optometry September 15, 2018

- 3** News Review
- 14** Letters to the Editor
- 16** Outlook
No More Fun and Games
JACK PERSICO
- 18** Through My Eyes
Narrow Focus, Wide Impact
PAUL M. KARPECKI, OD
- 22** Chairside
The Softer Side of Vickers
MONTGOMERY VICKERS, OD
- 24** Clinical Quandaries
Mission: Uncorrectable
PAUL C. AJAMIAN, OD
- 26** The Essentials
True Colors
BY BISANT A. LABIB, OD
- 28** Coding Connection
Playing with Fire: OCT-A Coding
JOHN RUMPAKIS, OD, MB
- 98** Cornea + Contact Lens Q&A
Third Time's the Charm?
JOSEPH P. SHOVLIN, OD
- 102** Urgent Care
The Many Hats of Herpes
**DAVID SCHAEFFER, OD,
NATALIE TOWNSEND, OD,
AND RICHARD MANGAN, OD**
- 106** Neuro Clinic
Led Astray
**MICHAEL TROTTINI, OD, AND
MICHAEL DELGIODICE, OD**
- 112** Review of Systems
There's a Killer on the Loose
**CARLO J. PELINO, OD, AND
JOSEPH J. PIZZIMENTI, OD**
- 117** Retina Quiz
Manic (Foveal) Depression
MARK T. DUNBAR, OD
- 120** Meetings & Conferences
- 122** Therapeutic Review
The Day I Became My Own Patient
**ALAN G. KABAT, OD, AND
JOSEPH W. SOWKA, OD**
- 124** Advertisers Index
- 127** Classifieds
- 130** Diagnostic Quiz
That's a Foul
ANDREW S. GURWOOD, OD



REVIEW[®] OF OPTOMETRY

BUSINESS OFFICES

11 CAMPUS BLVD., SUITE 100
NEWTOWN SQUARE, PA 19073

CEO, INFORMATION SERVICES GROUP

MARC FERRARA
(212) 274-7062 • MFERRARA@JOBSON.COM

PUBLISHER

JAMES HENNE
(610) 492-1017 • JHENNE@JOBSON.COM

REGIONAL SALES MANAGER

MICHELE BARRETT
(610) 492-1014 • MBARRETT@JOBSON.COM

REGIONAL SALES MANAGER

MICHAEL HOSTER
(610) 492-1028 • MHOSTER@JOBSON.COM

VICE PRESIDENT, OPERATIONS

CASEY FOSTER
(610) 492-1007 • CFOSTER@JOBSON.COM

VICE PRESIDENT, CLINICAL CONTENT

PAUL M. KARPECKI, OD, FAAO
PKARPECKI@JOBSON.COM

PRODUCTION MANAGER

SCOTT TOBIN
(610) 492-1011 • STOBIN@JOBSON.COM

SENIOR CIRCULATION MANAGER

HAMILTON MAHER
(212) 219-7870 • HMAHER@JHIHEALTH.COM

CLASSIFIED ADVERTISING

(888) 498-1460

SUBSCRIPTIONS

\$56 A YEAR, \$88 (US) IN CANADA,
\$209 (US) IN ALL OTHER COUNTRIES.

SUBSCRIPTION INQUIRIES

(877) 529-1746 (US ONLY)
OUTSIDE US CALL: (845) 267-3065

CIRCULATION

PO Box 81
CONGERS, NY 10920
TEL: (TOLL FREE): (877) 529-1746
OUTSIDE US: (845) 267-3065



CEO, INFORMATION SERVICES GROUP
MARC FERRARA

SENIOR VICE PRESIDENT, OPERATIONS
JEFF LEVITZ

VICE PRESIDENT, HUMAN RESOURCES
TAMMY GARCIA

VICE PRESIDENT, CREATIVE SERVICES & PRODUCTION
MONICA TETTAMANZI

CORPORATE PRODUCTION DIRECTOR
JOHN ANTHONY CAGGIANO

VICE PRESIDENT, CIRCULATION
EMELDA BAREA

ARE YOU FOCUSING ON THE RIGHT GROWTH STRATEGIES?

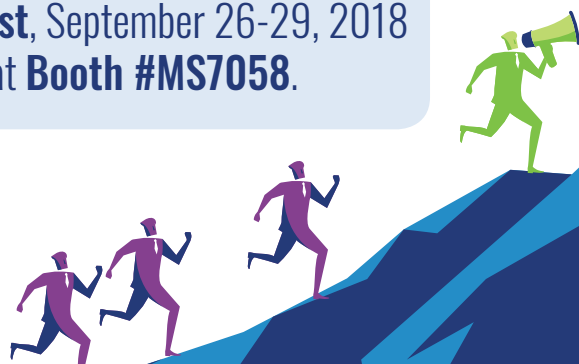- **Identify** your practice level based on size
- **Diagnose** practice needs
- **Design** your action plan
- **Leverage** targeted growth strategies

With **IDOC Consulting**, you'll make informed choices with expert guidance in all areas of practice management.

Get your **Step-by-Step Guide** to grow your practice at optometry.idoc.net/practicegrowth

**VISION
EXPO**

Attending **Vision Expo West**, September 26-29, 2018 in Las Vegas, NV? Visit us at **Booth #MS7058**.



The June 2018 Focus on Refraction column, “Home on the Range,” addresses a misconception among optometry students: some falsely believe their mission is to find a single, ideal refraction for each patient and prescribe accordingly. The column generated praise and disbelief, both of which are expressed in the following letter.

A Range of Emotions

I was so pleased by the very well-written article co-authored by Drs. Taub and Harris, and simultaneously so sad that there is a need for such an article.

My colleagues and I—those of us older than 60—earned the art and science of refraction and vision care in optometry school through the Optometric Extension Program Skeffington papers and study groups.

It is a shame that with the emphasis on medical optometry, refraction—the essence, heart and soul of optometry—and functional vision care have lately been neglected by most optometry schools.

New graduates have little experience with retinoscopes and prescribe whatever they come up with using a phoropter without considering the subtleties of optometry that differentiate our quality of patient care.

I was told that what I consider to be basic knowledge (performing an optometric vision analysis) is now considered a niche practice. What a shame. Basic optometric visual testing is now referred to as a “specialty.”

Thank you, Drs. Taub and Harris, but shame on you, colleges of optometry.

—Errol Rummel, OD, Jackson, NJ

Drs. Taub and Harris Respond

We are thrilled at the opportunity to write this column and, at the same time, disappointed at how far optometry has drifted from its core. Even though there has been a push toward the medical side of the field, we must treat each patient’s visual system as part of their entire body. Refractive care is not cut and dry and, time and time again, we find ourselves sending our students back into the exam room to perform more tests and spend more time with the retinoscope.

We urge ODs to acknowledge this challenge and meet it head-on. Do not simply allow your students, or yourselves for that matter, to rely on an autorefractor to spit out new prescriptions; this is a recipe for disaster. I (Dr. Taub) learned this lesson from Dr. Rummel 15 years ago when I worked for him, and have taken it with me through my career.

Thank you, Dr. Rummel, for all that you do for your patients. Keep fighting the good fight.

CONTRIBUTING EDITORS

PAUL C. AJAMIAN, OD, ATLANTA
AARON BRONNER, OD, KENNEWICK, WASH.
MILE BRUJIC, OD, BOWLING GREEN, OHIO
DEREK N. CUNNINGHAM, OD, AUSTIN, TEXAS
MARK T. DUNBAR, OD, MIAMI
ARTHUR B. EPSTEIN, OD, PHOENIX
JAMES L. FANELLI, OD, WILMINGTON, NC
FRANK FONTANA, OD, ST. LOUIS
GARY S. GERBER, OD, HAWTHORNE, NJ
ANDREW S. GURWOOD, OD, PHILADELPHIA
ALAN G. KABAT, OD, MEMPHIS, TENN.
DAVID KADING, OD, SEATTLE
PAUL M. KARPECKI, OD, LEXINGTON, KY.
JEROME A. LEGERTON, OD, MBA, SAN DIEGO
JASON R. MILLER, OD, MBA, POWELL, OHIO
CHERYL G. MURPHY, OD, BABYLON, NY
CARLO J. PELINO, OD, JENKINTOWN, PA.
JOSEPH PIZZIMENTI, OD, SAN ANTONIO, TEXAS
JOHN RUMPAKIS, OD, MBA, PORTLAND, ORE.
DIANA L. SHECHTMAN, OD, FORT LAUDERDALE, FLA.
JEROME SHERMAN, OD, NEW YORK
JOSEPH P. SHOVLIN, OD, SCRANTON, PA.
JOSEPH W. SOWKA, OD, FORT LAUDERDALE, FLA.
MONTGOMERY VICKERS, OD, LEWISVILLE, TEXAS
WALTER O. WHITLEY, OD, MBA, VIRGINIA BEACH, VA.

EDITORIAL REVIEW BOARD

JEFFREY R. ANSHEL, OD, ENCINITAS, CALIF.
JILL AUTRY, OD, RPH, HOUSTON
SHERRY J. BASS, OD, NEW YORK
EDWARD S. BENNETT, OD, ST. LOUIS
MARC R. BLOOMENSTEIN, OD, SCOTTSDALE, ARIZ.
CHRIS J. CAKANAC, OD, MURRYSVILLE, PA.
JERRY CAVALLERANO, OD, PHD, BOSTON
CLARK CHANG, OD, PHILADELPHIA
WALTER L. CHOATE, OD, MADISON, TENN.
BRIAN CHOU, OD, SAN DIEGO
A. PAUL CHOUS, MA, OD, TACOMA, WASH.
ROBERT M. COLE, III, OD, BRIDGETON, NJ
GLENN S. CORBIN, OD, WYOMISSING, PA.
ANTHONY S. DIECIDUE, OD, STROUDSBURG, PA.
S. BARRY EIDEN, OD, DEERFIELD, ILL.
STEVEN FERRUCCI, OD, SEPULVEDA, CALIF.
MURRAY FINGERET, OD, HEWLETT, NY
IAN BEN GADDIE, OD, LOUISVILLE, KY.
PAUL HARRIS, OD, MEMPHIS, TN
MILTON HOM, OD, AZUSA, CALIF.
BLAIR B. LONSBERRY, MS, OD, MED, PORTLAND, ORE.
THOMAS L. LEWIS, OD, PHD, PHILADELPHIA
DOMINICK MAINO, OD, MED, CHICAGO
KELLY A. MALLOY, OD, PHILADELPHIA
RICHARD B. MANGAN, OD, LEXINGTON, KY.
RON MELTON, OD, CHARLOTTE, NC
PAMELA J. MILLER, OD, JD, HIGHLAND, CALIF.
BRUCE MUCHNICK, OD, COATESVILLE, PA.
MARC MYERS, OD, COATESVILLE, PA.
WILLIAM B. POTTER, OD, FREEHOLD, NJ
CHRISTOPHER J. QUINN, OD, ISELIN, NJ
MICHAEL C. RADOIU, OD, STAUNTON, VA.
MOHAMMAD RAFIETARY, OD, MEMPHIS, TN
JOHN L. SCHACHET, OD, ENGLEWOOD, COLO.
JACK SCHAEFFER, OD, BIRMINGHAM, ALA.
LEO P. SEMES, OD, BIRMINGHAM, ALA.
LEONID SKORIN, JR., OD, DO, ROCHESTER, MINN.
JOSEPH W. SOWKA, OD, FORT LAUDERDALE, FLA.
BRAD M. SUTTON, OD, INDIANAPOLIS
LORETTA B. SZCZOTKA, OD, PHD, CLEVELAND
MARC TAUB, OD, MEMPHIS, TN
TAMMY P. THAN, MS, OD, BIRMINGHAM, ALA.
RANDALL THOMAS, OD, CONCORD, NC
SARA WEIDMAYER, OD, ANN ARBOR, MI
KATHY C. WILLIAMS, OD, SEATTLE
KAREN YEUNG, OD, LOS ANGELES

DAILIES TOTAL1® MULTIFOCAL CONTACT LENSES

DESIGNED FOR SUCCESS



Todd Cohan, OD

Forsight Vision, Ltd.
Long Grove, IL

Dr. Cohan was compensated by Alcon for his participation in this testimonial

Successful practices make patients' best interests their top priority. This means a commitment to providing excellent vision correction and to improving patients' daily lives. In our office, we help patients achieve their vision and lifestyle goals by educating them about their vision correction options and ensuring that they have access to the latest innovations in contact lens technologies. It is this commitment that drives patient satisfaction, new business, and loyalty to the practice.

Today's presbyopes want vision correction that keeps up with their active lives, but unfortunately, many are under the impression that spectacles or readers are their only options. As an eye care practitioner, it is up to me and my staff to help our patients understand that multifocal contact lenses are an option that can provide the exceptional vision and freedom from glasses that they need. For me, the conversation with presbyopic patients always starts with DAILIES TOTAL1® Multifocal contact lenses, which combine the convenience and lifestyle benefits of a daily disposable contact lens with vision and comfort that are truly exceptional.^{1,3} I have been fitting patients with DAILIES TOTAL1® Multifocal contact lenses since the day they became available, and they continue to be my first choice for patients.

I start by telling patients that DAILIES TOTAL1® Multifocal contact lenses can give them the vision they want without the potential lifestyle impacts of glasses or visual compromises with monovision. I explain that the innovative Precision Profile® Design of

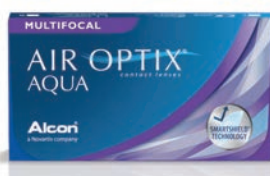DAILIES TOTAL1® Multifocal contact lenses — and all Alcon multifocal lenses — provides the crisp, clear vision that they need at all distances.^{1,4,5} Next, I tell patients that with the groundbreaking Water Gradient and SmartTears® Technologies, DAILIES TOTAL1® Multifocal contact lenses provide outstanding moisture,^{6,8} breathability⁹ and all-day comfort^{2,3} that can make a real difference in their lives, whether they are interested in full-time or part-time wear. Most importantly, patients need the opportunity to try DAILIES TOTAL1® Multifocal contact lenses for themselves. My patients, whether they are new or experienced contact lens wearers, are amazed by how comfortable DAILIES TOTAL1® Multifocal contact lenses are.^{2,3} In fact, the most common response I get from patients is that they feel like they are not wearing lenses at all. The 'wow' that my patients experience when they first try DAILIES TOTAL1® Multifocal contact lenses is priceless — for them and for me!

The 'wow' that my patients experience when they first try DAILIES TOTAL1® Multifocal contact lenses is priceless — for them and for me

All Alcon multifocal contact lenses, including DAILIES TOTAL1® Multifocal, are fit using the same 2-step process that supports high rates of fitting success and makes it easy to fit new wearers.¹⁰⁻¹² The combination of innovative lens technologies with a simplified fitting process makes DAILIES TOTAL1® Multifocal contact lenses

my go-to lens for presbyopic patients.

After recently fitting a patient who is an avid tennis player with DAILIES TOTAL1® Multifocal contact lenses, our office was promptly contacted by several of her teammates who wanted the same vision, comfort and convenience that their friend was experiencing on and off the court. The secret to success with DAILIES TOTAL1® Multifocal contact lenses is simple: tell patients about their unique benefits, use the easy fitting process and then let the lenses speak for themselves! By offering DAILIES TOTAL1® Multifocal contact lenses, we are giving patients exceptional vision correction, and helping to build our practice.



References 1. Lemp J, Kern J. Alcon multifocal contact lenses for presbyopia correction. Presented at the Canadian Association of Optometrists Congress, June 28-30, 2017. Ottawa, ON. 2. Kern J, Kannarr S, Miller JD. Clinical outcomes for Dailies Total1 Multifocal lens in symptomatic patients. Presented at the British Contact Lens Association Clinical Conference & Exhibition, June 9-11, 2017. Liverpool, UK. 3. Based on a survey of 544 presbyopic contact lens wearers. Alcon data on file, 2017. 4. Alcon data on file, 2008. 5. Alcon data on file, 2016. 6. Thekveli S, Qui Y, Kapoor Y, et al. Structure-property relationship of delectracon A lenses. *Cont Lens Anterior Eye*. 2012;35(suppl 1):e14. 7. Based on laboratory measurement of unworn lenses. Alcon data on file, 2011. 8. Angelini T, Nixon R, Dunn AC, et al. Viscoelasticity and mesh-size at the surface of hydrogels characterized with microheology. *Invest Ophthalmol Vis Sci*. 2013;54:E-abstract 500. 9. Based on published manufacturer-provided Dk and thickness values in: Tyler's Quarterly Soft Contact Lens Parameters Guide. June 2016. 10. Alcon fitting guide for multifocal contact lenses. 11. In established presbyopes, where n=27 for AIR OPTIX® AQUA Multifocal contact lenses and n=26 for DAILIES® AquaComfort Plus® Multifocal contact lenses. Alcon data on file, 2011. 12. Bauman E, Lemp J, Kern J. Material effect on multifocal contact lens fitting of lenses of the same optical design with the same fitting guide. Presented at the British Contact Lens Association Clinical Conference & Exhibition, June 9-11, 2017. Liverpool, UK.

Important information for AIR OPTIX® AQUA Multifocal (lotrafilcon B) contact lenses: For daily wear or extended wear up to 6 nights for near/far-sightedness and/or presbyopia. Risk of serious eye problems (i.e., corneal ulcer) is greater for extended wear. In rare cases, loss of vision may result. Side effects like discomfort, mild burning or stinging may occur.

See product instructions for complete wear, care and safety information. 

© 2017 Novartis 10/17 USD-DM-17-E-2644

Our passion is to help your patients see, look and feel their best.



Sponsored by

Alcon A Novartis Division



PRINTED IN USA

FOUNDING EDITOR, FREDERICK BOGER
1891-1913

EDITORIAL OFFICES
11 CAMPUS BLVD., SUITE 100
NEWTOWN SQUARE, PA 19073

SUBSCRIPTION INQUIRIES
1-877-529-1746

CONTINUING EDUCATION INQUIRIES
1-800-825-4696

EDITOR-IN-CHIEF • JACK PERSICO
(610) 492-1006 • JPERSICO@JOBSON.COM

MANAGING EDITOR • REBECCA HEPP
(610) 492-1005 • RHEPP@JOBSON.COM

SENIOR EDITOR • BILL KEKEVIAN
(610) 492-1003 • BKEKEVIAN@JOBSON.COM

ASSOCIATE EDITOR • CATHERINE MANTHORP
(610) 492-1043 • CMANTHORP@JOBSON.COM

ASSOCIATE EDITOR • MARK DE LEON
(610) 492-1021 • MDELEON@JOBSON.COM

SPECIAL PROJECTS MANAGER • JILL HOFFMAN
(610) 492-1037 • JHOFFMAN@JOBSON.COM

ART DIRECTOR • JARED ARAUJO
(610) 492-1032 • JARAUJO@JOBSON.COM

DIRECTOR OF CE ADMINISTRATION • REGINA COMBS
(212) 274-7160 • RCOMBS@JOBSON.COM

EDITORIAL BOARD

CHIEF CLINICAL EDITOR • PAUL M. KARPECKI, OD

ASSOCIATE CLINICAL EDITORS • JOSEPH P. SHOVLIN, OD;
ALAN G. KABAT, OD; CHRISTINE W. SINDT, OD

DIRECTOR OPTOMETRIC PROGRAMS • ARTHUR EPSTEIN, OD

CLINICAL & EDUCATION CONFERENCE ADVISOR
PAUL M. KARPECKI, OD

CASE REPORTS COORDINATOR • ANDREW S. GURWOOD, OD

CLINICAL CODING EDITOR • JOHN RUMPAKIS, OD, MBA

CONSULTING EDITOR • FRANK FONTANA, OD

COLUMNISTS

CHAIRSIDE • MONTGOMERY VICKERS, OD

CLINICAL QUANDARIES • PAUL C. AJAMIAN, OD

CODING CONNECTION • JOHN RUMPAKIS, OD

CORNEA & CONTACT LENS Q+A • JOSEPH P. SHOVLIN, OD

DIAGNOSTIC QUIZ • ANDREW S. GURWOOD, OD

THE ESSENTIALS • BISANT A. LABIB, OD

FOCUS ON REFRACTION • MARC TAUB, OD;

PAUL HARRIS, OD

GLAUCOMA GRAND ROUNDS • JAMES L. FANELLI, OD

NEURO CLINIC • MICHAEL TROTTINI, OD;

MICHAEL DELGIODICE, OD

OCULAR SURFACE REVIEW • PAUL M. KARPECKI, OD

RETINA DILEMMAS • DIANA L. SHECHTMAN, OD;

JAY M. HAYNIE, OD

RETINA QUIZ • MARK T. DUNBAR, OD

REVIEW OF SYSTEMS • CARLO J. PELINO, OD;

JOSEPH J. PIZZIMENTI, OD

SURGICAL MINUTE • DEREK N. CUNNINGHAM, OD;

WALTER O. WHITLEY, OD, MBA

THERAPEUTIC REVIEW • JOSEPH W. SOWKA, OD;

ALAN G. KABAT, OD

THROUGH MY EYES • PAUL M. KARPECKI, OD

URGENT CARE • RICHARD B. MANGAN, OD

JOBSON MEDICAL INFORMATION LLC



Outlook

By Jack Persico, Editor-in-Chief



No More Fun and Games

Digital device use is in the crosshairs of new efforts to curb myopia and protect the retina.

On August 29, the government of China took the unprecedented step of calling for limits on the sale and use of video games. The decision came from President Xi Jinping himself. The action—almost certainly an overreaction—came in response to the rise in myopia cases in Chinese children. According to a World Health Organization study cited by *China Daily*, myopia rates among Chinese youth are the highest in the world at 70% for high school and college students and nearly 40% for primary school students.

The goal is to reduce the incidence of myopia at least 0.5% per year. By 2030, the government wants the myopia rate to fall below 3% for six-year-old children, according to the plan. “It also suggests that less than 38% of primary students and no more than 70% of high school students should be wearing glasses by 2030,” states a report from China Global TV Network, a state-run news outlet.

Both educational and recreational activities that entail heavy near vision work have been cited in the literature on myopia pathogenesis. A recent study on participation in ‘cram schooling’ among Taiwanese children found a correlation with higher myopia. But the connection isn’t strong. “We’re not sure if it’s the near work that’s driving” increased myopia rates, pediatric ophthalmologist Aaron Miller, MD, told the *Washington Post*, “or what’s not happening because those individuals are doing near work.” Namely, time spent outdoors.

The Chinese regulations will be implemented by a number of government agencies, and parents are also encouraged to intervene and change behavioral norms. “All of society should take action to jointly protect the vision of children so that they can all have a brighter future,” Xi Jinping is cited in *China Daily* as saying. “The use of electronic products for non-learning purposes should not exceed 15 minutes and should not be more than one hour per day,” an official told *Bloomberg*.

As the parent of a young child, all I can say is: good luck with that.

Making myopia reduction a priority is, of course, an admirable goal. Maybe China’s authoritarian-leaning culture can pull off such an ambitious bit of social engineering. It’ll be fascinating to watch either way.

Western countries, meanwhile, are diving headlong into virtual reality gaming with perhaps too blasé an attitude toward its ill effects. Headsets like the Oculus Rift and Magic Leap are popularizing a radical new use of digital screens—strapping them an inch away from the eyes—that doesn’t get enough attention as a potential hazard.

This month’s cover story delves into that brave new world. Such devices place largely untested ver- gence demands on the oculomotor system, reduce the blink rates needed to preserve the tear film and bathe the eyes in blue light that could harm the retina. Optometrists would do well to be at the forefront of patient education on responsible use of this new visual experience before usage habits become ingrained. ■



TEST.



RESULTS.

Include The Bruder Moist Heat Eye Compress In Your Dry Eye Treatment Protocol

It's a fact. More and more doctors are testing their patients for evidence of dry eye. Not surprising. With the incidence of this chronic disease on the rise, early treatment is important.

Whatever treatment strategy you plan for your patient, it should include the Bruder Moist Heat Eye Compress – recommended by more doctors than any other heat compress.

The patented compress provides a clinically proven treatment that helps relieve dry eye symptoms while improving overall ocular surface health.

The Bruder compress is an effective dry eye treatment that your patient takes home between visits to your office. It's easily incorporated into your patient's daily routine, increases compliance, and provides quick relief.



#1 DOCTOR RECOMMENDED MOIST HEAT COMPRESS

Go to www.bruder.com/getresults-now to learn why more and more doctors are making dry eye an integral part of their practice. And why the 'Bruder Mask' is an important part of their treatment protocol.

VISIT US AT VISION EXPO WEST BOOTH #MS11034 TO LEARN MORE.



Narrow Focus, Wide Impact

Opportunities abound for ODs looking to add a specialty—now and in the future.

By Paul M. Karpecki, OD, Chief Clinical Editor

Adding a specialty to your practice helps you do more for patients in need while standing out in the community. The fastest growing one in optometry is dry eye, but ODs are also turning their attention to specialty contact lenses, vision therapy, low vision and myriad other niches. Here's what these opportunities can do for you.

What it Brings to the Table

First and foremost, adding a specialty provides enjoyment. You wouldn't specialize in an area if you didn't have a passion for the patients and the subject matter. We spend more time at work than almost any other sphere of life, so it's worth maximizing our enjoyment of it. As the saying goes, find work you enjoy and you'll never work a day in your life.

A specialty also brings in esteem and recognition. In this day of information on demand and social media, patients are looking on the internet for doctors who can help their condition and who specialize in the field. Finally, you're likely to see growth and success as your practice expands in all areas beyond the specialty. Dry eye patients, for example, may have other associated ocular conditions such as glaucoma, cataracts and contact lens wear issues.

Your Options

Dry eye centers are popping up everywhere, and 90% or more are run by optometrists. In the United States, there are an estimated 30 to 50 million people with dry eye dis-

ease, but only about 1.5 million are currently being treated with therapeutics.¹ We can help these patients dramatically today: advanced diagnostics such as osmolarity, MMP-9 testing and meibography can help us catch dry eye earlier and allow us to initiate treatment.

Once diagnosed, patients have pharmaceuticals available to treat dry eye, superficial punctate keratitis and flare-ups and treatments for obstructed meibomian glands, including lid debridement and highly effective hydrating compresses. For the biofilm that develops in almost all forms of dry eye disease, we have blepharoxfoliation and new lid scrubs.

Even our most basic therapies—artificial tears—are more advanced than ever. Other advances include 180-day dissolving punctal plugs, neurostimulation and omega fatty acids with GLA/EPA/DHA. Dry eye specialty clinics are now packed with myriad treatment options to help every patient, no matter their clinical signs and symptoms.

Retina is another specialty opportunity to better serve a large patient base. Age-related macular degeneration (AMD), for example, is similar to dry eye in its prevalence: likely to double in the next decade or two. As with dry eye, tools now exist for early diagnosis, such as dark adaptometry, better imaging with optical coherence tomography and better monitoring technology. Even multiple treatment options exist such as nutritional supplements with carot-

enoids, AREDS formulations for intermediate AMD, spectacle lenses that block high energy visible light, anti-VEGF injections for wet AMD and even intraocular implants for advanced AMD.

Low vision is another key player in advanced AMD therapy—and an entire specialty for some practices. In fact, any patient not correctable to 20/20 might benefit from a low vision intervention.

Patients with diabetic retinopathy (DR) also benefit from doctors who can better communicate among the professions (e.g., endocrinologists, primary care providers, retina specialists), monitor appropriately and refer should proliferative DR signs or diabetic macular edema present.

Almost every aspect of optometry stands as a potential specialty for your practice: glaucoma, vision therapy, contact lenses, pediatrics—the list goes on. If you select an area of particular focus, take the time to educate yourself extensively. Visit other doctors who already specialize in the field—work with a retina group if you want to focus on patients with diabetic retinopathy, for example—join societies specific to that area and gain extensive experience.

Any area of eye care with a substantial need can be an important focus that will differentiate your practice, enhance your day-to-day enjoyment and help countless patients. ■

1. Steinberg et al. *Equity Research Americas*, May 18, 2017:1-38.

YOUR CAMPAIGN YOUR SUPPORT



Think About Your Eyes drove **3.4MM incremental eye exams** and **\$752MM in incremental industry revenue** in 2017.

These industry leaders make the campaign a reality, and to keep it going, they need your support. Show them your appreciation, and encourage other companies you do business with to join the campaign.

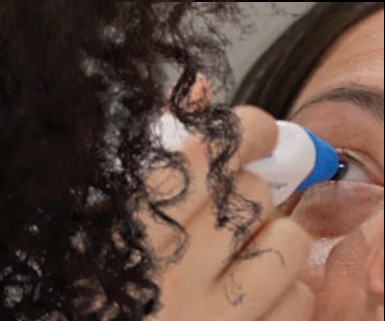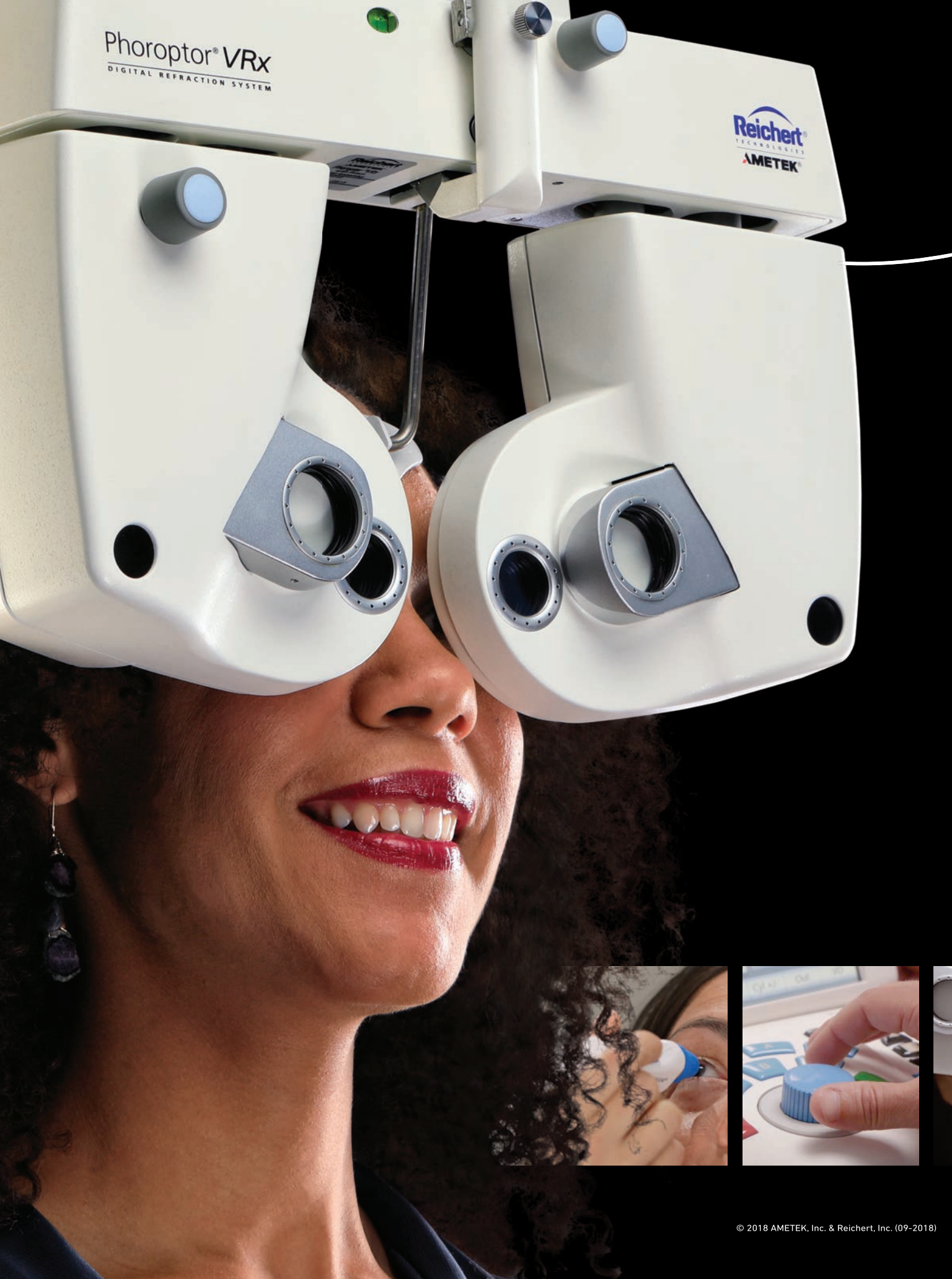Think About your Eyes can get even bigger and more impactful with your help.


thinkabout
youreyes.com

Brought to you by the AOA
AMERICAN OPTOMETRIC ASSOCIATION

Phoroptor® VRx
DIGITAL REFRACTION SYSTEM

Reichert®
TECHNOLOGIES
AMETEK





Passionate About Eye Care!

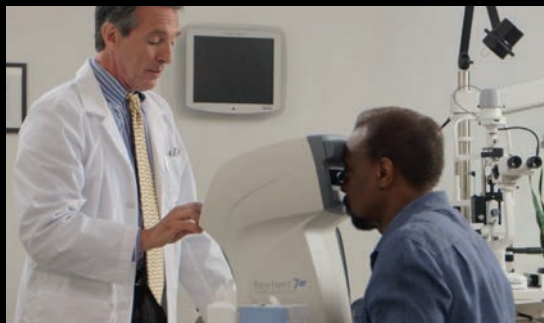
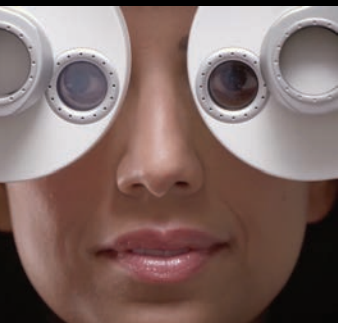We share your **passion for patient experience** with our complete line of digital refraction devices, featuring Phoroptor® VRx.

We also share your **passion for patient care** with our innovative glaucoma diagnostics, featuring Ocular Response Analyzer® G3 with Corneal Hysteresis.

SEE AMERICAN INNOVATION IN DIAGNOSTICS: VISION EXPO WEST #MS9043



reichert.com/visionexpo



The Softer Side of Vickers

Just kidding—these poems are brutally honest.

By **Montgomery Vickers, OD**

I haven't had time to write poetry since I moved to Texas, and everyone who knows me knows just how much poetry means to me.

Quit laughing, I am serious. As an example of my passion, here are a few of my recent poems:

Ode to My Staff

Thank you for the things you do.
Thank you for what you don't do.
It's too bad I need to let you go,
Because of what you won't do.

Your Lens

These are your lenses we have made for you.
If you can't see, why'd you choose
Number one instead of number two?

Bumps

There are bumps on your eyelid
That don't mean a thing.
There are bumps on your eye
That make your eyes sting.
Bumps in the day and bumps in the night
All you know is something ain't right.
So you try every eye drop they sell at the store,
And when those don't work you try even more.
You soak it and rub it and nothing will work.
Then you call me on Sunday, you lousy jerk!

My Glasses

"Where are my glasses?" you asked with a grin.

"You told me they'd be here but never said when."

"I'm leaving for Holland on the very first plane."

There's a problem at the lab and let me explain.

Something was broken and the order was lost.

The lab'll work on it, no matter the cost.

So please just be patient. They'll be here soon.

Maybe next May, but probably next June.

My Retinal Haiku

Sunny nowadays
A sighted, blurred eyeball sees
Nothing but floaters

Your Kid's Eyes

Your kid can't see,
That's what I say
But you're on your phone
Just texting away.
Please turn it off and put it down
Before I stomp it to bits
On the cold, hard ground.

Online

So you want your prescription
To buy it online.
OK by me if
you think it's fine

To stare at computers

And then feel the strain,

To feel like puking again and again,

To rub your eyes all day long,

To do your work and get it all wrong.

Don't give me low reviews for goodness's sake

When *you* are the fool that made the mistake!

Final Thoughts

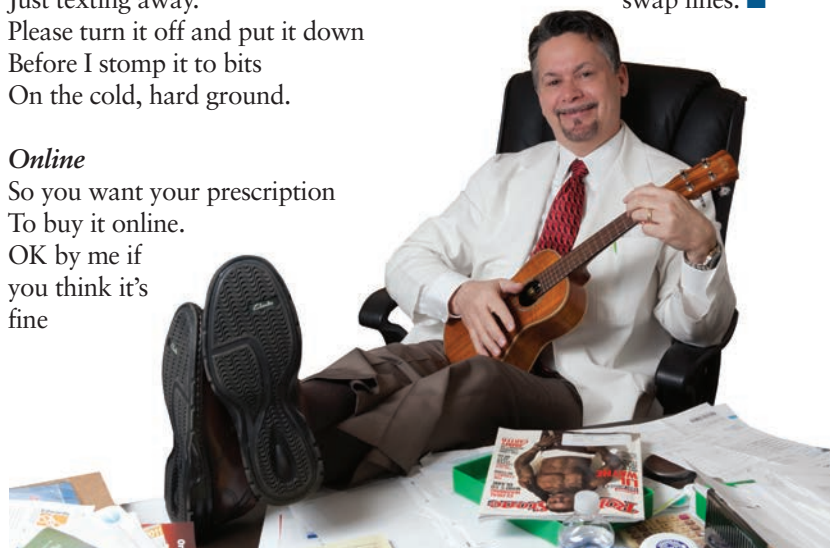All that we do, we do for love.

To protect your sight, a gift from above.

We are not perfect. We won't try to be.

But what you get is what you can see.

That last one really had me tearing up. Writing poetry can be a great release—maybe you should give it a try. Just don't track me down to swap lines. ■





Mission: Uncorrectable

When a patient can't achieve 20/20 vision, give it your all to find a solution.

Edited by Paul C. Ajamian, OD

Q I have a one-month post-op cataract patient who told me on two successive visits that something was wrong with the vision in the right eye. The anterior segment was normal, and best-corrected acuity 20/25+1. What's next?

A During the course of a busy day, it's easy to ignore slightly reduced visual acuity. "Don't," emphasizes Dr. Ajamian, Director of Omni Eye Services of Atlanta. "Any time patients tell you there is a change in vision, investigate." Refract carefully and document that you dilated the patient to come up with an answer. Doing so will protect yourself from legal consequences.

Dr. Ajamian has consulted on a number of cases over the years where doctors got into hot water by not taking vision loss seriously.

Front to Back

Dr. Ajamian advises a methodical sweep of the eye from ocular surface to optic nerve. First, look at the cornea. With such small acuity loss to account for, the cause could be dry eye, map-dot-fingerprint dystrophy or other forms of ocular surface disease. Even if the slit lamp exam of the cornea appears normal, don't forget to look at the topography.

Though you need to keep an open mind when investigating, stick with the most plausible scenarios first. Dr. Ajamian says he's seen well-meaning clinicians order MRIs to try to explain reduced acuity, but something simpler and cheaper like topography would suffice. Especially in a post-surgical patient,

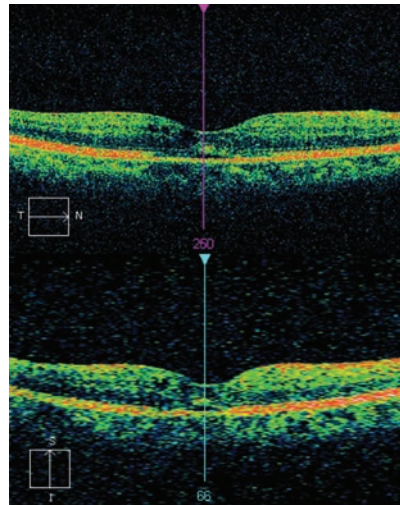


Fig. 1. This macular OCT scan demonstrates increased average thickness OD, confirming a thorough search.

you may encounter some induced astigmatism. "Even if topography is normal, consider the 'hard lens trick' that has rescued me many times," adds Dr. Ajamian. Put a trial hard lens on the eye and over-refract; if the cornea was the issue, vision will return to 20/20.

Next, make sure both the anterior and the posterior chambers are clear. Carefully examine the crystalline lens—or, in the case of a pseudo-phake, the posterior capsule—using direct illumination, as well as retroillumination off the fundus. Milky nuclear sclerosis is the only cataract that can cause confusion because of the disparity between the clinician's view in (clear) and the patient's view out (reduced).

The fundus should be the next area of concern, and a dilated stereo exam using a 78D or 90D lens

is the best way to rule out issues here. It affords you a more accurate look at elevation, cup-to-disc ratios and other essential elements of a fundus exam.

Optic nerve damage can also cause vision loss, so practitioners should not forget to look for cupping, pallor and nerve fiber layer loss such as wedge defects. Check optic nerve function by carefully ruling out an afferent pupillary defect and perhaps evaluate color vision. Visual fields and electrodiagnostic testing will be useful in many cases.

Every patient that cannot read the 20/20 line needs an explanation or a plan to explore the issue further. That plan may be as simple as having them follow up in a week or two to retake acuity. Not everyone is at their best every day, and subjective acuity is variable. "Keep in mind the visual axis, examine carefully all the structures in its path and you will be able to explain the unexplained in most cases," says Dr. Ajamian. "If you can't, document your concern and get specialty help when needed."

Unmasking the Culprit

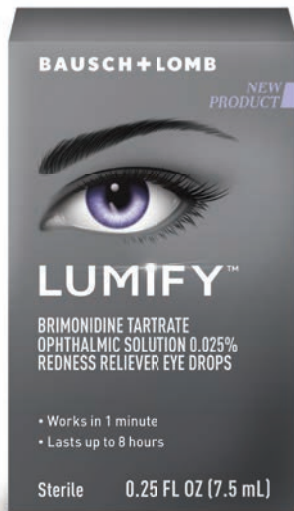
"Our patient insisted that something wasn't right, and we dilated and saw what appeared to be early cystoid macular edema," says Dr. Ajamian. A macular optical coherence topography scan confirmed this, and the patient was started on a topical nonsteroidal anti-inflammatory drug BID and prednisolone acetate 1% QID for at least six weeks (Figure 1). Any delay in treatment could have spelled disaster." ■

NEW!

LUMIFY™


BRIMONIDINE TARTRATE OPHTHALMIC SOLUTION 0.025%
REDNESS RELIEVER EYE DROPS

A NEW REDNESS RELIEVER LIKE NO OTHER:



- The first and only OTC eye drop with low dose brimonidine tartrate (0.025%)
- Strong safety and efficacy profile with no tachyphylaxis and virtually no rebound redness in clinical trials
- Starts working in 1 minute - lasts for up to 8 hours

LUMIFY redness reliever eye drops are available at national retailers in 2.5 mL and 7.5 mL sizes.



Images representative of clinical trial results, individual results may vary.

Introduce your patients to a new kind of redness reliever.

Learn more at lumifydrops.com/professional
To sell LUMIFY in your office, call 1-800-828-9030.

LUMIFY is a trademark of Bausch & Lomb Incorporated or its affiliates. © 2018 Bausch & Lomb Incorporated. PN08878 LUM.0193.USA.18

FROM THE EYE CARE EXPERTS AT **BAUSCH + LOMB**



True Colors

Diagnosing and monitoring ocular disease isn't always black-and-white.

By Bisant A. Labib, OD

Color vision testing is a staple to screen for congenital color vision defects; it's also helpful to detect or monitor disease progression in patients with various neuro-ophthalmic conditions. Often, a color vision test can be a cost-effective and readily accessible technique to identify and monitor certain ocular diseases and enable earlier intervention.

The Options

Color vision tests are comprised of two categories:¹

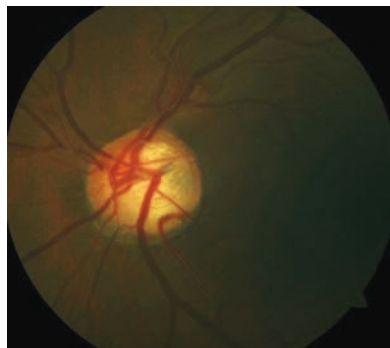
Pseudoisochromatic plates, such as the Ishihara and Hardy-Rand-Rittler tests, distinguish between the different types of dichromatism, such as protanopia and deuteranopia (red-green), or tritanopia (blue-yellow).^{1,2} Widely available, inexpensive and easy to perform and interpret, these are the most commonly used color tests in clinical practice.^{1,2}

When clinicians use color plate testing, they should record not only the number of plates identified but also the speed in which the patient identifies the plates.⁴

Color arrangement tests, such as the Farnworth-Munsell 100 hue test, involve patients categorizing colored objects with a fixed chroma in sequential order.¹ While providing more detail and a higher sensitivity, they are more time-consuming.^{1,2}

The Nerve

Because color discrimination is mediated through cones that absorb



POAG may create blue-yellow color vision defects.

light stimuli and transmit that sensory information to the optic tract and, ultimately, the occipital cortex, the optic nerve is sensitive to changes in color.³ Thus, defects in the optic nerve or photoreceptors can alter color perception, leading to dyschromatopsia. Optic nerve disease will affect color vision more so than any other disease.²

In a study evaluating color vision defects in the presence of optic neuropathies, macular diseases, media opacities and amblyopia, preserved visual acuity (VA) with loss of color vision was strongly correlated with optic neuropathy. While profound vision loss in macular disease and amblyopia also leads to reduced color vision, this is likely due to the poor VA and trouble identifying the color plates.²

In patients with primary open-angle glaucoma (POAG), color vision defects are more likely to affect the blue-yellow spectrum. Often, color deficits will present prior to a visual field defect. As a

result, color testing may be beneficial in monitoring ocular hypertension patients and their probability of developing glaucoma. Because the color deficiency progresses as glaucomatous damage does, it can also offer a quantifiable measurement of retinal ganglion cell damage.³

A New Use

Color vision testing may also be an inexpensive alternative to optical coherence tomography (OCT) for diabetic macular edema. Studies using the Farnworth-Munsell 100 hue test uncovered blue-yellow defects in diabetic patients, and researchers have developed a computerized color vision test that shows promise. It reveals a correlation between the degree of color vision abnormality and macular thickness volume on OCT.⁵

Color vision screening can offer great clinical insight on disease identification and progression. While it is sensitive to optic neuropathies, it may also show future promise in the detection of macular diseases. As such, optometrists should not overlook this valuable tool. ■

1. Zhao J, Davé SB, Wang J, et al. Clinical color vision testing and correlation with visual function. *Am J Ophthalmol.* 2015;3(140):547-52.

2. Almog Y, Nemet Y. The correlation between visual acuity and color vision as an indicator of the cause of vision loss. *Am J Ophthalmol.* 2010;149:1000-4.

3. Papaconstantinou D, Georgalas I, Kalantzis G, et al. Acquired color vision and visual field defects in patients with ocular hypertension and early glaucoma. *Clin Ophthalmol.* 2009;3:251-7.

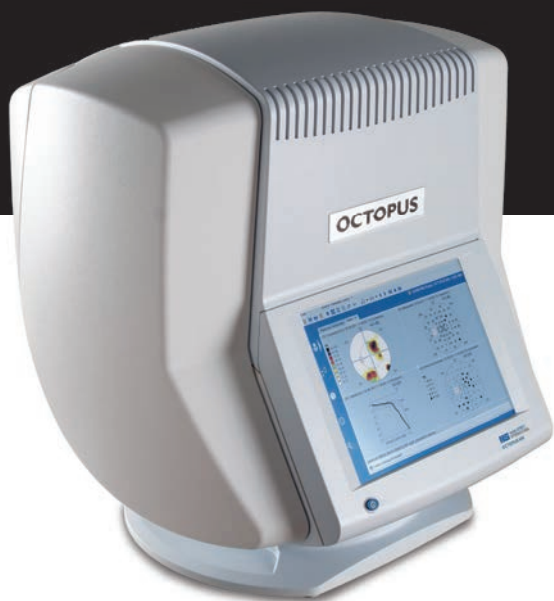4. Behbehani R. Clinical approach to optic neuropathies. *Clin Ophthalmol.* 2007;1(3):233-46.

5. Shin YJ, Park KH, Hwang JM, et al. A novel color vision test for detection of diabetic macular edema. *Invest Ophthalmol Vis Sci.* 2014;55:25-32.

Visit us at
**Vision
Expo West**
Booth #MS10043

OCTOPUS 600.

YOU'LL DETECT A DIFFERENCE RIGHT AWAY.



Reach threshold in just 2.5 minutes with the fast, accurate TOP strategy.

With the Octopus 600, the differences start with TOP, an exclusive strategy that maximizes patient compliance and minimizes chair time with thresholds in a blazing 2.5 minutes. Our Pulsar stimulus detects glaucomatous changes far earlier, and true fixation control eliminates bad data due to fixation losses, while EyeSuite allows you to look at it all with a click of a button.

Learn more at HSoctopus.com.

800.787.5426
HSoctopus.com

© 2018 Haag-Streit USA. All Rights Reserved.

 **HAAG-STREIT
USA**



Playing with Fire: OCT-A Coding

Know the reimbursement rules before you invest.

By John Rumpakis, OD, MBA, Clinical Coding Editor

In today's world of outcome-based care and intense scrutiny of medical necessity for clinical testing, questions of reimbursements and subsequent economics have become integral when considering purchasing or leasing a new piece of diagnostic equipment. They may be just as important to consider as whether or not the new technology will improve patient care.

It's better to know in advance how to code specific procedures, and what you can and cannot bill for when buying new equipment; guessing after the fact can get you into trouble.

Fueling the Flames

As an example, let's look at the somewhat recent release of optical coherence tomography angiography (OCT-A). When this technology was first introduced in the literature in 2008, it was recognized as a groundbreaking diagnostic device for the earlier detection of disease and more effective management of disease states.¹ The first OCT-A instrument became commercially available in the United States in September 2015 and has the potential to replace intravenous dye-based angiography for most macular diseases.

As with any new technology, most clinicians have a strong desire to incorporate the latest and greatest into their practice. This is where the "reimbursement noise" starts to hit the chat rooms and blogs—clinicians begin informally discussing ways to bill for the new diagnostic tests. Unfortunately, most of the rhetoric

in these forums is not factual; it's simply the result of creative billing by many to enhance reimbursements. This, of course, is driven by the higher cost of the new technology and the desire to reach the break-even and profitability curve more quickly.

On a popular OD website, one clinician recommended that ODs bill OCT-A as follows:

- 92134 – (regular OCT of the retina)
- 92499 – Enhanced angiography portion of OCT

Many who follow this website believed this was a legitimate way to bill for OCT-A and were quite happy with the increased reimbursement they received, even if the additional portion was being paid by the patient. Positive stories and feedback on this post fed the flames, and the behavior soon became common.

Extinguish the Hype

This coding path had a major flaw. The American Medical Association publication of the CPT clearly defines the coding of OCT-A to be exactly the same as coding for OCT: 92134. This code alone is the proper way to code the procedure—no enhancements or embellishments, and no increased reimbursement.

The February 2011 *CPT Assistant* discusses CPT 92134: "For the posterior segment, two distinct areas are imaged using the new technology, the optic nerve and the retina. The evaluation of the images differs. Consequently, codes 92133 and 92134 have been added to report

scanning computerized ophthalmic diagnostic imaging of the optic nerve and retina, respectively [...] Code 92134 describes scanning computerized ophthalmic diagnostic imaging of the retina."²

Furthermore, local coverage determinations by CMS regional carriers also provide guidance and acknowledge that using CPT code 92134 is appropriate for OCT-A. Using any additional codes is duplicative, inappropriate and unwarranted.

This reimbursement issue clearly affects the decision-making process when acquiring new technology in a practice. While you may not like it, this is the prevailing rule as of today, and upcoding this procedure to a carrier or, worse yet, charging it to the patient is problematic for a multitude of reasons that can all lead to greater audit exposure and monetary fines. If you are coding and billing a procedure with the knowledge that you are doing so incorrectly, that is tantamount to doing so with intent and is thus considered fraud, not waste and abuse; fraud convictions are generally criminal, not civil.

Knowing the rules is paramount, not only when crunching the numbers to justify purchasing a new and exciting diagnostic tool but when considering its day-to-day use as well. ■

Send questions and comments to rocodingconnection@gmail.com.

1. Fingler J, Readhead C, Schwartz DM, Fraser SE. Phase-contrast OCT imaging of transverse flows in the mouse retina and choroid. *Invest Ophthalmol Vis Sci*. 2008;49(11):5055-9.
2. American Medical Association. *CPT Assistant*. February 2011. https://commerce.ama-assn.org/store/catalog/productDetail.jsp?product_id=prod1170021.

Visit Katena
in Booth
MS9048
Vision Expo West
2018

Extraordinary view - Great price!

Diamond series ophthalmic lenses

Exceptional optics

- Anti-reflective coating
- Low distortion & high resolution
- Superior small pupil performance

Ergonomic, durable design

- Lightweight construction
- "Sure Grip" handling ring
- Evaporated diamond hard coating (scratch resistance)

NEW!

Contact lenses: \$150.00 per lens

Diagnostic lenses



K31-1002
3 mirror*



K31-1005
4 mirror*

Diagnostic & laser lens (PRP)



K31-1330
Retina 200

Bi-aspheric non-contact lenses: \$125.00 per lens

Diagnostic lenses (slit lamp)



K31-2360
60D



K31-2355
78D



K31-2350
90D

Diagnostic & laser lenses



K31-2370
20D



K31-2365
28D

katena
DESIGNED FOR SIGHT®

800-225-1195 • www.katena.com

*3 mirror and 4 mirror lenses do not require anti-reflective or evaporated diamond coatings



Retool Your Office Tech to Boost Efficiency

These tips can help you get more out of EHR, patient communication tools and new diagnostic devices. **By Brian Chou, OD**

With more business threats emerging by the day—including online ophthalmic product sales, remote vision testing, greater regulatory burden, increasing costs and the deluge of new OD graduates—it is more important than ever for optometrists to get the most out of their practice.

The first step is resourcefully finding the most efficient office workflow, which could include everything from spending money on the greatest bang-for-the-buck to reducing wasted motion, eliminating double entry of data and ensuring staff productivity. Using new technology, such as electronic health record systems (EHRs) and new diagnostic devices, can help.

Two decades ago, optometrists were regularly using paper records, manual keratometers, direct ophthalmoscopes and rigid contact lens polishing units. While these aren't extinct, they are well on their way to joining tangent screens and Schiottz tonometers in the optometric boneyard. Doctors are now bringing new diagnostic technology—such as meibography, specular microscopy, optical coherence tomography angiography (OCT-A), fundus autofluorescence imaging, pattern electroretinogram (ERG) and macular pigment optical density—into their practice for a multitude of reasons. These new technologies can improve the medical care, create a new revenue stream, elevate the patient experience or enhance efficiency, or a combination of all of these.

But sometimes the most important technology has nothing to do with diagnostics. An office management system is often at the heart of today's optometric

practice, and it can make or break the experience for patients, clinicians and staff alike. Let's take a closer look at how newer technologies can boost practice efficiency and keep your practice booming.

Proceed with Caution

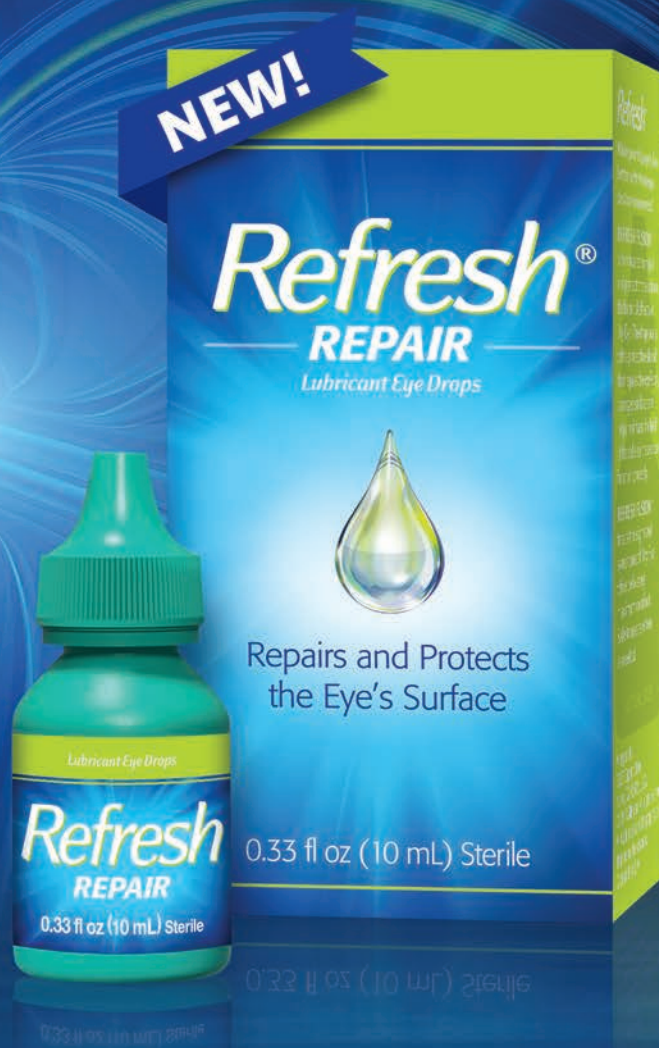One of my former practices offered patients ultra-widefield retinal imaging, macular pigment density measurement and retinal nerve fiber analysis—all advanced technology, even by today's standards. Each measurement was offered to patients for an additional fee during preliminary testing. However, patients balked at having to elect these "a-la-carte" services at a high price, which inevitably caused operational inefficiency.


In retrospect, the fallacy was that this approach created choice overload for the patient; they felt they were being pressured and nicked-and-dimed. The patient had to discern what was unnecessary and what had compelling value for their health, burdening staff and doctor time that could be better spent elsewhere. Asking the patient to choose whether to have three additional tests created eight different permutations of selection and caused an inconsistent workflow and more errors when charging the patient.

As this example shows, advanced diagnostics alone are not enough; they must also be orchestrated well. When multiple elective tests exist, consider bundling them together rather than having your staff sell each one individually. Alternatively, build them into your exam at no additional fee. Removing patient choice

INTRODUCING
REFRESH[®] REPAIR

The first and only artificial tear in the U.S.
formulated with CMC, HA,* and Osmoprotectants.



REFRESH[®] REPAIR helps promote healing of the cornea and conjunctival epithelia and improves visual performance in Dry Eye patients. Safe to use with contacts. 

refreshbrand.com/doc | 

 **Allergan.**

*HA is an inactive ingredient.

© 2018 Allergan. All rights reserved. All trademarks are the property of their respective owners. REF115212 05/18

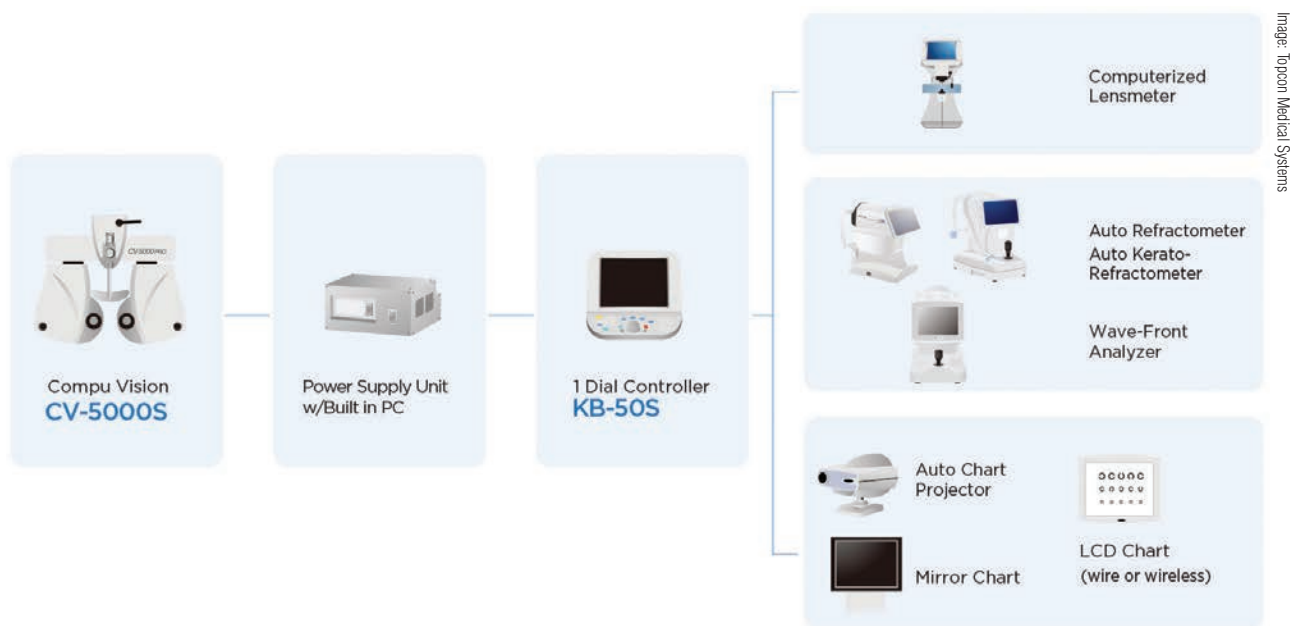

Image: Topcon Medical Systems

Fig. 1. This chart shows communication between various instruments in an automated refraction system.

inherently creates greater efficiency with fewer moving parts that can fail.

My current practice, for example, provides digital retinal imaging and fundus OCT for all patients during their routine examination for no additional cost. This creates consumer surplus and elevates their level of care with absolute consistency. The resultant efficiency means I can spend more time discussing the results and giving treatment recommendations. Although across-the-board retinal imaging and OCT are novel, I believe it will eventually become commonplace, if not standard in our industry.

Repetition = Opportunity

Futurists have projected that artificial intelligence and robots will one day take away jobs. If this becomes a reality, the consensus is that the most exposed jobs are those that are “routine, repetitive and predictable.”¹ In the same way, tasks within the optometric practice that fit such a description arguably present the greatest opportunity for using EHR and new diagnostic technology to bring greater efficiency.

Thinking through the patient cycle can help you identify several such opportunities, from scheduling and appointment confirmations to patient in-take and case history, preliminary exam measurements, the examination, prescription fulfillment and ordering, billing and collections and post-encounter administration such as delivery notifications and surveys.

System Check

The backbone of any modern optometric practice is the computerized system for recording patient demographic information, scheduling, payment history and exam findings. Today, with more than 40 EHRs available in our industry, optometric practice owners have many choices to pattern their workflow. Which EHR to use is a critical, but rarely easy, decision. Each EHR requires a significant investment in time and money for training and implementation.

After using four different EHRs extensively, I know first-hand that the wrong EHR can create massive inefficiency, but the right one can boost efficiency. The EHR in my previous practice (implemented by a private equity-funded consolidator) tripled the number of mouse clicks required to complete an examination. A poorly matched EHR gratuitously hinders your ability to interact with the patient, forcing you to increase your level of interaction with the computer instead. Conversely, efficient technology frees up more time you can spend with your patient.

If you’re searching for the right EHR, one place to start is rating and review websites, including ehrcompare.com, created by two optometrists, Adam Parker, OD, and Kevin Lafone, OD. You can also narrow the list of potential systems further by speaking with vendors and colleagues, visiting exhibit hall displays and trialing versions of their software to evaluate the functionality and ease of use.

THE INTELLIGENT TONOMETER

icare
HOME

THE PATIENT
CHOICE



icare
ic100

THE PROFESSIONAL
CHOICE

VISIT VEV 2018 **BOOTH #MS7045** FOR **SHOW SPECIAL!**

Learn more: info@icare-usa.com or www.icare-usa.com

Another important consideration is evaluating the list of instruments with which your desired EHR can integrate.

Create the Perfect Network

Once you have an EHR system in place, you'll be able to interface with certain diagnostic instruments, whether they are existing instruments or those you acquire over time. Interfacing for tasks that are repeated frequently, such as lensometry and refraction, is a significant time-saver. An interfaced automated refraction system is particularly valuable because refraction is crucial to every comprehensive exam and requires a significant amount of data exchange. By comparison, while non-contact tonometers can also be interfaced with EHR, there is less value in doing so. IOP can be recorded with just one value per eye, while refraction has three values (sphere, cylinder and axis). With an integrated, automated refraction system, for example, the autolensometer measures the glasses prescription and then transfers the data to the EHR, automatically populating the sphere and cylinder values into the appropriate fields. If you have a complete automated

What Hurts Can Also Help

Because most optometric practices still heavily rely on mercantile sales for revenue, it's no surprise many optometrists are unhappy when patients fill their glasses and contact lens prescriptions elsewhere, including warehouse and online stores. But optometrists shouldn't be so quick to shun these resources—they may offer other opportunities to save and promote efficiency.

Many practice owners save time and money by purchasing their business supplies online and from warehouse stores. You can also tap into this third-party vendor system by hiring freelancers for graphic design, website and app development, digital marketing and on-hold telephone voice-overs, to name just a few. Most vendors have adapted to allow business owners to order or troubleshoot online, reducing time spent on hold waiting for service.

While online patient ratings and reviews can strike a nerve with some clinicians, they can be invaluable when researching services that your business may need.

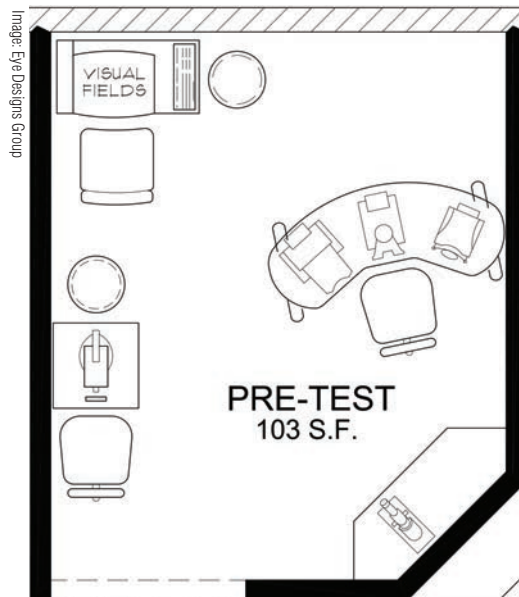


Fig. 2. A proposed layout of diagnostic instruments in a pre-test area. Space planning can optimize function and flow.

refraction system—autolensometer, autorefractor, digital phoropter and digital visual acuity chart—all of the instruments can interface with each other and the EHR (Figure 1).

My new practice has a complete automated refraction system where the digital phoropter receives readings from both the autolensometer and the autorefractor. The lensometer, autorefractor and manifest refraction are all transferred from the digital phoropter, which acts as a hub, to the EHR through an instrument interface. Like many other optometrists, I have found this increases my efficiency by reducing the amount of time needed to record measurements, all while also eliminating transcription errors and significantly

improving consistency.

“Arguably the most powerful use of efficiency with regards to EHR is to have your software integrated with an automated refraction system, along with the peripherals like an autorefractor/keratometer and automated lensmeter,” said Scott Shone, president of Ophthalmic Instruments, an independent dealer of ophthalmic instruments, in an interview. “To be able to test a patient with the autorefractor and autolensometer in the pretest room, press a button and have that data transmitted to the automated refraction unit in the exam room is a tremendous time saver.”

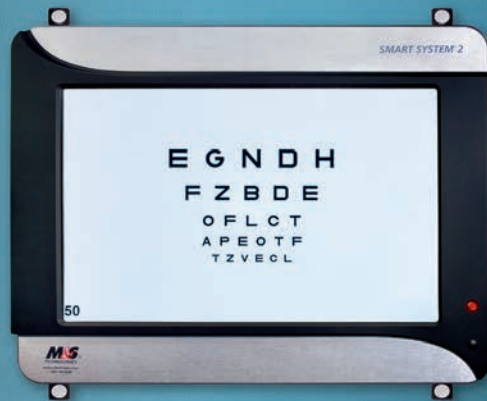Having such a set-up also allows the OD to “instantly compare the patient’s old Rx with their new prescription,” he says. Customized programs can include the full 21-point exam or any other refracting procedure you prefer. “The icing on the cake,” Mr. Shone says, is that once completed, the refraction, previous Rx, new Rx, automated reference data and so on can all be downloaded into the EHR program. “Not only does the information send over in a matter of seconds, but this eliminates any transcription errors as well.”

Plan Your Space

The list of pre-exam measurements requires careful thought, as does the layout of diagnostic instruments. Ideally, the patient should not have to sit down and stand up multiple times. Because all of my patients

Visit us at
VEW 2018!

Booth
MS11039



Give your
patients
the best

Call today
1/847-763-0500



Learn more about the Visual Acuity Testing System which includes the best USA-based customer service and technical support in the industry!

Learn more at:
mstech-eyes.com/ebook/ssebook.pdf

SMART SYSTEM[®] 2 | 2020

ACCURACY • RELIABILITY • REPEATABILITY

See how the **Smart System[®] 2** technology enables increased quality of care, streamlines exams and improves engagement with your patients at every level.

Over 50 different Vision Tests, including VA, contrast, stereopsis, binocular balance and color vision.

Near, Intermediate and Distance Testing

DVD Functionality allows the user to play DVDs directly providing immediate fixation on retinoscopies.

Patient Education includes 26 pre-loaded patient education images with the flexibility for additional images and videos

Internal Marketing allows you to load PowerPoint slides, images or videos to promote your practice and educate your patients.

LEA SYMBOLS[®] & LEA NUMBERS[®] is the standard in pediatric vision testing.

M&S[®]
TECHNOLOGIES

The First Choice in Vision Testing Systems



M&S holds US Patents 7,354,155; 7,926,948; 8,425,040; 8,167,429; 8,419,184 & 8,550,631. Other Patents Pending.

Toll Free: 877-225-6101
mstech-eyes.com

undergo automated perimetry, autorefractometry, fundus photography and retinal OCT, these instruments are all on the same instrument table, allowing sequential capture while the patient remains seated throughout the process. The autolensometer is placed on a fixed-height table since this does not need to raise or lower to accommodate the patient's height. Automated perimetry is done before fundus photography so that the photographic flash does not cause an afterimage that can confound the visual field measurement. Meanwhile, my topographer is placed on its own instrument table because only certain patients require this measurement, thereby minimizing the burden on patients.

Admittedly, there is an advantage to building a new facility, since patient traffic flow can be streamlined, and electrical and cabling needs can be planned from the start, rather than retrofitting an existing space, which may pose more limitations. This is where a space planner that works within the eye care industry can be immensely helpful. They can produce drawings that will help you plan how to place your various instruments to maximize efficiency and patient flow (*Figure 2*).

For optometrists who have limited space within their practices, combination units are often a wonderful option. For example, my previous practice had a combined autorefractor, autokeratometer and a non-contact tonometer. This space saver was highly efficient for my prior workflow, especially considering it also integrated with the EHR.

Instrument distributors can be a valuable resource due to their familiarity with a cross section of instruments by different manufacturers, and they often know everything about each instrument's speed and integration capabilities. Such knowledge can help you make the right choices when shopping for new equipment to integrate into your practice.

Secondary Interfaces

In the previous decade, many eye care EHR manufacturers concentrated their development efforts on allowing users to qualify for federal incentives. Unfortunately, many EHRs at the time lacked desirable functionality for communicating with patients and delivering desired practice metrics.

To provide these functions, a cottage industry of secondary software interfaces that transferred data out of the EHR databases into their software systems sprung up. Today's patient communication software—customer relationship management systems—allow appointment reminders, exam recalls, surveying, marketing and so forth through e-mail, text and phone

Call Them, and They Will Come

By Kevin Henne, OD

When adding technology to our practices, we've probably all been guilty of seeing nothing but another monthly payment, for which we will have to sell services and change our routines to recover the monthly expense. We always need to evaluate our practice patterns before a major purchase, but we also need to contemplate a host of other cost concerns, such as principal and interest, buying vs. leasing, property tax implications, Americans With Disabilities Act credit considerations, depreciation, service contract options, property taxes and longevity of both the instrument and the technology's relevance.

We can't become bogged down by the paralysis of analysis—it's one of the main reasons a practice can stagnate after 15 to 20 years. I was guilty of not investing in new technology at the rate I should have been because I thought I didn't want to be paying off expensive equipment late in my career. But paying off expensive equipment is easier when you are excited about the improved care it provides. It's also easier when you have a thriving, not withering, patient base.

Upgrade and Explode

ODs often cite a lack of patients as an excuse for not investing in their practice—but optometrists don't do a very good job of recalling the patients they do have, either. If you are still sending recall cards, calling patients by telephone or pre-appointing, you are in the dark ages.

In today's high-tech practice, a patient communication software program is a must. In my own practice, finally investing in one caused a significant overnight jump in patient load. In my 35+ years in practice, this is the single greatest surprise—and the best thing I have ever done in practice. It is relatively inexpensive, and I believe you will recuperate the monthly subscription fee in the first two hours of each month that you use it. In addition, you can keep patients connected with your office without spending your staff's valuable time.

Keep the Ball Rolling

Most ODs add additional equipment, such as visual fields, topographers, OCT and retinal cameras, all in the name of better patient care, but you have to have patient flow to justify these expenditures.

This is why the patient communication system was the lynch-pin for my practice. Once I had the patient flow, I was able to delegate more of the actual data collection to my staff, giving me time to evaluate the data and ensure everyone was working to their highest level of training. It also has allowed me time to discuss examination findings with patients in greater detail and explore other topics related to their care such as contact lenses, nutritional supplements and ocular health such as glaucoma and cataracts.

You can't see patients if they don't make appointments, and you can't add services if you don't have patients. It's all connected. Adding technology can be the single most important improvement you make to your practice—as long as you add the right technology. For my practice, an improved communication tool made all the difference.

voice messaging. Other secondary platforms can help you gather practice management metrics, which can make a big difference when looking to implement data-driven business decisions. All these operations facilitate efficiency and reduce the burden on staff of having to pull charts and call patients.

More EHR companies are now developing their software to incorporate the functionality previously handled by these patient communication software and business dashboard systems—a welcome trend for practicing optometrists. For example, some EHRs now include patient portals that give patients the convenience of completing registration forms online before their appointment or upon arrival to the office using a workstation or tablet. The staff can then transfer the patient’s data directly into the electronic record. According to Carlos Rivero, regional account manager for My Vision Express (Insight Software), this “reduces the double data entry by the staff to enter demographic and health history information into the system.”

Many EHRs now also include patient communication modules that permit online patient scheduling and other patient communication functionalities, such as text and email appointment reminders, recall, optical status and birthday messages. Some may even include automated communication to patients who have not been in for an annual exam in the past 12 months and do not have active recall or an appointment scheduled in the system.

A Team Approach

When technology is used properly, it can tackle repetitive tasks to reduce their burden. In optometric workflow, achieving high efficiency is a customized endeavor that requires careful implementation of the right EHR for your needs. From there, you must also coordinate diagnostic instruments and secondary software to interface with the EHR. The physical location of instruments, including cable drops and electrical outlets, plays an important role in overall efficiency as well.

All of this coordination doesn’t have to be on your shoulders, however; your instrument and EHR representatives, office space planner and IT professional all become an integral part of your office team, along with your clinical staff, to help you achieve the most efficient workflow and patient flow. ■

Dr. Chou practices at ReVision Optometry in San Diego, where he directs a referral-based scleral lens and keratoconus clinic.

1. Mahdawi A. What jobs will still be around in 20 years? Read this to prepare your future. The Guardian. www.theguardian.com/us-news/2017/jun/26/jobs-future-automation-robots-skills-creative-health. June 26, 2017. Accessed July 25, 2018.



INTRODUCING THE NEW SK FAMILY

Visual Field Analyzer Retinal Camera

SK-850A	SK-650A
GOLDMAN STANDARD In full compliance with the Goldman standard as well as features designed according to international standards	DICOM COMPATIBLE Easily transmit, store, retrieve, print, process, and display medical imaging information
AUTO GAZE TRACKING 3-dimensional fixation monitoring with infrared light tracking of the pupil on the x, y and z planes	AUTO MOSAIC FUNCTION Built with a 9-point fixation system allowing for auto mosaic photography over a large retinal area
EASE OF USE Easy to read printed report, without requiring any additional training or explanation	OPTICAL RED-FREE Red-free visual testing for obvious comparison of nerve fiber layers to help diagnose glaucoma
AUTO-CALIBRATION Automatic calibration and brightness measurement immediately when the machine is powered on	SUPERIOR PICTURE QUALITY New optical design guarantees full 45° image capture to avoid losing fundus information, while producing premier quality imaging



Patient Care for the Modern OD

There is a common trend in society to move towards a healthier lifestyle. With this trend, the market for vitamins and minerals has also grown, and it continues to grow about 6% year over year. This growth is due to the aging population, as well as an increase in awareness of preventative healthcare. Eye care professionals can use this growth to their advantage and begin dispensing nutraceuticals in-practice.

Why Supplement?

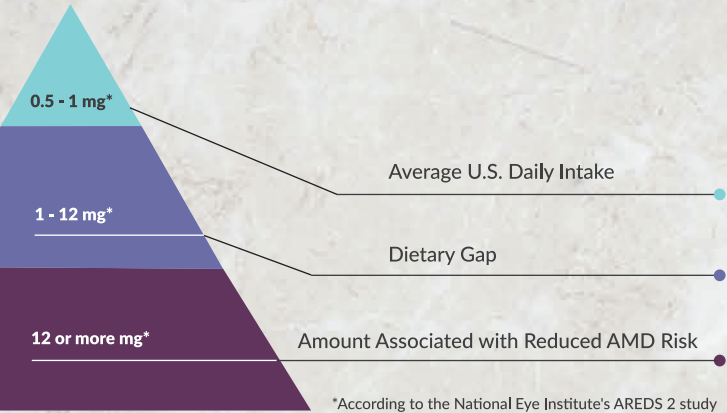
While there is a trend towards living a healthier life, most Americans are woefully lacking in the nutrition their eyes desperately crave. Specifically, the typical diet lacks two important carotenoids: zeaxanthin and lutein. Nutritional counseling and dietary modification can help, but it's difficult to get the amounts of these two antioxidants from food alone. It's often easier for patients to take a daily nutraceutical to bridge the dietary gap.

Who Needs Supplements?

To be frank, MOST people could benefit from starting a nutraceutical regimen because the standard American diet doesn't support eye health in the way it needs to. Those with other risk factors for diseases like AMD and diabetic retinopathy should be supplementing with a nutraceutical to help protect their vision.

Risk Factors Include:

Zeaxanthin & Lutein Dietary Gap



Age-Related Macular Degeneration



Beyond nutritional support, eye health nutraceuticals can protect against eye health concerns like age-related macular degeneration (AMD), diabetic retinopathy, and dry eye. Patients tend to find supplementation easier than making a dramatic lifestyle and dietary change, and it ensures they are actually receiving all the nutrients their eyes need in the amounts that will make a true impact.

- Family history
- Age
- Female
- Light skin and eyes
- Low MPOD
- Smoking (past or present)
- High BMI



- Diabetic
- Pre-diabetic



While there are no concrete “risks” for dry eye, patients experiencing any of the following symptoms can benefit from a dry eye nutraceutical:

- Itchiness
- Irritation
- Blurred vision
- Dryness
- Grittiness

How Do You Know They’re Working?

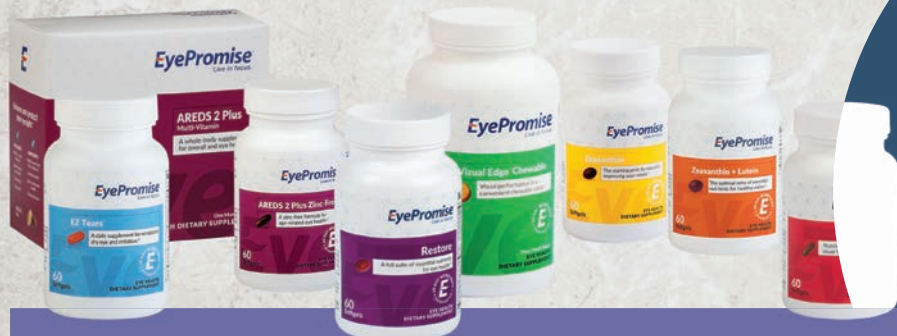When patients are on a dry eye nutraceutical, they can usually feel if it’s taking effect or not. Some can even feel relief within the first week of supplementation, depending on the product. Macular health nutraceuticals are more difficult to prove their effectiveness. In my practice, I measure macular pigment optical density (MPOD) with the QuantifEye® MPS II. The macular pigment is made up of zeaxanthin and lutein, and without nutritional support, it can become less effective, resulting in a lower MPOD score. Patients consistently supplementing with these two carotenoids will be able to see a noticeable improvement in their MPOD scores.

I consider supplementation to be a best practice among eye care professionals because it’s important for both eye and overall health. With MPOD measurement, I’m able to track my macular patients’ progress, and they get a simple score to associate with their eye health, making adoption of the nutraceuticals easier. It’s important to choose a lineup that is supported by sound science and guaranteed to make an impact. I recommend researching what products you’d like to offer your patients. One great way to become more knowledgeable and stay current with the latest science is to become a member of the Ocular Wellness Nutrition Society; for more information visit www.ocularnutritionssociety.org.



Pamela Lowe, OD, FAO, is currently Director/President of Professional Eye Care Center, Incorporated, a full-scope primary care practice she founded in 1992 on Chicago’s Northwest Side. She is a 1988 graduate of the Illinois College of Optometry; the college named her the Alumnus of the Year in 2002. Dr. Lowe is active in organized optometry and is a Past President of the Illinois Optometric Association and a career long member of the American Optometric Association, currently serving as Chair-elect on the AOA Contact Lens and Cornea Section. She is a Fellow with the American Academy of Optometry and a Diplomate of the American Board of Optometry.

Disclosures: Dr. Lowe received honoraria and consulting fees from EyePromise.



Offer patients premium protection with **EyePromise** nutraceuticals.

eyepromise.com/betterpatientcare-ro

References

Teichner, Warren, and Megan Lesko. “Cashing in on the Booming Market for Dietary Supplements.” McKinsey & Company, McKinsey & Company, Dec. 2013. www.mckinsey.com/business-functions/marketing-and-sales/our-insights/cashing-in-on-the-booming-market-for-dietary-supplements.

OCT-A

for AMD, Diabetes and Beyond

Imaging retinal and choroidal bloodflow can have a significant impact on how you diagnose and treat any number of ocular conditions.

By Steven Ferrucci, OD, and Jay M. Haynie, OD

Optical coherence tomography angiography (OCT-A) is a relatively new, noninvasive imaging technique that obtains images in rapid succession and evaluates for changes to examine retinal and choroidal blood flow. The technology also captures retinal and choroidal structure as well as vascular function and, when superimposed, allows more direct clinical correlation. This information can help clinicians diagnose and treat many retinal conditions such as age-related macular degeneration (AMD), diabetic retinopathy, vein occlusions and other retinal vascular diseases. Here's a look at how this new diagnostic technology can augment your clinical acumen.

AMD

This condition is currently the leading cause of irreversible vision loss in adults older than age 50, and approximately 11 million people are currently diagnosed with AMD in the United States alone. With increased life expectancy, this number is expected to double by 2050.¹ Although only roughly 10% are the wet—or exudative—form, these account for the vast majority of severe vision loss and legal blindness.¹

For years, the standard for evaluation of AMD and associated choroidal neovascular membranes (CNVM) has been fluorescein angiography (FA). However, this only provides a two-dimensional resolution of the retinal and choroidal vasculature and does not visualize underlying vasculature obscured by fluid, hemorrhage, retinal pigment epithelium (RPE) detachments or other areas of hyperfluorescence.² In addition, the modality itself can present a similar problem: the leakage of dye in an FA may obscure

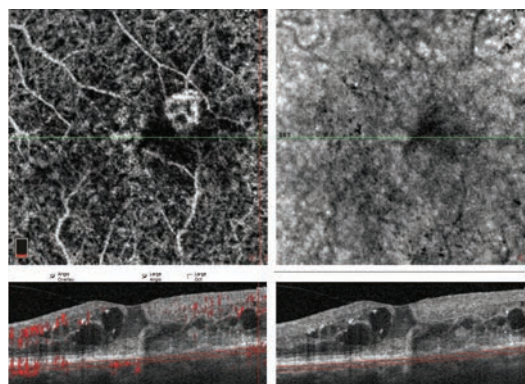
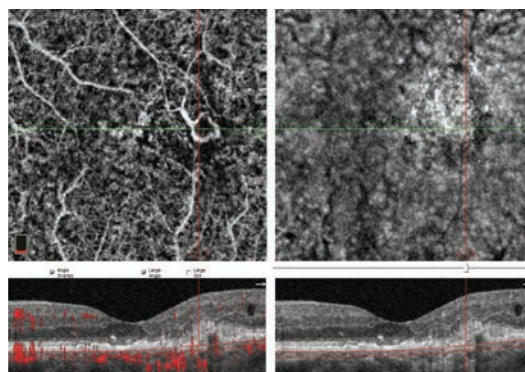



Fig. 1. This patient's initial lesion (above) regressed substantially after three injections (below) but more injections were recommended to see if it could be reduced even further.



ARE PATIENTS CHECKED OUT BEFORE EVER CHECKING IN?

Eyefinity[®] Can Change That.



Easy patient check-in with our new
integrated front-desk Kiosk app.

See it in action at
www.eyefinity.com/kiosk



Electronic Health Records • Practice Management
Patient Engagement • Business Insights

©2018 Eyefinity, Inc. All rights reserved.
Eyefinity is a registered trademark of Eyefinity, Inc.
All other brands or marks are the property of their respective owners. 27455

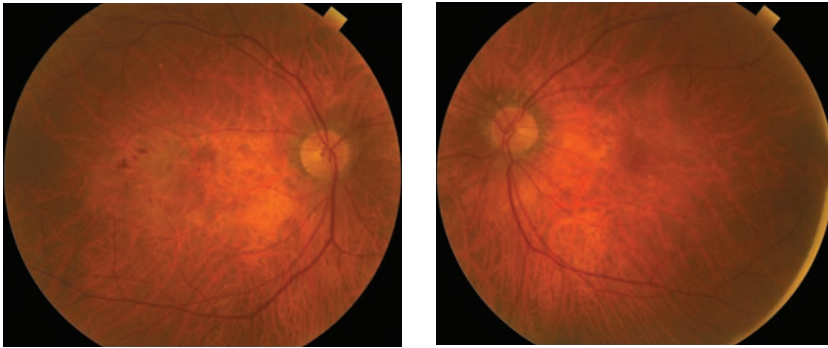


Fig. 2. The apparent hemes in this patient's right macula (left) are suggestive of new-onset CNVM. Several small, scattered drusen are present in the left macula (right).

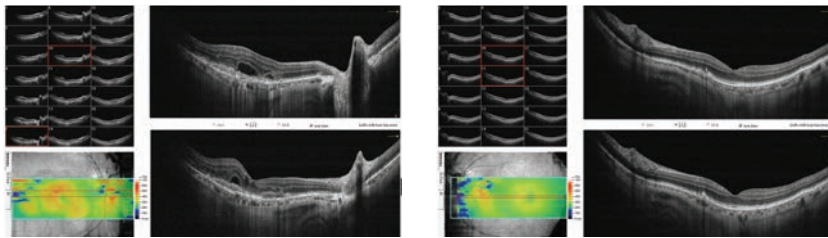


Fig. 3. The patient's raster OCT shows subretinal fluid and apparent CNVM in the right eye and drusen and RPE disruption without subretinal fluid in the left.

underlying vasculature; the dye can also pool, as in a pigment epithelial detachment, leading to an obscured view as well.

Traditional FA poorly visualizes the choroidal vasculature, as the hyperfluorescence is blocked by RPE pigment. Further, the procedure involves injection of a dye that may have adverse effects ranging from nausea and vomiting to anaphylactic reactions and, rarely, death.

OCT-A is easier and faster to acquire than FA, does not require injections and provides cross-sectional and *en face* images of retinal as well as choroidal features, allowing three-dimensional visualization of choroidal neovascular lesions.

Diagnosis. OCT-A technology allows us to evaluate not only the size of the CNVM lesion, but also its relative depth in the retina. With this new knowledge, we now know that not all CNVMs are the same. Three primary subtypes exist. Type 1 lesions arise from the choroid,

penetrate Bruch's membrane and invade the RPE. Type 2 lesions also originate from the choroid but infiltrate between the RPE and the retina. Type 3 lesions, also called retinal angiomatous proliferation lesions, likely arise from downward proliferation of the deep plexus layer of retina vessels to the RPE. Each of these may respond better or worse to treatment, depending on its morphologic features. Improved imaging of these lesions with OCT-A may soon lead to a better understanding of the best treatment patterns based on morphologic features.³

Type 1 CNVM lesions can be further broken down based on OCT-A appearance. One study described two clinical distinctions: a "medusa" form, representing about 55% of all lesions, where vessels radiate in all directions from a large feeder vessel; and a "sea-fan" form, about 25% of all presentations, where the majority of smaller vessels radiate from one large feeder vessel. The rest of the

membranes did not have smaller vessels. However, the study found these different morphologic patterns were not predictive of the rate of RPE detachments, atrophy or the number of injections needed to treat.⁴

Type 2 CNVM lesions are described as either "medusa-shaped" or "glomerulus-shaped," and are characterized by intertwined vessels with interspersed hypodensity.⁵ Currently, it is unclear whether these different morphologies noted on OCT-A will aid in treatment.

OCT-A also allows specialists to identify and diagnose subclinical CNVM, although much debate exists as to whether these inactive lesions need treatment or close monitoring until exudation appears. Patients with subclinical CNVMs were found to have a much higher rate of exudation over the course of a year—almost 15-fold higher than eyes without such lesions.⁶ Therefore, close monitoring of these subclinical lesions is a must to treat at the first sign of true exudation.

Treatment. OCT-A can be useful beyond diagnosis and may be integral to monitoring response to treatment. Repeat OCT-A after a series of anti-vascular endothelial growth factor (VEGF) injections can provide useful information and help clinicians decide if additional treatment is warranted (*Figure 1*).

OCT-A can be useful in differentiating exudative AMD from masquerading conditions such as central serous retinopathy (CSR) and polypoidal choroidal vasculopathy. The presence or absence of a CNVM deep in the choroidal space is instrumental in the differential diagnosis between CSR and wet AMD, as the clinical course carries a far different visual prognosis for the patient.⁷

Case example. An 81-year-old Hispanic male presented to the clinic reporting a black spot in the right

eye for about a month. The patient had been to the clinic nine months prior and diagnosed with Stage 2 dry AMD, with 20/25 OU acuity. He was counseled on the importance of supplementation—advice he did not take, for unclear reasons. The patient also has Type 2 diabetes with no retinopathy. Upon examination the second time, his vision was reduced to 20/150 in the right eye.

Fundus photos revealed a hemorrhage in the right eye suspicious for exudative AMD (Figure 2). The left eye revealed multiple small drusen, consistent with stage 2 dry AMD. Spectral domain (SD) OCT revealed subretinal fluid (SRF) overlying a RPE lesion, suggestive of a CNVM in the right eye and multiple drusen and RPE disruption without any SRF in the left eye (Figure 3). OCT-A of the right eye further revealed a large almost 3x3mm sea-fan like lesion in the outer retina and the choroid, consistent with a large Type 1 CNVM (Figure 4). The patient was referred to the retinal service for anti-VEGF injections.

Diabetes

OCT-A also plays a powerful role in evaluating and following diabetic retinopathy (DR) and macular ischemia. Diabetes is the leading cause of functional vision loss in the working population and second only to AMD as the leading cause of vision loss in adults.⁸ Approximately 347 million people worldwide have diabetes mellitus (DM), and the prevalence is expected to rise to 430 million by the year 2030.^{8,9}

ODs must remain proactive in the fight against blindness from diabetes, and OCT-A is an important diagnostic tool to catch signs of DR as early as possible.

The early complications of DM first occur in the capillary plexus of the deep retina, which is better eval-

uated with OCT-A than traditional FA. DR is characterized by microaneurysmal lesions, capillary nonperfusion and ischemia. The majority of vision loss is secondary to diabetic macular edema and ischemic maculopathy, the latter of which is associated with functional retinal damage and vision loss and can be a predictive factor in DR progression.¹⁰ Treatment for these complications is vital for preserving functional vision in patients with DM.

Diagnosis. Traditional FA and SD-OCT have been the standard diagnostic tests for evaluating the complications of DM, most notably ischemia and macular edema. However, traditional FA may fall short when evaluating the subclinical stages of retinopathy that can be difficult to catch with slit lamp biomicroscopy or retinal photography.

OCT-A allows the clinician to evaluate the retina's microvascular system in much greater detail than traditional angiography. With the ability to see subclinical microaneurysmal lesions and early ischemic changes in the retina, clinicians can be more proactive in discussing better systemic glucose control to slow retinopathy progression. Earlier intervention for those with early capillary drop is associated with a better long-term prognosis, as more aggressive anti-VEGF therapy can help prevent progression of ischemia.

Treatment. Evaluating the retinal vasculature is a vital part of following patients with DM, and a noninvasive diagnostic test such as OCT-A can help follow the patient more frequently without the cumbersome process and risk of traditional intravenous FA. In addition, some patients with later stages of DM will have poor venous access, making FA more difficult. OCT-A allows the clinician to follow progression in

BUILT TO LAST.



2018
Reliance 7000 Premiere Chair



120 years of craftsmanship, comfort, and style. And a future that promises to be as enduring as our past.

Builttosupport.com

© 2018 Haag-Streit USA. All Rights Reserved.

ischemic retinal disease without the need for venous access.

In a clinical setting, OCT-A gives us a better estimation of ischemic retinal changes (non-perfusion) compared with intravenous angiography due to the ability to image the capil-

lary plexus of the deep retina, which is not visualized with traditional FA.

New software will one day allow the clinician to monitor and track the progression of non-perfusion by comparing serial images over time and measuring the area of

non-perfusion present in a particular location of the fundus (similar to the RNFL and GCC progression used in our glaucoma patients with traditional SD-OCT thickness scans). This may prove beneficial for patients receiving intravitreal anti-

Glaucoma Care and OCT-A: A Promising Pair

By Carolyn E. Majcher, OD

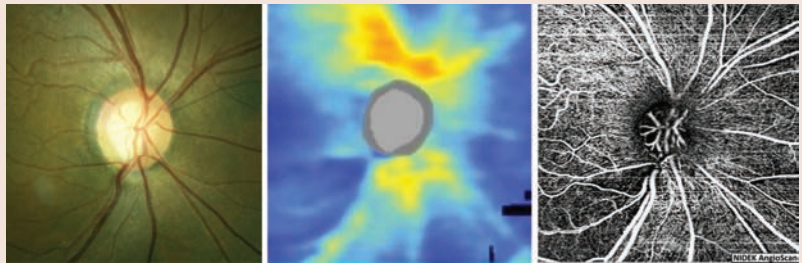
Researchers have long thought that vascular perfusion compromise and dysfunction of vascular autoregulation play a pivotal role in the pathogenesis of glaucomatous optic neuropathy. Now, with the advent of OCT-A to noninvasively assess ocular blood flow and capillary density, studies confirm the presence of decreased papillary, peripapillary and macular perfusion in glaucoma eyes compared with normal eyes.¹⁻⁴

Until recently, the main factor limiting OCT-A in glaucoma management was a lack of quantitative perfusion measures. Without it, clinicians had to visually detect and monitor perfusion abnormalities over time. But the FDA's recent approval of Optovue's AngioAnalytics now provides clinicians with quantitative peripapillary and macular vessel density data—another objective quantitative measure to monitor progression over time, in addition to nerve fiber layer (NFL) and optic nerve head morphology OCT analysis.⁵

Using this software, researchers demonstrate significantly reduced OCT-A radial peripapillary capillary density in all peripapillary sectors in glaucomatous eyes compared with normal eyes.⁶ The peripapillary vessel density was highly correlated with glaucoma severity, as determined by ganglion cell complex (GCC), NFL and rim area measures.⁶ Others who investigated the performance of OCT-A AngioAnalytics vessel density measurements compared with conventional OCT NFL thickness found the two are similar in their ability to discriminate glaucomatous from healthy eyes.⁴ Their research also suggests that OCT-A vessel density measures are not significantly influenced by disc size, a factor known to affect NFL and optic nerve head morphologic results.⁴

In Your Clinic

OCT-A may prove clinically useful in demonstrating short-term perfusion improvement upon initiation of glaucoma therapy.⁷ Whether these effects are due to vasoactive properties of the medications themselves or increased perfusion as an indirect result of IOP lowering is yet to be determined.




Color disc photo (left), NFL thickness (middle) and radial peripapillary capillary plexus OCT-A (right) of an eye with POAG and loss of the inferior temporal NFL.

The verdict is out on whether OCT-A detected perfusion abnormality is the cause or consequence of glaucomatous structural loss. One study shows progressive decrease of macular vessel density occurs in primary open-angle glaucoma (POAG) eyes; however, it was not accompanied by progressive GCC thinning, suggesting vascular dysfunction may precede, and is not a consequence of, structural loss.⁸

Vascular compromise likely plays a more substantial role in glaucoma development for some individuals than others, particular those with normal tension forms of the condition. In the future, OCT-A may allow clinicians to identify and customize care for patients with significant perfusion dysfunction by selecting IOP-lowering medications that favorably influence retinal or optic nerve perfusion.

Dr. Majcher is an assistant clinical professor at Rosenberg School of Optometry, University of the Incarnate Word in San Antonio, Texas.



GCC deviation map (left) and OCT-A superficial capillary plexus (right) of the same eye. Note loss of the inferior GCC and corresponding OCT-A vessel density loss.

1. Dastiridou A, Chopra V. Potential applications of OCT-A in glaucoma. *Curr Opin Ophthalmol*. 2018 May;29(3):226-33.
2. Majcher C, Trevino R, Ramirez K, et al. Evaluation of OCT-A nerve and peripapillary vasculature and vasculature-structure, vasculature-function relationships in glaucoma. *ARVO* 2018. Abstract #5056-B0007.
3. Trevino R, Majcher C, Sponsel W, et al. Diagnostic accuracy and correlates of OCT-A macular vessel density in glaucoma. *ARVO* 2018. Abstract #5062-B0013.
4. Yarmohammadi A, Zangwill LM, Diniz-Filho A, et al. OCT-A vessel density in healthy, glaucoma suspect, and glaucoma eyes. *Invest Ophthalmol Vis Sci*. 2016;57(9):451-9.
5. Optovue. Optovue receives FDA clearance for AngioAnalytics – the world's first OCT angiography metrics. June 11, 2018. www.optovue.com/news/optovue-receives-fda-clearance-for-angioanalytics-the-worlds-first-oct-angiography-metrics. Accessed August 3, 2018.
6. Lommatzsch C, Rothaus K, Koch JM, et al. Vessel density in OCT-A permits differentiation between normal and glaucomatous optic nerve heads. *Int J Ophthalmol*. 2018;11(5):835-43.
7. Dosch E, Majcher C, Trevino R, et al. OCT-A retinal vascular response of dorzolamide in healthy eyes. *ARVO* 2018. Abstract #2862-B0280.
8. Shoji T, Zangwill LM, Akagi T, et al. Progressive macular vessel density loss in primary open-angle glaucoma: a longitudinal study. *Am J Ophthalmol*. 2017 Oct;182:107-17.

AND LAST.




Fig. 4. OCT-A reveals a large CNVM in the right eye, prompting an immediate referral.

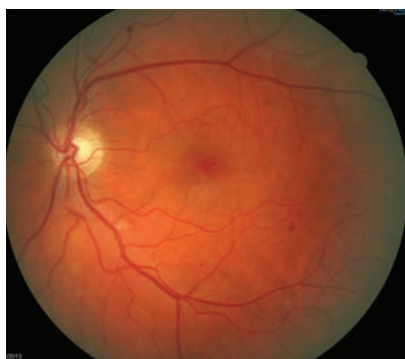

Fig. 5. This fundus image shows scattered dot/blot hemorrhages in the left eye consistent with mild NPDR.

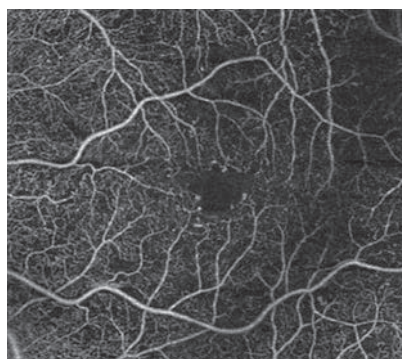


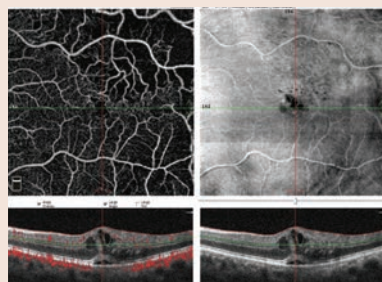
Fig. 6. OCT-A of the left eye reveals microaneurysms with early alteration of the FAZ.

VEGF therapy and may help the clinician titrate a maintenance dosage of anti-VEGF usage for the degree of ischemia and rate of progression.

Vein Occlusions

OCT-A can be helpful in determining ischemia in a number of retinal conditions, such as vascular occlusive disease. Knowledge of ischemia, as well as its extent, may be useful in the prognosis and treatment options available to these patients.

This OCT-A demonstrates a patient with an ischemic branch retinal vein occlusion in the left eye with macular edema. The area of ischemia is most pronounced in the superficial retina superior to the macula.



Case example 1. A 57-year-old female with a 12-year history of Type 2 diabetes presented for her annual dilated retinal examination. Her visual acuity measured 20/20 in each eye, and she had no subjective symptoms. The dilated retinal examination revealed a few dot hemorrhages in the posterior pole of the left eye (*Figure 5*) consistent with mild nonproliferative DR. OCT imaging revealed normal macular thickness and foveal contour compared with normative data. OCT-A, however, clearly showed more aneurysmal lesions in the parafoveal region, as well as a disruption of the foveal avascular zone (FAZ) consistent with early ischemic maculopathy (*Figure 6*).

Because ischemic retinal changes are indicative of a more rapid progression in retinopathy, she was considered at a higher risk for vision loss than you might expect with a diagnosis of mild nonproliferative DR. Because of the OCT-A findings,



1962
Reliance Model 680 Chair



120 years of craftsmanship, comfort, and style. And a future that promises to be as enduring as our past.

Builtsupport.com

© 2018 Haag-Streit USA. All Rights Reserved.

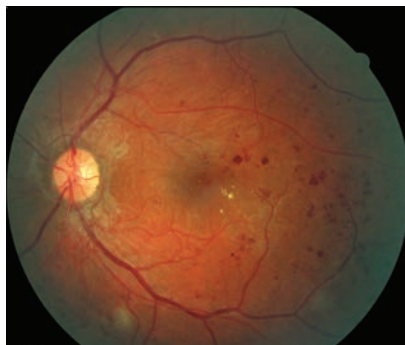


Fig. 7. Scattered dot-blot hemorrhages, retinal exudates and neovascularization inferior to the optic nerve head in the left eye.

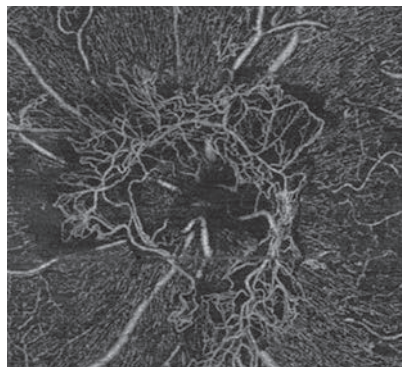


Fig. 8. This OCT-A scan confirms neovascularization in the left eye consistent with proliferative DR.

this patient is being followed more closely.

Case example 2. A 32-year-old man with a 27-year history of Type 1 DM was referred for a retinal evaluation by his primary care physician, although he had no symptoms of visual loss and his visual acuity was 20/20 OU. Dilated fundus examination revealed dot-blot hemorrhages with hard exudate in the posterior pole area of the left eye, as well as irregular vessels inferior to the optic nerve head suspicious for neovascularization (Figure 7). OCT-A confirmed a large frond of neovascularization of the disc consistent with proliferative DR of the left eye (Figure 8). Traditional FA confirmed the presence of neovascularization with leakage of dye in the later phases of the angiogram. He was treated with intravitreal bevacizumab and pan-retinal photocoagulation. The neo-

vascularization regressed over time, stabilizing his retinopathy.

Advances on the Way

Although OCT-A is still an emerging technology in the clinic, it's already improving with several newer innovations, each with useful applications for certain disease types:

AMD. AngioVue, a new technology by Optovue, recently gained FDA approval to assess flow area. Users can manually measure an area of abnormal flow by outlining a region for vessel detection corresponding to a CNVM or another lesion. The flow area is monitored precisely to see if a lesion is increasing with time, requiring additional treatment, or if an existing lesion is decreasing with treatment, a true measure of treatment response. New software will allow for custom segmentation and propagation, which

will enhance the removal of artifacts from the OCT-A analysis and make it easier to quantify changes throughout the retina and choroid.¹¹

Diabetes. The primary disadvantage of OCT-A for this patient population is its limited ability to image the midperipheral retina; however, the initial scan dimension of 3x3mm has grown to 6x6mm and even 8x8mm in size. An 8x8mm scan will capture the optic nerve, central macula and the posterior pole out to the vascular arcades in a single scan. Shifting patient fixation and acquiring a series of images has allowed for an evaluation of the midperiphery, and newer OCT-A technology includes internal fixation and montage software to stitch multiple images together much like we currently have with retinal photography and OCT imaging, although current OCT software only includes one internal fixation and must be moved manually to gain off-center images.

Optovue's AngioVue will also allow for an objective, qualitative analysis of the vascular structure of the retina and choroid and may be instrumental in following our patients with diabetes. FAZ tools will be available to accurately measure the area of the FAZ in square millimeters. This area can then be followed sequentially over time for changes, indicating worsening retinal damage (Figure 9). Vessel density mapping will calculate the percent of the total area in and around the macula occupied by vessels. As capillary dropout increases, the vessel density will decrease, signifying increasing ischemia and potential need for intervention (Figure 10).

In addition to the current imaging capabilities available on the Cirrus OCT-A (Carl Zeiss Meditec), a new software version will provide montage capabilities to obtain a wider field of view. A 14x14mm

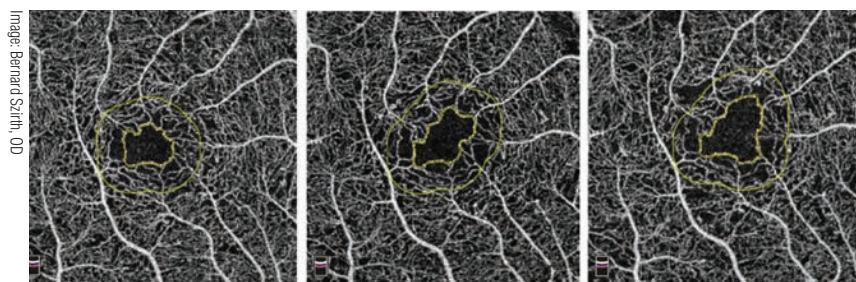


Fig. 9. Example of increasing FAZ over three visits in a patient with diabetes.

AND LAST.

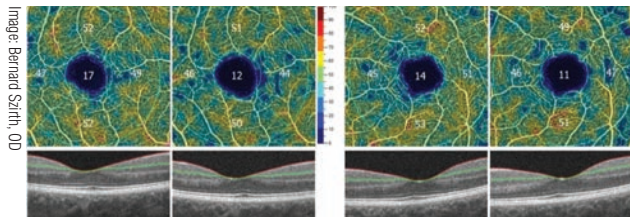


Fig. 10. Decreasing vessel density in both eyes over two sequential visits, associated with increasing ischemia.

image is a software montage of five separate 6x6mm images captured by a technician (Figure 11). The PlexElite swept-source OCT (Carl Zeiss Meditec) with scanning speeds of 100,000 A-scans per second is available for research purposes and will also allow for wider scanning abilities without needing montage software. Such improvements in software and montage capabilities will allow clinicians to use OCT-A to image the midperipheral fundus without the risk of adverse reactions to sodium fluorescein.

OCT-A is an exciting technology that may become instrumental in caring for patients with retinal disease. It already provides the data necessary to diagnose conversion to wet AMD before traditional FA, identify subclinical CNVM before retinal fluid is seen on OCT or a subjective symptom of blurred vision or metamorphopsia and evaluate patients with early retinopathy and ischemia—yet future advances

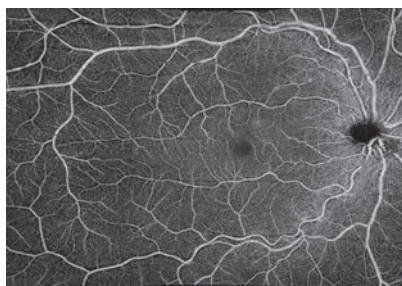

Fig. 11. A 14x14mm montaged image of five individual 6x6mm images captured on the Cirrus 5000.

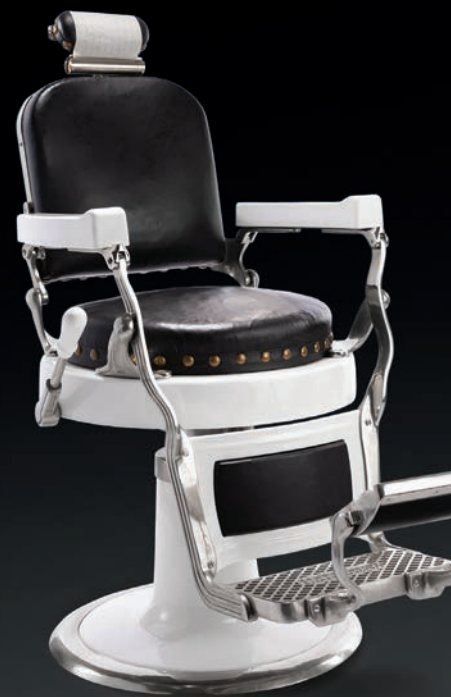show even more promise. Newer models may provide larger scan dimensions, montage software and software to track ischemic progression.

OCT-A moves optometry one step closer to a proactive profession that identifies disease and intervenes before visual loss. This, in the end, could potentially reduce the visual threat from AMD, DM and other retinal vascular diseases in our clinical population. ■

Dr. Ferrucci is chief of optometry at the US Department of Veterans Affairs in North Hills, Calif., and is a professor at the Southern California College of Optometry at Marshall B. Ketchum University in Fullerton, CA.

Dr. Haynie is in private practice in Washington state.

1. Rein DB, John S, Wittenborn JS, Zhang X; Vision Health Cost-Effectiveness Study Group. Forecasting age-related macular degeneration through the year 2050—the potential impact of new treatments. *Arch Ophthalmol.* 2009;127(4):533-40.
2. Cole ED, Novais EA, Louzada RN, Waheed NK. Contemporary retinal imaging techniques in diabetic retinopathy: a review. *Clin Exp Ophthalmol.* 2016;44:289-99.
3. Ma J, Desai R, Nesper P, et al. Optical coherence tomographic angiography imaging in age-related macular degeneration. *Ophthalmology and Eye Diseases.* 2017 Mar 20;9:1179172116686075.
4. Kuehlewein L, Bansal M, Lenis TL, et al. Optical coherence tomography of type 1 neovascularization in age-related macular degeneration. *AM J Ophthalmol.* 2015; 160:739-748.
5. El Ameen A, Cohen SY, Semoun O, et al. Type 2 neovascularization secondary to age related macular degeneration imaged by optical coherence tomography angiography. *Retina.* 2015;35:2212-8.
6. de Oliveira Dias JR, Zhang Q, Garcia JMB, et al. Natural history of subclinical neovascularization in nonexudative age-related macular degeneration using swept-source oct angiography. *Ophthalmology.* 2018;125(2):255-66.
7. Bonini Filho MA, Talisa E, Ferrara D, et al. Association of choroidal neovascularization and central serous chorioretinopathy with optical coherence tomography angiography. *JAMA Ophthalmol.* 2015;133(8):899-906.
8. Korobelnik JF, Do DV, Schmid-Erfurth U, et al. Intravitreal aflibercept for diabetic macular edema. *Ophthalmology.* 2014;121(11):2247-54.
9. Varma R, Bressler NM, Doan QV, et al. Prevalence of and risk factors for diabetic macular edema in the United States. *JAMA Ophthalmol.* 2014;132(11):1334-40.
10. Lee R, Wong TY, Sabanayagam C. Epidemiology of diabetic retinopathy, diabetic macular edema and related vision loss. *Eye Vis (Lond).* 2015;2:17.
11. Optovue. Optovue receives FDA clearance for AngioAnalytics – the world's first OCT angiography metrics. June 11, 2018.



1926
Reliance Barber Chair



Please join us at
Vision Expo West as
we say cheers to
120 amazing years.

Champagne Toast:
Thursday, September 27
Starting at 4:00 PM
Booth MS10043

Earn up to
19 CE
Credits*

NEW TECHNOLOGIES
& TREATMENTS IN
2018 EYE CARE



REVIEW OF OPTOMETRY®
EDUCATIONAL MEETINGS OF CLINICAL EXCELLENCE

ARLINGTON, VIRGINIA NOVEMBER 2-4, 2018

Join *Review of Optometry's* New Technologies & Treatments in Eye Care
November 2-4, 2018, at The Westin Arlington Gateway.

The Westin Arlington Gateway

801 N Glebe Road
Arlington, VA 22203
Phone: (703) 717-6200



Program Chair:
Paul Karpecki, OD, FAAO

Faculty:
Doug Devries, OD
Jeffry Gerson, OD
Justin Schweitzer, OD

A limited number of rooms have been reserved at the rate of **\$159/night**. Please book with the hotel directly by calling the number above. Mention "Review of Optometry" for group rate.

REGISTRATION COST: \$495

REGISTER ONLINE: www.reviewsce.com/arlington2018
EMAIL: reviewmeetings@jhihealth.com or **CALL:** 866-658-1772

WWW.REVIEWSCE.COM/ARLINGTON2018 | REVIEWMEETINGS@JHIHEALTH.COM | 866-658-1772

Administered by
Review of Optometry®

Partially supported by an unrestricted
educational grant from
Alcon

Review of Optometry® partners with Salus University for those ODs who are licensed in states that require university credit.

November 2-4, 2018

The Westin Arlington Gateway

801 N Glebe Road, Arlington, Virginia 22203

See event website for hotel accommodations.

Earn up to
19 CE Credits*

Registration Information

Name	Title	NPI # (NPI numbers will only be used for HCP reporting purposes)	
Practice Affiliation	License #/State	OE Tracker #	
Work Mailing Address	City	State	Zip Code
Work Telephone	Cell	E-mail	Fax

Name Badge Information (please print clearly)

My Name	My Guest	Additional Guests
---------	----------	-------------------

Payment Information

	Rate per person		No. in party		Subtotal
OD Registration: \$495 (Includes up to 19 hours of CE, breakfast, reception) Call 866-685-1772 for daily and student rates.	\$595	x	1	=	\$ _____
Additional Guest(s): \$45 (12 years and older, reception only)	\$45	x	_____	=	\$ _____

Complimentary Workshops (simultaneous, separate registration required)

- | | |
|---|---|
| <input type="checkbox"/> Dry Eye Disease Workshop (2:00pm-4:00pm)
Speaker: Paul Karpecki, OD, FAAO | <input type="checkbox"/> Blepharitis/MGD Workshop (4:00pm-6:00pm)
Speaker: Paul Karpecki, OD, FAAO |
| <input type="checkbox"/> Glaucoma Management Workshop (2:00pm-4:00pm)
Speaker: Justin Schweitzer, OD | <input type="checkbox"/> Retina Workshop (4:00pm-6:00pm)
Speaker: Jeffrey Gerson, OD |
| <input type="checkbox"/> Check enclosed (make checks payable to Jobson Healthcare, LLC) | |

Charge my: American Express Mastercard Visa

Credit Card Number _____ Exp Date _____

Cardholder (print name) _____

Signature _____

Conference Cancellation Policy

Full refund until September 7, 2018
50% refund of registration fee
until October 21, 2018
No refund past October 21, 2018

For more information or to register
Call: 866-658-1772
E-mail: reviewmeetings@jhihealth.com

Mail Form: Review Group c/o Jobson
11 Campus Blvd, Ste. 100
Newtown Square, PA 19073

Fax Form: Review Group
610-492-1039

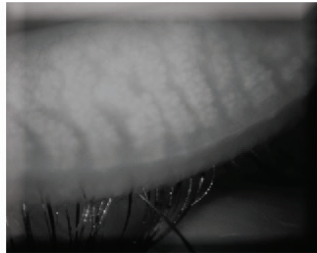
WWW.REVIEWSCE.COM/ARLINGTON2018 | REVIEWMEETINGS@JHIHEALTH.COM | 866-658-1772



*Approval pending

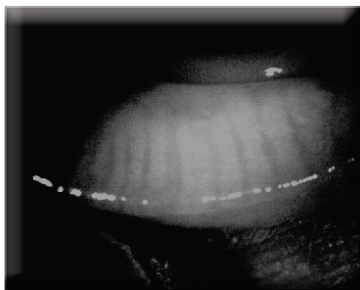


An essential tool for managing Dry Eye patients.



What Meibography does for your Patients:

- Screen for Dry Eye disease
- Demonstrate need for treatment
- Show efficacy of treatment



Make your exams
more productive and more profitable with
TelScreen's IR solution!

Reap the many benefits of owning an
EyeResTM Imaging System.
Multi-system discounts available.

Call **800.769.4933** today.

All Meibography Cameras Are **NOT** the Same!

TelScreen's **Functional Meibography** is a new approach, which captures the Infrared energy emitted by the Meibomian glands to produce an "**energy map**" that indicates which areas of the glands are consuming cellular ATP. Brighter spots indicate higher metabolic function, so you know which parts of the glands are working.

Traditionally, Infrared (IR) light sources have been used to send IR energy through the lids to an IR camera which creates an image of the Meibomian glands. With computer processing, this initial technology produces IR images which only indicate the **presence** of Meibomian glands. For optimal eye health, the glands have to be working; it isn't enough to just "show up!"



www.TelScreen.com



THE RICK BAY FOUNDATION

for Excellence in Eyecare Education

www.rickbayfoundation.org

Support the Education of Future Healthcare & Eyecare Professionals



About Rick

Rick Bay served as the publisher of *The Review Group* for more than 20 years.



To those who worked for him, he was a leader whose essence was based in a fierce and boundless loyalty.


To those in the industry and the professions he served, he will be remembered for his unique array of skills and for his dedication to exceeding the expectations of his customers, making many of them fast friends.

Scholarships are awarded to advance the education of students in both **Optometry** and **Ophthalmology**, and are chosen by their school based on qualities that embody Rick's commitment to the profession, including integrity, compassion, partnership and dedication to the greater good.

Interested in being a partner with us?

Visit www.rickbayfoundation.org

(Contributions are tax-deductible in accordance with section 170 of the Internal Revenue Code.)



THE RICK BAY FOUNDATION
for Excellence in Eyecare Education



(The Rick Bay Foundation for Excellence in Eyecare Education is a nonprofit, tax-exempt organization under section 501(c)(3) of the Internal Revenue Code.)



Reality Check:

Protecting Ocular Health from Headset Hazards

Devices are expanding your patients' visual landscapes. What are they doing to their eyes? **By Jerome Legerton, OD, MS, Liz Segre and Jay Marsh, MSME**

The wearable display industry is developing and commercializing headsets and eyewear that enable applications with broad benefits for health care, education, entertainment and more. However impressive they are, these technologies raise some concerns and opportunities for optometrists. What impact could these devices have on eye health and vision by potentially increasing blue light exposure, presenting new peripheral focal demands and creating untested strains on convergence and accommodation?

Eye care needs to define the categories of impact on the eye and vision and invite good research to investigate the reality of the emerging extended reality. Practitioners also have an opportunity for intervention when clinical signs and symptoms present.

A New Reality

Extended reality (XR) is a term that encompasses *virtual reality* (VR), *mixed reality* (MR) and *augmented reality* (AR).¹ Research into the development of wearable XR devices cites concern for convergence-accommodation conflict.² The developers also cited the issues with size and weight of wearable headsets, along with the heat generation inherent with displays, like other light sources, that convert a portion of energy to heat.

Optometry is primarily concerned about high-energy blue light exposure, visual task-exacerbated dry eye, the role of sustained near-centered tasks on refractive error development and the role of peripheral focus or defocus on refractive error development.³⁻⁵ Other



Virtual reality headsets, such as the one seen here, fully occlude a room's light and fit close to the user's face.

concerns include visual field obstruction, the potential for cybersickness, increased asthenopia and headache, fatigue and sleep disorders.⁶⁻⁸

A paucity of data and controlled studies support the concerns or estimate the risk levels from a safety perspective. Using a near eye display is clearly different from any normal visual task. Near eye display viewing is not something the natural eye can accomplish without optics in the system or novel imaging technology. Wearable displays represent a new manner of using the eyes, along with a new set of visual and perceptual stimuli.



We are your complete resource.

So much more than just optical displays,
exam consoles and reception furniture.

VIEW BOOTH 16076
AAOPT BOOTH 943

WWW.EYEDESIGNS.COM | 800.346.8890

Wearable Displays

A goal of wearable display design is to minimize the stimulus for accommodation for the plane of the display content. It is ideal if there is no, or at least minimal, demand for accommodation and, in the absence of three-dimensional scenes, no demand on convergence. The developers could argue that display use free of a demand on accommodation and convergence does not present a new manner of using the eyes. Even so, the display itself presents a proximal stimulus, the display content is dynamic and 3D and will be a common property of display content.

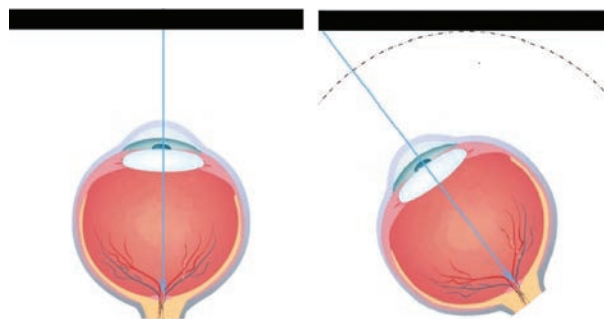
The lack of controlled studies creates the need for conversation before drawing unsubstantiated conclusions on one side of the controversy or the other. It would be unfair and dangerous to move quickly from theory to doctrine and doctrine to dogma with regard to the safety or dangers of wearable display use.

How It Works

Wearable displays have two main components. The first is the means of generating the display; the second is the optics that allow viewing of the display. The digital display in the headset or eyewear is electronic and delivered in the spectacle plane or the plane of the headset. The optics are a means of providing the dioptric power needed to see the display content.

Displays can be occluded or transparent. All VR systems use occluded displays, many in the form of headsets that fully block the real world while providing wide field of view displays. The displays are flat panels that may one day be curved. The flat panel presents a challenge to have adequate depth of focus in the optical system because the corners of the display are a greater distance from the center of rotation of the eye than the center of the display when placed at the pupillary distance (PD) of the user.

Transparent displays are produced by using a combiner. The combiner can be something like a beam splitter in a biomicroscope that allows a camera to capture the same image that is being viewed by the practitioner. This form of combiner requires focusing optics. Other forms of optical combiners exist and wave-guides are the most frequently used systems. Light is guided by nano-channels in the spectacle lens to reflecting elements that direct each pixel of the display to the eye without a focal demand. Most wave-guide displays do not require optics to focus the light.



The distance from the eye to the flat panel display is greater at the edge than in the center, resulting in a lower focal demand at the corners and edges than in the center.

Light-field technology is another method of producing a transparent display that does not require optics between the display and the eye. In an oversimplified description, this employs layers of transparent displays to produce pixels that can accommodate different refractive states and focal demands and does not require focusing optics.⁹

Not all transparent displays impact the eye and vision in the same way. Each must be studied clinically to understand the relative impact regarding binocular vision demands, field obstruction, cybersickness, asthenopia, headache, fatigue, blue light hazard, dry eye and mood and sleep disorders.

The second display component is the optical element that allows for viewing the near eye display.

All commercialized VR systems employ geometric optics in the form of high plus lenses in their headsets, similar to a Keystone stereoscope. The designers use adaptive optics to control the distortions of high plus lenses and manage the problem of the variation from the center to the corners of the flat panel distance from the eye. The inherent reduced size of the exit port or eye-box limits users' ability to make full versions when viewing. This narrow range of eye movement may be an issue with long-term use of VR headsets. Even so, humans rarely make versions greater than 25 degrees due to the phenomenon of head movement propensity.

Contact lenses and intraocular lenses (IOLs) are in development to eliminate the need for optics in the display system.¹⁰ One design incorporates a central micro-lens to focus the display and incorporates a light-polarizing or spectral filter that prevents the display light from passing through the normal refractive correction optic zone. The eye-borne optics are engineered for wide field of view and extended depth-of-field.¹¹ This optical solution potentially allows any display otherwise requiring geometric optics to be viewed in the spectacle plane without the geometric optics in the system. The eye-box limitation of geometric optics in a VR system is thereby eliminated, and the eye is free to make full versions.

Commercialized XR display headsets and eyewear products can be binocular or monocular. Of the binocular products, only a few offer limited pupillary distance (PD) adjustments. The need for a range of PD for the wearable display headsets and eyewear is expected, due to the distribution of PD across the population. The chromatic aberration of the high-powered geometric optic increases with the angle of off-axis viewing, and a relative vergence demand increases with a user's PD that departs significantly from the average or pre-set PD. Clinicians can help patients understand the limitations of the XR devices when they have a PD that is significantly wider or narrower than the mean PD incorporated in the device.

Most all XR display headsets and eyewear to date do not incorporate individual prescriptions. Refractive errors affect an estimated 68% of American adults, with 66% wearing some type of eyewear (eyeglasses, contact lenses, reading glasses).¹² Users must wear additional eyewear behind the headsets, wear contact lenses or perform the task without their respective refractive corrections when the prescription is not incorporated in the headsets or display eyewear. Companies are producing refractive correction lenses for placement between the geometric optics or displays and the eye as an alternative to wearing conventional spectacles in addition to the headset.¹³ The solution of wearing contact lenses to manage refractive correction with wearable displays may support a forecast for a new reason for consumers to wear contact lenses. Providing refractive correction with XR devices is a clear opportunity for eye care practitioners and strong reason for adding a case history question regarding the use of XR headsets and eyewear.

Are Wearables Bearable?

The most well-understood concern with binocular wearable displays is convergence-accommodation conflict.¹⁴ The display is in a fixed plane in a headset or in the spectacle eyewear. While demand on accommodation is fixed, the binocular content can vary in its stimulus for convergence. The disparity that produces stereovision, or 3D, can stimulate convergence, which in turn stimulates accommodation. The fixed plane of the display does not allow accommodation without blurring of the image. The result is a conflict wherein the image can be blurred and single or clear and with a vergence demand.

This conflict is known to cause fatigue and discomfort for some users.¹⁵ Efforts to increase the depth of focus of the optical system can mitigate this conflict



NuLids™ transformational dry eye therapy

Transforms your patients' lives



Finally... A doctor-directed at-home treatment for dry eye disease that is safe, effective and easy to use.

A multi-center study¹ showed:

- 50% decrease in dry eye symptoms
- 65% improvement in TBUT
- 80% increase in meibomian glands yielding liquid secretions.

For more information visit
www.NuSightMedical.com/ropt9
or call us at 833-368-5437



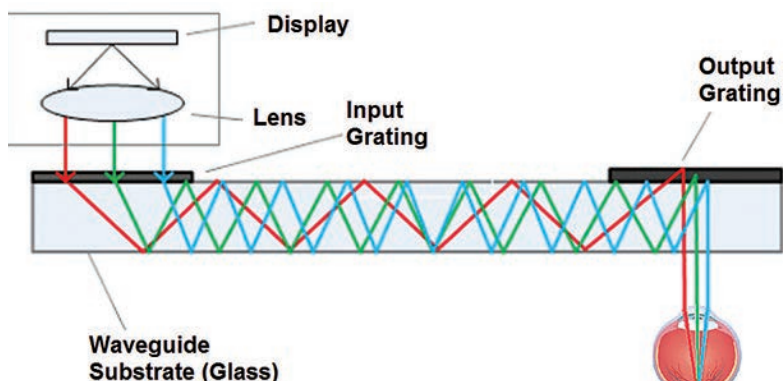
¹ Schanzlin, Olkowski, Coble, Gross. NuLids II Study, April 2018



NuLids™

Doctor prescribed, at-home dry eye relief

Wearable Displays



Above, wave-guide channels and reflectors direct individual pixels of light toward the eye to create a transparent display that also allows simultaneous viewing of the real world. At right, a beam splitter as a combiner allows for simultaneous viewing of virtual content and the real world.

by allowing the eye to accommodate with convergence without the concomitant blur, as an increased depth of focus should keep the image clear with convergence accommodation. Some wearable display systems are expected to have more or less convergence accommodation conflict than others.¹⁶

Many questions will remain unanswered: Will we find a higher incidence of symptoms in patients who are also found to have weaker binocular vision measures? What intervention strategies do we envision beyond suggesting discontinuation of use of the XR devices?

Thus far, the eyewear form factor wearable displays have frames that house the display technology, including the electronics and, in some cases, the power supplies. Field obstruction results when the frame endpieces and temples are larger than conventional frame designs and occlude a portion of the visual field. Safety concerns may arise from the reduced peripheral awareness when performing activities while wearing display eyewear that obstructs the visual field.

Computer Blues

The ophthalmic industry has embraced a concern for risks of exposure to high-energy visible blue light.¹⁷ The wavelength of high-energy visible blue light that was studied on explanted retinal tissue is 405nm.¹⁸ The range of wavelength for the theoretical risk to photoreceptors includes 400nm to 430nm. liquid-crystal

display (LCD) and organic light-emitting diode (OLED) displays are different from each other in that an LCD display is back-lit, while the OLED emits the light directly. The blue light emitted in each case is centered in the range of 445 to 465nm and not in the 400nm to 430nm range.¹⁹

Sunlight and micro-displays are not equivalent with regard to the significant spike in the range of theoretical concern. The spectral power distribution comparison must also be analyzed in the context of the luminance to understand the relative exposure of photoreceptors to the theoretically harmful visible blue light. Sunlight, on an average day, has a luminance of 35,000 candela per meter squared, while the average display brightness

when used indoors has a luminance of 250 candela per meter squared.²⁰ The luminance difference alone in the absence of the fact that the spectral power distribution has more visible blue light in the 400nm to 430nm range in sunlight suggests that the total retinal exposure to high-energy visible blue light is greater in five minutes of average daytime sunlight than it is in more than 11.5 hours of wearable display use.²¹ The outcome is similar for computer monitors that have a luminance in the range of 250 to 500 candela per meter squared.²²

The concern for visible blue light hazard will become more relevant when display luminance increases above the 1,000 candela per meter squared level and if the band of blue light shifts to lower wavelengths. The Laws and Regulations for Radiation Emitting Products of the Food and Drug Administration provide guidance for display products issues related to electromagnetic radiation.²³ Blue light hazard is not listed as a specific consideration in this guidance.

The correlation of use of computer displays in general with sleep disorders is a current concern.²⁴ The same is expected with the use of wearable displays. The wavelength of light known to suppress melatonin through the non-visual retinal pathway of the intrinsically photosensitive ganglion cells is 460nm to 480nm.²⁵ The wavelength emitted by electronic micro-displays, including those used in wave-guide and light-field technology, fall in this range. Sleep disorders are one known result of continual visible blue light expo-

sure in this wavelength. The absence of exposure to wavelengths in this range also causes sleep disorders due to the need for circadian rhythm that is made possible by alternate suppression and subsequent production of melatonin. It is straightforward to create smart eyewear that reduces the blue light emission based on a pre-determined sensing or signal, to shift the exposure to the visible red light to stop the melatonin suppression in an effort to restore normal circadian rhythm.

Incorporating technology that modulates the chromaticity of the display output such as f.lux and Apple's Night Shift feature can also regulate the different bands of visible blue light toward these same ends. Eye care practitioners may choose to investigate the number of hours per day of their patients' use of XR headsets and eyewear and consider recommendations for reducing the time of exposure to visible blue light or the use of contact lenses that filter the majority of the band between 400nm and 430nm while exercising caution in over-filtering the band between 460nm and 480nm.

On the Blink

Dry eye symptoms or disorders are a concern with sustained visual tasks. One cause is a reduced blink rate or quality that occurs with concentrated visual tasks.²⁶ The reduced blink rate is correlated with greater evaporation of the tears. Observations with the use of VR headsets appear to support that they are sealed and warm. It is possible the VR headsets may have a therapeutic benefit due to the goggle effect, known to increase the relative humidity around the eye is known to have therapeutic value for evaporative dry eye.²⁷ Even so, there is an opportunity to investigate signs and symptoms of dry eye in patients who report multi-hour use of XR devices.

Cybersickness—also called simulator sickness—is a form of motion sickness associated with VR environments.²⁸ A disagreement with visually perceived movement and movement sensed by the vestibular apparatus is the likely cause.²⁹ The otoliths and semi-circular canals, along with proprioceptors within muscles of the body, may not send the same movement signals as the visual system during wearable display use.³⁰ The vestibular apparatus may signal a stationary position while the visual content signals rapid motion or shifts in the position of objects relative to ego-centric localization. The experience of cybersickness may be different with fully occluded VR systems than with AR and MR systems that allow a peripheral lock

NuLids™ transformational dry eye therapy

Transforms your practice

The NuLids System helps reduce patient out-of-pocket expenses while creating an additional revenue stream for the practice – all without impacting overhead costs or disrupting other in-office treatments.

A multi-center study¹ showed 95% were satisfied or very satisfied with the treatment.

For more information visit
www.NuSightMedical.com/ropt9
or call us at 833-368-5437

¹ Schanzlin, Olkowski, Coble, Gross. NuLids II Study, April 2018



NuLids™

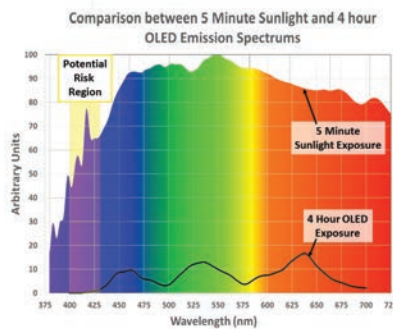
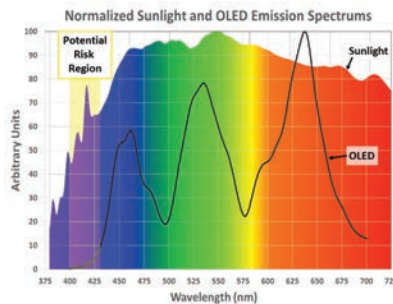
Doctor prescribed, at-home dry eye relief



Wearable Displays

on the real world. There is an opportunity to investigate vision therapy strategies for patients who use XR headsets and eyewear and report symptoms of cybersickness.

Use of near eye displays may also play a role in refractive error development. One study reported correlation between sustained near centered tasks and development of myopia.³¹ The correlation of sustained near tasks and myopiagenesis is without a well understood mechanism. Correlation and causation are not the same. The cause may be the absence of outdoor activity in individuals who engage in near work for long periods. More research is needed to strengthen the evidence basis for the role of sustained close work and myopiagenesis in general and to see if a correlation also exists with wearable display use in particular.



Display blue light's peak wavelength has lower energy, and the relative intensity of display light is significantly lower.

A second factor in myopiagenesis is the peripheral focus, or defocus, of the optical system of the wearable display. The evidence of the role of peripheral defocus in regulating myopia supports the value of a myopic peripheral defocus while the central image falls on the fovea.³² A myopic peripheral defocus occurs when on- and off-axis peripheral imaging is focused in front of the peripheral retina and is held to be advantageous in reducing the progression of myopia. The flat panel display in conjunction with all geometric optics including eye-borne optics results in the peripheral retinal image of a VR display being focused in front of the retina, because the peripheral display is further from the eye and, therefore, has a lesser focal demand while being focused by the same dioptric power.

Hiring Optical Staff?

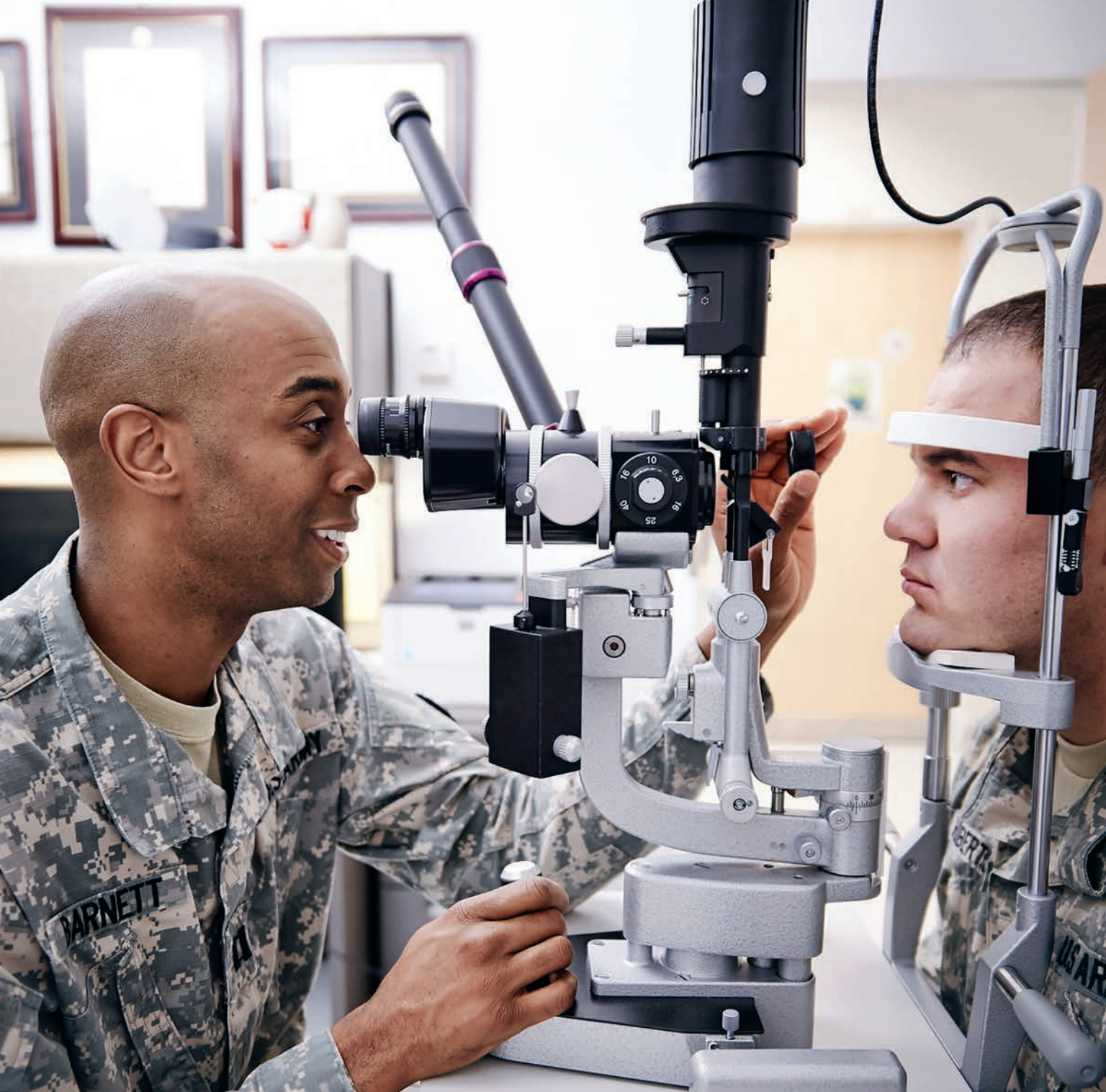More Opticians, Insurance Specialists, and other optical staff find jobs on Local Eye Site than anywhere else.

Save 20% on your job listing with coupon code **REVOPT**

localeyesite.com



Local Eye Site
JOBS IN EYE CARE



FOR SOME ELITE SOLDIERS, THIS IS WEAPONS MAINTENANCE.

As an ophthalmologist and officer on the U.S. Army health care team, you will provide world-class optical care for our Soldiers. Working in state-of-the-art facilities you'll have access to the latest treatments and drug therapies as you treat any type of disease, injury or disorder of the eyes. More importantly, you will be helping Soldiers maintain a vital weapon: their vision.

To see the benefits of being an Army medical professional call 800-431-6717
or visit healthcare.goarmy.com/mc35



The optical modeling of the current flat panel and geometric optics supports that the use of wearable displays is expected to inherently provide a therapeutic myopic defocus image shell. Such an effect will be produced even when a curved display is available with curvature equivalent to the base curve of a spectacle lens, since the periphery of the display will be further from the eye than the center of the display.

In the long-term, the eye care community will benefit from studying refractive error development in users of XR systems to determine if there is therapeutic value or otherwise.

What to Watch and What to Do

It's the job of clinical researchers to evaluate the impact these wearable displays may have on visual performance and eye health. The potential for harnessing this technology for personal and professional use in surgical visualization, situation awareness, patient engagement while accessing electronic medical records, visual rehabilitation, low vision and continuing education is significant. Consumers are already adopting the technology at a high rate and will seek our care when symptoms and challenges to adaptation occur. There are pitfalls in making hasty causal conclusions whether positive or negative with regard to the impact of the technology. The XR industry has already spent billions of dollars in research and development and is aiming high. They are expected to do anything and everything they can to mitigate real problems.

Controlled clinical investigations are needed, along with peer-reviewed case studies, to provide an evidence basis for conclusions about the technology that is emerging and that will usher in a widespread change in how our patients will be using their eyes and vision. In the meantime, practitioners have an opportunity to apply the art and science of vision care as intervention for patients who struggle to adapt to the XR headsets and eyewear, and who report symptoms or have clinical signs related to the anticipated problems with convergence accommodation conflict, high-energy visible blue light exposure, visual task-exacerbated dry eye, emerging myopia, cybersickness, field obstruction, increased asthenopia and headache, fatigue and sleep disorders. ■

Dr. Legerton is the co-founder of SynergEyes and Inmovega.

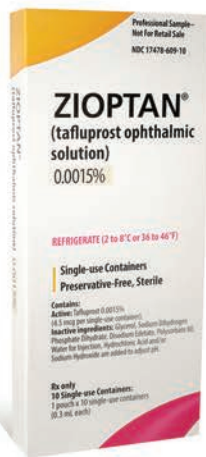Ms. Segre has served in eye care journalism for 24 years and is the founding editor of allaboutvision.com.

Mr. Marsh has a Masters in Mechanical Engineering, Cal Poly Pomona and serves as the vice president, engineering for Inmovega.

1. Fink C. War of AR/VR/MR/XR Words. Forbes. www.forbes.com/sites/charlie-fink/2017/10/20/war-of-arvr-mr-xr-words/#7f99f4b58d07 October 20, 2017. Accessed August 28, 2018.
2. Zhang S. The obscure neuroscience problem that's plaguing VR. Wired. www.wired.com/2015/08/obscure-neuroscience-problem-thats-plaguing-vr/. August 11, 2015. Accessed August 11, 2018.
3. Tosini G, Ferguson I, Tsubota K. Effects of blue light on the circadian system and eye physiology. *Molecular Vision*. 2016;22:61-72.
4. Moon J, Kim K, Moon N. Smartphone use is a risk factor for pediatric dry eye disease according to region and age: A case control study. *BMC Ophthalmol*. 2016;16:1:188.
5. Mutti D, Mitchell G, Moeschberger M, et al. Parental myopia, near work, school achievement, and children's refractive error. *Invest Ophthalmol Vis Sci*. 2002;43(12):3633-40.
6. LaViola J. A discussion of cybersickness in virtual environments. *SIGCHI Bulletin*. 2000;32(1):47-56.
7. Rebenitsch L, Owen C. Review on cybersickness in applications and visual displays. *Virtual Reality*. 2016;20(2):101-25.
8. Christian C. Evening exposure to a light-emitting diodes (LED)-backlit computer screen affects circadian physiology and cognitive performance. *J Appl Physiol*. 2011;110(5):1432-8.
9. Simonite T. How magic leap's augmented reality works. MIT Technology Review. www.technologyreview.com/s/532001/how-magic-leaps-augmented-reality-works/. October 23, 2014. Accessed August 17, 2018.
10. Legerton J. Technology in your practice; contact lenses of the future are not as far off as you might think. *Contact Lens Spectrum*. 2017;32(8):28-34.
11. Sprague R, Schwiegerling J. Full field-of-view augmented reality using contact lenses. Paper presented at the Interservice/Industry Training, Simulation, and Education Conference, November 29-December 2, 2010; Orlando, Fla.
12. National Eye Institute & Lions Clubs International Foundation. 2005 survey of public knowledge, attitudes, and practices related to eye health and disease. Bethesda, MD: National Eye Institute. (2007).
13. Luxexcel to 3D print optical prescription lenses for Vuzix AR headsets. 3ders. www.3ders.org/articles/20180105-luxexcel-to-3d-print-optical-prescription-lenses-for-vuzix-ar-headsets.html Jan. 5, 2018. Accessed August 17, 2018.
14. Kramida G, Varhney A. Resolving the vergence-accommodation conflict in head mounted display. University of Maryland. www.cs.umd.edu/sites/default/files/scholarly_papers/Kramida-rev.pdf. Accessed August 17, 2018.
15. Hoffman D, Girshick A, Akeley K, Banks M. Vergence-accommodation conflicts hinder visual performance and cause visual fatigue. *J Vis*. 2008;8(3):33.1-30.
16. Lanmann, D. Near-eye light field displays. NVIDIA Research. talks.stanford.edu/douglas-lanmann-near-eye-light-field-displays/. October 9, 2013. Accessed August 17, 2018.
17. Flint Ford H. Learn the science and key clinical points to help educate—and ultimately protect—your patients. *Rev Optom*. 2016;153(4):88-93.
18. Roehlecke C, Shumann U, Ader M, et al. Influence of blue light on photoreceptors in a live retinal explant system. *Molecular Vision*. 2011;17:876-884.
19. Triggs R. AMOLED vs LCD: differences explained. Android Authority, February 8, 2016 <https://www.androidauthority.com/amoled-vs-lcd-differences-572859/>. Accessed August 15, 2018.
20. Guttag K. ODG R-8 and R-9 Optic with a OLED Microdisplays (Likely Sony's). Karl Guttag on Technology. January 4, 2017. www.kguttag.com/2017/01/04/odg-r-8-and-r-9-optic-with-a-oled-microdisplays-likely-sonys/. Accessed August 15, 2018.
21. Halsted C. Brightness, luminance, and confusion. *Information Display*. 1993;9(3):21-4.
22. Dohrman P. How to measure the brightness of computer monitors. Techwalla. www.techwalla.com/articles/how-to-measure-the-brightness-of-computer-monitors. Accessed July 7, 2018.
23. Radiation Control Act. FDA. www.fda.gov/radiation-emittingproducts/electronicproduct-radiationcontrolprogram/lawsandregulations/ucm2007155.htm. March 22, 2018. Accessed August 17, 2018.
24. Volpi D. Heavy technology use linked to fatigue, stress and depression in young adults. *Huffington Post*. October 2, 2012. Accessed August 17, 2018.
25. Turner P, Van Someren E, Mainster M. The role of environmental light in sleep and health: Effects of ocular aging and cataract surgery. *Sleep Med Rev*. 2010 Aug;14(4):269-80.
26. Acosta M, Gallar J, Belmonte C. The influence of eye solutions on blinking and ocular comfort at rest and during work at video display terminals. *Exp Eye Research*. 1999;68(6):663-9.
27. Korb D, Blackie C. Using goggles to increase periocular humidity and reduce dry eye symptoms. *Eye & Contact Lens*. 2013;39(4):273-6.
28. Virre E. Virtual reality and the vestibular apparatus. *IEEE Engineering in Medicine and Biology Magazine*. 1996;15(2):41-43, 69.
29. Barrett G, Thornton C. Relationship between perceptual style and simulator sickness. *J Applied Psychol*. 1968;52(4):304-8.
30. Mittelstaedt J. Effects of display type and motion control on cybersickness in a virtual bike Simulator. *Displays*:51.2018:43-50.
31. Jones-Jordan L, Sinnott L, Cotter S, et al. Time outdoors, visual activity, and myopia progression in juvenile-onset myopes. *Invest Ophthalmol Vis Sci*. 2012 Oct 1;53(11):7169-75.
32. Smith E. Prentice award lecture 2010: a case for peripheral optical treatment strategies for myopia. *Optom Vis Sci*. 2011;88(9):1029-44.

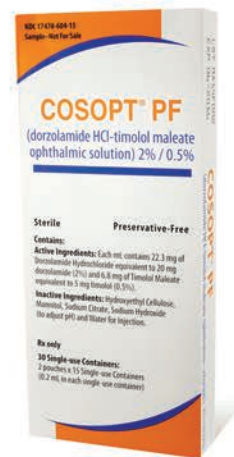

100% PRESERVATIVE FREE



If you're attending
AAO 2018, visit us at

**AKORN BOOTH
#3700**





ZIOPTAN[®]
(tafluprost ophthalmic
solution) 0.0015%

www.ZIOPTAN.com


Cosopt[®] PF
(dorzolamide HCl - timolol maleate
ophthalmic solution) 2% / 0.5%

www.CosoptPF.com

COSOPT is a registered trademark of Merck Sharp & Dohme Corp and is used under license. ZIOPTAN is a registered trademark of Merck Sharp & Dohme Corp and is used under license.

 ZIOPTAN is licensed by Santen Pharmaceutical Co., Ltd.

 **AKORN**

©2018 Akorn, Inc. All rights reserved. E089 Rev 07/18

Why Refer When You Can Retain?

Adding a specialty focus elevates your practice and dramatically improves your patients' lives. **By Catherine Manthorp, Associate Editor**

As optometry grows at an impressive rate—new grads outpace retirees every year—it becomes more difficult to stand out from the crowd. If yours is a typical practice, what draws patients in beside proximity and the insurance plans you accept? Those may have been enough to help you get by in the past. But sooner or later, you will need more.

There are plenty of ways ODs can spice up their practices. You could buy that expensive piece of equipment you have been eyeing. Perhaps you could look into bringing a ground-breaking new treatment or another doctor on board. Maybe you could even add a specialty.

Specializing allows ODs to differentiate and expand their practices, increase their profit margins and meet more patient needs. Some specialties build on the services a practice already offers. Others completely reinvent a practice. But all come with a few basic requirements.

Practice management guru Gary Gerber, OD, of Treehouse Eyes and the Power Practice, says integrating

a specialty into a primary care practice should be done carefully and with plenty of forethought to ensure positive clinical outcomes.

Dr. Gerber says the biggest lesson he has learned and continues to preach is that clinicians interested in specializing cannot dabble. You will be doing your patients and specialty more harm than good, he says, because dabbling prevents patients from receiving the quality of care they need. If you are going to call yourself a specialist, you better make sure you can live up to the title.

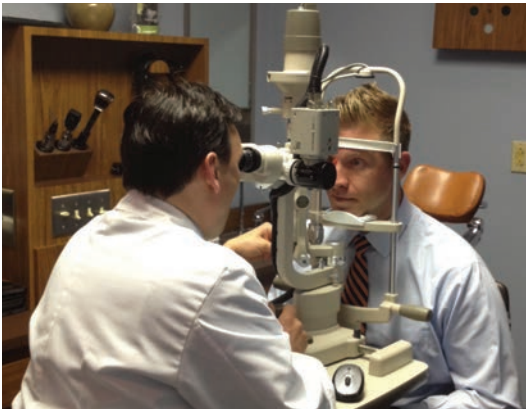Clinicians must learn the ins and outs of the trade and its patient demographic, and staff must be appropriately trained as well, according to Dr. Gerber. You must also understand the time commitment, the equipment investment and the billing process, he notes. By putting in the work before providing care, Dr. Gerber says clinicians are able to plan ahead, better manage and balance competing priorities and pave the way for a successful specialty practice without disrupting the current establishment.

This article discusses several specialties and the fundamental steps clinicians can take to master each, beginning with simpler undertakings and progressing to some of the more ambitious pursuits. What makes one easier to integrate than another? Minimal added expense for maximum gain, services that appeal to a broad swathe of patients and clinical services that build on your existing knowledge base.

Dry Eye

Nearly 35% of Americans are affected by dry eye, according to Peter Cass, OD, of Beaumont, TX, and Nevada's Douglas Devries, OD. This number, however, is conservative because symptoms are misjudged, hard to understand and easily confused with those of other conditions, the doctors noted during their lecture on starting a dry eye clinic at the AOA annual conference in Denver earlier this year.

While the percentage of the population affected by dry eye is increasing, Jennifer Lyerly, OD, of Cary, NC, says clinicians rely on the same



Paul Karpecki, OD, performs a slit lamp exam on a dry eye patient. An early interest in dry eye led Dr. Karpecki to devote much of his professional career to the discipline, helping him make a name for himself.

simple solutions—like prescribing artificial tears and daily disposable lenses—and fail to provide personalized care that offers long-term relief.

Drs. Cass and Devries argue that specializing in dry eye is cost-effective, is profitable and pays for itself.

To properly motivate a dry eye patient to comply with treatment regimens and prevention strategies, it is important to first educate all members of a practice about dry eye so they can facilitate effective patient education, according to Dr. Lyerly. She adds that tasks should be delegated; technicians must be able to explain the purpose and function of different devices, take images and perform treatment procedures, while clinicians are in charge of identifying candidates for treatment and interpreting images.

Dr. Lyerly suggests focusing on the high rate of meibomian gland dysfunction (MGD) among patients—a study suggests 86% of dry eye patients have associated MGD—by investing in devices that photograph and treat the glands.¹ TearScience's LipiView and LipiScan meibographers and LipiFlow treatment device, BlephEx (Rysurg), intense pulsed light and MiBo Thermoflo

(MiBo Medical Group) are all used by specialists to treat MGD, says Dr. Lyerly.

Once your office is geared up and your staff is trained, Drs. Cass and Devries note that specialists should standardize the process of screening and examining patients with a questionnaire like the Standard Patient Evaluation of Eye Dryness (SPEED), which quickly evaluates the frequency and severity of symptoms on a scale

from 0 to 28, 0 indicating the least severe form of the disease. These patients will likely need long-term clinical observation and care, so establishing baselines is important for measuring progress.

Specialty Contact Lenses

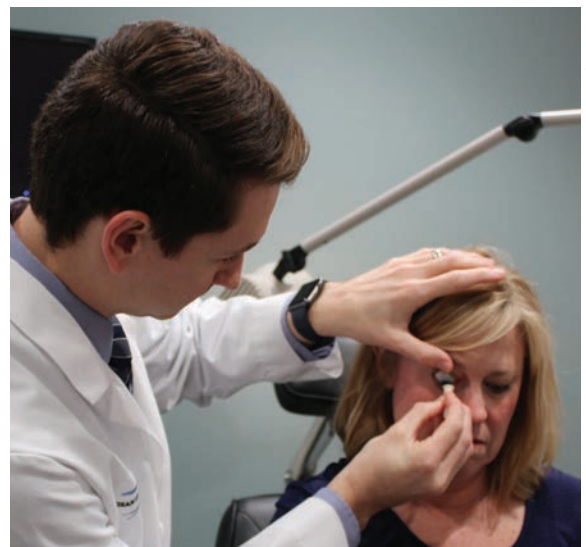Fitting custom lenses builds practices, increases referrals, better serves an existing yet underserved patient population and is rewarding on a personal and professional level, says Cory Collier, OD, of Lakewood Ranch, FL. It is also an extension of a clinician's ability to manage corneal and ocular surface conditions.

Many specialty contact lens patients have medical conditions that require separate follow-up care and management, creating additional streams of revenue, according to Dr. Collier. It is also an ideal way to insulate your practice from

the commodification of soft contact lenses that causes patients to look toward online lens suppliers.

Dr. Collier recommends clinicians gain as much knowledge about specialty lenses as possible prior to investing their time, money and resources into building a practice that may not be of any personal interest or value to them. Brooke Messer, OD, of Edina, MN, says clinicians can do so by making connections, forming relationships and taking advantage of resources, such as conferences and CE courses.

Dr. Messer suggests establishing a rapport with specialty lens labs and their consultants to learn more, understand the warranty process and order the right products for a larger number of patients. Dr. Collier says one of the biggest mistakes he sees is when a specialist acquires a little bit of knowledge about many products rather than a lot of knowledge about a few products. He suggests honing your craft on a lens design you understand and making it your "primary weapon" so you can become an expert in one thing instead of a generalist in a lot of things.



Dr. Collier helps a specialty contact lens patient insert a custom lens.

To provide quality care, the entire practice needs to be on board. Staff must be trained and prepared to interact with different patient groups and ocular conditions and educate patients about lenses, fitting and wear and care, says Dr. Messer. Maybe most importantly, staff needs to understand how custom lenses benefit the patient and the practice, notes Dr. Collier.

Because most primary care offices already have the fundamentals, Dr. Collier says the equipment investment is minimal. To ensure a practice has the necessary tools, Dr. Messer notes that it is worth investing in a corneal topographer, an OCT capable of anterior segment imaging and a specular endothelial microscope. You will also need fitting sets for GPs and scleral lenses.

When acquiring patients, Dr. Collier suggests using a mixture of internal and external marketing strategies. Staff must be able to identify candidates from their current patient pool and educate clinicians who do not offer specialty contact lens services, or work with those who do, on the signs of a specialty lens patient, he says.

Dr. Collier recommends reserving initial visits for consults to assess a patient's condition, and educate them about it and the process so both parties feel comfortable, are on the same page and have similar expectations. Basic fitting and lens information, tips, resources, costs and responsibilities should be outlined in a brochure or contract, and patients should be given the chance to ask questions and express concerns, notes Dr. Messer.

When beginning the process of fitting custom lenses, Dr. Messer says it is smart to start with and learn from patients who have a milder version of the condition for which they are being treated. Only after a clinician

completes more fittings and masters the common symptoms of less severe conditions should they start treating conditions that have progressed, according to Dr. Messer.

Each specialist determines their own fitting fee, which could amount to several hundred dollars, and how much to mark up their lenses based on the value they place on their time and expertise, says Dr. Collier.

Pediatrics

One in four children has an undiagnosed vision problem that could lead to adverse effects ranging from chronic headaches to school difficulties, according to the AOA.² Kathleen Foster Elliott, OD, of Tulsa, OK, says caring for these underserved patients is important because 80% of learning occurs visually, and untreated vision problems in children could be life-threatening.

Specializing in pediatrics is also low-cost and profitable, Dr. Elliott notes, because most primary care offices already have the necessary equipment, and clinicians are able to schedule family members and more appointments of shorter lengths.

However, to treat this young patient demographic, staff must be trained to interact with children and educate parents, according to Dr. Elliott. Accommodating kids can be tricky; they need their own waiting room amenities (toys, coloring books, videos, kid-sized chairs), appropriate diagnostic equipment—and unconditional patience from everyone in the office.

When stocking their practices with appropriate frame sizes, designs and brands, Dr. Elliott says clini-

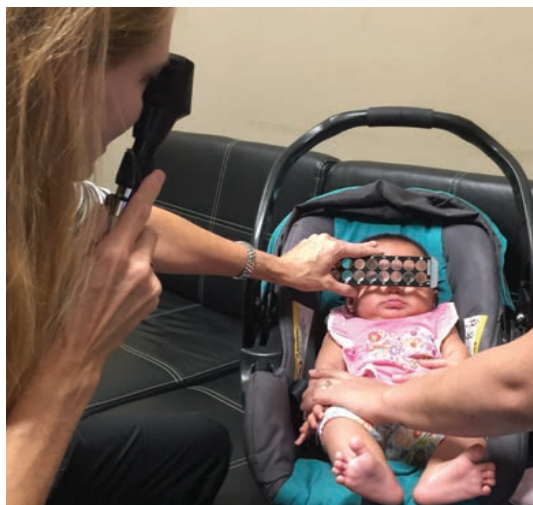

Photo: Kathleen Foster Elliott, OD

Dr. Elliott performs retinoscopy on a baby that remains in a car seat to ensure a smoother exam.

cians should take into account the flat nose bridges typical of children. Along the same lines, she notes that clinicians should be mindful of purchasing tools suited for young patient care, including cyclopentolate eye drops to ascertain an exact prescription and lens bars to perform retinoscopy. Dr. Elliott also recommends investing in the Spot Vision Screener (Welch Allyn), which can serve as a portable autorefractor for adults, to pick up early signs of amblyopia, refractive error, strabismus and astigmatism in patients as young as newborns. Using their newly acquired equipment, Dr. Elliott notes that specialists will be able to perform appropriate exams, such as a cycloplegic exam to obtain an accurate refraction and diagnose accordingly.

Due to children's short attention spans, Dr. Elliott suggests performing eye exams in an infant and toddler room and keeping patients occupied with toys or cartoons on a laptop or the Acuity Pro (Vision Science Software), which also enables clinicians to use an eye chart. Dr. Elliott recommends letting young kids sit on their parents' laps and

keeping babies in their car seats to accommodate them comfortably and alleviate fear. Pending parental approval, Dr. Elliott says clinicians could implement a reward system for children who are on their best behavior throughout the exam.

Dr. Elliott recommends specialists develop relationships with local family doctors and pediatricians to educate them on when to refer, raise awareness about their pediatric services and improve patient flow.

Vision Therapy

Adding this specialty can differentiate your practice as a referral center, expand your patient base, add an income stream and better serve existing patients, according to Heidi Sensenig, OD, of Reading, PA. Vision therapy is unique because it is one of a few eye specialties that only ODs learn in school, notes Rima Bakhru, OD, of Park Slope Eye. MDs are simply not a competitive factor, and honestly, most ODs are not either; the field is small.

Dr. Sensenig says changing lives for the better and success stories—including a 10-year-old boy who earned his first A on a reading test and a 28-year-old woman who is able to play with her son without getting a headache for the first time since her concussion—are the most compelling reasons to specialize in vision therapy.

To become an expert, Dr. Bakhru suggests clinicians find a specialist to shadow or complete an in-state residency to better understand the specific model. Clinicians can also connect with other practitioners and expand their knowledge through CE courses, Dr. Sensenig notes. Understanding vision therapy from the inside out is especially important if a clinician plans on working with traumatic brain injury patients.

As soon as a clinician has the specialty knowledge they need, they are ready to join a practice interested in vision therapy. Some doctors do their own vision therapy, Dr. Sensenig says, while others hire vision therapists. According to Dr. Bakhru, vision therapy in a private practice is only profitable if a therapist sees patients while a specialist performs exams and evaluations, or if the specialist sees multiple patients at once for therapy.

If a vision therapist is brought on board, they must be trained to care for patients under the direction of the specialist, says Dr. Sensenig. One way they can master their trade is by shadowing the specialist or another vision therapist, notes Dr. Bakhru.

As vision therapy is integrated, Dr. Bakhru recommends holding staff meetings to ensure all members of the practice understand therapy programs and billing processes.

Although specializing in vision therapy requires an investment in equipment, Dr. Sensenig notes that a practice can start with the basics and add products and equipment as necessary down the road. Dr. Bakhru suggests purchasing flippers, prisms and vectograms and looking into modern technology, including the Sanet Vision Integrator (HTS Vision), the Computer Orthoptics




Photo: Heidi Sensenig, OD

To improve their peripheral vision, a patient may use a Marsden Ball during therapy.

S4OPTIK SLIT LAMPS

NEW LED Illumination

More than 50,000
hours of clear, cool
illumination.



Easier observation of
minute details.

Color temperature
maintained through the full
range of illumination
adjustment.

S4OPTIK

250 Cooper Ave., Suite 100 Tonawanda NY 14150

www.s4optik.com | 888-224-6012

Sensible equipment. Well made, well priced.

For today's modern office.

VTS4 (HTS Vision) and virtual reality accessories from Vivid Vision. A one-time equipment cost of around \$30,000 quickly pays for itself, and the revenue from therapy sessions, products, exams and evaluations increases the profitability of becoming a vision therapy specialist, according to Dr. Bakhru.

Dr. Bakhru notes that it is important to carefully design room features—window placement, chair type, equipment setup—when considering treatment effectiveness in spaces where clinicians care for patients. She recommends using clear doors so parents can check on and reassure their children.

Dr. Sensenig suggests hiring someone who can effectively market your practice and optimize your website, social media pages and general internet presence. In addition, Dr. Bakhru recommends visiting local schools and doctors' offices to raise awareness about your services and educate staff on the signs and symptoms of a child experiencing binocular vision problems so they are able to point them in the right direction.

Patient education should begin during the initial evaluation, says Dr. Bakhru. She recommends explaining the therapy process in a simple, reassuring way to the parent and the child while performing the exam. Letting parents watch the exam and see the results helps convince them that therapy is necessary to correct their child's vision problems, notes Dr. Bakhru.

According to Dr. Sensenig, one of the most important parts of opening a vision therapy clinic is creating an environment where patients feel at home and comfortable that their needs are the first priority. Dr. Bakhru says identifying with patients on a personal level and tailoring the



Photo: Anthony Diecidue, OD

Dr. Diecidue reviews an OCT scan of the retina for any indications of diabetic retinopathy.

therapy process to their interests and needs goes a long way toward making a successful experience possible.

Diabetes

Data from the World Health Organization shows that nearly 425 million people worldwide have diabetes, and that is not even including those who have prediabetes.³ Paul Chous, OD, of Tacoma, WA, adds that at least half of many offices' patients could have abnormal blood glucose levels and be at significant risk of developing diabetes-related eye diseases.

As the number of prediabetic and diabetic patients and the demand for services grows, so does the profitability of specializing in diabetes, notes Ansel Johnson, OD, of Blue Island, IL.

To acquire the necessary knowledge, Dr. Johnson suggests finding a mentor and joining the American Association of Diabetes Educators.

Dr. Chous notes that while the majority of diabetes equipment is low-cost, most primary care offices already have the basics. He says investing in imaging technology gives clinicians the ability to detect ocular changes caused by diabetes earlier and predict the onset of associated eye diseases. Dr. Johnson recommends purchasing an OCT, extended color vision testing, a central VF, an ERG and nutritional supplements.

This specialty is tougher than some others because clinicians need to be adept at spotting early diabetic retinopathy, and their knowledge of systemic health and endocrine function must go above and beyond what is expected in general optometric care. It also puts the pressure on you to be the quarterback of care among the patient's general practitioner, endocrinologist and retina specialist.

Dr. Johnson says taking advantage of the training manufacturers offer staff and the information they give patients helps practices and patients alike understand diabetes and its ocular effects. He recommends providing additional information and further educating patients through handouts and conversations.

Dr. Chous suggests clinicians advertise the services they are offering to current patients and other diabetes care providers to attract a larger patient base. When treating patients, Dr. Chous says it is important to help those who are high-risk monitor and reduce modifiable risk factors—such as what they eat and drink, how often they exercise and how many hours they sleep—and pay attention to factors—including glycosylated hemoglobin levels, duration of poor glucose control and insulin use—that increase the risk of eye diseases like diabetic retinopathy and macular edema.

Myopia Management

This one shouldn't be hard to specialize in, right? Wrong. The stakes are higher than you may realize and it's a time-consuming endeavor.

One in four, or 10 million, children in the United States is myopic, according to Kevin Chan, OD, of Treehouse Eyes. Dr. Chan notes that childhood myopia is seen so often

that clinicians usually default to advising parents to order a stronger prescription for their child—a temporary remedy for clearer vision before the child’s prescription changes again. Relying on this course of action may do kids a clinical disservice, says Dr. Chan, and can potentially put them at an increased risk of irreversible ocular consequences like myopic retinal detachment in adulthood.

As the number of myopic patients increases—a study suggests half of the global population will be myopic by 2050—so does the need for specialized care.⁴ Myopia management, however, is time-consuming and requires unique expertise, technology and resources, according to Dr. Chan. He advises clinicians who want to commit to managing myopia to be prepared to give up other areas of their practices to ensure quality care and patient satisfaction. Dr. Gerber says untreated progressive myopia may come with clinical consequences, and dabbling only reinforces the problem and its risks.

The first order of business is learning everything there is to know about myopia management from the clinical and business perspectives, according to Dr. Gerber. Staff must be trained to explain myopia and

its treatment options to parents, he says. He adds that it is important for specialists to be proactive about communication so they can keep parents informed and up-to-date on options for their children.

Clinicians must then obtain technology that helps meet the goal of myopia management: slowing down axial length growth. Dr. Chan says quality technology can objectively measure changes in axial length to a finer degree. He adds that having a reliable, accurate and reproducible way of measuring length helps demonstrate how well a treatment is working. Dr. Chan recommends clinicians invest in a corneal topographer and look into open field autorefractometry, peripheral autorefractometry and wavefront aberrometry.

To acquire patients and establish a reputation, Dr. Chan suggests combining social and digital marketing, using testimonials, treating local physicians’ kids and doing consumer research. Because there are no FDA-approved treatments at this time, Dr. Gerber says an attorney who specializes in healthcare and consumer law should vet all marketing ideas.

Dr. Chan says thorough myopia management consultations and assessments could take at least an hour with parent discussions adding half an hour, while follow-ups could take twice as long as routine contact lens appointments. Ultimately, Dr. Gerber says the time spent caring for a myopic patient amounts to six to eight times the time spent caring for a regular patient. For these reasons, Dr. Chan encourages clinicians to schedule appointments for myopic patients on

Photo: Gary Gerber, OD



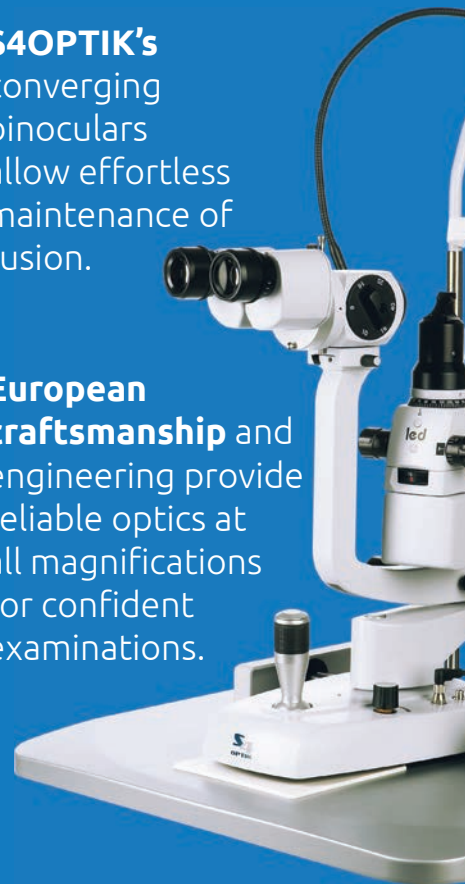Dr. Chan examines a young myope.

S4OPTIK SLIT LAMPS

SEE MORE - Exceptional Optics

S4OPTIK’s converging binoculars allow effortless maintenance of fusion.

European craftsmanship and engineering provide reliable optics at all magnifications for confident examinations.



Vertical and compact configurations available.

S4OPTIK

250 Cooper Ave., Suite 100 Tonawanda NY 14150

www.s4optik.com | 888-224-6012

Sensible equipment. Well made, well priced.

For today’s modern office.

the same days.

Due to a lack of understanding about the consequences of myopia, Dr. Chan notes that it is important to communicate the differences between refractive changes and eye complications with patients and parents and focus on the long-term benefits of myopia treatment. He also suggests specialists conduct pre-testing for younger patients instead of technicians to engage young, anxious patients and establish a rapport.

Glaucoma

About half of patients with glaucoma are undiagnosed and undertreated, according to Eric Schmidt, OD, of Omni Eye Specialists. As the prevalence of glaucoma grows with an aging population, he says ODs will have to step in to satisfy the larger demand for treatment.

Dr. Schmidt adds that glaucoma practices are profit centers because each patient is seen so frequently and requires consistent testing.

Because the need for services is increasing and the majority of practices already see glaucoma patients, Dr. Schmidt suggests group practices appoint the doctor most knowledgeable about glaucoma as the specialist. He recommends acquiring knowledge and hands-on experience through a mentorship

or fellowship. Dr. Schmidt adds that students who are interested in specializing in glaucoma should complete a residency to witness care protocols for every form of the disease—from how it presents to how it progresses to medical and surgical management. Specialists can continue to acquire knowledge and brush up on their skills through programs and CE courses, he notes.

Dr. Schmidt recommends allocating time and resources to train and educate staff on what glaucoma is, whom it affects and its blinding nature. He says technicians or assistants should be hired and trained to administer tests and explain the importance of eye drops, compliance and follow-up to patients.

Starting a glaucoma practice is costly, as investing in the right equipment to properly treat patients is key. According to Deepak Gupta, OD, of Milford, CT, spending between \$50,000 and \$60,000 on the first round of purchases buys an applanation tonometer, a gonioscope, a fundus camera and a threshold VF analyzer. Dr. Gupta also recommends investing in a nerve fiber analyzer—an OCT costs between \$60,000 and \$80,000—and a corneal pachymeter.

To begin the patient acquisition process, Dr. Schmidt notes that specialists should broadcast their services to current patients and local practices. He says it is important to establish your specialty practice as safe and trustworthy when setting it apart from others and encouraging referrals from doctors.

Dr. Schmidt says the hardest part of treating glaucoma is ensuring patients understand the disease and its sight-threatening implications. Educat-

ing patients through conversations, brochures and videos is important for compliance; patients who understand the sight-threatening nature are more likely to adhere to treatment and see better results.

Low Vision

Some would argue that this specialty should be listed first, as every practice has patients not correctable to 20/20 who yearn to see better. Leaving no stone unturned in the pursuit of better vision is also a fundamental part of what it means to be an OD. Yet low vision remains intimidating to many, sometimes out of concerns that it is too much work or fear of interprofessional friction as doctors compete for patients. Inadequate insurance coverage for visual aids also adds complexity to the experience, as out-of-pocket costs for patients can sometimes be high.

Beside the overwhelming need for services—research shows that just under 255 million people worldwide suffer from vision impairment—Richard Shuldiner, OD, of Corona, CA, says reasons to specialize in low vision include the professional satisfaction of helping someone who feels helpless, the ability to build and differentiate your practice and the financial rewards.⁵ To reap the benefits, however, clinicians have to know where to start. This is where things get challenging.

Dr. Shuldiner says specializing in low vision is difficult because there is no standard process. At the very least, specialists must be able to conduct low vision exams, be knowledgeable about rehabilitation devices and techniques and understand what it takes to be a low vision doctor and care for patients with vision impairment, according to Dr. Shuldiner. He adds that it is



In a glaucoma specialty practice, a handheld tonometer makes taking IOP readings a breeze.

Photo: Nathan Stevens, OD



This elderly patient wears bioptics to drive, but is more independent and self-sufficient as a result.

important to shadow local experts and take advantage of learning opportunities to ensure the best, most efficient quality of care.

Staff must have a similar comprehension of low vision to answer questions, provide information and promote patient satisfaction and a reputable practice, says Alexis Malkin, OD, of Baltimore, MD.

Specialists should put their newly acquired knowledge to work by purchasing low vision equipment for their offices. Dr. Malkin says essential items include an ETDRS chart, a contrast sensitivity chart, a continuous text reading card, materials to test patients' spot reading abilities and visual-assistive equipment.

Dr. Shuldiner recommends clinicians market their specialty practices to the public rather than eye care providers so patients know what low vision is and that services exist and are available.

Once a patient expresses an interest in low vision services, Dr. Shuldiner notes it is then up to the specialist to determine if the patient qualifies for and can be helped by low vision care and set practical expectations of cost, options and what can and cannot be done. Dr. Malkin adds that patients must report their functional history,

which measures the impact of vision impairment on reading, visual information and sight, mobility, daily activities and driving.

After qualifying a patient, Dr. Shuldiner then performs a one-hour exam and prescribes a custom-made device, such as a telescope, microscope, prism or filter.

Specialists bill for visits based on time spent interacting with patients rather

than medical complexity, notes Dr. Malkin. Medicare covers low vision as a rehabilitation service for patients with medical diagnoses, but Dr. Malkin says patients must pay for the refraction cost. Thus, she adds that it is important to discuss all options and coverage plans with patients.

Follow Your Bliss

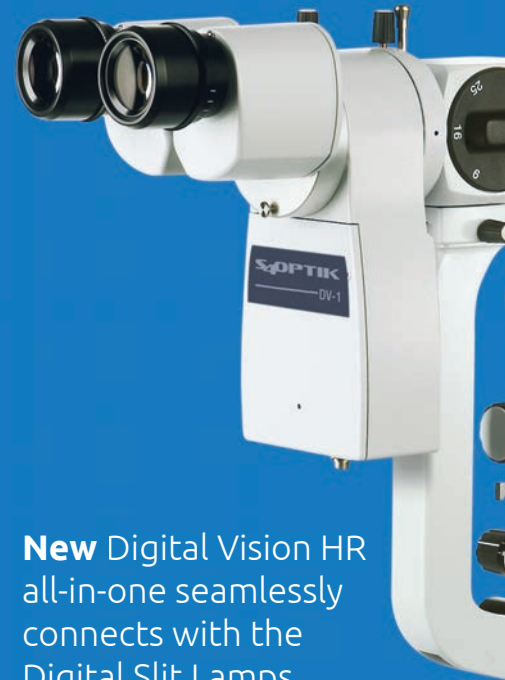These specialty focuses are by no means an exhaustive list. In a sense, anything can become a specialty if you care enough about it.

Provided you are passionate about pursuing a specialty and have access to a large enough patient population to make becoming a specialist financially worthwhile, you will be well on your way to carving out a niche in your practice in no time. ■

1. Nichols KK, Foulks GN, Bron AJ, et al. The international workshop on meibomian gland dysfunction: executive summary. *Invest Ophthalmol Vis Sci.* 2011;52:1922-9.
2. American Optometric Association. School days: time for comprehensive eye exams. www.airoptik.com/contact-technology.shtml#ultra-smooth. Accessed September 15, 2018.
3. NCD Risk Factor Collaboration. Worldwide trends in diabetes since 1980: a pooled analysis of 751 population-based studies with 4.4 million participants. *Lancet.* 2016;387(10027):1513-30.
4. Holden BA, Fricke TR, Wilson DA, et al. Global prevalence of myopia and high myopia and temporal trends from 2000 through 2050. *Ophthalmology.* 2016;123(5):1036-42.
5. Bourne RRA, Flaxman SR, Braithwaite T, et al. Magnitude, temporal trends and projections of the global prevalence of blindness and distance and near vision impairment: a systematic review and meta-analysis. *Lancet Glob Health.* 2017;5(9):888-97.

S4OPTIK SLIT LAMPS

EFFORTLESS Digital Imaging



New Digital Vision HR all-in-one seamlessly connects with the Digital Slit Lamps to provide brilliant imaging at the press of a button.

Still Images or Video Sequences



S4OPTIK

250 Cooper Ave., Suite 100 Tonawanda NY 14150

www.s4optik.com | 888-224-6012

Sensible equipment. Well made, well priced.

For today's modern office.

Master Pediatric Spectacle Wear Challenges

Uncooperative kids, anxious parents and unusual clinical challenges raise the stakes. Here's how to succeed. **By Sarah Galt, OD, Katherine Weise, OD, MBA, and Cathy Baldwin, LDO**

Doctors, technicians and opticians all play a critical role in the potential success of a child's visual performance—and some kids require a little more creative thinking by every care provider on the team. These unique spectacle wear challenges help to illustrate the many methods you can employ—including new frame technology, innovative lens design and motivating techniques—to ensure your pediatric patient's spectacle success.

Everyday Challenges with Real World Solutions

Most pediatric patients are prescribed spectacles and instructed to return for follow up to check their response to the glasses after two to three months of wear. In cases where visual acuity has not improved with spectacle wear and amblyopic factors continue to linger, one culprit is often to blame: patient compliance.

Non-compliance typically involves parents, peers, spectacle fit, prescription or some combination of all of these. It is important to anticipate these reasons during your exam and address them when spectacles are first prescribed to increase the likelihood

of good spectacle wear habits from the beginning. If we don't, the child could completely miss the opportunity for improved visual development and be stuck with poor vision in one or both eyes. These cases exhibit the top reasons for non-compliance in the pediatric spectacle-wearing population:

Pessimistic parent. A three-year-old black female was referred by her pediatrician for reduced acuity OD. She had anisometropic hyperopia OD>OS with reduced best-corrected acuity OD. She was a cooperative child,

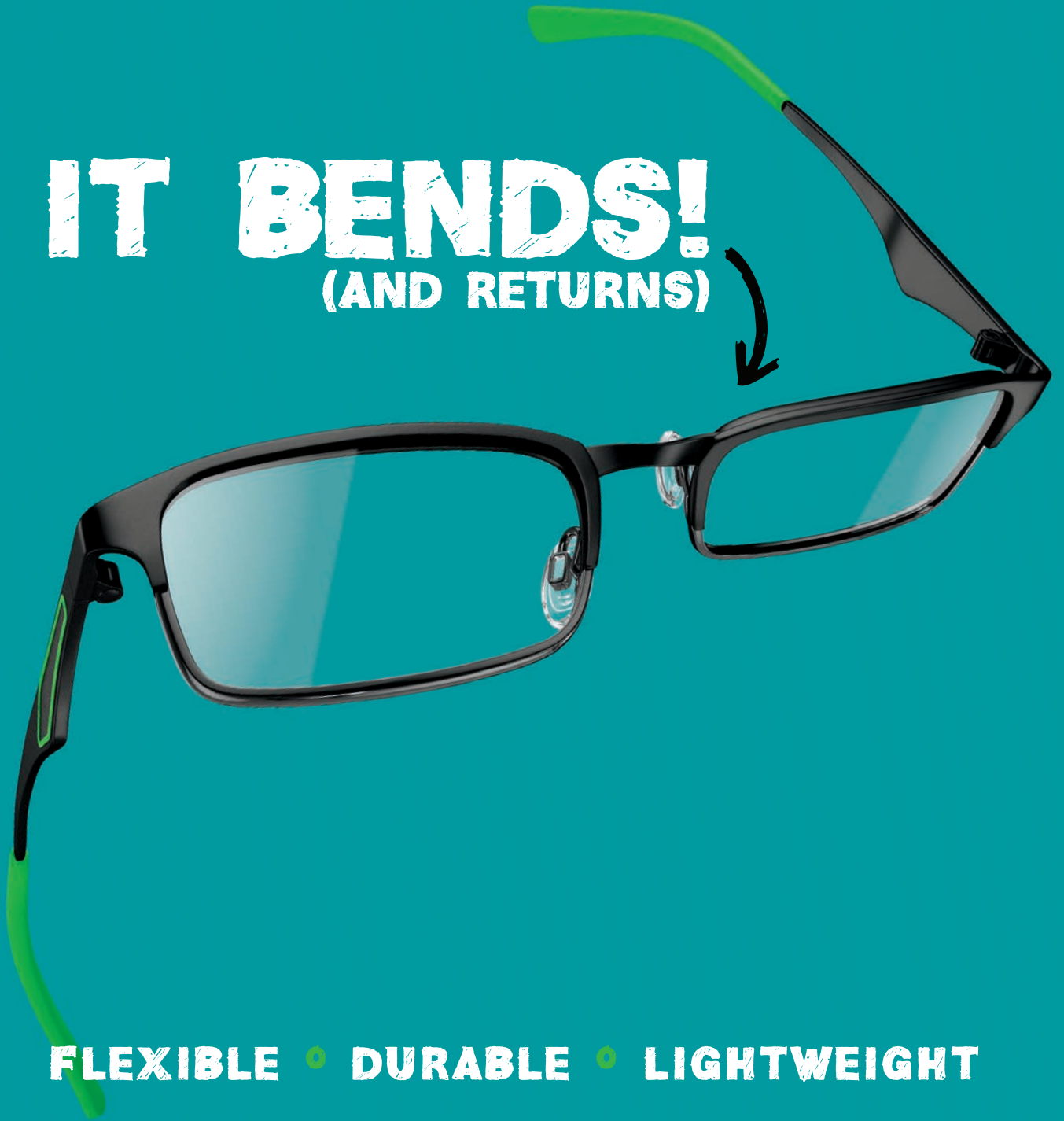but as three-year-olds will do, she got antsy by the end of the exam. At this point, her mother said, "If you don't sit still, they are going to give you glasses." This negative take on glasses laid the groundwork for an uphill battle in compliance right out of the gate.

Solution: Your most formidable tool in combating a situation such as this is good communication with both the patient and parent. When you announce that glasses are the best vision correction option, it is important that the parent understands why glasses are prescribed, how they will help their child see better and what to anticipate when first trying the glasses. Reassure the parents



Fig. 1. This child's small pupillary distance and round head presents a fitting challenge.

IT BENDS!
(AND RETURNS)



FLEXIBLE • DURABLE • LIGHTWEIGHT

© 2018 Marchon Eyewear, Inc. Style shown: Flexon Juniors Capricorn. Although Flexon frames are durable, they are not indestructible. Flexon frames should not be twisted more than 90° and Flexon temples should not be twisted more than once around the finger.

Flexon[®]
JUNIOR

that you only prescribe glasses when: (1) they are absolutely necessary and (2) they will improve the child's quality of life.

The final prescription may take one or two additional visits every three months to monitor for stability or to verify that the objectively measured refractive error is measured consistently.

Once you have finalized the prescription, these tips can help you increase compliance and maximize vision potential:

- Make a trial frame of the “opposite prescription” for the parent. This allows them to see for themselves that vision may be functional, but far from perfect.
- Try a game of I-spy with new glasses, pointing out objects in the distance that, prior to correction, the child could not see.
- Explain the importance of wearing glasses: there can be no negotiating. Glasses should be worn at all times or risk permanent vision deprivation. Parents should understand that glasses wear can be as important as using a car seat.
- Give the child some of the responsibility. Some useful phrases include: “When they’re not on your face, put them in your case” and “There are only two times when you don’t have to wear your glasses. Can you guess? If you’re not in the tub and not in the bed, where should your glasses be? On your head.”
- Find the patient’s motivation. If the glasses help improve binocular vision and stereopsis, this might be just what the athlete and athlete’s parents want to hear. The fear of not passing a driver’s license vision test can be a significant motivation for older patients. Find out your state’s vision requirements for driving and try to get your amblyopes to that level at a young age. Otherwise, it may be difficult to develop good vision by the time they are old enough to drive.

Peer pressure. A five-year-old Hispanic female was referred by her pediatrician for reduced visual acuity OU. Her isoametropic high mixed astigmatism was fully corrected with glasses, which was prescribed for full-time wear. Upon returning for visual acuity check, her mother reported that the child loved her glasses the first day she got them! However, after a single day at school with her



Fig. 2. Compared with the child in Figure 1, this patient was fit with glasses that placed the pupils in the center of the frame and with less wasted lens space temporally.

new style, the child refused to wear them.

Solution: There are phases in school-aged children when everyone seems to want glasses, and other times when no one wants glasses. The Children’s Attitudes about Kids in Eyeglasses study showed 24 paired photos to 80 kids (8.3 years +/- 1.3 years) and asked a series of questions about participants’ perception of the children in the photos.¹ In response to, “Which child looks smarter?” children were more likely to choose the spectacle wearer. The participants showed no significantly different perceptions of kids wearing glasses for all other questions.

Nonetheless, kids are often driven by peer pressure, and negative attention due to glasses wear can thwart compliance quickly. Words of encouragement during the glasses fitting and dispense, citation of age-appropriate TV personalities, sports icons and even wearing fun glasses yourself during the exam can increase positivity about their new prescription and encourage wear.

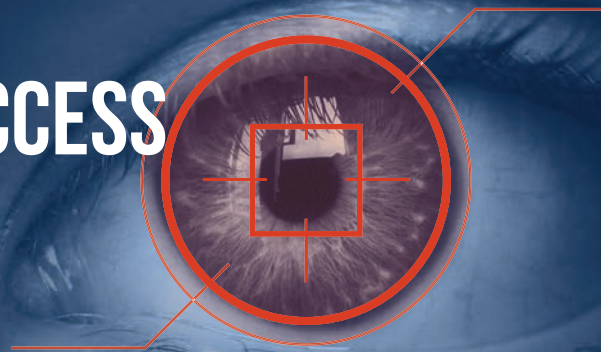
Perfect prescription, imperfect fit. A seven-year-old Hispanic female was referred from a school screening for reduced visual acuity OU. She had anisometropic high hyperopia and high astigmatism OS>OD. The child was given a prescription that fully corrected the anisometropia and the astigmatism, but the hyperopic prescription was cut symmetrically by one diopter to maximize adaptation to high cyl glasses. At follow-up, her visual acuity had only slightly improved. While her mother stated that the child did try to wear her glasses, the glasses fit poorly and fell off of her nose. The patient’s face was slightly too wide for child frames, but her pupillary distance was too narrow for the adult frames (*Figure 1*).

Pediatric Prescribing Resources

For specifics on refractive error prescribing recommendations, visit www.aoa.org, following the prompts: Home > Optometrists > Tools & Resources > Clinical Care Publications > AOA Optometric Clinical Practice Guidelines.

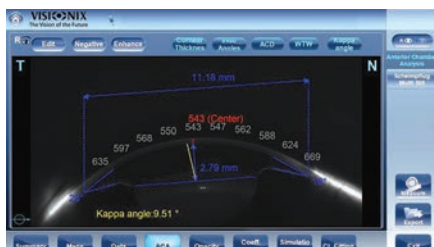
Another valuable resource for prescribing is www.pedig.jaeb.org. This public website of NIH-funded research shares results from many clinical trials involving amblyopia and other pediatric ocular conditions that will help guide prescribing decisions.

FOCUS ON CONTACT LENS FIT SUCCESS



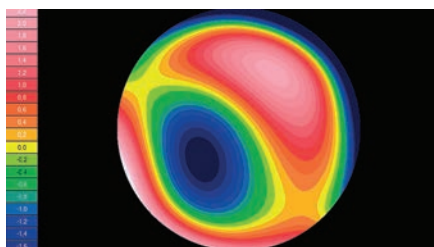
THE POWER OF 3

The Visionix VX130+ is the only instrument combining multi-slit Scheimpflug imaging, Shack-Hartmann wavefront aberrometry and Placido Ring corneal topography in a single instrument. This power gives you the most accurate anterior segment analysis available, in just 90 seconds, allowing you to focus on the right fit for your contact lens patients.



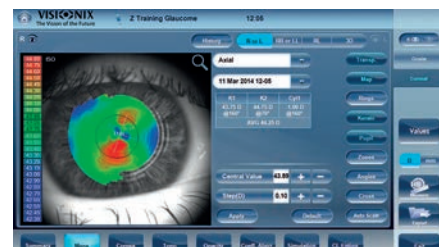SCHEIMPFLUG

- ✓ Assess corneal ectasia and edema
- ✓ Early keratoconus detection on posterior corneal surface
- ✓ Angle kappa for multifocal contact lens fitting



SHACK-HARTMANN

- ✓ Objective over refraction
- ✓ Corneal and internal astigmatism and wavefront error
- ✓ Vision quality simulation



PLACIDO RING

- ✓ Keratoconus
- ✓ Irregular astigmatism
- ✓ Custom contact lens designs

DEMO AT VEW BOOTH #LP7065

1-800-729-1959 | VISIONIXUSA.COM/VX130

Solution: During our exam, it is easy to think that getting the correct prescription may be the most meaningful aspect of our care. However, if we are unable to fit a pediatric patient in spectacles that are comfortable, stable and provide adequate optics, the prescription is fruitless. Children are unique and have many features that can challenge an ideal spectacle fit. For example, a flat bridge and round cheeks can keep glasses from staying in place, or a high level of physical activity can increase the risk that glasses are broken during wear.

When prescribing for the pediatric population, you or your optician should help them select frames based on stability, durability and protection. These pointers can help you master pediatric fitting:

- Consider spring hinges, frames that do not rest on cheeks and frames that do not put the entire weight of the frame on one location.
- For highly astigmatic glasses, choose round frames to avoid asymmetric edge thicknesses.
- For highly hyperopic glasses, avoid frames that sit close to the eyes to avoid lashes hitting the centers. Metal frames or frames with nose pads can help pull the frame out a bit for those with extra long eyelashes.
- For high myopes, avoid large or semi-rimless frames that increase edge thickness and lens weight.
- For all high prescriptions, vertex distance and pupillary distance should follow the carpenter's rule: measure twice, cut once.
- Avoid choosing glasses with the assumption that the patient will grow into them. Kids will generally not grow enough in one year to warrant changing the frame.
- Avoid using adult frames on kids when the pupillary distance is small and the patient's head is round or wider in the spectacle area.

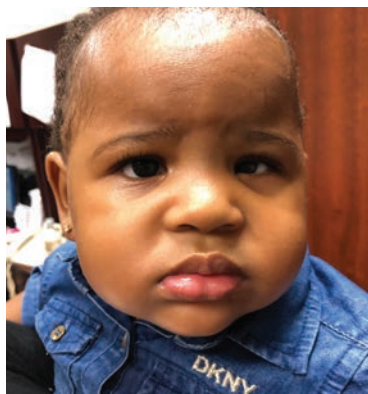

Fig. 3. As the neonate aphakic patient with micro-ophthalmia ages, the difference in eye size becomes more prominent. A magnifying plus lens may make the eyes appear more equal.

The patient's eye should be centered horizontally to avoid decentration (Figure 2). Temples should not touch the sides of the head until right before the ear. If you can stick a pencil or your finger between the temple of the frame and the side of the patient's face, it's too big.

Tricky Prescriptions

There are times when a child reports they can see just fine without glasses or can see no better with them—and they may be right. Anisometropic patients, those with high astigmatism and even high myopes often need glasses to help with more than simply clearer vision:

- Anisometropic patients who have one eye with minimal prescription and one eye with a significant prescription often have no visual complaints. However, covering the better-seeing eye helps to show the child what it would be like if he lost his better-seeing eye. Polycarbonate or Trivex lenses are required for these children for extra protection.
- Patients with significant astigmatism often see 20/30 with and without glasses. Here, patient and parent education is key once again. Explain that with continual wear, vision will get noticeably better with time and with the right prescription.
- Patients with highly hyperopic glasses may see worse in their glasses. Explain that the eyes are doing too much work without glasses, like carrying around five-pound dumbbells. The glasses will help the child see more comfortably, not just more clearly. If, after one to two follow ups with minimal to no glasses wear, consider prescribing one drop of atropine 1% in each eye on a Saturday and Sunday. Explain to the parent that this restricts the child's ability to accommodate through their prescription, which helps them avoid working their eyes too hard. It also helps to demonstrate to the child that the glasses improve blurry vision. This may allow for adaptation to the feeling of the glasses, as well as the diffraction and peripheral changes that come with moderate to high hyperopic prescriptions.

Extra Bells and Whistles

The optometric oath indicates that we have committed to offering our patients the spectrum of available options for eye care. The average progression of myopia is about 0.50D per year in the school-age group, but that's just an average.² In addition, kids can easily lose or break their glasses. While many ODs consider these good reasons to offer basic packages for kids that include a sturdy, warranted frame and polycarbonate, shatter-resistant lenses, some upgrades might serve the patient better:

- **Anti-reflective coating.** Reducing glare into and off of the lenses may make the difference between good compliance and no compliance. A thorough literature search can help you decide if this age group could benefit from AR coating that blocks blue light. Some blue and ultra-violet light is good when used to help

Would you fit her in a standard diameter contact lens?



Meet Nina.

She has smaller than average size corneas. So if you put her in a standard diameter, the lens will not fit correctly which can compromise her comfort.

Fact is, 27% of patient corneas fall outside the norm. Don't put Nina, and patients like her, in a 'one size fits all' lens. Fit Extreme H2O specialty disposable soft contact lenses.

extremeH2O[®] 13.6

The right fitting solution for your disposable soft lens patients:

- Have small corneas or lid apertures
- Need easy insertion and removal
- Need a comfortable lens

Extreme H2O 13.6 is available in daily, weekly and monthly modalities to match her lifestyle and her pocketbook.

13.6 is just one example of how we cater to your needs. Challenge us to help you protect your contact lens practice. **Call X-Cel Specialty Contacts at 877.336.2482 today.**

DRY EYE DISEASE: NOT ONLY A MEDICAL CONDITION, BUT A QUALITY-OF-LIFE CONDITION!

"I love long bike rides off the beaten path. Eye drops limited my freedom. Occlusion Therapy not only relieved my dry eye symptoms, but eliminated the need for eye drops. The back country is mine again!"¹

VisiPlugs® and LacriPro® Punctum Plugs: For all your dry eye patients!



Lacrimedics

(800) 367-8327

E-mail: info@lacrimedics.com
www.lacrimedics.com

¹Dramatization. Not a real patient.
©2017 Lacrimedics, Inc.

Pediatrics

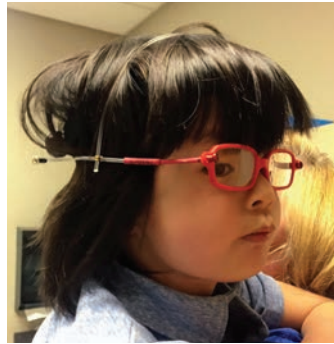

Fig. 4. This four-year-old boy has long hair to hide the absence of ears. Thanks to specialty frames, the glasses fit perfectly on this active boy.

the body manufacture vitamin D and when such high-energy visible light helps boost alertness. Light also influences the circadian rhythm. Some of the eye's components have diurnal variations associated with high lights (like being outside) and low darkness (turning lights out before bed), which seems important in accurate eye growth. On the other hand, excessive use of devices that emit blue

light may affect vision in a less positive way, such as when the eyes are strained from extended use. Blue light has also been shown to suppress melatonin, the hormone that promotes sleepiness, suggesting that blue-light emitting devices used before bed have the potential to impact the body's circadian rhythm.³⁻⁵

- *Trivex lenses.* These are shatter resistant, thinner and lighter—all of which can improve the cosmesis of high prescriptions.
- *Photo-sensitive or prescription sunglasses.* These may seem like an extravagance, but the clear media of the eye in this age group may make childhood the most vulnerable age for sun exposure.

Unique Challenges with Creative Solutions

Kids with special needs and facial features that make for a poor fit with conventional frames present an entirely different set of challenges. You have to get creative and search the best prescribing recommendations to find the life-changing result your patient needs. These cases help illustrate some of the necessary out-of-the-box solutions:

Unilateral trauma. A two-year-old African American female was referred for evaluation following trauma that included a fork to her right eye. This resulted in high anisometropic refractive error post lens extraction. Her left eye had a minimal refractive error, which allowed her good visual function. As such, the patient had been without correction since surgery four to five months prior. Examination determined that she had a refractive error of +15.00D OD.

Polycarbonate spectacles were prescribed for protection of the phakic eye as well as to correct refractive error. A cable temple and a sturdy bridge were chosen to distribute the weight of the high plus spectacles. Because of her

Visit us at
**Vision
Expo West**
Booth #MS10043

SHIFT YOUR PRACTICE INTO HIGH GEAR.



THE BI 900. STANDARD-SETTING OPTICS. IMAGING READY.

Now you can experience true agility in the exam room. Easily shift from a routine slit lamp exam with precision optics to advanced imaging: the BI 900 features a standard imaging port that allows you to add an imaging set either at the time of purchase or at a later date.

See how the BI 900 can smooth out the road ahead for you. Find out more at hsdriven.com.

Take advantage of these current offers:

BI 900 + Free Tonometer
PRICE: \$11,599 (savings of \$4,055)

BI 900 + Imaging Set + Free Tonometer
PRICE: \$15,999 (savings of \$5,077)

800.787.5426

© 2018 Haag-Streit USA. All Rights Reserved.

DRIVEN TO EXCELLENCE

 **HAAG-STREIT
USA**

recent high refractive anisometropia, the patient was instructed to patch her phakic left eye.

With many aphakic patients, our aim is to get them into extended wear contact lenses for best optical benefits. Even with aphakic contact lenses, it is important to maintain polycarbonate spectacle lens over-wear for protection.

Aphakia and micro-ophthalmia. A neonate African American female patient with a history of recent lens extraction and micro-ophthalmia OS presented for a contact lens fit (Figure 3). During her early years, contact lenses will be used to maximize the visual potential OS. But when she is old enough to care about the visible difference in size between her eyes, the power of the contact lens in the aphakic eye can be modified so that a hyperopic polycarbonate lens can be placed in front of the left eye. The result will be relative magnification of the smaller eye to balance the appearance of the size of the eyes.

No earpieces, no problem. A four-year-old Asian male presented with his mother for evaluation of an eye turn that required glasses. The patient, who had been adopted from China at 18 months of age, had no ears. Even when he eventually received ear prosthesis, they would be quite fragile. Without any commercial frames that do not require stabilization with earpieces, custom spectacles were made (Figure 4). The patient's glasses had a plastic cable that vaulted over and behind his head.

Sensory sensitivity vs. spectacles. A six-year-old female with a sensory disorder presented for evaluation after having suffered a concussion. She had never worn spectacles before and was found to have a moderate hyperopic prescription. The patient was currently undergoing occupational therapy to work on wearing shoes, blue jeans, shirts with tags and jackets—all of which were uncomfortable for her. She could not stand to wear the prescribed glasses for more than a few minutes at a time, yet was still symptomatic while reading uncorrected.

We called the patient's occupational therapist and worked together on a plan to increase spectacle wear time. At a follow up visit seven months later, the patient could now wear sandals, blue jeans and glasses for a few hours at a time—a huge step forward. Co-management and communication with the patient and her mother during examination and at dispense turned the challenge of a sensory disorder into a spectacle wear success.

Frame Technologies

Many newer technologies exist to improve spectacle

wear in pediatrics patients, including bendable frames, Flexon metal (Marchon Eyewear), straps behind the head and silicon “keep-ons” to fit behind patients' ears. However, these needs cannot be met without a clinician who is informed about options and knows how the patient can best access these technologies. If you do not serve a large pediatric population, it may not be profitable for you to keep many styles in your optical. Attend local society meetings to find out which opticals near you carry and can fit pediatric and specialty pediatric frames. The exhibition hall at conferences and trade shows can be a great place to browse a high volume of pediatric frames.

Children are not little adults—a truth in the exam room and optical space. If you take the time to get the right pediatric prescription, take the additional time and effort to prescribe the perfect fit. No one ever says, “Wow, that prescription looks great!” Understanding new frames technologies, being smart with lens design and discovering what motivates your patients will allow you to be successful beyond your exam room. Those glasses are not only your walking billboards, they are the springboards to your patients' future successes. ■

Dr. Galt recently completed her residency in pediatric optometry at the University of Alabama at Birmingham (UAB) School of Optometry. She is currently working at a multidisciplinary pediatric private practice in Denver.

Dr. Weise is director of the Pediatric Optometry Service at UAB Eye Care. She served as the Correction of Myopia Evaluation Trial (COMET) investigator, studying nearsightedness in children through the NIH from 1997 to present. She is the co-protocol chair on another NIH-funded trial studying myopia and atropine, and is the team eye doctor for UAB Blazers football.

Ms. Baldwin is a licensed dispensing optician trained at Duke University. She also served as the NIH-funded COMET Optician at UAB for more than 10 years.

1. Walline JJ, Sinnott L, Johnson ED, et al. What do kids think about kids in eyeglasses? *Ophthalmic Physiol Opt.* 2008;28(3):218-24.
2. Gwiazda J, Hyman L, Hussein M, et al. A randomized clinical trial of progressive addition lenses versus single vision lenses on the progression of myopia in children. *Invest Ophthalmol Vis Sci.* 2003 Apr;44(4):1492-500.
3. American Academy of Pediatrics. Council on Communications and Media. Media use in school-aged children and adolescents. American Academy of Pediatrics Policy Statement. 2016. <http://pediatrics.aappublications.org/content/early/2016/10/19/peds.2016-2592>. Accessed July 27, 2018.
4. Heiting G. Blue light: it's both bad and good for you. All About Vision. www.allaboutvision.com/cvs/blue-light.htm. Accessed July 27, 2018.
5. Gringas P, Middleton B, Skene DJ, Revell, VL. Bigger, brighter, bluer-better? Current light-emitting devices – adverse sleep properties and preventative strategies. *Front Public Health.* October 13, 2015. www.frontiersin.org/articles/10.3389/fpubh.2015.00233/full. Accessed July 27, 2018.

For best-in-class lens materials with best-in-class visual performance, we've got you covered.



Lenses made with PPG Trivex[®] material provide kid-tested toughness along with uncompromising visual quality and 100% UV protection, allowing every child to see their best at all times. Protect their eyes today and tomorrow. Recommend TRIVEX lenses this back-to-school season.



How Drug Abuse Affects the Eye

Drug use can be identified from a set of ocular sequelae. Learn to recognize the signs and how to respond with this guide.

By Nicholas Karbach, OD, Natalia Kobrenko, OD, Marc Myers, OD, and Andrew S. Gurwood, OD

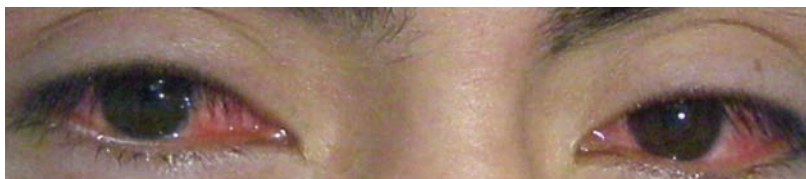It's no secret that Americans are in the midst of a substance abuse crisis.

According to the NIH, more than 33,000 Americans died from opioid overdoses in 2015 alone.¹ That same year, approximately two million Americans suffered from substance abuse disorders related to prescription opioid pain relievers, 591,000 from heroin use alone.² The cost can be devastating, but substance abuse is a modifiable lifestyle factor. As primary care physicians, optometrists can play a role in recognizing damage or dysfunction to either ocular structures or the components of the visual pathway these drugs cause and counseling patients in these circumstances.

This article reviews commonly used legal and illicit substances, and how each are associated with the formation, or exaggeration, of disease or damage.

Caffeine

The average cup of coffee or tea (in the United States) contains between 40mg and 150mg of caffeine.^{3,4} Over-the-counter commercially available caffeine supplements contain between 100mg and 200mg per unit.^{3,4} It is not



This patient displays toxic conjunctivitis secondary to methamphetamine use.

until an individual ingests in excess of 5g of caffeine that toxicity is observed.³

Lid and cornea impact. Excess caffeine is associ-

ated with eyelid myokymia.^{5,6} In animal models, during prenatal development ingested caffeine caused decreased total corneal thickness; it changed the thickness of each corneal layer in chicken embryos via changes in structure and the amount of collagen fibers.^{7,8}

Caffeine consumption increases pupil size and amplitude of accommodation and can even dampen spontaneous pupillary oscillations up to six and a half hours after ingestion.⁹

Glaucoma. Although previous reports indicated that coffee consumption (and by extension, caffeine) raised intraocular pressure (IOP), more recent studies could not elicit a statistically significant change.¹⁰⁻¹⁶ The rise in previous studies was likely secondary to water absorption.^{15,16} In fact, more recent research lauds the potential use of caffeine to decrease ocular hypertension and attenuate neuroinflammatory responses, particularly in reducing the loss of retinal ganglion cells in ocular hypertensives.^{17,18}

Posterior segment. Additionally, caffeine consumption is associated with decreased choroidal thickness at least four hours after ingestion.¹⁹ Highly caffeinated energy drink consumption can cause intraretinal hemorrhages and acute loss of vision, which may be irreversible.²⁰ Similarly, excessive energy drink consumption can lead to transient macular ischemia via choroidal vasoconstriction, which causes bilateral central scotomas.²¹ With the increased frequency of these types of occurrences, these retinal findings have been termed “coffee and donut maculopathy” or “energy drinkers’ maculopathy.”²² With these ocular effects in mind, it is recommended that daily energy drink dosage should not exceed 400mg/day.²³

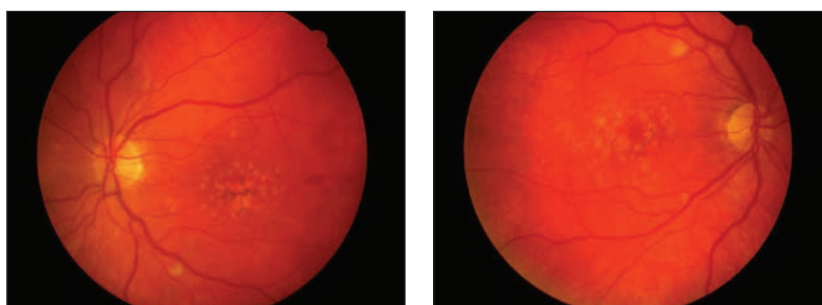
Alcohol

The most commonly abused substance in the United States, alcohol accounts for 3.5% of deaths annually.^{24,25} It should go without saying that excess consumption creates adverse effects which include liver cirrhosis, neurotoxicity and carcinogenesis.²⁵

Macular degeneration. When it comes to ischemic heart disease, alcohol consumption has a J-shaped curve, meaning the dose-risk association shows a clear benefit in moderate drinkers but an increased risk as consumption increases to abusive levels.²⁵ That J-shaped curve applies to age-related macular degeneration (AMD) as well.²⁵ Some studies show a protective effect against AMD in moderate wine drinkers but a 20% increase in the development of AMD when alcohol consumption exceeds three drinks per day.^{25,26} The pathophysiology of this double-edged effect is uncertain, but researchers theorize that the benefit of moderate drinking comes from raised levels of high-density lipoproteins.²⁶

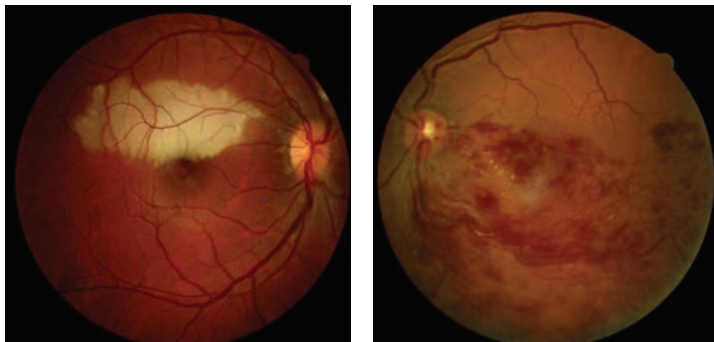
Table 1. Drug Characteristics

Drug	MOA	Route of Admin.	Systemic Effect	Immediate Ocular Effect
Alcohol	Promotes inhibitory neurotransmission	Oral	CNS inhibition	Horizontal gaze-evoked nystagmus
Caffeine	Dopamine, noradrenaline and serotonin release	Oral, topical	CNS stimulation, increased vigilance and metabolic activity	Increased saccadic velocity, myokymia, pupil dilation, increased accommodation, changes in corneal curvature, increased tear production, choroidal thinning, retinal vasoconstriction
Nicotine	Nicotinic acetylcholine agonist	Oral, smoke	Tachycardia, hypertension	Smoke-related dryness, delayed corneal healing, increased cataract progression, increased risk of AMD progression and severity
Marijuana	CB1 and CB2 receptor stimulation	Oral, smoked	Tachycardia, hypertension, psychotropic effects	Decreased IOP, conjunctival injection, decreased saccadic accuracy
Cocaine	Dopamine and norepinephrine potentiation	Injection, inhalation	Euphoria, sympathetic stimulation	Pupillary dilation
Meth	Catecholamine potentiation	Injection, inhalation	Euphoria, increased concentration, sympathetic stimulation	Pupillary dilation, decreased accommodation
Heroin	Opioid receptor stimulation	Injection, inhalation	Analgesia, CNS depression, respiratory depression	Pupillary constriction, exo posture



Macular degeneration, as demonstrated in these fundus images, is associated with the abuse of a number of illicit substances, including alcohol.

Cataract development has been linked to alcohol abuse through a proposed mechanism of metabolic



These eyes display branch retinal artery occlusion. Tobacco use in particular can contribute to problems in the eye's vasculature system.

byproducts such as acetaldehyde which reacts with and modifies lens proteins causing opacification of the crystalline lens.²⁶

Ocular motility disturbance. Alcohol also contains ethanol, a central nervous system depressant, which exerts its effects first on higher-order functions, such as reasoning, judgement and memory, and then on lower-order functions such as speech, gait and balance. As blood alcohol concentration (BAC) increases, multiple cortical structures are implicated including those that control voluntary eye movements.²⁷⁻⁴⁴ Alcohol can decrease maximum saccade velocity by 17% to 19%.²⁸ Smooth pursuits are affected by increased saccadic intrusions. Doll's head eye movements, a reflex originating in the brainstem, remain unaffected.^{26,28} One study shows an alcohol-induced effect on ocular alignment via changes in distance and near phoric deviations.²⁸ Patients with alcohol abuse issues often enter into presbyopia prematurely.²⁹

Optic nerve and neurological impact. 'Tobacco-alcohol amblyopia' is characterized by a central or paracentral scotoma, color vision defects and optic nerve pallor in heavy drinkers and smokers.³⁰ Originally presumed to be caused only by tobacco and alcohol toxicity, it is now known that the dominant pathologic factor is vitamin deficiencies brought about by the nutritional neglect seen in heavy drinkers.³⁰ Wernicke's encephalopathy, a neurological syndrome caused by alcohol abuse, can cause horizontal nystagmus, gaze nystagmus, and disc edema.³¹⁻³³ Fetal alcohol syndrome affects ocular tissues the most and can cause optic nerve hypoplasia, retinal vessel tortuosity, strabismus, saccadic dysfunction, coloboma, microphthalmia and corneal clouding.^{26,34,35}

Tobacco

Cigarette smoke's inflammatory effects can impact both the eye's vasculature and the ocular surface.

Ocular surface and anterior segment. Cigarette smoking increases the risk of dry eye disease (DED), due to the smoke acting as a direct irritant to the eyes.^{36,37} In patients already suffering from DED, smoking increases burning and foreign body sensation.^{37,38} Smoking lowers tear break-up time, lowers mean Schirmer scores, decreases corneal and conjunctival sensitivity and increases punctate staining.^{39,40} Decreased corneal and conjunctival sensitivity is associated with significant loss of goblet cells, squamous metaplasia and altered tear proteins in smokers.^{37,41}

One mechanism responsible for dry eye symptoms is lipid peroxidation of the outer layer of the tear film, leading to tear film instability.⁴⁰ Specifically, lipid peroxidation leads to nonuniform spreading of tears and patchy lipid layer thickening; this, particularly of the nonpolar oils, alters the function of the mucin layer, which makes the corneal surface unwettable.^{37,42}

Cigarette smoking is also associated with delayed corneal epithelial healing, persistent clinical and sub-clinical corneal abrasions and chronic keratitis and progression of Fuchs' endothelial corneal dystrophy.^{39,43,44} Similarly, current smokers have an increased risk of delayed treatment response in episcleritis and scleritis compared to nonsmokers.⁴⁵ The nicotine found in tobacco products is associated with decreased central corneal thickness via increased oxidative burden leading to endothelial cell apoptosis and reduced endothelial function.^{39,43}

Cataracts. Smoking is a strong risk factor for the hastened development of age-related nuclear cataracts in a dose-dependent fashion.⁴⁶⁻⁴⁹ The pathogenesis of cataract formation is hastened via direct oxidative damage, direct toxicity to the lens and reduced antioxidant levels.³⁹

Ocular and systemic issues. Smoking during pregnancy increases risk of poor stereoacuity via interruption of central fusion development in the fetus. It also increases the risk of strabismus; specifically, congenital esotropia and exotropia.^{50,51} Smoking exacerbates Graves' hyperthyroidism and thyroid orbitopathy.^{52,53}

Glaucoma. Smoking is associated with increased IOP and reduced choroidal blood flow, leading to increased resistance to aqueous humor leaving the anterior chamber.^{54,55} Smoking is associated with increased intraocular pressure and increases the risk of primary open angle glaucoma (POAG) compared with former or non-smokers; heavy smokers have significantly

higher risk.^{56,57} Additionally, the course and progression of POAG appears to be hastened by smoking.⁵⁷ This is due to an increased inflammation and apoptosis marker levels in the aqueous humor and plasma. While some evidence supports increased outflow facility secondary to nitric oxide derived from vascular endothelial cell processes, this is offset by decreased trabecular meshwork cell volume.⁵⁸⁻⁶⁰

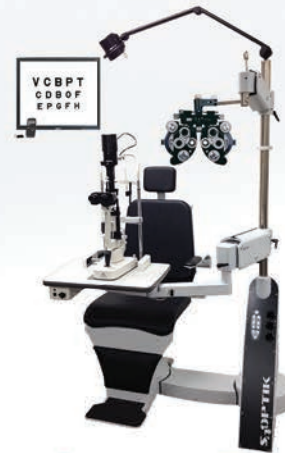Retina. Smoking impedes blood flow directly to the macula and increases inflammation, promoting macular degeneration.^{61,62} Cigarette smoking coupled with a genetic susceptibility increases the risk of AMD synergistically.⁶³ It can also increase the risk of first-time uveitis, bilateral uveitis, panuveitis and idiopathic cystoid macular edema (CME) as well as CME after cataract surgery.⁶⁴ The smoking of *any* substance confers a threefold risk of retinal vein occlusion (RVO) and creates circumstances that provoke or accelerate cardiovascular disease risk.²³ Any patient with an occlusion or RVO should be educated on the cessation of smoking (anything) to prevent comorbidities and further vascular damage.⁴²

Marijuana

A paucity of evidence exists for the direct ocular side effects of cannabis. Marijuana increases sympathetic nervous system activity, increasing heart rate and blood pressure via Delta 9-tetrahydrocannabinol ($\Delta 9$ -THC).⁶⁵ Cannabinoid use is associated with similar ocular signs, including conjunctival hyperemia, chemosis, severe corneal opacification and neurotoxicity.⁶⁶

Glaucoma. Although cannabinoids are effective in reducing IOP, their therapeutic use is precluded due to short duration of action, receptor desensitization and association with behavioral side effects.⁶⁷ There is ongoing research in isolating key active compounds and endocannabinoid receptors in an effort to create an effective therapeutic strategy, while avoiding retinal ganglion cell dysfunction and the functional side effects.^{66,68}

Visual performance. Cannabis has a direct effect on short term memory and eye movements such as decreased saccadic accuracy, and decreased smooth pursuit eye movements, leading to trouble reading, trouble tracking, decreased visual search capabilities, decreased ability to detect peripheral stimuli.⁶⁹ Cannabis use also leads to color discrimination distortions, changes in pupil size, reduced accommodative range, decreased acuity and increased photophobia.^{70,71} Chronic cannabis use is associated with



Exam Lane Packages

Opening a new practice?
Looking to upgrade your equipment?

**Veatch exam lanes are an investment
in your patients, your equipment
and your business.**

Bundled Packages: Save Time and Money

- Visual acuity system
- Manual or Digital Refractor
- Exam chair & stand

The Quality Tools You Need At A Price You Can Afford

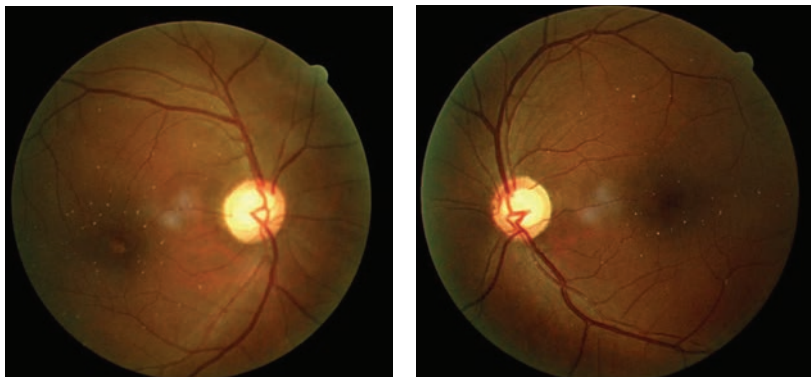
Don't Get Left Behind

IT'S TIME TO GO DIGITAL

Contact Us Today

Veatch Ophthalmic Instruments

www.VOI2020.com | 800.447.7511



Talc retinopathy, as shown in these fundus images, is associated with heroin use.

distortions in depth perception, color discrimination, pattern recognition and visual perception.⁷² Evidence exists both for and against night vision with improvement with cannabinoids.^{70,73,74} Although some studies find decreased dark adaptation abilities, others have found a decreased a-wave amplitude of the full-field electroretinogram in scotopic conditions after acute cannabis inhalation.^{70,73,74}

Cocaine

This drug's primary mechanism of action is inhibition of dopamine reuptake, making it a powerful agent of long term addiction.⁷⁵⁻⁷⁷ With respect to the eye, the immediate effects of cocaine include mydriasis, lid retraction, conjunctival blanching and decreased corneal sensation.^{78,79}

Cornea. Cocaine abuse (whether via smoking or snorting) may lead to a condition called *crack cornea*, a well-reported syndrome of chronic corneal toxicity ranging in severity from mild punctate keratitis to severe bilateral infectious ulcers.^{80,81} Although the mechanism is unknown, it has several known contributors. Snorted cocaine, absorbed through the nasal mucosa, produces bilateral keratitis (worse on the side most frequently used for snorting) secondary to corneal nerve devitalization.⁷⁵ Smoked cocaine makes direct contact with the cornea and acts like most topical anesthetics, softening the cornea and indirectly reducing the blink reflex.^{80,81} Aerosolized adulterants such as talc, sugar, flour, starch or procaine may cause surface damage as well.⁸²

From direct irritation of the ocular surfaces to exposure keratopathy, mechanical damage from rubbing, secondary infectious keratopathy with common or atypical organisms (*Streptococcus mitis*, *Capnocytophaga* and *Candida albicans*), crack smoke has the

potential to create vision-threatening keratopathy.⁸⁰ Management is often made difficult due to problems with compliance and follow up.⁸³ Hospital admission may be helpful to prevent re-use in the acute infection period.⁸⁰

Orbital inflammation. Nasally inhaled cocaine is locally destructive to the nasal mucosa and supporting bony tissues due to vasoconstrictive ischemia and toxic contaminants.⁸⁴ This may lead to bony-destructive focal inflammatory granulomatous lesions as well as recurrent infections, which cause further erosion of the paranasal sinuses orbital tissues.⁸⁴

Inflammatory effects may also create orbital complications on the affected side such as extraocular muscle inflammation, nasolacrimal duct obstruction, orbital apex syndrome, orbital cellulitis, optic neuropathy, optic perineuritis and central retinal vein occlusion (CRVO).^{85,86} Vision loss from optic neuropathy may occur via compressive, infiltrative or ischemic mechanisms.⁸⁶ Neuroimaging shows characteristic bony destruction of the nasal and paranasal sinuses and nasal septum.⁸⁶ Opportunistic infections, such as mucormycosis or bacterial orbital cellulitis, may be visually devastating and life-threatening.⁸⁷

Retinal vasculature. Ocular vascular sequelae from any mode of intake may result from chronic cocaine use secondary to its sympathetic effects created by increased norepinephrine and resulting vasospasm, hypertension and atherosclerosis. Reported retinal vascular complications include central retinal artery occlusion, cilioretinal artery occlusion, intraretinal bleeding and CRVO.⁷⁵ Additionally, cutting agents such as talcum powder (magnesium silicate) can deposit in retinal arterioles after chronic intravenous administration producing embolic sequelae.^{75,78} These particles appear as fine, refractile yellow-white crystals in the inner retinal layers and have been found in patients who inject other illicit substances such as heroin and methylphenidate.^{88,89}

Retinal complications include ischemic atrophy of the inner retinal layers as well as the formation of peripheral retinal neovascularization (sea fans).⁸⁸ Depending on the location of obstruction, this may result in vision loss, vitreous hemorrhage and tractional retinal detachment.⁸⁸ Duration and severity of drug use seems to be the dominant factor in the severity of presentation and complications that arise.⁸⁸

Heroin

Opiates have been used for effective pain relief for millennia.⁹⁰ However, their proclivity for dependence has led to widespread abuse of both prescription and illicit opiate forms.⁹¹

Retina. As with other intravenously administered illicit drugs, talc retinopathy can develop, appearing as small white refractile particles visible on funduscopy, leading to focal retinal ischemia and peripheral retinal neovascularization.³⁴ Similar to cocaine, heroin—when inhaled nasally—can result in inflammation and infection, including fungal mucormycosis.⁹² Other ocular adverse effects of injected heroin are endogenous infectious endophthalmitis and toxoplasmic chorioretinitis.⁹²⁻⁹⁸

Binocular system. While exo posture and pupillary miosis are associated with opioid dependence, opioid withdrawal is associated with eso posture and pupillary mydriasis.⁹⁹⁻¹⁰¹ A comitant acute eso deviation may develop and last for months after detoxification.^{99,100} This finding does not involve cranial nerve VI pathology and is not correlated with a hyperopic shift.^{99,100} There is no accepted mechanism for this; however, some theories assert that overactive accommodative convergence is the driving force (spasm of the near reflex).⁹⁹ This seems to suggest that both opioid use and withdrawal creates a disequilibrium within the accommodative triad of miosis, convergence and accommodation, likely due to the disruption of normal mu opioid receptor activity in the midbrain.^{99,100}

Fetal development. Neonatal abstinence syndrome is a multisystem disorder in infants who experience opioid withdrawal from maternal opioid use. It has strong associations with certain ophthalmic abnormalities including pendular horizontal nystagmus, abnormal visual evoked potential, delayed visual maturation and strabismus.¹⁰²⁻¹⁰⁵

Methamphetamines

Methamphetamine is a strong central nervous system stimulant.¹⁰⁶⁻¹⁰⁹ It increases the amount of dopamine and other catecholamines released by preventing their breakdown and reuptake.^{107,110} Direct sympathetic stimulation induced by methamphetamine causes acute pupillary dilation as well as blurred vision secondary to decreased accommodation.¹⁰⁷

Acute vascular complications may occur with methamphetamine use due to acute blood pressure elevation related to vasospasm and an increased heart rate.^{107,110} This may manifest as hemorrhagic stroke,



The Future Is **Now**
The Ophthalmic Industry
Is Going Digital
And for Good Reason.

1. Greater Efficiency & Accuracy.
2. Large Return on Investment.
3. Increased Capabilities, Integration and Connectivity.

**Focus on the Patient,
Not Repetitive Data Entries**

- Dual cross cylinder
- Programmable sequences
- Wireless interface with pre-test equipment.

Don't Get Left Behind

IT'S TIME TO GO DIGITAL

Contact Us Today

Veatch Ophthalmic Instruments

www.VOI2020.com | 800.447.7511

intracranial hemorrhage, intra-retinal hemorrhage or a non-ischemic optic neuropathy-type presentation.^{106,107,110,111} Methamphetamine use is also associated with episcleritis, scleritis and retinal vasculitis resembling that seen in polyarteritis nodosa.¹⁰⁶

Cornea. Ulceration is prevalent among methamphetamine users due to a variety of possible mechanisms, including the pharmacological effects of the drug, the effects of cutting agents and effects related to the route of administration.^{106,110} Corneal nerves have a high concentration of dopamine receptors and may be target of neurotoxicity mediated by excessive dopamine production.¹⁰⁷ Damage to corneal sensory nerves can result in a neurotrophic keratitis and corneal ulceration.¹¹²

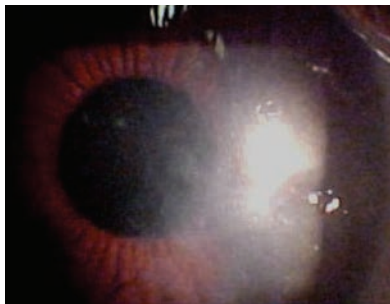
Elevation of the pain threshold during methamphetamine use may decrease the blink reflex and predispose to exposure keratopathy.¹¹⁰ Diluent additives such as lidocaine may further weaken the epithelium and lead to ulceration.¹¹⁰ Nasal inhalation brings methamphetamine into both spatial and circulatory proximity to the eye and may increase the risk of keratitis.¹¹⁰ Compounding the issue, mental effects of the drug such as increased awareness, heightened concentration and irritability result in excessive and harmful rubbing and scratching of the eyelids and ocular surface if symptoms develop.¹¹⁰

Systemic Impact

When an optometrist uncovers a substance abuse disorder with a direct bearing on the patient's ocular and systemic health, the opportunity arises to provide initial counseling and an appropriate referral to a primary care physician or counseling center. Familiarity with the existing local network will be helpful here but the patient's primary care physician or the local emergency room may be the most appropriate referrals depending on the severity of the situation.

Initial counseling can be performed in the exam room and should start with the basics: the patient has a vision-threatening condition with modifiable lifestyle factors. Explaining the connection between their behavior and their vision may strike a chord in the patient's mind and be the catalyst to changing their behavior.

The American Society of Addiction Medicine has nationally established criteria for placement and treat-



Perhaps due to its method of delivery, snorting, cocaine abuse can lead to corneal ulcers, as seen here.

ment of patients with addiction and co-occurring conditions. Emergency room and primary care physicians will be familiar with the particulars of these guidelines and may be the most appropriate referral sites depending on the urgency of the situation.¹¹³ Depending on the severity of their substance abuse disorder, patients can expect an individually tailored treatment plan on the continuum ranging from intensive medical care to outpatient services. ■

Dr. Karbach is a clinical instructor at The Eye Institute, Pennsylvania College of Optometry at Salus University.

Dr. Kobrenko practices at Bucks-Mont Eye Associates and Visionworks.

Dr. Myers is senior staff optometrist at the Coatesville Veterans Affairs Hospital in Pennsylvania.

Dr. Gurwood is a professor at Salus University.

1. Rudd R, Seth P, David F, Scholl L. Increases in drug and opioid-involved overdose deaths—United States, 2010–2015. *CDC Morbidity and Mortality Weekly Report*. 2016;65(50-51):1445–52.
2. Center for Behavioral Health Statistics and Quality. (2016). Key substance use and mental health indicators in the United States: Results from the 2015 National Survey on Drug Use and Health (HHS Publication No. SMA 16-4984, NSDUH Series H-51). Retrieved from www.samhsa.gov/data/.
3. Kerrigan S, Lindsey T. Fatal caffeine overdose: two case reports. *Forensic Sci Int*. 2005;153(1):67–9.
4. Stohs S, Badmaev V. A review of natural stimulant and non-stimulant thermogenic agents. *Phytother Res*. 2016;30(5):732–40.
5. Eyelid Disorders. National Eye Institute. www.nei.nih.gov/faqs/eyelid-disorders-myokymia-twitching-eye. Accessed December 11, 2017.
6. Banik R, Miller N. Chronic myokymia limited to the eyelid is a benign condition. *J Neuroophthalmol*. 2004;24(4):290–2.
7. Kujawa-Hadrys M, Tosik D, Bartel H. Changes in thickness of each layer of developing chicken cornea after administration of caffeine. *Folia Histochem Cytobiol*. 2010;48(2):273–7.
8. Monika K, Dariusz T, Hieronim B. Ultrastructural changes in the developing chicken cornea following caffeine administration. *Folia Histochem Cytobiol*. 2010;48(3):371–6.
9. Abokyi S, Owusu-Mensah, Osei KA. Caffeine intake is associated with pupil dilation and enhanced accommodation. *Eye (Lond)*. 2017;31(4):615–9.
10. Avisar R, Avisar E, Weinberger D. Effect of coffee consumption on intraocular pressure. *Ann Pharmacother*. 2002;36(6):992–5.
11. Pasquale LR, Kang JH. Lifestyle, nutrition, and glaucoma. *J Glaucoma*. 2009;18(6):423–8.
12. Li M, Wang M, Guo W, et al. The effect of caffeine on intraocular pressure: a systematic review and meta-analysis. *Graefes Arch Clin Exp Ophthalmol*. 2011 Mar;249(3):435–42.
13. Kang JH, Willett WC, Rosner BA, et al. Caffeine consumption and the risk of primary open-angle glaucoma: a prospective cohort study. *Invest Ophthalmol Vis Sci*. 2008;49(5):1924–31.
14. Chandrasekaran S, Rochtchina E, Mitchell P. Effects of caffeine on intraocular pressure: the Blue Mountains Eye Study. *J Glaucoma*. 2005;14(6):504–7.
15. Chandra P, Gaur A, Varma S. Effect of caffeine on the intraocular pressure in patients with primary open angle glaucoma. *Clin Ophthalmol*. 2011;5:1623–9.
16. Dervisogullari MS, Totan Y, Yuce A, et al. Acute effects of caffeine on choroidal thickness and ocular pulse amplitude. *Cutan Ocul Toxicol*. 2016;35(4):281–6.
17. Madeira MH, Ambrósio AF, Santiago AR, et al. Caffeine administration prevents retinal neuroinflammation and loss of retinal ganglion cells in an animal model of glaucoma. *Sci Rep*. 2016;6:27532.
18. Boia R, Ambrósio AF, Santiago AR. Therapeutic Opportunities for Caffeine and A2A Receptor Antagonists in Retinal Diseases. *Ophthalmic Res*. 2016;55(4):212–8.
19. Zengin MO, Cinar E, Karahan E, et al. The effect of caffeine on choroidal thickness in young healthy subjects. *Cutan Ocul Toxicol*. 2015;34(2):112–6.
20. Asensio-Sánchez VM. Energy drinks and visual health. *Arch Soc Esp Oftalmol*. 2014;89(11):467.
21. Lofli K, Grunwald JE. The effect of caffeine on the human macular circulation. *Invest Ophthalmol Vis Sci*. 1991;32(12):3028–32.
22. Kerrison J, Pollock S, Bioussé V, et al. Coffee and doughnut maculopathy: a cause of acute central ring scotomas. *Br J Ophthalmol*. 2000;84(2):158–64.
23. Kolar P. Risk Factors for Central and Branch Retinal Vein Occlusion: A Meta-Analysis of Published Clinical Data. *J Ophthalmol*. 2014(6):724780.



Alcohol Threatened My Life, Optometry Saved Me

—Message from an optometrist in recovery

I'm John B. and I'm an alcoholic. I grew up in what I thought was a normal household. I was first exposed to alcohol as a teenager, when I realized my father was an alcoholic, and started drinking myself around 15 years old. When I finally graduated high school (just barely), I enlisted in the Army and did a few tours overseas. I trained to be an airplane mechanic, but in my free time I would binge drink. I returned home a good mechanic and a better drinker. That's when I fell into a deep depression and soothed with at least one bottle daily. This went on for a long time and I started noticing trouble with my vision. So, I set up an appointment with an optometrist.

He asked me about my health and if I smoke, take drugs or use alcohol. I said no. From there he proceeded with rest of the exam and told me I was a little nearsighted but otherwise OK. He seemed like someone I could talk to, and I finally admitted I did drink "once in a while" and asked if that caused my nearsightedness. He said no, but he asked how much I drink a day. I told him a couple of beers (the standard answer) and he laughed and in a good-natured way. The jig was up.

My exam was over, but the doc said, "Let's talk about this for few more minutes." He revealed that he had an alcoholic relative who struggled many years, to the point where he had developed serious medical problems. He was ashamed of his alcoholism, much like I was, and was reluctant to seek help. He finally did, though. "It's never too late," the doctor told me. This interaction turned out to be one of the most important moments of my life. He directed me to a 12-step program that required me to faithfully attend meetings with other alcoholics.

I've been sober now for three years. I have a great job, attend meetings regularly and even reach out to other alcoholics. I know it sounds funny, but an eye doctor actually saved my life! I always wondered if he had special training in optometry school, but all it really took was a little compassion, asking simple questions and being prepared to listen and respond.

24. Perloff BP, Rizek RL, Haytowitz DB, Reid PR. Dietary intake methodology. II. USDA's Nutrient Data Base for Nationwide Dietary Intake Surveys. *J Nutr.* 1990;120(11):1530-4.

25. Madeleine KMA, Chong EW, Williamson E, et al. 20/20—Alcohol and Age-related Macular Degeneration: The Melbourne Collaborative Cohort Study. *Am J Epidemiol* 2012;176(4):289-98.

26. Hiratsuka Y, Li G. Alcohol and eye diseases: a review of epidemiologic studies. *J Stud Alcohol.* 2001;62(3):397-402.

27. Xu L, You QS, Jonas JB. Prevalence of alcohol consumption and risk of ocular diseases in a general population: The Beijing Eye Study. *Ophthalmology* 2009;116(10):1872-9.

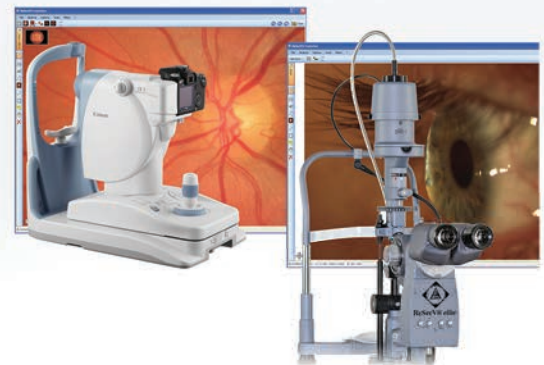28. Wilkinson IM. The influence of drugs and alcohol upon human eye movement. *Proceedings of the Royal Society of Medicine.* 1976;69(7):479-80.

29. Campbell H, Dougherty MJ, Heron G, Ackerley RG. Influence of chronic alcohol abuse and ensuing forced abstinence on static subjective accommodation function in humans. *Ophthalmic Physiol Opt.* 2001;21(3):197-205.

30. Grzybowski A, Holder GE. Tobacco optic neuropathy (TON) - the historical and present concept of the disease. *Acta Ophthalmol.* 2011;89(5):495-9.

31. Day GS, del Campo CM. Wernicke encephalopathy: a medical emergency. *CMAJ: Canadian Medical Association Journal.* 2014;186(8):E295.

32. Manzo G, De Gennaro A, Cozzolino A, et al. MR Imaging Findings in Alcoholic and Nonalcoholic Acute Wernicke's Encephalopathy: A Review. *BioMed Research International.* 2014:503596.



Imaging Solutions:

Serve Your Patients Further

**ReSeeVit: The latest technology,
Built specifically for ophthalmic
professionals**

Leaders of Our Industry

Choose from our suite of imaging solutions, including:

- Anterior segment imaging
- Endothelium cell imaging
- Corneal topography
- Retinal imaging

**Imaging Solutions:
Providing For Your Patients.**

Don't Get Left Behind

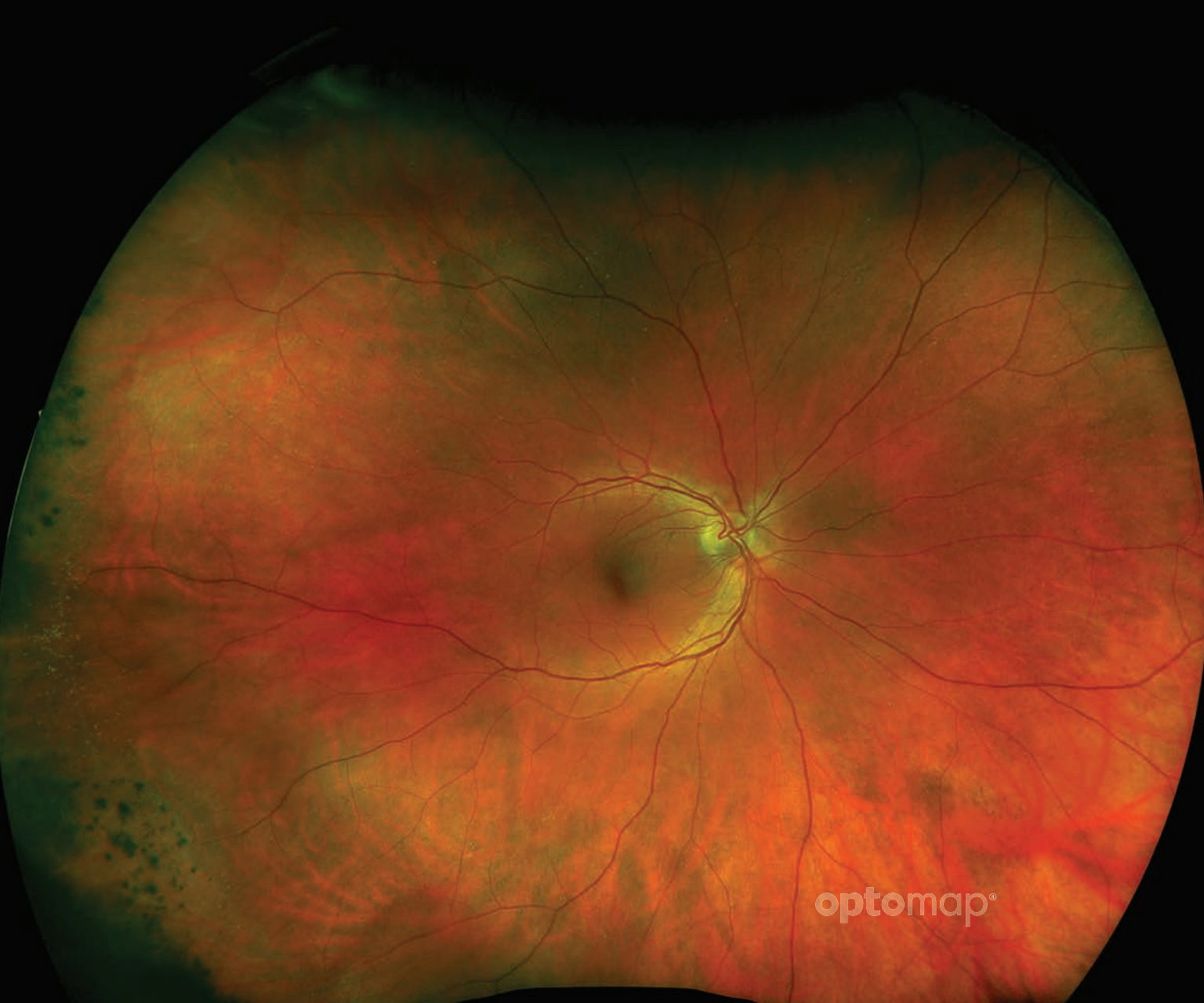IT'S TIME TO GO DIGITAL

Contact Us Today

Veatch Ophthalmic Instruments

www.VOI2020.com | 800.447.7511

33. Thomson AD, Marshall EJ. The natural history and pathophysiology of Wernicke's encephalopathy and Korsakoff's psychosis. *Alcohol and Alcoholism*. 2005;41(2):151-8.
34. Peragallo J, Biousse V, Newman NJ. Ocular manifestations of drug and alcohol abuse. Current opinion in ophthalmology. 2013;24(6):566-73.
35. Brennan D, Giles S. Ocular involvement in fetal alcohol spectrum disorder: a review. *Curr Pharm Des*. 2014;20(34):5377-87.
36. Masmali AM, Al-Shehri A, Alanazi SA, et al. Assessment of Tear Film Quality among Smokers Using Tear Ferning Patterns. *J Ophthalmol*. 2016;11(1):8154315.
37. Altinors DD, Akca S, Akova YA, et al. Smoking associated with damage to the lipid layer of the ocular surface. *Am J Ophthalmol*. 2006;141(6):1016-21.
38. Galor A, Lee DJ. Effects of smoking on ocular health. *Curr Opin Ophthalmol*. 2011;22(6)(11):477-82.
39. Nita M, Grzybowski A. Smoking and eye pathologies. a systemic review. Part I. Anterior eye segment pathologies. *Curr Pharm Des*. 2017;23(4):629-38.
40. Cooke JP. New insights into tobacco-induced vascular disease: clinical ramifications. *Methodist DeBakey Cardiovascular Journal*. 2015;11(3):156-9.
41. Matsumoto Y, Dogru M, Goto E, et al. Alterations of the tear film and ocular surface health in chronic smokers. *Eye*. 2008;22(5):296-301.
42. Xu L, Zhang W, Zhu XY, et al. Smoking and the risk of dry eye: a Meta-analysis. *Int J Ophthalmol*. 2016;9(10):1480-6.
43. Jetton JA, Ding K, Kim Y, et al. Effects of tobacco smoking on human corneal wound healing. *Cornea*. 2014;33(5):453-6.
44. Zoega GM, Fujisawa A, Sasaki H, et al. Prevalence and risk factors for cornea guttata in the Reykjavik Eye Study. *Ophthalmology*. 2006;113(4):565-9.
45. Boonman ZF, de Keizer RJ, et al. Smoking delays the response to treatment in episcleritis and scleritis. *Eye (Lond)*. 2005;19(9):949-55.
46. Klein BE, Klein R, Linton KL, et al. Cigarette smoking and lens opacities: The Beaver Dam Eye Study. *Am J Prev Med*. 1993;9(1):27-30.
47. Theodoropoulos S, Theodosiadis P, Samoli E, et al. The epidemiology of cataract: a study in Greece. *Acta Ophthalmol*. 2011;89(2):e167-73.
48. Ye J, He J, Wang C, et al. Smoking and risk of age-related cataract: a meta-analysis. *Invest Ophthalmol Vis Sci*. 2012;53:3885-95.
49. Wu R, Wang JJ, Mitchell P, et al. Smoking, socioeconomic factors, and age-related cataract: the Singapore Malay Eye Study. *Arch Ophthalmol*. 2010;128(8):1029-35.
50. Torp-Pedersen T, Boyd HA, Poulsen G, et al. In-utero exposure to smoking, alcohol, coffee, and tea and risk of strabismus. *Am J Epidemiol*. 2010;171(8):868-75.
51. Fernandes M, Yang X, Li JY, et al. Smoking during pregnancy and vision difficulties in children: a systematic review. *Acta Ophthalmol*. 2015;93(3)(5):213-23.
52. Xing L, Ye L, Zhu W, et al. Smoking was associated with poor response to intravenous steroids therapy in Graves' ophthalmopathy. *Br J Ophthalmol*. 2015;99(12):1686-91.
53. Schwitzer T, Schwann R, Albusson E, et al. Association between regular cannabis use and ganglion cell dysfunction. *JAMA Ophthalmol*. 2017;135(1):54-60.
54. Kamble G, Rani J, Taranikanti M, et al. Intraocular Pressure in smokers and nonsmokers. *Niger J Physiol Sci*. 2007;22(1-2):33-6.
55. Lee A, Rochtchina, E, Wang J, et al. Does smoking affect intraocular pressure? Findings from the blue mountain study. *J Glaucoma*. 2003;12(3):209-12.
56. Bonovas S, Filioussi K, Trantas A, et al. Epidemiological association between cigarette smoking and primary open-angle glaucoma. *Arch Ophthalmol*. 2003;121(12):256-61.
57. Jain V, Jain M, Abdull MM, et al. The association between cigarette smoking and primary open-angle glaucoma: a systematic review. *Int Ophthalmol*. 2017;37:291-301.
58. Zanon-Moreno V, Garcia-Medina JJ, Zanon-Viguer V, et al. Smoking, an additional risk factor in elder women with primary open-angle glaucoma. *Mol Vis*. 2009;15:2953-9.
59. Dismuke WM, Ellis DZ. Activation of the BK(Ca) channel increases outflow facility and decreases trabecular meshwork cell volume. *J Ocul Pharmacol Ther*. 2009;25(4):309-14.
60. Ellis DZ, Dismuke WM, Chokshi BM. Characterization of soluble guanylate cyclase in NO induced increases in aqueous humor outflow facility and in the trabecular meshwork. *Invest Ophthalmol Vis Sci*. 2009;50(4):1808-13.
61. Marazita M, Dugour, Marquioni-Ramella M, et al. Oxidative stress-induced premature senescence dysregulates VEGF and CFH expression in retinal pigment epithelial cells: Implications for Age-related Macular Degeneration. *Redox Biology*. 2016;7:78-87.
62. Jabbarpoo Bonyadi MH, Yaseri M, Bonyadi M, Soheilani M, Nikkha H. Association of combined cigarette smoking and ARMS2/LOC387715 A69S polymorphisms with age-related macular degeneration: A meta-analysis. *Ophthalmic Genet*. 2017;1:1-6.
63. Schmidt S, Hauser M, Scott W, et al. Cigarette smoking strongly modifies the association of LOC387715 and Age-related macular Degeneration. *Am J Hum Genet*. 2006;78(5):852-64.
64. Thorne JE, Daniel E, Jabs DA, et al. Smoking as a risk factor for cystoid macular edema complicating intermediate uveitis. *American journal of ophthalmology*. 2008;145(5):841-6.
65. Franz CA, Frishman WH. Marijuana Use and Cardiovascular Disease. *Cardiol Rev*. 2016;24(7):158-62.
66. Panahi Y, Manayi A, Nikan M, et al. The arguments for and against cannabinoids application in glaucomatous retinopathy. *Biomed Pharmacother*. 2017;86(2):620-7.
67. Cairns EA, Toguri JT, Porter RF, et al. Seeing over the horizon - targeting the endocannabinoid system for the treatment of ocular disease. *J Basic Clin Physiol Pharmacol*. 2016; 27(3)(5):253-65.
68. Schweitzer KS, Chen SX, et al. Endothelial disruptive proinflammatory effects of nicotine and e-cigarette vapor exposures. *American Journal of Physiology - Lung Cellular and Molecular Physiology*. 2015;309(7):L175-L187.
69. Kleinlog D, Liem-Moolenaar M, Jacobs G, et al. Does olanzapine inhibit the psychomimetic effects of Δ9-tetrahydrocannabinol. *Journal of Psychopharmacology*. 2012;26(10):1307-16.
70. Akano OF. Marijuana Use and Self-Reported Quality of Eyesight. *Optom Vis Sci*. 2017;94(5):630-3.
71. Bardak H, Bardak Y, Ercalici Y et al. Evaluation of the acute changes in objective accommodation, pupil size and ocular wavefront aberrations after cigarette smoking. *Cutan Ocul Toxicol*. 2017;36(1)(3):25-8.
72. Lerner AG, Goodman C, Rudinski D, et al. Benign and time-limited visual disturbances (flashbacks) in recent abstinent high-potency heavy cannabis smokers: a case series study. *Isr J Psychiatry Relat Sci*. 2011;48(1):25-9.
73. Schwitzer T, Schwan R, Laprevote V, et al. Transient Retinal Dysfunctions after Acute Cannabis Use. *Eur Addict Res*. 2016;22(6):287-91.
74. Russo EB, Merzuoki A, Mesa JM, et al. Cannabis improves night vision: A case study of dark adaptometry and scotopic sensitivity in kif smokers of the Rif mountains of northern Morocco. *J Ethnopharmacol*. 2004;93(1)(7):99-104.
75. Mantelli F, Lambiasi A, Sacchetti M, et al. Cocaine snorting may induce ocular surface damage through ocular sensitivity impairment. *Graefes Arch Clin Exp Ophthalmol*. 2015;253(5):765-72.
76. Sanchez-Villarejo MV, López-Pedrajas R, Sanchez-Vallejo V, et al. Chronic cocaine effects in retinal metabolism and electrophysiology: treatment with topiramate. *Curr Eye Res*. 2014;39(5):493-503.
77. Nestler EJ. The Neurobiology of Cocaine Addiction. *Science & Practice Perspectives*. 2005;3(1):4-10.
78. Colatella N, Daniel TE. Crack eye syndrome. *J Am Optom Assoc*. 1999;70(3):193-7.
79. Grzybowski A. Cocaine and the eye: a historical overview. *Ophthalmologica*. 2008;222(5):296-301.
80. Vasconcelos SBD, Guerra FM, Morato GM et al. Acquired anterior staphylocoma after corneal ulcer associated with the use of crack. *Arq. Bras. Oftalmol*. 2016;79(7):4.
81. Miller AD, Sherman SC. Crack eye. *J Emerg Med*. 2009;37(1):75-6.
82. Rabin JG, Rabin LC. Blindness due to illicit use of topical cocaine. *Ann Ophthalmol*. 1979;11(6):863-4.
83. Ghosheh FR, Ehlers JP, Ayres BD, et al. Corneal ulcers associated with aerosolized crack cocaine use. *Cornea*. 2007;26(8):966-9.
84. Lascaratos G, McHugh J, McCarthy K, Bunting H. Advanced cocaine-related necrotising sinusitis presenting with restrictive ophthalmoplegia. *Orbit*. 2016;35(3):164-6.
85. Siemerink MJ, Freling NJM, Saade P. Chronic orbital inflammation disease and optic neuropathy associated with long-term intranasal cocaine abuse: 2 cases and literature review. *Orbit*. 2017;36(5):350-5.
86. Silva-Araújo A, Tavares MA. Development of the eye after gestational exposure to cocaine. Vascular disruption in the retina of rats and humans. *Ann N Y Acad Sci*. 1996;801:274-88.
87. Tran KH, Ilsen PF. Peripheral retinal neovascularization in talc retinopathy. *Optometry*. 2007;78(8):409-14.
88. Zoumalan C, Marmor M. Revisiting Talc Retinopathy. *Arch Ophthalmol*. 2007;125(7):988.
89. Stefano GB, Pilonis N, Ptacek R, Kream RM. Reciprocal Evolution of Opiate Science from Medical and Cultural Perspectives. *Medical Science Monitor: International Medical Journal of Experimental and Clinical Research*. 2017;23(6):2890-6.
90. Weiss RD, Rao V. The Prescription Opioid Addiction Treatment Study: What have we learned. *Drug and Alcohol Dependence*. 2017;173(4):S48-S54.
91. Martín-Moro JG, Calleja JML, Garcia MB, et al. Rhinoorbitocerebral mucormycosis: A case report and literature review. *Med Oral Patol Oral Cir Bucal*. 2008;13(12):E792-5.
92. Doan T, Venulakonda GA, Choi D, et al. Retinal Neovascularization and Endogenous Fungal Endophthalmitis in Intravenous Drug Users. *Ophthalmology*. 2014;121(9):1847-8.
93. Bagheri N, Shahlaee A, Sridhar J, Ho AC, En face optical coherence tomography and angiography of talc retinopathy. *Acta Ophthalmol*. 94(1):103-4.
94. Patel SN, Rescigno RJ, Zarbin MA, et al. Endogenous endophthalmitis associated with intravenous drug abuse. *Retina*. 2014;34(7):1460-5.
95. Maleczak F, Arne JL, Bec P, et al. Candida endophthalmitis after heroin abuse. *Mycopathologia*. 1985;92(2):73-6.
96. Bettendorf BA, Thomson M, Reichstein D, Thomas J. Acute central vision loss in an IV drug user. Poster presented at Midwest Society of General Internal Medicine Meeting. Sept 13, 2013; Chicago, IL.
97. Rabin RL. A Case Report of Nystagmus with Acute Comitant Esotropia Secondary to Heroin Withdrawal: A Novel Presentation. *Case Reports in Ophthalmology*. 2015;6(3):333-8.
100. Firth AY. Heroin and diplopia. *Addiction*. 2005;100(1):46-50.
101. Patrick WB, Welch P, Henningfield JE, Cone EJ. Opiate-induced pupillary effects in humans. *Methods Find Exp Clin Pharmacol*. 1989;11(12):759-63.
102. Kocherlakota P. Neonatal abstinence syndrome. *Pediatrics*. 2014;134(2):e547-e561.
103. Spiteri Cornish K, Hrabovsky M, Scott NW, et al. The short- and long-term effects on the visual system of children following exposure to maternal substance misuse in pregnancy. *Am J Ophthalmol*. 2013;156(1):190-4.
104. Gill AC, Oei J, Lewis NL, et al. Strabismus in infants of opiate-dependent mothers. *Acta Paediatr*. 2003;92(3):379-85.
105. Hamilton R, McGlone L, MacKinnon JR, et al. Ophthalmic, clinical and visual electrophysiological findings in children born to mothers prescribed substitute methadone in pregnancy. *Br J Ophthalmol*. 2010;94(6):696-700.
106. Hazin R, Cadet JL, Kahook MY, Saed D. Ocular manifestations of crystal methamphetamine use. *Neurotox Res*. 2009;15(2):187-91.
107. Wijaya J, Salu P, Leblanc A, Bervoets S. Acute unilateral visual loss due to a single intranasal methamphetamine abuse. *Bull Soc Belge Ophtalmol*. 1999;271:19-25.
108. Charukamnetkanok P, Wagoner MD. Facial and ocular injuries associated with methamphetamine production accidents. *Am J Ophthalmol*. 2004;138(5):875-6.
109. Lai H, Zeng H, Zhang C, et al. Toxic Effect of Methamphetamine on the Retina of CD1 Mice. Current eye research. 2009;34(9):785-90.
110. Poulsen EJ, Mannis MJ, Chang SD. Keratitis in methamphetamine abusers. *Cornea*. 1996;15(9):477-82.
111. Wallace RT, Brown GC, Benson W, Sivalingham A. Sudden retinal manifestations of intranasal cocaine and methamphetamine abuse. *Am J Ophthalmol*. 1992;114(2):158-60.
112. Semeraro F, Forbice E, Romano V. Neurotrophic keratitis. *Ophthalmologica*. 2014;231(4):191-7.
113. The ASAM Criteria. Resources. American Society of Addiction Medication. www.asam.org/resources/the-asam-criteria/about. Accessed April 26, 2018.



optomap®

▶ **optomap®** Images beyond the vortex vessels
in less than half a second

the ONLY 200° single-capture image

Visit us at booth 6051

or contact us for your risk-free evaluation at 800-854-3039 or BDS@optos.com



A Nikon Company



Building *The* Retina Company

optos.com

Optometry CE Study Center



The CE You Need In 2018!

As low as
\$17.50
per Credit Hour

Buy just one 2-hour course for \$35 or buy as many as you need

Choose from over 50 individual CE courses

Includes the hard to find topics that fulfill your state requirements

All available in a convenient online format

Purchase Now!

www.reviewsce.com

The CE Study Center courses have been developed in conjunction with expert faculty from leading schools of optometry and are oriented toward clinical practice issues that are designed to assist eye care professionals in serving their patient's healthcare needs. CE Courses also appear in print monthly in Review of Optometry.

1-800-825-4696 • INFO@REVIEWSCE.COM

These COPE-Accredited CE courses are administered in partnership with an accredited school of optometry.



2 CE
Credits
(COPE approved)



SLAYING THE GIANT CELL ARTERITIS

Uncover the symptoms of this deadly condition and know how to help manage the patient. **By Trenton Cleghern, OD**

Giant cell, temporal or cranial arteritis is a systemic vasculitis involving mainly the medium-to-large arteries of the head and neck. The condition can affect blood vessels elsewhere in the body, but tends to involve the cranial and ophthalmic arteries. Giant cell arteritis (GCA) is an autoimmune condition of unknown etiology. It is the most common systemic vasculitis seen in adults.¹ GCA occurs in adults older than 70 and has a wide variety of symptoms and complications.² It is of particular interest to eye care providers due to its potential for

visually devastating complications, such as rapidly progressing bilateral blindness.

Temporal arteritis is a topic that is introduced as early as the first or second year in an optometric curriculum because of its dire, and potentially deadly, consequences. The condition can present in a variety of ways, making diagnosis a challenge. Patients may present with only systemic symptoms, or only ocular symptoms. This article focuses on the clinical presentation of GCA. This condition can simply never be missed—for the sake of the patient's vision and life.

The Basics

We know that GCA is a condition of older adults and that it is extremely rare to occur before age 50.² Research places the average age of diagnosis approximately 72 to 77 years.² Age is actually the greatest risk factor, though the risk does rise after age 50.² Similar to other autoimmune disease, the risk of developing GCA is more common in women, with a ratio of three to one, women to men.⁷ Temporal arteritis is also more common in Caucasian individuals, especially those from Scandinavian countries or of Scandinavian descent. The

Release Date: September 15, 2018

Expiration Date: September 15, 2021

Goal Statement: Giant cell arteritis is a rare, but urgent and potentially life-threatening, presentation that can have ocular consequences. This course details how to tell which patients are likely to have it based on their history and symptoms as well as how to test for it using both imaging and lab work, and reviews the optometrist's role in treating and comanaging these patients. It also details likely comorbidities.

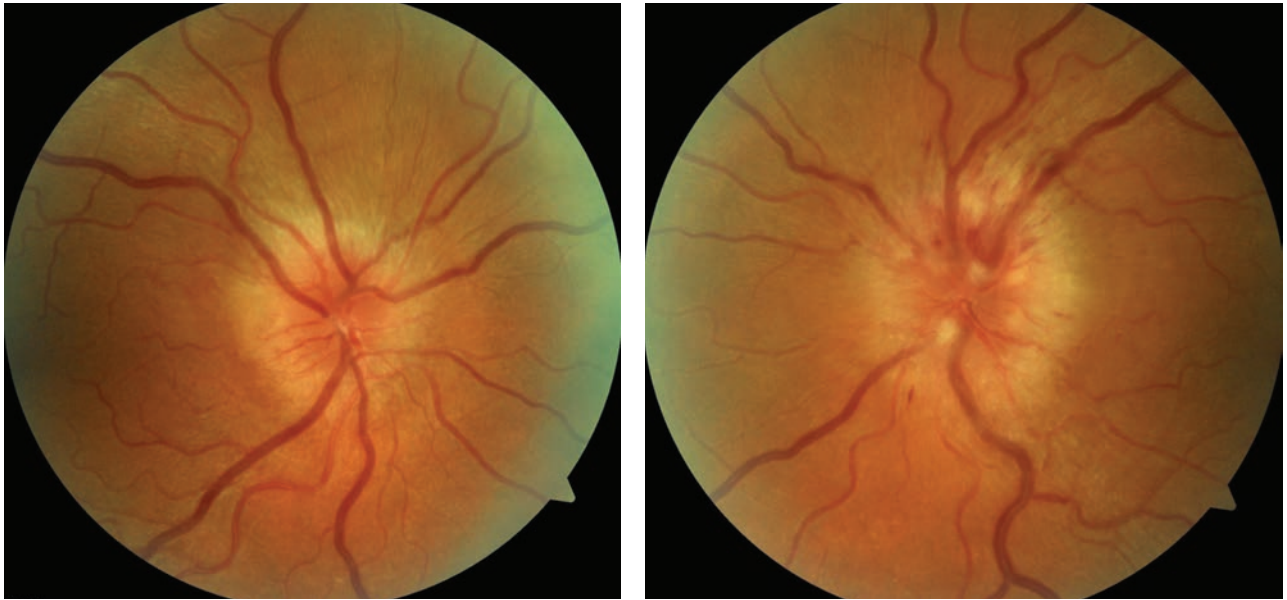
Faculty/Editorial Board: Trenton Cleghern, OD

Credit Statement: This course is COPE approved for 2 hours of CE credit. Course ID is **59139-NO**. Check with your local state licensing board to see if this counts toward your CE requirement for relicensure.

Disclosure Statements:

Authors: The author has no relationships to disclose.

Editorial staff: Jack Persico, Rebecca Hepp, William Kekevan, Catherine Manthorp and Mark De Leon all have no relationships to disclose.



Optic nerve photos of a 65-year-old Caucasian patient with bilateral disc edema, headache and scalp tenderness. Presentations such as this warrant immediate steroid therapy and blood work.

disease is rare in black and Asian populations. It was once thought to be rare in Hispanic populations, but some recent evidence has questioned that notion.³

GCA is a systemic autoimmune vasculitis with an unknown origin. It is typically a medium and large vessel disease, but may also affect small vessels. When larger vessels, such as the carotid, subclavian or aorta are affected, it is referred to as *large-vessel GCA*.⁴ Immune cells made of mostly T-lymphocytes and macrophages invade the arterial wall.⁵ Granulomatous changes can then occur, leading to the formation of giant cells. This causes vascular remodeling of the inner vessel wall in the form of hyperplasia. The remodeled lumen can become occluded, which is the cause of the ischemic events in GCA. The disease process likely occurs from an inciting event in a susceptible individual.

Many environmental and microbial origins have been proposed, including the herpes zoster viruses, but none have been found to have a causal relationship.^{6,7}

Patients with GCA can present with a variety of symptoms, creating a diagnostic challenge. Patients may present to an eye care provider with only vision complaints, or may present to a general practitioner with only systemic complaints. Of course, the patient may have both ocular and systemic complaints. The patient's symptoms can either be acute or subacute, but tend to be more subacute.⁷ The most common systemic symptoms in GCA are headache, scalp tenderness, neck/shoulder/pelvic pain, fatigue, malaise, weight loss, jaw claudication and fever (*Table 1*).⁸

Systemic Symptoms

Headache is the most common symptom in GCA.⁸ No pathogeno-

monic features are associated with the headache in GCA, except that the complaint is new. If a patient has chronic headaches, the patient would describe a new type of headache. The pain is usually temporal, occipital or diffuse. Headaches are usually constant in GCA patients, but may wax and wane. Patients may describe the headache as throbbing, boring, dull or even burning.

Even though headache is the most common symptom, patients need to be specifically questioned because they may not associate the headache with other symptoms.⁸ The headache should resolve rapidly after the institution of oral or intravenous steroids. When the headache does not resolve after initial steroid treatment, other etiologies must be investigated.

Table 1. Most Commonly Reported Symptoms in GCA

Symptom	Initial	Throughout Course of Disease
Headache	33%	72%
Neck/torso/pelvic pain	25%	58%
Fatigue and malaise	20%	56%
Jaw claudication	4%	40%
Fever	11%	35%

Seetharaman M. Giant Cell Arteritis (Tempoeral Arteritis) Clinical Presentation. Medscape. emedicine.medscape.com/article/332483-clinical.

Scalp tenderness is sometimes included as part of the headache complaint. However, its presence can indicate an inflamed superficial temporal artery. Even light touches, such as brushing one's hair or putting on spectacles, can elicit pain over this area. The superficial temporal artery should be palpated in patients in whom you have suspicion for temporal arteritis, even if the patient makes no complaint of scalp tenderness.

GCA patients may also complain of neck, shoulder, torso or hip girdle pain. Affected patients may have fatigue, weight loss or malaise. Constitutionally, they will seem very poor in most cases. Generally, GCA patients look and feel very ill. In my experience, it's unlikely these patients will sit in your exam chair with a cheerful disposition. Jaw claudication, or pain after prolonged chewing, is a result of ischemia of the maxillary artery, which provides blood flow to the masseter muscles in the jaw. Jaw or tongue claudication, visual abnormalities and temporal artery abnormalities are the highest specific clinical features. When compared with other symptoms, jaw claudication had the highest association with a positive temporal artery biopsy.⁹ Patients need to be specifically questioned about jaw claudication, because again they might not associate their jaw symptoms with their presenting complaint.

Fever is a non-specific symptom that GCA patients will sometimes experience. Interestingly, one study

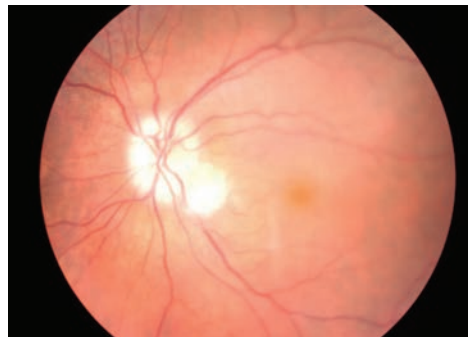


Photo: Steven Bloom, MD

This optic nerve image shows retinal ischemia consistent with AAION, the most common cause of vision loss from GCA.

found that one in six fevers in older adults with an unknown etiology were from temporal arteritis.¹⁰

Other, less common systemic symptoms include: maxillary pain, facial swelling, tongue or throat pain, dysarthria, hearing loss, limb claudication, stroke, carpal tunnel syndrome and pericarditis.^{7,11} In large-vessel GCA, aortitis, aortic dissection and aortic aneurysm are possible complications. Large artery GCA, compared with cranial arteritis, tends to affect patients at a younger age, produce fewer headache symptoms and are less likely to have a positive temporal artery biopsy.¹²

Ocular Symptoms

Approximately half of GCA patients experience visual symptoms over the course of the condition.¹³ Vision loss can be transient or constant, unilateral or bilateral. The vision loss is usually painless, although the patient may complain of pain elsewhere, such as headache, scalp tenderness or other body aches. Patients may have actual ocular pain as well

from associated ocular ischemia. The patient may experience transient vision loss. Sudden, persistent loss of vision is often irreversible. Vision loss in the fellow eye can occur in a significant portion of patients.¹³ The second eye can become involved in one to two weeks, but it can happen sooner.⁶ Once corticosteroid therapy has been initiated, new or further vision loss is fairly rare.

The most common cause of vision loss in GCA is from arteritis anterior ischemic optic neuropathy (AAION) at around 80% of cases.⁶ AAION is the result of vessel occlusion of the short posterior ciliary arteries or ophthalmic artery. Other causes of vision loss include central retinal artery occlusion (CRAO), branch retinal artery occlusion (BRAO), posterior ischemic optic neuropathy (PION) and cerebral ischemia. CRAO accounts for about 10% of vision loss in GCA.⁶ If a patient at least 55 years of age presents with bilateral CRAO, or unilateral CRAO with no vascular risk factors, a GCA investigation should be included in the work-up. BRAO and PION are rare causes of vision loss in GCA.⁶ Cerebral ischemia from GCA occurs because of infarction in the vertebrobasilar circulation.

Another symptom of temporal arteritis patients, although rare, is diplopia. About 5% of patients may have diplopia from either sixth or third nerve palsies.¹³ Sixth nerve palsy with GCA is slightly more common than third nerve.¹³ This occurs from ischemia to either the muscles, cranial nerves or even the brain stem. When encountering an older patient with an isolated sixth or third nerve palsy, inquire about GCA-related symptoms.

Clinical Evaluation

GCA patients can present clinically in a variety of scenarios. The clinician must be able to perform a

Table 2. Erythrocyte Sedimentation Rate Norms

Men	Women
Age/2	(Age + 10)/2
Younger than age 50: less than 15mm/hour	Younger than age 50: less than 20mm/hour
Older than age 50: less than 20 mm/hour	Older than age 50: less than 30mm/hour

Examination Tips

When an adult older than 55 presents with optic nerve edema, question them thoroughly about systemic symptoms including headache, scalp tenderness, jaw claudication, aches, fatigue and fever. Never ignore headache complaints. Temporal arteritis patients may only experience systemic complaints, but ocular involvement can occur later. A laboratory work-up should be initiated as soon as possible. However, steroids should not be withheld to obtain laboratory tests beforehand. In these cases, always evaluate both eyes, even if the complaints are monocular. This goes without saying, but the appearance of the fellow optic nerve can be quite helpful in distinguishing non-arteritic AION from arteritic AION.

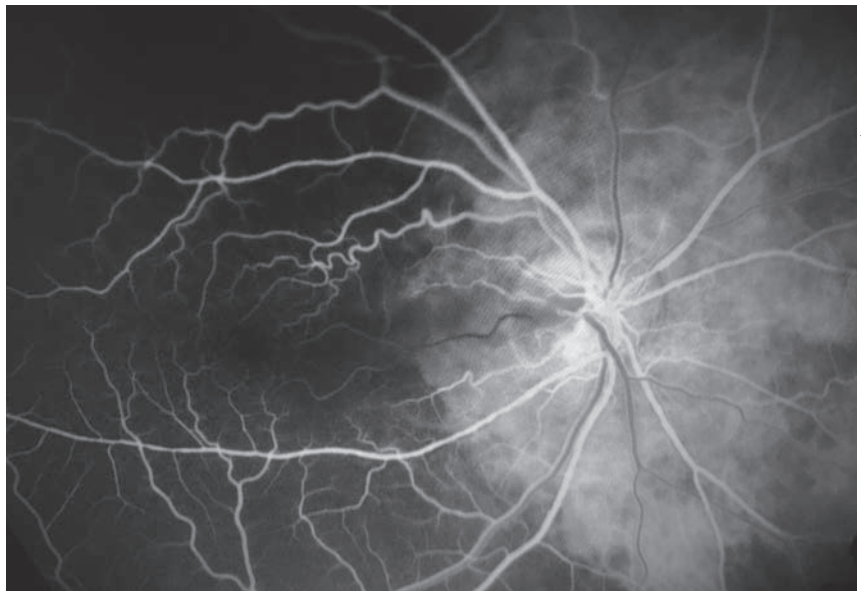

Photo: Kristin Madonna, MD

This fluorescein angiography of a GCA patient shows choroidal ischemia temporally, optic nerve leakage and cilioretinal artery occlusion.

thorough and detailed examination if temporal arteritis is suspected. Reduced acuity is a concerning finding because of the high likelihood of permanent vision loss.⁵ The extraocular motilities and cover test must be performed to evaluate for a sixth or third nerve palsy. This is a rare finding, but isolated cranial nerve palsies without any other ophthalmic signs of GCA have been reported.⁷ Pupil assessment is paramount to look for a relative afferent pupillary defect (RAPD). If both nerves are affected, there may not be an RAPD. In this scenario, the pupils may be sluggish to react to light depending on the optic nerve involvement. Color vision may be affected due to the damaged optic nerves, so this should be included in the work-up.

Visual fields, optical coherence tomography (OCT) and fundus photos are helpful to obtain during the evaluation. Visual field defects in GCA can vary and could be altitudinal, diffuse or enlarged blind spots. It is imperative to obtain a visual field to assess for any field loss, and

to have as a baseline. When optic nerve edema is present, OCT of the retinal nerve fiber layer is clinically useful to obtain objective data. It is easy to observe optic nerve edema using the slit lamp, but an OCT of the optic nerve provides a quantitative value to monitor for progression. As with visual fields and OCT, fundus photographs of the optic nerve and posterior pole should be obtained to monitor for progression.

Nearly all the ophthalmic findings in GCA are in the posterior segment; however, anterior segment ischemia can be present, as well as cells and flare in the anterior chamber. Ocular ischemic syndrome is a rare but documented sequela from GCA.¹³ If ocular ischemic syndrome is present, patients may manifest neovascularization of the iris, anterior chamber inflammation and elevated IOP.¹⁸ Potential posterior segment findings include optic disc edema, CRAO, retinal hemorrhages and cotton wool spots.¹⁷ The disc edema in AAION is sometimes described as “chalky white.”¹⁶ This term refers to the pallor that can happen quickly in the

disease process, sometimes in as little as a few weeks. Cotton-wool spots may be present as a result of severe ischemia. Retinal hemorrhages associated with the disc edema typically emanate from the optic nerve in a radial pattern. If a CRAO is present with concurrent optic nerve edema, GCA is likely.

Lab Work

Blood testing plays a large role in the evaluation of patients suspected to have GCA. The two main lab tests to aid in the diagnosis are the erythrocyte sedimentation rate (ESR) and C-reactive protein (CRP). A complete blood count (CBC) can also be extremely helpful. The hallmark laboratory finding in GCA is an elevated ESR and CRP.⁵ Both the ESR and CRP are acute phase reactants that the body produces in reaction to infection or inflammation. The ESR is measured in millimeters per hour (mm/hour) and the CRP is measured in milligrams per liter (mg/L). Neither are specific to GCA, but when both are elevated, the sensitivity and specificity is greatly increased.

Polymyalgia Rheumatica

This systemic autoimmune disease causes shoulder and hip girdle pain. About 50% of GCA patients also have polymyalgia rheumatica (PMR), and around 10% to 15% of PMR patients develop GCA.⁷ The epidemiology mirrors that of GCA. Controversy exists as to whether GCA and PMR are separate diseases or different manifestations on a spectrum of the same disease. PMR responds well to low-dose corticosteroids and a rapid response is considered pathognomonic.

For patients who do not respond to steroids, another diagnosis should be considered. The prognosis is excellent, but relapses can happen if steroids are tapered too quickly. Any patient with PMR with complaints of loss of vision, headache, scalp tenderness, jaw claudication or fever need to be urgently investigated for GCA.

Biousse V, Newman NJ. Ischemic optic neuropathies. *N Engl J Med*. 2015;372(25):2428-36.

A significant number of patients can have a positive temporal artery biopsy with a normal ESR and CRP.¹⁴ In a study of 167 biopsy-proven GCA patients, the ESR was less than 50mm/hour in 11% of patients and less than 40mm/hour in 5%.¹⁴ A normal ESR and CRP does not rule out GCA, but an elevated ESR and CRP raises the likelihood of having the condition. A CBC can reveal a normochromic normocytic anemia, as well as an elevated platelet count. The liver enzymes, alkaline phosphatase and aspartate aminotransferase can be elevated in some GCA patients, but are not routinely ordered in clinical practice.

ESR is age- and gender-dependent (Table 2). The CRP is not age or gender specific. A CRP under 10mg/L is considered normal.

Since GCA cannot be excluded based on a normal ESR and CRP, a temporal artery biopsy is necessary for diagnosis. This biopsy is standard for diagnosing GCA. Patients

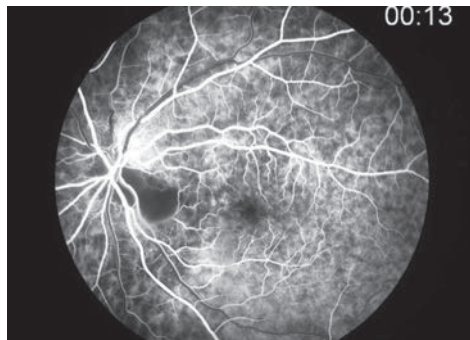


Photo: Steven Bloom, MD

Fluorescein angiography for GCA patients typically shows delayed choroidal and central retinal artery filling, with possible choroidal non-perfusion, especially in the peripapillary area.

suspected of having GCA should be referred to a neuro-ophthalmologist or oculoplastic surgeon for a biopsy. If these disciplines are not available, facial plastic surgeons, vascular surgeons or neurosurgeons can perform the biopsy.

It is important to order the temporal artery biopsy because GCA requires prolonged treatment with oral corticosteroids or immunosuppressants for six to 18 months. Keep in mind, temporal artery biopsies can produce false negatives due to “skip lesions.” Therefore, a 1.5cm to 2cm biopsy should be obtained to avoid these skip areas of the artery. Another diagnostic option for GCA is color duplex ultrasonography (CDUS). Scanning the head, neck and upper extremities with CDUS is noninvasive and can provide information on arteries other than the temporal artery. However, at this time more research needs to be done to determine the effectiveness of CDUS, and thus temporal artery biopsy remains the standard.

Long-term Management

When you have an older adult patient with suspicion of GCA, clinicians should not hesitate to start oral steroid therapy. A laboratory work-up should be initiated as soon as possible. However, steroids should

not be withheld to obtain laboratory tests or temporal artery biopsy beforehand. At our clinic, we employ the “shoot first and ask questions later” philosophy with temporal arteritis. It is better to start oral steroid therapy and soon discover that is not GCA than to withhold steroids and have the patient suffer devastating vision loss. Of course, we are judicious to ascertain that GCA is a legitimate concern due to the serious adverse effects of oral steroid therapy.

High-dose oral steroids can elicit significant side effects, but they are usually minimal during a short duration. In our practice, we typically prescribe 80mg of prednisone to be taken as four 20mg tablets in one dose. Steroid therapy can also be given intravenously followed by an oral taper.

In true temporal arteritis, patients will sometimes need steroid therapy for six to 18 months, so they are most appropriately managed by neuro-ophthalmology or rheumatology long-term. Somewhat recently, the immunosuppressant drug, Actemra (tocilizumab, Genentech), has emerged as an option for GCA patients.¹⁴ In many cases, it is not ideal for patients to be on steroids for over a year, so that is where immunosuppressant drugs may play a future role in GCA treatment.

While GCA patients are best managed by neuro-ophthalmology or rheumatology, it is optometry’s responsibility as the primary eye care providers to recognize and treat these patients in the initial presentation of the condition. GCA suspects require a shoot-first-ask-questions-later approach. It is better to start oral steroid therapy and soon discover that is not GCA, than to withhold steroids and see patients suffer devastating vision loss. ■

Dr. Cleghern is a staff optometrist at VisionAmerica of Birmingham in Alabama and an assistant clinical professor at University of Alabama at Birmingham School of Optometry.

1. Kermani T, Schäfer VS, Crowson CS, et al. Increase in age at onset of giant cell arteritis: a population-based study. *Ann Rheum Dis.* 2010 Apr;69(4):780-1.
2. Biouesse V, Newman NJ. Ischemic optic neuropathies. *N Engl J Med.* 2015;372(25):2428-36.
3. Cid M, Campo E, Ercilla G, et al. Immunohistochemical analysis of lymphoid and macrophage cell subsets and their immunologic activation markers in temporal arteritis. *Influence*

- of corticosteroid treatment. *Arthritis Rheum.* 1989;32(7):884-93.
4. Brack A, Martinez-Taboada V, Stanson A, et al. Disease pattern in cranial and large-vessel giant cell arteritis. *Arthritis Rheum.* 1999;42(2):311-7.
5. Gonzalez-Gay MA, Barros S, Lopez-Diaz MJ, et al. Giant cell arteritis: disease patterns of clinical presentation in a series of 240 patients. *Medicine (Baltimore).* 2005;84(5):269-76.
6. Seetharaman M. Giant cell arteritis (Temporal Arteritis) clinical presentation. Medscape. emedicine.medscape.com/article/332483-clinical-presentation. July 11, 2017. Accessed July 30, 2018.
7. Docken W, Rosenbaum J. Clinical manifestations of giant cell arteritis. www.uptodate.com/contents/clinical-manifestations-of-giant-cell-arteritis. December 8, 2017. Accessed July 30, 2018.
8. Gabriel S, O'Fallon W, Achkar A, et al. The use of clinical characteristics to predict the results of temporal artery biopsy among patients with suspected giant cell arteritis. *J Rheumatol.*

- 1995;22(1):93-6.
9. Knockaert D, Vanneste L, Bobbaers H. Fever of unknown origin in elderly patients. *J Am Geriatrics Soc.* 1993;41(11):1187-92.
10. Bhatti M, Frohman L, Neshor G. MD roundtable: diagnosing giant cell arteritis. *EyeNet.* 2017;21(6):31-4.
11. Waldman C, Waldman S, Waldman R. Giant cell arteritis. *Med Clin North Am.* 2013;97(2):329-35.
12. Salvarani C, Hunder G. Giant cell arteritis with low erythrocyte sedimentation rate: frequency of occurrence in a population-based study. *Arthritis Rheum.* 2001;45(2):140-5.
13. Hayreh S, Podhajsky P, Zimmerman B. Ocular manifestations of giant cell arteritis. *Am J Ophthalmol.* 1998;125(4):509-20.
14. FDA approves Roche's Actemra/RoActemra (tocilizumab) for giant cell arteritis. Roche. www.roche.com/media/releases/med-cor-2017-05-23.htm. May 23, 2017. Accessed July 30, 2018.

OSC QUIZ

You can obtain transcript-quality continuing education credit through the Optometric Study Center. Complete the test form and return it with the \$35 fee to: Jobson Medical Information, Dept.: Optometric CE, 440 9th Avenue, 14th Floor, New York, NY 10001. To be eligible, please return the card within one year of publication. You can also access the test form and submit your answers and payment via credit card at *Review of Optometry* online, www.reviewofoptometry.com/ce.

You must achieve a score of 70 or higher to receive credit. Allow four weeks for processing. For each Optometric Study Center course you pass, you earn 2 hours of transcript-quality credit from Pennsylvania College of Optometry and double credit toward the AOA Optometric Recognition Award—Category 1.

Please check with your state licensing board to see if this approval counts toward your CE requirement for relicensure.

1. In which of the following patient populations would GCA be found most commonly?
 - a. Hispanic.
 - b. Caucasian.
 - c. African American.
 - d. Asian.
2. Which of the following arteries can GCA affect?
 - a. Subclavian.
 - b. Aorta.
 - c. Carotid.
 - d. All of the above.
3. What is the most commonly reported systemic symptom of GCA?
 - a. Headache.

- b. Jaw claudication.
- c. Body aches.
- d. Fever.

4. Which of the following symptoms was found to have the highest association with a positive temporal artery biopsy?
 - a. Vision loss.
 - b. Headache.
 - c. Scalp tenderness.
 - d. Jaw claudication.

5. Which clinical finding is considered almost pathognomonic for GCA?
 - a. AION.
 - b. Tongue infarction.
 - c. Unilateral headache.
 - d. Neck or shoulder pain.

6. Which of the following is not a recognized ophthalmic complication of GCA?
 - a. CRAO.
 - b. Choroidal ischemia.
 - c. Facial nerve palsy.
 - d. Sixth nerve palsy.

7. Approximately what percentage of GCA patients experience visual symptoms over the course of the disease?
 - a. 10%.
 - b. 25%.
 - c. 50%.
 - d. 90%.

8. The most common cause of vision loss in patients affected by GCA is:
 - a. AION.
 - b. CRAO.
 - c. CRVO.
 - d. Stroke.

9. Which of the following statements about the ESR laboratory test is false?
 - a. It is age-dependent.
 - b. It is gender-dependent.
 - c. It is specific to GCA.
 - d. A patient can have GCA but have a normal ESR.

10. Which of the following battery of tests should be ordered for patients suspected of GCA?
 - a. ESR, CRP, CBC.
 - b. ESR, CBC, ANA.
 - c. CRP, CBC, ANA.
 - d. CRP, CBC, RF.

11. The normal ESR values in a 65-year-old male would be:
 - a. Less than 5mm/hour.
 - b. Less than 10mm/hour.
 - c. Less than 20mm/hour.
 - d. Less than 35mm/hour.

12. The standard for diagnosing GCA is:
 - a. ESR/CRP.
 - b. CBC.
 - c. Color duplex ultrasonography.
 - d. Temporal artery biopsy.

13. Which of the following conditions has a strong association with GCA?
 - a. Diabetes mellitus.
 - b. Polymyalgia rheumatica.
 - c. Rheumatoid arthritis.
 - d. Sjögren's syndrome.

14. Which of the following statements about GCA is true?
 - a. It is the most common systemic vasculitis in adults.
 - b. Men are more commonly affected.

OSC QUIZ

- c. The greatest risk factor is diet.
- d. Patients usually have concurrent rheumatoid arthritis.

15. The hallmark of polymyalgia rheumatica is:

- a. Jaw claudication.
- b. Headache.
- c. Rapid response to steroids.
- d. Neck pain.

16. What is the defining feature of headaches in GCA patients?

- a. New headache.
- b. Occipital.
- c. Worse in the morning.
- d. Do not respond to steroids.

17. Which is false regarding large-vessel GCA as compared to cranial arteritis?

- a. Tends to affect younger patients.
- b. The aorta is commonly affected.
- c. Higher likelihood of having a positive temporal artery biopsy.
- d. Produces fewer headache symptoms.

18. The vision loss in GCA can usually be described by all of the following characteristics except:

- a. Sudden.
- b. Painful.
- c. Symptoms of flashes and floaters.
- d. Can be constant or transient.

19. Which of the following procedures or tests would be the least helpful in the investigation of GCA?

- a. Lab work.
- b. Color duplex ultrasonography.
- c. Temporal artery biopsy.
- d. MRI of the brain.

20. What is the etiology of GCA?

- a. Viral.
- b. Bacterial.
- c. Environmental trigger.
- d. The exact cause is unknown.



TAKE THE TEST ONLINE TODAY!
[www.reviewofoptometry.com/
continuing_education/](http://www.reviewofoptometry.com/continuing_education/)

Examination Answer Sheet

Slaying The Giant Cell Arteritis

Valid for credit through September 15, 2021

Online: This exam can be taken online at www.reviewofoptometry.com/ce. Upon passing the exam, you can view your results immediately and download a real-time CE certificate. You can also view your test history at any time from the website.

Directions: Select one answer for each question in the exam and completely darken the appropriate circle. A minimum score of 70% is required to earn credit.

Mail to: Jobson Medical Information, Dept.: Optometric CE, 440 9th Avenue, 14th Floor, New York, NY 10001.

Payment: Remit \$35 with this exam. Make check payable to Jobson Medical Information LLC.

Credit: This course is COPE approved for 2 hours of CE credit. Course ID is 59139-NO.

Sponsorship: This course is joint-sponsored by the Pennsylvania College of Optometry.

Processing: There is a four-week processing time for this exam.

Answers to CE exam:

- 1. (A) (B) (C) (D)
- 2. (A) (B) (C) (D)
- 3. (A) (B) (C) (D)
- 4. (A) (B) (C) (D)
- 5. (A) (B) (C) (D)
- 6. (A) (B) (C) (D)
- 7. (A) (B) (C) (D)
- 8. (A) (B) (C) (D)
- 9. (A) (B) (C) (D)
- 10. (A) (B) (C) (D)
- 11. (A) (B) (C) (D)
- 12. (A) (B) (C) (D)
- 13. (A) (B) (C) (D)
- 14. (A) (B) (C) (D)
- 15. (A) (B) (C) (D)
- 16. (A) (B) (C) (D)
- 17. (A) (B) (C) (D)
- 18. (A) (B) (C) (D)
- 19. (A) (B) (C) (D)
- 20. (A) (B) (C) (D)

Post-activity evaluation questions:

Rate how well the activity supported your achievement of these learning objectives:
1=Poor, 2=Fair, 3=Neutral, 4=Good, 5=Excellent

21. Understand how to identify the likely suspects for giant cell arteritis. (1) (2) (3) (4) (5)

22. Recognize the clinical presentations associated with giant cell arteritis. (1) (2) (3) (4) (5)

23. Craft a work-up protocol for suspected giant cell arteritis patients. (1) (2) (3) (4) (5)

24. Understand how and when to use steroids in suspected cases of giant cell arteritis. (1) (2) (3) (4) (5)

25. Understand the mechanism by which giant cell arteritis can lead to vision loss. (1) (2) (3) (4) (5)

26. Develop a plan to partner with other physicians and follow-up. (1) (2) (3) (4) (5)

Rate the quality of the material provided:

1=Strongly disagree, 2=Somewhat disagree, 3=Neutral, 4=Somewhat agree, 5=Strongly agree

27. The content was evidence-based. (1) (2) (3) (4) (5)

28. The content was balanced and free of bias. (1) (2) (3) (4) (5)

29. The presentation was clear and effective. (1) (2) (3) (4) (5)

30. Additional comments on this course:

Please retain a copy for your records. Please print clearly.

First Name

Last Name

E-Mail

The following is your: Home Address Business Address

Business Name

Address

City State

ZIP

Telephone # - -

Fax # - -

By submitting this answer sheet, I certify that I have read the lesson in its entirety and completed the self-assessment exam personally based on the material presented. I have not obtained the answers to this exam by any fraudulent or improper means.

Signature _____ Date _____

Lesson 117083

RO-OSC-0918



Third Time's the Charm?

Two graft failures later and a patient is running out of options.

Edited by Joseph P. Shovlin, OD

Q I have a 32-year-old keratoconus patient who has already had two graft failures following full thickness grafting on the left eye. He has some peripheral neovascularization circumferentially, but it is not excessive. Is there any new information on minimizing the risk of repeated graft failures to help avoid a third?

A Corneal transplant surgery is considered the most successful organ transplant procedure, with 86% of grafts surviving their first year, says Scott G. Hauswirth, OD, of the Ocular Surface Center at the University of Colorado School of Medicine.¹ However, high-risk corneal transplant patients—those who have two or more quadrants of corneal neovascularization or have experienced a previous graft rejection—have a five-year success rate of less than 35%, he notes.^{2,3} Assuming this patient experienced two previous graft failures due to graft rejection—immune-mediated destruction of the corneal endothelium—he would be classified as a high-risk corneal transplant patient.

Corneal graft failure is widely defined as an unresponsive graft edema with a loss of graft clarity, notes Mitch Ibach, OD, of Vance Thompson Vision.⁴ Causes of graft failure are either immune-mediated or non-immune-related, which include primary donor failure, endothelial decompensation, glau-

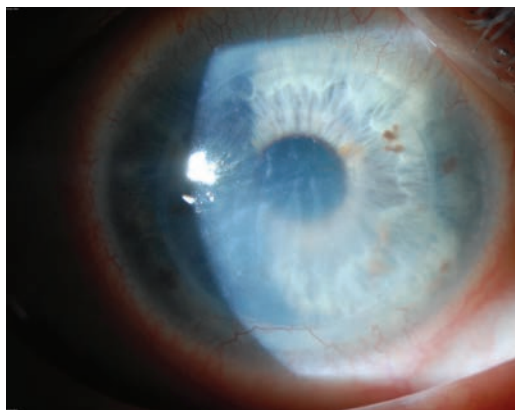


Photo: Christopher Ranuano, MD

This patient is experiencing graft rejection, an immune-mediated cause of graft failure.

coma, corneal melt, corneal ulcer, exposure keratitis and ocular surface disease, says Dr. Hauswirth.⁵

High Risk, Low Odds

While the odds are not in his favor, this patient has a few options, including an endothelial keratoplasty (EKP) and a Boston keratoprosthesis (KPro) Type I. EKP quickly recovers best-corrected acuity, has a lower risk of transplant rejection and does not require extensive suture removal, according to Dr. Ibach. If the area over the visual axis is mildly edematous but free of neovascularization and scar formation, Dr. Hauswirth recommends performing a Descemet's stripping endothelial keratoplasty. He says replacing the endothelium may help clear the cornea to restore vision and is less invasive than a repeat penetrating keratoplasty (PKP). In addition to the presence of scar tissue, Dr.

Hauswirth notes it is important to consider the posterior topography of the graft, which may affect adhesion of the endothelial lenticle.⁶

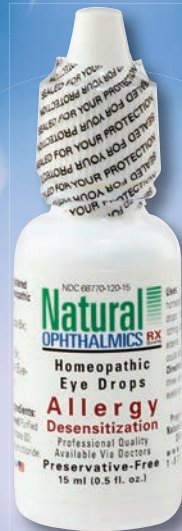Prior graft failure is one of the leading reasons for Boston KPro Type I use, according to Dr. Hauswirth.⁷ Retention and success rates with the Boston KPro have increased, he notes; a study suggests that the chances of maintaining vision better than 20/200 and a clearer graft were greater with a

Boston KPro than a repeat PKP.⁸ Dr. Hauswirth says patients receiving a Boston KPro, however, must be carefully monitored for glaucoma and maintain topical antibiotic use and contact lens wear to reduce the risk of corneal melt.⁷

Medicate, Monitor and Hope

An emerging treatment for patients with advancing corneal neovascularization, which increases the risk of graft rejection, is to use anti-vascular endothelial growth factor agents such as Avastin (bevacizumab, Genentech), topical drops and subconjunctival injections, according to Dr. Ibach.⁹ He adds that administering Avastin before performing a PKP on a patient with progressing neovascularization is prudent for graft survival. A study evaluating 50 eyes that received Avastin subconjunctival injections immediately following PKP found that 70% of the grafts

***“Show me a
better ALLERGY
eye drop!”***



Natural Ophthalmics Allergy Desensitization Eye Drops

- OK with contacts
- Works fast/
feels great
- Desensitization
- No side effects
- No suppression
- Safe for
children
- Tear film
stimulation
- Use PRN
- No rebound
or dryness
- Affordable

***Try a Dozen Bottles on
your toughest allergy patients***

(12 bottles @ \$6.39 ea = \$76.68)
Includes FREE full line trial pack worth \$60
100% money back guarantee to your patient

Call today: 877-220-9710



Natural
OPHTHALMICS **RX**
Quality

www.NaturalEyeDrops.com

survived during the three years of follow-up.¹⁰

Immunosuppression plays another key role in improving the chances of graft survival in high-risk corneal transplant patients, according to Dr. Hauswirth. A survey of Cornea Society members found that, to suppress the immune response in high-risk patients, respondents preferred using either Pred Forte (prednisolone acetate 1.0%, Allergan) or Maxidex (dexamethasone 0.1%, Novartis) six to eight times per day for eight months as the postoperative regimen.¹¹ Oral cyclosporine, oral tacrolimus and Cellcept (mycophenolate mofetil, Genentech)—which suppresses dendritic cell maturation, reduces antibody formation and induces T-lymphocyte apoptosis—also prolong graft survival but require monitoring, says Dr. Hauswirth.¹²⁻¹⁸

Survival of the Fittest

To further improve the chances of graft survival, it is important to prevent rejection episodes, avoid intraocular pressure (IOP) spikes and fend off microbial keratitis, says Dr. Ibach. He suggests clinicians regularly apply topical ste-

roids if IOP issues do not present. In the event of an acute rejection episode, Dr. Ibach notes that aggressive topical and oral steroids can reverse the corneal edema and immune reaction.

He also recommends clinicians use aqueous suppressants when treating a corneal transplant patient with steroid-induced IOP spikes. Finding the balance between using topical steroids for graft health and glaucoma drops to lower IOP can be a struggle; Dr. Ibach encourages clinicians to exercise caution when dealing with carbonic anhydrase inhibitors and prostaglandin analogs to avoid harming the endothelial cells.

He adds that microbial keratitis is a threat throughout the life of the graft. For better outcomes, he notes that patients should be treated prophylactically with topical antibiotics immediately after surgery. Due to the presence and removal of sutures, however, epithelial breakdown and infection are still possible, according to Dr. Ibach.

While clinicians can take several steps to minimize the risk of graft failure, this patient has already had two, and, unfortunately, his next corneal graft almost assuredly will not be his last, says Dr. Ibach. This highlights the importance of educating the patient on signs and symptoms of graft rejection and failure so both patient and provider can work together to monitor and manage the graft appropriately. ■




Photo: Mitch Ibach, OD

This patient has an acute corneal graft rejection and a Khodadoust line, both of which could lead to graft failure.

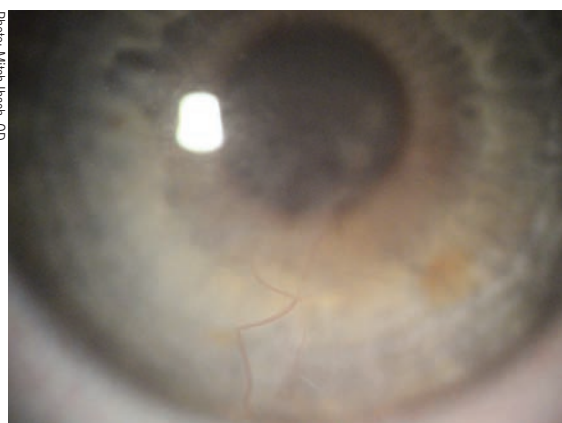

Photo: Mitch Ibach, OD

Here is a patient with deep stromal neovascularization before being treated with Avastin subconjunctival injections.

1. Williams KA, Esterman AJ, Bartlett C, et al. How effective is penetrating corneal transplantation? Factors influencing long-term outcome in multivariate analysis. *Transplantation*. 2006;81(6):896-901.
2. The collaborative corneal transplantation studies (CCTS). Effectiveness of histocompatibility matching in high-risk corneal transplantation. The Collaborative Corneal Transplantation Studies Research Group. *Arch Ophthalmol*. 1992;110(10):1392-403.
3. Abud TB, Di Zazzo A, Kheirkhah A, et al. Systemic immunomodulatory strategies in high-risk corneal transplantation. *J Ophthalmic Vis Res*. 2017;12(1):81-92.
4. Kelly TL, Williams KA, Coster DJ, et al. Corneal transplantation for keratoconus: a registry study. *Arch Ophthalmol*. 2011;129(6):691-7.
5. Price MO, Thompson RW Jr, Price FW Jr. Risk factors for various causes of failure in initial corneal grafts. *Arch Ophthalmol*. 2003;121(8):1087-92.
6. Anshu A, Price MO, Price FW Jr. Descemet's stripping endothelial keratoplasty under failed penetrating keratoplasty: visual rehabilitation and graft survival rate. *Ophthalmology*. 2011;118(11):2155-60.
7. Saeed HN, Shanbhag S, Chodosh J. The Boston keratoprosthesis. *Curr Opin Ophthalmol*. 2017;28(4):390-6.
8. Ahmad S, Mathews PM, Lindsley K, et al. Boston type I keratoprosthesis versus repeat donor keratoplasty for corneal graft failure: a systematic review and meta-analysis. *Ophthalmology*. 2016;123(1):165-77.
9. The Australian Corneal Graft Registry. 1990 to 1992 report. *Aust N Z J Ophthalmol*. 1993;21(2 Suppl):1-48.
10. Dekaris I, Gabri N, Dra A, et al. Three-year corneal graft survival rate in high-risk cases treated with subconjunctival and topical bevacizumab. *Graefes Arch Clin Exp Ophthalmol*. 2015;253(2):287-94.
11. Kharod-Dholakia B, Randleman JB, Bromley JG, et al. Prevention and treatment of corneal graft rejection: current practice patterns of the Cornea Society (2011). *Cornea*. 2015;34(6):609-14.
12. Hill JC. Systemic cyclosporine in high-risk keratoplasty. Short-versus long-term therapy. *Ophthalmology*. 1994;101(1):128-33.
13. Shimazaki J, Den S, Omoto M, et al. Prospective, randomized study of the efficacy of systemic cyclosporine in high-risk corneal transplantation. *Am J Ophthalmol*. 2011;152(1):33-9.
14. Joseph A, Raj D, Shanmuganathan V, et al. Tacrolimus immunosuppression in high-risk corneal grafts. *Br J Ophthalmol*. 2007;91(1):51-5.
15. Sloper CM, Powell RJ, Dua HS. Tacrolimus (FK506) in the management of high-risk corneal and limbal grafts. *Ophthalmology*. 2001;108(10):1838-44.
16. Allison AC, Eugui EM. Mechanisms of action of mycophenolate mofetil in preventing acute and chronic allograft rejection. *Transplantation*. 2005;80(2 Suppl):S181-90.
17. Birnbaum F, Mayweg S, Reis A, et al. Mycophenolate mofetil (MMF) following penetrating high-risk keratoplasty: long-term results of a prospective, randomised, multicentre study. *Eye (Lond)*. 2009;23(11):2063-70.
18. Reinhard T, Reis A, Böhringer D, et al. Systemic mycophenolate mofetil in comparison with systemic cyclosporine A in high-risk keratoplasty patients: 3 years' results of a randomized, prospective trial. *Graefes Arch Clin Exp Ophthalmol*. 2001;239(5):367-72.

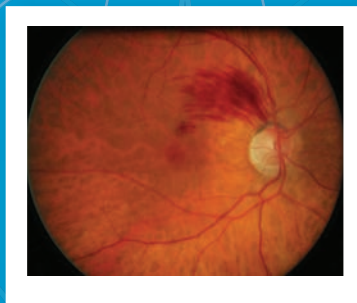

“Acuity Pro grows with us”
 - Vicki Leung, OD



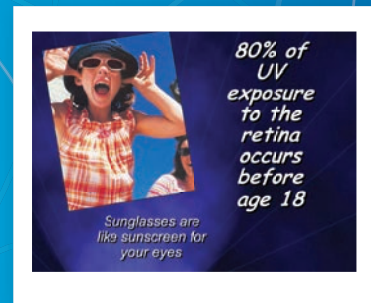INCREASE REFRACTION SPEED AND ACCURACY

- Instantly change charts and randomize optotypes.
- Instantly switch from multi-row to single row to shorter single row.
- Create macros to customize sequences.



INCREASE SPEED OF PATIENT EDUCATION

Acuity Pro was the first digital chart to incorporate patient education libraries for rapidly switching from acuity testing to patient education. We include 50 common pathology images. You can add as many as you wish.



BRAND & MARKET YOUR PRACTICE FROM THE CHAIR

Educate while they wait. Our 200 included practice and product promotion slides are just the beginning. Create custom slides that speak to your patient population and promote your specialties and social media presence.

SLOAN / SNELLEN / NUMBERS / CONTRAST SENSITIVITY / HOTV / ALL ETRS CHARTS / WHITE ON BLACK OPTION / VIDEO LIBRARY / SINGLE LETTER - SINGLE LINE - MULTI-LINE / 56 KEY CUSTOM REMOTE / MARCO INTEGRATION / INFINITE OR LIMITED RANDOMIZATION OPTIONS / ALL IN ONE SYSTEMS OR SOFTWARE ONLY / FREE SUPPORT/ NO ANNUAL FEES

DISASTER PROOF BY DESIGN - 580.243.1301 / ACUITYPRO.COM



USED ON BOARD THE INTERNATIONAL SPACE STATION AND IN OVER 20 COUNTRIES ON EARTH

VISIT US AT BOOTH MS5058 AT VEW



The Many Hats of Herpes

This virus can present in a variety of ways. Here, we enumerate them.

By David Schaeffer, OD, Natalie Townsend, OD, and Richard Mangan, OD

A 58-year-old African-American male presented to the clinic complaining of hazy vision in his left eye for three weeks. He was seen in urgent care two weeks prior and was diagnosed with an acute anterior uveitis in the left eye. He was prescribed 1% prednisolone acetate every two hours and 1% atropine twice daily.

At presentation, his best-corrected visual acuity (BCVA) was 20/20 OD and 20/40 OS. The left pupil was pharmacologically fixed, and there was no afferent pupillary defect seen in either eye. A slit lamp exam of the left eye revealed a dendritic corneal ulcer with central fluorescein staining and mild underlying anterior stromal edema without infiltration (*Figure 1*). The anterior chamber was deep and quiet. Iris was dilated and without atrophy. Corneal sensitivity was absent with cotton wisp in the left eye and present in the right. Preauricular nodes were not palpable. Dilated fundus exam and intraocular pressures (IOPs) were normal and equal.

We diagnosed him with herpes simplex epithelial keratitis (HEK) and prescribed him oral acyclovir 400mg five times a day for 10 days and explained that he needed to taper the prednisolone rapidly, starting QID for two days then decreasing by one drop every two days.

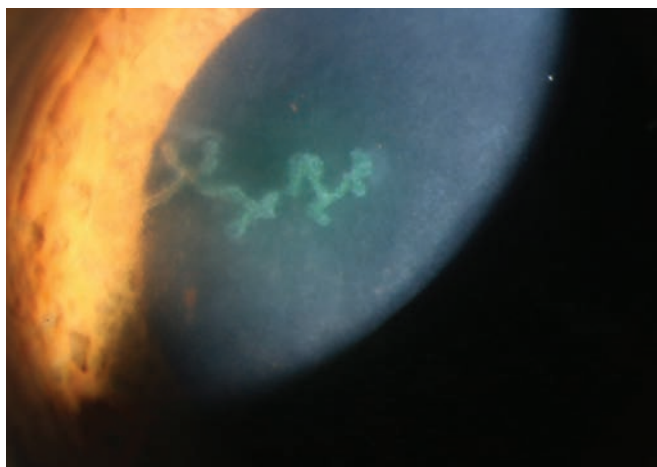


Fig. 1. This patient demonstrates active herpetic dendrite as seen using sodium fluorescein staining.

Hazed and Confused

This patient was seen three times over the following two weeks. His epithelial defect closed and his vision improved to 20/25 with correction. The anterior chamber remained quiet after the prednisolone had been discontinued. One week after completing the oral acyclovir, the patient reported hazy vision in his left eye. His acuity was 20/25, but a slit lamp exam revealed a focal disciform area of stromal edema with bullae and underlying keratic precipitates localized to the area of swelling (*Figure 2*). No stromal neovascularization or infiltrate was noted.

The anterior chamber was quiet. IOP was normal and equal. On dilated examination, the vitreous and fundus were normal.

The diagnosis of herpes simplex endotheliitis was made, and the patient was restarted on topical 1% prednisolone acetate QID in the left eye and oral acyclovir 400mg five times a day for another 14 days, then BID after that.

Table 1. Suggested Treatment Guidelines⁴

Condition	Antiviral	Topical Steroid
Dendritic Keratitis	Topical—therapeutic, then prophylactic for 7 days after ulcer healed	Contraindicated
	Oral—therapeutic for 7-10 days	
Geographic Keratitis	Topical—therapeutic, then prophylactic for 7 days after ulcer healed	Contraindicated
	Oral—enhanced therapeutic for 14-21 days	
Endotheliitis	Oral—therapeutic for 7-10 days, then prophylactic	4-8x/day Taper as indicated
Iridocyclitis	Oral—therapeutic for 7-10 days, then prophylactic	4-8x/day Taper as indicated

The patient's previous records noted two separate incidences of herpetic eye disease, a dendrite in 2010 and keratouveitis in 2011 with treatment the corneal findings resolved and BCVA returned to 20/20. Acyclovir was continued at prophylactic dosing 400mg BID.

Discussion

For a patient to present with three distinct anterior segment manifestations of herpes simplex virus (HSV) in such a short period is atypical, but it makes for a great review of some of the different ways ocular HSV can present and is treated. For brevity, this discussion will only focus on some anterior segment conditions; however, it is imperative that clinicians perform a dilated fundus exam in any urgent case to rule out posterior involvement.

HSV is the most common infectious cause of blindness in the developed world.¹ Risk factors for HSV activation or recurrence include stress, ultraviolet exposure, trauma, menstruation and illness.^{1,2} Herpetic eye disease (HED) is typically unilateral and recurrent in the same eye. Patients with history of atopy, immune-compromise or immunosuppression can present with bilateral or more recurrent herpetic disease.²

Ocular manifestations of HSV are typically presumptive and diagnoses are made on clinical exam.³ Most conditions likely represent a combination of viral activity and host immune response.¹ Confirmatory tests exist but are typically not performed because they are costly, impractical or unreliable.² Methods include cytology, culture or polymerase chain reaction of tissue scraping or AC paracentesis.⁴ Basic serology is of limited value as many are latently infected by HSV.¹

Treatments are prescribed empirically based on clinical presentation.

Presentations

Herpes simplex uveitis. Acute anterior uveitis (AAU) is usually idiopathic and does not warrant diagnostic testing. HSV accounts for up to 10% of all AAU.¹⁻³ Suspicion of HSV uveitis increases in the presence of iris stromal atrophy, elevated IOP, diffuse keratic precipitates (KP) or history of recurrent uveitis or other herpetic disease in the same eye.^{1,3} Hyphema can be present in up to 12% of cases, and corneal manifestations of HSV may precede or follow uveitis.^{2,5} Differential diagnosis for HSV uveitis includes other causes of uveitis, including sarcoidosis, tuberculosis, Fuchs' heterochromic iridocyclitis (FHI), Possner-Schlossman syndrome (PSS) and cytomegalovirus (CMV).^{1,2}

Herpes simplex epithelial keratitis. HEK accounts for up to two-thirds of HED and presents as an ulceration

LOMBART VALUE LANE PACKAGE

~~\$13,995~~
\$13,595
LIMITED TIME OFFER



- ✓ LOMBART CS-5 Instrument Stand & Exam Chair
- ✓ Topcon SL-2G Slit Lamp
- ✓ Topcon VT-10 Refractor
- ✓ LOMBART CVSe Acuity System

ASK US ABOUT
QUICK DELIVERY!

EXPIRES 9/30/18 | USE CODE: CS5SALE

CALL US TODAY AT 1.800.LOMBART

whose center stains with sodium fluorescein and edges with rose bengal.^{6,7} Depending on the time of presentation, ulcers can be punctate, linear, dendritic or geographic.⁶ Ulceration is exacerbated by steroid use. HEK resolves on its own in 25% of cases, but can leave scarring, corneal hypoesthesia or both.^{6,7} Differentials for HEK can include neurotrophic or other infectious ulcers.

Herpes simplex endotheliitis. This form can present as a focal or diffuse area of stromal edema with KPs underlying the area. Mild anterior chamber reaction, elevated IOP, or both, may be present or absent.^{4,7} Studies and epidemiology on this specific condition are limited, as it has been included as a subset of herpes stromal keratitis (HSK) in the past though is now considered a distinct entity.^{4,8} Differentials for HSV endotheliitis include CMV endotheliitis, FHI and PSS.

Treatment

The goal of therapy is to preserve vision, alleviate pain and prevent morbidity (Table 1). Both topical and oral antivirals are available, and the choice between topical and oral is determined on a case-by-case basis.

The safety profile of oral acyclovir and valacyclovir is excellent—they are well tolerated long-term and are listed as pregnancy category B.^{4,7} However, adjusted dosing is necessary for patients with renal disease.^{4,7} Topical 1% trifluridine can cause corneal toxicity, and treatment should not exceed 21 days. Topical Zirgan (0.15% ganciclovir gel, Bausch + Lomb) does not show similar toxicity as trifluridine, but long-term studies are limited.⁴ While oral agents demonstrate good corneal penetration and therapeutic aqueous humor levels, available topicals do not. Topical 3% acyclovir ointment shows good penetration and aqueous levels, but is not available in the United States.^{4,9} So far, no evidence

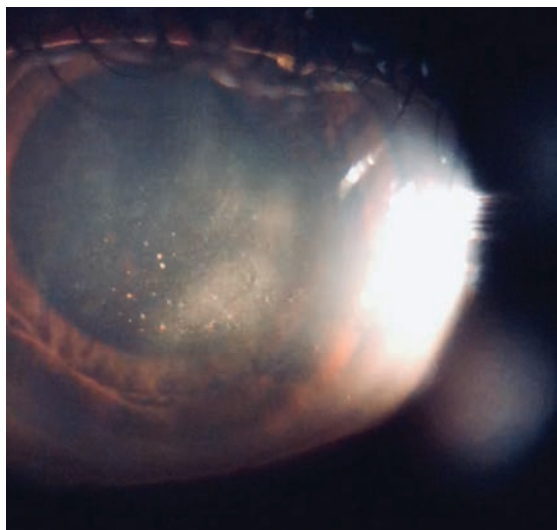


Fig. 2. Here the patient demonstrates disciform herpes endotheliitis.

suggests combined topical and oral antiviral treatment is superior to a single treatment method alone.^{4,9}

HEK can be treated with topical antivirals (Table 2). Oral antivirals are technically off label for HEK, but research shows therapeutic oral dosing is equivalent to topical treatment (Table 3).⁶ For geographic ulcers, enhanced therapeutic dosages are indicated.⁴

Adding epithelial debridement with antiviral treatment is not superior to antiviral alone, according to the literature.⁶ Debridement with placement of an amniotic

membrane may be an alternative when antivirals are contraindicated or compliance is poor.¹⁰

For HSV iridocyclitis, or any keratitis other than HEK, oral antivirals are preferred over topical for superior penetration and long-term use. Start them before initiating steroids.^{4,7}

The Herpetic Eye Disease Study (HEDS) suggests that therapeutic oral antiviral dosing, when added to topical steroid regimen, might be beneficial for treating HSV iridocyclitis, though the study sample was small.^{9,11} With endotheliitis, therapeutic dosing and topical steroids are recommended.¹² For both conditions, steroids are tapered slowly over a month or longer to avoid rebound inflammation.^{3,4}

Cycloplegics aid to prevent iris synechiae.^{1,4} Topical hypotensives can control elevated IOP, but IOP responds well to steroid and antiviral treatment in HSV uveitis and endotheliitis as apposed to FHI or CMV keratouveitis.³

Prophylactic antiviral dosing should be used for all conditions needing steroids even after completing the therapeutic regimen to prevent other conditions from blossoming.⁴ Long-term oral prophylaxis is recommended for patients with recurrent disease or high risk for vision loss. The HEDS group noted significant reduction in recurrence rates while on 12-month prophylactic acyclovir, especially those with a history of HSK. However, there was no improvement in recurrence rates after 12-month prophylactic therapy was completed, which suggests indefinite prophylaxis is necessary for some patients.^{4,9,13}

Table 2. Topical Dosing

	Trifluridine 1% solution	Ganciclovir 0.15% gel
Prophylactic	5x/day	3x/day
Therapeutic	9x/day	5x/day

Table 3. Oral Dosing

	Acyclovir	Valacyclovir	Famciclovir
Prophylactic	400mg BID	500mg QD	250mg BID
Therapeutic	400mg 3-5x/day	500mg BID	250mg BID
Enhanced therapeutic	800mg 5x/day	1g TID	500mg BID


Herpes can present in the eye in a variety of ways, and those outlined here only scratch the surface. In the above case, it is quite likely the patient's uveitis was due to HSV, which then bloomed into a dendrite while he was on topical steroids without antivirals. There was nothing from his previous note to suggest his uveitis required antivirals at initial presentation, so close follow up was important to catch his HSV. The rapid taper of the steroids was initiated out of concern for exacerbating the dendrite but may have induced his conversion to endotheliitis. It may have been better to reduce, not discontinue, the steroid for several weeks to prevent such rebound.

Thankfully, with close follow up and appropriate treatment adjustments, the eye returned to normal and the patient was happy. For now, he will remain on prophylactic oral antivirals, perhaps indefinitely, as he has shown multiple recurrences in the past. ■

Dr. Schaeffer is a resident optometrist at Bascom Palmer Eye Institute at the University of Miami's Miller School of Medicine in Miami.

Dr. Townsend is the optometric residency director at Bascom Palmer Eye Institute at the University of Miami's Miller School of Medicine.

1. Gaynor B, Margolis T, Cunningham E. Advances in diagnosis and management of herpetic uveitis. *Int Ophthalmol Clin.* 2000;40(2):85-109.
2. Tabbara KF, Chavis PS. Herpes simplex anterior uveitis. *Int Ophthalmol Clin.* 1998;38(4):137-47.
3. Siverio C, Imai Y, Cunningham E. Diagnosis and management of herpetic anterior uveitis. *Int Ophthalmol Clin.* 2002;42(1):43-48.
4. White ML, Chodosh J. Herpes simplex virus keratitis: a treatment guideline. *Hoskins Centers Compendium of Evidence-Based Eye Care.* www.aao.org/clinical-statement/herpes-simplex-virus-keratitis-treatment-guideline. 2014. Accessed April 4, 2018.
5. Wilhelmus K, Falcon M, Jones B. Herpetic iridocyclitis. *Int Ophthalmol Clin.* 1991;4(3):143-50.
6. Guess S, Stone D, Chodosh J. Evidence-based treatment of herpes simplex virus keratitis: a systematic review. *Ocul Surf.* 2007;5(3):240-50.
7. Tsatsos M, MacGregor C, Athanasiadis I, et al. Herpes simplex virus keratitis: an update of the pathogenesis and current treatment with oral and topical antiviral agents. *Clin Exp Ophthalmol.* 2016;44(9):824-37.
8. Prepose J. Herpes simplex keratitis: role of viral infection versus immune response. *Surv Ophthalmol.* 1991;35:345-52.
9. Sudesh S, Laibson P. The impact of the herpetic eye disease studies on the management of herpes simplex virus ocular infections. *Curr Opin Ophthalmol.* 1999;10:230-3.
10. Sheha H, Tighe S, Cheng A, Tseng S. A stepping stone in treating dendritic keratitis. *Am J Ophthalmol.* 2017;Case Reports 7:55-8.
11. A controlled trial of oral acyclovir for iridocyclitis caused by herpes simplex virus. The Herpetic Eye Disease Study Group. *Arch Ophthalmol.* 1996;114:1065-72.
12. Porter S, Patterson A. A comparison of local and systemic acyclovir in the management of herpetic disciform keratitis. *Bri J Ophthalmol.* 1990;74:283-5.
13. Acyclovir for the prevention of recurrent herpes simplex virus eye disease. The Herpetic Eye Disease Study Group. *New Engl J Med.* 1998;339(5):300-6.



SERVICE SOLUTIONS

A CONFIDENT DIAGNOSIS STARTS WITH YOUR EQUIPMENT.

Your ophthalmic equipment works better for you and your patients when taken care of properly. Lombart's dedicated, factory-trained technicians are fully equipped with the latest calibration and repair tools to help restore your instruments to like-new condition.

WE OFFER:

- ✓ Instrument Repairs
- ✓ Reupholstery Services
- ✓ Phoropter Cleaning
- ✓ Preventative Maintenance
- ✓ Practice Relocations

TO SCHEDULE YOUR SERVICE, GO TO:
LOMBARTINSTRUMENT.COM/REQUESTSERVICE

WHEN YOU THINK OPHTHALMIC INSTRUMENTS,
THINK LOMBART



Ongoing Support



Reliable Service



Nationwide Coverage



Led Astray

A variable presentation can make myasthenia gravis tricky. This patient took several wrong turns before getting the right diagnosis.

By Michael Trottini, OD, and Michael DelGiodice, OD. Case by Dr. Trottini.

A 54-year-old Caucasian female presented to the hospital with a complaint of new-onset double vision for approximately one week. She reported that it was constant and diagonal with both a horizontal and vertical component and worse when looking to the left. She also stated that her friends have been commenting that her left eyelid would droop. When the double vision first started, she went to an urgent care center that sent her to see an ophthalmologist, but that clinician told her that her eye exam was normal and that she needed a neurologist to evaluate her for a stroke. The patient then presented to the emergency department (ED), where a neurologist diagnosed her with a partial third nerve palsy. She was admitted, and the neurologist ordered magnetic resonance imaging of her brain and orbits as well as magnetic resonance angiography of her brain. All testing came back normal, at which point I was consulted.

During her bedside examination, her visual acuity was 20/25 OU. Her extraocular motilities appeared to be full. Her pupils were equal, round and reactive to light with no afferent pupillary defect (APD). Her cover test revealed a right hypertropia worse on left gaze and worse on right head tilt. I also noted an exotropia (Figure 1). External examination showed a variable ptosis of the left upper eyelid that would range

from being in the normal position to approximately 50% closed.

Although her right hypertropia was consistent with a right fourth nerve palsy, the additional findings of the exotropia and variable lid ptosis were highly suspicious for myasthenia gravis (MG). She denied dysphagia, dyspnea or any generalized weakness. Her neurological exam was otherwise unremarkable.

The most likely diagnosis, ocular MG, required acetylcholine receptor antibody (binding, blocking and modulating) testing, as well as thyroid labs because thyroid orbitopathy can often cause various ocular motility deficits. In light of her findings, she was discharged with instructions to immediately return to the ED if she developed any swallowing or breathing difficulties before following up with me to review her labs.

The Follow Up

One week later, her labs revealed elevated acetylcholine receptor antibodies. T3, T4, TSH and thyroglobulin were normal; however, her thyroperoxidase was elevated. Her laboratory studies confirmed the diagnosis of ocular MG. She was referred her to neurology for MG treatment and recommended consultation with her internist to evaluate the elevated thyroperoxidase.

(R. Tilt)	10 XT 5 RHT		10 XT 1-2 RHT	(L. Tilt)
(R. Gaze)	8 XT 1 RHT	12 XT 1-2 RHT	10 XT 5 RHT	(L. Gaze)

Fig. 1. On this cover test, the patient presented with a right hypertropia worse on left gaze and right head tilt.

Re-examination three months later revealed some right hypertropia with some exotropia. However, the cover test measurements had significantly improved, and the patient stated that her double vision was essentially resolved. She was prescribed 90mg Mestinon (pyridostigmine, Bausch + Lomb) QID. Her neurologist sent her for a chest CT to rule out a thymoma which was normal, and her internist is currently evaluating her for thyroid dysfunction. She was instructed to follow up with our office in three months.

Discussion

MG is a rare autoimmune disease with an annual incidence that ranges from 0.04 to 5.00 per 100,000.¹ Acetylcholine molecules are released at the neuromuscular junction, bind to the receptors on striated muscle and depolarize the postsynaptic membrane, resulting in muscle contraction. In patients with MG, anti-acetylcholine receptor antibodies block the receptors and cause

10TH ANNUAL
2018

WEST COAST Optometric Glaucoma Symposium

Up to
**12 CE
Credits***

DECEMBER 14-15, 2018

Join our faculty of renowned ODs and MDs for a highly interactive meeting covering the most up-to-date information in glaucoma care. Up to 12 CE credits for only \$275.

MONARCH HOTEL

1 Monarch Beach Resort
Dana Point, CA 92629
949-234-3900

MEETING CO-CHAIRS:



Murray Fingeret, OD



Robert Weinreb, MD

SPEAKERS: Andrew Camp, MD
Ben Gaddie, OD

Alex Huang, MD, PhD
Richard Madonna, OD

THREE WAYS TO REGISTER

www.reviewsce.com/WCOGS2018
Email: reviewmeetings@jhihealth.com
Call Lois DiDomenico: 877-451-6514

Administered by

Review Group Vision Care Education, LLC



*Approval pending



Partially supported by an
unrestricted educational grant from
Bausch + Lomb

Review Group Vision Care Education, LLC partners with Salus University for those ODs who are licensed in states that require university credit. See event website for up-to-date information.

defective transmission at the neuromuscular junction, leading to muscle weakness.¹

Generalized MG involves the bulbar, limb and respiratory muscles. Patients will typically complain of weakness of the involved muscles that worsens during periods of activity and improves with rest. Additionally, symptoms will generally worsen throughout the day. When the muscles in control of swallowing are affected, patients are at risk for choking. Additionally, patients can develop respiratory failure, a life-threatening emergency.²

In ocular MG, symptoms are localized to the extraocular muscles, levator and orbicularis oculi. Patients will typically present with variable lid ptosis and double vision. In patients with ocular MG, 50% to 80% will progress and develop generalized MG, 90% of which evolve over the first two years.¹

The clinical and ocular presentations of MG can vary greatly. The extraocular motility deficits can mimic various disorders, including cranial nerve palsies, internuclear ophthalmoplegia, external ophthalmoplegia and thyroid orbitopathy. A suspicion for MG should always be present when examining patients with double vision or ptosis, as many have coined it the “great masquerader.” Often, the clinician will observe variability of the motility and lid deficits during the exam and from visit to visit.

The most common muscles involved in ocular MG are the medial rectus and superior rectus. If a ptosis is present, place an ice pack over the affected lid to observe if the ptosis improves. Cooling may reduce anticholinesterase activity, increasing the amount of available acetylcholine at the neuromuscular junction.¹

Clinicians should order laboratory

studies looking for anti-acetylcholine receptor antibodies. A positive test result can confirm the diagnosis, but a negative test does not necessarily exclude MG. In approximately 50% of patients with ocular MG and 10% to 15% with generalized MG, testing for these antibodies will give negative results.^{3,4}

Muscle-specific kinase (MuSK) is a protein found in the neuromuscular junction and is essential for each step in the neuromuscular synapse formation.⁴ In approximately 40% of patients who are seronegative for anti-acetylcholine receptor antibodies, anti-MuSK antibodies will be detectable. Patients who have positive anti-MuSK antibodies are typically middle-aged women, present with facial, neck and respiratory muscle weakness and are at a much higher risk for acute exacerbations.

If serology cannot confirm the diagnosis, the patient should undergo single fiber electromyography, which evaluates the electrical activity when stimulating skeletal muscle. When testing the frontalis or orbicularis muscles, it has a sensitivity of 85% to 100% for ocular MG and a sensitivity of 91% to 100% for generalized MG.¹

Additionally, when MG is diagnosed, order a chest computed tomography scan to rule out a thymoma, since it is present in 15% of patients with MG.⁵

Thyroiditis is also frequently associated with autoimmune disorders such as MG, and patients diagnosed with MG should be evaluated for any thyroid dysfunction.^{6,7}

Treatment

Therapy depends on the severity of disease. Mestinon, an acetylcholinesterase inhibitor, allows for a greater concentration of acetylcholine at the neuromuscular junction and better neuromuscular transmission.⁴ In

addition to Mestinon, immunosuppressants such as prednisone, azathioprine and cyclophosphamide can help to treat MG. For acute exacerbations, especially when respiratory muscles are involved, treatments such as plasmapheresis and intravenous administration of immunoglobulins are common for crisis intervention. The goal of this treatment is to remove the antibodies targeting the neuromuscular junction.

Because MG commonly causes ocular symptoms such as diplopia and lid ptosis, patients will often present to the optometrist first. In addition to significantly impacting a patient’s daily quality of life, MG can be a fatal disease. It is of the utmost importance to always maintain a suspicion for MG whenever a patient presents with diplopia, ptosis or generalized muscle weakness. Patients often receive an incorrect initial diagnosis, as seen with this case. It is not uncommon to see these patients misdiagnosed with cranial nerve palsies, internuclear ophthalmoplegia or another neurologic disorder. A prompt diagnosis will favor better outcomes, especially in patients with generalized MG that affects their breathing and swallowing. ■

1. Nair AG, Patil-Chhablani P, Venkatramani DV, Gandhi RA. Ocular myasthenia gravis: a review. *Indian J Ophthalmol.* 2014;62(10):985-91.

2. Wendell LC, Levine JM. Myasthenic crisis. *Neurohospitalist.* 2011;1(1):16-22.

3. Peeler CE, De Lott LB, Nagia L, et al. Clinical utility of acetylcholine receptor antibody testing in ocular myasthenia gravis. *JAMA Neurol.* 2015;72(10):1170-4.

4. Sieb JP. Myasthenia gravis: An update for the clinician. *Clin Exper Immunol.* 2014;175:408-18.

5. Beydoun SR, Gong H, Ashikian N, Rison RA. Myasthenia gravis associated with invasive malignant thymoma: two case reports and a review of the literature. *J Medical Case Reports.* 2014;8:340.

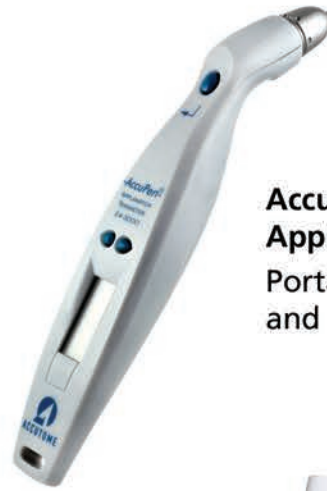6. Lopomo A, Berrih-Aknin S. Autoimmune thyroiditis and myasthenia gravis. *Front Endocrinol.* 2017;8:169.

7. Lin YP, Iqbal U, Nguyen Pa, et al. The concomitant association of thyroid disorders and myasthenia gravis. *Transl Neurosci.* 2017;8:27-30.

Tonometry Done Right



D-KAT Digital
Keeler quality.



**AccuPen - Handheld
Applanation Tonometer**
Portable, versatile,
and easy-to-use.



Intellipuff
The standard for hand held mobility.



Pulsair Desktop
Smallest footprint and simple to use!

*Purchase a Pulsair Desktop by
December 31, 2018 and get a
\$1,366 Instant Rebate!*

Buy Online!
keelerusa.com

Keeler
OPTICS

Earn up to
20 CE
Credits*

ANNUAL • EST. 1976

WINTER OPHTHALMIC CONFERENCE

A REVIEW GROUP VISION CARE EDUCATION, LLC MEETING OF CLINICAL EXCELLENCE

THE LONGEST RUNNING WINTER CE MEETING IN EYE CARE!

FEBRUARY 15-19, 2019

Join Review Group Vision Care Education, LLC in Aspen, CO for the 2019 Winter Ophthalmic Conference. This meeting features relevant topics in glaucoma, dry eye, external disease and retina.

WESTIN SNOWMASS CONFERENCE CENTER

100 Elbert Lane
Snowmass Village, CO 81615
Phone: 970-923-8200

CONTINUING EDUCATION:

- Earn up to 20 hours of COPE CE* credits
- **Registration cost: \$575**
- **Single day registration is available**
- Visit www.skivision.com for meeting agenda

THREE WAYS TO REGISTER

online: www.skivision.com

e-mail: reviewmeetings@jhihealth.com or call: 866-730-9257

See event website for all accommodations and rates.

MEETING CO-CHAIRS:



Murray Fingeret, OD, FAAO



Leo Semes, OD, FAAO

SPEAKERS:

Jack Cioffi, MD
Mark Dunbar, OD
Ben Gaddie, OD
Elisa Kramer, OD
Ron Melton, OD
Andrew Morgenstern, OD
Jack Schaeffer, OD
Randall Thomas, OD

Administered by
Review Group Vision Care Education, LLC



*Approval pending



Review Group Vision Care Education, LLC partners with Salus University for those ODs who are licensed in states that require university credit.

Earn up to
18-28 CE
Credits*

REVIEW GROUP
VISION CARE EDUCATION, LLC

NEW TECHNOLOGIES
& TREATMENTS IN
2019 EYE CARE



Join us for our
2019 MEETINGS

FEBRUARY 15-19, 2019 - ASPEN, CO

Annual Winter Ophthalmic Conference

Westin Snowmass Conference Center

Program Co-chairs: Murray Fingeret, OD, and Leo Semes, OD

REGISTER ONLINE: www.skivision.com

MARCH 7-10, 2019 - ORLANDO, FL

Disney Yacht & Beach Club

Program Chair: Paul Karpecki, OD, FAAO

APRIL 11-14, 2019 - SAN DIEGO, CA**

Manchester Grand Hyatt

Program Chair: Paul Karpecki, OD, FAAO

May 17-19, 2019 - NASHVILLE, TN

Gaylord Opryland

Program Chair: Paul Karpecki, OD, FAAO

NOVEMBER 1-3, 2019 - BALTIMORE, MD

Renaissance Baltimore Harborplace

Program Chair: Paul Karpecki, OD, FAAO

Visit our website for the latest information: www.reviewsce.com/events
e-mail: reviewmeetings@jhihealth.com or call: 866-658-1772

Administered by

Review Group Vision Care Education, LLC



*Approval pending



Pennsylvania College of Optometry



**16th Annual Education Symposium
Joint Meeting with NT&T in Eye Care

Review Group Vision Care Education, LLC partners with Salus University for those ODs who are licensed in states that require university credit.
See www.reviewsce.com/events for any meeting schedule changes or updates.



There's a Killer on the Loose

Patient history and visual field testing can help ODs catch cases of glioblastoma multiforme before it's too late. **By Carlo J. Pelino, OD, and Joseph J. Pizzimenti, OD**

An 80-year-old white male presented to the eye clinic with complaints of blurred vision on his right side of one month's duration. This was especially noticeable when the patient attempted to read. In addition, he reported mild right-sided weakness for the past five weeks. The patient's medical history was positive for long-standing hypertension and Type 2 diabetes.

His visual acuities were 20/20 OD, OS. He had a grade 1+ relative afferent pupillary defect (RAPD) in the right eye, and confrontation fields revealed a right field deficit in each eye. Threshold perimetry revealed a right homonymous hemianopia (*Figure 1*).

An Unfortunate Turn of Events

These concerning signs and symptoms prompted emergent neuroimaging, which revealed a left optic tract mass consistent with glioblastoma multiforme (GBM). The tumor was compressing the left optic tract and the crus cerebri (cerebral peduncle) of the midbrain, thus creating the right RAPD and right-sided weakness. He was referred for neurosurgical evaluation and treatment.

Gliomas represent the most common form of brain tumor. They originate in the glial cells that support the brain's neurons, including astrocytes, oligodendrocytes and ependymal cells. GBM is the most malignant form of glioma, causing 3% to 4% of all cancer-related deaths.¹ The World Health Organization defines GBM as a grade IV




Fig. 1. Visual field defects may indicate signs of tumor progression in GBM and should prompt further investigation.

cancer characterized as malignant, mitotically active and predisposed to necrosis.^{1,2}

Optometrists are in a position to detect early signs of GBM and perhaps help improve the paltry average survival of 12 to 15 months.¹

Hard Facts

GBM is a type of malignant brain tumor that forms from the star-shaped glial cells known as astrocytes. According to the American Brain Tumor Association, about 80,000 new cases of primary brain tumors are expected to be diagnosed annually in the United States. Of these, GBM will account for around 15%.³ GBM rarely metastasizes to other parts of the body.

While GBM is not the most common brain tumor, it is the deadliest; median survival is just 14.6 months after diagnosis if a patient undergoes standard therapy of tumor resection with concurrent radiotherapy and

chemotherapy. As such, a desperate need exists to identify new therapies to prevent and treat GBM. The development of proteomic, genetic and epigenetic tools may one day improve survival rates.³

Symptoms of GBM may appear slowly and be quite subtle, at first. Patients with GBM may present with headaches, confusion, memory loss, motor weakness and seizures. Other patient complaints include nausea, personality changes, difficulty concentrating, hemiparesis, vision loss and aphasia.⁴

ODs on the Lookout

Ocular manifestations of gliomas and GBM are similar to those of other space-occupying lesions and may include any of the following:

- Headache
- Blurred vision
- Visual field loss (defects correlate with site of tumor)
- Spatial neglect



TRIOD

TRIFECTA IN OCULAR DISEASE

10 Hours
of CE!
Cope Approved

WHAT:

An educational program dedicated to the co-management of ocular diseases

WHEN:

Saturday & Sunday
October 13-14, 2018

WHERE:

Four Seasons Hotel
1435 Brickell Ave
Miami, FL 33131



The TRIOD will incorporate 10 hours of COPE/Florida CE certified courses including the required 6 hours of TQ, Medical errors & Florida Jurisprudence.

TRIOD will feature a trifecta panel of optometrist, ophthalmologists and sub-specialists from the Tri-County areas.

TRIOD endeavors to keep you engaged with fast paced Grand Round style lectures discussing co-management in eye care.

REGISTER NOW!

SPONSORED BY



RETINA MACULA
SPECIALISTS OF MIAMI

For more information,
contact ecordinator@retinamiami.com
or visit our website

WWW.TRIODOCULAR.COM

preregistration \$175.00
(includes parking and meals)

Neoplastic Disease

Cancer is responsible for approximately 25% of all deaths in the United States and is the second most common cause of death after heart disease. The American Cancer Society defines cancer (or carcinoma) as a group of diseases characterized by uncontrolled growth and spread of abnormal cells. Cancer has the capacity to invade surrounding normal tissue, metastasize and kill the host in which it originates.² Cancer has environmental, chemical, cellular and genetic causes, with the host genetic composition and immunobiological status contributing to the process.^{1,2} All multicellular organisms have the potential to develop cancer.

Neoplasia is the process of abnormal growth that starts from a single altered cell.⁸ A neoplasm is an abnormal mass of tissue that results when cells divide more than they should or do not die when they should. Neoplasms may be benign or malignant, depending on their biological activity. Benign neoplasms cannot spread by invasion or metastasis—they only grow locally. Malignant neoplasms are capable of spreading by invasion and metastasis. By definition, the term “cancer” applies only to malignant tumors.⁸

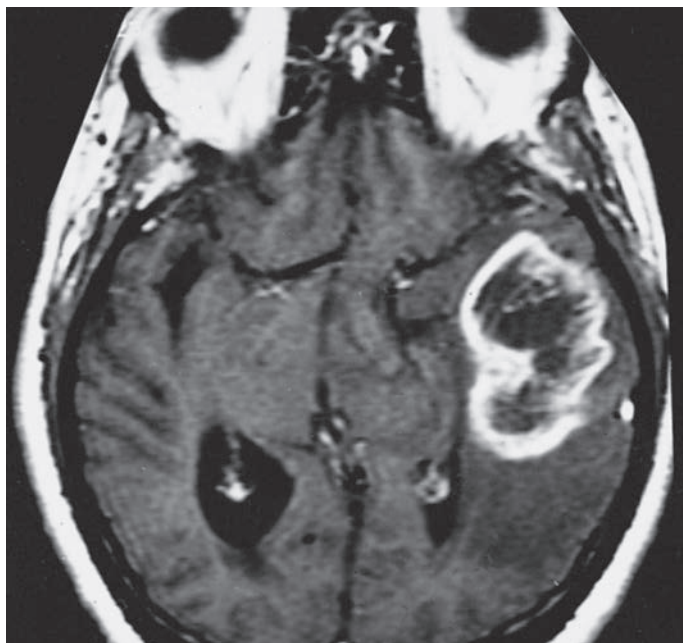


Fig. 2. MRI of GBM in a different patient showing a ring-shaped zone of contrast enhancement around a dark central area of necrosis.

Image: The Armed Forces Institute of Pathology

- Cranial nerve palsies
- Optic disc edema and atrophy
- Pupillary abnormalities, including RAPD
- Gaze-induced nystagmus

Clinical evaluation is crucial for these patients, particularly a thorough review of systems, including questions of weight loss, dizziness, headache, muscle weakness, loss of appetite, malaise, etc. Clinical evidence of progression can actually precede magnetic resonance imaging (MRI) evidence in both initial and recurrent GBM, with seizures being the most common preceding symptom.⁴ One study of two cases found distinct, progressive visual field defects predated neuroimaging identification of tumor progression.⁵ Thus, new or worsening field defects may indicate signs of tumor progression in GBM and should prompt further investigation.

Patients suspected of having GBM or other space-occupying conditions should undergo neuroimaging studies such as computed tomography,

MRI with and without contrast, positron emission tomography and magnetic resonance spectroscopy of the brain (*Figure 2*).⁶

Obtaining tumor genetics with electroencephalography, lumbar puncture and cerebrospinal fluid studies may also be useful for predicting response to adjuvant therapy.

Although no curative treatment for GBM exists, the standard therapy consists of maximal safe surgical resection, radiotherapy and concomitant and adjuvant chemotherapy with temozolomide.^{3,6} The addition of radiotherapy to surgery increases patient survival, and adjuvant chemotherapy shows a significant survival benefit in more than 25% of patients.⁷ However, clinicians must balance these therapies with quality of life issues, and in patients aged 70 or older, less aggressive therapy with radiation or temozolomide alone may be considered.

A patient diagnosed with GBM should be treated and managed by an interprofessional team that

includes neurosurgeons, neurologists, neuro-oncologists, neuroradiologists, neuropathologists, radiation oncologists, physical therapists, social workers and other specialists with advanced training and extensive experience in brain tumors. ODs can and should be vital members of that team, beginning with diagnosis and continuing through comanagement and visual field enhancement. ■

1. Louis DN, Ohgaki H, Wiestler OD, et al. The 2007 WHO classification of tumours of the central nervous system. *Acta Neuropathol.* 2007;114(2):97-109.
2. McLendon RE, Halperin EC. Is the long-term survival of patients with intracranial glioblastoma multiforme overstated? *Cancer.* 2003;98(8):1745-8.
3. Cornett PA, Dea TO. *Cancer.* In: McPhee SJ, Papadakis MA, eds. 2010 Current Medical Diagnosis and Treatment. 49th ed. New York: McGraw Hill Medical; 2009:1450-1511.
4. Hanif F, Muzaffar K, Perveen K, et al. Glioblastoma multiforme: A review of its epidemiology and pathogenesis through clinical presentation and treatment. *Asian Pacific J Cancer Prevention.* 2017;18(1):3-9.
5. Chittiboia P, Connor DE Jr, Caldito G, et al. Occult tumors presenting with negative imaging: analysis of the literature. *J Neurosurg.* 2012;116(6):1195-1203.
6. Xie K, Liu CY, Hasso AN, Crow RW. Visual field changes as an early indicator of glioblastoma multiforme progression: two cases of functional vision changes before MRI detection. *Clinical Ophthalmology (Auckland, NZ).* 2015;9:1041-7.
7. Davis ME. Glioblastoma: overview of disease and treatment. *Clin J Oncol Nursing.* 2016;20(5):S2-S8.
8. Vitucci M, Hayes DN, Miller CR. Gene expression profiling of gliomas: Merging genomic and histopathological classification for personalised therapy. *Br J Cancer.* 2011;104:545-53.

Earn up to
11 CE
Credits*

SAVE THE DATE!

The Optometric Retina Society &
Review Group Vision Care Education Present

RETINAUPDATE 2018

November 30 - December 1 • Scottsdale, AZ



FAIRMONT SCOTTSDALE

7575 E Princess Drive
Scottsdale, AZ 85255
480-585-4848

A limited number of rooms have been reserved at \$259/night plus applicable taxes. Make your reservations with the hotel at 1-800-344-4758, mention "Review's Optometric Retina Society Meeting" for group rate.

REGISTRATION COST:

ORS Member: \$405 Non-member: \$450
EARLY BIRD DEADLINE: September 28, 2018

FACULTY:

Mark Barakat, MD; Steven Ferrucci, OD, FFAO;
Jeffrey Gerson, OD, FFAO; Mohammad Rafieetary, OD, FFAO;
Leo Semes, OD, FFAO; Brad Sutton, OD, FFAO

ORS MISSION STATEMENT

The mission of the Optometric Retina Society (ORS) is to promote the advancement of vitreoretinal knowledge for clinicians, ophthalmic educators, residents, and students.

The ORS is dedicated to posterior segment disease prevention, diagnosis, management and co-management.

THREE WAYS TO REGISTER

email: reviewmeetings@jhihealth.com | call: 800-999-0975

online: www.reviewsce.com/orsretupdate2018

Administered by

Review Group Vision Care Education, LLC



*Approval pending



Review Group Vision Care Education, LLC partners with Salus University for those ODs who are licensed in states that require university credit. See event website for up-to-date information.

2018 VEGAS
30 YEARS

V VISION
EXPO

EDUCATION SEPTEMBER 26-29 EXHIBIT HALL SEPTEMBER 27-29 SANDS CONVENTION CENTER, LV



**EVERYTHING
VISION.
BECAUSE
VISION IS
EVERYTHING.**

SEE FOR YOURSELF

Bring your vision into focus among the glitz and glamour of Vegas for the event of the year, where eyecare meets eyewear, and education, fashion and innovation mingle.

YOUR VISION. YOUR WORLD—VISION EXPO.

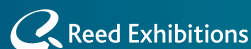BROUGHT TO YOU BY



PROUD SUPPORTER OF

thinkabout
youreyes.com
Brought to you by the AOA
AMERICAN OPTOMETRIC ASSOCIATION

PRODUCED BY



VisionExpoLV.com
#VISIONEXPO



Manic (Foveal) Depression

Can imaging unveil the underlying issue of this patient's unilateral blur?

By Mark T. Dunbar, OD

A 73-year-old Hispanic female presented with blurry vision and distortion in her right eye, which she said began about five years earlier. She reported a slow, steady progressive loss of vision in that eye. The left eye is near-perfect with only mild blurry vision but no distortion. Her past ocular history is unremarkable. Her medical history is significant for hypertension, for which she takes medication.

On examination, her best-corrected visual acuity was 20/80 OD, 20/20 OS. Extraocular motility testing was normal. Her confrontation visual fields were full-to-careful finger counting and the pupils were equally round and reactive; there was no afferent pupillary defect. An Amsler grid showed a large area of central distortion in the right eye. Her anterior segments were remarkable for 1+ nuclear sclerotic cataracts OU. Tensions by applanation measured 14mm Hg OU.

On dilated fundus exam, she had large optic nerves and moderate-sized cups with good rim coloration and perfusion in both eyes. The macula in the right eye showed changes, however (Figure 1). Optical coherence tomography angiography (OCT-A) and spectral domain OCT were also performed (Figures 2 and 3). The peripheral was normal.

Take the Retina Quiz

1. What does the SD-OCT show of the outer retinal layers?
 - a. Normal IS/OS junction.
 - b. Atrophy and loss of the photo-

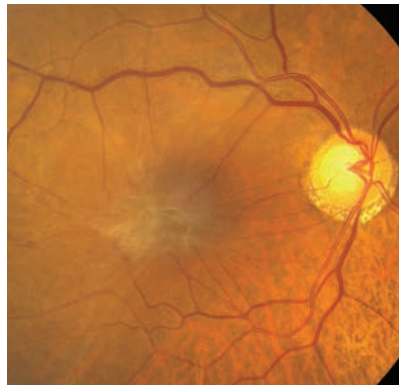


Fig 1. This fundus photo shows the right eye of our patient. Can you spot the changes to the macula?

receptor interior and outer segment junction.

- c. Choroidal neovascularization.
 - d. Ganglion cell loss.
2. What does the OCT-A show?
 - a. Extensive leakage of the retinal arteries and veins.
 - b. Extensive capillary dropout and ischemia.
 - c. Distortion and dragging of the retinal vasculature but no leakage.
 - d. Intraretinal neovascularization.
 3. What is the correct diagnosis?
 - a. Epiretinal membrane.
 - b. RPE hamartoma.
 - c. Wet AMD with CNV.
 - d. VMT with macular edema.

4. What other findings do you expect to be present on your clinical exam?
 - a. Cystoid macular edema.
 - b. Posterior vitreous detachment.
 - c. Macular hole.

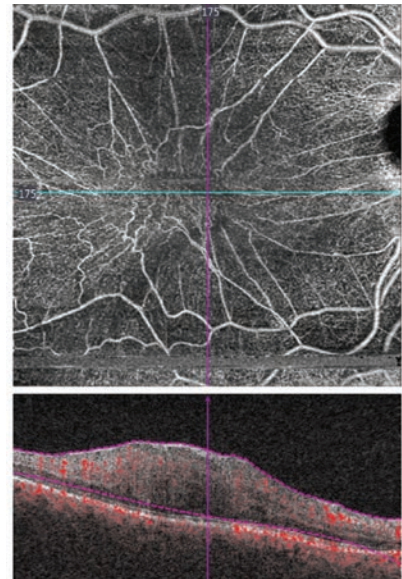


Fig 2. What do these OCT angiography images reveal about the patient's vision?

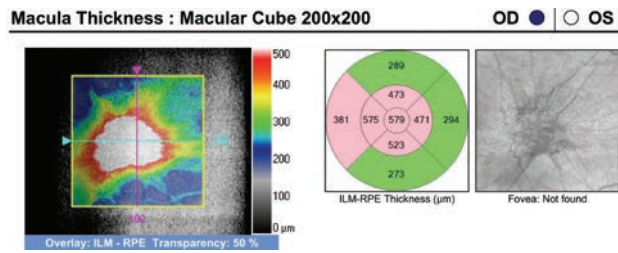
- d. Peripheral retinal tear.
5. How should she be managed?
 - a. Observation.
 - b. Intravitreal anti-VEGF medication.
 - c. Intravitreal injection ocriplasmin.
 - d. Referral for pars plana vitrectomy and membrane peel.

For answers, see page 130.

Discussion

Our patient has a significant epiretinal membrane (ERM) in the right eye causing reduced acuity and central distortion of her vision. On the SD-OCT, we observed a complete loss of foveal depression and significant retinal elevation of the macula. The thickness map of the right eye

Fig. 3. How can these OCT images of the patient's right eye illuminate the etiology behind her visual distortion?



measures 579 μ m of elevation compared with the normal thickness of 234 μ m in the fellow eye. Interestingly, we saw no intraretinal fluid or cystoid macular edema as one might expect with an ERM of this size. What's more, the photoreceptor interior and outer segment (IS/OS) junction appears intact.

ERM are most commonly seen in the elderly population.¹ In autopsy eyes, it was present in 20% of subjects older than 75 and in only 4% younger than 60.¹ An ERM represents a fibrocellular member that grows on the surface of the retina. The membrane is made up of glial cells, retinal pigment epithelial cells, macrophages, fibrocytes and collagen cells.² The initiating event in the development of most ERMs is often a posterior vitreous detachment (PVD). The traction on the retina from the PVD results in a small break or dehiscence in the ILM that starts the cascade. Therefore, it's not surprising that up to 90% of patients with ERMs also have PVD.¹ Our patient also had a PVD that was easily seen on clinical exam, which was purposely not disclosed. Other causes of PVD include uveitis, trauma and prior intraocular surgery.

Often, the highly reflective membrane can be easily observed on the inner surface of the retina on OCT. In our patient, it was not so easy to see on the horizontal line scan, probably because it is so tightly adherent to the retina. However, on the transverse cut, we see a lot of

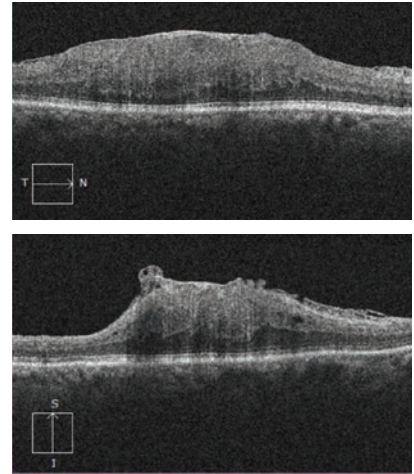
superficial irregularities that stand out.

Most ERMs will remain stable and not affect visual function to any great extent. Population studies show that 16% to 33% of patients with ERM will progress. For those patients who develop symptomatic ERM, pars plana vitrectomy with membrane peel is the treatment of choice. Surgical success is dependent on the extent and severity as well as the level of the visual acuity.

Treatment

No definitive standard describes when surgery is recommended for ERM. For the majority, it is based on symptoms. If patients are asymptomatic, most surgeons elect to observe. When symptoms become intolerant or begin to affect quality of life, surgery is recommended. The SD-OCT may provide a good barometer for detecting structural changes within the retina, either at the level of the IS/OS junction or if patients develop fluid or cystic changes within the retina. Once this occurs, most retina specialists agree that surgery is warranted.

Generally speaking, better visual outcomes are achieved when there is better preoperative vision. The expectation for recovery of visual acuity following surgery is considered to be approximately 50% of what their preoperative acuity was. For example, patients with 20/60 acuity from an ERM would expect to achieve at least 20/30 or better as a final outcome.



Regardless of the preoperative acuity, most patients will achieve some level of improvement. In one study, 70% of ERM patients had improvement in visual acuity and over half achieved vision better than 20/40.¹ Even though VA may remain unchanged for some patients after surgery, the perceived visual quality may be much better due to improvement in patients' metamorphopsia.

Our patient did not have any cystoid macular edema and the IS/OS junction was intact so we were optimistic that PPV and MP would offer her the best chance for improving vision and providing relief of her metamorphopsia. However, given the size and density of the ERM, we were cautious on just how much she would improve. She elected to proceed with pars plana vitrectomy and membrane peel. One month following the surgery, her acuity improved to 20/40 and her metamorphopsia was much better. She is scheduled for a follow up exam in four to six weeks. ■

1. Dawson SR, Shunmugan M, Williamson TH. Visual acuity outcomes following surgery for idiopathic epiretinal membrane: an analysis of data from 2001 to 2011. *Eye*. 2014;28:219-24.

2. Smiddy W, Maguire A, Green W, et al. Idiopathic epiretinal membranes. Ultrastructural characteristics and clinicopathologic correlation. *Ophthalmology*. 1989;96(6):811-20.



A child should never be limited by poor vision

Help a child to see.



Take the Challenge
DONATE today

Every \$100 can provide eye care for up to 20 children!

To learn more or to donate today visit
givingsight.org or call 303-526-0430

OPTOMETRYGIVINGSIGHT

Transforming lives through the gift of vision

Meetings + Conferences

October 2018

■ **3-4.** *Indiana Optometry's Fall Seminar.* Indiana Memorial Union, Bloomington, IN. Hosted by: Indiana Optometric Association.

Key faculty: Mark Dunbar, Brett King, Neil Pence, Damon Dierker, Austin Lifferth, Sara Weidmayer, Arthur Epstein. CE hours: 14. For more information, email Bridget Sims at blsims@ioa.org, call (317) 237-3560 or go to www.ioa.org.

■ **4-6.** *Idaho Optometric Physicians Annual Congress.* Coeur d'Alene Resort, Coeur d'Alene, ID. Hosted by: Idaho Optometric Physicians. CE hours: 32 total, 19 per OD. For more information, email Randy Andregg at execd@iopinc.org, call (208) 461-0001 or go to idaho.aoa.org.

■ **4-6.** *EastWest Eye Conference 2018.* Huntington Bank Cleveland Convention Center, Cleveland, OH. Hosted by: Ohio Optometric Association. Key faculty: Paul Ajamian, Brad Sutton, Stuart Richer, Danica Marrelli, Steve Ferrucci, Milton Horn. CE hours: 250 total, 26 per OD. For more information, email Jordan Quickel at [jqickel@ooa.org](mailto:jquickel@ooa.org) or go to www.eastwesteye.org.

■ **4-11.** *AEA Cruises Taste of Bordeaux Optometric Cruise.* On board AmaDolce. Hosted by: AEA Cruises. CE hours: 10. For more information, email Marge McGrath at aeacruises@aol.com, call (773) 594-9866 or go to www.optometriccruiseseminars.com.

■ **6-7.** *Symposium on Ocular Disease.* Swan and Dolphin Hotel, Orlando, FL. Hosted by: PSS EyeCare. Key faculty: Stuart Kaplan, Richard Castillo, David Masihdas, Deepak Gupta, Michael Tolentino, Pinakin Davey. CE hours: 18. For more information, email Sonia Kumari at education@psseyecare.com or go to www.psseyecare.com.

■ **10-11.** *Michigan Optometric Association Fall Seminar.* Lansing Center, Lansing, MI. Hosted by: Michigan Optometric Association. Key faculty: Marc Bloomenstein, Milton Horn, David Kading, Lillian Kalaczinski, Christopher Wolfe. CE hours: 14. For more information, email info@themoa.org, call (517) 482-0616 or go to themoa.org/aws/moa/pt/sp/fall_seminar.

■ **11-14.** *2018 Annual MOA Convention.* Branson Convention Center, Branson, MO. Hosted by: Missouri Optometric Association. Key faculty: Christopher Wolfe, Jeffrey Walline, Wes DeRosier. CE hours: 15. For more information, email Lee Ann Barrett at moaed@moeyecare.org, call (573) 635-6151 or go to www.moeyecare.org.

■ **11-14.** *GWCO Congress.* Oregon Convention Center, Portland, OR. Hosted by: Great Western Council of Optometry. CE hours: 82 total, 26 per OD. For more information go to www.gwco.org.

■ **13-14.** *CE in Houston Featuring the 2018-2019 Benedict in Practice Management and Administration.* UHCO Health & Biomedical Sciences Building, Houston, TX. Hosted by: University of Houston College of Optometry. Key faculty: Sam Quintero. CE hours: 16. For more information, email optce@central.uh.edu, call (713) 743-1900 or go to ce.opt.uh.edu.

■ **14.** *Annual Applebaum Symposium.* Marshall B. Ketchum University, Fullerton, CA. Hosted by: Marshall B. Ketchum

University's Southern California College of Optometry. Key faculty: Mark Sawamura, Judy Tong, David Sendrowski, Justin Kwan. CE hours: 8. For more information, email Antoinette Smith at asmith@ketchum.edu, call (714) 872-5684 or go to www.ketchum.edu/ce.

■ **20-21.** *VOA Fall Conference.* Hilton Richmond Hotel & Spa/ Short Pump, Richmond, VA. Hosted by: Virginia Optometric Association. Key faculty: Bruce Onofrey, Marc Haskelson, Mark Dunbar. CE hours: 10. For more information, email Bo Keeney at office@thevoa.org, call (804) 643-0309 or go to www.thevoa.org/voa/89-events/482-2018-voa-fall-conference.

■ **20-21.** *Envision NY.* SUNY College of Optometry, New York, NY. Hosted by: SUNY College of Optometry. CE hours: 49 total, 7/day per OD. For more information, email Betsy Torres btorres@sunyopt.edu, call (212) 938-5830 or go to www.sunyopt.edu/cpe.

■ **20-21.** *CE in Fort Worth.* Dallas Fort Worth Marriott Hotel & Golf Club, Fort Worth, TX. Hosted by: University of Houston College of Optometry. Key faculty: Sheila Morrison. CE hours: 16. For more information, email optce@central.uh.edu, call (713) 743-1900 or go to ce.opt.uh.edu.

■ **20-21.** *Georgia Optometric Association Fall Education Conference.* University of Georgia Center for Continuing Education and Hotel, Athens, GA. Hosted by: Georgia Optometric Association. CE hours: 18. For more information, email Vanessa Grosso at vanessa@goaeyes.com or go to www.goaeyes.com.

■ **20-22.** *Annual Education Conference.* Mystic Marriott Hotel & Spa, Groton, CT. Hosted by: Connecticut Association of Optometrists. CE hours: 18. For more information, email Lynn Sedlak at lsedlak@cteyes.org, call (860) 529-1900 or go to www.cteyes.org.

■ **21-22.** *Continuing Education Seminar and Optifair Canada Trade Show.* Embassy Grand Convention Centre, Brampton, Ontario, Canada. Hosted by: The Academy of Ophthalmic Education. CE hours: 14. For more information, email Claudia Marks at cmarks@aoece.com, call (905) 731-6022 or go to aoece.com.

■ **27-28.** *Orlando Super Weekend.* Nova Southeastern University—Orlando Campus, Orlando, FL. Hosted by: Nova Southeastern University College of Optometry. Key faculty: Barry Frauens. CE hours: 13. For more information, email Vanessa McDonald at ocea@nova.edu, call (954) 262-4224 or go to optometry.nova.edu/ce/index.html.

November 2018

■ **1-4.** *Optometric Management Symposium.* Disney's Yacht & Beach Club, Lake Buena Vista, FL. Hosted by: Pentavision. Key faculty: Mark Dunbar, John Rumpakis, Whitney Hauser, Mark Myers, Andrew Gurwood. CE hours: 50+ total, 31 per OD. For more information, email Maureen Trusky at maureen.trusky@pentavisionmedia.com or go to www.omconference.com.

■ **2-4.** *New Technologies and Treatments in Eye Care.* The Westin Arlington Gateway, Arlington, VA. Hosted by: *Review of Optometry*. Key faculty: Paul Karpecki (Program Chair), Doug Devries, Justin Schweitzer, Jeffrey Gerson. CE hours: 19. For more information, email Lois DiDomenico at reviewmeetings@jhihealth.com, call (866) 658-1772 or go to www.reviewofoptometry.com/arlington2018.

■ **2-4.** *2018 AZOA Fall Congress.* Sedona Hilton Resort, Sedona, AZ. Hosted by: Arizona Optometric Association. Key faculty: Michael S. Cooper, Steven Ferrucci, Blair Lonsberry. CE hours: 16. For more information, email Kate Diedrickson at kate@azoa.org, call (602) 279-0055 or go to www.azoa.org/connect.

■ **2-7.** *Forum on Primary Eye Care.* Atlanta Marriott Marquis, Atlanta, GA. Hosted by: PSS EyeCare. Key faculty: Damon Dierker, Mile Brujic, Deepak Gupta, Pinakin Davey, David Masihdas, and Robert McCullough. CE hours: 18. For more information, email Sonia Kumari at education@psseyecare.com, call (203) 415-3087 or go to www.psseyecare.com.

■ **5-6.** *AFOS/Academy 2018.* Marriott Plaza San Antonio, San Antonio, TX. Hosted by: Armed Forces Optometric Society. Key faculty: Federal Service Chiefs (Air Force, Army, Navy, IHS and VA) plus leading-edge optometric educators. CE hours: 12. For more information, email Lindsay Wright at execdir@afos2020.org, call (720) 442-8209 or go to www.afos2020.org.

■ **6.** *Optometric Glaucoma Society Annual Scientific Meeting.* Grand Hyatt San Antonio, San Antonio, TX. Hosted by: Optometric Glaucoma Society. Key faculty: Michael Chaglasian, Nevin El-Nimri, Donald Miller, Alex Huang, Jay Katz, Robert Feldman, Arthur Sit, Thomas Freddo. For more information, go to optometricglaucomasociety.org.

■ **7-10.** *Academy 2018 San Antonio.* Henry B. Gonzalez Convention Center, San Antonio, TX. Hosted by: American Academy of Optometry. CE hours: 250+ total, 33 per OD. For more information, email registration@aaoptom.org, call (321) 319-4860 or go to www.aaopt.org/regsite.

■ **9-10.** *2018 Wisconsin Optometric Association Primary Care Symposium.* Glacier Canyon Lodge at the Wilderness, Wisconsin Dells, WI. Hosted by: Wisconsin Optometric Association. CE hours: 9. For more information, email Joleen Breunig at joleen@woa-eyes.org, call (608) 824-2200 or go to www.woa-eyes.org.

■ **9-11.** *Fall Congress 2018.* The Omni Grove Park Inn, Asheville, NC. Hosted by: North Carolina Optometric Society. Key faculty: Karl Stonecipher, Dan Bennett, Chad Morgan, Eric Schmidt, Keith Smithson, Patrick Vollmer, Zack Kemp. CE hours:

18. For more information, email Christy Santacana at christy@nceyes.org or go to www.nceyes.org/fall-congress.

■ **14.** *Educational Dinner Lectures.* Jumping Brook Country Club, Neptune City, NJ. Hosted by: New Jersey Academy of Optometry. CE hours: 2. For more information, email Dennis Lyons at dhl2020@aol.com or call (732) 920-0110.

■ **28-Dec. 2.** *Art & Science of Optometric Care—A Behavioral Perspective.* OEP NEC, Timonium, MD. Hosted by: Optometric Extension Program. Key faculty: Paul Harris. CE hours: 35. For more information, email Karen Ruder at karen.ruder@oep.org, call (410) 561-3791 or go to www.oep.org.

■ **30-Dec. 1.** *Retina Update 2018.* Fairmont Scottsdale Princess, Scottsdale, AZ. Hosted by: *Review of Optometry* and the Optometric Retina Society. Key faculty: Mohammad Rafieetary (Program Chair), Mark Barakat, Steve Ferrucci, Jeff Gerson, Leo Semes, Brad Sutton. CE hours: 11. For more information, email Lois DiDomenico at reviewmeetings@jobson.com or go to www.reviewsce.com/orsretupdate2018.

■ **30-Dec. 1.** *4th Annual Terrific Tulsa Winter Weekend.* Hard Rock Hotel & Casino, Tulsa, OK. Hosted by: Oklahoma College of Optometry. CE hours: 9. For more information, email Callie McAtee at mcateec@nsuok.edu, call (918) 316-3602 or go to optometry.nsuok.edu/continuingeducation.

December 2018

■ **2.** *Clinical Topics in Optometry.* Marshall B. Ketchum University, Fullerton, CA. Hosted by: Southern California College of Optometry. CE hours: 8. For more information, email Antoinette Smith at asmith@ketchum.edu or go to www.ketchum.edu/ce.

■ **2-3.** *35th Annual Cornea, Contact Lens & Contemporary Vision Care Symposium.* Westin Memorial City, Houston, TX. Hosted by: University of Houston College of Optometry. Key faculty: Jan Bergmanson. CE hours: 16. For more information, email optce@central.uh.edu or go to ce.opt.uh.edu.

■ **9.** *Orlando Super Sunday.* Nova Southeastern University—Orlando Campus, Orlando, FL. Hosted by: Nova Southeastern University College of Optometry. Key faculty: Chandra Mickles. CE hours: 8. For more information, email Vanessa McDonald at oceaa@nova.edu or go to optometry.nova.edu/ce/index.html.

■ **14-15.** *West Coast Optometric Glaucoma Symposium.* Monarch Hotel, Dana Point, CA. Hosted by: *Review of Optometry*. Key faculty: Murray Fingeret, Robert N. Weinreb. CE hours: 12. For more information, email Lois DiDomenico at reviewmeetings@jhihealth.com, call (866) 658-1772 or go to www.reviewofoptometry.com/arlington2018.

■ **23-30.** *Advanced Ocular Care.* Western Caribbean Cruise—Round trip from New Orleans. Hosted by: Dr. Travel Seminars. Key faculty: Richard Mangan. CE hours: 16. For more, email Robert Pascal at info@drtravel.com or go to www.drtravel.com.

To list your meeting, please send the details to:

Mark De Leon, Associate Editor

Email: mdeleon@jobson.com

Phone: (610) 492-1021



The Day I Became My Own Patient

An idiopathic condition really put me through the ringer.

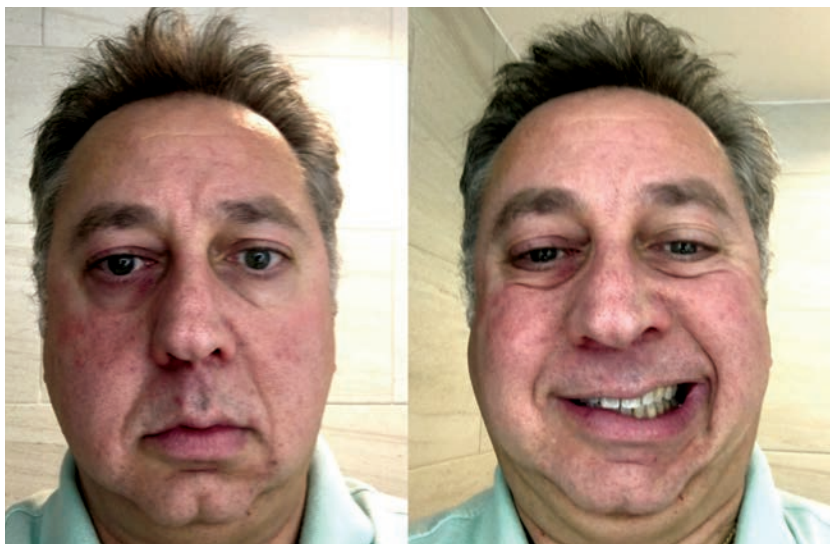By Alan G. Kabat, OD, and Joseph W. Sowka, OD

I (Dr. Kabat) must have burned my tongue on something. That was the only logical explanation. I was eating a delicious dinner on my 54th birthday, but it didn't taste right. In fact, it barely tasted at all. Maybe some more salt? Nope...well, this is depressing. It'll be better tomorrow, I thought.

Breakfast the next morning was equally bland. At work, I noticed that my right eye was tearing excessively, and that was unusual. Did I injure it somehow? Well, the eye felt a little bit scratchy. Some artificial tears should take care of it. Unfortunately, it kept on tearing throughout the day, and my eye felt... funny. Not painful, but almost like I had put a drop of tetracaine in my eye. Boy, this really isn't my week.

It wasn't until I started shaving on the third day that I realized what was going on. As I tried to puff out my cheeks, I found myself sputtering and spitting on the mirror. I looked closer at my face. I smiled a wide grin, and to my astonishment, only the left side of my face responded.

OK, think. You're a doctor, after all. Are you having a stroke? I quickly checked my motor function. Both arms and legs seemed to be working alright. Memory? I knew my name, my address, where I was and where I was going that day. I thought, 'Let's run through cranial nerves.' CN I (olfactory), check. CN II (optic), vision was fine in both eyes and no apparent hemispheric field loss. CN III, IV and VI, no diplopia in any gaze. CN V (trigeminal), sensation on both sides of the face are equal and muscles of mastication are working fine. CN VII (facial), definite disparity on the right side. My blink appeared asymmetric, favoring the left side, although I could squeeze the right eye shut if I tried. So my orbicularis oculi, orbicularis oris and buccinator function were all compromised on the right



At left, note the flattening of the right side of the face, with drooping of the nasolabial fold, corner of the mouth and lower eyelid. At right, when smiling, the teeth remain unexposed on the affected right side.

side. CN VIII (vestibuloauditory), no balance problems and I seemed to be hearing equally in both ears. CN IX and X, no problems swallowing or coughing (but I refused to check my own gag reflex). CN XI, shoulder shrug and neck turns were equal to both sides. CN XII, stuck out my tongue and it was straight. Phew!

What's My Problem?

So, what's my diagnosis, doc? If you thought "Bell's palsy," then we're on the same page. Bell's palsy represents an idiopathic dysfunction of CN VII, and is the most common presentation of facial nerve palsy.¹⁻⁴ The characteristic clinical presentation involves generalized weakness of one side of the face. There will be an inability to fully close the ipsilateral eye, which can result in lower lid ectropion and epiphora; with persistent lagophthalmos, patients may manifest conjunctival hyperemia and exposure keratopathy, resulting in dry eye symptoms. Additionally, there will be unilateral flattening of the nasolabial fold, drooping of the corner of the mouth and diminished wrinkling

of the forehead. These signs become more evident when asking the patient to purse the lips, puff out the cheeks, smile widely and raise the eyebrows. Since the CN VII also supplies sensory innervation to the anterior two-thirds of the tongue, altered or decreased taste sensation is common. Depending upon the severity and branches involved, patients may additionally report pain in or behind the ear, as well as hyperacusis—increased sensitivity to sound—on the affected side.

The onset of all these symptoms is typically abrupt, although, as in my case, it may be several days before the patient fully recognizes the magnitude of their disability. By the time a patient presents for evaluation, it is likely that 24 to 72 hours have already passed.

For Whom the Bell's Tolls

The literature shows some debate regarding the epidemiology of Bell's palsy. The reported annual incidence varies throughout the world, with estimates varying between 11 and 40 cases per 100,000 individuals.^{3,5} It has no known gender, ethnic or racial predilection. Most cases are seen in mid- to later-life and the median age of onset is 40.^{1-4,6-9} Known risk factors include diabetes, pregnancy, severe preeclampsia, obesity and hypertension.²⁻⁴ The underlying pathophysiology of Bell's palsy, as observed in post-mortem cases, involves vascular distension, inflammation and edema with associated ischemia of the facial nerve.⁵

As to the etiology, the condition is classified as idiopathic, but current thinking suggests that it is most likely associated with reactivation of herpes simplex virus (HSV) or herpes zoster virus (HZV) from the geniculate ganglia.^{2,5}

Although the clinical presentation may be easily recognized, physicians need to always bear in mind that Bell's palsy is a diagnosis of exclusion. Despite wanting to spare our patients the time and expense involved, a thorough medical evaluation should be obtained in these scenarios. Approximately half of all facial nerve palsies are idiopathic and fall into the category of Bell's palsy, but that means 50% have another cause.

Acquired facial nerve palsies may be associated with trauma, ischemia, systemic infection (e.g., Lyme disease or tuberculosis), granulomatous disorders (e.g., sarcoidosis or granulomatosis with polyangiitis), autoimmune disease, vasculitis, numerous viruses (e.g., coxsackievirus, cytomegalovirus, adenovirus, mumps, rubella, influenza B and Epstein-Barr), or even neoplastic disorders. Laboratory testing and radiologic evaluation are essential to rule out these other potential causes, or any substantial comorbidities that may

have been undiagnosed previously. While a “shotgun” diagnostic approach is discouraged in these cases, a targeted systemic workup based on the patient's personal and family history as well as concurrent symptoms or signs is essential.

Comanagement with the patient's primary care physician may be the best and most efficient way to obtain this information. In my case, MRI with and without contrast of the brain was ordered as a prophylactic measure.

Unringing That Bell

Strong evidence suggests that systemic corticosteroids may hasten recovery of Bell's palsy.^{8,10-14} The preferred therapeutic regimen is prednisolone 60mg/d (in divided doses) for five days, then subsequently tapered for five additional days.¹³ Ideally, treatment should be initiated within 72 hours following the onset of symptoms.^{8,10-14} There is less agreement among experts regarding the role of antivirals in acute Bell's palsy. Some studies show a modest benefit to oral antivirals, but the prevailing opinion is that these medications alone are no better than placebo. If considered at all, oral antiviral agents (e.g., valacyclovir 1,000mg TID for seven days) should be given in conjunction with oral corticosteroids, but only after alternate infectious causes have been eliminated.^{8,10-17} Non-traditional, but potentially beneficial, therapies may include acupuncture, hyperbaric oxygen therapy and various forms of physical therapy.¹⁸⁻²¹

The primary optometric goal in Bell's palsy is mitigating the effects of exposure keratopathy. Lubricating drops or ointments, or both, can be helpful for symptoms, but a bandage contact lens may be more protective to the cornea and provide greater, lasting relief. Nighttime exposure due to lagophthalmos can be prevented by taping the affected lids closed or by using a sleep/moisture retention mask. I found the Eyeseals Hydrating Sleep Mask (Eye Eco) to be exceptional. The use of external eyelid weights, such as Blinkze (MedDev Corporation) should be considered in the elderly, those with diabetes and those with pre-existing eye disease.²²

Many individuals with Bell's palsy will recover fully within several weeks to months, although some potential facial paralysis may linger. In such cases, surgical intervention may be a consideration, although the evidence for success is not extensive.^{4,23} Failure to observe resolution of signs after three months should prompt the clinician to consider an alternative diagnosis and initiate additional medical testing.

Advertisers Index

Acuity Pro/VisionScience Software, Inc. 101 Phone (877) 228-4890 or (580) 243-1301 Fax (580) 243-1377 info@acuitypro.com	Lombart Instruments 103, 105 Phone (800) 446-8092 Fax (757) 855-1232
Akorn Pharmaceuticals 61 Phone (800) 932-5676 www.akorn.com	Luneau Technology USA, Inc. 73 Phone (800) 729-1959 www.visionixusa.com
Alcon Laboratories 2, 7, 8, 15, 132 Phone (800) 451-3937 Fax (817) 551-4352	M&S Technologies 35 Phone (877) 225-6101 Fax (847) 763-9170
Allergan, Inc. 31 Phone (800) 347-4500	Marchon 71 Phone (800) 645-1300 Fax (800) 544-1334
Bausch + Lomb 25 Phone (800) 323-0000 Fax (813) 975-7762	Menicon 5 Phone (800) MENICON information@menicon.com www.meniconamerica.com
Beaver-Visitec International, Inc. ... 9 Phone (866) 906-8080 Fax (866) 906-4304 www.beaver-visitec.com	Natural Ophthalmics, Inc. 99 Phone (877) 220-9710 Info@NaturalEyeDrops.com www.NaturalEyeDrops.com
Bruder Ophthalmic Products 17 Phone (888) 827-8337 eyes@bruderophthalmic.com	NuSight Medical Operations . 55, 57 Phone (833) 468-5437 www.NuSightMedical.com
Coburn Technologies 37 Phone (800) 262-8761 www.coburntechnologies.com	Optos North America 89 Phone (877) 455-8855 x 100 Fax (508) 486-9310
CooperVision 131 Phone (800) 341-2020	PPG 79 Phone (724) 325-5168 www.ppgoptical.com
DGH Technology, Inc. 23 Phone (800) 722-3883 Fax (610) 594-0390 info@dghkoi.com www.dghkoi.com	Reichert Technologies 20-21 Phone (888) 849-8955 Fax (716) 686-4545 www.reichert.com
Eye Designs 53 Phone (800) 346-8890 Fax (610) 489-1414	Reliance Medical 43, 45, 47 Phone (800) 735-0357 Fax (513) 398-0256
Eyefinity 41 Phone (800) 269-3666	S4OPTIK 65, 67, 69 Phone (888) 224-6012
Haag-Streit 27, 77 Phone (800) 627-6286 Fax (603) 742-7217	TelScreen 50 www.TelScreen.com DryEye@TelScreen.com
Icare USA 33 Phone (888) 389-4022 www.icare-usa.com	U.S. Army 59 Phone (800) 431-6731 www.healthcare.goarmy.com/at66
IDOC 13 Phone (203) 853-3333 info@idoc.net optometry.idoc.net/learnmore	Veatch 83, 85, 87 Phone (800) 447-7511 Fax (602) 838-4934
Katena 29 Phone (800) 225-1195 www.katena.com	X-Cel Speciality Contacts 75 Phone (877) 336-2482 www.xcelspecialitycontacts.com
Keeler Instruments 10, 109 Phone (800) 523-5620 Fax (610) 353-7814	ZeaVision, LLC 38-39 Phone (866) 833-2800 support@eyepromise.com www.eyepromise.com
Lacrimedics, Inc 76 Phone (800) 367-8327 Fax (253) 964-2699 info@lacrimedics.com www.lacrimedics.com	

This advertiser index is published as a convenience and not as part of the advertising contract. Every care will be taken to index correctly. No allowance will be made for errors due to spelling, incorrect page number or failure to insert.

Therapeutic Review

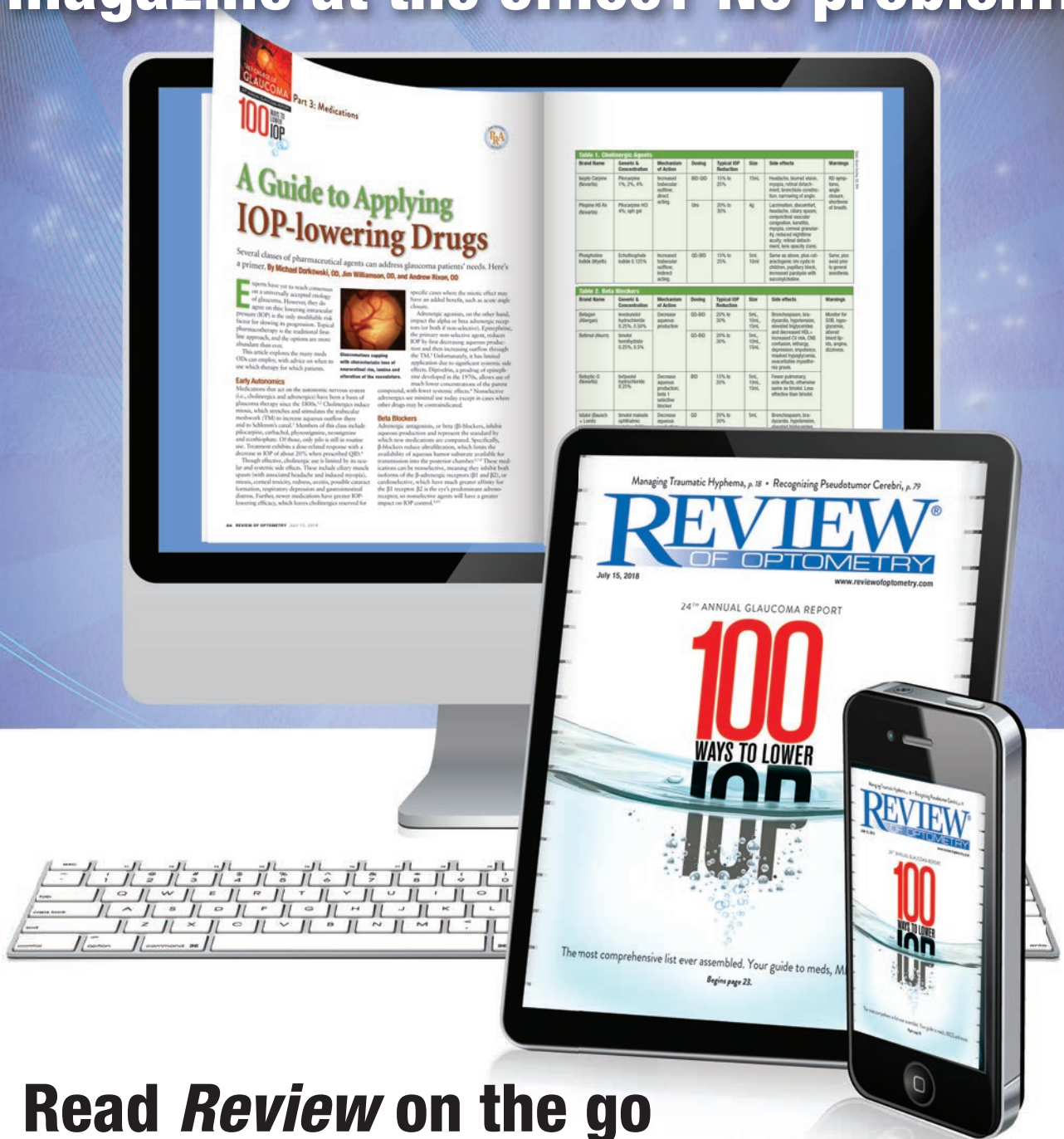As I write this, it has been 10 days since my initial onset of symptoms, and I'm already noting recovery of both sensory and motor function. I consider myself fortunate. I'm even curious to see what the inside of an MRI machine looks like.

Taking it to the Limit

On a very different note, I want to let our regular (and occasional) readers know that I will no longer be a regular contributor to Therapeutic Review. It has, in fact, been 14 years since Dr. Sowka and I penned our first column, and in the immortal words of Harry Callahan (Clint Eastwood), "A man's got to know his limitations." I am honored to have had the opportunity to share my clinical experience and insight with my colleagues and will continue to do so in other venues and media. Thanks to our numerous editors over the years for their talent, encouragement and patience, especially Mike Hoster and Bill Kekevan. ■

1. Baugh RF, Basura GJ, Ishii LE, et al. Clinical practice guideline: Bell's palsy. *Otolaryngol Head Neck Surg.* 2013;149(3 Suppl):S1-27.
2. Zandian A, Osiro S, Hudson R, et al. The neurologist's dilemma: A comprehensive clinical review of Bell's palsy, with emphasis on current management trends. *Med Sci Monit.* 2014;20:83-90.
3. Warner MJ, Dulebohn SC. Bell Palsy. *StatPearls* [Internet]. Treasure Island (FL): StatPearls Publishing; 2018 Apr 15.
4. Eviston TJ, Croxson GR, Kennedy PG, et al. Bell's palsy: aetiology, clinical features and multidisciplinary care. *J Neurol Neurosurg Psychiatry.* 2015;86(12):1356-61.
5. Somasundara D, Sullivan F. Management of Bell's palsy. *Aust Prescr.* 2017 Jun;40(3):94-97.
6. Albers JR, Tamang S. Common questions about Bell palsy. *Am Fam Physician.* 2014;89(3):209
7. Gagyor I, Madhok VB, Daly F, et al. Antiviral treatment for Bell's palsy (idiopathic facial paralysis). *Cochrane Database Syst Rev.* 2015;11:CD001869.
8. Madhok VB, Gagyor I, Daly F, et al. Corticosteroids for Bell's palsy (idiopathic facial paralysis). *Cochrane Database Syst Rev.* 2016;7:CD001942.
9. Patel DK, Levin KH. Bell palsy: Clinical examination and management. *Cleve Clin J Med.* 2015;82(7):419-26.
10. Sullivan FM, Swan IR, Donnan PT, et al. Early treatment with prednisolone or acyclovir in Bell's palsy. *N Engl J Med.* 2007; 357:1598-607.
11. Hato N, Yamada H, Kohno H, et al. Valacyclovir and prednisolone treatment for Bell's palsy: a multicenter, randomized, placebo-controlled study. *Otol Neurotol.* 2007;28(3):408-13.
12. Engström M, Berg T, Stjernquist-Desatnik A, et al. Prednisolone and valacyclovir in Bell's palsy: a randomised, double-blind, placebo-controlled, multicentre trial. *Lancet Neurol.* 2008; 7:993-1000.
13. Axelsson S, Berg T, Jonsson L, et al. Bell's palsy - the effect of prednisolone and/or valacyclovir versus placebo in relation to baseline severity in a randomised controlled trial. *Clin Otolaryngol.* 2012;37(4):283-90.
14. Berg T, Bylund N, Marsk E, et al. The effect of prednisolone on sequelae in Bell's palsy. *Arch Otolaryngol Head Neck Surg.* 2012;138(5):445-9.
15. Hato N, Sawai N, Teraoka M, et al. Valacyclovir for the treatment of Bell's palsy. *Expert Opin Pharmacother.* 2008;9(14):2531-6.
16. Lockhart P, Daly F, Pitkethly M, et al. Antiviral treatment for Bell's palsy (idiopathic facial paralysis). *Cochrane Database Syst Rev.* 2009;4:CD001869.
17. Gagyor I, Madhok VB, Daly F, et al. Antiviral treatment for Bell's palsy (idiopathic facial paralysis). *Cochrane Database Syst Rev.* 2015;11:CD001869.
18. Chen N, Zhou M, He L, et al. Acupuncture for Bell's palsy. *Cochrane Database Syst Rev.* 2010;8:CD002914.
19. Holland NJ, Bernstein JM, Hamilton JW. Hyperbaric oxygen therapy for Bell's palsy. *Cochrane Database Syst Rev.* 2012;2:CD007288.
20. Teixeira LJ, Valbuza JS, Prado GF. Physical therapy for Bell's palsy (idiopathic facial paralysis). *Cochrane Database Syst Rev.* 2011;12:CD006283.
21. Monini S, Buffoni A, Romeo M, et al. Kabat rehabilitation for Bell's palsy in the elderly. *Acta Otolaryngol.* 2017;137(6):646-50.
22. Hohman MH, Hadlock TA. Etiology, diagnosis, and management of facial palsy: 2000 patients at a facial nerve center. *Laryngoscope.* 2014;124:E283-93.
23. McAllister K, Walker D, Donnan PT, Swan I. Surgical interventions for the early management of Bell's palsy. *Cochrane Database Syst Rev.* 2013;10:CD007468.

Left your *Review of Optometry* magazine at the office? No problem!



24th Annual Glaucoma Report Part 3: Medications

100 WAYS TO LOWER IOP

A Guide to Applying IOP-lowering Drugs

Several classes of pharmaceutical agents can address glaucoma patients' needs. Here's a primer. **By Michael Berkowski, OD, Jim Williamson, OD, and Andrew Nixon, OD**

Experts have yet to reach consensus on a generally accepted ranking of glaucoma therapies. However, there do appear to be some key factors for choosing an agent on this basis, including immediate effect for lowering intraocular pressure, typical pharmacokinetics in the traditional dosing approach, and the option for more advanced drug classes.

This article explores the most common IOP-lowering agents and when to use each therapy for your patients.

Early Autonomics

Medications that act on the autonomic nervous system (i.e., cholinergics and adrenergics) have been a mainstay of glaucoma therapy since the 1950s. Cholinergics inhibit muscarinic receptors and stimulate the trabecular meshwork (TM) to increase aqueous outflow and to Schlemm's canal. Members of this class include pilocarpine, carbachol, phosfocarpine, neostigmine, and metoprolol. Of these, only pilocarpine is still in common use. Treatment exhibits a dose-related response with a decrease in IOP of about 30% when prescribed QID.¹ Though effective, cholinergic use is limited by its narrow therapeutic window and systemic side effects. These include blurry vision, increased salivary secretions, increased bronchospasm, increased vagal tone, and gastrointestinal distress. Further, newer medications have greater IOP-lowering efficacy, which leaves cholinergics reserved for

specific cases where the miotic effect may have an added benefit, such as acute angle closure.

Adrenergics, on the other hand, impact the alpha or beta adrenergic receptors (or both if non-selective). Epinephrine, the primary non-selective agent, reduces IOP by both decreasing aqueous production and then increasing outflow through the TM. Unfortunately, it has limited application due to significant systemic side effects. Diprivation, a product of epinephrine developed in the 1970s, allows use of much lower concentrations of the parent compound, with fewer systemic effects. Nonselective adrenergics are minimal use today except in cases where other drugs may be contraindicated.

Beta Blockers

Adrenergic antagonists, or beta (β)-blockers, inhibit aqueous production and represent the standard by which new medications are compared. Specifically, β-blockers reduce inflammation, which limits the availability of aqueous humor substrate available for transmission into the posterior chamber.^{2,3} These medications can be nonselective, meaning they inhibit both isoforms of the β-adrenergic receptors (β1 and β2), or cardioselective, which have much greater affinity for the β1 receptor. β1 is the eye's predominant adrenergic receptor, so nonselective agents will have a greater impact on IOP control.^{4,5}

Drug Name	Class & Concentration	Mechanism of Action	Dosing	Typical IOP Reduction	Size	Side effects	Warnings
Acetyl Carpine (Brevital)	Cholinergic 1%, 2%, 4%	Increased aqueous outflow	BD-QD	15% to 20%	15mL	Headache, blurred vision, myopia, retinal detachment, bronchospasm, sinus tachycardia, dry mouth, salivary gland enlargement	RD signs, avoid use in patients with glaucoma, avoid use in patients with narrow angle glaucoma
Phosphate NE Acetylcarpine	Cholinergic 4%, 8% qd	Increased aqueous outflow	QD	20% to 30%	4g	Lacrimation, decreased tear production, dry mouth, salivary gland enlargement, sinus tachycardia, retinal detachment, bronchospasm, sinus tachycardia, dry mouth, salivary gland enlargement	Some use alone, plus carbonic dehydratase inhibitor to increase outflow, usually with timolol
Phospholine Iodide (Iopidine)	Cholinergic 1.25%	Increased aqueous outflow	QD-QD	15% to 20%	5mL, 10mL	Some use alone, plus carbonic dehydratase inhibitor to increase outflow, usually with timolol	Some use alone to increase outflow, usually with timolol

Drug Name	Class & Concentration	Mechanism of Action	Dosing	Typical IOP Reduction	Size	Side effects	Warnings
Bimatoprost (Bimatoprost)	Beta Blocker 0.03%, 0.06%	Decreased aqueous production	QD	20% to 30%	5mL, 10mL	Headache, blurred vision, myopia, retinal detachment, sinus tachycardia, dry mouth, salivary gland enlargement	Monitor for RD, hyperopia, avoid use in patients with narrow angle glaucoma
Bimatoprost (Bimatoprost)	Beta Blocker 0.03%, 0.06%	Decreased aqueous production	QD	20% to 30%	5mL, 10mL	Headache, blurred vision, myopia, retinal detachment, sinus tachycardia, dry mouth, salivary gland enlargement	Monitor for RD, hyperopia, avoid use in patients with narrow angle glaucoma
Bimatoprost (Bimatoprost)	Beta Blocker 0.03%, 0.06%	Decreased aqueous production	QD	20% to 30%	5mL, 10mL	Headache, blurred vision, myopia, retinal detachment, sinus tachycardia, dry mouth, salivary gland enlargement	Monitor for RD, hyperopia, avoid use in patients with narrow angle glaucoma



Read *Review* on the go from any mobile device!

Simply go to www.reviewofoptometry.com and click on the digimag link to get your current issue.

25TH ANNUAL

OPHTHALMIC

Product Guide



Innovative products to
enhance your practice

The **future**
is in your
hands. One
tap, many
possibilities.

Experience the digital edition on your handheld device.
Use your smart device to scan the code below or visit:



www.reviewofoptometry.com/publications/archive

Download a QR scanner app. Launch app and hold your mobile device over
the code to view <https://www.reviewofoptometry.com/publications/archive>

REVIEW
OF OPTOMETRY

Merchandise Offered

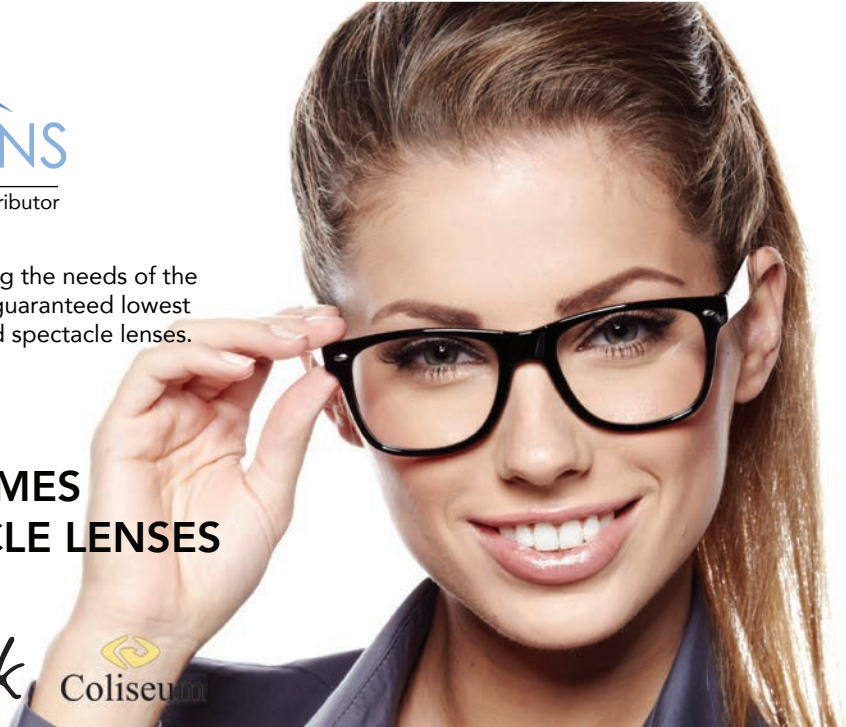


NATIONAL LENS

America's Leading Discount Optical Distributor

National Lens is dedicated to fulfilling the needs of the optical profession by providing the guaranteed lowest prices on contact lenses, frames, and spectacle lenses.

**CONTACT LENSES
100% ITALIAN FRAMES
FINISHED SPECTACLE LENSES**



GUARANTEED LOWEST PRICES | FREE FIRST CLASS SHIPPING*

*In stock products (when available)

Contact Lenses

Impressions

Color Contact Lens

Unleash your true color!



Amethyst * Brown * Grey * Green



Turquoise * Hazel * Honey * Pure Hazel * True Sapphire

Impressions colored contacts blend naturally with your patients eyes to create a beautiful look. Available in nine dazzling opaque colors of which Brown, Grey, Green, Hazel, Honey, Pure Hazel and True Sapphire are available in RX PL to -8.00. Impressions are fun, hip, fashionable and very competitively priced to help your bottom line. POP materials and posters are available upon request.

Available Exclusively at



America's Leading Discount Lens Distributor
1-866-923-5600 • 1-866-923-5601 FAX
www.national-lens.com

Equipment and Supplies

WHY PAY RETAIL???



Pretesting Tables of all shapes and sizes at Wholesale Prices.

Search the word PRETESTING at EBAY

Save hundreds even thousands on all your pretesting needs.

Or call: 316-734-4265

Place Your Ad Here!

Toll free: 888-498-1460

E-mail: sales@kerhgroup.com

Practice For Sale

ARE YOU IN CONTROL?

Don't buy a job...acquire a business.

Select clients have larger practices available for outright purchase. Positive cash flow and 100% financing available. America's leading optometry business development consultancy provides support before, during and after closure.

We'll help you acquire the optometry practice of your dreams with no cost to you. See our current offerings at:

<http://www.cleinman.com/buy>

800-331-5536



Practice Sales • Appraisals • Consulting
www.PracticeConsultants.com

**PRACTICES FOR SALE
NATIONWIDE**

Visit us on the Web or call us to learn more about our company and the practices we have available.

info@PracticeConsultants.com

800-576-6935

www.PracticeConsultants.com

Career Opportunities

Staff Optometrist Wanted

Bard Optical is a family owned full-service retail optometric practice with 22 offices (and growing) throughout Central Illinois. Bard Optical prides itself on having a progressive optometric staff whose foundation is based on one-on-one patient service. We are currently accepting CV/resumes for Optometrists to join our medical model optometric practice that includes extended testing. The practice includes but is not limited to general optometry, contact lenses and geriatric care. Salaried, full-time positions are available with excellent base compensation and incentive programs and benefits. Some part-time opportunities may also be available.

Current positions are available in Bloomington/Normal, Decatur/Forsyth, Peoria, Sterling and Canton as we continue to grow with new and established offices.

Please email your information to mhall@bardoptical.com or call Mick at 309-693-9540 ext 225.

Mailing address if more convenient is:

Bard Optical

Attn: Mick Hall, Vice President
8309 N Knoxville Avenue
Peoria, IL 61615

Bard Optical is a proud Associate Member of the Illinois Optometric Association.



www.bardoptical.com



Targeting Optometrists?

CLASSIFIED ADVERTISING WORKS

- JOB OPENINGS
- CME PROGRAMS
- PRODUCTS & SERVICES
- AND MORE...

Contact us today for classified advertising:

Toll free: 888-498-1460

E-mail: sales@kerhgroup.com



30 year private optometry practice opportunity

in Fairbanks, Alaska.

See patients of all ages.

Excellent leased location on busy thoroughfare.

907-978-7481

or [email virginalind@yahoo.com](mailto:virginalind@yahoo.com)

Career Opportunities

MEDICAL OPTOMETRISTS

The American Board of Certification in Medical Optometry (ABCMO) is recognized at Joint Commission (JC) accredited medical facilities as issuing board certification in the specialty of medical optometry and those ABCMO certifies are eligible for credentialing at these facilities as specialists rather than general optometry practitioners.[^]

The Joint Commission, the accepted national Gold Standard, reviews and accredits over 21,000 federal, state and local-chartered medical facilities.

To Be Eligible for ABCMO board certification:

1. Complete an accredited residency in medical optometry
2. Pass the national Advanced Competence in Medical Optometry Examination
3. Practice in a medical setting for a minimum of two years.*



www.abcmo.org

Visit www.abcmo.org to understand how JC accredited medical facilities credential specialists and why specialty certification can enhance the careers of optometrists who complete residencies in medical optometry.

For Application procedures see www.abcmo.org or contact myers.kenj@gmail.com

[^] At this time, 127 JC accredited hospitals, clinics and teaching institutions recognize ABCMO specialist certification.
^{*} www.jointcommission.org
^{*} Waived for two years after residency

Continuing Education

Dr. Travel Seminars, LLC

In Partnership With The NJ Society of Optometric Physicians

Baltic Sea / Northern European Capitals Cruise

NCL's Getaway - Sailing Roundtrip From Copenhagen, Denmark

July 22 - 31, 2019 (9 Night Cruise)

Sailing to Berlin/Lubeck, Tallinn, St. Petersburg (2 Days), Helsinki, Stockholm

Optional Private Group Tours

Optional Pre & Post Cruise Copenhagen Hotel Stay



Dr. TRAVEL SEMINARS, LLC is a COPE approved provider Course approved for 16 CE

Special Amenity Included: Choose Free

Drinks, Gratuities, Specialty Dining

"Comprehensive Program for the Anterior Segment, the Ocular Surface, and the Contact Lense Practice of the Future" - Jack Schaeffer, OD, FFAO

Additional Seminar Cruises (12-16 C E):

New Zealand Cruise: Jan. 25 - Feb. 6 2019 - R/T Sydney Australia - Princess Cruise Line's New Ship Randall Thomas, OD, FFAO

President's Week: February 16 - 23, 2019 - Royal Caribbean's New Ship - Symphony Of The Seas Special Group Pricing Now in Effect - SAVE \$900 Per Person (Ends Nov. 30)

Dalmatian Coast Cruise: June 28 - July 8, 2019 - Randall Thomas, OD, FFAO Venice to Rome - Celebrity Cruise Line - Special Pricing through April 19

www.DrTravel.com

800-436-1028

Do you have Equipment and Supplies for Sale?



Contact us today for classified advertising:

Toll free: 888-498-1460 • E-mail: sales@kerhgroup.com



Targeting Optometrists?

CLASSIFIED ADVERTISING WORKS

- JOB OPENINGS
- CME PROGRAMS
- PRODUCTS & SERVICES
- AND MORE...

Contact us today for classified advertising:

Toll free: 888-498-1460

E-mail: sales@kerhgroup.com





That's a Foul

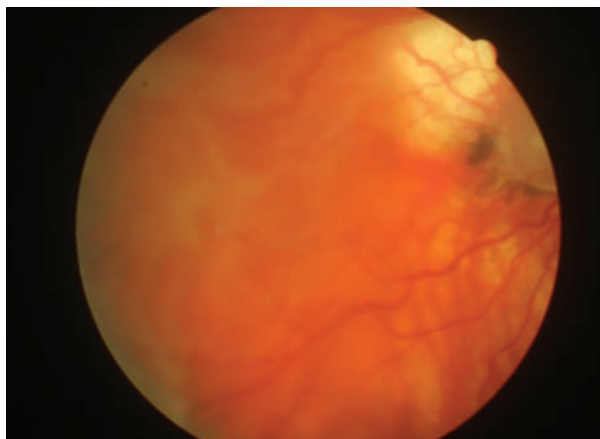
By Andrew S. Gurwood, OD

History

A 32-year-old Caucasian male reported to the clinic with a chief complaint of vision loss in his left eye following trauma received during a basketball game. He explained that he had been hit around the left eye by an elbow during a game, saw an impressive flash of light and now felt some of the floor was missing or foggy. His systemic and ocular histories were unremarkable and he denied exposure to chemicals or allergies of any kind.

Diagnostic Data

His best corrected entering visual acuities were 20/20 OU at distance and near. His external examination was normal with no evidence of afferent pupil defect. His peripheral confrontational visual field



After an elbow to the face during a basketball game, this 32-year-old's fundus looked like this. Can this image and his presentation combined explain his visual disturbance?

found distorted and missing floor in the inferior temporal quadrant. The biomicroscopic examination of the anterior segments found normal structures with Gold-

mann applanation tonometry measuring 15mm Hg OU.

The pertinent dilated fundus findings are demonstrated in the photograph.

Your Diagnosis

Does the case presented require any additional tests, history or information? What steps would you take to manage

this patient? Based on the information provided, what would be your diagnosis? What is the patient's most likely prognosis? To find out, visit www.reviewofoptometry.com.

Retina Quiz Answers (from page 117): 1) a; 2) c; 3) a; 4) b; 5) d.

Next Month in the Mag

In our October issue, *Review of Optometry* will take a special look at optometry, today and tomorrow. Topics include:

- *A Comprehensive State-By-State Look at Optometric Scope of Practice Laws*
- *Strategic Planning Decisions: Partnerships, Retirement, Alliances and more*

- *How is Your Practice Faring in the Age of Online Refraction Testing?*
- *Landmark Glaucoma Studies: What's Still Relevant and What Isn't?*
- *The ABCs of Radiologic Testing for the Optometrist.* (Earn 2 CE credits)

REVIEW OF OPTOMETRY (ISSN 0147-7633) IS PUBLISHED MONTHLY, 12 TIMES A YEAR BY JOBSON MEDICAL INFORMATION LLC, 440 9TH AVENUE, 14TH FLOOR, NEW YORK, NY 10013-1678. PERIODICALS POSTAGE PAID AT NEW YORK, NY AND ADDITIONAL MAILING OFFICES. POSTMASTER: SEND ADDRESS CHANGES TO REVIEW OF OPTOMETRY, PO BOX 81, CONGERS, NY 10920-0081. SUBSCRIPTION PRICES: US: ONE YEAR \$56; TWO YEARS \$97, CANADA: ONE YEAR \$88, TWO YEARS \$160, INT'L: ONE YEAR \$209, TWO YEARS \$299. FOR SUBSCRIPTION INFORMATION CALL TOLL-FREE (877) 529-1746 (USA); OUTSIDE USA, CALL (845) 267-3065. OREMAIL US AT REVOPPTOMETRY@CAMBEYWEST.COM. PUBLICATIONS MAIL AGREEMENT NO: 40612608. CANADA RETURNS TO BE SENT TO BLEUCHIP INTERNATIONAL, P.O. BOX 25542, LONDON, ON N6C 6B2.

the contact lens choice
for future leaders, busy mamas
& joy seekers alike.



It's a great, big, beautiful world out there. Upgrade your 2-week and monthly patients to the convenience of clariti® 1 day, a high-oxygen silicone hydrogel 1-day lens at the price of a hydrogel. Plus, with a full family of lenses, there's a clariti® 1 day to fit virtually all patients. To which we say, Oh, happy day. [Prescribecleariti.com](https://www.Prescribecleariti.com)

clariti® 1 day

GIVE YOUR PATIENTS OUTSTANDING COMFORT FROM DAY 1 TO DAY 30^{1-3*}



Excellent Deposit Protection^{4,5}



Lasting Lens Surface Moisture^{6,7}

AIR OPTIX[®]
plus
HydraGlyde[®]
contact lenses
Alcon A Novartis
Division

FOR A LIMITED TIME, PATIENTS CAN
SAVE UP TO \$50

ON AN ANNUAL SUPPLY VIA MAIL-IN OR ONLINE REBATE**
WITH THE AIR OPTIX[®] CHOICE PROGRAM!

Visit AIROPTIXCHOICE.com to learn more

*Based on clinical studies with AIR OPTIX[®] AQUA contact lenses.

**Savings via mail-in (or online) rebate in the form of an Alcon VISA[®] pre-paid card. Valid on an annual supply purchase (four 6-ct boxes) of AIR OPTIX[®] brand lenses from your eye care professional or participating retailer between 5/1/18 and 12/31/18. An eye exam or lens fitting is required and must occur within 90 days prior to your contact lens purchase. Rebate claim must be submitted within sixty (60) days of your purchase. Additional Restrictions apply. Visit AIROPTIXCHOICE.com for full Terms and Conditions. Questions? Call 1-855-344-6871.

References: 1. Eiden SB, Davis R, Bergenske P. Prospective study of lotrafilcon B lenses comparing 2 versus 4 weeks of wear for objective and subjective measures of health, comfort, and vision. *Eye Contact Lens*. 2013;39(4):290-294. 2. Lemp J, Kern J. A comparison of real time and recall comfort assessments. *Optom Vis Sci*. 2016;93:Eabstract 165256. 3. Merchea M, Mathew J, Mack C. Assessing Satisfaction with lotrafilcon B Packaged with an EOBO Wetting Agent Combined with EOBO-Based Lens Care Solutions. Poster presented at the Annual Meeting of the American Academy of Optometry, October 11-14, 2017, Chicago, IL. 4. Nash W, Gabriel M, Mowrey-McKee M. A comparison of various silicone hydrogel lenses; lipid and protein deposition as a result of daily wear. *Optom Vis Sci*. 2010;87:Eabstract 105110. 5. Nash WL, Gabriel MM. Ex vivo analysis of cholesterol deposition for commercially available silicone hydrogel contact lenses using a fluorometric enzymatic assay. *Eye Contact Lens*. 2014;40(5):277-282. 6. In vitro study over 16 hours to measure wetting substantivity, Alcon data on file, 2015. 7. Muya L, Lemp J, Kern JR, Sentell KB, Lane J, Perry SS. Impact of packaging saline wetting agents on wetting substantivity and lubricity. *Invest Ophthalmol Vis Sci* 2016;57:E-abstract 1463.

Important information for AIR OPTIX[®] plus HydraGlyde[®] (lotrafilcon B): For daily wear or extended wear up to 6 nights for near/farsightedness, presbyopia and/or astigmatism. Risk of serious eye problems (i.e. corneal ulcer) is greater for extended wear. In rare cases, loss of vision may result. Side effects like discomfort, mild burning or stinging may occur.



Recommend CLEAR CARE[®] PLUS
or OPTI-FREE[®] Puremoist[®]
as the perfect combination
with AIR OPTIX[®] lenses.

Alcon A Novartis
Division

See product instructions for complete wear, care and safety information.

Rx only

© 2018 Novartis 08/18 US-AOH-18-E-0424(2)