

EARN 2 CE CREDITS: *Managing Uveitis With Steroids and Biologic Agents*


REVIEW[®] OF OPTOMETRY

May 15, 2018

www.reviewofoptometry.com








PATHS TO
DRY

*Its causes and courses vary wildly.
Here  expert advice on finding your way.*

EYE
SUCCESS

19TH ANNUAL DRY EYE REPORT

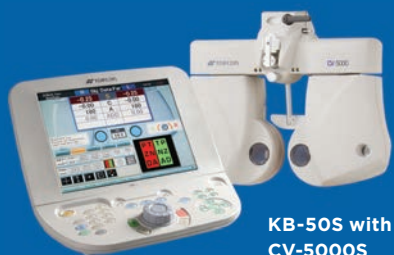Four Steps to a Simple and Effective Screening, P. 34  All About Osmolarity, P. 42  Mixed DED: A Chimera in Your Chair, P. 50
Managing Dry Eye for the Long Haul, P. 58  Sjögren's, Dry Eye and You, P. 68

ALSO: Finding Systemic Diseases in the Anterior Segment, P. 78  *New series*  Take Charge of Glaucoma, P. 88

AVOID TRANSCRIPTION ERRORS. GO DIGITAL.

Pencils Down

Easily output all examination data to your EMR with the touch of a button—no transcription necessary. Automatically send pre-test data and patient name to every CV-5000S system throughout your office. Save time and make paperless refraction a reality. Learn more at topconmedical.com.



KB-50S with
CV-5000S

 **TOPCON**

YOUR VISION. OUR FOCUS.

IN THE NEWS

Individuals born at below-average weight are more likely to have refractive issues in adulthood, according to new research. The study defined low birth weight (BW) as less than 5.5lbs, normal as between 5.5lbs and 8.8lbs and high BW as 8.8lbs or more. Investigators looked at 8,369 study participants and found **an association between low BW and both spherical equivalent and best-corrected visual acuity** compared with normal BW.

Fieß A, Schuster AK, Nickels S, et al. Association of low birth weight with myopic refractive error and lower visual acuity in adulthood: results from the population-based Gutenberg Health Study (GHS). *Br J Ophthalmol*. March 15, 2018. [Epub ahead of print].

Researchers have developed a **hydrogel eye drop filled with nanoparticles containing cannabigerolic acid (CBGA), a cannabis compound that shows promise in relieving glaucoma symptoms**. The new delivery system may aid treatment during sleep. The drops, applied before bedtime, form a coating over the eye and the nanoparticles dissolve slowly during the night, reaching the cornea. The coating dissolves by morning.

Kabiri M, Kamal SH, Pawar SV, et al. A stimulus-responsive, in situ-forming, nanoparticle-laden hydrogel for ocular drug delivery. *Drug Deliv Transl Res*. March 5, 2018. [E-pub ahead of print].

A new study suggests **glaucoma patients find sustained treatment options**—drug-eluting contact lenses, ring inserts, punctal plugs and subconjunctival injections—**acceptable, but with caveats**. The treatment's ability to eliminate surgery was key to acceptance, as was efficacy. Contact lenses were the most acceptable (59%), while rings were the least (51%). Only 23% to 35% approved of an alternative if it reduced drops, and 27% to 42% said it was OK if it eliminated glaucoma drops.

Varadaraj V, Kahook MY, Ramulu PY, Pitha IF. Patient acceptance of sustained glaucoma treatment strategies. *J Glaucoma*. 2018;27(4):328-35.

Eye Care Education Expands Abroad

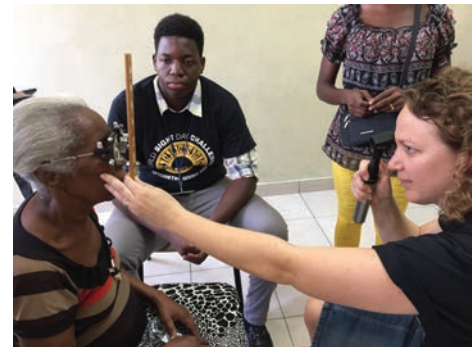Haiti's new optometry school will provide much-needed care to the community.

By Bill Kekevan, Senior Editor

The trend of new optometric educational institution launches, which added six schools in the United States in the last decade, now extends internationally. The Republic of Haiti recently opened its first facility, the School of Optometry & Vision Sciences at the Faculty of Medicine and Pharmacy of l'Université d'État d'Haïti in its capital city Port-au-Prince. The school's five-year program aims to graduate 16 ODs a year.

Until now, the island, which hosts a population of approximately 10 million, has been home to just three optometrists. However, the small nation has the highest level of blindness and visual impairment in its region, according to a press release about the launch. In fact, the Haitian National Committee for the Prevention of Blindness (CNPC) estimates the prevalence of blindness at 1%, while other regional data estimates moderate and severe visual impairment at 5% and 22%, respectively.¹

“With virtually no optometrists, there has been limited opportunity for the Haitians to obtain quality vision care,” said Jeff Duncan, executive vice president and chief operating officer for Vision Source, a major donor and partner.



Dr. Christine Bowman and Dr. Shane Foster with Vision Source participate in community outreach clinic in Port-au-Prince.

Haiti, a nation located on the Caribbean island of Hispaniola, approximately 400 miles southeast of Cuba, has suffered a series of recent natural disasters. In particular, a devastating earthquake in 2010 cost hundreds of thousands of lives.

The effort to open this optometry school goes back five years, according to Christina Sanko, the senior director of development at Optometry Giving Sight.

The school was founded with the aid of Vision Source and Optometry Giving Sight, a joint venture of the Brien Holden Vision Institute Foundation, International Agency for the Prevention of Blindness and the World Council of Optometry, which was created to mobilize resources from the global optometric

(continued on page 4)

Vets and Dry Eye: A Whole Body Issue

Researchers at the Miami Veterans Administration (VA) Medical Center, Bascom Palmer Eye Institute and Miller School of Medicine teamed up to take a look at dry eye disease (DED) in veterans—and found some interesting results.

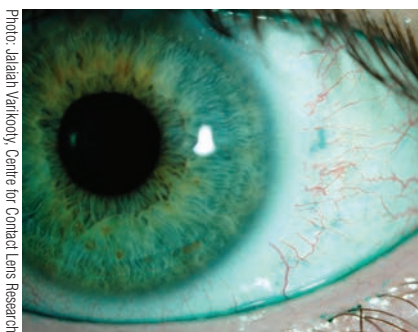

Photo: Jalalain Varikooly, Centre for Contact Lens Research

Dry eye is always complex, but new data suggests veterans may have even more confounding factors at play.

Body and Mind

One of two studies found chronic pain conditions and mental health issues such as post-traumatic stress disorder (PTSD) correlate with more intense DED symptoms.¹

The study looked at 326 patients using quantitative sensory testing to assess nociceptive system integrity and both the Dry Eye Questionnaire-5 and Ocular Surface Disease Index to document dry eye symptoms. It found that mental health indices positively correlated with a discordance between DED signs and symptoms.

TBI-DED Link

The same researchers also found DED and other pain disorders occur more frequently in patients with traumatic brain injury (TBI), suggesting a shared pathophysiology. Researchers retrospectively reviewed the charts of veterans seen

in a VA hospital between January 2010 and December 2014 to determine the prevalence of DED and comorbidities. They then compared results between those with and without a diagnosis of TBI.²

The records revealed that patients with a TBI diagnosis were more likely to also have a DED diagnosis than those without TBI. Those with TBI were also twice as likely to suffer from chronic pain, headache, depression or PTSD. Analysis showed that “central pain syndrome, cluster headache, sicca syndrome, keratoconjunctivitis sicca and late effect of injury to the nervous system (as can be seen after TBI) were all closely clustered together,” the study says.²

An earlier report found dry eye

comorbid with other chronic pain syndromes. Among the population studied, 29.4% experienced dry eye, and disease frequency increased with the number of pain conditions reported. Ocular pain was most strongly associated with headache, temporomandibular joint dysfunction, pelvic pain, central pain syndrome and fibromyalgia/muscle pain. Tear film dysfunction was most closely associated with osteoarthritis and postherpetic neuralgia.³

1. Ong ES, Felix ER, Levitt RC, et al. Epidemiology of discordance between symptoms and signs of dry eye. *Br J Ophthalmol.* 2018;102(5). [Epub ahead of print].
2. Lee CJ, Felix ER, Levitt RC, et al. Traumatic brain injury, dry eye and comorbid pain diagnoses in US veterans. *Br J Ophthalmol.* 2018;102(5). [Epub ahead of print].
3. Charity CJ, Levitt RC, Felix ER, et al. Evidence that dry eye is a comorbid pain condition in a U.S. veteran population. *Pain Reports: Nov/Dec 2017*;2(6):629.

Haitian OD Education

(continued from page 3)

community in an effort to eliminate refractive error blindness and low vision across the world.²

Push for Legal Recognition

Currently, Haiti is largely unaware of the profession of optometry, according to Christina Sanko, the senior director of development at Optometry Giving Sight. The organization had to advocate not only for a school but also for the profession itself, she said.

The school is now in the process of seeking accreditation from the nation’s ministers of health and education. The Brien Holden Vision Institute is assisting in that process by helping to educate government officials about the discipline and what it can offer Haitians, according to Ms. Sanko.

Curriculum

The school already has 19 students enrolled and is bringing in two optometrists from Quebec to teach—the students are currently taking medical school classes alongside ophthalmology students.

“The curriculum is based on the US model,” explains Ms. Sanko. The program also offers a fifth year in which students will use their newfound skills to perform community service.

School benefactors expect the Haitian government will embrace optometry “once they see how ophthalmology can work in tandem with optometry,” says Ms. Sanko.

1. Tousignant B, Brûlé J. Prevalence of eye disease and visual impairment in Île de la Gonave, Haiti. *Med Sante Trop.* 2017 Aug 1;27(3):326-8.
2. Optometry Giving Sight. Welcome. www.givingsight.org/about2/welcome.html. Accessed April 12, 2018.

THE JOURNEY TO **IMPROVED VISION** STARTS WITH *YOU*

Successful cataract surgery often depends on strong collaboration between patients, optometrists, and surgeons. **Alcon is here to support YOU** in building those partnerships.

Alcon Surgical Offerings

- The AcrySof® family of IOLs has been implanted over **100 MILLION TIMES**¹ – more than any other brand – and provides exceptional quality, clarity, and stability.²⁻⁴
- Our full range of products helps you meet each individual's needs, including astigmatic and presbyopic patients.
- We provide resources to support collaborative care between the optometrist and ophthalmologist.

Visit myalcon.com/cataractresources to order resources for your patients and your practice.

Alcon A Novartis
Division

 AcrySof® IQ IOL Family

References: 1. Alcon sales data on file. 2. Wirtitsch MG, Findl O, Menapace R, et al. Effect of haptic design on change in axial position after cataract surgery. *J Cataract Refract Surg.* 2004;30(1):45-51. 3. Visser N, Bauer NJ, Nuijts RM. Toric intraocular lenses: Historical overview, patient selection, IOL calculation, surgical techniques, clinical outcomes, and complications. *J Cataract Refract Surg.* 2013;39(4):624-637. 4. Potvin R, Kramer BA, Hardten DR, Berdahl JP. Toric intraocular lens orientation and residual refractive astigmatism: An analysis. *Clin Ophthalmol.* 2016;10:1829-1836.

© 2018 Novartis 04/18 US-ODE-18-E-0547a

AcrySof® Family of Single-Piece IOLs Important Product Information

(AcrySof® UV, AcrySof® IQ, AcrySof® IQ Toric, AcrySof® IQ ReSTOR®, and AcrySof® IQ ReSTOR® Toric IOLs)

CAUTION: Federal law restricts these devices to sale by or on the order of a physician. **INDICATION:** The family of AcrySof® single-piece intraocular lenses (IOLs) includes AcrySof® UV-absorbing IOLs ("AcrySof® UV"), AcrySof® IQ, AcrySof® IQ Toric and AcrySof® IQ ReSTOR® and AcrySof® IQ ReSTOR® Toric IOLs. Each of these IOLs is indicated for visual correction of aphakia in adult patients following cataract surgery. In addition, the AcrySof Toric IOLs are indicated to correct pre-existing corneal astigmatism at the time of cataract surgery. The AcrySof IQ ReSTOR IOLs are for cataract patients with or without presbyopia, who desire increased spectacle independence with a multifocal vision. All of these IOLs are intended for placement in the capsular bag. **WARNINGS/PRECAUTIONS: General cautions for all AcrySof® and AcrySof® UV IOLs:** Careful preoperative evaluation and sound clinical judgment should be used by the surgeon to decide the risk/benefit ratio before implanting any IOL in a patient with any of the conditions described in the Directions for Use that accompany each IOL. Caution should be used prior to lens encapsulation to avoid lens decentration or dislocation. Viscoelastic should be removed from the eye at the close of surgery. **Additional Cautions associated with AcrySof® IQ ReSTOR® IOLs:**

Some patients may experience visual disturbances and/or discomfort due to multifocality, especially under dim light conditions. A reduction in contrast sensitivity may occur in low light conditions. Visual symptoms may be significant enough that the patient will request explant of the multifocal IOL. Spectacle independence rates vary with all multifocal IOLs; as such, some patients may need glasses when reading small print or looking at small objects. Clinical studies indicate that posterior capsule opacification (PCO), when present, may develop earlier into clinically significant PCO with multifocal IOLs. **Additional Cautions associated with AcrySof® IQ Toric, AcrySof® UV Toric and ReSTOR® Toric IOLs:** Optical theory suggests that, high astigmatic patients (i.e. > 2.5 D) may experience spatial distortions. Possible toric IOL related factors may include residual cylindrical error or axis misalignments. Toric IOLs should not be implanted if the posterior capsule is ruptured, if the zonules are damaged, or if a primary posterior capsulotomy is planned. Rotation can reduce astigmatic correction; if necessary lens repositioning should occur as early as possible prior to lens encapsulation. Prior to surgery, physicians should provide prospective patients with a copy of the appropriate Patient Information Brochure available from Alcon informing them of possible risks and benefits associated with the AcrySof® IQ Toric, AcrySof® IQ ReSTOR® and AcrySof® IQ ReSTOR® Toric IOLs. Do not resterilize. Do not store at temperatures over 45° C. Use only sterile irrigating solutions to rinse or soak IOLs. **ATTENTION:** Refer to the Directions for Use labeling for the specific IOL for a complete list of indications, warnings and precautions.

News Review

AI Takes on Diabetic Retinopathy

The FDA recently cleared for marketing a product called IDx-DR, the first medical device that uses artificial intelligence (AI) to detect "greater than mild" diabetic retinopathy (DR) in adults with diabetes. It is marketed by privately owned start-up venture IDx, LLC, of Coralville, IA.

An FDA release says IDx-DR "provides a screening decision without the need for a clinician to also interpret the image or results, which makes it usable by health care providers who may not normally be involved in eye care."

The system uses an AI algorithm to analyze images taken with a Topcon NW400 retinal camera and uploaded to a cloud server. The software then provides one of two results: (1) "more than mild diabetic retinopathy detected: refer to an eye care professional" or (2) "negative for more than mild diabetic retinopathy; rescreen in 12 months."

As part of the decision, the FDA evaluated data from a clinical study of retinal images obtained from 900 patients with diabetes at 10 primary care sites. In the study, IDx-DR correctly identified the presence of more than mild diabetic retinopathy 87.4% of the time and correctly identified those who did not have more than mild diabetic retinopathy 89.5% of the time.

The approval comes with con-

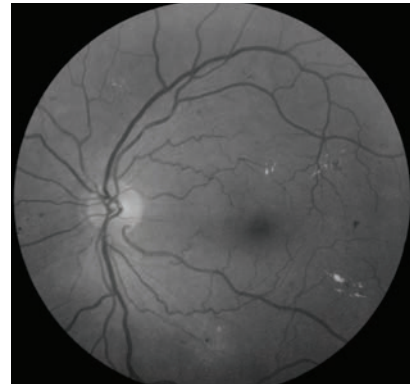


Photo: A. Paul Chrous, MD

Fig. 1. This patient with mild non-proliferative DR shows microaneurysms, mild intraretinal hemorrhage and hard exudate formation outside the central macula. The patient has had Type 2 diabetes for nine years, had a recent HbA1c of 7.2%, blood pressure of 137/88, 20/20 visual acuity in each eye, and is on metformin plus Levemir (insulin detemir, NovoNordisk); this patient would not be flagged for referral to an eye care provider by the newly approved AI diagnostic protocol.

traindications, however. Patients who shouldn't be screened with the device include those with a history of laser treatment, surgery or injections in the eye or who have persistent vision loss, blurred vision, floaters, previously diagnosed macular edema, severe non-proliferative retinopathy, proliferative retinopathy, radiation retinopathy or retinal vein occlusion. Other contraindications include patients with diabetes who are pregnant.

 AcrySof® IQ IOL Family

 A Novartis Division

© 2018 Novartis 04/18 US-ODE-18-E-0547a



Want to see more? Check out *Review of Optometry's* daily News Feed at www.reviewofoptometry.com/news or scan the QR code.

AI and ODs

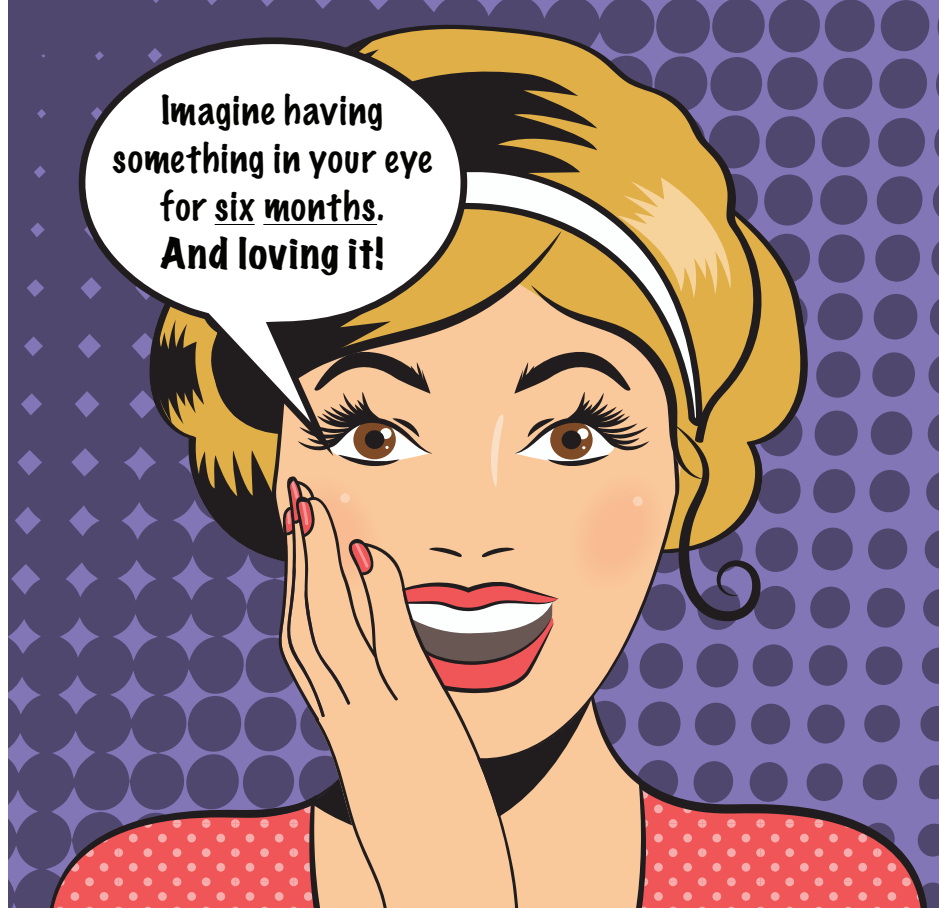"The argument for diabetic eye disease screening with AI is that it can provide care to those who

otherwise wouldn't have access—and that will save patients' vision, the healthcare system money and even boost revenue for some practitioners, depending on the reimbursement by third-party payers," says diabetes expert A. Paul Chous, OD, who has a private practice in Tacoma, WA. "But it comes with some downsides ODs need to be aware of."

Patients with diabetes often have other ocular complications that won't be detected by AI, and while DR screening may come back negative, that doesn't mean the patient's eyes are healthy, Dr. Chous says. In addition, the study that led to this device's approval still had a 13% false-positive rate, leaving significant room for improvement. A major stumbling block, according to Dr. Chous, is the technology's inability to detect milder forms of diabetic retinopathy and in particular diabetic macular edema, a disease Dr. Chous says is best detected via stereo ophthalmoscopy and optical coherence tomography. "Also, evidence shows structural and functional abnormalities long before the appearance of retinal vascular findings associated with DR," he says, "and passing or failing patients based on a specific threshold may eliminate early intervention for patients with a milder form—a crucial step in saving vision long-term" (Figure 1).

"AI will be a part of diabetes care in the future, no doubt," Dr. Chous concludes. "But for now, it makes much more sense, in most communities, for primary care providers and other specialists to work collaboratively with eye care providers to ensure the best patient care."

US Food and Drug Administration. FDA permits marketing of artificial intelligence-based device to detect certain diabetes-related eye problems. www.fda.gov/NewsEvents/Newsroom/PressAnnouncements/ucm604357.htm. April 11, 2018. Accessed April 12, 2018.

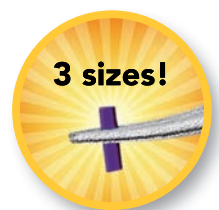

Six Full Months* of Effective Dry Eye Relief

The Extend 180™ Long-Term Dissolvable Implant

Featuring

- Simple insertion technique
- No foreign body sensation
- Exceptionally reliable retention



Indications

- Post-ocular surgery or seasonal dry eye
- Contact lens intolerance
- Dry eye associated with digital eye strain

1-866-906-8080
bvimedical.com



* 510(k) Summary K162361

BVI, BVI Logo and all other trademarks (unless noted otherwise) are property of Beaver-Visitec International ("BVI") © 2018 BVI

Autism-Accommodative Connection

Children with autism spectrum disorder (ASD) are significantly more likely to have accommodative deficits and associated near visual deficits, than typically developing children, according to investigators in the United Kingdom. The study, published in the March issue of *Optometry and Vision Science*, looked at 124 participants between ages six and 17 who had ASD, and 204 age-matched control subjects. It found 17.4% of subjects in the ASD group had significant lag in accommodation while only 4.9% of the control group displayed similar symptoms, as assessed by modified Nott dynamic retinoscopy.¹

The researchers advised “appraisal of refractive error, accommodation and NVA [near visual acuity] should be considered in visual assessment of children with ASD.” In prior studies, researchers

have discovered that children with developmental disabilities such as Down syndrome are also likely to have accommodative deficits.²

ASD refers to a range of conditions that can have a wide variety of symptoms that often impact communication and social interaction. Due to this, performing an ocular exam on patients with ASD requires special skills.

Kathleen Elliott, OD, a pediatric optometrist in Oklahoma, suggests taking a few special considerations into mind. Children on the autism spectrum “generally do not like having the phoropter against their face, so the preferred method of retinoscopy is lens bars,” she says. She goes on to describe how this is performed in her office. “During retinoscopy, the younger children are placed on the parent’s lap and we have them look at a cartoon at the end of the room or a toy, or the

parent can use their phone or device for them to look at to get their attention while the doctor performs the retinoscopy.”

She also stresses the importance of “a good cycloplegic refraction, dilating the eyes with 1% cyclopentolate as well as 2.5% phenylephrine.” Finally, she says, “To evaluate the retina with binocular indirect ophthalmoscopy, have a technician hold a toy to hold the child’s attention. Younger children may need their head secured by the parent or nurse to ensure a good view. We have a method on smaller children, toddlers and infants in which the child is on their back with their head secured.”

1. Anketell P, Saunders K, Gallagher S, et al. Accommodative Function in Individuals with Autism Spectrum Disorder. *Optom Vis Sci.* 2018;95(3):193-201.

2. Woodhouse JM, Cregg M, Gunter HL, et al. The effect of age, size of target, and cognitive factors on accommodative responses of children with Down syndrome. *Invest Ophthalmol Vis Sci.* 2000;41(9):2479-85.

Opternative Working With ODs

File under: “If you can’t beat ’em, join ’em.” On the heels of a new Kentucky law that attempts to find common ground with optometrists, online refractive start-up Opternative recently announced two major developments.

The company will now offer software that enables an eye care practice to include digital refractions and visual acuity tests on its own website. The software, EZRx, will license a digital refraction and visual acuity screener in such a way that matches an individual optometry practice’s branding and website flow.

Previously, ophthalmologists

reviewed Opternative’s online refractions since they could operate across state lines. However, EZRx brings optometrists into the mix by associating the software with their individual practices. In turn, practice owners are charged a subscription fee.

In the same week, Opternative announced a partnership with web-based company, Lensabl, a lab that will “cheaply replace old lenses with an updated prescription,” according to the company’s website.

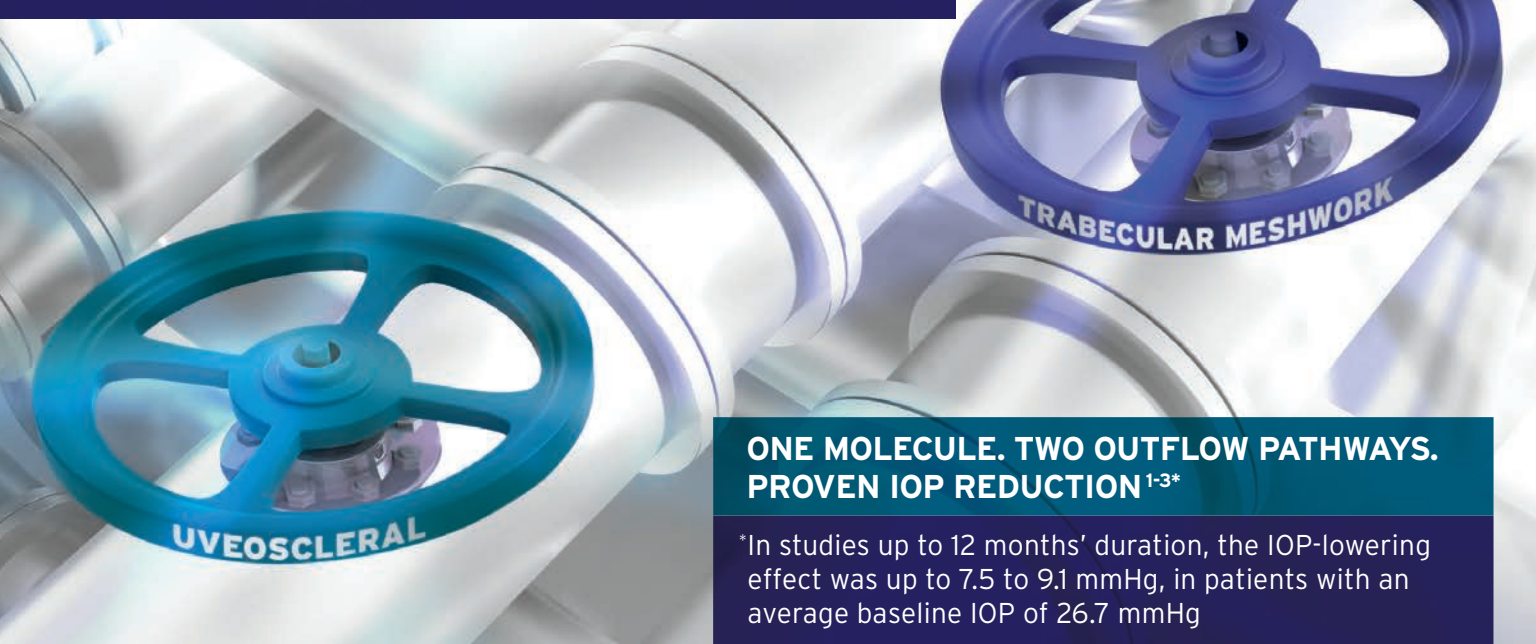
A new law recently signed by Kentucky Governor Matt Bevin appears to represent a compromise between the optometric commu-

nity and Opternative. The Consumer Protection in Eye Care Act provides specific regulations for telehealth and online eye tests. It requires all patients to be at least 18 years old and for all patients to complete an in-person eye exam at least once every 24 months. It also keeps the patient’s business in-state by requiring all diagnostic information and data be reviewed by a Kentucky licensed physician.

“This is a turning point victory for higher standards, greater accountability and improved outcomes in health care,” a representative for the AOA told VMail, a publication of *Vision Monday*. ■

VYZULTA DELIVERS A DUAL MECHANISM OF ACTION

FOR THE REDUCTION OF IOP IN GLAUCOMA PATIENTS¹



**ONE MOLECULE. TWO OUTFLOW PATHWAYS.
PROVEN IOP REDUCTION^{1-3*}**

*In studies up to 12 months' duration, the IOP-lowering effect was up to 7.5 to 9.1 mmHg, in patients with an average baseline IOP of 26.7 mmHg

INDICATION

VYZULTA™ (latanoprostene bunod ophthalmic solution), 0.024% is indicated for the reduction of intraocular pressure (IOP) in patients with open-angle glaucoma or ocular hypertension.

IMPORTANT SAFETY INFORMATION

- Increased pigmentation of the iris and periorbital tissue (eyelid) can occur. Iris pigmentation is likely to be permanent
- Gradual changes to eyelashes, including increased length, increased thickness, and number of eyelashes, may occur. These changes are usually reversible upon treatment discontinuation
- Use with caution in patients with a history of intraocular inflammation (iritis/uveitis). VYZULTA should generally not be used in patients with active intraocular inflammation
- Macular edema, including cystoid macular edema, has been reported during treatment with prostaglandin analogs. Use with caution in aphakic patients, in pseudophakic patients with a torn posterior lens capsule, or in patients with known risk factors for macular edema

IMPORTANT SAFETY INFORMATION (CONTINUED)

- There have been reports of bacterial keratitis associated with the use of multiple-dose containers of topical ophthalmic products that were inadvertently contaminated by patients
- Contact lenses should be removed prior to the administration of VYZULTA and may be reinserted 15 minutes after administration
- Most common ocular adverse reactions with incidence $\geq 2\%$ are conjunctival hyperemia (6%), eye irritation (4%), eye pain (3%), and instillation site pain (2%)

For more information, please see Brief Summary of Prescribing Information on next page.

References:

1. VYZULTA Prescribing Information. Bausch & Lomb Incorporated. 2017.
2. Weinreb RN, Sforzolini BS, Vittitow J, Liebmann J. Latanoprostene bunod 0.024% versus timolol maleate 0.5% in subjects with open-angle glaucoma or ocular hypertension: the APOLLO study. *Ophthalmology*. 2016;123(5):965-973.
3. Medeiros FA, Martin KR, Peace J, Sforzolini BS, Vittitow JL, Weinreb RN. Comparison of latanoprostene bunod 0.024% and timolol maleate 0.5% in open-angle glaucoma or ocular hypertension: the LUNAR study. *Am J Ophthalmol*. 2016;168:250-259.

For more information about VYZULTA and how it works, visit vzultanow.com

BAUSCH+LOMB

VYZULTA and the V design are trademarks of Bausch & Lomb Incorporated or its affiliates.
©2018 Bausch & Lomb Incorporated. All rights reserved. VYZ.0118.USA.18


VYZULTA™
(latanoprostene
bunod ophthalmic
solution), 0.024%

BRIEF SUMMARY OF PRESCRIBING INFORMATION

This Brief Summary does not include all the information needed to use VYZULTA safely and effectively. See full Prescribing Information for VYZULTA.

VYZULTA™ (latanoprostene bunod ophthalmic solution), 0.024%, for topical ophthalmic use.

Initial U.S. Approval: 2017

1 INDICATIONS AND USAGE

VYZULTA™ (latanoprostene bunod ophthalmic solution) 0.024% is indicated for the reduction of intraocular pressure (IOP) in patients with open-angle glaucoma or ocular hypertension.

4 CONTRAINDICATIONS

None

5 WARNINGS AND PRECAUTIONS

5.1 Pigmentation

VYZULTA™ (latanoprostene bunod ophthalmic solution), 0.024% may cause changes to pigmented tissues. The most frequently reported changes with prostaglandin analogs have been increased pigmentation of the iris and periorbital tissue (eyelid).

Pigmentation is expected to increase as long as latanoprostene bunod ophthalmic solution is administered. The pigmentation change is due to increased melanin content in the melanocytes rather than to an increase in the number of melanocytes. After discontinuation of VYZULTA, pigmentation of the iris is likely to be permanent, while pigmentation of the periorbital tissue and eyelash changes are likely to be reversible in most patients. Patients who receive prostaglandin analogs, including VYZULTA, should be informed of the possibility of increased pigmentation, including permanent changes. The long-term effects of increased pigmentation are not known.

Iris color change may not be noticeable for several months to years. Typically, the brown pigmentation around the pupil spreads concentrically towards the periphery of the iris and the entire iris or parts of the iris become more brownish. Neither nevi nor freckles of the iris appear to be affected by treatment. While treatment with VYZULTA™ (latanoprostene bunod ophthalmic solution), 0.024% can be continued in patients who develop noticeably increased iris pigmentation, these patients should be examined regularly [see Patient Counseling Information (17) in full Prescribing Information].

5.2 Eyelash Changes

VYZULTA may gradually change eyelashes and vellus hair in the treated eye. These changes include increased length, thickness, and the number of lashes or hairs. Eyelash changes are usually reversible upon discontinuation of treatment.

5.3 Intraocular Inflammation

VYZULTA should be used with caution in patients with a history of intraocular inflammation (iritis/uveitis) and should generally not be used in patients with active intraocular inflammation as it may exacerbate this condition.

5.4 Macular Edema

Macular edema, including cystoid macular edema, has been reported during treatment with prostaglandin analogs. VYZULTA should be used with caution in aphakic patients, in pseudophakic patients with a torn posterior lens capsule, or in patients with known risk factors for macular edema.

5.5 Bacterial Keratitis

There have been reports of bacterial keratitis associated with the use of multiple-dose containers of topical ophthalmic products. These containers had been inadvertently contaminated by patients who, in most cases, had a concurrent corneal disease or a disruption of the ocular epithelial surface.

5.6 Use with Contact Lens

Contact lenses should be removed prior to the administration of VYZULTA because this product contains benzalkonium chloride. Lenses may be reinserted 15 minutes after administration.

6 ADVERSE REACTIONS

The following adverse reactions are described in the Warnings and Precautions section: pigmentation (5.1), eyelash changes (5.2), intraocular inflammation (5.3), macular edema (5.4), bacterial keratitis (5.5), use with contact lens (5.6).

6.1 Clinical Trials Experience

Because clinical trials are conducted under widely varying conditions, adverse reaction rates observed in the clinical trials of a drug cannot be directly compared to rates in the clinical trials of another drug and may not reflect the rates observed in practice.

VYZULTA was evaluated in 811 patients in 2 controlled clinical trials of up to 12 months duration. The most common ocular adverse reactions observed in patients treated with latanoprostene bunod were: conjunctival hyperemia (6%), eye irritation (4%), eye pain (3%), and instillation site pain (2%). Approximately 0.6% of patients discontinued therapy due to ocular adverse reactions including ocular hyperemia, conjunctival irritation, eye irritation, eye pain, conjunctival edema, vision blurred, punctate keratitis and foreign body sensation.

8 USE IN SPECIFIC POPULATIONS

8.1 Pregnancy

Risk Summary

There are no available human data for the use of VYZULTA during pregnancy to inform any drug associated risks.

Latanoprostene bunod has caused miscarriages, abortion, and fetal harm in rabbits. Latanoprostene bunod was shown to be abortifacient and teratogenic when administered intravenously (IV) to pregnant rabbits at exposures \geq 0.28 times the clinical dose.

Doses \geq 20 μ g/kg/day (23 times the clinical dose) produced 100% embryofetal lethality. Structural abnormalities observed in rabbit fetuses included anomalies of the great vessels and aortic arch vessels, domed head, sternal and vertebral skeletal anomalies, limb hyperextension and malrotation, abdominal distension and edema. Latanoprostene bunod was not teratogenic in the rat when administered IV at 150 mcg/kg/day (87 times the clinical dose) [see Data].

The background risk of major birth defects and miscarriage for the indicated population is unknown. However, the background risk in the U.S. general population of major birth defects is 2 to 4%, and of miscarriage is 15 to 20%, of clinically recognized pregnancies.

Data

Animal Data

Embryofetal studies were conducted in pregnant rabbits administered latanoprostene bunod daily by intravenous injection on gestation days 7 through 19, to target the period of organogenesis. The doses administered ranged from 0.24 to 80 mcg/kg/day. Abortion occurred at doses \geq 0.24 mcg/kg/day latanoprostene bunod (0.28 times the clinical dose, on a body surface area basis, assuming 100% absorption). Embryofetal lethality (resorption) was increased in latanoprostene bunod treatment groups, as evidenced by increases in early resorptions at doses \geq 0.24 mcg/kg/day and late resorptions at doses \geq 6 mcg/kg/day (approximately 7 times the clinical dose). No fetuses survived in any rabbit pregnancy at doses of 20 mcg/kg/day (23 times the clinical dose) or greater. Latanoprostene bunod produced structural abnormalities at doses \geq 0.24 mcg/kg/day (0.28 times the clinical dose). Malformations included anomalies of sternum, coarctation of the aorta with pulmonary trunk dilation, retroesophageal subclavian artery with absent brachiocephalic artery, domed head, forepaw hyperextension and hindlimb malrotation, abdominal distention/edema, and missing/fused caudal vertebrae.

An embryofetal study was conducted in pregnant rats administered latanoprostene bunod daily by intravenous injection on gestation days 7 through 17, to target the period of organogenesis. The doses administered ranged from 150 to 1500 mcg/kg/day. Maternal toxicity was produced at 1500 mcg/kg/day (870 times the clinical dose, on a body surface area basis, assuming 100% absorption), as evidenced by reduced maternal weight gain. Embryofetal lethality (resorption and fetal death) and structural anomalies were produced at doses \geq 300 mcg/kg/day (174 times the clinical dose). Malformations included anomalies of the sternum, domed head, forepaw hyperextension and hindlimb malrotation, vertebral anomalies and delayed ossification of distal limb bones. A no observed adverse effect level (NOAEL) was established at 150 mcg/kg/day (87 times the clinical dose) in this study.

8.2 Lactation

Risk Summary

There are no data on the presence of VYZULTA in human milk, the effects on the breastfed infant, or the effects on milk production. The developmental and health benefits of breastfeeding should be considered, along with the mother's clinical need for VYZULTA, and any potential adverse effects on the breastfed infant from VYZULTA.

8.4 Pediatric Use

Use in pediatric patients aged 16 years and younger is not recommended because of potential safety concerns related to increased pigmentation following long-term chronic use.

8.5 Geriatric Use

No overall clinical differences in safety or effectiveness have been observed between elderly and other adult patients.

13 NONCLINICAL TOXICOLOGY

13.1 Carcinogenesis, Mutagenesis, Impairment of Fertility

Latanoprostene bunod was not mutagenic in bacteria and did not induce micronuclei formation in the *in vivo* rat bone marrow micronucleus assay. Chromosomal aberrations were observed *in vitro* with human lymphocytes in the absence of metabolic activation.

Latanoprostene bunod has not been tested for carcinogenic activity in long-term animal studies. Latanoprost acid is a main metabolite of latanoprostene bunod. Exposure of rats and mice to latanoprost acid, resulting from oral dosing with latanoprost in lifetime rodent bioassays, was not carcinogenic.

Fertility studies have not been conducted with latanoprostene bunod. The potential to impact fertility can be partially characterized by exposure to latanoprost acid, a common metabolite of both latanoprostene bunod and latanoprost. Latanoprost acid has not been found to have any effect on male or female fertility in animal studies.

13.2 Animal Toxicology and/or Pharmacology

A 9-month toxicology study administered topical ocular doses of latanoprostene bunod to one eye of cynomolgus monkeys: control (vehicle only), one drop of 0.024% bid, one drop of 0.04% bid and two drops of 0.04% per dose, bid. The systemic exposures are equivalent to 4.2-fold, 7.9-fold, and 13.5-fold the clinical dose, respectively, on a body surface area basis (assuming 100% absorption). Microscopic evaluation of the lungs after 9 months observed pleural/subpleural chronic fibrosis/inflammation in the 0.04% dose male groups, with increasing incidence and severity compared to controls. Lung toxicity was not observed at the 0.024% dose.

Distributed by:

Bausch + Lomb, a division of

Valeant Pharmaceuticals North America LLC

Bridgewater, NJ 08807 USA

U.S. Patent Numbers: 6,211,233; 7,273,946; 7,629,345; 7,910,767; 8,058,467.

VYZULTA is a trademark of Bausch & Lomb Incorporated or its affiliates.

© Bausch & Lomb Incorporated

Based on 9464800 11/2017 VYZ.0055.USA.16 Issued: 11/2017

Contents

Review of Optometry
May 15, 2018



Four Steps to a Simple—and Effective—Dry Eye Screening

Don't be intimidated by the complexity of the science. This is a service any OD can perform.

BY JANE COLE, CONTRIBUTING EDITOR

PAGE 34

All About Osmolarity

This biomarker can be a significant help for dry eye testing and monitoring.

BY MICHELLE HESSEN, OD

PAGE 42

Mixed DED: A Chimera in Your Chair

What is it and how can you diagnose and manage patients who have it?

BY DOAN HUYNH KWAK, OD

PAGE 50

Managing Dry Eye for the Long Haul

Specific actions and lifestyle changes can optimize the treatment of this chronic disease and provide lasting relief.

BY CHANDRA MICKLES, OD

PAGE 58

Sjögren's, Dry Eye and You

Ocular symptoms can precede systemic ones by a decade. Here's how you can spot it early and manage its symptoms.

BY SUZANNE SHERMAN, OD, AND FIZA SHUJA, OD

PAGE 68

Finding Systemic Diseases in the Anterior Segment

Keep an eye out for findings that might implicate these conditions during your anterior segment examination.

BY JASON FLIEGEL, OD, SARA WEIDMAYER, OD, KATHY LEWIS, OD, AND TRACI SENG, OD ~ PAGE 78

Glaucoma: A Primary Care Crusade

Investing your knowledge and energy is all it takes to get your practice glaucoma-ready.

BY FRANCESCA CROZIER-FITZGERALD, ASSOCIATE EDITOR ~ PAGE 88

EARN 2 CE CREDITS: Managing Uveitis with Steroids and Biologic Agents

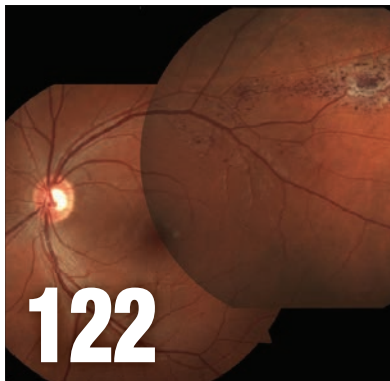
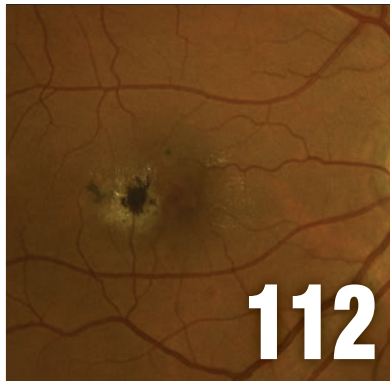
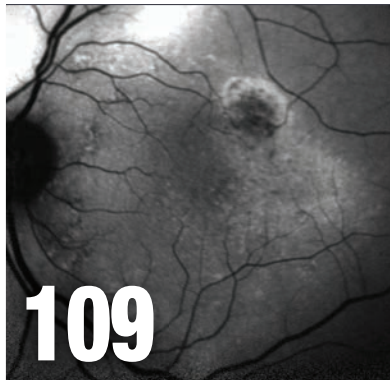
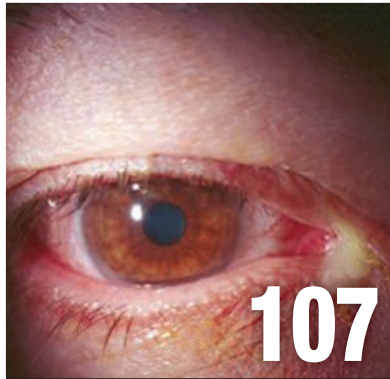
The latest developments for this condition are based on underlying immunologic mechanisms. Here's what that means for your practice.

BY JESSICA STEEN, OD ~ PAGE 97

Departments

Review of Optometry May 15, 2018

- 3 News Review**
- 18 Outlook**
That's News to Me
JACK PERSICO
- 20 Through My Eyes**
Optometry's Well: Far From Dry
PAUL M. KARPECKI, OD
- 22 Chairside**
Leisure, OD-style
MONTGOMERY VICKERS, OD
- 24 Clinical Quandaries**
A Calculated Risk
PAUL C. AJAMIAN, OD
- 30 The Essentials**
Allergies: A Glitch in the Matrix
BISANT A. LABIB, OD
- 32 Coding Connection**
Documenting for the Long Haul
JOHN RUMPAKIS, OD, MBA
- 107 Cornea + Contact Lens Q&A**
Concentrate on Povidone-iodine
JOSEPH P. SHOVLIN, OD
- 109 Urgent Care**
What Lies Beneath
**JIM WILLIAMSON, OD,
MEAGAN WILLIAMS, OD, AND
RICHARD MANGAN, OD**
- 112 Retina Quiz**
Tel Me What You See
**ERIC DILLINGER, OD, AND
MARK T. DUNBAR, OD**
- 114 Review of Systems**
The Dusky Side of Hypertension
**CARLO J. PELINO, OD, AND
JOSEPH J. PIZZIMENTI, OD**
- 117 Meetings & Conferences**
- 117 Advertisers Index**
- 118 Classifieds**
- 122 Diagnostic Quiz**
Through the Grapevine
ANDREW S. GURWOOD, OD



REVIEW[®] OF OPTOMETRY

BUSINESS OFFICES
11 CAMPUS BLVD., SUITE 100
NEWTOWN SQUARE, PA 19073

CEO, INFORMATION SERVICES GROUP
MARC FERRARA
(212) 274-7062 • MFERRARA@JOBSON.COM

PUBLISHER
JAMES HENNE
(610) 492-1017 • JHENNE@JOBSON.COM

REGIONAL SALES MANAGER
MICHELE BARRETT
(610) 492-1014 • MBARRETT@JOBSON.COM

REGIONAL SALES MANAGER
MICHAEL HOSTER
(610) 492-1028 • MHOSTER@JOBSON.COM

VICE PRESIDENT, OPERATIONS
CASEY FOSTER
(610) 492-1007 • CFOSTER@JOBSON.COM

VICE PRESIDENT, CLINICAL CONTENT
PAUL M. KARPECKI, OD, FAAO
PKARPECKI@JOBSON.COM

PRODUCTION MANAGER
SCOTT TOBIN
(610) 492-1011 • STOBIN@JOBSON.COM

SENIOR CIRCULATION MANAGER
HAMILTON MAHER
(212) 219-7870 • HMAHER@JHIHEALTH.COM

CLASSIFIED ADVERTISING
(888) 498-1460

SUBSCRIPTIONS
\$56 A YEAR, \$88 (US) IN CANADA,
\$209 (US) IN ALL OTHER COUNTRIES.

SUBSCRIPTION INQUIRIES
(877) 529-1746 (US ONLY)
OUTSIDE US CALL: (845) 267-3065

CIRCULATION
PO Box 81
CONGERS, NY 10920
TEL: (TOLL FREE): (877) 529-1746
OUTSIDE US: (845) 267-3065



CEO, INFORMATION SERVICES GROUP
MARC FERRARA

SENIOR VICE PRESIDENT, OPERATIONS
JEFF LEVITZ

VICE PRESIDENT, HUMAN RESOURCES
TAMMY GARCIA

VICE PRESIDENT, CREATIVE SERVICES & PRODUCTION
MONICA TETTAMANZI

CORPORATE PRODUCTION DIRECTOR
JOHN ANTHONY CAGGIANO

VICE PRESIDENT, CIRCULATION
EMELDA BAREA



dry eyes or
eyelove?

Definitely eyelove

Guys, the face of dry eye is changing. That's why it's super important to have a chat with your patients about the things that can trigger their dry eye symptoms—like staring at screens all day.

Shire is here to help. We want to make sure you and your patients are feeling the eyelove. And what better way to show it than by encouraging eye health for everyone? Together, we can ensure that eyes are healthy and loved, now and in the future. That's eyelove.

Start with some eyelove.

Join us at sharesomeeyelove.com

 eyelove

Shire

©2017 Shire US Inc., Lexington, MA 02421. 1-800-828-2088. All rights reserved. SHIRE and the Shire Logo are trademarks or registered trademarks of Shire Pharmaceutical Holdings Ireland Limited or its affiliates. The EYELOVE logo and marks designated ® and ™ are owned by Shire or an affiliated company. S36312.12/17

CONTRIBUTING EDITORS

PAUL C. AJAMIAN, OD, ATLANTA
AARON BRONNER, OD, KENNEWICK, WASH.
MILE BRUJIC, OD, BOWLING GREEN, OHIO
DEREK N. CUNNINGHAM, OD, AUSTIN, TEXAS
MARK T. DUNBAR, OD, MIAMI
ARTHUR B. EPSTEIN, OD, PHOENIX
JAMES L. FANELLI, OD, WILMINGTON, NC
FRANK FONTANA, OD, ST. LOUIS
GARY S. GERBER, OD, HAWTHORNE, NJ
ANDREW S. GURWOOD, OD, PHILADELPHIA
ALAN G. KABAT, OD, MEMPHIS, TENN.
DAVID KADING, OD, SEATTLE
PAUL M. KARPECKI, OD, LEXINGTON, KY.
JEROME A. LEGERTON, OD, MBA, SAN DIEGO
JASON R. MILLER, OD, MBA, POWELL, OHIO
CHERYL G. MURPHY, OD, BABYLON, NY
CARLO J. PELINO, OD, JENKINTOWN, PA.
JOSEPH PIZZIMENTI, OD, SAN ANTONIO, TEXAS
JOHN RUMPAKIS, OD, MBA, PORTLAND, ORE.
DIANA L. SHECHTMAN, OD, FORT LAUDERDALE, FLA.
JEROME SHERMAN, OD, NEW YORK
JOSEPH P. SHOVLIN, OD, SCRANTON, PA.
JOSEPH W. SOWKA, OD, FORT LAUDERDALE, FLA.
MONTGOMERY VICKERS, OD, LEWISVILLE, TEXAS
WALTER O. WHITLEY, OD, MBA, VIRGINIA BEACH, VA.

EDITORIAL REVIEW BOARD

JEFFREY R. ANSHEL, OD, ENCINITAS, CALIF.
JILL AUTRY, OD, RPH, HOUSTON
SHERRY J. BASS, OD, NEW YORK
EDWARD S. BENNETT, OD, ST. LOUIS
MARC R. BLOOMENSTEIN, OD, SCOTTSDALE, ARIZ.
CHRIS J. CAKANAC, OD, MURRYSVILLE, PA.
JERRY CAVALLERANO, OD, PHD, BOSTON
WALTER L. CHOATE, OD, MADISON, TENN.
BRIAN CHOU, OD, SAN DIEGO

A. PAUL CHOUS, MA, OD, TACOMA, WASH.
ROBERT M. COLE, III, OD, BRIDGETON, NJ
GLENN S. CORBIN, OD, WYOMISSING, PA.
ANTHONY S. DIECIDUE, OD, STROUDSBURG, PA.
S. BARRY EIDEN, OD, DEERFIELD, ILL.
STEVEN FERRUCCI, OD, SEPULVEDA, CALIF.
MURRAY FINGERET, OD, HEWLETT, NY
IAN BEN GADDIE, OD, LOUISVILLE, KY.
PAUL HARRIS, OD, MEMPHIS, TN
MILTON HOM, OD, AZUSA, CALIF.
BLAIR B. LONSBERRY, MS, OD, MED, PORTLAND, ORE.
THOMAS L. LEWIS, OD, PHD, PHILADELPHIA
DOMINICK MAINO, OD, MED, CHICAGO
KELLY A. MALLOY, OD, PHILADELPHIA
RICHARD B. MANGAN, OD, LEXINGTON, KY.
RON MELTON, OD, CHARLOTTE, NC
PAMELA J. MILLER, OD, JD, HIGHLAND, CALIF.
BRUCE MUCHNICK, OD, COATESVILLE, PA.
MARC MYERS, OD, COATESVILLE, PA.
WILLIAM B. POTTER, OD, FREEHOLD, NJ
CHRISTOPHER J. QUINN, OD, ISELIN, NJ
MICHAEL C. RADOIU, OD, STAUNTON, VA.
MOHAMMAD RAFIETARY, OD, MEMPHIS, TN
JOHN L. SCHACHET, OD, ENGLEWOOD, COLO.
JACK SCHAEFFER, OD, BIRMINGHAM, ALA.
LEO P. SEMES, OD, BIRMINGHAM, ALA.
LEONID SKORIN, JR., OD, DO, ROCHESTER, MINN.
JOSEPH W. SOWKA, OD, FORT LAUDERDALE, FLA.
SRUTHI SRINIVASAN, PHD, BS OPTOM, WATERLOO, ONT.
BRAD M. SUTTON, OD, INDIANAPOLIS
LORETTA B. SZCZOTKA, OD, PHD, CLEVELAND
MARC TAUB, OD, MEMPHIS, TN
TAMMY P. THAN, MS, OD, BIRMINGHAM, ALA.
RANDALL THOMAS, OD, CONCORD, NC
SARA WEIDMAYER, OD, ANN ARBOR, MI
KATHY C. WILLIAMS, OD, SEATTLE
KAREN YEUNG, OD, LOS ANGELES



10 Years of Advancing
Careers in Eye Care

Local Eye Site
JOBS IN EYE CARE

We're Celebrating 10 Years of Advancing Careers in Eye Care!
Join the celebration for a chance to win \$250 by visiting:
localeyesite.com/10years



PHILADELPHIA VISION



*Join us at the Philadelphia VisionFest
for an afternoon of music, food and fun
benefitting the*

FOUNDATION FIGHTING BLINDNESS

Sunday, June 10, 2018
1:00 PM - 4:00 PM

Ridgeland Mansion in Fairmount Park
4100 Chamounix Drive, Philadelphia, PA 19131

www.FightBlindness.org/PhiladelphiaVisionFest

For more information including tickets and sponsorship information please contact
Katie VanBenschoten at (212) 244-1470 or KVanBenschoten@FightBlindness.org

Visionary Supporters

Genentech, Inc., A Member of the Roche Group
Shire

The urgent mission of the Foundation Fighting Blindness is to drive the research that will provide preventions, treatments, and cures for people affected by retinitis pigmentosa, macular degeneration, Usher syndrome, and the entire spectrum of retinal degenerative diseases.

www.FightBlindness.org
(212) 244-1470

How to Overcome Cost by Offering Value

Practitioners share advice on how to help patients recognize the many benefits of silicone hydrogel 1-day lenses.

Research shows that, if costs were equivalent, 95% of eye care practitioners would choose silicone hydrogel over hydrogel for their 1-day contact lens patients. This obviously demonstrates that doctors recognize the true **value** of silicone hydrogel 1-day lenses and understand that they can offer more oxygen¹, healthier² corneas, and added convenience. However, many doctors struggle with how to convey this message to patients without getting hung up on price.

We asked three optometrists who regularly refit wearers into silicone hydrogel 1-day lenses to share advice on how they move the conversation from price to value. Here, they share their strategies on how to more effectively engage wearers, strengthen the doctor-patient relationship, and overcome perceived cost barriers.

Some doctors are uncomfortable with the transactional nature of making a contact lens recommendation, which makes them hesitant to suggest lens upgrades. What is your advice for overcoming this hesitation?

Dr. Rosinski: Contact lens dispensing is, by nature, transactional—no matter what lens you fit. It's also important to note that there is value to what we do as doctors. It's up to us to explain why we prescribe certain things. Being honest and knowledgeable makes you a doctor, not a salesman. Furthermore, it earns trust and patients will be more likely to come back on a regular basis.

Dr. Frogozo: I believe silicone hydrogel is the healthiest option. In fact, 87% of eye care professionals agree with me that silicone hydrogel material should be the first choice of material for daily disposable lenses.

Dr. Huisman: Be confident. Steer your focus away from cost and focus instead on the professional service you provide when you prescribe what you believe is best for the patient's ocular health.

How do you introduce patients to silicone hydrogel 1-day contact lenses?

Dr. Huisman: By asking the right questions, you can get patients to identify their needs. For example, ask patients if they LOVE their contact lenses. Or, ask what they would change about their lenses if they could. This opens the door and creates connections to the benefits of 1-day silicone hydrogel lenses.

Dr. Rosinski: The reputation I've built with my patients plays a significant role. They expect me to always have the newest and greatest products and anticipate that I will tell them about it every year. You don't need to make it complicated; just deliver the facts. I simply explain that silicone hydrogel 1-day contact lenses offer high oxygen, all-day comfort and great vision for a few cents more per day.

Dr. Frogozo: The patient education in my practice focuses on ocular health and the importance of oxygen transmission. Beyond that, I strive to be frank with my patients. I tell them what I think is best for them and they trust me.

The Practitioners



Melanie Frogozo
OD, FFAO, FSLs
The Contact Lens
Institute of San
Antonio
San Antonio, Texas



Ethan E. Huisman
OD, FFAO
Elite Eye Care
West Des Moines,
Iowa



Steve Rosinski
OD
Crozet Eye Care
Charlottesville,
Virginia

Research shows that 56% of eye-care professionals view the cost to the patient as the greatest barrier to the increased adoption of silicone hydrogel 1-day contact lenses³. How do you overcome price barriers in your practice?

Dr. Rosinski: I find it's helpful to tell patients that the cost disparity has dropped dramatically over the years. Plus, they'll receive rebates. I also point out that patients won't have to spend approximately \$100 per year for solutions and cases. And, if a lens tears or becomes lost for some reason, they are only out a single use 1-day lens. All of this combined makes the conversation surrounding 1-day much easier. With regard to material, patients want to know why it is better for their eyes, so

Four Steps to Converting Patients to Silicone Hydrogel 1-Day Lenses

- ✓ 1. Ask the patient to describe a typical day
- ✓ 2. Ask the patient to describe how the current lenses feel. Listen carefully for identifiers such as discomfort, dryness, reduced wearing time, or redness
- ✓ 3. Propose a better experience and why
- ✓ 4. Trial a silicone hydrogel 1-day lens

share with them what you know about silicone hydrogel and how it compares to hydrogel. The key is to believe it yourself and share your honest opinion. My patients trust what I have to say and take my recommendations seriously. Yours will too.

Dr. Frogozo: There is not a huge cost difference. As with many things that relate to our wellbeing, healthier options can be more cost effective in the long run.

Dr. Huisman: I say, "this is more money, but here is why I'm prescribing it for you." While cost is a genuine concern for many patients, it's not the doctor's job to make assumptions about what patients value or how they choose to spend their money. The doctor's job is to educate patients.

If a patient is satisfied with a less expensive lens, is presenting silicone hydrogel 1-day worthwhile, or might it jeopardize the doctor-patient relationship?

Dr. Huisman: Patients prefer honesty and candor. The greater risk to the relationship occurs when a patient suspects you're holding something back.

Dr. Rosinski: The greater detriment stems from failure to offer the best options to our patients. They should hear it from us first instead of hearing about new technology online, via social media or by word-of-mouth.

Dr. Frogozo: You also jeopardize retention if the patient is uncomfortable or develops a problem. Silicone hydrogel 1-day lenses help us to keep patients comfortable in their lenses, which is good for them and for our practice.

What role does the lens trial process have in moving patients to silicone hydrogel 1-day lenses?

Dr. Huisman: Trials are the tipping point, but I believe in educating patients on the benefits of silicone hydrogel 1-day lenses prior to fitting them in trial lenses.

Dr. Frogozo: I agree. The trial is important, but the patient education is a more significant driving force in my practice. I educate up front, so the patient understands why I am selecting a particular lens. The trial is secondary—although it is great to hear patients describe how happy they are with their new lenses.

Dr. Rosinski: Patients are usually willing to try new technology. We just need to do our part by giving them the opportunity! You may be surprised by how many patients ask to switch to silicone hydrogel 1-day lenses after trialing them. My patients come back saying their eyes feel better and they have better vision. And when this happens, they start referring more family and friends.

Bring Value into Perspective

CooperVision's portfolio of silicone hydrogel 1-day contact lenses offers a lens for virtually every eye—and every budget. From the breadth of the clariti® 1 day family to the uncompromising performance of MyDay®, CooperVision provides the options needed to meet the demands of almost any patient.

For more information, visit CooperVision.com



1 Manufacturer stated oxygen transmissibility values (Dk/t): MyDay® daily disposable (100), clariti® 1 day (86), 1-DAY ACUVUE® MOIST® (25.5), SofLens® daily disposable (24).
2 With higher oxygen permeability than hydrogel materials, silicone hydrogel contact lenses minimize or eliminate hypoxia-related signs and symptoms during lens wear.

3 Cello Health Insight. June 2017. Base: All US ECPs (n=61); US committed SiHy users (n=28); US non-committed SiHy users (n=33) Q203. Q204A/B/C/D. Question text in notes.

* With manufacturer's rebate. \$200 rebate applies to patients new to CooperVision contact lenses. © 2018 CooperVision, Inc. 6047 04/18



PRINTED IN USA

FOUNDING EDITOR, FREDERICK BOGER
1891-1913

EDITORIAL OFFICES

11 CAMPUS BLVD., SUITE 100
NEWTOWN SQUARE, PA 19073

WEBSITE • WWW.REVIEWOFOPTOMETRY.COM

SUBSCRIPTION INQUIRIES

1-877-529-1746

CONTINUING EDUCATION INQUIRIES

1-800-825-4696

EDITOR-IN-CHIEF • JACK PERSICO

(610) 492-1006 • JPERSICO@JOBSON.COM

MANAGING EDITOR • REBECCA HEPP

(610) 492-1005 • RHEPP@JOBSON.COM

SENIOR EDITOR • BILL KEKEVIAN

(610) 492-1003 • BKEKEVIAN@JOBSON.COM

ASSOCIATE EDITOR • MICHAEL IANNUCCI

(610) 492-1043 • MIANNUCCI@JOBSON.COM

ASSOCIATE EDITOR • FRANCESCA CROZIER-FITZGERALD

(610) 492-1021 • FCROZIER@JOBSON.COM

SPECIAL PROJECTS MANAGER • JILL HOFFMAN

(610) 492-1037 • JHOFFMAN@JOBSON.COM

ART DIRECTOR • JARED ARAUJO

(610) 492-1032 • JARAUJO@JOBSON.COM

DIRECTOR OF CE ADMINISTRATION • REGINA COMBS

(212) 274-7160 • RCOMBS@JOBSON.COM

EDITORIAL BOARD

CHIEF CLINICAL EDITOR • PAUL M. KARPECKI, OD

ASSOCIATE CLINICAL EDITORS • JOSEPH P. SHOWLIN, OD;
ALAN G. KABAT, OD; CHRISTINE W. SINDT, OD

DIRECTOR OPTOMETRIC PROGRAMS • ARTHUR EPSTEIN, OD

CLINICAL & EDUCATION CONFERENCE ADVISOR
PAUL M. KARPECKI, OD

CASE REPORTS COORDINATOR • ANDREW S. GURWOOD, OD

CLINICAL CODING EDITOR • JOHN RUMPAKIS, OD, MBA

CONSULTING EDITOR • FRANK FONTANA, OD

COLUMNISTS

CHAIRSIDE • MONTGOMERY VICKERS, OD

CLINICAL QUANDARIES • PAUL C. AJAMIAN, OD

CODING CONNECTION • JOHN RUMPAKIS, OD

CORNEA & CONTACT LENS Q+A • JOSEPH P. SHOWLIN, OD

DIAGNOSTIC QUIZ • ANDREW S. GURWOOD, OD

THE ESSENTIALS • BISANT A. LABIB, OD

FOCUS ON REFRACTION • MARC TAUB, OD;

PAUL HARRIS, OD

GLAUCOMA GRAND ROUNDS • JAMES L. FANELLI, OD

NEURO CLINIC • MICHAEL TROTTINI, OD;

MICHAEL DELGIODICE, OD

OCULAR SURFACE REVIEW • PAUL M. KARPECKI, OD

RETINA QUIZ • MARK T. DUNBAR, OD

REVIEW OF SYSTEMS • CARLO J. PELINO, OD;

JOSEPH J. PIZZIMENTI, OD

SURGICAL MINUTE • DEREK N. CUNNINGHAM, OD;

WALTER O. WHITLEY, OD, MBA

THERAPEUTIC REVIEW • JOSEPH W. SOWKA, OD;

ALAN G. KABAT, OD

THROUGH MY EYES • PAUL M. KARPECKI, OD

URGENT CARE • RICHARD B. MANGAN, OD

JOBSON MEDICAL INFORMATION LLC



Outlook

By Jack Persico, Editor-in-Chief



That's News to Me

Late-breaking reports on research, general interest stories and product launches, on our website every day.

I still remember the first scoop I got as a young reporter. In the early 1990s, a few months into my career, I'd heard of a study about to come out at ARVO that purported to show an increased number of complications from daily disposable contact lenses over reusables. I know—it's not exactly Watergate, but it was a big deal at that time and in this field. Disposables were considered safer to wear, so why would they lead to *more* complications? It sounded juicy. The company flew me down to Florida so I could go see the presentation. I dashed off a quick story just under the wire for our print deadline. It was out in a few weeks. Not bad for a monthly magazine in 1992.

It turned out to be nothing, of course. But the experience of digging for a story and reporting as quickly as the means of news dissemination allowed always stuck with me. And now I'm at it again—well, the whole *Review* editorial staff is, I should say.

In early April we launched a news feed on the magazine's website: www.reviewofoptometry.com/news. Naturally, these days we can deliver news much faster. Each weekday morning we post a few stories, and we add more throughout the day. It's been a little stressful, a little distracting and a lot of fun. Connecting with our readers as soon as we have something to share is a novelty for a monthly publication, especially one more known for complex 'how-to' articles that take months to prepare and usually weigh in at around 3,000 words and 50 references.

Long-form journalism of that sort is *Review's* strength, and we don't intend to give up our tradition of publishing instructional features, most with an incredible shelf life—some of the most popular articles on our website are a few years old. One on meibomian gland expression has been in our top 10 page views for almost a decade, in effect making it our own *Dark Side of the Moon*.

So, we'll stick with what ODs turn to us for each month. But I hope you'll also start looking to *Review* for real-time reporting on the news of the day.

Some will surely end up like my old scoop from '92: much ado about nothing. So it goes in the news business. The bulk of our coverage thus far has been tightly focused stories about studies that look potentially clinically relevant. Will they change the world? For most, likely not. But each adds a little something to the mosaic of knowledge you have about the multifaceted world of clinical optometry. And some, like the controversial DREAM study of omega fatty acids for dry eye, will indeed have long-lasting impact on what you do all day—and we were able to share our thoughts on that as it happened. When something warrants more depth, we'll flesh it out for expanded coverage in the magazine's News Review section, adding quotes from experts not found online.

My one regret about the *Review* news feed: with today's technology, we were able to do this year's ARVO coverage entirely from our offices. No tickets to Hawaii for us. Such is the price of progress. ■

Are you tired of....

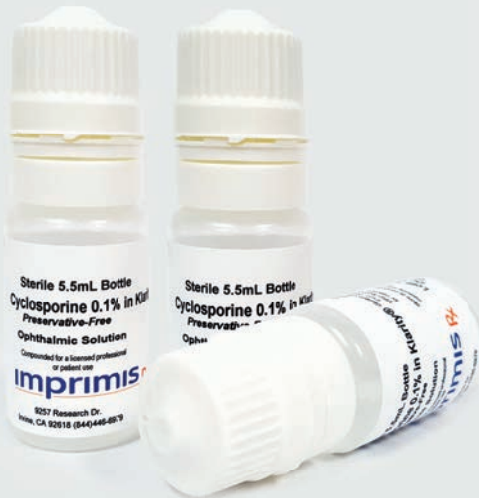...countless **prior authorizations**
with **repeat denials**?

...handing out **stacks of coupons** that often
don't work for many of your patients?

... multiple **call backs** from pharmacies
and patients taking up your **valuable time**?



We have the solution for you and your patients:



TOTALTEARS™

**Cyclosporine 0.1% / Chondroitin
Sulfate Ophthalmic Emulsion***
(preservative-free) 5.5mL Bottles

First 3 bottles \$99⁹⁹

No Prior Authorizations | No Coupons | No Pharmacy Call Backs

Learn more at www.imprimisrx.com/RevOfOpt2018

*For professional use only. Imprimis Pharmaceuticals specializes in customizing medications to meet unique patient and practitioner needs. Imprimis Pharmaceuticals dispenses only to individually identified patients with valid prescriptions. No compounded medication is reviewed by the FDA for safety or efficacy. Imprimis Pharmaceuticals does not compound copies of commercially available products. References available upon request.

Total Tears and ImprimisRx are trademarks of Imprimis Pharmaceuticals, Inc. ©2018 Imprimis Pharmaceuticals, Inc. All Rights Reserved. IMP00242 3/18

imprimis **Rx®**
844.446.6979



Optometry's Well: Far From Dry

We are only treating 2% to 9% of all patients with DED. How can we improve those numbers? **By Paul M. Karpecki, OD, Chief Clinical Editor**

Several studies estimate dry eye disease (DED) prevalence at more than 30 million—and yet only about 16 million cases are diagnosed and less than 1.5 million are being treated therapeutically.^{1,2} This is a huge problem for patients in need—and a significant area of growth for our practices. DED diagnosis and treatment can become an integral part of your practice, and this month's issue covers many aspects that can help boost your dry eye care, including osmolarity testing, systemic confounders and long-term therapy options, to name a few.

Put a Number on It

I couldn't run a successful DED clinic without osmolarity testing. It has helped me avoid missteps in more cases than I can count. If a patient measures between 280mOsmol/L and 295mOsmol/L and both eyes are within 5mOsmol/L, chances are slim they have DED.

Such a quick indicator can be hugely helpful. Just think of the myriad conditions that present with a normal tear film but dry, gritty, burning, irritated eyes: eye misalignment, Salzmann's, basement membrane dystrophy, conjunctivochalasis, concretions, allergic conjunctivitis, mucin fishing syndrome, *Demodex*, GPC, limbal stem cell deficiency and many more.

However, osmolarity above 300mOsmol/L, or an inter-eye difference of than 8mOsmol/L, indices a lack of tear film homeostasis and instability indicative of DED.

A Whole Body Issue

Sjogren's syndrome (SS), as an important systemic diagnosis, warrants an aggressive treatment regimen combined with systemic immunosuppression. Diagnostic tests such as the Sjö test (Bausch + Lomb) are helping to positively diagnose more patients and get them the treatment they need. SS can affect practically every organ in the body, not just the eyes and mouth—ODs can be crucial care partners to help improve patients' lives with early diagnosis.

The Long Haul

DED is akin to rheumatoid arthritis: chronic, progressive and with occasional flare-ups. For evaporative DED, long-term treatment might include hydrating compresses, lid hygiene, artificial tears and topical anti-inflammatory meds plus oral omega fatty acids. These patients will occasionally require in-office treatments such as thermal pulsation, blepharoexfoliation and amniotic membrane for persistent corneal superficial punctate keratitis and filamentary keratitis. They may also require topical corticosteroids for flare-ups. Aqueous-deficient dry eye patients often need more aggressive therapy such as autologous serum, punctal occlusion and scleral lenses.

Ask the Right Questions

One key to reaching undiagnosed patients is better screening. The 2014 Optometric Dry Eye Summit provided four key questions we should ask every patient prior to examination:

1. Do your eyes tear, burn, feel dry, gritty or irritated?
2. Are your eyes red or do your eyes occasionally get red?
3. Do you experience blurred or fluctuating vision?
4. Are you using or do you feel the urge to use artificial tears?

Asking these questions is a crucial step toward increasing our treatment rates and preventing disease progression. If these screening questions are positive, validated questionnaires are valuable to follow patient symptoms, as are other tests such as osmolarity, vital dyes, meibomian gland expression and meibography.

An Ounce of Prevention

The recent history of health care generally, and eye care as well, emphasizes preventive medicine. We need to direct more attention to dry eye. This might include the use of an ocular hygienist (perhaps: *eye-genist*?) who, under the supervision of an OD, would perform blepharoexfoliation, meibomian gland expression and help suggest proper nutrition, hydrating compresses, lid hygiene and lifestyle changes.

We must get in front of this condition and prevent its progressive, chronic nature from interrupting our patients' lives. ■

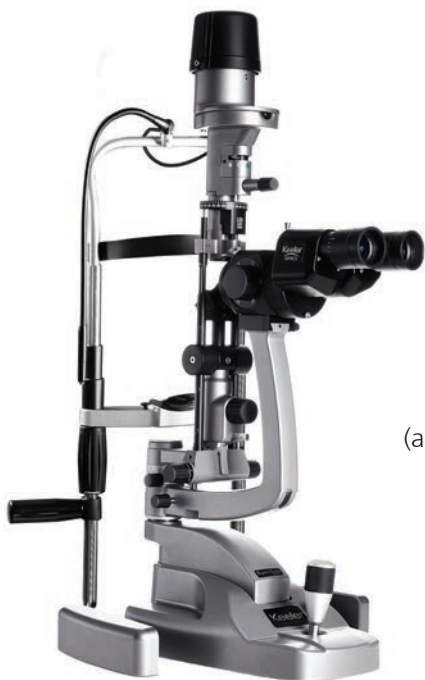Dr. Karpecki is a consultant to several companies in the dry eye field.

1. Schaumberg DA, Sullivan DA, Buring JE, Dana MR. Prevalence of dry eye syndrome among US women. *Am J Ophthalmol.* 2003;136(2):318-26.
2. Paulsen AJ, Cruickshanks KJ, Fischer ME, et al. Dry eye in the beaver dam offspring study: prevalence, risk factors, and health-related quality of life. *Am J Ophthalmol.* 2014;157(4):799-806.

The Keeler³ Trade In Program

Buy 3 // Trade 3 // Get 1 Free

The Power of 3. Purchase any 3 Keeler Slit Lamps and trade in 3 of your old Slit Lamps and we'll send you a 4th Keeler Slit Lamp absolutely free of charge.



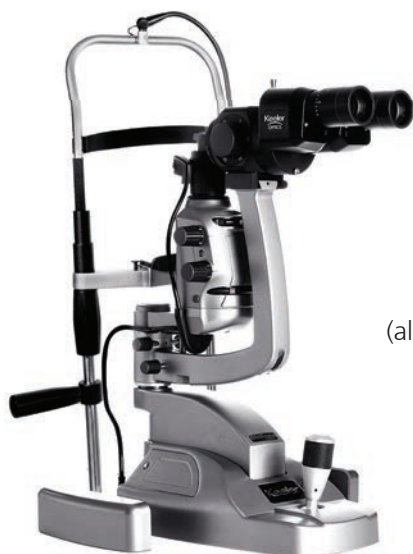KSL-H

(also in Digital Ready)



KSL-H-D

(full Digital)



KSL-Z

(also in Digital Ready)



KSL-H-D

(full Digital)



Keeler Instruments, Inc. • 3222 Phoenixville Pike, bldg. 50 • Malvern, PA 19355
Tel: (800) 523-5620 • Fax: (610) 353-7814 • email: keeler@keelerusa.com

Offer valid until June 30, 2018.

Contact Keeler or one of our authorized dealers for more information.

Leisure, OD-style

Come on, doc. It's springtime! Time to have some fun.

By **Montgomery Vickers, OD**

You have been working like a dog, assuming there is a breed of dog that sits around all day barking, "Which is better?" With spring upon us, I know all of you are Googling "vacation ideas" instead of logging your electronic health record notes from the past month.

My secret posse of analysts has been watching you for years and we have compiled a few lists of the most common ways optometrists spend their leisure time. I'll admit, I was surprised by what we found.

Most popular destinations for a summer vacation:

1. Any hotel where there is CE. This allows the OD to write off the trip and not have to spend any time with the griping kids since they "have to get my hours."
2. The Mittendorf Dot Hall of Fame just outside Poughkeepsie, New York. The most common comment overheard there is "Dang! That's huge!" The second most common is "Mom! Can we leave?"
3. The office. It can be quite exhilarating to go through that dusty box of contact lenses you were supposed to return for credit in 2006.
4. The local ophthalmologist's office. It's a great way to get a free exam and stuff your pockets with samples of prescription eye drops the sales reps never bring to you.
5. Wild boar hunting from a helicopter. This surprised me too.

Most popular vacation sports:

1. Fixing the toilet in the basement. Fun for the whole family.
2. Long distance running from the car to McDonalds.
3. Looking at golf clubs online. Maybe next year you will play more.
4. Weight lifting. Wait, I misread that... gin and tonic lifting.
5. Speed purging your 20,000 unread emails.

Most popular poolside web searches:

1. How much do you charge for contact lenses?
2. Why do hyperopes lie like dogs?
3. Who was that guy that was only in one James Bond movie?
4. Are there more optometry schools than pigeons?
5. How do I delete recent web searches from my phone?

Most popular summer books:

1. "Valley of the No Shows."
2. "Lord of the Weiss Ring."
3. "War and I Think I Have a Piece of Contact Lens in My Eye."
4. "The Adventures of Huckleberry Schlemm's Canal."
5. "Harry Trantas Dotter."

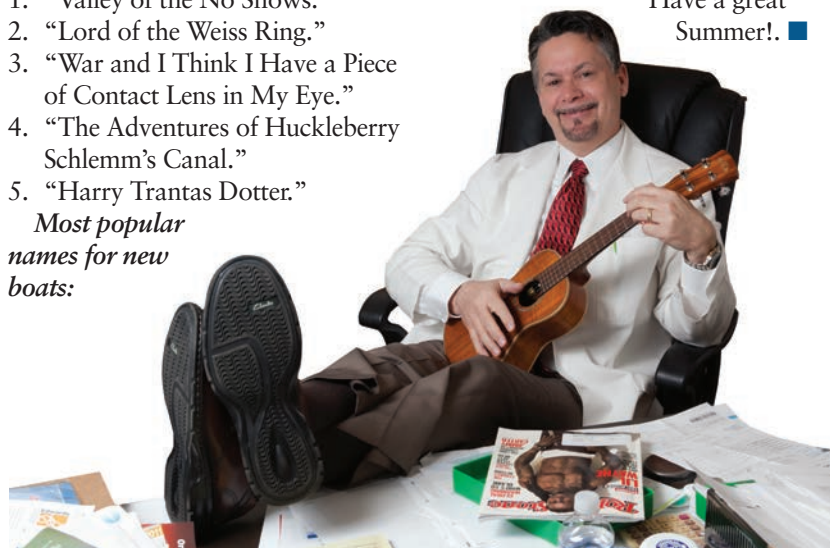Most popular names for new boats:

1. "Seeworthy."
2. "Vitreous Floater."
3. "450 Nanometers."
4. "FZBDE."
5. "I Am For Sale Already."

Most popular items on every optometrist's "bucket list":

1. One day that family of four will all show up for their Saturday appointments.
2. They will invent a daily contact lens material that will turn into 50% atropine after 16 hours of lens wear.
3. At least one patient per career will respond to a texted appointment reminder.
4. No one will ever call on Sunday afternoon and begin the message with "Last Wednesday..."
5. Everyone in the world will come together in peace and harmony and call my office for an appointment—and actually show up.

Have a great Summer! ■





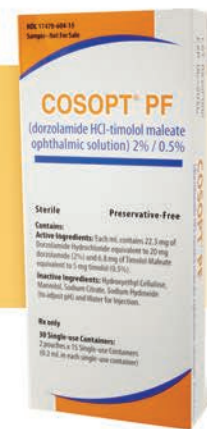100% PRESERVATIVE-FREE

ZIOPTAN[®]
(tafluprost ophthalmic solution) 0.0015%

Cosopt[®] PF
(dorzolamide HCl - timolol maleate ophthalmic solution) 2% / 0.5%



**ORDER
FREE SAMPLES**



**Go to either website
and select "Request Sample"**

www.Zioptan.com

www.CosoptPF.com

Cosopt is a registered trademark of Merck Sharp & Dohme Corp and is used under license. ZIOPTAN is a registered trademark of Merck Sharp & Dohme Corp and is used under license.

Santen ZIOPTAN is licensed by Santen Pharmaceutical Co., Ltd.

AKORN

©2017 Akorn, Inc. All rights reserved. P481(a) Rev 4/17



A Calculated Risk

Not every patient will succeed with presbyopic IOLs, but judicious patient selection and education can help you improve their chances. **Edited by Paul C. Ajamian, OD**

Q The cataract surgeon I use paints a rosy picture of presbyopic intraocular lenses (IOLs) to every patient, but I manage some who aren't happy post-surgery. How should I best counsel patients about multifocal/presbyopic IOLs to maximize success?


A “The best advice to maximize success is proper patient selection and education before the referral—and to hope for a little luck,” says Walter O. Whitley, OD, MBA, director of optometric services at Virginia Eye Consultants. Patients with unreasonable expectations, reduced visual potential, uncontrolled ocular surface disease and significant higher-order aberration should be discouraged at the start.

A perfect patient selection process doesn't exist, Dr. Ajamian adds. “We have had a few I would have bet the farm would do well with a multifocal who didn't.” Given that, the best a clinician can do is to carefully follow these steps:

1. Manage expectations. “Some technologies may not be able to meet our patient's vision needs,” says Dr. Whitley. “Each option is a compromise that patients and providers must accept.”

“Tell patients up front that they will wear glasses for certain situations,” says Dr. Whitley. “If they expect to throw their spectacles away, they are not a good candidate.”

Night vision requirements could be another deal-breaker. Although newer IOL designs minimize glare and haloes, some patients may not be able to tolerate them, says Dr.



A drawing of postoperative glare by a seemingly “perfect” multifocal candidate.

Whitley. As such, he would not recommend presbyopic IOLs to patients with night vision demands, high myopia or large pupils.

Be sure to educate patients who are not ideal candidates for presbyopic IOLs about why they aren't a good candidate, and would be better suited for a standard IOL and a near prescription post-surgery, he adds. “We also need to let our surgeons know why we aren't recommending presbyopic IOLs for the patient.”

2. Learn the technology. “Discuss with your surgeon the pros and cons of the various IOL options and their experience with each,” says Dr. Whitley. Coming to an understanding about the various technologies is imperative so your messages to your mutual patients are consistent.

Current options for these patients include the Restor 2.5D and 3.0D IOL (Alcon), and the Tecnis Symphony IOL (Abbott Medical Optics), which are available in toric versions as well. In Dr. Whitley's experience, the Restor 2.5D maximizes distance vision while providing good intermediate and

some near with the least glare. The Tecnis Symphony IOL, meanwhile, uses diffractive echelettes to elongate range of focus and reduce chromatic aberration. Dr. Whitley has seen numerous positive outcomes, and a few negatives, with each option.

3. Optimize the ocular surface. This should be done for all patients prior to the referral. “Dry eye disease can and does affect IOL calculations, leading to residual refractive error, in addition to post-op decrease in vision,” Dr. Whitley says. To minimize the risk of poor visual outcomes post-surgery, he recommends paying attention to the ocular surface pre-op and aggressively treating dry eye signs and symptoms prior to referring for a cataract evaluation.

Other ocular surface conditions that must be addressed prior to surgery include epithelial basement membrane dystrophy, Salzmann's nodules and pterygium. “If a patient has any of these conditions, multifocal candidate or not, consider a superficial keratectomy or pterygium removal prior to cataract surgery,” Dr. Whitley suggests.

Overall, the optimal presbyopic IOL candidate has realistic expectations, minimal ocular surface disease and higher-order aberrations and good vision potential, Dr. Whitley says. “Remember, it's all about matching the patient to the ‘lifestyle’ technology and the ‘lifestyle’ technology to the patient. Not everyone will be a candidate for presbyopic IOLs, but taking these steps into account can help make some very happy patients.” ■

AMBIODisk™

DEHYDRATED AMNIOTIC MEMBRANE FOR IN-OFFICE PROCEDURES

RELIEF IN SIGHT

EFFECTIVE

- Retains the growth factors found in natural amniotic membrane¹
- Retains more of these growth factors than other dehydrated amniotic membrane product¹

WELL-TOLERATED

- No tape tarsorrhaphy required
- Minimized foreign body sensation

SIMPLE IN-OFFICE PROCEDURE

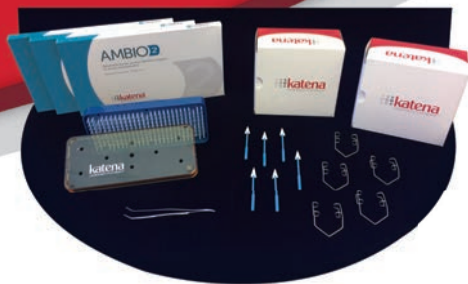
- Easily applied to a dry cornea
- Covered with a bandage contact lens

CONVENIENT

- 5 year shelf life
- Stored at room temperature
- No freezer or special shipping & handling required



¹ Koob TJ, Lim JJ, Zabek N, Masseur M. 2014. Cytokines in single layer amnion allografts compared to multilayer amnion/chorion allografts for wound healing. J Biomed Mater Res Part B 2014;00B:000-000



*Katena — Your complete resource for amniotic membrane procedure products:
Single use speculums
Single use spears
Forceps*

APPLICATIONS

- Conditions associated with excessive dry eye
- Recurrent corneal erosions
- Corneal ulcers
- Chemical and thermal burns
- Neurotrophic ulcers

THE PURION® PROCESS

- The gold standard in dehydrated amniotic membrane preservation
- Safely and gently cleans and preserves the amniotic membrane

100,000+ EYES TREATED



www.katena.com • 800.225.1195



Trehalose & Eye Care



A Molecule Poised to Revolutionize Ocular Surface Care

By Mile Brujic, OD, FAAO

Ocular surface disease and dry eye disease are prevalent and pervasive diseases impacting the eye health of patients. The Dry Eye Workshop II (DEWS II) and other current research offer new insights on the characteristics and pathophysiology of Dry Eye Disease (DED), as well as best practices for treatment and management.

Therapeutic strategies that support the ocular surface, counteract hyperosmolarity and restore the tear film can aid in rehabilitating the eye's structures. This knowledge offers an opportunity to introduce new ways to stabilize the tear film and improve patient comfort through rehydration, reduction of surface inflammation, and protection against future desiccation.

An expanding pool of clinical data is supporting the benefits and sustained efficacy of therapies that include bioprotectants such as trehalose to protect cells against hyperosmolarity and promote exit of the vicious cycle of DED physiopathology.¹

As such, lubricant eye drops enhanced with trehalose can provide patients with a new, successful way to rehabilitate the tear film in Ocular Surface Disease (OSD) and DED.

OSD & DED Prevalence & Impact

The 2017 Gallup Study of Dry Eye (conducted by Multi-sponsor Surveys, Inc.) revealed that 56% of adults report experiencing dry eyes frequently (14%) or occasionally (42%).² Projected to the U.S. population, this translates to a staggering 140 million dry eye sufferers.²

From a pathophysiological standpoint, DED amplifies hyperosmolarity in an unforgiving cycle either directly or by inducing a cascade of inflammatory events, contributing to a loss of epithelial and goblet cells that decreases surface wettability and promotes early tear film breakup.³

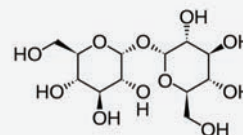
In addition to the physical toll this disease takes on patients, it also has

significant quality-of-life impacts. A number of studies have reported measurable negative effects of DED on daily-living tasks such as reading, carrying out professional tasks and driving.

Insights on Addressing the Problem

The Tear Film & Ocular Surface Society (TFOS) published the Dry Eye

What is Trehalose?



Trehalose—a bisacetal, non-reducing homodisaccharide in which two glucose units are linked together in a α -1,1-glycosidic linkage (α -D-glucopyranosyl- α -D-glucopyranoside; mycose, mushroom sugar)¹—is found abundantly in nature and in the biological world. The “extraordinary” properties of trehalose are responsible for this molecule’s bioprotective role.¹

1. Jain NK, Roy I. Effect of trehalose on protein structure. *Protein Sci.* 2009 Jan;18(1):24-36.

Trehalose – Enhancing as an Excipient

Excipient—an inactive substance that serves as the vehicle or medium for a drug or other active substance. It confers a therapeutic enhancement on the active component in the form of, for example, additional absorption, solubility or strength.

Essentially, an excipient serves to enhance the effectiveness of an active ingredient.

Workshop II report, which includes an updated DED definition that keenly accounts for the pivotal role that tear film hyperosmolarity plays, often resulting in ocular surface inflammation. As well, DEWS II, an evidence-based report involving 150 worldwide experts, illuminates the pathophysiology of dry eye and its central mechanism of evaporative water loss leading to hyperosmolar tissue damage.³

When it comes to DED treatment, longstanding research advocates the use of lubricating eye drops as a palliative technique for symptom relief and to rehabilitate some of the eye

structures, such as the cornea and conjunctiva, which may have suffered the sequelae of dry eye.

New research shows that recent attempts to counteract tear hyperosmolarity in DED have included bioprotectant features and small organic molecules used in many cell types throughout the natural world to restore cell volume and stabilize protein function.¹ These molecules may directly protect cells against hyperosmolarity and promote exit from the vicious circle of DED physiopathology.¹ There is an expanding pool of clinical data on the efficacy of DED therapies that include trehalose, whose unique properties have shown exceptional osmotic and bioprotectant abilities enabling them to act as a water replacement and prevent against desiccation stress.^{1,4,5}

How Trehalose Works

Trehalose maintains cell protein integrity during drying and rehydration, and it has been shown to protect against oxidative strain and stabilize protein function.⁶

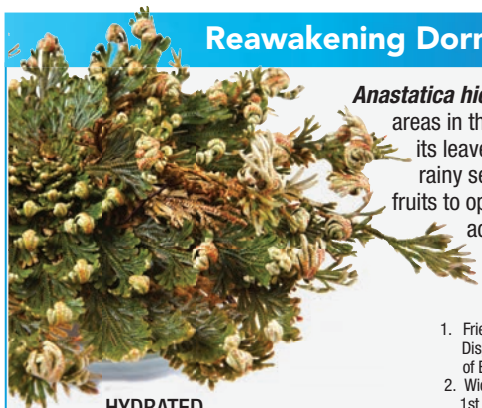
The mechanism by which this member of the polyhydroxyl compound molecules works is by increasing compactness and stability in organisms, thereby aiding in the overcoming of

Clinical Support for Trehalose

Studies have shown that trehalose offers the following ocular surface benefits:

- Protection of human corneal epithelial cells from desiccation-induced death in culture.⁷ One trehalose-containing solution was found to be “effective and safe” for treatment of moderate to severe dry eye syndrome.
- Increased tear film thickness after instillation of one trehalose-containing drop up to 240 minutes compared with drops without trehalose.⁸
- Better patient satisfaction and a therapeutic advancement in treatment of moderate to severe DED when comparing an eyedrop containing hyaluronic acid-trehalose with an HA-only eyedrop.⁹
- Increased tear production at day 14 of treatment in a dry eye mouse model.¹⁰
- Decreased eye surface apoptosis at day 14 of treatment in a dry eye mouse model.¹⁰
- Improved appearance of ocular surface epithelial disorders through suppression of apoptosis and serum-like response upon topical application, as well as maintained corneal health.¹⁰
- Suppressed inflammatory and proteolytic MMP-9 and HSP70 expression and keratinization, and restored ocular surface integrity in mice with dry eye damaged by a desiccative model.¹¹

Reawakening Dormant Desert Life



HYDRATED

Anastatica hierochuntica or white mustard flower, commonly called Rose of Jericho, is found in arid areas in the Middle East and the Sahara Desert.¹ After the rainy season, the plant dries up, drops its leaves and curls its branches into a tight ball to hibernate. Once re-wetted in a subsequent rainy season, the ball uncurls and awakens from its dormant state, causing the capsular fruits to open and disperse seeds. The plant's extraordinary ability to achieve this reawakening activity is attributed to the presence of trehalose, a disaccharide sugar involved in several mechanisms of cryptobiosis.²



DEHYDRATED

1. Friedman J, Stein J. The Influence of Seed-Dispersal Mechanisms on the Dispersion of *Anastatica Hierochuntica* (Cruciferae) in the Negev Desert, Israel. *Journal of Ecology* 1980;68(1):43-50.
2. Wickens GE. *Ecophysiology of Economic Plants in Arid and Semi-Arid Lands* 1st ed. Berlin, Germany: Springer-Verlag Heidelberg; 1998.

Trehalose Use in Dry Eye Disease

Trehalose has been shown to:

1. Rehydrate Tear Film

- Retain moisture when drying out
- Help increase tear film thickness⁸

2. Protect Against Future Irritation

- Help improve corneal staining⁷
- Help protect corneal epithelial cells from apoptosis after desiccation^{3,5}

3. Support Homeostasis of Tear Film

- Restore osmotic balance to ocular surface¹⁰
- Help maintain homeostasis of corneal cells¹⁰

stress conditions such as heat, cold and desiccation.⁶ As a result, trehalose has the unique ability to stabilize proteins and the lipid bilayer.⁶

Remarkably, trehalose can also act as a water substitute. Classified as a kosmotrope or water-structure maker, this molecule is involved in various bioprotective actions.⁶

Future of Treatment

New trehalose-containing solutions are becoming available to help eye care professionals offer patients an alternative treatment and management strategy. As one example, TheraTears[®] is launching a new lubricant eye drop, TheraTears[®] EXTRA Dry Eye Therapy, which contains trehalose as an excipient, serving to enhance the action of the solution's active ingredient, Carboxymethylcellulose (CMC). Doctors

“The inclusion of the excipient trehalose in TheraTears[®] EXTRA Dry Eye Therapy makes it a natural first-line choice for eye care professionals.”— Mile Brujic, OD, FAAO

are excited about the potential of lubricant eye drops enhanced with trehalose.

Elevated tear osmolarity, ocular surface stress and desiccation have long been challenges when treating dry eye patients. DEWS II—the most contemporary knowledge base available in the area of DED management—advocates for the use of artificial tears to retain moisture in and stabilize the tear film, as well as defend against desiccating conditions.

We are fortunate that a new lubricant eye drop enhanced with trehalose—TheraTears[®] Extra Dry Eye Therapy—offers the opportunity to enhance moisture retention in ocular surface cells and foster a rich healing environment for tear film rehabilitation. Research shows that the carboxymethylcellulose formula in TheraTears[®] Extra Dry Eye Therapy is effective in reestablishing normal osmolarity levels, and in improving signs and symptoms in dry eye patients.¹²

In addition, trehalose as an excipient gives us a new way to counteract local environment stressors and support a return to equilibrium through its bioprotective and

osmotic properties. This extraordinary disaccharide has the remarkable ability to shield against desiccating factors, protect corneal epithelial cells from apoptosis and rehydrate the tear film.

With TheraTears[®] Extra Dry Eye Therapy, we can potentially advance dry eye treatment while enhancing patient comfort and vision outcomes. The inclusion of the excipient trehalose in this therapy makes it a natural first-line choice for eye care professionals.

Dr. Brujic practices at Premier Vision Group in Bowling Green, Ohio.

1. Baudouin C, Aragona P, Messmer EM, et al. Role of hyperosmolarity in the pathogenesis and management of dry eye disease: proceedings of the OCEAN group meeting. *Ocul Surf.* 2013 Oct;11(4):246-58.
2. The 2017 Gallup Study of Dry Eye Sufferers (conducted by Multi-sponsor Surveys, Inc.).
3. Nelson JD, Craig JP, Esen A, et al. TFOS DEWS II Report. *Ocul Surf* 2017; 2017 July;15(3):269-650.
4. Jones L, Downie LE, Korb D, et al. TFOS DEWS II management and therapy report. *Ocul Surf.* 2017 Jul;15(3):575-628.
5. Matsuo T. Trehalose protects corneal epithelial cells from death by drying. *Br J Ophthalmol.* 2001;85:610-2.
6. Jain NK, Roy I. Effect of trehalose on protein structure. *Protein Sci.* 2009 Jan;18(1):24-36.
7. Matsuo T, Tsuchida Y, Morimoto N. Trehalose eye drops in the treatment of dry eye syndrome. *Ophthalmology.* 2002 Nov;109(11):2024-9.
8. Schmidl D, Schmetterer L, Witkowska KJ, et al. Tear film thickness after treatment with artificial tears in patients with moderate dry eye disease. *Cornea.* 2015 Apr;34(4):421-6.s
9. Chiambaretta F, Doan S, Labetoulle M, et al. A randomized, controlled study of the efficacy and safety of a new eyedrop formulation for moderate to severe dry eye syndrome. *Eur J Ophthalmol.* 2017 Jan 19;27(1):1-9.
10. Chen W, Zhang X, Liu M, et al. Trehalose protects against ocular surface disorders in experimental murine dry eye through suppression of apoptosis. *Exp Eye Res.* 2009 Sep;89(3):311-8.
11. Li J, Roubeix C, Wang Y, et al. Therapeutic efficacy of trehalose eye drops for treatment of murine dry eye induced by an intelligently controlled environmental system. *Mol Vis* 2012;18:317-29.
12. Ng L, Nguyen A, Karpecki P, Houtman D. Evaluation of Tear Osmolarity Over Time with Sustained Use of TheraTears[®] Lubricant Eye Drops. Poster presented at: The American Academy of Optometry Annual Meeting; November 9-12, 2016; Anaheim, CA.

Trehalose Current and Future Uses

- Major industries: Food, cosmetics, medicine
- An excipient in each of: Herceptin[®], Avastin[®], Lucentis[®] and Advate[®]
- Future applications: Solid dosage formulations, most notably in quick-dissolving tablets

new!

thera
tears®

EXTRA



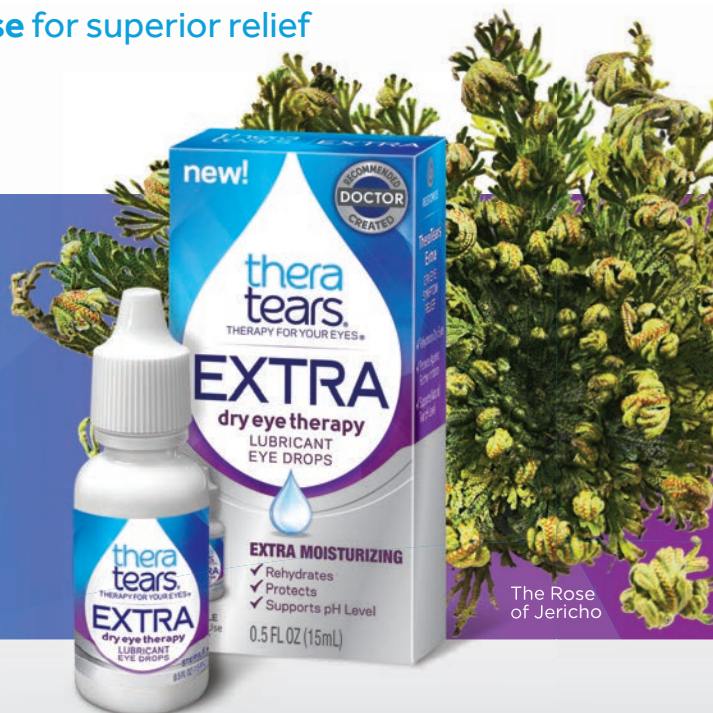HARNESS EXTRA POWER FROM A NATURAL WONDER

NEW TheraTears® Extra Dry Eye Therapy
is enhanced with trehalose for superior relief

Trehalose is a natural disaccharide found in plants with moisture retention properties that help organisms survive in absence of water. In ophthalmic products, trehalose enhances active ingredients to help:

- Protect corneal cells from desiccation
- Restore osmotic balance to the ocular surface
- Maintain the homeostasis of corneal cells

-2017 DEWS II Report



The Rose of Jericho

Learn about our complete line of
dry eye therapy products at theratears.com

Reference: 1. Jones L, Downie L, Korb D, et al. TFOS Dews II Management and Therapy Report. The Ocular Surface Jul 2017; 575-628.
© 2018 Akorn Consumer Health | A Division of Akorn, Inc. | M17-047



Allergies: A Glitch in the Matrix

Pollen, dust and dander are harmless. But the body treats them as threats. Why?

By Bisant A. Labib, OD

In the midst of allergy season, optometrists can expect to see a rise in allergic conjunctivitis (AC). Approximately 20% to 40% of individuals, primarily young adults with a robust immune system, living in developed countries suffer from ocular allergies, with the incidence rising due to genetics, air pollution and pets.¹⁻³ This commonly encountered condition requires understanding of the underlying pathological mechanisms, which trigger often debilitating symptoms.

Classification

AC has two main subtypes: seasonal allergic conjunctivitis (SAC) and perennial allergic conjunctivitis (PAC), with SAC constituting about 90% of cases.³ SAC typically lasts less than four weeks and occurs in response to seasonal allergens such as a genetically susceptible patient's exposure to pollen.^{2,4} In contrast, PAC is more chronic, lasting greater than four weeks, and occurs in response to indoor allergens such as pet dander or dust mites that are present year round.²

Immune Mechanisms

Regardless of the classification, both subtypes are considered Type I immunoglobulin (Ig) E mediated, or immediate, hypersensitivity reactions.^{2,4,5} The process begins when a genetically predisposed individual is first exposed to a specific allergen, a process called sensitization. Neutrophils, macrophages and dendritic cells involved with the

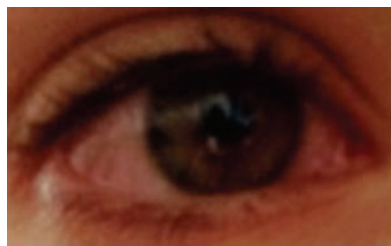


Photo: Alexandra Oszustowicz, OD

Diffuse hyperemia/inflammation in a patient with allergic conjunctivitis.

innate immune system interact with T-lymphocyte cells, producing cytokines that regulate both IgE and eosinophil proliferation. Activated T-cells interact with B-cells that have also encountered the allergen, producing antigen-specific IgE and the allergic and inflammatory response upon re-exposure.^{4,5}

On second exposure to the allergen, these antigen-specific IgE receptors, present on mast cells on the surface of the conjunctiva, cause degranulation and release inflammatory mediators, primarily histamine.^{4,6,7} This leads to the signs and symptoms common for AC patients.

A patient's susceptibility to certain allergens is complex and largely genetically determined. For example, an individual with no family history of allergy has roughly a 10% chance of developing an allergy, whereas 60% to 80% of children with both parents affected develop allergies.

In addition to genetics, a strong correlation exists between exposure in early in life, such as during prenatal development or infancy, and the development of allergic disease later in life. The first 12 to 18 months of

life is a critical period for immune development, and exposure to a specific allergen may lead to the formation of memory T-cell responses that present later in life.⁸

The "hygiene hypothesis"—proposed to explain the increasing rise of atopic and allergic disease—suggests early exposure to infectious agents actually offered protection towards many immune-related disorders. With the decreasing incidence of infectious diseases in developed countries, an incidental rise in immune-mediated diseases has occurred. This is likely because the immune system has fewer potential targets to attack as part of its defense mechanisms, and so it looks for other environmental targets such as pollen or pet dander.⁹

Signs and Symptoms

The hallmark presentation of a patient with AC is bilateral pruritus. Additional signs include conjunctival hyperemia, tearing, eyelid edema and infraorbital edema or darkening, termed an "allergic shiner."⁴ These manifestations arise from the activation of the histamine (H) receptors on the conjunctiva released by mast cells. H1 and H2 are the two main receptors in that area. H1 activation is responsible for itching, while H2 results in vasodilation leading to hyperemia, eyelid edema and chemosis. Recent evidence suggests that H4 receptors may also play a role in the signs and symptoms involved in ocular allergies, though information is limited.⁷

Additional Associations

Because allergic conjunctivitis is a manifestation of systemic allergies, 70% to 95% of patients with allergic conjunctivitis also present with rhinitis resulting from the same allergen.^{1,6} As such, patients treated with either oral or intranasal anti-allergy medications will find that their ocular symptoms also subside. This relationship is best described with the nasal ocular reflex theory, which suggests that the nasolacrimal duct acts as a physical connection from the nasal cavity to the ocular cavity, and that histamine release from mast cells in the nasal mucosa can initiate both the rhinitis and conjunctivitis.⁶

ODs will no doubt run into patients with ocular manifestations of systemic allergies, especially during this time of the year. Understanding the immunologic

changes at play will allow the clinician to choose the right treatment options to target the various cells and receptors.

While this may seem like a rather benign condition, the symptoms are often debilitating for patients. It is also implicated in the possible pathogenesis of corneal ectasia, as excessive eye rubbing may alter corneal collagen, further highlighting the importance of this condition.¹⁰ ■

1. Williams DC, Edney G, Maiden B, Smith PK. Recognition of allergic rhinitis in patients with allergic conjunctivitis. *World Allergy Organization Journal*. 2013;6(4):1-3.
2. Gonzalez-Estrada A, Newton LP. Does allergic conjunctivitis always require prescription eyedrops? *Cleveland Clinic J Med*. 2015;82(12):810-3.
3. Akil H, Celik F, Ulas F, Kara IS. Dry eye syndrome and allergic conjunctivitis in the pediatric population. *Middle East Afr J Ophthalmol*. 2015;22(4):467-71.

Table 1. Hypersensitivity Reactions and Ocular Presentations





Type of Hypersensitivity	Examples of Ocular Diseases
IgE mediated	Allergic conjunctivitis
Cytotoxic IgG mediated	Myasthenia gravis, ocular cicatricial pemphigoid
Immune complex mediated	Steven Johnson's syndrome, uveitis from systemic inflammatory conditions
Cell mediated	Contact dermatitis, herpetic keratitis, phlyctenulosis, corneal transplant rejection

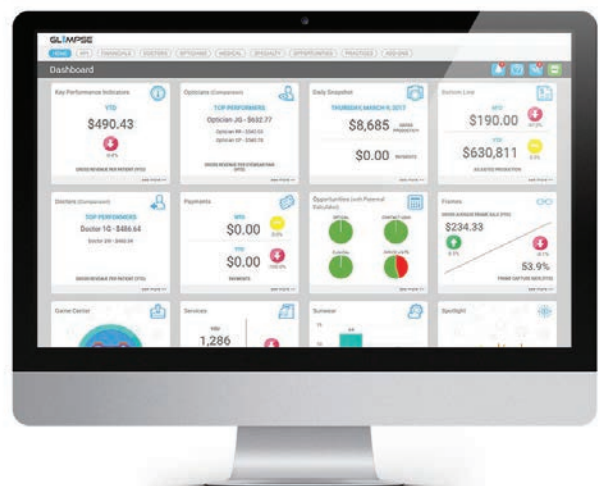4. Bielory BP, O'Brien TP, Bielory L. Management of seasonal allergic conjunctivitis: guide to therapy. *Acta Ophthalmologica*. 2012;90:399-407.
5. Chigbu DI, Coyne AM. Update and clinical utility of alcaftadine ophthalmic solution 0.25% in the treatment of allergic conjunctivitis. *Clin Ophthalmol*. 2015;9:1215-25.
6. Hom MM, Bielory L. The anatomical and functional relationship between allergic conjunctivitis and allergic rhinitis. *Allergy Rhinol*. 2013;4:e110-9.
7. McLaurin EB, Marsico NP, Ackerman SL, et al. Ocular itch relief with alcaftadine 0.25% versus olopatadine 0.2% in allergic conjunctivitis: pooled analysis of two multicenter randomized clinical trials. *Adv Ther*. 2014;31:1059-71.
8. Chad Z. Allergies in children. *Pediatric Child Health*. 2001;6(8):555-66.
9. Okada H, Kuhn C, Feillet H, Bach JF. The 'hygiene hypothesis' for autoimmune and allergic diseases: an update. *Clin Exp Immunol*. 2010;160(1):1-9.
10. Sharma N, Rao K, Maharana PK, Vajpayee RB. Ocular allergy and keratoconus. *Indian J Ophthalmol*. 2013;61:407-9.

GLIMPSE

Unlocking the Future of Healthcare Analytics

ARE YOU KEEPING UP WITH THE COMPETITION?

-  Quickly identify missed revenue opportunities
-  Create your own metric dashboard
-  Complete accuracy customized to your billing habits
-  Have fun and engage your team with Gamification





Documenting for the Long Haul

You've got to get it right the first time when coding for long-term medication use.

By John Rumpakis, OD, MBA, Clinical Coding Editor

When managing chronic diseases in eye care, it's not uncommon for patients to be on multiple medications, whether topical, systemic or both—many of which may cause ocular sequelae. You yourself will likely prescribe long-term medications for conditions such as glaucoma and dry eye. Knowing the rules in the ICD-10 hierarchy to code properly in both of these situations is crucial for getting paid when managing these patients.

Laundry List of Codes

When long-term medications are mentioned in eye care, most think about macular disease associated with Plaquenil (hydroxychloroquine, Sanofi-Aventis)—coded using Z79.899 – other long term (current) drug therapy. However, coding for these situations goes far beyond this one code. Here are the following categories specified by the ICD-10 for long-term medication use, under the heading of long term (current) drug therapy (Z79):

- Z79.0 – long-term (current) use of anticoagulants and anti-thrombotics/antiplatelets.
- Z79.01 – long-term (current) use of anticoagulants.
- Z79.02 – long-term (current) use of antithrombotics/antiplatelets.
- Z79.1 – long-term (current) use of non-steroidal anti-inflammatories.
- Z79.2 – long-term (current) use of antibiotics.
- Z79.3 – long-term (current) use

of hormonal contraceptives.

- Z79.4 – long-term (current) use of insulin.
- Z79.5 – long-term (current) use of steroids.
- Z79.51 – long-term (current) use of inhaled steroids.
- Z79.52 – long-term (current) use of systemic steroids.
- Z79.81 – long-term (current) use of agents affecting estrogen receptors and estrogen levels.
- Z79.810 – long-term (current) use of selective estrogen receptor modulators (serms).
- Z79.811 – long-term (current) use of aromatase inhibitors.
- Z79.818 – long-term (current) use of other agents affecting estrogen receptors and estrogen levels.
- Z79.82 – long-term (current) use of aspirin.
- Z79.83 – long-term (current) use of bisphosphonates.
- Z79.84 – long-term (current) use of oral hypoglycemic drugs.
- Z79.891 – long-term (current) use of opiate analgesic.
- Z79.899 – other long-term (current) drug therapy.

Any number of these will likely crop up as you treat patients over their lifetime. In a dry eye practice, for example, it may be typical to see that the use of hormonal agents—Z79.81—is a causative factor in the dry eye disease process. Another good example is diabetes care; for this common disease, it is important to note in your list of diagnoses if the patient is taking insulin by using the ICD-10 code Z79.4.

The Right Code in Sight

Often, long-term medical therapy comes in two categories in optometry: (1) long-term treatment for an ocular condition such as dry eye or glaucoma, and (2) ocular side effects of long-term systemic therapy. While ODs are well-versed in coding the former, some may be less comfortable with the latter. When coding for side effects of systemic therapy, you must first communicate with the care provider who prescribed the medication to discuss the underlying systemic condition being treated. This will help you better understand the clinical picture and the therapy options available.

From there, follow these steps when coding any ocular condition that may be caused or exacerbated by the use of systemic medications:

1. Code the systemic disease. This is the primary diagnosis.
2. Code the ocular sequelae caused by the medication.
3. Code the proper long-term use of the medication based on the list of possible codes. Remember, ICD-10 requires you to be as specific as possible, so don't fall into the habit of always using Z79.899 just because it's easier.

These basic rules should allow you to always accurately describe, in ICD-10 terms, the conditions the patient presents with. Accuracy and attention to detail will ensure you are reimbursed properly and have fewer claim rejections. ■

Send questions and comments to rocodingconnection@gmail.com.



LOMBART EXCLUSIVE PROMOTIONS

Product Specials • Financing Deals • Service Packages • Used Equipment

LEARN MORE AT LOMBARTINSTRUMENT.COM/PROMOTIONS

WHEN YOU THINK OPHTHALMIC INSTRUMENTS,

THINK LOMBART



**Ongoing
Support**



**Reliable
Service**



**Nationwide
Coverage**

Lombart is committed to meeting the full range of ophthalmic needs of optometry and ophthalmology practices, universities, hospitals and the US government through customized solutions and dedicated partnerships.

Four Steps to a Simple —and Effective— Dry Eye Screening

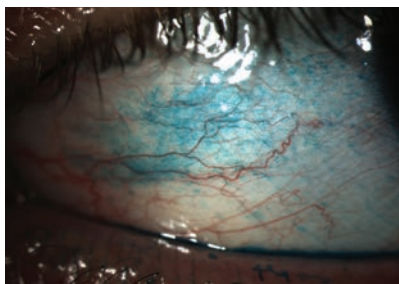
Don't be intimidated by the complexity of the science. This is a service any OD can perform. **By Jane Cole, Contributing Editor**

New recommendations and research have changed the management landscape for dry eye disease (DED), as have new products and devices to test for hallmarks such as tear film homeostasis, hyperosmolarity, meibomian gland dysfunction (MGD) and ocular surface inflammation.

These recent additions have led to questions about the dry eye standard of care and what tests are necessary to properly diagnose these patients.

“We don't have a single gold standard test or even a symptom questionnaire that can make a definitive diagnosis in isolation,” says Dan Fuller, OD, chief of Cornea and Contact Lens Service at Southern College of Optometry. “Setting cut-off values to categorize dry eye patients as normal, mild, moderate or severe has proven challenging.” Instead, doctors need to obtain a symptom questionnaire, run a battery of tests, sift through the results and then correlate the information with the risk factors in the history, he explains.

Photo: Whitney Hauser, OD



Staining with lissamine green is an integral—and easy—step in the dry eye diagnostic process.

Still, experts say you can keep it simple when working up patients.

The Tear Film and Ocular Surface Society's Dry Eye Workshop II (TFOS DEWS II) report “really aims at letting anyone know that they can diagnose dry eye,” says Kelly Nichols, OD, MPH, PhD, Dean of the University of Alabama School of Optometry. “You don't have to have expensive equipment and call yourself an expert or specialist to identify dry eye in clinical care.”

Atlanta's Josh Johnston, OD, echoes this sentiment. “If you just keep it simple, if you talk to your

patients and listen to your patients, and also have your technicians or staff ask about symptoms of dry eye during the exam, and you do the minimal amount of testing which may include fluorescein or lissamine green staining, that is low-level stuff that can get you to a diagnosis.”

These experts' advice comes down to four simple steps to an easy—and accurate—dry eye diagnosis.

Step 1: History is Key

While big-ticket devices are helpful, a thorough patient history is a vital first step, experts say. A complete and accurate case history is arguably the most important part of a DED screening, says Whitney Hauser, OD, associate professor at Southern College of Optometry. “The practitioner should document the history of present illness and the review of systems that can shed light on the origin of the patient's dry eye complaint and describe how the condition affects their quality of life.”

At Schaeffer Eye Center in Alabama, Jack Schaeffer, OD, asks

patients four simple questions:

1. Do you think your eyes look healthy?
2. Do your eyes feel healthy?
3. Are there times when your vision isn't as clear as you'd want it to be?
4. Do your eyes ever feel dry or uncomfortable?

Identifying prior and failed treatments is essential to avoid repeating inadequate options, Dr. Hauser adds. "The final opportunity in obtaining case history of the dry eye patient is to build rapport. Dry eye sufferers have higher levels of anxiety and depression than other patient populations and would benefit from developing a connection and trusting relationship with their doctor."

Step 2: Questionnaire and Risk Factor Analysis

Next, a practitioner or staff member can go into a detailed history with a questionnaire such as the Ocular Surface Disease Index (OSDI) or a Standardized Patient Evaluation of Eye Dryness (SPEED) to help you see if the patient is symptomatic or not, Dr. Schaeffer adds. "These will really determine if this patient should be medically triaged. Keep in mind, when you're examining a patient, your staff should have a flow chart of what you do next when you have a symptomatic patient because you know there are issues identified by the screening questions. When you are dealing with an asymptomatic patient, when all the screening questions are negative, the direction is determined only after you examine the eye and there are signs of ocular surface disease."

DEWS II recommends asking a short series of triaging questions to get an idea whether a patient has dry eye (see, "Triage Trouble-shooting from a DEWS II Insider," p. 42). This can be done in tandem with

a simultaneous risk factor profile, Dr. Nichols says. These questions—designed to uncover DED symptoms and rule out other diseases such as ocular allergy or Sjögren's—can be asked during a case history or on an intake form. They cover topics such as previous artificial tear use, how a patient's eyes feel, if they have dryness or discomfort, contact lens wear and medications.

While many different questionnaires are available, DEWS II recommends the OSDI or the Dry Eye Questionnaire 5 (DEQ-5).¹

"Both short surveys give you a number as a result. And then you look at the score received from the survey in addition to some of the triage questions and risk factor analysis," Dr. Nichols says.

The DEQ-5 offers brief questions about eye discomfort, dryness and watering, and addresses frequency of changes, fluctuation throughout the day and level of symptom intensity, Dr. Hauser explains. "The advantage of the DEQ-5 compared to the more widely recognized OSDI is ease of use, which makes it more applicable as a screening tool. Scoring the DEQ-5 requires simple addition with instructions provided at the bottom of the survey."

Step 3: Simple Tests

Following the questionnaire, Dr. Fuller suggests performing noninvasive testing prior to invasive testing, including tear prism height, debris in the tear film, lid margin contours, gland capping, abnormal blood vessel growth, notching or crusting that may indicate a *Demodex* infestation.

DEWS II recommends up to three noninvasive clinical tests for screening, Dr. Nichols says, which include tear film osmolarity, tear film break-up time (TBUT) and corneal staining assessment. A positive finding in any one of those three tests, in addi-

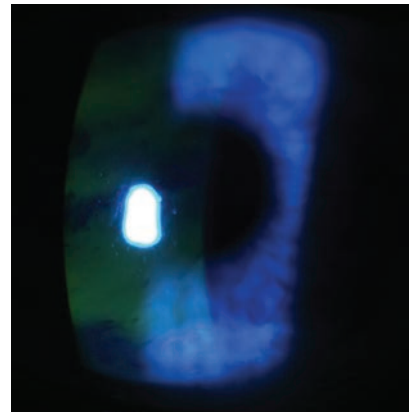


Photo: Whitney Hauser, OD

Fluorescein staining remains a key part of any dry eye workup and doesn't cost much money or time to perform.

tion to abnormal results from the surveys, indicates DED, Dr. Nichols says. "Basically it's the triaging questions + the risk factor assessment + abnormal findings on one of two surveys + one abnormal on one of three tests = dry eye."

Fluorescein and lissamine green staining, in addition to meibomian gland expression and a lid seal test, don't require much of an investment and will cover many issues pertaining to dry eye, Dr. Johnston adds.

Every practice can perform a conventional fluorescein TBUT. Noninvasive TBUT measurements can be performed with instruments such as corneal topographers and interferometers. Clinicians who do not have these technologies can do standard fluorescein TBUT tests.¹ DEWS II recommends both corneal fluorescein and conjunctival staining, with a preference for lissamine green over rose bengal, as it is easier to obtain and less toxic.¹ "There are a lot of new tests, but nothing is more important than fluorescein staining of the cornea, conjunctiva and lid margins," says Dr. Schaeffer.

To determine if the dry eye is evaporative, DEWS II recommends expressing the meibomian glands to look at the quality and quantity of



Triage Trouble-shooting from a DEWS II Insider

TFOS DEWS II added another item to your dry eye diagnostic tool kit: triaging questions.¹ The eight questions are designed to exclude other ocular surface conditions that can mimic dry eye.

“The purpose of the triaging questions is really to aid in a simplistic diagnostic approach to help rule in dry eye or rule out other masking conditions,” says Dr. Nichols, a key contributor to DEWS II.

She offers some insight on the objectives of the questions and how to best interpret your patients’ responses:

1. How severe is the eye discomfort?

The word *severe* correlates strongly with *frequency*, Dr. Nichols says. However, severity gets to the core of how significant the issue is from the patient’s perspective. “It is important to know this before going into diagnosis and management,” she says.

With the answer in hand, the doctor can then try to understand what might be creating the eye discomfort, she says. An appropriate follow-up question would be, “Is the discomfort in one eye or both?” If one eye is worse than the other, you’d try to sort through why that might be, Dr. Nichols says.

2. Do you have any mouth dryness or swollen glands?

One of the main objectives of this question is to rule out Sjögren’s syndrome, Dr. Nichols says. “You’re trying to see if there is a systemic reason why the patient could have dry eye symptoms. Sometimes you hear people talk about the cracker test question, ‘Can you chew and swallow a cracker without a glass of water?’ Usually a patient who has dryness of their mouth will respond, ‘No,’ and that’s another indicator they should be considered for a Sjögren’s workup.”

3. How long have your symptoms lasted and was there any triggering event?

This will flesh out the chronicity of symptoms, and the follow-up question would be, “What have you done to try and alleviate your symptoms and has anything helped?” Dr. Nichols says. “Often times, you’ll have patients say, ‘Well, one day, I just couldn’t wear my contact lenses anymore,’ but that’s generally not the case.” You can tease out the real chain of events by finding out if there was a build-up to that point, where perhaps a patient has had a period of dryness and finally discontinued lens use because they couldn’t take the discomfort anymore. The longevity of symptoms can help you find out if there was a trigger and possibly a recent trigger from allergy or another event, Dr. Nichols says.

4. Is your vision affected and does it clear upon blinking?

This delves into visual disturbance. It is not the black-and-white high contrast visual ability that’s changing, Dr. Nichols says. Often, patients will report they have a hard time keeping their vision clear, and they might blink a lot or put in artificial tears to help if they’ve been on the computer for a long period of time, and by the end of the day, their

eyes have gotten drier as a result. “I’ve had patients who’ve told me, ‘I need to blink a lot when I’m wearing my contact lenses in the evening and that happens right before I decide to take them out.’ So this question has to do with transient visual blur and not, ‘Which is better, one or two?’ visual change.”

5. Are the symptoms or any redness much worse in one eye than the other?

This helps to rule out an infection or episcleritis, Dr. Nichols says. It may indicate whether there is an inflammatory component to the dry eye, and the symptom of redness is generally equal between the eyes in dry eye, she says. If there is some other precipitating factor, like lagophthalmos, redness can be unequal as well.

6. Do your eyes itch, appear swollen or crusty, or give off any discharge?

This will rule out allergic conjunctivitis, allergy or another type of conjunctivitis such as bacterial or viral, Dr. Nichols says. Of course, a patient can have allergy and dry eye simultaneously. “If this is the case, you need to sort through what is the major element leading the patient to these symptoms. So if a patient has ocular itch, it doesn’t mean that they don’t have dry eye too. So you’d treat the allergy first and see what’s left.”

7. Do you wear contact lenses?

Since contact lens use can be a contributing factor to dry eye, it’s important to know if your patient is a current contact lens wearer. If so, ask about replacement schedules, type of lens material and any contributing environmental factors such as computer use.²

8. Have you been diagnosed with any health conditions (including respiratory infections) or are you taking any medications?

Dry eye is associated with certain medications, including those for depression and anxiety, Dr. Nichols says. “If a patient has started something new that has a dry eye side effect they are not aware of, it’s a good time for some education. Likely, the patient may not be able to change that medication, but a conversation with their prescribing family care provider could be beneficial to help with the appropriate management of dry eye due to the medication.” Also, if a patient has been recently diagnosed with a general health condition, such as rheumatoid arthritis where there is a link to inflammation, it may be showing up in their eyes with dryness. This may predispose the patient to a greater risk of developing symptoms. Environmental factors also need to be considered. For example, if a patient lives in arid conditions, a humidifier may help ease the symptoms.

After completing these questions, if you have identified another ocular surface condition, treat for that. If dry eye symptoms persist, consider going further with dry eye diagnosis and management, Dr. Nichols says.

PRESCRIBE MORE THAN A TORIC LENS—
TREAT YOUR PATIENTS TO BIOFINITY.®



With Biofinity® toric and Biofinity® XR toric, you can fit virtually all your astigmatic patients in premium, innovative contact lenses. With its proven performance, Biofinity® toric is the most prescribed toric lens on the market.¹ And patients are just as happy with the performance², that's why over **93%** of US Biofinity® toric wearers remained in the brand¹ and **84%** of patients surveyed agreed or strongly agreed that out of all the contact lenses they've worn, Biofinity® toric lenses are the **best**.²

Find out more about the unparalleled advantages of Biofinity® toric and the rest of the Biofinity® family. For details, visit OnlyBiofinity.com/toric.

FROM SPHERE TO SPECIALTY
Only Biofinity®

SPHERE TORIC MULTIFOCAL

1. Q3 2017 US industry data on file. 2. The results of an online survey involving patients who wear Biofinity® toric contact lenses. January 2018 Biofinity® toric wearer online survey. Data on file.

©2018 CooperVision 5023D 4/18

the secretions. “This will give you an idea if the lipid layer is disrupted, allowing excessive evaporation,” Dr. Nichols says. “Likewise for aqueous deficiency, you’d be looking at a low volume. The DEWS II recommendation is for the tear meniscus height to be measured. A lower meniscus would indicate a more severe version of aqueous deficiency.”

Step 4: Beyond the Basics

Other tools have come out in recent years to help with your DED diagnosis. Here’s a look at some new technologies currently on the market:

Tear osmolarity. “This can be measured by TearLab’s osmometer or the I-Pen tear osmolarity system (I-Med Pharma), the latter of which is newly emerging in the United States,” Dr. Hauser says. A hyperosmolar tear indicates a breakdown of homeostasis, causing tear instability and then inflammation and cellular apoptosis. “The breakdown further reduces the ability of mucins to lubricate,” Dr. Hauser says.

Adds Dr. Schaeffer: “Is everybody doing osmolarity testing today? At this point, no, but they should. You should have a base numeric level of dry eye, an objective score that you can observe after treatment. The change in osmolarity due to your treatment can help determine future strategy.”

Osmolarity has been a hot topic over the last few years, and many doctors worry about the extra cost, says Dr. Nichols. “Certainly, hyperosmolarity is included in the core mechanisms of dry eye. If you are measuring it, it is a good tool. Patients really like having a value to compare between visits. It makes them feel like they can do something about it, like high blood pressure.”

However, variability between the eyes is a hallmark of dry eye. In osmolarity testing, if a big difference

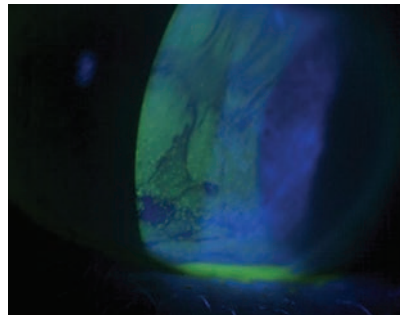


Photo: Jack Schaeffer, OD

TBUT from simple dry eye, measured through fluorescein staining as seen here, is often confused with TBUT associated with epithelial basement membrane dystrophy, although it can be a combination of both.

in readings between the eyes exists, it could still indicate the patient has dry eye even if the numbers are normal, Dr. Nichols adds.

Meibography. This provides static or dynamic images evaluating the structure of the meibomian glands. Tortuosity, atrophy and ductal dilation may be observed and recorded, Dr. Hauser says. Traditionally, the glands can be observed by transillumination technique. However, this is difficult to record and details of the glands are limited, Dr. Hauser adds.

Matrix metalloproteinase-9 (MMP-9) testing. “MMP-9 is a useful biomarker for detecting and managing dry eye disease,” Dr. Hauser says, and this point-of-care test, using InflammDry (Quidel), identifies the presence of MMP-9 in tears ($\geq 40\text{ng/ml}$).

TearLab has applied for FDA approval of its universal MMP-9 platform test as well as osmolarity, although it’s not commercially available yet, Dr. Johnston says.

Aqueous volume testing. These include a Schirmer test or phenol red thread (PRT). Although both tests evaluate tear volume, testing parameters are different, Dr. Hauser says: normal values for Schirmer test are 10mm or greater, while PRT

is 20mm or greater. Additionally, testing times are different: Schirmer is five minutes while PRT is 15 seconds, Dr. Hauser says.

The Diagnostic Future

Looking ahead, biomarker research may one day play a key role in DED diagnosis, and ODs should get familiar with point-of-care tear analysis platforms as new additions using this concept are poised to come on the market, Dr. Nichols says.

“It’s important to note that, while we’ve learned a lot in dry eye, there are still things we don’t have a full understanding of, including how the eye’s ocular surface regulates itself in terms of homeostasis,” Dr. Nichols says. “We know there are hundreds of proteins and hundreds of lipids on the ocular surface and in the tear film, many of which are probably very important in terms of having them in the right quantity relative to other elements in the tear film. So as new diagnostic tests are created looking at specific proteins or lipids, we would hope to have paired treatments that would respond well. This is the whole idea behind biomarker research and then diagnostics around certain biomarkers.”

One final pearl for DED diagnosing from Dr. Schaeffer: screen early. “In early dry eye, patients are having visual fluctuation, and that could be the only observable sign. We need to pick that up during a refraction process. Also, dry eye is a progressive disease. By the time a patient is 50, you’ve probably lost the majority of time you have to really reverse any issues. All you are doing at that point is hopefully slowing down progression. Dry eye screening should start in a patient’s 20s and 30s.” ■

1. Wolffsohn JS, Arita R, Chalmers R, et al. TFOS DEWS II diagnostic methodology report. *Ocul Surf.* 2017;15:544-79.
2. Fuller D. Yes, dry eye patients can wear contacts. *Rev Optom.* 2015;152(8):40-8.



SMART SYSTEM[®] 2 20/20

NEW!

Give your
patients
the best

Call today
1/847-763-0500



Learn more about the Visual Acuity Testing System which includes the best USA-based customer service and technical support in the industry!

ACCURACY • RELIABILITY • REPEATABILITY

Experience the **NEW** All-in-One **Smart System[®] 2**. This state-of-the-art System delivers enhanced performance. Its sleek, compact appearance will streamline and innovate the look of your office.

50 Different Vision Tests, including VA, contrast, stereopsis, binocular balance and color vision.

Near, Intermediate and Distance Testing

DVD Functionality allows the user to play DVDs directly providing immediate fixation on retinoscopies.

Patient Education includes 26 pre-loaded patient education images with the flexibility for additional images and videos

Internal Marketing Load PowerPoint slides, images or videos to promote your practice and educate your patients.

LEA SYMBOLS[®] & LEA NUMBERS[®] The standard in testing children.

M&S
TECHNOLOGIES

Learn more at:
mstech-eyes.com/ebook/ssebook.pdf

The First Choice in Vision Testing Systems

Toll Free: 877-225-6101
mstech-eyes.com



M&S holds US Patents 7,354,155; 7,926,948; 8,425,040; 8,167,429; 8,419,184 & 8,550,631. Other Patents Pending.

Punctal Plugs: An Essential Tool in the Management of Dry Eye

According to current studies, as many as 30 million American adults may have symptomatic dry eye disease (DED).^{1,2} Many of these individuals elect to self-manage their symptoms, usually turning to over-the-counter eye drops. A smaller percentage seek the advice of eye care professionals, who may recommend a myriad of treatment options such as artificial tears, gels or ointments, lid hygiene products, topical or oral pharmaceuticals and nutritional supplements. Less commonly, physicians may employ in-office procedures designed to mitigate symptoms and promote ocular surface health. And although a range of new technologies has been introduced in recent years, no single treatment has emerged that can successfully address all cases of DED.

Historical Perspective

Punctal occlusion has been a recognized therapy for managing disorders of the ocular surface since the 1930s.^{3,4} The concept of punctal occlusion involves a very simple and straightforward mechanism of action. By creating a physical obstruction to tear drainage through the canaliculus, clinicians can provide both increased tear volume and enhanced tear residence time on the ocular surface.⁵

Through the 1990s and early 2000s, punctal plugs were a mainstay of dry eye therapy. As recently as 2003, experts were recommending punctal occlusion for even mild DED (defined as symptoms of dryness without observable signs), typically incorporating this treatment as second-line therapy for those who failed to attain symptomatic relief with tear substitutes alone.^{6,7} Despite the advent of many new forms of therapy, the most current and comprehensive publication on DED—the TFOS DEWS II Report (2017)—remains favorable to early intervention with punctal plugs. In the new treatment algorithm for staged management of DED, experts list punctal occlusion just after the use of non-preserved ocular lubricants, but before prescription drugs such as topical anti-inflammatories (see “TFOS: DEWS II Punctal Occlusion Recommendations”).⁸

Alan G. Kabat, OD, FAAO
Consultant to Lacriversa



When and Where to Plug

While we know that punctal plugs are not ideal for every DED patient, it is important to understand where they may play an appropriate and essential role in therapy. First and foremost, punctal plugs should be considered in all cases of aqueous-deficient DED—specifically, those individuals who show diminished tear volume (as measured by Schirmer strips, phenol red thread test or direct measurement of the tear meniscus), reduced tear stability (rapid tear break-up time) and a symptom profile consistent with dry eye. This includes patients with underlying systemic conditions that predispose toward DED, such as Sjögren syndrome or rheumatoid arthritis, as well as those taking medications that are known to reduce tear production.

Second, patients who develop DED as a consequence of contact lens wear or refractive surgery may also be excellent candidates for punctal plugs. Recent studies corroborate this recommendation.^{9,10}

Third, punctal plugs may benefit patients who are consistently using topical anti-inflammatory medications for DED (e.g. cyclosporine or lifitegrast) but who nonetheless continue to be symptomatic.¹⁵ Additionally, those patients with incomplete lid closure or corneal irregularities that affect tear stability should be considered for punctal plugs.

It is important to understand also that punctal occlusion does not preclude the concurrent use of artificial tears. On the contrary, artificial tears may provide an additional mechanism for relief of sporadic symptoms, but studies have shown that punctal plugs help to significantly reduce the need for frequent drop instillation in patients with DED.¹⁰⁻¹²

Product Considerations

A wide variety of punctal plugs are currently available from numerous manufacturers, but in general there are three basic categories: short-term temporary plugs, long-term temporary plugs, and permanent plugs. The short-

term variety, such as the VeraC7™ are composed of collagen and designed to be absorbed completely in seven to 10 days. Practitioners should think of collagen plugs as a diagnostic tool to determine if punctal occlusion will be well-tolerated by the patient.

Long-term temporary plugs are composed of synthetic polymers that absorb more slowly than collagen. The Vera90™ is made of ε-caprolactone/L-lactide copolymer (PCL), a substance that absorbs in 60 to 180 days. Lacri-vera's temporary plugs are 2.0 mm in length and reside completely within the canaliculus once inserted. They come in 0.3, 0.4 and 0.5 mm diameters to accommodate a range of punctal openings. Long-term temporary plugs are an excellent option for patients that may be expected to have self-limited DED issues, such as those anticipating refractive or cataract surgery. In addition, these can be used for patients who have been identified as good candidates for punctal occlusion, but suffer from awareness with conventional punctal plugs that have exposed caps along the lid margin.

Permanent plugs are composed of non-dissolvable materials, most commonly silicone, although some hydrogel and acrylic devices are also available. The VeraPlug™ and VeraPlug™ FlexFit™ are both silicone plugs designed in the Freeman style. Both products are available in multiple sizes to accommodate various sized punctal openings, but the newer FlexFit™ offers a unique nose technology that collapses upon insertion, thereby allowing for easier sizing and placement. Lacri-vera also offers a product designed to provide partial occlusion. The VeraPlug™ Flow has a narrow inner channel that reduces, but does not completely eliminate tear outflow. It is ideally suited for patients who benefit from punctal occlusion, but experience epiphora with standard permanent plugs.

Regardless of which occlusion device is used, billing and coding remains consistent. Reimbursement is identical for short-term collagen, long-term synthetic inserts and silicone punctal plugs, although most third-party payers limit the frequency that a provider can bill for this service. Checking with the patient's carrier before carrying out these procedures helps to avoid denials and appeals.

The Take-home Message

While punctal occlusion may not be a new therapy, it has proven its value time and time again. Despite setbacks, research and expert consensus validates this treatment modality as a beneficial aspect of DED therapy. Earlier intervention with punctal occlusion makes sense in a great many cases, particularly those outlined here. And

TFOS DEWS II Punctal Occlusion Recommendations⁸

The DEWS II Report also stipulated those clinical situations where punctal plugs might specifically be indicated:

- Dry eye associated with a rapid tear film break-up time
- Aqueous-deficient dry eye secondary to systemic disease (e.g., Sjögren syndrome)
- Systemic medications that reduce tear production (e.g., antihistamines, antidepressants)
- Symptomatic contact lens wear
- Dry eye related to refractive surgery
- Lid closure abnormalities
- Corneal irregularities or scarring that affects tear stability
- Toxic epitheliopathy
- Superior limbic keratoconjunctivitis

while addressing ocular surface inflammation is of great importance, concomitant tear conservation with punctal occlusion appears to further diminish signs and symptoms in those with DED. Unquestionably, these devices should be utilized much more frequently than current trends indicate. Incorporating the use of punctal plugs in one's practice helps to expand its therapeutic reach, enhance its financial health and achieve greater overall patient satisfaction. ■

1. Paulsen AJ, Cruickshanks KJ, Fischer ME, et al. Dry eye in the beaver dam offspring study: prevalence, risk factors, and health-related quality of life. *Am J Ophthalmol*. 2014;157(4):799-806.
2. US Census Bureau. Annual estimates of the resident population for selected age groups by sex for the United States, States, Counties, and Puerto Rico Commonwealth and Municipios: April 1, 2010 to July 1, 2014. Available at: <http://files.hawaii.gov/dbedt/census/popestimate/2014-state-characteristics/>
3. Beetham WP. Filamentary Keratitis. *Trans Am Ophthalmol Soc*. 1935;33:413-35.
4. Macmillan JA, Cone W. THE PREVENTION AND TREATMENT OF KERATITIS NEURO-PARALYTICA BY CLOSURE OF THE LACHRYMAL CANALICULI. *Can Med Assoc J*. 1937 Oct;37(4):348-50.
5. Chen F, Shen M, Chen W, et al. Tear meniscus volume in dry eye after punctal occlusion. *Invest Ophthalmol Vis Sci*. 2010 Apr;51(4):1965-9.
6. Murube J. Surgical treatment of dry eye. *Orbit*. 2003 Sep;22(3):203-32.
7. Calonge M. The treatment of dry eye. *Surv Ophthalmol*. 2001 Mar;45 Suppl 2:S227-39.
8. Jones L, Downie LE, Korb D, et al. TFOS DEWS II Management and Therapy Report. *Ocul Surf*. 2017 Jul;15(3):575-628.
9. Li M, Wang J, Shen M, et al. Effect of punctal occlusion on tear menisci in symptomatic contact lens wearers. *Cornea*. 2012 Sep;31(9):1014-22.
10. Alfawaz AM, Algehedan S, Jastaneiah SS, et al. Efficacy of punctal occlusion in management of dry eyes after laser in situ keratomileusis for myopia. *Curr Eye Res*. 2014 Mar;39(3):257-62.
11. Roberts CW, Carniglia PE, Brazzo BG. Comparison of topical cyclosporine, punctal occlusion, and a combination for the treatment of dry eye. *Cornea*. 2007 Aug;26(7):805-9.
12. Nava-Castaneda A, Tovilla-Canales JL, Rodriguez L, et al. Effects of lacrimal occlusion with collagen and silicone plugs on patients with conjunctivitis associated with dry eye. *Cornea*. 2003 Jan;22(1):10-4.



All About Osmolarity

This biomarker can be a significant help for dry eye testing and monitoring.

By Michelle Hessen, OD

The Tear Film and Ocular Surface Society's 2017 Dry Eye Workshop II defined dry eye disease (DED) as a multifactorial disease with symptoms of discomfort or visual disturbance, and tear film instability with potential damage to the ocular surface. The disease is accompanied by increased tear film osmolarity and inflammation of the ocular surface.^{1,2} While osmolarity has been a part of the dry eye definition for more than 10 years, it has become increasingly important in clinical practice as more research highlights its utility for diagnosing and monitoring DED.^{1,2}

Objectively, research into hyperosmolarity's potential effect on the epithelium and nerves shows tear instability is associated with ratings of discomfort and symptoms of burning and stinging.³ Subjectively, tear film osmolarity is an appealing test because it offers a numerical value for dry eye—something most other DED tests lack. Here, we

Images: Shari Narayanan, OD, PhD, F-Map

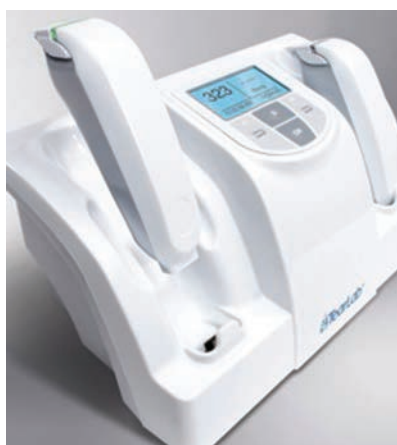

Fig. 1. At left, the TearLab Osmometer is currently the only device clinicians can use in the United State to measure tear film osmolarity.

Fig 2. Below, the I-Pen Tear Osmolarity System is another device currently in use in other countries and on its way to the US market soon.



explore what osmolarity is, how it affects the eye and its value in DED diagnosis and management.

Osmolarity 101

A simple measure of solid particles in a solution, osmolarity is an objective measure of the salt concentration in a patient's tears. Scientifically, it is defined as the concentration of an osmotic solution when measured in liters of the solution. Changes in osmolarity

are due to fluctuations in water content, not tear composition specifically—the balance of proteins, lipids and mucins in tears remains stable.⁴ Hyperosmolarity, whether due to an increased evaporation rate or a reduction of tear secretion, is indicative of reduced aqueous levels.⁵ Tear film hyperosmolarity stimulates epithelial cell death, which then initiates an inflammatory cascade and leads to proinflammatory cytokine production,

cell death via apoptosis and loss of goblet cells.⁶⁻¹⁰

Research suggests proinflammatory mediators and other sources of desiccating corneal stress stimulate compensatory reflex lacrimal tear secretion via the corneal trigeminal nerves.¹¹ Goblet cell loss also leads to a decrease in mucin production and subsequent tear film instability.¹² Increased evaporation resulting from this reduced mucin production may then result in a hyperosmolar state.

In addition, neurogenic inflammation may also play a significant role in the onset and chronicity of ocular surface inflammation and dry eye. This inflammation is produced through the release of neuro-modulators when an eye is exposed to pathogens or mechanical disruption, which can cause the release of polymorphonuclear leukocytes into the tears and the intervention of systemic immunity.¹³

Also, a subsequent loss of corneal sensitivity could further decrease lacrimal production and exacerbate disease severity.^{1,11}

Testing, Testing... 1,2,3

The commonly used instrument to measure tear osmolarity, TearLab's osmometer, uses a micro-electrode to measure the electrical impedance in a tear sample (~0.2 microliters); the electrode is designed to reduce potential reflex tearing, as it avoids direct contact with the ocular surface and collects the tear fluid by passive capillary action (*Figure 1*).¹⁴ The tears are collected at the outermost area of the lateral tear meniscus to minimize the risk of injury to the cornea. Studies show the accuracy differs by only 2mOsm/L in both normal and dry eye patients.¹⁴ The instant result, after the tear sample has been collected, also minimizes the level of tear evapora-

tion.^{14,15} Researchers have found tear osmolarity values are consistent when testing up to four readings taken one to 15 minutes apart.^{16,17}

The I-Pen tear osmolarity system (I-Med Pharma) is another device designed to detect and indirectly measure tear film osmolarity values (*Figure 2*). It uses single-use sensors to gather a sample with approximately two to five seconds of contact with the tear-soaked palpebral

conjunctiva, rather than a liquid sample (*Figure 3*). This may be considered a benefit in cases of severe dry eye when a tear sample may be difficult to obtain. The I-Pen is designed to measure the electrical impedance in the tear-soaked tissues 192 times in less than five seconds and then calculate the osmolarity of the tear film. It has received regulatory approval in Columbia and Argentina and is now available

Systemic and Ocular Associations

A number of studies show increased osmolarity in various ocular conditions other than DED, such as ocular graft-vs.-host disease (GVHD), Sjögren's syndrome (SS), pterygium, thyroid ophthalmopathy, ocular mucous membrane pemphigoid and in patients using topical glaucoma medications and in association with air pollution.¹⁻¹⁰ One study found tear osmolarity increased in patients with chronic ocular GVHD and was significantly correlated with tear break-up time (TBUT) and, to a lesser extent, Schirmer test values and Ocular Surface Disease Index (OSDI) scores.¹ Another study also reported a significant positive correlation between tear osmolarity and corneal staining and OSDI scores, and a significant negative correlation between tear osmolarity and Schirmer value and TBUT.¹

In primary SS, research shows a positive correlation between mean osmolarity and OSDI score and fluorescein ocular surface staining; a negative correlation between mean osmolarity and Schirmer test without anesthesia; and no correlation between osmolarity and TBUT.⁵

Diabetes mellitus is associated with hyperosmolarity as well, particularly based on the duration of the diagnosis.^{11,12} Research suggests the mechanism is a decrease in aqueous secretion as a result of microvascular damage in the lacrimal gland and corneal nerve.¹²

Dry eye symptoms are common in patients with Graves' disease, and one study found ocular discomfort was associated with hyperosmolarity in approximately half of patients with the disease. Increased interpalpebral fissure in patients with Graves' disease was also significantly correlated with hyperosmolarity.¹³

1. Berchicci L, Luliano L, Miserocchi E, et al. Tear osmolarity on ocular graft-versus-host disease. *Cornea*. 2014;33:1252-6.
2. Na K, Yoo Y, Hwang K, et al. Tear osmolarity and ocular surface parameters as diagnostic markers of ocular graft-versus-host disease. *Am J Ophthalmol*. 2015;160(1):143-9.
3. Bunya VY, Langelier N, Chen S, et al. Tear osmolarity in Sjögren syndrome. *Cornea*. 2013;32:922-7.
4. Utine CA, Bicakcigil M, Yavus S, et al. Tear osmolarity measurements in dry eye related to primary Sjögren syndrome. *Curr Eye Res*. 2011;36:683-90.
5. Kim M, Kim HS, Na KS. Correlation between tear osmolarity and other ocular surface parameters in primary Sjögren's syndrome. *Korean J Ophthalmol*. 2017;31(1):25-31.
6. Julio G, Lluch S, Pujol P, et al. Tear osmolarity and ocular changes in pterygium. *Cornea*. 2012;31:1417-21.
7. Labbé A, Terry O, Brasnu E, et al. Tear film osmolarity in patients treated for glaucoma or ocular hypertension. *Cornea*. 2012;31:994-9.
8. Torricelli AM, Novaes P, Marsuda M, et al. Correlation between signs and symptoms of ocular surface dysfunction and tear osmolarity with ambient levels of air pollution in a large metropolitan area. *Cornea*. 2013;32:e11-e15.
9. Iskeleli G, Karakoc Y, Abdula A. Tear film osmolarity in patients with thyroid ophthalmopathy. *Jpn J Ophthalmol*. 2008;52(4):323-6.
10. Miserocchi E, Luliano L, Berchicci L, et al. Tear film osmolarity in ocular membrane pemphigoid. *Cornea*. 2014;33:668-72.
11. Alves M, Reinach PS, Paula JS, et al. Comparison of diagnostic tests in distinct well-defined conditions related to dry eye disease. *PLoS One*. 2014;9(5):e97921.
12. Sagdik HM, Uğurbas SH, Can M, et al. Tear film osmolarity in patients with diabetes mellitus. *Ophthalmic Res*. 2013;50:1-5.
13. Gilbard JP, Farris RL. Ocular surface drying and tear film osmolarity in thyroid eye disease. *Acta Ophthalmol*. 1983;61(1):108-16.



Images: Shihari Narayanan, OD, PhD, I-Med




Fig. 3. At left, TearLab's osmometer collects a liquid sample at the outermost area of the lateral tear meniscus. The I-Pen, at right, gathers a sample with approximately two to five seconds of contact with the tear-soaked palpebral conjunctiva.

in five countries in South America. The Food and Drug Administration issued an Acceptance Review Notification for the device's 510k submission in December 2017, and distribution in the United States is expected after 510k approval sometime in 2018.¹⁸

During a dry eye evaluation, clinicians should remember to perform tear osmolarity before any other test, such as vital dye ocular surface staining, to avoid introducing a solution or creating reflex tearing, which could alter the osmolarity. Contact lenses do not have to be removed before this test. TearLab also recommends not collecting tear fluid from a patient within two hours of their use of eye drops, topical medications, face lotions or eye makeup remover, as all of these may trigger reflex tearing.

A Numbers Game

Tear osmolarity threshold values vary from 305mOsm/L to 316mOsm/L, depending on the research.^{15,16} One study reports that using an osmolarity threshold of 305mOsm/L gave a 98.4% positive predictive value.¹⁶ In other studies, a tear osmolarity threshold of 316mOsm/L to 317mOsm/L gave a sensitivity that varied from 59% to 81% and a specificity from 78% to 94%, with a positive predictive value of 85% and a negative pre-

dictive value of 74%.^{19,21} A meta-analysis that used a 316mOsm/L threshold noted that tear osmolarity may be more accurate in the diagnosis of dry eye than lactoplate immunoassay test, Schirmer test and rose bengal testing.¹⁹ Studies also show tear osmolarity is influenced by, and correlated with, disease severity.^{19,20}

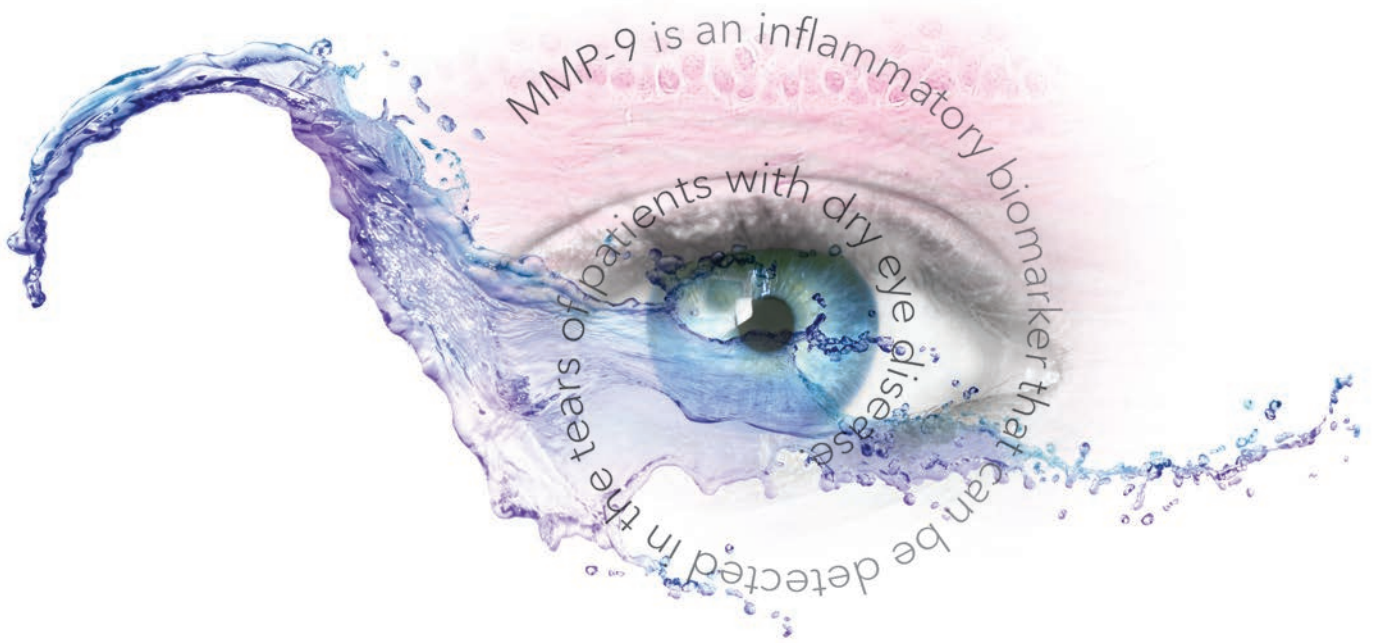
Currently, most researchers believe the 316mOsm/L threshold better discriminates between mild and moderate-severe dry eye, while 308mOsm/L is a widely accepted threshold.¹⁵ Most clinicians identify the 308mOsm/L threshold with diagnosing dry eye, as it appears to be the most sensitive for discriminating between normal eyes and those presenting with early stages of the disease.¹⁹ In one study, a tear osmolarity of 308mOsm/L correctly diagnosed severe dry eye 90.7% of the time and normal tear film 81.3% of the time.¹⁹ TearLab reliability studies determining diagnostic performance revealed a sensitivity of 81% and a specificity of 80% when using the threshold value of 308mOsm/L.²² Another study reported the coefficient of reproducibility was 39mOsm/L and the coefficient of repeatability was 33mOsm/L.²³ The highly variable nature of the tear film may be at play with these relatively large values, which may be due to a small

tear film sample in the tear meniscus at that given time. Others show that a variation of 35mOsm/L in consecutive tear osmolarity readings in an individual and an average over three consecutive readings was a reliable indicator of tear osmolarity at a 95% confidence interval.²⁴

Inter-eye tear osmolarity variability can also be diagnostic of dry eye; one study found variability between the two eyes in mild, moderate and severe dry eye patients was 6.9 ± 5.9 mOsm/L, 11.7 ± 10.9 mOsm/L and 26.5 ± 22.7 mOsm/L, respectively.¹⁹ Variability also seems to increase with severity, both in inter-eye measurements and repeat measurements in the same eye.¹⁹ Using the higher osmolarity value of the two eyes can increase the likelihood of a correct diagnosis. Because the tear film is highly dynamic, a single osmolarity value of the tear meniscus sample should be only one data piece to consider in addition to other dry eye testing.

Fitting In

Researchers looked at tear osmolarity testing in dry eye patients vs. normal control subjects and even compared it with diagnostic tests already in use, including Schirmer I, fluorescein break-up time, ferning test, lissamine green vital staining, tear clearance, corneal esthesiometry, conjunctival scraping and imprint cytology. Tear osmolarity's diagnostic performance is promising: research found a highest correlation between tear osmolarity and tear clearance, TBUT and a clinical score; a medium correlation with lissamine green staining, ferning testing, scraping and imprint conjunctival cytology; and a small correlation with subjective symptoms score, tear volume and corneal esthesiometry. Given osmolarity's good performance compared with



Are dry, itchy eyes caused by contact lenses?


It's not complicated.

Your contact lens wearing patient presents with dry, itchy eyes. It's easy for doctor and patient to assume that this is a complication associated with lens wear, but that's not always the case. With similarities in lens related and inflammatory related dry eye symptoms it's critical to perform the proper diagnostics.

If elevated MMP-9, a key inflammatory biomarker for dry eye, is tested for and detected you'll know that it's more than just their contact lenses. You'll have an opportunity to create a more comprehensive treatment plan, aimed at alleviating symptoms and improving comfort while mitigating potential complications of lens wear with the presence of inflammatory dry eye disease.

InflammaDry is the only rapid, CLIA-waived, in-office, point-of-care test that detects MMP-9. InflammaDry provides results in minutes, is easily performed in 4 simple steps, is minimally invasive and requires no special equipment.

To find out how testing for MMP-9 with InflammaDry can take the complication out of your dry itchy eye treatment therapies before there are complications, visit us at **AOA, Booth #1408** or contact your Quidel Account Manager at **800.874.1517**.





other mainstream dry eye testing, particularly in severe dry eye, researchers feel it should be considered a valuable clinical test. Not only can it be helpful in making a diagnosis of dry eye, it can also be used to evaluate the management plan with serial testing on follow-up examinations.¹⁶

A review that evaluated the correlation between changes in tear

osmolarity, symptoms and corneal fluorescein staining in patients with DED found a statistically significant correlation between changes in corneal fluorescein and symptoms of DED. Interestingly, there was no correlation between the recorded change in dry eye symptoms or tear osmolarity in corneal fluorescein staining. A multivariate analysis revealed that changes in corneal

fluorescein staining had a predictive value on symptom changes, whereas tear osmolarity changes did not. Therefore, improvement in corneal staining was associated more with an improvement in patient symptoms than improvement in osmolarity values.²⁵

While tear film osmolarity is a beneficial measurement as part of a dry eye evaluation, it should be

The Influence of External Factors

Any number of environmental stimuli can impact osmolarity, the most well known being smoking. A prospective, case-controlled, comparative study demonstrated that smoking one pack of cigarettes a day caused significantly higher osmolarity values and OSDI scores than nonsmoking subjects.¹ Others found acute smoke exposure caused tissue damage associated with increased products of lipid peroxidation and degradation products of the extracellular matrix.^{2,3} Lipid disruption of the tear film also occurs in smokers, as one study found the lipids did not spread over the corneal surface when the tear interference pattern was analyzed with a DR-1 lipid layer interferometry device.⁴

Other external factors may have an effect, but research is still divided. For example, controversy exists over whether humidity impacts osmolarity, as the few existing studies show conflicting results. Some studies show a high variability in osmolarity in “normal” subjects exposed to low relative humidity, while others show no increase or variability based on exposure to low humidity.^{5,6}

Research into contact lenses and osmolarity also shows either an increase or no effect on osmolarity with contact lens wear.⁷⁻¹² One study of 52 women using oral contraceptive pills and contact lenses compared with 45 women not using any form of hormonal contraception, found no significant differences in OSDI and tear osmolarity among the same subject groups.¹² However, the researchers did conclude that dry eye symptomatology was worse in the group using oral contraception and wearing contact lenses.¹²

Ocular surgery may influence tear film osmolarity, but study results depend on the procedure and patient age. One study found tear osmolarity in patients with an average age of 70.83 ± 10.66 increases after cataract surgery.¹³ In contrast, patients with an average age of 26.2 ± 4.4 status-post refractive surgery did not demonstrate an increase in tear osmolarity.¹⁸

Immediately after phacoemulsification, statistically significantly detrimental changes occurred in all dry eye parameters (tear production, evaporation, lipid layer interferometry, osmolarity and corneal sensation) and tear physiology recovered by one month. Corneal sensation, however, did not return to normal values in three months, but a trend towards full recovery was noted.

Patients on chronic topical anti-glaucoma medication and post-trabeculectomy patients were more likely to have raised tear film osmolarity and dry eye symptoms, suggesting significant ocular surface disease.¹⁴ Researchers note dellen formation proximate to the blebs in 10% of trabeculectomy cases, which they thought was associated with a compromised tear film that has a tendency to break up adjacent to the bleb.¹⁵

In addition, antimetabolites (e.g., mitomycin C) compromise the corneal epithelium, which, combined with inflammatory cells, may lead to a poor tear film.^{16,17}

1. Aktas S, Tetikoglu M, Kocak Am, et al. Impact of smoking on the ocular surface, tear function, and tear osmolarity. *Curr Eye Res.* 2017;42(12):1585-9.
2. Kirkham PA, Spooner G, Rahman I, Rossi AG. Macrophage phagocytosis of apoptotic neutrophils is compromised by matrix proteins modified by cigarette smoke and lipid peroxidation products. *Biochem Biophys Commun.* 2004;318(1):32-7.
3. Duthie GG, Arthur JR, Beattie JA, et al. Cigarette smoking, antioxidants, lipid peroxidation, and coronary heart disease. *Ann N Y Acad Sci.* 1993;686:120-9.
4. Altinors DD, Akca S, Akova YA, et al. Smoking associated with damage to the lipid layer of the ocular surface. *Am J Ophthalmol.* 2006;141(6):1016-21.
5. Tomlinson A, Madden LC, Simmons PA. Effectiveness of dry eye therapy under conditions of environmental stress. *Curr Eye Res.* 2013;38(2):229-36.
6. López-Miguel A, Tesón M, Martín-Martínez V, et al. Dry eye exacerbation in patients exposed to desiccating stress under controlled environmental conditions. *Am J Ophthalmol.* 2014;157(4):788-98.e2.
7. The Definition and Classification Subcommittee of the International Dry Eye Workshop. The definition and classification of dry eye disease: report of the Definition and Classification Subcommittee of the International Dry Eye Workshop (2007). *Ocul Surf.* 2007;5(2):75-92.
8. Lemp MA, Bron AJ, Baudouin C, et al. Tear osmolarity in the diagnosis and management of dry eye disease. *Am J Ophthalmol.* 2011;151(5):792-8.
9. Nichols JJ, Sinnott LT. Tear film, contact lens, and patient-related factors associated with contact lens-related dry eye. *Invest Ophthalmol Vis Sci.* 2006;47(4):1319-28.
10. Miller WL, Doughty MJ, Narayanan S, et al. A comparison of tear volume (by tear meniscus height and phenol red thread test) and tear fluid osmolarity measures in non-lens wearers and in contact lens wearers. *Eye Contact Lens.* 2004;30(3):132-7.
11. Muselier-Mathieu A, Bron AM, Mathieu B, et al. Ocular surface assessment in soft contact lens wearers; the contribution of tear osmolarity among other tests. *Acta Ophthalmol.* 2014;92(4):364-9.
12. Chen SP, Massaro-Giordano G, Pistilli M, et al. Tear osmolarity and dry eye symptoms in women using oral contraception and contact lenses. *Cornea.* 2013;32(4):423-28.
13. Khanal S, Tomlinson A, Esakowitz L, et al. Changes in corneal sensitivity and tear physiology after phacoemulsification. *Ophthalmic Physiol Opt.* 2008;28(2):127-34.
14. Lee SY, Wong TT, Chua J, et al. Effect of chronic anti-glaucoma medications and trabeculectomy on tear osmolarity. *Eye (Lond).* 2013;27(10):1142-50.
15. Soong HK, Quigley HA. Dellen associated with filtering blebs. *Arch Ophthalmol.* 1982;101(3):385-87.
16. Coppens G, Maudgal P. Corneal complications of intraoperative mitomycin C in glaucoma surgery. *Bul Soc Belge Ophthalmol.* 2010;314:19-23.
17. Hau S, Barton K. Corneal complications of glaucoma surgery. *Curr Opin Ophthalmol.* 2009;20(2):131-6.
18. Demirok A, Ozgurhan EB, Agca A, et al. Corneal sensation after corneal refractive surgery with small incision lenticule extraction. *Optom Vis Sci.* 2013;90(10):1040-7.

Healing Beyond Relief

Go beyond simply
managing symptoms

PROKERA is the only device with amniotic membrane recognized by the FDA for reducing inflammation.¹ **PROKERA** may accelerate healing of the ocular surface and has demonstrated sustained reduction of DEWS score from 3.25 to 1.44 with one treatment in 3-5 days.²

To learn more, call or
visit: 1.888.296.8858

www.biotissue.com



PROKERA[®]

¹ Bio-Tissue, Inc. Request for Designation (RFD), Letter on file, 2001

² McDonald et al. "Treatment Outcomes in the Dry Eye Amniotic Membrane (DREAMS) study." Clinical Ophthalmology. 2018

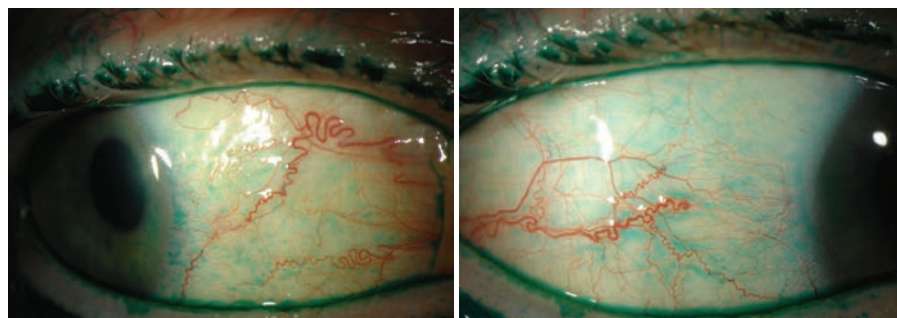


Fig. 4. Osmolarity is a helpful tool to use in addition to other dry eye diagnostics, such as lissamine green staining on the conjunctiva, seen here.

used in combination with other testing (Figure 4). In early stages of DED, for example, compensatory mechanisms occur to help maintain osmolar homeostasis, which may result in variable—even normal—osmolarity readings in patients with dry eye symptoms. Examples of compensatory mechanisms include increased blink rate and aqueous tear production.

Periodic osmolarity testing is quite helpful when evaluating the progress of treatment, as most therapies are designed to significantly reduce osmolarity values:

Meibomian gland expression.

A single-center review of patients with meibomian gland dysfunction and DED with baseline osmolarity >307mOsm/L reported a statistically significant reduction in mean tear film osmolarity from 317mOsm/L to 306.6mOsm/L after thermal pulsation treatment.²⁶

Topical steroids. For patients with moderate to severe dry eye, topical 1% methylprednisolone QID reduced osmolarity and cytokine levels at four weeks and eight weeks compared with baseline.²⁷

Artificial tears. When evaluating osmolarity values with the use of different artificial tear drops five times daily in patients with moderate to severe dry eye, researchers found the mean tear osmolarity decrease at week 12 was any-

where from -25.7 ± 13.1 mOsm/L to 33.8 ± 8.3 mOsm/L, depending on the brand.²⁸

Tear film osmolarity is quickly becoming an important tool in clinical practice; it's not only a useful numeric value to obtain as part of a dry eye evaluation, but it's also great for monitoring treatment progress. With a good understanding of the inflammatory pathophysiology of dry eye, clinicians can appreciate the utility of osmolarity testing and successfully integrate it into their dry eye management plan. ■

Dr. Hessen is a clinical instructor at the Wilmer Eye Institute's Ocular Surface Diseases and Dry Eye Clinic at Johns Hopkins School of Medicine, where she specializes in ocular surface disease, including autoimmune disorders.

1. The Definition and Classification Subcommittee of the International Dry Eye Workshop. The definition and classification of dry eye disease: report of the Definition and Classification Subcommittee of the International Dry eye Workshop (2007). *Ocul Surf.* 2007;5(2):75-92.
2. Craig JP, Nichols KK, Akpek EK, et al. TFOS DEWS II definition and classification report. *Ocul Surf.* 2017;15(3):276-83.
3. Liu H, Begley C, Chen M, et al. A link between tear instability and hyperosmolarity in dry eye. *Invest Ophthalmol Vis Sci.* 2009;50(8):3671-79.
4. Gilbard JP, Rossi SR. Changes in tear ion concentrations in dry-eye disorders. *Adv Exp Med Biol.* 1994;350:529-33.
5. Baudouin C, Aragona P, Messmer E, et al. Role of hyperosmolarity in the pathogenesis and management of dry eye disease: proceedings of the OCEAN group meeting. *Clinical Science.* 2013;114(4):246-58.
6. Li DQ, Chen Z, Song XJ. Stimulation of matrix metalloproteinases by hyperosmolarity via a JNK pathway in human corneal epithelial cells. *Invest Ophthalmol Vis Sci.*

- 2004;45(12):4302-11.
7. Li DQ, Luo L, Chen Z, et al. JNK and ERK MAP kinases mediate induction of IL-1 beta, TNF-alpha and IL-8 following hyperosmolar stress in human limbal epithelial cells. *Exp Eye Res.* 2006;82(4):588-96.
8. Lee JH, Kim M, Im YS, et al. NFAT5 induction and its role in hyperosmolar stress in human limbal epithelial cells. *Invest Ophthalmol Vis Sci.* 2008;49(5):1827-35.
9. Luo L, Li DQ, Corrales RM, Pflugfelder SC. Hyperosmolar saline is a proinflammatory stress on the mouse ocular surface. *Eye Contact Lens.* 2005;31(5):186-93.
10. Luo L, Li DQ, Pflugfelder SC. Hyperosmolarity-induced apoptosis in human corneal epithelial cells is mediated by cytochrome c and MAPK pathways. *Cornea.* 2007;26(4):452-60.
11. Bron AJ, Ukoi N, Gafney E, Tiffany JM. Predicted phenotypes of dry eye: proposed consequences of its natural history. *Ocul Surf.* 2009;7(2):78-92.
12. Pflugfelder SC, Tseng SC, Yoshino K, et al. Correlation of goblet density and mucosal epithelial membrane mucin expression with rose bengal staining in patients with ocular irritation. *Ophthalmology.* 1997;104(2):223-35.
13. Beuerman RW, Stern ME. Neurogenic inflammation: A first line defense for the ocular surface. *Ocul Surf.* 2005;3(4 suppl):S203-6.
14. Tomlinson A, McCann LC, Pearce EI. Comparison of human tear film osmolarity measured by electrical impedance and freezing point depression techniques. *Cornea.* 2010;29(9):1036-41.
15. Jacobi C, Jacobi A, Kruse FE, Cursiefen C. Tear film osmolarity measurements in dry eye disease using electrical impedance technology. *Cornea.* 2011;30(12):1289-92.
16. Versura P, Profazio V, Campos EC. Performance of tear osmolarity compared to previous diagnostic tests for dry eye diseases. *Curr Eye Res.* 2010;35(7):553-64.
17. Keech A, Senchyna M, Jones L. Impact of time between collection and collection method on human tear fluid osmolarity. *Curr Eye Res.* 2013;38(4):428-36.
18. OCUsoft Partners with I-MED Pharma to Bring the I-Pen Osmolarity System to the U.S. PRNewswire. January 8, 2018. www.prnewswire.com/news-releases/ocusoft-partners-with-i-med-pharma-to-bring-the-i-pen-osmolarity-system-to-the-us-300579088.html. Accessed April 10, 2018.
19. Lemp MA, Bron AJ, Baudouin C, et al. Tear osmolarity in the diagnosis and management of dry eye disease. *Am J Ophthalmol.* 2011;151(5):792-8.
20. Sullivan BD, Whitmer D, Nichols KK, et al. An objective approach to dry eye disease severity. *Invest Ophthalmol Vis Sci.* 2010;51(12):6125-30.
21. Khanal S, Tomlinson A, McFadyen A, et al. Dry eye diagnosis. *Invest Ophthalmol Vis Sci.* 2008;49(4):1407-14.
22. Sullivan BD, Eldridge DC, Berg M, et al. Diagnostic performance of osmolarity combined with subset markers of dry eye disease in an unstratified patient population. *Invest Ophthalmol Vis Sci.* 2010;51:3380.
23. Esperjesi F, Aujla M, Bartlett H. Reproducibility and repeatability of the Ocusense TearLab osmometer. *Graefes Arch Clin Exp Ophthalmol.* 2012;250:1201-5.
24. Khanal S, Millar TH. Barriers to clinical uptake of tear osmolarity measurements. *Br J Ophthalmol.* 2012;96:341-4.
25. Amparo F, Jin Y, Hamrah P. What is value of incorporating tear osmolarity measurement in assessing patient response to therapy in dry eye disease? *Am J Ophthalmol.* 2014;157(1):69-77.
26. Kim MJ, Stinnett SS, Gupta PK. Effect of thermal pulsation treatment on tear film parameters in dry eye disease patients. *Clin Ophthalmol.* 2017;11:883-6.
27. Lee JH, Min K, Kim SK, et al. Inflammatory cytokine and osmolarity in the tears of dry eye patients treated with topical 1% methylprednisolone. *Yonsei Med J.* 2014;55(1):203-8.
28. Cómez AT, Tufan HA, Kocabişik O, et al. Effects of lubricating agents with different osmolarities on tear osmolarity and other function tests in patients with dry eye. *Curr Eye Res.* 2013;38(11):1095-103.

Bausch + Lomb ULTRA® for Astigmatism PROVIDES ALL-DAY COMFORT, STABILITY, AND CONSISTENTLY CLEAR VISION¹

EXPANDED PARAMETERS
NOW AVAILABLE



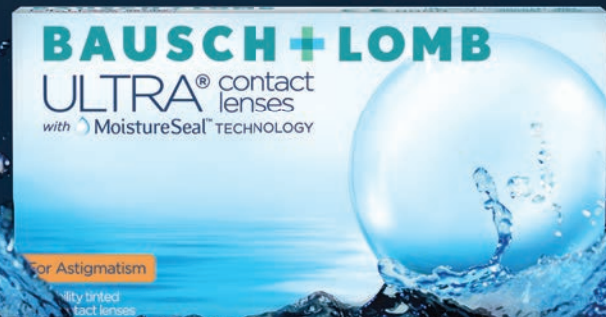Helps maintain **95%**
of lens moisture for
a full **16 hours**²

OPTICALIGN™ DESIGN

For stability to promote
a **successful first fit**¹



- ECPs reported **rotation** at dispensing of **5 degrees or less** for 94% of patients¹
- **Spherical aberration control** optimized in both axes helps **reduce halos and glare**^{1,2}



**PRESCRIBE BAUSCH + LOMB ULTRA®
FOR ASTIGMATISM**

REFERENCES: 1. Results from a 7-investigator, multi-site 2-week study of Bausch + Lomb ULTRA® for Astigmatism contact lenses on 157 current soft contact lens wearers. 2. Data on file. Bausch & Lomb Incorporated. Rochester, NY.

®/™ are trademarks of Bausch & Lomb Incorporated or its affiliates.
©2017 Bausch & Lomb Incorporated. UFA.0218.USA.17

BAUSCH + LOMB
See better. Live better.

Mixed DED: A Chimera in Your Chair

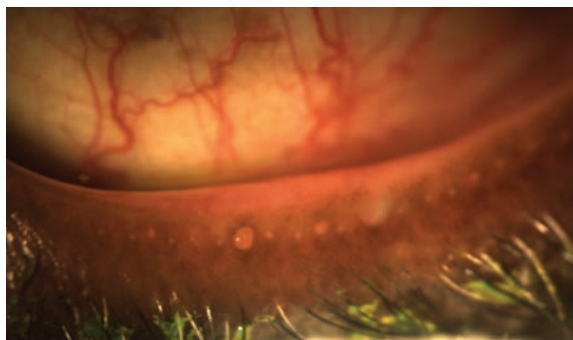
What is it and how can you diagnose and manage patients who have it?

By Doan Huynh Kwak, OD

Caring for patients with dry eye disease (DED) has always been a complex process that begins with a search for the underlying etiologies at play. Whether a patient has aqueous-deficient dry eye (ADDE) or evaporative dry eye (EDE) is a crucial distinction for management purposes, yet they are not mutually exclusive. Research now suggests 30% to 70% of dry eye patients may have a hybrid of both forms.¹ This article explores the new understanding of mixed dry eye presented by the Tear Film and Ocular Surface Society's (TFOS) Dry Eye Workshop (DEWS) II, and how to manage it in your clinic.

Update Your Outlook

The TFOS DEWS II revised definition characterizes DED as a loss of tear film homeostasis accompanied by ocular symptoms. Tear film instability and hyperosmolarity, ocular surface inflammation and damage and neurosensory abnormalities are all included as possible etiologies.²



This lower lid shows signs of obstructed meibomian glands, and digital pressure releases thickened and cloudy meibum.

Additionally, the revised classification system now indicates that ADDE and EDE are no longer two separate entities; rather, they are coexistent on a continuum.² Considering epidemiological and clinical studies suggest that most DED is evaporative in nature, the report shows the majority of this continuum is EDE.^{2,3} According to DEWS II, tear hyperosmolarity and instability are the two major players of DED. Tear hyperosmolarity—the increased osmolarity of the tears compared with the epithelial cells—leads to reduced epithelial cell volume and increased solute

concentrations.⁴ In ADDE, hyperosmolarity is created by a reduction of lacrimal secretion. Reduced tear secretion caused by lacrimal gland dysfunction in age-related DED is just one example of ADDE. In EDE, however, the hyperosmolarity is created by an excessive evaporation from the tear film.² The tear film lipid deficiency from meibomian gland dysfunction (MGD) is a common

example of the excessive evaporation seen in EDE. The DEWS II report recognizes that these two subtypes, ADDE and EDE, can often coexist as a hybrid or mixed dry eye.

Diagnostic Maze

When diagnosing the primary etiology of a patient's dry eye, an important first step is determining if it's due to a lipid or an aqueous deficiency. Unfortunately, because



Chimera (kī mirə)

In Greek mythology, a hybrid creature comprised of two or more animals.

the two are closely related, each able to affect the other, getting to the bottom of the problem isn't as easy as it sounds. For one, researchers hypothesize that the early and late stages of DED may differ in their clinical features.⁵ DED may initially present as purely ADDE or EDE, but as it progresses, the characteristics of both will likely become more pronounced, presenting as a mixed form of DED.^{3,5} Thus, a patient with mild ADDE may present with low aqueous tear secretion secondary to lacrimal dysfunction and a normal evaporative rate in the absence of an eyelid or ocular surface-related cause. If the patient's DED progresses to a more severe form, it may become associated with a slow tear film lipid layer spreading, resulting in an increase in tear evaporation—a hybrid of ADDE and EDE.⁵

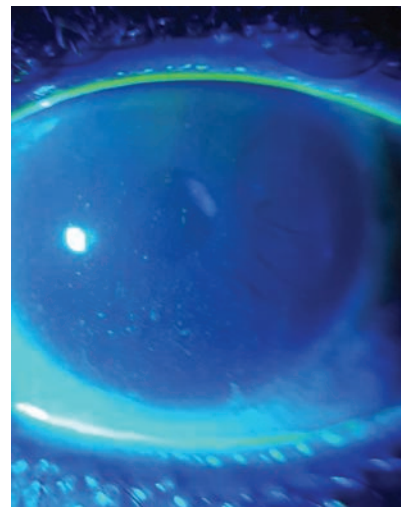
To understand mixed dry eye, clinicians must first understand the many physiological changes at play.

ADDE. This is composed of two subcategories: Sjögren's syndrome (SS) dry eye and non-SS dry eye. SS is an autoimmune disorder consisting of immune cell infiltration of exocrine glands (i.e., salivary and lacrimal) and systemic complications secondary to events such as autoantibody production and lymphocytic infiltration of organs.⁶ In SS dry eye, immune cell infiltration of lacrimal and salivary glands leads to glandular destruction and sicca symptoms.⁶ This destruction and additional inflammatory changes lead to a loss of aqueous tear flow.⁶

The clinical features of non-SS dry eye, although similar to SS dry eye, occur later in life and are usually less severe.⁶ Apart from the glandular destruction or dysfunction, reduction in lacrimal tear secretion may be attributed to a decreased corneal sensitivity to all sensory modalities. Age-related ADDE is the most com-

mon form of non-SS dry eye, and its incidence increases around age 50.⁶ With this form, the accumulated changes in the ocular structures and function over time may contribute to the development of dry eye. Research has proposed many mechanisms, including decreased corneal sensitivity to mechanical and chemical stimuli with age and lacrimal gland damage from oxidative stress.⁶ Congenital and acquired etiologies that may contribute to non-SS include congenital alacrima, sarcoidosis, viral infection, radiation injury, Stevens-Johnson syndrome, mucous membrane pemphigoid, topical anesthetic use, refractive surgery, contact lens wear, neurotrophic keratitis and diabetes mellitus, to name a few.⁶

EDE. Tear hyperosmolarity is an integral component of DED, and some consider all forms of DED to



Ocular surface staining, as seen here, can help to reveal dry eye.

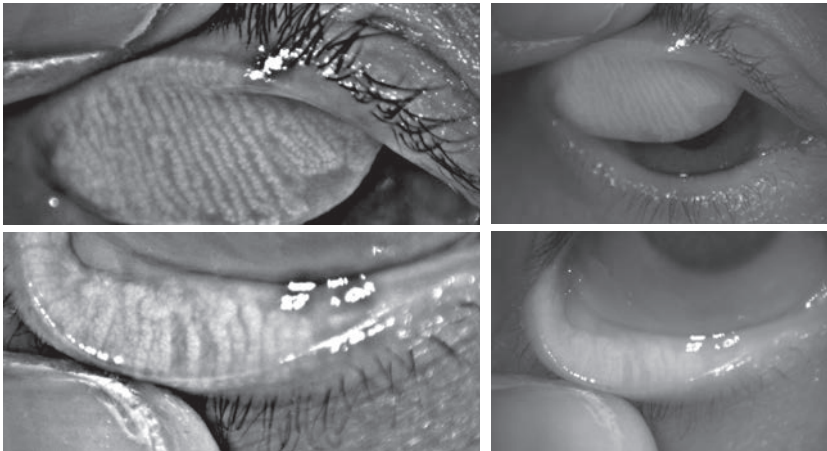
be evaporative, since tear hyperosmolarity cannot occur without evaporation.^{6,7} EDE, then, is a hyper-evaporative state resulting from the

Circling the Target

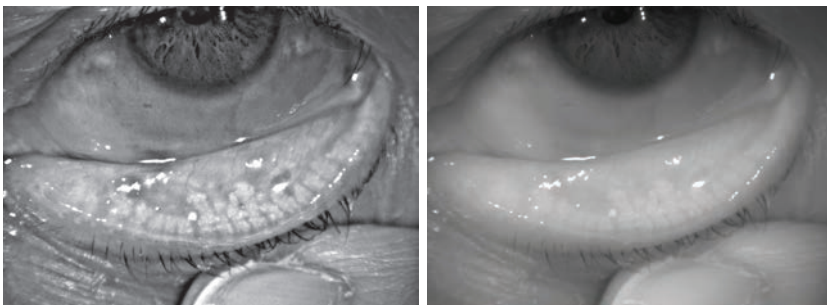
The DEWS II concept of the vicious circle of dry eye is that of a self-perpetuated, cyclical system with multiple entry points, including tear hyperosmolarity, tear film instability, apoptosis and inflammation—all of which are related to each other. Tear film instability caused by a rapid tear break up leads to surface drying and hyperosmolarity of the epithelium.⁸ Tear hyperosmolarity stimulates a cascade of signaling events within the ocular surface epithelial cells that generates the release of inflammatory mediators, such as inflammatory cytokines and proteases. These agents recruit inflammatory cells to the surface, exponentially increasing inflammatory mediators. This leads to decreased expression of glycocalyx mucins and to the apoptotic and non-apoptotic death of epithelial cells and the loss of goblet cells. The chain of events leads to ocular surface damage and destroys the ocular surface's defense system. This heightens the ocular surface hyperosmolarity, continuing the vicious circle.⁶

Extrinsic factors such as ocular surface inflammation from allergic eye disease, topical preservative toxicity, topical anesthesia, corneal surgery, contact lens wear, systemic medications such as antihistamines and beta-blockers and environmental elements such as low humidity, high airflow and high temperature can also disrupt reflex tear secretion or increase tear film instability and initiate entry into the vicious circle.^{6,8} Understanding this vicious circle is crucial for selecting appropriate treatment and therapies to disrupt it.⁸ Of course, once initiated, the vicious circle may continue despite the reduction or elimination of the initial cause, and treatment may need to target multiple mechanisms at play.

Patients within the vicious circle of DED suffer from both visual and ocular discomfort arising from tear film instability, tear hyperosmolarity, inflammatory mediators, hypersensitivity of corneal nerves due to the loss of the epithelial barrier and friction between the globe and lids. A loss of lubrication due to reduced tear volume, loss of goblet cell mucin, degradation of glycocalyx mucin and loss of lubricin may cause damage to orbital structures, as is seen in lid-parallel conjunctival folds, lid wiper epitheliopathy and superior limbic keratoconjunctivitis.⁶



Above, infrared images of the upper and lower eyelids with non-invasive meibography shows healthy, long meibomian glands. In comparison, the patient below has MGD. The glands are greatly shortened compared to those above, and the areas devoid of glands indicate dropout.



loss of an evaporative barrier function of the tears or reduced surface wettability.⁶ Like ADDE, EDE is subdivided into two categories: lid-related and ocular-surface related. The most common cause of EDE is MGD, specifically obstructive MGD.^{7,8} This causes low meibum delivery and is either caused by a displacement of the terminal ducts or secondary to a hyperkeratinization process to the terminal ducts.

Meibomian glands are large sebaceous glands vertically located in the tarsal plate and open onto the eyelid margin just anterior to the mucocutaneous junction. In cicatricial MGD, the terminal duct is dragged posteriorly into either the marginal conjunctival or tarsal mucosa.^{6,9,10} In non-cicatricial MGD, terminal ductal keratinization occurs, and slough-

ing of the ductal cells into the lumen forms keratotic plugs.^{6,7} The meibum thickens and becomes cloudy, blocking the ducts and orifices, eventually leading to secondary disuse or pressure atrophy of the glands.⁶ In addition, the tear film's lipid content is reduced secondary to the absence of normal meibum, promoting entry into the vicious circle of DED.⁸

As DED progresses and the ocular surface is exposed to desiccating stress, a compensatory secretory tear response, driven by impulses from corneal cold-modality thermoreceptors, slows disease progression by dampening the rise in tear osmolarity. This is triggered by both tear hyperosmolarity and surface cooling. Not only do these cold modality fibers increase basal tearing, they lead to an increased blink rate,

which refreshes the tear film more often and helps to decrease the tear osmolarity.^{3,6} This compensatory response leads to eye awareness, contributes to discomfort symptoms and may explain why some patients complain of epiphora in MGD-related DED.⁶ In pure ADDE (no signs of EDE such as MGD) and pure EDE (abnormal tear film lipid layer in the presence of normal lacrimal function), the compensatory tear response helps to slow the disease progression.⁵

However, as the disease worsens, it may also include a progressive loss of corneal sensitivity and the corresponding compensatory response, further increasing disease severity. In worsening ADDE, the rate of the tear film lipid layer spreading diminishes progressively and is amplified when the compensatory reflex tearing is reduced. One study suggests this reduced tear film lipid layer spreading is likely accompanied by an increase in evaporative loss, converting the ADDE into mixed dry eye. In EDE, corneal damage and a loss of reflex sensory drive to the lacrimal gland will result in further tear hyperosmolarity and evolve the pure EDE to a mixed dry eye.⁵

Tools of the Trade

A battery of diagnostic tests can help confirm DED and whether ADDE or EDE is the predominant cause of a patient's mixed dry eye.

The TFOS DEWS II DED management algorithm starts with triaging questions to help exclude conditions that may mimic DED (such as allergic eye disease) and assess risk factors the patient may have such as office environment, contact lens wear, systemic history and medications and topical medications.¹¹ Various questionnaires, such as the Ocular Surface Disease Index and Dry Eye Questionnaire

Technology in balance



Health



Vision




Comfort

Miru 1month: a unique family of silicone hydrogel monthly lenses.

Coming Spring 2018

MeniSilk™ and Nanogloss™ technologies designed to meet the demands of today's contact lens wearer.*



Material and surface technologies

MeniSilk™

- Ultra high Dk/t - 161 @ -3.00D
- Exceptional hydration
- Optimized transparency

Nanogloss™

- Super smooth surface
- Resistance to bacteria
- Excellent wettability



www.meniconamerica.com

*Menicon data on file April 2016



are useful for gauging the patient's visual symptoms and DED's impact on their quality of life. These validated questionnaires also provide a means to monitor patients' treatment progress.¹¹

TFOU DEWS II recommends diagnostic tests that assess homeostasis markers, tear break-up time (TBUT), osmolarity and ocular surface staining (>5 corneal spots, >9 conjunctival spots, or ≥ 2 mm and $\geq 25\%$ width lid margin). TBUT is commonly performed with fluorescein, although non-invasive TBUT has become increasingly popular since fluorescein may reduce tear film stability.

When measuring osmolarity with a TearLab osmometer or OcuSoft i-Pen, ≥ 308 mOsm/L in one eye or an inter-ocular difference >8 mOsm/L is considered a positive result.

Clinicians should also assess for ocular surface staining with fluorescein, lissamine green or both. Corneal staining appears in the later stages of DED, and the combination of fluorescein and lissamine green staining is recommended as the diagnostic technique to evaluate for ocular surface damage.¹¹

The diagnosis of DED is made when the patient is symptomatic and has one positive homeostasis marker. However, signs alone warrant management to prevent the manifestation of DED.

To determine if it is predominantly EDE or ADDE, clinicians should evaluate the tear volume, lipid thickness and dynamics and posterior lid. For tear volume measurement, one can assess the tear meniscus at the slit lamp or with meniscometry or tests such as phenol red thread test and Schirmer test. The Schirmer test without anesthetic is recommended for confirmed severe ADDE.

Meibography allows observation of the silhouette of the meibomian glands and clinicians can observe

Table 1. Dry Eye Diagnostic Testing¹¹

Tear film stability	Tear break-up time <ul style="list-style-type: none"> • Non-invasive: observation of specular reflection of illuminated grid pattern from tear film (e.g., interferometry, placido disc reflection) • Invasive: fluorescein
Tear volume/production	<ul style="list-style-type: none"> • Meniscometry (tear meniscus assessment): slit lamp assessment, spectral-domain OCT • Phenol red thread test • Schirmer test
Tear film osmolarity	<ul style="list-style-type: none"> • Portable <i>in situ</i> osmometer
Ocular surface	<ul style="list-style-type: none"> • Staining: fluorescein, rose bengal, lissamine green; recommend using fluorescein and lissamine green • Visual assessment <ul style="list-style-type: none"> • Lid-parallel conjunctival folds • Conjunctival redness
Posterior eyelid	<ul style="list-style-type: none"> • Lid wiper staining (for lid wiper epitheliopathy) • Meibography • Meibomian gland assessment: quantity, quality and expressibility
Anatomical abnormalities	<ul style="list-style-type: none"> • Blink/lid closure: complete vs. incomplete blinks and closure • Ectropion eyelids • Palsies

structural changes such as gland shortening. To evaluate meibomian gland function, the clinician must check the expressibility of the glands with digital pressure and the meibum quantity and quality. Normal eyelids will have clear meibum easily expressed with gentle pressure; in MGD, the meibum loses clarity and is more difficult to express. Lipid thickness can be assessed with interferometry, and clinicians should also determine if the patient's blink is complete. These tests should be performed in the order of least to most invasive, as the testing sequence can affect results (*Table 1*).¹¹

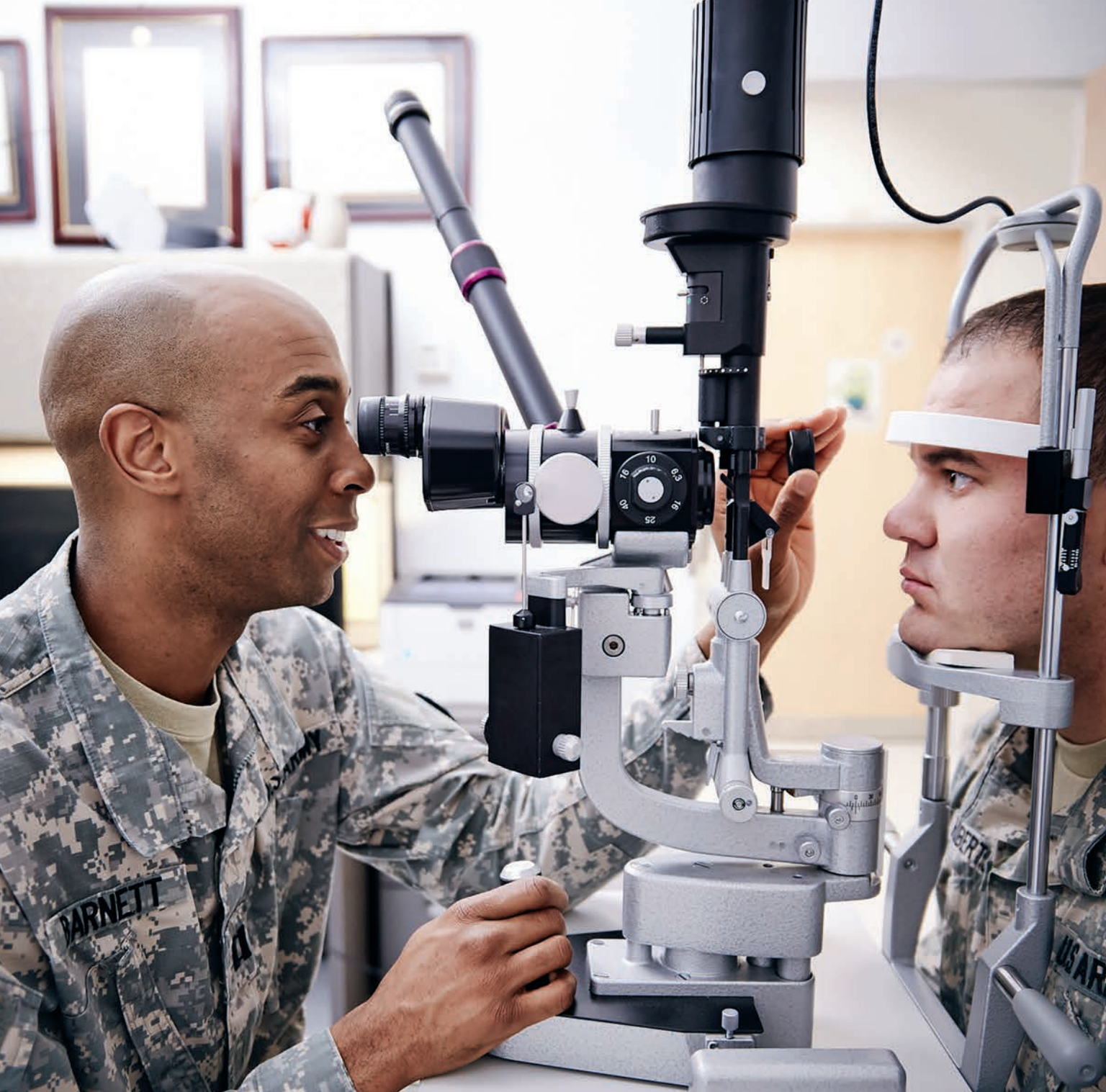Although these tests can help the clinician determine if the DED is primarily caused by aqueous deficiency or evaporation, DED often manifests as a hybrid, and treatment will need to target the primary cause as well as any other etiologies involved.

Therapy Options

The goal of DED management is to break the vicious circle, restore homeostasis of the ocular surface

and prevent a return to the vicious circle—not always an easy task.¹ DED therapy is often complicated and, at times, difficult because of its multifactorial nature and the timeline required for treatment. In addition, each patient's dry eye management regimen will vary depending on the underlying etiologies, disease severity and any contributing extrinsic factors such as environment or medications. Patients may suffer from psychological factors such as depression and stress because of their dryness and are often seeking a "quick fix."¹ A clinician's first job after diagnosing DED and differentiating between ADDE, EDE or mixed dry eye is properly educating the patient on the condition, treatment expectations and timeline.

Typically, management begins with low-risk and commonly available therapies such as over-the-counter lubricants for early stage disease; therapies advance as disease severity increases (*Table 2*).¹ Follow-up is essential to check for improvement in symptoms and signs and to



FOR SOME ELITE SOLDIERS, THIS IS WEAPONS MAINTENANCE.

As an ophthalmologist and officer on the U.S. Army health care team, you will provide world-class optical care for our Soldiers. Working in state-of-the-art facilities you'll have access to the latest treatments and drug therapies as you treat any type of disease, injury or disorder of the eyes. More importantly, you will be helping Soldiers maintain a vital weapon: their vision.

To see the benefits of being an Army medical professional call 800-431-6717 or visit healthcare.goarmy.com/ha86



ensure the patient is compliant. If the patient's signs and symptoms do not improve within three months, clinicians should explore other management options. For patients who are not responding to treatment, a more advanced treatment or consideration of other causes may be necessary.

ADDE. Treatments for this form of DED include tear replacement with ocular lubricants or artificial tears. Typically, artificial tears are recommended for three to four daily applications and may be low-viscosity solutions. As disease severity increases, non-preservative solutions and lubricants that have a higher retention rate such as gels or ointments may be necessary. Punctal occlusion may help with tear con-

servation and should be considered for dry eye secondary to refractive surgery, symptomatic contact lens wear, ADDE secondary to systemic diseases and dry eye with a rapid TBUT. However, it is controversial to use punctal plugs if the patient has an inflammatory component, as it may prolong the presence of pro-inflammatory cytokines on the ocular surface.¹ Moisture chamber goggles and humidifiers may help to slow tear evaporation, especially if the patient lives or works in an adverse environment. For patients with severe ADDE or those not responding to other treatments, consider autologous or allogeneic serums. Oral secretagogues may be considered for ADDE or mixed dry

eye patients with SS in particular.¹

EDE. Treatments for this form or lid abnormalities include lid hygiene with diluted baby shampoo or commercially available lid cleansers and warm compresses with a moist, heated cloth, masks or infrared warm compression devices. If ocular lubricants are warranted, clinicians may want to recommend lubricants containing lipids.

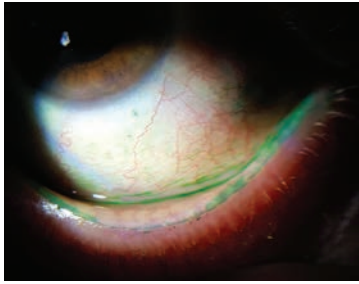
Physical meibomian gland treatments with warm compresses, gland expression or intraductal probing help improve or restore function by removing ductal obstruction. Intraductal probing should be reserved for MGD patients unresponsive to conventional treatment because it is invasive and comes with a risk of damage to the ductal system.

A short course of topical antibiotics such as ofloxacin may help reduce the bacterial load on the lid margin (typically in patients with DED associated with blepharitis).¹ Doxycycline and minocycline are used for their anti-inflammatory and lipid-regulating roles and may be dosed at 50mg to 100mg once or twice a day for a short duration or low dose (20mg) on a long-term basis. Another antibiotic, azithromycin, is a good option for patients with MGD and rosacea; its anti-inflammatory properties may also help control lid inflammation and lid bacterial flora.

Anti-inflammatory therapies for DED include limited-duration corticosteroids. Long-term use of corticosteroids may be used for severe DED or non-responsive patients, but risks (ocular hypertension, cataracts and opportunistic infections) exist. For these patients, repeated short-term pulse therapy may be a better option. Other commercially available anti-inflammatory products include Restasis (cyclosporine, Allergan) and Xiidra (lifitegrast, Shire).¹

Table 2. DED Management and Treatment Recommendations¹

Step 1
<ul style="list-style-type: none"> • Education regarding condition, including management, dietary modifications, oral essential fatty acid supplementation and prognosis • Modification of local environment • Identification and possible modification/elimination of offending systemic and topical medications • Ocular lubricants (For MGD, consider lipid-containing supplements) • Lid hygiene and warm compresses of various types (e.g., warm compress, face masks)
Step 2
<ul style="list-style-type: none"> • Non-preserved ocular lubricants • Tea tree oil treatment for <i>Demodex</i> (if present) <ul style="list-style-type: none"> • Tear conservation • Punctal occlusion • Moisture chamber spectacles/goggles • Overnight treatments (ointment or moisture chamber devices) • In-office heating and expression of meibomian glands, either manually or with LipiFlow (TearScience) • In-office intense pulse light therapy for MGD • Prescription medications <ul style="list-style-type: none"> • Topical antibiotic or antibiotic/steroid combination applied to lid margins for anterior blepharitis (if present) • Topical corticosteroid (pulsed or short duration) • Topical secretagogues • Restasis (cyclosporine, Allergan) • Xiidra (lifitegrast, Shire) • Oral macrolide or tetracycline antibiotics
Step 3
<ul style="list-style-type: none"> • Oral secretagogues • Autologous/allogenic serum eye drops • Therapeutic contact lens options (soft and rigid scleral)
Step 4
<ul style="list-style-type: none"> • Topical corticosteroid of longer duration • Amniotic membrane grafts • Surgical punctal occlusion • Other surgical approaches (e.g., tarsorrhaphy, salivary gland transplantation)



Lissamine green staining on a patient's conjunctiva and lid margin.

Other treatment options include contact lenses and amniotic membranes. Patients may also benefit from dietary or environmental modifications such as increased water-intake, omega-3 fatty acid

supplementation, altering systemic medications such as beta-blockers, antihistamines and antidepressants, and switching to preservative-free ocular medications. If the patient has chronic symptoms but limited clinical signs and lack of response to treatment, then clinicians may need to consider a non-DED etiology such as neuropathic pain.^{1,11}

As a multifactorial disease that can present with a mixture of aqueous-deficient and evaporative dry eye etiologies, DED requires a treatment that targets the various causes of the dry eye and breaks the vicious circle. DED is progressive and if not treated early, may become severe in nature and cause the patient significant discomfort. Patients who are not responsive to conventional therapies may benefit from a referral to a specialty dry eye clinic that has advanced management options. ■

Dr. Kwak is an Illinois College of Optometry graduate and did her Primary Care residency at Salus University Pennsylvania College of Optometry. After years of practice at an anterior segment practice, she recently joined Salus University as a clinical faculty member.

1. Jones L, Downie LE, Korb D, et al. TFOS DEWS II management and therapy report. *Ocul Surf.* 2017;15(4):580-634.
2. Craig JP, Nichols KK, Akpek EK, et al. TFOS DEWS II definition and classification report. *Ocul Surf.* 2017;15(4):276-83.
3. Craig JP, Nelson JD, Azar DT, et al. TFOS DEWS II report executive summary. *Ocul Surf.* 2017;15(4):802-12.
4. Baudouin C, Aragona P, Messmer EM, et al. Role of hyperosmolarity in the pathogenesis and management of dry eye disease: proceedings of the OCEAN Group meeting. *Ocul Surf.* 2013;11(4):246-58.
5. Bron AJ, Yokoi N, Gaffney E, et al. Predicted phenotypes of dry eye: Proposed consequences of its natural history. *Ocul Surf.* 2009;7(2):78-92.
6. Bron AJ, dePaiva CS, Chauhan SK, et al. TFOS DEWS II pathophysiology report. *Ocul Surf.* 2017;15(4):438-510.
7. Bron AJ, Tiffany JM. The contribution of meibomian disease to dry eye. *Ocul Surf.* 2004;2(2):149-64.
8. Baudouin C, Messmer EM, Aragona P, et al. Revisiting the vicious circle of dry eye disease: a focus on the pathophysiology of meibomian gland dysfunction. *Br J Ophthalmol.* 2016;100:300-6.
9. Nichols KK, Foulks GN, Bron AJ, et al. The international workshop on meibomian gland dysfunction: executive summary. *Invest Ophthalmol Vis Sci.* 2011;52:1922-9.
10. Blackie CA, Korb DR, Knop E, et al. Nonobvious obstructive meibomian gland dysfunction. *Cornea.* 2010;29(12):1333-45.
11. Wolffsohn JS, Arita R, Chalmers R, et al. TFOS DEWS II diagnostic methodology report. *Ocul Surf.* 2017;15:544-79.
12. Caparas VL. Medical management of dry eye. In: Chan C, ed. *Dry Eye: A Practical Approach.* Springer; 2015.



Lacrimedics' VisiPlug is not like "other" punctum plugs. We have *no* reported "pop-outs" since VisiPlug's introduction in 2003... and it's distributed in over forty countries!

FDA approved for the treatment of the Dry Eye components of varying Ocular Surface Diseases (OSD), after surgery to prevent complications due to Dry Eye Disease, and to enhance the efficacy of topical medications.

**VisiPlug® –
a visibly better plug
to treat dry eye!**



Lacrimedics

(800) 367-8327

E-mail: info@lacrimedics.com

www.lacrimedics.com

¹Dramatization. Not a real patient.

©2017 Lacrimedics, Inc.

Managing Dry Eye for the The Long Haul

Specific actions and lifestyle changes can optimize the treatment of this chronic disease and provide lasting relief. **By Chandra Mickles, OD**

When we think of conditions that require long-term management, diabetes, hypertension and glaucoma often come to mind. Like these chronic conditions, dry eye disease (DED) also requires both ongoing management for lasting positive outcomes and an awareness that success lies in the long-term collaboration of the practitioner and patient. Ultimately, successful DED management necessitates a shift in perspective of the doctor and patient from short-term treatment goals that result in temporary relief to a comprehensive chronic care plan for a more permanent resolution. Armed with the right strategies and approaches, clinicians can give their dry eye patients a lifetime of relief.

Know Your Target

The ultimate aim of DED management is to restore the homeostasis of the ocular surface by offering long-term options that prevent the resurgence of symptoms.¹ Achieving this goal goes beyond identifying the root cause of DED, such as aqueous deficiency or meibomian gland dysfunction (MGD), but also involves getting to truly know your patient and the modifiable contributing factors that can lead to life-long wellness. Even with medicinal management, DED symptoms can be exacerbated by lifestyle and environmental factors. When these factors aren't identified and addressed properly,

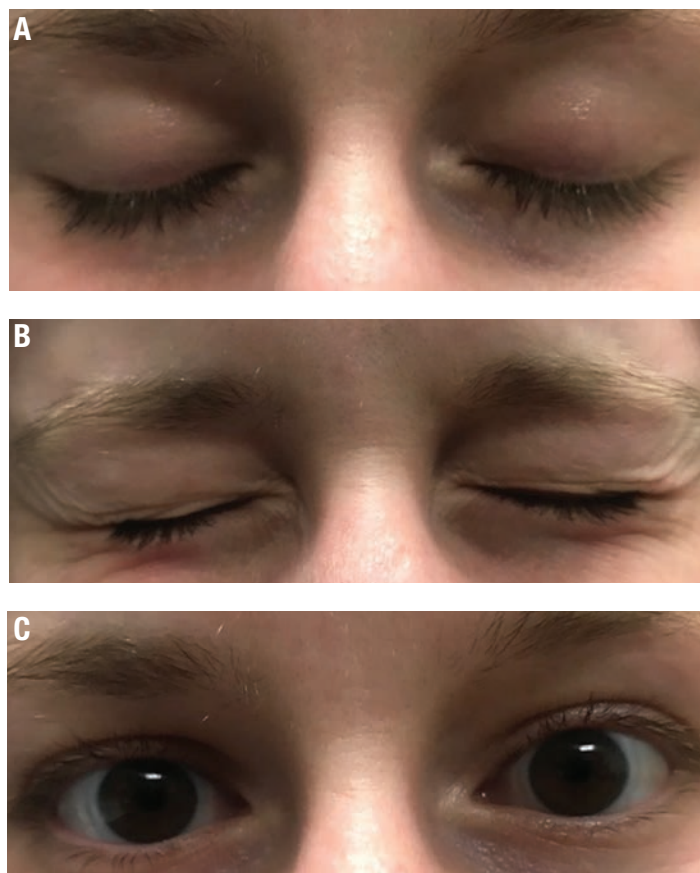

Fig. 1. Blinking exercises will help make proper complete blinking a habit. The blink sequence: (A) Close normally for a count of two and open. Close normally for a count of two again. (B) Squeeze the eyelids together for a count of two. (C) Open to complete the blink sequence.

Simple Lifestyle Changes For Long-term Relief

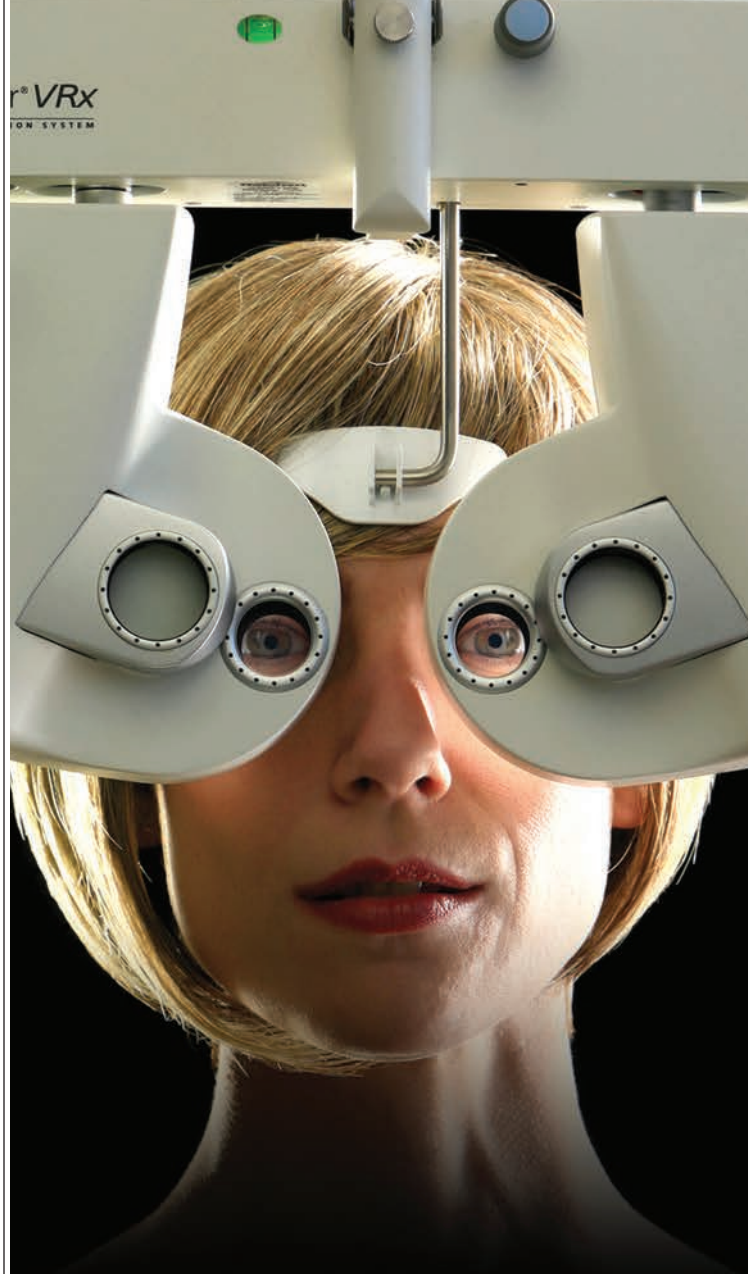Daily activities and environmental factors can contribute to dry eye disease. Here are some lifestyle modifications that can keep dry eye symptoms at bay.

- **Increasing water consumption.** Drinking more water and decreasing caffeine, a diuretic, can help alleviate dry eyes. Sufficient water is vital for overall health, and you should encourage DED patients to drink the recommended eight to 10 glasses of water every day.
- **Avoid blowing air.** Constant air flow is known to dry the eyes. Advise DED patients to not sleep under ceiling fans and to point air vents away from them in the home and car. Wrap-around sunglasses or moisture chamber glasses can benefit DED patients who work in windy environments.
- **Alter the digital work space.** Upgaze position can increase the palpebral fissure size, exposing the ocular surface, consequently destabilize the tear film.¹ A stabilized tear film can result when the palpebral fissure is narrowed in downgaze.¹ Educate patients to set up their work space so that their eyes are positioned slightly downgaze when viewing digital screens. Raising chairs and lowering computer monitors so that the eyes are positioned downgaze should help minimize computer-related dry eye symptoms.
- **Stop smoking.** Tobacco smoke is known to exacerbate dry eye.^{2,3} It causes tear film instability and increases ocular surface staining.² Smokers are nearly twice as likely to have dry eyes.³ Encourage smoking cessation and avoidance of smoke.

1. Pansell T, Porsblad M, Abdi S. The effect of vertical gaze position on ocular tear film stability. *Clin Exp Optom.* 2007;90(3):176-81.
2. Thomas J, Jacob GP, Abraham L, Noushad B. The effect of smoking on the ocular surface and the precorneal tear film. *Australas Med J.* 2012;5(4):221-6.
3. Moss SE, Klein R, Klein BE. Prevalence of and risk factors for dry eye syndrome. *Archives of Ophthalmology.* 2000;118(9):1264-8.

patients can become discouraged by the belief that the treatment isn't working. Often, this results in patients discontinuing therapy or departing from the practice. Like an effective weight loss plan, lasting results in DED management often require a permanent lifestyle change.

The Ocular Surface Disease Index (OSDI) questionnaire is an excellent tool that identifies activities and environmental factors that contribute to DED, such as driving, computer use and windy, air-conditioned environments.² When daily activities and environmental factors known to exacerbate dry eye (DE) are identified as targets, patients can be educated on lifestyle modifications that can have a meaningful impact on DED symptoms in the long-term. Visually demanding tasks, such as digital device use and driving, reduce the blink rate and increase the rate of incomplete blinks, leading to tear film instability.^{3,4} Proper blinking habits that support a stable tear film can be achieved through



PASSIONATE ABOUT PATIENT EXPERIENCE?

The most advanced Phoroptor® ever.

Phoroptor® VRx Digital Refraction System

A premium refraction experience. Incredibly fast.
Ultra-quiet. Effortless integration. Made in USA.

Watch the video at reichert.com/vrx

Reichert
TECHNOLOGIES

AMETEK © 2018 AMETEK, Inc. & Reichert, Inc. (03-2018) · Made in USA

Phoroptor is a registered trademark of Reichert, Inc. · www.reichert.com ·

daily blinking exercises (*Figure 1*).⁵ If patients have difficulty incorporating blink exercises into their daily schedule, free computer applications are available such as the Donald Korb Blink Training App (TearScience) and EyeLeo.^{5,6} The applications encourage proper blinking with reminders and proper pacing.^{5,6} As an alternative, patients also can make proper blinking a habit by blinking during activities that they perform frequently such as sending an email. Blinking fully can be an impactful lifestyle change for DE patients, especially during sustained visual tasks.

Other adjustments in daily lifestyle, such as pointing air vents away from the face, make for simple environmental modification that can be easily used by patients long-term if air-conditioned environments are identified as drying for a patient (*see “Simple Lifestyle Changes for Long-term Relief,” page 59*).

An assessment of systemic conditions and medications that contribute to DED is important as well. As long as patients continue to use drying systemic agents or have poor control of systemic conditions such as diabetes or autoimmune disease, they may appear to have a limited response to DED pharmaceutical management. A simple change in medication to one that is less drying or education on the importance of good control of a underlying DED-associated systemic condition can have a lasting impact on keeping DED symptoms to a minimum. However, keep in mind that your patient’s family physician, internist or psychiatrist may have labored to find the right medicine. That’s why it’s necessary to have a comprehensive picture of your patient’s lifestyle. By identifying key targets, doctors can prescribe effective medical therapy and lifestyle changes that help prevent the resurgence of symptoms. Once these targets are identified, a customized plan can be created.

Develop a Customized Chronic Care Plan

Since DED is multifactorial, the clinician and patient should recognize that one treatment will not completely address this chronic condition and that no single treatment plan works for everyone. A customized

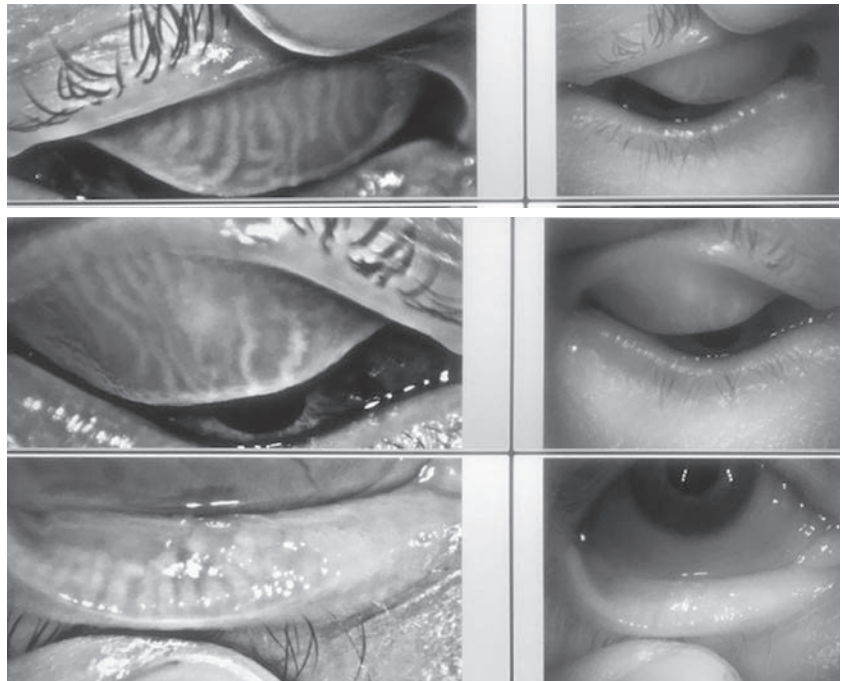


Fig. 2. Advanced imaging, such as meibography, can help foster compliance.

chronic care plan that suits the individual patient will be most effective for long-term positive outcomes.

On a day-to-day basis, the patient is responsible for their own care. Thus, chronic care plan development should involve a regimen that addresses the patient’s unique presentation and can be realistically incorporated into their day-to-day lives. A barrier to effective use of medications includes complex regimens, which often incorporate numerous medications.⁷ The more medications prescribed, the less likely the patient is to comply with the treatment regimen.^{8,9} For lasting success, the management plan should include a targeted approach that includes only a few effective interventions that the patient will reasonably use long-term, rather than a random selection of a multitude of options in which the least effective management options are employed by the patient.

Thus, simplified DED treatment regimens that target the predominant cause of DED—whether it be evaporative dry eye (EDE) or aqueous tear-deficient (ADDE)—are ideal. In ADDE lacrimal function is reduced with normal evaporation.¹ In EDE, we see excessive evaporation in the presence of normal lacrimal function.¹ However, ADDE and EDE are not mutually exclusive categories. As DED progresses, eventually the characteristics of both ADDE and EDE will be present.¹ In such cases, in addition to recom-

mending a treatment that is specifically indicated for the predominant subtype, it is best to recommend a therapy with a target that is central to multiple aspects of the patient's DED presentation. Since inflammation is a commonality in both EDE and ADDE, an anti-inflammatory therapy such as Xiidra (lifitegrast ophthalmic solution 5%, Shire Pharmaceuticals) or Restasis (topical cyclosporine 0.05%, Allergan) can be a complementary option that minimizes the need for numerous interventions.

Tear hyperosmolarity is a hallmark of DED that also occurs in both forms of the disease.¹ While artificial tears are typically viewed as solely palliative, when artificial tears are needed, a hypo-osmolar lubricant, such as TheraTears (Akorn Pharmaceuticals) is a good choice, especially if multiple therapies are a concern either due to cost or adherence.

Unfortunately, long-term management of DED can be complex, and it does not lend itself to one precise algorithm that works for everyone.¹ Nonetheless, DED can be successfully managed for a lifetime with a minimum treatment regimen that produces results. Simplified, customized, chronic care plans that target the cause of DED and are tailored to the patient's lifestyle should maximize patient adherence and optimize patient outcomes.

As Time Goes By

Whether it is contact lens use, diabetes medications or glaucoma eye drops, getting patients to correctly and consistently adhere to treatment recommendations is an obstacle faced by most health care providers. DED therapy is no different. Understandably, as time goes on, DED patients can end up inconsistently or improperly follow treatment plans. Nonetheless, treatment adherence is an essential component of lasting DED management success. Eye care professionals are positioned to partner with patients to implement key compliance strategies that should help DED patients overcome adherence barriers and keep the condition well managed for the long haul.

Long-lasting compliance is likely not going to come from simply telling a patient to follow a treatment plan; rather, you must identify the obstacle that prevent patients from complying. Since the cause of poor adherence can be multifaceted and individual-specific, identifying such barriers is the first step in success. Beginning the discussion by asking what is challenging for them can have a more meaningful impact than recapping a list of tasks they should implement. A simple question such as, "What is preventing you from using the



PASSIONATE ABOUT PATIENT EXPERIENCE?





Pixel-perfect acuity testing.

ClearChart® 4 · 4X · 4P Digital Acuity Systems
Simple-to-use interface. 24-inch, LED backlit display.
Custom developed for acuity testing. Made in USA.

See the full line at reichert.com/clearchart

Reichert
TECHNOLOGIES

AMETEK © 2018 AMETEK, Inc. & Reichert, Inc. (03-2018) · Made in USA

ClearChart is a registered trademark of Reichert, Inc. · www.reichert.com ·    

drops?” will uncover specific barriers to adherence that you can focus on to incite change.

One barrier to adherence might be that the patient doesn't clearly understand the chronic nature of DED and the necessity of taking a specific medication for an extended period of time. We may think that we explained DED and its treatment well, but inevitably there are patients who truly don't understand the condition and consequently discontinue treatment. Explaining the chronic nature of condition and why ongoing therapy is essential in clear and simple language can increase the likelihood of patient adherence. Patients may cease using an important treatment by assuming that the costly medication isn't necessary or expecting it to be effective instantly. I've found that explaining how a particular treatment such as Restasis addresses a central cause of their dry eye symptoms and that continued use is needed to maintain relief goes a long way.

Some patients may not understand the seriousness of their condition and, as a result, do not place importance on the treatment plan. Advanced imaging technology such as meibography can impact the way patients understand the severity of their DED and encourage them to adhere to a treatment regimen. Patients are frequently more interested in how the disease is specifically affecting them than a general academic assessment of the condition. The easy-to-understand reports and imaging (*Figure 2*) allows patients to clearly visualize the effects of DED on their eyes and the importance of proper treatment compliance.

Complex medication dosing regimens are a significant barrier to patient adherence.^{10,11} If complexity is a barrier for the patient, simplify the patient's treatment regimen by minimizing the number of treatment options and streamlining the dosing regimen. Since many DED treatments are BID, prescribing all therapies as BID if possible is convenient and easy for the patient (*Figure 3*). The BID regimen can be easily incorporated into their daily morning and evening hygiene routine.

Other frequently cited reasons for nonadherence are cost and side effects.^{12,13} Clinicians can contribute to noncompliance by not discussing the necessity of the

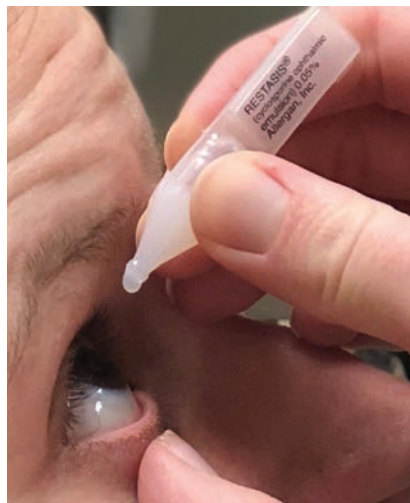

Fig. 3. Most DED pharmaceutical and eyelid hygiene therapies are BID. Streamlining the dosing regimen to BID should improve adherence.

medication. Even if a patient can afford more costly medications, they may not fill the prescription if they don't understand the need for the medication or the impact of not taking it.

Research shows Restasis (Allergan) can lead to fewer office visits, less time off work and decreased use of artificial tears.¹⁴ Using one costly yet effective medication can sometimes benefit the patient by saving time, reducing overall costs and, ultimately positively impacting quality of life. Taking the time to educate patients about the rationale for using a medication as it relates to quality of life can enhance compliance.

While we should never pre-judge patients' ability to pay for medica-

tions, some clinicians may subvert their own efforts by not attempting to tailor the treatment plan to something affordable for the patient. While prescribing the most effective option is optimal, if cost is a concern, sometimes a similarly efficacious but less costly alternative is available. Pharmaceutical assistance programs offered by manufacturers such as Allergan and Shire and charitable organizations such as the Patient Access Network are also available to help uninsured patients with the cost of prescribed medications.¹⁵ Benefits-CheckUp is a user-friendly website that provides links to nearby patient benefit programs.¹⁶

Although dry eye medications can have adverse effects that are frequently non-serious and temporary, patients may discontinue a medication due to lack of awareness of potential side effects. Proactively alerting patients of these and providing strategies to minimize them work well to ensure compliance despite them.

Lotemax (topical loteprenol etabonate 0.5%, Bausch + Lomb) pretreatment is an effective strategy to minimize Restasis-associated stinging and subsequent discontinuation, for example. One study shows significantly less Restasis-associated stinging and discontinuation with loteprednol induction therapy.¹⁷

Anecdotally, punctal occlusion can reduce Xiidra-associated dysgeusia. Anecdotally, my patients have found that chewing gum after instillation of Xiidra may help reduced dysgeusia, but no research has examined this.

Unfortunately, no matter how customized and

cutting-edge a dry eye treatment plan is, it won't work for patients who don't follow it.¹⁸ Thus, clinicians must recognize the importance of patient adherence in long-term DED management success. Patient-centered compliance strategies can ultimately advance the possibility of long-lasting dry eye relief.¹⁷

Face Setbacks Head on

What do you do if there is a resurgence of symptoms or a return of significant ocular surface staining? If there is a recurrence of symptoms or signs, increasing the level of pharmaceutical therapy isn't always the answer. We shouldn't assume that the current medicines and dosages aren't sufficient to control the DED. Contributory DED extrinsic or intrinsic factors can arise at any time and become a culprit. When DED symptoms worsen or return, inquire about recent DED altering life changes such as increases in alcohol or caffeine consumption, changes in work or home environment, new diagnoses and medications that have a drying effect. Nonetheless, it is important for the patient and practitioner to realize that despite best efforts, DED is variant and symptoms will wax and wane.

If your treatment plan isn't working, or results in only mild improvement in symptoms and signs, a formal dry eye assessment, including a detailed case history and a series of evidence based dry eye diagnostic tests, will likely lead to a correct treatment plan. Perhaps the patient may have concomitant disease that mimics dry eye that was overlooked. In this case, the DED component may have been effectively addressed, but symptoms and signs remain as a result of a masquerading condition.¹⁹ When only mild improvement in symptoms and signs occurs, practitioners should look for conditions that manifest with similar symptoms or signs to DED. Clinicians should look out for conditions such as mucin fishing syndrome, conjunctivochalasis, *Demodex*, and asthenopia from binocular vision disorders.¹⁹ There are also situations where there are chronic symptoms but limited signs that are refractory to treatment.¹ When this occurs, neuropathic pain, rather than DED should be considered.¹ Unless these conditions are addressed, the patient will continue to exhibit symptoms and become frustrated irrespective of a proper DED management plan.

When treatment failure occurs, poor compliance frequently comes to mind, yet patients will report that they are following the treatment plan like clockwork. In this scenario, although their intentions are good, patients maybe missing the mark by administering the treatment incorrectly. In a study evaluating eye drop



PASSIONATE ABOUT PATIENT EXPERIENCE?

Elements of pre-test.

OptoChek™ Plus Auto Refractor + Keratometer
LensChek™ Plus & Pro Digital Lensometers

Reichert® combines technology, simplicity,
and value at the core of your exam.

Learn more at reichert.com/exam

Reichert
TECHNOLOGIES

AMETEK © 2018 AMETEK, Inc. & Reichert, Inc. (03-2018)

www.reichert.com · [f](#) [@](#) [t](#) [v](#) [y](#)

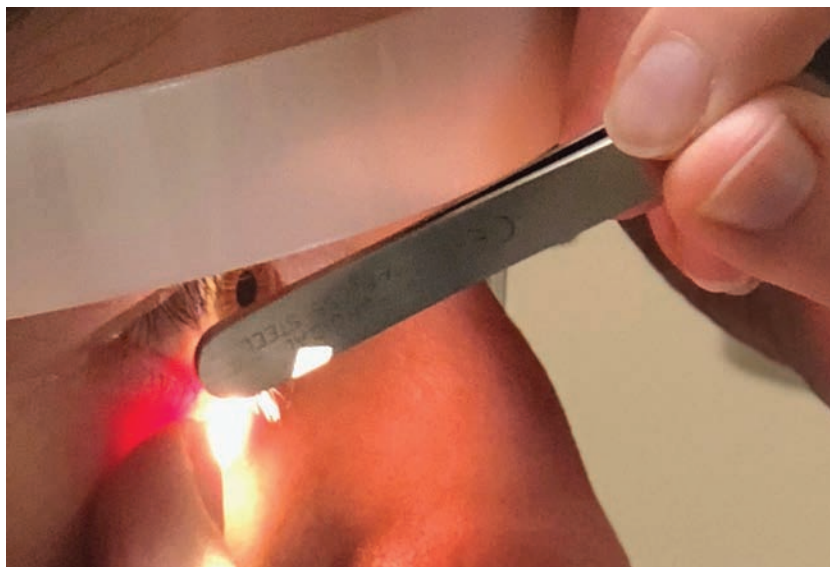

Fig. 4. Lid margin debridement with a blunt golf spud or similar instrument can prevent or delay MGD-associated DED.

instillation technique with a tear substitute, for over a third of the patients, the artificial tear landed on the eyelid or cheek.²⁰ It is easy to take for granted that patients know how to administer eye drops or use lid scrubs correctly. Using the American Medical Association's teach-back method is effective in revealing where patients are going wrong.²¹ In-office and video demonstrations provided by pharmaceutical companies or found online are tremendously useful in subverting treatment failure and getting patients on the right path for treatment success. It is also essential that close follow-up ensues once treatment is initiated to ensure patients are successfully implementing the recommended plan.²²

Nonetheless, poor technique and other extrinsic factors may not be the cause of treatment failure. Sometimes patients are just truly not responding to a given level of management and treatment plans will need to be adapted to replace or include an additional therapy. However, immediate adjustments to treatment plans should be avoided. While therapeutic response varies with the individual and therapy, with the exception of cyclosporine, therapeutic effect for most DED treatment options should occur anywhere from one to six months.²² Beyond this time period, for the majority of DED treatments, improvements are unlikely and modifications to the management plan are recommended.²² Awareness and education on expected onset of treatment effect is important in any DED management strategy.

DED treatment setbacks can be avoided when management objectives and the nature of the disease are clearly defined early and reinforced on a regular basis along the way. However, DED setbacks occur even under the best of patient management circumstances. Additionally, patients must recognize that once DED is controlled, achieving and maintaining an asymptomatic or minimally symptomatic state requires continuing effort and, sometimes, adjustments.

Develop a Maintenance Plan

Fortunately, there is light at the end of the tunnel on the DED journey.

In most cases, eventually a patient's DED will be controlled sufficiently for practitioners to reduce the number and frequency of supportive therapies such as artificial tears. However, a treatment maintenance strategy with follow-up at appropriate intervals and consistent care is essential in sustained relief. As with diabetes, patients should understand that regular maintenance and follow care for DED is important for long-term success. Home maintenance especially for MGD associated DED can be achieved with basic eyelid hygiene practices such as lid scrubs and warm compresses with eye masks. Like regular teeth brushing and face washing, these home eyelid hygiene care practices can be easily incorporated into their daily morning and evening hygiene routine and can help maintain control and possibly preventing MGD-associated DED.

Regular in-office maintenance treatments such as manual lid margin debridement are beneficial for MGD associated DED patients as well (*Figure 4*). Lid margin debridement can effectively remove accumulated debris and skin cells that obstruct the meibomian gland orifices.²³ Similar to dental plaque, the material can re-accumulate over time.²³ Thus treatments such as lid margin debridement should be performed on a regular basis. "Lid cleanings" at regular intervals can become standard practice for these patients as teeth cleaning.

Regular in-office maintenance treatments such as manual lid margin debridement are beneficial for MGD associated DED patients as well (*Figure 4*). Lid margin debridement can effectively remove accumulated debris and skin cells that obstruct the meibomian gland orifices.²³ Similar to dental plaque, the material can re-accumulate over time.²³ Thus treatments such as lid margin debridement should be performed on a regular basis. "Lid cleanings" at regular intervals can become standard practice for these patients as teeth cleaning.

Lipiflow (TearScience) and Mibo Thermoflo (Mibo Medical Group) are also in-office MGD treatments options. Both devices use heat and massage to unblock clogged meibomian glands. While Lipiflow can be efficacious for up to three years and Mibo Thermflo

anecdotally for up nine months, concurrent home maintenance therapies such as warm compresses, lid hygiene and omega-3 supplements is critical for long-term success.²⁴ Patients should recognize that neither of these devices are a cure for MGD and both regular in-office and home maintenance therapies are important. In the future, regular ocular surface maintenance with routine visits for DED patients may become as standard as annual diabetic exams and quarterly visits for glaucoma patients. The long-term efficacy of Lipi-flow and Mibo are yet to be made clear in the academic literature.

Unfortunately, no one-size-fits-all approach can successfully solve dry. However, implementing effective long-term management strategies and elevating DED to the level of other chronic diseases in the mindset of the patient can optimize outcomes for a lifetime. ■

Dr. Mickles is an associate professor and the coordinator of the Dry Eye Care Center at Nova Southeastern University College of Optometry. She is a fellow of the American Academy of Optometry and a principal investigator of dry eye and contact lens research investigations.

1. Craig JP, Nelson JD, Azar DT, et al. TFOS DEWS II Report Executive Summary. *Ocul Sur.* 2017;15(4):802-12.
2. Ngo W, Srinivasan S, Keech A, et al. Self-versus examiner administration of the ocular surface disease index comparison between the self-guided and guided by an examiner administration of the ocular surface disease index test. *J Optom.* 2017;10(1):34-42.
3. Hirota M, Uozota H, Kawamorita T, et al. Effect of incomplete blinking on tear film stability. *Optom Vis Sci.* 2013;90(7):650-7.
4. Gowrisankaran S, Nahar NK, Hayes JR, Sheedy JE. Asthenopia and blink rate under visual and cognitive loads. *Optometry Vis Sci.* 2012;89(1):97-104.
5. Korb Blink Training App. itunes.apple.com/us/app/donald-korb-blink-training/id941412795?mt=8. Accessed April 18, 2018.
6. Eyeleo PC application. [eyeleo.com](https://www.eyeleo.com). Accessed April 18, 2018.
7. Jimmy B, Jose J. Patient medication adherence: Measures in daily practice. *Oman Med J.* 2011;26(3):155-9.
8. Martin LR, Williams SL, Haskard KB, et al. The challenge of patient adherence. *Ther Clin Risk Mang.* 2005;1(3):189-99.
9. Robin AL, Covert D. Does adjunctive glaucoma therapy affect adherence to the initial primary therapy? *Ophthalmology.* 2005;112:863-8.
10. Claxton A, Cramer J, Pierce C. A systematic review of the associations between dose regimens and medication compliance. *Clin Ther.* 2001;23(8):1296-310.
11. Tsai J. A comprehensive perspective on patient adherence to topical glaucoma therapy. *Ophthalmology.* 2009;116:S30-6.
12. Boston Consulting Group. The hidden epidemic: finding a cure for unfilled prescriptions and missed doses. 2003. www.bcg.com/documents/file14265.pdf. Accessed March 14, 2018.
13. Kennedy J, Tuleu I, Mackay K. Unfilled prescriptions of Medicare beneficiaries: prevalence, reasons, and types of medicines prescribed. *J Manag Care Pharm.* 2008;14(6):553-60.
14. Cross W, Lay L, Walt J, Kozma C. Clinical and economic implications of topical cyclosporin A for the treatment of dry eye. *Manag Care Interface.* 2002;15(9):44-9.
15. The Patient Access Network Foundation. 2018. panfoundation.org/index.php/en/about-us. Accessed March 14, 2018.
16. National Council of Aging. BenefitsCheckUP. 2018. www.benefitscheckup.org/about-us. Accessed March 14, 2018.
17. Sheppard J, Scoper SV, Samudre S. Topical loteprednol pretreatment reduces cyclosporine stinging in chronic dry eye disease. *J Ocul Pharmacol Ther.* 2011;27(1):23-7.
18. Osterberg L, Blaschke T. Adherence to medication. *N Engl J Med.* 2005;353(5):487-97.
19. Karpecki PM. Why dry eye trials often fail. *Rev Optom.* 2013;150(1):50-9.
20. Gupta R, Patil B, Shah BM, et al. Evaluating eye drop instillation technique in glaucoma patients. *Arch Ophthalmol.* 2012;21(3):189-92.
21. Tamura-Lis W. Teach-back for quality education and patient safety. *Urologic Nursing.* 2013;33(6):267-71.
22. Jones L, Downie LE, Korb D, et al. TFOS DEWS II Management and Therapy Report. *Ocul Sur.* 2017;15(3):575-628.
23. Korb DR, Blackie CA. Debridement-scaling: a new procedure that increases meibomian gland function and reduces dry eye symptoms. *Cornea.* 2013;32:1554-7.
24. Greiner JV. Long-term (3 Year) effects of a single thermal pulsation system treatment on meibomian gland function and dry eye symptoms. *Eye Cont Lens.* 2016;42(2):99-107.



PASSIONATE ABOUT PATIENT CARE?

His sight depends on your confidence.

Ocular Response Analyzer® G3

Corneal Hysteresis, a more objective predictor of glaucoma progression. CPT code 92145.

Watch the videos at reichert.com/glaucomaconfidence

Reichert
TECHNOLOGIES

AMETEK © 2018 AMETEK, Inc. & Reichert, Inc. (03-2018) · Made in USA

Ocular Response Analyzer is a registered trademark of Reichert, Inc. · www.reichert.com ·

A Win-Win Proposition

*The latest feedback from doctors and patients reveals that **Biofinity® toric** contact lenses are surpassing expectations.*

In all areas of healthcare, patients rely on professionals for their knowledge and guidance. The eye care industry is no different. Patients look to eye care professionals to fit them in the best and healthiest lenses possible. So what do you recommend to astigmatic patients?

It's true these patients add a new layer of complexity to fitting contact lenses. From your perspective, the variables of fitting a toric lens can be challenging. For patients who may be used to their existing contact lenses, being fit in new lenses can be nerve racking. Finding a proven, reliable toric lens that satisfies you and patients can be a game changer for your practice. That's where CooperVision's Biofinity® toric comes into play.

The latest feedback reveals that both doctors and patients are extremely happy with Biofinity® toric contact lenses. Not only do eye care practitioners prescribe Biofinity® toric contact lenses more than any other toric lens in the United States today,¹ but survey findings show that 94% of patients are happy with their overall vision in Biofinity® toric contact lenses.²

A Reliable Fit

Biofinity® toric's design has set a high bar for toric lenses. The contact lenses feature Optimized Toric Lens Geometry™, which provides uniform ISO thickness, an optimized ballast band design, large toric optic zone, and a smooth, continuous surface to ensure the lens is easy-to-fit³ and stable.

The unique design is reducing patient chair time and delivering greater visual acuity, faster lens settling, and excellent rotational recovery, according to doctors who are fitting the lenses.⁴ This is translating into long-lasting comfort and a better visual experience for patients. A recent survey found that 91% of patients said their Biofinity® toric lenses were comfortable throughout the day,² and **80% agreed that their vision remained clear and stable throughout the day.**²


"I chose **Biofinity® toric as my toric lens of choice** because it has the highest success on initial fitting, and my patients love the lens," said Ethan E. Huisman, OD, FAAO, an optometrist at Elite Eye Care in West Des Moines, IA. "Biofinity® toric's design has superior stability, and quickly settles into alignment with minimal rotation. The Biofinity® material is very comfortable and gives patients all-day comfort in a monthly modality that increases patient compliance."



Paul Bernstein,
OD, FAAO, FCOVD



Melanie Frogozo,
OD, FAAO



Casey L. Hogan,
OD, FAAO, FSLs



Ethan E. Huisman,
OD, FAAO

Biofinity® toric is the most prescribed toric contact lens on the market.¹

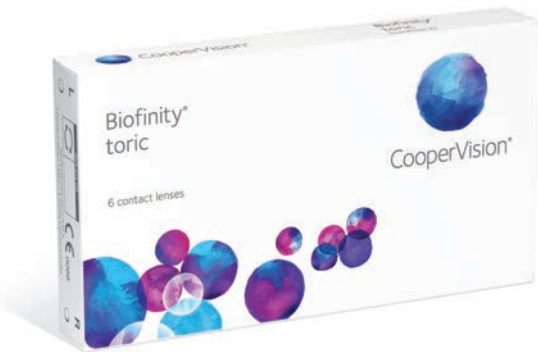Added, Paul Bernstein, OD, FAAO, FCOVD, "Biofinity® toric lenses have proven to be a predictable lens which can be **fit on the majority of my patients.**"

The 'WOW' Factor

It's not surprising that Biofinity® toric is the **most prescribed toric lens on the market**¹ when you hear what your peers and patients are saying about the contact lens. Beyond its extraordinary design, Biofinity® toric's remarkable performance is grabbing the attention of patients.

"My patients report that Biofinity® toric lenses provide the **best vision and all-day comfort**," said Casey L. Hogan, OD, FAAO, FSLs. "But it's the optical quality that is the 'wow factor.' They are often **'wowed'** by the crisp vision as soon as they insert their diagnostic lenses."

With Biofinity® toric and Biofinity® XR toric, there are more than 20,000 SKUs available, which means you have a multitude of options to choose from—increasing the chances of a perfect match when it comes to contact lens



selection. This wide range is driving success for those who try the lens. More than **93% of Biofinity® toric wearers in the U.S. have chosen to stay in the brand,**¹ and upwards of **91%** of wearers of the lens say they are **happy** with it.²

The fact that many patients who try Biofinity® toric contact lenses are remaining loyal to the brand makes the decision to recommend Biofinity® toric a “no-brainer.” You can relax, knowing that the contact lens will meet or exceed your patients’ expectations.

“Biofinity® toric is my **lens of choice** for astigmatic patients,” said Melanie Frogozo, OD, FAAO. “Due to its stability and comfort, my patients are happy with Biofinity® toric. They experience sharp vision and can wear the lenses all day. The wide lens selection combined with the comfort and performance makes Biofinity® toric an easy choice.”

Patient Satisfaction

As an eye care professional, you have a lot riding on your ability to please astigmatic patients. A successful contact lens fitting can create a lifelong patient, but a failure will make it harder to build trust with the patient, and may even mean that the patient goes elsewhere to get their contact lenses.

So, knowing that **87%** of patients surveyed planned to tell their doctor at their next visit that they wanted to **stay in Biofinity® toric contact lenses,**² and that **84%** agreed or strongly agreed that Biofinity® toric lenses were the **best contact lenses they had ever worn,**² you can be confident in fitting your patient in Biofinity® toric lenses.

“The immediate comfort as described by my patients, coupled with superior optics make the lens an easy recommendation,” said Dr. Bernstein. “The high rate of patient acceptance in conjunction with the sophisticated silicone hydrogel material make the Biofinity® toric lens a **healthy toric lens option.** The lens is a **winner for both the patient and the practitioner.**”

Added Dr. Hogan, “With Biofinity® toric, I can be confident that the lens design will offer the best fit possible and excellent optics, which leads to **greater patient satisfaction.**”

The Time is Now

The latest feedback from everyone is clear: Biofinity® toric contact lenses are a win for doctors and patients around the country. By prescribing Biofinity® lenses, you are likely to create satisfied, long-time wearers.

For your 1-day patients, you can still get the same proven design features as Biofinity® toric with MyDay® toric. For more information, visit PrescribeMyDay.com/toric.

Just Listen to Wearers

Patient Satisfaction

91% of patients surveyed **agree** they are **happy** with their overall vision in Biofinity® toric²

90% of patients surveyed **would recommend** Biofinity® toric to family and friends²

84% of patients surveyed agreed or strongly agreed that out of all the contact lenses they've worn, Biofinity® toric lenses are **the best**²

Comfort

More than 91% of patients surveyed said their Biofinity® toric lenses are **comfortable** throughout the day²

73% of patients surveyed said their Biofinity® toric lenses **don't dry out** during the day²

66% of patients surveyed agreed that their eyes feel as **good** at the end of the day as they did at the beginning of the day with Biofinity® toric lenses²

Vision

More than 80% of patients surveyed **agree** that their vision **remains clear and stable** throughout the day with my Biofinity® toric lenses²

Ease of Use

93% of patients surveyed said their Biofinity® toric lenses are **easy** to handle²

Eye Health

89% of patients surveyed **agree** that they believe their Biofinity® toric contact lenses are **healthy** for their eyes²

Visit OnlyBiofinity.com/toric to learn about the unparalleled advantages of fitting your patients in Biofinity® toric contact lenses.

1. US industry data on file.

2. The results of an online survey involving patients who wear Biofinity toric contact lenses. January 2018 Biofinity toric wearer online survey. Data on file.

3. Results based on 144 participating eye care professionals in a multi-national online survey, 2016.

4. Comparison of fitting stability of the different soft toric contact lenses. Contact Lens & Anterior Eye 37 (2014) Hamed Momeni-Moghaddam et al. Optimised Toric Lens Geometry™ compared to available prism ballast, precision balance and accelerated stabilization toric lens designs.




Sjögren's, Dry Eye and You

Ocular symptoms can precede systemic ones by a decade. Here's how you can spot it early and manage its symptoms. **By Suzanne Sherman, OD, and Fiza Shuja, OD**

As optometrists, we see patients with dry eye disease (DED) on a daily basis. Although we now understand how prevalent DED can be, we sometimes forget that a dry eye diagnosis isn't always the end of the story. Eye care providers need to start paying closer attention to underlying systemic conditions such as Sjögren's syndrome (SS) that might exacerbate patients' dry eye signs and symptoms.

SS is the second most common autoimmune rheumatic disease, affecting between three and six per 100,000 Americans.¹ The peak incidence is between the ages of 40 and 60, with a higher predilection in women than men (9 to 1).² As optometrists, it is inevitable some of your DED patients will need extra care because of this underlying condition. Most challenging is the fact that a dry eye diagnosis in patients with SS can precede systemic symptoms and complications by almost 10 years.³ This article reviews the basics of SS, the diagnostic challenges and clinical pointers for dry eye management.



This Sjögren's patient with significant dry eye has diffuse inferior superficial punctate keratitis.

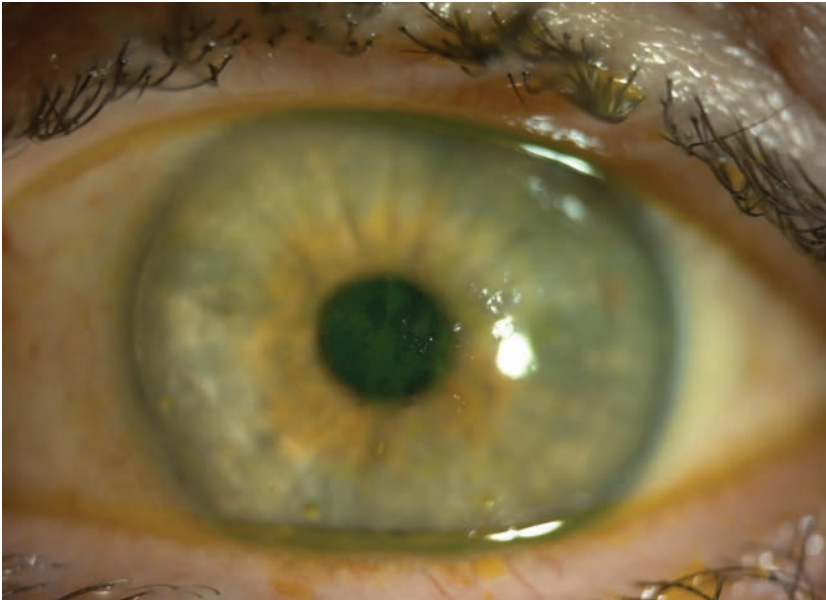
SS Basics

Autoimmune diseases arise from an immune response against endogenous tissues. SS in particular targets the exocrine glands of mucous membranes and is often referred to as an "autoimmune epithelitis."⁴ The autoimmune response in Sjögren's occurs from mononuclear infiltration of the salivary and lacrimal glands, leading to the hallmark complaints of dry mouth and dry eyes. However, many parts of the body can be affected, leading to complaints of joint and muscle pain,

skin rashes, chronic dry cough, vaginal dryness, extremity numbness or tingling and fatigue.^{3,5} These symptoms can occur years after the onset of the ocular and oral symptoms, and almost 60% of patients presenting with primary Sjögren's develop these symptoms eventually.^{3,5}

SS can be divided into two categories: primary and secondary. In primary SS, the individual has no secondary disease causing the SS. With secondary Sjögren's, the disease occurs in conjunction with another autoimmune disease, such as rheumatoid arthritis or systemic erythematous lupus.⁵

As with other autoimmune diseases, SS involves both genetic and environmental factors.⁶ The largest genetic predisposition to SS is the human leukocyte antigen, specifically HLA B-8, HLA DR-w2 in women and HLA DR-w3 in men.² Roughly 10% to 15% of patients with Sjögren's will have systemic extraglandular manifestations due to lymphocytic infiltration surrounding the epithelium of target organs—such as the liver, kidneys and bronchi—and can present



This patient with both SS and lupus has central fluorescein staining. The central coalesced superficial punctate keratitis is causing decreased vision and discomfort.

with the clinical picture of vasculitis, arthralgia or arthritis.⁷ When examining these patients, clinicians should check their skin, as cutaneous involvement is common and can present as xeroderma in 67% of patients, eyelid dermatitis in 40%, annular erythema in 9% and cutaneous vasculitis in 5% to 10% of patients with Sjögren's.²

Additional symptoms of fatigue, depression, myalgia and arthralgia can affect patients' quality of life both before and after an SS diagnosis.^{3,8} Patients with SS also have increased risk of cerebrovascular events, myocardial infarction, arthritis, neuropathies and vasculopathies, Raynaud's phenomenon,

pulmonary fibrosis, renal tubular acidosis and, due to internal organ damage, lymphomas, specifically non-Hodgkin B-cell lymphoma.^{8,9}

Diagnostic Puzzle

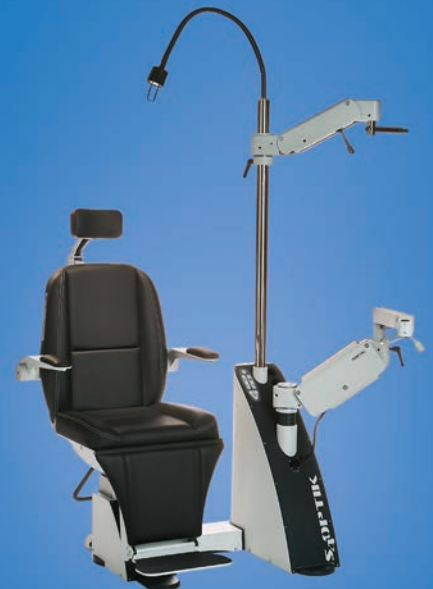SS diagnosis can be difficult because of the associated symptoms and comorbidities.⁸ Experts have sought to create diagnostic guidelines for patient inclusion in clinical and research trials. The American-European Consensus Group (AECG) developed a criteria in 2002 for use in clinical trials with the following parameters: subjective ocular and oral dryness, dry eye testing using Schirmer's test, reduced salivary flow, positive salivary gland biopsy

Table 1. 2012 ACR Proposed Classification Criteria for SS³

The classification of Sjögren's syndrome will be met in patients who have at least two of the following three objective features:

1. Positive serum anti-SS-A/Ro, anti-SS-B/La or positive rheumatoid factor and ANA >1:320
2. Labial salivary gland biopsy exhibiting focal lymphocytic sialadenitis with a focus score >1 focus/4mm²
3. Keratoconjunctivitis sicca with ocular staining score >3 (assuming the individual is not currently using daily eye drops for glaucoma and has not had corneal surgery or cosmetic eyelid surgery in the last five years)

Optimize space and functionality.



Affordable, space-saving chair & stand solutions.

Small footprint
41.2" x 34.2"

Table 2. 2016 ACR/EULAR Primary SS Classification Criteria^{3,5}

Item	Score
Labial salivary gland with focal lymphocytic sialadenitis and focus score >1 foci/4mm ²	3
Anti-SSA/Ro positive	3
Ocular staining score <5 (or van Bijsterveld score <4) in a least one eye	1
Schirmer's test <5mm/5min in at least one eye	1
Unstimulated whole saliva flow rate <0.1mL/min	1

The classification of primary SS applies to any individual who meets the inclusion criteria, does not have any of the exclusion criteria and has a score of greater than or equal to 4.

Inclusion criteria
At least one symptom of ocular or oral dryness, defined as a positive response to at least one of the following questions:

1. Have you had daily, persistent, troublesome dry eyes for more than three months?
2. Do you have a recurrent sensation of sand or gravel in the eyes?
3. Do you use tear substitutes more than three times a day?
4. Have you had a daily feeling of dry mouth for more than three months?
5. Do you frequently drink liquids to aid in swallowing dry food?

Exclusion criteria
Prior diagnosis of:

1. History of head and neck radiation treatment
2. Active hepatitis C infection with confirmation by polymerase chain reaction testing
3. HIV or AIDS
4. Sarcoidosis
5. Amyloidosis
6. Graft-vs.-host disease
7. IgG4-related disease

and positive autoantibodies against SS-A and SS-B, with the last two as mandatory requirements.^{10,11}

The American College of Rheumatology (ACR), in conjunction with the Sjögren's Collaborative Clinical Alliance (SICCA), established a different guideline for clinical

research in 2012. This eliminated the subjective complaints, requiring two out of three objective measurements: (1) biomarker positivity (Ro or La) or positive rheumatoid factor (RF), (2) antinuclear antigen (ANA) or labial salivary gland biopsy findings and (3) keratoconjunctivitis sicca (Table 1).³ Between the AECG and ACR guidelines, the AECG identified more SS patients, but the ACR was able to identify Sjögren's patients earlier.¹⁰

In 2016, the ACR and the European League Against Rheumatism (EULAR) combined both the AECG and ACR guidelines to form a new standard for research practices.¹² The new guidelines also included systemic manifestations and sicca symptoms with a weighted score assigned to each parameter including: positive salivary gland, anti-SSA/Ro-positive, ocular staining, Schirmer's test, salivary flow rate (Table 2).^{3,5} A diagnosis is made

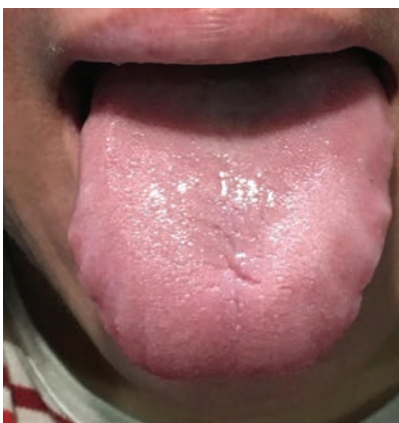
after patients scored four or greater based on the guidelines. The AECG and the ACR/EULAR guidelines showed a good correlation and consensus in diagnosing SS in clinical and research trials, with an increase in early diagnosis with the ACR/EULAR guidelines.¹²

Biopsy of the minor salivary glands remains the most specific test to diagnose Sjögren's syndrome and is a necessary component for the AECG and ACR guidelines.³ Though invasive, a biopsy is specific for SS; however, damage may have already occurred in the glandular systems.³ It is important that the salivary gland biopsy be performed by a trained professional and be reviewed by an experienced pathologist.³ Two noninvasive procedures, salivary gland ultrasonography and acoustic radiation force impulse of the parotid and submandibular glands, can also aid in identifying anatomical and functional damage in patients diagnosed with SS.^{3,13}

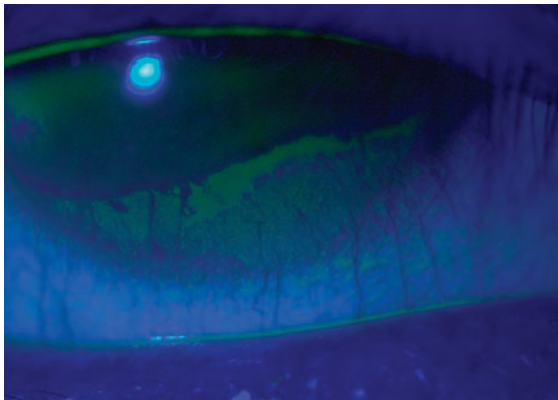
SS in Your Office

DED is one of the hallmark signs of SS, which requires optometrists to be an integral part of identifying and managing the disease. Since ocular symptoms can precede the systemic effects of SS, diagnosing DED can often be the first step in identifying SS in a patient. Clinicians should suspect SS when patients present with difficult dry eye, inflammation and dry mouth.¹⁴ Aqueous DED (ADDE) is commonly associated with SS because T-cells attack the lacrimal glands, resulting in cell death and tear hyposecretion.¹⁴ SS patients also have a poor mean meiboscore and meibomian gland expressability compared with non-SS dry eye patients, indicating a correlation between SS and evaporative DED (EDE).⁹

In the clinical setting, ODs know



It is important to examine skin and cutaneous involvement. A patient may have a sore, cracked tongue that can be suggestive of Sjögren's.



Before being diagnosed with SS, this gas permeable contact lens wearer presented complaining of severe dry eye, dry mouth and vaginal dryness. This image shows her severe dry eye and superficial punctate keratitis along the entire lower half of her cornea. She experienced some relief with Xiidra and punctal plugs.

dry eye can adversely affect patients' quality of life. Those with SS report functional disability comparable with patients affected by lupus.⁸ Surveys and questionnaires can help clinicians form a subjective understanding of patients' dry eye symptoms to help tailor treatment appropriately. The Ocular Surface Disease Index (OSDI) correlates the symptoms of DED with its effect on visual function and can be incorporated into clinical practice to successfully grade the degree of DED from normal, mild to moderate and severe.^{15,16} The McMonnies questionnaire, the Standard Patient Evaluation of Eye Dryness questionnaire, the Symptom Assessment in Dry Eye survey and the Impact of Dry Eye on Everyday Life survey are a few other questionnaires that are also used for clinical and research trials.¹⁷ Though questionnaires can provide valuable information, they are not enough to confirm a diagnosis of DED or SS.¹⁸


Using the OSDI, clinicians can connect patient responses with clinical findings. Patients often complain of burning, stinging, foreign body

sensation, itching, pain and blurred vision with some improvement upon blinking. Tear film irregularities show a decreased tear meniscus; instead of the normal 1mm, dry eye patients will have a reduced tear strip.¹⁸ Thus, ocular dyes and tear secretion tests, such as Schirmer's test, can help diagnose DED. The tear film and conjunctiva are best evaluated through the use of fluorescein, rose Bengal and lissamine green vital dyes.


With fluorescein, the tear film is assessed for dark spots, which indicate the tear break-up time (TBUT). Normal TBUT is greater than 10 seconds, and anything less than 10 seconds is indicative of DED.^{14,17} Schirmer's test measures total tear secretion rate, therefore differentiating between ADDE and EDE, as ADDE occurs due to lacrimal gland dysfunction.¹⁶ Schirmer's test without topical anesthetic quantifies reflex tear secretion, while testing with topical anesthetic quantifies basal tears. A patient tests positive for DED with measurements of <5mm to 7mm for reflex tear secretion and <3mm for basal secretion.^{14,17}

The Sjö test (Bausch + Lomb) is a billable laboratory or in-office blood test for biomarkers specific for SS, including the traditional SS biomarkers anti-SS-A/R0, anti-SS-B/La, ANA, and RF, as well as new biomarkers such as salivary gland protein-1, parotid secretory protein and carbonic anhydrase VI.^{3,14} If results return positive for SS, refer the patient to a rheumatologist for further management and testing.

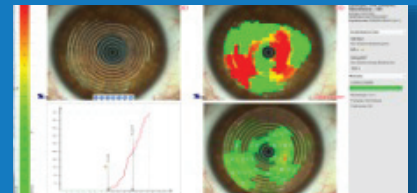
S4OPTIK ANTARES



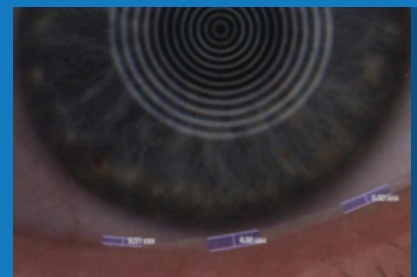
Corneal Topography & More!



Meibomian Gland Imaging & Analysis



Non-Invasive Tear Film Break-up Analysis



Tear Meniscus Height

S4OPTIK

250 Cooper Ave., Suite 100 Tonawanda NY 14150

www.s4optik.com | 888-224-6012

Sensible equipment. Well made, well priced

For today's modern office.

The addition of the new biomarkers allows for better sensitivity and specificity because of their possible early detection of SS.³ Case reports show patients who had an early diagnosis of SS tested positive for the new biomarkers after they had already tested negative for the traditional biomarkers.³

Treatment

With no cure for SS, the therapeutic goals are aimed toward eliminating the hallmark complaints of dry eye and dry mouth. Clinicians should target treatment based on the severity of the disease. Mild dry eye can be alleviated with simple changes, such as modifying the environment (e.g., reducing time spent in dry or windy environments). Other methods include eyelid hygiene and following a diet high in omega-3 fatty acids.¹⁷

As DED progresses beyond what these simple changes can manage, artificial tears become the first line of therapy. The ingredients in artificial tears, mainly a polymeric base or a viscosity agent, are designed to increase the amount of time the tears are on the ocular surface, thereby increasing the tear meniscus.¹⁷ Different classes of artificial tears have different formulations, and some may work better with certain patients. For example, some

contain potassium and bicarbonate ions while others are designed to configure the lipid portion of the tear film.¹⁷ Although no studies prove any particular artificial tear is superior, specific ingredients to watch out for include preservatives such as benzalkonium chloride and EDTA, which can be toxic and worsen dry eye. Gel tears and ophthalmic ointments are thicker and last longer on the ocular surface, but can cause temporary blurred vision. Ointments are best reserved for nighttime use and can help to relieve dry eye symptoms during sleep.

The Tear Film and Ocular Surface Society's Dry Eye Workshop II report includes "inflammation of the ocular surface" in its definition of DED, and studies show the presence of inflammatory cells, such as lymphocytes in the ocular surface.¹⁴ Anti-inflammatory drops help control the inflammatory response in keratoconjunctivitis sicca, especially in patients with moderate to severe dry eye that present with SS. Although cases show subjective and objective improvement in dry eye symptoms and signs with corticosteroids, the possible side effects of elevated intraocular pressure and posterior subcapsular cataracts deter long-term use.

Restasis (cyclosporine, Allergan) is FDA-approved to treat moder-

ate to severe DED, and studies show significant improvement in corneal signs, such as fluorescein staining and increased tear production, after using cyclosporine 0.05%;

as many as 59% of patients had increased tear production.¹⁷ Burning is one of the side effects of cyclosporine use, which can be alleviated by a low-dose steroid during the first two weeks of use.¹⁷ Studies have yet to show any contraindication in using cyclosporine for an extended period; after three years, patients did not report any adverse effects.¹⁷ Xiidra (lifitegrast, Shire), also FDA-approved for treatment of DED, inhibits inflammatory cells and affects the T-cell mediated immune response, thereby decreasing inflammation.¹⁴ Early trials show improvement in corneal staining and subjective complaints in dry eye symptoms; however, since it is a newer medication, long-term studies are pending.¹⁴ Possible side effects include ocular burning and dysgeusia, or a change in taste sensation.¹⁹ Punctal plugs remain a popular option for treating DED. Their purpose is to retain natural and artificial tears on the eye for a longer period. Studies show improvement in clinical signs and subjective improvement, such as through the OSDI questionnaire, after punctal occlusion. It is important to understand with punctal occlusion there will be an increase in pro-inflammatory cells on the ocular surface.²⁰ Other, less common therapies include secretagogues and autologous serum. In the case of secretagogues for SS, oral pilocarpine and cevimeline cause tear secretion from the lacrimal gland and saliva from the salivary glands. Salagen (MGI Pharma) and Evoxac (Daiichi Sankyo) are secretagogues approved for treatment of dry mouth, but not specifically for dry eye; however, off-label use shows improvement in dry eye symptoms and clinical signs.¹⁷ Autologous serum can be used for severe dry eye patients who have exhausted all other treatments

SJOGRENS ANTIBODY SS-B (LA)			Order: 225210107
Status: Edited Result - FINAL Visible to patient: Yes (MyChart) Next appt: 02/02/2018 at 10:20 AM in Rheumatology (Stephen Smiles, MD) Dx: Eosinophilia; Dermatitis due to sun; ...			
SJOGREN'S ANTIBODY ANTI-SS-B	Ref Range & Units 0.0 - 0.9 AI	8d ago <0.2	
Resulting Agency	01		
Specimen Collected: 01/23/18 13:43	Last Resulted: 01/25/18 17:12		
SJOGRENS ANTIBODY SS-A (RO)			Order: 225210108
Status: Edited Result - FINAL Visible to patient: Yes (MyChart) Next appt: 02/02/2018 at 10:20 AM in Rheumatology (Stephen Smiles, MD) Dx: Eosinophilia; Dermatitis due to sun; ...			
SJOGREN'S ANTIBODY ANTI-SS-A	Ref Range & Units 0.0 - 0.9 AI	8d ago >8.0 ▲	
Resulting Agency	01		

These lab results for a patient sent for Sjögren's bloodwork are positive for SS-B and SS-A antibodies.

without improvement. The patient's own blood is used to create the serum because the shared biochemistry between the serum and natural tears improves efficacy.¹⁷ The serum has a host of components that aid in improving the ocular surface, including fibronectin, vitamin A, cytokines, growth factors and anti-inflammatory factors.¹⁷ Research shows symptoms and corneal signs improve after using autologous serum, although careful handling is important to prevent infections due to contamination.¹⁷

To properly manage and treat DED associated with SS, clinicians must understand the systemic disease as a whole. SS should be a priority in our differentials for patients with DED. By looking at all reliable symptoms, including any secondary autoimmune disease and specific complaints of a dry, cracked tongue, clinicians can help to diagnose SS sooner and initiate treatment in a timely manner. Because SS is also associated with comorbidities such as depression and fatigue, an early diagnosis and subsequent treatment will allow patients an improved quality of life.

Prompt referral to and comanagement with rheumatology will help provide the appropriate care for the patient. Autoimmune diseases such as rheumatoid arthritis and systemic erythematous lupus that occur concurrently with SS will need to be managed by rheumatology as well. Anti-rheumatic drugs used for these autoimmune diseases have also shown beneficial for those diagnosed with SS.⁸

Treating and managing these patients may seem systematic, with lifestyle modifications and artificial tears as initial starters; however, each patient will respond differently to treatment. Therapy must be modified as signs or symptoms change,

but relieving subjective and objective complaints will remain imperative to improving quality of life. ■

Dr. Sherman is an instructor in Optometric Science (in Ophthalmology) at Columbia University Medical Center, NY. She specializes in complex and medically necessary contact lens fittings and ocular disease.

Dr. Shuja is an optometrist at New York-Presbyterian Hospital.

1. Jonsson R, Vogelsang P, Volchenkov R, et al. The complexity of Sjögren's syndrome: Novel aspects on pathogenesis. *Immunology Letters*. 2011;141(1):1-9.
2. Generali E, Costanzo A, Mainetti C, et al. Cutaneous and mucosal manifestations of Sjögren's syndrome. *Clinic Rev Allerg Immunol*. 2017;53(3):350-7.
3. Beckman KA, Luchs J, Milner MS, Ambrus JL. The potential role for early biomarker testing as part of a modern, multidisciplinary approach to Sjögren's syndrome diagnosis. *Advances in Therapy*. 2017;34(4):799-812.
4. Skopouli FN, Moutsopoulos HM. Autoimmune epitheliitis: Sjögren's syndrome. *Clin Exp Rheumatol*. 1994;12(Suppl 11):S9-11.
5. Del Papa N, Vitali C. Management of primary Sjögren's syndrome: recent developments and new classification criteria. *Thera Adv Musculoskeletal Dis*. 2018;10(2):39-54.
6. Chaigne B, Lasfargues G, Marie I, et al. Primary Sjögren's syndrome and occupational risk factors: a case-control study. *J Autoimmun*. 2015;60:80-5.
7. Oxholm P, Asmussen K. Primary Sjögren's syndrome: the challenge for classification of disease manifestations. *J Intern Med*. 1996;239(6):467-74.
8. Vivino FB, Carsons SE, Foulks G, et al. New treatment guidelines for Sjögren's disease. *Rheum Dis Clin North Am*. 2016;42(3):531-51.
9. Kang YS, Lee HS, Li Y, et al. Manifestations of meibomian gland dysfunction in patients with Sjögren's syndrome, non-Sjögren's dry eye and non-dry eye controls. *Int Ophthalmol*. 2017 May 31:1-7. [Epub ahead of print].
10. Both T, Dalm VA, Van Hagen PM, Van Deelee PL. Reviewing primary Sjögren's syndrome: Beyond the dryness - From pathophysiology to diagnosis and treatment. *Internat J Medical Sci*. 2017;14(3):191-200.
11. Corneec D, Saraux A, Cochener B, et al. Level of agreement between 2002 American-European Consensus Group and 2012 American College of Rheumatology classification criteria for Sjögren's syndrome and reasons for discrepancies. *Arthritis Research and Therapy*. 2014;16(2):R74.
12. Franceschini F, Andreoli L, Tincani A. The 2016 classification criteria for primary Sjögren's syndrome: What's new? *BMC Medicine*. 2017;15(1):69.
13. Baldini C, Luciano N, Tarantini G, et al. Salivary gland ultrasonography: A highly specific tool for the early diagnosis of primary Sjögren's syndrome. *Arthritis Res Thera*. 2015;17(1):146.
14. Kuklinski E, Asbell PA. Sjögren's syndrome from the perspective of ophthalmology. *Clin Immunol*. 2017;182:55-61.
15. Schiffman RM, Christianson MD, Jacobsen G, et al. Reliability and validity of the Ocular Surface Disease Index. *Arch Ophthalmol*. 2000;118(5):615-21.
16. Ocular Surface Disease Index. www.dryeyezone.com/documents/osdi.pdf. Accessed March 17, 2018.
17. Foulks GN, Forstot SL, Donshik PC, et al. Clinical guidelines for management of dry eye associated with Sjögren disease. *The Ocular Surface*. 2015;13(2):118-32.
18. Beckman KA, Luchs J, Milner MS. Making the diagnosis of Sjögren's syndrome in patients with dry eye. *Clin Ophthalmol*. 2015;10:43-53.
19. US Food and Drug Administration. FDA approves new medication for dry eye disease. www.fda.gov/NewsEvents/Newsroom/PressAnnouncements/ucm510720.htm. Accessed April 10, 2018.
20. Shih KC, Lun CN, Jhanji V, et al. Systematic review of randomized controlled trials in the treatment of dry eye disease in Sjögren syndrome. *J Inflammation*. 2017;14(26).


S4OPTIK

LCD Visual Acuity System VA-1



Comprehensive Visual Acuity Solution

- Multiple optotype selections
- All acuity slides presented with ETDRS Spacing
- Contrast sensitivity testing
- Crowding bars (for pediatrics)
- Multimedia system and more!



S4OPTIK

250 Cooper Ave., Suite 100 Tonawanda NY 14150

www.s4optik.com | 888-224-6012

Sensible equipment. Well made, well priced.

For today's modern office.

Using Premium Technology to Deliver Premium Results

A guide to helping patients achieve the outcomes they expect from presbyopia-correcting intraocular lenses.



By Sondra Black, OD

Today's presbyopic patients lead active lifestyles and expect their vision to meet the demands of their hectic lives. Seventy-two percent of Baby Boomers plan to work after retirement, 83% spend more time on their computers than watching television, and 72% have cell phones, checking their phones 46 times a day on average.¹⁻⁴

All these factors come into play when patients complain that they can no longer read up close. Presbyopic patients expect far more refractive flexibility than a pair of reading glasses can deliver, wanting sharp distance, intermediate, and near vision.

UNDERSTANDING LENS CHANGES

A new term has been introduced to describe lens changes as we age—dysfunctional lens syndrome (DLS). With this term, clinicians can grade lens changes that occur and explain them to patients. The stages are shown in Figure 1 (see adjacent page).

We need to explain to all patients that presbyopia will occur and progressive lens changes eventually will affect their vision, eventually leading to cataracts. This is especially important if patients older than 40 are considering refractive surgery. A colleague tells his patients, "If you can touch it, you won't be able to see it." This is a good reminder of what patients can expect, so they do not think their LASIK "wore off" as they hit their mid-40s.

Dysfunctional Lens Syndrome (DLS)

Stage 1 (mid-40s – early 50s)

- Lens stiffens and cannot change shape as easily
- Loss of accommodation

Stage 2 (50s – 60s)

- Increasing lens haze
- Yellow discoloration
- Scatter of light
- Decreased quality of vision

Stage 3 (60s – 80s)

- Cataract: a clouding of the lens of the eye that obstructs the passage of light

Figure 1. Stages of dysfunctional lens syndrome.

We should reassure them that we will monitor their lens changes and recommend appropriate surgical options when the time is right.

GROWING LIST OF OPTIONS

When patients say they want to be able to read up close, they actually wish for a natural range of good quality vision. Regardless of how we correct presbyopia, however, there will be compromises.

Patients in Stage 1 may prefer to use reading glasses or multifocal contact lenses. For those who want to reduce their dependence on glasses, we can

discuss corneal inlays or LASIK or PRK monovision. High hyperopes may be better suited to a refractive lens exchange.

In Stage 2, corneal inlays are no longer an option because they magnify lens aberrations occurring at this stage. We need to tell patients contemplating LASIK or PRK at this stage that we do not know how long this correction will last and steer them to an intraocular procedure.

By the time the patient reaches Stage 3, with a cataract, the only options are distance-only, monovision, or presbyopia-correcting intraocular lenses (IOLs).

Previous IOL choices included monofocal IOLs, which corrected distance only; multifocal IOLs, which provided a 33-cm working distance, with night glare and halos; and accommodating IOLs, which did not work for everyone. Patients did not have good intermediate vision, which is very important for many tasks.

Advances in IOL technology brought a variety of presbyopia-correcting solutions: monofocal IOLs targeting monovision, low-add IOLs, extended depth of focus IOLs, and even mixing and matching presbyopia-correcting IOLs.

Patient satisfaction is high with pseudophakic monovision if patients have been successful with monovision

contact lenses, but it decreases depth perception.

Today's low-add multifocals provide either 42 cm of near vision or 50 cm of intermediate vision, with less glare and halos compared with previous multifocal IOLs. We often mix and match these.

Tecnis multifocal IOLs (Johnson & Johnson Vision) are pupil independent and correct for spherical aberration. The ActiveFocus (Alcon) +2.50 showed the same contrast sensitivity as monofocal IOLs at distance.^{6,7}

Extended depth of focus (EDOF) IOLs provide very good visual quality and contrast sensitivity as they reduce chromatic aberration.⁵ The diffractive echelette design gives a more natural range of vision, increasing depth of focus, and reduced glare, halos, and night vision problems.⁸

EDOF IOLs provide good distance and intermediate vision and reduce spectacle dependence. Eighty-five percent of patients with EDOF IOLs are virtually glasses free. Studying patients who received the Tecnis Symphony (Johnson & Johnson Vision) bilaterally, Beatrice Cochener, MD, reported that patients tolerated residual cylin-

der as great as 0.75 D.⁹ In an investigation of eyes receiving four different presbyopia-correcting IOLs, Francesco Carones, MD, found that postoperative residual errors were better tolerated with the EDOF IOL than with diffractive bifocal and trifocal IOLs.¹⁰

For patients who want more reading vision, we can do a bit of monovision with EDOF IOLs if they can tolerate mini-monovision. If a patient needs a 50/50 split between intermediate and near, we implant an EDOF IOL in the dominant eye and a low-add multifocal in the nondominant eye for close vision.

Mini-monovision with presbyopia-correcting IOLs (monovision targeting -0.50 D or -0.75 D) increases near vision and reduces spectacle dependence but increases night vision disturbances.

“A new term has been introduced to describe lens changes as we age—dysfunctional lens syndrome.”

— *Sondra Black, OD*

INTEGRAL ROLE OF OPTOMETRISTS

To understand our patients' expectations and personality traits, we use a questionnaire and ask about their work and free time, at what distance they read, and whether they do a lot of night driving. We need to know which area of vision is most important to them and

“We need to manage expectations if patients expect to be 100% glasses free. I remind them that they may need readers for smaller print and they may have glare and halos immediately after surgery, but 97% of patients adapt during the first 6 months. If patients know this ahead of time, they are more likely to be satisfied with their outcomes.”

where they are willing to compromise.

We need to manage expectations if patients expect to be 100% glasses free. I remind them that they may need readers for smaller print and they may have glare and halos immediately after surgery, but 97% of patients adapt during the first 6 months. If patients know this ahead of time, they are more likely to be satisfied with their outcomes. I also explain that neuroadaptation and healing take time, and they will achieve the full benefit after binocular surgery.

We need to spend extra time with myopic patients. These patients often want their IOLs to correct distance but may not realize that they will lose their reading vision with distance correction.

In building comanagement relationships with surgeons, we should choose ophthalmologists whose philosophies match our own and we need to define our roles and expectations from the beginning.

The optometrist plays an important role in educating patients about the dynamic process of lens changes and understanding patients' lifestyles and visual needs. We should convey our knowledge of the patient and recommendations to the surgeon to help our patients achieve the visual outcomes they expect.

References

1. Data on file, Bausch & Lomb Incorporated, SurgiVision Datalink.
2. 2010 Del Webb Baby Boomer Survey, November-December, 2009, pp. 23A, 39A.
3. Sauer T, Moran E, McDonnell J. The state of the media democracy: generational shifts in media consumption and creation. New York, NY: Deloitte Research, 2009, p. 28.
4. Jones S. Generations online in 2009. Washington, DC: Pew Research Center, 2009.
5. www.tecnismultifocal.com/
6. <https://www.myalcon.com/products/surgical/acrysof-iq-restor-iol/>
7. <http://www.alconsurgical.co.za/acrysof-iq-restor-2-5-d-iol.aspx>
8. <http://www.tecnisiol.com/eu/tecnis-symfony-iol.htm>
9. Cochener B. Tecnis Symphony intraocular lens with a "sweet spot" for tolerance to postoperative residual refractive errors. *Open J Ophthalmol.* 2017; 7:14-20.
10. Carones F. Residual astigmatism threshold and patient satisfaction with bifocal, trifocal and extended range of vision intraocular lenses (IOLs). *Open J Ophthalmol.* 2017; 7:1-7.

Dr. Black practices in Toronto, Canada. She is a consultant for Acufocus, Johnson & Johnson, Valeant, and Latician Ophthalmics.

Systemic Disease Rising to the Surface

Keep an eye out for findings that might implicate these conditions during your anterior segment examination.

By Jason Fliegel, OD, Sara Weidmayer, OD, Kathy Lewis, OD, and Traci Seng, OD

A thorough anterior segment evaluation remains a necessary component of every ocular health exam, and sometimes it can uncover a systemic diagnosis. Cataracts, floppy eyelid syndrome (FES), uveitis, conjunctivitis and episcleritis are just a few presentations that may have an underlying systemic component. In an effort to reduce ocular and systemic morbidity, clinicians must understand the relationship between these ocular findings and any associated conditions so they can clearly communicate with other pertinent care providers.

These systemic conditions are just a few that can present with anterior segment manifestations.

Wilson's Disease

This is a rare autosomal recessive disorder—a result of defective excretion of copper by the biliary system—that can lead to copper accumulation in various organs,

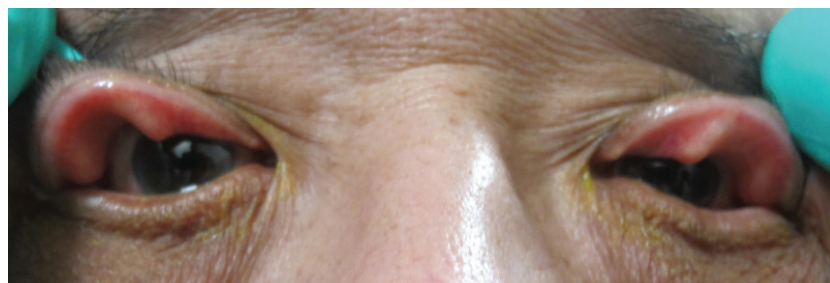

Fig. 1. These upper lids demonstrate significant laxity and easy eversion consistent with floppy eyelid syndrome.

particularly in the liver and brain.¹⁻⁴ Excess copper can be toxic and can result in acute liver failure.⁴ Neurologic manifestations of Wilson's disease (WD) include personality and cognitive changes and motor dysfunctions such as dystonias, tremors and ataxias.¹

Kayser-Fleischer (KF) rings are the most common ocular manifestation of WD; however, they can occur in other chronic cholestatic disorders as well.⁴ KF rings, which do not affect vision, appear in the peripheral cornea and are the result

of copper deposition in Descemet's membrane.⁴⁻⁶ The color of the ring can vary from golden, green, ruby or brown and usually forms superiorly and inferiorly before becoming circumferential.⁴ Only about half of patients with WD isolated to liver involvement have KF rings, though they are present in nearly all patients with neurologic involvement.¹

"Sunflower" cataracts, which are not usually visually significant, may also form from copper accumulation in the lens.⁴⁻⁶ Those with WD may also have thinner central corneal

thicknesses, steeper keratometric values and shallower anterior chamber depths than normal patients.⁷

Systemic treatment for WD, generally oral chelating agents, will lead to the resolution of the KF ring.⁴

OSA

Affecting approximately 15% of the US population, obstructive sleep apnea (OSA) has become an increasingly common sleep-related breathing disorder.⁸

The collapse of the pharyngeal airway during the sleep cycle leads to decreased

levels of blood oxygenation and increased levels of carbon dioxide. Consequently, frequent arousal from sleep is necessary to allow for normalized blood-gas exchange.^{9,10} Risk factors for OSA include increasing age, male sex, obesity, craniofacial and upper airway abnormalities and smoking.^{8,11,12}

Floppy eyelid syndrome is a common, yet often underdiagnosed, ocular condition with a well-known association with OSA. Of those diagnosed with FES, 85% have OSA, whereas between 4% and 16% of patients with OSA will present with FES.^{13,14} Due to increased laxity and easily everted lids, patients with FES often present with complaints of foreign body sensation, burning, tearing and matting, which are commonly worse upon waking as a result of exposure, mechanical irritation or both (*Figure 1*).¹⁵⁻¹⁸ Consequently, corneal and conjunctival complications are common and may include papillary conjunctivitis, superficial punctate keratitis, keratoconus, filamentary keratitis and infectious keratitis.^{15,17-19}

When patients present with suspicious findings, clinicians should

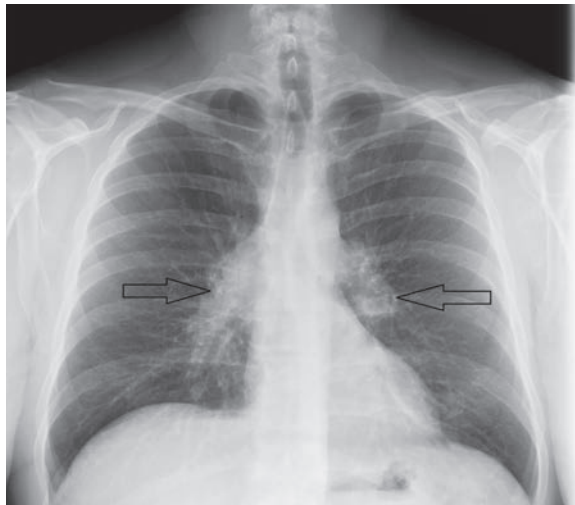


Fig. 2. This patient's chest x-ray reveals sarcoid-associated bilateral hilar lymphadenopathy (arrows).

obtain an appropriate history from both patient and bed partner, if available, regarding the patient's sleep habits, particularly in patients without an OSA diagnosis. Snoring, episodes of apnea witnessed by the bed partner, daytime sleepiness, restless sleep, fatigue, nocturia and cognitive deficits are common among those with undiagnosed OSA.^{17,20,21} Most importantly, an OSA diagnosis carries significant systemic implications such as increased incidence of systemic hypertension, cardiac arrhythmias, coronary artery disease, cognitive dysfunction, congestive heart failure, Type 2 diabetes and increased mortality.^{15,20,21} Given the systemic risks and the high incidence of OSA in patients with FES, providers should refer patients with FES who have not been diagnosed with OSA for a diagnostic sleep study, especially when symptoms of OSA are present.^{17,20,22}

Sarcoidosis

This disorder is characterized by the presence of noncaseating granulomatous inflammation, often involving multiple organs.^{23,24} While upwards of 95% of cases exhibit

pulmonary involvement as the most common complication, 30% of patients experience extrapulmonary complications that may involve the eye, skin, liver, nervous system and heart, among others.²⁴⁻²⁶ Sarcoidosis presents between the ages of 20 to 40 in approximately 70% of those affected, with African Americans having a higher incidence (35.5 in 100,000) compared with Caucasians (10.9 in 100,000) in the United States.^{27,28}

Diagnosis typically requires radiologic investigation of the chest—which reveals bilateral hilar lymphadenopathy and

reticular opacities—exclusion of other causal disease and histopathologic confirmation of noncaseating granulomas from a suspected organ site (*Figure 2*).^{23,29} Interestingly, the lacrimal gland is a common, easily accessible biopsy site used for diagnosis of sarcoidosis.³⁰

While statistics vary, ocular sequelae occur in 25% to 50% of patients with sarcoidosis and are the initial presenting complication in 5% of all cases.^{28,31,32} Anterior uveitis, the most commonly detected ocular condition, presents in 66% to 70% of those with ocular involvement.³³ Sarcoid-associated anterior uveitis may be monocular or binocular and typically reveals the presence of mutton-fat keratic precipitates, which are characteristic of granulomatous disease (*Figure 3*).^{26,31,34} Additional findings that may indicate a more chronic course of sarcoid-associated granulomatous uveitis include Busacca and Koeppe iris nodules (found on the surface of the iris and near the pupillary border, respectively), band keratopathy, posterior synechiae and secondary glaucoma.^{26,31,33,35} Because 20% of those with uveitis will develop vision




Photo: Jennifer Hartman, OD

Fig. 3. Granulomatous mutton-fat keratic precipitates typical of sarcoid-associated anterior uveitis.

loss, prompt recognition and treatment is crucial to the management of this disease.²⁸

While certainly less common than uveitis, other anterior segment findings can present in sarcoidosis. Infiltrative lacrimal gland enlargement often results in keratoconjunctivitis sicca (KCS) and occurs in 15% to 28% of cases.^{28,31} Conjunctivitis, conjunctival granulomas, scleral nodules, interstitial keratitis, episcleritis and scleritis are also possible.^{26,31,33}

HLA-B27-associated Spondyloarthropathies

The spondyloarthropathies are a group of inflammatory disorders that share common clinical characteristics such as inflammation of the axial joints, peripheral arthritis,

dactylitis, enthesitis and a negative rheumatoid factor.^{36,37} The spondyloarthropathies demonstrate a strong association with the human leukocyte antigen (HLA)-B27, a glycoprotein that assists in determining immune response and is associated with an increased incidence of ocular complications, often involving the anterior segment.^{38,39}

Common forms of spondyloarthropathies include ankylosing spondylitis (AS), reactive arthritis, psoriatic arthritis and idiopathic inflammatory bowel disease. Overall prevalence is approximately 0.5% to 1.9% of the population.^{38,39}

Ankylosing spondylitis is the most common spondyloarthropathy, with prevalence approaching 1.4% of the American population.³⁶⁻³⁸ Nearly 95% of AS patients have a positive HLA-B27 association, whereas other forms of spondyloarthropathies exhibit a range of only 20% to 70%.^{36,40} Subsequently, ocular complications are common, particularly acute anterior uveitis, which develops in 40% of those with AS (*Figure 4*).^{38,40,41} Acute anterior uveitis typically presents unilaterally, with recurrent episodes often involving the same eye; however, future

involvement of the fellow eye in a similar, recurrent pattern is not uncommon.⁴² Unsurprisingly, acute anterior uveitis also exhibits a strong association with HLA-B27.^{39,42} In cases of acute anterior uveitis, 50% are HLA-B27 positive with incidence increasing to around 70% after recurrent episodes.^{39,43} Following a literature review of 29,877 patients with any form of spondy-

loarthropathy, uveitis presented in 32.7% of cases, with acute anterior uveitis being the most commonly detected type of uveitis, further demonstrating the important relationship between this finding and a spondyloarthropathy diagnosis.⁴⁴

Idiopathic inflammatory bowel disease encompasses both Crohn's disease and ulcerative colitis. Episcleritis, anterior scleritis, corneal infiltrates and orbital and eyelid edema are anterior segment findings found among those with Crohn's disease, whereas ulcerative colitis typically involves episodes of uveitis.^{39,45,46}

Reactive arthritis occurs in response to infection and may show ocular involvement as its initial manifestation.³⁸ Arthritis, conjunctivitis and urethritis constitute the classic triad of this disease, although it only occurs in approximately 30% of patients with reactive arthritis.^{38,39,47} Uveitis, keratitis and episcleritis are also possible findings.⁴⁸

Psoriatic arthritis, a condition characterized by arthritis and psoriatic skin lesions, develops ocular findings in more than 30% of cases.⁴⁹ While conjunctivitis is the most common ocular complication, uveitis, dry eye and episcleritis may also present.^{49,50}

Rheumatoid arthritis

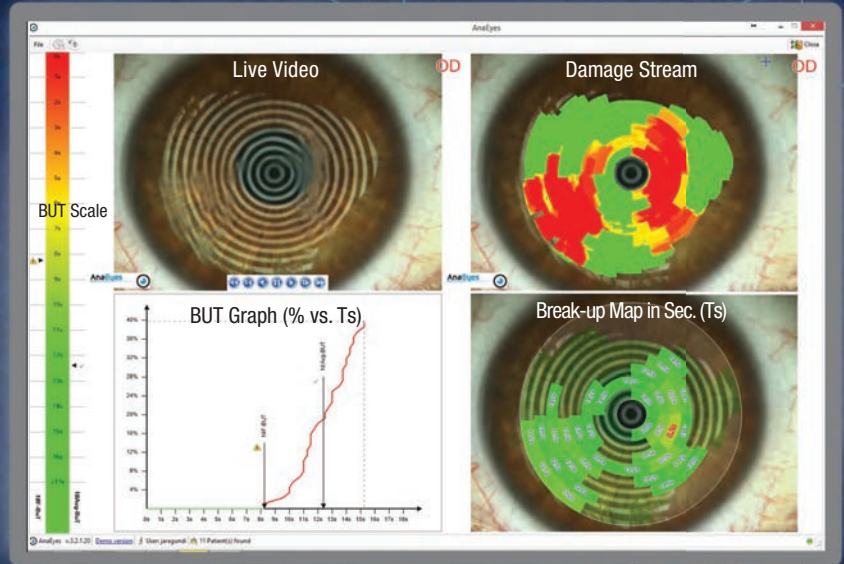
This chronic autoimmune multi-system collagen vascular disease exhibits prevalence approaching 1% worldwide.⁵¹ Rheumatoid arthritis (RA) affects women nearly three times more often than men, with peak onset typically occurring between the ages of 40 and 75.^{52,53}

Involvement is typically articular; however, extra-articular complications are also possible and occur in approximately 40% of patients diagnosed with RA.⁵⁴ Symptoms of early articular RA include a gradual onset of symmetric pain, morning

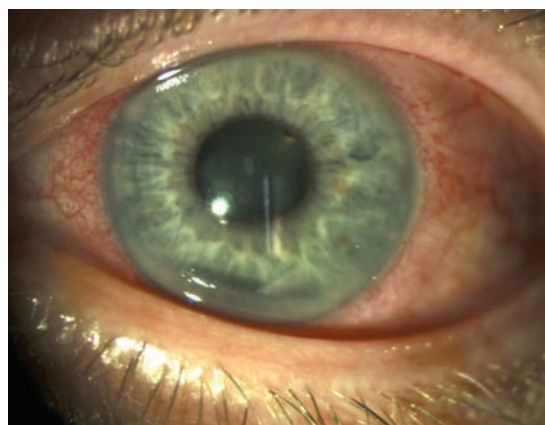

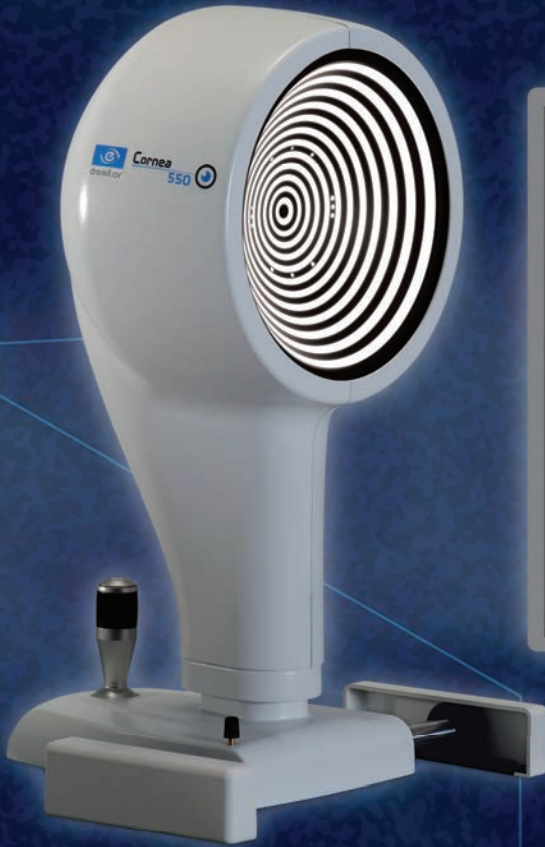Fig. 4. This eye demonstrates diffuse conjunctival injection and ciliary flush, commonly seen in HLA-B27-associated acute anterior uveitis.

THE COMPLETE SOLUTION
FOR **PRECISE** DIAGNOSIS
AND **EFFORTLESS**
DRY EYE ASSESSMENT



FOR ADVANCED CORNEAL ANALYSIS

Factors such as aging, diabetes, digital device usage, and contact lens wear are drivers for the increasing prevalence of dry eye disease.

The Cornea 550 Corneal Analyzer helps you diagnose the disease with an advanced tear film analysis for treatment.

- Blue and white light image capture allowing real-time observation of the tear film clearance
- Non-invasive measurement of the tear film break-up time and the anterior segment (pictures and videos)
- Meibography with color scale enabling evaluation of gland loss

Let us show you how Essilor Instruments can benefit your practice.



855-393-4647



essilorinstrumentsusa.com



info@essilorinstrumentsusa.com

stiffness and swelling of the joints, particularly those of the hands, wrists and toes.⁵⁵⁻⁵⁷

As no specific test confirms a diagnosis of RA, adult patients who exhibit these symptoms for more than six weeks' duration are highly suspect for RA, particularly in the presence of a positive laboratory test for rheumatoid factor (RF) or anti-citrullinated protein antibodies (ACPA).⁵⁷ Extra-articular involvement can affect multiple organs including the skin, heart, nervous system, kidneys, liver, lungs and eyes.^{58,59} Risk factors include increased age, smoking, early disability and the presence of a positive RF and antinuclear antibody (ANA) laboratory findings.⁵⁴

KCS is the most common ocular complication of RA and occurs in nearly 25% of those with RA.^{53,59,60} It typically occurs as a result of lymphocytic infiltration of the lacrimal gland due to RA-associated Sjögren's syndrome.^{53,61,62} Punctate epithelial keratopathy, mucin stranding and filamentary keratitis are common corneal findings, which, along with conjunctival tissue, progressively exhibit positive staining over the course of the disease.^{53,62}

Episcleritis occurs in less than 1% of patients with RA; however, a more common and concerning ocular complication detected in more advanced cases of RA is scleritis.^{63,64} Incidence approaches 6.3% in patients with RA, and one study reported 33% of those presenting with active scleritis had a positive diagnosis of RA.⁶³ Corneal complications, which are often associated with scleritis and are potentially sight-threatening, include sclerosing keratitis, limbal guttering, peripheral ulcerative keratitis, acute stromal keratitis and keratolysis.⁵³ Additionally, scleritis-associated anterior uveitis may present.^{58,62,65}

Lymphoma

This condition is cancer of the lymphatic system, which begins with lymphocytes (white blood cells). Two main types of lymphoma exist: Hodgkin and non-Hodgkin lymphoma (NHL).⁶⁶ Hodgkin lymphoma comprises about 14% of malignant lymphomas and is characterized by multi-nucleated giant cells known as Reed-Sternberg cells, but rarely involves the ocular adnexa or anterior segment.^{67,68} NHL is the most common hematologic malignancy.⁶⁷ It may be B-cell, T-cell or, rarely, natural killer cell, and several of each subtype exist.^{67,69}

About 1% of all lymphomas and 2% to 8% of extranodal lymphomas develop in the eye's adnexa—approximately 37% of those are orbital, 25% to 29% conjunctival, 29% lacrimal and 14% involve the eyelid, although lymphoma can also present at other sites within the globe as well.^{68,70} Special lymphoid tissue within the conjunctiva and lacrimal gland are part of the mucosa-associated lymphoid tissue (MALT) system, from which B-cell NHL can arise.^{68,71} The risk of developing lymphoma increases in the presence of chronic inflammatory diseases such as Sjögren syndrome, which has a nearly 14-fold increased incidence of NHL.^{72,73}

Lacrimal gland lymphoma may present with eyelid swelling, pain or proptosis and generally appears as a solid enlarged mass.⁷⁴ Eyelid lymphoma can involve the skin, subcutaneous connective tissue, as well as the orbicularis oculi.⁶⁹ Lymphoma may also appear as a chronic anterior uveitis.

Conjunctival lymphomas typically present as raised, salmon-colored

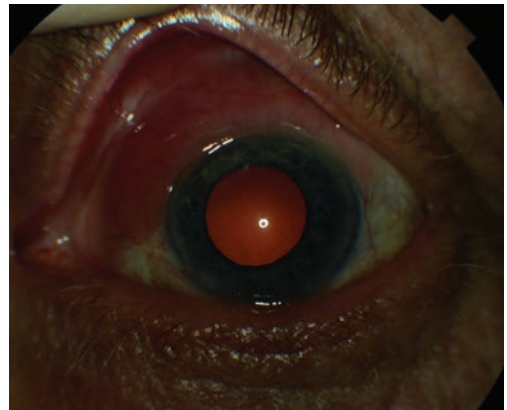


Fig. 5. This left eye demonstrates a large, elevated salmon-colored conjunctival lymphoma involving a large area of the bulbar conjunctiva and limbus.

lesions.⁷¹ They may be round or oval when involving the bulbar conjunctiva (*Figure 5*). In the fornix, they tend to conform to the forniceal contour, with the inferior fornix being the most commonly involved conjunctival site.^{75,76} While they are usually smooth, the lesions can appear lobulated or present similar to a follicular conjunctivitis.⁶⁶ They are bilateral in 20% to 38% of cases, most often occur in the 5th to 7th decades of life and affect females slightly more often than males.^{66,70}

Most conjunctival lymphomas are NHL B-cell with one of four major subtypes (in decreasing order of frequency): extranodal marginal zone lymphoma of the MALT system, follicular, mantle cell and diffuse large B-cell lymphoma.⁷⁰ Extranodal marginal zone and follicular lymphomas are low-grade, whereas mantle cell and diffuse large B-cell are high-grade malignancies.^{66,70,77} Tissue biopsy of the suspected site is necessary for diagnosis and subtype differentiation, which will also help to guide treatment.⁷¹

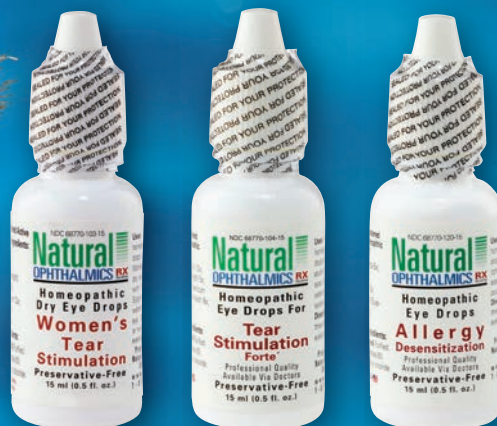Most conjunctival lymphomas are primary, with approximately one-third of those having regional lymph node and/or systemic involvement.⁶⁶ Additionally, 20% of those

Go from
"Arrghh!"

to

"Ahhh!"

Rather than sampling lubricants and prescribing antihistamines for dry eye or allergy—now you can dispense therapeutic treatments that your patients will prefer.



www.NaturalEyeDrops.com

Try a dozen bottles on your toughest patients (\$76.68) and receive a free intro pack worth \$60.

Call today
1-877-220-9710

*Professional Quality
Available Via Doctors*

Natural
OPHTHALMICS **RX**
Quality

Systemic Disease

with local conjunctival lymphoma will develop systemic lymphoma; therefore, a referral for appropriate systemic investigation is critical.^{66,78}

Mucous Membrane Pemphigoid

This is a multisystem autoimmune subepithelial blistering disorder that affects the mucous membranes at the ocular, oral, nasopharyngeal, tracheal, esophageal, anogenital and genitourinary orifices.⁷⁹ Common findings include inflammation, subepithelial blistering and cicatricial shrinking of the affected tissue.⁷⁹ The incidence of mucous membrane pemphigoid (MMP) is low, at 1.16 to 2 per million.⁸⁰ Conjunctival involvement is referred to as ocular cicatricial pemphigoid (OCP) and is detected in approximately 70% of patients with MMP.^{79,82}

OCP causes deposition of immunoglobulin and complement in conjunctival basement membrane.^{81,83}

Circulating autoantibodies bind to antigens within the basement membrane and activate the complement cascade. Cellular response then leads to subepithelial bullae formation and scarring.⁸³ As the condition progresses, the eye develops symblepharon with shortening of the fornices; this leads to xerosis, tear abnormalities, meibomian gland dysfunction and abnormalities of the eyelid margin, which also can cause mechanical trauma to the surface of the eye (Figure 6).⁸³ Endstage corneal damage can occur, resulting in decreased vision from vascularization and opacification.^{81,84}

Early diagnosis can be challenging, as the initial presentation is usually a unilateral, chronic, recurrent, papillary conjunctivitis; as a

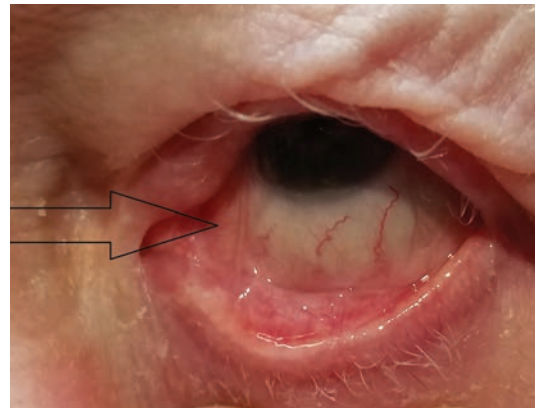


Fig. 6. Focal symblepharon extending from medial palpebral conjunctiva of lower lid to nasal area of bulbar conjunctiva, commonly seen with OCP (arrow).

non-specific finding, this contributes to the typical 2.8 years until arriving at a correct diagnosis of OCP.^{83,85} By the time of diagnosis, most patients will already have significant bilateral fornical shortening and ocular morbidity.⁸⁵ A high level of suspicion for OCP should be present in any unexplained, chronic, recurrent conjunctivitis, especially in the presence of subepithelial scarring of the conjunctiva. Conjunctival biopsy with pathologic analysis can help to confirm a diagnosis of OCP, although false negatives are possible.^{81,83}

Treatment is difficult and is applied in a step-wise fashion to minimize side effects.⁸⁴ Topical treatment alone is rarely successful for long-term control; oral immunomodulatory or biologic therapies are typically indicated, and management should be provided by a specialist familiar with the administration and monitoring of these therapies.⁸⁴

Detection of anterior segment manifestations of systemic disease is a significant opportunity for ODs to participate in life-changing, and in some cases life-saving, care. Because the related systemic condition may be previously unknown to the patient, it is our responsibility to accurately

Lyme Disease: An OD's First-hand Account

By Cheryl G. Murphy, OD, Contributing Editor

What started as a dull ache behind my right eye soon turned into the worst headache of my life. I became feverish, fatigued and weak. I saw "wiggling worms of light" dancing in my inferior visual field. My condition continued to decline—I lost all appetite and could barely get out of bed. I thought maybe I had the flu, but it was June and flu season had passed.

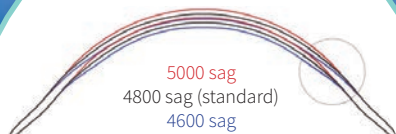On the fourth day I went to the emergency room (ER) and was diagnosed with viral meningitis. The ER doctor explained that any virus at any time (even viruses that cause the common cold or a cough) can sporadically decide to invade the brain and spinal cord. I asked how he knew it wasn't bacterial meningitis. He said I "would have been dead by the fourth day." After extensive testing, scans and blood work, all of which came back negative, I was discharged and instructed to wait the virus out. Stay hydrated and rest, the doctor said.

Once home, I decided to take a cool shower. It was then I noticed a red rash on my right hip. It wasn't a bulls-eye, but I immediately thought of Lyme disease. We had just moved into a new house that sat on an acre of woods, and deer were known to forage for food throughout the neighborhood. Although my blood test for Lyme had come out negative, I visited my general physician and pleaded with her to start me on the recommended course of doxycycline. She agreed, but only to a three-day dose; she would repeat blood work for Lyme and increase to the full course of antibiotics only if it came back positive.

The new blood work came back positive. Luckily, I caught it relatively early and after completing a 21-day course of doxycycline, have not suffered any long-term effects.

With the number of ticks carrying Lyme disease on the rise in the Northeast, it is essential for us as optometrists to be aware of the possibility that a seemingly harmless or vague symptom such as dull eye pain could be the beginning of something much more serious.

Indicated for Ocular Surface Disease Including Dry Eye



SmartCurve™ Technology

Simplify your fitting.
Modify only those parameters
that need to change.



MicroVault™ Technology

Fully vaults the lens over elevations
that might interfere with a
proper landing.

Straight. Forward. Technology.

For Straightforward Scleral Lens Fitting.



For irregular corneas

- Vaults the cornea and limbus to fit a wide range of corneas
- Lens diameters of 16.0 mm and 17.0 mm
- Prolate and oblate designs for a variety of corneal shapes



For regular corneas

- Smaller diameters of 14.8 mm and 15.4 mm for regular corneas
- Single profile prolate design

Assistance from FCLSA*
trained fitting consultants

* Fellow of Contact Lens Society of America

**Scleral lens technology to help you...
and your patients.**

To learn more, call or visit:

800-253-3669 • www.bauschsvp.com

*/TM are trademarks of Bausch & Lomb Incorporated or its affiliates. © Bausch & Lomb Incorporated. ALZN.0056.USA.17



BAUSCH+LOMB
Specialty
VISION PRODUCTS

diagnose, manage and communicate our findings and concerns to the appropriate medical specialty to ensure timely care. ■

Drs. Fliegel, Weidmayer, Lewis and Seng are staff optometrists in the VISN 10: VA Healthcare System – US Department of Veteran Affairs.

Contents in this publication do not represent the views of the US Department of Veterans Affairs or the United States government.

1. Biswas S, Paul N, Das SK. Nonmotor manifestations of Wilson's disease. *Int Rev Neurobiol.* 2017;134:1443-59.
2. Scheinberg IH, Sternlieb I. Wilson's disease. In: Smith LH, Jr, ed. *Major Problems in Internal Medicine.* Philadelphia: WB Saunders; 1984;23:25-35.
3. Gitlin JD. Wilson disease. *Gastroenterology.* 2003;125:1868-77.
4. Pandey N, John S. Kayser Fleischer Ring. *StatPearls.* Treasure Island, FL: StatPearls Publishing; November 7, 2017.
5. Ala A, Walker AP, Ashkan K, et al. Wilson's disease. *Lancet.* 2007;369:397-408.
6. European Association for the Study of the Liver. Clinical practice guidelines: Wilson's disease. *J Hepatol.* 2012;56:671-85.
7. Necip K, Seyyar SA, Saygılı O, et al. Anterior segment parameters in patients with Wilson disease. *Cornea.* 2018;37(4):466-69.
8. Young T, Palta M, Dempsey J, et al. Burden of sleep apnea: rationale, design, and major findings of the Wisconsin Sleep Cohort study. *WJMJ.* 2009;108:246-9.
9. Eckert DJ, Malhotra A. Pathophysiology of adult obstructive sleep apnea. *Proc Am Thorac Soc.* 2008 Feb 15;5(2):144-53.
10. Dempsey JA, Veasey SC, Morgan BJ, O'Donnell CP. Pathophysiology of sleep apnea. *Physiol Rev.* 2010;90(1):47-112.
11. Young T, Skatrud J, Peppard PE. Risk factors for obstructive sleep apnea in adults. *JAMA.* 2004;291(16):2013-6.
12. Wetter DW, Young TB, Bidwell TR, et al. Smoking as a risk factor for sleep-disordered breathing. *Arch Intern Med.* 1994;154(19):2219-24.
13. Muniesa MJ, Huerva V, Sánchez-de-la-torre M, et al. The relationship between floppy eyelid syndrome and obstructive sleep apnoea. *Br J Ophthalmol.* 2013;97:1387-90.
14. Karger RA, White WA, Park WC, et al. Prevalence of floppy eyelid syndrome in obstructive sleep apnea-hypopnea syndrome. *Ophthalmology.* 2010;117:831-8.
15. Burkat CN, Kersten RC. Malposition of the eyelids. In: Mannis MJ, Holland EJ, eds. *Cornea.* 4th ed. Philadelphia: Elsevier; 2017:298-316.
16. Huerva V, Muniesa MJ, Ascaso FJ. Floppy eyelid syndrome in obstructive sleep apnea. *Sleep Medicine.* 2014;15:724-5.
17. Bowling B. Eyelids. In: Bowling B, ed. *Kanski's Clinical Ophthalmology.* 8th ed. Philadelphia: Elsevier; 2017:1-62.
18. Mills DM, Meyer DR, Harrison AR. Floppy eyelid syndrome: quantifying the effect of horizontal tightening on upper eyelid position. *Ophthalmology.* 2007;114(10):1932-6.
19. Donnenfield ED, Perry HD, GTibalter RP, et al. Keratoconus associated with floppy eyelid syndrome. *Ophthalmology.* 1991;98:1674-8.
20. Strohl KP. Overview of obstructive sleep apnea in adults. In: Collop N, Finlay G, eds. *UpToDate.* Accessed November 21, 2017.
21. Kimoff RJ. Obstructive sleep apnea. In: Broaddus VA, ed. *Murray and Nadel's Textbook of Respiratory Medicine.* 6th ed. Elsevier; 2016:1552-68.e9.
22. Kapur VK, Auckley DH, Chowdhuri S, et al. Clinical practice guideline for diagnostic testing for adult obstructive sleep apnea: an American Academy of Sleep Medicine clinical practice guideline. *J Clin Sleep Med.* 2017;13(3):479-504.
23. King TE. Extrapulmonary manifestations of sarcoidosis. In: Flaherty KR, Hollingsworth H, eds. *UpToDate.* Accessed December 12, 2017.
24. Baughman RP, Teirstein AS, Judson MA, et al. Clinical characteristics of patients in a case control study of sarcoidosis. *Am J Respir Crit Care Med.* 2001;164:1885-9.
25. Rizzato G, Tinelli C. Unusual presentation of sarcoidosis. *Respiration.* 2005;72(1):3-6.

26. Cowan CL. Sarcoidosis. In: Yanoff M, Duker JS, eds. *Ophthalmology.* 4th ed. Elsevier; 2014:753-7.e1.
27. Rybicki BA, Major M, Popovich J Jr, et al. Racial differences in sarcoidosis incidence: a 5-year study in a health maintenance organization. *Am J Epidemiol.* 1997;145(3):234-41.
28. West SG. Sarcoidosis. In: Hochberg MC, Silman AJ, Smolen JS, et al., eds. *Rheumatology.* 6th ed. Mosby; 2015:1392-1400.
29. Statement on sarcoidosis. Joint statement of the American Thoracic Society (ATS), the European Respiratory Society (ERS) and the World Association of Sarcoidosis and other Granulomatous Disorders (WASOG) adopted by the ATS Board of Directors and by the ERS Executive Committee, February 1999. *Am J Respir Crit Care Med.* 1999;160:736-55.
30. King TE. Clinical manifestations and diagnosis of pulmonary sarcoidosis. In: Flaherty KR, Hollingsworth H, eds. *UpToDate.* June 19, 2017.
31. Baughman RP, Lower EE, Kaufmann AH. Ocular sarcoidosis. *Semin Respir Crit Care Med.* 2010;31:452-62.
32. Jamilloux Y, Kodjikian L, Brousolle C, et al. Sarcoidosis and uveitis. *Autoimmune Rev.* 2014;13:840.
33. Sepah YJ, Agarwal A, Jabs DA, et al. Sarcoidosis. In: Schachat AP, Sadda SR, Hinton DR, et al., eds. *Ryan's Retina.* 6th ed. Elsevier; 2018:1572-85.
34. Iwata K, Nanka, Sobu K, et al. Ocular sarcoidosis. Evaluation of into-ocular findings. *NY Acad Sci.* 1976;278445-54.
35. Ohara K, Judson MA, Baughman RP. Clinical aspects of ocular sarcoidosis. In: Drent M, Costabel U. *Sarcoidosis.* Wakefield, UK: Charlesworth Group; 2005:188-209.
36. Rudwaleit M. Classification and epidemiology of spondyloarthritis. In: Hochberg MC, Silman AJ, Smolen JS, et al., eds. *Rheumatology.* 6th ed. Mosby; 2015:941-5.
37. Yu DT, van Tubergen A. Overview of the clinical manifestations and classification of spondyloarthritis. In: Sieper J, Romain PL, eds. *UpToDate.* Accessed December 1, 2017.
38. Denniston AK, Rhodes B, Gayed M, et al. Rheumatic disease. In: Schachat AP, Sadda SR, Hinton DR, et al., eds. *Ryan's Retina.* 6th ed. Elsevier; 2018:1597-1623.
39. Holland S, Almond MC. HLA-B27-related uveitis. In: Mannis MJ, Holland EJ, eds. *Cornea.* 4th ed. Elsevier; 2017:1214-21.
40. Gensler LS. Clinical features of axial spondyloarthritis. In: Hochberg MC, Silman AJ, Smolen JS, et al., eds. *Rheumatology.* 6th ed. Mosby; 2015:946-50.
41. Rothova A, van Veenendaal WG, Linssen A, et al. Clinical features of acute anterior uveitis. *Am J Ophthalmol.* 1987;103:137-45.
42. Pavesio CE, Jones N. Uveitis related to HLA-B27. In: Yanoff M, Duker JS, eds. *Ophthalmology.* 4th ed. Philadelphia: Elsevier; 2014:748-52.
43. Ehlers N, Kissmeyer-Nielsen F, Kjerbye KE, et al. HLA-B27 in acute and chronic uveitis. *Lancet.* 1974;1:99.
44. Zeboulon N, Dougados M, Gossec L. Prevalence and characteristics of uveitis in the spondyloarthropathies: a systematic literature review. *Ann Rheum Dis.* 2008;67:955-9.
45. Salmon JF, Wright JP, Murray AD. Ocular inflammation in Crohn's disease. *Ophthalmology.* 1991;98:480-4.
46. Korelitz BI, Coles RS. Uveitis (iritis) associated with ulcerative and granulomatous colitis. *Gastroenterology.* 1967;52:78-82.
47. Nissman DB, Shankar PV, Pope TL. Reactive arthritis. In: Pope T, Bloehm HL, Beltran J, et al., eds. *Musculoskeletal Imaging.* 2nd ed. Saunders; 2015:684-90.
48. Lee DA, Barker SM, Su WP, et al. The clinical diagnosis of Reiter's syndrome. Ophthalmic and non-ophthalmic aspects. *Ophthalmology.* 1986;93:350-6.
49. Lambert JR, Wright V. Eye inflammation in psoriatic arthritis. *Ann Rheum Dis.* 1976;35(4):354-35.
50. Husni ME. Classification and epidemiology of psoriatic arthritis. In: Hochberg MC, Silman AJ, Smolen JS, et al., eds. *Rheumatology.* 6th ed. Mosby; 2015:986-8.
51. Liao KP, Karlson E. Classification and epidemiology of rheumatoid arthritis. In: Hochberg MC, Silman AJ, Smolen JS, eds. *Rheumatology.* 6th ed. Mosby; 2015:691-7.
52. Gabriel SE, Crowson CS. Epidemiology of, risk factors for and possible causes of rheumatoid arthritis. In: Maini RV, ed. *Accessed January 18, 2018.*
53. Taylor S, Li JY. Corneal diseases in rheumatoid arthritis. In: Mannis MJ, Holland EJ, eds. *Cornea.* 4th ed. Elsevier; 2017:1050-65.
54. Turesson C, O'Fallon WM, Crowson CS, et al. Extra-articular disease manifestations in rheumatoid arthritis: incidence trends and risk factors over 46 years. *Ann Rheum Dis.* 2003;62(8):722-7.
55. Lee DM, Weinblatt ME. Rheumatoid arthritis. *Lancet.* 2001;358(9285):903-11.
56. Fleming A, Crown JM, Corbett M. Early rheumatoid disease. I.

- Onset. *Ann Rheum Dis.* 1976;35(4):357-60.
57. Brasington RD. Clinical features of rheumatoid arthritis. In: Hochberg MC, Silman AJ, Smolen JS, eds. *Rheumatology.* 6th ed. Mosby; 2015:704-11.
58. Turesson C, Matteson EL. Extraarticular features of rheumatoid arthritis and systemic involvement. In: Hochberg MC, Silman AJ, Smolen JS, eds. *Rheumatology.* 6th ed. Mosby; 2015:712-19.
59. Matteson EI, Davis JM. Overview of the systemic and nonarticular manifestations of rheumatoid arthritis. In: Maini R, Romain P, eds. *UpToDate.* Accessed January 12, 2018.
60. Thompson M, Eadie S. Kerato-conjunctivitis sicca and rheumatoid arthritis. *Ann Rheum Dis.* 1956;15(1):21-5.
61. Baer A. Clinical manifestations of Sjogren's syndrome: Exocrine gland disease. In: Fox R, Romain P, eds. *UpToDate.* Accessed January 12, 2018.
62. Dana R. Ocular manifestations of rheumatoid arthritis. In: Maini R, Trobe J, Romain P, eds. *UpToDate.* June 14, 2017.
63. McGavin DD, Williamson J, Forrester JV, et al. Episcleritis and scleritis. A study of their clinical manifestations and association with rheumatoid arthritis. *Br J Ophthalmol.* 1976;60(3):192-226.
64. Sainz de la Maza M, Jabbur NS, Foster CS. Severity of scleritis and episcleritis. *Ophthalmology.* 1994;101:389-96.
65. Sainz de la Maza M, Jabbur NS, Foster CS. Scleritis-associated uveitis. *Ophthalmology.* 1997;104:58-63.
66. Sein J, Stefanovic A, Kemp CL. Diagnosis and treatment of conjunctival lymphoma. *Eyenet.* Septembr 2012.
67. Kahl B. Lymphomas: The Basics. University of Wisconsin Lymphoma Service. williams.medicine.wisc.edu/lymphomaoverview.pdf. Accessed March 30, 2018.
68. Verdijk RM. Lymphoproliferative tumors of the ocular adnexa. *Asia-Pac J Ophthalmol.* 2017;6:132-42.
69. Svendsen FH, Rasmussen PK, Coupland SE, et al. Lymphoma of the eyelid—an international multicenter retrospective study. *Am J Ophthalmol.* 2017;58-68.
70. Kirkegaard MM, Rasmussen PK, Coupland SE, et al. Conjunctival lymphoma—an international multicenter retrospective study. *JAMA Ophthalmol.* 2016;134(4):406-14.
71. Coupland S, Heegaard S. Can conjunctival lymphoma be a clinical diagnosis? *Br J Ophthalmol.* 2014;98:574-5.
72. McNab AA. The 2017 Doyné Lecture: the orbit as a window to systemic disease. *Eye.* 2018;32:248-61.
73. Liang Y, Yang Z, Qin B, Zhong R. Primary Sjogren's syndrome and malignancy risk: a systematic review and meta-analysis. *Ann Rheum Dis.* 2014;73:1151-6.
74. Rasmussen P, Raifkaer E, Prause JU, et al. Malignant lymphoma of the lacrimal gland. *Arch Ophthalmol.* 2011;129(10):1275-80.
75. Ehlers JP, Shah CP. *Wills Eye Manual: Office and Emergency Room Diagnosis and Treatment of Eye Disease.* 5th ed. Philadelphia: Wolters Kluwer; 2010:123.
76. Greenwald MF, Meirick TM, McConnell LK, Shriver EM. Conjunctival lymphoma. eyerounds.org/cases/243-conjunctival-lymphoma.htm. Accessed March 30, 2018.
77. Kirkegaard MM, Coupland SE, Prause JU, Heegaard S. Malignant lymphoma of the conjunctiva. *Surv Ophthalmol.* 2015;60(5):444-58.
78. Coupland S, Krause L, Delecluse HJ, et al. Lymphoproliferative lesions of the ocular adnexa: analysis of 112 cases. *Ophthalmol.* 1998;105:1430-41.
79. Chan LS, Ahmed AR, Anhalt GH, et al. The first international consensus on mucous membrane pemphigoid: definition, diagnostic criteria, pathogenic factors, medical treatment, and prognostic indicators. *Arch Dermatol.* 2002;138:370-9.
80. Ong HS, Setterfield JF, Minnassian DC, et al. Mucous membrane pemphigoid with ocular involvement: the clinical phenotype and its relationship to direct immunofluorescence findings. *Ophthalmology.* 2017;1-9.
81. Goldich Y, Ziai S, Artomsombudh P, Avni-Zauberman N, et al. Characteristics of patients with ocular cicatricial pemphigoid referred to a major tertiary hospital. *Can J Ophthalmol.* 2015;50(2):137-42.
82. Schmidt E, Zillikens D. Pemphigoid diseases. *Lancet.* 2013;381:320-32.
83. Kirzhner M, Jakobiec FA. Ocular cicatricial pemphigoid: A review of clinical features, immunopathology, differential diagnosis, and current management. *Semin Ophthalmol.* 2011;26:4-5:270-7.
84. Queisi MM, Zein M, Lamba N, Meese H, Foster CS. Update on ocular cicatricial pemphigoid and emerging treatments. *Surv Ophthalmol.* 2015;12:007.
85. Foster CS. Cicatricial pemphigoid. *Trans Am Ophthalmol Soc.* 1986;84:527-663.

One Problem -- Two Solutions

Temporary and permanent punctum plug solutions for dry eye



SuperEagle® Punctum Plug:

Tapered shaft

Facilitates better patient retention

Low profile cap

All the comfort with less foreign body sensation

Fine distal tip

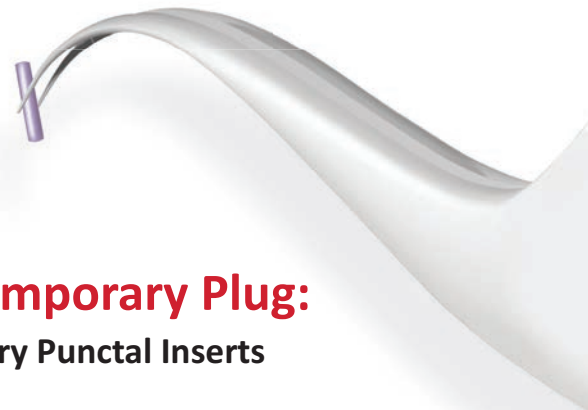For easy insertion

Softest pliable silicone

To accommodate any anatomy

Easy to size

Small, medium, large



DuraPlug® Temporary Plug:

Synthetic Temporary Punctal Inserts

Effective 60 – 180 days

Now available in four sizes:

0.2mm, 0.3mm, 0.4mm, and now 0.5mm

Each box comes with 10 sterile sleeves of two plugs



PART OF THE KATENA
FAMILY OF PREMIUM
OPHTHALMIC PRODUCTS



800.225.1195 • info@katena.com • www.katena.com

KEV-Adv-032918-Rev0

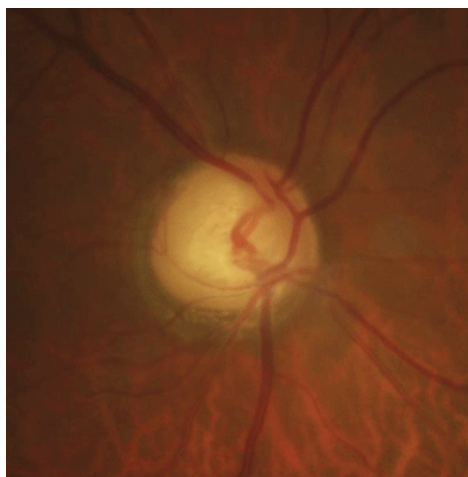
Glaucoma: A Primary Care Crusade

Investing your knowledge and energy is all it takes to get your practice glaucoma-ready. **By Francesca Crozier-Fitzgerald, Associate Editor**

“I’m on a quest to make glaucoma sexy again,” said Eric Schmidt, OD, of Omni Eye Specialists, during a 2018 SECO presentation in Atlanta, Ga. Unloved by many ODs and MDs alike, the disease is on the precipice of an epidemic, experts say, given the high rate of undiagnosed glaucoma sufferers, an inevitable age-related increase in prevalence that’s well underway and woeful under-capacity among ophthalmologists to meet the need today, let alone tomorrow.

This is a golden opportunity for optometrists to shine. The bulk of glaucoma care, Dr. Schmidt believes, can and should be done in the optometric office. “This is a primary care disease,” he says. “You should have all the equipment, training and legislation you need to treat it—now you just need the confidence.”

Advanced technology, academic curriculum reform and new legislation have all made this shift possible. While glaucoma treatment was once considered primarily within the oph-



A simple-to-obtain fundus image can reveal glaucomatous thinning, as seen here.

thalmologist’s realm, it’s now clear that a disease requiring frequent, ongoing monitoring with a slowly progressive course and relatively low stakes on any given day is best served at the primary care level and is ideal for the OD.

This article, first of a four-part series on how optometrists can succeed in glaucoma care, looks at the state of optometric involvement and how you can overcome barriers both real and perceived.

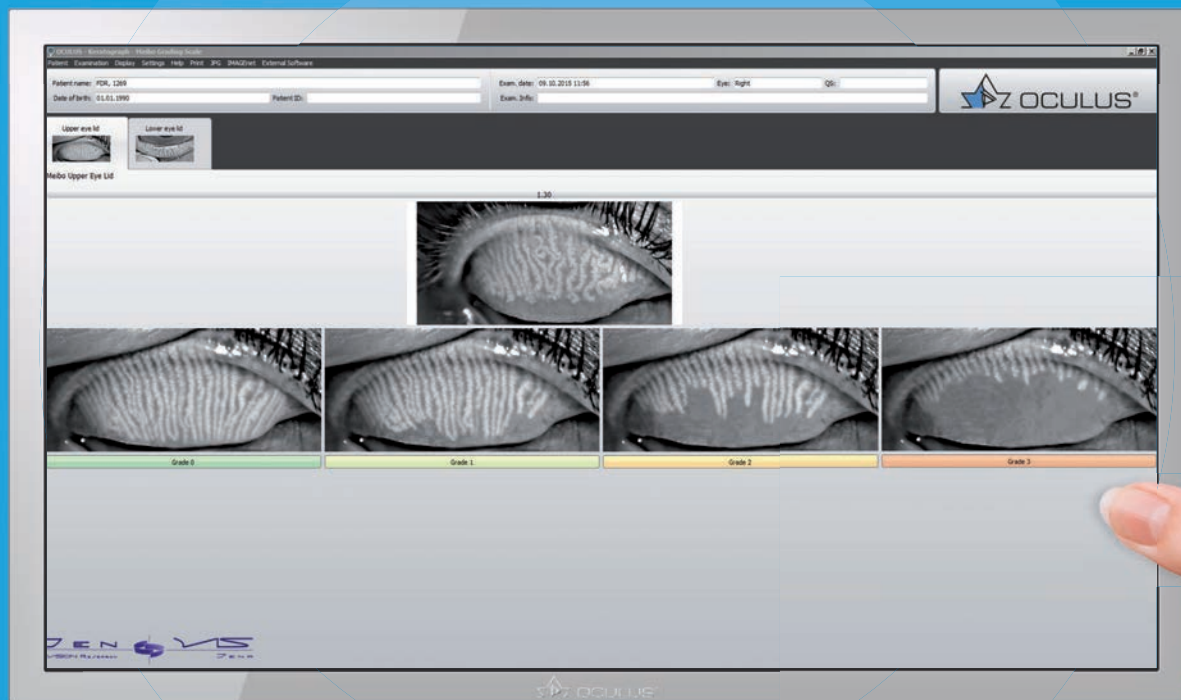
Care By the Numbers

If you’re leery of incorporating glaucoma care into your practice, you aren’t alone. It isn’t a priority for many optometrists, according to 2014 Medicare data presented by Mark Swanson, OD, MSPH, of University of Alabama at Birmingham, at the 2017 American Academy of Optometry Meeting in Chicago.¹

For example, two-thirds of ODs—a total of 26,000—submitted Medicare claims that year for glaucoma-related services, but only 8.3% of those submitted at least 10 claims for pachymetry, a classic diagnostic tool for glaucoma, he said, compared with nearly 40% of ophthalmologists (out of a pool of roughly 19,000 OMDs). The four other tests commonly part of the glaucoma workup revealed a similar disparity (*Table 1*). Fundus photos had the highest number of claim submissions for ODs, at 45.9%; when analyzed in a pool of all ODs and MDs who submit claims, “optometrist providers represented 58% of those who submitted claims for photography,”

Photo: Justin Cole, OD, and Jarell Mezzanella, OD

OCULUS Keratograph® 5M

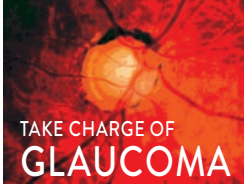


Let's Focus on Dry Eye!



The Keratograph® 5M assists you in finding the cause of dry eye quickly and reliably. Create a comprehensive analysis of the meibomian glands!

- JENVIS Grading Scales: Easy classification of MGD based on individual meibography
- Meibo-Scan: Analysis of the meibomian glands of the upper and lower eyelids
- Comparative display of meibomian glands from up to four examinations



Part 1: Primary Care

Table 1. 2014 Glaucoma-related Medicare Claims (at least 10) Submitted by Optometrists and Ophthalmologists¹

	ODs (26,821)	OMDs (17,817)	Total of 44,638 Providers	Total # of OD claims	Total # of OMD claims
Pachymetry	8.3%	37.8%	24.8% ODs vs. 75.1% OMDs	65,037	327,605
Gonioscopy	9.5%	38.2%	27.1% ODs vs. 72.7% OMDs	128,798	705,303
Visual Field	42.6%	72.1%	46.8% ODs vs. 52.6% OMDs	652,416	2,122,866
OCT	35.7%	63%	45.8% ODs vs. 53.8% OMDs	521,132	1,795,206
Photography	45.9%	47.9%	58.5% ODs vs. 40.6% OMDs	1,093,204	1,772,056

Dr. Swanson said in his presentation.¹

Broken down based on the number of diagnostic tests any given Medicare Part B provider submits for, “almost 40% of the 26,000 optometrists submit zero claims that hit the 10 mark,” he said. “A very small percentage—less than 5% of optometrists—submit at least 10 claims per year covering all five tests” (Table 2).

Part of the imbalance, according to Dr. Swanson, is the volume of patients. Going back to optometry’s one strong suit in the data, “if you look at the total numbers for the photography services, it’s one million for optometry and 1.7 million for ophthalmology.” And the same is true across the board. For every test, MDs see significantly more patients, with the disparity for fundus photography being the least.¹

He admits the data has many limitations, however. While these five tests are often routine for glaucoma care, the data provided “doesn’t mean it was necessarily glaucoma-related services; it could be for an examination for other services.”¹

In addition, providers had to submit at least 10 claims a year for any given test, possibly skewing data away from smaller practices that only care for a few glaucoma patients each year, Dr. Swanson said. Still, the numbers provided by Medicare suggest “ophthalmologists provide the overwhelming majority of glaucoma tests for Medicare Part B recipients.”¹

This statistic is precisely what optometry should strive to combat. Optometrists already have the training to diagnose and treat the disease in all states aside from Massachusetts, and it’s just a matter of investing the time and a little capital to build a glaucoma culture and take over the bulk of the ongoing care in the United States.

These five simple and practical steps can help make your optometry office glaucoma-conscious.

Step One: Rethink Referral

First, the good news. Many optometrists already have and use all the tools needed to detect and monitor glaucoma; they also already document additional risk factors such as family history, age, race, hypertension, nearsightedness, cardiovascular disease, corneal thickness and asymmetric cupping of the optic nerve. A refresher on the information you learned in school, new research and properly interpreting test results—found online or at annual conferences—may be all it takes to redirect your energy toward glaucoma care and avoid the knee-jerk referral to the ophthalmologist down the street.

“Once you give your patient up to a person that you’re not working with regularly, they’re gone,” says James Thimons, OD, of Ophthalmic Consultants of Connecticut. “You’ve shown your patient that you’re not comfortable. To grow a glaucoma practice you need to be comfortable in your knowledge and comfortable

in your clinical skill to set a goal and plan in place.”

“Lately, all we want is instant gratification and quick fixes, so we’re not wired for the slow-moving longitudinal nature of this disease,” Dr. Schmidt says. But that’s easy to change with today’s high-resolution, multifunctional optical coherence tomography (OCT) technology and self-administered tonometry devices for patients to use at home, he says. For the majority of glaucoma patients, a referral is unnecessary. You have what it takes to provide the best care right in your office. In fact, ODs—as primary care providers—are better positioned to handle the ongoing care these patients need. Even when a referral is necessary, ODs should remain comanaging partners on the team.

Step Two: Refocus

“More than anything, you’ve got to start thinking glaucoma,” Dr. Schmidt said at SECO. During his internship and fellowship, he saw many glaucoma suspects and patients daily. “In my mind, because I saw so many, I became convinced that everybody was going to get glaucoma, and I still think that way,” he said. “If we think everyone who sits in the chair could get glaucoma, we’re far more likely to start cultivating glaucoma suspects and catching this disease early.”

“If you want to develop a glaucoma practice, you need to develop a glaucoma *suspect* practice,” added

Dry Eye Diagnosis and Treatment is on the rise. . .

EyeRes™

Digital Imaging Systems for slit lamps.

A Versatile System:

Anterior-segment imaging, Retinal imaging, and Infrared imaging all from a slit lamp.

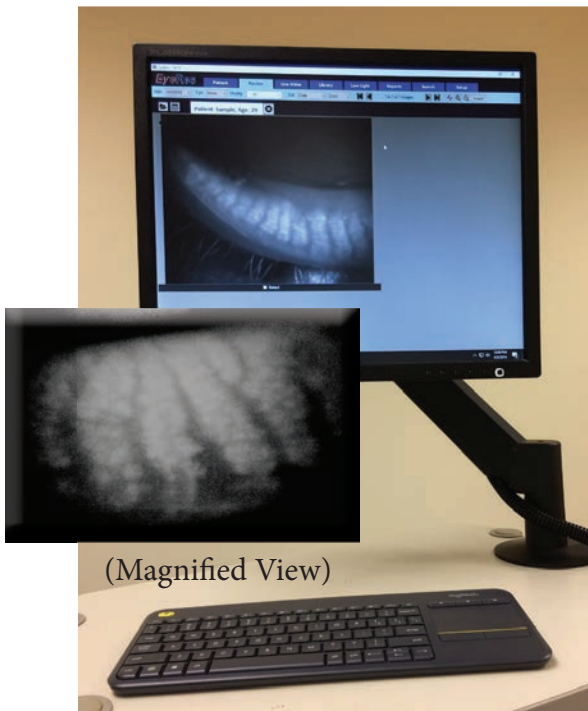
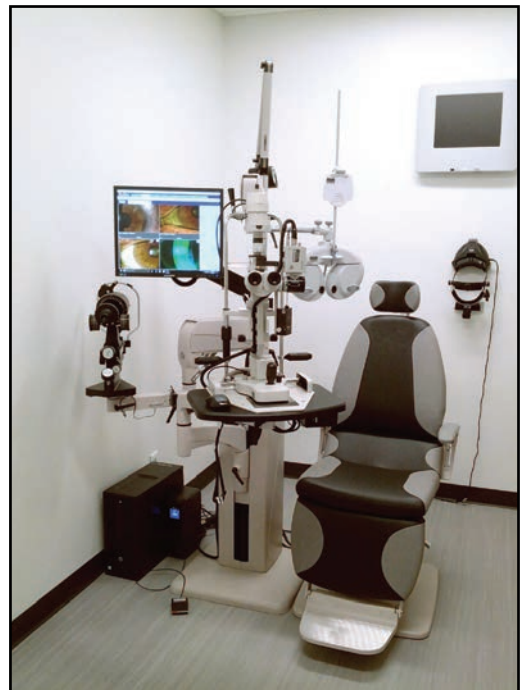Save time, money, and space while enhancing the patient's experience.

Reap the many benefits of owning an


EyeRes™ imaging system.

Call **800.769.4933** today.

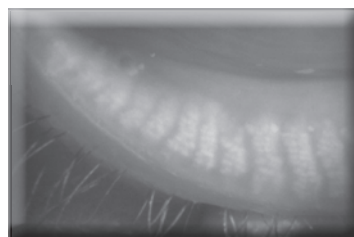
www.TelScreen.com



(Magnified View)

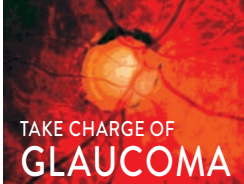


Our Platinum EyeRes system is compatible with most slit lamps.



Our Infrared camera is compatible with our ER-11 slit lamp.

TelScreen



Part 1: Primary Care

Dr. Schmidt. “If you think you don’t have glaucoma patients or glaucoma suspects, you’re not looking in the right places.”

It all comes down to making the decision to treat this disease in your practice. “You’ve gotta sit your staff down and say, ‘Hey, we’re going to embrace this disease,’ and then actually do it,” he said during his presentation.

Step Three: Stock the Toolbox

While your office does not need every bell and whistle to get started, Dr. Schmidt listed six main equipment needs for a glaucoma practice: visual field analyzer, pachymeter, fundus camera, OCT, gonioscopy lens and tonometer.

Fundus imaging. This is crucial for assessing the optic nerve for everything from thinning of the neuroretinal rim and deepening of the optic cup to nerve fiber atrophy, increased cupping and vessel changes, Dr. Schmidt said.

Visual fields. Although OCT’s ascendancy has made some question the continued value of this testing modality, it’s still standard of care, according to Dr. Schmidt. Clinicians can use standard automated perimetry (SAP), short wavelength automated perimetry (SWAP) or frequency doubling technology perimetry (FDT). While FDT and SWAP are similar in flagging abnormal locations, research shows FDT defects were more extensive in 62% of patients, he said. In addition, SWAP is more specific and accurate than SAP but harder to administer. Clinicians should use 10-2 SAP in advanced glaucoma, Dr. Schmidt further explained.

Pachymetry. This is “absolutely essential,” Dr. Schmidt said in his lecture. “Why? Because thick corneas may be protective.” Data shows 36% of patients with intraocular pressure (IOP) above 25.75mm Hg and corneal thickness below 555 μ m developed primary open-angle glaucoma (POAG); in contrast, only 6% of patients with the same IOP but corneal thicknesses greater than 588 μ m converted to POAG, he said—telling numbers.

While not yet standard of care, the Ocular Response Analyzer (ORA) from Reichert is a new tool that can take baseline pachymetry to the next level by assessing corneal hysteresis and providing more data for predicting progression.

“A fundus camera is essential, an OCT is now standard of care and directly after that, a device like the ORA is a great financial investment for the practice,” says Dr. Thimons. “It allows us to generate an immense amount of patient throughput on normal patients, so that when you have a patient that’s at risk, it adds an element of diagnostic capability that’s really quite remarkable.”

Tonometry. While this is must-have office equipment and you almost certainly already have this covered, new technology is inviting the patient into their glaucoma care

plan. Home IOP monitoring can provide practitioners data from peak pressure hours outside of the office, often informing and altering the treatment plan.

“I’d say 30% to 40% of these patients have a 5mm Hg difference between my highest IOP recording and what they found off-office hours with the device,” Dr. Thimons said during his own 2018 SECO presentation. It requires minimal patient training, and the additional data, printed in a clear graph after a few days of monitoring, adds valuable insight into peak pressure behavior, he added.

Gonioscopy. This is an invaluable skill to have when treating glaucoma patients, as it can help you differentiate the subtype. Unfortunately, two separate studies show that less than half of POAG patients underwent gonioscopy during their initial workup.^{2,3} A quick refresher on technique and some good old-fashioned practice can get you up to speed on using your gonio lens—and boosting your clinical care.

OCT. Once relegated to specialists, this is now widely considered standard of care for glaucoma.

“It’s simple: the OCT is worth the financial investment,” says Dr. Thimons. “Now we can do the pachymetry map and anterior segment high-density, and we can differentiate microns of change on the corneal surface. Investing in the base technology is the best thing you could do. At minimum it will make everything you do better; at maximum, it will significantly benefit your bottom line.” For a practice serious about detecting glaucoma early, OCT will be one of the most-used tools.

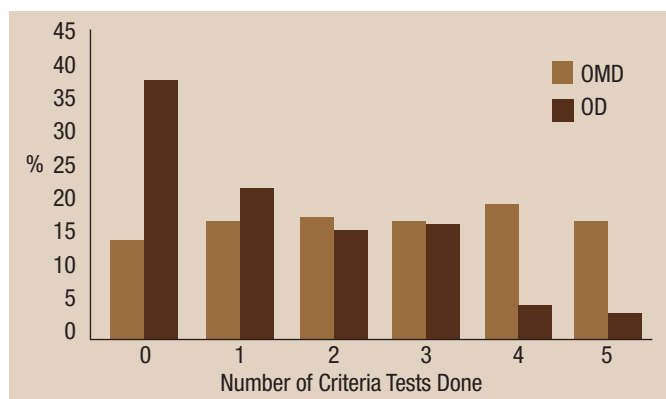


Table 2. Test profile by provider type, based on 2014 Centers for Medicare and Medicaid data.

Would you fit her in a standard diameter contact lens?



Meet Nina.

She has smaller than average size corneas. So if you put her in a standard diameter, the lens will not fit correctly which can compromise her comfort.

Fact is, 27% of patient corneas fall outside the norm. Don't put Nina, and patients like her, in a 'one size fits all' lens. Fit Extreme H2O specialty disposable soft contact lenses.

extremeH2O[®] 13.6

The right fitting solution for your disposable soft lens patients:

- Have small corneas or lid apertures
- Need easy insertion and removal
- Need a comfortable lens

Extreme H2O 13.6 is available in daily, weekly and monthly modalities to match her lifestyle and her pocketbook.

13.6 is just one example of how we cater to your needs. Challenge us to help you protect your contact lens practice. **Call X-Cel Specialty Contacts at 877.336.2482 today.**

With its high-resolution images and automated tracking of subtle optic nerve, retinal nerve fiber layer (RNFL), ganglion cell layer and macular thickness changes, OCT makes that all-important decision—to treat or not to treat?—easier.

“For early glaucoma diagnosis, our job is to sort out the suspects from early disease,” says Dr. Thimons. “When you look at the loss of the ganglion cell layer or even total macular thickness with OCT and you see that thinning, that’s a very good indicator to treat.”

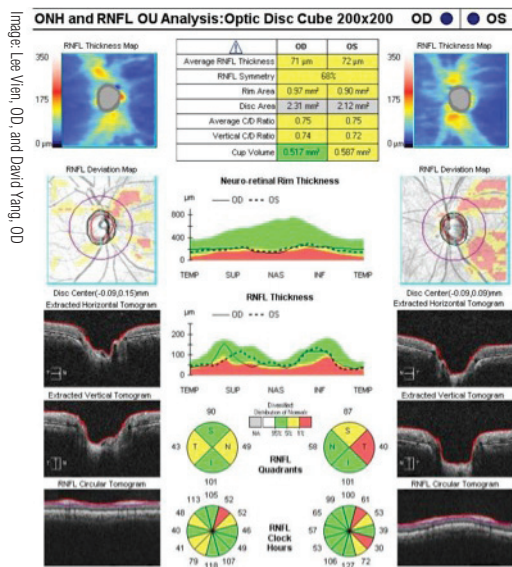
Dr. Schmidt lays it on the line: “I will go as far as to say that if you don’t have it, you probably can’t treat this disease,” he said.

Step Four: Hire Help

Perhaps one of the most accessible resources for building your glaucoma practice comes in the form of new practitioners graduating each year. They have robust classroom and clinical experience in diagnosing and treating glaucoma with some of the newer technologies and, most importantly, they’re passionate. This new talent should not be overlooked as a resource.

“If you ask graduates from our 23 optometry schools if they want to treat glaucoma or eye disease in the future, I think the vast majority of them would say yes,” says Michael Chaglasian, OD, president of the Optometric Glaucoma Society and associate professor at Illinois College of Optometry. “I don’t think they’re going through the hard training of the four-year program to say, ‘No, I just want to do glasses and contact lenses.’”

“We as optometrists need to be better advocates for glaucoma, pushing residencies in glaucoma and maybe offering better support



SD-OCT optic nerve head and RNFL analysis in a patient with early POAG. The right eye has movement with a motion artifact superiorly. Both eyes have RNFL loss borderline or outside normal limits compared with the normative database.

to those students during their residency, because we need them. We need them to lift glaucoma up,” says Dr. Schmidt. “Wherever a practice is on the spectrum of glaucoma care, we can all go up a notch.” And new grads can be a key player.

Step Five: Get Engaged

Treating glaucoma can be quite rewarding, and all it takes is the right approach. Discussing suspicions of the disease or a new diagnosis with your patient is a challenging, yet powerful conversation. This is an opportunity to connect, as your tone and demeanor can have an immense impact on the patient’s emotional stamina throughout their treatment process. Optometrists already have an established foundation of trust and familiarity with their patients, and the dynamic of the primary care practice lends itself well to this new journey.

“Having a chronic disease is like running a marathon with high

hurdles,” says Dr. Thimons. “You’re not just stepping forward; every once in a while you have to jump up and get over something. I try to be empathetic but supportive. The next level is being informative, and then I become an advocate. At every level, you need to try to diminish the hurdles in their path, because they’ll come.” That’s why optometrists are perfect for this job: they have the doctor-patient rapport necessary to coach patients through the care process.

Glaucoma patients will be back in your office often, perhaps every three weeks in some cases. Such sustained care, once considered a burden, is now viewed as an honor and a challenge.

“I’ve been treating glaucoma for 20 years now,” says Dr. Chaglasian, “and the needle of glaucoma care across the country really has not increased enough, there is still so much untapped opportunity for optometry. This shift will really require support and direction from organized optometry to help overcome the obstacles to a new model of more a disease-based eyecare model. It’s been very frustrating, and it’s time for significant reform.”

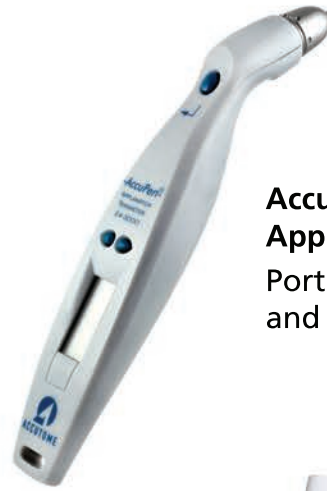You can be an agent of that change with just a few changes of your own: arm your practice with the right talent, equipment and understanding, and you can dramatically improve your patient’s life. And, maybe, optometry’s as well. ■

1. Swanson M. Glaucoma testing under the 2014 Medicare Part B Program. Presented at American Academy of Optometry’s Annual Meeting, October 11-14, 2017; Chicago, Ill.
2. Fremont AM. Patterns of care for open-angle glaucoma in managed care. Arch Ophthalmol. 2003;121(6):777-83.
3. Hertzog LH, Albrecht KG, LaBree L, Lee PP. Glaucoma care and conformance with preferred practice patterns. Examination of the private, community-based ophthalmologist. Ophthalmology. 1996;103(7):1009-13.

Tonometry Done Right



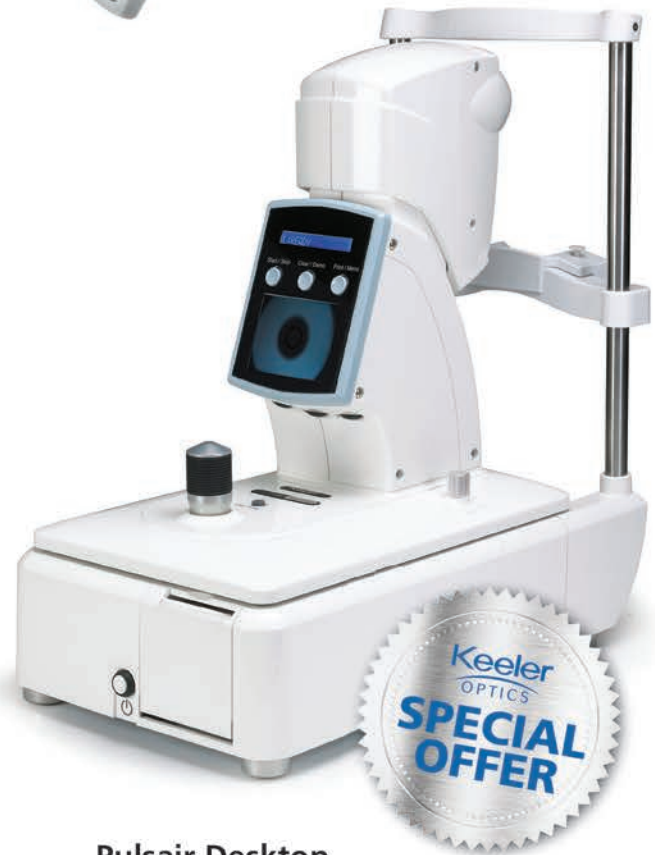D-KAT Digital
Keeler quality.



**AccuPen - Handheld
Applanation Tonometer**
Portable, versatile,
and easy-to-use.



Intellipuff
The standard for hand held mobility.



Pulsair Desktop
Smallest footprint and simple to use!

*Purchase a Pulsair Desktop by
June 30, 2018 and get a \$1,366
Instant Rebate!*

Buy Online!
keelerusa.com

Keeler
OPTICS



TEST.



RESULTS.

Include The Bruder Moist Heat Eye Compress In Your Dry Eye Treatment Protocol

It's a fact. More and more doctors are testing their patients for evidence of dry eye. Not surprising. With the incidence of this chronic disease on the rise, early treatment is important.

Whatever treatment strategy you plan for your patient, it should include the Bruder Moist Heat Eye Compress – recommended by more doctors than any other heat compress.

The patented compress provides a clinically proven treatment that helps relieve dry eye symptoms while improving overall ocular surface health.

The Bruder compress is an effective dry eye treatment that your patient takes home between visits to your office. It's easily incorporated into your patient's daily routine, increases compliance, and provides quick relief.

#1

#1 DOCTOR RECOMMENDED MOIST HEAT COMPRESS

Go to www.bruder.com/getresults-now to learn why more and more doctors are making dry eye an integral part of their practice. And why the 'Bruder Mask' is an important part of their treatment protocol.



MANAGING UVEITIS WITH STEROIDS AND BIOLOGIC AGENTS

The latest developments for this condition are based on underlying immunologic mechanisms. Here's what that means for your practice. **By Jessica Steen, OD**

Uveitis is a manifestation of approximately 30 diseases, which are characterized by intraocular inflammation—rather than a single disease process.¹⁻⁷ It can result from a wide range of underlying pathogeneses, such as infection, systemic disease or autoimmune dysfunction.¹⁻⁹ While acute anterior uveitis is the most common presentation of intraocular inflammation we manage, chronic intermediate or posterior uveitis is less responsive to conventional therapy and has greater potential for long-term vision

loss.¹⁻⁸ The goal of treatment of all forms of uveitis is to achieve remission, with complete withdrawal of steroid and biologic agents, without relapse. This can be a challenge in chronic disease states.^{5,10} While each disease may have a specific therapeutic target, our classic treatment approach to all forms of uveitis—once infection is ruled out or controlled—is to broadly suppress inflammation with a single group of therapeutics.

The impressive therapeutic potential of biologic agents to treat a wide range of ophthalmic conditions is

informing precision medicine in ophthalmic disease. Biologic agents are bioengineered complexes that alter expression of immunologic components of the immune system, including TNF- α inhibitors, anti-interleukins and interferon therapy.^{2,5,7} This article shows how an expanding appreciation of underlying pathogeneses of noninfectious uveitis—including improved understanding of genetic factors, cytokine expression and cellular characterization—is ushering in targeted biologic therapies for non-infectious uveitis.

Treatment and monitoring of

Release Date: May 2018

Expiration Date: April 12, 2021

Goal Statement: New research is lauding the potential of bioengineered complexes designed to cater to individual patients and alter their immune systems to respond to a variety of pathologies. This article explains how those techniques can target uveitis and how steroids can be used to help these patients; it also provides a detailed explanation of various types of uveitis and the mechanisms behind its development.

Faculty/Editorial Board: Jessica Steen, OD

Credit Statement: This course is COPE approved for 2 hours of CE credit. Course ID is **57600-AS**. Check with your local state licensing board to see if this counts toward your CE requirement for relicensure.

Disclosure Statements:

Authors: The author has no relationships to disclose.

Editorial staff: Jack Persico, Rebecca Hepp, William Kekevan and Michael Iannucci all have no relationships to disclose.

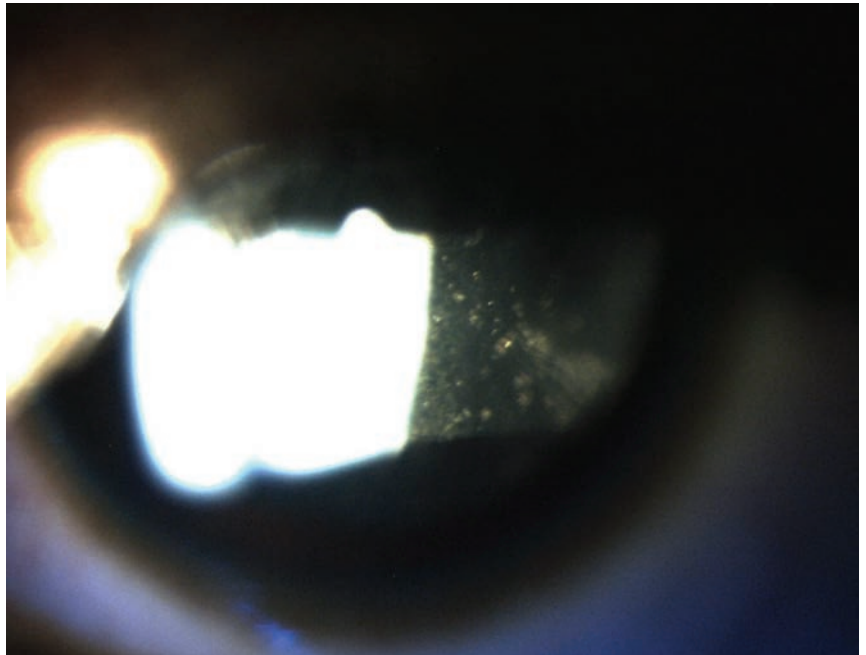
patients receiving biologic therapy for uveitis requires a multispecialty approach.^{1,4,5} However, every optometrist should have a grasp of biologic therapy for the treatment of noninfectious uveitis to best prepare for comanagement.

Long-term Steroids

While topical steroids are typically sufficient to control and resolve acute noninfectious anterior uveitis, and may be beneficial in treating intermediate uveitis in pseudophakic, aphakic or vitrectomized patients, periocular and systemic steroids are often needed for treatment of intermediate and posterior uveitis.^{1-3,5,7}

Periocular steroids, including intravitreal injections and sustained-delivery implants, are effective for suppression of intraocular inflammation due to non-infectious uveitis.^{10,11} Despite their efficacy, all steroids can cause local adverse effects that can include cataract formation, elevated intraocular pressure (IOP), delayed healing and secondary infection development.^{1,5,10,11}

Intravitreal steroid options include Kenalog (triamcinolone acetonide, Clint Pharmaceuticals) or Triesence (triamcinolone acetonide preservative-free, Alcon). While both are effective, only Triesence is approved by the FDA for intraocular use. Sustained-release intravitreal implants Ozurdex (dexamethasone 0.7mg, Allergan), Retisert (fluocinolone acetonide 0.59mg, Bausch + Lomb) and the insert Iluvien (fluocinolone acetonide 0.19mg, Alimera) may be effective for up to six months, 30 months and three years, respectively.^{10,11} While intravitreal steroids are effective in suppressing intraocular inflammation, the Multicenter Uveitis Steroid Treatment (MUST) trial determined that patients with chronic uveitis saw improved visual



This image show anterior vitreous cells in a patient with pars planitis.

outcome with systemic immunosuppressive therapy compared with Retisert implant alone through seven years of follow up.¹²

In patients for whom inflammation cannot be controlled locally (a typical problem for those with posterior uveitis and panuveitis), systemic immunosuppression is necessary. Prednisone, given orally or intravenously, is effective for short-term control of inflammation.^{1,2,5,10} For patients with chronic uveitis that requires years of immunosuppression, significant systemic side effects, including elevated blood pressure, blood glucose dysfunction, gastrointestinal ulceration, fluid retention, osteoporosis and neuropsychiatric effects, make long-term treatment with steroids unpleasant—and typically unfeasible.¹⁰

Given the inability to treat chronic inflammation with systemic steroid agents, conventional non-corticosteroid immunosuppressive agents—also referred to as disease-modifying antirheumatic drugs (DMARDs)—or antimetabolites

including methotrexate, azathioprine and mycophenolate mofetil have been used adjunctively to minimize systemic steroid treatment.^{5,7,8,10} In general, DMARDs are administered orally and act to suppress the entire immune system, as compared with biologic agents which are generally administered by subcutaneous injection or intravenous infusion and target specific locations within the inflammatory cascade.^{1,8,10} Effectiveness of conventional DMARDs may take months to determine.^{8,10,14} Each medication carries specific side effects, which include bone marrow suppression and liver toxicity.^{8,10} In rheumatologic disease, research shows, biologic agents such as TNF- α inhibitors and interleukin blockers are often more effective than traditional DMARDs alone.¹⁴

Contemporary management of noninfectious uveitis favors aggressive treatment early in the disease course, especially for chronic or relapsing uveitis cases.¹

Doctors frequently use biologic agents, either alone or in

combination with steroids or traditional DMARDs, to control inflammation and to prevent associated vision-threatening consequences including macular edema, optic nerve disease or exudative retinal detachment.^{1,5,8,15}

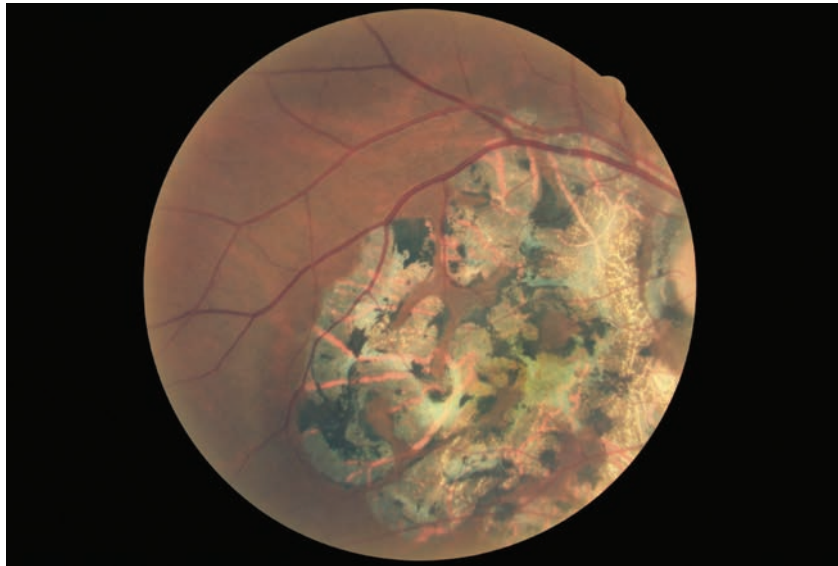
Biologic agents, while technically DMARDs, are bio-engineered complexes which target specific immunologic modulators, which are either up- or down-regulated in

uveitis.^{2,5,7,8,10} Inflammatory components of the immune system—which include regulatory T-lymphocytes that produce cytokines such as TNF- α and interleukins—can be targeted at various levels to suppress downstream inflammation.^{2,5,6,10,16} Available treatments focus on inflammatory targets, which often overlap in uveitis cases.^{6,10,16}

Biologic agents have been successfully used to treat rheumatologic conditions such as rheumatoid arthritis, plaque psoriasis, Crohn's disease and ankylosing spondylitis; however, only a few specific groups of immune mediators are effective in uveitis treatment.^{8,10,14,17} All biologic agents currently available were developed for conditions other than uveitis, so the challenge to applying these therapies is determining the appropriate dosage for an adequate therapeutic response.^{2,8} A higher dosage at more frequent intervals is often required for control of uveitis.¹⁶

TNF- α Inhibitors

The most common biologic agents used in the treatment of uveitis are TNF- α inhibitors.^{1,2} TNF- α is a



This fundus photograph of inactive serpiginous choroiditis shows classic RPE and retinal atrophy.

pro-inflammatory signaling protein, which is expressed in uveitis.^{8,10,16,18} TNF- α interacts with membrane receptors which, when activated, may signal apoptosis, activation or proliferation.^{16,18} In the normal state, typically no detectable level of TNF- α exists in the aqueous and vitreous humor.^{10,16} Elevated serum TNF- α is found in cases of inflammation—including inflammation due to trauma or immune-mediated processes.¹⁶ Currently available TNF- α inhibitors block various portions of the TNF- α pathway.¹⁰

Blocking a specific cytokine (e.g., signaling molecule), results in decreased immune response and often has secondary effects on other immunological pathways, which can cause significant adverse events.¹⁸ Adverse drug effects of TNF- α inhibitors include unmasking or inducing demyelinating disease, such as multiple sclerosis (MS), reactivation of latent tuberculosis, or viral hepatitis, auto-antibody formation and systemic lupus erythematosus.^{1,16,18} Additionally, the literature shows some controversy over a potential increased risk of

lymphoma in patients with rheumatoid arthritis and pediatric Crohn's disease.¹⁵

Prior to initiation of therapy, patients must undergo a complete physical evaluation to establish baseline organ function and rule out associated systemic

inflammatory disease and infection.^{1,4} Risk of malignancy should also be assessed.^{1,15,29} Patients should have a baseline complete blood count with differentiation, purified protein derivative testing and chest radiograph to ensure no latent tuberculosis infection.^{4,15} MS can be exacerbated or induced by TNF- α inhibition.¹ As pars planitis is associated with MS, pre-treatment magnetic resonance imaging (MRI) must be considered to rule out demyelinating disease, especially for patients with intermediate uveitis.^{1,6,15}

While undergoing treatment with TNF- α inhibitors, serologic evaluation including a complete blood count with differential and metabolic panel, may be ordered monthly for the first three months of treatment and every two to four months afterwards.¹⁶

While many TNF- α inhibitors have been studied for the treatment of noninfectious uveitis, two common ones, Remicade (infliximab, Janssen Biotech) and Humira (adalimumab, Abbvie), have recently been recommended by an expert panel as first-line immunomodulatory

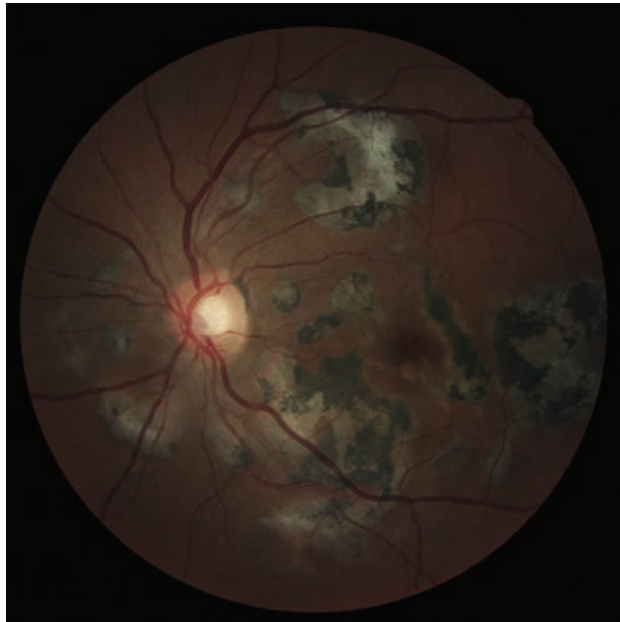
treatment in Behçet's disease.¹⁸

Remicade is given as an intravenous infusion to suppress inflammation by binding to free and membrane-bound TNF- α to block activation, thereby reducing downstream inflammation.^{18,20} The majority of studies of infliximab in uveitis are in patients with JIA- and Behçet's-associated uveitis due to the need for long-term treatment and the vision-threatening nature of the sequelae of chronic uveitis.^{8,18,21} In Behçet's-associated uveitis, complete remission was achieved with infliximab alone in 86% of patients.^{1,5} Inflammation

control was achieved in as little as two weeks, which was more rapid than treatment with intravenous corticosteroid or intravitreal triamcinolone alone.²¹

Humira is an FDA-approved biologic agent for the treatment of noninfectious uveitis and is indicated for intermediate, posterior and panuveitis in adults.¹⁸ Researchers believe adalimumab has less immunologic activity than infliximab due to its chemical structure. It blocks the inflammatory cascade by binding soluble and membrane-bound TNF- α .^{13,15,16,18} Off label, research shows an additional benefit in controlling anterior segment inflammation in patients with ankylosing spondylitis.¹⁷ Adalimumab is administered subcutaneously, although it is currently undergoing trials for intravitreal administration.²³

Safety of treatment with TNF alpha inhibitors such as infliximab and adalimumab has not been evaluated in pregnant patients; however, they are considered to be pregnancy category B agents by the FDA.^{6,18}



Fundus photograph of inactive serpiginous choroiditis shows retinal atrophy and RPE hyperpigmentation.

While TNF- α inhibitors share a similar mechanism of action, effectiveness in controlling intraocular inflammation of one agent does not necessarily mean that all agents will be equally effective.

Enbrel (etanercept, Amgen) is an isoform of the TNF receptor that inhibits inflammation through blockage of TNF- α and TNF- β from binding to the active TNF receptor.^{16,18} Although etanercept is effective in controlling inflammation in systemic conditions, it has shown no benefit in improving intraocular inflammation compared with placebo, and there is some, although limited, evidence that etanercept may induce uveitis and sarcoid-like disease.^{1,2,6,18}

Non-TNF- α Inhibitors

Researchers are exploring non-TNF- α inhibitors such as Rituxan (rituxumab, Genentech), type I interferons and Orencia (abatacept, Bristol-Myers Squibb) for the treatment and management of noninfectious uveitis.

Rituxan is administered intravenously and binds to CD20 on B-cells, resulting in a combination of downstream effects including B-cell elimination, which permits their natural replacement.²⁴ In addition to being approved for the treatment of certain forms of leukemia and lymphoma, it is often used as an off-label treatment for refractory cases of systemic lupus erythematosus and for uveitis due to juvenile idiopathic arthritis.^{6,24} Uncommon but potentially life-threatening side effects include progressive multifocal leukoencephalopathy, which results in progressive, irreversible white

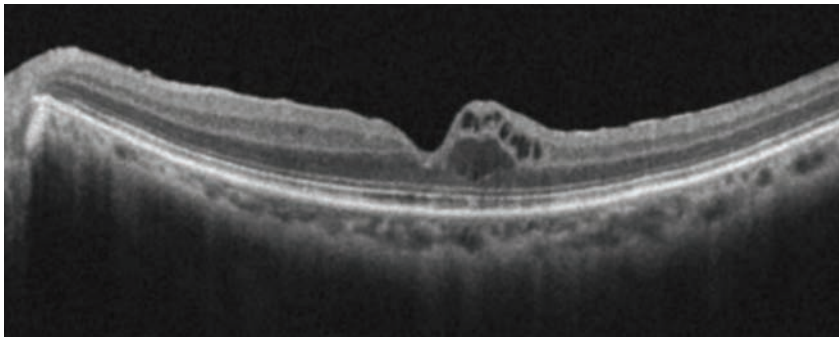
matter destruction.²⁴

Type I interferons, including interferon alpha 2a, alpha 2b and interferon beta are effective in decreasing inflammation in Behçet's-associated uveitis and intermediate uveitis associated with MS.^{5,10} Type I interferons increase the production of regulatory T-cells, which helps to keep the immune response in check.⁶ While interferon drugs may result in flu-like symptoms and depression, they are not associated with unmasking of demyelinating disease or reactivation of latent tuberculosis.^{5,10}

Orencia is a biologic agent under investigation for the control of inflammation in uveitis. It suppresses inflammation by binding to CD80 and CD86 receptors on antigen presenting cells, which downregulates T-cell activation and reduces the immune response.⁶

Interleukin Blockers

Cosentyx (secukinumab, Novartis) is an interleukin blocker used for the treatment of psoriasis, ankylosing spondylitis and psoriatic arthritis.⁷



Cystoid macular edema, seen here using OCT, is frequently observed in uveitis patients.

Secukinumab binds and blocks IL-17A, which is present in high levels in Behçet's disease, but in low levels in healthy patients.^{1,25} Secukinumab is most effective intravenously, but it is not currently recommended for the treatment of non-infectious uveitis due to the limited data to support its use.^{1,25}

Researchers are investigating other agents, including daclizumab, gevokizumab and tocilizumab, due to their theoretical potential to reduce inflammation in uveitis.^{2,26}

Calling it Like it Is

A contemporary approach to uveitis diagnosis begins with a careful history and review of systems and a clinical examination that includes a dilated fundus examination and ancillary testing, when necessary.⁴

A proper dilated fundus examination can rule out masquerade syndromes and secondary causes of presumed inflammation.¹⁹ Many nonuveitic conditions can present clinically as a red eye with anterior chamber cell and flare, including leukemia and intraocular foreign body.^{4,19} Pigmented retinal epithelial cells in the anterior vitreous due to peripheral retinal break may appear as vitreous haze.¹⁹ Uveal melanoma can give rise to cells and flare due to breakdown of the blood-retinal barrier and leakage of proteins.^{4,19}

The standardization of nomenclature in uveitis was developed

to accurately and consistently describe features of uveitis amongst clinicians.²⁷ It takes into account a description of the uveitis, including location of the primary site of inflammation, onset (sudden or insidious), laterality, duration (limited or persistent) and course (acute, chronic or recurrent) based on history of the condition and clinical characteristics.^{4,19,27}

Sudden-onset uveitis is considered to be acute when a single episode is of limited duration, lasting less than three months.²⁷ Chronic uveitis will relapse as soon as treatment is discontinued.⁴ In anterior uveitis, if topical steroid treatment is withdrawn, or tapered too quickly, a true acute form of uveitis may appear to be chronic.¹⁰

Intraocular inflammation is best treated aggressively, and topical ocular steroids should not be tapered until there is complete resolution of the inflammation—that is, no cells, flare or conjunctival hyperemia. Chronic disease is likely to have insidious onset and be persistent in duration.^{4,27} These particular cases typically require systemic immunosuppressive therapy due to the inability to control inflammation adequately with local treatment alone.^{4,10}

Recurrent acute uveitis episodes are separated by a period of quiescence of at least three months before recurrence.^{4,10,27} Patients with recur-

rent, acute uveitis only require treatment during an active episode.⁴

Uveitis may be unilateral, alternating or bilateral.^{4,27} Identifying cases of bilateral asynchronous disease—where one eye is affected first, then the other becomes involved—is key as they are often associated with chronic ocular or systemic disease.^{4,27}

Anatomic description of uveitis is based on the location of primary inflammation.^{4,27} In anterior uveitis, the primary site of iris and ciliary body inflammation is manifested in the anterior chamber, but there may be “spill-over” inflammation behind the lens into the anterior vitreous.²⁷ Intermediate uveitis, which includes pars planitis, is characterized by signs of inflammation, primarily in the vitreous, clinically observed as vitreous haze.²⁷ It is important to recall that inflammation can also “spill-over” from the vitreous into the anterior chamber. Findings common in anterior uveitis, such as posterior synechiae and peripheral anterior synechiae, are not likely to be found in intermediate uveitis.^{4,27} If synechiae are observed in what appears as an intermediate uveitis, there is likely to be a second, primary site of inflammation in the anterior segment. Posterior uveitis includes involvement of the retina and/or choroid and can be classified as retinitis, choroiditis, retinal vasculitis or neuroretinitis. Panuveitis includes inflammation throughout the eye.²⁷

For anterior uveitis, clinical features revealed by a careful case history and close examination of the anterior segment will assist in making the correct diagnosis. For example, the presence of a hypopyon puts both Behçet's disease and HLA-B27-associated uveitis high on the list of differential diagnoses.^{3,4,7} In patients with recurrent, acute onset unilateral or unilateral

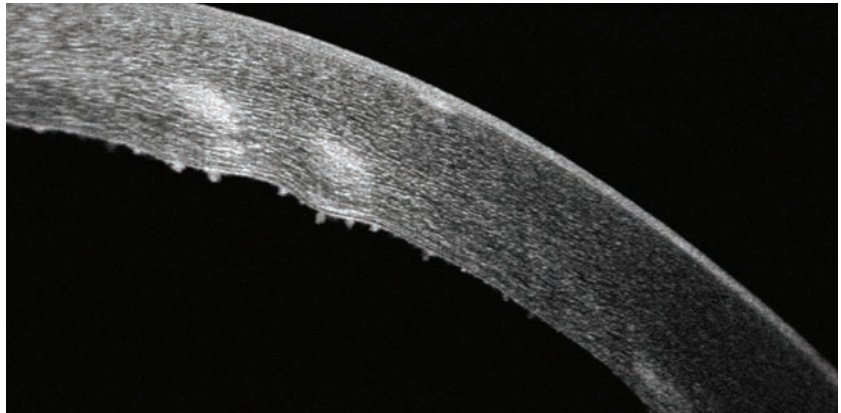
alternating uveitis, an underlying spondylarthropathy is likely.^{4,17} Heterochromia, iris atrophy and diffuse, stellate keratic precipitates will guide the diagnosis towards Fuch's heterochromic uveitis.^{3,4}

With a case description based on history, review of systems and clinical findings, we can guide our laboratory evaluation, if necessary, from differential diagnosis.

Narrowing Down the Cause

Infectious causes of uveitis include tuberculosis, Lyme disease, cytomegalovirus, syphilis and herpes.^{3,4,6} Each has varied clinical features, relevant historical features and potential systemic findings that patients should be queried for through a careful history and targeted review of systems.⁴ Identification of an infectious cause will guide the course of treatment—which may include anti-inflammatory agents, including biologic agents, once infection is under control—to prevent inflammatory damage from the disease.^{1,8}

Noninfectious causes of uveitis may be associated with systemic diseases including sarcoidosis, Behçet's disease, Vogt-Koyanagi-Harada syndrome, ankylosing spondylitis and juvenile idiopathic arthritis (JIA).^{4,6,8,17,28,29} While angiotensin-converting enzyme (ACE) may be elevated in sarcoidosis, it has a low positive predictive value (22%), which limits its utility as a screening tool.^{4,29} A review of systems that focuses on specific organ systems including lungs, skin and reticuloendothelial system (liver, spleen, lymph nodes), will help to guide your diagnostic approach.^{4,29} In diseases such as Behçet's disease and Vogt-Koyanagi-Harada syndrome, the diagnosis is made on clinical features, as no diagnostic laboratory studies exist. Risk factors for "masquerade syndromes" in uveitis should always be considered.^{2,4,19}



Keratic precipitates are visible on the corneal endothelium with SD-OCT imaging.

In many cases of uveitis, an underlying cause will not be determined.^{1,4,6} After the completion of a careful clinical examination, ancillary testing and indicated laboratory work, in the absence of infection, neoplasm or systemic disease, uveitis may be determined undifferentiated.⁴ The traditional term, "idiopathic," which we may be more familiar with, is a less precise descriptor. Undifferentiated noninfectious uveitis can be understood to be due to an inappropriate immune system response to an inflammatory trigger and, as such, is not truly idiopathic.^{4,6} Complete remission of undifferentiated forms of uveitis is possible through a presumed re-education process of the immune system.^{2,5,7}

The diagnostic approach to uveitis should consider each form of the condition to be separate, but with overlapping features.⁴ Each case of uveitis should be approached carefully and systematically so focused laboratory or ancillary testing can be obtained when indicated.

Literature Prevalence

The literature evaluating the efficacy of specific biologic agents is dominated by two specific conditions: Behçet's disease and JIA. These two conditions manifest quite differently, but share similar sequelae of uveitis including vision loss due to macular

edema, choroidal neovascularization and hypotony.^{18,28,30,31} They both also require chronic immunosuppression due to the nature of disease. JIA-associated uveitis involves patients younger than 16, and Behçet's disease uveitis typically affects working-age patients.^{28,30,31} As such, the need for effective, steroid-sparing therapies make biologic agents a promising group of treatments for the prevention of vision loss in the school and working population.

Behçet's disease is presumed to be a result of a significant systemic inflammatory response.³¹ No specific laboratory test exists to confirm the diagnosis; rather, diagnosis is based on the presence of disease manifestations including oral lesions, urogenital ulcerations, skin nodules—most commonly on the lower extremities—and uveitis classically characterized with the presence of hypopyon.^{22,25,31} Uveitis associated with Behçet's disease typically takes on a relapsing and remitting course that affects the anterior or posterior segment.^{18,22,25,31} A positive pathergy test, which indicates hypersensitivity to minor trauma, may aid in the diagnosis of Behçet's disease; however, due to low sensitivity, especially in the North American population, a positive pathergy test is not required for diagnosis.²⁵

JIA is a group of conditions that result in arthritis lasting more than six weeks in children younger than 16.^{18,28,30} The number of joints affected, presence of fever and skin rash and laboratory results help classify JIA.^{28,30} These conditions have varying serological findings including potential rheumatoid factor positivity, HLA-B27 positivity and ANA positivity.^{28,30} Patients who have high ANA and who have an earlier age of onset of arthritis are more likely to develop uveitis.^{28,30}

In JIA, the most common presentation of uveitis is bilateral insidious onset, chronic anterior uveitis.^{4,28,30} Treatment with biologic agents in uveitis patients has been frequently the target of study due to the condition's profound potential for vision loss from secondary complications including macular edema, band keratopathy, uveitic glaucoma and hypotony, resulting in poor visual prognosis.^{18,28,30} As this condition manifests in childhood, vision loss has profound impact on the patient's life.

Precision Medicine

Currently, systemic biologic agents are generally used off-label as second-line therapy for control of inflammation in patients with noninfectious uveitis who are not controlled with corticosteroids alone.^{1,7,10} Access to biologic agents can be challenging due to lack of FDA support for the majority of available treatments. General treatment trends in chronic uveitis are evolving from high-dose corticosteroids with delayed antimetabolites, to earlier adoption of biologic agents, with limited corticosteroid use.^{1,10}

The best route of administration of biologic agents in chronic noninfectious uveitis, particularly intermediate, posterior and panuveitis, is still uncharted. While intravitreal or

Data Interpretation Challenges

Clinical relevance of studies that evaluate efficacy of biologic agents in uveitis is often difficult to determine.⁶ The rarity of the conditions being studied means trials are often limited to small cohorts and are often retrospective in nature.⁶ Many of the available studies use a range of inclusion criteria, including different forms of underlying causes of uveitis, as well as outcome measures—making it difficult to directly compare results and apply findings to a broader population.^{6,9}

local therapy seems logical to ensure high-dose treatment to the specific structures affected and minimizing systemic effects, uveitis is considered secondary to an abnormal systemic immune reaction and, as such, systemic therapy may be necessary for effective treatment.⁶

Underlying pathogenesis of uveitis varies greatly. Specific immune targets may be central to the inflammatory cause in one disease state, but minimally important in another. The challenge is applying immunological mechanisms to complex, multifactorial diseases in an effort to achieve a predictable, repeatable response.¹⁶

While non-corticosteroid treatment options exist, many more are in the pipeline. For now, an informed individualized approach to the treatment of uveitis that best suits a particular patient's disease course takes into account the cause of uveitis, systemic comorbidities and previous therapies. The not-so-distant future of uveitis management will involve a precision approach, which will focus on particular pathway targets in complex disease states in a specific genetic environment to determine optimal treatments. ■

Dr. Steen is an attending optometrist and assistant professor of ocular pharmacology at Nova Southeastern University's College of Optometry.

- Dick AD, Rosenbaum JT, Al-Dhibi HA, et al. Guidance on noncorticosteroid systemic immunomodulatory therapy in non-infectious uveitis. Fundamentals of care for Uveitis (FOCUS) Initiative. *Ophthalmology*. 2018 Jan 6. [Epub ahead of print].
- Schwartzman S, Schwartzman M. The use of biologic therapies in uveitis. *Clinic Rev Allergy Immunol*. 2015;49:307-316.
- Jabs DA, Dick A, Doucette JT. Interobserver agreement among uveitis experts on uveitic diagnoses: the Standardization of Uveitis Nomenclature experience. *Am J Ophthalmol*. 2018;186:19-24.
- Jabs DA, Busingye J. Approach to the diagnosis of the uveitides. *Am J Ophthalmol*. 2013;156:228-236.
- Sharma SM, Fu DJ, Xue K. A review of the landscape of targeted immunomodulatory therapies for non-infectious uveitis. *Ophthalmol Ther*. 2017 Nov 30 [Epub ahead of print].
- Lin P, Suhler EB, Rosenbaum JT. The future of uveitis treatment. *Ophthalmology*. 2014;121:365-376.
- Jabs DA. Immunosuppression for the uveitides. *Ophthalmology*. 2018;125:193-202.
- Pasadhika S, Rosenbaum JT. Update on the use of systemic biologic agents in the treatment of noninfectious uveitis. *Biologics*. 2014;8:67-81.
- Burkholder BM, Ramulu PY. Improving more than just vision in noninfectious uveitis. *JAMA Ophthalmol*. 2017;135:518-519.
- Foster CS, Kothari S, Anesi SD, et al. The Ocular Immunology and Uveitis Foundation preferred practice patterns of uveitis management. *Surv Ophthalmol*. 2016;61:1-17.
- Cabrera M, Yeh S, Albin TA. Sustained-release corticosteroid options. *J Ophthalmol*. 2014; 2014:164692.
- The Multicenter Uveitis Steroid Treatment (MUST) Trial and Follow-up Study Research Group. Association between long-lasting fluocinolone acetonide intravitreal implant vs. systemic anti-inflammatory therapy and visual outcomes at seven years among patients with intermediate, posterior, or panuveitis. *JAMA*. 2017;317:1993-2005.
- Cordero-Coma M, Calleja-Antolin S, Garzo-Garcia I, et al. Adalimumab for treatment of noninfectious uveitis: immunogenicity and clinical relevance of measuring serum drug levels and antidrug antibodies. *Ophthalmology*. 2016;123:2618-2625.
- Jones G, Sebba A, Gu J, et al. Comparison of tocilizumab monotherapy versus methotrexate monotherapy in patients with moderate to severe rheumatoid arthritis: the AMBITION study. *Ann Rheum Dis*. 2010;69:88-96.
- Wakefield D, McCluskey P, Wildner G, et al. Inflammatory eye disease: pre-treatment assessment of patients prior to commencing immunosuppressive and biologic therapy: recommendation from an expert committee. *Autoimmun Rev*. 2017;16:213-222.
- Cordero-Coma M, Sobrin L. Anti-tumor necrosis factor-alpha therapy in uveitis. *Surv of Ophthalmol*. 2015;60:575-89.
- Fabiani C, Vitale A, Lopalco G, et al. Different roles of TNF inhibitors in acute anterior uveitis associated with ankylosing spondylitis: state of the art. *Clin Rheumatol*. 2016;35:2631-2638.
- Levy-Clarke, Jabs D, Read R, et al. Expert-panel recommendations for the use of anti-tumor necrosis factor biologic agents in patients with ocular inflammatory disorders. *Ophthalmology*. 2014;121:785-96.
- Grange LK, Kouchouk A, Dalal MD, et al. Neoplastic masquerade syndromes in patients with uveitis. *Am J Ophthalmol*. 2014;157:526-531.
- Maleki A, Sahawneh HF, Ma L, et al. Infliximab therapy in patients with noninfectious intermediate uveitis resistant to conventional immunomodulatory therapy. *Retina*. 2017;37:836-843.
- Markomichelakis N, Delicha E, Masselos S, et al. A single infliximab infusion vs corticosteroids for acute panuveitis attacks in Behçet's disease: a comparative 4-week study. *Rheumatology (Oxford)*. 2011;50:593-597.
- Sakai T, Watanabe H, Kuroyanagi K, et al. Health- and vision-related quality of life in patients receiving infliximab therapy for Behçet uveitis. *Br J Ophthalmol*. 2013;97:338-342.
- Kheir WJ, Mehanna CJ, Fattah MA, et al. Intravitreal adalimumab for the control of breakthrough intraocular inflammation. *Ocular Immun Inflamm*. 2017 Sep 14:1-6. [Epub ahead of print].

24. Lasave AF, You C, Ma L, et al. Long-term outcomes of rituximab therapy in patients with noninfectious posterior uveitis refractory to conventional immunosuppressive therapy. *Retina*. 2018;38:395-402.

25. Rokutanda R, Kishimoto M, Okada M. Update on the diagnosis and management of Behçet's disease. *Open Access Rheumatol*. 2015;7:1-8.

26. Mesquida M, Molins B, Llorens V, et al. Twenty-four month follow-up of tocilizumab therapy for refractory uveitis-related macular edema.

Retina. 2017 May 16. [Epub ahead of print].

27. Jabs DA, Nussenblatt RB, Rosenbaum JT. Standardization of uveitis nomenclature for reporting clinical data. Results of the First International Workshop. *Am J Ophthalmol*. 2005;140:509-16.

28. Prakken B, Albani S, Martini A. Juvenile idiopathic arthritis. *Lancet*. 2011;377:2138-49.

29. Iannuzzi MC, Fontana JR. Sarcoidosis: clinical presentation, immu-

nopathogenesis, and therapeutics. *JAMA*. 2011;305:391-9.

30. Tugal-Tutkun I, Quartier P, Bodaghi B. Disease of the year: juvenile idiopathic arthritis associated uveitis—classification and diagnostic approach. *Ocul Immunol Inflamm*. 2014;22:56-63.

31. McNally TW, Damato EM, Murray PI, et al. An update on the use of biologic therapies in the management of uveitis in Behçet's disease: a comprehensive review. *Orphanet J Rare Dis*. 2017;12:130.

OSC QUIZ

You can obtain transcript-quality continuing education credit through the Optometric Study Center. Complete the test form and return it with the \$35 fee to: Jobson Medical Information, Dept.: Optometric CE, 440 9th Avenue, 14th Floor, New York, NY 10001. To be eligible, please return the card within one year of publication. You can also access the test form and submit your answers and payment via credit card at *Review of Optometry* online, www.reviewofoptometry.com/ce.

You must achieve a score of 70 or higher to receive credit. Allow four weeks for processing. For each Optometric Study Center course you pass, you earn 2 hours of transcript-quality credit from Pennsylvania College of Optometry and double credit toward the AOA Optometric Recognition Award—Category 1.

Please check with your state licensing board to see if this approval counts toward your CE requirement for relicensure.

- Recurrent uveitis episodes are separated by a period of quiescence of at least _____.
 - One week.
 - One month.
 - Three months.
 - Six months.
- Behçet's disease is commonly characterized by:
 - Positive ANA, uveitis and nodules on the lower extremities.
 - Elevated ACE, uveitis and nodules on the lower extremities.
 - Positive HLA-B27, uveitis and nodules on the lower extremities.
 - Uveitis, nodules on the lower extremities and mucosal ulcers.
- Alternative therapies for the treatment of chronic uveitis are needed as:
 - Side effects of long-term steroids are often intolerable.
 - Systemic steroids do not reduce inflammation in uveitis.
 - Conventional DMARDs are more effective in

treating uveitis than steroids.

d. In the majority of patients with chronic uveitis, there is no need for alternatives to steroid therapy.

4. Which of the following is an infectious cause of uveitis?

- Sarcoidosis.
- Ankylosing spondylitis.
- Vogt-Koyanagi-Harada syndrome.
- Syphilis.

5. Which of the following is true regarding conventional DMARDs and biologic agents?

- Biologic agents are typically administered orally.
- Conventional DMARDs may be efficacious after a single dosage.
- Biologic agents target a specific location within the immune system.
- An example of a conventional DMARD is etanercept.

6. When treating unilateral sudden onset, acute anterior uveitis:

- Biologic agents should always be considered as a first-line therapy.
- Patients should first undergo a complete serological evaluation to evaluate for infectious and noninfectious causes, and underlying malignancy.
- Topical steroids should not be tapered until complete resolution of all signs of active inflammation.
- Dilation is not necessary unless visual acuity is reduced.

7. Which of the following agents is currently FDA approved for the treatment of noninfectious uveitis?

- Adalimumab.
- Etanercept.
- Infliximab.
- Rituximab.

8. JIA-associated uveitis is typically:

- Sudden onset.
- Limited to the posterior segment.
- Insidious onset.

d. Uveitis is uncommon in patients with JIA.

9. Presence of hypopyon may be characteristic of what underlying systemic condition?

- Sarcoidosis.
- Behçet's disease.
- JIA.
- Hypopyon does not occur in uveitis.

10. The preferred contemporary term for uveitis that cannot be attributed to an underlying condition is:

- Idiopathic.
- Undifferentiated.
- Unknown.
- Uncharted.

11. Advantages of an intravitreal implant or insert compared with intravitreal injection include:

- Sustained release of steroid.
- Shorter duration of action.
- Less risk of adverse event.
- Smaller needle.

12. Pars planitis is a form of:

- Anterior uveitis.
- Intermediate uveitis.
- Posterior uveitis.
- Panuveitis.

13. The general concept of biologic therapy is to:

- Broadly suppress systemic inflammation.
- Use immunologic agents to act on specific immune system targets to alter the immune response.
- Block the production of arachidonic acid.
- Block the production of cyclooxygenase.

14. In a patient with chronic intermediate uveitis who wishes to become pregnant, the most appropriate therapy may be:

- Leflunomide.
- Adalimumab.
- Methotrexate.
- Azathioprine.

OSC QUIZ

15. Which steroid-sparing treatment may be safe and effective in a patient with multiple sclerosis and concomitant intermediate uveitis?
- Adalimumab.
 - Interferon alpha 2a.
 - Infliximab.
 - Etanercept.
16. Which of the following are features of the standardization of nomenclature in uveitis?
- Location of the primary site of inflammation.
 - Onset.
 - Laterality.
 - All of the above.
17. Side effects of TNF- α inhibitors include:
- Reactivation of latent tuberculosis.
 - Unmasking of MS.
 - Development of lupus erythematosus.
 - All of the above.
18. Which of the following is true regarding Triescence?
- It is not FDA approved for intraocular use.
 - It is less effective than Kenalog.
 - It is a preservative-free formulation of triamcinolone acetonide.
 - It may be effective for up to three years following intravitreal injection.
19. Adalimumab is FDA approved for noninfectious uveitis through which route of administration?
- Periocular injection.
 - Subcutaneous injection.
 - Intravenous infusion.
 - Intravitreal injection.
20. Which of the following is true regarding TNF- α inhibitors?
- Abatacept and secukinumab are examples of TNF- α inhibitors.
 - They are all administered subcutaneously.
 - Infliximab has shown to be effective in patients with Behçet's-disease associated uveitis.
 - They are only effective in controlling inflammation in posterior uveitis.



TAKE THE TEST ONLINE TODAY!
[www.reviewofoptometry.com/
continuing_education/](http://www.reviewofoptometry.com/continuing_education/)

Examination Answer Sheet

Managing Uveitis with Steroids and Biologic Agents Valid for credit through April 12, 2021

Online: This exam can be taken online at www.reviewofoptometry.com/ce. Upon passing the exam, you can view your results immediately and download a real-time CE certificate. You can also view your test history at any time from the website.

Directions: Select one answer for each question in the exam and completely darken the appropriate circle. A minimum score of 70% is required to earn credit.

Mail to: Jobson Medical Information, Dept.: Optometric CE, 440 9th Avenue, 14th Floor, New York, NY 10001.

Payment: Remit \$35 with this exam. Make check payable to Jobson Medical Information LLC.

Credit: This course is COPE approved for 2 hours of CE credit. Course ID is 57600-AS.

Sponsorship: This course is joint-sponsored by the Pennsylvania College of Optometry.

Processing: There is a four-week processing time for this exam.

Answers to CE exam:

- A B C D
- A B C D
- A B C D
- A B C D
- A B C D
- A B C D
- A B C D
- A B C D
- A B C D
- A B C D
- A B C D
- A B C D
- A B C D
- A B C D
- A B C D
- A B C D
- A B C D
- A B C D
- A B C D
- A B C D
- A B C D

Post-activity evaluation questions:

Rate how well the activity supported your achievement of these learning objectives:
1=Poor, 2=Fair, 3=Neutral, 4=Good, 5=Excellent

- Grow my understanding of long-term steroid use and the potential of biologic agents. 1 2 3 4 5
- Familiarize me with the biologic options available and the differences between them. 1 2 3 4 5
- Recognize the symptoms associated with uveitis and understand the differential diagnosis. 1 2 3 4 5
- Trace the origin of non-infectious causes of uveitis and understand why that applies to using biologics. 1 2 3 4 5
- Understand the experiences patients with different types of uveitis can expect. 1 2 3 4 5
- Become familiar with the prevalence of—and various research into—uveitis. 1 2 3 4 5

Rate the quality of the material provided:

1=Strongly disagree, 2=Somewhat disagree, 3=Neutral, 4=Somewhat agree, 5=Strongly agree

- The content was evidence-based. 1 2 3 4 5
- The content was balanced and free of bias. 1 2 3 4 5
- The presentation was clear and effective. 1 2 3 4 5
- Additional comments on this course:

Please retain a copy for your records. Please print clearly.

First Name

Last Name

E-Mail

The following is your: Home Address Business Address

Business Name

Address

City State

ZIP

Telephone # - -

Fax # - -

By submitting this answer sheet, I certify that I have read the lesson in its entirety and completed the self-assessment exam personally based on the material presented. I have not obtained the answers to this exam by any fraudulent or improper means.

Signature _____ Date _____

Lesson 116558

RO-OSC-0518

YOUR INDUSTRY YOUR CAMPAIGN YOUR SUCCESS.



Think About Your Eyes (TAYE) promotes the importance of getting an annual eye exam at an eye doctor.

- In 2017, an estimated **1.4 million incremental eye exams** were driven by TAYE advertising,
 - 2018 advertising will reach **95% of Americans aged 25-49**
- **Can prospective patients find you?** Purchase or upgrade to a Premium listing on the doctor locator.

**Your practice is your biggest investment.
Take full advantage of the campaign that's invested in your success.**

Go to thinkaboutyoureyes.com/enroll to join or upgrade to Premium.

thinkabout
your**eyes**.com

Brought to you by the AOA
AMERICAN OPTOMETRIC ASSOCIATION



Concentrate on Povidone-iodine

Its standard of care has been in place for decades, but a lower concentration could provide steady results with less toxicity. **Edited by Joseph P. Shovlin, OD**

Q I know povidone-iodine is a helpful ocular surface antiseptic in virtually all situations. What is the ideal concentration for topical use for prophylaxis? What about for therapeutic measures against an assortment of pathogens?

A “Researchers on povidone-iodine for ophthalmic purposes started to pick up steam in the 1970s,” says William G. Myers, MD, of Chicago. “Back then, a number of studies determined that of the available pre-surgical antiseptics, 10% povidone-iodine was the least toxic to the cornea.” That was used along with the simple recommendation of washing your face after surgery until the 1980s. However, that concentration is still relatively toxic and patients “will feel a lot of sting,” says Dr. Myers.

Further research eventually led to the adoption of 5.0% povidone-iodine used for three minutes at a time as the standard of care for preoperative ocular antisepsis. This thinking has persisted for three decades with many positive characteristics, including low cost, high water solubility, absence of microbial resistance, ease of application and storage and relatively low toxicity.¹ However, new research suggests an even lower concentration could achieve the same effect.

“That standard has not changed for a third of a century, despite the significant epithelial toxicity observed,” says Dr. Myers. “Our view is that the surgeon has to balance effectiveness at both high and

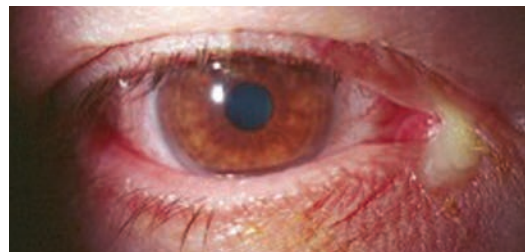
low concentrations of bacteria.”

In a recent study, Dr. Myers and a group of researchers set out to gauge the minimum concentration of povidone-iodine that reduces the bacterial load by 3 log units, which is required of antiseptic agents by the FDA. Results led the group to conclude that “povidone-iodine 1.0%, applied in three 30-second applications for preoperative surface disinfection might be as effective for preoperative antisepsis” as the 5.0% povidone iodine standard.²

“Povidone-iodine 1.0% applied three times, spaced at least two minutes apart, was as effective (as 5.0% concentration) in an *in vitro* model,” the study said. “This could be accomplished in an *in vivo* situation by dosing once in the preoperative area, once more on entering the procedure room and finally a third time after the lid speculum is placed.”

Therapeutics

While povidone-iodine is commonly used to prep for surgery, it isn’t just limited to preoperative use. A study out of Japan found that 0.25% povidone-iodine can reduce the anterior chamber bacteria contamination rate to zero when used to irrigate the ocular surface during a procedure.³ Additionally, it can be used therapeutically for a number of ocular conditions.



Using 1.0% or 0.25% povidone-iodine can be effective against cases of bacterial conjunctivitis, shown here.

Photo: Alan G. Kahan, OD

According to Dr. Myers, povidone-iodine can serve as an inexpensive alternative to antibiotics for recalcitrant corneal ulcer treatment. One recent study found 1.25% povidone-iodine was just as effective in treating bacterial keratitis as neomycin–polymyxin B–gramicidin and ciprofloxacin 0.3%.⁴ This is particularly helpful in places without many medical resources, as povidone-iodine is inexpensive and widely available. For treatment of bacterial conjunctivitis, meanwhile, Dr. Myers recommends using 1.0% or 0.25% povidone-iodine frequently for several days.

Overall, povidone-iodine is a helpful antiseptic in most situations. However, when it comes to concentration, today’s standard of care may not be ideal for all situations. ■

1. Chakrabarti A, John SR, Stephen V, Chakrabarti M. Povidone-iodine in ophthalmology. *Kerala Journal of Ophthalmology*. 2007;29(3):282-6.
2. Silas MR, Schroeder RM, Thomson RB, Myers WG. Optimizing the antiseptic protocol: Effectiveness of 3 povidone-iodine 1.0% applications versus a single application of povidone-iodine 5.0%. *J Cataract Refract Surg*. 2017;43(3):400-4.
3. Shimada H, Arai S, Nakashizuka H, et al. Reduction of anterior chamber contamination rate after cataract surgery by intraoperative surface irrigation with 0.25% povidone-iodine. *Am J Ophthalmol*. 2011;151:11-7.
4. Isenberg SJ, Apt L, Valenton M, et al. Prospective, randomized clinical trial of povidone-iodine 1.25% solution versus topical antibiotics for treatment of bacterial keratitis. *Am J Ophthalmol*. 2017;176:244-53.

Earn up to
19 CE
Credits*

NEW TECHNOLOGIES
& TREATMENTS IN
2018 EYE CARE



REVIEW OF OPTOMETRY®
EDUCATIONAL MEETINGS OF CLINICAL EXCELLENCE

ARLINGTON, VIRGINIA NOVEMBER 2-4, 2018

Join *Review of Optometry's* New Technologies & Treatments in Eye Care
November 2-4, 2018, at the Westin Arlington Gateway.

The Westin Arlington Gateway

801 N Glebe Road
Arlington, VA 22203
Phone: (703) 717-6200



Program Chair:
Paul Karpecki, OD, FAAO

See website for additional information.

Registration Cost: **\$495**
Early Bird Special: **\$420**

Must register before Sept. 21, 2018,
for early bird special pricing.

A limited number of rooms have been reserved at the rate of **\$159/night**. Please book with the hotel directly by calling the number above. Mention "Review of Optometry" for group rate.

THREE WAYS TO REGISTER

ONLINE: www.reviewofoptometry.com/ARLINGTON2018
EMAIL: reviewmeetings@jobson.com -or- **CALL:** 866-658-1772

REGISTER ONLINE: WWW.REVIEWOFOPTOMETRY.COM/ARLINGTON2018

Administered by
Review of Optometry®


*Approval pending

 **SALUS**
UNIVERSITY
Pennsylvania College of Optometry

Review of Optometry® partners with Salus University for those ODs who are licensed in states that require university credit. See event website for complete details.



What Lies Beneath

Thickness is a bad thing when it signifies this underdiagnosed condition.

By Jim Williamson, OD, Meagan Williams, OD, and Richard Mangan, OD

Uveal effusion syndrome (UES) is a rare clinical entity with the potential to cause devastating visual consequences. Uveal effusion itself refers to transudation from the choriocapillaris into the suprachoroidal space, which causes subsequent choroidal thickening and detachment.¹ It may also lead to subretinal fluid and serous retinal detachments.² Causes of uveal effusion include inflammation—which can result from trauma, scleritis, photocoagulation or uveitis—and hydrostatic conditions such as hypotony, primary angle closure glaucoma and drug-induced, arterio-venous fistula.¹

When uveal effusion occurs in the absence of inflammation or hydrostatic changes, the term UES applies, making it a diagnosis of exclusion.¹⁻³ Investigators believe UES patients have an abnormality of the choroid or sclera.^{1,4} Most cases of UES involve peripheral choroidal detachments. However, posterior uveal effusion syndrome (PUES), a variant of UES, remains isolated to the posterior pole.^{4,5}

Case Example

A 59-year-old Caucasian male presented with a chief complaint of blurred spots in his vision, more so in his left eye than his right. The spots were constant and did not change with eye movement. The symptoms in his left eye had been present since he underwent cataract surgery in 2012 with gradual enlargement and changes in shape of the spots. Conversely, the area in his

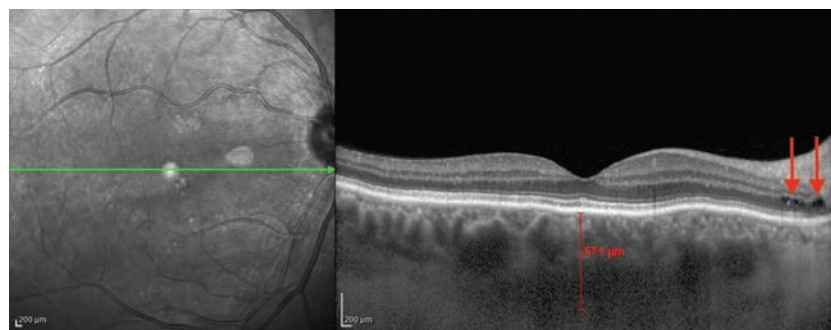


Fig. 1. Above, this OCT B-scan shows the patient's right eye.

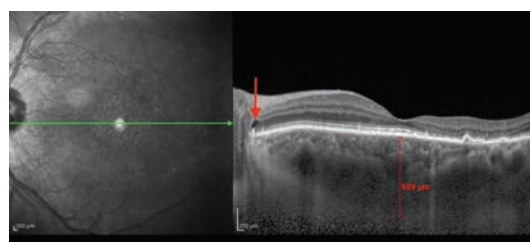


Fig. 2. This OCT B-scan shows the patient's left eye. The posterior subretinal fluid that may have extended from the cystic spaces is noted with red arrows at the optic disc margin.

right eye had only been present for two weeks. The patient described his vision as “looking through water.”

His best-corrected visual acuity measured 20/20 OD with +1.50D, and 20/30+2 OS with +0.75-0.75x090. His ocular history included pterygium removal from the left eye in 1980. His medical history was positive for hypertension and gout. No medication use was reported. Anterior segment examination revealed nasal corneal scarring consistent with the previous pterygium surgery in the left eye; and presbyopia-correcting intraocular lenses in both eyes with mild posterior capsular opacification. Prior to cataract development, the patient maintained acuities of 20/20 OD and OS with a refractive error of +3.00 OD, and +3.75 OS.

Intraocular pressures (IOP) obtained with Goldmann tonometry were 13mm Hg OD and OS. Dilated fundus exam results included flat, pink optic nerves with a cup-to-disc ratio of 0.25 round OU. Scattered areas of retinal pigment epithelial (RPE) disruption were noted within the posterior pole in both eyes. Optical coherence tomography B-scans (OCT-B) with enhanced depth imaging (EDI) were obtained along with fundus autofluorescence (FAF) pictures and ultrasound B-scans.

The OCT-B EDI scans (*Figures 1 and 2*) demonstrated marked pachychoroid of nearly 600μm OD and 700μm OS. FAF of the right eye highlighted an area of autofluorescence approximately the size of the macula inside the superior temporal arcade (*Figure 3*). OCT-B

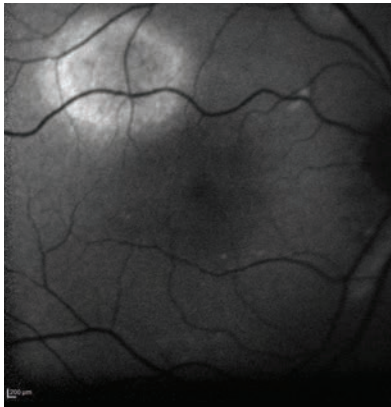


Fig. 3. This image shows an area of autofluorescence in the superotemporal arcade of the right eye.

scans of this area confirmed a serous retinal detachment (*Figure 4*). The more diffuse autofluorescence in the FAF image of the left eye (*Figure 5*) included two areas of increased intensity superior and superotemporal to the optic nerve (exaggerated due to instrument gain amplification). A retinal thickness map of the segmented outer nuclear layer (ONL) in the left eye (*Figure 6*) illustrated the extensive areas of ONL atrophy. The “hot spot” correlated to a focal retinoschisis. The FAF

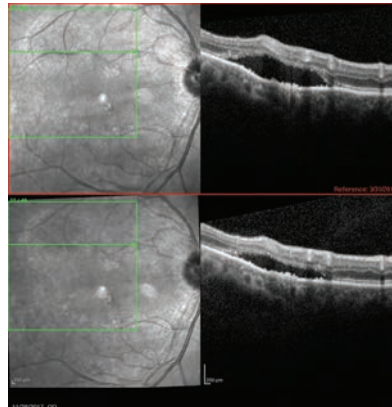


Fig. 4. OCT-B scans in the same area reveal a serous retinal detachment.

of the left eye also shows an area absent of autofluorescence about 1DD superotemporal to the macula. An OCT-B scan through this area revealed outer retina and RPE atrophy (*Figure 7*). The ultrasound B-scan (*Figure 8*) exhibited a thickened retina-choroid-sclera complex, but no peripheral choroidal detachments, which correlated to clinical findings. An ultrasound biomicroscopy scan was not obtained due to the lack of peripheral choroidal involvement.

Discussion

UES is an uncommon diagnosis where uveal effusion and serous retinal detachment are the most characteristic clinical findings.¹ It has a middle aged-male predilection, and 65% of cases occur bilaterally.^{1,3} UES is closely related to nanophthalmos or hyperopia and a thick sclera, and is rarely accompanied by significant inflammation.^{1,6} It results from abnormal transscleral diffusion of choroidal extravascular proteins from the suprachoroidal space.^{3,7} This leads to vortex vein compression and subsequent congestion of choroidal veins.³ Pachychoroid ensues from fluid accumulation, thus setting the stage for ciliochoroidal and non-rhegmatogenous retinal detachments.

When UES is confined to the posterior pole, the alternative diagnosis PUES applies. Speculation exists as to the mechanism of fluid transfer into the posterior pole. In this patient, the posterior subretinal fluid may have extended from the cystic spaces noted at the optic disc margin—see the arrows in *Figures 1 and 2*. Research shows this in patients

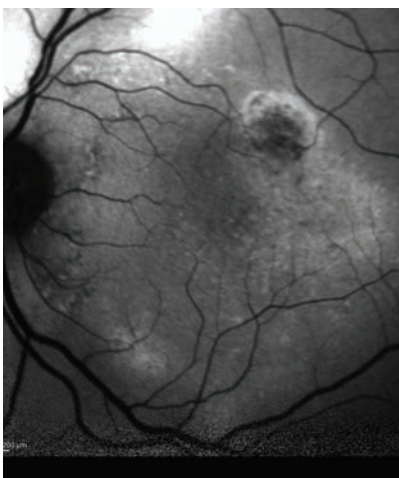


Fig. 5. Fundus autofluorescence OS shows two areas of increased intensity superior and superotemporal to the optic nerve.

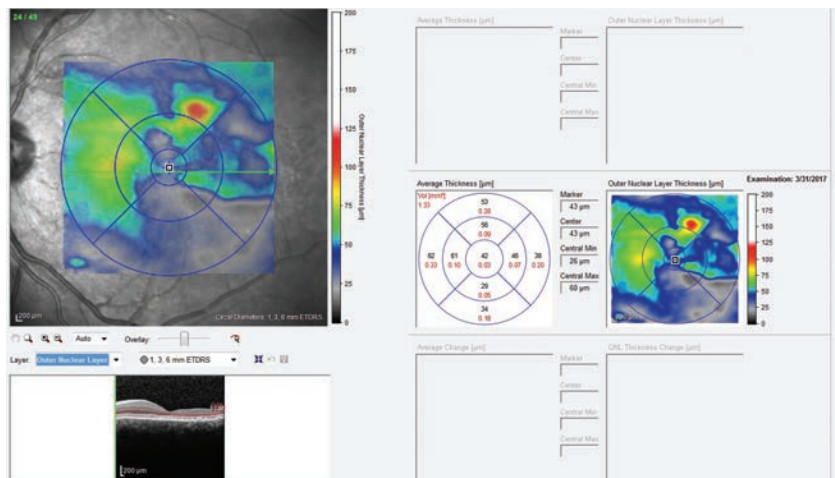


Fig. 6. A retinal thickness map of the eye illustrated extensive areas of outer nuclear layer atrophy.

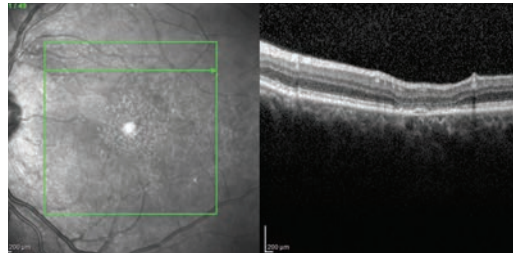
with PUES.^{4,5} One team even postulated that a combination of RPE and photoreceptor loss in the presence of a temporal disc crescent could facilitate the movement of choroidal fluid to the neurosensory retina.⁵ This anatomical appearance of a thick peripapillary choroid and disc crescent may present a weak link in the blood-retinal barrier.⁴ A fluorescein angiogram could pinpoint these areas of peripapillary leakage (this patient declined consent for the procedure).

UES is thought to be extremely rare and few reports of PUES exist in the literature.^{1,3-5} This may be due to a lack of diagnostic acumen. Middle-aged to older patients presenting with pigmentary changes and subretinal fluid may erroneously be diagnosed with exudative macular degeneration. In these cases, the clinician should image the choroid with OCT-B EDI to evaluate for pachychoroid.

PUES Diagnoses

The disease may also be confused with central serous chorioretinopathy (CSR) as similar clinical findings, multimodal imaging results and demographics (male predilection) exist. As with this patient, comparable data made CSR a strong diagnostic contender. The lean toward an ultimate PUES diagnosis hinged on several factors.

First, a meta-analysis found the mean subfoveal choroidal thickness in patients affected by CSR to be $413.1 \pm 93.0 \mu\text{m}$.⁸ Using this data, the right eye's choroidal thickness in this patient would be almost two standard deviations above the mean, while the left eye's choroidal thickness would be three times above it. Second, the patient did not exhibit CSR risk factors such as cortico-



Figs. 7. This OCT-B scan reveals the left eye's outer retina and RPE atrophy.

steroid use, Type A personality, or other medications associated with the disease.

Third, cataract surgery may exacerbate existing UES.^{1,4} Our patient self-reported a blurred spot post cataract extraction which would appear to support this correlation.

Finally, the peripapillary cystic spaces in both eyes were consistent with the fluid leakage theory in PUES proposed by others. All the above combined with the hyperopic status and thickened sclera (*Figure 8*) edged PUES to the more likely diagnosis.

Treatment

Both UES and PUES are difficult to manage and often follow a relapsing course.⁶ Full-thickness sclerectomy is the surgical treatment of choice by many for UES, but outcomes are variable.¹ In their case of PUES, investigators reported effective treatment with oral acetazolamide for the acute stage, with a switch to the topical form for maintenance. They cited a 2009 literature review which shows posterior pole effects from topical carbonic anhydrase inhibitor therapy and theorized that since PUES is isolated to the posterior pole, this treatment may increase fluid transport from the subretinal space to the choroid.⁴ In this case, the patient declined any treatment and elected to observe the condition. At eight months, some areas

of serous retinal detachment improved (*Figure 4*) while others remained relatively stable. The fovea remained flat with intact architecture OU.

UES and PUES can lead to serious and permanent vision loss, but prompt recognition of their characteristic clinical signs and appropriate ancillary testing will guide management strategies. Diagnosing UES or PUES necessitates the use of multimodal imaging and expanded critical thinking. ■

1. Haque R. Efficacy and safety of dexamethasone/povidone-iodine ophthalmic suspension in adenoviral conjunctivitis. Presented at: Association for Research and Vision in Ophthalmology annual meeting; May 7-11, 2017; Baltimore.
2. Levinger E, Trivizki O, Shachar Y, et al. Topical 0.03% tacrolimus for subepithelial infiltrates secondary to adenoviral keratoconjunctivitis. *Graefes Arch Clin Exp Ophthalmol*. 2014;252(5):811-6.
3. Özen Tunay Z, Ozdemir O, Petricli IS. Povidone iodine in the treatment of adenoviral conjunctivitis in infants. *Cutan Ocul Toxicol*. 2015;34(1):12-5.
4. Pepose JS. Topical Ganciclovir for the treatment of adenovirus conjunctivitis. *Advanced Ocular Care*. peposevision.com/wp-content/uploads/2014/05/aoc0912_Cornea_Pepose.pdf. September/October 2012. Accessed Feb. 12, 2018.
5. Pepose JS, Price F, Goldberg D, et al. A placebo controlled comparison of topical Zirgan versus Genteal gel for the treatment of adenovirus conjunctivitis. NIH. clinicaltrials.gov/ct2/show/record/NCT01533480. Accessed Feb. 12, 2018.
6. Sambursky R, Tauber S, Schirra F, et al. The RPS adeno detector for diagnosing adenoviral conjunctivitis. *Ophthalmology*. 2006;113(10):1758-64.
7. Hillenkamp J, Reinhard T, Ross R. The effects of cidofovir 1% with and without cyclosporin A 1% as a topical treatment of acute adenoviral keratoconjunctivitis. *Ophthalmology*. 2002;109:845-50.
8. Shiuuey Y, Ambati B, Adamis A. A randomized, double-masked trial of topical Ketorolac versus artificial tears from treatment of viral conjunctivitis. *Ophthalmology*. 2000;107:1512-7.
9. Melton R, Thomas R. Stop EKC with a 'silver bullet.' *Rev Optom*. 2008;145(11):77-81.
10. Pihos A. Epidemic keratoconjunctivitis: A review of current concepts in management. *Journal of Optometry*. 2013;6(2):69-74.

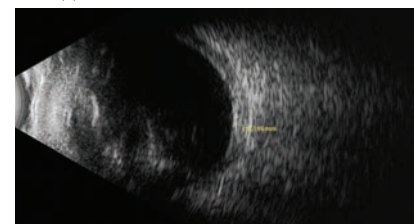


Fig. 8. This ultrasound of the left eye shows a thickened retina-choroid-sclera complex, but no peripheral choroidal detachments.



Tel Me What You See

A patient's fundus shows signs of an underlying disease.

By Eric Dillinger, OD, and Mark T. Dunbar, OD

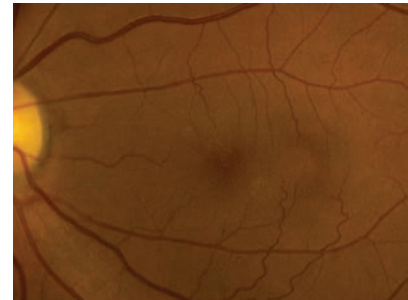
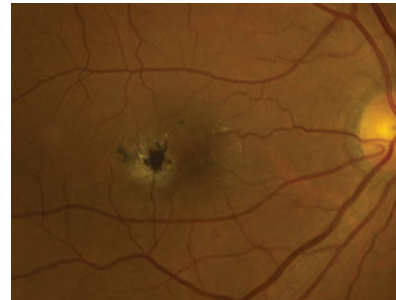A 57-year-old female presented for evaluation of possible diabetic retinopathy. She has had poorly controlled diabetes for 12 years and currently is on Januvia (sitagliptin, Merck) and insulin. Her hemoglobin A1c was 9.0 a month earlier. She reported that the vision in her right eye has been poor for more than 10 years, but sees well out of her left eye.

On examination, her best-corrected visual acuities measured 20/40 OD and 20/20 OS. Confrontation visual fields were full-to-careful finger counting in both eyes. Her ocular motility testing was normal and her pupils were equally round and reactive without an afferent pupillary defect. Her anterior segment was unremarkable. Tensions by applanation measured 17mm Hg OU.

On dilated fundus exam, her optic nerves appeared healthy with a small cup and good rim coloration and perfusion in both eyes. Examination of the macula in the right eye showed obvious changes (Figure 1). Close inspection of the left eye also shows subtle findings (Figure 2). Spectral-domain optical coherence tomography (SD-OCT) was also performed (Figures 3 and 4) and OCT angiography (OCT-A) of the right eye is also available for review (Figure 5).

Take the Retina Quiz

1. What do the small white spots that are visible in the right eye represent?



Figs. 1 and 2. This is the right and left eye of our patient. Note the pigment changes seen in the right eye. But don't ignore the left eye—what do you see?

- a. Drusen.
 - b. Exudate.
 - c. Retinal crystals.
 - d. Talc.
2. What is the essential finding on the SD-OCT in the right eye?
- a. Choroidal neovascularization.
 - b. Center-involved diabetic macular edema.
 - c. Cystoid macular edema.
 - d. Scarring and parafoveal loss of the IS/OS Junction.
3. What is the essential finding on the SD-OCT of the left eye?
- a. The OCT is normal.
 - b. Cystoid macular edema.
 - c. Internal limiting membrane drupe.
 - d. Subretinal fluid.
4. What is the correct diagnosis?
- a. Macular telangiectasia.
 - b. Mild nonproliferative diabetic retinopathy.
 - c. Choriorretinal scar from toxoplasmosis.
 - d. Retinal detachment.
5. How should this patient be managed?
- a. Observation.
 - b. Observation right eye, anti-VEGF treatment left eye.
 - c. Anti-VEGF therapy both eyes.
 - d. Pars plana vitrectomy, membrane peel.

For answers, see page 122.

Diagnosis

We observed an obvious large plaque of retinal pigment hyperplasia adjacent to the macula in the right eye with parafoveal loss of the inner segment/outer segment (IS/OS) junction. We observed no subretinal fluid, nor a choroidal neovascular membrane. With direct comparison of the SD-OCT, the bright intraretinal hyperreflective spot on the OCT represents the retinal pigment epithelial (RPE) hyperplasia, which is blocking the transmission signal posterior to the plaque. Remarkably, our patient is still able to see 20/40 OD. That should not be a big surprise

because, on close evaluation of the OCT, the IS/OS junction at the fovea is intact.

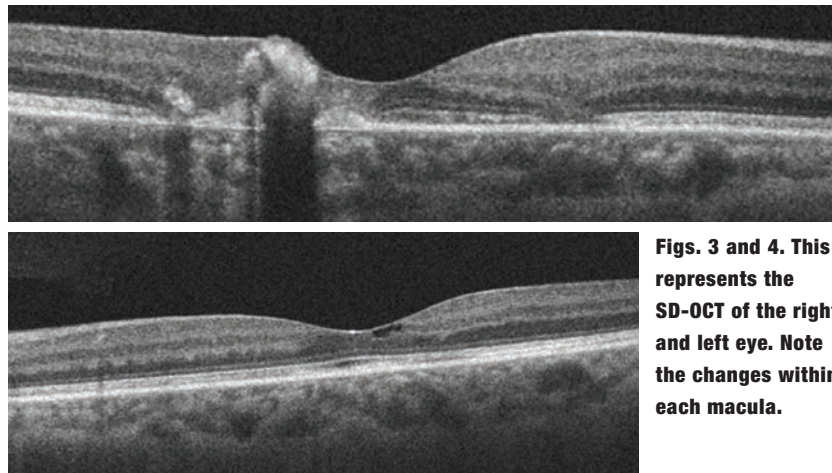
The other interesting findings in the right eye were small refractile white deposits scattered throughout the macula. They appeared to be intraretinal and represent small crystalline deposits. Of particular interest were intraretinal crystals in the left eye. What's more, the SD-OCT in the left eye is also quite revealing. Slightly temporal to the macula is what appeared to be a small pocket of fluid or perhaps a small retinal cyst. What this represents is an internal limiting membrane drape.

All these findings are typical for macular telangiectasia (MacTel).

Discussion

MacTel can be autosomal dominant but with reduced penetrance.¹ MacTel is divided into two main types. Type 1 is categorized as macular aneurismal telangiectasia and type 2 as macular perifoveal telangiectasia.^{1,2} Our patient has type 2. In type 1, patients are more likely to have obvious vascular changes with more pronounced aneurismal dilations and cystoid macular edema. Type 2 patients will have minimal exudation and a central lamellar cyst with a "draping" of the retina over the central cystic, which is seen in the left eye of our patient on the OCT. In addition, type 2 patients will have loss of the retinal transparency and more subtle telangiectatic changes within the capillaries. This can be seen on the OCT-A in the right eye of our patient temporal to the macula. These subtle telangiectatic vascular changes were not as obvious on the OCT-A in the left eye but they were present.

Another subtle finding in the left eye is how the retinal veins temporal to the macula appear to be



Figs. 3 and 4. This represents the SD-OCT of the right and left eye. Note the changes within each macula.

blunted or come to an abrupt stop. What's happening is that the veins are making a right angle turn and "diving" posterior into the macula. We can't see this in the right eye because of the plaque of pigment, which is also characteristic for the late stages of MacTel.

Most patients will develop these plaques of intraretinal pigment over time. It's usually not as extreme as what is seen in our patient. This may be in response to a chronic incompetence of the retinal capillaries, which results in slow leakage and atrophic changes in the photoreceptor layer.¹ This stimulates the pigment to migrate from the RPE and extend into the sensory retina. The pathophysiology may be similar to bone spicule-like pigmentation that is in retinitis pigmentosa.¹

Patients can also develop choroidal neovascularization, which can also result in scarring and RPE hyperplasia. We were not sure why the pigment was so dense in the right eye of our patient and was not present at all in the left eye. Perhaps she had a CNV at one point in time. Remember, our patient said the vision in the right eye had been reduced for more than 10 years.

In this case, our patient's MacTel was stable and required no treat-

ment. Of concern was a history of concurrent poorly controlled diabetes. Even though she did not have diabetic retinopathy, she is at risk because of her elevated blood sugar levels. She was counseled on the importance of tighter control of her blood sugar and asked to return for follow-up in six months. ■

1. Hayreh SS, Zimmerman MB. Amaurosis fugax in ocular vascular occlusive disorders: prevalence and pathogenesis. *Retina*. 2014;34(1):115-22.
2. Hayreh SS. Acute retinal arterial occlusive disorders. *Prog in Retin Eye Res*. 2011;(5):359-94.
3. Subramanian PS. How urgent is the treatment of transient vision loss? *Br J Ophthalmol*. 2014;98(6):719-20.

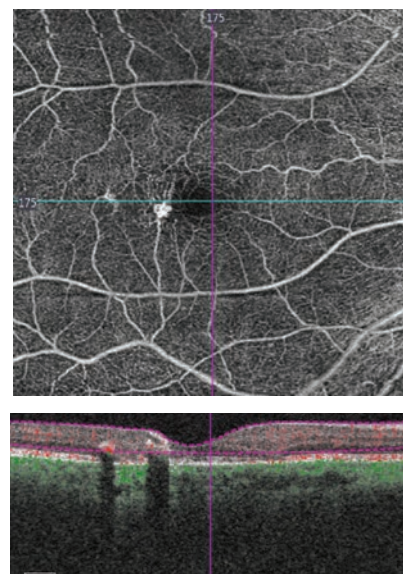


Fig. 5. This OCT-A shows our patient's right eye.



The Dusky Side of Hypertension

Although uncommon, pheochromocytoma may present with ophthalmic signs.

By Carlo J. Pelino, OD, and Joseph J. Pizzimenti, OD

Pheochromocytomas—tumors of the adrenal glands—are a common cause of secondary hypertension. While usually benign, they may also present as, or develop into, a malignancy.¹ Because ocular symptoms may be the first or even the only sign, optometrists often see these patients before an internist. Thus, pheochromocytomas must be in the list of differentials whenever a patient presents with ocular evidence of vascular disease.

Pheochromocytoma Basics

The adrenal glands sit on top of each of the two kidneys. Chromaffin cells of the adrenal medulla, or the inner area of gland, are responsible for synthesizing and releasing catecholamines such as dopamine, epinephrine (adrenaline) and norepinephrine (noradrenaline)—the “flight or fight” neurohormones.¹

Catecholamines stimulate alpha-adrenergic receptors, resulting in elevated blood pressure (BP), increased cardiac contractility, glycogenolysis, gluconeogenesis and intestinal relaxation.² They also stimulate beta-adrenergic receptors, causing increased heart rate and contractility. Increased blood pressure secondary to high catecholamine levels can cause headaches, sweating, pounding heart, anxiety and chest pain.²

Pheochromocytomas are tumors of the chromaffin cells. The term *pheochromocytoma* refers to the color the tumor cells acquire when stained with chromium salts (in Greek, *phios* means dusky, *chroma*

means color and *cytoma* means tumor).² Although pheochromocytomas occur in people of all races, they are diagnosed less frequently in blacks than in whites. They may affect patients of any age, with peak incidence from the third to the fifth decades of life.¹ Approximately 10% occur in children.¹

The majority of pheochromocytomas are sporadic. Approximately 30% result from inherited mutations, and roughly 10 genes have been identified as sites of mutations.² Tumors are malignant in 10% of cases, and may be cured completely by surgical removal.¹ Pheochromocytomas can occur in combination with other tumors and in some familial syndromes. They have classically been associated with von Hippel-Lindau (VHL) syndrome, multiple endocrine neoplasia type 2 and neurofibromatosis type 1 (NF1).

Approximately 85% of the tumors are located within the adrenal glands. When they occur outside of the adrenal gland, they are termed extra-adrenal pheochromocytomas, or paragangliomas.^{1,2}

Anything that can cause over-

activity of the sympathetic nervous system should be on the list of diagnoses to rule out when suspecting a pheochromocytoma.

What to Expect

Patients with pheochromocytoma present with myriad symptoms and signs, giving rise to the tumor’s title of “great masquerader.” In the visual system, hypertensive retinopathy, choroidopathy and optic neuropathy are the main complications.³ In addition, associated conditions such as NF1 and VHL may cause severe neurological manifestations and visual disturbances.

Systemically, the main clinical feature is hypertension, although pheochromocytomas are present in only about 0.2% of those with high blood pressure. Increased blood pressure may be an abrupt, precipitous elevation associated with tachycardia, palpitations, headache, sweating, tremor, postural hypotension, fever, pallor and weight loss. Abdominal or chest pain, nausea and vomiting may occur.^{1,2,4}

Pheochromocytoma-associated hypertensive episodes are caused by increased sympathetic neuronal impulse frequency with excessive release of norepinephrine into the synaptic cleft with each impulse. The secondary hypertension may eventually precipitate congestive heart failure, pulmonary edema, myocardial infarction, ventricular fibrillations and cardiovascular disease.¹ Rarely, familial pheochromocytomas may cause no symptoms or signs.⁴

Table 1. Major Causes of Secondary Hypertension^{1,2,4,5}

- Renal artery stenosis
- Renal parenchymal disease
- Estrogen use
- Coarctation of the aorta
- Pheochromocytoma
- Hyperaldosteronism
- Cushing’s syndrome
- Hyperthyroidism
- Hyperparathyroidism

How to Handle the Situation

A thorough history and meticulous clinical exam are powerful diagnostic tools that can correctly identify the cause of secondary hypertension, and pheochromocytomas in particular (Table 1).^{1,2,4,5} Although secondary hypertension makes up only about 10% of all hypertensive cases, it is often correctable.¹

Hypertension can be confirmed by a simple blood pressure measurement. The laboratory diagnosis of pheochromocytoma is based on the 24-hour urinary excretion/collec-tion of free catecholamines and their metabolites. Plasma metanephrine may also be done. If these are more than two times the normal level, imaging studies are usually necessary to look at the adrenal glands.^{1,2,4}

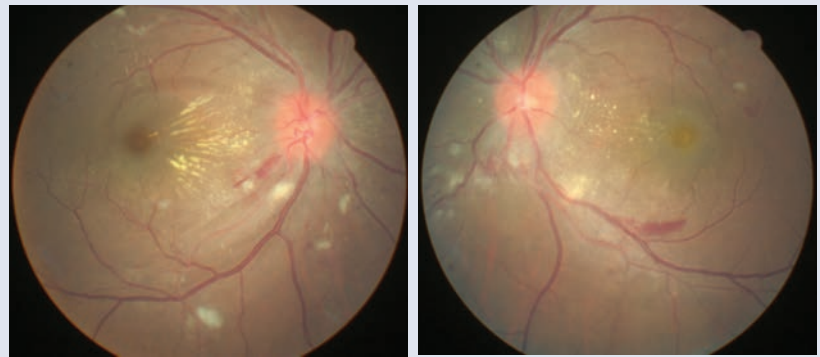
Abdominal CT scanning has a high accuracy for detecting adrenal masses with a spatial resolution of 1cm or greater.⁵ MRI is the preferred imaging choice in children and pregnant/lactating women, with a sensitivity of up to 100% in detecting adrenal pheochromocytoma.⁵

Scintigraphy is reserved for bio-chemically confirmed cases in which CT or MRI do not show a tumor.⁵

Positron emission tomography (PET) scanning is another useful technique.⁵ Because cancer cells often take up more glucose than normal cells, PET imaging is particularly useful for visualizing them.

Surgical resection is the treat-ment of choice and usually cures the hypertension and ocular side effects. Preoperative treatment with alpha and beta blockers is required to control blood pressure and prevent intraoperative hypertensive crises. Until the tumor is removed, blood pressure control is a top priority.⁴

Both malignant and benign pheochromocytomas can recur after surgery. The statistics vary between studies, but recurrence rates average



Figs. 1 and 2. The patient's fundus photos show signs of hypertensive retinopathy, prompting the decision to test for secondary hypertension and pheochromocytoma.

Case Example

A 30-year-old female presented with complaints of moderate bilateral visual blur associated with headaches and photophobia. She stated that she had been to the emergency room one week prior to address the onset of heart palpitations. She was treated for severe hypertension and released for further medical management by her primary care provider (PCP).

During her visit, her pinhole visual acuity was 20/40 OD and 20/50 OS. Ophthalmoscopy showed bilateral optic disc edema, soft exudates, macular star, flame-shaped hemorrhages and arterial narrowing (Figures 1 and 2). Her blood pressure measured 141/92mm Hg. An ocular diagnosis of Grade 4 hypertensive retinopathy was established, and the patient was referred back to her PCP for continued treatment. Due to the patient's young age, we needed to rule out secondary hypertension.

Neuroimaging studies revealed a right adrenal gland mass. After ablation, the tumor proved to be a pheochromocytoma, and immunohistochemistry showed dopamine secretion. In addition to continued medical treatment, the patient will return to our clinic in one month to assess visual function and monitor ocular health.

around 10%.^{2,4} Therefore, long-term follow-up care after surgery is essential. In the low percent of these already rare tumors in which malignant behavior is evident, survival may still be quite prolonged, as the pace of the disease is often slow. Participation in clinical trials of new therapies is strongly encouraged in the unfortunate case of metastatic pheochromocytoma.⁵ This will direct the plan of management, thus preventing treatment delay and potentially serious complications.

Whenever the diagnosis is in doubt, biochemical testing can establish the presence or absence of a pheochromocytoma, and localization with neuroimaging is almost always possible. While an

uncommon finding, ODs must keep pheochromocytomas on their list of differentials, especially for patients who present with sustained or paroxysmal hypertension and any manifestations suggesting excess catecholamines. Quick diagnosis and proper comanagement are key to reduce the negative effects of secondary hypertension. ■

1. Waguespack SG, Rich T, Grubbs E, et al. A current review of the etiology, diagnosis, and treatment of pediatric pheochromocytoma and paraganglioma. *J Clin Endocrinol Metab.* 2010;95(5):2023-37.
2. Sheps SG, Jiang NS, Klee GG, van Heerden JA. Recent developments in the diagnosis and treatment of pheochromocytoma. *Mayo Clin Proc.* 1990;65(1):88-95.
3. Hayreh SS. Hypertensive fundus changes. In: Gyer DR, ed. *Retinavitreal macula*. Philadelphia: Saunders; 1999:345-71.
4. Frankel F. *Virchows Arch. f. path. Anat.* 1886;103:244-63
5. Lenders JW, Duh QY, Eisenhofer G, et al. Pheochromocytoma and paraganglioma: an endocrine society clinical practice guideline. *J Clin Endocrinol Metab.* 2014;99(6):1915-42.

Your Donations at **Work**

Photo Credit: Brian Holden/Vision The Way



Your donations will help support more programs like the first ever School of Optometry in Haiti. After almost 5 years in planning, the school has welcomed 17 new students to the Bachelor of Vision Science program. Pierre Christopher (pictured) was delighted to commence his 5-year degree on November 6th.

The creation of locally trained optometrists will be a huge benefit for the 70% of the population who currently have little or no access to eye care services. Within 10 years, there will be at least 80 new locally educated eye care professionals who will be providing eye care to more than 360,000 Haitians per year.

A regular donation to Optometry Giving Sight will help transform even more lives.

OPTOMETRYGIVINGSIGHT

Transforming lives through the gift of vision

To learn more or to donate today please visit: givingsight.org or call 1-888- 647-4483

Meetings + Conferences

June 2018

■ **6-10.** *Indian Health Service Biennial Eye Care Meeting.* Marshall B. Ketchum University Fullerton Campus, Fullerton, CA. Hosted by: Marshall B. Ketchum University Southern California College of Optometry & Indian Health Service. CE hours: 25. For more information, email Antoinette Smith at asmith@ketchum.edu, call (714) 872-5684 or go to www.ketchum.edu/ce.

■ **6-10.** *Art & Science of Optometric Care, A Behavioral Perspective.* NOVA Southeastern University, Fort Lauderdale, FL. Hosted by: The Optometric Extension Program Foundation. Key faculty: John Abbondanza. CE hours: 35. For more information, email Karen Ruder at karen.ruder@oep.org, call (410) 561-3791 or go to www.oep.org.

■ **8-10.** *Everything Therapeutic: Houston.* University of Houston College of Optometry (UHCO), Houston. Hosted by: UHCO. Key faculty: Bruce Onofrey. CE hours: 24. For more information, email optce@central.uh.edu, call (713) 743-1900 or go to ce.opt.uh.edu.

■ **20-24.** *AOA/Optomety's Meeting.* Colorado Convention Center, Denver, CO. Hosted by: American Optometric Association and American Optometric Student Association. CE hours: 215 total, 43 per OD. For more information, email cspampani@aoa.org, call (314) 983-4124 or go to optometrymeeting.org.

July 2018

■ **8-18.** *Therapeutic Pharmaceutical Agents Certification/Board Review Course.* NOVA Southeastern University, Fort Lauderdale, FL. Hosted by: NOVA Southeastern University College of Optometry. Key faculty: Joseph Sowka, Julie Tyler, Chandra Mickles, Diana Shechtman, Sherrol Reynolds. CE hours: 100. For more information, email Vanessa McDonald at oceaa@nova.edu, call (954) 262-4224 or go to optometry.nova.edu/ce/index.html.

■ **12-15.** *July Advanced Procedures.* Oklahoma College of Optometry Academic Wing, Tahlequah, OK. Hosted by: Oklahoma College of Optometry. Key faculty: Nate Lighthizer, Richard Castillo, Joseph Shetler, Doug Penisten. CE hours: 32. For more information, email Callie McAtee at mcateec@nsuok.edu, call (918) 316-3602 or go to optometry.nsuok.edu/continuingeducation.

■ **12-15.** *CE in the Rockies.* Ridgeline Hotel, Estes Park, CO. Hosted by: University of Houston College of Optometry. Key faculty: Danica Marrelli. CE hours: 20. For more information, email optce@central.uh.edu, call (713) 743-1900 or go to ce.opt.uh.edu.

To list your meeting, please send the details to:

Michael Iannucci
Associate Editor

Email: miannucci@jobson.com

Phone: (610) 492-1043

Advertisers Index

Akorn Consumer Health .26-29 Phone (800) 579-8327 www.akornconsumerhealth.com	Lacrivera 40-41 Phone (855) 857-0518 www.lacrivera.com
Akorn Pharmaceuticals 23 Phone (800) 932-5676 www.akorn.com	Lombart Instruments 33 Phone (800) 446-8092 Fax..... (757) 855-1232
Alcon Laboratories 5, 6, 124 Phone (800) 451-3937 Fax..... (817) 551-4352	M&S Technologies..... 39 Phone (877) 225-6101 Fax..... (847) 763-9170
Bausch + Lomb 9, 10, 49 85, 123 Phone (800) 323-0000 Fax..... (813) 975-7762	Menicon..... 53 Phone (800) MENICON information@menicon.com www.meniconamerica.com
Beaver-Visitec International, Inc. 7 Phone (866) 906-8080 Fax..... (866) 906-4304 www.beaver-visitec.com	Natural Ophthalmics, Inc. 83 Phone (877) 220-9710 info@natoph.com www.natoph.com
Bio-Tissue, Inc..... 47 Phone (305) 412-4430 Fax..... (305) 412-4429	Oculus, Inc. 89 Phone (888) 284-8004 Fax..... (425) 867-1881
Bruder Ophthalmic Products 96 Phone (888) 827-8337 eyes@bruderophthalmic.com	Quidel 45 Phone (800) 874-1517 customerservice@quidel.com www.quidel.com
CooperVision 16-17, 37 66-67 Phone (800) 341-2020	Reichert Technologies ... 59, 61 63, 65 Phone (888) 849-8955 Fax..... (716) 686-4545 www.reichert.com
Essilor of America..... 81 www.essilorusa.com	S4OPTIK..... 69, 71, 73 Phone (888) 224-6012
Imprimis Pharmaceuticals, Inc. 19 Phone (858) 704-4040 Fax..... (858) 345-1745 www.imprimispharma.com	Shire Ophthalmics 13 www.shire.com
Katena 25, 87 Phone (800) 225-1195 www.katena.com	TelScreen 91 www.TelScreen.com DryEye@TelScreen.com
Keeler Instruments..... 21, 95 Phone (800) 523-5620 Fax..... (610) 353-7814	Topcon Medical Systems 2 Phone (800) 223-1130 Fax..... (201) 599-5250
Lacrimedics, Inc 57 Phone (800) 367-8327 Fax..... (253) 964-2699 info@lacrimedics.com www.lacrimedics.com	U.S. Army..... 55 Phone (800) 431-6731 www.healthcare.goarmy.com/at66
	X-Cel Speciality Contacts.... 93 Phone (877) 336-2482 www.xcelspecialitycontacts.com

This advertiser index is published as a convenience and not as part of the advertising contract. Every care will be taken to index correctly. No allowance will be made for errors due to spelling, incorrect page number, or failure to insert.

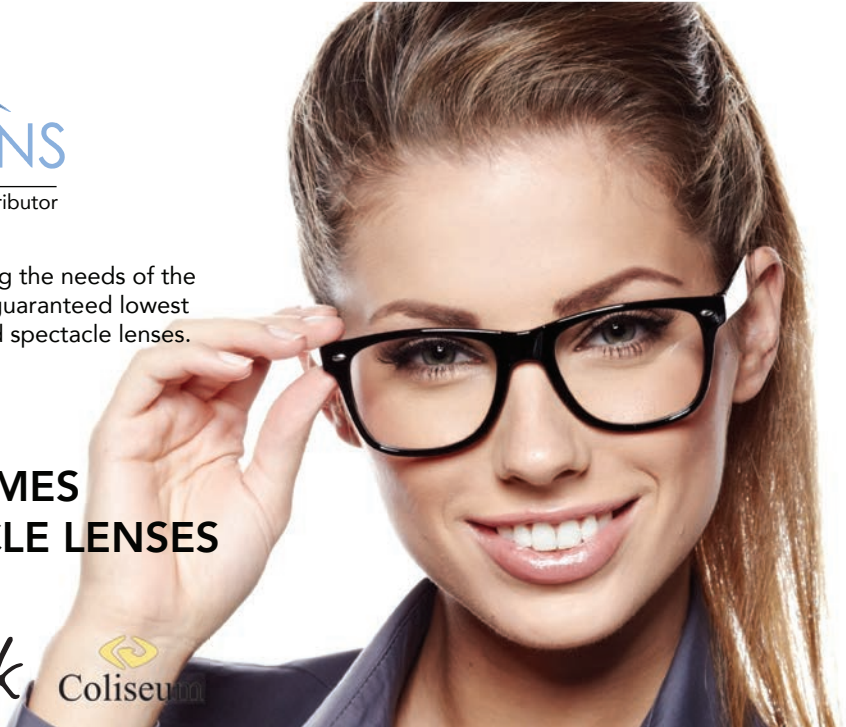Merchandise Offered



America's Leading Discount Optical Distributor

National Lens is dedicated to fulfilling the needs of the optical profession by providing the guaranteed lowest prices on contact lenses, frames, and spectacle lenses.

**CONTACT LENSES
100% ITALIAN FRAMES
FINISHED SPECTACLE LENSES**



GUARANTEED LOWEST PRICES | FREE FIRST CLASS SHIPPING*

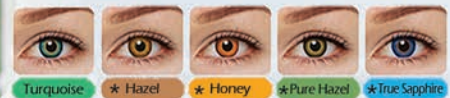*in stock products (when available)

Contact Lenses

Impressions

Color Contact Lens

Unleash your true color!



Impressions colored contacts blend naturally with your patients eyes to create a beautiful look. Available in nine dazzling opaque colors of which Brown, Grey, Green, Hazel, Honey, Pure Hazel and True Sapphire are available in RX PL to -8.00. Impressions are fun, hip, fashionable and very competitively priced to help your bottom line. POP materials and posters are available upon request.


Available Exclusively at




Continuing Education

Dr. Travel Seminars, LLC
 In Partnership With The NJ Society of Optometric Physicians
Christmas Week Seminar Cruise
Group Pricing & All Beverages or Gratuities Included
 NCL Breakaway - Sailing From New Orleans - Western Caribbean Cruise
 Sunday to Sunday, December 23 - 30, 2018


Deluxe Ship



All Programs Are in Partnership
With the New Jersey Society of
Optometric Physicians



Special Group Pricing



Dr. TRAVEL SEMINARS, LLC
is a COPE approved provider

Celebrating 23 years **Group Pricing Ends Aug. 24**

Advanced Ocular Care - by Richard Mangan, OD, FAAO - 16 CE

Additional Seminar Cruises (12-16 CE):
 Alaska Glacier Bay Cruise - July 29 - August 5, 2018 - Maynard Pohl, O.D., F.A.A.O.
 Roundtrip Seattle, WA - NCL's Norwegian Pearl - Free Drinks or Gratuities
 New Zealand Cruise - Jan 25 - Feb. 6, 2019 - Randall Thomas, O.D., F.A.A.O.
 Roundtrip Sydney, Australia - Princess Cruise Lines: New Majestic Princess
 President's Week - February 16 - 23, 2018 - Royal Caribbean's New Symphony of the Seas

www.DrTravel.com 800-436-1028

MEDICAL OPTOMETRISTS

The American Board of Certification in Medical Optometry (ABCMO) is recognized at Joint Commission (JC) accredited medical facilities as issuing board certification in the specialty of medical optometry and those ABCMO certifies are eligible for credentialing at these facilities as specialists rather than general optometry practitioners.[^]

The Joint Commission, the accepted national Gold Standard, reviews and accredits over 21,000 federal, state and local-chartered medical facilities.

To Be Eligible for ABCMO board certification:

1. Complete an accredited residency in medical optometry
2. Pass the national Advanced Competence in Medical Optometry Examination
3. Practice in a medical setting for a minimum of two years.*

www.abcmo.org



Visit www.abcmo.org to understand how JC accredited medical facilities credential specialists and why specialty certification can enhance the careers of optometrists who complete residencies in medical optometry.

**For Application procedures see
www.abcmo.org
or contact myers.kenj@gmail.com**

[^] At this time, 127 JC accredited hospitals, clinics and teaching institutions recognize ABCMO specialist certification.
^{*} www.jointcommission.org
^{*} Waived for two years after residency

Career Opportunities


Staff Optometrist Wanted

Bard Optical is a family owned full-service retail optometric practice with 22 offices (and growing) throughout Central Illinois. Bard Optical prides itself on having a progressive optometric staff whose foundation is based on one-on-one patient service. We are currently accepting CV/resumes for Optometrists to join our medical model optometric practice that includes extended testing. The practice includes but is not limited to general optometry, contact lenses and geriatric care. Salaried, full-time positions are available with excellent base compensation and incentive programs and benefits. Some part-time opportunities may also be available.

Current positions are available in
 Bloomington/Normal, Decatur/Forsyth,
 Peoria, Sterling and Canton as we continue
 to grow with new and established offices.

Please email your information to mhall@bardoptical.com or call Mick at 309-693-9540 ext 225. Mailing address if more convenient is:
Bard Optical
Attn: Mick Hall, Vice President
8309 N Knoxville Avenue
Peoria, IL 61615

Bard Optical is a proud Associate Member of the Illinois Optometric Association.



www.bardoptical.com

OPTOMETRY PRACTICE IN GREATER ORLANDO AREA

Current established Optometry practice in greater Orlando area. Great income potential for a Great Optometrist. Current Optometrist retiring.

Candidate will have current income plus room to increase earnings

Full team support, equipment, and systems. Private practice that offers self pay as well as specific insurance plans for Patients.

Options for Sub-lease with Optometric group.

Contact us for more information and see how this can be a tremendous opportunity.

We look forward to meeting you soon.
Phone 888-796-0002
Email o.d.orlandofl@gmail.com

Place Your Ad Here!
 Toll free: **888-498-1460**
 E-mail: sales@kerhgroup.com

Equipment and Supplies

WHY PAY RETAIL???



\$825.00

Pretesting Tables of all shapes and sizes at Wholesale Prices.

Search the word PRETESTING at EBAY

Save hundreds even thousands on all your pretesting needs.

Or call: 316-734-4265

Faculty



ASSISTANT PROFESSOR POSITIONS: PRIMARY CARE, PEDIATRICS AND LOW VISION
 (Full-time non-tenure track faculty positions for the Chicago College of Optometry)

RESPONSIBILITIES: CANDIDATES ARE EXPECTED TO BE HIGHLY KNOWLEDGEABLE IN THE FIELD OF PRIMARY CARE, PEDIATRICS OR LOW VISION AND CAN DEVELOP AND TEACH COURSES AND/OR LABORATORIES IN THE SUBJECT AREA. THE CANDIDATE MUST ALSO BE ABLE TO PROVIDE DIRECT PATIENT CARE AND CLINICAL INSTRUCTION TO PROFESSIONAL STUDENTS AS WELL AS RESIDENTS, AND BE INVOLVED IN INTERDISCIPLINARY PRACTICE WITH OTHER EDUCATIONAL PROFESSIONALS.

Candidates must be willing to actively participate in curricular assessment, professional development, student counseling and service activities within the college, university and the scientific community. Successful candidates are also expected to be involved in research and scholarly activities, and have a sincere commitment to optometric education, community service and patient care. Primary duties include, but are not limited to:

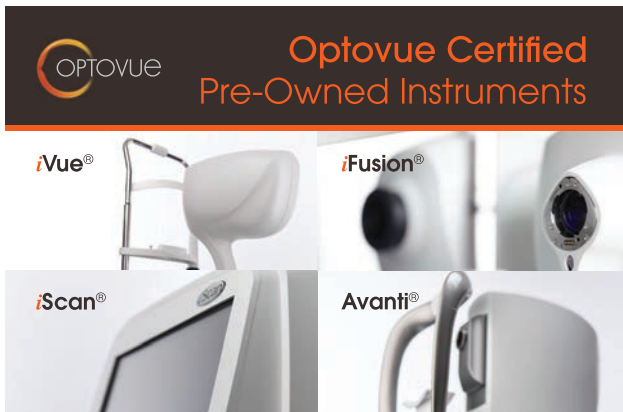- | | | |
|--|--|--|
| <p>a) Teaching</p> <ul style="list-style-type: none"> Developing and delivering lectures and/or laboratories for related areas, as assigned; Embracing and enhancing the didactic philosophies in the O.D. program; Maintaining and expanding the high quality clinical practice environment for optometry students on rotation; Precepting students on clinical rotation at the Midwestern University Eye Institute; | <p>b) Service</p> <ul style="list-style-type: none"> Helping to maintain and grow the state of the art optometry program with a strong interdisciplinary focus that meets the needs of patients in the surrounding community; is efficient, patient friendly, and cost-effective; Working closely together with all optometry and ophthalmology faculty to provide a complete range of eye and vision care services; Participating in leadership roles in state, regional, and national optometry organizations; | <ul style="list-style-type: none"> Participating on College and University committees, as assigned; Participating in College and University service activities. <p>c) Scholarly activity</p> <p>Engaging in research and scholarly activity, including presentations at scientific meetings, research, and publication in peer reviewed journals sufficient to qualify for academic advancement in a non-tenure track position.</p> |
|--|--|--|

QUALIFICATIONS: Candidates must possess a Doctor of Optometry degree from an ACOE-accredited institution, must have completed an ACOE-accredited residency, and must be eligible for an optometric state license in the state in which the college is located. Primary eye care clinical expertise is also required.

CONTACT INFORMATION: Contact information: Interested applicants should apply online at www.midwestern.edu and include curriculum vitae and letter of interest specifying the position and college that he/she wishes to be considered for. Inquiries may be directed to Dr. Melissa Suckow, Dean; Midwestern University: msucko@midwestern.edu.

Midwestern University is an Equal Opportunity/Affirmative Action employer that does not discriminate against an employee or applicant based upon race, color, religion, gender, national origin, disability, or veterans status, in accord with 41 C.F.R. 60-1.4(a), 250.5(a), 300.5(a) and 741.5(a).

Equipment for Sale



A certified pre-owned OCT system from Optovue delivers outstanding performance and value. And to make your decision even easier, Optovue protects your investment with a one-year warranty.

Act fast — a limited number of pre-owned systems are available!

Check System Availability
www.optovue.com/feature/certified-pre-owned

Continuing Education



KEY WEST Educational Conference

July 27th & 28th, 2018

9hrs CE / 6hrs TQ
 Including Prevention of Medical Errors.

MARGARITAVILLE RESORT & MARINA

245 Front Street
 Key West, FL 33040

For more information contact:
 Gloria Ayan @ 305.491.3747 or E-Mail: ocularhealthfoundation@gmail.com

Practice For Sale

ARE YOU IN CONTROL?

Don't buy a job...acquire a business.

Select clients have larger practices available for outright purchase. Positive cash flow and 100% financing available. America's leading optometry business development consultancy provides support before, during and after closure.

We'll help you acquire the optometry practice of your dreams with no cost to you. See our current offerings at:

<http://www.cleinman.com/buy>
800-331-5536



REVIEW
OF OPTOMETRY

Targeting Optometrists?

CLASSIFIED ADVERTISING WORKS

- JOB OPENINGS
- CME PROGRAMS
- PRODUCTS & SERVICES
- AND MORE...

Contact us today for classified advertising:
Toll free: **888-498-1460**
E-mail: sales@kerhgroup.com



Products and Services


ACCESS
HEALTHCARE CAPITAL

The key to making practice financing simple. Put our expertise to work for you to accomplish your professional goals. Under the guidance of Michael Hildebrandt, MHA CPA, Access Healthcare Capital offers loan services to open, purchase, or modernize Optometry Practices. Other loan services include, Equipment Financing, Restructuring, and Partnership Buy-in/Buy-Outs.

Easy App Up To \$250,000

- 100% Financing plus working capital
- Simplified Processing for loans up to \$350,000
- Partnership Buy-In Programs
- Tax & Accounting Services
- Terms up to 15 years
- Application Only for equipment and technology purchases
- Consulting

We also offer Consulting, Tax, and Accounting Services. Call to schedule a phone consultation today.
www.accesshealthcarecapital.com • michael@narxeye.com • 1.888.727.4470



Contact us today for classified advertising:
Toll free: **888-498-1460**
E-mail: sales@kerhgroup.com

REVIEW
OF OPTOMETRY

MD Stem Cells

The Solution to Vision Loss
Stems From Us

- Network with MD Stem Cells - leader in Ocular Adult Stem Cell treatment
- Build your practice in Regenerative Eye Care
- Peer Reviewed Publications

Compensation to practitioners for required Follow-up exams

For information contact:
MD Stem Cells - Dr. Steven Levy
stevenlevy@mdstemcells.com
203-423-9494

Practice Consultants

Practice Sales • Appraisals • Consulting
www.PracticeConsultants.com

**PRACTICES FOR SALE
NATIONWIDE**

Visit us on the Web or call us to learn more about our company and the practices we have available.

info@PracticeConsultants.com

800-576-6935

www.PracticeConsultants.com

Place Your Ad Here!
Toll free: **888-498-1460**
E-mail: sales@kerhgroup.com



Through the Grapevine

By Andrew S. Gurwood, OD

History

A 26-year-old Caucasian female presented for an eye examination without any chief complaints. She had not had an eye evaluation in more than five years and wanted to update her medical status. She reported no history of ocular disease or systemic illnesses of any kind. She also denied having allergies of any kind.

Diagnostic Data

Her best-corrected visual acuity was measured at 20/20 OU. An external examination was deemed to be normal and no evidence of afferent pupillary defect was seen.

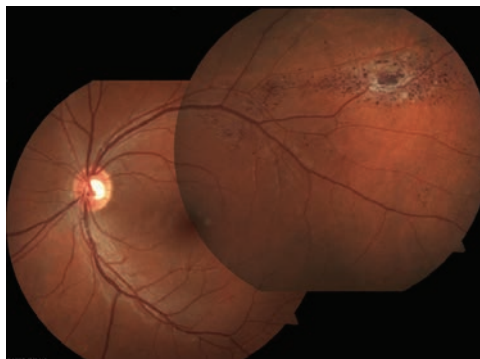A refractive evaluation, however, uncovered that she had a mild hyperopia of +0.50D. Biomicroscopy revealed normal lids and

lashes in both eyes with normal, healthy anterior segment structures. The intra-ocular

pressures for both of her eyes was measured at 16mm Hg with the use of Goldmann applanation. The pertinent posterior segment finding is documented in the fundus photographs provided.

Your Diagnosis

Does the patient's case presented require any additional tests, his-



The findings in these fundus photographs portray a 26-year-old patient who presented without any complaint. Does the imaging provide insight into any signs of ocular disease?

tory or information? What steps would you take to manage this patient? Based on the information provided, what diagnosis would you make? What is the patient's most likely prognosis? To find the answers and read about how this case was managed, please visit *Review of Optometry* online at www.reviewofoptometry.com. ■

Retina Quiz Answers (from page 112): 1) c; 2) d; 3) c; 4) a; 5) a.

Next Month in the Mag

Coming in June, *Review of Optometry* will present its Annual Retina Report.

Topics include:

- *When Substance Abuse Reaches the Retina: A Guide for Optometrists*
- *Infectious Retinitis: Diagnosis and Differentials*
- *Triaging of Retinal Hemorrhages: When to Monitor and When to Treat?*

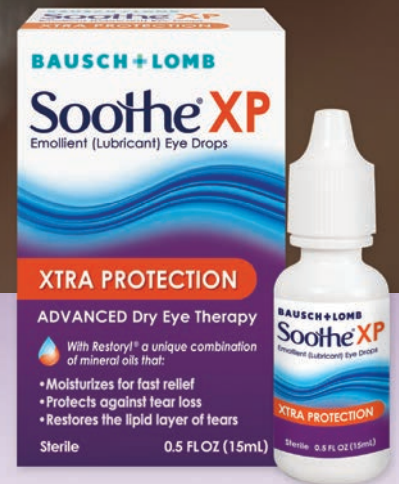Also in this issue:

- *Warding Off the Blues: What Optometrists Should Know about Blue Light Exposure and the Eye*
- *Diagnostic Glaucoma Testing: Yesterday, Today and Tomorrow*

REVIEW OF OPTOMETRY (ISSN 0147-7633) IS PUBLISHED MONTHLY, 12 TIMES A YEAR BY JOBSON MEDICAL INFORMATION LLC, 440 9TH AVENUE, 14TH FLOOR, NEW YORK, NY 10013-1678. PERIODICALS POSTAGE PAID AT NEW YORK, NY AND ADDITIONAL MAILING OFFICES. POSTMASTER: SEND ADDRESS CHANGES TO REVIEW OF OPTOMETRY, PO BOX 81, CONGERS, NY 10920-0081. SUBSCRIPTION PRICES: US: ONE YEAR \$56; TWO YEARS \$97, CANADA: ONE YEAR \$88, TWO YEARS \$160, INT'L: ONE YEAR \$209, TWO YEARS \$299. FOR SUBSCRIPTION INFORMATION CALL TOLL-FREE (877) 529-1746 (USA); OUTSIDE USA, CALL (845) 267-3065. OR EMAIL US AT REVOPOTOMETRY@CAMBEYWEST.COM. PUBLICATIONS MAIL AGREEMENT NO: 40612608. CANADA RETURNS TO BE SENT TO BLEUCHIP INTERNATIONAL, P.O. BOX 25542, LONDON, ON N6C 6B2.

For Dry Eye/MGD Patients

The eye's protective layer is thinner than a human hair, and it's what stands between the eyes and the world.



MGD can cause the lipid layer to break down. Soothe® XP helps replenish this layer.

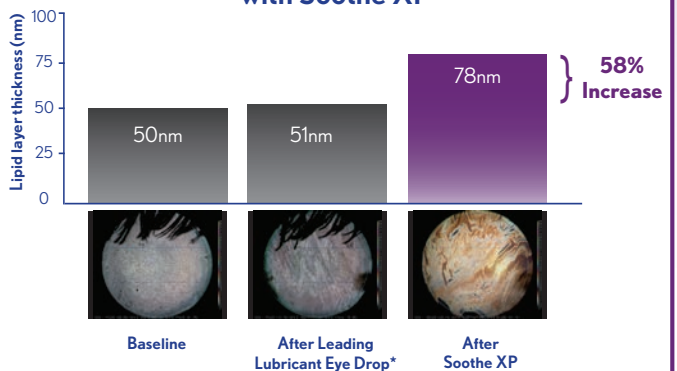
- Up to 86% of patients reporting dry eye symptoms have Meibomian Gland Dysfunction (MGD).¹
- MGD can cause the lipid layer to break down, which may lead to a compromised tear film.²
- Soothe XP contains Restoryl® mineral oils that can benefit MGD patients by helping to restore the lipid layer, seal in moisture, and protect against tear loss.

¹ Lemp MA et al. Distribution of Aqueous-Deficient and Evaporative Dry Eye in a Clinic-Based Patient Cohort: A Retrospective Study. *Cornea*. 2012; 31:472-478.

² Horwath-Winter J. Prevalence of MGD in a clinical dry eye population. *Acta Ophthalmol* 2011; 89 (s248)-2334.

®/TM are trademarks of Bausch & Lomb Incorporated or its affiliates.
© 2018 Bausch & Lomb Incorporated. PNO8612 SXP0018 USA.18

Improved lipid layer thickness after treatment with Soothe XP



*Non-lipid containing eye drop (Systane Ultra)

Lipid layer thickness (LLT) prior to and 15 minutes following a single drop of emollient or non-emollient eye drop in dry eyes with meibomian gland dysfunction. Data are the mean (±SD) LLT based on stroboscopic video color microscope (SVCM) measurements in study eyes (qualifying eye in subjects with only one qualifying eye, or the eye with the lowest LLT at baseline in subjects with two qualifying eyes). p<0.001 paired t-test for the change from baseline. p<0.001, n=35, following a single drop.

BAUSCH + LOMB
See better. Live better.



Don't let Irritating Lens Face ruin your patients' important moments.

Recommend OPTI-FREE® Puremoist® with HydraGlyde® Moisture Matrix to help your patients stay comfortable in their contact lenses from morning 'til night.¹

3X

fewer patients report end-of-day dryness^{2*}

*Compared to habitual lens care solutions (at baseline); Based on patient responses to a survey after trying OPTI-FREE® Puremoist® solution for 2 weeks; n=10,602



SEE COMFORTABLY.™

1. Lally J, Ketelson H, Borazjani R, Senchyna M, Napier L. A new lens care solution provides moisture and comfort with today's contact lenses. *Optician*. 2011;241(6296):42-46. 2. Lemp J, Kern JR. Results from a global survey of contact lens-wearer satisfaction with OPTI-FREE® Puremoist® Multi-Purpose Disinfecting Solution. *Clinical Optometry*. 2013;5:39-46.