

REVIEW[®] OF OPTOMETRY

January 15, 2015

www.reviewofoptometry.com

EARN 2 CE CREDITS

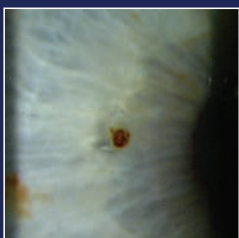
Annual Pharmaceutical Issue

GOING ANTIVIRAL: How to Bring **HERPES** to a **HALT**

A review of the most commonly prescribed topical and oral antiviral medications used to manage herpetic eye disease. **PAGE 50**

» ORAL MEDS: WHEN A DROP ISN'T ENOUGH, **PAGE 38**

» OFF LABEL, BUT ON TARGET, **PAGE 46**



ALSO INSIDE:

- NEW SERIES — ESSENTIAL PROCEDURES AT THE SLIT LAMP
PART 1: **FOREIGN BODY REMOVAL** IN 12 STEPS, **PAGE 22**
- AN INTRO TO **NEURO**, **PAGE 30**
- PRACTICAL PEARLS FOR MANAGING **ANTERIOR UVEITIS**, **PAGE 58**

NEW! -2.75 cyl now available

Unsurpassed in
COVERAGE

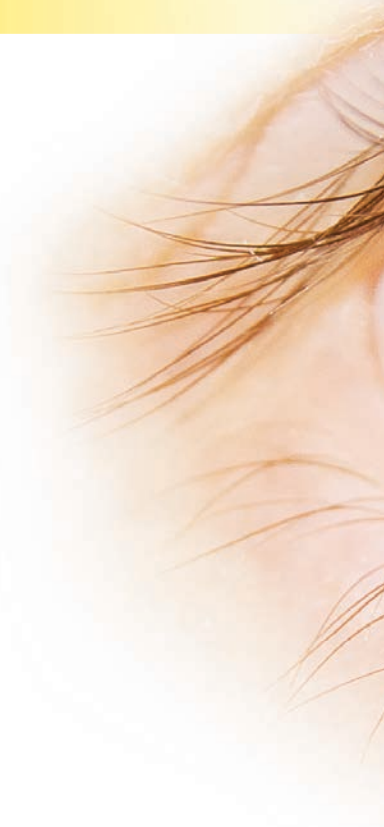Unbeaten in
COMFORT


THE WIDEST PARAMETER COVERAGE FOR SPHERICAL
AND ASTIGMATIC EYES

Now with the **first** and **only** silicone hydrogel toric lens with -2.75 cyl readily available,* ACUVUE® OASYS® Brand Contact Lenses provides coverage for 98% of astigmatic and spherical patients.

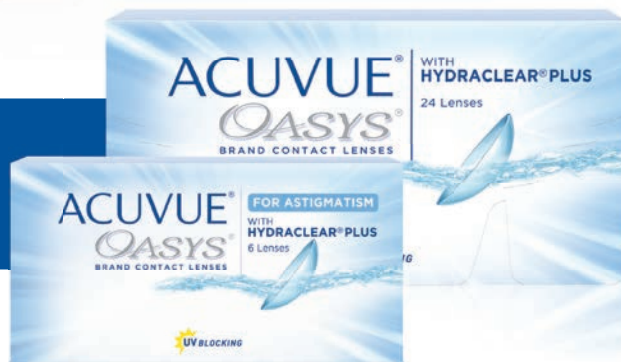NEVER BEEN BEATEN ON COMFORT BY ANY LEADING
MONTHLY LENS

Based on a review of published clinical studies and those registered on clinicaltrials.gov with comfort as an end point.





Feel confident that more of your patients
are covered and comfortable with
ACUVUE® OASYS® Brand



ACUVUE® Brand Contact Lenses are indicated for vision correction. As with any contact lens, eye problems, including corneal ulcers, can develop. Some wearers may experience mild irritation, itching or discomfort. Lenses should not be prescribed if patients have any eye infection, or experience eye discomfort, excessive tearing, vision changes, redness or other eye problems. Consult the package insert for complete information. Complete information is also available from VISTAKON® Division of Johnson & Johnson Vision Care, Inc., by calling 1-800-843-2020 or by visiting www.acuvueprofessional.com.

*Available without needing to place a special order. Contact Lens Manufacturer Published Parameters, June 2014.

ACUVUE®, ACUVUE® OASYS®, HYDRACLEAR® and VISTAKON® are trademarks of Johnson & Johnson Vision Care, Inc.

© Johnson & Johnson Vision Care, Inc. 2014 ACU-A44718 November 2014

ACUVUE®
OASYS®
BRAND CONTACT LENSES

FOR ASTIGMATISM

IN THE NEWS

All **children** aged 36 to 72 months should be have a **vision screening** annually (best practice) or at least once (acceptable minimum standard), according to the **National Expert Panel to the National Center for Children's Vision and Eye Health**. The panel's findings appear in the January issue of *Optometry & Vision Science*. "A best practice for children who fail vision screening includes documentation of the referral to and subsequent comprehensive eye examination by an optometrist or ophthalmologist," the panel advises.

About **93% of American adults** spend more than two hours per day using **digital devices**—a length of time that is increasing the prevalence of digital eyestrain, says **The Vision Council** in its "2015 Digital Eye Strain Report."

Digital eyestrain has grown exponentially with the increase in use of computers, smartphones, tablets and other electronic devices. The report attributes this trend primarily to factors including screens with small text held too close to the face, a reduced blink rate as a result of staring for prolonged periods and poorly designed work-spaces.

Adults with computer-oriented jobs are considered most at risk for digital eyestrain, followed closely by those who use electronic devices for recreational reading. **Children** are also at risk for digital eyestrain and subsequent problems, with one in four spending more than three hours per day using electronic devices. More than one in five parents reported concern about the impact of digital devices on their children's eyes, the report found.

High Blood Pressure is Now a Glaucoma Risk

A new study suggests that chronic hypertension does not protect against elevated IOP. **By Bill Kekevia, Senior Editor**

Instead of viewing hypertension as beneficial in the fight against glaucoma, it should be identified as a risk factor, an Australian research team suggests.

That's because, in older patients, any benefit from high blood pressure counteracting high intraocular pressure is lost as damage to blood vessels—a consequence of hypertension—becomes more prevalent, according to a study in the December issue of *Investigative Ophthalmology & Visual Science (IOVS)*.¹

The idea that hypertension has protective qualities against IOP elevation was supported by research conducted in the 1990s, which found systemic hypertension to be protective for younger patients, but a risk factor in older patients.² Those authors proposed that patients in the early stage of hypertension are likely to benefit from improved ocular perfusion pressure and blood flow to the eye.

In the recent experimental study in *IOVS*, researchers compared the effect of normal blood pressure with one-hour (acute) and four-week (chronic) hypertension in lab rats with elevated IOP.

The team found that rats with chronic hypertension did not get the same protection against elevated IOP. The researchers partially associate the effect with a reduced capacity for ocular blood flow to autoregulate in response to IOP

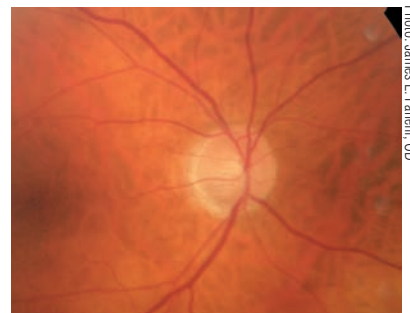


Photo: James L. Fanelli, OD

Contrary to earlier theories, chronic high blood pressure adds a risk for glaucoma.

elevation in chronic hypertension.

"What this means is that having high blood pressure for a longer time has compromised the eye's capacity to cope with high eye pressure. It seems that hypertension might damage the blood vessels in the eye so that they can't compensate for changes in blood flow when eye pressure increases," says researcher Bang V. Bui, PhD, BSc(optom), of the University of Melbourne.

The authors acknowledged that chronic hypertension in their experiment was limited to four weeks. They speculated that, with longer periods of hypertension and thus more severe vascular damage, the protective effect of high blood pressure might be further reduced.

1. He Z, Vingrys AJ, Armitage JA, et al. Chronic hypertension increases susceptibility to acute IOP challenge in rats. *Invest Ophthalmol Vis Sci*. 2014;55:7888-95.

2. Tielsch JM, Katz J, Sommer A, et al. Hypertension, perfusion pressure, and primary open-angle glaucoma. A population-based assessment. *Arch Ophthalmol*. 1995;113:216-21.

Tonometry Done Right

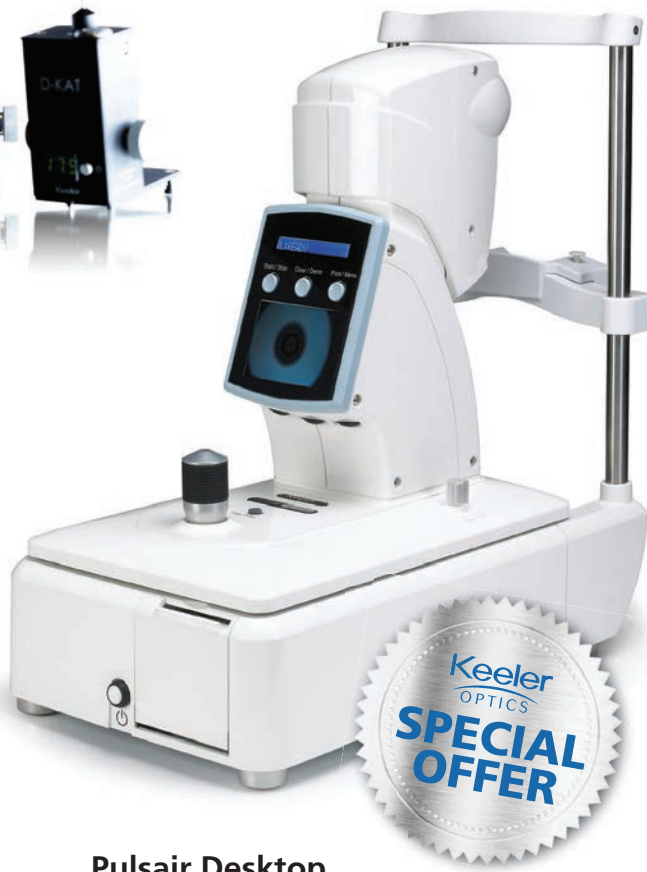new



D-KAT Digital
Keeler quality.



Intellipuff
The standard for hand held mobility.



Pulsair Desktop
Smallest footprint and simple to use!

*Purchase a Pulsair Desktop
by March 31, 2015 and get
a \$1,300 Instant Rebate!*

Buy Online!
keelerusa.com



Keeler
OPTICS

NJ ODs Seek to Retain Rx of Opioids

Optometrists in New Jersey are seeking to push through a bill to reinstate their privileges to prescribe hydrocodone, an opioid pain medication.

Optometrists lost this privilege in October 2014, when the Drug Enforcement Administration (DEA) rescheduled products containing hydrocodone from Schedule III to Schedule II, meaning that optometrists are no longer authorized to prescribe such products under state law.

“This change affects the ability of New Jersey optometrists to provide the best possible care to patients with ocular injuries and serious eye infections,” says Howard Cooper, executive director of the New Jersey Society of Optometric Physicians (NJSOP).

New Jersey optometrists had obtained such prescription rights in 2004, when their state legislature passed a bill that would allow them

to prescribe drugs in the Schedule III, IV and V categories.

The latest bill, S-2578/A-3922, does not expand ODs’ scope of practice but it would restore their ability to prescribe hydrocodone, not other medications. The bill argues that optometrists have for many years prescribed products containing hydrocodone without incident.

NJSOP has been working collaboratively with state legislators to address this change in schedule, Mr. Cooper says. The collaboration seems to be making some inroads on the bill. In late December 2014, S-2578 passed the Senate unanimously. The NJSOP is working to have the Assembly version heard in committee when the legislature returns in January, Mr. Cooper adds.

“Our interests are to ensure that New Jersey optometrists provide the best possible care to their patients and, when appropriate,

treat patients with ocular injuries and serious eye infections with the proper medications,” he says.

The Medical Society of New Jersey (MSNJ) has taken the position that it’s appropriate to restrict the prescription of opioids in light of ongoing state efforts to prevent and treat chemical dependence on this class of drugs.

In a letter from MSNJ to the members of the New Jersey Senate Commerce Committee, the society cites that the legislature prudently limited ODs’ prescription rights when the original expanded scope of practice bill was passed in 2004 because of the “high potential for abuse, which may lead to severe psychological or physical dependence” on Schedule II dangerous substances.

On the federal level, the American Optometric Association says it fought against the rescheduling of hydrocodone drugs.

But despite the best efforts of the AOA and other organizations, the DEA moved forward with the decision.

Since hydrocodone’s move from a Schedule III to a Schedule II drug, the AOA has worked with individual states to amend the law, according to the AOA.

Several other states—Alaska, Arkansas, Arizona, California, Colorado, Georgia, Illinois, Kentucky, Michigan, Oklahoma and Utah—have since enacted similar legislation authorizing optometrists licensed in those states to continue prescribing pharmaceutical agents containing hydrocodone as they did prior to federal rescheduling.

Stay tuned as the New Jersey legislature takes up the bill again this month.

Weight Loss Surgery Can Impact Eyes

Weight loss surgery can improve your waistline—but hurt your eyes, according to a recent study published in *Obesity Surgery*.

People who have the procedure should take vitamin supplements to avoid ocular complications, investigators advise.

Bariatric surgery (such as gastric binding or gastric bypass) involves restriction or removal of some of the stomach, which limits the body’s ability to absorb key nutrients, resulting in vitamin deficiencies.¹

This recent study specifically shows that patients who have undergone bariatric surgery (especially “malabsorptive” procedures) may lack nutrients essential to ocular health, including vitamins A, E, B₁ (thiamine) and copper.² These nutrients help with the normal functioning of the eye and optic system.

Vitamin A deficiency, in particular, is linked to eye-related complications developing after bariatric surgery.

The researchers recommend that patients who have undergone bariatric surgery adopt some form of supplement regimen.

1. Shankar P, Boylan M, Sriram K. Micronutrient deficiencies after bariatric surgery. *Nutrition*. 2010 Nov-Dec;26(11-12):1031-7.

2. Guerreiro RA, Ribeiro R. Ophthalmic complications of bariatric surgery. *Obes Surg*. 2015 Jan;25(1):167-73.



Monotherapy Maintained.

Proven IOP reduction¹

Established tolerability with
low discontinuation rate²

On Your Terms.

Broad preferred coverage³

Comprehensive patient support

INDICATION

LUMIGAN® (bimatoprost ophthalmic solution) 0.01% is indicated for the reduction of elevated intraocular pressure in patients with open angle glaucoma or ocular hypertension.

IMPORTANT SAFETY INFORMATION

WARNINGS AND PRECAUTIONS

LUMIGAN® 0.01% causes changes to pigmented tissues, mostly increased pigmentation of the iris, eyelid, and eyelashes as long as LUMIGAN® 0.01% is administered. Iris color change may not be noticeable for several months to years. After discontinuation of bimatoprost, iris pigmentation is likely to be permanent, while eyelid and eyelash changes have been reported to be reversible in some patients. Patients should be informed of the possibility of increased pigmentation. The long term effects of increased pigmentation are not known.

Prostaglandin analogs, including bimatoprost, have been reported to cause intraocular inflammation. These products may also exacerbate inflammation, so use with caution in patients with active intraocular inflammation (e.g., uveitis). Macular edema, including cystoid macular edema, has been reported with LUMIGAN® 0.01%. LUMIGAN® 0.01% should be used with caution in aphakic patients, in pseudophakic patients with a torn posterior lens capsule, or in patients with known risk factors for macular edema. Remove contact lenses prior to instillation of LUMIGAN® 0.01% and reinsert after 15 minutes.

ADVERSE REACTIONS

The most common adverse reaction was conjunctival hyperemia (31%). Approximately 1.6% of patients discontinued therapy due to conjunctival hyperemia. Other adverse drug reactions (reported in 1 to 4% of patients) with LUMIGAN® 0.01% included conjunctival edema, conjunctival hemorrhage, eye irritation, eye pain, eye pruritus, erythema of eyelid, eyelids pruritus, growth of eyelashes, hypertrichosis, instillation site irritation, punctate keratitis, skin hyperpigmentation, vision blurred, and visual acuity reduced.

Please see Brief Summary of the full Prescribing Information on adjacent page.

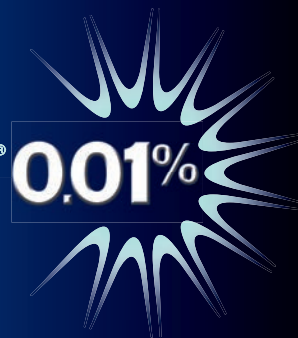1. LUMIGAN® Prescribing Information. 2. Katz LJ, Cohen JS, Batoosingh AL, Felix C, Shu V, Schiffman RM. Twelve-month, randomized, controlled trial of bimatoprost 0.01%, 0.0125%, and 0.03% in patients with glaucoma or ocular hypertension. *Am J Ophthalmol.* 2010;149(4):661-671. 3. Managed Markets Insight & Technology, LLC, database, as of October 2014.

 ALLERGAN

©2014 Allergan, Inc., Irvine, CA 92612. ®marks owned by Allergan, Inc. Managed Markets Insight & Technology is a portfolio company of Susquehanna Growth Equity. www.lumigan.com APC43HN14 143788



LUMIGAN® 0.01%
(bimatoprost ophthalmic solution) 0.01%



LUMIGAN® 0.01%

(bimatoprost ophthalmic solution)

Brief Summary—Please see the LUMIGAN® 0.01% package insert for full Prescribing Information.

INDICATIONS AND USAGE

LUMIGAN® (bimatoprost ophthalmic solution) 0.01% is indicated for the reduction of elevated intraocular pressure in patients with open angle glaucoma or ocular hypertension.

CONTRAINDICATIONS

None

WARNINGS AND PRECAUTIONS

Pigmentation: Bimatoprost ophthalmic solution has been reported to cause changes to pigmented tissues. The most frequently reported changes have been increased pigmentation of the iris, periorbital tissue (eyelid) and eyelashes. Pigmentation is expected to increase as long as bimatoprost is administered. The pigmentation change is due to increased melanin content in the melanocytes rather than to an increase in the number of melanocytes. After discontinuation of bimatoprost, pigmentation of the iris is likely to be permanent, while pigmentation of the periorbital tissue and eyelash changes have been reported to be reversible in some patients. Patients who receive treatment should be informed of the possibility of increased pigmentation. The long term effects of increased pigmentation are not known.

Iris color change may not be noticeable for several months to years. Typically, the brown pigmentation around the pupil spreads concentrically towards the periphery of the iris and the entire iris or parts of the iris become more brownish. Neither nevi nor freckles of the iris appear to be affected by treatment. While treatment with **LUMIGAN®** (bimatoprost ophthalmic solution) 0.01% can be continued in patients who develop noticeably increased iris pigmentation, these patients should be examined regularly [see Patient Counseling Information (17.1)].

Eyelash Changes: **LUMIGAN®** 0.01% may gradually change eyelashes and vellus hair in the treated eye. These changes include increased length, thickness, and number of lashes. Eyelash changes are usually reversible upon discontinuation of treatment.

Intraocular Inflammation: Prostaglandin analogs, including bimatoprost, have been reported to cause intraocular inflammation. In addition, because these products may exacerbate inflammation, caution should be used in patients with active intraocular inflammation (e.g., uveitis).

Macular Edema: Macular edema, including cystoid macular edema, has been reported during treatment with bimatoprost ophthalmic solution. **LUMIGAN®** 0.01% should be used with caution in aphakic patients, in pseudophakic patients with a torn posterior lens capsule, or in patients with known risk factors for macular edema.

Bacterial Keratitis: There have been reports of bacterial keratitis associated with the use of multiple-dose containers of topical ophthalmic products. These containers had been inadvertently contaminated by patients who, in most cases, had a concurrent corneal disease or a disruption of the ocular epithelial surface [see Patient Counseling Information (17.3)].

Use with Contact Lenses: Contact lenses should be removed prior to instillation of **LUMIGAN®** 0.01% and may be reinserted 15 minutes following its administration.

ADVERSE REACTIONS

Clinical Studies Experience: Because clinical studies are conducted under widely varying conditions, adverse reaction rates observed in the clinical studies of a drug cannot be directly compared to rates in the clinical studies of another drug and may not reflect the rates observed in practice.

In a 12-month clinical study with bimatoprost ophthalmic solutions 0.01%, the most common adverse reaction was conjunctival hyperemia (31%). Approximately 1.6% of patients discontinued therapy due to conjunctival hyperemia. Other adverse drug reactions (reported in 1 to 4% of patients) with **LUMIGAN®** 0.01% in this study included conjunctival edema, conjunctival hemorrhage, eye irritation, eye pain, eye pruritus, erythema of eyelid, eyelids pruritus, growth of eyelashes, hypertrichosis, instillation site irritation, punctate keratitis, skin hyperpigmentation, vision blurred, and visual acuity reduced.

Postmarketing Experience: The following reaction has been identified during postmarketing use of **LUMIGAN®** 0.01% in clinical practice. Because it was reported voluntarily from a population of unknown size, estimates of frequency cannot be made. The reaction, which has been chosen for inclusion due to either its seriousness, frequency of reporting, possible causal connection to **LUMIGAN®** 0.01%, or a combination of these factors, includes headache.

In postmarketing use with prostaglandin analogs, periorbital and lid changes including deepening of the eyelid sulcus have been observed.

USE IN SPECIFIC POPULATIONS

Pregnancy: Pregnancy Category C

Teratogenic effects: In embryo/fetal developmental studies in pregnant mice and rats, abortion was observed at oral doses of bimatoprost which achieved at least 33 or 97 times, respectively, the maximum intended human exposure based on blood AUC levels.

At doses at least 41 times the maximum intended human exposure based on blood AUC levels, the gestation length was reduced in the dams, the incidence of dead fetuses, late resorptions, peri- and postnatal pup mortality was increased, and pup body weights were reduced.

There are no adequate and well-controlled studies of **LUMIGAN®** (bimatoprost ophthalmic solution) 0.01% administration in pregnant women. Because animal reproductive studies are not always predictive of human response **LUMIGAN®** 0.01% should be administered during pregnancy only if the potential benefit justifies the potential risk to the fetus.

Nursing Mothers: It is not known whether **LUMIGAN®** 0.01% is excreted in human milk, although in animal studies, bimatoprost has been shown to be excreted in breast milk. Because many drugs are excreted in human milk, caution should be exercised when **LUMIGAN®** 0.01% is administered to a nursing woman.

Pediatric Use: Use in pediatric patients below the age of 16 years is not recommended because of potential safety concerns related to increased pigmentation following long-term chronic use.

Geriatric Use: No overall clinical differences in safety or effectiveness have been observed between elderly and other adult patients.

Hepatic Impairment: In patients with a history of liver disease or abnormal ALT, AST and/or bilirubin at baseline, bimatoprost 0.03% had no adverse effect on liver function over 48 months.

OVERDOSAGE

No information is available on overdosage in humans. If overdose with **LUMIGAN®** (bimatoprost ophthalmic solution) 0.01% occurs, treatment should be symptomatic. In oral (by gavage) mouse and rat studies, doses up to 100 mg/kg/day did not produce any toxicity. This dose expressed as mg/m² is at least 210 times higher than the accidental dose of one bottle of **LUMIGAN®** 0.01% for a 10 kg child.

NONCLINICAL TOXICOLOGY

Carcinogenesis, Mutagenesis, Impairment of Fertility: Bimatoprost was not carcinogenic in either mice or rats when administered by oral gavage at doses of up to 2 mg/kg/day and 1 mg/kg/day respectively (at least 192 and 291 times the recommended human exposure based on blood AUC levels respectively) for 104 weeks.

Bimatoprost was not mutagenic or clastogenic in the Ames test, in the mouse lymphoma test, or in the *in vivo* mouse micronucleus tests.

Bimatoprost did not impair fertility in male or female rats up to doses of 0.6 mg/kg/day (at least 103 times the recommended human exposure based on blood AUC levels).

PATIENT COUNSELING INFORMATION

Potential for Pigmentation: Advise patients about the potential for increased brown pigmentation of the iris, which may be permanent. Also inform patients about the possibility of eyelid skin darkening, which may be reversible after discontinuation of **LUMIGAN®** (bimatoprost ophthalmic solution) 0.01%.

Potential for Eyelash Changes: Inform patients of the possibility of eyelash and vellus hair changes in the treated eye during treatment with **LUMIGAN®** 0.01%. These changes may result in a disparity between eyes in length, thickness, pigmentation, number of eyelashes or vellus hairs, and/or direction of eyelash growth. Eyelash changes are usually reversible upon discontinuation of treatment.

Handling the Container: Instruct patients to avoid allowing the tip of the dispensing container to contact the eye, surrounding structures, fingers, or any other surface in order to avoid contamination of the solution by common bacteria known to cause ocular infections. Serious damage to the eye and subsequent loss of vision may result from using contaminated solutions.

When to Seek Physician Advice: Advise patients that if they develop an intercurrent ocular condition (e.g., trauma or infection), have ocular surgery, or develop any ocular reactions, particularly conjunctivitis and eyelid reactions, they should immediately seek their physician's advice concerning the continued use of **LUMIGAN®** 0.01%.

Use with Contact Lenses: Advise patients that **LUMIGAN®** 0.01% contains benzalkonium chloride, which may be absorbed by soft contact lenses. Contact lenses should be removed prior to instillation of **LUMIGAN®** 0.01% and may be reinserted 15 minutes following its administration.

Use with Other Ophthalmic Drugs: Advise patients that if more than one topical ophthalmic drug is being used, the drugs should be administered at least five (5) minutes between applications.

©2014 Allergan, Inc., Irvine, CA 92612

® marks owned by Allergan, Inc.

Patented. See: www.allergan.com/products/patent_notices

Made in the U.S.A.

APC87B014 based on 71807US14.

Rx only

 ALLERGAN

Most Ocular Vitamins Don't Match AREDS

Of 11 top-selling ocular vitamins, seven don't contain the ingredient dosages identical to the formulas identified by the Age-Related Eye Disease Study (AREDS) or AREDS2, according to a study published online in *Ophthalmology*.

The study also found that claims made in the promotional materials of all of the products lack scientific evidence.

In their analysis, the researchers identified the five top-selling brands of ocular nutritional supplements (during June 2011 to June 2012) and compared the brands' 11 products to the exact AREDS and AREDS2 formulas. They found that all of the products did contain the ingredients from the AREDS or AREDS2 formulas, but only four of the products had doses equivalent to AREDS or AREDS2 ingredients. Another four of the products contained lower doses of all the AREDS or AREDS2 ingredients. Also, four of the products included addition-

al vitamins, minerals and herbal extracts not part of the AREDS or AREDS2 formulas.

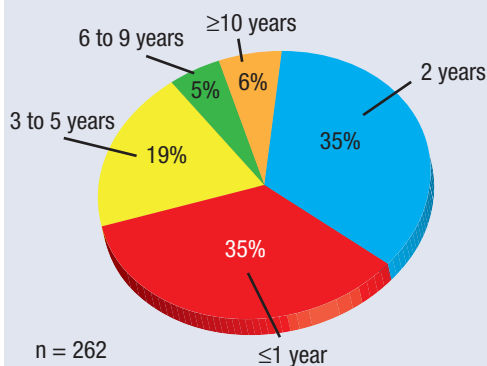
In addition, all 11 of the products' promotional materials contained claims that the supplements "support," "protect," "help" or "promote" vision and eye health; however, none had language stating that nutritional supplements have been proven effective only in people with specific stages of AMD.

The supplements' promotional materials also lacked another important message: "At this time, nutritional supplements have yet to be proven clinically effective in preventing the onset of eye diseases such as cataracts and AMD," Dr. Yong says.

Results of the study's product analysis can be found at: www.aaopt.org/newsroom/release/upload/Table-1-OcularNutritionalSupplements-InPress.pdf.

Yong JJ, Scott IU, Greenberg PB. Ocular nutritional supplements: Are their ingredients and manufacturers' claims evidence-based? *Ophthalmology*. 2014 Nov 20. [Epub ahead of print]

Doctor, how long has it been since *you* had a complete eye exam?



Source: *Review of Optometry's* 2014 Diagnostic Technology Survey

Nearly one-third (30%) of ODs haven't had a complete eye exam in three years or more, according to our recent Diagnostic Technology Survey.

Still, that's better than what ODs said in our survey in 2012, in which 34% reported that it'd been longer than three years since their last exam.

The good news is that 70% of ODs have had an eye exam in the past two years.

REVIEW[®] OF OPTOMETRY

BUSINESS OFFICES
11 CAMPUS BLVD., SUITE 100
NEWTOWN SQUARE, PA 19073

CEO, INFORMATION SERVICES GROUP
MARC FERRARA
(212) 274-7062 • MFERRARA@JOBSON.COM

PUBLISHER
JAMES HENNE
(610) 492-1017 • JHENNE@JOBSON.COM

REGIONAL SALES MANAGER
MICHELE BARRETT
(610) 492-1014 • MBARRETT@JOBSON.COM

REGIONAL SALES MANAGER
MICHAEL HOSTER
(610) 492-1028 • MHOSTER@JOBSON.COM

VICE PRESIDENT, OPERATIONS
CASEY FOSTER
(610) 492-1007 • CFOSTER@JOBSON.COM

VICE PRESIDENT, CLINICAL CONTENT
PAUL M. KARPECKI, OD, FAAO
PKARPECKI@JOBSON.COM

PRODUCTION MANAGER
SCOTT TOBIN
(610) 492-1011 • STOBIN@JOBSON.COM

SENIOR CIRCULATION MANAGER
HAMILTON MAHER
(212) 219-7870 • HMAHER@JHIHEALTH.COM

CLASSIFIED ADVERTISING
(888) 498-1460

SUBSCRIPTIONS
\$56 A YEAR, \$88 (US) IN CANADA,
\$209 (US) IN ALL OTHER COUNTRIES.

SUBSCRIPTION INQUIRIES
(877) 529-1746 (US ONLY);
OUTSIDE US, CALL (847) 763-9630

CIRCULATION
PO Box 2025
SKOKIE, IL 60076
TEL: (TOLL FREE) 1-877-529-1746
OUTSIDE US: (847) 763-9630
FAX: (847) 763-9631



CEO, INFORMATION SERVICES GROUP
MARC FERRARA

SENIOR VICE PRESIDENT, OPERATIONS
JEFF LEVITZ

SENIOR VICE PRESIDENT, HUMAN RESOURCES
LORRAINE ORLANDO

VICE PRESIDENT, CREATIVE SERVICES & PRODUCTION
MONICA TETTAMANZI

VICE PRESIDENT, CIRCULATION
EMELDA BAREA



MEASURE IN COLOR

ICARE COLORS ON SALE AS LOW AS \$2995*!

RANDALL THOMAS, OD
& RON MELTON, OD

"As soon as we had the Icare tonometry performed on ourselves, our skepticism turned to amazed acceptance and we couldn't wait to use it on our patients. It is indeed asymptomatic in virtually all instances and certainly atraumatic in all cases."

* Limited quantities available. Call 609.617.3403 to find out how to purchase an Icare Tonometer for as low as \$2995.



NO CALIBRATION
NO DROPS, NO AIR

Contents

Review of Optometry January 2015

Annual Pharmaceutical Issue

38 When a Drop Isn't Enough

Oral antibiotics and analgesics often are clinically necessary when treating certain ocular conditions. Here's a rundown of our favorite systemic agents.

By Carl H. Spear, OD, MBA, and Mark Obenchain, OD

46 Off Label, But on Target

Using drugs off label is not only permissible, it's often standard of care. Get to know the following non-FDA approved indications (if you don't know them already).

By John Murphy, Executive Editor

Earn 2 CE Credits:



50 Going Antiviral: How to Bring Herpes to a Halt


A review of the most commonly prescribed topical and oral antiviral medications used to manage herpetic eye disease.

By Michael J. Lyons, OD

Essential Procedures at the Slit Lamp: 22 Foreign Body Removal in 12 Steps

Need to remove a foreign body and rust ring? We'll show you how it's done. Here's the first in a new, six-part, print-and-video instructional series.

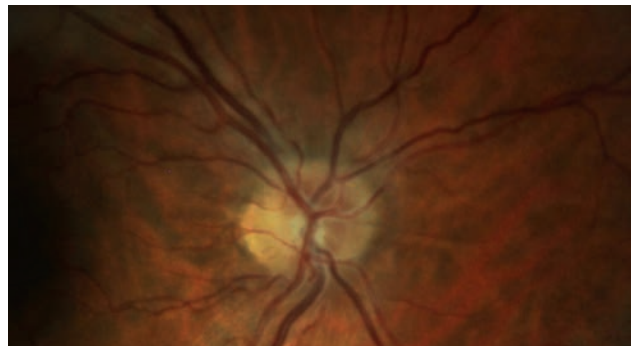By Joseph Shetler, OD, and Nathan Lighthizer, OD



30 An Intro to Neuro

Neuro-ophthalmic disorders can be intimidating—but you can diagnose and manage many of them. Here's a simple guide for these serious presentations.

By Michael Trottni, OD, and Michael DelGiodice, OD



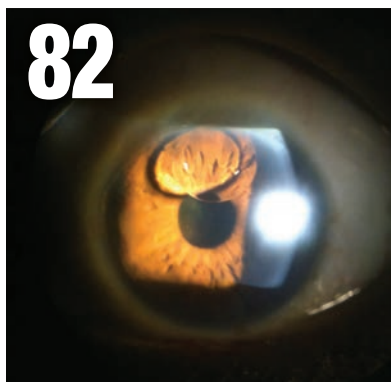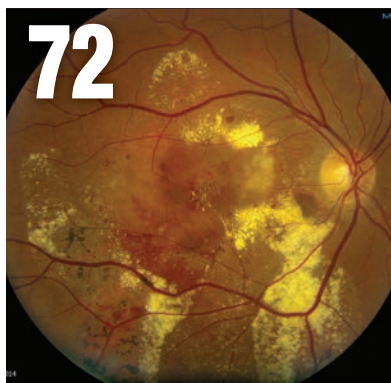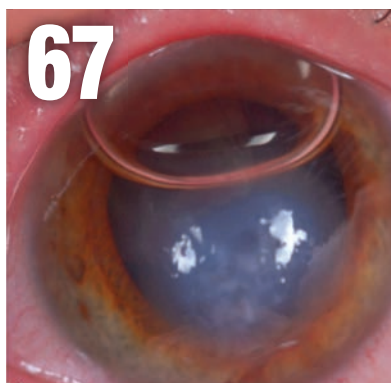
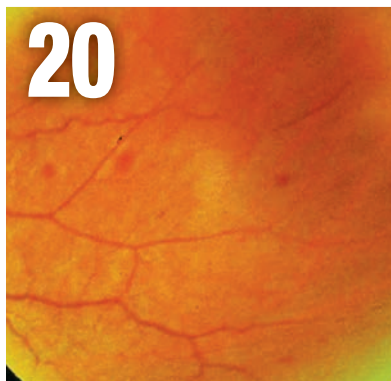58 Practical Pearls for Managing Anterior Uveitis

When diagnosing uveitis, let the history and signs guide your treatment plan. By Kyle D. Dohm, OD

Departments

Review of Optometry January 2015

- 4 News Review**
- 16 Outlook**
Optometry, We've Got You Covered
JACK PERSICO
- 18 Chairside**
This Column Can Rent a Car!
MONTGOMERY VICKERS, OD
- 20 Clinical Quandaries**
This Eye is Choking
PAUL C. AJAMIAN, OD
- 65 Coding Connection**
New Year, New Connections
JOHN RUMPAKIS, OD, MBA
- 67 Cornea + Contact Lens Q+A**
Gas it up
JOSEPH P. SHOVLIN, OD
- 68 Review of Systems**
Tiny Viruses, Major Diseases
CARLO J. PELINO, OD
JOSEPH J. PIZZIMENTI, OD
- 72 Retina Quiz**
Two Decades of Poor Vision
MARK T. DUNBAR, OD
- 74 Therapeutic Review**
Don't Delay Optic Neuritis Dx
JOSEPH W. SOWKA, OD
ALAN G. KABAT, OD
- 79 Ocular Surface Review**
The Evolution of Dry Eye
PAUL M. KARPECKI, OD
- 82 Surgical Minute**
Conquering Cataracts
DEREK N. CUNNINGHAM, OD
WALTER O. WHITLEY, OD, MBA
- 84 Product Review**
- 85 Meetings + Conferences**
- 85 Advertisers Index**
- 86 Classifieds**
- 90 Diagnostic Quiz**
Her Vision is on the Bubble
ANDREW S. GURWOOD, OD



Stock Images: ©iStock.com/JobsonHealthcare

On The Web >> and more

Check out our multimedia and continuing education online at:
www.reviewofoptometry.com

Digital Edition



Left your copy of *Review of Optometry* at the office? No problem! Access *Review* on your computer or mobile device!

Go to www.reviewofoptometry.com and click on the digimag link for the current issue.

Facebook and Twitter



For daily updates, "Like" our page on Facebook or "Follow" us on Twitter!

- www.facebook.com/revoptom
- <http://twitter.com/#!/revoptom>

Look for augmented content and special offers from *Review* and our advertisers. Specified pages work in conjunction with your smartphone or other mobile device to enhance the experience. With Layar, interactive content leaps off the page!



Step 1: Download the free Layar app for iPhone or Android.



Step 2: Look for pages with the Layar Logo.  INTERACTIVE PRINT



Step 3: Open the Layar app, hold the phone above the page and tap to scan it. Hold the phone above the page to view the interactive content.

The first 150 app downloads and completed forms will be entered into a drawing for a complimentary registration to one of *Review's* 14-hour CE meetings, valued at \$495.


LOTEMAX[®] GEL—UNIQUE FORMULATION DESIGNED TO CONTROL INFLAMMATION

 **MUCOADHESIVE TECHNOLOGY**—
Engineered to adhere to the ocular surface¹⁻³

 **DOSE UNIFORMITY**—
No shaking required to resuspend drug^{1,4,5}

 **LOW PRESERVATIVE AND TWO
KNOWN MOISTURIZERS**^{1,2,4,6}

 **PROVEN EFFICACY AND
ESTABLISHED SAFETY**^{1,2,7}



Indications and Usage

- LOTE[®]MAX GEL is a corticosteroid indicated for the treatment of post-operative inflammation and pain following ocular surgery

Important Risk Information about LOTE[®]MAX GEL

- LOTE[®]MAX GEL is contraindicated in most viral diseases of the cornea and conjunctiva including epithelial herpes simplex keratitis (dendritic keratitis), vaccinia, and varicella, and also in mycobacterial infection of the eye and fungal diseases of ocular structures
- Intraocular pressure (IOP) increase—Prolonged use of corticosteroids may result in glaucoma with damage to the optic nerve, defects in visual acuity and fields of vision. If this product is used for 10 days or longer, IOP should be monitored
- Cataracts—Use of corticosteroids may result in posterior subcapsular cataract formation
- Delayed healing—Use of steroids after cataract surgery may delay healing and increase the incidence of bleb formation and occurrence of perforations in those with diseases causing corneal and scleral thinning. The initial prescription and renewal of the medication order should be made by a physician only after examination of the patient with the aid of magnification
- Bacterial infections—Prolonged use of corticosteroids may suppress the host response and thus increase the hazard of secondary ocular infection. In acute purulent conditions, steroids may mask infection or enhance existing infections
- Viral infections—Use of corticosteroid medication in the treatment of patients with a history of herpes simplex requires great caution. Use of ocular steroids may prolong the course and exacerbate the severity of many viral infections of the eye (including herpes simplex)
- Fungal infections—Fungal infections of the cornea are particularly prone to develop coincidentally with long-term local steroid application. Fungus invasion must be considered in any persistent corneal ulceration where a steroid has been used or is in use
- Contact lens wear—Patients should not wear contact lenses when using LOTE[®]MAX GEL
- The most common ocular adverse drug reactions were anterior chamber inflammation (5%), eye pain (2%) and foreign body sensation (2%)

Please see brief summary of full prescribing information on adjacent page.

References: 1. LOTE[®]MAX GEL Prescribing Information, September 2012. 2. Fong R, Leitritz M, Siou-Mermet R, Erb T. Loteprednol etabonate gel 0.5% for postoperative pain and inflammation after cataract surgery: results of a multicenter trial. *Clin Ophthalmol*. 2012;6:1113-1124. 3. Shaikh R, Singh TRR, Garland MJ, Woolfson AD, Donnelly RF. Mucoadhesive drug delivery systems. *J Pharm Bioallied Sci*. 2011;3(1):89-100. 4. Data on file, Bausch & Lomb Incorporated. 5. Coffey MJ, Davio SR. Viscoelastic and sedimentation characterization of loteprednol etabonate ophthalmic gel, 0.5%. Poster presented at: Association for Research in Vision and Ophthalmology (ARVO); May 6-10, 2012; Fort Lauderdale, FL. Poster #6283/D1143. 6. Lotemax Prescribing Information, April 2006. 7. Rajpal RK, Roel I, Siou-Mermet R, Erb T. Efficacy and safety of loteprednol etabonate 0.5% gel in the treatment of ocular inflammation and pain after cataract surgery. *J Cataract Refract Surg*. 2013;39:158-167.

^{®/™} are trademarks of Bausch & Lomb Incorporated or its affiliates. ©2013 Bausch & Lomb Incorporated. US/LGX/13/0049 [4/13]

BAUSCH + LOMB



LOTE[®]MAX GEL
loteprednol etabonate
ophthalmic gel 0.5%

DISCOVER THE POWER OF GEL

BAUSCH + LOMB

LOTEMAX[®]

loteprednol etabonate
ophthalmic gel 0.5%

Brief Summary: Based on full prescribing information.

To report SUSPECTED ADVERSE REACTIONS, contact Bausch & Lomb at 1-800-323-0000 or FDA at 1-800-FDA-1088 or www.fda.gov/medwatch

INDICATIONS AND USAGE

LOTEMAX is a corticosteroid indicated for the treatment of post-operative inflammation and pain following ocular surgery.

DOSAGE AND ADMINISTRATION

Invert closed bottle and shake once to fill tip before instilling drops.

Apply one to two drops of LOTEMAX into the conjunctival sac of the affected eye four times daily beginning the day after surgery and continuing throughout the first 2 weeks of the post-operative period.

CONTRAINDICATIONS

LOTEMAX, as with other ophthalmic corticosteroids, is contraindicated in most viral diseases of the cornea and conjunctiva including epithelial herpes simplex keratitis (dendritic keratitis), vaccinia, and varicella, and also in mycobacterial infection of the eye and fungal diseases of ocular structures.

WARNINGS AND PRECAUTIONS

Intraocular Pressure (IOP) Increase

Prolonged use of corticosteroids may result in glaucoma with damage to the optic nerve, defects in visual acuity and fields of vision. Steroids should be used with caution in the presence of glaucoma. If this product is used for 10 days or longer, intraocular pressure should be monitored.

Cataracts

Use of corticosteroids may result in posterior subcapsular cataract formation.

Delayed Healing

The use of steroids after cataract surgery may delay healing and increase the incidence of bleb formation. In those diseases causing thinning of the cornea or sclera, perforations have been known to occur with the use of topical steroids. The initial prescription and renewal of the medication order should be made by a physician only after examination of the patient with the aid of magnification such as slit lamp biomicroscopy and, where appropriate, fluorescein staining.

Bacterial Infections

Prolonged use of corticosteroids may suppress the host response and thus increase the hazard of secondary ocular infections. In acute purulent conditions of the eye, steroids may mask infection or enhance existing infection.

Viral Infections

Employment of a corticosteroid medication in the treatment of patients with a history of herpes simplex requires great caution. Use of ocular steroids may prolong the course and may exacerbate the severity of many viral infections of the eye (including herpes simplex).

Fungal Infections

Fungal infections of the cornea are particularly prone to develop coincidentally with long-term local steroid application. Fungus invasion must be considered in any persistent corneal ulceration where a steroid has been used or is in use. Fungal cultures should be taken when appropriate.

Contact Lens Wear

Patients should not wear contact lenses during their course of therapy with LOTEMAX.

ADVERSE REACTIONS

Adverse reactions associated with ophthalmic steroids include elevated intraocular pressure, which may be associated with infrequent optic nerve damage, visual acuity and field defects, posterior subcapsular cataract formation, delayed wound healing and secondary ocular infection from pathogens including herpes simplex, and perforation of the globe where there is thinning of the cornea or sclera.

The most common adverse drug reactions reported were anterior chamber inflammation (5%), eye pain (2%), and foreign body sensation (2%).

USE IN SPECIFIC POPULATIONS

Pregnancy

Teratogenic Effects: Pregnancy Category C.

Loteprednol etabonate has been shown to be embryotoxic (delayed ossification) and teratogenic (increased incidence of meningocele, abnormal left common carotid artery, and limb flexures) when administered orally to rabbits during organogenesis at a dose of 3 mg/kg/day (35 times the maximum daily clinical dose), a dose which caused no maternal toxicity. The no-observed-effect-level (NOEL) for these effects was 0.5 mg/kg/day (6 times the maximum daily clinical dose). Oral treatment of rats during organogenesis resulted in teratogenicity (absent innominate artery at ≥ 5 mg/kg/day doses, and cleft palate and umbilical hernia at ≥ 50 mg/kg/day) and embryotoxicity (increased post-implantation losses at 100 mg/kg/day and decreased fetal body weight and skeletal ossification with ≥ 50 mg/kg/day). Treatment of rats with 0.5 mg/kg/day (6 times the maximum clinical dose) during organogenesis did not result in any reproductive toxicity. Loteprednol etabonate was maternally toxic (significantly reduced body weight gain during treatment) when administered to pregnant rats during organogenesis at doses of ≥ 5 mg/kg/day.

Oral exposure of female rats to 50 mg/kg/day of loteprednol etabonate from the start of the fetal period through the end of lactation, a maternally toxic treatment regimen (significantly decreased body weight gain), gave rise to decreased growth and survival, and retarded development in the offspring during lactation; the NOEL for these effects was 5 mg/kg/day. Loteprednol etabonate had no effect on the duration of gestation or parturition when administered orally to pregnant rats at doses up to 50 mg/kg/day during the fetal period.

There are no adequate and well controlled studies in pregnant women. LOTEMAX should be used during pregnancy only if the potential benefit justifies the potential risk to the fetus.

Nursing Mothers

It is not known whether topical ophthalmic administration of corticosteroids could result in sufficient systemic absorption to produce detectable quantities in human milk. Systemic steroids appear in human milk and could suppress growth, interfere with endogenous corticosteroid production, or cause other untoward effects. Caution should be exercised when LOTEMAX is administered to a nursing woman.

Pediatric Use

Safety and effectiveness in pediatric patients have not been established.

Geriatric Use

No overall differences in safety and effectiveness have been observed between elderly and younger patients.

NONCLINICAL TOXICOLOGY

Carcinogenesis, Mutagenesis, Impairment Of Fertility

Long-term animal studies have not been conducted to evaluate the carcinogenic potential of loteprednol etabonate. Loteprednol etabonate was not genotoxic *in vitro* in the Ames test, the mouse lymphoma tk assay, or in a chromosome aberration test in human lymphocytes, or *in vivo* in the single dose mouse micronucleus assay. Treatment of male and female rats with up to 50 mg/kg/day and 25 mg/kg/day of loteprednol etabonate, respectively, (600 and 300 times the maximum clinical dose, respectively) prior to and during mating did not impair fertility in either gender.

PATIENT COUNSELING INFORMATION

Administration

Invert closed bottle and shake once to fill tip before instilling drops.

Risk of Contamination

Patients should be advised not to allow the dropper tip to touch any surface, as this may contaminate the gel.

Contact Lens Wear

Patients should be advised not to wear contact lenses when using LOTEMAX.

Risk of Secondary Infection

If pain develops, redness, itching or inflammation becomes aggravated, the patient should be advised to consult a physician.

FOR MORE DETAILED INFORMATION, PLEASE READ THE PRESCRIBING INFORMATION.

Bausch & Lomb Incorporated

Tampa, Florida 33637 USA

US Patent No. 5,800,807

©Bausch & Lomb Incorporated

®/™ are trademarks of Bausch & Lomb Incorporated or its affiliates.

CONTRIBUTING EDITORS

PAUL C. AJAMIAN, OD, ATLANTA
AARON BRONNER, OD, KENNEWICK, WASH.
MILE BRUJIC, OD, BOWLING GREEN, OHIO
DEREK N. CUNNINGHAM, OD, AUSTIN, TEXAS
MARK T. DUNBAR, OD, MIAMI
ARTHUR B. EPSTEIN, OD, PHOENIX
JAMES L. FANELLI, OD, WILMINGTON, NC
FRANK FONTANA, OD, ST. LOUIS
GARY S. GERBER, OD, HAWTHORNE, NJ
ANDREW S. GURWOOD, OD, PHILADELPHIA
ALAN G. KABAT, OD, MEMPHIS, TENN.
DAVID KADING, OD, SEATTLE
PAUL M. KARPECKI, OD, LEXINGTON, KY.
JEROME A. LEGERTON, OD, MBA, SAN DIEGO
JASON R. MILLER, OD, MBA, POWELL, OHIO
CHERYL G. MURPHY, OD, HOLBROOK, NY
CARLO J. PELINO, OD, JENKINTOWN, PA.
JOSEPH PIZZIMENTI, OD, FORT LAUDERDALE, FLA.
JOHN RUMPAKIS, OD, MBA, PORTLAND, ORE.
DIANA L. SHECHTMAN, OD, FORT LAUDERDALE, FLA.
JEROME SHERMAN, OD, NEW YORK
JOSEPH P. SHOVLIN, OD, SCRANTON, PA.
JOSEPH W. SOWKA, OD, FORT LAUDERDALE, FLA.
MONTGOMERY VICKERS, OD, ST. ALBANS, W.VA.
WALTER O. WHITLEY, OD, MBA, VIRGINIA BEACH, VA.

EDITORIAL REVIEW BOARD

JEFFREY R. ANSHEL, OD, CARLSBAD, CALIF.
JILL AUTRY, OD, RPH, HOUSTON
SHERRY J. BASS, OD, NEW YORK
EDWARD S. BENNETT, OD, ST. LOUIS
MARC R. BLOOMENSTEIN, OD, SCOTTSDALE, ARIZ.

CHRIS J. CAKANAC, OD, MURRYSVILLE, PA.
JERRY CAVALLERANO, OD, PHD, BOSTON
WALTER L. CHOATE, OD, MADISON, TENN.
BRIAN CHOU, OD, SAN DIEGO
A. PAUL CHOUS, MA, OD, TACOMA, WASH.
ROBERT M. COLE, III, OD, BRIDGETON, NJ
GLENN S. CORBIN, OD, WYOMISSING, PA.
ANTHONY S. DIECIDUE, OD, STROUDSBURG, PA.
S. BARRY EIDEN, OD, DEERFIELD, ILL.
STEVEN FERRUCCI, OD, SEPULVEDA, CALIF.
MURRAY FINGERET, OD, HEWLETT, NY
IAN BEN GADDIE, OD, LOUISVILLE, KY.
MILTON HOM, OD, AZUSA, CALIF.
BLAIR B. LONSBERRY, MS, OD, MED, PORTLAND, ORE.
THOMAS L. LEWIS, OD, PHD, PHILADELPHIA
DOMINICK MAINO, OD, MED, CHICAGO
KELLY A. MALLOY, OD, PHILADELPHIA
RICHARD B. MANGAN, OD, LEXINGTON, KY.
RON MELTON, OD, CHARLOTTE, NC
PAMELA J. MILLER, OD, JD, HIGHLAND, CALIF.
BRUCE MUCHNICK, OD, COATESVILLE, PA.
MARC MYERS, OD, COATESVILLE, PA.
WILLIAM B. POTTER, OD, FREEHOLD, NJ
CHRISTOPHER J. QUINN, OD, ISELIN, NJ
JACK SCHAEFFER, OD, BIRMINGHAM, ALA.
MICHAEL C. RADOIU, OD, STAUNTON, VA.
KIMBERLY K. REED, OD, FORT LAUDERDALE, FLA.
LEO P. SEMES, OD, BIRMINGHAM, ALA.
LEONID SKORIN, JR., OD, DO, ROCHESTER, MINN.
BRAD M. SUTTON, OD, INDIANAPOLIS
LORETTA B. SZCZOTKA, OD, PHD, CLEVELAND
TAMMY P. THAN, MS, OD, BIRMINGHAM, ALA.
RANDALL THOMAS, OD, CONCORD, NC
KATHY C. WILLIAMS, OD, SEATTLE



FASHION
Optical
DISPLAYS
NATIONWIDE

DELIVERING HAND-
CRAFTED QUALITY
WITH UNSURPASSED
VALUE

Fashion Optical Displays will lay out your dispensing and waiting areas at no charge. We will work with you until you are satisfied we have created the best possible design for your dispensary.

To get started, give us a call or go to our website and fill out our No Obligation Quote Form today!

UPCOMING
SHOWS

SECO 2015 - Atlanta, GA
Mar. 5-7 | BOOTH #931

Vision Expo East - New York, NY
Mar. 20-22 | BOOTH #3535

800.824.4106
FASHIONOPTICAL.COM



PRINTED IN USA

FOUNDING EDITOR
FREDERICK BOGER
1891-1913

EDITORIAL OFFICES

11 CAMPUS BLVD., SUITE 100
NEWTOWN SQUARE, PA 19073

EMAIL • REVIEWOFOPTOMETRY@JOBSON.COM

WEBSITE • WWW.REVOPTOM.COM

SUBSCRIPTION INQUIRIES

1-877-529-1746

CONTINUING EDUCATION INQUIRIES

1-800-825-4696

EDITOR-IN-CHIEF • JACK PERSICO
(610) 492-1006 • JPERSICO@JOBSON.COM

EXECUTIVE EDITOR • JOHN MURPHY
(610) 492-1021 • JMURPHY@JOBSON.COM

SENIOR EDITOR • BILL KEKEVIAN
(610) 492-1003 • BKEKEVIAN@JOBSON.COM

ASSOCIATE EDITOR • ALIZA MARTIN
(610) 492-1043 • AMARTIN@JOBSON.COM

DIRECTOR ART/PRODUCTION • JOE MORRIS
(610) 492-1027 • JMORRIS@JOBSON.COM

ART DIRECTOR • JARED ARAUJO
(610) 492-1032 • JARAJO@JOBSON.COM

DIRECTOR OF CE ADMINISTRATION • REGINA COMBS
(212) 274-7160 • RCOMBS@JOBSON.COM

SPECIAL PROJECTS/E-PRODUCTS MANAGER • KAREN ROMAN
(610) 492-1037 • KROMAN@JOBSON.COM

EDITORIAL BOARD

CHIEF CLINICAL EDITOR • PAUL M. KARPECKI, OD
ASSOCIATE CLINICAL EDITORS • JOSEPH P. SHOVLIN, OD;

ALAN G. KABAT, OD; CHRISTINE W. SINDT, OD

DIRECTOR OPTOMETRIC PROGRAMS • ARTHUR EPSTEIN, OD

CLINICAL & EDUCATION CONFERENCE ADVISOR

PAUL M. KARPECKI, OD

CASE REPORTS COORDINATOR • ANDREW S. GURWOOD, OD

CLINICAL CODING EDITOR • JOHN RUMPAKIS, OD, MBA

CONSULTING EDITOR • FRANK FONTANA, OD

COLUMNISTS

CHAIRSIDE • MONTGOMERY VICKERS, OD

CLINICAL QUANDARIES • PAUL C. AJAMIAN, OD

CORNEA & CONTACT LENS Q+A • JOSEPH P. SHOVLIN, OD

DIAGNOSTIC QUIZ • ANDREW S. GURWOOD, OD

GLAUCOMA GRAND ROUNDS • JAMES L. FANELLI, OD

OCULAR SURFACE REVIEW • PAUL M. KARPECKI, OD

URGENT CARE • RICHARD B. MANGAN, OD

RETINA QUIZ • MARK T. DUNBAR, OD

REVIEW OF SYSTEMS • CARLO J. PELINO, OD;

JOSEPH J. PIZZIMENTI, OD

SURGICAL MINUTE • DEREK N. CUNNINGHAM, OD;

WALTER O. WHITLEY, OD, MBA

THERAPEUTIC REVIEW • JOSEPH W. SOWKA, OD;

ALAN G. KABAT, OD

NEURO CLINIC • MICHAEL TROTTINI, OD;

MICHAEL DELGIODICE, OD

FOCUS ON REFRACTION • MARC TAUB, OD;

PAUL HARRIS, OD

JOBSON MEDICAL INFORMATION LLC



Optometry, We've Got You Covered

As your scope of practice expands, so does ours. Look for these new editorial additions. **By Jack Persico, Editor-in-Chief**

Not many 124-year-olds are nimble enough to adapt and improve. As of this issue, *Review of Optometry* is just one year shy of its 125th birthday. And it's still going strong and getting better every month.

To that end, we're adding a few new things and updating some old standbys, to educate you and connect with you even better in 2015. As your trusted advisor and practice companion, *Review* aims to provide answers and guidance for all the clinical challenges you face—from puzzling refraction problems to daunting neuro-ophthalmic cases to surgical comanagement, and everything in between.

Here's a quick rundown of our improvements for 2015:

- **Comanagement Q+A** by Dr. Paul Ajamian is now **Clinical Quandaries** (page 20), with an emphasis that better reflects the primary care role that optometrists now embrace.

- **Coding Abstract** by Dr. John Rumpakis has been retooled as **Coding Connection** (page 65). Dr. Rumpakis will still bring you all the latest coding and billing updates, but with an even greater connection to the clinical presentations you see every day. He'll also present coding sidebars in several key feature articles throughout the year.

- **Ocular Surface Review** (page 79) is a brand new column by Paul Karpecki, OD, that addresses perhaps the #1 cause of clinical office visits in optometry—and one of the toughest to get under control.

- **Neuro Clinic**, another all-new column, will help you take care of those tricky, intimidating neuro cases yourself instead of referring them out. Drs. Michael Trottini and Michael DelGiodice kick it off this month with a terrific feature, "Intro to Neuro" (page 30). Their bimonthly column starts in March.

- **Focus on Refraction** is another new column that will appear every other month, beginning in February. Penned by Drs. Marc Taub and Paul Harris, this column brings you back to optometry's roots—refraction and optics—by challenging you with engaging, real-life cases of patients who just won't refract by the book.

- **Urgent Care**, by Richard Mangan, OD, will give detailed advice on ocular emergencies from chemical burns to penetrating wounds to retinal detachments. It too debuts in February and runs bimonthly.

- **Research Review**—online! This has always delivered the most up-to-date analysis of ocular research and how it affects patient care. Now it will be exclusively online, so you won't have to wait for your monthly issue to keep current on timely news.

- This issue also kicks off a new six-part series, **Essential Procedures at the Slit Lamp** (page 22) that presents step-by-step instructions, photos and video to guide you through the most asked-about new optometric procedures like amniotic membranes and even YAG capsulotomy.

It's all a bit ambitious, sure, but whenever you're asked to do more, *Review* will be there to help. ■

COST OF GOODS SAVINGS CAN ONLY HELP YOU GROW SO MUCH

IN THE NEW ERA OF
POPULATION HEALTH MANAGEMENT,
WHAT'S YOUR PLAN
TO WIN:

- More Patients
- More Profits
- More Time
- All of the Above

Go To **VisionSourcePlan.com** and
We'll Give You Ours



© Vision Source L.P. 2015. All Rights Reserved.

**VISION
SOURCE**
SIGNATURE EYE CARE

This Column Can Rent a Car!

“Chairside” has officially turned 25 years old. Although this column is of legal age to drink and vote, it doesn’t. It’s too busy trying to be funny. **By Montgomery Vickers, OD**

After bragging for several months that 2014 was my 25th year writing “Chairside”—and receiving many, many pats on the back, interspersed with a couple of folks who only read the column to let me know how messed up it is each month—I have now been told that 2015 is, in fact, my 25th year. So, please update your letters of praise for 2015.

Twenty-five years... that’s 300 columns...180,000 words... 4,012 “...”s as I still have no clue how to end my sentences... See what I mean?

I blame optometry. Nobody ever asked me to write about the other important subjects in my life, such as guitars, cowboy boots, cigars and the occasional libation. Of course, that did not matter because I just put those subjects and many more right into “Chairside” in clever ways like this: *“I love cowboy boots and that reminds me of blue jeans and big ol’ buckles and those remind me of retinal detachments.”*

We all know how funny retinal detachments can be, right? See, this stuff writes itself! Besides, the last thing you want to read in an optometry publication is stuff about optometry.

Hearken Back to 1991

“Chairside” started so a normal, private practice optometrist could

express himself in *Review of Optometry*. Unfortunately, all of the normal optometrists were busy that week, so they called me. The good news is I have my two BS degrees, so cranking out a monthly column about nothing in particular is right up my alley.



I have even had moments of—in my humble, nonbiased opinion—genius. Who didn’t love Blind Bat Vickers? That got me the opportunity to perform with Bad

Habits, the Eye Docs of Rock, at the Rock and Roll Hall of Fame!

Of course, I’ve had my share of average to below average columns—although I did win an award for the column I wrote about my dog dying, always a timely optometric subject. It’s interesting to me that the weakest articles get just as much attention as the better ones. Guess that means people haven’t quite given up on me.

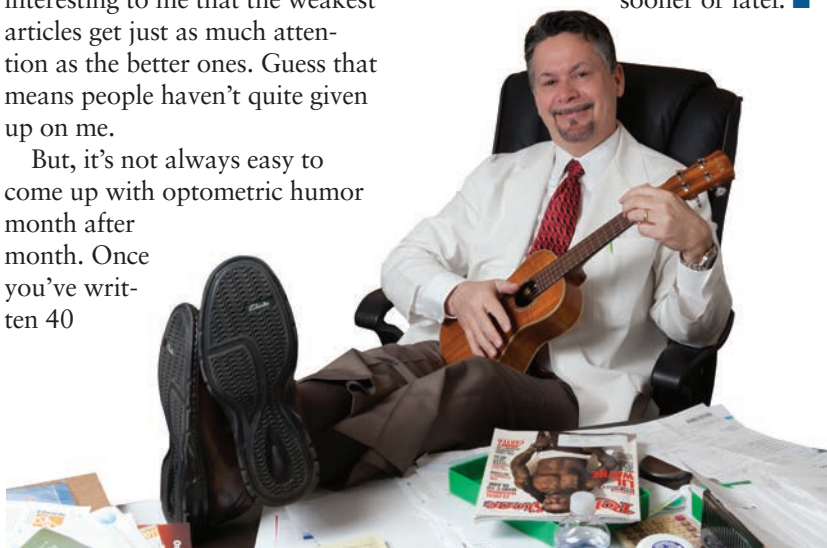But, it’s not always easy to come up with optometric humor month after month. Once you’ve written 40

times about how utterly hilarious phoropters are, where do you go?

In 25 years, I’ve always tried to talk about the challenges that you and I face personally and professionally with some little bit of humor. Many times herein I have mentioned Dr. Keith Shillington, my organic chem professor, who bitterly reminded me that I could “either laugh or cry” when I started a fire in lab. I chose to laugh.

Finally, when my little heart baby granddaughter, Grace, was facing multiple surgeries and dangerous times, my readers—you guys!—poured out prayers and donations and much love. I can never repay that, no matter how many times I write about how messy my desk is, and it surely is. But Grace is doing very well indeed!

Thanks to you, “Chairside” remains a team effort. So, keep reading. I am bound to get it right sooner or later. ■



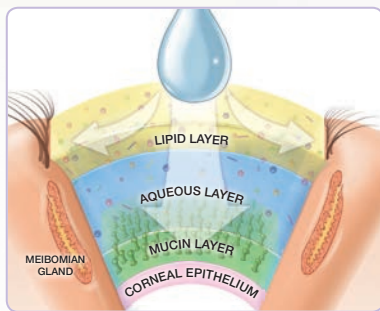
For the 75% of dry eye patients worldwide with evaporative dry eye (MGD) symptoms¹...

DRY EYE CAN BE RELENTLESS

CALM THE STORM WITH LASTING RELIEF

SYSTANE® BALANCE Lubricant Eye Drops:

Protecting the Ocular Surface by Increasing Lipid Layer Thickness (LLT)



SYSTANE® BALANCE Lubricant Eye Drops forms a protective matrix that is designed to replenish the lipid layer for long-lasting relief from the symptoms associated with evaporative dry eye (MGD). This unique formulation is designed to work on all 3 layers of the tear film, specifically increasing LLT. This helps create a protective environment for the ocular surface.²

SYSTANE® Brand products are formulated for the temporary relief of burning and irritation due to dryness of the eye.

References: 1. Akpek EK, Smith RA. Overview of age-related ocular conditions. *Am J Manag Care*. 2013;19 (5 suppl):S67-S75. 2. Korb DR, Blackie CA, Meadows DL, Christensen M, Tudor M. Evaluation of extended tear stability by two emulsion based artificial tears. Poster presented at: 6th International Conference on the Tear Film and Ocular Surface: Basic Science and Clinical Relevance; September 22-25, 2010; Florence, Italy.

Your recommendation counts.

Make sure your patients get the lasting symptom relief they need by offering them SYSTANE® BALANCE Lubricant Eye Drops.²



Alcon
a Novartis company

© 2014 Novartis 05/14 SYS14005JAD-B

Systane
Family of Products

Relief that lasts



This Eye is Choking

Vision loss and ocular pain are clues to prompt you to ask about a history of heart disease. So, what's the diagnosis? **By Paul C. Ajamian, OD**

Q A 60-year-old white male reported decreased vision and pain in his left eye that persisted for about two months. The patient recently had an episode of complete loss of vision, which returned after about 30 seconds. Dilated fundus examination revealed mid-peripheral retinal hemorrhages 360° in the left eye. What do I need to be mindful of regarding this patient?

A “This patient seems to be exhibiting signs and symptoms of ocular ischemic syndrome,” says Trennda Rittenbach, OD. It’s not a common condition, but she sees it often at the Palo Alto Medical Foundation in Sunnyvale, Calif.

The most frequent symptom of ocular ischemic syndrome (OIS) is vision loss in the affected eye, which is present in more than 90% of patients with OIS; about 67% have a gradual vision loss over a few weeks to months, Dr. Rittenbach says.¹ Other common symptoms include episodes of transient vision loss (amaurosis fugax), peripheral vision loss and pain.¹

Signs of OIS are narrowed retinal arteries, beaded and dilated veins with tortuosity, dot-and-blot hemorrhages and microaneurysms located in the mid-peripheral retina (which may extend to the posterior pole as hypoxia increases), cotton-wool spots, anterior ischemic optic neuropathy, rubeosis iridis, iris atrophy and asymmetric cataract.^{1,2}

Differential diagnoses of OIS include diabetic retinopathy (which is often confused for OIS), hypertensive retinopathy and a mild or

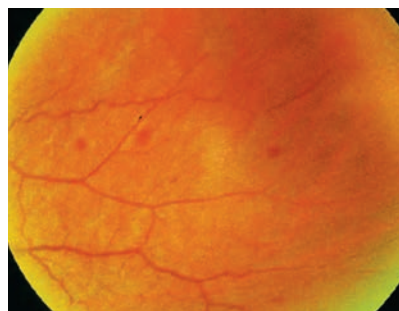


Photo: Joseph J. Pizzimenti, OD

Mid-peripheral retinal hemorrhages are common in ocular ischemic syndrome.

moderate central retinal vein occlusion.

“OIS occurs when stenosis or occlusion of the carotid arteries causes ocular hypoperfusion,” Dr. Rittenbach says.² “The hypoperfusion puts the eye in a hypoxic state, leading to attenuated arteries, venous tortuosity and mid-peripheral hemorrhages.”

Atherosclerosis is usually the main underlying cause for the changes in the carotid arteries, Dr. Rittenbach says, adding that she diagnosed OIS in a patient recently. “I dug deeper into his medical history and found that he already had a carotid endarterectomy on his right side and a history of atherosclerosis,” she says.

She performs auscultation on every patient she suspects has a carotid artery occlusion problem, but acknowledges that the sensitivity and specificity of auscultation of the carotid arteries is not definitive.

“Also during initial examination, be sure to look closely for an important complication secondary to OIS: neovascularization of the

iris, which can lead to neovascularization glaucoma,” she says.

Management of the patient with OIS includes ordering a lipid panel for hypercholesterolemia, as well as a bilateral carotid ultrasound. “It is an absolute must to rule out giant cell arteritis, so I always order a complete blood count with differentials to see if there is evidence of thrombocytosis related to GCA, as well as a sedimentation rate and C-reactive protein,” she says.

“The five-year mortality rate is as high as 40% in patients diagnosed with OIS,” Dr. Rittenbach says.³ “So, these patients must be comanaged with a vascular surgeon, cardiovascular physician or primary care physician.”

For her own recent experience with an OIS patient, Dr. Rittenbach ordered a carotid ultrasound and referred him back to his vascular physician for consideration of carotid endarterectomy, pending the ultrasound results. Also, in her referral letter, she noted that this patient’s blood pressure was 158/86mm Hg, which needs to be addressed.

Remember, as a health care provider, you should check blood pressure on all your patients, day in and day out. ■

1. Terelak-Borys B, Skonieczna K, Grabska-Liberek I. Ocular ischemic syndrome - a systematic review. *Med Sci Monit.* 2012 Aug;18(8):RA138-44.

2. Lyons-Wait VA, Anderson SF, Townsend JC, De Land P. Ocular and systemic findings and their correlation with hemodynamically significant carotid artery stenosis: A retrospective study. *Optom Vis Sci.* 2002 Jun;79(6):353-62.

3. Hazin R, Daoud YJ, Kahn F. Ocular ischemic syndrome: recent trends in medical management. *Curr Opin Ophthalmol.* 2009 Nov;20(6):430-3.

NEW

Lombart CS-5 Package

Quality, Style & Value

Package includes:

- The Lombart CS-5 Chair & Stand 
- Topcon VT-10 Refractor
- Topcon SL-2G Slit Lamp
- Reichert LongLife Chart Projector  with mount, slide & screen
- Upgrade to the Lombart CVS-PC for only \$1500 or to the CVSi21 for only \$2000 more
- Additional upgrades & configurations available.

\$13,595

Or lease for \$265/mo.
for 60 months*

*Lease rate subject to credit approval, 1st payment is due at signing with 59 remaining rental payments of \$265 and a \$1.00 purchase option. Taxes, freight and installation additional. Hand Instruments optional. Subject to change without notice.

1-800-566-2278

Call 1-800-Lombart

Or Your Local Lombart Representative

Corporate Office - 5358 Robin Hood Road, Norfolk, VA 23513-2430
757-853-8888 | FAX 757-855-1232 | 800-566-2278

www.lombartinstrument.com
lombart@lombartinstrument.com

Sales and Service Centers Coast to Coast

ATLANTA • BALTIMORE/WASHINGTON D.C. • BOSTON • BOYNTON BEACH/MIAMI • BRADENTON • CHARLOTTE • CHICAGO • CINCINNATI • DALLAS • DENVER • DETROIT • GREENSBORO • HOUSTON
JACKSON • KANSAS CITY • KNOXVILLE • LOS ANGELES • MILWAUKEE • MINNEAPOLIS • NEW JERSEY/NEW YORK/PENNSYLVANIA • NORFOLK • PORTLAND • SAN ANTONIO • SAN DIEGO • SAN FRANCISCO





Essential Procedures at the Slit Lamp

Foreign Body Removal in 12 Steps

Need to remove a foreign body and rust ring? We'll show you how it's done. Here's the first in a new, six-part, print-and-video instructional series.

By Joseph Shetler, OD, and Nathan Lighthizer, OD

Was it a touchdown, or did his knee drop just before the goal line? The championship game is on and before the review team in the box can make the call, your phone rings. *"Doc, hate to bother you during the big game, but I just can't take it any longer. I was working under my car yesterday, and I thought it would get better, but..."* and the rest is history.

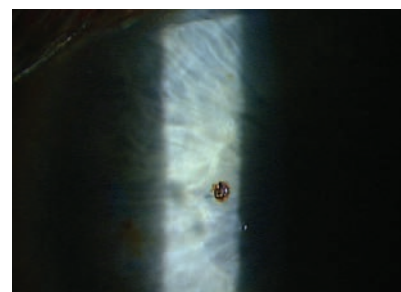
Removing corneal foreign bodies can be one of the most rewarding aspects of the profession. They can interrupt a full day—or the season's championship game. But when handled professionally and efficiently, this procedure not only preserves sight but also generates loyal and referring patients.

This article is the first in a new six-part series that will show you, step-by-step, the essential procedures you can do at the slit lamp. Plus, you'll find a short but thorough video on the *Review* website to walk you through each procedure.

1. Spread the Word

The first step in removing corneal foreign bodies is having patients. Despite optometrists' advances in scope of practice and adopting the medical model, many patients still think of the ER or their primary care provider when their eyes hurt and they suspect they have something in their eyes.

Do you take every opportunity to remind your patients that you and your fellow optometrists remove all kinds of objects from the eye on a daily basis? A simple technique that we've found to be very effective is to hand the patient your card, and



The patient in this case was grinding metal without protective eyewear.

then write your cell phone or after-hours service number on it, and let them know that they will receive specialized care—and save time and money—when they call your office for an eye emergency. A win-win situation.

Another idea: Can a patient visit your website or your Facebook page and watch a video of you removing a corneal foreign body and hear your soothing voice? We made a video. So can you. (See ours on www.reviewofoptometry.com.)



To see a narrated video of foreign body removal, visit www.reviewofoptometry.com, or scan this QR code.

2. Set Up Phone Triage

The second step is to educate your staff so they are prepared to deal with the patient with a presumed foreign body. It starts at the front desk. Train your welcome leader to recognize the signs of a corneal foreign body over the phone and understand the importance of instructing the patient to come directly to the office.

We keep it simple and emphasize the three calling cards of corneal problems: pain, photophobia and lacrimation. (Or, in the patient's words, "It hurts and waters, especially in the sun.")

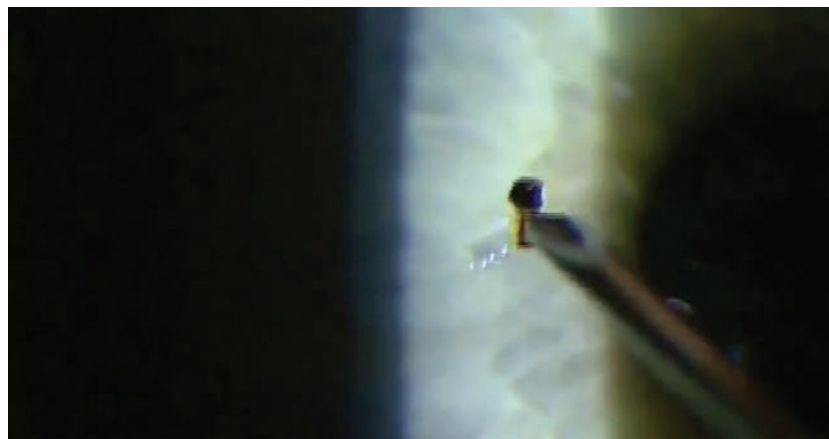
3. Take a Careful History

Before you pick up that spud and spin that Alger brush, first take a thorough history to prepare for the procedure. Like a good investigator, ask the important questions: what, when, where and how? In the vast majority of cases, the story is generally explained very quickly.

- **What?** If the entering substance was associated with vegetative matter or a rusty nail, the answer to this question will influence the type of treatment that may be required postoperatively.

- **When?** This question lends itself to the type of education that you'll need to provide after removal, as well as being aware if the odds of infection, inflammation and rust have dramatically increased with time. Approximately four to six hours is all the time required for the fluid of the cornea to begin to decompose the iron foreign body and rust begins to leach into the surrounding tissue.

- **Where?** Although "where?" does not seem as clinically relevant as "what?" and "when?," it could be one of the most sought-after notations in your record to evaluate worker's compensation issues,



After taking a good history, recording visual acuity and anesthetizing the eye, it's time to choose your weapon. A magnetic spud or 25-gauge needle works well to dislodge and remove most superficial metallic foreign bodies without much damage to the surrounding tissue. Always approach the foreign body tangentially to avoid perforating the cornea.

which insurance company will be liable, and other safety issues.

Be sure to note in the record if the patient had safety eyewear on. This could be important to a company policy or, if a personal incident, it opens the door to educate and sell safety glasses to your patient. A pair of safety glasses can seem like a trivial expense in light of the pain, missed work and monetary cost of removing a corneal foreign body.

- **How?** Asking how the injury happened will assist you in determining the force with which the foreign body entered the cornea and whether or not other scans will become necessary to rule out an intraocular foreign body. It is also important to inquire as to when the patient had their last tetanus shot.

4. Determine Entering Visual Acuities

After the history, be sure that you or your staff have recorded best-corrected vision before you begin the procedure. For clinical as well as medicolegal reasons, it is extremely important to know the patient's

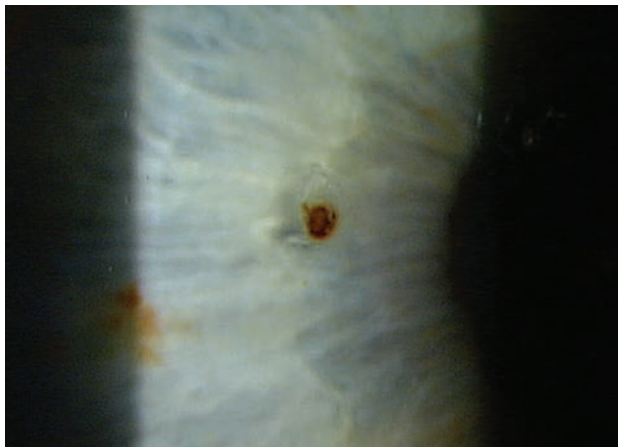
best-corrected vision before you start. Explaining amblyopia or prior scarring on the witness stand is very difficult if your records don't indicate prior decreased vision, and you find yourself defending 20/decreased vision after you have removed the foreign body.

5. Anesthetize the Eye

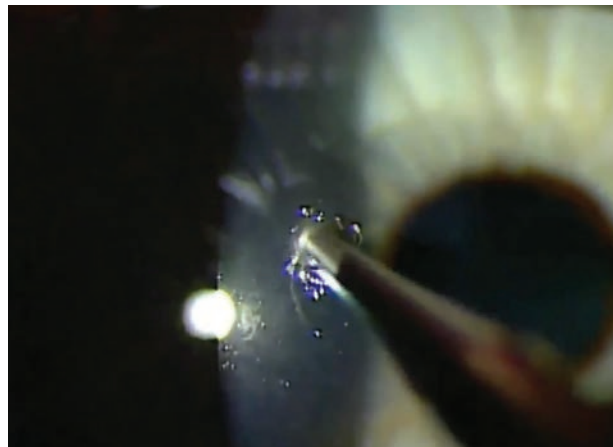
The use of proparacaine prior to the initial evaluation will make your patient more comfortable during the process and enhance the efficiency as well. Instill proparacaine in both eyes to reduce the sensitivity of each eye and assist in preventing reflex movement. If the initial VA was in question due to pain, now's the time to repeat the VA of the involved eye. Proparacaine is typically the anesthetic of choice but other topical anesthetics, such as tetracaine, also provide the necessary anesthetic effect.

6. Choose the Right Instrument

The initial step at the slit lamp is to get the lay of the land. Remember that it is certainly possible to have



After the metal particle is removed, re-examine the area. If the metal has been lodged for a few hours or more, a pocket of rust will likely remain.



Rust never sleeps, so it must be excavated. Here, we used an Alger brush. Be sure to hold the instrument at an angle, not perpendicularly, to avoid penetration.

multiple foreign bodies or one in the fellow eye that the patient may be unaware of. The adage, “If it isn’t written down, it isn’t done” applies as with any medical investigation. So, make certain you document the depth of the foreign body, the type of foreign body, the condition of the fellow eye as well as any additional pertinent information.

Be sure to accurately assess the depth of the foreign body, keeping in mind that objects that have penetrated into the stroma are more likely to result in scarring. Also note the proximity to the visual axis.

After the initial survey and assessment of the foreign body, it’s time to choose your weapon. As you look over your choices, take this moment to communicate with your patient about the procedure and possible complications. If you’re concerned about central scarring and potential vision loss, discuss this with the patient before the procedure. If you anticipate needing the Alger brush, explain the process to the patient and give them the opportunity to hear the sound of the motor and be reassured this will be done under anesthetic.

Pause a moment to give the

patient a chance to ask questions and assess anxiety before proceeding.

The instrument you choose will be determined by the task at hand as well as personal preference. If the identified foreign body is metallic, consider using a magnetic spud. The advantage of the magnetic spud is that you can sometimes lift out a very superficial metallic foreign body with minimal tissue damage. The spud is also readily available to you for additional depth and scraping if you should need it. The other advantage of the magnetic spud is that you’ll be able to catch the flakes of the metallic material with a swipe around the area, and leave the wound field clean of debris with minimal effort.

In many cases, the best instrument is a needle. A 25-gauge 5/8” needle gives adequate strength and is short enough to avoid flexure. Typically, less surrounding tissue damage is caused when using a needle than a spud. The blunt edge of the spud dramatically reduces the risk of perforation, but in the hands of a steady practitioner, the needle is often preferred.

In a minority of cases, jeweler’s

forceps may be the best choice. If the foreign body is of vegetative matter, or simply adhered to the cornea without true penetration, jeweler’s forceps is often the instrument of choice so that no additional tissue is damaged and the material simply lifts off the cornea.

7. Take a Tangential Approach

Always approach the foreign body tangentially to avoid corneal perforation. Giving the patient a target to focus on will slow down eye motion and decrease patient anxiety. Entering at the temporal peripheral edge of the foreign body, with a depth just slightly deeper than the foreign body, generally results in removing the offending agent with minimal collateral damage. A subtle flicking motion usually completes the procedure.

8. Remove the Rust Ring

After removal of a metallic foreign body, re-evaluate the excavation area for the presence of rust. If metal is lodged in the cornea for more than four to six hours, rust will begin to form in the adjacent tissue. This is typically seen as a brownish-orange ring that appears

For allergic conjunctivitis¹

THE POWER TO CALM THE ITCH



**BEPREVE® — FIRST-LINE, YEAR-ROUND,
WITH BROAD-SPECTRUM ALLERGEN COVERAGE**



Scan this QR code or visit beprevecoupon.com to

- Order samples
- Learn about the automatic co-pay program
- Help your patients find participating pharmacies

INDICATION AND USAGE

BEPREVE® (bepotastine besilate ophthalmic solution) 1.5% is a histamine H₁ receptor antagonist indicated for the treatment of itching associated with signs and symptoms of allergic conjunctivitis.

IMPORTANT RISK INFORMATION

BEPREVE® is contraindicated in patients with a history of hypersensitivity reactions to bepotastine or any of the other ingredients. BEPREVE® is for topical ophthalmic use only. To minimize risk of contamination, do not touch the dropper tip to any surface. Keep the bottle closed when not in use. BEPREVE® should not be used to treat contact lens-related irritation. Remove contact lenses prior to instillation of BEPREVE®.

The most common adverse reaction occurring in approximately 25% of patients was a mild taste following instillation. Other adverse reactions occurring in 2%-5% of patients were eye irritation, headache, and nasopharyngitis.

Please see the accompanying prescribing information for BEPREVE® on the following page.

Reference: 1. BEPREVE [package insert]. Tampa, FL: Bausch + Lomb, Inc; 2012.

BAUSCH + LOMB

For product-related questions and concerns, call 1-800-323-0000 or visit www.bepreve.com.

®/TM are trademarks of Bausch & Lomb Incorporated or its affiliates.

©2014 Bausch & Lomb Incorporated. US/BEP/12/0026(1) 1/14

Made by the trusted eye-care
specialists at **BAUSCH + LOMB**

BEPREVE®
(bepotastine besilate
ophthalmic solution) 1.5%

BEPREVE® (bepotastine besilate ophthalmic solution) 1.5%

HIGHLIGHTS OF PRESCRIBING INFORMATION

These highlights do not include all the information needed to use BEPREVE® (bepotastine besilate ophthalmic solution) 1.5% safely and effectively. See full prescribing information for BEPREVE®.

BEPREVE® (bepotastine besilate ophthalmic solution) 1.5%

Initial U.S. Approval: 2009

-----RECENT MAJOR CHANGES-----
Contraindications (4) 06/2012

-----INDICATIONS AND USAGE-----
BEPREVE® is a histamine H1 receptor antagonist indicated for the treatment of itching associated with allergic conjunctivitis. (1)

-----DOSAGE AND ADMINISTRATION-----
Instill one drop into the affected eye(s) twice a day (BID). (2)

-----DOSAGE FORMS AND STRENGTHS-----
Solution containing bepotastine besilate, 1.5%. (3)

-----CONTRAINDICATIONS-----
Hypersensitivity to any component of this product. (4)

FULL PRESCRIBING INFORMATION: CONTENTS*

- 1 INDICATIONS AND USAGE
- 2 DOSAGE AND ADMINISTRATION
- 3 DOSAGE FORMS AND STRENGTHS
- 4 CONTRAINDICATIONS
- 5 WARNINGS AND PRECAUTIONS
 - 5.1 Contamination of Tip and Solution
 - 5.2 Contact Lens Use
 - 5.3 Topical Ophthalmic Use Only
- 6 ADVERSE REACTIONS
 - 6.1 Clinical Trial Experience
 - 6.2 Post-Marketing Experience
- 8 USE IN SPECIFIC POPULATIONS
 - 8.1 Pregnancy
 - 8.3 Nursing Mothers
 - 8.4 Pediatric Use
 - 8.5 Geriatric Use

FULL PRESCRIBING INFORMATION

1 INDICATIONS AND USAGE

BEPREVE® (bepotastine besilate ophthalmic solution) 1.5% is a histamine H₁ receptor antagonist indicated for the treatment of itching associated with signs and symptoms of allergic conjunctivitis.

2 DOSAGE AND ADMINISTRATION

Instill one drop of BEPREVE into the affected eye(s) twice a day (BID).

3 DOSAGE FORMS AND STRENGTHS

Topical ophthalmic solution containing bepotastine besilate 1.5%.

4 CONTRAINDICATIONS

Bepreave is contraindicated in patients with a history of hypersensitivity reactions to bepotastine or any of the other ingredients [see *Adverse Reactions* (6.2)].

5 WARNINGS AND PRECAUTIONS

5.1 Contamination of Tip and Solution

To minimize contaminating the dropper tip and solution, care should be taken not to touch the eyelids or surrounding areas with the dropper tip of the bottle. Keep bottle tightly closed when not in use.

5.2 Contact Lens Use

Patients should be advised not to wear a contact lens if their eye is red. BEPREVE should not be used to treat contact lens-related irritation.

BEPREVE should not be instilled while wearing contact lenses. Remove contact lenses prior to instillation of BEPREVE. The preservative in BEPREVE, benzalkonium chloride, may be absorbed by soft contact lenses. Lenses may be reinserted after 10 minutes following administration of BEPREVE.

5.3 Topical Ophthalmic Use Only

BEPREVE is for topical ophthalmic use only.

6 ADVERSE REACTIONS

6.1 Clinical Trials Experience

Because clinical trials are conducted under widely varying conditions, adverse reaction rates observed in the clinical trials of a drug cannot be directly compared to rates in the clinical trials of another drug and may not reflect the rates observed in clinical practice.

-----WARNINGS AND PRECAUTIONS-----

- To minimize the risk of contamination, do not touch dropper tip to any surface. Keep bottle tightly closed when not in use. (5.1)
- BEPREVE should not be used to treat contact lens-related irritation. (5.2)
- Remove contact lenses prior to instillation of BEPREVE. (5.2)

-----ADVERSE REACTIONS-----

The most common adverse reaction occurring in approximately 25% of patients was a mild taste following instillation. Other adverse reactions which occurred in 2-5% of subjects were eye irritation, headache, and nasopharyngitis. (6)

To report SUSPECTED ADVERSE REACTIONS, contact Bausch & Lomb Incorporated, at 1-800-323-0000, or FDA at 1-800-FDA-1088 or www.fda.gov/medwatch. See 17 for PATIENT COUNSELING INFORMATION

Revised: 10/2012

11 DESCRIPTION

12 CLINICAL PHARMACOLOGY

- 12.1 Mechanism of Action
- 12.3 Pharmacokinetics

13 NONCLINICAL TOXICOLOGY

- 13.1 Carcinogenesis, Mutagenesis and Impairment of Fertility

14 CLINICAL STUDIES

16 HOW SUPPLIED/STORAGE AND HANDLING

17 PATIENT COUNSELING INFORMATION

- 17.1 Topical Ophthalmic Use Only
- 17.2 Sterility of Dropper Tip
- 17.3 Concomitant Use of Contact Lenses

*Sections or subsections omitted from the full prescribing information are not listed

The most common reported adverse reaction occurring in approximately 25% of subjects was a mild taste following instillation. Other adverse reactions occurring in 2-5% of subjects were eye irritation, headache, and nasopharyngitis.

6.2 Post Marketing Experience

Hypersensitivity reactions have been reported rarely during the post-marketing use of BEPREVE. Because these reactions are reported voluntarily from a population of unknown size, it is not always possible to reliably estimate their frequency or establish a causal relationship to drug exposure. The hypersensitivity reactions include itching, body rash, and swelling of lips, tongue and/or throat.

8 USE IN SPECIFIC POPULATIONS

8.1 Pregnancy

Pregnancy Category C: Teratogenicity studies have been performed in animals. Bepotastine besilate was not found to be teratogenic in rats during organogenesis and fetal development at oral doses up to 200 mg/kg/day (representing a systemic concentration approximately 3,300 times that anticipated for topical ocular use in humans), but did show some potential for causing skeletal abnormalities at 1,000 mg/kg/day. There were no teratogenic effects seen in rabbits at oral doses up to 500 mg/kg/day given during organogenesis and fetal development (>13,000 times the dose in humans on a mg/kg basis). Evidence of infertility was seen in rats given oral bepotastine besilate 1,000 mg/kg/day; however, no evidence of infertility was observed in rats given 200 mg/kg/day (approximately 3,300 times the topical ocular use in humans). The concentration of radio-labeled bepotastine besilate was similar in fetal liver and maternal blood plasma following a single 3 mg/kg oral dose. The concentration in other fetal tissues was one-third to one-tenth the concentration in maternal blood plasma.

An increase in stillborns and decreased growth and development were observed in pups born from rats given oral doses of 1,000 mg/kg/day during perinatal and lactation periods. There were no observed effects in rats treated with 100 mg/kg/day.

There are no adequate and well-controlled studies of bepotastine besilate in pregnant

women. Because animal reproduction studies are not always predictive of human response, BEPREVE® (bepotastine besilate ophthalmic solution) 1.5% should be used during pregnancy only if the potential benefit justifies the potential risk to the fetus.

8.3 Nursing Mothers

Following a single 3 mg/kg oral dose of radiolabeled bepotastine besilate to nursing rats 11 days after delivery, the maximum concentration of radioactivity in milk was 0.40 mcg-eg/mL 1 hour after administration; at 48 hours after administration the concentration was below detection limits. The milk concentration was higher than the maternal blood plasma concentration at each time of measurement.

It is not known if bepotastine besilate is excreted in human milk. Caution should be exercised when BEPREVE (bepotastine besilate ophthalmic solution) 1.5% is administered to a nursing woman.

8.4 Pediatric Use

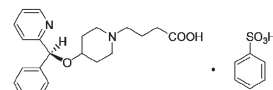
Safety and efficacy of BEPREVE (bepotastine besilate ophthalmic solution) 1.5% have not been established in pediatric patients under 2 years of age. Efficacy in pediatric patients under 10 years of age was extrapolated from clinical trials conducted in pediatric patients greater than 10 years of age and from adults.

8.5 Geriatric Use

No overall difference in safety or effectiveness has been observed between elderly and younger patients.

11 DESCRIPTION

BEPREVE (bepotastine besilate ophthalmic solution) 1.5% is a sterile, topically administered drug for ophthalmic use. Each mL of BEPREVE contains 15 mg bepotastine besilate. Bepotastine besilate is designated chemically as (+) -4-[(S)-p-chloro-alpha -2-pyridylbenzyl]oxy]-1-piperidine butyric acid monobenzenesulfonate. The chemical structure for bepotastine besilate is:



Bepotastine besilate is a white or pale yellowish crystalline powder. The molecular weight of bepotastine besilate is 547.06 daltons. BEPREVE® ophthalmic solution is supplied as a sterile, aqueous 1.5% solution, with a pH of 6.8. The osmolality of BEPREVE (bepotastine besilate ophthalmic solution) 1.5% is approximately 290 mOsm/kg.

Each mL of BEPREVE® (bepotastine besilate ophthalmic solution) 1.5% contains:

Active: Bepotastine besilate 15 mg (equivalent to 10.7 mg bepotastine)

Preservative: benzalkonium chloride 0.005%

Inactives: monobasic sodium phosphate dihydrate, sodium chloride, sodium hydroxide to adjust pH, and water for injection, USP.

12 CLINICAL PHARMACOLOGY

12.1 Mechanism of Action

Bepotastine is a topically active, direct H₁-receptor antagonist and an inhibitor of the release of histamine from mast cells.

12.3 Pharmacokinetics

Absorption: The extent of systemic exposure to bepotastine following topical ophthalmic administration of bepotastine besilate 1% and 1.5% ophthalmic solutions was evaluated in 12 healthy adults. Following one drop of 1% or 1.5% bepotastine besilate ophthalmic solution to both eyes four times daily (QID) for seven days, bepotastine plasma concentrations peaked at approximately one to two hours post-instillation. Maximum plasma concentration for the 1% and 1.5% strengths were 5.1 ± 2.5 ng/mL and 7.3 ± 1.9 ng/mL, respectively. Plasma concentration at 24 hours post-instillation were below the quantifiable limit (2 ng/mL) in 11/12 subjects in the two dose groups.

Distribution: The extent of protein binding of bepotastine is approximately 55% and independent of bepotastine concentration.

Metabolism: *In vitro* metabolism studies with human liver microsomes demonstrated that bepotastine is minimally metabolized by CYP450 isozymes.

In vitro studies demonstrated that bepotastine besilate does not inhibit the metabolism of various

cytochrome P450 substrate via inhibition of CYP3A4, CYP2C9, and CYP2C19. The effect of bepotastine besilate on the metabolism of substrates of CYP1A2, CYP2C8, CYP2D6 was not studied. Bepotastine besilate has a low potential for drug interaction via inhibition of CYP3A4, CYP2C9, and CYP2C19.

Excretion: The main route of elimination of bepotastine besilate is urinary excretion (with approximately 75-90% excreted unchanged in urine).

13 NONCLINICAL TOXICOLOGY

13.1 Carcinogenesis, Mutagenesis and Impairment of Fertility

Long-term dietary studies in mice and rats were conducted to evaluate the carcinogenic potential of bepotastine besilate. Bepotastine besilate did not significantly induce neoplasms in mice receiving a nominal dose of up to 200 mg/kg/day for 21 months or rats receiving a nominal dose of up to 97 mg/kg/day for 24 months. These dose levels represent systemic exposures approximating 350 and 200 times that achieved with human topical ocular use. The no observable adverse effect levels for bepotastine besilate based on nominal dose levels in carcinogenicity tests were 18.7 to 19.9 mg/kg/day in mice and 9.6 to 9.8 mg/kg/day in rats (representing exposure margins of approximately 60 and 20 times the systemic exposure anticipated for topical ocular use in humans).

There was no evidence of genotoxicity in the Ames test, in CHO cells (chromosome aberrations), in mouse hepatocytes (unscheduled DNA synthesis), or in the mouse micronucleus test.

When oral bepotastine was administered to male and female rats at doses up to 1,000 mg/kg/day, there was a slight reduction in fertility index and surviving fetuses. Infertility was not seen in rats given 200 mg/kg/day oral bepotastine besilate (approximately 3,300 times the systemic concentration anticipated for topical ocular use in humans).

14 CLINICAL STUDIES

Clinical efficacy was evaluated in 2 conjunctival allergen challenge (CAC) studies (237 patients). BEPREVE (bepotastine besilate ophthalmic solution) 1.5% was more effective than its vehicle for relieving ocular itching induced by an ocular allergen challenge, both at a CAC 15 minutes post-dosing and a CAC 8 hours post dosing of BEPREVE.

The safety of BEPREVE was evaluated in a randomized clinical study of 861 subjects over a period of 6 weeks.

16 HOW SUPPLIED/STORAGE AND HANDLING

BEPREVE® (bepotastine besilate ophthalmic solution) 1.5% is supplied in a white low density polyethylene plastic squeeze bottle with a white controlled dropper tip and a white polypropylene cap in the following size:

- 5 mL (NDC 24208-629-02)
- 10 mL (NDC 24208-629-01)

STORAGE

Store at 15° – 25°C (59° – 77°F).

17 PATIENT COUNSELING INFORMATION

17.1 Topical Ophthalmic Use Only

For topical ophthalmic administration only.

17.2 Sterility of Dropper Tip

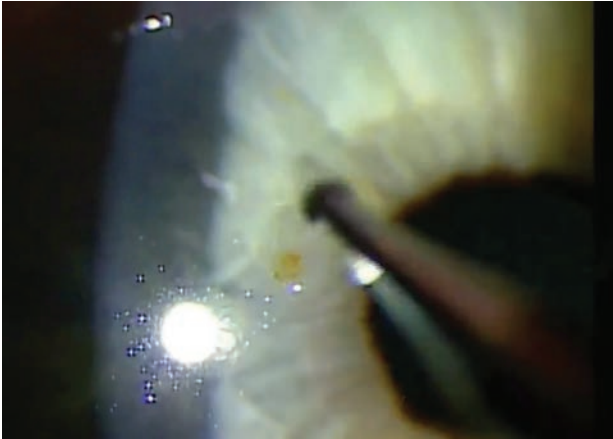
Patients should be advised to not touch dropper tip to any surface, as this may contaminate the contents.

17.3 Concomitant Use of Contact Lenses

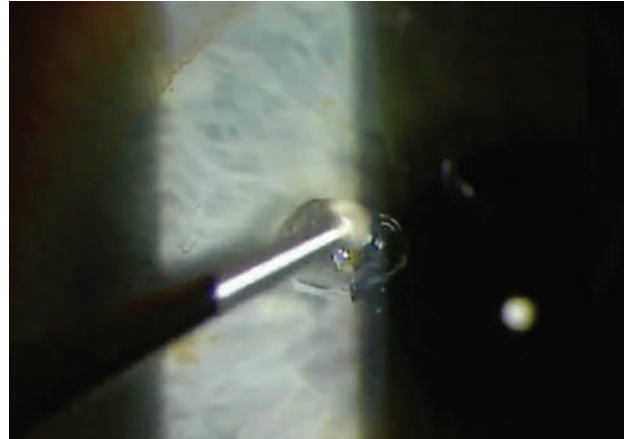
Patients should be advised not to wear a contact lens if their eye is red. Patients should be advised that BEPREVE should not be used to treat contact lens-related irritation.

Patients should also be advised to remove contact lenses prior to instillation of BEPREVE. The preservative in BEPREVE, benzalkonium chloride, may be absorbed by soft contact lenses. Lenses may be reinserted after 10 minutes following administration of BEPREVE.

Manufactured by: Bausch & Lomb Incorporated
Tampa, FL 33637
Under license from:
Senju Pharmaceutical Co., Ltd.
Osaka, Japan 541-0046
®/TM are trademarks of Bausch & Lomb Incorporated or its affiliates
© 2012 Bausch & Lomb Incorporated.



Don't be afraid to apply pressure to get the rust out. And take a few passes at it. In between, give the patient the opportunity to blink. Even so, a trace of rust may remain, as seen here.



To get out the last of that deep, stubborn rust, try holding the Alger brush in your other hand. This automatically reverses the direction of burr's rotation within the wound to scour it well.

to feather into the surrounding tissue. A dense brown patch is also typically noted in the bottom of the excavated area. Although the rust ring can occasionally be lifted in its entirety with a jeweler's forceps, an Alger brush will be required in the vast majority of cases to free the area of rust. Be sure to use a clean, sterilized tip for each case.

The Alger brush should be brought toward the area tangentially. Although the stroma is difficult to penetrate with an Alger brush, it's still prudent to work tangentially and not perpendicularly. It's also easier to control the Alger brush depth from this angle.

In some cases, slight pressure is required to adequately remove the rust. Although the rust may loosen with time and rise closer to the surface, try to remove as much rust as possible at the initial visit to prevent re-entry into the area, which will disturb epithelial healing. A slight amount of rust left in the center of the excavated pit will dissipate with time, and based on the clinician's judgment, it's often less traumatic to leave a slight amount of rust as opposed to excessive tissue disruption. Keep in

mind that remaining rust will create inflammation and retard healing, so do your best to leave the wound as clean and rust free as possible.

If confidently ambidextrous, hold the burr in your opposite hand to allow the spinning motion of the blade to approach the wound in the opposite direction and loosen stubborn areas of rust.

After successfully burring the rust away, pass the magnet around the area to remove any filings. Rinse the eye with saline to clean the field as well.

9. Do a Double Check

After successful removal, be certain to re-evaluate the area. Evaluate with white light, and also look for any foreign matter that might have fallen into the lower palpebral conjunctiva. Do a finalized inspection with sodium fluorescein and cobalt blue filter to review and document the extent of the evacuation and to be certain no foreign matter or additional foreign bodies exist.

10. Rx Appropriately

Postoperatively, place the patient on a broad-spectrum antibiotic for one week. (Keep in mind that dia-

betic patients typically re-epithelize at a slower rate.) Pain management depends on the extent of tissue damage and the depth of the foreign body, as well as the level of inflammation and infection.

A bandage contact lens can also reduce discomfort. It creates an artificial surface that provides protection from continual tearing of the epithelium, promotes healing and decreases the risk of corneal erosion. But use the bandage contact lens with caution. If placed on the eye of a patient without contact lens experience, it might inadvertently be dislodged or taco-rolled, leading to another phone call from the patient concerned about the discomfort produced. Also, a bandage contact lens may contribute to a more infective climate, so monitor the patient closely. Be sure to remove the contact lens in 24 hours to check the cornea for edema and striae as well.

Standard of care dictates that corneal foreign body cases be seen in 24 hours, but that certainly varies depending on the severity and the depth of the foreign body.

Pressure patching is another method of controlling pain, but

THE TIME AND MONEY THAT YOU COMMIT TO YOUR EDUCATION IS A CRITICAL INVESTMENT IN YOUR OPTOMETRIC CAREER.

MAKE IT COUNT AT SECO 2015 WHERE SIGHT MEETS VISION

HERE ARE
6
REASONS TO ATTEND:



Because optometry is **changing**.



Because you will uncover **solutions** to all your practice challenges in **Optometry's Marketplace at SECO™**.



Because our **cutting-edge** courses for ODs and AOPs will keep you ahead of the curve and focused on success.



Because we have a **registration option** to fit your needs.



Because nearly **7,000** of your colleagues will be there and you don't want to miss out.



Because **Atlanta** is a world-class city filled with things to do.



The SECO Champion Program is an elite partnership between leaders of the ophthalmic industry and SECO International. Their goal is to provide optometric professionals with the tools to achieve the highest levels of clinical knowledge and performance.

PREMIER PARTNERS

Alcon
a Novartis company

ACUVUE
BRAND CONTACT LENSES
INNOVATION FOR HEALTHY VISION™

vsp
Global

ALLERGAN

HOYA

PARTNERS

BAUSCH+LOMB

Abbott
Medical Optics



SECO2015

Atlanta, GA | March 4-8
WHERE SIGHT MEETS VISION™

Two Registration Options



All-Inclusive Package includes everything at SECO - CE courses, exhibit hall, social events and access to SECO University.

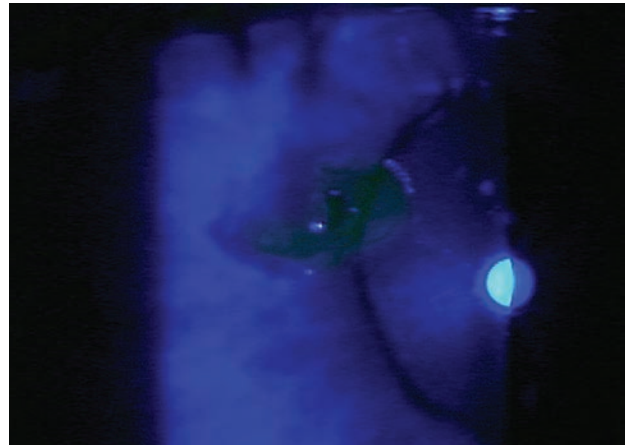
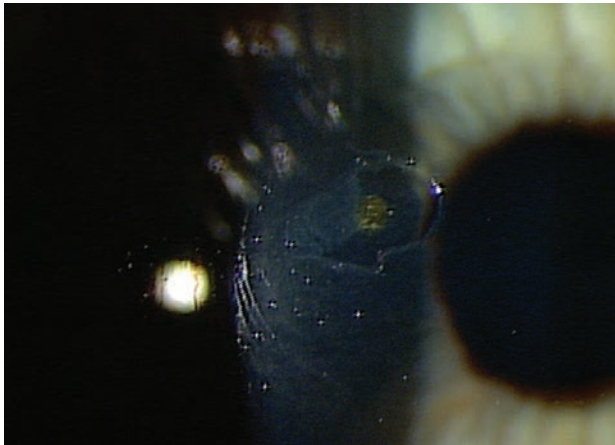


A la Carte Package includes access to the exhibit hall and social events, but lets you choose and pay only for the CE courses you want.

Register by Jan 7 and Save

Find out more at SECO2015.com





After successful removal of the foreign body and residual rust, do a final inspection with white light. Rinse the eye with saline and use a magnet or swab to remove any metal filings or debris, particularly in the lower palpebral conjunctiva. Lastly, stain the eye, then measure and document the lesion. Schedule the patient for a one-day follow up, and prescribe a broad-spectrum antibiotic.

finds less favor with patients who are still leading an active lifestyle, and is often unnecessary.

In the case of non-central superficial foreign bodies, a topical antibiotic is typically all that's required. If excessive inflammation has already occurred or the amount of burring required was extensive, the use of homatropine BID for three days, in conjunction with the topical antibiotic, often provides adequate pain management and decreases the risk of iritis.

Topical non-steroidal anti-inflammatory agents can also assist in pain management without jeopardizing epithelial healing. Steroids, even in the presence of iritis or ensuing iritis, are relatively contraindicated until re-epithelialization has been noted.

In the case of central foreign bodies, its depth determines the level of medication. Superficial corneal foreign bodies—regardless of their location—will not scar. But if the foreign body is centrally located and has penetrated into the stromal layer, scarring will result. So, consider steroids to help reduce the scarring and risk for potential vision loss. The dosage and dura-

tion of the steroid varies depending on the depth of the foreign body, the amount of inflammation and the risk of scarring, but the most common dosage is QID for seven to 10 days, followed by a short taper. Be aggressive and use a strong steroid, such as prednisolone acetate, difluprednate or loteprednol 0.5%.

An amniotic membrane, such as the Prokera Slim device (Bio-Tissue), may also be appropriate for those central, deep foreign bodies where the risk of scarring is great.

11. Revisit on Day One

Significant healing should be noted within 24 hours. The most common concerns at postoperative visits are infection, iritis and recurrent corneal erosion.

12. Bill Properly

No job is complete until the paperwork is done. The code commonly used is 65222 (Corneal foreign body removal with slit lamp). Be certain to use modifiers to indicate if more than one foreign body was removed. This code does not have a global post-op period, so it is appropriate to bill an E/M code for follow-up visits.

Corneal foreign bodies can represent a scary, vision-threatening situation to the patient. With the proper patient education, foreign body removal technique and treatment, you will have the metal and rust out of the cornea efficiently and effectively. Your patient will leave feeling significantly better and you will have gained a patient to your practice.

Assuming the phone call came at half time, you can be back for the exciting second half and you'll enjoy it knowing you've done an outstanding service for your patient, and your patient will enjoy the second half reassured they are in good hands and made the right call. ■

Dr. Shetler is an assistant professor and chief of the university clinic facilities at the Oklahoma College of Optometry.

Dr. Lighthizer is the assistant dean for clinical care services, director of continuing education, and chief of both the specialty care clinic and the electrodiagnostics clinic at the Oklahoma College of Optometry.

Next month: Amniotic Membrane Application

An Intro to Neuro

Neuro-ophthalmic disorders can be intimidating—but you can diagnose and manage many of them. Here's a simple guide for these serious presentations.

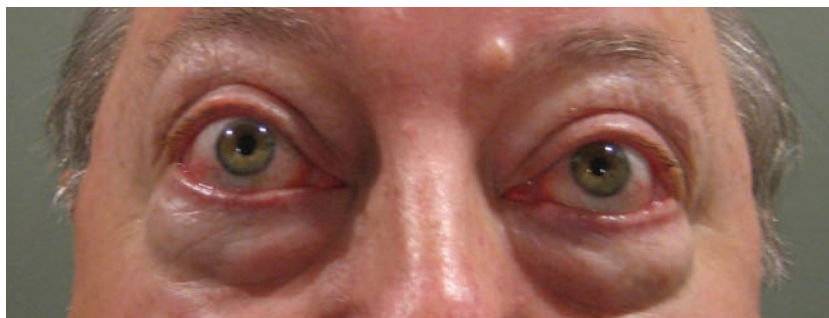By Michael Trottini, OD, and Michael DelGiodice, OD

Many optometrists avoid diagnosing and managing patients with neuro-ophthalmic disorders. We may perceive these cases to be very complex, time-consuming and possibly vision- or life-threatening.

While challenging, these conditions can be successfully managed by optometrists and comanaged with other specialties.

This article reviews each element of the exam, along with the appropriate ancillary testing required for proper diagnosis. Our goals are to give a good clinical approach for diagnosis and management, to help you decide which cases require non-urgent, urgent or emergent attention, and to encourage you to comanage certain disorders with neurology, neuro-surgery and any other appropriate specialty.

(Starting in the March 2015 issue, we'll also be presenting neuro-ophthalmic case reports and discussions every other month.)



This patient with thyroid orbitopathy has moderate proptosis and periorbital edema. He also has significantly reduced extraocular motility.

History

By taking a detailed history, the practitioner can start making a list of differential diagnoses, and then direct the exam toward narrowing that list to find the etiology. This approach helps to keep clinical testing specific to the problem, instead of performing unnecessary tests.

Here are some of the more common neurologic complaints optometrists encounter:

- **Diplopia.** Your first question about double vision should be

whether it's monocular or binocular.

Monocular diplopia may be a result of uncorrected refractive error, keratoconus, cataract or maculopathy. Polyopia, which can occur following cerebral damage, is a perception of two or multiple images that can be seen monocularly.¹ However, this is a very rare complaint and patients will usually have a prior neurologic cause such as stroke or traumatic brain injury.

In patients with true binocular diplopia, horizontal diplopia is

frequently a result of a sixth nerve palsy or internuclear ophthalmoplegia (INO), while vertical diplopia is usually from a fourth or third nerve palsy. The diplopia is more prominent when the patient looks toward the affected muscle. For example, a patient with a left sixth nerve palsy will complain of horizontal diplopia that worsens upon left gaze.

Decompensating phorias can be either horizontal or vertical, but are usually intermittent rather than constant, as seen with nerve palsies and INO. Diplopia from thyroid orbitopathy can also be horizontal or vertical, but is typically present with other signs and symptoms, such as pain, pressure, proptosis, periorbital edema and chemosis/injection. Myasthenia gravis (MG) should always be a differential diagnosis, especially if the diplopia is variable, not consistent with any of the nerve palsies or if there are other symptoms such as lid ptosis, fatigue, dysphagia or dyspnea.

• **Vision loss/disturbances.** Noting whether the vision loss is monocular or binocular, along with its frequency, can be very helpful in narrowing down potential causes. Transient monocular vision loss, or amaurosis fugax, may be a precursor to both ocular and systemic pathology. A retinal embolus or artery occlusion, carotid artery insufficiency, non-arteritic ischemic optic neuropathy (NAION), arteritic ischemic optic neuropathy (AION) or vein occlusion may present with warning signs of fleeting vision loss. Alternatively, individuals who experience sudden binocular vision loss are more likely to have intracranial pathology.

Documenting the frequency of vision loss is also helpful in determining the cause. Loss of vision lasting a few seconds can point to papilledema or an impending

AION.² Retinal emboli and transient ischemic attacks (TIAs) typically cause vision loss for seconds to minutes, while visual phenomena from non-neurologic type migraine may last for hours, but typically less than 24 hours.

• **Headaches.** Headaches are a very common complaint and often not a result of serious pathology. However, certain symptoms or characteristics may imply vision- or life-threatening causes. Headaches that are newly noted, have different severity, frequency or duration—as well as those noted upon waking, those that wake the patient during the night or those that are unresponsive to pain medication or accompany other neurologic symptoms—should all be explored.³

A sudden-onset, severe headache—typically reported as “the worst headache of my life”—can be due to an intracranial hemorrhage or carotid artery dissection, and should be evaluated emergently.³ Neck pain and swelling or a Horner’s syndrome may be noted on the same side of the headache in carotid artery dissection patients.

Be sure to rule out giant cell arteritis (GCA) in individuals older than 55 years who experience headache accompanied by symptoms such as jaw claudication, scalp tenderness, fatigue, weight loss and generalized weakness.

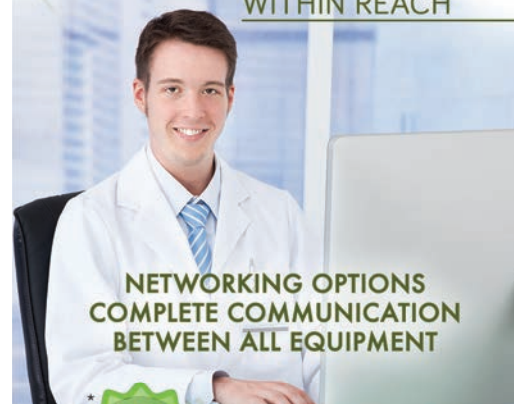Headaches that are worse in the morning, exacerbated by changes in posture and accompanied with transient visual obscurations, nausea, vomiting and tinnitus are typical for increased intracranial pressure.

Painful, monocular vision loss is characteristic of optic neuritis. The pain is usually worse with eye movement. Multiple neurological symptoms—such as paresthesias, ataxia, diplopia, fatigue, Uhthoff’s

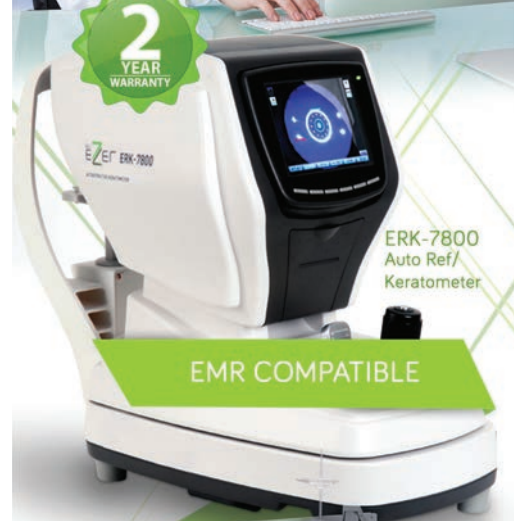

EZER WAY OF LIFE

QUALITY OF LIFE
WITHIN REACH

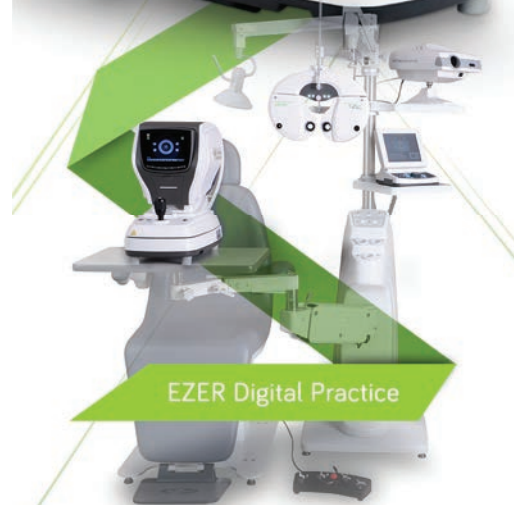

NETWORKING OPTIONS
COMPLETE COMMUNICATION
BETWEEN ALL EQUIPMENT



ERK-7800
Auto Ref/
Keratometer

EMR COMPATIBLE

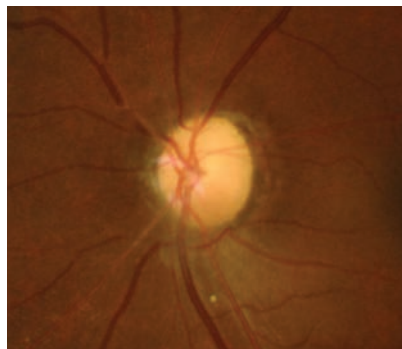
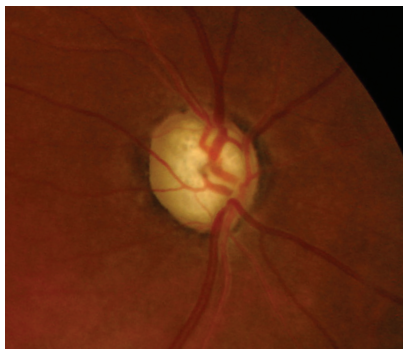

EZER Digital Practice

*2 Year warranty available on the
ERK-7800, EDR-7800 and ECP-5400 only.



www.usophthalmic.com
info@usophthalmic.com
Toll Free 1.888.334.4640



Compare glaucomatous optic nerve pallor from total cupping (left) to non-glaucomatous pallor from optic atrophy due to an old ischemic optic neuropathy (right).

phenomenon and Lhermitte's sign—may be present in patients with optic neuritis associated with multiple sclerosis.

External Exam

- **Gross observation.** Facial and lid abnormalities can be indicators of neurologic eye disease. These include signs of ptosis, proptosis, resistance to retropulsion, lagophthalmos, facial weakness, head turn or tilt, and blepharospasm.

It can be helpful to observe the patient in the waiting room (i.e., if they are turning or tilting their head, favoring one eye, showing difficulty with reading or watching television). This is especially beneficial with children who may not be able to give accurate histories or patients who are malingering.

- **Extraocular motility.** Perform extraocular motilities to look for any restricted gaze or pursuit deficits. Saccades can also be tested to help localize an issue. For example, slow saccades can be noted with a neurogenic process vs. a restrictive process, which will have normal saccades.⁴ Finally, the eyes should also be examined for nystagmus.

- **Confrontation field testing.** While automated perimetry is the standard of care, don't skip confrontation testing, which can quickly screen for certain key field

defects. For instance, we've examined asymptomatic patients with no other exam findings except for confrontation field defects, which led to diagnoses of pituitary adenomas and prior cerebrovascular accidents (CVA). Although confrontation field testing has a fairly low sensitivity for arcuate defects and bitemporal hemianopsia, it has a high sensitivity for detection of altitudinal defects and homonymous hemianopsia.^{5,6}

- **Pupillary testing.** This is a great objective measurement for identifying neuro-ophthalmic conditions. Pupil size should be measured in both dark and bright illumination to help differentiate a sympathetic vs. parasympathetic issue. For example, Horner's syndrome, which is an oculosympathetic palsy, will have anisocoria greater in dim illumination, while a third nerve palsy will have anisocoria greater in bright illumination. Afferent pupillary defects will be present with optic nerve and retinal disorders such as NAION, AION, optic neuritis and artery occlusions. In patients with an Adie's tonic pupil, the pupil generally has an irregular shape and a slow constriction, often with sectoral paralysis. It will constrict with pilocarpine 0.125%, however.

- **Cover test.** This test is critical

in evaluating patients with diplopia. If there is a small deviation, testing extraocular motilities is not sufficient for diagnosing a fourth or sixth nerve palsy. The cover test needs to be measured in all views of gaze in order to localize most deviations. We find the easiest method to measure the deviation is to use a prism bar during cover test while the patient is fixating at a distant target.

Anterior Segment Exam

While the majority of neuro-ophthalmic findings are localized to the posterior segment of the eye, a number of pertinent findings can manifest within the anterior structures. For instance, unilateral corkscrew vessels of the conjunctiva can be an indication of intracranial dural arteriovenous malformation (AVM) or carotid cavernous fistula (CCF). The phakomatoses—a group of congenital disorders characterized by systemic hamartosis—can manifest as hyperpigmented lesions of the iris, known as Lisch nodules.⁷ In addition, anterior chamber cell and flare in an elderly patient may be an indication of ocular ischemia secondary to carotid occlusive disease.

Funduscopy

Posterior segment findings are best observed with a combination of viewing modalities including direct, indirect and non-contact high-resolution imaging.

In the setting of optic nerve pathology, the optic nerve has only two responses to injury: atrophy or edema, whereby the former is the end result of any pathologic process. Some of the more common causes of pathology include compression, ischemia, inflammation, infiltration and metabolic or toxic disturbances. Sometimes, congenital

anomalies of the optic nerve may simulate pathologic processes.

The color of the optic disc depends on light reflecting off the surface vessels and nerve fiber layer (NFL). In cases of pseudophakia and high myopia, a healthy disc may appear pale. However, in cases of true optic neuropathy, the clinical examination may yield isolated or combined pathological processes such as NFL dropout, loss of peripapillary capillaries, visual acuity and field defects, as well as an afferent pupillary defect.^{8,9}

Individuals with swelling of the optic nerve often present as a diagnostic challenge. Most cases can be categorized based on timing of the event, visual acuity, laterality, associated systemic symptoms, and appearance of the optic nerve and retinal vasculature. Older individuals who present with painless vision loss, optic nerve edema and systemic vascular disease are at risk for NAION. Accordingly, the optic nerve may show sectoral edema with dilated capillaries and an altitudinal visual field defect. Nonetheless, immediate complete blood count (CBC) with platelets, erythrocyte sedimentation rate (ESR) and C-reactive protein (CRP) must be ordered to discount arteritic disease even when constitutional symptoms of temporal arteritis are absent. While the two may be indistinguishable from a clinical appearance, some have described pallid swelling of the disc and worse visual acuity when discussing AION.⁹

Younger individuals who present with insidious vision loss in one eye and pain on eye movement with either normal or hyperemic swelling of the disc may be suffering from an optic neuritis event or a space-occupying intraorbital process that occurs with transient vision loss in peripheral gaze positions. Sub-

sequent testing of the visual field, color vision, afferent system and NFL will allow for quantifying the pathology. In cases of bilateral disc edema, it is critical to assess the appearance of the optic nerve with respect to its rim tissue, NFL, vasculature and presence or absence of venous pulsation. Bilateral opacification of the nerve fiber layer, splinter hemorrhages at or adjacent to the disc, and lack of spontaneous venous pulsation are highly suggestive of increased intracranial pressure, which warrants emergent neuroimaging to discount an intracranial hemorrhage or mass. In the event the imaging is unremarkable, then lumbar puncture can be scheduled to measure the opening pressure and evaluate for idiopathic intracranial hypertension.

Lastly, a small physiologic cup with normal coloring, anomalous vasculature branching (i.e., trifurcations), disc drusen, absence of a high watermark sign and no frank opacification of the NFL is more likely to represent pseudopapilledema.

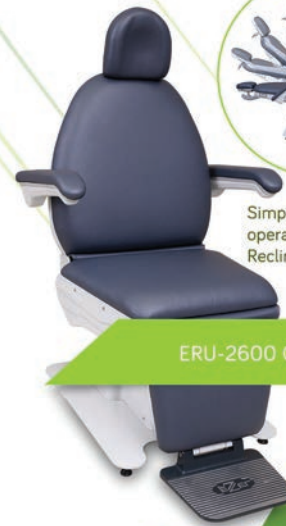However, in most cases, determining true edema from congenital disc anomalies cannot be made by clinical exam alone. Ancillary testing of the visual field, B-scan ultrasound, optic coherence tomography (OCT) and serial photography of the optic disc will allow for both structural and functional assessment.

Visual Field Testing

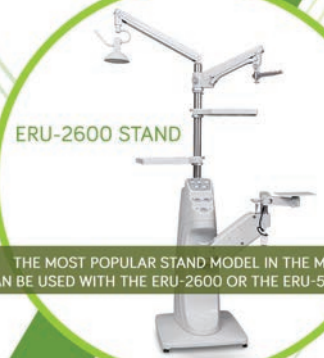In neuro-ophthalmic disease, visual field assessment is important for evaluating lesions thought to be affecting the visual pathway, as well as for monitoring progression of optic nerve disease and intracranial pathology. It is most commonly used in guiding treatment and monitoring for conditions such as

ELI
EZER

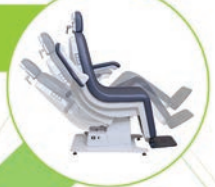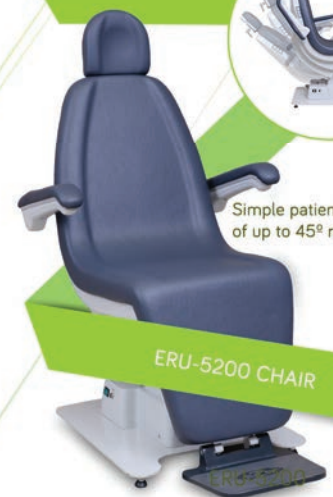EZER WAY OF LIFE



Simple One Touch operation control panel. Reclines 180°.



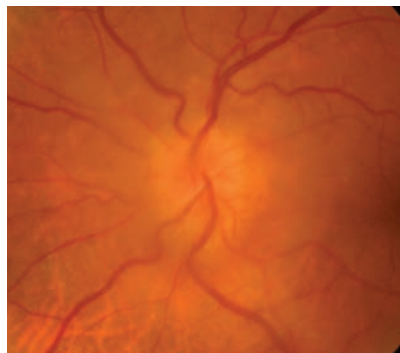
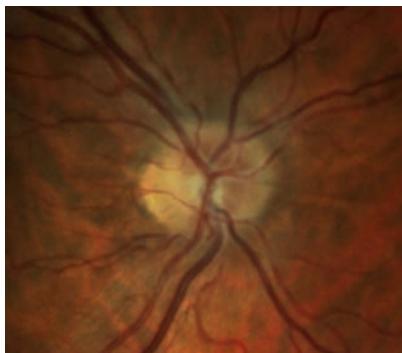
THE MOST POPULAR STAND MODEL IN THE MARKET. CAN BE USED WITH THE ERU-2600 OR THE ERU-5200 CHAIR.



Simple patient positioning of up to 45° recline.

USO
US OPHTHALMIC

www.usophthalmic.com
info@usophthalmic.com
Toll Free 1.888.334.4640



Which is true disc edema? At left is pseudo disc edema from crowding of the optic disc. At right is true disc edema in a patient with a sphenoid wing meningioma.

idiopathic intracranial hypertension (IIH), optic neuropathy, pituitary adenomas and other sellar lesions.¹⁰

While there are diverse applications, visual field testing essentially serves two main functions: localization of the visual pathway and assessment for progression or regression analysis. (See “*Visual Field Defects Associated with Visual Pathways*,” page 36.)

Additionally, testing can be performed by a number of different techniques, including confrontation (with finger counting, red target or facial Amsler), tangent screen, Goldmann kinetic perimetry and standard automated perimetry (SAP). The confrontation technique makes up the majority of our screening fields and is reliable and efficient. When compared to Goldmann and automated perimetry, the confrontation method has a sensitivity of approximately 20% for arcuate, 50% for bitemporal, 70% for homonymous hemianopia and nearly 100% for altitudinal defects.^{5,6}

Remember that while a defect identified by confrontation field testing has a relatively high predictive value of true defects confirmed with formal perimetry, confrontation testing has many limitations. Patients in whom there is a history of neurologic deficit, certain or sus-

pected screening field defects, loss of vision or evidence of optic neuropathy require formal visual field assessment. Also, employ formal field testing in patients with acute or chronic headache syndromes and transient vision loss despite a normal ophthalmologic examination, as slow-growing intracranial masses and migraine-associated cerebrovascular accidents may be identified.

Frequency doubling technology (FDT) has been developed as a screening tool for glaucoma.¹¹ Advantages include efficiency and high sensitivity and specificity when compared to SAP in assessing field loss from optic neuropathy, with limitations in ascribing field loss located to the chiasm and retrochiasm.¹² However, an updated model, FDT (Humphrey Matrix), was found to exhibit greater sensitivity for optic nerve, chiasmal and retrochiasmal disorders when compared to its former counterpart.^{13,14}

Optical Coherence Tomography

Currently, OCT is commonly used to demonstrate pathophysiologic phenomena in a variety of neuro-ophthalmic disorders. It has been studied in several neuro-ophthalmic conditions, including anterior ischemic optic neuropathy, optic neuritis/multiple sclerosis,

neuromyelitis optica, idiopathic intracranial hypertension, migraine, optic nerve head drusen, compressive optic neuropathy and Leber’s hereditary optic neuropathy, as well as Alzheimer’s and Parkinson’s disease.^{15,16}

OCT allows the clinician to quantify the thickness of the retinal nerve fiber layer (RNFL), which is useful in managing disorders of the optic nerve and residual effects of intracranial processes. In particular, it can be of great clinical value in differentiating a low-grade disc edema from pseudo-disc edema, namely optic nerve head drusen (ONHD). Specifically, ONHD is associated with a focal, hyperreflective mass on spectral-domain OCT, along with an adjacent hyporeflective region where the outer nuclear layer covers the drusen. Also, ONHD has a much thinner peripapillary RNFL, while disc edema has a much thicker RNFL in the nasal quadrant.¹⁷

Neuroimaging

Appropriately diagnosing and managing patients with neuro-ophthalmic disease can be both challenging and rewarding. The nature of the disease course—whether urgent or emergent—dictates which neuroimaging study will deliver the most essential information in a timely manner. The most common clinical indications for the use of neuroimaging are as follows: undetermined visual loss, unilateral or bilateral visual field defects and scotomas, anisocoria, ptosis, proptosis, diplopia, ophthalmoplegia, oscillopsia, optic nerve anomalies and pupillary defects.

In general, magnetic resonance imaging (MRI) is the modality of choice for imaging suspected neuro-ophthalmic disease processes, while computed tomography (CT) is more

Table 1. A Brief Comparison of CT and MRI Capabilities

<i>Computed tomography</i>	<i>Magnetic resonance imaging</i>
Ionizing radiation	No ionizing radiation
Excellent visualization of acute hemorrhage	Difficult visualization of acute hemorrhage
Very sensitive to calcification and bony lesions	Difficult visualization of calcification and bony lesions
Limited planes	Multiplanar imaging
Limited visualization near dense bone	Dense bone does not impose any limitation
Limited contrast resolution in soft tissues	Superb soft tissue contrast resolution
Quick to obtain, easily available, inexpensive	Limited availability, time consuming, expensive

appropriate for evaluating intracranial bleeding, osseous lesions of the bony orbit or optic nerve calcifications. (See “A Brief Comparison of CT and MRI Capabilities,” above.)

Additionally, both CT and MR angiography have been successful as non-invasive procedures for studying the arteries in cases of suspected intracranial arterial abnormality.¹⁸ These non-invasive angiographic studies may be used with conventional studies to more accurately assess patients with documented or suspected vascular malformations, intracranial aneurysms and neoplastic vascular growths for which conventional MRI/CT is unremarkable or insufficient.

Nonorganic Vision Loss

Patients who describe and present with physical illness in the absence of an organic cause are referred to as having functional loss. In such cases, it is important to take into account the following considerations: nature of the symptoms, attitude and motivation of the individual. Additionally, most nonorganic disorders can be categorized by three types: malingering, Munchausen syndrome and psychogenic. Patients who present with nonorganic neuro-ophthalmic disorders most commonly complain of

dysfunction of vision, visual field, ocular motility, pupil size and reactivity, eyelid position and function, and cornea sensation.

The most common cause of functional illness is vision loss. Individuals generally present with severe vision loss in one or both eyes despite a normal ophthalmologic examination without refractive error. Such cases present a diagnostic challenge and often occupy a great deal of chair time. Following meticulous history, some of the more common in-office tests are SAP, optokinetic (OKN) drum, mirror test, finger touching, stereopsis, high plus lens refraction and the 4 base-out prism test. These tests allow for an object assessment of visual function and binocularity.¹⁹

As optometrists, our profession continues to evolve. Managing and comanaging neuro-ophthalmic cases are well within our scope of practice. High-tech office equipment is rarely required for diagnosis and management of these disorders, and most optometric offices are equipped with the necessary resources.

Often, it can be difficult for patients to see a neuro-ophthalmologist, as tertiary practices are fewer in number, appointments are often

GREAT QUALITY OPTICS

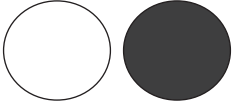
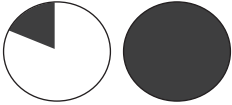
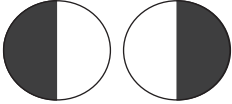

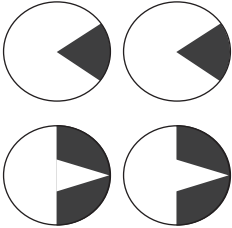
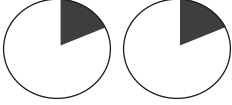
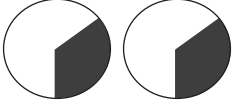






Latest Technology
ESL-7800

Style and comfort
ESL-1800 / ESL-5200

ESL-2600/ ESL-1200

Visual Field Defects Associated with Visual Pathways

Visual Field Defect	Lesion Location
 Decreased vision, right eye	Right optic nerve
 Junctional scotoma	Posterior right optic nerve
 Bitemporal hemianopia	Chiasm
 Right homonymous hemianopia	Left optic tract
 Right homonymous sectoranopias	Left lateral geniculate nucleus
 Right homonymous superior hemianopic defect	Left temporal lobe
 Right homonymous inferior hemianopic defect	Left parietal lobe
 Right homonymous inferior quadrantanopia	Left occipital lobe (upper bank)
 Right homonymous superior quadrantanopia	Left occipital lobe (lower bank)
 Right homonymous macular-sparing hemianopia	Left occipital lobe
 Right homonymous scotomas	Tip of the left occipital lobe

Biousse V, Newman NJ. Neuro-Ophthalmology Illustrated. New York: Thieme; 2009: 41-3.

limited and the distance to travel is usually greater. As a result, optometrists have now become vital providers in serving patients with neuro-ophthalmic disease. ■

Dr. Trottni is in practice at Outlook Eyecare in Monroe Township, NJ.

Dr. DelGiodice is in practice at Associated Eye Physicians in Clifton, NJ.

- Cornblath WT, Butter CM, Barnes LL, Hasselbach MM. Spatial characteristics of cerebral polyopia: a case study. *Vision Res.* 1998 Dec;38(24):3965-78.
- Athappilly G, Pelak VS, Mandava N, Bennett JL. Ischemic optic neuropathy. *Neurol Res.* 2008 Oct;30(8):794-800.
- Hainer BL, Matheson EM. Approach to acute headache in adults. *Am Fam Physician.* 2013 May 15;87(10):682-7.
- Ramat S, Leigh RJ, Zee DS, Optican LM. What clinical disorders tell us about the neural control of saccadic eye movements. *Brain.* 2007 Jan;130(Pt 1):10-35.
- Trobe JD, Acosta PC, Krischer JP, Trick GL. Confrontation visual field techniques in the detection of anterior visual pathway lesions. *Ann Neurol.* 1981 Jul;10(1):28-34.
- Johnson LN, Baloh FG. The accuracy of confrontation visual field test in comparison with automated perimetry. *J Natl Med Assoc.* 1991 Oct;83(10):895-8.
- Cibis GW, Tripathi RC, Tripathi BJ. Glaucoma in Sturge-Weber syndrome. *Ophthalmology.* 1984 Sep;91(9):1061-71.
- Trobe JD, Glaser JS, Cassady J, et al. Nonglaucomatous excavation of the optic disc. *Arch Ophthalmol.* 1980 Jun;98(6):1046-50.
- Rader J, Feuer WJ, Anderson DR. Peripapillary vasoconstriction in the glaucomas and the anterior ischemic optic neuropathies. *Am J Ophthalmol.* 1994 Jan 15;117(1):72-80.
- Kedar S, Ghate D, Corbett JJ. Visual fields in neuro-ophthalmology. *Indian J Ophthalmol.* 2011 Mar-Apr;59(2):103-9.
- Wall M, Neahring RK, Woodward KR. Sensitivity and specificity of frequency doubling perimetry in neuro-ophthalmic disorders: a comparison with conventional automated perimetry. *Invest Ophthalmol Vis Sci.* 2002 Apr;43(4):1277-83.
- Noval S, Contreras I, Rebolledo G, et al. A comparison between Humphrey and frequency doubling perimetry for chiasmal visual field defects. *Eur J Ophthalmol.* 2005 Nov-Dec;15(6):739-45.
- Huang CQ, Carolan J, Redline D, et al. Humphrey Matrix perimetry in optic nerve and chiasmal disorders: comparison with Humphrey SITA standard 24-2. *Invest Ophthalmol Vis Sci.* 2008 Mar;49(3):917-23.
- Taravati P, Woodward KR, Keltner JL, et al. Sensitivity and specificity of the Humphrey Matrix to detect homonymous hemianopias. *Invest Ophthalmol Vis Sci.* 2008 Mar;49(3):924-8.
- Subei AM, Eggenberger ER. Optical coherence tomography: another useful tool in a neuro-ophthalmologists armamentarium. *Curr Opin Ophthalmol.* 2009 Nov;20(6):462-6.
- Pasol J. Neuro-ophthalmic disease and optical coherence tomography: glaucoma look-alikes. *Curr Opin Ophthalmol.* 2011 Mar;22(2):124-32.
- Johnson LN, Diehl ML, Hamm CW, et al. Differentiating optic disc edema from optic nerve head drusen on optical coherence tomography. *Arch Ophthalmol.* 2009 Jan;127(1):45-9.
- Weishaupt D, Köchli DV, Marincek B. How Does MRI Work? An Introduction to the Physics and Function of Magnetic Resonance Imaging. Berlin, Germany: Springer-Verlag Berlin and Heidelberg GmbH & Co. K; 2008.
- Miller NR, Newman NJ, Biousse V, Kerrison JB, Walsh and Hoyt's Clinical Neuro-Ophthalmology: The Essentials. 2nd ed. Philadelphia: Lippincott Williams & Wilkins; 2008.




BIOFINITY MULTIFOCAL LENSES
AVAILABLE UP TO -10.00D

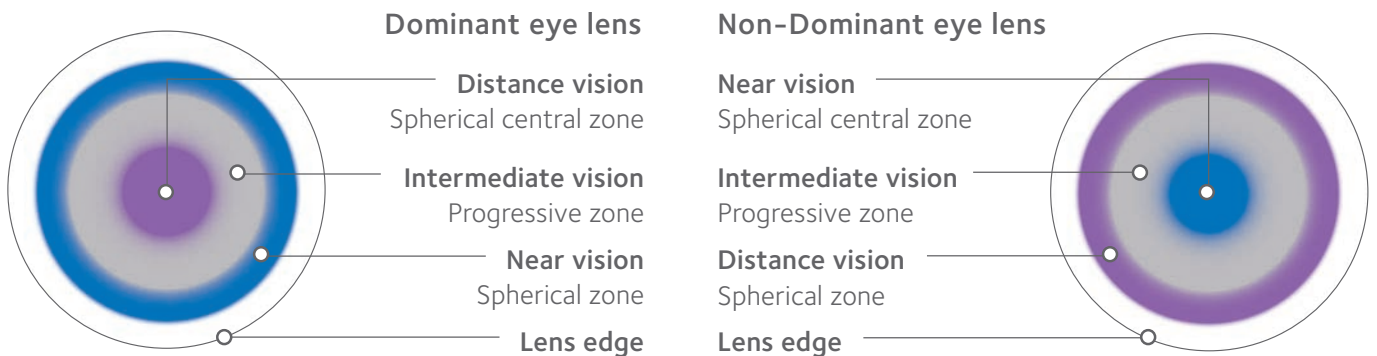
An easy fit

for you and
your presbyopic
patients.

CooperVision Biofinity® multifocal lenses combine a high-performing 3rd generation material with a streamlined fitting process. Now even your most challenging presbyopic patients can enjoy the freedom of **all-distance clarity and lasting comfort.**



Balanced Progressive™ Technology enhances vision near, far and intermediate.
It also allows for an individualized fitting for each wearer and each eye.



Biofinity & Biofinity XR Biofinity toric **Biofinity multifocal**

Download your Biofinity multifocal 3-step fitting guide at
coopervision.com/fitting-guide



CooperVision®
Live Brightly.®

Annual Pharmaceutical Issue

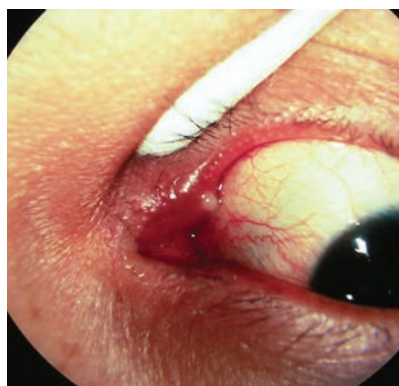When a Drop Isn't Enough

Oral antibiotics and analgesics often are clinically necessary when treating certain ocular conditions. Here's a rundown of our favorite systemic agents.

By Carl H. Spear, OD, MBA, and Mark Obenchain, OD

Oral medications play a very important and clearly defined role in daily practice. Our profession has grown and matured significantly during the last three decades, and now the vast majority of us are able to prescribe more orals than ever before. Expanded prescribing rights allow us to more effectively manage our patients, as well as bring additional value and savings to the health care system.

Although several categories of oral medications play an important role in patient care, anti-infectives and analgesics are among the most frequently prescribed agents. In order to effectively use these medications in clinical practice, however, it is essential to balance a number of factors—such as side effect profiles, drug allergies and pregnancy status—that will ultimately lead to the success or failure of treatment.



Which oral antibiotic would be most appropriate to treat dacryocystitis, as seen in this patient?

A Lesson in History

Before initiating oral meds, a complete ocular and systemic history is crucial. This includes detailed knowledge of any other medications the patient is taking and whether the individual has any relevant drug allergies. Also, it is important document his or her general health status—particularly

liver and kidney function. Remember that proper liver function is critical for the metabolism of oral medications, and kidney function is integral to drug excretion.

A practical pointer—when encountering patients with extensive medication lists and multiple drug allergies, it may be helpful to ask them which agents they've used in the past for pain management or certain infections. We have several of these patients in our practice. Over time, many of them have learned which pain medications, for example, they can take without difficulty.

Oral Anti-Infective Agents in Eye Care

We like to employ the “big bottle theory” when prescribing oral medications. If you look behind the counter in any pharmacy, you will see all sizes and shapes of pill bottles. The understood rule here



For patients with decreased tear production presumed to be due to
ocular inflammation associated with Chronic Dry Eye

THE DRY EYE TREATMENT SHE NEEDS TODAY. BECAUSE TOMORROW MATTERS.



RESTASIS® twice a day, every day, helps patients experience increased tear production

Increased tear production was seen at 6 months.¹

Indication and Usage

RESTASIS® (cyclosporine ophthalmic emulsion) 0.05% is indicated to increase tear production in patients whose tear production is presumed to be suppressed due to ocular inflammation associated with keratoconjunctivitis sicca. Increased tear production was not seen in patients currently taking topical anti-inflammatory drugs or using punctal plugs.

Important Safety Information

Contraindications

RESTASIS® is contraindicated in patients with known or suspected hypersensitivity to any of the ingredients in the formulation.

Warnings and Precautions

Potential for Eye Injury and Contamination: To avoid the potential for eye injury and contamination, individuals prescribed RESTASIS® should not touch the vial tip to their eye or other surfaces.

Use With Contact Lenses: RESTASIS® should not be administered while wearing contact lenses. If contact lenses are worn, they should be removed prior to the administration of the emulsion.

Adverse Reactions

In clinical trials, the most common adverse reaction following the use of RESTASIS® was ocular burning (upon instillation)—17%. Other reactions reported in 1% to 5% of patients included conjunctival hyperemia, discharge, epiphora, eye pain, foreign body sensation, pruritus, stinging, and visual disturbance (most often blurring).

Please see Brief Summary of the full Prescribing Information on adjacent page.

Reference: 1. RESTASIS® Prescribing Information.



©2014 Allergan, Inc., Irvine, CA 92612
® marks owned by Allergan, Inc.
APC20AF14 141005

RESTASIS® (Cyclosporine Ophthalmic Emulsion) 0.05%

BRIEF SUMMARY—PLEASE SEE THE RESTASIS® PACKAGE INSERT FOR FULL PRESCRIBING INFORMATION.

INDICATION AND USAGE

RESTASIS® ophthalmic emulsion is indicated to increase tear production in patients whose tear production is presumed to be suppressed due to ocular inflammation associated with keratoconjunctivitis sicca. Increased tear production was not seen in patients currently taking topical anti-inflammatory drugs or using punctal plugs.

CONTRAINDICATIONS

RESTASIS® is contraindicated in patients with known or suspected hypersensitivity to any of the ingredients in the formulation.

WARNINGS AND PRECAUTIONS

Potential for Eye Injury and Contamination

To avoid the potential for eye injury and contamination, be careful not to touch the vial tip to your eye or other surfaces.

Use with Contact Lenses

RESTASIS® should not be administered while wearing contact lenses. Patients with decreased tear production typically should not wear contact lenses. If contact lenses are worn, they should be removed prior to the administration of the emulsion. Lenses may be reinserted 15 minutes following administration of RESTASIS® ophthalmic emulsion.

ADVERSE REACTIONS

Clinical Trials Experience

Because clinical trials are conducted under widely varying conditions, adverse reaction rates observed in the clinical trials of a drug cannot be directly compared to rates in the clinical trials of another drug and may not reflect the rates observed in practice.

In clinical trials, the most common adverse reaction following the use of RESTASIS® was ocular burning (17%).

Other reactions reported in 1% to 5% of patients included conjunctival hyperemia, discharge, epiphora, eye pain, foreign body sensation, pruritus, stinging, and visual disturbance (most often blurring).

Post-marketing Experience

The following adverse reactions have been identified during post approval use of RESTASIS®. Because these reactions are reported voluntarily from a population of uncertain size, it is not always possible to reliably estimate their frequency or establish a causal relationship to drug exposure.

Reported reactions have included: hypersensitivity (including eye swelling, urticaria, rare cases of severe angioedema, face swelling, tongue swelling, pharyngeal edema, and dyspnea); and superficial injury of the eye (from the vial tip touching the eye during administration).

USE IN SPECIFIC POPULATIONS

Pregnancy

Teratogenic Effects: Pregnancy Category C

Adverse effects were seen in reproduction studies in rats and rabbits only at dose levels toxic to dams. At toxic doses (rats at 30 mg/kg/day and rabbits at 100 mg/kg/day), cyclosporine oral solution, USP, was embryo- and fetotoxic as indicated by increased pre- and postnatal mortality and reduced fetal weight together with related skeletal retardations. These doses are 5,000 and 32,000 times greater (normalized to body surface area), respectively, than the daily human dose of one drop (approximately 28 mcL) of 0.05% RESTASIS® twice daily into each eye of a 60 kg person (0.001 mg/kg/day), assuming that the entire dose is absorbed. No evidence of embryofetal toxicity was observed in rats or rabbits receiving cyclosporine at oral doses up to 17 mg/kg/day or 30 mg/kg/day, respectively, during organogenesis. These doses in rats and rabbits are approximately 3,000 and 10,000 times greater (normalized to body surface area), respectively, than the daily human dose.

Offspring of rats receiving a 45 mg/kg/day oral dose of cyclosporine from Day 15 of pregnancy until Day 21 postpartum, a maternally toxic level, exhibited an increase in postnatal mortality; this dose is 7,000 times greater than the daily human topical dose (0.001 mg/kg/day) normalized to body surface area assuming that the entire dose is absorbed. No adverse events were observed at oral doses up to 15 mg/kg/day (2,000 times greater than the daily human dose).

There are no adequate and well-controlled studies of RESTASIS® in pregnant women. RESTASIS® should be administered to a pregnant woman only if clearly needed.

Nursing Mothers

Cyclosporine is known to be excreted in human milk following systemic administration, but excretion in human milk after topical treatment has not been investigated. Although blood concentrations are undetectable after topical administration of RESTASIS® ophthalmic emulsion, caution should be exercised when RESTASIS® is administered to a nursing woman.

Pediatric Use

The safety and efficacy of RESTASIS® ophthalmic emulsion have not been established in pediatric patients below the age of 16.

Geriatric Use

No overall difference in safety or effectiveness has been observed between elderly and younger patients.

NONCLINICAL TOXICOLOGY

Carcinogenesis, Mutagenesis, Impairment of Fertility

Carcinogenesis: Systemic carcinogenicity studies were carried out in male and female mice and rats. In the 78-week oral (diet) mouse study, at doses of 1, 4, and 16 mg/kg/day, evidence of a statistically significant trend was found for lymphocytic lymphomas in females, and the incidence of hepatocellular carcinomas in mid-dose males significantly exceeded the control value.

In the 24-month oral (diet) rat study, conducted at 0.5, 2, and 8 mg/kg/day, pancreatic islet cell adenomas significantly exceeded the control rate in the low-dose level. The hepatocellular carcinomas and pancreatic islet cell adenomas were not dose related. The low doses in mice and rats are approximately 80 times greater (normalized to body surface area) than the daily human dose of one drop (approximately 28 mcL) of 0.05% RESTASIS® twice daily into each eye of a 60 kg person (0.001 mg/kg/day), assuming that the entire dose is absorbed.

Mutagenesis: Cyclosporine has not been found to be mutagenic/genotoxic in the Ames Test, the V79-HGPRT Test, the micronucleus test in mice and Chinese hamsters, the chromosome-aberration tests in Chinese hamster bone-marrow, the mouse dominant lethal assay, and the DNA-repair test in sperm from treated mice. A study analyzing sister chromatid exchange (SCE) induction by cyclosporine using human lymphocytes *in vitro* gave indication of a positive effect (i.e., induction of SCE).

Impairment of Fertility: No impairment in fertility was demonstrated in studies in male and female rats receiving oral doses of cyclosporine up to 15 mg/kg/day (approximately 2,000 times the human daily dose of 0.001 mg/kg/day normalized to body surface area) for 9 weeks (male) and 2 weeks (female) prior to mating.

PATIENT COUNSELING INFORMATION

Handling the Container

Advise patients to not allow the tip of the vial to touch the eye or any surface, as this may contaminate the emulsion. To avoid the potential for injury to the eye, advise patients to not touch the vial tip to their eye.

Use with Contact Lenses

RESTASIS® should not be administered while wearing contact lenses. Patients with decreased tear production typically should not wear contact lenses. Advise patients that if contact lenses are worn, they should be removed prior to the administration of the emulsion. Lenses may be reinserted 15 minutes following administration of RESTASIS® ophthalmic emulsion.

Administration

Advise patients that the emulsion from one individual single-use vial is to be used immediately after opening for administration to one or both eyes, and the remaining contents should be discarded immediately after administration.

Rx Only



Based on package insert 71876US17

© 2013 Allergan, Inc.

Irvine, CA 92612, U.S.A.

® marks owned by Allergan, Inc. APC37BD13

Patented. See www.allergan.com/products/patent_notices

Made in the U.S.A.

is that the medications kept in the biggest bottles are the ones that are most often used, so the pharmacy keeps more of them on hand. Although there certainly are times when less common medications are needed, it is our experience that most infectious ocular conditions can be treated with five to six oral agents.

Determining whether the infectious process at hand is acute or chronic is the first decision point in our medication selection process. Once we have made this determination, we then go to our “Fabulous Five” oral anti-infectives to select the most appropriate drug for that individual.

Our ‘Fabulous Five’ Oral Antibiotics

1. Amoxicillin with or without clavulanic acid. This is a great choice for soft tissue infections, such as hordeolum, preseptal cellulitis, dacryocystitis and dacryoadenitis.¹ Amoxicillin is a member of the penicillin family. It does not kill bacteria directly, but prevents them from multiplying by prohibiting cell wall formation. When clavulanic acid is added to amoxicillin, it enhances the agent’s bactericidal effect via inactivation of the enzyme beta lactamase. This further prohibits microbial resistance against organisms that produce beta lactamase, such as *S. aureus*, *S. epidermidis* and *H. influenza*.²

Anyone with children knows that pediatricians prescribe amoxicillin and Augmentin (amoxicillin/clavulanic acid, GlaxoSmithKline) for a variety of infections. Augmentin is especially good against gram-negative *H. influenza*.² It is available in a variety of formulations and flavors, and is our first choice in children with acute infections.

Specifically for use in pediatric patients, Augmentin is prescribed as 20mg/kg/day to 40mg/kg/day for no more than 10 days. Any time we treat children, we always call their pediatrician as a courtesy and send a follow-up letter. This has proven to be a great practice builder, frequently resulting in referrals.

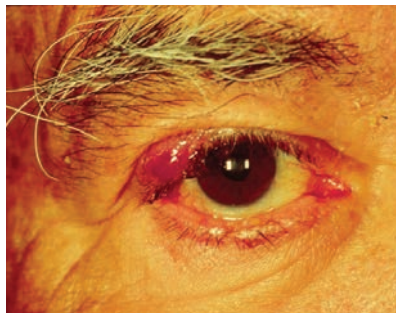
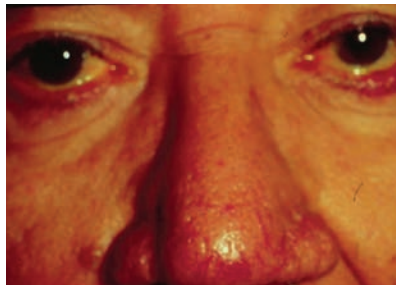
For adults, dosing should be 500mg to 875mg BID for five to seven days. Further, because Augmentin is a Category B drug, it can be used by female patients who are pregnant or nursing.

If Augmentin is prescribed, it should be taken with food or milk to improve clavulanic acid absorption. Be sure to document hepatic function in the patient history, because the drug is contraindicated in those with acute liver injury and/or liver disease.

2. Cephalexin. For adults with soft tissue infections (e.g., preseptal cellulitis, dacryocystitis, dacryoadenitis), our first choice is Keflex (cephalexin, Advancis Pharmaceutical) at a dosage of 250mg to 500 mg QID for 10 to 14 days. Cephalexin is a member of the cephalosporin antibiotic class. These agents demonstrate a similar mode of action and side effect profile as the penicillins.

Keflex is a great choice due to cost and proven efficacy. Although Augmentin would be our first choice for pediatric patients, Keflex can also be dosed at 25mg/kg/day to 50mg/kg/day.

The cross-sensitivity of cephalexin and penicillin is reported to be anywhere from 1% to 10%.¹⁻³ Thus, you may wish to consider other antibiotic options for patients who have a documented history of penicillin allergy. Keflex also is contraindicated in patients with hemophilia and/



Doxycycline is our first choice for the management of chronic inflammatory conditions, such as rosacea (top) and lid disease (bottom).

or other blood disorders due to altered vitamin K absorption.¹

3. Doxycycline. If we could prescribe only one oral medication, it would be doxycycline. This agent is especially useful in treating chronic infections and inflammatory conditions that affect the lids, such as meibomianitis and blepharitis, but also can be used to manage rosacea, chlamydial conjunctivitis and recurrent corneal erosions.

A member of the tetracycline class, doxycycline is bacteriostatic and works by binding to bacterial ribosomes and inhibiting protein synthesis. Clinically, doxycycline is preferred over tetracycline because it is much better absorbed.^{1,4} Doxycycline should be taken on an empty stomach to further aid absorption.

Doxycycline (and all tetracyclines, in general) are contraindicated in children younger than eight years, nursing mothers and

during pregnancy. Clinicians also should keep in mind that pseudotumor cerebri has been documented in patients who use doxycycline—especially in younger individuals.^{1,5} Increased photosensitivity and gastric distress are other common side effects.

Dosages for doxycycline vary depending upon the patient's disease state. For severe cases of meibomianitis, consider a dosage of 100mg BID for two to four weeks, followed by 50mg BID for two to four months. Recent studies have indicated that doxycycline dosages as low as 20mg BID are clinically effective, yield fewer side effects and improve compliance.^{6,7} Thus, we use 50mg BID initially for four weeks, then 20mg BID for three to six months.

For rosacea, 50mg to 100mg daily for two to six weeks should effectively reduce symptoms. Then, the medication can be titrated to 20mg per day as a maintenance dose.

Doxycycline also exhibits anti-inflammatory properties, and reduces the production of inflammatory compounds, such as matrix metalloproteinase (MMP).⁸ This characteristic makes doxycycline effective against inflammatory lid disease. Studies also have shown that this anti-inflammatory activity can reduce the incidence and severity of recurrent corneal erosions.^{4,9} A dosage of 50mg doxycycline BID, in conjunction with topical fluorometholone 0.1% TID, for four to eight weeks is recommended to relieve symptoms and decrease recurrence.

Doxycycline is our choice for chronic infectious disease, and can be prescribed as an alternative for acute infections when patients are allergic to penicillin and/or the

higher cost of azithromycin is a consideration.

4. Azithromycin. This agent is macrolide antibiotic and derivative of erythromycin. Azithromycin is a first-line treatment for chlamydial infections, such as adult inclusion conjunctivitis and trachoma. For these disease processes, a one-time, a cumulative dose of 1,000mg (four 250mg capsules or two 500mg capsules) should be sufficient.

To treat soft tissue infections, azithromycin can be administered at 500mg for one day and 250mg for four days. Also, it is our first choice for patients with known penicillin or cephalosporin allergies. Azithromycin is safe to use during pregnancy, and is a great alternative to amoxicillin and cephalexin for pediatric patients.

Due to a high rate of azithromycin prescriptions in the US, *S. pneumonia* and *H. influenzae* have developed resistance. Several researchers have advocated that prescribing physicians should minimize these prescribing habits.¹⁰⁻¹²

Furthermore, the FDA has advised clinical discretion, when

prescribing azithromycin to patients with a documented history of cardiac problems. Studies have shown that the drug can cause an elongated QT interval, leading to abnormal heart rhythm and possibly death.¹³

5. Trimethoprim/sulfamethoxazole. A lesser-known but clinically useful oral antibiotic is trimethoprim/sulfamethoxazole. Given its broad spectrum of activity and effectiveness against *S. aureus*, this is our drug of choice if MRSA is suspected, for patients with infections that are resistant to other medications and for healthcare personnel. The medication is generally well tolerated, and is dosed just twice a day.

Sepra (trimethoprim/sulfamethoxazole, Monarch Pharmaceuticals) and Bactrim (trimethoprim/sulfamethoxazole, Roche) are contraindicated in children less than two months of age, pregnant or nursing mothers, patients with sickle cell disease and those with sulfa allergies. Patients who use either medication may be at a higher risk of Stevens-Johnson syndrome.¹

For soft tissue infections in adults, the proper dosage of trimethoprim/sulfamethoxazole is 80mg/400mg to 160mg/800mg BID for 10 to 14 days. Take note that the medication should not be taken with food. Several pediatric options are available for children older than two months; however, the recommended dosage depends on the type and severity of the infection.

Oral Analgesics in Eye Care

Conditions such as corneal or conjunctival foreign bodies, corneal abrasions, recurrent corneal erosion, post-refractive surgery, blunt ocular trauma, post-herpetic neuralgia and anterior uveitis could warrant pain management. The options for pain management include over-the-counter medications, prescription medications and heavily regulated narcotic analgesics.

Analgesics either work peripherally (non-steroidal anti-inflammatory drugs and aspirin) at the end receptors or centrally (opioids and acetaminophen) in the nervous system. This fundamental understanding helps us determine the most suitable medication for each patient. We can also take advantage of the different mechanisms of action, as well as the synergistic effect created by using combination medications that include one peripherally- and one centrally-acting agent.

Acetaminophen (Tylenol, McNeil Consumer Healthcare), which is a non-opioid analgesic, helps with pain and fever, but does not exhibit anti-inflammatory properties. The exact mechanism of action is not completely understood, but is thought to work centrally when reducing pain.¹⁴

Oral NSAIDs and aspirin, on the

Guidelines for Judicious Oral Analgesics Use

When prescribing for pain, you must carefully consider the advantages and limitation of each drug choice. Side effects such as drowsiness, dizziness, nausea, vomiting and constipation must be taken into account, as well as whether the individual drinks alcohol in excess. These potential complications must be discussed with the patient before deciding upon an appropriate agent.

Always be cautious of patients who exhibit drug-seeking behavior. Be wary of those who “self-diagnose” and/or “self-prescribe,” or patients who seek multiple physicians for the same condition. Also, be on the lookout for new patients who present with the exact same illness as someone to whom you recently prescribed narcotics. Other safety measures you might consider include keeping prescription pads safe, not preprinting DEA numbers, not pre-signing Rx pads and writing out numbers (e.g., “ten” vs. “10”).

Pay special attention to any pregnant patients who report significant pain. When in doubt, there is no harm in contacting or deferring to the individual’s primary care provider or OB/GYN. Medications that are safe to prescribe in pregnancy include erythromycin, azithromycin, amoxicillin, amoxicillin with clavulanic acid and Tylenol #3, as well as the antiviral medications acyclovir, valacyclovir and famciclovir.

other hand, work on the peripheral nervous system by inhibiting cyclooxygenase (COX) at the site of injury.

Opioids act on the central nervous system by blocking incoming nociceptive signals to the brain, thus reducing pain sensitivity. It is worth noting that opioids do not have anti-inflammatory properties.

Our 'Fabulous Five' Analgesic Agents

1. Acetaminophen and ibuprofen. These OTC options are solid choices for basic pain management. The synergistic effect of centrally-acting acetaminophen and peripherally-acting ibuprofen provides excellent pain management. One study indicated that combined ibuprofen and acetaminophen worked more effectively than the concur-

rent use of an opioid and acetaminophen for pain relief following dental operations.¹⁵

The study also showed that the ibuprofen and acetaminophen combination was safer than any analgesic combinations that included opioids.

Over-the-counter Tylenol is the safest pain management option for children and pregnant mothers when used as monotherapy.¹⁵ The daily dosage limitation for adults is 4,000mg. Further, Tylenol should not be prescribed to patients who are diagnosed with liver impairment and/or alcoholism.

Ibuprofen dosing should not exceed 2,400mg/day, and should be taken with food if the patient reports gastrointestinal upset.

Contraindications for Narcotic Analgesics

- Known hypersensitivities
- COPD
- Liver and kidney problems
- Pregnancy
- History of pain medication abuse

2. Ketoprofen. At one time, ketoprofen was available OTC. But now, it is a prescription-only NSAID prescribed for mild to moderate pain. It is available in 50mg and 75mg capsules, and typically is dosed every six to eight hours. Additionally, there is a 200mg QD option; however, total daily dosing should not exceed 300mg.

We have found ketoprofen is especially useful in cases where significant ocular inflammation exists, such as trauma-induced anterior

Your own custom App

for iPhone, Android, iPad and Mobile Website!

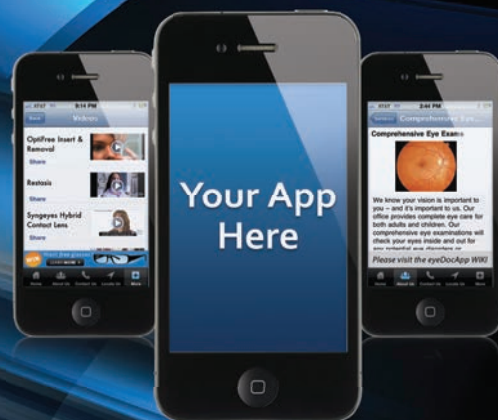EyeDocApp makes it easy for Individuals and Businesses to have their own custom App for iPhone, Android and iPad. Now you can use the same technology that Fortune 500 companies are using, for a fraction of the cost!

Apps are the most powerful mobile marketing tools in the world! Your custom App can be downloaded by anyone in the world via the iTunes and Android Marketplace. Now all your customers can have your business in their pocket, and at their fingertips. You can even send PUSH Notifications which instantly pop up on their phone, just like a text message.

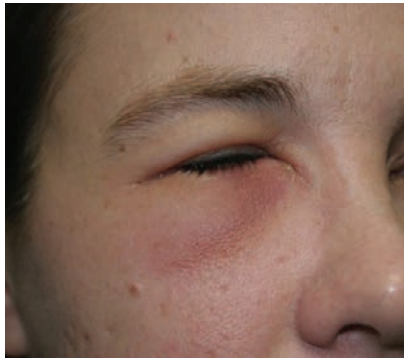Unlimited upgrades, push notifications, features and a user friendly interface –
All for \$49.⁹⁹/month

Learn more at EyeDocApp.com

EyeDocApp



Exclusively Marketed by
Jobson Optical's
ECP
BUSINESS SERVICES
Understand. Manage. Grow.



In addition to amoxicillin, which oral anti-infective agent demonstrates good clinical efficacy against preseptal cellulitis, as seen here?

uveitis. Studies have shown that ketoprofen is superior to OTC ibuprofen for pain management, so it is an effective alternative to narcotic analgesics.¹⁶

3. Hydrocodone and ibuprofen. Hydrocodone is six times more potent than codeine.¹⁷ Unfortunately, with this increased potency comes a profoundly higher likelihood of addiction.

Because of a perceived increase in both drug-seeking behavior and opioid abuse during the last decade, officials from the Drug Enforcement Agency (DEA) reclassified hydrocodone as a Schedule II medication in August 2014. The majority of states only allow optometrists to prescribe Schedule III, IV and V medications.¹⁸

It is your responsibility to learn whether you live in a state that still permits ODs to prescribe Schedule II agents. If you are, then Vicoprofen (AbbVie) is our choice. Again, we like taking advantage of the centrally-acting opioid analgesic hydrocodone and the peripherally-acting ibuprofen.

Vicoprofen is available in a 7.5mg/200mg formulation, and can be taken every four to six hours, as needed. Patients should not take more than five tablets per

day. Also, Vicoprofen is approved for patients 16 years of age and older.

4. Tylenol with codeine. For those who live in states that do not permit optometrists to prescribe Schedule II medications, we recommend Tylenol with codeine (Janssen Pharmaceuticals). While it does not provide the synergistic analgesic effect associated with hydrocodone and ibuprofen, it does meet our big bottle criteria, and is one of the most frequently prescribed opioid analgesics in the US.

We recommend two formulations—300mg/30mg (Tylenol #3) and 300mg/60mg (Tylenol #4). Tylenol #3 can be prescribed for children older than seven years, and Tylenol 4 can be prescribed for children older than 13 years. If being used long-term, it is prudent to taper the medication to avoid drug dependence.

5. Tramadol. In July 2014, the DEA universally classified tramadol as a Schedule IV medication. Ultram (Janssen Pharmaceuticals) is available in 50mg and 100mg, 200mg and 300mg extended-release dosages. Maximum dosing is 300mg/day for moderate to severe pain.

Oral medications are a wonderful tool for eye care providers. However, each practitioner's experience, confidence and comfort level with oral prescribing varies dramatically. Involving primary care providers and other medical specialists, as well as pharmacists, can help improve your knowledge of oral medications, appropriate dosing protocols and potential adverse effects.

Our predecessors have worked long and hard to gain oral prescribing rights in clinical practice. Therefore, we encourage you to

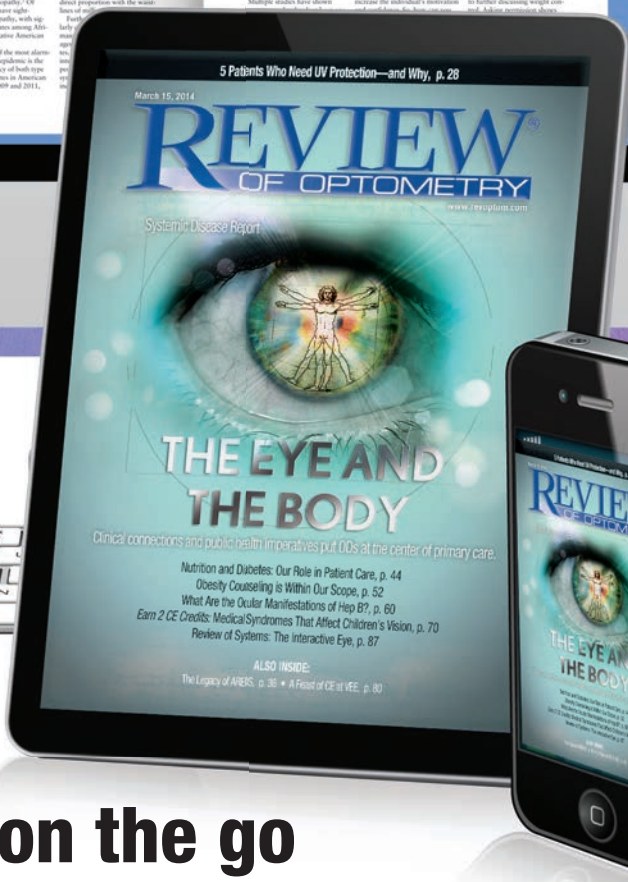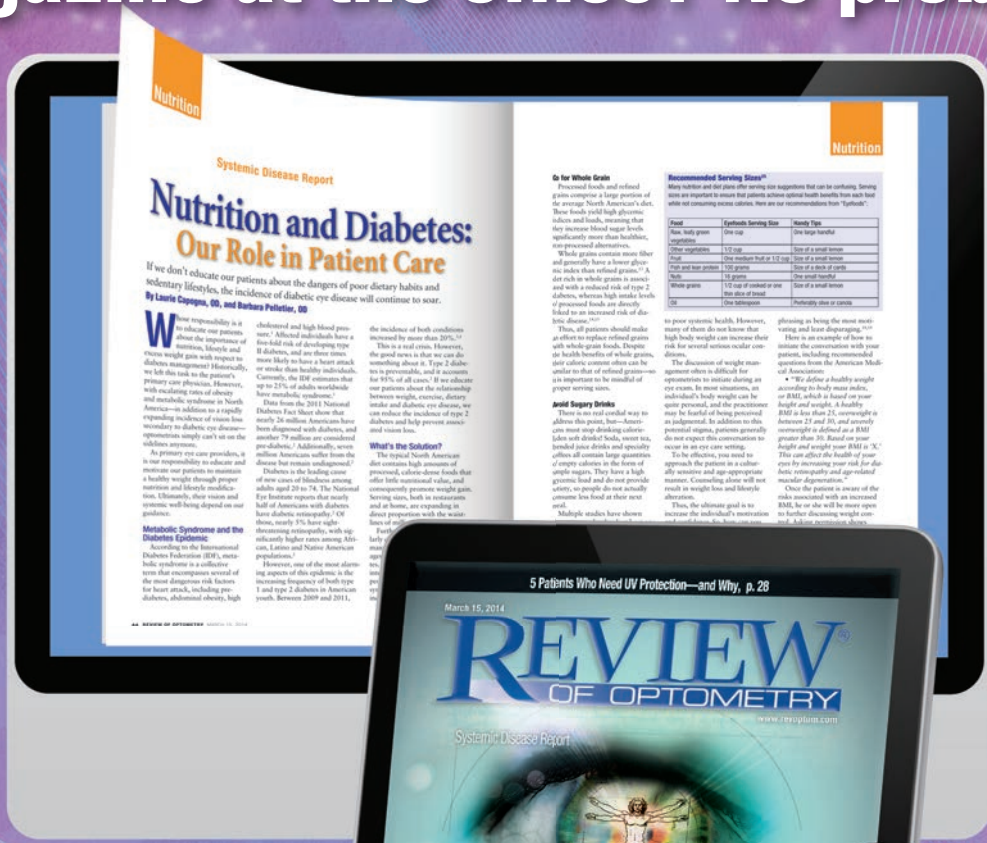use them to the fullest scope of your licensure and comfort level to ensure that your patients receive the best care possible. ■

Dr. Spear owns and operates Sight and Sun Eyeworks, a five-location optometry/ophthalmology practice in Pensacola, Fla.

Dr. Obenchain is in private practice at Sight and Sun Eyeworks in Pensacola.

1. Cooper DH, Krainik AJ, Lubner SJ. The Washington Manual of Medical Therapeutics, 32nd ed. Chapter 12. Antimicrobials. United States: Wolters Kluwer; 2007.
2. Rang HP, Dale MM, Ritter JM, Flower RJ. Rang and Dale's Pharmacology, 6th ed. Drugs used in the treatment of infection and cancer. China: Elsevier; 2007.
3. Preston SL, Briceland LL. Accuracy of penicillin allergy reporting. Am J Hosp Pharm. 1994 Jan 1;51(1):79-84.
4. Lonsberry B. Doxycycline: Do's and Don'ts. Rev Optom. 2014 Feb;151(2):38-41.
5. Tabibian JH, Gutierrez MA. Doxycycline-induced pseudotumor cerebri. South Med J. 2009 Mar;102(3):310-1.
6. van Zuuren EJ, Graber MA, Hollis S, et al. Interventions for rosacea. Cochrane Database Syst Rev. 2005 Jul 20;(3):CD003262.
7. Yoo SE, Lee DC, Chang MH. The effect of low-dose doxycycline therapy in chronic meibomian gland dysfunction. Kor J Ophthalmol. 2005 Dec;19(4):258-63.
8. Research in dry eye: report of the Research Subcommittee of the International Dry Eye WorkShop (2007). Ocul Surf. 2007 Apr;5(2):179-93.
9. Wang L, Tsang H, Coroneo M. Treatment of recurrent corneal erosion syndrome using the combination of oral doxycycline and topical corticosteroid. Clin Exp Ophthalmol. 2008 Feb;36(1):8-12.
10. Jenkins SG, Brown SD, Farrell DJ. Trends in antibacterial resistance among *Streptococcus pneumoniae* isolated in the USA: update from PROTEKT US years 1-4. Ann Clin Microbiol Antimicrob. 2008 Jan 11;7:1.
11. Hoban DJ, Doern GV, Fluit AC, et al. Worldwide prevalence of antimicrobial resistance in *Streptococcus pneumoniae*, *Haemophilus influenzae*, and *Moraxella catarrhalis* in the SENTRY Antimicrobial Surveillance Program, 1997-1999. Clin Infect Dis. 2001;32(Suppl. 2):S81-93.
12. Serisier DJ. Risks of population antimicrobial resistance associated with chronic macrolide use for inflammatory airway diseases. Lancet Respir Med. 2013 May;1(3):262-74.
13. U.S. Food and Drug Administration (FDA). Azithromycin (Zithromax or Zmax) and the risk of potentially fatal heart rhythms. FDA Drug Safety Communication, 2013. Available at: www.fda.gov/drugs/drugsafety/ucm341822.htm. Accessed December 28, 2014.
14. Rang HP, Dale MM. Rang and Dale's Pharmacology, 6th ed. Section 2 - Chemical Mediators: Anti-inflammatory and immunosuppressant drugs. China: Elsevier; 2007.
15. Moore PA, Hersh EV. Combining ibuprofen and acetaminophen for acute pain management after third-molar extractions: translating clinical research to dental practice. J Am Dent Assoc. 2013 Aug;144(8):898-908.
16. Sarzi-Puttini P, Atzeni F, Lanata L, et al. Efficacy of ketoprofen vs. ibuprofen and diclofenac: a systematic review of the literature and meta-analysis. Clin Exp Rheumatol. 2013 Sep-Oct;31(5):731-8.
17. Anderson R, Sifers JH, Abram S, Schlicht C. Accuracy in equianalgesic dosing conversion dilemmas. J Pain Symptom Manage. 2001 May;21(5):397-406.
18. Meers GF, Allredge BF. Learn to Spot Drug-Seeking Behavior. Rev Optom. Feb;151(2):42-8.

Left your *Review of Optometry* magazine at the office? No problem!



Read *Review* on the go from any mobile device!

Just simply go to www.reviewofoptometry.com and click on the digimag link to get your current issue.

Off Label, But on Target

Using drugs off label is not only permissible, it's often standard of care. Get to know the following non-FDA-approved indications (if you don't know them already).

By John Murphy, Executive Editor

You're probably using ophthalmic drugs for off-label uses (those not approved by the FDA) more often than you realize.

In fact, about half of medications prescribed routinely in eye care are likely used off label.¹ For example, topical antibiotics are generally approved only for treating bacterial conjunctivitis—but are even more valuable when used off label against bacterial keratitis.

Not only is this permissible, it's good medicine.

"The FDA acknowledges that physicians may prescribe any legally marketed product for an off-label use, as long as it is in the best interest of the patient," according to a position statement made by the Alliance of Specialty Medicine.² "Off-label use is often the standard-of-care in the community. Not using medicines off label could be considered malpractice in many circumstances."

So, why don't drug companies pursue these indications "on label"?

There are several reasons, says

Louis Catania, OD, an innovator in off-label uses of drugs in eye care. Not the least of these is the added costs to the pharmaceutical company to sponsor clinical trials to pursue additional labeling, and the many years required for the FDA approval process.

Thus, off-label drug usage may not only be effective, but more expeditious. Indeed, in the days before optometrists had therapeutic prescribing privileges, Dr. Catania advocated the use of over-the-counter Polysporin ointment for eyelid and conjunctival infections and inflammation—a legal and legitimate therapy.

These days, better treatments are available and ODs have the license to use them. But the FDA approval process is still slow and narrowly focused, and many treatment needs remain unmet. "Thus, it's imperative for practitioners to keep up with the drug literature and research, and to recognize legitimate clinical studies, trials, results and potential off-label uses," Dr. Catania says.

To that end, here are the best off-label applications chosen by some of optometry's therapeutic experts.

Restasis for Uveitis

"As an immunosuppressive agent, cyclosporine has enormous value in all forms of inflammation—well beyond that caused from dry eye," Dr. Catania says.

Specifically, it's a great off-label treatment for uveitis, he suggests.

While Restasis (cyclosporine A 0.05%, Allergan) is known to take weeks (or sometimes months) to be effective in patients with chronic dry eye, that's not the case in patients with an acute inflammatory condition such as uveitis—it works quickly. "The literature is extensive (from as far back as the 1990s) regarding the efficacy and response time of topical and oral cyclosporine (effects within days) vs. steroids (sometimes weeks) for uveitis," Dr. Catania says.³

He points to a recent research poster that showed that topical cyclosporine hastened improvement when used adjunctively in a

small group of patients with recurrent anterior uveitis. “The patients had statistically significant fewer episodes of anterior uveitis, shorter duration of episodes and fewer total days of inflammation per year while on topical cyclosporine A 0.05%,” the authors reported.⁴

Barring contraindications, “any immunomodulator that can begin to reduce the extensive use of topical steroids in eye care should be considered by clinical optometric practitioners as both a primary and adjunctive therapy for most external and uveitis inflammation,” Dr. Catania says.

Start Restasis with the recommended BID dosage, Dr. Catania says. “However, dosages may have to be increased based on the response to BID and/or the severity of the condition.”

Advil for Anterior Uveitis

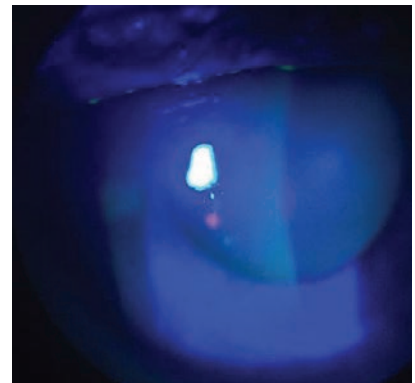

To shorten or eliminate the use of oral or high-dose topical steroids for anterior uveitic inflammation, try oral ibuprofen, Dr. Catania says.

“As an anti-inflammatory, I found its use in dosages as high as 2,400 to 3,000mg/day (given standard contraindications) to be valuable as a substitute for steroids or used as adjunct therapy.”

He adds, “I even found, when used prodromally in certain forms of recurrent uveitis—Fuchs’ being notorious for patients’ prodromal awareness of an acute attack—ibuprofen proved to be effective in reducing the recurrences and/or the intensity of the recurrence.”

Lotemax for Dry Eye

Lotemax gel (loteprednol 0.5%, Bausch + Lomb) is FDA approved for treating inflammation and pain following ocular surgery—but it’s routinely used for a variety of anterior segment inflammatory condi-



This patient presented with recurrent corneal erosion (left). After debridement, he began doxycycline 20mg BID for 2.5 months. He’s been symptom-free ever since (right).

tions, such as allergic conjunctivitis, rosacea, superficial punctate keratitis (SPK), herpes zoster keratitis, iritis, cyclitis and others.

Scott Ensor, OD, MS, who teaches systemic pharmacology at Southern College of Optometry in Memphis, Tenn., says there are two main circumstances when he uses Lotemax for dry eye.

“The first is when there are visible signs of inflammation—when the disease has progressed to the point where there is visible hyperemia and/or SPK, and the usual lubricant drops are much less effective. The anti-inflammatory properties of Lotemax help decrease those signs and hopefully give the patient a feeling of relief,” he says.

In such cases, the dosage depends on the severity of the inflammation, but is usually BID to QID, Dr. Ensor says. Because loteprednol is less likely than other steroids to cause a rise in intraocular pressure, a duration of six months or even longer is usually safe (although he monitors patients’ progress during this time). Also, be sure to measure IOP before treatment to compare it to the post-treatment IOP.

The second circumstance is when starting Restasis. “One of the drawbacks to Restasis treatment is the length of time that it sometimes

takes for the patient to feel relief. This often leads to discontinuation of the medication and the feeling that it didn’t work,” Dr. Ensor says. “A short course of Lotemax to ‘jump start’ the process can give faster relief and encourage the patient to continue the Restasis.”⁵

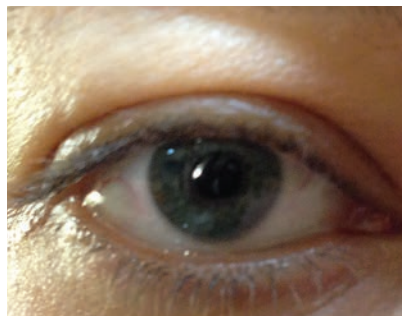
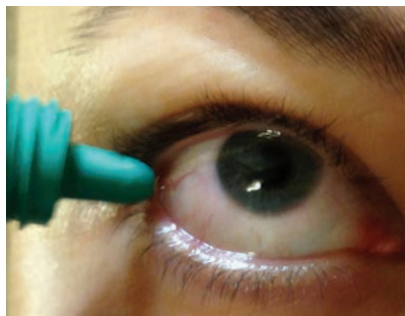Here’s his regimen: Start with Lotemax BID for two weeks, then use both Restasis and Lotemax BID for another two weeks. At that time, stop the Lotemax and continue with the Restasis alone. “I have much more success with Restasis when I follow this plan than when I use Restasis alone,” Dr. Ensor says.⁵

In either case, “patient education and follow-up appointments are essential,” he says. “Many patients are used to the simple artificial tears approach to dry eye treatment, and they don’t understand the difference in getting the corticosteroid,” Dr. Ensor says. “They must return to the office for IOP monitoring and proper discontinuation (i.e., tapering) of the medication.”

Doxycycline for RCE

Riddle: When is an antibiotic not an antibiotic?

Answer: When it’s used in a sub-antimicrobial dose as an anti-inflammatory.



Substitute patients' tetrahydrozoline with a drop of diluted brimonidine to “get the red out.” Diluted brimonidine also improves comfort and won't cause rebound hyperemia.

Indeed, when used in low doses (100mg or less), oral tetracyclines offer several anti-inflammatory benefits—not the least of which is downregulating the proinflammatory matrix metalloproteinases (MMPs).

In ocular surface conditions, notably recurrent corneal erosion (RCE), MMPs break down the epithelial adhesion complexes between the epithelium and the basement membrane, explains Jeffrey Varanelli, OD, who practices at Simone Eye Center in suburban Detroit.

“So, if we can decrease these inflammatory enzymes with doxycycline, then there's the potential for stronger adhesions, less chance of the adhesions breaking down and ideally fewer recurrences of corneal erosions,” he says.⁶

For ophthalmic purposes, “low-dose” oral doxycycline means 20mg or 25mg. If the price of the 20mg tablets is too steep, prescribe the comparatively less expensive 50mg tablet and tell the patient to cut it in half, Dr. Varanelli says.

He uses a four-pronged combination approach for most patients with RCE. First, he debrides the cornea (by instilling tetracaine and then using a blade or cellulose sponge) to remove the damaged epithelium. Then, he applies an amniotic membrane (or a bandage contact lens) to cover the wound

and begin the healing process.

About a week later, when the membrane has dissolved, the patient begins low-dose doxycycline BID as well as a “soft” steroid (Lotemax) for two to three months.

“I had one patient who was symptomatic almost every day. He'd wake up and his eyes would be a little scratchy. And when he came into the office, he'd show early signs of recurrent erosion,” says Dr. Varanelli, who treated the patient with the combination approach. “That was back in March 2014, and he's been symptom-free ever since.”

A Better ‘Get-the-Red-Out’

White eyes look bright and healthy, and that's why people use “get the red out” drops like Visine (tetrahydrozoline, McNeil), says Marc Bloomenstein, OD, director of optometric services at Schwartz Laser Eye Center in Scottsdale, Ariz.

But as optometrists know (and many patients discover), “redness relievers” like tetrahydrozoline are only a short-term solution because they frequently lead to rebound hyperemia.

Instead, Dr. Bloomenstein provides patients with a dilution of the alpha agonist brimonidine to relieve red eyes. “When I have patients who have chronic red eyes, this

drop comes in handy,” he says.

Interestingly, “selective alpha-2 adrenergic receptor agonists, when used at conventional doses of 0.1% or higher, are associated with a number of undesirable side effects, such as rebound hyperemia,” he says. “But the diluted version of this compound does not carry the same effects.”

How was this discovered? “In the late 1990s, we knew that brimonidine was a good vasoconstrictor, and thus it was applied before refractive surgery to reduce subconjunctival hemorrhage and hyperemia,” Dr. Bloomenstein says.⁷

More recently, a study of diluted brimonidine instilled before LASIK reduced subconjunctival hemorrhage and injection, and improved patient comfort after surgery.⁸

For Dr. Bloomenstein's redness reliever, trial and error led to the dilution that offered the best effect. “I use the formula of two drops of brimonidine to every 1ml of low-viscosity tear solution,” he says. “The drop usually lasts about four to six hours, so I tell patients to use it when they feel they need it for the whitening effect.”

While this diluted compound is generally safe for most patients, the best candidates have no signs or symptoms of ocular pathology, he recommends.

Put a Plug in it

Off-label indications apply not only to drugs, but also to devices such as punctal plugs, says Walt Whitley, OD, MBA, director of optometric services at Virginia Eye Consultants in Norfolk, Va.

Like other medical devices, punctal plugs require FDA clearance before being marketed to treat dry eye disease.

But they have additional uses besides dry eye, Dr. Whitley says.

For instance, he uses temporary, collagen punctal plugs to intensify and prolong the effect of medications, particularly in conditions that require a high therapeutic dose. “In acute cases of recurrent corneal erosion, corneal abrasion or corneal ulcer—in which hourly antibiotic doses of topical fluoroquinolone are needed—I’ll insert a temporary plug in the lower tear duct, which evidently increases the medication’s residence time on the corneal surface,” Dr. Whitley says.

Anecdotally, he says, this seems to speed recovery and enhance compliance.

But it’s not just for acute conditions. In a chronic disease such as glaucoma, where compliance with daily drops is essential, punctal occlusion helps to lower IOP just a bit more.⁹

The next step, Dr. Whitley pre-

dicts, are drug-releasing punctal plugs. Some are already in Phase II clinical trials, including a punctal plug for post-cataract surgery that releases dexamethasone and one for glaucoma that provides a sustained dose of travoprost.^{10,11}

Last but not least, a few words of caution from Dr. Varanelli, who lectures frequently on off-label usage: “Make sure the application is a prudent clinical decision that is based on a firm, scientific rationale and sound medical evidence,” he says. “Also, be sure to let the patient know that what you’re prescribing is an off-label indication, and make sure that you document the drug’s use and effects in the chart.” ■

1. Ask the Ethicist: Off-label Meds. EyeNet. 2011 May;15(5):55.
2. Alliance of Specialty Medicine. Physician Directed Applications (Off Label Use): A Position Statement of the Alliance of Specialty Medicine. October 14, 2011; Washington DC. Available at: www.specialtydocs.org/weblev/user_upload/

[Final Alliance offlabel position statement.pdf](#). Accessed January 5, 2015.

3. Kaçmaz RO, Kempen JH, Newcomb C, et al. Cyclosporine for ocular inflammatory diseases. *Ophthalmology*. 2010 Mar;117(3):576-84.
4. Michelotti M, Shtein RM, Prabhu SS, Cooney T. Topical cyclosporine A 0.05% for recurrent anterior uveitis. Poster presented at American Society of Cataract and Refractive Surgery Annual Symposium. April 25, 2014; Boston, MA.
5. Sheppard JD, Donnfeld ED, Holland EJ, et al. Effect of loteprednol etabonate 0.5% on initiation of dry eye treatment with topical cyclosporine 0.05%. *Eye Contact Lens*. 2014 Sep;40(5):289-96.
6. Dursun D, Kim MC, Solomon A, Pflugfelder SC. Treatment of recalcitrant recurrent corneal erosions with inhibitors of matrix metalloproteinase-9, doxycycline and corticosteroids. *Am J Ophthalmol*. 2001 Jul;132(1):8-13.
7. Norden RA. Effect of prophylactic brimonidine on bleeding complications and flap adherence after laser in situ keratomileusis. *J Refract Surg*. 2002 Jul-Aug;18(4):468-71.
8. Pasquali TA, Aufderheide A, Brinton JP, et al. Dilute brimonidine to improve patient comfort and subconjunctival hemorrhage after LASIK. *J Refract Surg*. 2013 Jul;29(7):469-75.
9. Aritürk N, Oge I, Erkan D, et al. The effects of nasolacrimal canal blockage on topical medications for glaucoma. *Acta Ophthalmol Scand*. 1996 Aug;74(4):411-3.
10. Endl MJ, Levenson JH, Walters TR, Majumdar PA. Multi-center evaluation of safety and efficacy of sustained-release dexamethasone after cataract surgery. Paper presented at American Society of Cataract and Refractive Surgery Annual Symposium. April 27, 2014; Boston, MA.
11. ClinicalTrials.gov. Phase 2b study evaluating safety and efficacy of OTX-TP compared to timolol drops in the treatment of subjects with open angle glaucoma or ocular hypertension. Identifier: NCT02312544. Last updated Dec 4, 2014.



SECO2015

Atlanta, GA | March 4-8
WHERE SIGHT MEETS VISION

Attendees on-site can pick up the SECO Daily each morning for the latest news and highlights. Those at home can stay in touch, too—a digital edition of the SECO Daily will be posted online, plus an e-newsletter will be sent out each morning with the day’s top stories.

Show copies will also be available at Review of Optometry booth #507.



THE 2015 SECO SHOW DAILY!

The SECO conference, one of the premier educational events of the year, will take place March 4-8, 2015 — and *Review of Optometry* will be there! *Review's* on-site editorial staff will provide live daily coverage of important show news and events, educational highlights, product launches and more.



Annual Pharmaceutical Issue

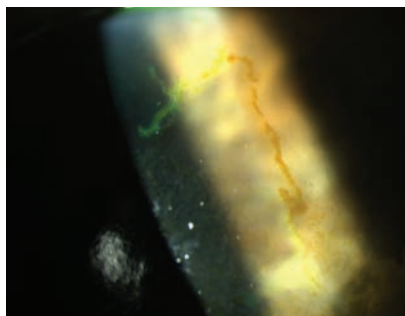
Going Antiviral: How to Bring Herpes to a Halt

Here's a review of the most commonly prescribed topical and oral antiviral medications used to manage herpetic eye disease. **By Michael J. Lyons, OD**

It can be difficult and awkward to talk about herpes. Yet, humans are the only natural host reservoir for both the herpes simplex virus (HSV) and the varicella zoster virus (VZV). Studies have indicated that adults may test as high as 90% for HSV antibodies and 95% for VZV antibodies, suggesting a history of prior infections.^{1,2}

So, maybe instead of being reluctant to talk about herpes, we should think about it and ask patients about it more often.

Viruses are the smallest of infectious pathogens, with the herpes organism ranging from 120nm to 300nm in size. Although tremendously small, viruses demonstrate extraordinary latency and patience.



This patient presented with evidence of herpes zoster keratitis.

Herpes possesses the unique characteristic of incorporating its viral genome into the host's deoxyribonucleic acid (DNA). This process renders the virus undetectable by the human immune system while allowing the host cell to survive.³ Thus,

the viruses can remain dormant for decades before being reactivated by changes in the host's immune system, stress or other environmental factors.

The spectrum of ocular disease that is caused by the herpes family varies widely—from blepharitis at the ocular adnexa all the way to retinitis in the posterior segment. One study published in 1980 indicated that the specific strain of herpes involved, as well as a variety of ancillary host factors, can yield different clinical presentations of herpetic ocular disease.⁴ Because of this, the diagnosis and treatment of ocular herpetic disease becomes a challenge—especially in the case of herpes simplex, when the condition

Release Date: January 2015

Expiration Date: January 1, 2018

Goal Statement: The visual consequence of ocular disease can be painful, devastating and life-long if not treated both promptly and aggressively. The purpose of this article is not to focus on the different presentations of HSV and VZV, but to describe the antiviral medications currently available. It will also offer a glimpse into the future of herpes infection prevention.

Faculty/Editorial Board: Michael J. Lyons, OD

Credit Statement: COPE approval for 2 hours of CE credit is pending for this course. Check with your local state licensing board to see if this counts toward your CE requirement for relicensure.

Joint-Sponsorship Statement: This continuing education course is joint-sponsored by the Pennsylvania College of Optometry.

Disclosure Statement: Dr. Lyons has no relationships to disclose.



does not exhibit traditional findings.

The purpose of this article is not to focus on the different presentations of HSV and VZV, but to describe the antiviral medications currently available. It will also offer a glimpse into the future of herpes infection prevention.

Replication Cycle of Herpes

Opinions vary on whether viruses are actually a form of life. Unlike most living organisms, viruses have no cellular structure or metabolism and are unable to self-replicate. However, they do possess DNA and have the ability to evolve through natural selection, making them more "life-like."⁵

Both simplex and zoster are similar in structure, consisting of a double-stranded DNA surrounded by an icosahedral capsid, with an outer cell membrane containing glycoproteins, carbohydrates and lipids. Because they are acellular, viruses depend on host cells to provide the structure and metabolism necessary for replication.

The primary virus infection starts when it binds to and invades a host cell and then initiates its own DNA replication. After the new viral components are made, the host cell releases new viruses that can infect other host cells. This type of infection produces an acute herpetic outbreak that is usually limited by the response of the host's immune system.⁶

The replication cycle of the herpes virus can be summarized into six stages:

1. Attachment. Using specialized receptors, the viral cell attaches to the host cell.

2. Penetration. The virus enters the host cell.

3. Uncoating. This is the process of the capsid being removed, releasing the DNA into the host cell.

HEDS Gives Prophylactic Treatment a Nod

The HEDS study was a set of multicenter, randomized, placebo-controlled trials sponsored by the National Eye Institute. They were designed to explore some of the questions associated with the treatment of HSV. Findings relative to antiviral treatment included:

- There was no statistically or clinically significant benefit in using oral acyclovir for the treatment of HSV stromal keratitis in patients who received concomitant topical corticosteroids and trifluridine with regard to time to treatment failure, proportion of patients who failed treatment, number of patients who experienced resolution, time to resolution or six-month best-corrected visual acuity.²³
- While the number of patients recruited in this trial was too small to achieve statistically conclusive results, patient outcomes suggest a benefit of oral acyclovir in the treatment of HSV iridocyclitis in those receiving topical corticosteroids and trifluridine prophylaxis.³⁶
- After ocular HSV resolution within one year, 12 months of treatment with oral acyclovir reduces the rate of recurrent ocular and orofacial HSV disease. Long-term antiviral prophylaxis is most important for patients with a history of HSV stromal keratitis, because it can prevent additional episodes and potential loss of vision.^{37,38}

The HEDS illustrated the importance of oral antiviral medications in the treatment of ocular HSV disease. However, the study did not account for individualized treatment considerations and included just 12 months of follow-up data. It is important to note that a separate research team showed that long-term oral acyclovir use seems to effectively decrease the number of ocular HSV recurrences beyond 12 months.³⁹ Thus, it appears that some strains of ocular HSV disease may benefit from long-term, if not life-long, prophylactic treatment.³⁹

4. Replication. The host's DNA is used to facilitate viral DNA proliferation.

5. Assembly. New viruses are formed within the host cell.

6. Release. Viruses exit the host cell and often experience lysis, resulting in cell death.

Additionally, some viruses enter a dormant state and will not immediately proceed through the entire replication cycle. Viral latency can occur within weeks of the primary infection, halting the replication of viral DNA inside the host.⁷ This potential outcome is further characterized by circularization of the viral genome, with only very limited gene expression.⁸ HSV latency usually takes place in the trigeminal ganglion, and VZV latency generally occurs in the sensory spinal or cerebral ganglia.^{6,8}

Treatment Considerations

The development of effective antiviral agents has been much slower than the development of antibacte-

rial drugs. This is attributed to the behavior of the virus following attachment to the host. Viruses are dependent on the host for growth and replication, so once the virus enters the host cell, it becomes part of the cell's metabolism, making it harder to eradicate.

It is important to note that all antiviral medications are at least somewhat toxic to the host cells. The challenge of creating an effective antiviral medication is making it selective for the virus while not disrupting the host cell too significantly. The agent's ability to perform within these parameters ultimately determines the clinical usefulness of the drug. Most of the antiviral drugs available today are antimetabolites, which disrupt DNA synthesis, halt further replication and render the virus incapable of infecting new hosts.⁶

The following antiviral medications are listed below in order of development:

Topical agents:

- **Idoxuridine.** In the early 1950s, idoxuridine became the first available topical antiviral medication. It was initially developed as an anti-cancer drug.⁹

Idoxuridine is a thymidine analog that inhibits DNA polymerases, preventing the incorporation of thymidine into viral DNA.¹⁰ The agent is highly toxic, systemically and topically, due to its unselective pairing with both host and viral DNA.

Today, idoxuridine is available as a 0.1% solution and 0.5% ointment for topical ocular use, and is available through compounding pharmacies. The drug is effective against HSV only.

- **Vidarabine.** Like idoxuridine, vidarabine was initially developed as an anticancer drug in 1960.¹¹ The agent also inhibits viral DNA polymerase, but this is due to its similarity to adenosine. Vidarabine is phosphorylated by both host and viral kinases, but is a more potent inhibitor of viral DNA polymerase than host DNA polymerase.⁶ This makes the agent safe to use systemically, because it is less toxic to the host cell than idoxuridine.

Vidarabine was once available in the US as a 3% ointment (Vira-A, Monarch Pharmaceuticals), but was discontinued. It is still available on a limited basis as a compounded ointment. It is effective against both

HSV and VZV. Vidarabine generally is less potent than other available agents, but is still useful in cases of suspected antiviral resistance.¹⁰

- **Trifluridine.** This thymidine analog also was originally developed as an anticancer agent.¹² Studies have indicated that trifluridine is superior in antiviral efficacy to both idoxuridine and vidarabine, making it the preferred treatment for infectious epithelial keratitis.¹⁰ But, trifluridine is still toxic to the host cells.

The agent is available as a 1% ocular solution (Viroptic, Monarch Pharmaceuticals), and is effective against HSV.

- **Acyclovir.** Unlike the aforementioned antiviral agents, acyclovir is highly selective and thus far less toxic. Its commercial release in 1982 marked a profound shift in the development of future antiviral medications.

Acyclovir is guanosine analog, and like other antiviral agents, it requires phosphorylation in order to become activated. However, acyclovir is only phosphorylated by virus-infected host cells containing viral thymidine kinase, making this significantly more toxic to viruses than the host.¹⁰ Once phosphorylation takes place, it selectively inhibits viral DNA synthesis by binding to DNA polymerase, resulting in chain termination.¹³

Acyclovir is active against both

HSV and VZV. It is available in Canada and Europe as a 3% ointment, but can be compounded at select pharmacies in the US. It also is available as an oral agent.

- **Bromodeoxyuridine.** This agent's mode of action is similar to that of acyclovir. Bromodeoxyuridine is commercially available in Europe, but not in the US. It is important to note that the drug has been shown to cause liver toxicity.¹⁴

- **Ganciclovir.** Initially approved for intravenous treatment of cytomegalovirus retinitis in AIDS patients, ganciclovir is now available as a 0.15% gel (Zirgan, Bausch + Lomb). The agent also selectively inhibits DNA polymerase in only virus-infected cells.

A study published in 1997 showed that ganciclovir gel's therapeutic efficacy was comparable to that of 3% acyclovir ointment, but patients tolerated ganciclovir gel much better.¹⁵

Oral agents:

- **Acyclovir.** As previously noted, acyclovir has become the prototype of antiviral agents due its selective nature against virus-infected cells. It is the most frequently prescribed oral antiviral agent in the United States, and has been commercially available for more than two decades.

It has demonstrated remarkable safety and efficacy against HSV and VZV in both normal and immunocompromised patients.¹⁶ However, the bioavailability of acyclovir is poor, with just 15% to 30% of the oral formulation being absorbed.¹⁷ In order to achieve better serum concentrations, higher doses of oral acyclovir are required.

Acyclovir is available in 200mg capsules and 400mg or 800mg tablets (Zovirax, GlaxoSmithKline). It is also available in a 200mg/5ml suspension.

- **Famciclovir.** Made available

Growing Concerns of Acyclovir Resistance

HSV's ever-increasing resistance to antiviral agents is of fundamental concern to both pharmaceutical researchers and health care providers. Acyclovir resistance has increased with the expanded use of antiviral therapy.

Resistance most commonly occurs in immunocompromised patients with chronic and/or progressive infections who've been subjected to prolonged or repeated courses of therapy.¹⁶ In such patients, an impaired immune system cannot fully suppress viral replication. Hence, the remaining medication load is the only means of antiviral activity.

A study published in 2008 showed that 6.4% of viral isolates found in 173 immunocompromised patients with herpetic keratitis were resistant to acyclovir.³⁴ In general, antiviral resistance should be suspected if the clinical response to therapy is less than that anticipated on the basis of prior experience.³⁵

in 1994, famciclovir is a prodrug of penciclovir. Once famciclovir is absorbed, it is rapidly converted to penciclovir by viral thymidine kinase found in virus-infected cells.

Similar to acyclovir, famciclovir inhibits DNA polymerase by competing with guanosine during viral replication. However, the agent is approximately 100-fold less potent than acyclovir in inhibiting herpes virus DNA polymerase activity.¹⁶ But because of its 65% to 77% bioavailability and long plasma half-life, it remains an effective antiviral agent.³

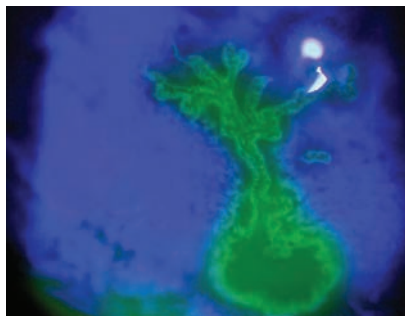
Famciclovir is active against HSV and VZV, and is available in 125mg, 250mg or 500mg tablets.

- **Valacyclovir.** Again, acyclovir's primary weakness is its poor bioavailability. Valacyclovir is a prodrug that converts to acyclovir, which yields the same mechanism of action, antiviral spectrum and resistance profiles as those of its parent drug.¹⁶ Following oral administration, valacyclovir is hydrolyzed by esterases in the gastrointestinal tract and liver, converting to acyclovir. This provides a bioavailability exceeding 50%, which is three to five times greater than that of oral acyclovir.¹⁸ It is available in 500mg and 1,000mg tablets.

Herpes Simplex Virus

HSV is classified as either type 1 (HSV-1) or type 2 (HSV-2). Although HSV-1 usually involves the oropharynx and HSV-2 usually involves the genital area, both types have been shown to infect both areas.¹⁹ For the purpose of this review, we will focus on HSV-1, because it typically is the root cause of associated ocular disease. (An exception is herpes keratitis in neonates, which is caused by HSV-2 in up to 75% of cases.²⁰)

There are an estimated 20,000 new cases of ocular HSV in the United States per year, and more



Fluorescein staining of a herpes simplex keratitis dendrite.

than 48,000 episodes reported annually.²¹ For HSV to cause an ocular infection, it first must enter the body through mucous membranes or the skin. The oral route is the most common pathway, as it provides access to the trigeminal ganglion, which ultimately leads to ocular infection. Interestingly, the primary HSV infection upon viral entry may be asymptomatic, with just 1% to 6% of infected individuals exhibiting clinical manifestations.¹⁰

After entry into the host, and primary infection with viral replication within the oral mucosa, HSV travels in a retrograde fashion to the trigeminal ganglion via the maxillary (V2) or mandibular (V3) branch of the trigeminal nerve (CN V). There, the virus resides in a latent state during the host's lifetime.

During a period of systemic and/or immunologic stress, viral replication starts again in the ganglion, resulting in recurrent disease to the end organ. However, recurrent disease does not have to follow the same path. In the case of ocular disease, for example, HSV travels via the ophthalmic nerve (V1).

Many factors have been implicated in the reactivation of latent HSV, including sunlight exposure, trauma, heat, abnormal body temperature, menstruation, emotional stress and the presence of other infections.¹⁰

Clinical manifestations of HSV include blepharitis, conjunctivitis,

iritidocyclitis and keratitis. HSV keratitis may be classified into following groups and subgroups:¹⁰

I. Infectious epithelial keratitis.

- a. Corneal vesicles.
- b. Dendritic ulcer.
- c. Geographic ulcer.
- d. Marginal ulcer.

II. Neurotrophic keratopathy.

III. Stromal keratitis.

- a. Necrotizing stromal keratitis.
- b. Immune stromal (interstitial) keratitis.

IV. Endotheliitis.

- a. Disciform.
- b. Diffuse.
- c. Linear.

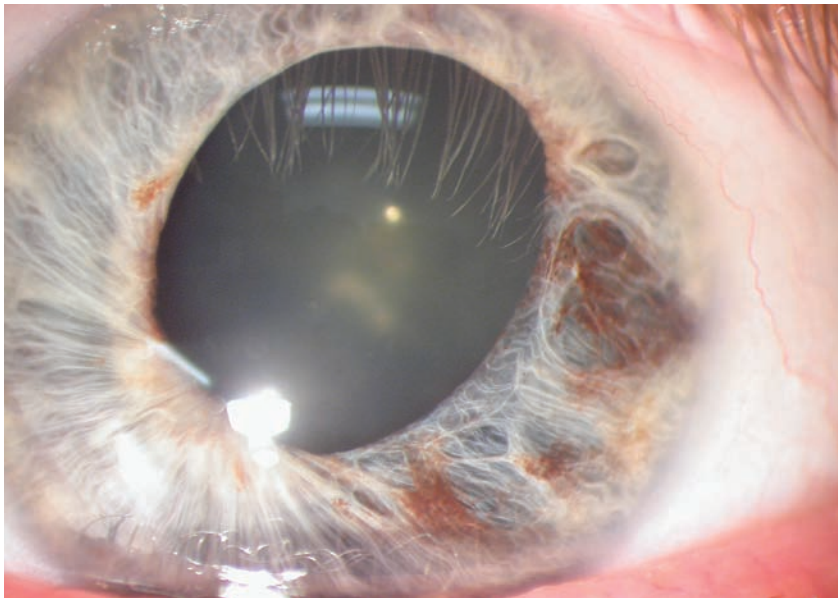
Recurrent HSV Disease

Considering the nature of ocular HSV, recurrent disease is a significant issue that can lead to devastating visual impairment and life-long treatment. In 1989, one research team evaluated 294 episodes of ocular HSV infection and reported recurrence rates of 9.6% at one year, 22.9% at two years and 63.2% at 20 years. After a second episode, 70% to 80% of patients had another recurrence within 10 years.²²

Additionally, the Herpes Eye Disease Study (HEDS) followed 346 patients who were diagnosed with ocular HSV within the previous year. The HEDS researchers documented a recurrence rate of 18% for both epithelial keratitis and stromal keratitis during the 18-month study period (see "HEDS Gives Prophylactic Treatment a Nod," page 61).

Antiviral Dosing and Recommendations

Ocular HSV, especially when recurrent, is a complex condition that doesn't always follow a set of rules. When talking with colleagues from other practices, I have also found that treatment strategies vary widely. An example of this is the use of oral vs. topical antiviral medications



This herpes simplex keratitis patient exhibited diffuse iris atrophy.

in the treatment of HSV epithelial keratitis.

One study, for instance, showed that oral acyclovir may be as effective as topical acyclovir, and thus some practices prefer this approach.²³ However, I believe that as long as you have a consistent plan in place and keep an open mind, you will be successful in disease control.

Topical antiviral dosage recommendations:

- **Idoxuridine**
 - One drop 0.1% solution every hour while awake.
 - Apply 0.5% ointment five times per day.
- **Vidarabine ointment**
 - Apply five times per day until ulcer is resolved.
- **Trifluridine**
 - One drop nine times per day.
- **Acyclovir ointment**
 - Apply five times per day.
- **Bromovinyldeoxyeridine**
 - Not commercially available in United States.
- **Ganciclovir gel**
 - One drop five times per day until ulcer heals, then one drop

three times per day for seven days.

Because herpetic infections heal at different rates, you may need to modify the aforementioned dosing regimens. Also, be sure to discontinue the topical antiviral medication once the ulcer is healed in order to avoid epithelial toxicity.

Oral antiviral dosing recommendations:

- **Acyclovir**
 - Active: 200mg to 400mg five times daily.
 - Suppression: 400mg to 800mg twice daily.
- **Famciclovir**
 - Active: 250mg three times daily.
 - Suppression: 125mg to 250mg twice daily.
- **Valacyclovir**
 - Active: 1,000mg to 3,000mg daily.
 - Suppression: 500mg 1,000mg daily.

Varicella Zoster Virus

As we know, varicella-zoster virus (VZV) causes two distinct clinical

conditions: varicella (chickenpox) and herpes zoster (shingles). It is important to distinguish varicella as the primary infection and herpes zoster as the reactivation of latent VZV within the sensory spinal or cerebral ganglia.

Serological studies indicate that 95% of the population within the United States has evidence of prior VZV infections.² The varicella vaccination was introduced in the United States in 1995. Prior to the vaccination, however, approximately four million cases of VZV infection occurred annually in the US, with the peak age of varicella occurrence at five to nine years.² In fact, before widespread use of the vaccination, more than 90% of American children had been infected with varicella before age 15.² Today, however, the incidence of varicella in the US has since declined by 57% to 90%.⁸

VZV Reactivation

The risk of developing herpes zoster is 10% to 30% in the US.²⁴ Prior to the introduction of the varicella vaccination, the incidence of herpes zoster ranged from 1.2 to 6.5 cases per 1,000 individuals—with approximately 500,000 cases reported annually in the United States.²⁵ Rates are gradually increasing among adults in the United States, but no correlation has been found between its increased incidence and the advent of the varicella vaccination.²⁶

Upon initial infection with varicella, VZV is transported from the vesicular lesions by the sensory axons, where it ultimately enters a state of latency in the dorsal roots or trigeminal ganglia. Reactivation of VZV involves an alteration of the immune system in association with age, trauma and/or neural degeneration.⁸ Once reactivated, the virus replicates within the various ganglia and then travel via axonal transport, resulting in the characteristic unilat-

eral dermatomal eruption of herpes zoster. Cranial nerve involvement occurs in 13% to 20% of all cases, with the trigeminal nerve seen most frequently.²⁷

Currently Available Vaccinations

• **Varivax (Merck)**, a live attenuated vaccine for varicella, received FDA approval in 1995 and was swiftly incorporated into the recommended immunization schedule for children. The vaccine was recommended for any infants, children, adolescents and adults in the US without a history of chickenpox (and without concurrent pregnancy).⁸

After nearly two decades of varicella vaccinations, disease incidence has been reduced by 57% to 90%.²⁸⁻³⁰ Despite these impressive statistics, controversy still surrounds continued use of the vaccine. In 2002, one research team speculated that the use of vaccinations may lead to an increase of adult-onset varicella and a greater incidence of herpes zoster.³¹ The researchers contended that intermittent exposure to those with chickenpox might boost immunity levels to both chickenpox and herpes zoster.³¹

Another research group predicted that there will be an increase in the incidence of herpes zoster over the next five to 40 years, but after that, the overall risk of herpes will decline progressively.³²

• **Zostavax (Merck)** was approved in 2006 as an immunization booster for the prevention of herpes zoster in immunocompetent individuals 60 years and older with no prior history of herpes. It is not indicated in those with prior herpes zoster, because an outbreak naturally boosts the immunity. Zostavax is made of the same modified virus as Varivax, but given at a higher dosage.

The Shingles Prevention Study reported an overall herpes zoster

What to Know About HZO

Herpes zoster ophthalmicus (HZO) results from herpes zoster involvement in the ophthalmic division of the trigeminal nerve, and can cause eyelid edema, conjunctivitis, episcleritis, scleritis, keratitis and uveitis. If vesicles present at the side or tip of the nose (i.e., Hutchinson's sign) the patient's risk of ocular involvement is approximately 50% to 76%.⁹ If Hutchinson's sign is absent, however, the risk decreases to just 34%.⁸

The guidelines listed below are appropriate for short-term treatment of acute herpes zoster ophthalmicus:

- **Acyclovir:** 800mg five times daily for seven to 10 days.
- **Famciclovir:** 250mg three times daily for seven days.
- **Valacyclovir:** 1,000mg three times daily for seven days.

Keep in mind, however, that the complexity of HZO may necessitate the use of both oral and topical antiviral therapy over an extended period.

incidence reduction of 51%, a reduced burden of illness zoster by 61% and a reduced incidence of postherpetic neuralgia by 66%.³³ The duration of the vaccine's protective effect is unknown, and currently there is no recommendation for a booster vaccination.⁸

The presentation of herpetic ocular disease is highly variable—the available antiviral treatment, however, is not. The visual consequence of ocular disease can be painful, devastating and life-long if not treated both promptly and aggressively. The use of antiviral medications plays an important role in disease control.

During the creation of this article, I encountered a monocular patient with a best-corrected visual acuity of 20/200 who manifested extensive ocular surface disease from an old traumatic injury. His chief complaint was a further visual decrease in his only functioning eye. The presentation was far from typical, with severe surface inflammation and corneal edema, but no ulceration or intra-ocular inflammation.

My initial thought was severe stem cell disease with neurotrophic keratopathy—but then I asked myself: “Could it be herpes?”

On follow-up several days later, a disciform appearance evolved and I immediately began antiviral treat-

ment. Once again, I realized I should never forget to consider how common this virus can be. ■

Dr. Lyons is a staff optometrist at the Uveitis and Cornea Clinic at the Cincinnati Eye Institute and a volunteer faculty member at the University of Cincinnati. He's also the founder of Focal Pointe Eye Care, a private, full-service optometric office in West Chester, Ohio.

1. Xu F, Schilling JA, Sternberg MR, et al. Seroprevalence and coinfection with herpes simplex virus type 1 and type 2 in the United States, 1988-1994. *J Infect Dis.* 2002 Apr 15;185(8):1019-24.
2. Straus SE. Overview: the biology of varicella-zoster virus infection. *Ann Neurol.* 1994;35 Suppl:S4-8.
3. Yolton D, Haesaert S. Anti-Infective Drugs. In: Bartlett JD, Jannus SD (eds.). *Clinical Ocular Pharmacology*, 5th ed. Philadelphia: Butterworth-Heinemann; 2008:196-205.
4. Wander AH, Centifanto YM, Kaufman HE. Strain specificity of clinical isolates of herpes simplex virus. *Arch Ophthalmol.* 1980 Aug;98(8):1458-61.
5. Holmes EC. Viral evolution in the genomic age. *PLoS Biol.* 2007 Oct 2;5(10):e278.
6. Yolton DP. Anti-Infective Drugs. In: Bartlett JD, Jannus SD (eds.). *Clinical Ocular Pharmacology*, 3rd ed. Philadelphia: Butterworth-Heinemann; 1995:281-9.
7. Kollias CM. Animal models of herpes simplex virus immunity and pathogenesis. *J Neurovirol.* 2014 Nov 12. [Epub ahead of print]
8. Lee WB, Liesegang TJ. Herpes Zoster Keratitis. In: Krachmer JH, Mannis MJ, Holland EJ (eds.). *Cornea*, 3rd ed. St. Louis: Mosby; 2011:985-1000.
9. Kaufman HE, Rayfield MA. Viral conjunctivitis and keratitis: herpes simplex virus. In: Kaufman H (eds.). *The Cornea*. New York: Churchill Livingstone; 1988.
10. Holland EJ, Schwartz GS, Neff KD. Herpes Simplex Keratitis. In: Krachmer JH, Mannis MJ, Holland EJ (eds.). *Cornea*, 3rd ed. St. Louis: Mosby; 2011:953-84.
11. Sneider W. *Drug discovery: a History*. New York: Wiley; 2005:258.
12. Kaufman HE, Heidelberger C. Therapeutic antiviral action of 5-trifluoromethyl-2'-deoxyuridine. *Science.* 1964 Aug 7;145(3632):585-6.
13. Eilon GB. The biochemistry and mechanism of action of acyclovir. *J Antimicrob Chemother.* 1983 Sep;12 Suppl B:9-17.
14. Liesegang T. Diagnosis and therapy of herpes zoster ophthalmicus. *Ophthalmology.* 1991 Aug;98(8):1216-29.
15. Colin J. Ganciclovir ophthalmic gel (Virgan; 0.15%) in the treatment of herpes simplex keratitis. *Cornea.* 1997 Apr;16(4):393-9.
16. Kimberlin DW, Whitley RJ. Antiviral therapy of HSV-1 and -2. In:

Arvin A, Campadelli-Fiume G, Mocarski E (eds.). *Human Herpesviruses: Biology, Therapy, and Immunoprophylaxis*. Cambridge: Cambridge University Press; 2007:1153-74.

17. Wagstaff AJ, Faulds D, Goa KL. Aciclovir. A reappraisal of its antiviral activity, pharmacokinetic properties and therapeutic efficacy. *Drugs*. 1994 Jan;47(1):153-205.

18. Soul-Lawton J, Seaber E, On N, et al. Absolute bioavailability and metabolic disposition of valaciclovir, the L-valyl ester of acyclovir, following oral administration to humans. *Antimicrob Agents Chemother*. 1995 Dec;39(12):2759-64.

19. Obara Y. Distribution of herpes simplex virus types 1 and 2 genomes in human spinal ganglia studies by PCR and in situ hybridization. *J Med Virol*. 1997 Jun;52(2):136-42.

20. Waggoner-Fountain LA, Grossman LB. Herpes simplex virus. *Pediatr Rev*. 2004 Mar;25(3):86-93.

21. Liesang TJ, Melton J III, Daly PJ, Ilstrup DM. Epidemiology of ocular herpes simplex. *Arch Ophthalmol*. 1989;107:1155-9.

22. Liesang TJ. Epidemiology of ocular herpes simplex. *Arch Ophthalmol*. 1989;107:1160-5.

23. Barron BA. Herpetic eye disease study. A controlled trial of oral acyclovir for herpes simplex stromal keratitis. *Ophthalmology*. 1994

Dec;101(12):1871-82.

24. Liesang TJ. The varicella-zoster virus disease. *Contemp Ophthalmol*. 2006;5:1-7.

25. Jumaan AO, Yu O, Jackson LA. Incidence of herpes zoster, before and after varicella-vaccination-associated decreases in the incidence of varicella, 1992-2002. *J Infect Dis*. 2005 Jun 15;191(12):2002-7.

26. Leung J, Harpaz R, Molinari NA, et al. Herpes zoster incidence among insured persons in the United States, 1993-2006: evaluation of impact of varicella vaccination. *Clin Infect Dis*. 2011 Feb 1;52(3):332-40.

27. Liesegang TJ. Herpes zoster ophthalmicus natural history, risk factors, clinical presentation, and morbidity. *Ophthalmology*. 2008 Feb;115(2 Suppl):S3-12.

28. Zhou F, Harpaz R, Jumaan AO, et al. Impact of varicella vaccination on health care utilization. *JAMA*. 2005 Aug 17;294(7):797-802.

29. Marin M, Meissner HC, Seward JF. Varicella prevention in the United States: a review of successes and challenges. *Pediatrics*. 2008 Sep;122(3):e744-51.

30. Weinmann S, Chun C, Schmid DS, et al. Incidence and clinical characteristics of herpes zoster among children in the varicella vaccine era, 2005-2009. *J Infect Dis*. 2013 Dec 1;208(11):1859-68.

31. Edmunds WJ. The effect of vaccination on the epidemiology of

varicella zoster virus. *J Infect*. 2002 May;44(4):211-9.

32. Quirk M. Varicella vaccination reduces risk of herpes zoster. *Lancet Infect Dis*. 2002 Aug;2(8):454.

33. Oxman MN. A vaccine to prevent herpes zoster and postherpetic neuralgia in older adults. *N Engl J Med*. 2005 Jun 2;352(22):2271-84.

34. Duan R. Acyclovir-resistant corneal HSV-1 isolates from patients with herpetic keratitis. *J Infect Dis*. 2008 Sep 1;198(5):659-63.

35. Kimberlin DW, Crumpacker CS, Straus SE, et al. Antiviral resistance in clinical practice. *Antiviral Res*. 1995 Apr;26(4):423-38.

36. The Herpetic Eye Disease Study Group. A controlled trial of oral acyclovir for iridocyclitis caused by herpes simplex virus. *Arch Ophthalmol*. 1996 Sep;114(9):1065-1072.

37. Herpetic Eye Disease Study Group. Oral acyclovir for herpes simplex virus eye disease: effect on prevention of epithelial keratitis and stromal keratitis. *Arch Ophthalmol*. 2000 Aug;118(8):1030-6.

38. Herpetic Eye Disease Study Group. Acyclovir for the prevention of recurrent herpes simplex virus eye disease. *N Engl J Med*. 1998 May;339(5):300-6.

39. Uchoa UB. Long-term acyclovir use to prevent recurrent ocular herpes simplex virus infection. *Arch Ophthalmol*. 2003 Dec;121(12):1702-4.

OSC QUIZ

You can obtain transcript-quality continuing education credit through the Optometric Study Center. Complete the test form (page 67), and return it with the \$35 fee to: Optometric CE, P.O. Box 488, Canal Street Station, New York, NY 10013. To be eligible, please return the card within one year of publication.

You can also access the test form and submit your answers and payment via credit card at *Review of Optometry* online, www.reviewofoptometry.com.

You must achieve a score of 70 or higher to receive credit. Allow eight to 10 weeks for processing. For each Optometric Study Center course you pass, you earn 2 hours of transcript-quality credit from Pennsylvania College of Optometry and double credit toward the AOA Optometric Recognition Award—Category 1.

Please check with your state licensing board to see if this approval counts toward your CE requirement for relicensure.

1. Common characteristics of VZV and HSV include:

- The ability to remain latent in host nerve cells.
- The ability to produce a variety of ocular conditions.
- The ability to produce recurrent ocular disease.
- All of the above.

2. Ocular herpes infections can present in many different fashions; however, the clinical manifestation generally is determined by:

- The nature of the host.
- The nature of the virus.
- The time of year.
- Both a and b.

3. Herpes viruses:

- Have the ability to self-reproduce.
- Possess unique cells for their metabolism.
- Are independent of host cells.
- Possess DNA.

4. What is the correct order of the herpetic life cycle?

- Attachment, assembly, release, uncoating, penetration and replication.
- Uncoating, replication, release, attachment, penetration and assembly.
- Attachment, penetration, uncoating, replication, assembly and release.
- Penetration, uncoating, replication, release, assembly and attachment.

5. Which cranial nerve is most frequently associated with reactivation of herpes simplex?

- Optic.
- Trigeminal.
- Oculomotor.
- Trochlear.

6. Which statement is true with regard to the development of antiviral medications?

- Antivirals are difficult to develop due to the virus' ability to become part of the host cell's metabolism.
- There have been many more antiviral medications developed than antibacterial medications.
- Antiviral medications typically disrupt the penetration of the virus into the host cells.
- The most favorable antiviral medications are those that are non-selective against the viral and host cells.

7. What statement about antiviral medications is true?

- All antiviral medications are commercially available in the US.
- All antiviral medications yield some toxicity on the host cells.
- All antiviral medications are effective against HSV and VZV.
- All antiviral medications are clinically effective as either topical or oral formulations.

8. What is the primary factor that determines the success of an antiviral medication?

- Its potency.
- Its half-life.
- Its ability to inhibit the virus while preserving the host cells.
- The ability to inhibit both HSV and VZV.

9. What was the first antiviral medication developed?

- Acyclovir.
- Idoxuridine.
- Bromovinyldeoxyuridine.
- Vidarabine.

10. Many of the early antiviral medications were originally designed to be:

- Anticancer drugs.
- Antibiotic drugs.
- Antifungal drugs.
- Antiemetic drugs.

11. Most antiviral medications work by:

- Inhibiting viral DNA replication.
- Inhibiting host DNA replication.
- Lysing host cells that contain viral DNA.
- Preventing attachment of viral cells to host cells.

12. Which topical antiviral medication is known to cause significant liver toxicity?

- Idoxuridine.
- Vidarabine.
- Trifluridine.
- Bromodeoxyuridine.

13. Valacyclovir is a prodrug of:

- Acyclovir.
- Penciclovir.
- Famciclovir.
- Ganciclovir.

14. Most herpetic ocular infections are caused by:

- HSV-1.
- HSV-2.
- Cytomegalovirus.
- Epstein-Barr virus.

OSC QUIZ

15. How many new cases of ocular HSV are reported in the United States each year?
 a. 5,000.
 b. 10,000.
 c. 20,000.
 d. 40,000.

16. Since the development of the varicella vaccination in 1995:
 a. There has been a reduction in the number of zoster outbreaks.
 b. There has been an increase in the number of hospitalizations due to severe outbreaks of varicella.
 c. There has been no statistical difference in the number of varicella outbreaks.
 d. Varicella incidence has been significantly reduced.

17. The development Zostavax (Merck) has resulted in:
 a. An increase in postherpetic neuralgia.
 b. A reduction in the incidence and severity of herpes zoster.
 c. Multiple boosters needed to maintain the protective effect of the vaccination.
 d. An increase in the reported cases of varicella.

18. The Herpetic Eye Disease Study (HEDS) showed that:
 a. Oral acyclovir is probably beneficial in the treatment of iridocyclitis.
 b. Oral acyclovir dramatically enhances the recovery from HSV stromal keratitis when used with topical corticosteroids and trifluridine.
 c. Use of oral acyclovir for 12 months does not reduce the number of recurrent HSV episodes.
 d. Oral valacyclovir was far superior to acyclovir in treatment of HSV disease.

19. What clinical presentation suggests a patient with herpes zoster likely will experience ocular involvement?
 a. Liesegang rings.
 b. Vortex keratopathy.
 c. Hutchinson's sign.
 d. Von Graefe's sign.

20. What is the recommended dosage for the treatment of herpes zoster ophthalmicus (HZO)?
 a. Valtrex 500mg QD.
 b. Valtrex 1,000mg QD.
 c. Valtrex 500mg TID.
 d. Valtrex 1,000mg TID.



TAKE THE TEST ONLINE TODAY!
[www.reviewofoptometry.com/
 continuing_education/](http://www.reviewofoptometry.com/continuing_education/)

Examination Answer Sheet

Valid for credit through January 1, 2018

This exam can be taken online at www.revoptom.com/continuing_education. Upon passing the exam, you can view your results immediately and download a real-time CE certificate. You can also view your test history at any time from the website.

Going Antiviral: How to Bring Herpes to a Halt

Directions: Select one answer for each question in the exam and completely darken the appropriate circle. A minimum score of 70% is required to earn credit.

Mail to: Jobson - Optometric CE, PO Box 488, Canal Street Station, New York, NY 10013

Payment: Remit \$35 with this exam. Make check payable to Jobson Medical Information LLC.

COPE approval for 2 hours of CE credit is pending for this course.

This course is joint-sponsored by the Pennsylvania College of Optometry

There is an eight-to-ten week processing time for this exam.

1 = Excellent 2 = Very Good 3 = Good 4 = Fair 5 = Poor

1. (A) (B) (C) (D)
2. (A) (B) (C) (D)
3. (A) (B) (C) (D)
4. (A) (B) (C) (D)
5. (A) (B) (C) (D)
6. (A) (B) (C) (D)
7. (A) (B) (C) (D)
8. (A) (B) (C) (D)
9. (A) (B) (C) (D)
10. (A) (B) (C) (D)
11. (A) (B) (C) (D)
12. (A) (B) (C) (D)
13. (A) (B) (C) (D)
14. (A) (B) (C) (D)
15. (A) (B) (C) (D)
16. (A) (B) (C) (D)
17. (A) (B) (C) (D)
18. (A) (B) (C) (D)
19. (A) (B) (C) (D)
20. (A) (B) (C) (D)

Rate the effectiveness of how well the activity:

21. Met the goal statement: (1) (2) (3) (4) (5)
22. Related to your practice needs: (1) (2) (3) (4) (5)
23. Will help you improve patient care: (1) (2) (3) (4) (5)
24. Avoided commercial bias/influence: (1) (2) (3) (4) (5)
25. How would you rate the overall quality of the material presented? (1) (2) (3) (4) (5)
26. Your knowledge of the subject was increased:
 Greatly Somewhat Little
27. The difficulty of the course was:
 Complex Appropriate Basic

How long did it take to complete this course?

Comments on this course:

Suggested topics for future CE articles:

Please retain a copy for your records. Please print clearly.

First Name _____

Last Name _____

E-Mail _____

The following is your: Home Address Business Address

Business Name _____

Address _____

City _____ State _____

ZIP _____

Telephone # _____ - _____ - _____

Fax # _____ - _____ - _____

By submitting this answer sheet, I certify that I have read the lesson in its entirety and completed the self-assessment exam personally based on the material presented. I have not obtained the answers to this exam by any fraudulent or improper means.

Signature _____ Date _____

Lesson 110890

RO-OSC-0115

Practical Pearls for Managing Anterior Uveitis

When diagnosing uveitis, let the history and signs guide your treatment plan.

By Kyle D. Dohm, OD

The uvea, a highly vascularized section of the eye located beneath the sclera, supplies most of the ocular structures with nutrients via the anterior and posterior branches of the ophthalmic artery.

The uvea consists of the iris, ciliary body and choroid. The iris controls how much light enters the eye, while the ciliary body produces aqueous humor and controls its outflow by contracting and widening the trabecular meshwork. The ciliary body also controls accommodation by contracting and relaxing.

The third element, the choroid, is a highly vascularized and pigmented tissue that provides nourishment to the outer retinal layers and absorbs excess light. Inflammation of any of these structures is known as uveitis.

One synonym of uveitis is *iritis*, and although iritis is more technically and anatomically specific, clinicians often use the terms inter-

changeably. The most common form of this disease is nongranulomatous anterior uveitis, which can present as unilateral or bilateral; chronic or acute; and idiopathic, infectious, immunological or neoplastic.

Classic symptoms include redness, photophobia and pain often described as dull ache; however, with chronic forms of the disease, these symptoms may be completely absent. Often, a sufficient medical and ocular history can reveal the precipitating cause, although even laboratory testing cannot uncover the underlying etiology in every instance.

Regardless, it is important to properly classify the uveitis in order to correctly diagnose and treat the patient, thus eliminating the potential for further complications, including blindness. This article will review typical signs and symptoms of anterior uveitis, as well as discuss essential treatment considerations.

Disease Classification, Workup and Diagnosis

When diagnosing anterior uveitis, you must consider a variety of presenting signs and associated features. As previously noted, characteristic symptoms include pain in the form of a dull ache, redness and photophobia. Visually, the customary ciliary flush (circumlimbal flush) is often seen and the pupil may be mid-dilated. For an official diagnosis, however, cells must be seen in the anterior chamber, and flare may or may not be present. It is important to note that flare sometimes can be seen in the anterior chamber when no active inflammation is present, because long-standing, chronic uveitis damages the vasculature integrity of the iris and ciliary body.¹

To properly diagnose and manage uveitis, you must first categorize it. Anterior inflammation confined to the iris and anterior chamber is termed iritis. When the inflammation also involves the

ciliary body, as evidenced by the presence of anterior vitreous cells, it is called *iridocyclitis*. However, when only the ciliary body is inflamed, it is simply called *cyclitis* (although this is not usually a clinically significant term). Intermediate uveitis, or pars planitis, involves inflammation of the pars plana, the middle portion of the ciliary body. Aggregates of white blood cells, or snowball opacities, accumulated near the inferior retina are typically seen in pars planitis.¹

Posterior uveitis involves inflammation in the posterior segment, including the retina, choroid, vitreous and sometimes sclera, while pan-uveitis involves all structures of the uvea in addition to adjacent tissues. It should be noted the further posterior the uveitis proceeds in the eye, the greater the risk of associated systemic disease, the more difficult it will be to treat, and the greater the risk of complications. In any case, the difference between the specific semantics helps the doctor with clinical diagnosis and directs attention to the appropriate areas of concern.

A “name meshing” strategy (see “*Name Meshing System for Uveitis Diagnosis*,” below) is one tool that can be used to focus clinical thought and provide a tailored, cost-effective evaluation and management of the patient’s disease.²⁻⁴ The uveitic entity should be broken down by its location, duration, pathology and laterality.¹⁻⁴

In reference to ocular inflamma-



Fig. 1. Small, resolving mutton-fat keratic precipitate (KP) in granulomatous uveitis.

tion, “granulomatous” typically refers to a more severe form of uveitis, with distinctive features like iris granulomas, Koepe nodules on the pupillary margin, Busacca nodules in the iris stroma and keratic precipitates (KPs) on the corneal endothelium that are large, globular and greasy, known as mutton-fat KPs (figure 1).^{1-3,5} A hypopyon may form in the anterior chamber if the inflammation goes unchecked.

Common granulomatous uveitides include tuberculosis, sarcoidosis and Lyme disease.² Nongranulomatous ocular inflammation, on the other hand, is less severe and is characterized by smaller KPs (figure 2), fewer (if any) nodules and decreased probability of synechiae formation (figures 3 and 4).^{2,3} Overall, granulomatous uveitis is more likely to be associated with systemic disease and more difficult to treat with greater risk for complications than nongranulomatous uveitis.

Frequently, a specific ocular history—in conjunction with a careful slit lamp examination—can lead to

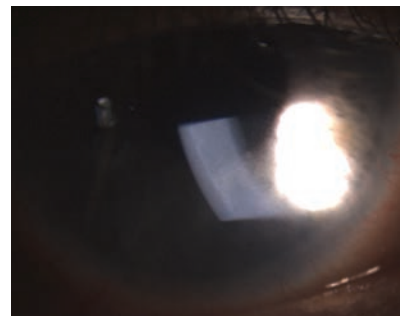


Fig. 2. Fine KPs on the endothelium in non-granulomatous uveitis.

the correct etiology of the uveitis without any further testing or laboratory studies. (See “*Derivation of Uveitis Etiology from Ocular History*,” page 60).¹

The “Nine I system,” which categorizes inflammation of ocular tissues into a specific heading, is another useful classification instrument (see “*The Nine ‘I’ System*,” page 62) Any of the nine “I’s” can be the root cause of uveitis, with up to 38% of the cases being idiopathic.⁶

Bloody Cues

Acute nongranulomatous uveitis can be associated with the human leukocyte antigen B27 (HLA-B27). Additional entities that can be linked to HLA-B27 include Reiter syndrome, inflammatory bowel disease (i.e., ulcerative colitis or Crohn’s disease), ankylosing spondylitis, Behçet disease and psoriatic arthritis.^{1,6,7} These entities are usually anterior and unilateral. Other acute nongranulomatous uveitides include Lyme disease and trauma. Common chronic nongranulomatous entities include juvenile rheumatoid arthritis and Fuchs’ heterochromic iridocyclitis.^{3,4,6}

Chronic uveitis is usually less symptomatic than acute presentations. Although syphilis is typically lumped into chronic granulomatous uveitis along with sarcoidosis and

Table 1. Name Meshing System for Uveitis Diagnosis

LOCATION	DURATION	PATHOLOGY	LATERALITY
Anterior	Acute	Granulomatous	Unilateral
Posterior	Chronic	Nongranulomatous	Bilateral
Intermediate	Recurrent		
Pan			

tuberculosis, it can present in any of the categories as a masquerader.^{4,6}

Posterior uveitides include tuberculosis, toxoplasmosis, histoplasmosis, sarcoidosis and herpes—although herpes is often anterior as well.^{3,6} Although usually posterior, any form of posterior uveitis can rarely present anteriorly. An entity that may be miscategorized as idiopathic anterior uveitis is glaucomatocyclitic crisis (i.e., Posner-Schlossman syndrome).¹ This is classically a white eye with a mild anterior chamber reaction and highly elevated IOP (30mm Hg to 60mm Hg). It tends to be unilateral, recurrent and relatively asymptomatic.^{1,5}

Blood studies often must be ordered in cases where the history and physical examination do not lead to a definitive diagnosis—especially in the presence of bilateral, granulomatous or recurrent uveitis.⁶ The “shotgun” approach is costly, nonspecific and can easily be avoided with astute clinical skills.

Here are some of the most common laboratory tests used to help localize the etiology of uveitis:⁶⁻⁸

- **Complete blood count (CBC)** with differential helps to determine the patient’s general health status, and can aid in diagnosing a variety of disorders, such as anemia, infection and leukemia.

- **C-reactive protein (CRP)** is a marker for inflammation and serves as a treatment response monitor.^{2,4} CPR tests are unable to determine the cause or location of the inflammation within the body, however.

- **Erythrocyte sedimentation rate (ESR)** is typically ordered in conjunction with a CRP test. An ESR helps detect inflammation and serves as a monitor for the underlying etiology.

- **Antinuclear antibody (ANA)** testing screens for certain autoimmune disorders like systemic lupus erythematosus, scleroderma, juvenile arthritis, polymyositis, inflammatory bowel disease and psoriasis.

- **Rheumatoid factor (RF)** testing can help you diagnose rheumatoid arthritis and Sjögren’s syndrome, among others that sometimes overlap with ANA testing.

- **Rapid plasma regain (RPR), venereal disease research laboratory (VDRL) and fluorescent treponemal antibody absorption test (FTA-ABS)** are used to screen for syphilis. The FTA-ABS is a 24-hour test used to detect antibodies to the bacteria *Treponema pallidum* and confirm the presence of syphilis. FTA-ABS does not indicate if the disease is active or inactive, however, and is typically administered after a screening test for active disease, RPR or VDRL. Other trepo-

nemal tests are available, such as microhemagglutination-*Treponema pallidum* (MHA-TP), *Treponema pallidum* particle agglutination assay (TP-PA) and *Treponema pallidum* hemagglutination assay (TPHA), but are not as commonly known in the eye care communities as FTA-ABS.

Both RPR and VDRL typically register positive in primary and secondary syphilis and negative in tertiary (latent) syphilis and after successful treatment of the disease.⁴ RPR is commonly chosen over VDRL because it is both easier to administer and less expensive. False positives can occur, however, with both tests. Entities that may disrupt the accuracy of the results include but are not limited to tuberculosis, malaria, lymphoma, lupus, Lyme disease, viral infections, connective tissue diseases, IV drug use and pregnancy.

- **Angiotensin-converting enzyme (ACE)** supports a sarcoidosis diagnosis and helps to monitor disease activity during treatment. A serum lysozyme test can also be used to test for sarcoidosis.

- **Chest X-ray (CXR)** or computed tomography (CT) scan is also helpful when investigating for tuberculosis or sarcoid nodules in the lungs.⁶ Normally, when I order a CXR to rule out sarcoid, I will

Table 2. Derivation of Uveitis Etiology from Ocular History^{1,3}

	Onset	Course	Symptoms	Treatment
Ocular History	Past occurrences	Trauma	Surgery	Past treatments
Medical History	Illnesses	Medications		
Social History	Drug use	Sexual history	Dietary habits	
Family History	Maternal infections	Contagious diseases	History of uveitis	Illnesses
Geographic History	Birthplace	Foreign travel	Other locations (i.e., Ohio)	
Demographic History	Age	Gender	Race	
Review of Systems	General, Derm, Rheum, Neuro, Resp, GI, GU, Musc-skel			

request posterior-anterior and lateral (PA/LAT) images. In any case, it is important to annotate what you are looking for (i.e., rule out sarcoid nodules in setting of bilateral uveitis) to help direct the radiologist in his or her examination. In a hospital setting, it is also paramount when ordering these tests to engage the patient's primary care physician (PCP) or appropriate specialist if abnormalities are found.

For eye doctors who do not have access to labs or imaging, sending the patient to his or her PCP with exact recommendations of what tests to order and why will aid in expediency for the patient and help guide the PCP who relies on your expertise for ophthalmic conditions.

- **Human leukocyte antigen B27 (HLA-B27)** is found on the surface of white blood cells and is associated with a number of autoimmune disorders, such as ankylosing spondylitis and Reiter syndrome. It is not necessarily a specific marker for any one disease, however, and can actually be the singular determining factor in some iritis cases.⁴

- **Purified protein derivative (PPD)** tests for latent tuberculosis.

- **Lyme titre and enzyme-linked immunosorbent assay (ELISA)**, together with anti-*Borrelia burgdorferi* immunoglobulins M and G (IgM/IgG), are used to detect the presence of Lyme disease. ELISA also can be used to detect HIV, as can the Western Blot test.^{2,7}

Other uncommon tests for uveitis that may have relevance in certain patient presentations include a Sjögren's antibody (SS-A, SS-B) profile, urinalysis and a search for viral entities like cytomegalovirus (CMV) IgG/IgM antibodies. Recall from immunology that IgG represents past exposure or immunity to a disease, and IgM represents recent exposure or likely active infection.

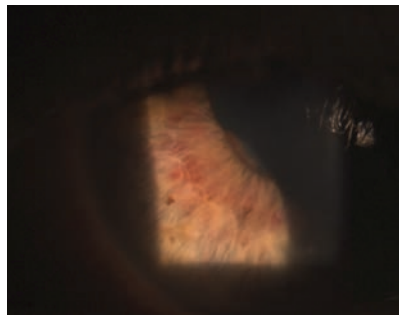


Fig. 3. Area of posterior synechia (iris adhered to lens), with dilated stromal iris vasculature.

Management of Non-Traumatic Uveitis

First episodes of mild, unilateral iritis are often idiopathic and associated with a viral or sinus infection, or traumatic event. Further diagnostic testing usually can be curbed, because observation and treatment of symptoms is typically sufficient in these low-risk cases.² Depending on the severity of inflammation with a traumatic iritis case, anti-inflammatory medicines sometimes can be withheld. However, sound clinical judgment must be exercised when determining if and when medication use is necessary.

For any therapeutic endeavor, a specific treatment goal is key. Obviously, increasing patient comfort is paramount in uveitis care. The fundamental purpose in uveitis management hinges on reducing inflammation, thus decreasing morbidity and the likelihood of other, more serious complications, such as vision loss and glaucoma.

In light of these goals, four main objectives should be considered when treating an iritis patient:

- Decrease pain.
- Prevent posterior synechiae and thus pupillary block.
- Prevent peripheral anterior synechiae (PAS) and thus angle closure.
- Re-establish the blood-aqueous barrier.

Atropine and other similar cycloplegics/mydriatics play an integral role in all four objectives.⁴ Cycloplegic agents act on the vasculature to help stabilize the blood-aqueous barrier, preventing further leakage. By immobilizing the iris, along with their action in ciliary muscle paresis, cycloplegics not only help with pain control, but their dilating effect is equally important in thwarting angle closure and pupillary block by averting iris to lens adhesion. Corticosteroids (usually topical for most cases of anterior uveitis) reduce the body's inflammatory response and are a mainstay in iritis care. They also help reduce capillary permeability and vasodilation.^{4,7,13}

Other therapeutic options include nonsteroidal anti-inflammatory drugs (NSAIDs), immunosuppressive/immunomodulatory agents and surgical options (e.g., laser peripheral iridotomy or periorcular implant).^{2,3,9,12} Corticosteroid use in uveitis normally needs to be tapered in order to prevent rebound inflammation.

Early, frequent steroidal administration classically is prescribed to guarantee a suitable loading dose in order to aggressively quell the inflammation. Tapering appropriately, according to clinical response, ensures the proper remission of the uveitis without a rebound of inflammation.³ However, if a steroid is prescribed in traumatic uveitis, it is generally over a brief time period, eliminating the necessity of medication tapering—especially since the inflammatory stimulus (trauma) is gone.

Increased IOP and posterior subcapsular cataract (PSC) are two primary concerns associated with corticosteroid use; however, these complications are not routinely seen following short-term use. Likewise,

Table 3. The Nine ‘I’ System²

Inflammatory	Autoimmune diseases
Infectious	Known pathogens
Infiltrative	Neoplastic processes
Injurious	Trauma
Iatrogenic	Surgery, medications and accidental trauma
Inherited	Metabolic and dystrophic diseases
Ischemic	Impaired circulation
Involitional	Age-related
Idiopathic	Unknown

increased IOP with concurrent corticosteroid use does not always mean that the steroid is the cause of the elevation. In uveitis, IOP generally is lower than normal—although in some cases, it can be higher than normal, depending on when in the disease process the patient presents for care.^{1,4,11} Two possible reasons for decreased IOP include:^{1,4}

- An increase in the release of endogenous prostaglandins augments uveoscleral outflow.
- A decrease in aqueous humor production by the inflamed ciliary body.^{1,4}

Potential explanations for increased IOP include:

- Clogging of the trabecular meshwork with inflammatory cells and protein.
- Trabeculitis, or inflamed, swollen meshwork fibers.
- Posterior synechiae.
- Peripheral anterior synechiae.
- Steroid-induced IOP elevation.
- The fact that the “sick” eye is returning to normal.

An IOP rise can occur during the corticosteroid treatment period, but it is not always secondary to the side effects of the corticosteroid itself. As such, the term “steroid-responder” is sometimes wrongly attributed to the healing eye’s normalization of aqueous production

before the trabecular meshwork has totally phagocytized the white blood cells and fibrinous protein remnants from the drainage angle.⁴ Prematurely stopping the steroid treatment prior to complete inflammatory resolution may, in fact, do more harm than good; instead, the steroid treatment should be maintained and an IOP-lowering medication (i.e., aqueous suppressant), such as a beta-blocker or carbonic anhydrase inhibitor, should be added.

It is important to note prostaglandin analogs and miotics should be avoided in uveitis, because they may increase inflammation.^{8,10-12} Miotics also increase the risk of posterior synechiae formation.¹ Adrenergic agonists, such as brimonidine and apraclonidine, generally are safe to use in uveitis patients with increased IOP.

When dealing with anterior uveitis, the exact dosing schedule is more art than science, as each case can present differently and slightly nuanced strategies can produce similar, positive results. One typical treatment protocol includes the administration of one drop of prednisolone acetate 1.0% every hour for two to three days, or until mild cells (< grade 2) are seen. Then, planned tapering of the steroid can be accomplished by continually cut-

ting the administration frequency in half every third day.

For milder presentations, loteprednol etabonate gel 0.5% administered at a less frequent dosing schedule might be best. For more severe or recalcitrant cases, however, difluprednate ophthalmic emulsion 0.05% QID or Q2H may be appropriate. Some patients may even require oral corticosteroids; a common choice is prednisone, which usually is dosed between 20mg to 40mg at a frequency of BID to QID for several days. When prescribing oral corticosteroids, take note of any systemic illnesses, as well as other medications that the patient is using, in case of side effects or interactions between the different medicines.

As such, you may want to consult with the patient’s PCP prior to prescribing oral corticosteroids. Consideration also should be given to prescribing an antihistamine that acts to inhibit stomach acid production, such as ranitidine (Zantac, GlaxoSmithKline), in order to prevent gastrointestinal upset. At the very least, ensure the patient takes the oral corticosteroid with some food or milk.

As previously mentioned, cycloplegics, such as homatropine 5.0% or atropine 1.0%, are necessary for proper uveitis management. A common approach may include one drop of homatropine 5% TID for three days, BID for two days and QD for one day; however, an extended period over several weeks may need to be employed for more severe cases. Remember, because the eye is inflamed, a dosing strategy that is greater than the half-life of the medication will be needed. This is because the medicine is being metabolized at a much faster rate in a sick eye. Depending on severity, the patient should return

for a follow-up visit in two to five days initially, then as needed.

Management of Traumatic Uveitis

The frequency of uveitis in the United States matches international numbers at approximately 15 cases per 100,000 persons.^{6,7} Trauma is the third most common cause of anterior uveitis.^{6,7} Morbidity generally results from symptoms, posterior synechiae, cystoid macular edema, increased IOP with resultant glaucoma, cataract formation and retinopathy.^{4,6,9} Other complications associated with traumatic iritis include hyphema, iridodialysis, iridoschisis, lens dislocation and/or opacification, commotio retinae, optic neuropathy, posterior vitreous detachment, retinal tears and detachments, choroidal rupture, corneal edema and angle recession.^{5,9-11}

Hyphema, if present, is a serious condition requiring close monitoring. Patients are typically confined to bed rest with limited activity, where their head should be elevated at least 30° and a shield placed over the eye for enhanced protection. Patients should avoid aspirin, but can take acetaminophen for pain as needed.

Atropine 1.0% should be instilled QD to TID and prednisolone acetate 1.0% dosed Q2H to QID. Oral aminocaproic acid, an antifibrinolytic, also should be administered, depending on the size of the hyphema.¹⁰⁻¹²

Laboratory studies also should be considered for hyphema cases. Typical labs ordered include complete blood count (CBC) with differential, prothrombin time (PT), partial thromboplastin time (PTT), blood urea nitrogen (BUN), creatinine, electrolytes, sickle prep and hemoglobin studies. IOP



Fig. 4. Posterior synechia partly broken after instillation of phenylephrine 10% and atropine 1%.

medications (i.e., beta-blockers) also should be instituted if IOP is elevated significantly. Prostaglandins and miotics should be avoided, because they can add to the inflammatory effect.^{8,10-12}

Angle recession is noted if there is an uneven iris insertion posteriorly, allowing a larger-than-normal band of ciliary body to be seen.⁸ This can be confirmed if the contralateral eye's gonioscopic findings are normal. Angle recession does not always occur with blunt trauma, and—if present—does not always produce an elevated IOP at onset. However, microscopic damage to the trabecular meshwork endothelial cells is possible, with resultant IOP increase years after the initial trauma.^{8,10} Regular eye examinations are needed to monitor these patients for future complications.

Uveitis may present concurrently with other morbidities. Therefore, it is prudent to be thorough when examining a patient with anterior segment inflammation. A methodical case history often can pinpoint the cause of the inflammation. Additionally, knowing what to look for during the slit lamp evaluation is imperative, so proper management and further diagnostic testing, if needed, can be instituted

in an expedited manner.

Iritis can range from mild to severe, with vision loss and even blindness occurring if left untreated. Most cases of iritis that present to the primary eye doctor are localized anteriorly, mild to moderate in severity and relatively simple to manage. The prognosis generally is favorable with appropriate treatment and follow-up regimens; the pillars for proper management remain corticosteroids and cycloplegics. Bilateral and recurrent cases may need further investigation into the etiology. Overall, it is vital to educate patients about symptoms and the importance of future periodic eye examinations to monitor for complications. ■

Dr. Dohm is the department head of optometry and the associate director for medical services at Naval Hospital Oak Harbor on Naval Air Station Whidbey Island in Oak Harbor, Wash. He has no direct financial interests in any of the products mentioned.

1. Yanoff M, Duker JS (eds.). Ophthalmology, 2nd ed. St. Louis: Mosby; 2004.
2. Medscape. Uveitis Classification. Available at: <http://emedicine.medscape.com/article/1208936-overview>. Accessed November 8, 2012.
3. Smith RE, Nozik RM. Uveitis: A Clinical Approach to Diagnosis and Management. Baltimore: Williams & Wilkins; 1983.
4. Harkins TJ. Personal communication. Kansas City Veterans Administration Medical Center; Kansas City, MO. Aug-Dec 2005.
5. Gold DH. Clinical Eye Atlas. Chicago: AMA Press; 2002.
6. Medscape. Iritis and Uveitis. Available at: <http://emedicine.medscape.com/article/798323-overview>. Accessed November 10, 2012.
7. Medscape. Uveitis evaluation and treatment. Available at: <http://emedicine.medscape.com/article/1209123-overview>. Accessed November 10, 2012.
8. Kunimoto DY. The Wills Eye Manual: Office and Emergency Room Diagnosis and Treatment of Eye Disease, 4th ed. Philadelphia: Lippincott Williams & Wilkins; 2004.
9. Kanski JJ. Clinical Ophthalmology: A Systematic Approach, 5th ed. London: Butterworth Heinemann; 2003.
10. Shingleton BJ, Hersh PS, Kenyon KR (eds.). Eye Trauma. St. Louis: Mosby; 1991.
11. Keil J, Chen S. Contusion injuries and their ocular effects. Clin Exp Optom 2001;84(1):19-25.
12. Kaiser PK, Friedman NJ, Pineda R. The Massachusetts Eye and Ear Infirmary Illustrated Manual of Ophthalmology, 2nd ed. Philadelphia: Saunders; 2004.
13. Pavan-Langston D. Manual of Ocular Diagnosis and Therapy, 4th ed. Boston: Little, Brown and Company; 1996.



Go Further—Without Leaving Home



Expand your clinical skills and catch up on your CE requirements, all from the comfort of your own home.

Review offers **nearly 100 hours** of COPE-approved continuing education — right now! It's **just a click away**. Our extensive library of exams runs the gamut from keratoconus to fundus autofluorescence, and everything in between.



www.reviewofoptometry.com/continuing_education

Download a QR scanner app. Launch app and hold your mobile device over the code to view www.reviewofoptometry.com/continuing_education.

REVIEW[®]
OF OPTOMETRY



New Year, New Connections

2015 will be a year full of changes, particularly in medical coding and compliance. We're starting on this very page. **By John Rumpakis, OD, MBA, Clinical Coding Editor**

The New Year has always been associated with change—and 2015 is going to be one filled with it. The area of medical coding and compliance is always subject to changes that are difficult to understand, let alone apply to clinical management in your practices.

Review of Optometry recognizes this, and is updating the format of our venerable department previously known as “Coding Abstract.” The column is now called “Coding Connection,” intended to provide you with content that’s more closely connected to the featured monthly clinical topics. Why? Because clinical decisions and coding responsibilities go hand in hand. To truly master the patient care of any given condition, we also need a good command of the documentation and billing aspects that enable it.

Our format is going to change as well. In some months, the coding coverage will come in the form of a sidebar integrated into a chosen clinical feature that month. Other times, it’ll be a standalone column like this one. Either way, our goal is to make the medical coding and compliance issues immediately applicable to the clinical content and situations you encounter on a daily basis, in a presentation that will be seamless as you read the magazine or web site each month.

Coding for Anterior Uveitis

For example, one of the clinical features in this issue concerns the management of anterior uveitis or iritis (“*Practical Pearls for Anterior*




Photo: Kyle D. Dohm, OD

White blood cells in the anterior chamber, seen here, are a characteristic sign of anterior uveitis, so this presentation doesn't usually require special tests for diagnosis.

Uveitis,” page 58). As we know, iritis can be acute or chronic, depending on the cause of the inflammatory event. Coding for iritis is fairly simple, yet it is critical to maintain a proper sequence of events in the medical record.

In other words, was the iritis the primary cause of the office visit or was it a sequelae of another clinical presentation?

Be precise in your recording of the chief complaint as well as the secondary reasons that the patient is in your office that day. Get in the habit of recording specifics such as the circumstances (injury or traumatic) and the laterality (right eye, left eye, both eyes) as this will be required for ICD-10.

The code for a typical office visit is 920X2 or the appropriate level 992XX code based upon the relevant history, physical exam and related medical decision making. If the iritis is caused by a systemic condition, keep in mind that both the ICD-9 and the forthcoming

ICD-10 require that the systemic diagnosis be primary and the ocular sequelae are secondary when filing the claim with a medical carrier.


It's rare that the management of iritis requires special ophthalmic tests such as anterior segment photos or OCT, unless you can specifically demonstrate the medical necessity for the specific procedure and how it aided you in getting a better clinical outcome.

Here's to starting strong in 2015: Out with the old and in with the new! Our format and presentation may change, but one thing that you can always count on is that I'll continue to bring you solutions to all of the core coding and medical record compliance issues that many of you face in day-to-day practice, just as I have since this column started nearly a decade ago. ■

You can still reach me here at *Review*, just at a new email address: ROcodingconnection@gmail.com. I look forward to hearing from you.

CAN'T WAIT UNTIL NEXT MONTH?

Optometric Physician delivers **UP-TO-DATE** news and research to your inbox every Monday morning, allowing you to view all of the latest clinical information on a convenient and consistent basis.



Subscribing to Optometric Physician is an efficient and easy way to stay current with all of the information and events going on in the field. To order your free subscription, e-mail: optometricphysician@jobson.com today.

Optometric
Physician™



Gas It Up

Though anterior chamber injections can be hazardous, are they the best course of action when treating corneal hydrops? **Edited by Joseph P. Shovlin, OD**

Q I have a patient with corneal ectasia following LASIK with an acute corneal hydrops. Apparently, he was a big eye rubber! He is extremely bothered by his loss of vision and is quite light sensitive. Should an anterior chamber injection be considered early, or is there no need to rush? Is there any value in injecting retinal gas (C_3F_8 or SF_6) over air if you are treating a patient with corneal hydrops?

A It's best to do it earlier rather than later, and to use gas rather than air.

Corneal hydrops, an uncommon complication seen in patients with keratoconus and other corneal ectatic disorders, occurs when a tear in Descemet's membrane allows the aqueous humor to enter the stroma, resulting in corneal edema. While painful and visually obstructive, most cases resolve naturally over several months, during which endothelial cells cover the break, restoring Descemet's membrane.¹

To supplement the natural healing process, consider use of topical corticosteroids to reduce pain and inflammation, as well as glaucoma drugs to lower the IOP and reduce the hydrostatic forces causing the edema, says Eric Donnenfeld, MD, a Long Island ophthalmologist who specializes in laser vision correction. Topical antibiotics can also be prescribed to prevent a secondary infection if there is significant corneal compromise.¹ Subsequent surgery may be necessary if corneal edema persists or resultant corneal scarring affects visual clarity.¹

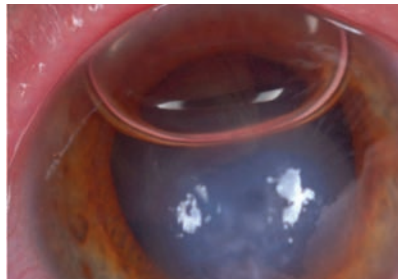


Fig. 1. Placement of intracameral C_3F_8 at nonexpansile concentration.

An alternative approach to managing corneal hydrops that has become more prevalent in recent years is the use of intracameral air or gas as a means to tamponade the exposure of aqueous to the corneal endothelium.

"Placement of air or gas can be performed at the slit lamp and can occlude the break in Descemet's membrane, leading to a dramatic reduction in corneal edema and a rapid resolution of the condition," explains William Trattler, MD, who performs refractive, corneal and cataract eye surgery at the Center for Excellence in Eye Care in Miami. Studies have shown markedly faster improvement compared to more conservative treatments.²⁻⁴

Dr. Trattler says gas does have a leg up over air. "The advantage of retinal gas is that it will stay within the anterior chamber for a longer period of time, reducing the chance a second injection is needed." He cautions there are still associated risks with using either, however. "The main risk is pupillary block, as enough air or gas needs to be placed within the eye to block the

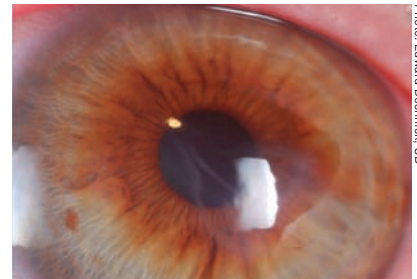

Fig. 2. After the procedure, the hydrops has resolved.

entrance of aqueous into the cornea." Thus, he adds, it is important to use a nonexpansile concentration of gas (*figure 1*), as expansion can lead to a complete fill of the anterior chamber, resulting in pupillary block. Other steps to reduce the risk of pupillary block include the use of dilating eye drops and placement of an inferior peripheral iridotomy.

Additional risks, says Dr. Trattler, include infection as a result of the needle's entrance into the anterior chamber. There is also evidence the presence of the gas in the anterior chamber may induce cataracts, notes Dr. Donnenfeld. He recommends patients lie on their back for several days following placement of the gas in the anterior chamber to achieve the best results possible. ■

1. Association of Optometric Contact Lens Educators. Acute Corneal Hydrops. Available at: www.aocle.org/livingL/hydrops.html. Accessed December 28, 2014.
2. Miyata K, Tsuji H, Tanabe T, et al. Intracameral air injection for acute hydrops in keratoconus. *Am J Ophthalmol* 2002;133(6):750-752.
3. Panda A, Aggarwal A, Madhavi P, et al. Management of acute corneal hydrops secondary to keratoconus with intracameral injection of sulfur hexachloride (SF_6). *Cornea*. 2007; 26(9):1067-1069.
4. Basu S, Vaddavalli PK, Ramappa M, et al. Intracameral perfluoropropane gas in the treatment of acute corneal hydrops. *Am J Ophthalmol* 2011;118(5):934-939.

Tiny Viruses, Major Diseases

Herpes, HIV, Ebola, enterovirus and rhinovirus (the common cold) are but a few notable examples. **By Carlo J. Pelino, OD, and Joseph J. Pizzimenti, OD**

From the Latin virus, meaning “poison” or “slimy liquid,” these pathogens are recognized as the cause of several diseases. We now know that viruses are small but powerful microorganisms that have widespread effects on the body—including the ocular structures and tissues.

Furthermore, Ebola, enterovirus, dengue and Middle East respiratory syndrome (MERS)—viruses many clinicians did not think much about a short time ago—are now causing a great deal of illness and worry worldwide.

How to Go Viral

In the late 1890s, German scientists Friedrich Loeffler and Paul Frosch concluded that foot-and-mouth disease in animals happens not by a bacteria or toxin, but by an “ultra-visible causative agent”—a minute particle, smaller than any bacteria, that is capable of reproduction under certain conditions.^{1,2}

This was an early clue to the nature of viruses; they are genetic entities that lie somewhere in the grey area between living and non-living states.

When found outside of the host cell, a virus is metabolically inert. The virus exists as a protein coat, or capsid, that surrounds either DNA or RNA, which codes for the virus elements.

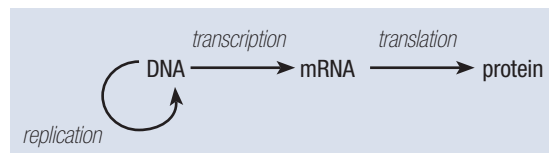
The entire infectious particle, called a virion, consists of the outer shell of protein and the nucleic acid within. The simplest viruses contain only enough RNA or DNA

to encode four proteins, while the most complex can encode 200 or more proteins.³

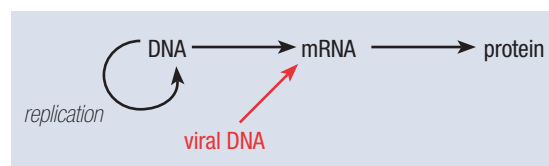
A virus cannot reproduce by itself. So, when it comes into contact with a host cell, the virus inserts its genetic material and takes over the host’s functions. Instead of its usual products, the infected cell produces viral protein and genetic material. Thus, once the virus infects a susceptible cell, it can direct that cell to produce more viruses.

In a normal cell, DNA is copied to make mRNA by a process called transcription. The information stored in mRNA is used (by ribosomes) to assemble proteins from amino acids, a process called translation.^{3,4,5}

The normal sequence is:



In DNA viruses, such as varicella zoster, when viral genetic material enters a cell, it is replicated, transcribed (mRNA is produced) and translated (proteins are produced from the mRNA).³⁻⁵ By this process, the host cell uses the genetic instructions in the virus to make more viruses:



In some RNA viruses, the viral RNA serves as mRNA after infection. The RNA of some viruses serves as a template to synthesize more RNA within the host cell. Some of the replicated RNA serves as mRNA and is used to produce proteins, while the remainder is packaged in new viral particles.^{3,5}

Retroviruses (a family of RNA viruses) use RNA as their genetic material, but the host cell must synthesize a “DNA copy” of the RNA before it can be transcribed or translated. This task is aided by the action of an enzyme known as reverse transcriptase. HIV is an example of a retrovirus.⁵

Some viruses remain dormant inside host cells for long periods, causing no obvious damage (a stage known as the lysogenic phase).

But when a dormant virus is stimulated, it enters the lytic phase. Here, new viruses are formed, self-assemble and burst out of the

host cell, killing it and going on to infect other cells.^{3,5,6}

A virus that infects only bacteria is called a bacteriophage.^{3,5,6} Viruses that infect animal or plant cells are referred to generally as animal viruses or plant viruses. Most animal viruses do not cross phyla, and some (e.g., poliovirus) infect only

closely related species, such as primates.

The host-cell range of some animal viruses is further restricted to a limited number of



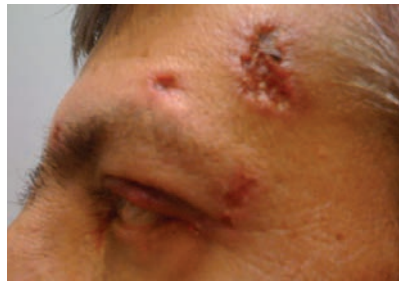cell types because only these cells have appropriate surface receptors to which the virions can attach.

Outbreaks and Vaccines

The term outbreak describes the sudden rise in the incidence of a disease. An epidemic occurs when an infectious disease spreads rapidly to many people—well beyond what is expected within a country or a part of a country.

When the infection takes place in several countries at the same time, it turns into a pandemic—an outbreak of global proportions. It happens when a novel virus emerges among humans.⁷ The virus causes serious illness and is easily human transmissible.

The emergence of vaccines has been one of the greatest advances in public health. A vaccination is the



This patient with herpes (varicella) zoster ophthalmicus was successfully treated with oral antiviral medication.

injection of a killed or weakened organism that produces immunity in the body against that organism. While vaccines produce immunization, some infections also cause immunization after an individual recovers from that disease.

Through use of vaccines, we have eradicated smallpox and nearly eliminated wild poliovirus. The benefits of vaccines appear to significantly outweigh the risks. However, no vaccine is 100% safe or effective for everyone because each person's body reacts to vaccines differently.

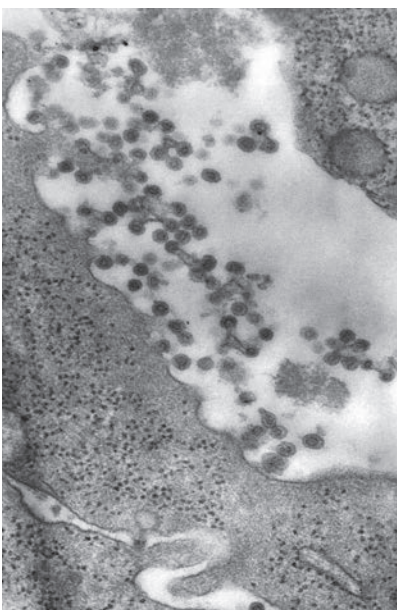
Viral Eye Disease

Along with the nose and mouth, eyes are a main access point for viruses. In addition, systemic viral infection from other areas of the body may manifest in ocular tissues, causing potentially sight-threatening complications. (See “*Viruses Encountered Most Frequently in the Eye*,” below.)

In forthcoming columns, we'll present an update on each of these viruses frequently encountered within the review of systems. First up in March: HIV. ■

1. Witz J. A reappraisal of the contribution of Friedrich Loeffler to the development of the modern concept of virus. *Arch Virol.* 1998;143(11):2261-3.
2. Rott R, Siddell S. One hundred years of animal virology. *J Gen Virol.* 1998 Nov;79 (Pt 11):2871-4.
3. Carter J, Saunders V. *Virology: Principles and Applications*, 2nd ed. Hoboken, NJ: Wiley; 2013:1-65.
4. Taylor MW. *Viruses and Man: A History of Interactions*. Switzerland: Springer International Publishing; 2014:1-40.
5. *Genes and Gene Expression*. BioChemWeb.org: The Virtual Library of Biochemistry and Cell Biology. Available at: www.biochemweb.org/genes.shtml. Accessed December 7, 2014.
6. Madigan MT, Martinko J (eds.). *Brock Biology of Microorganisms*, 11th ed. Upper Saddle River, NJ: Prentice Hall; 2006.
7. Porta M (ed.). *A Dictionary of Epidemiology*, 6th ed. New York: Oxford University Press; 2014:209.

Image: Centers for Disease Control and Prevention



This transmission electron micrograph reveals rubella virions in the process of budding from the host cell surface to be freed into the host's system. The rubella virus is known to be the cause of measles. Congenital rubella can result in retinopathy.

Viruses Encountered Most Frequently in the Eye

FAMILY	OPHTHALMIC INVOLVEMENT
<i>DNA Virus Families</i>	
Adenoviridae	Epidemic keratoconjunctivitis (most commonly associated serotypes are adenovirus 8, 19 and 37)
Herpesviridae	Herpes simplex ocular disease Varicella zoster ophthalmicus Cytomegalovirus retinitis (human herpes virus 5)
Papoviridae	Papilloma (human papilloma virus) of lids, adnexa and conjunctiva
Poxviridae	Molluscum contagiosum of lids and adnexa
<i>RNA Virus Families</i>	
Togaviridae	Rubella retinopathy
Retroviridae	HIV (affects many ocular tissues)

DOWNLOAD LAYAR APP
FOR INTERACTIVE EXPERIENCE



layar

INTERACTIVE PRINT

First 150 app downloads and completed forms will be entered into a drawing for FREE MEETING AND REGISTRATION VALUED AT \$495

SAVE THE DATE

REVIEW OF OPTOMETRY EDUCATIONAL MEETINGS OF CLINICAL EXCELLENCE

SAN DIEGO, CA

APRIL 10-12



CE COURSE TOPICS:

- Management of Lid Margin Disease
- Innovations in Eye Care
- Glaucoma Management Insights
- Diagnostic Dilemmas and Solutions
- Emergency and Urgency Diagnosis and Treatment
- Anterior Segment Disease Diagnosis and Treatment
- Medical Management of Ocular Disease
- Comanagement of Cataract and Refractive Surgery
- Writing Oral Prescriptions

NEW!!

Dry Eye Workshop • Glaucoma Workshop

FACULTY

Paul Karpecki, OD
[Program Director]



Marc Bloomenstein, OD



Derek Cunningham, OD



Doug Devries, OD



Ben Gaddie, OD



FOR MORE INFORMATION:
WWW.REVIEWOFOPTOMETRY.COM



Up to
17 CE Credits
(COPE approval pending)

OMNI SAN DIEGO HOTEL

675 L STREET SAN DIEGO, CA 92101

Up to 17 Credits

(COPE Approval Pending)

www.revoptom.com/SanDiego2015

Registration Information

Name	NPI # (NPI numbers will only be used for HCP reporting purposes)		
Practice Affiliation			
Mailing Address	City	State	Zip Code
Telephone	Fax	Email	

Name Badge Information (please print clearly)

My Name	My Guest	Additional Guests
---------	----------	-------------------

Payment Information

	Rate per person	No. in party	Subtotal
OD Registration - \$495 (\$100 off if registered by March 10th) (includes 15 hours of CE, breakfasts, reception) <small>Call for daily and student rates.</small>	\$495	x _____	= \$ _____
Additional Guest(s) - \$45 (12 years and older, includes reception)	\$45	x _____	= \$ _____
Concurrent Workshop Sessions (Saturday, April 11, 2:30-4:30pm) <small>Select only one if interested in additional session and credits</small>			
Dry Eye Workshop - \$70 (Earn 2 additional CE Credits)	\$70	x _____	= \$ _____
Glaucoma Workshop - \$70 (Earn 2 additional CE Credits)	\$70	x _____	= \$ _____
		TOTAL	= \$ _____

Check enclosed (make checks payable to *Review of Optometry*)

Charge my: American Express Mastercard Visa

Credit Card Number _____ Exp Date _____

Cardholder (print name) _____

Signature _____

CONFERENCE CANCELLATION POLICY

- Full refund on registration fee until March 10, 2015
- 50% refund on registration fee until March 28, 2015
- No refund past March 28, 2015

For more information or to register,
contact Lois DiDomenico at 866-658-1772
or at ReviewMeetings@Jobson.com.



*Approval pending



Two Decades of Poor Vision

After more than 20 years, is it even remotely possible to restore the visual acuity in our patient's right eye? **By Mark T. Dunbar, OD**

A 53-year-old Hispanic male presented for a second opinion on a previous diagnosis. He reported vision loss in his right eye that had persisted for more than 20 years. His medical history was unremarkable.

The patient was told that "he had pressure in his eye," but admitted that he didn't really understand the diagnosis. He suggested that the vision in his right eye had been fairly stable over the past several years since he moved to the United States.

On examination, his best-corrected visual acuity measured 20/400 OD and 20/20 OS. Extraocular motility testing was normal. Confrontation visual fields were full to careful finger counting OU. Pupils were equally round and reactive, with trace evidence of afferent defect in his right eye. The anterior segment was unremarkable. His intraocular pressure measured 15mm Hg OU.

Dilated fundus exam revealed healthy optic nerves, with good rim

coloration and perfusion. We noted significant retinal changes in his right eye (*figure 1*). We also noted changes in the left eye (*figure 2*). Additionally, we ordered a spectral-domain optical coherence tomography (SD-OCT) scan (*figure 3*).

Take the Retina Quiz

1. How would you characterize the SD-OCT findings documented in his right eye?

- a. Retinal pigment epithelium (RPE) tear.
- b. Exudative retinal detachment.
- c. Combination pigment epithelial detachment (PED) and serous detachment.
- d. Macular schisis.

2. How do you account for the areas of RPE hypertrophy OU?

- a. Retinal degeneration from early-stage retinitis pigmentosa (RP).
- b. Unreported trauma.
- c. Previous episodes of retinal edema and fluid.
- d. Previous toxoplasmosis.

3. What is the correct diagnosis for this patient?

- a. Wet macular degeneration.
- b. Coats' disease.
- c. Polypoidal choroidal vasculopathy (PCV).
- d. Branch retinal vein occlusion with subretinal neovascularization.

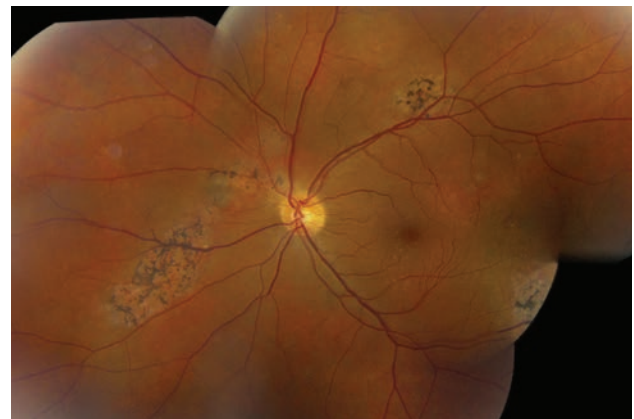
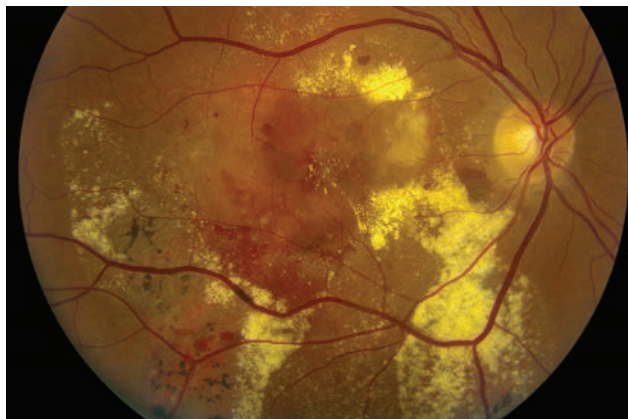
4. How should this patient likely be treated?

- a. Laser photocoagulation.
- b. Photodynamic therapy (PDT).
- c. Anti-VEGF injection.
- d. Combination PDT and anti-VEGF therapy.

For answers, turn to page 90.

Discussion

There is massive exudation and subretinal hemorrhage throughout the posterior pole of our patient's right eye. The SD-OCT shows an irregular pigment epithelial detachment with an overlying serous retinal detachment, as well as cystoid macular edema OD.



Figs. 1 & 2. Fundus image of his right eye (left), and widefield view of his left eye (right). How do you explain the pigmentary anomalies?



It would be easy to assume that these findings, in conjunction with the subretinal hemorrhage, are due to a large, occult choroidal neovascular membrane. But, that is not the likely cause. Instead, he has PCV.

Lawrence A. Yannuzzi, MD, first described polypoidal choroidal vasculopathy in 1982.¹ The hallmark feature of PCV is a network of vessels located in the inner choroid that develop peculiar aneurismal dilations. The disease is characterized by multiple, recurrent, serosanguineous detachments of the RPE and neurosensory retina secondary to leakage and bleeding from these aneurismal choroidal vascular lesions.¹⁻³ In fact, one of the earliest names for the condition was “posterior uveal bleeding syndrome,” because of the massive amount of hemorrhaging and exudation. Looking at our patient, you can understand why.

In the earlier disease stages, you can sometimes see the aneurismal polyp-like lesions located below the RPE. These appear as reddish-orange, spheroidal lesions. Over time, these vessels can slowly begin to bleed with varying amounts of exudation. Indocyanine green angiography (IGC) may be the definitive test for establishing a diagnosis of PCV, as the polyp-like aneurismal dilations are clearly highlighted.

Keep in mind that PCV easily can be misdiagnosed for wet macular degeneration. In one study of 167 consecutive patients diagnosed with wet AMD, the researchers determined that 13 patients (7.8%) actually had PCV.⁴ Additionally, PCV tends to present in more darkly pigmented individuals (i.e., blacks, Hispanics and Asians), compared to AMD, which is more frequently diagnosed in whites.

PCV also tends to occur in younger individuals—50 to 65 years

of age, compared to 65+ for AMD.³ Our patient is 53, much younger than the typical AMD patient. Finally, AMD is associated with drusen, which typically are not seen in younger PCV patients.

The changes seen in our patient’s left eye are also quite revealing. We noted localized areas of bony pigment spiculing, which likely is due to previous PCV activity. It appears that the patient developed scarring from resolved episodes of bleeding, exudation and retinal edema. But, because these features did not involve the macula, the patient remained completely unaware of any underlying disease process.

Photodynamic therapy has emerged over thermal laser as the treatment of choice for PCV. However, more recently, researchers have investigated the clinical efficacy of intravitreal anti-VEGF therapy.

The EVEREST study was a multicenter, double-masked trial comparing the therapeutic effect of PDT plus Lucentis (ranibizumab, Genentech/Roche), PDT monotherapy, and Lucentis monotherapy on polypoidal choroidal vasculopathy.⁵ The six-month results indicated that PDT plus Lucentis and PDT monotherapy were superior to Lucentis treatment alone in achieving complete polyp closure regression (77.8% and 71.4% vs. 28.6%, respectively). Eyes treated with PDT plus Lucentis also achieved better visual acuity. Specifically, patients who underwent combination PDT and Lucentis gained 10.9 ETDRS letters, those who received Lucentis monotherapy gained 9.2 letters and those who underwent PDT monotherapy gained 7.5 letters.⁵ It is important to note that patients who received PDT (either alone or in combination) exhibited better PCV resolution than those who received

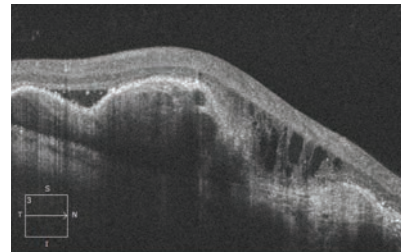


Fig. 3. Spectral-domain optical coherence tomography scan through the macula of our patient’s right eye. What is the underlying etiology?

Lucentis monotherapy.⁵

Given these findings, it seems that combination PDT and Lucentis therapy may yield better lesion regression and a longer duration of treatment effect than either form of monotherapy.⁵ A similar study comparing the clinical efficacy of Lucentis and Avastin (bevacizumab, Genentech/Roche) for PCV produced similar results.⁶

We referred our patient to a retinal specialist for treatment. Considering his 20-year history of vision loss, it doesn’t seem likely that he will recover much central vision. On the other hand, the retinal findings do not look consistent with a process that has been progressing for two decades. So perhaps, if we can get rid of the fluid and flatten his macula, we may be pleasantly surprised at how well he does. Only time will tell. ■

1. Yannuzzi LA. Idiopathic polypoidal choroidal vasculopathy. Presented at the Macula Society Meeting, February 5, 1982; Miami, Fla.
2. Yannuzzi LA, Sorenson J, Spaide RF, Lipscomb B. Idiopathic polypoidal choroidal vasculopathy (IPCV). *Retina*. 1990;10(1):1-8.
3. Yannuzzi LA, Ciardella A, Spaide RF, et al. The expanding clinical spectrum of idiopathic polypoidal choroidal vasculopathy. *Arch Ophthalmol*. 1997 Apr;115(4):478-85.
4. Yannuzzi LA, Wong DW, Sforzolini BS, et al. Polypoidal choroidal vasculopathy and neovascularized age-related macular degeneration. *Arch Ophthalmol*. 1999 Nov;117(11):1503-10.
5. Koh AH, Chen LJ, Chen SJ, et al. Polypoidal choroidal vasculopathy: evidence-based guidelines for clinical diagnosis and treatment. *Retina*. 2013 Apr;33(4):686-716.
6. Cho HJ, Kim JW, Lee DW, et al. Intravitreal bevacizumab and ranibizumab injections for patients with polypoidal choroidal vasculopathy. *Eye (Lond)*. 2012 Mar;26(3):426-33.

Don't Delay Optic Neuritis Dx

Because of the close association between optic neuritis and MS, a prompt diagnosis and referral for treatment is paramount. **By Joseph W. Sowka, OD, and Alan G. Kabat, OD**

Early in our training and careers, we often avoided diagnosing patients with optic neuritis. When the prototypical patient came to us (e.g., a young person, often female, complaining of color vision loss, blurred vision and significant pain upon eye movement, and manifesting a relative afferent pupillary defect but a normal optic disc appearance), we were hesitant to make a confirmatory diagnosis of optic neuritis—though it often was our suspicion.

Our reluctance stemmed from the strong association of optic neuritis with multiple sclerosis (MS). While we were able to use magnetic resonance imaging (MRI) to identify characteristic MS brain lesions, we rarely did so. The reason was that, even if we did confirm that optic neuritis was the first manifestation of MS, there was nothing we could do to treat the patient.

Usually, optic neuritis would spontaneously improve and had a good visual prognosis. However, there was no accepted treatment for MS at that time. We knew that if we definitively diagnosed optic neuritis, the underlying implication of MS could pose a hardship for patients who—at that time—could have lost or not qualified for medical or disability insurance because carriers might suspect they could be on the hook for a disabling disease. Thus, we took a “don't ask, don't tell” policy.

Today, fortunately, the climate is much different. Over the past several years, research has made great advances in immunomodulatory therapy that can diminish the disabling effects of MS. Not only are these therapies beneficial in reducing disability, but the early initiation of therapy offers the best patient outcomes.

What is Optic Neuritis and MS?

Optic neuritis is an acute, inflammatory, demyelinating event of the optic nerve that may be idiopathic and localized to the optic nerve, or may be or become associated with other systemic illnesses—notably MS. Optic neuritis often is the initial presenting sign of MS.¹⁻³ After five years, clinically definite multiple sclerosis (CDMS) develops in 30% of patients who present with optic neuritis, although the degree of neurological impairment is generally mild at that point.⁴ The typical patient with demyelinating optic neuritis is a young female, often between the ages of 20 and 40. In 92% of cases, the vision loss is painful—particularly upon eye movement.⁵

Multiple sclerosis is an acquired, multifactorial, autoimmune inflammatory demyelinating disease that affects the white matter located in the central nervous system (CNS). MS is defined by recurrent bouts of CNS inflammation that damage both the myelin sheath surrounding the axons and the axons themselves. There is a predilection

for specific areas of the CNS, including the optic nerve and periventricular white matter of the cerebellum, brain stem, basal ganglia and spinal cord. Myelin is responsible for insulating the nerves of the peripheral and central nervous system, permitting speeding of electrical impulses along nervous tissues.

Evidence suggests that the cellular immune response contributes to the degradation of myelin. This patchy demyelination likely is caused by a deposition of mononuclear cells, such as macrophages and B-cells in perivascular regions.⁶ Loss of myelin greatly slows nervous conduction and leads to the neurological deficits seen in MS.

On average, patients experience clinical relapses every one to two years during the so-called relapsing/remitting phase of the disease—although serial MRI suggests that inflammatory lesions are practically continuous throughout this period.

Current MS Therapies

MS frequently is treated using immunomodulatory agents. The major drugs used in the United States include interferon beta-1b (Betaseron, Bayer HealthCare) and interferon beta-1a (Avonex, Biogen Idec; and Rebif, Pfizer). Glatiramer acetate (Copaxone, Teva) also is frequently used.⁷

- **Betaseron** is injected subcutaneously. The recommended dose is 0.25mg every other day. It is



supplied as 0.3mg of lyophilized powder in a single-use vial for reconstitution.

- **Avonex** is FDA approved to treat relapsing forms of MS, decrease the number of disease recurrences and to slow the onset of associated physical disabilities. It is indicated for use in people who have experienced a first attack and have lesions consistent with MS via MRI.

Avonex is a once-weekly treatment that is available in three dosage forms: a prefilled syringe; a single-use, prefilled autoinjector that uses a covered needle that's 50% shorter than the standard Avonex needle; and an unmixed form designed to be used with a standard Avonex syringe.

- **Rebif** is administered three times per week, and also is available in three dosing forms: Rebif Rebidose, a preassembled, prefilled, single-use autoinjector; the Rebiject II autoinjector, which works with the Rebif prefilled syringe and is designed to automate the injection process; and a ready-to-use, preassembled, prefilled syringe.

- **Copaxone** is a synthetic analogue of the MS-associated antigen, myelin basic protein. Copaxone 40mg is an injectable therapy that is taken three times per week. Copaxone is available as both a prefilled syringe and an autoinjector.

Is Early Treatment Better?

Numerous studies have evaluated the effectiveness of immunomodulatory therapies in reducing disease recurrence, accumulation of disability and progression to CDMS. Additionally, multiple research groups have sought to determine if the timing of therapeutic initiation

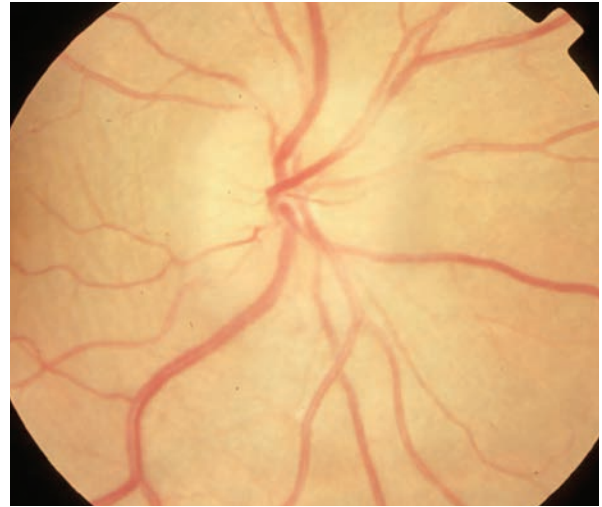
has a clinical effect on the severity of MS development and progression.

Betaseron's effects on MS are currently unknown, but are thought to block T cells from attacking myelin. However, the Betaseron in Newly Emerging Multiple Sclerosis for Initial Treatment (BENEFIT) study showed that early treatment with beta-1b significantly delayed the time to a second flare-up and conversion to CDMS compared with placebo.⁸

The Controlled High Risk Avonex Multiple Sclerosis Study (CHAMPS) looked at whether the initiation of Avonex in patients experiencing a first-time demyelinating event, such as optic neuritis, and who also had MRI brain abnormalities suggestive of prior demyelinating events could delay or prevent progression to CDMS.⁹

Its three-year results were very impressive.⁹ Development of CDMS occurred in 35% of patients using Avonex and in 50% of placebo-treated patients. Additionally, patients who used Avonex experienced a decrease in the number and size of new MRI brain lesions compared to those in the placebo group.⁹

A 10-year extension of the CHAMPS study looked at whether immediate initiation of treatment at the time of a clinical demyelinating event in patients at high risk for CDMS (those with an abnormal brain MRI) could alter long-term disease progression.¹⁰



Swollen optic disc in a patient with optic neuritis and MS.

The immediate-treatment group exhibited a 40% lower rate of CDMS, as well as a reduced relapse rate. Also, few patients in the immediate treatment group reached the Expanded Disability Status Scale milestone scores of 4.0 or greater (9% of patients) or 6.0 or greater (6% of patients). The researchers believed that immediate initiation of Avonex at the time of a clinically isolated syndrome (such as optic neuritis) in high-risk patients reduced relapse rates by more than 10 years, and was associated with better clinical outcomes.¹⁰

In the PreCISE study, patients who used Copaxone experienced a significantly reduced rate of, and longer conversion time to, CDMS than those who took a placebo—with a 45% incidence reduction overall, and a 66% reduction if optic neuritis was the presenting finding.¹¹

More recently, the same research team noted that initial treatment with Copaxone reduced CDMS conversion risk by 41% compared to delayed-treatment, and was associated with a 972-day delay

Therapeutic Review

in conversion to CDMS. They concluded that the reduced rate of CDMS conversion, as well as lower MRI measures of disease activity and lesion burden, support initiating Copaxone treatment soon after the first clinical symptoms suggestive of MS manifest.¹² Further, they recommend continuing treatment to sustain benefits.¹²

Clearly, there has been a paradigm shift in the way that we diagnose and manage patients with optic neuritis and other conditions associated with MS development. While eye care practitioners are not going to manage patients with MS, we frequently are the individuals to diagnose conditions associated with the disease.

Before, we never rushed to make the diagnosis of optic neuritis and

MS because there were no interventions available to help patients. Now, the immunomodulatory therapies available have clearly shown to reduce the burden of MS, and that early treatment can delay the onset and taper the severity of CDMS.

When encountering optic neuritis, internuclear ophthalmoplegia or any condition associated with MS, the treatment paradigm dictates prompt diagnosis with a risk assessment and referral to a physician skilled in the management of patients with MS. This will ensure that appropriate intervention will be started to provide patients with the maximum benefit. ■

1. Chan JW. Optic neuritis in multiple sclerosis. *Ocul Immunol Inflamm.* 2002;10(3):161-86.
2. Soderstrom M. Optic neuritis and multiple sclerosis. *Acta Ophthalmol Scand.* 2001 Mar;79(3):223-7.

3. Pirko I, Blauwet LK, Lesnick TG, et al. The natural history of recurrent optic neuritis. *Arch Neurol.* 2004 Sep;61(9):1401-5.
4. Optic Neuritis Study Group. The five-year risk of MS after optic neuritis. Experience of the optic neuritis treatment trial. *Neurology.* 1997 May;49(5):1404-13.
5. Beck RW. Optic neuritis study group. Neurologic impairment 10 years after optic neuritis. *Arch Neurol.* 2004 Sep;61(9):1386-9.
6. Confavreux C, Vukusic S. Accumulation of irreversible disability in multiple sclerosis: from epidemiology to treatment. *Clin Neurol Neurosurg.* 2006 Mar;108(3):327-32.
7. Plosker GL. Interferon1b: a review of its use in multiple sclerosis. *CNS Drugs.* 2011 Jan;25(1):67-88.
8. Kappos L, Polman CH, Freedman MS, et al. Treatment with interferon beta-1b delays conversion to clinically definite and McDonald MS in patients with clinically isolated syndromes. *Neurology.* 2006 Oct 10;67(7):1242-9.
9. Jacobs LD, Beck RW, Simon JH, et al. Intramuscular interferon beta-1a therapy initiated during a first demyelinating event in multiple sclerosis. CHAMPS Study Group. *N Engl J Med.* 2000 Sep 28;343(13):898-904.
10. Kinkel RP, Dontchev M, Kollman C, et al. Association between immediate initiation of intramuscular interferon beta-1a at the time of a clinically isolated syndrome and long-term outcomes: a 10-year follow-up of the Controlled High-Risk Avonex Multiple Sclerosis Prevention Study in Ongoing Neurological Surveillance. *Arch Neurol.* 2012 Feb;69(2):183-90.
11. Comi G, Martinelli V, Rodegher M, et al. Effect of glatiramer acetate on conversion to clinically definite multiple sclerosis in patients with clinically isolated syndrome (PreCISe study): a randomised, double-blind, placebo-controlled trial. *Lancet.* 2009 Oct 31;374(9700):1503-11.
12. Comi G, Martinelli V, Rodegher M, et al. Effects of early treatment with glatiramer acetate in patients with clinically isolated syndrome. *Mult Scler.* 2013 Jul;19(8):1074-83.



 Local Eye Site
JOBS IN EYE CARE

YOU'RE INVITED TO

LOCAL EYE SITE **LIVE!**

Eye Care's Online Career Fair

Thursday, February 19, 2015

11 AM - 2 PM & 6 PM - 9 PM EST

LIMITED
SPACE
REGISTER
NOW!

REGISTER ONLINE >> localeyesite.com/live

SPONSORED BY





INTERNATIONAL
**VISION
EXPO**
& CONFERENCE
NEW YORK

VISIONARIES

IN EDUCATION, FASHION AND TECHNOLOGY

Are you practicing full-scope medical eyecare? International Vision Expo offers advanced education focused on the core competencies of your practice: management of eye disease, contact lens technology, practice management and other optical topics. By expanding your knowledge base, you'll enhance the scope of your practice and patient offerings to the maximum extent your license allows.

International Vision Expo brings together world-class visionaries from all areas of clinical care to provide extensive, leading-edge education in ocular disease, contact lenses and therapeutics.

With hundreds of medical and diagnostic exhibitors and 333 hours of education under one roof, you can extend your learning with hands-on product and equipment demonstrations.

It's no surprise that more Optometrists and Opticians choose to continue their education at International Vision Expo than at any other conference globally. Whether it's new ideas, new products, new applications or new processes, innovation and education are what improve the quality of treatment and service you provide your clients and patients.

International Vision Expo has added new tracks to address trending industry topics including Retail, Wearable Technology and the Ocular Wellness Program. Also new this year, look for an increase in classroom collaboration and engagement with more courses featuring technology, and infusing crowd sourced learning for maximum peer-to-peer impact.

INTERNATIONAL VISION EXPO 2015

EDUCATION: THURSDAY, MARCH 19-SUNDAY, MARCH 22

EXHIBITION: FRIDAY, MARCH 20-SUNDAY, MARCH 22

JAVITS CENTER | NEW YORK, NY | VisionExpoEast.com | [#VisionExpo](https://twitter.com/VisionExpo)

PROUD SUPPORTER OF: 


19TH ANNUAL

OPHTHALMIC PRODUCT GUIDE



Innovative products to
enhance your practice

The **future**
is in your
hands. One
tap, many
possibilities.

Experience the digital edition on your handheld device.
Use your smart device to scan the code below or visit:



www.revoptom.com/supplements/

Download a QR scanner app. Launch app and hold your mobile device over
the code to view <http://www.revoptom.com/supplements>

REVIEW
OF OPTOMETRY



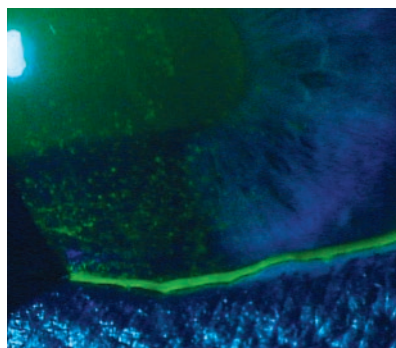
The Evolution of Dry Eye

Our understanding of dry eye has become more sophisticated in recent years. So too should our approach to care. **By Paul M. Karpecki, OD**

The concept of dry eye, or at least an understanding of the need for tears, has been recognized by healers for over 3,500 years, as the first mention of our tears was recorded in 1550 BC as “the water within” in ancient Egyptian documents known as the Ebers Papyrus.¹ However, the discipline of ocular surface care didn’t actually begin until the mid-1850s, when a mechanism of tear secretion was first proposed. The modern era of dry eye began in 1973 when Frank Holly explained the role of mucin. Soon thereafter, the work of Tseng, Plugfelder, Lemp, Korb, Nichols and others allowed us to develop a better understanding of the interaction of the ocular surface and tear film.

Today, dry eye is one of the leading causes of patient visits to eye care providers (ECPs) in the US.³ Although anywhere from 20 to 30 million people have early signs and symptoms of dry eye (depending on the study cited), only eight million patients manage their condition with artificial tears at a minimum, and a much lower percentage are actually receiving ongoing treatment from an ECP.⁴ Studies around the world show similar numbers, though certain regions like Asia may have as much as 33% of the population experiencing significant dry eye.²

Simply put, dry eye is the number one medical condition that motivates patients to see their ECP—and it will only grow. The predisposing factors that will likely make this disease increase in prevalence are:



Dry eye in a patient who presented with superficial punctate keratitis.

- *Digital device use.* Studies show the average American spends three to five hours on electronic devices daily.⁵

- *Systemic diseases.* Diabetes is just one example of a systemic disease with a significant connection to dry eye; it is expected to increase from 29 million Americans in 2012 to 54 million in 2050.^{6,7}

- *The aging population.* Demographic trends and life expectancy gains will expand the senior citizen population from 14% in 2013 to 20% in 2050.⁸

These trends—which clearly indicate a pressing need for ongoing education in the field of dry eye—are the impetus for this new bimonthly column, “Ocular Surface Review.”

Past Meets Present

Along the historic path, there were some great, early insights that impact how the disease is diagnosed and managed today.

The first mention of increased tear osmolarity was in 1941 by Von Bahr and colleagues.⁹ But osmolarity

requires two key things: acquisition of tears in a reservoir, and then measurement. Although those capabilities were not as readily available then as they are today, the science of hyperosmolarity as an underlying finding began almost 75 years ago.

In the early 1960s, it was discovered that a decrease in lacrimal gland secretion leads to ocular surface desiccation.¹⁰ In the 1970s, the multilayered ocular surface was recognized as an integrated functional unit. This is analogous to our present efforts to consider the conjunctiva, cornea, lacrimal and meibomian glands as interrelated parts of a functional anatomical unit.

The late 1970s brought us the first mention of the role of meibomian glands in the pathogenesis of evaporative tear loss, and the role of the lipid layer in preventing the loss of aqueous was identified soon afterward.^{10,11} These clinical findings have affected how we manage dry eye disease and play a key role in the tests and treatments being administered.

Despite our knowledge today, there is no “gold standard” for the diagnosis of dry eye disease; instead, we must interpret multiple testing results. This fundamental piece of the dry eye puzzle is similar to the management of glaucoma, where many objective and subjective factors play a part in revealing the evidence that helps determine the diagnosis.

The combination of these as well as other key findings—like MMP-9, blink analysis, eyelid apposition and symptomatology—all provide the

data we need to diagnose dry eye.

Part of the reason we have to employ multiple tests in the diagnosis is because signs and symptoms of DED are poorly correlated.^{12,13} In fact, many patients with significant symptoms may have milder forms of dry eye. As the nerves downregulate and signs become more apparent, the symptoms decrease. In fact, one study showed less than 60% of dry eye patients (based on objective signs) were actually symptomatic.¹⁴

The progressive nature of this disease also increases the importance of recording objective findings like meibography, osmolarity, MG expression, inflammatory marker testing, lid margin evaluation, vital dye staining, blink analysis and lid apposition.¹⁵

With this many factors to continually monitor and evaluate, modern dry eye care can seem daunting. Fortunately, a few recent studies are helping to connect the dots.

One recent paper found that variability between eyes in osmolarity testing is a hallmark sign of DED. For example, the difference in osmolarity readings between the eyes would be within 5mOsmol/L, and both eyes would have readings under 300mOsmol/L.

A second critical new finding, also published in late 2014, mapped the inflammatory cascade. The sequence is as follows: increased osmolarity → inflammation → tear film instability → rapid tear film break-up time → change in VA → eventually other symptoms and signs.

Another landmark study looked at the effect of desiccating stress on the mouse meibomian gland function.¹⁶ The proposed cascade is as follows: low humidity → chronic evaporative stress → increased meibocyte production > oil production → dilation of ducts, extensive and possible obstruction → short maturation time

= increase in protein/lipid ratio → tear film stability impaired equal to or greater than evaporative stress.

All of these studies were published in 2014 and will have major implications to how we manage dry eye going forward. They also have significant areas of overlap, even though the original cause may be different.

Routine Check-ups

Given the progression of this disease, one might surmise the most appropriate future protocol might be that of the dental model. In this analogy, patients—especially those with early symptoms such as end-of-day contact lens discomfort or decreased wear time—should be evaluated and managed routinely, even in the absence of symptoms, to prevent future damage or loss of glands.

In the 1850s, when dry eye research began, people didn't know to brush their teeth, and they eventually lost them. Today, because of the use of electronic devices in particular, patients are losing their meibomian glands. We should be assessing this every year at a minimum and suggest that patients manage the early disease before it progresses.


Our eyelids are like our gums—they need to be managed daily. Patient education should stress the importance of daily at-home care with lid wipes and warm compresses. In the office, we can offer thermal pulsation treatment, mechanical cleaning devices that remove biofilms and debridement/scaling of the lid margin. When the lids are inflamed, we may need to use medications like topical cyclosporine or corticosteroids, and in advanced cases, orals like doxycycline.

We must embrace this new understanding of OSD to help our patients live with the most common condition they will face for decades to come. Working to shorten the

adoption lifecycle will have an amazing effect not only on dry eye disease patients and more advanced forms like Sjögren's syndrome, but also contact lens wearers, those who use electronic devices more than three hours a day and patients preparing for procedures such as cataract surgery. Getting involved now will help your practice and, most importantly, your patients' quality of life. ■

Excerpts taken from the Dry Eye Summit, which took place on December 12, 2014 in Dallas/Fort Worth, with input from 30 of the top educators in ocular surface disease.

1. Hirschberg J. The History of Ophthalmology, Vol. 1: Antiquity. Translated by FC Blodi. Bonn, West Germany: Verlag JP Wayenborgh, 1982.
2. Gayton, JL. Etiology, prevalence, and treatment of dry eye disease. Clin Ophthalmol. 2009; 3: 405–412.
3. Sullivan, D.A., Hammit, K.M., Schaumberg, D.A. et al. Report of the TFOS/ARVO Symposium on Global Treatments for Dry Eye Disease: An unmet need. Ocul Surf. 2012; 10: 108–116
4. Dahl AA and Davis CP. Dry Eye Syndrome (Dry Eyes, Keratoconjunctivitis Sicca). Available at: www.medicinenet.com/dry_eyes/article.htm. Accessed September 19, 2014.
5. U.S. Dept of Labor. American Time Use Survey Summary. Available at: www.bls.gov/news.release/atus_nr0.htm. Accessed October 1, 2014.
6. Centers for Disease Control and Prevention. National Diabetes Statistics Report, 2014. Available at: www.cdc.gov/diabetes/pubs/statsreport14/national-diabetes-report-web.pdf. Accessed October 1, 2014.
7. Centers for Disease Control and Prevention. Number of Americans with Diabetes Projected to Double or Triple by 2050. Available at: www.cdc.gov/media/presrel/2010/r101022.html. Accessed October 1, 2014.
8. Ortman JM, Howard H, Victoria VA. An Aging Nation: The Older Population in the United States. May 2014. Available at: www.census.gov/prod/2014pubs/p25-114.pdf. Accessed October 1, 2014.
9. Von Bahr G. Konnte der Flüssigkeitsabgang durch die cornea von physiologischer bedengtung sein. Acta Ophthalmol (Copenh). 1941;19:125-34.
10. Asbell PA, Lemp MA (eds.). Dry Eye Disease: The Clinician's Guide to Diagnosis and Treatment. Thieme Publications; 2006
11. Jester JV, Nicolaidis N, Smith RE. Meibomian gland studies: histologic and ultrastructural investigations. Invest Ophthalmol Vis Sci. 1981;20:537-47
12. Nichols KK, Nichols JJ, Mitchell GL. The lack of association between signs and symptoms in patients with dry eye disease. Cornea. 2004 Nov;23(8):762-70.
13. Sullivan BD, Crews LA, Messmer EM, et al. Correlations between commonly used objective signs and symptoms for the diagnosis of dry eye disease: clinical implications Acta Ophthalmol. 2014;92:161-166.
14. Bron AJ, Tomlinson A, Foulks GN, et al. Rethinking dry eye disease: a perspective on clinical implications. OculSurf. 2014;12(2 Suppl):S1-S31.
15. Rao SN. Topical cyclosporine 0.05% for the prevention of dry eye disease progression. J Ocul Pharmacol Ther. 2010 Apr;26(2):157-64.
16. Suhailim JL, Parfitt GJ, Xie Y, et al. Effect of desiccating stress on mouse meibomian gland function. Ocular Surface 2014, Vol. 12 (1):59-68.



THE RICK BAY FOUNDATION

for Excellence in Eyecare Education

www.rickbayfoundation.org

Support the Education of Future Healthcare & Eyecare Professionals



About Rick

Rick Bay served as the publisher of *The Review* Group since 1991.

To those who worked for him, he was a leader whose essence was based in a fierce and boundless loyalty.



To those in the industry and the professions he served, he will be remembered for his unique array of skills and for his dedication to exceeding the expectations of his customers, making many of them fast friends.

Scholarships will be awarded to advance the education of students in both **Optometry** and **Ophthalmology**, and will be chosen by their school based on qualities that embody Rick's commitment to the profession, including integrity, compassion, partnership and dedication to the greater good.

Interested in being a partner with us?

Visit www.rickbayfoundation.org

(Contributions are tax-deductible in accordance with section 170 of the Internal Revenue Code.)



THE RICK BAY FOUNDATION
for Excellence in Eyecare Education

(The Rick Bay Foundation for Excellence in Eyecare Education is a nonprofit, tax-exempt organization under section 501(c)(3) of the Internal Revenue Code.)

By Derek N. Cunningham, OD, and Walter O. Whitley, OD, MBA



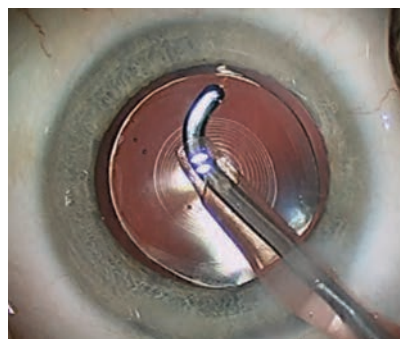
Conquering Cataracts

Today's techniques put "premium" outcomes within reach of more patients than ever.

Cataract surgery has come a long way in the past few decades. From extracapsular extraction to phacoemulsification with clear corneal incisions to femtosecond laser-assisted surgery, cataract removal has evolved dramatically, thanks to continuous innovations in techniques and technology. As primary eye care providers, it is important for us to remember where we stand with regard to traditional surgery and why we've seen so many recent advances. Our role is to prepare and educate our patients for cataract removal, review their IOL options and discuss our perioperative responsibilities. A simple, generic referral for cataract surgery is no longer sufficient.

Patients want to improve their quality of life following cataract surgery and to be less dependent on corrective lenses after the procedure. During the cataract evaluation, patients must be informed of all available treatment options and ultimately decide which IOL option best suits their visual needs.

Every available IOL option comes with some sort of compromise, and patients must have realistic visual expectations. Many patients have spoken with friends or family members who've undergone surgery, and often hear "I don't have to wear glasses." What these patients don't understand is that multiple variables



Premium IOLs, such as this Alcon Restor multifocal, allow correction of near vision. Note the concentric rings of the diffractive optics visible centrally.

involved in the preoperative work-up, including topography, biometry, IOL calculations, any presence of ocular pathology, and IOL selection, will directly contribute to individualized postoperative outcomes.

A 2012 study found modern cataract surgery outcomes to be within $\pm 0.50D$ of the target refraction in just 71% of cases.¹ With many patients electing to pay out of pocket for premium IOLs, expectations are at an all-time high. And as consistent as we believe our cataract surgeons can be, isn't it nice to know we can help to further perfect our patients' surgical outcomes? Let's review modern-day surgical techniques with phacoemulsification and clear corneal incisions.

Modern Cataract Removal

First, a paracentesis is created to provide access for the surgical instruments. Next, an injection of intracameral lidocaine and viscoelastic is placed into the anterior chamber to protect the corneal

endothelium, manipulate tissues and maintain space during surgery.

Then, a secure, clear corneal incision is made to achieve a stable anterior chamber, minimize surgically induced astigmatism, provide adequate instrument maneuverability and prevent post-op wound leaks. This is followed by a continuous, curvilinear capsulotomy (capsulorhexis) to enable hydrodissection, prevent posterior capsule tears and allow for the implantation, fixation and centration of the IOL within the capsular bag. Hydrodissection is performed to reduce zonular stress during phaco by mobilizing the nucleus and epinucleus. Next, phacoemulsification fractures the cataract's nucleus, which is followed by the removal of the remaining epinucleus and cortex with irrigation/aspiration.

Once complete, the IOL is implanted and centered within the capsular bag. Finally, the surgeon removes any remaining viscoelastic to minimize intraocular pressure spikes, then checks the clear corneal incision to ensure it is secure.

Be sure patients understand that many variables in the pre-op work-up (e.g., topography, biometry, IOL calculations, lens choice, any ocular pathology) influence outcomes. As a result, the approach will be highly individualized—and so will the results. Future columns will delve into how the technologies of modern cataract surgery address these patient-specific factors. Stay tuned! ■

1. Behndig A, Montan P, Stenevi U, et al. Aiming for emmetropia after cataract surgery: Swedish National Cataract Register study. *J Cataract Refract Surg.* 2012 Jul;38(7):1181-6.



To see a narrated video of this procedure, visit www.reviewofoptometry.com, or scan the QR code.

DOWNLOAD LAYAR APP FOR INTERACTIVE EXPERIENCE



First 150 app downloads and completed forms will be entered into a drawing for **FREE MEETING AND REGISTRATION VALUED AT \$495**



REVIEW OF OPTOMETRY

EDUCATIONAL MEETINGS OF CLINICAL EXCELLENCE



PAUL KARPECKI, OD
PROGRAM CHAIR


SAVE THESE DATES




SAN DIEGO, CA
APRIL 10-12



CHARLESTON, SC
JUNE 12-14



MAUI, HI
JULY 23-26



PHILADELPHIA, PA
NOVEMBER 6-8

NEW Includes hands-on workshop

For more information visit www.reviewofoptometry.com



*Approval pending

Up to 17 CE Credits
(COPE approval pending)

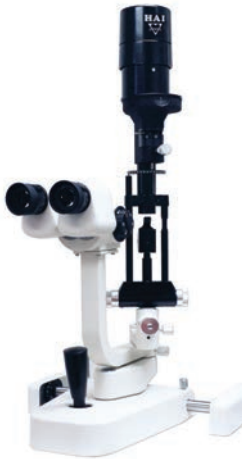Product Review

Diagnostic Equipment

Adjustable Slit Lamp

Hai Laboratories recently announced a new slit lamp, the Hai Elevate, that allows a comfortable exam experience for patients of all body types. The slit lamp's base is shorter than other devices to accommodate larger patients. The first point of contact between patient and tabletop can be raised to the upper chest so the patient can easily reach the chinrest.

Visit www.hailabs.com.



New Software for Spectralis

New spectral-domain optical coherence tomography software (Glaucoma Module Premium Edition, Heidelberg Engineering) can improve serial analysis of glaucoma patients and suspects by using anatomic registration to track progression. The program combines an anatomic positioning system (APS) and specific scan patterns to better analyze the optic nerve head, the retinal nerve fiber layer and ganglion cell layer to permit earlier diagnosis of glaucoma, the company says.

The APS detects the fovea and optic nerve head and uses them as landmarks to create a map of the eye and center on the optic nerve head.

Visit www.heidelbergengineering.com.

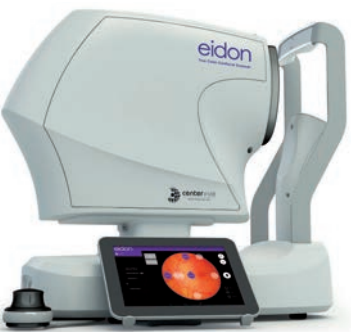True-Color Retinal Scanner

CenterVue recently announced 510(k) FDA clearance for its Eidon true-color confocal scanner for retinal disease detection.

The technology is the first to combine confocal imaging and white light illumination, the company says, for imaging of the central retina and periphery.

Eidon includes three imaging modes—true-color,

red-free and infrared—and automatic patient sensing, alignment and focus capabilities. It operates as a



standalone unit via a software application and can be used automatically or manually with or without pupil dilation.

Visit www.centervue.com.

Dry Eye Management

FDA Clears Punctal Occluder for Dry Eye

The FDA recently cleared Lacriversa's VeraPlug punctal occluder for use in treating chronic dry eye. Available in three sizes—small, medium and large—the VeraPlug is individually packaged and preloaded on a sterile, disposable inserter/dilator. The device includes a unique shaft design and low-profile dome to offer easy insertion and better patient comfort, the company says.

Visit www.lacriversa.com.



Contact Lenses

Patient Education Initiatives

Bausch + Lomb is launching consumer education efforts on proper contact lens wear and care using social media. The campaign encourages people to visit their eye doctor. The programs include:

- Bausch + Lomb Ultra Contact Lenses: Keeping Up With Today's Advances in Digital Technology
- Biotrue Oneday Contact Lenses: What's in Your Dryness Survival Kit?
- PureVision 2 Multi-Focal Contact Lenses for Presbyopia: Do Your Eyes Show Your Age?
- Biotrue Multi-purpose Solution: The Eye-opening Facts About Binge-Watching

Visit www.bausch.com.

Silicone Hydrogel Lens Enters US Market

CooperVision has announced wider distribution of Clariti 1-day silicone hydrogel contact lenses in the US market. This expansion is a result of CooperVision's recent acquisition of Sauflon Pharmaceuticals earlier this year.

The Clariti 1-day lenses are manufactured with a high water content for good oxygen transmissibility, says the manufacturer, and are available with sphere powers from +8.00D to -10.00D, a base curve of 8.6mm and a diameter of 14.1mm. Toric and multifocal options are also available.

Visit www.coopervision.com. ■

Meetings + Conferences

February 2015

- **6-8.** *2015 PBCOA Winter Seminar.* PGA National Resort & Spa, Palm Beach Gardens, FL. Hosted by: Palm Beach County Optometric Association. CE hours: 20. Key faculty: Carl Pelino, OD and Kimberly Reed, OD. To register, go to: www.pbcoa.org.
- **7-8.** *Destination CE.* Crowne Plaza Hotel, New Orleans, LA. Hosted by: Southern College of Optometry. CE Hours: 12. Key Faculty: Michael Gerstner, OD, FAAO; Whitney Hauser, OD; Mike Dorkowski, OD, FAAO; John Rumpakis, OD, MBA. To register, call 800-238-0180, ext. 5, or email ce@sco.edu.
- **13-15.** *54th Annual Contact Lens and Primary Care Congress.* Sheraton Kansas City Hotel at Crown Center. Kansas City, Mo. Hosted by: Heart of America Contact Lens Society. To register, go to www.hoacis.org.
- **13-17.** *Ski Vision 2015.* Westin Snowmass Luxury Resort. Snowmass Village, Co. Hosted by: AAO and UABSO. CE hours: 20. Key faculty: Murray Fingeret, OD, Leo Semes, OD, Jack Schaeffer, OD, Jack Cioffi, MD, David Friedman, MD, PhD, and more. To register, go to <http://skivision.com>.
- **19-22.** *115th TOA Annual Convention.* Downtown Austin Hilton Hotel, Austin. Hosted by: Texas Optometric Association. CE hours: 27. Key faculty: Ian Ben Gaddie, OD, FAAO, Steven Ferucci, OD, FAAO and Diana Shechtman, OD, FAAO. To register, call Sherry Balance at (512) 707-2020 or email sherry@txeyedoctors.com.
- **20-21.** *2015 Winter Conference.* Grand Summit Hotel Sugarloaf, USA, Carrabassett Valley, ME. Hosted by: Maine Optometric Association. To register, call (207) 237-2000.
- **26-28.** *Montana Optometric Association Winter Education Symposium Big Sky 2015.* Big Sky Resort, Big Sky, MT. Hosted by: Montana Optometric Association. CE hours: 13. Key faculty: Bruce Onofrey, OD, RPh, FAAO, FOGS; Curtis R. Baxstrom, OD. To register, go to www.mteyes.com.

March 2015

- **4-8.** *SECO 2015.* Georgia World Congress Center, Atlanta, Ga. Hosted by: SECO. To register, go to: www.seco2015.com.
- **20-22.** *Vision Expo East.* Jacob K. Javits Convention Center. New York, New York. Hosted by: International Vision Expo and Conference. To register, go to www.visionexpoeast.com.

To list your meeting, please send the details to:

Jack Persico, Editor-in-Chief
Email: jpersico@jobson.com
Phone: (610) 492-1006

Advertisers Index

For advertising opportunities contact:

Michele Barrett (215) 519-1414 or mbarrett@jobson.com

James Henne (610) 492-1017 or jhenne@jobson.com

Alcon Laboratories	19, 92
Phone	(800) 451-3937
Fax.....	(817) 551-4352
Allergan, Inc.	7, 8, 39, 40
Phone	(800) 347-4500
Bausch + Lomb	13, 14
Phone	(800) 323-0000
Fax.....	(813) 975-7762
Bausch + Lomb	25, 26
Phone	(866) 246-8245
.....	www.bausch.com
CooperVision	37, 91
Phone	(800) 341-2020
Fashion Optical Displays	15
Phone	(800) 824-4106
Fax.....	(530) 877-2013
Icare USA	10
Phone	(888) 389-4022
.....	www.icare-usa.com
Keeler Instruments	5
Phone	(800) 523-5620
Fax.....	(610) 353-7814
Lombart Instruments	21
Phone	(800) 446-8092
Fax.....	(757) 855-1232
US Ophthalmics	31, 33, 35
Phone	(888) 334-4640
.....	info@usophthalmic.com
.....	www.usophthalmic.com
Vision Source	17
Phone	(281) 312-1111
Fax.....	(281) 312-1153
.....	www.visionsource.com
Vistakon	2-3
Phone	(800) 874-5278
Fax.....	(904) 443-1252

This advertiser index is published as a convenience and not as part of the advertising contract. Every care will be taken to index correctly. No allowance will be made for errors due to spelling, incorrect page number, or failure to insert.

Merchandise Offered



**INNOVATIVE DISPENSARY
PLANNING & DESIGN**



**WIDEST SELECTION ON
PREMIUM DISPLAY PRODUCTS**

0% FINANCING FOR 36 MONTHS*

* for well qualified applicants only

ESSILOR'S FRAME DISPLAYS GROUP
Innovative Dispensary Planning & Design
– Authentic Craftsmanship & Integrity
Visit the website to view examples of what Frame Displays can create for you, and schedule a free consultation with one of the design professionals.

1-877-274-9300



Products and Services



The key to making Professional Healthcare Practice Financing simple. Whether you are buying, starting, or updating your practice, Access Healthcare capital is here to help you with your financing needs with one common goal. We want to help you maximize your cash flow. Let us help you unleash your Entrepreneurial Spirit:

Easy App Up To \$250,000

- 100% Financing plus working capital
- Simplified Processing for loans up to \$350,000
- Partnership Buy-In Programs
- Terms up to 15 years
- Application Only for equipment and technology purchases

www.accesshealthcarecapital.com • info@narxeye.com

Access Healthcare Capital • 1-888-727-4470 • P.O. Box 349, Gladwyne, PA 19035

Conference

**Become Board Certified by the
American Board of Optometry**

Exam is held each January & July.

Apply today at

americanboardofoptometry.org



Program certified by the National Commission for Certifying Agencies



RETINA RISK



Retina Risk™ is a revolutionary, clinically validated decision support system that enables eye-care professionals to **effectively educate** patients about their individualized risk for sight-threatening **diabetic retinopathy (STR)**

For a Free Trial go to

www.retinarisk.com

Merchandise Offered

EYEDESIGNS

BUILDING YOU A BETTER BUSINESS

SPACE PLANNING
INTERIOR DESIGN
DISPLAY INNOVATION
MANUFACTURING

WWW.EYEDESIGNS.COM
800.346.8890



FREE GIFT for the first 25 people to contact us.
Ref code OPT0115 exp. 01/31/15



FORM
FUNCTION

Style

opticaldisplays.com™

INFO@OPTICALDISPLAYS.COM TO REQUEST OUR CATALOG & DESIGN SERVICES CALL 610.489.7620

FREE GIFT for the first 25 people to contact us.
Ref code: OPT0115 exp. 01/31/15

Equipment and Supplies



OPTINOMICS
Pretesting Solutions

It's What the Best Pretest on!

(800) 522-2275
www.optinomics.com
sales@optinomics.com

Superior Quality • Competitive Pricing • Worldwide Shipping

WWW. **GuldenOphthalmics** .COM

Enter "AZ16" at checkout for 15% off your order!



Offer valid online or by phone: 800-659-2250

Eye Models

- Great for patient demonstrations
- Astigmatism
- Cataract/IOL
- Cornea disorders
- Floaters & more!

Prisms & Prism Bars

- Hand-made since 1938
- Laser calibrated for accuracy
- Gulden is the only manufacturer of the patented EZ View™ Prism Bar
- Prism re-polish service available

Occluders

- Large assortment:
- Maddox/Occluders
- Clip-on Occluders
- Spielmanns
- Lorgnettes & more online!



@GuldenEye

Gulden's **New and Innovative** Products are Proudly Made in the U.S.A.



REVIEW

OF OPTOMETRY

Targeting Optometrists?

CLASSIFIED ADVERTISING WORKS

Contact us today for classified advertising:
Toll free: 888.498.1460 • E-mail: sales@kerhgroup.com

kerh

group



Continuing Medical Education



**American Academy of Optometry
New Jersey Chapter**
13th Annual Educational Conference
April 22-26, 2015
Myrtle Beach, South Carolina
Hilton Embassy Suites at Kingston Plantation

Dr. Mark Friedberg, M.D.
Founding Editor of the
Wills Eye Manual

Dr. Alan Kabat, OD., F.A.A.O.

**16 HOURS
COPE CE**

Registration: \$475.00
One, Two or Three Bedroom Suites
Accommodations Include a Daily Breakfast Buffet
and Evening Cocktail Reception
PACK YOUR CLUBS!
Golf details to follow.
For Accommodation and Additional Information, contact:
Dennis H. Lyons, OD, F.A.A.O.
Phone: (732) 920-0110
E-Mail: dhl2020@aol.com

REVIEW
OF OPTOMETRY

Do you have CE Programs?

**CONTACT US TODAY
FOR CLASSIFIED ADVERTISING**
Toll free: 888-498-1460
E-mail: sales@kerhgroup.com

Continuing Education

**EAGLE EYE
SEMINARS**

JULY 18-25, 2015
Erik Schmidt OD, FAAO

JULY 16-23, 2016
Nathan Lighthizer OD, FAAO

**WORLD CLASS MUSKY,
WALLEYE, SMALLMOUTH
FISHING**

- Eagle Lake Island lodge
- Eagle Lake Ontario
- 12 hours of CE

Contact Dean Springer OD
SPRINGEREYE@CHIBARDUN.NET
Phone: 715-637-2020

**31st Annual
Palm Beach Winter Seminar**
February 6th to 8th, 2015

PBCOA PALM BEACH COUNTY OPTOMETRIC ASSOCIATION

www.PBCOA.org

PGA National Resort & Spa
400 Avenue of the Champions
Palm Beach Gardens, FL 33418

Featured Speakers:
Carlo Pelino, O.D., F.A.A.O.
Kimberly Reed, O.D., F.A.A.O.

Classes include:
*20 hours COPE approved CE including 8 hours TQ
*Florida Jurisprudence
*Medical Errors

Exhibit Hall:
*over 25 industry supporters
We're looking forward to seeing you!
Rooms are filling up fast, book now!

Conference registration www.pbcoa.org
Room registration link
Tinyurl.com/2015PBWS

Software

Take a closer look...

**at Eyecom for your
electronic health record needs!**

tablet compliant
share patient data securely
over 25 years experience
cloud-based access anytime, anywhere




Eyecom³ EHR
WEB-BASED OPTOMETRIC SOFTWARE

800.788.3356 www.eyecom3.com

**Medical Facility
Optometrists**

The American Board of Certification in Medical Optometry is utilized at accredited medical facilities to verify specialist-level competence in medical optometry. ABCMO certifies specialized competence of a higher level than that required for licensure and general practice. Visit www.abcmo.org to learn why medical facilities require board certification of specialists and why only ABCMO board certification in the specialty of medical optometry is accepted. Questions? myers.kenj@gmail.com.

NOTICE: After August 1, 2003, all applicants for ABCMO board certification must have completed an ACOE residency in medical optometry and passed the Advanced Competence in Medical Optometry examination of the NBEO.

www.abcmo.org

Scientia est Potentia



Contact us today
for classified advertising:
Toll free: **888-498-1460**
E-mail: sales@kerhgroup.com

Professional Opportunities

**FULL TIME/RELIEF
DOCTOR
FORT WORTH, TX**

Position available for full time/relief doctor in Fort Worth, TX for large group practice, 5K signing bonus, excellent salary, paid vacations, & paid professional liability insurance.

**40 HOUR WORK WEEK WITH
NO SUNDAYS**

Call Angela at
(817) 738-6672 x11
or e-mail curricular vitae to
amonk@luckoptical.com

WORCESTER

FT OD NEEDED

Busy practice with two ophthalmologists and two optometrists seeks FT optometrist. Saturdays and one late evening required. Competitive compensation and benefits.

Contact: Michele Rickert
Phone: 508-853-2020
Email: rickertmi@aol.com

Place Your
Ad Here!

Toll free: 888-498-1460

E-mail: sales@kerhgroup.com

STAFF OPTOMETRIST

Bard Optical is a leading Midwest vision care organization in business for over 70 years and we are still growing. The company is based in Peoria, IL with 20 retail offices throughout the central Illinois area, as far north as Sterling and as far south as Jacksonville. Once again this year we were named to the Top 50 Optical Retailers in the United States by Vision Monday - currently ranking 37th. A progressive optometric staff is vital to the continued growth of our organization whose foundation is based on one-on-one patient service. We are currently accepting CV/resumes for optometrists focused on full scope primary medical patient care. The candidate must have an Illinois license with therapeutics. The practice includes (but is not limited to) general optometry, contact lenses, and geriatric care. Salaried, full-time positions are available with excellent growth programs and benefits. Some part-time opportunities may be available also. Please email your information to hr@bardoptical.com or fax to 309-693-9754. Mailing address if more convenient is Bard Optical, Attn: HR, 8309 N Knoxville Avenue, Peoria, IL 61615. Ask about opportunities within Bard Optical. We have openings in several existing and new offices opening soon in central Illinois.

Bard Optical is a proud Associate Member of the Illinois Optometric Association.



www.bardoptical.com

Practice For Sale



Do you have
CE Programs?

**CLASSIFIED
ADVERTISING
WORKS**

Contact us today for
classified advertising:
Toll free: 888-498-1460
E-mail: sales@kerhgroup.com



**PRACTICE SALES
& APPRAISAL**

Expert Services for:

- Buying or Selling a Practice
- Practice Appraisal
- Practice Financing
- Partner Buy-in or Buy-out

Call for a Free Consultation
(800) 416-2055

www.TransitionConsultants.com

**OPTOMETRIC PRACTICE FOR SALE
NORTHEASTERN PA**

Very Successful ongoing optometric practice for sale in Northeastern PA. The practice is grossing 600K/yr. This practice is one of a kind with a very large and broad patient base and large contact lens base. The practice services many vision care programs that lends to its success, along with a full complement of direct paying patients. I will be willing to work in the practice.

Serious replies only.

Email: resume6@kerhgroup.com
WITH COMPLETE NAME AND CONTACT INFO



Practice Sales • Appraisals • Consulting
www.PracticeConsultants.com

**PRACTICES FOR SALE
NATIONWIDE**

Visit us on the Web or call us to learn more about our company and the practices we have available.

info@PracticeConsultants.com

800-576-6935

www.PracticeConsultants.com



Do you have
CE Programs?

CONTACT US TODAY
FOR CLASSIFIED ADVERTISING
Toll free: 888-498-1460
E-mail: sales@kerhgroup.com



Her Vision is on the Bubble

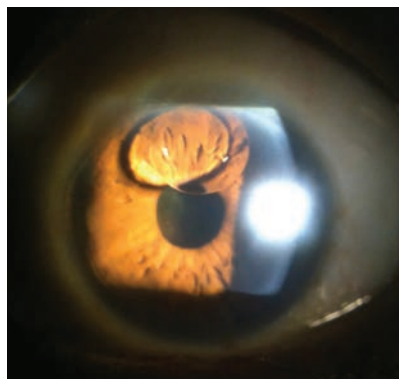
By Andrew S. Gurwood, OD

History

A 47-year-old black female presented with a chief complaint of blurry vision in her right eye. She explained that her vision had been poor since she underwent retinal reattachment surgery secondary to advanced proliferative diabetic retinopathy (PDR) OS six months earlier.

Her ocular history was remarkable for PDR OU, which was treated with panretinal photocoagulation (PRP) and vascular endothelial growth factor (VEGF) inhibitor injections; clinically significant macular edema OU, which was treated with focal laser and VEGF therapy; and tractional retinal detachment OS, which was repaired by a retina specialist six months prior.

Her systemic history was remarkable for hypertension and type 1 diabetes mellitus, which were properly controlled with valsartan/hydrochlorothiazide, metformin, glipizide and insulin.



This patient with a history of proliferative diabetic retinopathy reported poor vision in her left eye following retinal reattachment surgery. What is the correct diagnosis?

She reported no known allergies of any kind.

Diagnostic Data

Her best-corrected visual acuity measured 20/50 OD and 20/100 OS at distance and near. Her external examination uncovered an afferent pupillary defect OS, with a decompensated esophoria second-

ary to unsustainable fixation. She was pseudophakic OS, with posterior capsular opacification.

Intraocular pressure measured 15mm Hg OU. Dilated fundus evaluation revealed areas of dense PRP OU, evidence of focal laser to both maculae, and an attached and flat retina OS with no new neovascular fronds or retinal breaks.

Your Diagnosis

How would you approach this case? Does this patient require any additional tests? What is your diagnosis? How would you manage this patient? What's the likely prognosis?

To find out, please visit *Review of Optometry Online*, www.reviewofoptometry.com. Click on the cover icon, and then click "Diagnostic Quiz" under this month's table of contents. ■

Thanks to Peter J. Perno, BS, a fourth-year student at Salus University in Elkins Park, Pa., for his contributions to this case.

Retina Quiz Answers (from page 72): 1) c; 2) c; 3) c; 4) d.

Next Month in the Mag

February features our Innovations in Eye Care Report.

Topics include:

- *Glaucoma: Beyond the Optic Nerve*
- *The Science of Dry Eye and Allergy*

- *Will ODs Treat Wet AMD Someday?*
- *Have You Kept Up With These Advances in Contact Lens Materials?*
- *Optometric Study Center: Understanding the Efferent Visual System (earn 2 CE credits)*

REVIEW OF OPTOMETRY (ISSN 0147-7633) IS PUBLISHED MONTHLY, 12 TIMES A YEAR BY JOBSON MEDICAL INFORMATION LLC, 100 AVENUE OF THE AMERICAS, NEW YORK, NY 10013-1678. PERIODICALS POSTAGE PAID AT NEW YORK, NY AND ADDITIONAL MAILING OFFICES. POSTMASTER: SEND ADDRESS CHANGES TO REVIEW OF OPTOMETRY, PO BOX 81, CONGERS, NY 10920-0081. SUBSCRIPTION PRICES: US: ONE YEAR \$56; TWO YEARS \$97, CANADA: ONE YEAR \$88, TWO YEARS \$160, INT'L: ONE YEAR \$209, TWO YEARS \$299. FOR SUBSCRIPTION INFORMATION CALL TOLL-FREE (877) 529-1746 (USA); OUTSIDE USA, CALL (845) 267-3065. OR EMAIL US AT REVOPOTOMETRY@CAMBEYWEST.COM. PUBLICATIONS MAIL AGREEMENT NO: 40612608. CANADA RETURNS TO BE SENT TO BLEUCHIP INTERNATIONAL, P.O. BOX 25542, LONDON, ON N6C 6B2.



All eyes deserve clariti.



clariti 1 day—now available for practices everywhere.

The world's first and only family of silicone hydrogel daily disposable contact lenses designed *for every patient type*—sphere, toric and multifocal.

**High Oxygen
Transmissibility**

**High Water
Content**

**Low
Modulus**

**UV
Protection**

**Affordable
Upgrade**

Now you can prescribe all of your patients with healthy, comfortable, affordable silicone hydrogel 1 day lenses—which will make all eyes very happy indeed.

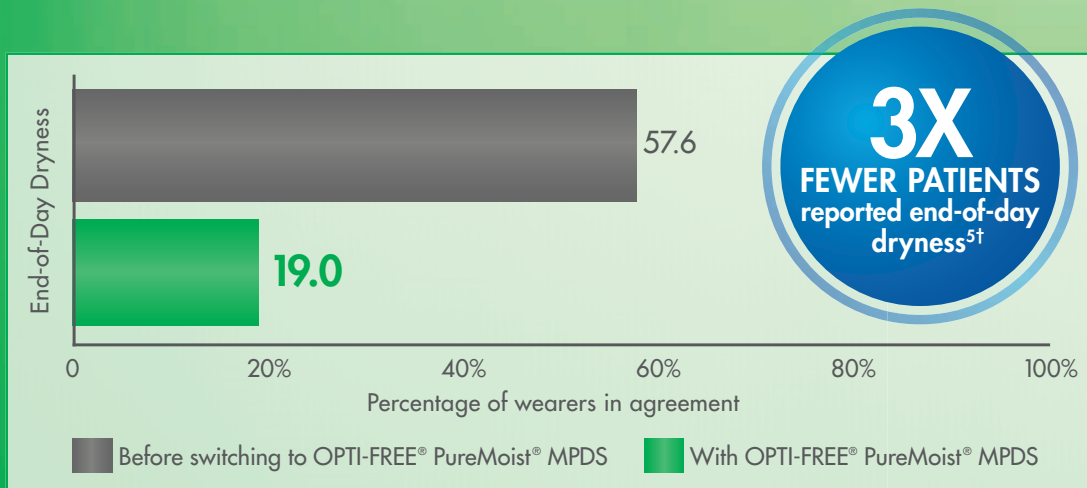

To learn more, contact your CooperVision representative today or visit **CooperVision.com/practitioner**.



CooperVision®
Live Brightly.®

THIS IS WHY OPTI-FREE® PureMoist® Solution allows patients to wear contact lenses MORE COMFORTABLY¹ AND LONGER each day.²

The HydraGlyde® Moisture Matrix attaches and forms a hydrophilic environment across the surface of the lens—providing moisture from morning 'til night.²⁻⁴



[†]Based on a global survey of 10,611 contact lens wearers who tried OPTI-FREE® PureMoist® for two weeks.

Talk to your patients about the benefit of OPTI-FREE® brand products. Learn more at MYALCON.COM



PERFORMANCE DRIVEN BY SCIENCE™

References: 1. Campbell R, Kame G, Leach N, et al. Clinical benefits of a new multipurpose disinfecting solution in silicone hydrogel and soft contact lens users. *Eye & Contact Lens*. 2012;38(2):93-101. 2. Alcon data on file, 2011. 3. Lally J, Ketelson H, Borazjani R, et al. A new lens care solution provide moisture and comfort with today's contact lenses. *Optician*. 2011;241:42-46. 4. Davis J, Ketelson HA, Shows A, Meadows DL. A lens care solution designed for wetting silicone hydrogel materials. ARVO Meeting Abstracts. 2012;38(2):93-101. 5. Lemp J, Kern JR. Results from global survey of contact lens-wearer satisfaction with OPTI-FREE® PureMoist® MPDS. *Clinical Optometry*. 2013;5:39-46.

Alcon
a Novartis company

© 2014 Novartis 4/14 OPM14001JAD