

'Tis the Season to Be... Careful, *Page 68*

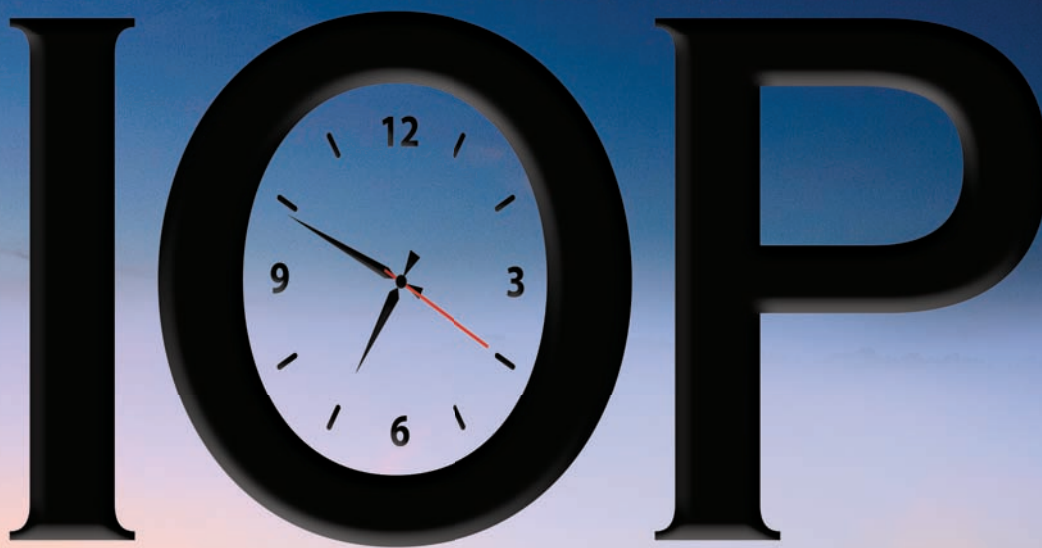REVIEW[®] OF OPTOMETRY

December 15, 2014

www.reviewofoptometry.com

37th Annual Technology Report

A DAY IN THE LIFE OF



It waxes, wanes and often spikes, creating patterns that currently go undetected. Can 24-hour monitoring devices reveal its secrets? *Page 26*

» OCT TESTING RECEIVES A 'NICE COMPLIMENT,' *PAGE 32*

» TECHNOLOGY SURVEY: WHAT YOU HAVE YOUR EYES ON, *PAGE 40*

ALSO INSIDE:

- HOW TO FIND AND KEEP FRONT DESK STAFF, *PAGE 47*
- CASE REPORT: IS THIS BIG VESSEL A BIG PROBLEM? *PAGE 51*

INSIDE — FREE CE CREDIT
SUCCESSFUL COMANAGEMENT OF OCULAR
SURGERY PATIENTS, *PAGE 43*

NEW! -2.75 cyl now available

Unsurpassed in
COVERAGE

Unbeaten in
COMFORT


THE WIDEST PARAMETER COVERAGE FOR SPHERICAL
AND ASTIGMATIC EYES

Now with the **first** and **only** silicone hydrogel toric lens with -2.75 cyl readily available,* ACUVUE® OASYS® Brand Contact Lenses provides coverage for 98% of astigmatic and spherical patients.

NEVER BEEN BEATEN ON COMFORT BY ANY LEADING
MONTHLY LENS

Based on a review of published clinical studies and those registered on clinicaltrials.gov with comfort as an end point.





Feel confident that more of your patients
are covered and comfortable with
ACUVUE® OASYS® Brand



ACUVUE® Brand Contact Lenses are indicated for vision correction. As with any contact lens, eye problems, including corneal ulcers, can develop. Some wearers may experience mild irritation, itching or discomfort. Lenses should not be prescribed if patients have any eye infection, or experience eye discomfort, excessive tearing, vision changes, redness or other eye problems. Consult the package insert for complete information. Complete information is also available from VISTAKON® Division of Johnson & Johnson Vision Care, Inc., by calling 1-800-843-2020 or by visiting www.acuvueprofessional.com.

*Available without needing to place a special order. Contact Lens Manufacturer Published Parameters, June 2014.
ACUVUE®, ACUVUE® OASYS®, HYDRACLEAR® and VISTAKON® are trademarks of Johnson & Johnson Vision Care, Inc.
© Johnson & Johnson Vision Care, Inc. 2014 ACU-A44718 November 2014

ACUVUE®
OASYS®
BRAND CONTACT LENSES

FOR ASTIGMATISM

IN THE NEWS

Valeant Pharmaceuticals International has acquired Nicox's US diagnostics subsidiary **Nicox Inc.**, in a deal worth up to \$20 million, effective immediately. Meanwhile, it appears that **Valeant** has dropped its hostile takeover bid to acquire **Allergan**, as **Actavis** will now acquire Allergan in a transaction valued at approximately \$66 billion. The combination of Actavis and Allergan will create one of the **top 10 global pharmaceutical companies** by sales revenue, with combined annual pro forma revenues of more than \$23 billion anticipated in 2015. This deal is expected to close in the second quarter of 2015.

The most commonly used class of **HIV/AIDS** drugs could be repurposed to treat **age-related macular degeneration (AMD)** because of a previously undiscovered intrinsic and inflammatory activity those drugs possess, researchers say. **Nucleoside reverse transcriptase inhibitors (NRTIs)** prevented retinal degeneration in a mouse model of dry AMD by blocking an innate immune pathway called the inflammasome, according to a recent study in *Science*. NRTIs were also effective in other disease models that share common signaling pathways with the dry AMD model, including **wet AMD** and **graft-versus-host disease**.

For the Record

The article "Hormones and Ocular Health," in the November 2014 issue, did not include the names of two co-authors, Denise Goodwin, OD, and Lorne Yudcovitch, OD, MS. *Review* regrets the error.

Michigan Law Prohibits Online Refraction

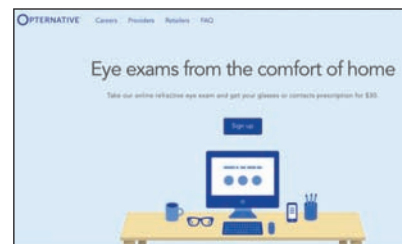
Law bans websites and robo-kiosks from providing spectacle prescriptions. **By John Murphy, Executive Editor**

This winter, a website that promises online refractive eye exams will debut. But Michigan residents won't be able to get eyeglass prescriptions from it, thanks to the Eye Care Consumer Protection Law (Senate Bill 853), which went into effect September 30. This law prohibits automated kiosks and websites from dispensing glasses or contact lens prescriptions.

Sen. Rick Jones introduced the bill because an in-office eye exam revealed an asymptomatic but vision-threatening eye disease in his wife. "The kiosk machine or robo-doctor cannot detect glaucoma, macular degeneration, diabetes or, in the case of my wife, a bleeding retina," he wrote. "My wife had no pain or blurred vision. The optometrist saved her vision by detecting the bleeding retina in time to have an ophthalmologist save her vision."

Sen. Jones added, "We did not ban the machine. They simply cannot give out a prescription ... [But] if people only use machines for their eye exams, then we will have more blind people on welfare. Taxpayers will pay the bill."

Paul Anton Hodge, OD, president of the Michigan Optometric Association, says that the law "is viewed as a public health issue by optometry and ophthalmology in Michigan, and the legislative and executive branches agreed that the public will be better served with this



Online refraction website promises: "Eye exams from the comfort of home."

legislation in effect."

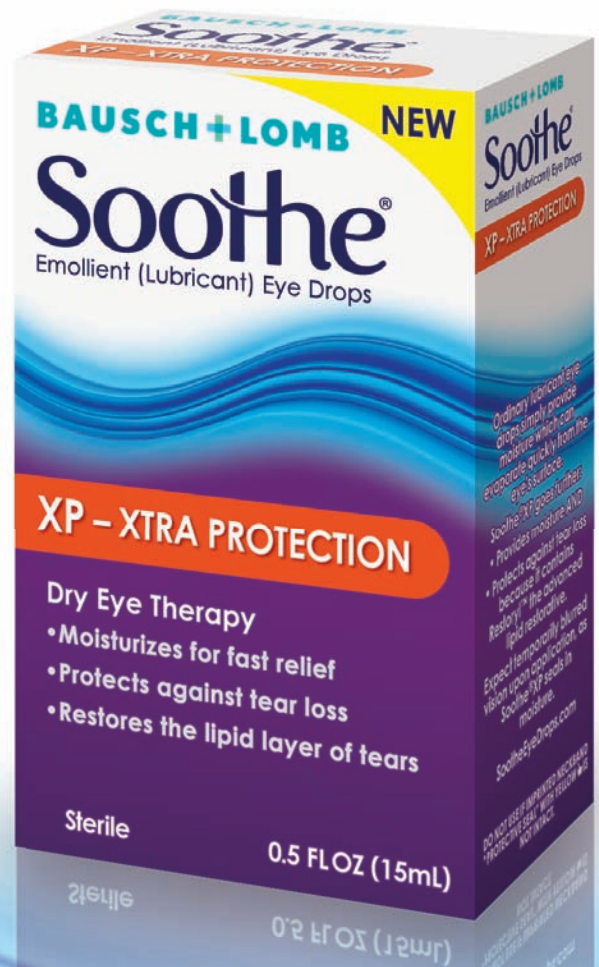Specifically, the law ties refraction to an ocular health exam such that a valid eyeglass or contact lens prescription can only come from a comprehensive eye examination.

Dr. Hodge adds, "If other states desire to pass similar legislation, they are encouraged to read our bill, which seeks to protect public health when it comes to eye and vision care."

Opternative, the website that promises FDA-compliant \$30 refractive eye exams "from the comfort of home," says that each prescription is "reviewed and signed by an eye care professional in your state." The online refractive site also advises customers to "visit an eye care professional's office for an eye health exam once every two years, as recommended by the American Optometric Association. After taking Opternative's refractive eye exam, we'll help you locate an optometrist or ophthalmologist in your area."

RELIEF AT THE MAIN SOURCE of dry eye symptoms

Target Lipid Layer Deficiency:
Soothe[®] XP
With Restoryl[®] Mineral Oils



Recommend Soothe XP as your first choice for dry eye patients.
To request samples, please call 1-800-778-0980.

Now available at major retailers nationwide.

Distributed by Bausch + Lomb, a Division of Valeant Pharmaceuticals North America LLC, Bridgewater, N.J. © 2014 Bausch & Lomb Incorporated. Soothe and Restoryl are trademarks of Bausch & Lomb Incorporated or its affiliates. All other brand/product names are trademarks of their respective owners. PNS07316 US/SXP/14/0006

BAUSCH + LOMB
See better. Live better.

Researchers Reverse Diabetes in Mice

Verapamil, a commonly prescribed blood pressure medication, has been shown to slow and even reverse cell damage caused by diabetes.

According to a research team at the University of Alabama (UAB), diabetic mice placed on calcium channel blocker therapy exhibited signs of complete disease reversal. Following future clinical testing, the researchers believe that verapamil could be used to effectively cure both type 1 and type 2 diabetes mellitus in humans.

“We want to find new drugs—different from any current diabetes treatments—that can help halt the growing, worldwide epidemic of diabetes and improve the lives of those affected by this disease,” says Anath Shalev, MD, director of UAB’s Comprehensive Diabetes Center and principal investigator of the verapamil clinical trial.

“Finally, we have reason to believe that we are on the right track.”

So, how could this information possibly be translated to primary eye care? Diabetes care expert, A. Paul Chous, OD, believes that calcium channel blockers, such as verapamil, could potentially play a significant role in reducing the risk and progression of diabetic retinopathy as a result of normalized blood glucose levels.

“The mouse models show that verapamil blocks an enzyme [TXNIP] that is associated with increased beta cell autoimmunity,”

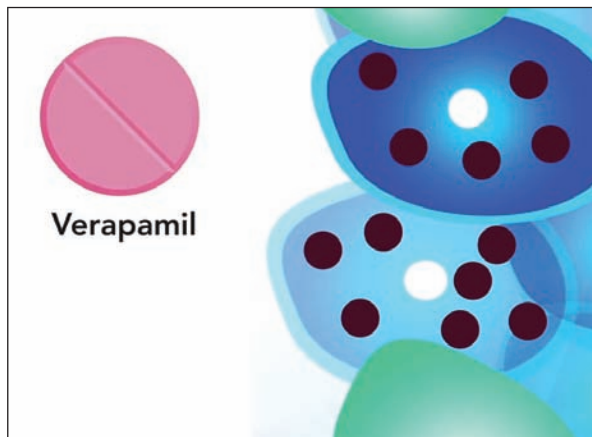


Image: UAB Comprehensive Diabetes Center

Verapamil reduces the harmful protein TXNIP (black dots) in insulin-producing human islet beta cells. Reduction of TXNIP restores beta cell activity, effectively reversing diabetes.

Dr. Chous says. “An important unanswered question is: ‘How long after initiation of beta cell autoimmunity might calcium channel blocking agents be effective?’”

In the past, researchers believed all beta cells ultimately were compromised by longstanding disease, Dr. Chous says. However, recent work has demonstrated that some beta cells survive—even in cases of long-term type 1 diabetes mellitus.

In the short term, however, “I think it is unlikely this [verapamil] is a therapy ODs will prescribe ... until long-term trials are completed,” Dr. Chous says.

Still, it’s interesting that “there is also evidence that calcium channel blocking agents may be neuroprotective in glaucoma, and this may also spill over into diabetic retinopathy,” Dr. Chous adds.

Human testing of verapamil therapy on patients with newly diagnosed type 1 diabetes mellitus is scheduled to begin at UAB in January 2015. So far, the number of volunteers for the human trial has been overwhelming, UAB says.

Increased Surveillance Needed for Microbial Keratitis

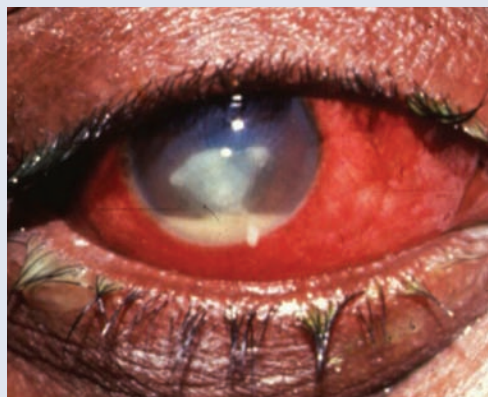


Photo: Joel A. Sliem, OD

Nearly one million clinical visits for keratitis occur annually in the United States, according to a comprehensive study conducted by researchers at the Centers for Disease Control and Prevention.

The CDC experts found that Americans made an estimated 930,000 doctor’s office and outpatient clinic visits and 58,000 emergency department visits for keratitis or contact

lens disorders. These cost an estimated \$175 million in direct health care expenditures and account for over 250,000 hours of clinician time annually. The majority (76.5%) of these visits resulted in antimicrobial prescriptions.

The report concluded: “Keratitis associated with poor contact lens hygiene is preventable” and “increased surveillance capacity is needed for microbial keratitis, in particular data from optometrist visits.”




MA1 MA2 MA3 MA4




MA5 MA6 MA7 MA8



MD 1 MD 2 MD 3 MD 4



MD 5 MD 6 MD 7 MD 8



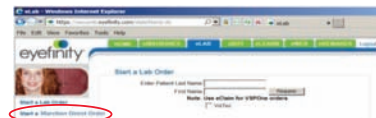CHANGE

MARCHON DIRECT
is changing the industry
with fast and easy ordering
of frames with lenses.

When you order from
Marchon Direct receive
30% OFF UNITY LENSES
and **FREE SHIPPING.**

Using eyefinity.com

- Step 1: Click on the "ebuy" tab and check frame availability.
- Step 2: Click on "elab" tab to start a Marchon Direct order.
- Step 3: Click on start a "Marchon Direct" order.



Using Marchon's MVP site

- Step 1: Create frame order as usual.
- Step 2: Click on the shopping bag. At the far right is a button for "order lens". Click on it.
- Step 3: Rx form will open. Type in Rx, measurements, select coatings, lens type, etc. Lens Material is a mandatory field.
- Step 4: Click the "Save" button. To see if the Rx saved, just click "Order Lens" again. The information saved will appear.



Your vending machine
for frames with lenses.

Low Vision Referrals Are Too Low, Study Says

How do you define low vision? The lack of a clear definition of this disorder may be discouraging referrals to low vision specialists, according to a poster presented at the recent American Academy of Optometry 2014 meeting by students from the New England College of Optometry.

“One of the major points our results suggest is that there is a discrepancy between what primary care optometrists and low vision specialists define as low vision,” says Anne Bertolet.

She and other optometry students—Emily Humphreys, Hannah Woodward, Jessica Zebrowski, Inna Kreydin and Jenna Adelsberger—focused on identifying patient barriers to low vision treatment. These include economic status, physical location relative to an office and a lack of access to relevant information.

Most of the low vision specialists they interviewed defined low vision as “any visual impairment that can



Photo: New England College of Optometry

Students from New England College of Optometry, along with faculty advisor Richard Jamara, OD, stand by their low vision research.

hinder quality of life or daily functioning.”

But primary care optometrists were more varied in their definitions, with some using a functional definition and others using one of a number of best-corrected visual acuity-based definitions.

These differing opinions mean it’s likely some patients who could benefit from low vision services are not getting the referral they need, Ms. Bertolet explained. Thus, “developing a standardized definition would be advantageous to help normalize the referral and treatment processes.” ■

Drs. Melton and Thomas Receive Educator Award



At the American Academy of Optometry 2014 meeting in Denver, Donald Korb, OD (center), congratulates Randall K. Thomas, OD, MPH, and Ron Melton, OD, upon receiving the Vincent Ellerbrock Clinician Educator Award. Drs. Thomas and Melton are the authors of *Review of Optometry's* annual “Clinical Guide to Ophthalmic Drugs.”

REVIEW[®] OF OPTOMETRY

BUSINESS OFFICES

11 CAMPUS BLVD., SUITE 100
NEWTOWN SQUARE, PA 19073

CEO, INFORMATION SERVICES GROUP

MARC FERRARA
(212) 274-7062 • MFERRARA@JOBSON.COM

PUBLISHER

JAMES HENNE
(610) 492-1017 • JHENNE@JOBSON.COM

SALES MANAGER, SOUTHEAST, WEST

MICHELE BARRETT
(610) 492-1014 • MBARRETT@JOBSON.COM

VICE PRESIDENT, OPERATIONS

CASEY FOSTER
(610) 492-1007 • CFOSTER@JOBSON.COM

VICE PRESIDENT, CLINICAL CONTENT

PAUL M. KARPECKI, OD, FAAO
PKARPECKI@JOBSON.COM

PRODUCTION MANAGER

SCOTT TOBIN
(610) 492-1011 • STOBIN@JOBSON.COM

SENIOR CIRCULATION MANAGER

HAMILTON MAHER
(212) 219-7870 • HMAHER@JHIHEALTH.COM

CLASSIFIED ADVERTISING

(888) 498-1460

SUBSCRIPTIONS

\$56 A YEAR, \$88 (US) IN CANADA,
\$209 (US) IN ALL OTHER COUNTRIES.

SUBSCRIPTION INQUIRIES

(877) 529-1746 (US ONLY);
OUTSIDE US, CALL (847) 763-9630

CIRCULATION

PO Box 2025
SKOKIE, IL 60076
TEL: (TOLL FREE) 1-877-529-1746
OUTSIDE US: (847)763-9630
FAX: (847)763-9631



CEO, INFORMATION SERVICES GROUP

MARC FERRARA

SENIOR VICE PRESIDENT, OPERATIONS

JEFF LEVITZ

SENIOR VICE PRESIDENT, HUMAN RESOURCES

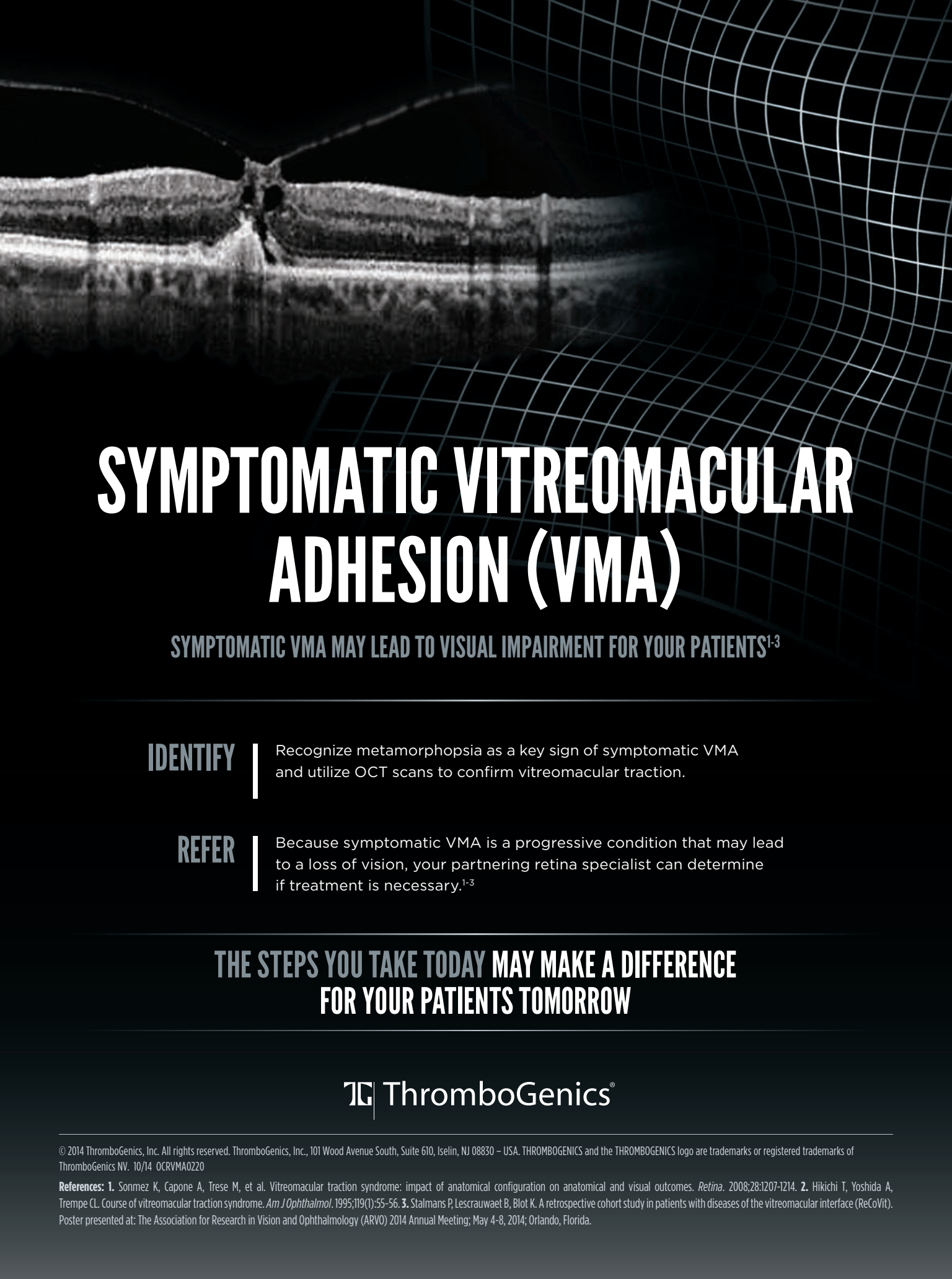
LORRAINE ORLANDO

VICE PRESIDENT, CREATIVE SERVICES & PRODUCTION

MONICA TETTAMANZI

VICE PRESIDENT, CIRCULATION

EMELDA BAREA



SYMPTOMATIC VITREOMACULAR ADHESION (VMA)

SYMPTOMATIC VMA MAY LEAD TO VISUAL IMPAIRMENT FOR YOUR PATIENTS¹⁻³

IDENTIFY

Recognize metamorphopsia as a key sign of symptomatic VMA and utilize OCT scans to confirm vitreomacular traction.

REFER

Because symptomatic VMA is a progressive condition that may lead to a loss of vision, your partnering retina specialist can determine if treatment is necessary.¹⁻³

THE STEPS YOU TAKE TODAY MAY MAKE A DIFFERENCE
FOR YOUR PATIENTS TOMORROW

 ThromboGenics®

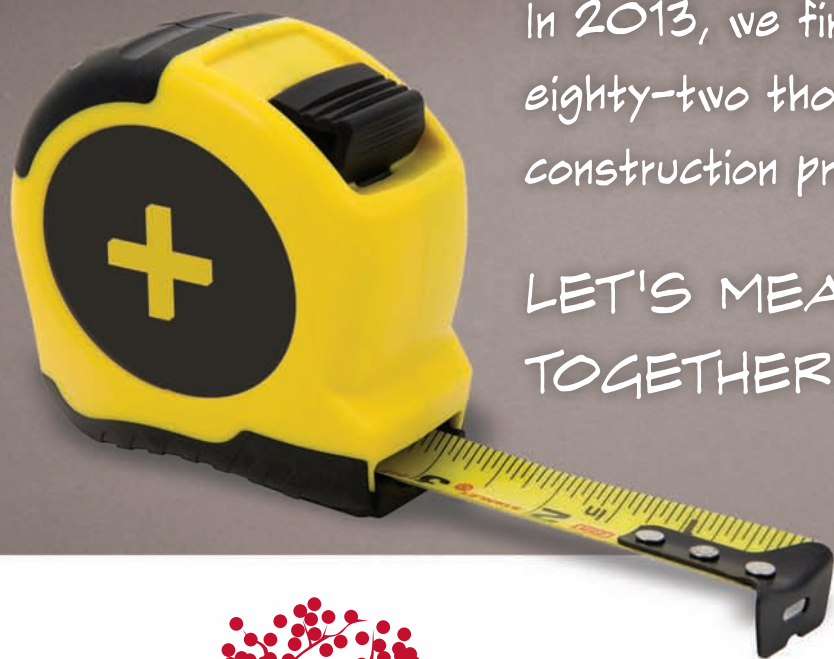© 2014 ThromboGenics, Inc. All rights reserved. ThromboGenics, Inc., 101 Wood Avenue South, Suite 610, Iselin, NJ 08830 – USA. THROMBOGENICS and the THROMBOGENICS logo are trademarks or registered trademarks of ThromboGenics NV. 10/14 OCRVMA0220

References: 1. Sonmez K, Capone A, Trese M, et al. Vitreomacular traction syndrome: impact of anatomical configuration on anatomical and visual outcomes. *Retina*. 2008;28:1207-1214. 2. Hikichi T, Yoshida A, Trempe CL. Course of vitreomacular traction syndrome. *Am J Ophthalmol*. 1995;119(1):55-56. 3. Stalmans P, Lescauwaet B, Blot K. A retrospective cohort study in patients with diseases of the vitreomacular interface (ReCoVit). Poster presented at: The Association for Research in Vision and Ophthalmology (ARVO) 2014 Annual Meeting; May 4-8, 2014; Orlando, Florida.

UP TO 100% FINANCING • COMPETITIVE INTEREST RATES • GROUND UP CONSTRUCTION

282,749

SQUARE FEET, AND COUNTING...



In 2013, we financed over two hundred eighty-two thousand square feet of construction projects.

LET'S MEASURE SUCCESS TOGETHER!



Jon Voeller
910.685.7745

Mike Montgomery
910.798.1215



LIVE OAK BANK
Lending More than Capital

Contents

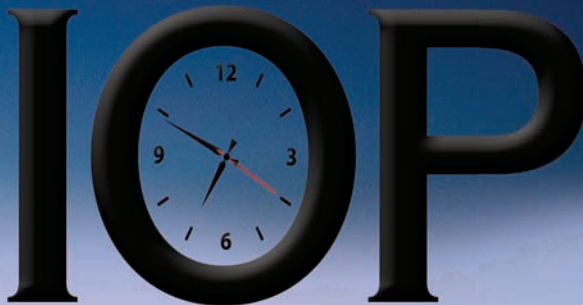Review of Optometry December 2014

37th Annual Technology Report



26

A DAY IN THE LIFE OF



It waxes, wanes and often spikes, creating patterns that currently go undetected. Can 24-hour monitoring devices reveal its secrets?

By **Renee Buddle, Senior Associate Editor**

32 OCT Testing Receives a 'Nice Complement'

Today, a multitude of diagnostic technologies can support glaucomatous, corneal and posterior segment findings detected via optical coherence tomography.

By **Amanda S. Legge, OD**

40 Technology Survey: What You Have Your Eyes On

Optometrists are earning more across the board, but private practice is 'the way to prosperity.'

By **John Murphy, Executive Editor**

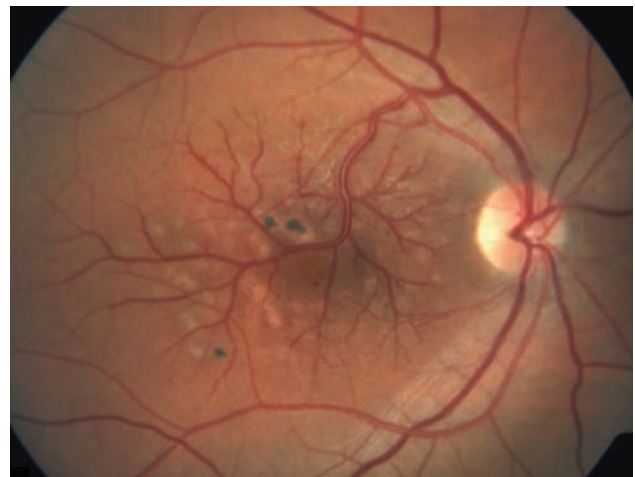
47 How to Find and Keep Front Desk Staff

From personality traits to ongoing training, these essential skills and staffing tips will help you hire and retain the best person for this important role. By **Jane Cole, Contributing Editor**



51 Is this Big Vessel a Big Problem?

Our patient presented with evidence of a congenital retinal macrovessel. How significant is this finding, and how should he be managed? By **Richard Zimbalist, OD**

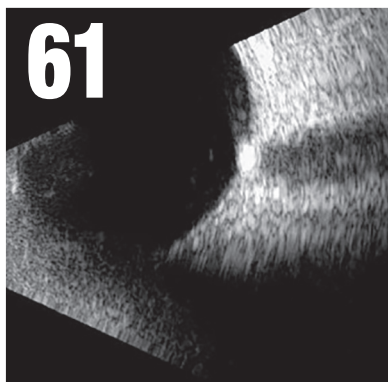


Departments

Review of Optometry December 2014

- 4** News Review
- 17** Letters to the Editor
- 18** Outlook
Technical Difficulties
JACK PERSICO
- 20** Chairside
Thanky Panky
MONTGOMERY VICKERS, OD
- 22** Coding Abstract
X Marks the Spot
JOHN RUMPAKIS, OD, MBA
- 58** Cornea + Contact Lens Q+A
An Eye on Cancer Treatment
JOSEPH P. SHOVLIN, OD
- 61** Glaucoma Grand Rounds
Don't Know Much 'Bout History
JAMES L. FANELLI, OD
- 65** Retina Quiz
Take a Shot at this Bull's Eye
MARK T. DUNBAR, OD
- 68** Therapeutic Review
'Tis the Season to Be... Careful
ALAN G. KABAT, OD
JOSEPH W. SOWKA, OD
- 70** Research Review
Innovations in Low Vision
DIANA L. SHECHTMAN, OD
PAUL M. KARPECKI, OD
- 72** Product Review
- 74** Meetings + Conferences
- 75** Advertisers Index
- 76** Classifieds
- 80** Surgical Minute
Size Matters
DEREK N. CUNNINGHAM, OD
WALTER O. WHITLEY, OD, MBA
- 82** Diagnostic Quiz
Chalk it Up to Drugs?
ANDREW S. GURWOOD, OD

Stock Images on cover:
©iStock.com/JobsonHealthcare
Cover images: ©iStock.com/klagyivik and
©iStock.com/noririn



On The Web >> and more

Look for augmented content and special offers from *Review* and our advertisers. Specified pages work in conjunction with your smartphone or other mobile device to enhance the experience. With Layar, interactive content leaps off the page!



Step 1: Download the free Layar app for iPhone or Android.



Step 2: Look for pages with the Layar Logo. 



Step 3: Open the Layar app, hold the phone above the page and tap to scan it. Hold the phone above the page to view the interactive content.

First 150 app downloads and completed forms will be entered into a drawing for free meeting AND registration valued at \$495

Check out our multimedia and continuing education online at:
www.reviewofoptometry.com

REVIEW[®] OF OPTOMETRY



PRINTED IN U.S.A.

FOUNDING EDITOR
FREDERICK BOGER
1891-1913

EDITORIAL OFFICES
11 CAMPUS BLVD., SUITE 100
NEWTOWN SQUARE, PA 19073
EMAIL • REVIEWOFOPTOMETRY@JOBSON.COM
WEBSITE • WWW.REVOPTOM.COM

SUBSCRIPTION INQUIRIES
1-877-529-1746
CONTINUING EDUCATION INQUIRIES
1-800-825-4696

EDITOR-IN-CHIEF • JACK PERSICO
(610) 492-1006 • JPERSICO@JOBSON.COM

EXECUTIVE EDITOR • JOHN MURPHY
(610) 492-1021 • JMURPHY@JOBSON.COM

MANAGING EDITOR • MICHAEL HOSTER
(610) 492-1028 • MHOSTER@JOBSON.COM

SENIOR ASSOCIATE EDITOR/WEB EDITOR • RENEE BUDDLE
(610) 492-1005 • RBUDDLE@JOBSON.COM

ASSOCIATE EDITOR • ALIZA MARTIN
(610) 492-1043 • AMARTIN@JOBSON.COM

DIRECTOR ART/PRODUCTION • JOE MORRIS
(610) 492-1027 • JMORRIS@JOBSON.COM

ART DIRECTOR • JARED ARAUJO
(610) 492-1032 • JARAUIO@JOBSON.COM

DIRECTOR OF CE ADMINISTRATION • REGINA COMBS
(212) 274-7160 • RCOMBS@JOBSON.COM

SPECIAL PROJECTS • JANE COLE
(610) 492-1043 • JCOLE@JOBSON.COM

EDITORIAL BOARD
CHIEF CLINICAL EDITOR • PAUL M. KARPECKI, OD
ASSOCIATE CLINICAL EDITORS • JOSEPH P. SHOVLIN, OD;
ALAN G. KABAT, OD; CHRISTINE W. SINDT, OD
DIRECTOR OPTOMETRIC PROGRAMS • ARTHUR EPSTEIN, OD
CLINICAL & EDUCATION CONFERENCE ADVISOR •
PAUL M. KARPECKI, OD
CASE REPORTS COORDINATOR • ANDREW S. GURWOOD, OD
CLINICAL CODING EDITOR • JOHN RUMPAKIS, OD, MBA
CONSULTING EDITOR • FRANK FONTANA, OD
EMERITUS CLINICAL EDITOR • ROBERT M. COLE, III, OD

COLUMNISTS
CHAIRSIDE • MONTGOMERY VICKERS, OD
COMANAGEMENT Q+A • PAUL C. AJAMIAN, OD
CORNEA & CONTACT LENS Q+A • JOSEPH P. SHOVLIN, OD
DIAGNOSTIC QUIZ • ANDREW S. GURWOOD, OD
GLAUCOMA GRAND ROUNDS • JAMES L. FANELLI, OD
RESEARCH REVIEW • PAUL M. KARPECKI, OD;
DIANA L. SHECHTMAN, OD
RETINA QUIZ • MARK T. DUNBAR, OD
REVIEW OF SYSTEMS • CARLO J. PELINO, OD;
JOSEPH J. PIZZIMENTI, OD
SURGICAL MINUTE • DEREK N. CUNNINGHAM, OD;
WALTER O. WHITLEY, OD, MBA
THERAPEUTIC REVIEW • JOSEPH W. SOWKA, OD;
ALAN G. KABAT, OD

JOBSON MEDICAL INFORMATION LLC

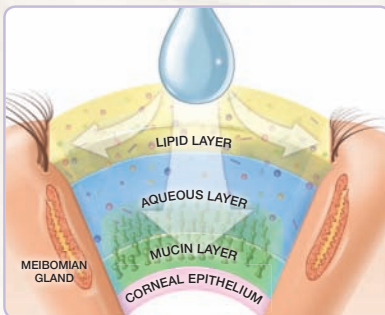


For the 75% of dry eye patients worldwide with evaporative dry eye (MGD) symptoms¹...

DRY EYE CAN BE RELENTLESS

CALM THE STORM WITH LASTING RELIEF

SYSTANE® BALANCE Lubricant Eye Drops:
Protecting the Ocular Surface by Increasing Lipid Layer
Thickness (LLT)



SYSTANE® BALANCE Lubricant Eye Drops forms a protective matrix that is designed to replenish the lipid layer for long-lasting relief from the symptoms associated with evaporative dry eye (MGD). This unique formulation is designed to work on all 3 layers of the tear film, specifically increasing LLT. This helps create a protective environment for the ocular surface.²

SYSTANE® Brand products are formulated for the temporary relief of burning and irritation due to dryness of the eye.

References: 1. Akpek EK, Smith RA. Overview of age-related ocular conditions. *Am J Manag Care*. 2013;19 (5 suppl):S67-S75. 2. Korb DR, Blackie CA, Meadows DL, Christensen M, Tudor M. Evaluation of extended tear stability by two emulsion based artificial tears. Poster presented at: 6th International Conference on the Tear Film and Ocular Surface: Basic Science and Clinical Relevance; September 22-25, 2010; Florence, Italy.

Your recommendation counts.

Make sure your patients get the lasting symptom relief they need by offering them SYSTANE® BALANCE Lubricant Eye Drops.²



Alcon
a Novartis company

© 2014 Novartis 01/14 SYS14005JAD

Relief that lasts

CONTRIBUTING EDITORS

PAUL C. AJAMIAN, OD, ATLANTA
AARON BRONNER, OD, KENNEWICK, WASH.
MILE BRUJIC, OD, BOWLING GREEN, OHIO
DEREK N. CUNNINGHAM, OD, AUSTIN, TEXAS
MARK T. DUNBAR, OD, MIAMI
ARTHUR B. EPSTEIN, OD, PHOENIX
JAMES L. FANELLI, OD, WILMINGTON, NC
FRANK FONTANA, OD, St. LOUIS
GARY S. GERBER, OD, HAWTHORNE, NJ
ANDREW S. GURWOOD, OD, PHILADELPHIA
ALAN G. KABAT, OD, MEMPHIS, TENN.
DAVID KADING, OD, SEATTLE
PAUL M. KARPECKI, OD, LEXINGTON, KY.
JEROME A. LEGERTON, OD, MBA, SAN DIEGO
JASON R. MILLER, OD, MBA, POWELL, OHIO
CHERYL G. MURPHY, OD, HOLBROOK, NY
CARLO J. PELINO, OD, JENKINTOWN, PA.
JOSEPH PIZZIMENTI, OD, FORT LAUDERDALE, FLA.
JOHN RUMPAKIS, OD, MBA, PORTLAND, ORE.
DIANA L. SHECHTMAN, OD, FORT LAUDERDALE, FLA.
JEROME SHERMAN, OD, NEW YORK
JOSEPH P. SHOVLIN, OD, SCRANTON, PA.
JOSEPH W. SOWKA, OD, FORT LAUDERDALE, FLA.
MONTGOMERY VICKERS, OD, St. ALBANS, W.VA.
WALTER O. WHITLEY, OD, MBA, VIRGINIA BEACH, VA.

EDITORIAL REVIEW BOARD

JEFFREY R. ANSHEL, OD, CARLSBAD, CALIF.
JILL AUTRY, OD, RPH, HOUSTON
SHERRY J. BASS, OD, NEW YORK
EDWARD S. BENNETT, OD, St. LOUIS
MARC R. BLOOMENSTEIN, OD, SCOTTSDALE, ARIZ.

CHRIS J. CAKANAC, OD, MURRYSVILLE, PA.
JERRY CAVALLERANO, OD, PHD, BOSTON
WALTER L. CHOATE, OD, MADISON, TENN.
BRIAN CHOU, OD, SAN DIEGO
A. PAUL CHOUS, MA, OD, TACOMA, WASH.
ROBERT M. COLE, III, OD, BRIDGETON, NJ
GLENN S. CORBIN, OD, WYOMISSING, PA.
ANTHONY S. DIECIDUE, OD, STROUDSBURG, PA.
S. BARRY EIDEN, OD, DEERFIELD, ILL.
STEVEN FERRUCCI, OD, SEPULVEDA, CALIF.
MURRAY FINGERET, OD, HEWLETT, NY
IAN BEN GADDIE, OD, LOUISVILLE, KY.
MILTON HOM, OD, AZUSA, CALIF.

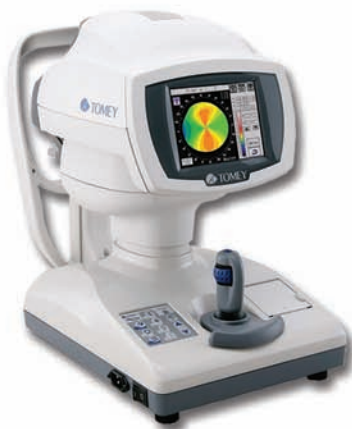BLAIR B. LONSBERRY, MS, OD, MED, PORTLAND, ORE.
THOMAS L. LEWIS, OD, PHD, PHILADELPHIA
DOMINICK MAINO, OD, MED, CHICAGO
KELLY A. MALLOY, OD, PHILADELPHIA
RICHARD B. MANGAN, OD, LEXINGTON, KY.
RON MELTON, OD, CHARLOTTE, NC
PAMELA J. MILLER, OD, JD, HIGHLAND, CALIF.
BRUCE MUCHNICK, OD, COATESVILLE, PA.
MARC MYERS, OD, COATESVILLE, PA.
WILLIAM B. POTTER, OD, FREEHOLD, NJ
CHRISTOPHER J. QUINN, OD, ISELIN, NJ
JACK SCHAEFFER, OD, BIRMINGHAM, ALA.
MICHAEL C. RADOIU, OD, STAUNTON, VA.
KIMBERLY K. REED, OD, FORT LAUDERDALE, FLA.
LEO P. SEMES, OD, BIRMINGHAM, ALA.
LEONID SKORIN, JR., OD, DO, ROCHESTER, MINN.
BRAD M. SUTTON, OD, INDIANAPOLIS
LORETTA B. SZCZOTKA, OD, PHD, CLEVELAND
TAMMY P. THAN, MS, OD, BIRMINGHAM, ALA.
RANDALL THOMAS, OD, CONCORD, NC
KATHY C. WILLIAMS, OD, SEATTLE



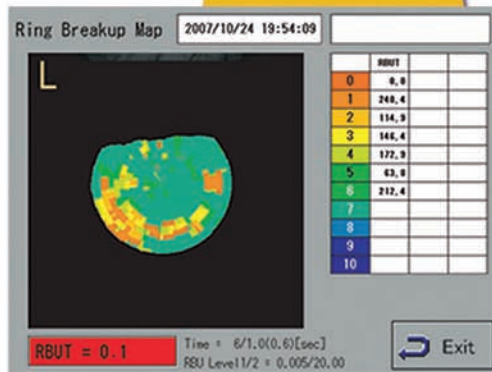
TOMEY[®] AUTOREFRACTOR/KERATOMETER/ TOPOGRAPHER

RT-7000 (3-in-1)

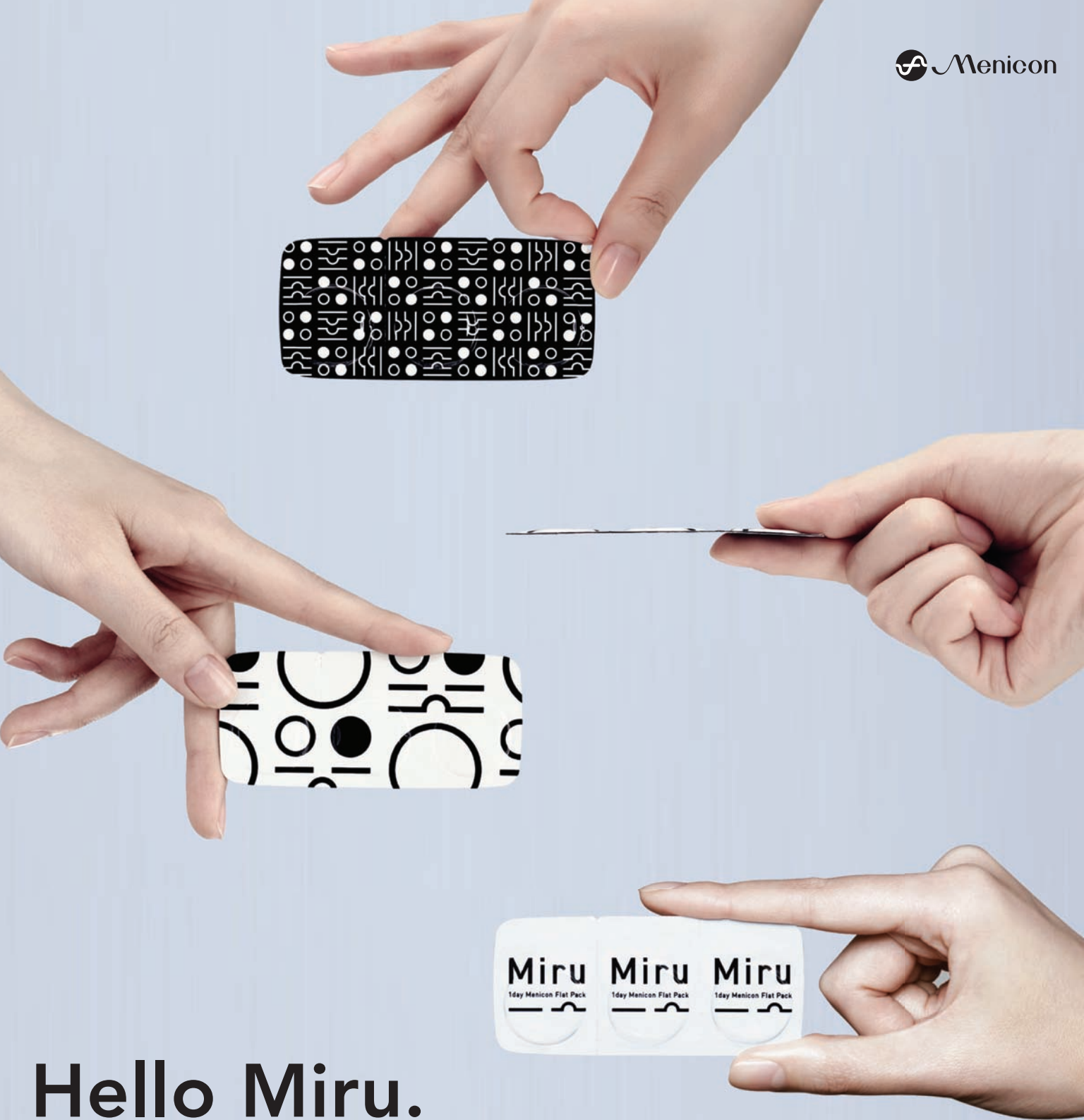**Dry Eye
Software
Included!**



- 3 Functions in 1 Instrument:
Auto Refractor, Keratometer,
& Topographer
- Easy & Fast Touch Screen
- Auto Alignment/Shot
- Tear Stability Analysis
System-Mode for Dry Eye
- Diameter Measurement
of Cornea & Pupil



888-449-4045 • WWW.TOMEYUSA.COM



Hello Miru. Bye, bye blister pack.

Introducing Miru 1day, the world's thinnest package for daily disposable contact lenses.

Miru's ultra lightweight 1mm thin package is about 1/8th the thickness of a traditional blister pack and was specifically developed to reduce the risk of microbial contamination. When opened, the lens is presented on a special disk, oriented correctly for proper insertion.

To learn more and request trials, please visit: miru.meniconamerica.com

©2014 Menicon America, Inc. Miru is a registered trademark of Menicon Company Ltd.

Miru
1day Menicon Flat Pack



1-DAY ACUVUE[®] MOIST[®] BRAND CONTACT LENSES

Exceptional all-day
lens wear, every day,
for every eye



UNSURPASSED COMFORT

Clinically unsurpassed in overall comfort and rated superior to Dailies[®] AquaComfort Plus[®] in beginning to end-of-day comfort

EXCELLENT SAFETY PROFILE¹

Confirmed in an unprecedented, year-long, observational study of 570 wearers—no other lens has published this kind of safety data, including Dailies[®] AquaComfort Plus[®]

UV PROTECTION[‡]

Blocks approximately 97% UVB and 82% UVA rays.[‡] Dailies[®] AquaComfort Plus[®] does not meet ANSI/ISO standards for UV blocking



ANSI=American National Standards Institute; ISO=International Organization for Standardization.

ACUVUE[®] Brand Contact Lenses are indicated for vision correction. As with any contact lens, eye problems, including corneal ulcers, can develop. Some wearers may experience mild irritation, itching or discomfort. Lenses should not be prescribed if patients have any eye infection, or experience eye discomfort, excessive tearing, vision changes, redness or other eye problems. Consult the package insert for complete information. Complete information is also available from VISTAKON[®] Division of Johnson & Johnson Vision Care, Inc., by calling 1-800-843-2020 or by visiting acuvueprofessional.com.

¹Helps protect against transmission of harmful UV radiation to the cornea and into the eye.

WARNING: UV-absorbing contact lenses are NOT substitutes for protective UV-absorbing eyewear such as UV-absorbing goggles or sunglasses, because they do not completely cover the eye and surrounding area. You should continue to use UV-absorbing eyewear as directed. **NOTE:** Long-term exposure to UV radiation is one of the risk factors associated with cataracts. Exposure is based on a number of factors such as environmental conditions (altitude, geography, cloud cover) and personal factors (extent and nature of outdoor activities). UV-blocking contact lenses help provide protection against harmful UV radiation. However, clinical studies have not been done to demonstrate that wearing UV-blocking contact lenses reduces the risk of developing cataracts or other eye disorders. Consult your eye care practitioner for more information.

[‡]UV-blocking percentages are based on an average across the wavelength spectrum.

¹This observational/surveillance registry relied on patient reports of symptomatic adverse events that led them to seek clinical care. These results should be considered in conjunction with other clinical results on the safety and efficacy of daily disposable etafilcon A contact lenses, which also generally show low rates of such events. Although no symptomatic infiltrative events were reported in this study, such events can occur with daily disposable lenses, including 1-DAY ACUVUE[®] MOIST[®], as noted in the product labeling.

¹Based on *Tyler's Quarterly Soft Contact Lens Parameter Guide*; June 2014.

1. Chalmers RL, Hickson-Curran SB, Keay LJ, Gleason W. Safety of hydrogel and silicone hydrogel daily disposables in a large post-market surveillance registry—the TEMPO registry. Presented at: ARVO 2014 Annual Meeting; May 4-8, 2014; Orlando, FL.

The third-party trademarks used herein are trademarks of their respective owners.

ACUVUE[®], 1-DAY ACUVUE[®] MOIST[®], BLINK STABILIZED[™], and VISTAKON[®] are trademarks of Johnson & Johnson Vision Care, Inc.

© Johnson & Johnson Vision Care, Inc. 2014 ACU-A44749 November 2014

*An eye exam is well worth the commute,
the wait, the time and the money!*

Superb Issue, Subpar Cover

Sometimes optometry inadvertently contributes to its own public relations failings with respect to the public and our own self-image.

The cover of the October 15, 2014 issue features a phoropter, which perpetuates the image of optometrists as refractionists. In counter-distinction, the subjects covered in this superb issue include IOL advances, a review of refractive surgery, post-operative complications of cataract surgery, retinal blood disorders and external ocular pathology.

We've come a long way from being primarily identified with refraction and glasses, and the images with which we identify ourselves should reflect the change.

—Harvey Rosenwasser, OD
Key Biscayne, Fla.

Editor's note: To explain, the cover concept was meant to illustrate how ODs are now integrating medical eye care with "traditional" optometry, as seen through the eyepieces of the phoropter.



Real Eye Exams Are Worth the Time, Trouble and Expense

Online eye exam technology has the potential of disrupting the industry and negatively impacting our profession. This technology has strong consumer support, and our efforts to block it could be viewed merely as protecting our own interests. But if optometry does not lead and own this conversation, we seriously risk losing credibility and authority on this issue.

In addition to dispensing a refractive prescription, the online eye exam will recommend an eye health exam with a local optometrist or ophthalmologist. However, this will not be required or enforced, with the digitally-signed Rx already given.

At least for now, no one under the age of 18 or over the age of 40, or with pre-existing medical conditions, is allowed to take the online eye exam. Yet we all know that serious eye diseases and medical conditions can be first diagnosed in this age group. For this reason, the Optometric Society's public service campaign focuses on this age category and on patient education

(<http://onlineeyeexamcost.com/>).

Let's send a strong message: an eye exam is well worth the commute, the wait, the time and the money!

Four things you can do:

1. Make sure your staff communicates with every patient the difference between a refraction and a comprehensive eye exam. In the waiting room, have written patient cases and testimonials of how ocular and medical conditions were found during a routine exam.

2. Write an op-ed for your local newspaper or give an interview at your local radio station, detailing the limitations of online eye exams and the importance of full-scope optometric care

3. Alert your state medical board and your state AOA chapter. Get involved!

4. Expand your services to include specialty contact lenses, orthokeratology, low vision and vision therapy. Expand the technology offered in your practice to deliver the highest level of eye care possible. ■

—Lisa Shin, OD

The Optometric Society

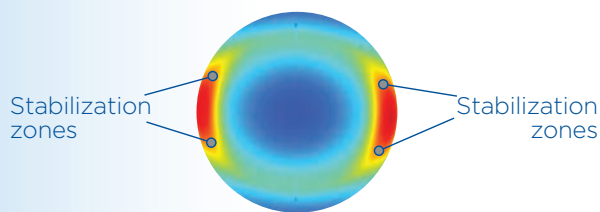
www.theoptometricsociety.org

SAME COMFORT, SAFETY, AND UV PROTECTION WITH ENHANCED STABILITY

— BLINK STABILIZED™ Design creates equal/opposite forces to limit rotation and better stabilize vision

— Nearly 200 more parameters than Dailies® AquaComfort Plus® Toric Lenses!

REALIGNS WITH EVERY BLINK



1-DAY ACUVUE®
MOIST®
BRAND CONTACT LENSES
FOR ASTIGMATISM



Technical Difficulties

Are we too slow in adopting new technology? Or is it moving too fast and passing us by?

By Jack Persico, Editor-in-Chief

As always, last month's American Academy of Optometry conference showcased many of the best and brightest minds in optometry, who delivered updates on the very latest advances in clinical care and research. It's always great to end the year in sessions on the cutting edge topics that are propelling the profession forward.

Or so I thought. At a symposium on cataract and refractive surgery, I asked a few optometrists for their impressions of the program. "This is great material and it's good to be here but, honestly, this stuff is from yesteryear," a Canadian optometrist commented. "It's too bad your FDA is so slow." (He used a more colorful word, FYI.) He meant no offense, and seemed politely chagrined at the possibility—as is the Canadian way—but I could see the troubled reactions on the faces of the other ODs around the table.

Many surgical technologies stuck in FDA purgatory have been available for years in other countries. Alcon's toric multifocal IOL was launched four years ago—outside the US. It has yet to come to these shores. The AcuFocus Kamra corneal inlay for presbyopia correction launched a year later, seemingly everywhere but here. And collagen crosslinking has been a routine part of corneal ectasia management worldwide for nearly a decade, again except for one conspicuous absence.

Those are just a handful of examples, unfortunately.

The High-Tech Clinic

Fortunately, the playing field is more level for diagnostic and other clinic-based technology. In the reader survey that's part of this month's 37th annual technology report (*page 40*), optometrists tell us they are learning that increasing efficiency—by investing in new technology—doesn't have to mean compromising care.

"I was tired of referring patients out to other doctors ... only because I did not have the proper diagnostic equipment," one optometrist says. "Not only have these purchases [of new instruments] allowed me to do that, but they have significantly improved my practice revenue. I'm taking better care of my patients than ever before."

Still, it's tough to keep up with the frenzied pace of innovation. The feature article by Amanda Legge, OD, on page 32 suggests that OCT—itself a darling of technophiles for many years—becomes even more useful to clinicians when used in conjunction with a whole host of complementary tests and technologies.

And this month's cover story reports from the research frontier on the prospects for monitoring IOP around the clock using high-tech intraocular implants or contact lenses. Our glaucoma experts feel the question isn't so much, "Can it be done?" but rather, "What the heck am I supposed to do with all that data?" Prepare for the deluge when it does become a reality.

It's enough to make your head spin, if you can look up from your smartphone long enough. Oh, wait—smartphones are passé. Smartwatches are all the rage now. And did Google Glass already come and go, or is *that* one the next in line?

Use the Force, Doc

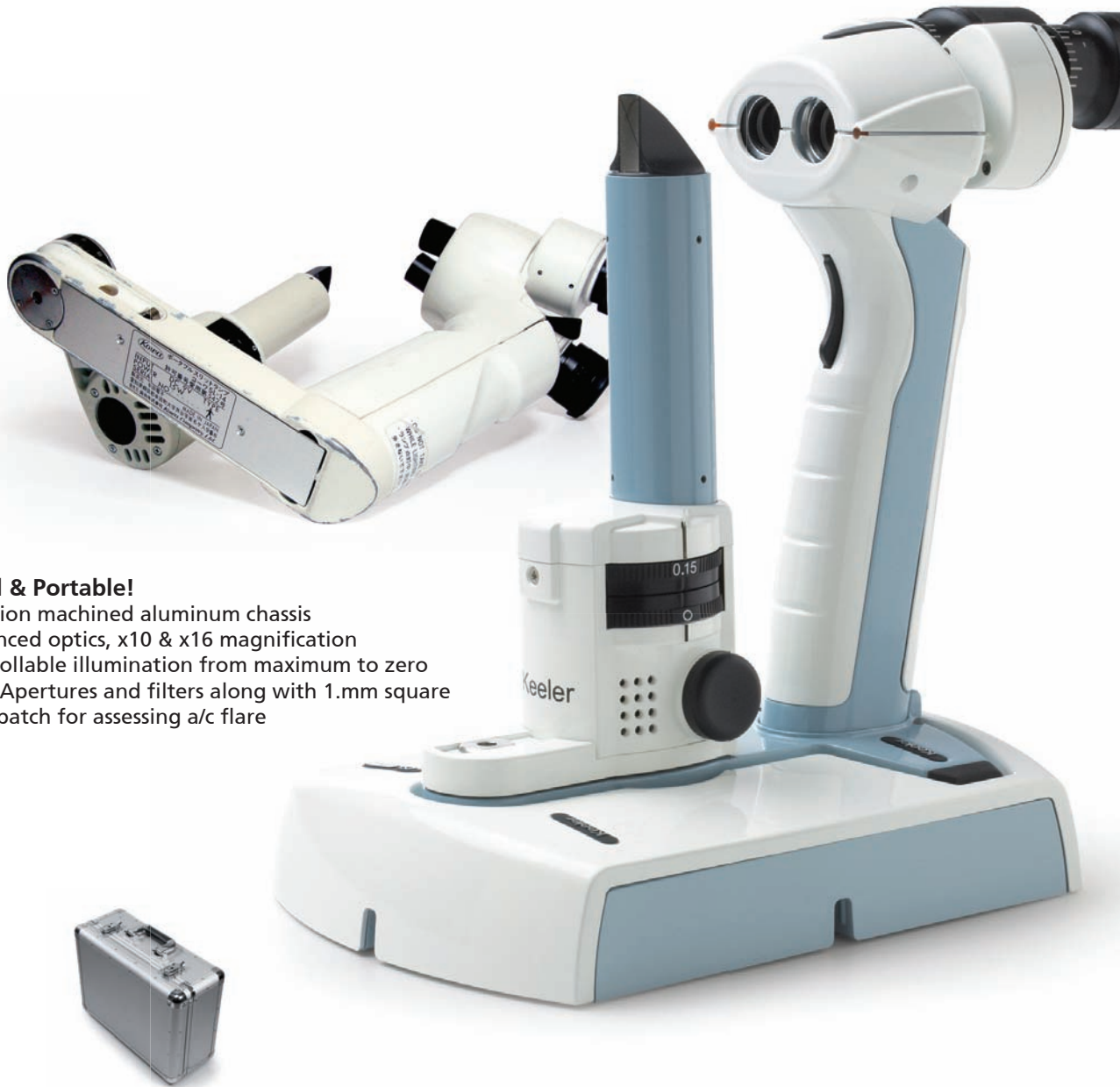With gadgets so pervasive in our personal and professional lives, are we becoming too reliant on technology? How does it affect the way optometrists care for their patients? Some veteran clinicians grouse that younger ODs don't know all the nuances of how to perform a though refractive and ocular exam, worrying that the profession's traditions and shared knowledge is in danger of being lost, or at least eclipsed. There's merit to that, and it's something for colleges and their student bodies to mind.

It's easy to get swept up in the thrill of gadget fever. Clinicians and their patients owe a debt of gratitude to the amazing technological innovations that improve patient care. But maybe the answer lies in a galaxy far, far away. *Star Wars* is a cultural touchstone not (just) because of the whiz-bang effects and the iconic characters. It's because the message—you have the power, trust your instincts—resonates universally. All the technology in the world is useless without someone in the cockpit.

Just something to ponder as you watch the new *Episode VII* trailer on your smartwatch. ■

Trade Up To Keeler

Trade-in your hand-held slit lamp & get \$600 towards Keeler's Advanced PSL Classic!



Powerful & Portable!

- Precision machined aluminum chassis
- Advanced optics, x10 & x16 magnification
- Controllable illumination from maximum to zero
- Most Apertures and filters along with 1.1mm square light patch for assessing a/c flare

Trade-in & Special Bonus

FREE Carrying Case. Only Portable Slitlamps that have a binocular microscope allowed as trade-in. Offer expires January 31, 2015.

Buy Online!
keelerusa.com



Keeler
OPTICS

Thanky Panky

'Tis the season to be thankful, right? It's time to celebrate our many blessings by giving thanks and then going to the mall. **By Montgomery Vickers, OD**

The recent retirement of one of the unsung heroes in optometry's evolution, my friendly colleague across town, Dr. John Casto, reminded me that many thanks are in order. He was on the front line of the first drug bill in the nation that allowed diagnostic and therapeutic drugs for ODs in West Virginia. Thank you, Dr. Casto!

On "The Tonight Show," Jimmy Fallon often takes a moment to write his Thank You notes. It's time for us to do the same, so let's get started:

- Thank you, pupil, for being there so we can see all the crazy crap that happens inside an eye, even the stuff that freaks us out.
- Thank you, "buy-glasses-and-the-eye-exam-is-free doctor," for reminding me that I am not the worst optometrist in the world after all.
- Thank you, Meaningful Use, for turning my last year's computer into the world's most expensive door stop.
- Thank you, late postponing patient, for calling to give my staff three minutes to fill the suddenly empty slot on my schedule.
- Thank you, whoever decided glasses should be huge again like they were in 1979, for all the sore noses I will hear about until you come to your senses.
- Thank you, contact lens company, for holding up my order until I pay my \$45 balance when I have done \$13,000 worth of business with you in the past year.

- Thank you, fluorescein, for staining the only decent white shirt I have left.

- Thank you, 20-year-old puff tonometer, for scaring off half my patients, and being inaccurate for the ones who do show up.

- Thank you, Rx recheck patient, for choosing number 2 when you meant to choose number 1.

- Thank you, pharmaceutical company, for constantly inventing new medications that may not work better than the old ones, but at least they cost a ton more.

- Thank you, online contact lens retailer, for faxing requests for verification on Thursday nights when you know damn well we don't open up again until Monday.

- Thank you, custom multifocal toric contact lens wearer, for letting me know Sunday night that you need a replacement contact lens tomorrow because you broke your glasses right after your exam three years ago and you tore your last contact lens three weeks ago and you are leaving for a month in Europe in two days.

- Thank you, state boards of optometry, for reminding me that I instantly forget everything I know as soon as I

drive across the state line.

- Thank you, disability attorney, for badgering me every day for records on my healthy 20/20 patient whose disability is because of an old injury to his left foot.

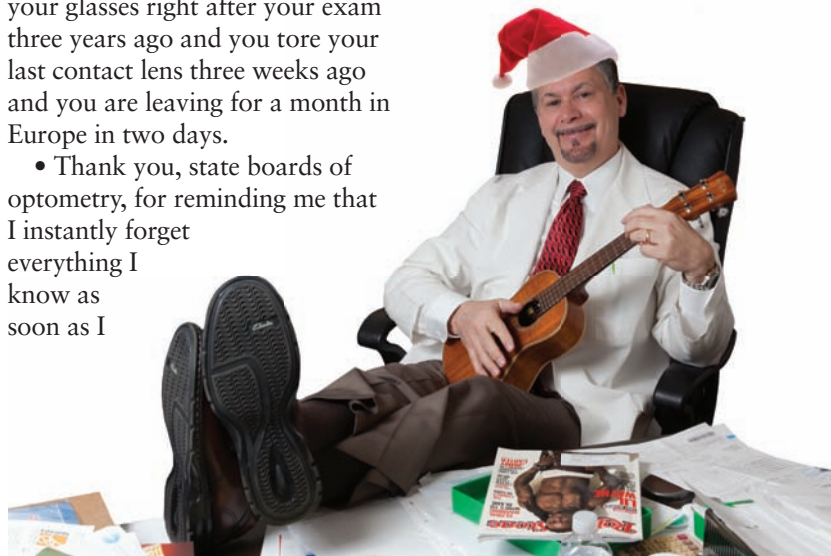- Thank you, Affordable Care Act, for not being affordable because you don't care if we act.

- Thank you, paperless EHRs, for making it so we only carry out 90 pounds of shredding every day.

- Thank you, fingernail polish remover, for being in the same sized bottle as 90% of the eyedrops we prescribe.

- And thank you, *Chairside* readers, for continuing to give me just one more chance every month for the past 24 years!

Now make your own list. We have much to be thankful for, so take a second over the holidays and be grateful! ■





THE TRAINING YOU NEED TO GROW YOUR MEDICAL PRACTICE


Attention all Optometrists

Attend a boot camp to learn the latest techniques for practicing **full-scope optometry**. Get a step-by-step implementation plan that includes:

- Understanding and implementing *ICD-10* codes
- Improving billing and medical record compliance
- Differentiating vision plan visits vs medical plan visits
- Gaining access to insurance panels
- Maximizing practice productivity and performance
- Motivating and training your staff

Expert faculty:

Scot Morris, OD, FAAO
John Rumpakis, OD, MBA
Allergan Eye Care Business Advisors



Upcoming PATHWAYS IN MEDICAL OPTOMETRY™ Courses

Location	Date
Houston, TX	Saturday, 1/31/2015
Orange County, CA	Saturday, 2/28/2015
Las Vegas, NV	Saturday, 3/14/2015
Ft Lauderdale, FL	Saturday, 4/11/2015
Ledyard, CT	Saturday, 4/18/2015
Memphis, TN	Saturday, 5/9/2015
Teaneck, NJ	Saturday, 5/16/2015
St Louis, MO	Saturday, 9/12/2015
Chicago, IL	Saturday, 10/24/2015
Atlanta, GA	Saturday, 11/14/2015

Each boot camp consists of 1 full-day course.

Cost per course:

First OD registration per practice **\$399 per course***

All additional practice registrations **\$199 per course***

* Cost required per PhRMA guidelines.

Register today at: AllerganODPathways.com

Questions? Call 1-844-750-2020



X Marks the Spot

The ‘modifier of last resort’ is being supplemented with X modifiers to further define separate services. **By John Rumpakis, OD, MBA, Clinical Coding Editor**

As a rule, we cannot bill for procedures provided at the same anatomic site at the same patient encounter. So, what about when you *do* need to indicate that a procedure or service is distinct or independent from another service performed on the same day?

Use modifier -59, which is applied to identify procedure(s) and service(s) that are not normally reported together, but are appropriate under the circumstances. This may represent a different session or patient encounter, different procedure or surgery, different site or organ system, separate incision/excision, separate lesion, or separate injury not ordinarily encountered or performed on the same day by the same physician.

A Dangerous Proposition

However, as I have discussed many times over the years, the routine use of modifier -59 is a very dangerous proposition. Here’s why:

- The -59 modifier is the most widely used modifier, according to the Centers for Medicare & Medicaid Services (CMS). Because it can be so broadly applied, it’s associated with considerable abuse and high levels of manual audit activity, leading to reviews, appeals and even civil fraud and abuse cases.

- Some providers incorrectly consider it to be the modifier to use to bypass the National Correct Coding Initiative (NCCI). So it’s the number one modifier to attract the attention of third-party carriers.

Keep in mind that modifier -59 can only bypass edits when:

- A combination of procedure codes represent procedures that wouldn’t normally be performed at the same time (e.g., a procedure on the head and a procedure on the feet).
- A different session or patient encounter is documented in patient’s medical record.
- Surgical procedures performed are not done through the same incisional site.
- Another modifier is not as appropriate (e.g., modifier -51).
- It’s used as a modifier of last resort.

But last year, CMS indicated that modifier -59 is the appropriate modifier to use in the very rare circumstances when performing fundus photography (92250) and OCT of the posterior segment (92134) on the same date of service, assuming you’ve met the rules of medical necessity.

Generation X

Accordingly, more precise coding options are needed to reduce improper use of the -59 modifier. To that end, CMS has established four new Healthcare Common Procedure Coding System (HCPCS) modifiers to selectively define subsets of the -59 modifier, used to designate a distinct procedural services.

These modifiers, collectively referred to as -X{EPSU} modifiers, will be implemented January 5, 2015. They define specific subsets of the -59 modifier:

XE—Separate Encounter: A service that is distinct because it occurred during a separate encounter.

XS—Separate Structure: A service that is distinct because it was performed on a separate organ/structure.

XP—Separate Practitioner: A service that is distinct because it was performed by a different practitioner.

XU—Unusual Non-Overlapping Service: The use of a service that is distinct because it does not overlap usual components of the main service.

Initially, either modifier -59 or a more selective -X{EPSU} modifier will be accepted, but notes that the -59 modifier should not be used when a more descriptive modifier is available. CMS may selectively require a more specific -X{EPSU} modifier for billing certain codes at high risk for incorrect billing.

At the time of this writing, more specific rules and clinical application of the X modifiers have not been released. I’m hopeful that within the coming weeks, we’ll have further clarification from CMS regarding the use of the X modifiers to continue to allow us to perform OCT and fundus photography on the same day of service when dictated by clinical circumstances.

Until then, please be aware of this change and be very judicious in your use of -59 in 2015. ■

Send questions and comments to CodingAbstract@gmail.com.

Best-in-class properties for best-in-class performance¹

Bausch + Lomb ULTRA[®] contact lenses with MoistureSeal[®] technology combine best-in-class physical properties for a revolutionary silicone hydrogel lens.¹

	Dk/t	MODULUS	ASPHERIC OPTICS	THIN EDGE DESIGN
Bausch + Lomb ULTRA[®] contact lenses	163	70	✓	✓
ACUVUE OASYS	147	73		✓
AIR OPTIX AQUA	138	102		
Biofinity	160	82	✓	

Patient preferred for end-of-day comfort over the leading silicone hydrogel lenses²

2 to 1
vs.
ACUVUE OASYS

3 to 1
vs.
AIR OPTIX AQUA

4 to 1
vs.
Biofinity

Retains moisture for a full 16 hours.¹



Go to www.blultra.com or contact a Bausch + Lomb sales representative today

REFERENCES: 1. Data on file. Bausch & Lomb Incorporated, Rochester NY; 2013. 2. Results from a 22-investigator, multi-site study of Bausch + Lomb Ultra contact lenses with MoistureSeal technology, on 327 current silicone hydrogel lens wearers. After 7 days of wear, subjects completed an online survey. Subjects rated performance across a range of attributes. Preference comparisons represent only those subjects expressing a preference. Ratio is based on the average across the silicone hydrogel lenses represented in the study.

®/™ are trademarks of Bausch & Lomb Incorporated or its affiliates. All other product/brand names are trademarks of their respective owners. ©2014 Bausch & Lomb Incorporated. US/ZUS/14/0149

BAUSCH + LOMB
See better. Live better.



Sequenom and RetnaGene are trademarks of Sequenom, Inc. and are used with permission by Sequenom Center for Molecular Medicine, LLC, dba Sequenom Laboratories.

© 2014 Sequenom Laboratories. All rights reserved.
© 2014 Nicox, Inc. All rights reserved. www.nicox.com 31-32002R1.0 0614

No test is perfect. The RetnaGene™ AMD and RetnaGene™ LR laboratory-developed tests are highly accurate, genetic tests. However, erroneous results may occur in rare cases.

The RetnaGene™ AMD and RetnaGene™ LR laboratory-developed tests were validated under federal laboratory guidelines by Sequenom Center for Molecular Medicine, dba Sequenom Laboratories, a wholly owned subsidiary of Sequenom, Inc. The tests have not been cleared or approved by the US Food and Drug Administration (FDA). Although laboratory-developed tests to date have not been subject to US FDA regulation, certification of the laboratory is required under CLIA to ensure the quality and validity of the test. Sequenom Laboratories is CAP-accredited and CLIA-certified to perform high-complexity clinical laboratory tests.

Advanced Genotyping Reveals Future AMD Risk

Now, visionary science puts the power of prediction in your hands

RetnaGene™ is a portfolio of laboratory-developed genetic tests that provides a highly accurate and comprehensive risk assessment for advanced AMD.

RetnaGene™

For more information about the RetnaGene™ tests, please call a *myNicox* concierge professional at **1.855.MY.NICOX** (1.855.696.4269), email **concierge@myNicox.com**, or visit **myNicox.com/RetnaGene**.

AMD=age-related macular degeneration; CAP=College of American Pathologists; CLIA=Clinical Laboratory Improvement Amendments.

37th Annual Technology Report

A Day in the Life of IOP

It waxes, wanes and often spikes, creating patterns that currently go undetected. Can 24-hour monitoring devices reveal its secrets? **By Renee Buddle, Senior Associate Editor**

Clinicians have long been frustrated by the disproportionate role that intraocular pressure (IOP) plays in glaucoma care. As the only factor amenable to medical or surgical intervention, its role is vital. Yet tonometry is inherently limited: A single reading taken every few months fails to depict IOP's diurnal ebb and flow. Even bringing patients in for multiple tonometry readings doesn't provide an ideal sense of the patient's IOP characteristics.

Experts believe you'll eventually fit patients with a tiny sensor housed on a contact lens or pair of glasses, or send them to an ophthalmologist to have one implanted in the eye. It would continuously measure IOP, exponentially increasing the quantity—and, hopefully, the value—of the data you receive. If the current approach to IOP documentation is like taking a snapshot, continuous 24-hour

IOP monitoring is more akin to capturing a video that records change over time rather than just giving one static reading.

These gadgets are still under development. Are they ready for prime time? Let's take a look at how IOP fluctuates, the clinical challenges it creates and the current state-of-the-art technologies that attempt to better track IOP

to allow for greater clinical understanding.

A Moving Target

Setting up a treatment plan based on achieving a target IOP is tricky when the target itself is moving. IOP fluctuates throughout the day—hour by hour, minute by minute, even second by second—based on a variety of endogenous and exogenous factors.

Within the ocular system, IOP can depend on the balance of aqueous humor production, outflow facility (how easily aqueous humor leaves the eye), episcleral venous pressure (the pressure in the veins on the surface of the eye) and uveoscleral outflow (a secondary pathway for aqueous humor to leave the eye).

For example, an increase in outflow facility or decrease in aqueous humor production would lower IOP, says Arthur




Photo: Ismail E. Araci

This implantable micro-fluidic 24-hour IOP monitoring sensor is currently in development at Stanford University.



J. Sit, MD, a glaucoma researcher at the Mayo Clinic in Rochester, Minn. Short-term jumps in IOP can also occur due to pressure on the eye from blinking or rubbing the eye or even during eye movement or blood pressure pulsations.

Intraocular pressure also fluctuates because of body position, time of day (peaks at night, troughs during the day), blood pressure and the related concept of ocular perfusion pressure (OPP), stress or pain levels, water and caffeine consumption.

Furthermore, vigorous activity and stress can make blood pressure, IOP and OPP peak, says Kaweh Mansouri, MD, MPH, an ophthalmologist at the University of Geneva and the University of Colorado Denver. Measurement of blood pressure in conjunction with IOP has value to determine how blood pressure affects IOP, says Dr. Mansouri. Researchers are currently using 24-hour IOP monitoring devices to explore these effects on glaucoma progression.

Here's how these variables affect IOP:

- **Body position.** Depending on the patient's position in the chair, the pressure can increase or decrease. For example, IOP is lowest when the patient is sitting in a neutral position. "Almost anything else causes IOP to increase, including bending the neck forward, bending the head backwards, turning the head to the side, lying down, bending over, blinking or rubbing your eyes," says Dr. Sit.

- **Water consumption.** Drinking a large volume of water causes the patient's blood volume to increase for a short time. Venous pressure also goes up when the patient consumes more water. "All they

Dos and Don'ts of IOP Measurement

IOP assessment may be erroneous if not captured frequently enough. But until 24-hour IOP monitoring devices are approved in the US, here are a few strategies that will allow you to capture a better picture of your glaucoma patients' pressures:

- **DON'T diagnose or treat after just one measurement.** Dr. Sowka advises optometrists not to start treatment immediately unless the pressure is excessively high or the optic nerves are already severely damaged and vulnerable; instead, measure pressure several times. It's also a good idea to get several pressure readings after initiating therapy to determine whether the medication is working, says Dr. Sowka. One IOP reading after starting a medication is really not enough to judge true efficacy.

- **DO tell patients to relax.** As mentioned earlier, patients may strain or hold their breath during tonometry. Tell them regularly to relax and breathe normally during the process, urges Dr. Mansouri.

- **DON'T let go of your suspicion.** If the patient's IOP measurements don't seem to match with your visual field and optic nerve assessments, there may be more going on with the patient's IOP than you realized, says Dr. Hartwick. Have them come back and measure their IOP at a different time of day, he adds.

- **DO consider a diurnal curve in select patients.** Recording a diurnal curve tonometrically is impractical and tedious for most patients. But if the level of IOP and the extent of damage seem incongruous—for instance, when you suspect normal tension glaucoma—consider the possibility, says Dr. Davey. If the patient is agreeable, bring them in early in the morning and record IOP every hour for eight to 10 hours. "That gives you the office diurnal curve, which might not be fully representative of the day/night values, but at least it gives you more than one measurement," he says.

have to do is consume 16 to 32oz, which is one or two small bottles of water, and within five minutes the pressure will be up by 6mm Hg," says Pinakin Guntant Davey, PhD, OD, professor and glaucoma expert at the College of Optometry at Western University of Health Sciences in Pomona, Calif.

- **Time of day.** The literature has shown peak IOP occurs at night in two-thirds of patients. The reason: aqueous is undersecreted at night, says Joseph Sowka, OD, professor of optometry at Nova Southeastern University College of Optometry in Ft. Lauderdale, Fla.

For instance, Dr. Mansouri observed patients for 24 hours in sleep labs and found the highest IOPs at night. Even though your patients won't be subject to sleep

studies, they may come to your office in the evening—if so, expect to see elevated IOPs relative to other times of day.

- **Blood pressure.** Baseline IOP is based on cardiac cycle, systolic and diastolic blood pressure. The force used to bring blood into the eye is the ocular perfusion pressure, explains James L. Fanelli, OD, of Cape Fear Eye Institute in Wilmington, NC.

If blood pressure is low, there is less force to "push" blood into the eye, and therefore, less perfusion pressure to the eye. Factors that cause IOP to elevate will have an effect on lowering perfusion pressure, and factors that lower blood pressure also will result in lower perfusion pressure—or a combination of any of those factors can play a role, Dr. Fanelli says. Blood pressure tends to down-

regulate during sleep hours in the early morning, which is also the time of day where IOP tends to be the highest.¹ These two opposing factors can have a duplicative effect in reducing IOP during nocturnal hours, which may allow increased damage to the ocular nerve head.

• **Stress.** An increase or decrease in stress causes hormonal changes that push IOP levels up or down. One of Dr. Mansouri's patients—studied using a 24-hour IOP monitoring sensor on a contact lens—had pressure spikes whenever her dog had epileptic fits at night.

– *General “nerves.”* It's possible that, in some patients, the stress of the eye exam itself—for instance, if they are worried about being diagnosed with glaucoma—may cause their IOP to go up, says Andrew Hartwick, OD, PhD, associate professor at Ohio State University College of Optometry in Columbus. For example, they may squeeze their eyes because they're stressed about the exam,

and IOP readings spike.

– *Pain* also causes surges in IOP because it causes stress. One of Dr. Mansouri's patients banged her leg badly in a parking lot. There was a spike in her IOP level at the exact moment she recalled her accident occurred, according to 24-hour monitoring data.

Consequences of Inaccurate IOP Readings

Studies have indicated that peaks in IOP could contribute to glaucoma progression.^{2,3} But if you examine a patient when IOP is at its lowest or highest, you may overestimate or underestimate the diagnosis of glaucoma or treatment required for the patient.

“If we catch a patient at a trough, where IOP is lowest, it may lead us away from a consideration of glaucoma,” especially if the reading falls within a statistically normal range, says Dr. Sowka. “Other times, we may get them at a peak IOP, where it's a little above normal—a scenario that tends to make practitioners

worry needlessly.”

Recording an IOP range would potentially allow improvement in glaucoma diagnosis and management. “If researchers could show that specific 24-hour IOP patterns are related to progression of glaucoma, then there is hope that detecting these patterns might help to identify patients at increased risk for progression and allow us to adapt their treatment accordingly,” says Dr. Mansouri.


Glaucoma could be identified sooner, allowing surgery or medications to commence more quickly, he adds. Eye doctors could also determine whether IOP-lowering drugs are effective at night or during specific activities that raise IOP.

Establishing a true IOP range would require continuous 24-hour IOP monitoring. This is a challenge, because a single IOP measurement collected during normal office hours doesn't capture the range of a patient's IOP, its peaks or changes during the day.⁴

Right now, determining IOP range is possible using Goldman applanation tonometry (GAT) through a diurnal tension curve (DTC), where IOP readings are captured at different time points during clinic hours. But this is problematic for both practitioner and patient. Nighttime curves are not recorded, and fewer than 1% of patients undergo DTC or IOP monitoring in a sleep lab.⁴

Indeed, researchers measured IOP for 24 hours and documented not only that IOP peaks nocturnally, but that IOP fluctuation was far greater during non-office

Photo: Implantsdata Ophthalmic Products GmbH



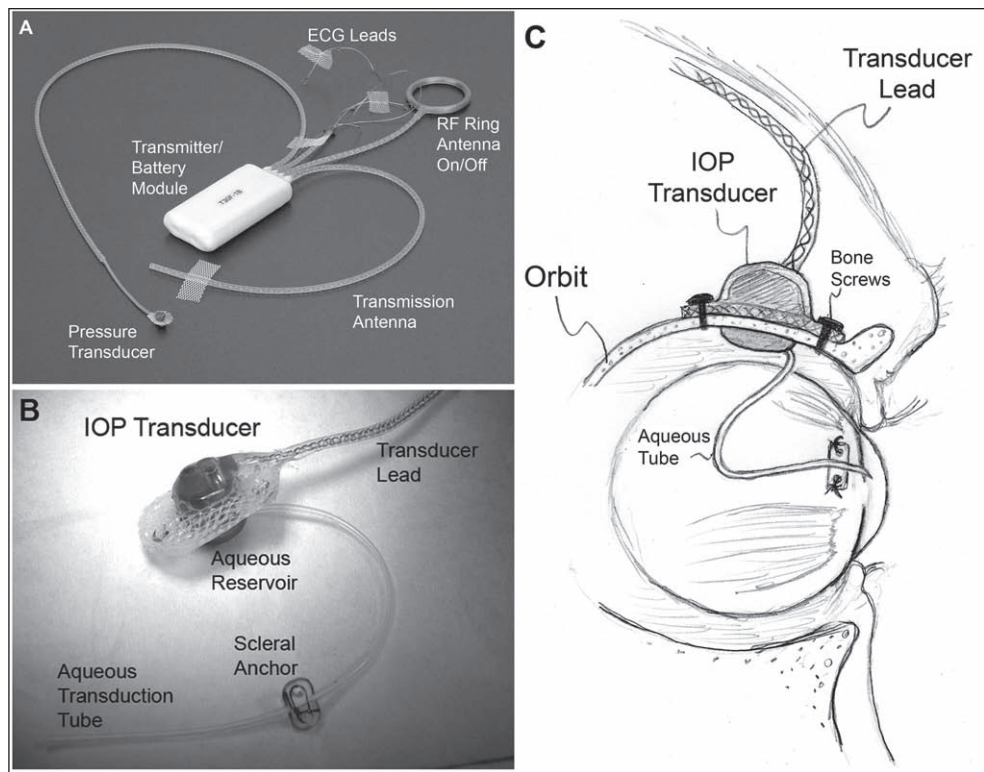
The Pro-IOP Sensor is a telemetric device that is implanted like an IOL.

hours.⁵ In a study of 35 patients whose IOP was recorded using a pneumatonometer in a sleep lab for 24 hours, most peak IOPs were recorded at night in older glaucoma patients compared to healthy people, whether sitting or lying down.⁶

More recently, investigators using 24-hour monitoring have learned that average IOP not only rises at night, but is actually spiking constantly—and more so during the day than at night.⁷ Researchers at the Devers Eye Institute in Portland, Ore., used a telemetry system implanted in monkey eyes to record 500 IOP measurements per second.

They found that IOP fluctuates much more than previously believed. “Blinks and eye movements generate large IOP spikes that occur about 12,000 times per hour and constitute about 12% of the total IOP energy that the eye must absorb during waking hours,” the researchers found. They believe that this data in monkeys will be about the same in humans. “IOP must now be viewed as dynamic and ever-changing, and IOP fluctuations may prove to be an important contributor to glaucoma.”⁸

They also found that the diurnal cycle does not repeat from day to day. Hence the need for continuous IOP monitoring. Current prototypes include implanted sensors and contact lens-based devices.



(A) A typical T30F total implant system (Konigsberg Instruments). **(B)** The extraorbital surface of the custom IOP transducer housing. **(C)** A 23-gauge silicone tube delivers aqueous from the anterior chamber to a fluid reservoir on the intraorbital side of the transducer (partially hidden from view in B); The tube (with appropriate slack to allow for eye movement) was trimmed and inserted into the anterior chamber.

Intelligent Implantables

Several start-up companies have been developing telemetric pressure sensors that can be implanted during cataract or glaucoma surgery. “Telemetric means that the pressure readings are captured remotely (i.e., from inside the eye) and transmitted wirelessly to an external reader,” says Dr. Sit.

Implantable devices currently being studied include:

- **Pro-IOP.** German-based Implandata Ophthalmic Products is working on the Pro-IOP, a wireless intraocular pressure transducer (WIT) that is powered telemetrically by a hand-held device. Resembling a tiny plastic ring, the WIT measures 11.3mm in diameter.⁹ It incorporates pres-

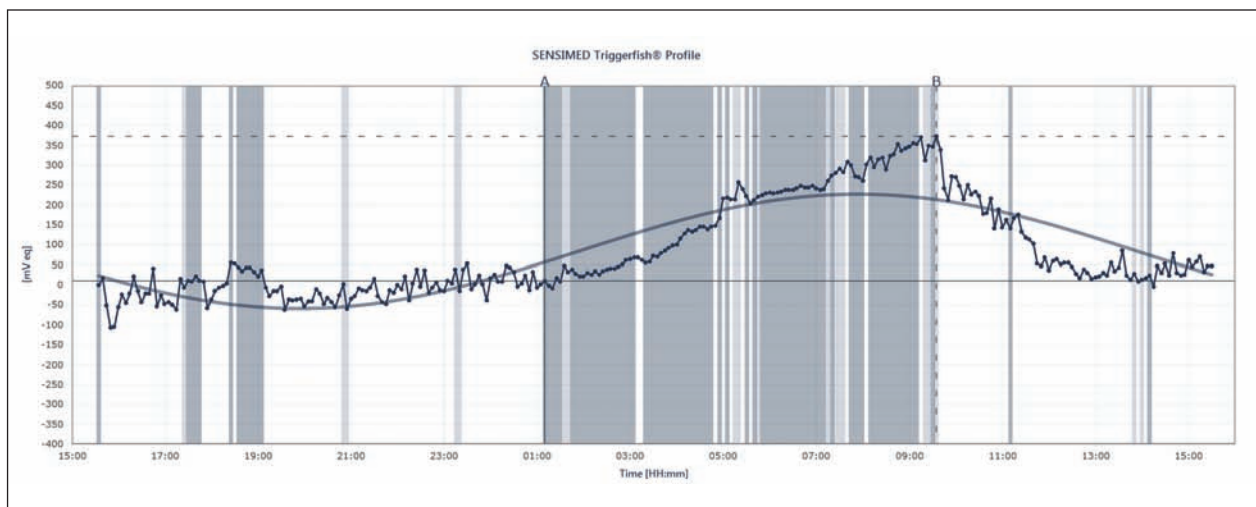
sure sensors, a temperature sensor, identification encoder, analog-to-digital encoder and telemetry unit into a single microelectromechanical system.⁹

An RFID chip with a built-in antenna broadcasts 24-hour IOP readings to an external hand-held reader. The patient and doctor may also eventually have the ability to receive the data via a smartphone app. The patient could also communicate with the doctor about IOP readings on the app.

The device has not yet received CE marks in Europe or FDA approval in the US, but researchers in Germany recently inserted the Pro-IOP into the first human subject, a woman in her 60s; no data has been published yet.⁹

IOP Monitoring

Photo: Kaweh Mansouri, MD, MPH



The flow chart shows the peaks and troughs of IOP in a patient wearing the Sensimed Triggerfish over a 24-hour period.

- **AcuMEMs.** An implantable in development by an American company of the same name, AcuMEMs functions similarly to the Pro-IOP. The sensor is a capacitive pressure sensor that changes shape with fluctuations in IOP. “When it changes shape, the electrical capacitance is altered and this can be detected externally with the reader,” says Dr. Sit.

The sensor can be implanted in the anterior chamber as a stand-alone procedure or as part of glaucoma surgery; it can also be inserted into the capsular bag during cataract surgery.

- **Microfluidic IOL implant.** Researchers at Stanford University and Bar-Ilan University in Israel are jointly developing an implantable microfluidic sensor. IOP would be measured “based on an established equilibrium pressure interface between an intraocular liquid and gas” contained in chambers in the sensor, according to the device patent. Patients and doctors could use their smartphones or an external reader to check their IOP.¹⁰ The inventors are awaiting patent approval for the sensor.

The signal transmitted from devices implanted in the eye may be more accurate than those attached to contact lenses, in theory, says Dr. Davey. The signal strength depends on how much energy the device puts out. “We implanted both devices (Pro-IOP and AcuMEMs) and they were not working so good,” Dr. Davey says.

Both the Pro-IOP and

AcuMEMs readers could potentially be attached to a pair of glasses, and data would be collected the same way, Dr. Sit says.

Clever Contact Lenses

Researchers first investigated contact lens sensors in the 1970s, but the available hard contact lenses were too uncomfortable and changed the structural integ-

Triggerfish Tracks IOP Differently

The Triggerfish contact lens differs from tonometry in how it records and presents data. The sensor does not transmit IOP in mm Hg. Instead, it’s measured in arbitrary units expressed as electric voltage, according to Dr. Mansouri. Various papers showed a correlation of 60% between the Triggerfish and tonometry readings measured in mm Hg.¹²

The data displayed on the external reader are a combination of intraocular pressure, intraocular volume and biomechanical properties of the eye, explains Dr. Mansouri. “It’s useful to give you an idea of the qualitative changes over 24 hours more than the quantitative changes because we cannot translate them into millimeters of mercury,” he says.

The Triggerfish provides valuable information nonetheless. Future studies using the device could help explain how unstable or stable pressure has been over 24 hours, when nighttime IOP peaks occur, how introducing treatment or treatment changes affects 24-hour IOP patterns and how specific activities affect 24-hour IOP patterns, such as yoga positions, caffeine intake, stressful situations and other causes of IOP spikes described above.

Dr. Mansouri also has normal or low-tension glaucoma patients undergo simultaneous 24-hour blood pressure and 24-hour IOP monitoring, as peaks may affect OPP.

But will the Triggerfish show a correlation between 24-hour IOP patterns and glaucoma progression? Many studies are underway to answer this essential question.

riety of the patient's eye, according to Dr. Davey.

The sensors were also not sensitive enough. "The person with a 'softer' eye had more accurate readings than a person with a more rigid eye," says Dr. Davey. "The technology was not good enough to get IOP values." A thicker cornea responds less readily to IOP changes, making tonometry (and contact lens sensors) less accurate.

Contact lens-based IOP sensors include:

- ***The Triggerfish (Sensimed).***

At the University of Geneva in Switzerland, ophthalmologists conducted early investigations of a contact lens dubbed the Triggerfish, led by Dr. Mansouri and others.

The Triggerfish is a hydrophilic soft contact lens fitted with a contact lens sensor (CLS). The CLS has two strain gauges located around the limbus that detect changes in ocular circumference. "These changes in ocular circumference are believed to be related to changes in IOP and intraocular volume, and this has been proven in enucleated eyes," says Dr. Mansouri. The device measures a mixture of IOP, intraocular volume and biomechanical property changes (a combination of corneal and scleral hysteresis and rigidity) that correlate with fluctuations in IOP. An external reader captures the data over a 24-hour period. (See "Triggerfish Tracks IOP Differently," page 30.)

The Triggerfish is CE mark-approved in Europe. FDA approval has not been reached in the US and the device is still undergoing clinical trials.

- ***Resonance circuit sensor contact lens.*** Another smart CLS device in development is a

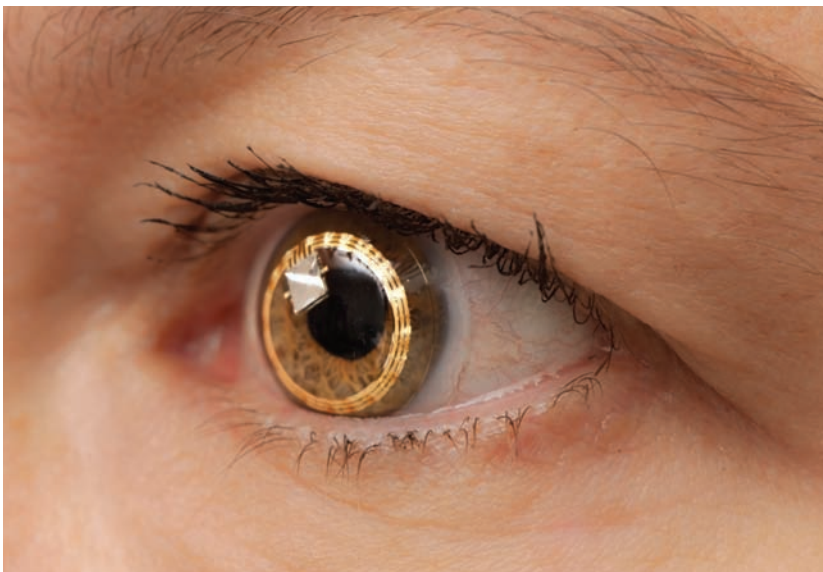


Photo: Sensimed AG

The Sensimed Triggerfish on the eye. It's still undergoing clinical trials in the US.

resonance circuit made of a thin-film capacitor combined with a sensing coil that detects corneal curvature deformation. It's in the early stages of development under David C.C. Lam at the Department of Mechanical and Aerospace Engineering at the Hong Kong University of Science and Technology.

In a September 2014 study, the CLS was tested on a silicone rubber eye model. The sensor was found to accurately track fluctuating IOP.¹¹

Like measuring glucose levels once a day for patients with diabetes or blood pressure once a day for heart disease patients, reliance on one IOP measurement could result in erroneous IOP data. But perhaps in the not-too-distant future, devices right out of a science fiction movie—contact lens and implantable sensors—could let you track IOP with greater understanding and less hassle for you and your patients. ■

1. Liu JH1, Gokhale PA, Loving RT, Kripke DF, Weinreb RN.

Laboratory assessment of diurnal and nocturnal ocular perfusion pressures in humans. *J Ocul Pharmacol Ther.* 2003 Aug;19(4):291-7.

2. Zeimer RC, Wilensky JT, Gieser DK, Viana MA. Association between intraocular pressure peaks and progression of visual field loss. *Ophthalmology.* 1991 Jan;98(1):64-69.

3. Konstas AG, Quaranta L, Mikropoulos DG, et al. Peak Intraocular Pressure and Glaucomatous Progression in Primary Open-Angle Glaucoma. *J Ocul Pharmacol Ther.* 2012 Feb;28(1):26-32.

4. Mansouri K, Weinreb RN, Medeiros FA. Is 24-hour intraocular pressure monitoring necessary in glaucoma? *Semin Ophthalmol.* May 2013; 28(3):157-164.

5. Barkana Y, Anis S, Liebmann J, Tello C, Ritch R. Clinical utility of intraocular pressure monitoring outside of normal office hours in patients with glaucoma. *Arch Ophthalmol.* 2006 Jun;124(6):793-7.

6. Mosaed S, Liu H, Weinreb RN. Correlation between peak nocturnal intraocular pressures in healthy subjects and glaucoma patients. *Am J Ophthalmol.* 2005; Feb;139(2):320-4.

7. Downs JC, Burgoyne CF, Seigfried WP, et al. 24-hour IOP telemetry in the nonhuman primate: implant system performance and initial characterization of IOP at multiple timescales. *Invest Ophthalmol Vis Sci.* 2011 Sep 21;52(10):7365-75.

8. Association for Research in Vision and Ophthalmology: Emerging trends and hot topics. Presented Monday, May 5, 2014 at the ARVO Annual Meeting. Available at: www.arvo.org/About_ARVO/Press_Room/Emerging_Trends_and_hot_topics_Presented_Monday_May_5_at_the_ARVO_Annual_Meeting. Accessed Nov 19, 2014.

9. Melki S, Todani A, Cherfan G. An Implantable Intraocular Pressure Transducer Initial Safety Outcomes. *JAMA Ophthalmol.* 2014 Oct 1;132(10):1221-5.

10. Mandel Y, Araci IE, Quake SR. Google Patents. Implantable micro-fluidic device for monitoring intraocular pressure. Available at: www.google.com/patents/WO2014137840A1?cl=en. Accessed October 17, 2014.

11. Chen GZ, Chan IS, Leung LK, Lam DC. Soft wearable contact lens sensor for continuous intraocular pressure monitoring. *Med Eng Phys.* 2014 Sep;36(9):1134-9.

12. Mottet B, Aptel F, Romanet JP, et al. 24-hour intraocular pressure rhythm in young healthy subjects evaluated with continuous monitoring using a contact lens sensor. *JAMA Ophthalmol.* 2013 Dec;131(12):1507-16.

37th Annual Technology Report

OCT Testing Receives a 'Nice Complement'

Today, a multitude of diagnostic technologies can support glaucomatous, corneal and posterior segment findings detected via optical coherence tomography.

By Amanda S. Legge, OD

During the last 15 years, optical coherence tomography (OCT) has revolutionized the way eye care practitioners diagnose and evaluate sight-threatening retinal, optic nerve and anterior segment disease. The technology has the unique ability to capture cross-sectional images of the cornea, retina and other ocular structures by evaluating interference patterns of reflected laser light. It is also able to analyze retinal nerve fiber layer (RNFL) and ganglion cell complex (GCC) thickness, generate a pachymetry map of the central cornea, and determine the exact degree of the anterior chamber angle.

Additional diagnostic technologies that have gained mainstream acceptance in recent years suitably complement OCT imaging. These include photography with fundus

autofluorescence (FAF), visual evoked potential (VEP), pattern electroretinogram (pERG), dark adaptation, formal visual field (VF), corneal topography, specular microscopy and B-scan ocular ultrasound. Correlating relevant clinical data can enhance and accelerate disease diagnosis and progression evaluation, as well as help guide management decisions.

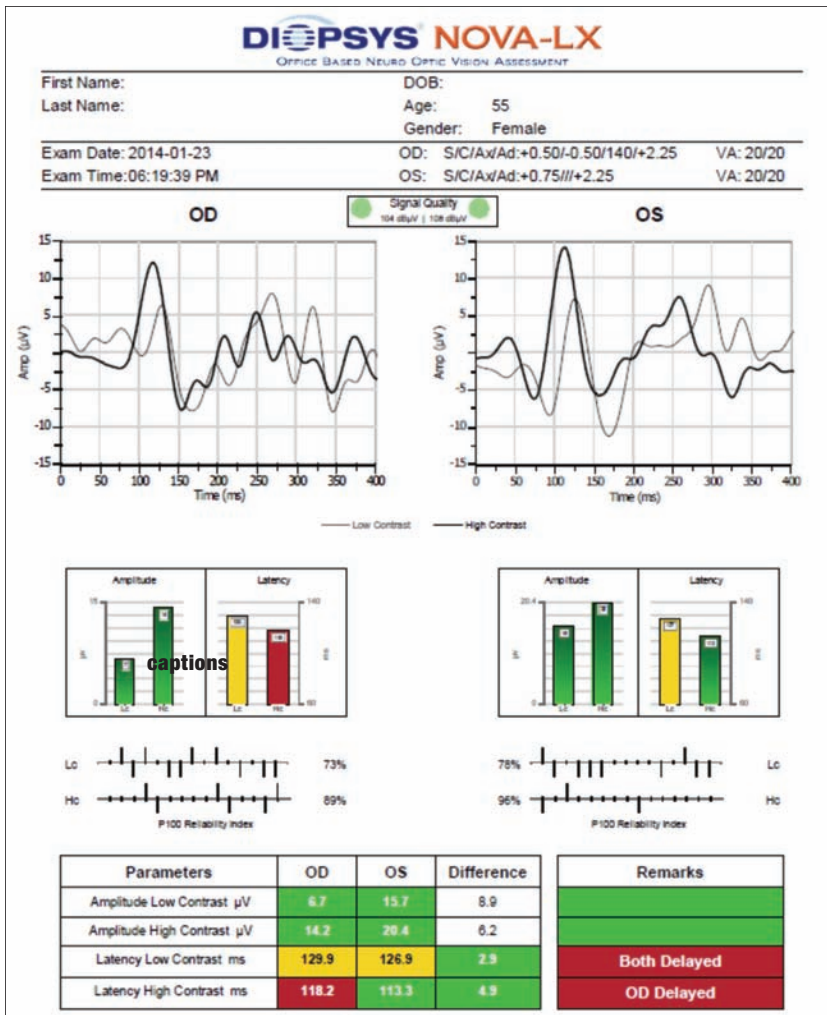
OCT Correlations in Glaucoma Testing

When diagnosing and managing glaucoma patients, daily data correlation is something we are already comfortable with. For example, a thinned inferior retinal nerve fiber layer on OCT that matches a superior nasal step on the visual field with thin pachymetry enables a straightforward diagnosis. In conjunction with

gonioscopy, this is the conventional method used to diagnose early glaucomatous change and monitor carefully for progression.

Newer instruments and software are now available to make the diagnosis of glaucoma even more precise. Further, this complementary data helps us diagnose borderline or anomalous cases that are not so clear, and allows detection of early disease progression in those already being treated for ocular hypertension or glaucoma.

- **VEP.** Visual evoked potential and pattern electroretinogram, previously reserved for specialty clinics, recently have been used more routinely in the detection and management of glaucoma. Both tests evaluate optic nerve function (which may diminish before structural damage manifests), and can help detect other optic neuropathy.



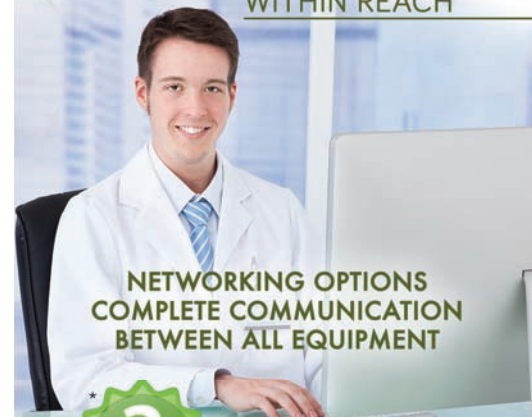Using visual evoked potential (VEP), the patient described in Case #1 exhibited borderline delayed latency at low contrast OU and delayed latency at high contrast OD. These findings are indicative of a functional deficit.

thies and macular diseases.

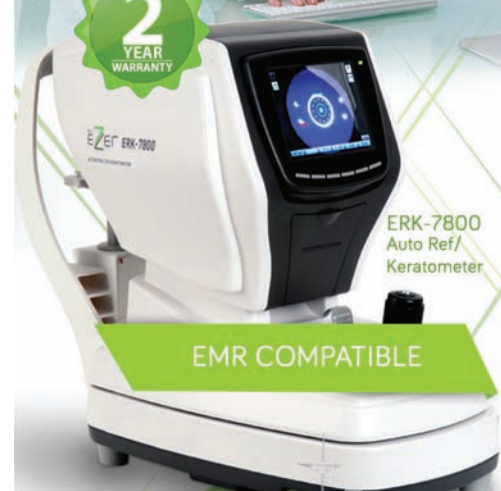VEP testing uses a reversal stimulus technique to measure visual pathway stability, as well as the conduction integrity of the optic nerve and ganglion cell axons. Electrodes are placed in standardized positions in order to detect electrical signals and the conduction rate of the visual cortex. The patient views a screen that generates a reversing black and white checkerboard pattern.

The Diopsys NOVA-VEP system for glaucoma tests at both high-

and low-contrast levels, which permits separation and interpretation of the parvocellular and magnocellular pathways.¹ In early glaucomatous change, the magnocellular pathway becomes dysfunctional, and thus the low-contrast amplitude of VEP appears abnormal first.² In more advanced stages of glaucoma, the high-contrast VEP appears abnormal as the parvocellular pathway becomes involved.¹ Thus, low-contrast abnormalities are a diagnostic indicator in early glaucoma cases.



NETWORKING OPTIONS
 COMPLETE COMMUNICATION
 BETWEEN ALL EQUIPMENT



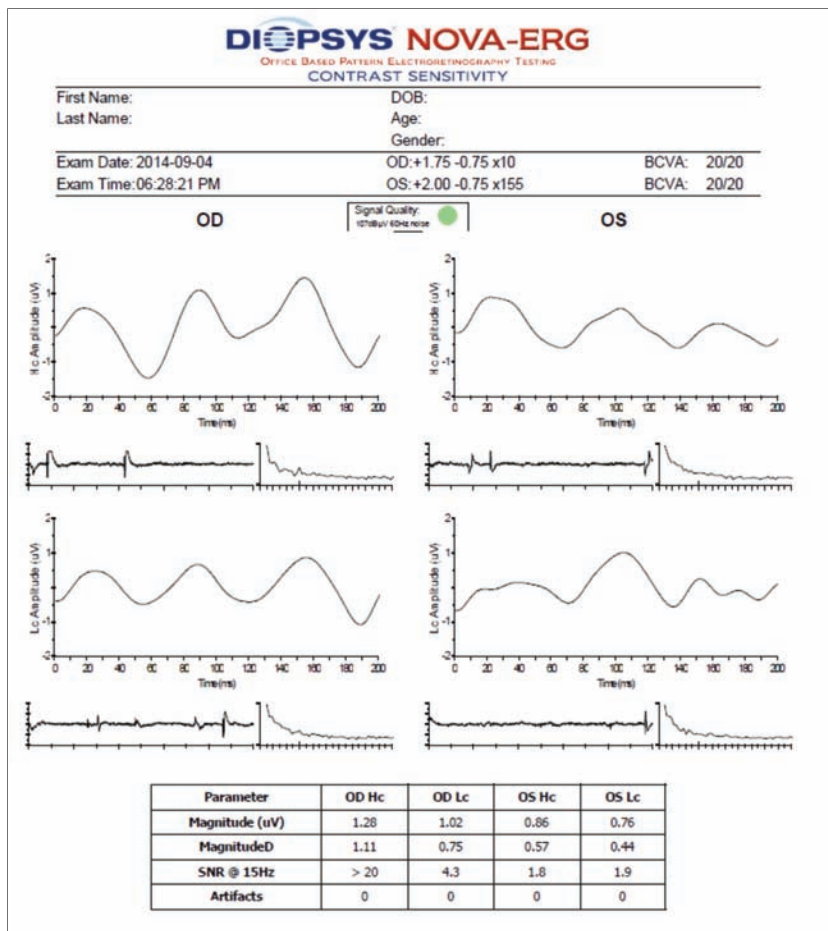
ERK-7800
 Auto Ref/
 Keratometer

EMR COMPATIBLE



EZER Digital Practice

*2 Year warranty available on the ERK-7800, EDR-7800 and ECP-5400 only.



Contrast sensitivity electroretinogram (ERG) indicated that the low-contrast waveform pattern OS was moderately abnormal in the patient described in Case #1. Together with the VEP results and ganglion cell complex findings, we diagnosed her with primary open-angle glaucoma.

Increased VEP latency is correlated with the degree of cupping and level of optic disc cupping (in the case of optic neuropathy), as well as the severity of visual field deficit on standard automated perimetry. It is not, however, associated with intraocular pressure, miotic pupils, increased age or reduced visual acuity.³

• **pERG.** The electrical responsiveness of retinal ganglion cells is measured by pERG with the Diopsys NOVA-ERG contrast sensitivity software. Similar to VEP testing, electrodes are placed in standardized positions—but, in this

instance, can garner information about retinal (specifically macular) electrical activity when the patient looks at a contrast-reversing stimulus.

In the early stages of glaucoma, the pERG signal from the ganglion cells diminish at a rate that exceeds the expected loss from the ganglion cell axon structure, which correlates with RNFL loss observed on OCT.⁴ Therefore, it is reasonable to monitor glaucoma suspects or established patients more carefully when they demonstrate significant abnormal pERG amplitudes, because these individuals have a

higher rate of RNFL thinning and glaucomatous progression.⁵

• **GCC imaging.** The ganglion cell complex (GCC) is comprised of the three innermost retinal layers (the nerve fiber layer, ganglion cell layer and inner plexiform layer), which likely are damaged in the earliest stages of glaucoma—even before ganglion cell axonal loss is clinically evident.⁷ Glaucoma preferentially affects these inner layers, as opposed to all macular layers, because they contain not only the axons but also the cell bodies and dendrites of the ganglion cells.⁸

GCC analysis software, available on newer OCT units, aids tremendously in glaucoma progression monitoring. When examining patients, this software is able to detect the earliest structural changes by evaluating only the inner retinal layers.⁶

Case #1 History

A 55-year-old white female was referred for glaucoma testing because of an increased and asymmetric cup-to-disc ratio (CDR) noted during clinical examination. She reported no visual or ocular complaints.

Diagnostic Data

Her best-corrected visual acuity measured 20/20 OD, OS and OU at distance and near. Untreated intraocular pressure measured 19mm Hg OD and 18mm Hg OS. Gonioscopy showed a wide-open angle to the ciliary body, with minimal pigment—although a few iris processes were seen in each quadrant. The iris had a flat contour. Upon dilated funduscopy, CDR measured 0.6 x 0.5 OD and 0.55 x 0.5 OS, with shallow cupping.

Retinal nerve fiber layer evaluation showed superior thinning and

borderline inferior thinning OD, with borderline inferior thinning OS. GCC analysis showed borderline thinning OU. Global loss volume was borderline, while focal loss volume (FLV%) was normal. However, we observed a significant interocular difference in FLV%.

Central pachymetry was moderately thin, measuring 496 μ m OD and 497 μ m OS. Humphrey 24-2 visual field was within normal limits OD; however, we recorded a high number of fixation losses. The left eye exhibited superior central defects with non-edge points and good reliability. We noted no significant ptosis during the clinical examination that might account for this pattern.

Diopsys contrast sensitivity ERG at 64-grating showed normal waveform patterns at high and low contrast OD, as well as a normal waveform pattern at high contrast OS. The N35, P50 and N95 peaks were easily identifiable, although amplitude—rather than latency—is the most sensitive electrophysiologic parameter for early glaucoma detection.⁹

Low-contrast waveform pattern was moderately abnormal OS. Because this ERG is not yet compared with age-related normals, interpretation is largely up to the managing clinician. Using 1.2 μ V as the normative cutoff, the right eye was within normal limits at high and low contrast, and the left eye was mildly abnormal at high contrast and moderately abnormal at low contrast. There also was a significant intereye difference, with amplitudes much smaller OS than OD at both high and low contrast.

The Diopsys NOVA-LX VEP is compared to age-related normals, so its results are easier to interpret. In glaucoma, the latency of VEP is more closely correlated to damage

than the amplitude, which is the opposite of pERG testing.¹⁰ Both eyes exhibited borderline delayed latency at low contrast. Additionally, the right eye showed evidence of delayed high contrast.

Discussion

Although the visual field findings were not very impressive or highly indicative of early glaucomatous field loss, the pERG and VEP confirm a functional deficit—especially when correlated with retinal nerve fiber layer and GCC analysis.

Along with the knowledge of thinned pachymetry readings, the open chamber angles on gonioscopy and CDR measurements obtained via funduscopy and fundus photography, we diagnosed patient with primary open-angle glaucoma.

OCT Correlations in Anterior Segment Disease

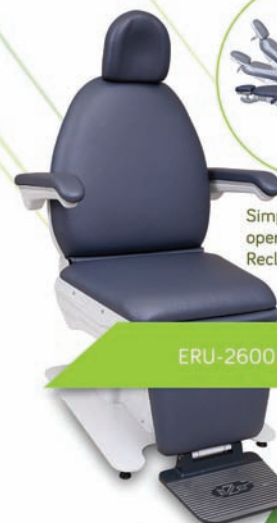Today, anterior segment OCT allows clinicians to evaluate corneal pachymetry from the central cornea out to 10mm, as well as more effectively quantify anterior chamber angle measurements. Further, the technology is capable of generating in vivo pseudo-histology data of anterior segment structures, including the cornea and iris.

In addition to slit lamp photography and anterior segment OCT, specular microscopy and corneal topography can help eye care providers more effectively examine corneal, iris and angle structures when diagnosing anterior segment disease.

• **Specular microscopy.** While OCT can evaluate the anatomic structure of all corneal layers in cross-section, specular microscopy provides a non-invasive, morphological analysis of the endothelial layer. It is the best imaging modal-

ELI
EZER

EZER WAY OF LIFE



ERU-2600 CHAIR



Simple One Touch operation control panel. Reclines 180°.



ERU-2600 STAND

THE MOST POPULAR STAND MODEL IN THE MARKET. CAN BE USED WITH THE ERU-2600 OR THE ERU-5200 CHAIR.



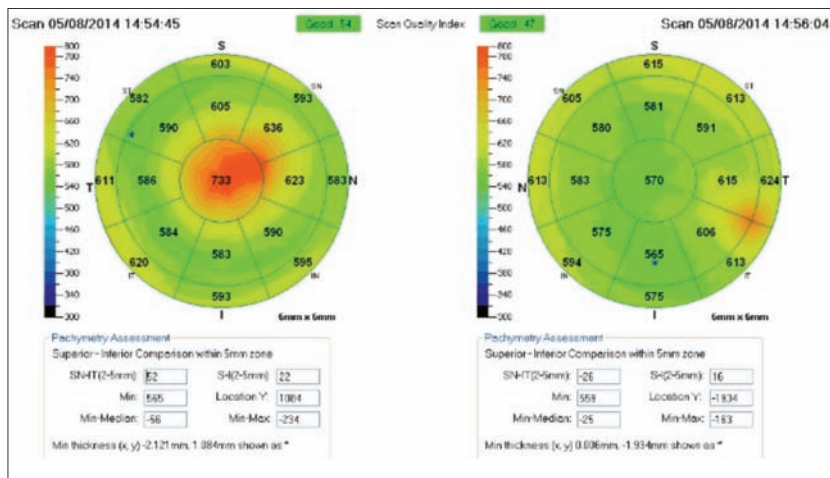
ERU-5200 CHAIR



Simple patient positioning of up to 45° recline.

USO
US OPHTHALMIC

www.usophthalmic.com
info@usophthalmic.com
Toll Free 1.888.334.4640



Anterior segment OCT pachymetry provides both qualitative and quantitative information over a 6mm diameter, which helps the clinician monitor treatment success. For the patient described in Case #2, the pachymetry report showed the presence of edema in the exact area of endothelial disruption seen at the slit lamp OD.

ity for analyzing corneal endothelial changes secondary to damage and cell death caused by disease, trauma or chemical toxicity.

Specular microscopy also is useful to evaluate cells that vary in size (polymegethism) and shape (polymorphism).¹¹ This capability makes it especially helpful when evaluating contact lens-related hypoxia, because affected patients typically exhibit statistically greater polymegethism while maintaining a normal endothelial cell density.¹²

- **Corneal topography.** This diagnostic technique offers qualitative and quantitative information about corneal curvature. While some topographers generate various topographical representations and analyses, all devices share core measurement characteristics that can be used to evaluate corneal disease, unusual steepening or flattening, irregular astigmatism and contact lens fits. Particularly in corneal disease, comparing corneal topography to cross-sectional, OCT-derived, semi-histological information offers a more complete understanding of current epithelial

status and long-term progression.

- **Pachymetry.** A measurement of corneal thickness is helpful in evaluating for the presence of edema or ectasia. Anterior segment OCT is capable of capturing a pachymetry measurement from several millimeters of cornea, rather than a single, central measurement via specular microscopy or conventional instrumentation. These measurements can be compared to corneal OCT scans taken at the site of concern in order to compare anatomic variation with topographical and quantified corneal thickness.

Case #2 History

A 57-year-old white male presented six weeks after uneventful cataract surgery OU. He had no documented history of retinal disease.

Diagnostic Data

His best-corrected visual acuity measured 20/40 OD and 20/30 OS. Funduscopy and OCT imaging did not reveal any evidence of macular pathology. Slit-lamp examination

showed corneal endothelial disturbance and stromal edema central OD and inferotemporal OS. We then performed corneal/external slit lamp photography, as well as anterior segment OCT and specular microscopy, to determine the underlying etiology and extent of disruption.

Evidence of endothelial tear and scarring was documented central OD and paracentral OS. Overlying stromal edema also was evident on OCT.

Discussion

Based on these findings, we placed the patient on Muro 128 (Bausch + Lomb) solution BID OU and Muro 128 ointment QHS OU. We referred him to a corneal specialist, who agreed with our findings of corneal endothelial disruption and central tear following cataract surgery with secondary stromal edema.

We then scheduled him for a two-month follow-up. If we do not see improvement in his signs and symptoms at that visit, we will likely consider referring him for DSAEK.

OCT Correlations in Macular Health

Optical coherence tomography helps eye care providers more effectively identify and treat diabetic macular edema, choroidal neovascularization, macular atrophy and central serous chorioretinopathy. Additionally, the technology helps differentiate between similar pathologies, such as vitelliform dystrophy and macular degeneration.

Certainly, spectral domain OCT's high-resolution capabilities have made it even easier to diagnose retinal pathologies than it was using previous-generation, time-

domain instruments. New OCT software also has the ability to examine the inner and outer retina, either simultaneously or separately, and can provide en face imaging for macular surface disease, such as epiretinal membrane.

In addition to OCT, macular disease can be monitored via fundus photography, fundus autofluorescence (FAF), multispectral imaging (MSI) and dark adaptation.

- **FAF.** Unlike other diagnostic technologies, fundus autofluorescence permits interpretation of the retinal pigment epithelium by imaging lipofuscin—a retinal fluorophore that ultimately accumulates in retinal pigment epithelium (RPE) lysosomes during photoreceptor outer segment phagocytosis. This allows indirect interpretation of the RPE's metabolic activity.¹³

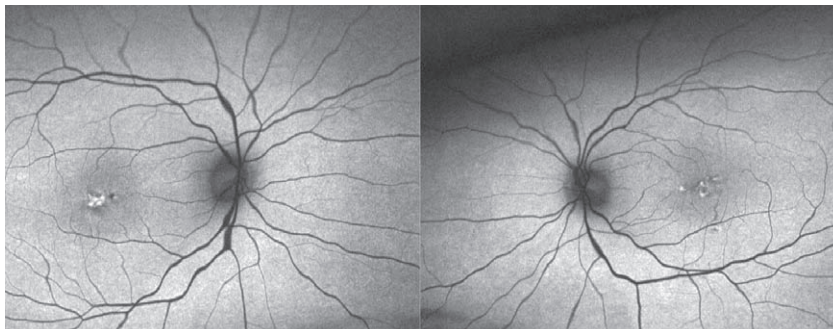
FAF imaging of a disease-free retina produces a uniform, granular, slightly hyperautofluorescent signal. Retinal disease and photoreceptor cell death, however, results in decreased autofluorescence secondary to diminished or non-existent metabolic demand on the RPE. Increased autofluorescence is due to rapid photoreceptor turnover or an abnormality in the phagosomal uptake of lipofuscin. In this instance, the patient has RPE compromise and active retinal disease.¹⁴

- **MSI.** Multispectral imaging is a noninvasive technique that permits an assessment of structural change in individual retinal layers and the choroid, based on their absorption spectra. MSI's en face progressive imaging technique enhances the localization, and thus interpretation, of retinal pathologies.¹⁵ Some software also offers a perfusion map feature that can identify exudative retinopathy by examining oxygenated vs. deoxygenated hemoglobin to identify changes in retinal vasculature and leakage.

- **Dark adaptation.** AdaptDx (Maculogix) is a newly available device that is particularly useful in evaluating retinal conditions that cause impaired dark adaptation, such as retinitis pigmentosa and inherited retinal dystrophies. Additionally, the technology is extremely helpful in identifying early age-related macular degeneration (AMD).

Photoreceptors require specific nutrients to replenish pigments and clear opsin in order to regain dark vision sensitivity after light exposure. As the RPE/Bruch's membrane complex structurally deteriorates in macular or retinal disease, nutrient and oxygen transportation to the rod and cone outer segments slows.¹⁶

Specifically in AMD, rod loss



Fundus autofluorescence imaging of our patient described in Case #3 (OD left, OS right) showed abnormal hyperautofluorescence located centrally (OD > OS).

ELI
EZER

EZER WAY OF LIFE

**GREAT
QUALITY OPTICS**



**Latest Technology
ESL-7800**



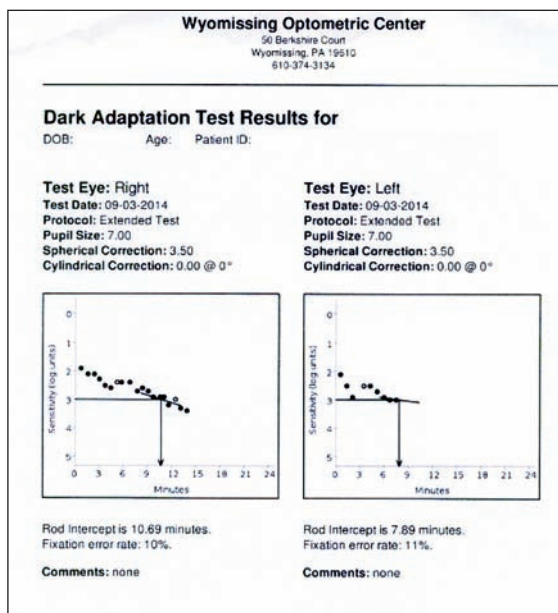
**Style and comfort
ESL-1800 / ESL-5200**



ESL-2600/ ESL-1200

USO
US OPHTHALMIC

www.usophthalmic.com
info@usophthalmic.com
Toll Free 1.888.334.4640



Normal dark adaptation time is 6.5 minutes or less. But, the patient described in Case #3 had a delayed rod intercept time of 10.69 minutes OD and 7.89 minutes OS.

precedes, and is more severe than, cone loss in the parafovea. This holds true even in the exudative form of AMD.¹⁷ Therefore, dark adaptation is a prominent early functional marker of AMD, with greater than 90% sensitivity and specificity following AdaptDx testing.¹⁸

Case #3 History

A 55-year-old white female presented with a history of exudative AMD in her right eye and nonexudative AMD in her left eye.

Diagnostic Data

Her best-corrected visual acuity measured 20/25-2 OD and 20/25 OS. She exhibited mild central metamorphopsia in her right eye on Amsler testing; however, her left eye was normal.

Fundus photography revealed RPE clumping and minimal drusen formation in both eyes. Additionally, her right eye exhibited a small

disciform scar located temporal to the foveal avascular zone.

Optical coherence tomography confirmed the disciform scar's location OD, as well as the bilateral drusen formation. Further, the OCT scan indicated that the photoreceptor integrity layer was intact OU, explaining the reasonably good visual acuity. Fundus autofluorescence showed abnormal hyperautofluorescence located centrally (OD > OS).

Dark adaptation showed delayed rod intercept of 10.69 minutes OD and 7.89 minutes OS, which matched the clinical scenario (i.e., the most severe findings were documented in the right eye). Normal dark adaptation time is 6.5 minutes or less, so the patient exhibited moderate bilateral impairment at baseline.

Discussion

The patient was already taking an AREDS supplement, and performing at-home Amsler monitoring. Because of the exudative status OD, as well as delayed dark adaptation OU, we scheduled her to return to the office every three months.

Optical coherence tomography has greatly enhanced clinical management of ocular disease; however, it only provides us with a modest portion of the total clinical picture.

In conjunction with OCT, other technologies used to assess en face structure and tissue function give

a more complete understanding of the pathology. Together, these instruments allow us to document disease progression over time, as well as evaluate the clinical efficacy of any prescribed treatment intervention. ■

Dr. Legge is in private practice at Wyomissing Optometric Center in Pennsylvania.

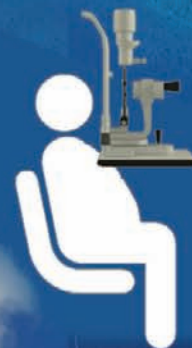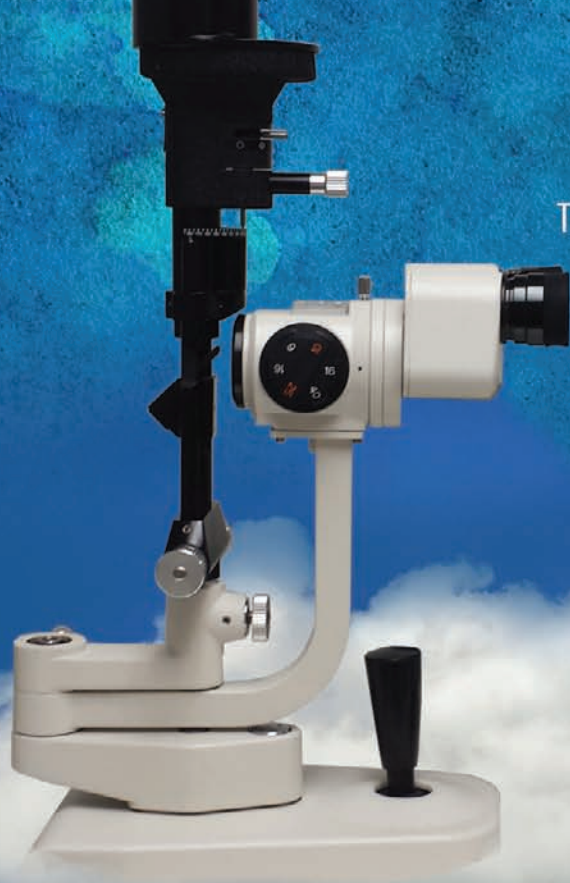- Rudvin I, Valberg A, Kilvak BE. Visual evoked potentials and magnocellular and parvocellular segregation. *Vis Neurosci.* 2000 Jul-Aug;17(4):579-90.
- Klistorner A. Early magnocellular loss in glaucoma demonstrated using the pseudorandomly stimulated flash visual evoked potential. *J Glaucoma.* 1999 Apr;8(2):87-154.
- Towle V, Moskowitz A, Sokol S, Schwartz B. The visual evoked potential in glaucoma and ocular hypertension: effect of check size, field size, and stimulation rate. *Invest Ophthalmol Vis Sci.* 1983 Feb;24(2):175-83.
- Ventura L. The relationship between retinal ganglion cell function and retinal nerve fiber layer thickness in early glaucoma. *Invest Ophthalmol Vis Sci.* 2006 Sep;47(9):3904-11.
- Banitt M. Progressive loss of ganglion cell function precedes structural loss by several years in glaucoma suspects. *Invest Ophthalmol Vis Sci.* 2013 Mar;54(3):2346-52.
- Ou T, Chopra V, Tzu-Hiu Lu A, et al. Detection of macular ganglion cell loss in glaucoma by fourier-domain optical coherence tomography. *Ophthalmology.* 2009 Dec;116(12):2305-14.e2.
- Mosca M, Rossi A, Sala R, Ratiglia R. Ganglion cell complex and peripapillary RNFL alterations in patients with open-angle glaucoma. *Invest Ophthalmol Vis Sci.* 2013;54:E-Abstract 2249.
- Kendell K, Quigley H, Kerrigan L, et al. Primary open-angle glaucoma is not associated with photoreceptor loss. *Invest Ophthalmol Vis Sci.* 1995 Jan;36(1):200-5.
- Ucles P, Almarcegui C, Fernandez F, Honrubia F. Early diagnosis of glaucoma with pattern-ERG. *J Fr Ophthalmol.* 1997 Feb;20(2):90-6.
- Parisi V, Miglior S, Manni G, et al. Clinical ability of pattern electroretinograms and visual evoked potentials in detecting visual dysfunction in ocular hypertension and glaucoma. *Ophthalmology.* 2006 Feb;113(2):216-28.
- McCarey B, Edelhauser H, Lynn M. Review of corneal endothelial specular microscopy for FDA clinical trials of refractive procedures, surgical devices, and new intraocular drugs and solutions. *Cornea.* 2008 Jan;27(1):1-16.
- McLaughlin R. Corneal endothelial response to refitting polymethyl methacrylate wearers with rigid gas-permeable lenses. *Optom Vis Sci.* 1990 May;67(5):346-51.
- Wing G, Blanchard G, Weiler J. The topography and age relationship of lipofuscin concentration in the retinal pigment epithelium. *Invest Ophthalmol Vis Sci.* 1978 Jul;17(7):601-7.
- von Rückmann A, Fitzke F, Bird A. Distribution of fundus autofluorescence with a scanning laser ophthalmoscope. *Br J Ophthalmol.* 1995 May;79(5):407-12.
- Everdell J, Styles I, Calcagni A, et al. Multispectral imaging of the ocular fundus using LED illumination. *Rev Sci Instrum.* 2010 Sep;81(9):093706.
- Owsley C, Jackson G, White M, et al. Delays in rod-mediated dark adaptation in early age-related maculopathy. *Ophthalmology.* 2001 Jul;108(7):1196-202.
- Curcio C, Medeiros N, Millican C. Photoreceptor loss in age-related macular degeneration. *Invest Ophthalmol Vis Sci.* 1996 Jun;37(7):1236-49.
- Jackson G, Scott I, Kim I, et al. Diagnostic sensitivity and specificity of dark adaptometry for detection of age-related macular degeneration. *Invest Ophthalmol Vis Sci.* 2014 Mar;55(3):1427-31.

ELEVATE

The slit lamp experience you've been waiting for is here.

Introducing the **HAI SL-5000e ELEVATE**, the world's first slit lamp redesigned from the ground up to meet the challenge of examining plus-sized patients and patients with limited mobility.

Developed through years of input from doctors, ELEVATE combines the power and features of a traditional slit lamp with a streamlined foundation. By raising the first point of contact between patient and tabletop to the upper chest, the patient can comfortably reach the chinrest and the operator can conduct a thorough exam.



Patent pending.
© 2014 HAI Laboratories, Inc.
All rights reserved.

Visit www.hailabs.com/elevate to learn more.

HAI
Laboratories, Inc.

YEAR-END 2014 CLEARANCE PRICES

	LIST PRICE	SALE PRICE
Basic Exam Lane Package*	\$12,998	\$11,500
SL-5000p Plus Slit Lamp	\$6,300	\$4,850
SL-5000s Standard Lamp	\$4,800	\$2,900
SL-5000h Handheld Slit Lamp	\$3,150	\$2,125
VC-170 17" LED Vision Chart	\$2,500	\$1,500
AB-6100 A/B Ultrasonic Scan	\$12,000	\$8,800

* Includes: HAI SL-5000b Basic Slit Lamp, HAI VC-170 17" LED Vision Chart, S4OPTIK CB-1600 Chair & Stand Combo and SL-Y100 Refractor

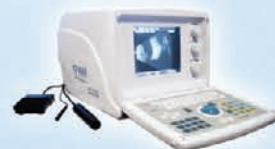

Basic Exam Lane Package

Get these great deals on clearance while supplies last!



HAI SL-5000h
Handheld Slit Lamp



HAI AB-6100
A/B Ultrasonic Scan

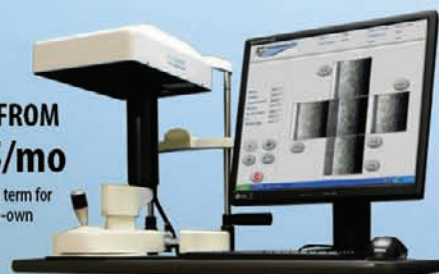
**NEW
MODEL**



**HAI SL-5000bx
Basic Slit Lamp**
Introductory
Price: **\$1,800**

**RENT FROM
\$385/mo**

52-month term for
rent-to-own



HAI CL-1000nc Non-Contact Specular Microscope

HAI
Ophthalmic

Visit www.haiophthalmic.com to order online, or call (781) 862-9884 for assistance!

37th Annual Technology Report

Technology Survey: What You Have Your Eyes On

To improve their care, optometrists have OCTs, digital cameras and automated refraction systems on their wish lists right now. **By John Murphy, Executive Editor**

What technology tops optometrists' wish lists right now? You might be surprised to learn that it's not a digital fundus camera or an optical coherence tomographer (OCT). It's not even a whiz-bang instrument like a tear film osmolarity tester.

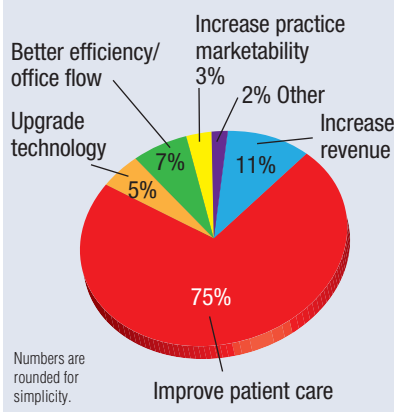
The number one item that ODs are looking to buy: an automated phoropter.

"The automated refraction system I bought last year increased my efficiency, reduced chair time and is a huge 'WOW' with my patients," says Mitchell Shulkin, OD, of San Diego. "I see more patients in less time."

Optometrists like Dr. Shulkin and others are seeking to increase productivity by seeing more patients per hour. Of course, increasing efficiency doesn't have to mean compromising care. Indeed, the primary reason why most ODs (75%) invest in new technology is to improve patient care.

These are just a few of the results

What is your most important factor for buying new technology?



from our latest Annual Diagnostic Technology Survey, based on the responses of 263 optometrists to an email questionnaire.

Top 10 Most Wanted

An automated phoropter is just one of the many technologies that optometrists currently have their eyes on. Of the top 10, here are the remaining nine most wanted items, in descending order:

2. OCT
3. Electronic health records (EHR)/software that integrates equipment and practice management programs
4. Spectral-domain OCT (SD-OCT)
5. Digital anterior segment camera
6. Tear film osmolarity test (TearLab)
7. Corneal topographer
8. Pachymeter
9. Digital fundus camera
10. Patient callback/reminder system

To obtain any of these instruments, optometrists aren't planning to bet the farm. Most of the ODs surveyed (about 53%) said they're planning to spend no more than \$20,000 on new technology in the coming year. And of these, about two-thirds say they'll spend less than \$10,000.

The majority (72%) say they'll buy their next big equipment investment, although one in four (24%) plan to lease it.

Top 10 Recently Purchased

Here are the top technologies and instruments that optometrists obtained in the past two years, in descending order:

1 and 2 (tie). Digital fundus camera; EHR/software that integrates equipment and practice management programs

3. SD-OCT

4 and 5 (tie). Corneal topographer; patient callback/reminder system

6. Automated refraction system

7. Tonometer

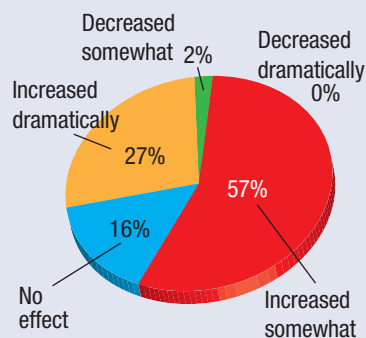
8. Perimeter/visual field analyzer

9. OCT

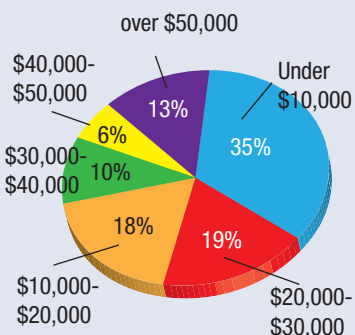
10. Widefield scanning laser ophthalmoscope (Optomap)

Of these, it's no surprise that EHRs topped the list, thanks to the

Has this new technology increased your profitability?



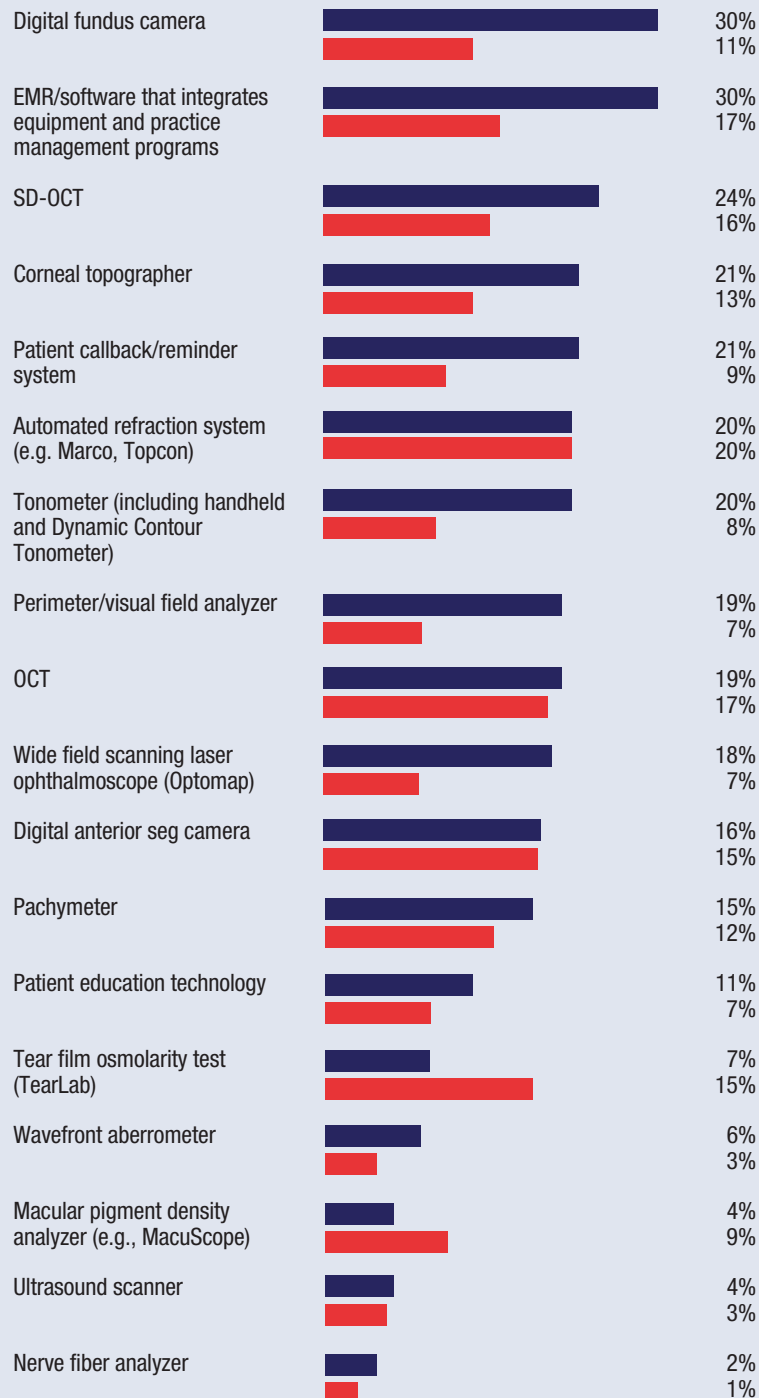
How much will you be spending on instruments and equipment this year?



What New Instruments Did You Get? Which Do You Want?

■ What new technology have you obtained in the past two years?

■ What new technology are you seriously considering/planning to obtain?



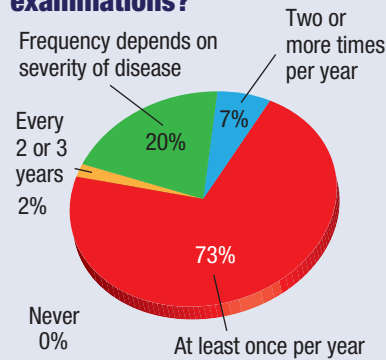
Health Information Technology for Economic and Clinical Health (HITECH) Act, which essentially mandates EHRs by 2015.

For many ODs, the switch to EHR has actually done what it's supposed to do: "Our new practice management software with EHR makes all aspects of the practice run better," says optometrist Lee D. Caplan of Baltimore. "Eliminating [both] patient paper files and the problem with paper file storage is absolutely fantastic."

Other top technologies that ODs are happy with:

- **Retinal camera.** "We are a new office, and being able to offer the latest and greatest while still being affordable and profitable is great. And it's great for when fill-in doctors and I see each other's patients," says Judy Nguyen, OD, of Newark,

For patients with eye diseases such as glaucoma or diabetes, how often do you perform fundus examinations?



Calif. "A picture is worth a thousand words."

Optometrist Leslie Varkey of Houston says, "I bought a fundus camera to better serve my patients. I take pictures of everything. It's

a great educational tool as well as great for documentation purposes. It has definitely increased my profit/revenue in the office."

- **OCT and SD-OCT.** "The OCT has had a phenomenal effect on patient care. My geriatric population benefits because many have mobility issues and no longer need to travel to another office to have this test completed," says Karyn R. Iovinelli, OD, of the Armed Forces Retirement Home Eye Clinic in Washington DC. "In addition to monitoring disease, I use this technology on all new patients to establish a baseline, which is stored in the database of the instrument."

SD-OCT has "dramatically increased my ability to diagnose and manage retinal disease and glaucoma," says Craig Match, OD, of Halifax, Pa. "Just today, in my small rural practice, I scanned two ERM patients with reduced vision, a Plaquenil check and a glaucoma six-month follow-up. Not all days are that busy with retinal disease, but it is nice to have the technology in house."

- **Widefield scanning laser ophthalmoscope.** "We purchased an Optos Daytona widefield scanning camera for improved patient care. The longer we use it and trust the results, the more we incorporate it into our practice," says Frank Chinisci, OD, of Albuquerque, NM. "It helped reduce exam time and patient waiting time, and it increased patient education, the thoroughness of my exams and our profits."

While three out of four optometrists say they obtained their new equipment to improve patient care, about the same number of ODs (73%) report that their recent investment also increased their profitability. So, good care makes good sense. ■

ODs' Other Favorite Technologies

- **Handheld rebound tonometer (Icare).** "It's simplified my exam, reduced chair time and increased patient comfort."—Paul Day, OD, Inverness, Fla.

- **Macular pigment optical density (MPOD) testing.** "The densitometer has helped to find those patients at higher risk for AMD and measure improvements in MPOD after supplemental therapy. This helps to differentiate my practice, as no one else in the area offers this service. It is also a boost to our bottom line, as the sale of carotenoid supplementation in office has become a profit center."—Alan Bishop, OD, Easton, Md.

- **Multi-spectral imaging (MSI) digital ophthalmoscope.** "New MSI equipment [Annidis RHA] is letting us find early macular RPE [retinal pigment epithelium] changes in some people very early in the process. This week, I had a 28-year-old with visible changes and counseled her on smoking cessation and carotenoid supplement use. Patient care has been enhanced."—Christopher Olson, OD, Mount Pleasant, Iowa.

- **OCT/fundus camera.** "Last year, I purchased a Cirrus photo 600 OCT/fundus autofluorescence camera (Carl Zeiss Meditec) and a corneal pachymeter. I purchased these because I wanted to expand my scope of practice and take care of my patients. I was tired of referring patients out to other doctors to manage these patients only because I did not have the proper diagnostic equipment. Not only have these purchases allowed me to do that, but they have significantly increased my practice revenue. I'm taking better care of my patients than ever before."—Sara Kurtis, OD, Moline, Ill. and Davenport, Iowa.

- **Pattern electroretinography testing.** "The Diopsy [NOVA-ERG] electrodiagnostic (ED) system allows us to monitor functionality of the visual electrical pathways, as opposed to direct viewing or imaging. ED testing adds to our management of glaucoma, macular degeneration and diabetes, as well as possibilities with traumatic brain injury, amblyopia and learning disorders. Patients are impressed by the technology and testing is reimbursed well by insurance."—Rodney Fong, OD, Honolulu, Hi.

SUCCESSFUL COMANAGEMENT OF OCULAR SURGERY PATIENTS

The Optometrist's Role in the Clinical Comanagement of Ocular Surgery Patients

by Paul M. Karpecki, OD, FAAO

Cataracts affect more than 24 million Americans age 40 and older, and by age 80, more than half of all Americans have cataracts.¹ Consider the number of aging baby boomers, and optometrists are really going to have to step up to help manage these patients. Fortunately, our role in the pre- and postop care of patients undergoing ocular surgery has already been increasing. I'm going to take a brief look at certain factors every optometrist who comanages ocular surgery patients needs to consider.

The Ocular Surface

The earlier we can pick up ocular surface disease, the better we improve the corneal surface, and the more likely the calculations will be right, so the intraocular lens will be accurate.

Osmolarity has become our most fundamentally accurate test for dry eye.² Patients who have problems with binocular function (e.g., fixation disparity, convergence insufficiency, vertical imbalances) often have complaints of burning, redness, stinging and fatigue, and they show mild signs of dry eye. And when you clear up their eye alignment issues, their symptoms go away. Those with dry eye will get a measurement above around 308 mOsm/L, while those who do not have dry eye will have a measurement under 300 mOsm/L and consistency between the two eyes (e.g., 281 mOsm/L OD and 282 mOsm/L OS). In that case, something else is going on, such as binocular vision problems, mild conjunctivochalasis or allergies.

Meibomian Gland/Eyelid Conditions

We're seeing more people lose their meibomian glands because we're living longer, and using computers and tablets, which cause the glands to upregulate, leading to dysfunction, because blinking is reduced. In the future, I think we are going to all recommend moist heat compresses and lid hygiene like dentists recommend brushing and flossing. We might even have ocular hygienists in the future who perform in-office meibomian gland treatments.

As far as testing, we perform blink analysis, osmolarity, lid margin and meibomian gland evaluation/expression and corneal staining. In the near future, we'll be doing meibomography on all patients to determine potential problems (e.g., why patients stop tolerating their contact lenses or have visual complaints after cataract surgery). Between 20% and 25% of patients drop out of contact lens wear every year in the United States.^{3,4} We believe that the number-one cause for dropout is nonfunctioning meibomian glands causing dry eye, so it's important to assess the meibomian glands in all patients.

Anterior blepharitis is very important. Eyelid conditions where there's Demodex or seborrheic blepharitis from *Staphylococcus* must be managed before cataract surgery is considered.

• **Staphylococcal blepharitis** can lead to endophthalmitis, as well as irregular ocular surfaces. Bacitracin or erythromycin ointment can help here, but if it's highly inflamed or chronic, consider loteprednol etabonate 0.5% and tobramycin 0.3%

ophthalmic suspension (Zylet, Bausch + Lomb), tobramycin 0.3% and dexamethasone 0.1% ophthalmic ointment (Tobradex, Alcon) or azithromycin ophthalmic solution 1% (AzaSite, Akorn Inc.). Lid hygiene (e.g., OCuSOFT Lid Scrub Plus [OCuSOFT]) would maintain this long term.

With Demodex blepharitis, you get corneal distortion and irregular eyelids, as well as a "sleeve" or concentration of debris at the base of the lashes. These patients don't usually complain about mattering—their most common complaint is itching. Every time I think of itching I think of allergies, so it's important to ask *where* they itch. Itching on the eye itself and canthal region point to allergic conjunctivitis, but itching of the eyelashes is probably blepharitis. Steroids will make it feel better, but it won't get rid of it. The treatment for Demodex blepharitis is tea tree oil and may be enhanced with the use of a BlephEx device (Scope Ophthalmics). Cliradex (Bio-Tissue) and OCuSOFT Lid Scrub Plus work well. SteriLid doesn't have a high-enough concentration of tea tree oil to get rid of the disease initially, but it's my go-to for hygiene in these patients for maintenance.

• **Seborrheic blepharitis**, described as flakes or scales of the eyelashes, would never be treated with tea tree oil. Rather, it is treated with a dermatological preparation such as triamcinolone cream 0.1% for two to three weeks.

Corneal Concerns

The best way to determine whether a patient needs Descemet's stripping endothelial

Release Date: December 2014

Expiration Date: November 30, 2015

Goal Statement: Optometrists are presented with a varying mix of ocular conditions ranging from the uncomplicated ocular allergy to more complicated conditions. In particular, the optometrist's role in the pre- and post care of patients undergoing ocular surgery is increasing, and so is the demand for their involvement. It is necessary to educate the OD on new technologies, new therapeutics and standards of care for these postop patients. The goal of this activity is to increase the optometrist's knowledge of such new offerings, including: new and soon-to-become-available agents; newer anti-infectives and anti-inflammatories (steroids and nonsteroidals); newer IOLs; laser technology, etc.

Faculty/Editorial Board: Mitchell A. Jackson, MD; Paul M. Karpecki, OD

Credit Statement: This course is COPE approved for 1 hour of CE credit. COPE ID is 43491-PO. Please check your state licensing board to see if this approval counts toward your CE requirement for relicensure.

Joint-Sponsorship Statement: This continuing education course is joint sponsored by the University of Alabama School of Optometry.

Disclosure Statement: *Dr. Jackson* is a consultant for Bausch + Lomb, Lensar, Nicox, Omeros and Marco. He is on the speakers' bureau of Allergan, TearLab, TearScience, Doctors Allergy and Carl Zeiss Meditec. *Dr. Karpecki* is a consultant for AMO, Akorn, Bausch + Lomb/Valeant, BioTissue and OCuSOFT. He also receives grant/research support from Akorn.

keratoplasty (DSEK) before cataract surgery is to ask them one particular question: how long does your vision stay blurred in the morning? Patients with Fuchs' dystrophy get blurred vision in the morning due to overnight edema. So if a person is getting about two hours of blurring in the morning, they're going to need a DSEK before cataract surgery.

Previous Ocular Trauma

You also want to know if a person going into cataract surgery has had a previous injury to the eye because it can cause many issues, including recurrent erosion causing corneal distortion. Patients can become more prone to retinal detachment after a surgery and angle recession can play a role. Additionally, blunt trauma to the eye can cause zonular damage, putting the capsule at risk for rupture during cataract surgery. Being aware of these points will help the surgeon be well prepared.

Inflammation/Edema

Macular edema is the biggest factor for a diabetic patient going into cataract surgery, although inflammation in general is higher in this patient population. The incidence of macular edema in a diabetic is five times greater than a nondiabetic after cataract surgery.

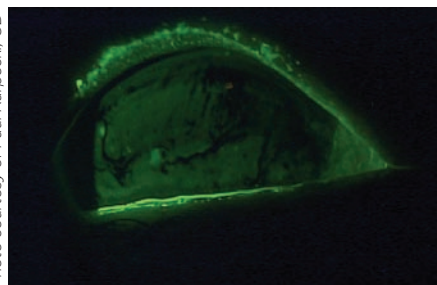
History of uveitis is another consideration, and sometimes your only sign of previous uveitis is pigment on the crystalline lens because it shows they have a history of synechia. And if it's bilateral, that's significantly even more important, because it means a systemic disease is likely the cause of the iritis. Nevertheless, you want to rule out any sort of uveitis because it can result in a patient who is prone to inflammation. And too much inflammation after any surgery is not desirable.

Herpes Simplex Virus

Be aware of herpes simplex virus (HSV) with patients heading in for cataract surgery—even if they had it 10 years ago because with surgery, you hit all three of the triggers for recurrent corneal HSV:

stress, which happens to patients when they go into surgery; trauma, which is what you would consider an incision made during surgery; and UV light, which shines in their eyes while they're in surgery. In one study, not a single person had a recurrence when they were prophylactically treated with 1,000mg valacyclovir hydrochloride (Valtrex, GlaxoSmithKline) or 800 mg acyclovir (Zovirax, GlaxoSmithKline) once a day for a week before surgery and two weeks after surgery.⁵ That's all it takes to prevent it, but we have to be aware of the history to prevent it.

Photo courtesy of Peju Karpecki, OD



Advanced ocular surface disease in a patient presenting for cataract surgery evaluation.

Medication Contraindications

If you have a patient going into any one of the new technologies, it's important to find out what medication(s) they're currently taking, as certain drugs can affect their results. Tamsulosin (Flomax, Boehringer Ingelheim Pharmaceuticals, Inc.) for example, has been strongly linked to intraoperative floppy iris syndrome (IFIS),^{6,7} which can make surgery more difficult through a small pupil if precautions are not taken. Other systemic alpha-1 adrenergic antagonists such as doxazosin (Cardura, Pfizer) and terazosin (Hytrin, Abbott) only tend to have a less than 10% incidence of IFIS.

The Personality Factor

During patient selection for a multifocal IOL, be wary of type-A personalities. If I ask patients whether they would be happy if

they lost "fine print" vision but had great intermediate and distance vision and they say yes, then I feel pretty good about a Crystallens accommodating IOL (Bausch + Lomb). Likewise, if I explain to a patient that they'll have good "fine print" vision and pretty good distance vision, but they may have halos when driving at night or a slightly faded image and they're not okay with that, then a multifocal IOL can be considered. I want to know so they don't go into a presbyopic IOL with unrealistic expectations. So be blunt and get a feel for their personality.

Patients Rely on Their OD's Input

Many patients make decisions about cataract surgery options based on their optometrist's knowledge and endorsement. So, our influence goes much further than anyone else's and has more of an impact in the patient's success than the surgery center or the surgeon. That's a big deal. Embrace your importance, and use it to make sure your surgical patients—and the managing ophthalmologist—are prepared.

Dr. Karpecki works in clinical services and heads the clinical research department at the Koffler Vision Group in Lexington, Ky. He is also Review of Optometry's vice president of Clinical Content and chief clinical editor.

1. Vision Problems in the U.S.: Prevalence of adult vision impairment and age-related eye disease in America. Prevent Blindness, 2012. Available at: <http://www.visionproblems.org/cataract.html>. Accessed: November 2014.
2. Pritchard N, Fonn D, et al. Discontinuation of contact lens wear: a survey. *Int Contact Lens Clin.* 1999;26(6):157-162.
3. Bron AJ, Tomlinson A, Foulks GN. Rethinking dry eye disease: a perspective on clinical implications. *Ocul Surf.* 2014;12 (2 Suppl):s1-31.
4. Pritchard N, Fonn D, et al. Discontinuation of contact lens wear: a survey. *Int Contact Lens Clin.* 1999;26(6):157-162.
5. Richdale K, Sinnott LT, et al. Frequency of and factors associated with contact lens dissatisfaction and discontinuation. *Cornea.* 2007;26(2):168-74.
6. de Rojas Silva MV, Díez-Feijóo E, Javaloy J, Sánchez-Salorio M. Prophylactic perioperative antiviral therapy for LASIK in patients with inactive herpetic keratitis. *J Refract Surg.* 2006;22(4):404-6.
7. Cantrell MA, Bream-Rouwenhorst HR, Steffensmeier A, et al. Intraoperative floppy iris syndrome (IFIS) associated with alpha-1 adrenergic receptor antagonists. *Ann Pharmacother.* 2008;42(4):558-63.
8. Chang DF, Osher RH, Wang L, Koch DD. Prospective multicenter evaluation of cataract surgery in patients taking tamsulosin (Flomax). *Ophthalmology.* 2007;114(5):957-64.

Diagnostic and Therapeutic Innovations That Optimize Outcomes

by Mitchell A. Jackson, MD

In terms of achieving optimal refractive surgery outcomes, the ocular surface, patient expectations and correction of the refractive error all play a role in our success. The tear film is the most important refracting surface of the eye, and anything that disrupts it may prevent us from getting accurate corneal measurements preoperatively and can cause poor postop visual outcomes. Fortunately, there are some great new diagnostic and therapeutic innovations coming out to

help ensure our success with these patients. I'll share some pearls about these new technologies and how to best approach working with ocular surgery patients here.

Getting Started

My normal refractive cataract workup consists of many parts: optical coherence tomography; corneal topography; pachymetry; and various devices to look at multiple data points so we're not missing our intended

refractive target. We also look at coma, and angle kappa in particular, and we aim to distinguish corneal from lenticular astigmatism. When I look at patients, I ask myself the following. Are they older? Have they had a previous refractive surgery? Do they have an autoimmune disease (e.g., diabetes, thyroid, rheumatoid arthritis)? Dry eye patients come to us, so it's our responsibility to diagnose them and save their lives, especially in the case of Sjögren's syndrome, which has a

5% lymphoma rate associated with it. Sjögren testing with new early proprietary titers to detect Sjögren's syndrome at a much earlier stage in the disease is now available. People who spend a good deal of time in front of a computer, tablet or their phone oftentimes experience low blink rate, which can lead to computer vision syndrome. I advise these patients to follow the 20/20/20 rule: every 20 minutes take a 20-second break and look at something 20 feet away.

Diagnosing the Ocular Surface

If the ocular surface isn't diagnosed, corneal changes can skew corneal topography and keratometry readings, which can lead to a surgeon putting in the wrong lens power. A prospective, multicenter study of 136 patients (272 eyes; average age: 70 years; range: 54 to 87) sought to determine the prevalence of preoperative dry eye in patients scheduled for cataract surgery.¹ It showed that 87% of patients were asymptomatic, yet 63% had tear break-up time under five seconds and 77% had positive corneal staining (50% central cornea).¹

The Problem With Astigmatism

As far as astigmatism goes, even 1D is not ideal because patients are going to complain. So I try to use devices that separate out corneal vs. lenticular astigmatism and show patients what I'm taking out (lenticular) and what is going to be left (corneal). So if they don't understand, at least I can show them a picture via electronic health record monitors and explain that if I don't treat the corneal astigmatism, it will be needed in their glasses postoperatively.

Avoiding Complications

Age-related macular degeneration (AMD). It's not good to put a multifocal lens in the eye of a patient at high risk of AMD because it has the potential to cause further aberrations if they develop AMD later in life. Multifocal intraocular lenses (IOLs) split light rays and induce some degree of spherical aberration, and if I can predict that a patient will develop AMD later in life, it is better to avoid this IOL technology at the time of cataract surgery. The RetnaGene AMD test (Sequenom Laboratories) is a way to predict risk. Based on the results, you can get patients on nutritional supplements early and possibly prevent AMD. We've recently begun using this test in our office to help patients start AMD prevention and to decide about lens implants ahead of time.

Tamsulosin. According to a 2008 online survey sent to American Society of Cataract and Refractive Surgery members, 95% of the nearly 1,000 respondents believe that tamsulosin (Flomax, Boehringer-Ingelheim Pharmaceuticals Inc.) makes cataract surgery more difficult and 77% believe that it increases the risks of surgery.² In fact, tamsulosin's association with intraoperative floppy iris syndrome (IFIS)

has become well established.³⁻⁵ IFIS has been reported with non-subtype specific alpha-1 adrenergic antagonists (e.g., terazosin [Hytrin, Abbott Laboratories Inc.], doxazosin [Cardura, Pfizer Inc.], alfuzosin [Uroxatral, Sanofi-Aventis]), but several prospective and retrospective studies suggest that IFIS is more likely to occur with tamsulosin than with the non-specific alpha-blockers.⁵⁻⁷ If a patient has one tamsulosin pill just one time, it will affect surgery even 10 years later because it saturates the iris dilator muscles. So if they're actively on it, stopping it is not going to make a difference, at the time of cataract surgery. Knowing about current or past use of this category of medication is the most important factor for the surgeon.

Corneal wound sealant. The ReSure Sealant (Ocular Therapeutix) is another new tool and I use it on all of my Descemet's stripping endothelial keratoplasty cases to avoid shooting a kerat graft out of the eye when you put the air bubble in. I also use these sealants for my complex cataract cases. It seals the wound, and bugs cannot get into the eye. In the FDA study, the ReSure sealant demonstrated superiority over sutures by successfully preventing wound leaks in 95.9% of cases, compared to sutures in only 65.9% ($p < 0.0001$) of cases.⁸

Cystoid macular edema (CME). This is the most common cause of visual decline after uncomplicated cataract surgery and can have long-term consequences for patients. A study by Wittmann and colleagues evaluated whether adding a perioperative nonsteroidal anti-inflammatory drug improves cataract surgery outcomes relative to topical steroids alone in patients without known risk factors for CME.⁹ They showed that a combination of steroids and nonsteroidals is the best approach.

Cataract and Refractive Procedures

I was anti femtosecond laser until I tried it. I implemented it in my office about four months ago, and now we're at about 87% conversion because of my improved phaco times—and the fact that corneas are near perfect the next day and vision recovery is faster. It has made a big difference because it fragments the lens and allows me to do astigmatic incisions. It also results in better capsulotomies, which is important for accommodating intraocular lenses and certain multifocals in terms of effective lens position.

The technology compensates for tilt and provides a buffer from the posterior capsule. I don't have to strip the epinucleus anymore—it gets all the way down to that level and it all comes out. It even grades cataracts and creates a pattern to remove the cataract live, based on the imaging. Several lasers are currently FDA approved, four of which do fragmentation, capsulotomy and corneal incisions.

Afterwards, I rely on intraoperative wavefront aberrometry, which is really good for post-LASIK patients and toric IOLs. The

device guides me in real time which way to rotate a toric IOL until the sweet spot of astigmatic neutrality is achieved. Also, I don't have to mark the eye ahead of time. I can even do real-time aberrometry with my astigmatic incisions—I can take a measurement and decide whether to open the incision on the table to get more effect. So the technology is really evolving and helping outcomes.

iStent

As we all are aware, patients aren't compliant with their drops. We now have the option of performing microincisional glaucoma surgery to insert an iStent (Glaukos Corp.) into the trabecular meshwork. It's approved for early glaucoma and one medication. It reduces IOP better than cataract surgery alone. The U.S. pivotal trial of iStent found that 66% of treatment eyes versus 48% of control eyes achieved a greater than 20% IOP reduction without medication at 12 months.¹⁰

A Team Effort

As a surgeon, I'm responsible for looking at the overall patient. But the majority of the time, when I'm referred a patient, I'm only meeting him for the first time, so I depend on my referring physicians to help me pick the right technology for the patient—because they know him best. There are a lot of options I can offer patients now. My job is to stay in tune with that.

Dr. Jackson is the founder/medical director of Jacksoneye and is a clinical assistant at the University of Chicago Hospitals. He specializes in cataract and refractive surgery and is involved in many Phase II, III and IV FDA clinical trials.

1. Trattler W. Dry eye more prevalent than expected in cataract patients. CRST supplement. October 2011.
2. Chang DF, Braga-mele R, Mamalis N, et al. Clinical experience with intraoperative floppy-iris syndrome. Results of the 2008 ASCRS member survey. *J Cataract Refract Surg* 2008; 34:1201-1209.
3. Cantrell MA, Bream-Rouwenhorst HR, Steffensmeier A et al. Intraoperative Floppy Iris Syndrome Associated with [alpha]-1-Adrenergic Receptor Antagonists. *Ann Pharmacother* 2008; 42:558-563.
4. Chang DF, Osher RH, Wang L, Koch DD. A prospective multicenter evaluation of cataract surgery in patients taking tamsulosin (Flomax). *Ophthalmology* 2007; 114:957-964.
5. Oshika T, Ohashi Y, Inamura M, et al. Incidence of intraoperative floppy iris syndrome in patients on either systemic or topical alpha (1)-adrenoceptor antagonist. *Am. J. Ophthalmol* 2007; 143:150-151.
6. Blouin M, Blouin J, Perreault S, et al. Intraoperative floppy iris syndrome associated with Alpha-1 adrenoceptors. Comparison of tamsulosin and alfuzosin. *J Cataract Refract Surg* 2007; 33:1227-1234.
7. Palea S, Chang DF, Rekkik M, et al. Comparative effect of alfuzosin and tamsulosin on the contractile response of isolated rabbit prostatic and iris dilator smooth muscles. Possible model for intraoperative floppy iris syndrome. *J Cataract Refract Surg* 2008; 34: 489-496.
8. Masket S, Hovanesian JA, et al. Use of a calibrated force gauge in clear corneal cataract surgery to quantify point-pressure manipulation. *J Cataract Refract Surg.* 2013 Apr; 39(4):511-8.
9. Wittmann JR, Silverstein S, Heier J, et al; Acular LS for Cystoid Macular Edema (ACME) Study Group. A randomized, masked comparison of topical ketorolac 0.4% plus steroid vs steroid alone in low-risk cataract surgery patients.
10. Samuelson TW, Katz LJ, Wells JM, et al., for the US iStent Study Group. Randomized evaluation of the trabecular micro-bypass stent with phacoemulsification in patients with glaucoma and cataract. *Ophthalmology.* 2011;118:459-467.

QUIZ

1. An osmolarity measurement of ___ indicates dry eye.

- a. 281 mOsm or 282 mOsm/L
- b. Above 308 mOsm/L
- c. Below 300 mOsm/L
- d. Below 280 mOsm/L

2. What percentage of patients drop out of contact lens wear every year?

- a. 15%
- b. 16% to 25%
- c. 35%
- d. 40% to 50%

3. Tea tree oil is used to treat:

- a. Dry eye
- b. Demodex blepharitis
- c. Seborrhic blepharitis
- d. All of the above

4. The most common complaint from patients with Demodex blepharitis is:

- a. Itching
- b. Irregular eyelids
- c. Mattering
- d. None of the above

5. Which of the following medications is NOT associated with intraoperative floppy iris syndrome:

- a. Terazosin
- b. Doxazosin
- c. Tamsulosin
- d. Valacyclovir hydrochloride

6. In a prospective study of 136 patients scheduled for cataract surgery, while 87% were asymptomatic for dry eye, ___ had tear break-up time <5 seconds.

- a. 70%
- b. 54%
- c. 63%
- d. <50%

7. In an FDA study, the ReSure Sealant prevented wound leaks in ___ of cases.

- a. 65.9%
- b. 95.9%
- c. 87%
- d. None of the above

8. What is the best approach for treating cystoid macular edema?

- a. A combination of steroids and nonsteroidals.
- b. Cataract surgery
- c. A perioperative nonsteroidal anti-inflammatory drug
- d. A topical steroid

9. Which of the following is NOT a capability of the femtosecond laser:

- a. Improved phaco times
- b. Lens fragmentation
- c. Indicates which way to rotate the intraocular lens
- d. Grades cataracts

10. The iStent reduces intraocular pressure better than:

- a. Medication
- b. Cataract surgery alone
- c. A change in diet
- d. All of the above

The opinions expressed in this supplement to Review of Optometry® do not reflect the views of or imply endorsement by the publisher of the host publication. Copyright 2014 Jobson Medical Information LLC.

This enduring activity may contain discussion of published and/or investigational uses of agents and/or devices that are not indicated by the FDA. Off-label use of a medication or a biological is defined as use for an indication, or in a manner for which FDA approval has not yet been obtained and which is therefore not included on the FDA-approved label or product packaging. Please refer to the official prescribing information for each product for discussion of approved indications, contraindications and warnings. Practitioners should critically assess the information herein and are encouraged to consult appropriate resources for any product or device mentioned in this program.

The educational content of this activity has been peer reviewed and validated to ensure that it is a fair and balanced representation of the topic based on the best available evidence.

Examination Answer Sheet

Valid for credit through November 30, 2015

This exam can be taken online at www.revoptom.com/CoMgmtSuccess. Upon passing the exam, you can view your results immediately and download a real-time CE certificate. You can also view your test history at any time from the website.

Successful Comangement of Ocular Surgery Patients

Directions: Select one answer for each question in the exam and completely darken the appropriate circle. A minimum score of 70% is required to earn credit.

Mail to: Jobson - Optometric CE, PO Box 488, Canal Street Station, New York, NY 10013
COPE approved for 1 hour of CE credit. COPE ID is 43491-PO .

This course is supported by an unrestricted educational grant from Bausch + Lomb.

There is an eight- to10-week processing time for this exam.

1 = Excellent 2 = Very Good 3 = Good 4 = Fair 5 = Poor

- 1. (A) (B) (C) (D)
- 2. (A) (B) (C) (D)
- 3. (A) (B) (C) (D)
- 4. (A) (B) (C) (D)
- 5. (A) (B) (C) (D)
- 6. (A) (B) (C) (D)
- 7. (A) (B) (C) (D)
- 8. (A) (B) (C) (D)
- 9. (A) (B) (C) (D)
- 10. (A) (B) (C) (D)

Rate the effectiveness of how well the activity:

- 11. Met the goal statement: (1) (2) (3) (4) (5)
- 12. Related to your practice needs: (1) (2) (3) (4) (5)
- 13. Will help you improve patient care: (1) (2) (3) (4) (5)
- 14. Avoided commercial bias/influence: (1) (2) (3) (4) (5)
- 15. How would you rate the overall quality of the material presented? (1) (2) (3) (4) (5)
- 16. Your knowledge of the subject was increased:
 Greatly Somewhat Little
- 17. The difficulty of the course was:
 Complex Appropriate Basic

How long did it take to complete this course?

Comments on this course:

Suggested topics for future CE articles:

Please retain a copy for your records. Please print clearly.

First Name _____

Last Name _____

E-Mail _____

The following is your: Home Address Business Address

Business Name _____

Address _____

City _____ State _____

ZIP _____

Telephone # _____ - _____ - _____

Fax # _____ - _____ - _____

By submitting this answer sheet, I certify that I have read the lesson in its entirety and completed the self-assessment exam personally based on the material presented. I have not obtained the answers to this exam by any fraudulent or improper means.

Signature _____ Date _____

Lesson 110807

RO-UAB-1214

How to Find and Keep Front Desk Staff

From personality traits to ongoing training, these essential skills and staffing tips will help you hire and retain the best person for this important role.

By Jane Cole, Contributing Editor

“Staff are as important or more important than the doctor,” says optometrist Aaron Werner of El Cajon, Calif., who started out working at the front desk at his father’s optometric practice when he was in high school.

In other words, a patient may come to a practice for the clinical skills and reputation of the doctor—but an unpleasant experience with a front desk staff member may keep him or her from coming back.

“Docs do not like hearing this because we want to believe that patients come to us for our exceptional clinical skills, and they do,” Dr. Werner says. “But, patients come to the practice for the complete experience. The front office staff is the face of the practice and is the first interaction a patient has during their visit and also the last.”

So, make sure your patient’s first and last interaction at your front desk isn’t also their last visit to your office. Carefully consider the skills, traits and training for this key position in your practice.

Front office staff need to be welcoming, but also have a strong personality to handle challenging patients and keep office flow moving, says Aaron Werner, OD.



Front and Center

“Your front office staff can make or break your practice,” says optometrist Pamela Miller of Highland, Calif. “They are the first point of contact and can often times be the determining factor whether a patient returns.”

Adds Jason Miller, OD, MBA, of Powell, Ohio, “It truly is the front line of the office and, many times, the first impression a patient has of your office. As the saying goes, you never get a second chance at a first impression.”

When hiring for this position, look for these key traits:

- **Friendly demeanor.** No shrinking violets here. “The front office staff must be people persons,” Dr. Werner says. “They are the face of an office and set the tone for the visit. They need to be welcoming and friendly.”

Front desk staff members are also the last to have contact with patients as they leave the office. So, the front desk staff person also reinforces the excellent experience the patient had, the quality optical

How to Hire the Right 'Girl'

"Dr. Ross was a bombastic, domineering oral surgeon who was lucky to keep an assistant for three months. He had a busy practice, so he reluctantly accepted the agency's choice: a mousy-looking spinster with a hair bun and steel-rimmed glasses. She's been on the job for more than two years and both Dr. Ross and the girl are happy."



This is an excerpt from the July 1969 *Review of Optometry* article, "Hiring the Right Girl." Although some of the article's descriptions are now dated and sexist, much of the article's hiring advice is still true—specifically, making sure the front desk staff person and the doctor have complementary personalities, says Pamela Miller, OD, JD.

It's important for these two positions in the office to not clash, but to each make up for what the other may lack. "It's a lot like a happy marriage. You don't want to hire someone just like you. If you have a quick temper, you don't want someone like that at the desk."

Dr. Miller offers these other modern day hiring tips:

- "Your front desk staffer should mirror your

patients." In other words, don't hire someone with multiple piercings and tattoos unless that's the fashion statement most of your patients are trying to make. "If you're a class act, you can't hire someone who's not a class act. At the same time, your front office staff person should be a reflection of the patients coming in to see you."

- "Experience is important, but don't forget to check references." Once you confirm the work history from a candidate's former employer, ask the employer if they would hire the employee again. If they say no, ask them why not. If they won't give an answer, you can infer a great deal by the person's tone on the other end of the phone, Dr. Miller says.

So how did *Review of Optometry's* 45-year-old article—which offered hiring nuggets such as, "If the girl will be visible to your patients, forget about her new hairdo or stunning dress. Visualize how she'll look in a plain skirt and blouse"—hold up today?

"The article is still pretty darn good," Dr. Miller says, although she adds that it's not appropriate to use the term "girl," and skirts and blouses are probably replaced with pants and a top or scrubs. Still, the core of the article rings true: Take the time to get to know the person during the interview and verify the candidate's skills before you make an offer.

purchases made, and even should be able to promote new contact lenses, Dr. Werner adds.

- **Juggling and multitasking.** At any given moment, an employee in this position may have to greet patients, check out other patients, answer the phone, order contact lenses, input insurance forms and handle billing. "There are a gazillion things going on at once, and they need to be able to handle it," Dr. Pamela Miller says.

- **Self-control and self-motivation.** A front desk staff person must be able to handle—and often times defuse—difficult patient situations,

says Dr. Pamela Miller.

"I look for an outgoing personality who can control a situation," adds Dr. Werner. "The front office staff works with a wide demographic of patients in a wide variety of interactions. They need to be welcoming, but also have a strong personality to handle challenging patients and keep office flow moving."

When Dr. Werner interviews individuals for this position, he wants to know how candidates can handle a conversation. "I look for friendly, confident, self-motivated individuals with a big smile. I don't want some-

one who needs constant direction, is a chatterbox or doesn't have a welcoming sense about them."

- **Quarterbacking staff.** Front office staff set the tone for the practice. They direct flow and make adjustments as needed. For example, if there is a long wait, the staff person can tell the patient that the doctor is running behind because of an emergency, and they can start their visit in the optical, Dr. Werner suggests.

"Everything may work out from the playbook during a scrimmage," Dr. Werner says. "But on game day, things may change and you have to be able to think on the fly."

Training is Key

At Dr. Pamela Miller's practice, training is ongoing. "I believe in cross-training—including the doctor," she says. "I expect staff to train me. If there is an area in my practice that is not working right, I want to know. A great office is a happy office."

When a new employee is hired at the front desk, Dr. Pamela Miller gives the individual a training manual for staff that she authored. The manual consists of short, easy-to-digest chapters.

Front office is not an easy job and requires a lot of attention, adds Dr. Jason Miller. To ensure the employees in this role are prepared at his practice, they are versed in office policies and then educated on proper phone technique. "Additionally, it is important that they experience what happens throughout the office. That enables them to field questions that may arise either in person or on the phone," he says.

During the second day on the job in Dr. Werner's practice, all new hires are treated like a regular patient and have a full eye exam.

“This allows them to not only see but feel the experience we expect all patients to have. If they require corrections in their contact lenses, we make the changes needed,” he says.

He also encourages staff to take advantage of online learning courses on topics ranging from phone etiquette to ocular anatomy.

Additionally, Dr. Werner trains front desk staff on the nuances of contact lenses. This can prevent the practice, and the doctor, from losing valuable chair time by having the patient return for numerous follow-up visits. For example, a well-trained staff member can field a call from a patient having trouble with a new monovision lens by asking appropriate questions to fully understand what’s causing the difficulty. The staff can then review the case with the doctor, thus saving valuable chair time.

When Training Pays Off

Recently, while making phone call appointment confirmations, a long-time patient—who also happened to be Dr. Werner’s former high school English teacher— informed the front desk staff member she was not happy with the experience she had with an optician the year before, and would not be returning for her annual visit.

“My wonderful team member took time to talk with this patient and inquire about her concerns. What she did next though was astounding,” Dr. Werner says. “She apologized for the less-than-exceptional experience the patient had and asked her to be sure to let us know at any time should her experience ever be less than expected.”

The staff person also took time to share positive attributes of the optician with whom the patient had a negative experience, Dr. Werner says. And, to avoid any potential



Front office dog Angel greets patients— along with employees Effie and DeNese— at the practice of Pamela Miller, OD, JD.

problems in the future, the staff person informed the patient she could be paired with a different optician, if she preferred, because her satisfaction was high on the practice’s priority list, he adds.

In this one conversation, Dr. Werner says, his staff member retained a patient who had already decided to go elsewhere and reinforced the practice’s philosophies to the patient, while building up the other team member with whom the patient had a negative interaction. Additionally, the front office staff was able to emotionally tie the patient back to the office—so much so that when Dr. Werner saw the patient on her return visit, his former high school English teacher had nothing but wonderful things to say about all of his team.

Front office staff is critical to the health of any practice. “They get hit from lots of different directions and are often blamed for things when they go wrong,” Dr. Jason Miller says. “Being able to handle people and understanding how to have fun can make a big difference in the culture of a practice.” ■

Tales from the Dark Side: Staffing Nightmares

If you’ve been in practice long enough, chances are you may have had an employee who wasn’t exactly a good fit at the front desk.

Veteran optometrist and attorney Pamela Miller offers a few frightful stories from her practice through the years:

- Dr. Miller thought she had made a good hire for the front desk. The individual was outgoing and happy, but one day she failed to show up and never returned. “One year later, I got a call from the unemployment office and the employee claimed I fired her.”

- Dr. Miller was attending a meeting in another city, and suddenly had a bad feeling. She called the office and spoke to her front office employee, who had worked at the practice for only a few months. “The staff person said, ‘I’m leaving and not coming back. I just told a patient to go to hell.’”

- Another time, Dr. Miller noticed her front desk employee seemed upset. Dr. Miller asked her what was wrong. “The employee said she saw small people hiding in the trees and they were laughing at her. I had to let her go, and she took me to labor court.”

- A different front desk employee stole from Dr. Miller, which taught her a valuable lesson. “I’m the only one who makes bank deposits now.”

- Yet another bad situation between front desk staff had to be worked out. Two staff members were arguing in front of a patient. Dr. Miller confronted the employees about it and later found one of the employees in question was very distraught. She informed Dr. Miller that the other employee told her she would kill her if she made her lose her job.

There was a happy ending. Dr. Miller required both employees to talk to a therapist. “I wound up keeping both of those employees for a long time, and one has now been working for me just over 20 years,” Dr. Miller says.

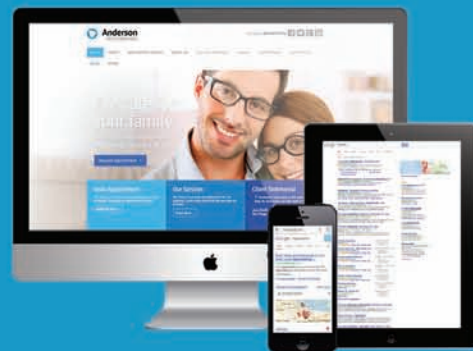You Help Patients See. We Help New Patients See You.

- ▶ A strong web presence is essential for new patients to find your practice.



Get the solution you need to create a powerful web presence.

- 📅 Appointment requests make it easy for new patients to contact you.
- ✓ Online forms streamline first time visits.
- ✂ The Frame Selector makes buying frames efficient.
- 🌐 An interactive Google map gets patients to your door.
- 🛒 An online store increases revenue and convenience.
- 📱 Blogs, social media, and video improve patient retention and referrals.



Is this **Big** Vessel a **Big** Problem?

Our patient presented with evidence of a congenital retinal macrovessel.

How significant is this finding, and how should he be managed? **By Richard Zimbalist, OD**

A congenital retinal macrovessel (CRM) is a rare ocular finding that is often noted incidentally on fundus evaluation. Some affected individuals may be visually asymptomatic, while others could present with decreased visual acuity caused by several different etiologies.

A congenital retinal macrovessel is frequently described as an enlarged single vessel that emanates

from the optic nerve or retinal arcade and crosses the horizontal raphe. Macrovessels often perfuse a large area of the fundus and may lead to an anastomosis between the arterial and venous vasculatures.

This case report illustrates how you can effectively differentiate a retinal macrovessel from other vascular anomalies, such as racemose hemangioma, arteriovenous malformation (AVM) or other ham-

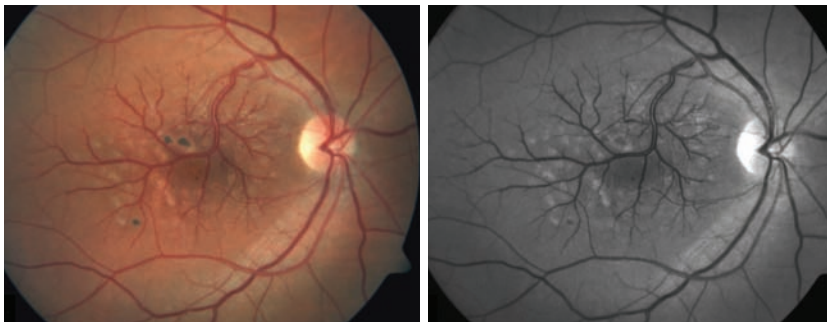
artomas of the retina and central nervous system.

History

A 45-year-old white male presented for an initial eye examination. His chief complaint was difficulty focusing at near with his current bifocal prescription. He also complained of intermittent irritation in his right eye that had persisted for several months, as well as frontal headaches that had continued for at least eight months. The patient reported that over-the-counter analgesics and bed rest relieved his headaches.

His systemic history was remarkable for hypertension, hyperlipidemia, environmental allergies, major depressive disorder, lower back pain, claw foot, sleep apnea, and a left arm AVM that was surgically corrected in 1994.

Current medications included citalopram 40mg, hydrochlorothiazide 25mg, ibuprofen 800mg TID, metoprolol 100mg, simvastatin



1, 2. Color (left) and red-free (right) fundus photographs of the right fundus revealed congenital retinal macrovessel (CRM) formation. The parafoveal areas of hypopigmentation were caused by previous focal laser treatment for cystoid macular edema. The aberrant vein does not cross over the foveola; however, the patient may still note a small angioscotoma.

Case Report

20mg and trazodone 25mg. At a recent physical, his blood pressure measured 118/75mm Hg.

He reported that his last ocular examination three years before uncovered “something in the back of his right eye.” He also stated that he underwent an unknown laser procedure on his right eye approximately 10 years prior.

Diagnostic Data

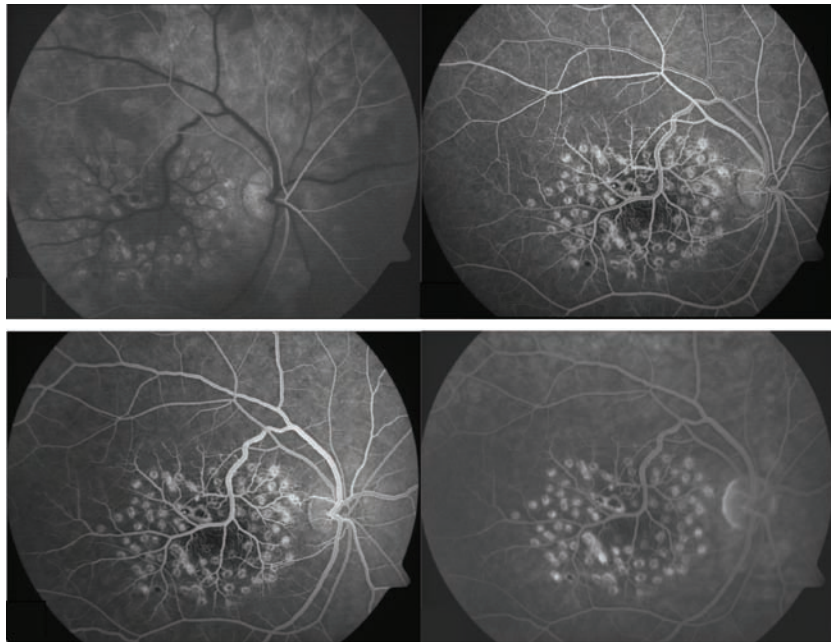
His best-corrected visual acuity was 20/25 OD and 20/20 OS. Extraocular motility was full and unrestricted OU. Confrontation fields were unremarkable OU. Both pupils were equal, round and reactive to light, with no evidence of an afferent defect in either eye. Slit-lamp examination was unremarkable OU.

The anterior chamber was deep and quiet in both eyes. Intraocular pressure measured 12mm Hg OD and 11mm Hg OS. Funduscopy with a 78D lens showed a 0.10 x 0.10 cup-to-disc ratio, with healthy neuroretinal rim tissue in both eyes.

The right fundus had a large retinal vessel branching from the superotemporal arcade, crossing over the horizontal raphe. The macula exhibited several areas of mottling and parafoveal atrophy, which were due to a previous focal laser treatment performed in 2004 (*figures 1 and 2*). The retinal examination of his left eye was unremarkable. The periphery of both eyes was flat and attached.

Fluorescein angiography of the right eye showed irregular arteriovenous anastomoses, with early filling of the aberrant retinal vessel during the venous phase (*figures 3-5*). There was no evidence of macular leakage throughout the study (*figure 6*).

Of particular interest was the



3-6. Fluorescein angiography of the right eye. Arterial phase showed full arterial filling in all quadrants (top left); arteriovenous phase demonstrated laminar flow of venous arcades and early CRM filling (top right); venous phase clearly showed the multiple aberrant arteriovenous anastomoses in the foveal avascular zone (bottom left); late-phase fluorescein angiography showed no vascular leakage (bottom right).

presence of capillary vasculature in the foveal region of the right eye. Here, the aberrant vessel had formed additional anastomoses with inherently normal arterioles. A macular cube optical coherence tomography scan taken on Cirrus HD-OCT (Carl Zeiss Meditec) revealed the absence of a foveal pit, as well as multiple areas of superficial hyper-reflectivity that corresponded to the presence of retinal vasculature branches located within the foveal avascular zone (*figure 7*).

Diagnosis

We diagnosed the patient with a congenital retinal macrovessel in the right eye.

Follow-Up

Due to his recent onset of headaches and previously discovered left arm AVM, we referred the

patient for a neurologic workup to rule out an intracranial and central nervous system hemangioma. He underwent an MRI with gradient-recalled echo sequencing, which showed no evidence of cerebral AVM.

The examining neurologist diagnosed him with tension headaches and started him on cyclobenzaprine 10mg TID and nortriptyline 25mg QHS. Then, he was scheduled for a six-month follow-up evaluation. Since then, the patient has remained asymptomatic, with no additional sequelae.

Discussion

Congenital retinal macrovessels were first identified in 1869 and were later defined as a large aberrant artery or vein that crosses the horizontal raphe, with minimal to no effect on vision or color perception.^{1,2} CRMs are rare, with

Unified in Our Commitment to Optometry

Trust Bausch+Lomb for a full suite of products: prescription medications, over-the-counter products, and contact lenses.

Zylet[®]
loteprednol etabonate 0.5%
and tobramycin 0.3%
ophthalmic suspension

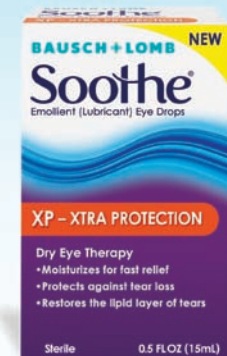
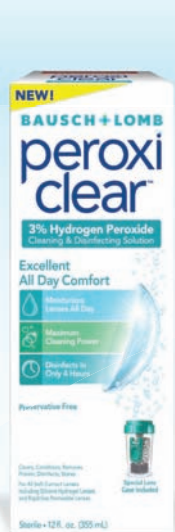Besivance[®]
besifloxacin ophthalmic
suspension, 0.6%

LOTEMAX GEL[®]
loteprednol etabonate
ophthalmic gel 0.5%

BEPREVE[®]
(bepotastine besilate
ophthalmic solution) 1.5%

LACRISERT[®]
(hydroxypropyl cellulose ophthalmic insert)

Alrex[®]
loteprednol etabonate
ophthalmic suspension 0.2%



Please visit www.bausch.com for more information.

BAUSCH+LOMB

Lacrisert is a registered trademark of Valeant Pharmaceuticals International or its affiliates.

®/™ are trademarks of Bausch & Lomb Incorporated or its affiliates.

©2014 Bausch & Lomb Incorporated. US/BES/14/0021

Case Report

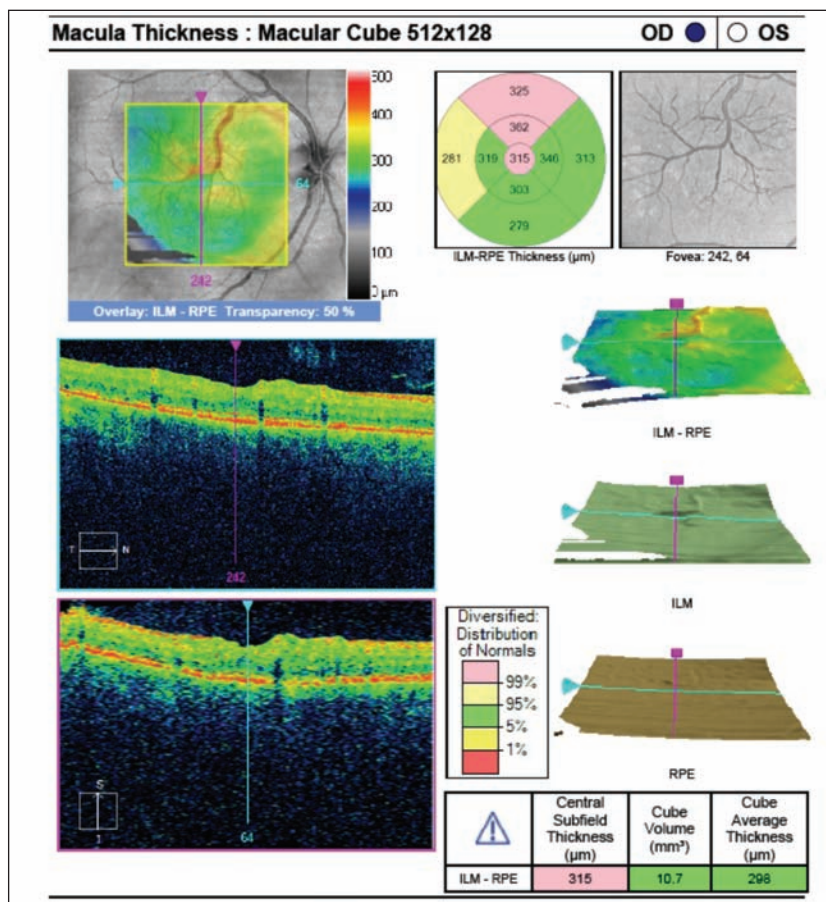
an estimated prevalence of one in 200,000 individuals.³

The presentation is often described as a single, enlarged vessel that emanates from the optic nerve. Venous CRMs are far more common than arteriolar CRMs. These vessels usually perfuse a large area of the fundus and also may lead to an anastomosis between the arterial and venous vasculature.^{4,6}

A patient with a congenital retinal macrovessel may present with normal or reduced visual acuity.^{5,7,8} Etiologies of decreased visual acuity include foveal ectopia, subfoveal retinal pigment epithelium alteration, foveal cysts and angioscotomas created by the path of the retinal vascular abnormality coursing through the central fovea.^{5,7,8} Less commonly, vasa retinopathy and retinal macroaneurysm also have been identified as secondary causes of CRM-associated visual loss.^{7,9}

Several other similarly appearing retinal vascular disorders may complicate accurate diagnosis of the abnormality. These include retinal arteriovenous communication, retinal hamartoma, capillary hemangioma, prepapillary vascular loops, hereditary or acquired retinal tortuosity, and racemose hemangioma or arteriovenous malformations associated with Wyburn-Mason syndrome.^{3,5} Although a congenital retinal macrovessel can be diagnosed on clinical examination alone, it is critical to rule out other retinal and systemically associated conditions.

Racemose hemangioma is a benign AVM that can occur independently or as a component of Wyburn-Mason syndrome.¹⁰ The terms “racemose hemangioma” and “Wyburn-Mason syndrome” are often used interchangeably;



7. Spectral-domain optical coherence tomography macular cube of the right eye. The scan was centered on the fovea and exhibited an irregular foveal architecture. The CRM disrupts the foveal avascular zone, creating shadows caused by the prominent retinal vasculature. Shadowing on an OCT scan also may be seen with vitreal floaters, congenital hypertrophy of the retinal pigment epithelium (CHRPE), dense collection of blood, cotton-wool spots, exudates, retinal pigment epithelium hyperplasia, intraocular foreign body, dense pigmented scars, choroidal nevi and thick subretinal neovascular membranes.^{14,15}

however, Wyburn-Mason syndrome is characterized by the subsequent finding of an AVM of the midbrain in the presence of an ipsilateral AVM of the retina.

The retinal manifestations of Wyburn-Mason syndrome include generalized tissue ischemia, retinal hemorrhage, venous occlusion and vitreal hemorrhage. Orbital or optic nerve AVM development can lead to papilledema, proptosis, cranial nerve palsies, conjunctival vasculature dilatation and ptosis.

Wyburn-Mason syndrome is a systemic condition that can cause hamartomas of the brain with severe neurologic deficits.¹¹

Intravenous fluorescein angiography is useful in determining the etiology of vision loss, as well as differentiating CRM from other vascular disorders, such as an AVM or the phacomatoses.

The characteristic angiographic findings of a CRM include an early filling and delayed evacuation of venule, dilated surrounding capil-

lary plexus, areas of capillary non-perfusion, hyperfluorescence due to retinal pigment epithelium alterations and leakage from the vascular wall.^{3,5,7} In contrast, racemose hemangiomas exhibit a direct arteriovenular communication, with retinal vessel stability and evenly distributed staining.¹³

A congenital retinal macrovessel is a rare ocular finding with an impressive and characteristic pattern that is often detected incidentally during ocular examination. Although CRMs do not typically affect vision, secondary alteration of the foveal architecture and the presence of angioscotomas could reduce visual acuity. Fluorescein angiography and ancillary tests, such as optical coherence tomography, may aid in this diagnosis.

CRM are usually benign, however, you must rule out Wyburn-Mason syndrome in the presence of neurologic symptoms. Clinicians should consider an MRI in those who present with suspicious retinal arteriovenous malformations and neurologic symptoms, such as mental changes, headaches, seizures, papilledema and unexplained homonymous hemianopsia. ■

Dr. Zimbalist practices at the Harry S. Truman Memorial Veterans' Hospital in Columbia, Mo.

1. Mauthner L. Lehrbuch der ophthalmoscopie. Vienna, Austria: Tendler; 1869:249.
2. Brown GC, Donoso LA, Magargal LE, et al. Congenital retinal macrovessels. Arch Ophthalmol. 1982 Sep;100(9):1430-6.
3. Gurwood AS, Bailey JT, Pelino CJ. Congenital retinal macrovessel: a case report. Optometry. 2001 Sep;72(9):597-602.
4. Alexander LJ. Congenital and Acquired Anomalies of the Optic Nerve Head In: Primary Care of the Posterior Segment, 2nd ed. Norwalk, Connecticut: Appleton & Lange; 1994:96.
5. Pérez-Carro G, Miranda-Rollón M, Junceda-Moreno C, et al. Congenital retinal macrovessels: A discovery by chance.

6. Polk TD, Park D, Sindt CW, Heffron ET. Congenital Retinal Macrovascular. Arch Ophthalmol. 1997 Feb;115(2):290-1.
7. de Crecchio G, Alfieri MC, Cennamo G, Forte R. Congenital macular macrovessels. Graefes Arch Clin Exp Ophthalmol. 2006 Sep;244(9):1183-7.
8. Yanuzzi LA. Pediatric Retina. In: The Retinal Atlas, 1st ed. New York: Saunders-Elsevier; 2010:184.
9. Koizumi H, Iida T, Mori T, et al. Retinal Arteriolar Macroaneurysm and Congenital Retinal Macrovascular. Ophthalmic Surg Lasers Imaging. 2009 Sep-Oct;40(5):513-5.
10. Materin MA, Shields CL, Marr BP, et al. Retinal racemose hemangioma. Retina. 2005 Oct-Nov;25(7):936-7.
11. Lee AG, Roy H. Wyburn-Mason Syndrome. Medscape. Available at: <http://emedicine.medscape.com/article/1219502-overview>. Accessed November 7, 2014.
12. Marks ES, Adamczyk DT, Thomann KH. Primary Eyecare in Systemic Disease. Aksionoff EB (ed.). In: Wyburn-Mason Syndrome. Norwalk, Connecticut: Appleton & Lange; 1995:344-7.
13. Richard G, Soubbrane G, Yanuzzi L. Neoplastic Diseases. In: Fluorescein and ICG Angiography: Textbook and Atlas, 2nd ed. New York: Thieme; 1998:338.
14. Reed B, Glabe, D, Yudcovitch L. Ocular Coherence Tomography Guide. Pacific University: Common Knowledge. Available at: <http://commons.pacific.edu/cgi/viewcontent.cgi?article=1011&context=coofac>. Accessed November 7, 2014.
15. Upender K. Clinical Applications of Optical Coherence Tomography in Ophthalmology: Selected Topics in Optical Coherence Tomography. Intech. Available at: www.intechopen.com/books/selected-topics-in-optical-coherence-tomography/clinical-applications-of-optical-coherence-tomography-in-ophthalmology. Accessed November 7, 2014.

Are you looking for ways to
plan for the future
of optometry?

Do you value
the importance of
quality education?

The time and money that you
commit to your education is a critical
investment in your ophthalmic career.
MAKE IT COUNT AT SECO 2015



SECO2015
Atlanta, GA | March 4-8
WHERE SIGHT MEETS VISION™


Two Registration Options

- 1 All-Inclusive Package includes everything at SECO - CE courses, exhibit hall, social events and access to SECO University.
- 2 A la Carte Package includes access to the exhibit hall and social events, but lets you choose and pay only for the CE courses you want.

Register today

Find out more at SECO2015.com





THE RICK BAY FOUNDATION

for Excellence in Eyecare Education

www.rickbayfoundation.org

Support the Education of Future Healthcare & Eyecare Professionals



About Rick

Rick Bay served as the publisher of *The Review* Group since 1991.

To those who worked for him, he was a leader whose essence was based in a fierce and boundless loyalty.



To those in the industry and the professions he served, he will be remembered for his unique array of skills and for his dedication to exceeding the expectations of his customers, making many of them fast friends.

Scholarships will be awarded to advance the education of students in both **Optometry** and **Ophthalmology**, and will be chosen by their school based on qualities that embody Rick's commitment to the profession, including integrity, compassion, partnership and dedication to the greater good.

Interested in being a partner with us?

Visit www.rickbayfoundation.org

(Contributions are tax-deductible in accordance with section 170 of the Internal Revenue Code.)



THE RICK BAY FOUNDATION
for Excellence in Eyecare Education

(The Rick Bay Foundation for Excellence in Eyecare Education is a nonprofit, tax-exempt organization under section 501(c)(3) of the Internal Revenue Code.)

NEW

Lombart CS-5 Package

Quality, Style & Value

Package includes:

- The Lombart CS-5 Chair & Stand 
- Topcon VT-10 Refractor
- Topcon SL-2G Slit Lamp
- Reichert LongLife Chart Projector  with mount, slide & screen
- Upgrade to the Lombart CVS-PC for only \$1500 or to the CVSi21 for only \$2000 more
- Additional upgrades & configurations available.

\$13,595

Or lease for \$265/mo.
for 60 months*

*Lease rate subject to credit approval, 1st payment is due at signing with 59 remaining rental payments of \$265 and a \$1.00 purchase option. Taxes, freight and installation additional. Hand Instruments optional. Subject to change without notice.

1-800-566-2278

Call 1-800-Lombart

Or Your Local Lombart Representative

Corporate Office - 5358 Robin Hood Road, Norfolk, VA 23513-2430
757-853-8888 | FAX 757-855-1232 | 800-566-2278

www.lombartinstrument.com
lombart@lombartinstrument.com



Sales and Service Centers Coast to Coast

ATLANTA • BALTIMORE/WASHINGTON D.C. • BOSTON • BOYNTON BEACH/MIAMI • BRADENTON • CHARLOTTE • CHICAGO • CINCINNATI • DALLAS • DENVER • DETROIT • GREENSBORO • HOUSTON
JACKSON • KANSAS CITY • KNOXVILLE • LOS ANGELES • MILWAUKEE • MINNEAPOLIS • NEW JERSEY/NEW YORK/PENNSYLVANIA • NORFOLK • PORTLAND • SAN ANTONIO • SAN DIEGO • SAN FRANCISCO



An Eye on Cancer Treatment

Be sure to watch for these rare but disastrous adverse ocular effects in patients on EGFR inhibitors who are being treated for cancer. **Edited by Joseph P. Shovlin, OD**

Q Over the years, I have had a few patients who have been on epidermal growth factor receptor inhibitors, such as panitumumab (for metastatic colorectal cancer) and erlotinib (for non-small cell lung cancer and pancreatic cancer). Do I need to be concerned about the ocular side effects listed (e.g., corneal perforation) and, if so, who specifically is at greatest risk?

A Ocular adverse effects associated with panitumumab and erlotinib use are fairly rare, but potentially serious. This is especially true in the case of contact lens wearers, or those who have pre-existing severe dry eye or a history of keratitis—especially ulcerative keratitis—says Kathy Kelley, OD, a medical optometrist specializing in cornea and external disease, and Matthew T. Feng, MD, a cornea, refractive and anterior segment surgeon. Both are part of Price Vision Group in Indianapolis.

Used to treat metastatic colorectal cancers that overexpress epidermal growth factor receptor (EGFR), panitumumab “is a recombinant human IgG₂ kappa monoclonal antibody administered intravenously to competitively inhibit EGFR at an extracellular binding site,” say Drs. Kelley and Feng. Erlotinib, in contrast, “blocks the EGFR intracellularly via its tyrosine kinase, like other tyrosine kinase inhibitors such as gefitinib, lapatinib and canertinib.”

EGFR inhibitors are most fre-

quently associated with cutaneous adverse effects like redness, itching or rashes on the face, neck or torso, Drs. Kelley and Feng explain. This is because EGFR regulates skin growth and regeneration, or “the proliferation, differentiation, migration and apoptosis of epidermal cells, including corneal and conjunctival epithelium.”¹ Panitumumab, in particular, carries a black box warning for dermatologic toxicity (seen in 90% of patients), with 15% of cases considered severe.^{2,3}

In the case of panitumumab use, irritation and conjunctivitis are the most common ocular adverse effects. However, say Drs. Kelley and Feng, there were early reports of one serious case of keratitis and three serious cases of ulcerative keratitis, as well as mild keratitis documented in clinical trials at a rate of 0.2-0.7%.⁴ This outcome prompted the manufacturer to release a physician warning.⁴ Other serious adverse effects, including corneal perforation that required penetrating keratoplasty, were also observed during a small case study, Drs. Kelley and Feng add.⁵

Erlotinib users may also experience decreased tear production, redness, pain and inflammation. Although these ocular effects are still quite rare based on the number of reports in literature, they appear to be more common for erlotinib than panitumumab, Drs. Kelley and Feng note. “One

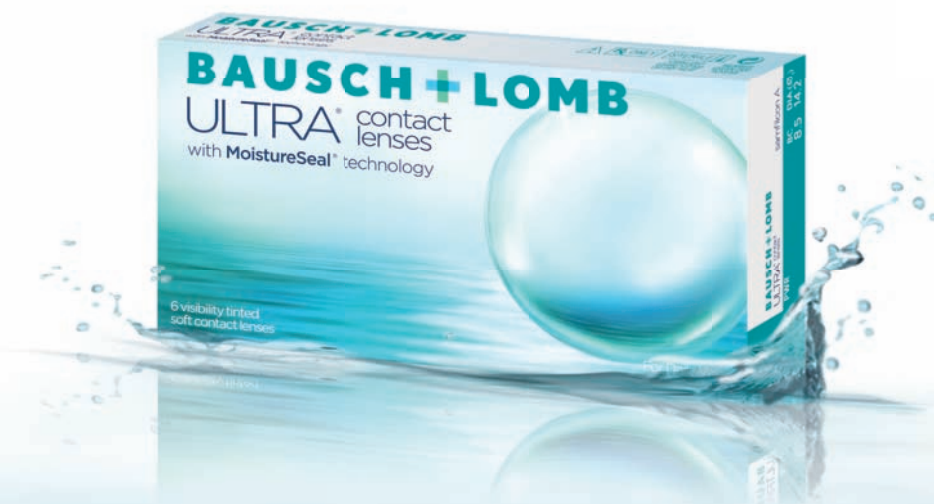theory is that intracellular kinase inhibitor is more potent than competitive extracellular antibodies inhibitors.”

Drs. Kelley and Feng recommend that any patients taking EGFR inhibitors should be educated regarding the symptoms of epithelial defects and keratitis and told to report any suspicions immediately. Because EGFR inhibitors impair corneal epithelial healing, “patients who are at greatest risk for epithelial damage may not recover normally, and instead experience persistent defects that rarely progress to non-inflammatory ulceration or even frank perforation,” they explain. “Those who present with confirmed epithelial defects or keratitis should be referred emergently to an ophthalmologist. In consultation with the prescribing oncologist, the EGFR inhibitor should be discontinued or at least held.” ■

1. Nakamura Y, Sotozono C, Kinoshita S. The epidermal growth factor receptor (EGFR): role in corneal wound healing and homeostasis. *Exp Eye Res.* 2001 May;72(5):511-7.
2. Van Cutsem E, Peeters M, Siena S, et al. Open-label phase III trial of panitumumab plus best supportive care compared with best supportive care alone in patients with chemotherapy-refractory metastatic colorectal cancer. *J Clin Oncol.* 2007 May 1;25(13):1658-64.
3. Amgen, Inc. Vectibix (panitumumab) injection for intravenous use prescribing information. Available at: http://pi.amgen.com/united_states/vectibix/vectibix_pi.pdf. Accessed November 11, 2014.
4. Amgen, Inc. Direct healthcare professional communication on the association of Vectibix (panitumumab) with keratitis and ulcerative keratitis. Cambridge, England; 2011.
5. Saint-Jean A, Sainz de la Maza M, Morral M, et al. Ocular adverse events of systemic inhibitors of the epidermal growth factor receptor: report of 5 cases. *Ophthalmology.* 2012 Sep;119(9):1798-802.



Break the Cycle of Discomfort™ for unsurpassed comfort & vision all day¹



“It’s like wearing nothing.” –Dr. Greg Usdan, Memphis, TN

See what happens when eye care professionals wear them for the first time at www.BLUltra.com

REFERENCE: 1. Results from a 22-investigator, multi-site study of Bausch + Lomb ULTRA® contact lenses with MoistureSeal® technology, on 327 current silicone hydrogel lens wearers. After 7 days of wear, subjects completed an online survey. Subjects rated performance across a range of attributes. Preference comparisons represent only those subjects expressing a preference. Ratio is based on the average across the silicone hydrogel lenses represented in the study.

®/™ are trademarks of Bausch & Lomb Incorporated or its affiliates. All other product/brand names are trademarks of their respective owners.

© 2014 Bausch & Lomb Incorporated. PNS07359 US/ZUS/14/0128

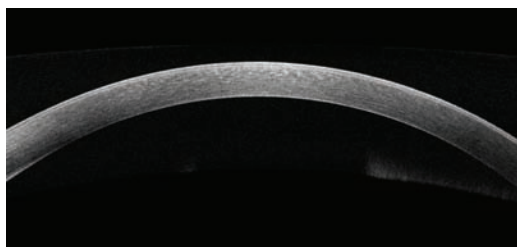
BAUSCH + LOMB
See better. Live better.

Advancing Smart OCT with New Imaging Applications

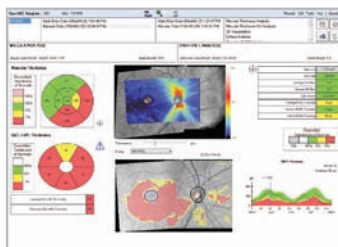
for Glaucoma & Anterior Segment



The first retinal OCT with full chamber scan – **NEW! ChamberView™ (15 mm)**



NEW! HD Cornea Scan (9mm)



NEW! PanoMap™ Analysis

Introducing New Smart OCT Imaging Applications

ZEISS has been at the forefront of industry-defining advancements that have made OCT a standard of care. Today, that leadership continues with NEW imaging applications, including:

- Anterior segment premier module – see the anterior segment like never before.
- PanoMap™ wide-field view helps assess structural damage in glaucoma.

Discover what's new with CIRRUS™ HD-OCT at www.meditec.zeiss.com/cirrus.

From the technology leader voted #1 Diagnostic Brand and Equipment Company in 2014.





Don't Know Much 'Bout History

'People are trapped in history and history is trapped in them,' James Baldwin wrote. Our job: To unlock that history as best as we can. **By James L. Fanelli, OD**

A 75-year-old white male, who not been to an eye care provider in several years, was recently referred for baseline diabetic retinal examination by his primary care provider. The patient has hypertension, rheumatoid arthritis, carotid artery disease and non-insulin dependent diabetes mellitus. Yet, he says, he "just needs new glasses."

History (or Lack Thereof)

The best that we could discern from the patient was that he's had type 2 diabetes mellitus for many years. He doesn't check his glucose levels but says that his primary care provider is "happy with his diabetes," which we assume means that he is adequately controlled.

He reported some type of cardiovascular event approximately 30 years earlier, but denied surgical intervention, in particular coronary artery bypass graft. He did report (and a noticeable scar was present) a right carotid endarterectomy approximately six months earlier—with either a residual 60% occlusion or a preoperative occlusion of 60%. He did not know which medications he was currently taking, and told my tech that we can get that information from his internist. When asked about medicine allergies, he replied, "maybe," but he couldn't remember for sure.

Upon further questioning, he evidently had cataract extractions OU several years ago, and possibly YAG capsulotomies shortly thereafter in at least one eye. Also, our

vague historian reported something about "high eye pressures" at a visit to another provider, for which he never followed up.

He simply was not a good historian, did not know what medications he was taking and had no real timeline of previous illnesses and surgeries. In fact, the only thing he was certain of was that he just wanted new glasses.

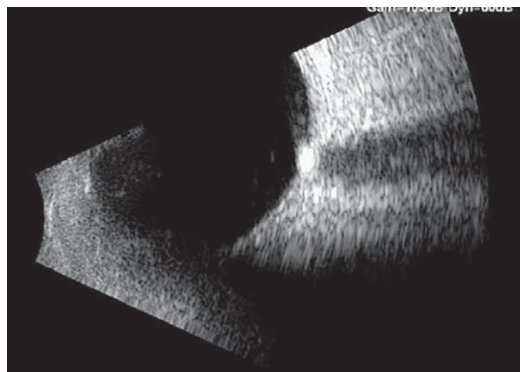
Diagnostic Data

Entering visual acuity was 20/30- OD and 20/25- OS through mild hyperopic astigmatic correction. Pupils were equal, round and reactive to light and accommodation, with no afferent defect. Confrontation fields were slightly constricted superiorly OU, which I attributed to his moderate dermatomal chiasmal. Blood pressure measured 194/82mm Hg, with a resting pulse of 58 bpm.

Slit-lamp examination of the anterior segments was unremarkable. Mild guttatae were present in both eyes, and the anterior chambers were deep and quiet.

Intraocular pressure measured 30mm Hg OD and 28mm Hg OS at 9:15 AM. Central corneal thickness readings measured 636µm OD and 626µm OS.

Dilated examination showed that the IOLs were clear and centered in the capsular bags. Bilateral



B-scan ultrasound shows the presence of buried disc drusen, which accounts for the patient's crowded optic disc appearance. But, does he have glaucoma?

posterior vitreous separations were present. Cup-to-disc ratios were estimated to be 0.1 x 0.1 OU. Optic discs were of normal size, but the neuroretinal rims were full and suggestive of disc drusen (both anterior and suspected buried drusen).

The retinal vasculature was characterized by grade 1 hypertensive retinopathy and grade 2 arteriolar sclerotic retinopathy, with moderate arteriovenous nicking in both eyes. The retinal venules were slightly dilated. Both maculae were characterized by isolated intraretinal hemorrhages and scattered perifoveal microaneurysms, consistent with non-proliferative diabetic retinopathy. There was no clinical evidence of diabetic macular edema, although there was loss of the foveal reflexes and disruption of subfoveal retinal pigment epithelium (OD > OS).

There was no evidence of neovascularization of the disc, the iris or elsewhere in either eye.

Diagnosis

The retinal examination showed mild, symmetrical non-proliferative diabetic retinopathy, as well as peripheral retinal degeneration OU. Further testing is necessary to determine if this patient also has glaucoma.

Discussion

Patients like this present many challenges to the busy health care provider—from lack of historical data to preconceived notions of what is going to occur during the office visit to compliance issues. As providers, we need to adapt to the individual circumstances of the encounter, while at the same time not compromising care.

In this particular case, I was dealing with someone who was unable to provide much of a relevant medical history. To confound the issue, the patient made it clear that he was just in the office for a new pair of glasses. We've all been faced with similar situations. The question is: How do we find the best course of action? Just as there are varied scenarios that hamstring our clinical evaluations, so too are there varied solutions to these patient encounters.

Considering this patient was clearly unwilling to undergo multiple tests on this initial visit, I had to prioritize which tests I deemed absolutely necessary to make an initial diagnosis on that day, and to reschedule further testing for a later date. Whether he will comply with further visits and evaluation remains to be seen, but I do have an obligation to render appropriate care at the moment of the patient encounter.

As such, I was able to determine that the diabetic retinopathy was mild and did not coincide with neovascularization or macular edema.

Nothing more needed to be done regarding the retinopathy at this visit, other than photodocument it.

The elevated IOP was of concern. Fortunately, we were able to slip in a pachymetry reading at this visit, which revealed rather thick corneas (partially accounting for the high tonometry readings).

While the cup-to-disc ratios were small, the clinical picture was clouded by the appearance of disc drusen. However, given the patient vasculopathy, it's possible that the crowding of the disc is related to separate optic nerve disease. Accordingly, I wanted to establish baselines for the optic nerve at this visit, in the context of both ocular hypertension as well as disc drusen, and possibly other disorders of the optic nerve.

Visual field testing was unlikely to be productive, so I deferred it for a future visit. But, I was able to talk the patient into fundus photography, which would help establish baseline optic nerve images, as well as baseline diabetic retinal images. We were also able to obtain consent for B-scan ultrasonography, which indeed showed the presence of buried disc drusen that would certainly account for the crowded optic discs.

But does the patient also have glaucoma, or at least ocular hypertension with a risk of neuroretinal rim damage due to the elevated IOP? At this initial visit, the best I could firmly say was: "I don't think so," which is not how I like to finish patient encounters—I'd prefer to make a diagnosis one way or the other. But in reality, a patient must take at least some responsibility for his own health care. And, in this particular case, the patient wasn't upholding his end of the doctor/patient relationship. Because of that, I could only do those things

that I believed were most important at that time.

Making Progress

But this case also brings up another question in making a diagnosis of glaucoma in patients with optic disc drusen: How do you evaluate the neuroretinal rim for glaucomatous damage in the presence of disc drusen? The answer goes back to a basic tenet of glaucoma: It is a progressive disease that is known to cause structural and functional changes to the optic nerve over time.

The key words here are "over time." Frankly, patients with disc drusen who also have glaucoma don't typically have the characteristic thinning and erosion of the neuroretinal rim because of the crowded nature of the disc. They will, however, demonstrate loss of rim tissue and volume over time if the glaucoma is progressing. So, in these cases, it is imperative to monitor for both structural and functional changes over time.

Are these cases complex? Yes, they can be. Can a diagnosis of glaucoma be made easily? Not usually in one or two visits. Diligent monitoring is key here—over time.

For this patient, I did not have enough evidence to demonstrate glaucoma at the conclusion of the initial visit. Therefore, we scheduled him for follow up in four months for visual field testing, gonioscopy, optical coherence tomography and Heidelberg Retina Tomography (HRT-3, Heidelberg Engineering).

Over time, I'll be able to determine if there is change. Whether he ventures back into the office remains to be seen. Take what you are given today, and give it your best shot. That can work for medicine, and life in general. ■

19TH ANNUAL

OPHTHALMIC PRODUCT GUIDE



Innovative products to
enhance your practice

The **future**
is in your
hands. One
tap, many
possibilities.

Experience the digital edition on your handheld device.
Use your smart device to scan the code below or visit:



www.revoptom.com/supplements/

Download a QR scanner app. Launch app and hold your mobile device over
the code to view <http://www.revoptom.com/supplements>

REVIEW
OF OPTOMETRY



Go Further—Without Leaving Home



Expand your clinical skills and catch up on your CE requirements, all from the comfort of your own home.

Review offers **nearly 100 hours** of COPE-approved continuing education — right now! It's **just a click away**. Our extensive library of exams runs the gamut from keratoconus to fundus autofluorescence, and everything in between.



www.reviewofoptometry.com/continuing_education

Download a QR scanner app. Launch app and hold your mobile device over the code to view www.reviewofoptometry.com/continuing_education.

REVIEW[®]
OF OPTOMETRY



Take a Shot at this Bull's Eye

Our patient with a history of rheumatoid arthritis reported a steady loss of vision. Was her medication to blame? **By Mark T. Dunbar, OD**

A 64-year-old Hispanic female presented for an evaluation at the request of her primary care physician. She reported her vision had been blurry for the past several months and further described the problem as a steady, painless, progressive loss of vision. Additionally, she noted a foreign body sensation—as if there were grains of sand in her eyes. Her last eye examination was approximately four years earlier.

She has a history of severe rheumatoid arthritis (RA) and currently is using several medications, including 10mg prednisolone QD and 200mg hydroxychloroquine BID.

Her best-corrected visual acuity measured 20/30 OU. Her pupils were equally round and reactive to light, with no evidence of afferent defect. Confrontation visual fields were full to careful finger counting OU, and ocular motility testing was normal. Her Amsler grid results were normal OU.

The anterior segment was significant for 1+ diffuse injection and moderate central corneal staining in both eyes. Further, we documented grade 1-2+ posterior subcapsular cataracts in both eyes. Intraocular pressure measured 14mm Hg OU.

Her optic nerves appeared healthy on dilated fundus examination, with a small cup and good rim coloration and perfusion OU. The vessels were of a normal caliber and her peripheral retinae were unremarkable. We performed a spectral-domain optical coherence

tomography scan, which is available for review (*figures 1 and 2*).

Take the Retina Quiz

1. What additional testing should be recommended for our patient?

- Amsler grid.
- Color vision.
- 10-2 threshold visual field.
- All of the above.

2. How would you interpret the spectral-domain optical coherence tomography (SD-OCT) images of our patient's maculae?

- Normal.
- Focal defect at the level of the ganglion cell layer.
- Diffuse macular edema.
- Focal loss at the level of the inner segment/outer segment (IS/OS) junction.

3. What do the findings in our patient represent?

- Hydroxychloroquine-induced toxicity.
- Fabry disease.
- Epiretinal membrane with diffuse macular thickening.
- None of the above.

4. What is considered to be a safe dose for hydroxychloroquine?

- 7.5mg/kg.
- 6.5mg/kg.
- 5.0mg/kg.
- Both b and c are correct.

Discussion

Our patient is suffering from moderate dry eye, as well as pos-

terior subcapsular cataracts. The cataracts likely are due to long-term prednisone use.

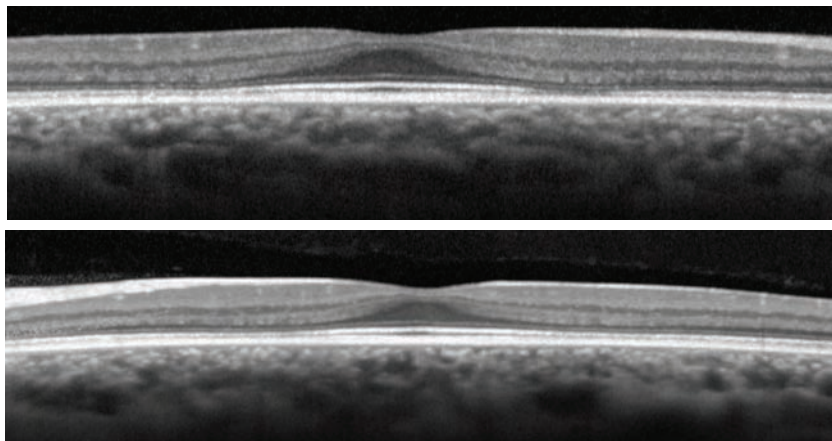
The patient explained that she has been taking 400mg Plaquenil (hydroxychloroquine, Sanofi-Aventis) for approximately 15 years. Careful clinical evaluation of both maculae appeared normal.

So, based on clinical evidence, can we conclude that she doesn't have hydroxychlorine-induced macular toxicity? Indeed not! Further testing is indicated, including a 10-2 visual fields evaluation, as well as any one of the following: SD-OCT, fundus autofluorescence (FAF) or multifocal electroretinogram (mERG). We chose to order an SD-OCT scan, and instructed her to return within a few weeks for a scheduled 10-2 visual field.

Her SD-OCT scan was quite revealing. In the outer retinal layers at the level of the IS/OS junction, we noted a focal loss or defect on the nasal and temporal side of the right macula. The left macula exhibited a similar presentation, but the line was not as bold and probably represented diffuse loss. Given these findings, our patient likely has early hydroxychloroquine-induced macular toxicity.

Hydroxychloroquine is a member of the quinolone family of drugs. Rheumatologists frequently prescribe the agent to treat RA, systemic/discoid lupus erythematosus and other connective tissue and inflammatory disorders.

Chloroquine and, to a lesser



1, 2. Spectral-domain optical coherence tomography images of the patient's maculae (OD top, OS bottom). What do you notice?

extent, hydroxychloroquine are well known to cause macular toxicity. In later disease stages, affected individuals may manifest a “bull’s eye” macular lesion with a corresponding visual field defect. Unfortunately, once these changes are actually visible in a clinical evaluation, the toxicity is already fairly advanced.

With the advent of SD-OCT and other specialized tests, such as FAF and mERG, eye care providers now can detect these changes before they affect visual function. With such advanced diagnostic technologies in mind, Michael F. Marmor, MD, and associates published revised recommendations for screening patients on Plaquenil therapy in 2011.¹ The updated guidelines removed color vision testing and Amsler grid as acceptable screening methods, and instead recommended that patients be followed with 10-2 visual fields and at least one of the following advanced diagnostic tests: mERG, SD-OCT or FAF.¹

All patients who are started on hydroxychloroquine should undergo a baseline eye exam within the first year of treatment. This should include a dilated fundus evaluation, 10-2 white-on-white threshold visual fields and at least one of the

forementioned advanced tests. These examinations do not have to be repeated for at least five years after dosing initiation, unless the patient exhibits other risk factors for hydroxychloroquine-induced macular toxicity.

Retinal toxicity from Plaquenil occurs in approximately 0.5% to 2.0% of long-term users; however, the true risk may be higher, because those percentages are derived from short-term use studies.^{1,2} A dose of 6.5mg/kg/day in a person of “ideal body weight” is believed to be a safe dosage.¹ For example, a patient who weighs 135lbs should take two 200mg tablets per day ($61.2\text{kg} \times 6.5\text{mg/kg/d} = 398\text{mg/d}$).^{1,2}

Dr. Marmor and associates recently published research evaluating the risk of associated toxicity from long-term Plaquenil use.² They conducted a retrospective study of an integrated health organization consisting of 3.4 million members. Of this population, approximately 2,361 patients used hydroxychloroquine for at least five years. The overall prevalence of toxicity was 7.5%, but this number varied based on daily dosage and duration of use.

Of interest, they used “real body weight” to calculate the daily

dosage compared to “ideal body weight.” When using real body weight, the researchers determined that 5.0mg/kg/day was equivalent to the ideal body weight measurements of 6.5 mg/kg/day. Using these calculations, Dr. Marmor’s group determined that for a dosage of 4.0mg/kg/day to 5.0mg/kg/day, the prevalence of macular toxicity dropped to less than 2% within the first 10 years and rose to almost 20% after 20 years.² They concluded that when Plaquenil is taken at dosages greater than 5.0mg/kg/day, the risk of retinal toxicity is two to three times higher.²

Our patient weighed approximately 130lbs. Using Dr. Marmor’s “real body weight” calculation: $130\text{lbs} = 58\text{kg} \times 5.0\text{mg/kg/d} = 290\text{mg}$. Thus, her daily dose of Plaquenil should be approximately 290mg, not 400mg as prescribed. So, it’s no wonder she developed retinal toxicity after 15 years of use.

We informed her rheumatologist that she developed retinal toxicity from the hydroxychloroquine use. We then educated the patient about her cataracts, but explained that she was not yet ready for surgery. Additionally, we started her on Restasis (cyclosporine, Allergan) BID and Lotemax (loteprednol, Bausch + Lomb) BID for her dry eye.

She returned two weeks later for a 10-2 visual field and, indeed, it showed a classic circular paracentral scotoma in both eyes that did not involve central fixation. After informing her rheumatologist of these findings, she was instructed to discontinue hydroxychloroquine therapy. ■

1. Marmor MF, Kellner U, Lai TY. Revised recommendations on screening for chloroquine and hydroxychloroquine retinopathy. *Ophthalmology*. 2011 Feb;118(2):415-22.

2. Melles RB, Marmor MF. The risk of toxic retinopathy in patients on long-term hydroxychloroquine therapy. *JAMA Ophthalmol*. 2014 Oct 2. [Epub ahead of print]

DOWNLOAD LAYAR APP
FOR INTERACTIVE EXPERIENCE



First 150 app downloads and completed forms will be entered into a drawing for **FREE MEETING AND REGISTRATION VALUED AT \$495**



REVIEW OF OPTOMETRY

EDUCATIONAL MEETINGS OF CLINICAL EXCELLENCE



PAUL KARPECKI, OD
PROGRAM CHAIR


SAVE THESE DATES




SAN DIEGO, CA
APRIL 10-12



CHARLESTON, SC
JUNE 12-14



MAUI, HI
JULY 23-26



PHILADELPHIA, PA
NOVEMBER 6-8

NEW Includes hands-on workshop

For more information visit www.reviewofoptometry.com



*Approval pending

Up to 17 CE Credits
(COPE approval pending)

‘Tis the Season to be... Careful

Here’s how you can help keep your patients’ vision merry and bright during the holidays. **By Alan G. Kabat, OD, and Joseph W. Sowka, OD**

It’s been said that “safety never takes a holiday.” With the season of ongoing winter holidays—Thanksgiving, Chanukkah, Kwanzaa, Festivus, Christmas and New Year’s—upon us, every physician dreads the idea of being called to the office for an emergency. More importantly, none of us want to find ourselves or our family members falling victim to an injury during this happy, normally carefree time.

So, as we get ready to celebrate the holidays, our gift to you is a few friendly words of advice and warning about the potential dangers that lurk in the guise of celebration, and how best to avoid or manage these untimely problems.

‘Oh Christmas Tree, Oh Christmas Tree!’

As beautiful as it may be to have a lighted and decorated evergreen in the house while the trees outside are bare and snow-covered, Christmas trees can pose many potential ocular threats. Between the pine/fir/spruce needles, the electric light bulbs and the glass ornaments, there are multiple hazards awaiting the holiday reveler... particularly if he or she has been indulging in a few glasses of “Christmas cheer!” The needles of some conifer trees can be up to 1.5in long, providing a unique and dangerous source of ocular trauma—especially corneal abrasions and possibly even perforation.

Several studies have reviewed the incidence of eye injuries related to Christmas trees, and researchers have noted that just as many (or even more) instances of trauma occur during the harvesting, transporting and disposal of the trees as do during initial setup and decoration.^{1,2}

Children may be especially vulnerable to such injuries, either from low-hanging branches impeding their path to gifts, or from sharp, irregularly shaped ornaments hanging at eye level.³ Ideally, we can prevent these situations by counseling patients (and their family members) to take proper precautions when carrying or decorating Christmas trees, including using safety eyewear to prohibit abrasions and foreign bodies. Likewise, to avoid unwanted trauma, make sure that presents placed beneath the tree are easily accessible.

‘You’ll Shoot Your Eye Out, Kid!’

There are probably very few of us who don’t recognize or recall this classic line from *A Christmas Story*, and it’s a good line to remember—children’s toys can be a significant cause of eye injuries. By far, the greatest culprits are projectile toys like paintball, pellet and even airsoft guns, which can all cause significant ocular trauma.^{4,6}

While not ubiquitous, these items are still very popular in some areas of the county and

present a possible danger to ocular health. The risk can be mitigated, however, with the use of appropriate safety eyewear—a mandatory stipulation with any and all types of toy guns. Parental supervision is another important consideration whenever children are using such projectile-firing devices.

A number of other toys also have been implicated in ocular trauma. Remote control helicopters, which are now widely available and affordable, are yet another potential source of devastating ocular injury.⁷ Additionally, toys or products that incorporate functioning lasers can lead to inadvertent, but sight-threatening, retinal burns.⁸

While we understand that accidents may happen, it is important to make sure that younger children receive safe and appropriate toys whenever possible and are counseled on proper use. In general, avoiding items with sharp edges, projectiles and high-intensity lights is good advice.

Happy New Year!

In the United States, it is often customary to pop champagne corks at the stroke of midnight on New Year’s Eve and celebrate the incoming year with a glass of bubbly. As you can imagine, ocular contusion injuries due to airborne corks pose a small but real threat to revelers. The array of possible trauma-related diagnoses include



corneal abrasion, hyphema, uveitis, iridodialysis, traumatic cataract, lens subluxation, retinal tears, retinal detachments and even globe rupture.^{9,10}

In other cultures, and some more localized areas of the US, New Year's festivities may include fireworks and even celebratory gunfire. The potential for ocular injuries due to recreational explosives and incendiary devices is well known: "party poppers" (hand-held, bottle-shaped plastic party favors that emit a shower of streamers and confetti when a string is pulled) can cause burns to the skin and eye if fired at close range, and more severe and sight-threatening injuries have been caused by firecrackers, cherry bombs, bottle rockets, roman candles and other such items.^{11,12}

It should come as no surprise that firing handguns into the air (a dangerous practice encountered every year on New Year's Eve in such places as Miami, Houston, Los Angeles and Puerto Rico) can lead to an array of injuries, including potentially to the eyes, and in some cases result in fatalities.¹³

So, with a little caution and a dash of common sense, you can help protect both your family and your patients from significant ocular injury during the coming weeks.

Here's wishing all of you a very happy, healthy and peaceful holiday season. We look forward to sharing our experiences and perspectives with you in 2015. ■

1. Brazier DJ. Eye damage from Christmas trees. *Lancet*. 1984 Dec 8;2(8415):1335.
2. Tsatsos M, Tsesmetzoglou E, Triandafyllidis C, et al. Christmas-related eye injuries: a prospective study. *Clin Experiment Ophthalmol*. 2010 Jan;38(1):85-6.
3. Kimia A, Lee L, Shannon M, et al. Holiday ornament-

Common Treatments for Not-So-Merry Mishaps

Having practiced for the last 25+ years, we can attest to the fact that it's no fun taking call over the holidays. But as many of us know all too well, patients with ocular injuries quite often receive better and more appropriate care from their optometrist than they would from a hospital emergency room. If an injury should take you away from your holiday festivities, triage the patient thoroughly and assess the level of damage. Then remember these important points:

- The most common traumatic injuries include corneal abrasions, burns and foreign bodies. Employ a potent cycloplegic (homatropine 5% or atropine 1% BID) to help suppress a secondary uveitis. Remove any superficial foreign bodies and debride any loose, burned or otherwise compromised epithelium. Then use a bandage contact lens with a prophylactic antibiotic (e.g., moxifloxacin 0.5% TID) to facilitate re-epithelialization. These types of injuries typically require follow-up daily or every other day until the cornea is re-epithelialized.
- In cases of projectile injury, careful but gentle examination is required. If no sign of perforating injury is seen, conduct a thorough ocular evaluation and perform a dilated fundus examination. Giant retinal tears (defined as involving >90° degrees of the retina) require immediate surgery, as do detachments involving or threatening the macula. In the latter case, recommend supine bed

rest until consultation and treatment can be arranged.¹⁴

Traumatic hyphema and uveitis are best managed with strong cycloplegics, potent topical steroids (e.g., difluprednate 0.05% dosed QID or greater) and relative immobilization. Hyphema patients must be examined daily for the first five days to guard against rebleed; uveitis patients may be seen for follow up as severity dictates. It is also important to rule out angle recession by performing gonioscopy on all closed globe injuries approximately 30 days after the incident.

- Patients suspected of having penetrating or perforating injuries must be quickly referred to an appropriate surgical facility. It is recommended that no prophylactic or therapeutic drops be instilled, but rather efforts should be directed at carefully shielding the patient's eye from further damage. Contact appropriate specialists for consultation, and arrange transportation for the patient.

Remember that MRI is generally contraindicated if a metallic foreign body (such as a BB or pellet) is suspected, so X-rays or CT scans are preferable options. In suspected perforating injuries, remember that "RSVP" isn't limited to holiday party invitations: Redness, Sensitivity to light, Vision loss and Pain are indicators of endophthalmitis resulting from orbital penetration.

related injuries in children. *Pediatr Emerg Care*. 2009 Dec;25(12):819-22.

4. Pahk PJ, Adelman RA. Ocular trauma resulting from paintball injury. *Graefes Arch Clin Exp Ophthalmol*. 2009 Apr;247(4):469-75.
5. Shazly TA, Al-Hussaini AK. Pediatric ocular injuries from airsoft toy guns. *J Pediatr Ophthalmol Strabismus*. 2012 Jan-Feb;49(1):54-7.
6. Bisplinghoff JA, Duma SM. Evaluation of eye injury risk from projectile shooting toys using the focus headform - biomed 2009. *Biomed Sci Instrum*. 2009;45:107-12.
7. Alphonse VD, Kemper AR, Rowson S, Duma SM. Eye injury risk associated with remote control toy helicopter blades. *Biomed Sci Instrum*. 2012;48:20-6.
8. Raoof N, Chan TK, Rogers NK, et al. 'Toy' laser macular burns in children. *Eye (Lond)*. 2014 Feb;28(2):231-4.
9. Cavallini GM, Lugli N, Campi L, et al. Bottle-cork injury

to the eye: a review of 13 cases. *Eur J Ophthalmol*. 2003 Apr;13(3):287-91.

10. Kuhn F, Mester V, Morris R, Dalma J. Serious eye injuries caused by bottles containing carbonated drinks. *Br J Ophthalmol*. 2004 Jan;88(1):69-71.
11. Tadisina KK, Abcarian A, Omi E. Facial firework injury: a case series. *West J Emerg Med*. 2014 Jul;15(4):387-93.
12. Sacu S, Ségur-Eltz N, Stenng K, Zehetmayer M. Ocular firework injuries at New Year's eve. *Ophthalmologica*. 2002 Jan-Feb;216(1):55-9.
13. Centers for Disease Control and Prevention (CDC). New Year's Eve injuries caused by celebratory gunfire—Puerto Rico, 2003. *MMWR Morb Mortal Wkly Rep*. 2004 Dec 24;53(50):1174-5.
14. García-Arumí J, Martínez-Castillo V, Boixadera A, et al. Rhegmatogenous retinal detachment treatment guidelines. *Arch Soc Esp Oftalmol*. 2013 Jan;88(1):11-35.

Innovations for Low Vision

Fewer complications and less invasive surgeries improve the prospects for success.

By Paul M. Karpecki, OD, and Diana L. Schectman, OD

Exciting new technologies for enhancing the lives of low vision patients include telescopic intraocular lenses (IOLs) and stem cells harvested from a patient's own body for transplant in the eye.

Let's talk briefly about how they work, and what recent research shows about their clinical value.

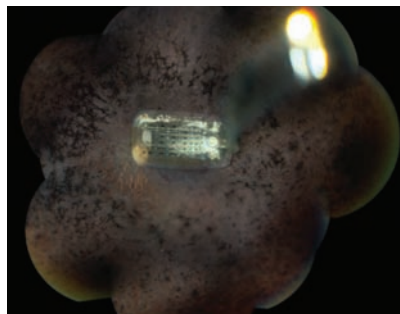
Stem Cell Transplants

Pluripotent skin stem cells are being programmed as retinal pigment epithelium (RPE) stem cells for the treatment of macular degeneration.¹ They are lauded as easier to grow and transplant, and are derived from the patient's own cells so they don't require an invasive procedure for harvesting. Additionally, the cells self-renew, expand in cultures and differentiate into RPE.¹

In September, a Japanese woman in her 70s became the world's first patient to receive tissue derived from induced pluripotent stem cells as part of an experimental treatment to repair damage caused by age-related macular degeneration.

RPE cells are derived from human induced pluripotent stem cells. During the two-hour procedure at the Institute for Biomedical Research and Innovation in Kobe, Japan, surgeons grafted a single 1.3mm x 3.0mm sheet of RPE cells into the subretinal space of one eye. No serious hemorrhaging or complications occurred.²

The epithelium sheet was developed by ophthalmologist Masayo Takahashi, MD, PhD, of the RIKEN



The Argus II Implant attached to the retinal surface with a tack. The cable that both powers the chip and conducts the image signal from the episcleral housing is seen temporally (on the right side of the photograph).

Center for Developmental Biology using pluripotent stem cells, which have the unique potential to differentiate into almost any type of cell found within the body. The most prominent type of pluripotent stem cell is the embryonic stem cell; however, limited resources and ongoing controversy has prevented widespread adoption. Induced pluripotent stem cells, on the other hand, are artificially derived from an adult somatic cell. In this case, the pluripotent stem cells were derived from the patient's own skin cells, then converted into RPE cells and grown into a sheet.

This pilot study follows an earlier preclinical safety and feasibility evaluation of human-induced pluripotent RPE cell sheets created without using artificial scaffolds.¹ The research examined cell morphology, physiological behavior, gene expression, immunogenicity and tumor

formation in rodent and non-human primate models.

RPE cells are formed into a sheet to be implanted into the subretinal space of a patient with AMD. Researchers believe the use of pluripotent stem cells will improve upon current treatments that are designed to halt neovascularization, but do not repair photoreceptor cell damage that may have already occurred prior to administration. The RPE graft, however, could stop further damage and may even eventually stimulate some healing of the epithelium.

Additionally, harvesting the patient's own cells from an innocuous site such as the skin reduces potential complications associated with immune rejection and avoids invasive harvesting procedures.

The current patient will be monitored for both functional integration and adverse reactions during a one-year initial intensive observation period, with subsequent follow-up observation for an additional three years. Five additional patients will be treated using the same procedure as part of the pilot study. Although early in progress, the possibilities could be life changing.

Artificial Implant Technologies

Although RPE stem cell transplantation is years away, innovative technologies available today for patients with end-stage macular diseases include the Argus II and telescopic IOLs.

- *Argus II* (Second Sight Medical Products). Essentially a circuit board



that allows for 32,000-pixel imaging, this device is inserted onto the macula. By stimulating a wireless system and spectacles as a transducer, it sends a current to the occipital lobe, allowing patients to see images, shadows and shapes. It is indicated in patients 25 years or older with late-stage retinitis pigmentosa progression if the patient sees only bare light or has no light perception, according to the manufacturer. Eligible patients must have no previous history of useful form vision. If the patient is phakic, the surgeon removes their natural lens during the implantation procedure.³

Recent small studies continue to show significant improvement in vision after implantation. In a study of 27 patients from 2011, 93% improved their ability to repeatedly touch a small square projected on a touch-screen monitor.⁴ In another study, researchers evaluated 12-month outcomes in six patients with no better than light perception. All patients visualized a bright light on the ceiling and a dark line on the floor after the surgery and improved in Goldman visual field tests. One patient had postoperative elevated intraocular pressure and another experienced a detached choroid following surgery.⁵ None of the patients had wound dehiscence, endophthalmitis or retinal detachments.

The FDA approved the Argus II in February 2013; currently, 13 centers across the US perform the surgery.

- **Telescopic IOLs.** These IOLs can magnify retinal images onto viable peripheral retinal locations in patients with low vision. There are three types of telescopic implants:
 - *IOL VIP Revolution* (Veni Vidi). Billed as “the IOL for visually impaired people,” this device magnifies images at the macula. Two



The wide-angle micro-optics of the Implantable Miniature Telescope work in combination with the optics of the cornea to create a telephoto system that magnifies objects approximately 2.2 to 2.7 times their normal size.

lenses are inserted into the capsular bag, with a plastic ring providing support.⁶ Available in the UK and Ireland, the Revolution is not approved yet for use in the US.

- *IMT* (VisionCare). The Implantable Miniature Telescope “enlarges images in front of the eye approximately 2.2 or 2.7 times their normal size,” according to the company. Two lenses are inserted in the capsular bag through a large corneal incision and are contained within a small tube mounted on a circular disc. Inform patients that they may lose peripheral vision, as the lens is implanted in only one eye, whichever is worse.⁶ The IMT is approved for use in the US.

- *iolAMD* (London Eye Hospital Pharma). Also known as the Hubble implant, the iolAMD is made up of two small lenses that are injected

into the eye through a micro-incision. The lenses are implanted in whichever eye is worse. It takes one to two months for the lenses to improve a patient’s vision.⁷ It’s not yet available here, but the US is in talks with the UK manufacturer to obtain clinical data on the device.

Make sure patients know their vision will not be corrected like in cataract surgery, and they will need glasses for both near and distance vision. They’ll still need low vision aids to assist them, as well.⁶

The future is bright, with potential for new technology to make the lives of patients with low vision easier. ■

Drs. Karpecki and Shechtman have no direct financial interest in any of the products mentioned.

1. Kamao H, Mandai M, Okamoto S, et al Characterization of human induced pluripotent stem cell-derived retinal pigment epithelium cell sheets aiming for clinical application. *Stem Cell Reports*. 2014 Jan 23;2(2):205-18.
2. RIKEN Center for Developmental Biology. First RPE cell sheet graft transplant. Available at: www.riken.jp/en/pr/top-ics/2014/20140912_1/. Accessed October 6, 2014.
3. University of Michigan Kellogg Eye Center. Argus II Retinal Prosthesis System: Retinal implant for individuals with late-stage retinitis pigmentosum. Available at: www.kellogg.umich.edu/argusii/. Accessed November 21, 2014.
4. Ahuja A, Dorn JD, Caspi A et al. Blind subjects implanted with the Argus II retinal prosthesis are able to improve performance in a spatial-motor task. *Br J Ophthalmol*. 2011;95(4):539-43.
5. Rizzo S, Belting C, Cinelli L. Am J Ophthalmol. The Argus II Retinal Prosthesis: 12-month outcomes from a single-study center. 2014 Jun;157(6):1282-90. Published online ahead of print February 19, 2014.
6. Luff AJ. Understanding telescopic lens implant surgery. Available at: www.sapphire-eyecare.co.uk/iol/understanding.htm. Accessed November 21, 2014.
7. iolAMD website. iolAMD Frequently Asked Questions. Available at: <http://iolamd.com/faq-patients.php>. Accessed November 21, 2014.

Going All Online

Innovation in eye care happens fast—sometimes too fast for busy practitioners to fully grasp in the moment. When a groundbreaking new research paper comes out, what are the salient points of the study that you need to factor in to your patient care decisions? That’s the challenge we’ve been privileged to help you overcome through this column for well over a decade. And starting next month, “Research Review” will appear exclusively online, so that we can deliver news and expert analysis from the research community to your exam room more quickly than ever before. We thank you for the many years of loyal readership our print column generated. Check out the online-only version in January at www.reviewofoptometry.com.

Product Review

Contact Lenses

Contact Lens Solution

Miraflow has been re-released after a four-year absence from the market. The company says it's the only extra-strength cleaner that removes mucus and protein that builds up on lenses. Patients achieve this by gently rubbing the lens in the solution in the palm of their hand. After that, the patient should rinse the lens with an all-in-one cleaner or sterile saline solution.



The cleaner works for soft, silicone hydrogel, toric, hard, bifocal and scleral lenses.

Visit www.miraflow.com.

Contact Lens Convenience Packs

You can help contact lens wearers learn the value of daily lens care with an appropriate multipurpose solution if you package the lenses and an MPS sample together. Practices that stock Bausch + Lomb's Ultra contact lens can use new convenience packs that combine Ultra lenses with samples of Biotrue multipurpose solution. When you purchase an inventory of Ultra lenses, you'll receive:

- 24 convenience pack boxes.
- 24 Biotrue multipurpose solution samples, each 10oz., with contact lens cases.
- One pad of Ultra consumer rebates (a \$60 rebate with the purchase of an annual supply of Ultra contact lenses).



Practitioners can then give patients a handy take-home pack at the dispensing visit. The packs also feature a built-in business card holder and referral reminder so patients can refer friends and family to your practice.

Visit www.bausch.com/ecp.

Contact Lenses Enhance Limbal Rings

A new contact lens, the 1-day Acuvue Define, already popular in Asia, enhances the natural beauty of the eye, says



Your own custom App

for iPhone, Android, iPad and Mobile Website!

EyeDocApp

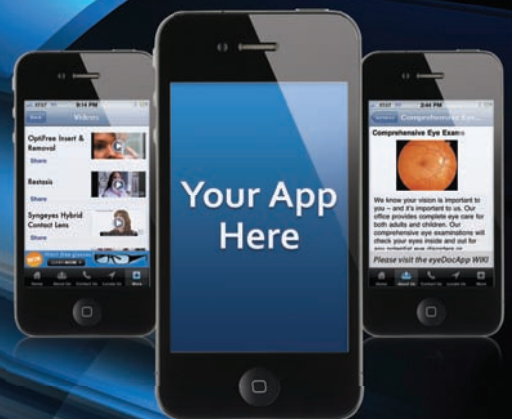EyeDocApp makes it easy for Individuals and Businesses to have their own custom App for iPhone, Android and iPad. Now you can use the same technology that Fortune 500 companies are using, for a fraction of the cost!

Apps are the most powerful mobile marketing tools in the world! Your custom App can be downloaded by anyone in the world via the iTunes and Android Marketplace. Now all your customers can have your business in their pocket, and at their fingertips. You can even send PUSH Notifications which instantly pop up on their phone, just like a text message.

Unlimited upgrades, push notifications, features and a user friendly interface –

All for \$49.⁹⁹/month

Learn more at EyeDocApp.com



Exclusively Marketed
by Jobson Optical's

BUSINESS SERVICES
Understand. Manage. Grow.

manufacturer J&J Vision Care. The lenses are designed to look like an iris, only darker. The dark limbal ring creates contrast between the iris and sclera and the inner translucent light effects pattern adds depth and definition, according to the manufacturer. The lenses do not change the eye's natural color. J&J says researchers have found that more pronounced limbal rings are associated with a healthy and youthful appearance.

The lenses come in +1.00 to -9.00 with a base curve of 8.5 and diameter of 14.2 mm in three styles, including Natural Sparkle, Natural Shine and Natural Shimmer.

Visit www.acuvueprofessional.com.

90-day Packs for Presbyopes

CooperVision announced increased convenience to patients with new 90-day packs of Proclear 1-day multifocal contact lenses. Patients can purchase a three-month supply and have new lenses every day. Proclear dailies



are still available in 30-day packs, the company says.

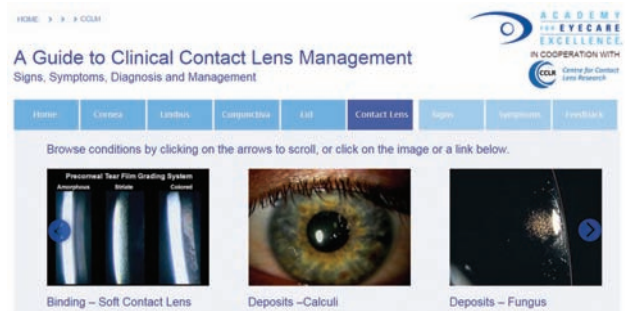Visit coopervision.com.

Online Contact Lens Complication Guide

Alcon is providing its free online Guide to Clinical Contact Lens Management to help you manage and treat contact lens complications.

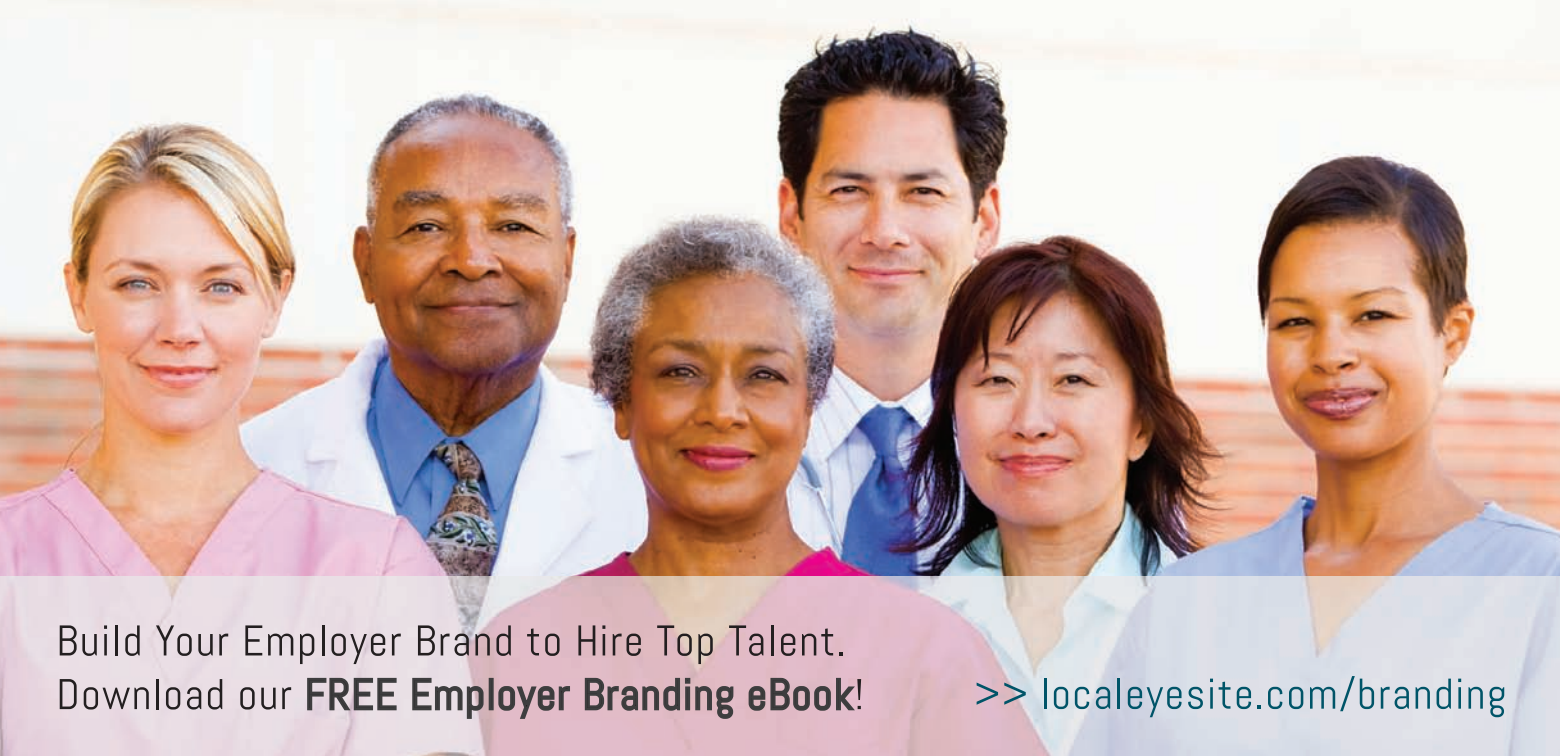The online resource stocks continuously updated images, videos and treatment suggestions for signs, symptoms and management options of anterior segment and contact lens-related conditions.

Visit www.myalcon.com/cclm.



Hire Quality.

 **Local Eye Site**
JOBS IN EYE CARE



Build Your Employer Brand to Hire Top Talent.
Download our **FREE Employer Branding eBook!**

>> localeyesite.com/branding

Meetings + Conferences

February 2015

- **6-8.** *2015 PBCOA Winter Seminar.* PGA National Resort & Spa, Palm Beach Gardens, FL. Hosted by: Palm Beach County Optometric Association. CE hours: 20. Key faculty: Carl Pelino, OD and Kimberly Reed, OD. To register, go to: www.pbcoa.org.
- **7-8.** *Destination CE.* Crowne Plaza Hotel, New Orleans, LA. Hosted by: Southern College of Optometry. CE Hours: 12. Key Faculty: Michael Gerstner, OD, FAAO; Whitney Hauser, OD; Mike Dorkowski, OD, FAAO; John Rumpakis, OD, MBA. To register, call 800-238-0180, ext. 5, or email ce@sco.edu.
- **13-15.** *54th Annual Contact Lens and Primary Care Congress.* Sheraton Kansas City Hotel at Crown Center. Kansas City, Mo. Hosted by: Heart of America Contact Lens Society. To register, go to www.hoacis.org.
- **13-17.** *Ski Vision 2015.* Westin Snowmass Luxury Resort. Snowmass Village, Co. Hosted by: AAO and UABSO. CE hours: 20. Key faculty: Murray Fingeret, OD, Leo Semes, OD, Jack Schaeffer, OD, Jack Cioffi, MD, David Friedman, MD, PhD, and more. To register, go to <http://skivision.com>.

REVIEW OF OPTOMETRY
EDUCATIONAL MEETINGS OF CLINICAL EXCELLENCE

NT & T
New Technologies and Treatments
IN VISION CARE
2015

PAUL KARPECKI, OD
PROGRAM CHAIR

SAVE THESE DATES

SAN DIEGO, CA
APRIL 10-12

CHARLESTON, SC
JUNE 12-14

MAUI, HI
JULY 23-26

PHILADELPHIA, PA
NOVEMBER 6-8

NEW Includes hands-on workshop

Up to 17 CE Credits

For more information visit www.reviewofoptometry.com

COVE
Approved provider

- **19-22.** *115th TOA Annual Convention.* Downtown Austin Hilton Hotel, Austin. Hosted by: Texas Optometric Association. CE hours: 27. Key faculty: Ian Ben Gaddie, OD, FAAO, Steven Ferucci, OD, FAAO and Diana Shechtman, OD, FAAO. To register, call Sherry Balance at (512) 707-2020 or email sherry@txeyedoctors.com.

txeyedoctors.com.

- **20-21.** *2015 Winter Conference.* Grand Summit Hotel Sugarloaf, USA, Carrabassett Valley, ME. Hosted by: Maine Optometric Association. To register, call (207) 237-2000.
- **26-28.** *Montana Optometric Association Winter Education Symposium Big Sky 2015.* Big Sky Resort, Big Sky, MT. Hosted by: Montana Optometric Association. CE hours: 13. Key faculty: Bruce Onofrey, OD, RPh, FAAO, FOGS; Curtis R. Baxstrom, OD. To register, go to www.mteyes.com.

March 2015

- **4-8.** *SECO 2015.* Georgia World Congress Center, Atlanta, Ga. Hosted by: SECO. To register, go to: www.seco2015.com.
- **20-22.** *Vision Expo East.* Jacob K. Javits Convention Center. New York, New York. Hosted by: International Vision Expo and Conference. To register, go to www.visionexpoeast.com.
- **26-28.** *OAOP Vision Summit.* Embassy Suites Hotel and Conference Center. Norman, OK. Hosted by: Oklahoma Association of Optometric Physicians. CE hours: 18. To register, go to www.oaop.org.

April 2015

- **15-17.** *World Cornea Congress VII.* San Diego Convention Center, San Diego, CA. Hosted by: ASCRS. To register, go to: <http://corneacongress.org>.
- **17-19.** *NOA Spring Conference-CE Event.* Embassy Suites, Lincoln, NE. Hosted by: Nebraska Optometric Association. To register, call Alissa Johnson, CAE, at (402) 474-7716 or email ajohnson@assocoffice.net.
- **18-19.** *Miami Nice Educational Symposium 2015.* Westin Colonnade, Coral Gables, FL. Hosted by: Miami-Dade Optometric Physicians Association. CE Hours: 17 COPE-approved, 12 transcript quality. Key Faculty: Ken Lebow, OD; John McGreal, OD; Carl Spear, OD; Al Morier, OD; John McClane, OD; Albert Woods, OD. To register, go to www.miami-eyes.org, call Steve Morris at (305) 342-5473 or email mdopa_board@gmail.com.
- **17-22.** *ASCRS-ASOA Symposium and Congress 2015.* San Diego Convention Center, San Diego, CA. Hosted by: ASCRS/ASOA. To register, go to: <http://annualmeeting.ascrs.org/>
- **22-26.** *13th Annual Educational Conference.* Hilton Embassy Suites at Kingston Plantation, Myrtle Beach, SC. Hosted by: American Academy of Optometry New Jersey Chapter. CE Hours: 16. Key Faculty: Mark Friedberg, MD; Alan Kabat, OD, FAAO. To register, call Dennis H. Lyons, OD, FAAO at (732) 920-0110 or email dhl2020@aol.com.
- **23-25.** *Mountain West Council of Optometrists (MWCO) Annual Congress.* Bally's, Las Vegas, NV. Hosted by:

Advertisers Index

Mountain West Council of Optometrists. CE Hours: 24. To register, visit www.mwco.org or call 1-888-376-6926.

■ **23-26.** *2015 Annual Spring Convention.* Marriott Hotel & Little Rock Convention Center, Little Rock, AR. Hosted by: Arkansas Optometric Association. To register, email Vicki Farmer at vicki@arkansasoptometric.org.

■ **29-May 7.** *Annual Educational Conference and Exposition.* Red Lion Colonial Hotel, Helena, MT. Hosted by: Montana Optometric Association. To register, call (406) 443-1160 or email sweingartner@rmsmanagement.com.

■ **30-May 1.** *Spring 2015 Convention.* Pierre Ramkota, Pierre, South Dakota. Hosted by: South Dakota Optometric Society. To register, email Deb Mortenson at deb.mortenson@pie.midco.net.

May 2015

■ 2-3. *8th Annual Evidence Based Care in Optometry Conference.* Turf Valley Conference Center and Resort, Ellicott City, MD. Hosted by: Maryland Optometric Association & John Hopkins-Wilmer Eye Institute. To register, call Annie Phan at (410) 486-9662 or email aphan@marylandoptometry.org.

■ 15-17. *Arizona Optometric Association 2015 Spring Congress.* Hilton Tucson El Conquistador Golf & Tennis Resort, Tucson, AZ. Hosted by: Arizona Optometric Association. To register, go to: <http://arizona.aoa.org>.

June 2015

■ **5-7.** *June "Summer" Conference.* Harborside Hotel & Marina, Bar Harbor, ME. Hosted by: Maine Optometric Association. To register, call (207) 288-5033 or toll-free 800-328-5033.

■ **12-14.** *2015 Annual Meeting.* Myrtle Beach, SC. Hosted by: North Carolina State Optometric Society. To register, call Adrienne Drollette at (919) 977-6964 or email adrienne@nceyes.org.

■ **19-21.** *2015 VOA Annual Conference.* Hilton, McLean, VA. Hosted by: Virginia Optometric Association. To register, call Bo Keeney at (804) 643-0309.

■ **24-28.** *Optometry's Meeting 2015.* Washington State Convention Center, Seattle, WA. Hosted by: American Optometric Association and American Optometric Student Association. To register, go to: <http://optometrymeeting.org>.

To list your meeting, please send the details to:

Renee Buddle, Senior Associate Editor

Email: rbuddle@jobson.com

Phone: (610) 492-1005

For advertising opportunities contact:

Michele Barrett (215) 519-1414 or mbarrett@jobson.com

James Henne (610) 492-1017 or jhenne@jobson.com

Alcon Laboratories 13

Phone (800) 451-3937

Fax..... (817) 551-4352

Allergan, Inc..... 21

Phone (800) 347-4500

Bausch + Lomb 5, 23

.....43-46, 53, 59, 84

Phone (800) 323-0000

Fax..... (813) 975-7762

Carl Zeiss Meditec Inc. 60

Phone (877) 486-7473

Fax..... (925) 557-4101

CooperVision 83

Phone (800) 341-2020

HAI Laboratories 39

Phone (781) 862-9884

Fax..... (781) 860-7722

Keeler Instruments..... 19

Phone (800) 523-5620

Fax..... (610) 353-7814

Live Oak Bank..... 10

Phone (910) 796-1676

laura.petty@liveoakbank.com

www.liveoakbank.com/healthcare

Marchon 7

Phone (800) 645-1300

Fax..... (800) 544-1334

Menicon..... 15

Phone(800) MENICON

..... information@menicon.com

..... www.meniconamerica.com

NicOx, Inc.....24-25

Phone (214) 346-2913

..... www.nicox.com

ThromboGenics Inc. 9

Phone (732) 590-2901

Fax..... (866) 936-6676

Tomey..... 14

Phone (888) 449-4045

..... www.tomeyusa.com

US Ophthalmics....33, 35, 37

Phone (888) 334-4640

..... info@usophthalmic.com

..... www.usophthalmic.com

Vistakon2-3, 16-17

Phone (800) 874-5278

Fax..... (904) 443-1252

This advertiser index is published as a convenience and not as part of the advertising contract. Every care will be taken to index correctly. No allowance will be made for errors due to spelling, incorrect page number, or failure to insert.

Merchandise Offered



EYEDESIGNS®
 SPACE PLANNING INTERIOR DESIGN
 DISPLAY INNOVATION MANUFACTURING
PROFIT BY DESIGN
 WWW.EYEDESIGNS.COM
 800.346.8890



**SHOWCASE
 PRODUCT
 IN STYLE**
 opticaldisplays.com™

INFO@OPTICALDISPLAYS.COM TO REQUEST OUR
 CATALOG & DESIGN SERVICES
 CALL 610.489.7620

Merchandise Offered

www.eyewear4less.com
 EVERYDAY LOW PRICES - HUGE SELECTION
 "Per UOMO" FACTORY DIRECT ITALIAN EYEWEAR
 BRAND NAME OVERSTOCKS,
 CLOSE-OUTS & SPECIALS
 "YOUR PRACTICE YOUR PROFIT"
800-762-0480

Equipment For Sale

FOR SALE



HUMPHREY MATRIX 715 WITH PRINTER (\$8000)
ZEISS GDx VCC WITH SOFT CARRY CASE (\$8000)
SONOGAGE CORNEO-GAGE PLUS (\$500)

All in great condition
 Will sell separate as priced above or all three
 together as package \$15,000

CONTACT: Dr. Jill Barksdale
PHONE: 540-875-8036 or
EMAIL: jebarksdale113@hotmail.com

Products and Services



The key to making Professional Healthcare Practice Financing simple. Whether you are buying, starting, or updating your practice, Access Healthcare capital is here to help you with your financing needs with one common goal. We want to help you maximize your cash flow. Let us help you unleash your Entrepreneurial Spirit:

Easy App Up To \$250,000

- 100% Financing plus working capital
- Simplified Processing for loans up to \$350,000
- Partnership Buy-In Programs
- * Terms up to 15 years
- Application Only for equipment and technology purchases

www.accesshealthcarecapital.com • info@narxeye.com

Access Healthcare Capital • 1-888-727-4470 • P.O. Box 349, Gladwyne, PA 19035

**Place Your
 Ad Here!**

Toll free: **888-498-1460**

E-mail: **sales@kerhgroup.com**

Merchandise Offered



**INNOVATIVE DISPENSARY
PLANNING & DESIGN**
**WIDEST SELECTION ON
PREMIUM DISPLAY PRODUCTS**

0% FINANCING FOR 36 MONTHS*

* for well qualified applicants only

ESSILOR'S FRAME DISPLAYS GROUP
Innovative Dispensary Planning & Design
— Authentic Craftsmanship & Integrity
Visit the website to view examples of what Frame Displays can create for you, and schedule a free consultation with one of the design professionals.

1-877-274-9300

An Essilor Company



Equipment and Supplies

OPTINOMICS
Pretesting Solutions

It's What the Best
Pretest on!
(800) 522-2275
www.optinomics.com
sales@optinomics.com

NEW! Fixi-Tic™

- Simplifies administration of both accommodative and vergence facility testing
- Features a countdown timer with an audible tone which signal when the time has expired
- Improves accuracy of results

Search "15112" on Gulden's site to shop. Also, check out our 250+ other products. Follow @GuldenEye on Twitter.

GuldenOphthalmics
time saving tools
800-659-2250 www.guldenophthalmics.com



Targeting Optometrists?

CLASSIFIED ADVERTISING WORKS

Contact us today for classified advertising:

Toll free: 888.498.1460 • E-mail: sales@kerhgroup.com



Contact Lenses



National Lens

America's Leading Discount Lens Distributer

1-866-923-5600 Phone • 1-866-923-5601 Fax • www.national-lens.com

2014	LOW	LOWER	LOWEST	2014	LOW	LOWER	LOWEST
Johnson and Johnson	1 to 5	6 to 10	11 & OVER	Bausch & Lomb	1 to 5	6 to 10	11 & Over
ACUVUE OASYS	22.50	21.75	20.25	PUREVISION / PUREVISION HD	27.50	26.95	25.95
ACUVUE 2	16.00	15.75	15.50	SOFLENS 38	14.50	13.95	13.50
ACUVUE ADVANCE	18.25	17.75	17.50	SOFLENS ONE DAY 90 PACK	33.50	32.50	29.95
ACUVUE 1 DAY MOIST 30 PACK	18.95	18.50	17.95	SOFLENS 59	9.25	8.95	8.75
ACUVUE 1 DAY MOIST 90 PACK	41.95	40.95	39.90	BIOTRUE 90 PACK	48.95	48.50	47.50
NEW ACUVUE OASYS FOR ASTIGMATISM	24.95	24.75	23.95	Alcon	1 to 5	6 to 10	11 & Over
CooperVision	1 to 5	6 to 10	11 & Over	AIR OPTIX AQUA	25.75	24.95	22.95
AVAIRA	17.25	16.95	14.95	AIR OPTIX FOR ASTIGMATISM	36.50	35.95	32.95
BIOFINITY	24.50	22.50	20.50	AIR OPTIX MULTIFOCAL	42.95	42.50	41.95
BIOFINITY TORIC	36.00	34.00	32.00	AIR OPTIX NIGHT & DAY AQUA	41.25	39.95	38.95
BIOMEDICS XC, 38% & 55%	15.95	13.95	12.50	DAILIES AQUA COMFORT PLUS 90 PACK	37.95	36.95	35.99
BIOMEDICS PREMIER	15.95	13.95	13.50	O2 OPTIX	16.50	16.25	15.95
EXPRESSION OPAQUE-PLANO	25.95	24.95	23.95	FRESHLOOK COLORBLENDS 2 PACK	10.50	9.75	9.25
FREQUENCY 55% & ASPHERICS	14.95	13.95	11.95	NEW FRESHLOOK 1 DAY COLORS-PLANO ONLY	10.95	10.50	9.95
NEW PROCLEAR 8.6 & 8.2	19.95	18.95	17.95	Color	1 to 5	6 to 10	11 & Over
NEW PROCLEAR 1 DAY 90 PACK	37.95	37.50	35.95	IMPRESSIONS COLOR Available in Rx!	23.95	22.95	21.95

Please call for prices on Ophthalmic Lenses

We'll Meet or Beat Any Competitors Price on Any Stock Lens

Please call for a full product and price list

Free Standard Shipping (when available) • Same Day Shipping • We Do Not Backorder Lenses

Software

Take a closer look...
at Eyecom for your electronic health record needs!

tablet compliant
 share patient data securely
 over 25 years experience
 cloud-based access anytime, anywhere

Drummond 2011-2012
 >>> certified
 ONC-ATCB
 COMPLETE EHR ASSESSMENT

Eyecom³ EHR
 WEB-BASED OPTOMETRIC SOFTWARE

800.788.3356 www.eyecom3.com

QUIKEYES ONLINE
WEB-BASED OPTOMETRY EHR

- \$99 per month after low cost set-up fee
- Quick Set-Up and Easy to Use
- No Server Needed
- Corporate and Private OD practices
- 14 Day Free Demo Trial
- Users Eligible for 44K incentives

www.quikeyes.com

Contact us today
 for classified advertising:
 Toll free: **888-498-1460**
 E-mail: sales@kerhgroup.com

Professional Opportunities

WORCESTER

FT OD NEEDED

Busy practice with two ophthalmologists and two optometrists seeks FT optometrist. Saturdays and one late evening required. Competitive compensation and benefits.

Contact: Michele Rickert
Phone: 508-853-2020
Email: rickertmi@aol.com

Clinicas Del Camino Real seeks

Optometrist

Position requires doctorate degree or equivalent in Optometry and CA optometrist license. Salaried/full time position.

Submit resume & salary requirements to Liana Lucio - **llucio@clinicas.org** or fax to **805-659-3217**.

For details about this job go to www.clinicas.org

STAFF OPTOMETRIST

Bard Optical is a leading Midwest vision care organization in business for over 70 years and we are still growing. The company is based in Peoria, IL with 20 retail offices throughout the central Illinois area, as far north as Sterling and as far south as Jacksonville. Once again this year we were named to the Top 50 Optical Retailers in the United States by Vision Monday – currently ranking 37th. A progressive optometric staff is vital to the continued growth of our organization whose foundation is based on one-on-one patient service. We are currently accepting CV/resumes for optometrists focused on full scope primary medical patient care. The candidate must have an Illinois license with therapeutics. The practice includes (but is not limited to) general optometry, contact lenses, and geriatric care. Salaried, full-time positions are available with excellent growth programs and benefits. Some part-time opportunities may be available also. Please email your information to hr@bardoptical.com or fax to 309-693-9754. Mailing address if more convenient is Bard Optical, Attn: HR, 8309 N Knoxville Avenue, Peoria, IL 61615. Ask about opportunities within Bard Optical. *We have openings in several existing and new offices opening soon in central Illinois.*

Bard Optical is a proud Associate Member of the Illinois Optometric Association.



www.bardoptical.com

Continuing Education

31st Annual

Palm Beach Winter Seminar
 February 6th to 8th, 2015



www.PBCOA.org

PGA National Resort & Spa
 400 Avenue of the Champions
 Palm Beach Gardens, FL 33418

Featured Speakers:

Carlo Pelino, O.D., F.A.A.O.
 Kimberly Reed, O.D., F.A.A.O.

Classes include:

- *20 hours COPE approved CE including 8 hours TQ
- *Florida Jurisprudence
- *Medical Errors

Exhibit Hall:

*over 25 industry supporters

We're looking forward to seeing you!

Rooms are filling up fast, book now!

Conference registration www.pbcoa.org
 Room registration link
Tinyurl.com/2015PBWS

Practice For Sale

PRACTICE SALES & APPRAISAL

Expert Services for:

- ✓ **Buying or Selling a Practice**
- ✓ **Practice Appraisal**
- ✓ **Practice Financing**
- ✓ **Partner Buy-in or Buy-out**

Call for a Free Consultation
(800) 416-2055

www.TransitionConsultants.com



Practice Sales • Appraisals • Consulting
www.PracticeConsultants.com

**PRACTICES FOR SALE
 NATIONWIDE**

Visit us on the Web or call us to learn more about our company and the practices we have available.

info@PracticeConsultants.com

800-576-6935

www.PracticeConsultants.com

**OPTOMETRIC PRACTICE FOR SALE
 NORTHEASTERN PA**

Very Successful ongoing optometric practice for sale in Northeastern PA. The practice is grossing 600K/yr. This practice is one of a kind with a very large and broad patient base and large contact lens base. The practice services many vision care programs that lends to its success, along with a full complement of direct paying patients. I will be willing to work in the practice.

Serious replies only.

Email: resume6@kerhgroup.com

WITH COMPLETE NAME AND CONTACT INFO



**Do you have CE or
 CME Programs?**

CONTACT US TODAY
 FOR CLASSIFIED ADVERTISING
 Toll free: 888-498-1460
 E-mail: sales@kerhgroup.com



Do you have CE or
 CME Programs?

**CLASSIFIED
 ADVERTISING
 WORKS**

Contact us today for
 classified advertising:

Toll free: **888-498-1460**

E-mail: sales@kerhgroup.com





Size Matters

With the move to 27-gauge surgery, retinal specialists continue to push the limits of instrument miniaturization in the quest for safer and more precise outcomes.

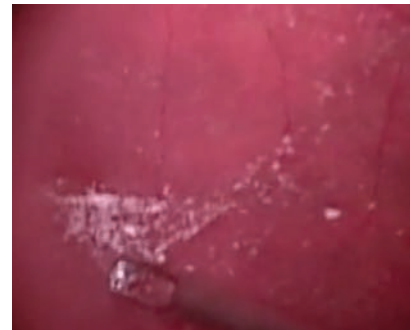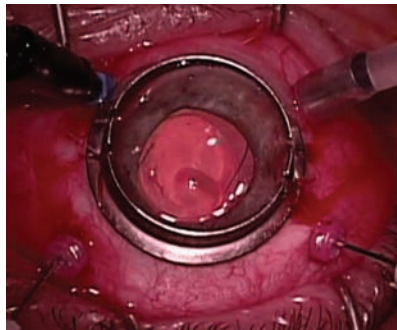
Retina surgery has historically been a high-risk proposition, given the delicate nature of the retina and the relative crudeness of instruments used. No retina surgery is undertaken without significant risk, and less than ideal outcomes are an eventuality even with the most skilled surgeons.

However, the evolution of retinal surgery instruments has greatly aided surgeons in ensuring better outcomes. The general trend is to decrease the size of the handheld instruments to produce less collateral tissue disruption and allow more precise tissue dissection.

Vitrectomies are the most commonly performed retinal surgeries in the United States, and require surgeons to insert instruments through scleral tunnel incisions. Commonly, three or four incisions (often called ports) are made. If fluid is injected into the vitreous, suturing of these incisions will be required.

Every scleral incision carries with it the risk of retinal detachment and infection. Decreasing the size of the incisions should decrease the risk of sclerotomy-related tears and infections, especially endophthalmitis—a rare but devastating complication.

The other major benefit that comes with the adoption of smaller instruments is an increased ability



Trocar insertion (left) and membrane peel (right) using 27-gauge instruments.

to dissect tissue. Smaller instruments allow for more precise placement and manipulation of the remarkably thin layers of the retina/vitreous interface. Dissection of preretinal membranes is the most difficult portion of a vitrectomy, and is also the stage when most surgical related complications happen.

Although trivial to the average observer, the decreased size of the 27-gauge vitrectomy tool can be a huge advantage over the traditionally larger 25-gauge instrument class—which, not long ago, was itself a pioneering advance over previous generations of instruments (20- and 23-gauge).

Complex Case, Smooth Sailing

In the accompanying video, Dr. Alan Franklin walks us through a vitrectomy in a patient with excessive diabetic fibrovascular proliferation throughout the retina. The video showcases the 27-gauge instrument's ability to aid in dissecting the vitreous and tenacious preretinal membranes from the

underlying mobile, detached retina. Another 27-gauge instrument is also then used to perform prophylactic panretinal photocoagulation with scleral indentation. A secondary benefit to the patient in this case: no sutures are needed at the sclerotomy site after the instruments are removed.

Due to the extensive manipulation of the retina in a case like this, postoperative retinal bleed or detachments are a concern. Close monitoring of the patient is needed in the post-op period while the patient uses topical steroids and antibiotics. Patients should be educated that visual fluctuation may be normal, but sudden or significant loss of vision should warrant an immediate evaluation.

Patients with this level of diabetic retinopathy are at high risk of future vision loss and need to be monitored closely. Risk factors for diabetic retinopathy progression should be reviewed by comanaging optometrists at follow-up visits; also encourage proper lifestyle maintenance. ■



To see a narrated video of 27-gauge vitrectomy, visit www.reviewofoptometry.com, or scan the QR code.

DOWNLOAD LAYAR APP
FOR INTERACTIVE EXPERIENCE



layar

INTERACTIVE PRINT

First 150 app downloads and completed forms will be entered into a drawing for FREE MEETING AND REGISTRATION VALUED AT \$495

SAVE THE DATE

REVIEW OF OPTOMETRY EDUCATIONAL MEETINGS OF CLINICAL EXCELLENCE

SAN DIEGO, CA

APRIL 10-12

OMNI SAN DIEGO HOTEL

675 L STREET SAN DIEGO, CA 92101



CE COURSE TOPICS:

- Management of Lid Margin Disease
- Innovations in Eye Care
- Glaucoma Management Insights
- Diagnostic Dilemmas and Solutions
- Emergency and Urgency Diagnosis and Treatment
- Anterior Segment Disease Diagnosis and Treatment
- Medical Management of Ocular Disease
- Comanagement of Cataract and Refractive Surgery
- Writing Oral Prescriptions

NEW 2-CREDIT AFTERNOON WORKSHOPS!!

Dry Eye Workshop • Glaucoma Workshop

FACULTY

Paul Karpecki, OD
Program Chair



Jill Autry, OD



Derek Cunningham, OD



Ben Gaddie, OD



FOR MORE INFORMATION:
WWW.REVIEWOFOPTOMETRY.COM



Up to
17 CE
Credits
(COPE approval pending)



Chalk it Up to Drug Use?

By Andrew S. Gurwood, OD

History

A 58-year-old white male presented for a comprehensive eye examination, with a chief complaint of blurred near vision in both eyes. He explained that his spectacles were old and that he simply required a new pair.

His systemic history was remarkable for both type 2 diabetes mellitus and hypertension, which were well controlled with metformin and lisinopril. Additional questioning uncovered a long history of substance abuse. His ocular history was non-contributory. He reported no known allergies of any kind.

Diagnostic Data

Best-corrected visual acuity measured 20/20 OU at distance and 20/40 OU at near. External examination was normal, with no evidence of afferent pupillary defect. Refraction revealed mild hyperopia with presbyopia that was correctable to 20/20 at distance and near.

Biomicroscopy showed normal anterior segment structures, with no rubeosis. IOP measured 16mm Hg OU. His cup-to-disc ratio measured 0.40 x 0.50 OU.

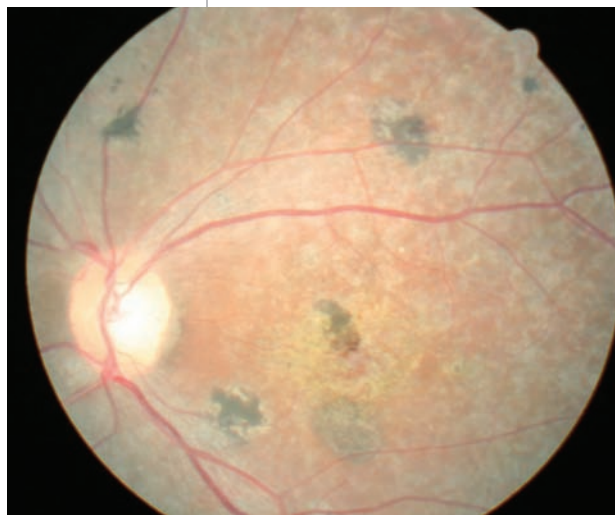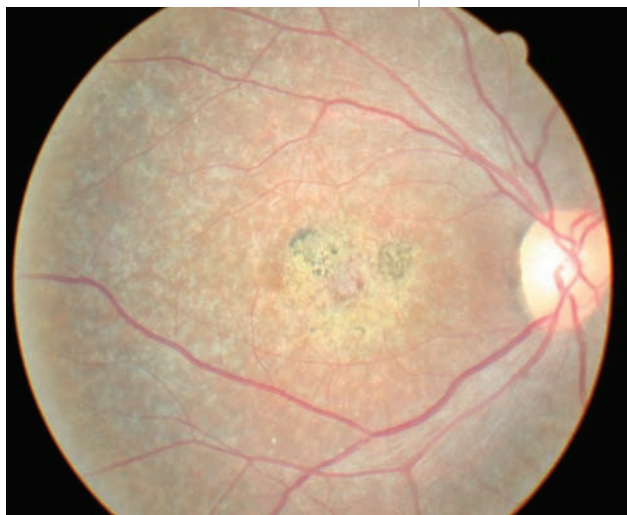The pertinent dilated fundus findings are illustrated in the photographs.

Your Diagnosis

How would you approach this case? Does this patient require any additional tests? What is your diagnosis? How would you manage this patient? What's the likely prognosis?

To find out, please visit *Review of Optometry Online*, www.reviewofoptometry.com. Click on the cover icon, and then click "Diagnostic Quiz" under this month's table of contents. ■

Thanks to David Lai, BSc, of Philadelphia for contributing to this case.



Our 58-year-old patient presented with a chief complaint of blurred vision in both eyes. What is the correct diagnosis?

Retina Quiz Answers (from page 65): 1) c; 2) d; 3) a; 4) d.

REVIEW OF OPTOMETRY (ISSN 0147-7633) IS PUBLISHED MONTHLY, 12 TIMES A YEAR BY JOBSON MEDICAL INFORMATION LLC, 100 AVENUE OF THE AMERICAS, NEW YORK, NY 10013-1678. PERIODICALS POSTAGE PAID AT NEW YORK, NY AND ADDITIONAL MAILING OFFICES. POSTMASTER: SEND ADDRESS CHANGES TO REVIEW OF OPTOMETRY, PO BOX 81, CONGERS, NY 10920-0081. SUBSCRIPTION PRICES: US: ONE YEAR \$56; TWO YEARS \$97, CANADA: ONE YEAR \$88, TWO YEARS \$160, INT'L: ONE YEAR \$209, TWO YEARS \$299. FOR SUBSCRIPTION INFORMATION CALL TOLL-FREE (877) 529-1746 (USA); OUTSIDE USA, CALL (845) 267-3065. OR EMAIL US AT REVOPATOMETRY@CAMBEYWEST.COM. PUBLICATIONS MAIL AGREEMENT NO: 40612608. CANADA RETURNS TO BE SENT TO BLEUCHIP INTERNATIONAL, P.O. BOX 25542, LONDON, ON N6C 6B2.

introducing
THE WORLD'S
FIRST
and
ONLY
family of
SILICONE HYDROGEL
1 DAY CONTACT LENSES



SINGLE VISION

ASTIGMATISM

PRESBYOPIA

For more information, contact your CooperVision sales representative or call Customer Service at 800-341-2020.



Discover Biotrue® ONEday Lenses

Made from HyperGel™, a bio-inspired material designed to work like the eye



Meets

oxygen level the open eye needs¹



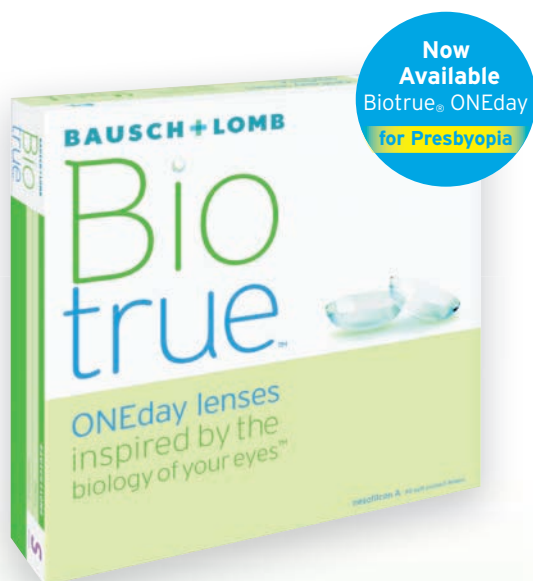Matches

water content of the cornea – 78%²



Mimics

lipid layer of the tear film³



Recommend comfortable vision throughout the day with **Biotrue ONEday** and **Biotrue ONEday** for Presbyopia.

For more information, call **1-800-828-9030**, contact your Sales Representative or visit **biotrue.com**

Distributed by Bausch + Lomb, a Division of Valeant Pharmaceuticals, North America LLC, Bridgewater, N.J. © 2014 Bausch & Lomb Incorporated. ®/™ are trademarks of Bausch & Lomb Incorporated or its affiliates. PNS07134 US/BPR/14/0013b

REFERENCE: **1.** Brennan NA. A Model of Oxygen Flux Through Contact Lenses, *Cornea* 20(1):104-108, 2001. **2.** Bergmanson J. *Clinical Ocular Anatomy and Physiology*, 14th ed. Houston, Texas: Texas Eye Research and Technology Center; 2007. **3.** Twenty-two subjects participated in a randomized, double-masked, contralateral eye study to evaluate water loss of Biotrue® ONEday, 1-Day ACUVUE MOIST, and 1-Day ACUVUE TruEye. After 4, 8, 12, and 16 hours of wear, lenses were removed and immediately weighed (wet weight). The lenses were then completely dried and reweighed (dry weight). The percent water loss was then calculated for each lens from the wet and dry weights.

BAUSCH + LOMB
See better. Live better.