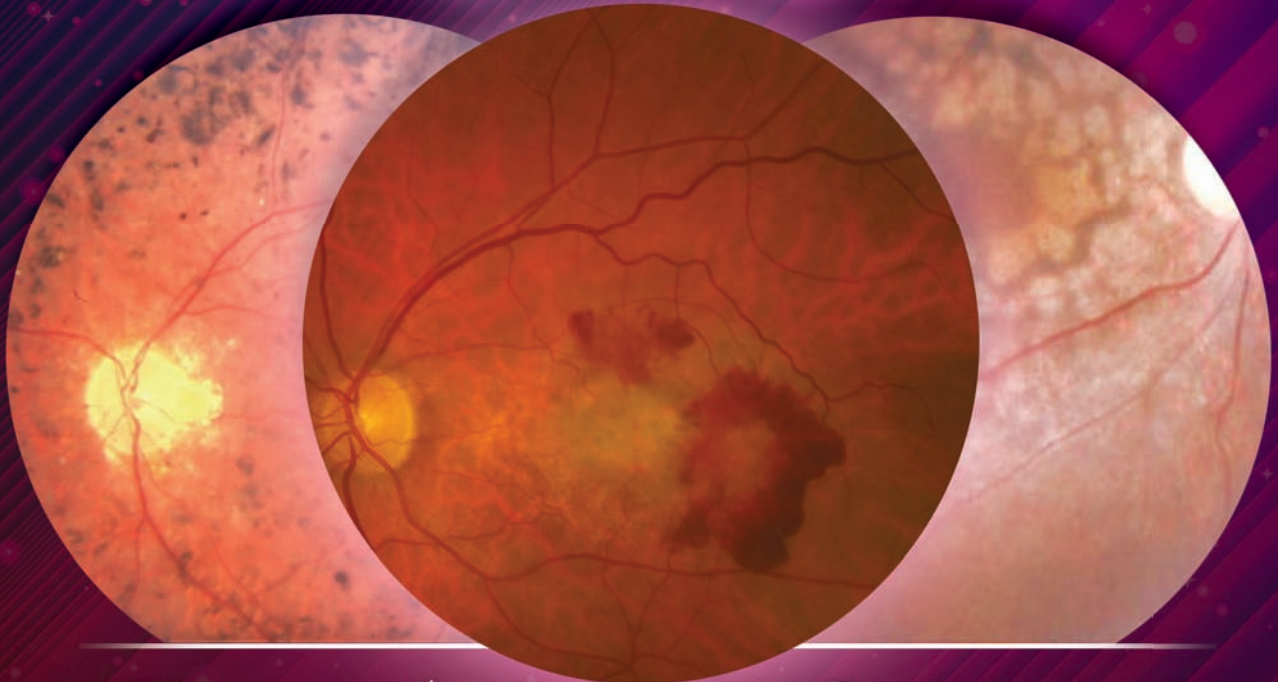


SUPPLEMENT TO

NOVEMBER 2014

# REVIEW<sup>®</sup> OF OPTOMETRY

[www.reviewofoptometry.com](http://www.reviewofoptometry.com)



## The 11<sup>th</sup> Annual Guide to **RETINAL DISEASE** A Focus on Clinical Research

This year, our experts review and summarize the landmark trials that most directly influenced the course of retinal disease management during the last three decades.

### **Age-Related Macular Degeneration**

*Steven Ferrucci, OD, FAAO*

### **Genetic Retinal Disease**

*Charles M. Wormington, OD, PhD, FAAO*

### **Diabetic Eye Disease**

*Carlo J. Pelino, OD, FAAO  
Joseph J. Pizzimenti, OD, FAAO*

### **Retinal Venous Occlusion**

*Julie Hutchinson McGinnis, OD, FAAO  
Andrew S. Gurwood, OD, FAAO, Dipl. (Supplement Editor)*



# SYMPTOMATIC VITREOMACULAR ADHESION (VMA)

SYMPTOMATIC VMA MAY LEAD TO VISUAL IMPAIRMENT FOR YOUR PATIENTS<sup>1-3</sup>

## IDENTIFY

Recognize metamorphopsia as a key sign of symptomatic VMA and utilize OCT scans to confirm vitreomacular traction.

## REFER

Because symptomatic VMA is a progressive condition that may lead to a loss of vision, your partnering retina specialist can determine if treatment is necessary.<sup>1-3</sup>

THE STEPS YOU TAKE TODAY MAY MAKE A DIFFERENCE  
FOR YOUR PATIENTS TOMORROW

 ThromboGenics®

© 2014 ThromboGenics, Inc. All rights reserved. ThromboGenics, Inc., 101 Wood Avenue South, Suite 610, Iselin, NJ 08830 – USA. THROMBOGENICS and the THROMBOGENICS logo are trademarks or registered trademarks of ThromboGenics NV. 10/14 OCRVMA0220

**References:** 1. Sonmez K, Capone A, Trese M, et al. Vitreomacular traction syndrome: impact of anatomical configuration on anatomical and visual outcomes. *Retina*. 2008;28:1207-1214. 2. Hikichi T, Yoshida A, Trempe CL. Course of vitreomacular traction syndrome. *Am J Ophthalmol*. 1995;119(1):55-56. 3. Stalmans P, Lescauwaet B, Blot K. A retrospective cohort study in patients with diseases of the vitreomacular interface (ReCoVit). Poster presented at: The Association for Research in Vision and Ophthalmology (ARVO) 2014 Annual Meeting; May 4-8, 2014; Orlando, Florida.



# Age-Related Macular Degeneration

By Steven Ferrucci, OD, FAAO

OVER THE PAST decade or more, many significant advances have been made in the treatment of age-related macular degeneration (AMD). When I was a resident from 1996 to 1997, we could offer very little hope for our AMD patients. All too often, we were forced to look on idly as they suffered devastating vision loss. Now, with extensive research into the protective benefits of vitamin supplementation and the ability to treat neovascularization with anti-VEGF therapy, we can offer our patients notably better quality of life. Today, we can help preserve existing visual function and, in some cases, even partially restore lost vision.

During the last 25 years, multiple landmark trials on AMD diagnosis and management have been published. Many of these studies are best known and identified by clever acronyms (e.g., AREDS). Here, we'll review some of the most important clinical data documented in these major studies and will show how these findings can most effectively translate into improved patient care.

## Early Research

• **MPS.** One of the very first trials that evaluated potential treatments for choroidal neovascularization (CNV) was the Macular Photocoagulation Study (MPS).<sup>1</sup> It was published in 1991 and consisted of a series of three separate clinical tests designed to evaluate the role of laser photocoagulation in wet AMD patients.

MPS results indicated that eyes with subfoveal CNV secondary to AMD benefited more from laser treatment than observation.<sup>1</sup> Eyes receiving laser therapy immedi-

ately lost more vision than observation eyes; however, at 12-month follow-up, treated eyes demonstrated better acuity than observation eyes.

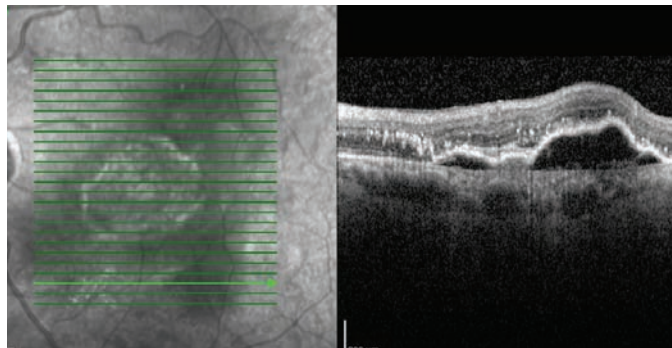
Thus, the long-term benefit

of improved visual acuity far outweighed the short-term vision loss caused by laser treatment.<sup>1</sup>

While MPS researchers noted that laser therapy certainly was not the most ideal treatment modality, it was shown to be at least somewhat more effective at preserving visual acuity in wet AMD patients than observation alone.<sup>1</sup>

• **TAP and VIP.** Nearly a decade after MPS was published, the Treatment of Age-Related Macular Degeneration with Photodynamic Therapy (TAP) and Verteporfin in Photodynamic Therapy (VIP) studies evaluated the role of photodynamic therapy in patients with CNV secondary to wet AMD.<sup>2,3</sup> The treatment used in these studies consisted of an intravenous injection of verteporfin, a light-activated drug. After infused verteporfin reaches the eye, it is activated by a laser source, thereby treating the CNV while reducing thermal damage to surrounding tissues.

The cumulative results of TAP and VIP confirmed that patients with classic CNV lesions lost less vision following treatment than untreated controls. (Classic lesions are those that tend to leak early and have well-defined borders, compared to occult lesions.) At the two-year TAP follow-up, 53%



On spectral-domain optical coherence tomography, we documented the presence of fluid associated with wet AMD.

of treated eyes lost fewer than 15 Snellen letters, compared to 38% of treated eyes.<sup>4</sup> However, it should be noted that patients with minimally classic lesions did not respond nearly as well to photodynamic therapy.<sup>4</sup>

Although intravitreal anti-VEGF injection largely has supplanted photodynamic therapy, it remains an important milestone in the history of AMD treatment.

• **CAPT.** One of the most comprehensive studies that evaluated laser as a potential treatment for AMD was the National Eye Institute-funded Complications of Age-Related Macular Degeneration Prevention Trial (CAPT).<sup>5</sup> Published in 2006, this multi-centered study was designed to determine if low-intensity laser treatment of eyes with existing drusen would prevent long-term vision loss associated with wet AMD.

The CAPT researchers administered unilateral laser treatment to more than 1,000 AMD patients with bilateral drusen formation. After five years of follow-up, they determined that laser yielded no clinically significant benefit on visual acuity compared to untreated contralateral eyes. In fact, 20.5% of treated eyes and 20.5% of observed eyes lost at least three

Snellen lines from baseline acuity measurements.<sup>5</sup> Further, the cumulative rate of CNV formation was 13.3 % for both treated and observed eyes.<sup>5</sup>

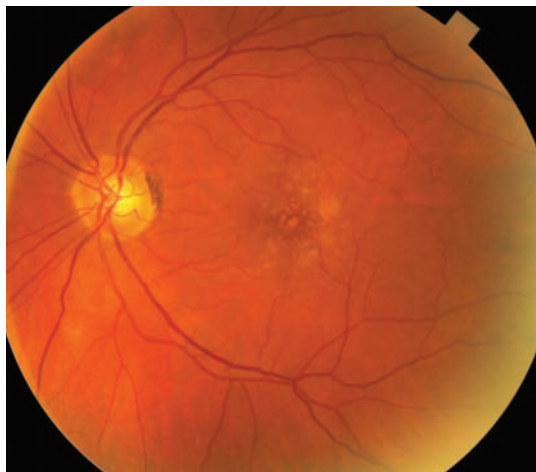### Vitamin Studies

• **AREDS.** The original Age-Related Eye Disease Study (AREDS) was one of the first large-scale clinical trials that evaluated whether high-dose antioxidant supplementation slowed or halted AMD progression.<sup>6</sup> The results showed that the AREDS formulation—comprised of 15mg beta carotene, 500mg vitamin C, 400IU vitamin E, 80mg zinc and 2mg copper—lowered the risk of progression to advanced AMD by 25% in patients with intermediate or advanced macular degeneration.<sup>6</sup>

• **AREDS 2.** The second AREDS study evaluated whether the addition of 10mg lutein, 2mg zeaxanthin and 1,000mg omega-3s offered greater protection against AMD progression than the original AREDS formula alone.<sup>7</sup> Additionally, the AREDS 2 researchers removed beta carotene from the original formula, as well as reduced the amount of zinc.

This multicenter trial was conducted at 82 clinical sites in the US from 2006 to 2012, and included 4,203 participants aged 50 to 85 years. The AREDS 2 participants consented to either take the original AREDS formulation or a randomly assigned variation. The principal outcome measurement was progression to advanced AMD (i.e., either CNV or central geographic atrophy). Progression of lens opacity and/or necessity of cataract surgery served as a secondary outcome.

Data from the primary analysis was first published in May 2013,



This patient with stage 3 (i.e., moderate) dry age-related macular degeneration would be an ideal candidate for supplementation with an AREDS 2-formulated vitamin.

and indicated that the addition of lutein, zeaxanthin and omega-3 fatty acids to the original AREDS formulation did not further reduce the risk of progression to advanced AMD.<sup>7</sup> However, because beta carotene supplementation has been associated with an increased risk of lung cancer in former smokers, the researchers determined that lutein with zeaxanthin are appropriate carotenoid substitutes in the formulation.<sup>7</sup>

The comparison of low-dose vs. high-dose zinc showed no evidence of a statistically significant effect, so a definitive clinical recommendation cannot be made.<sup>7</sup> Also, daily lutein and zeaxanthin supplementation had no statistically significant effect on cataract surgery rates or opacity-related vision loss.

However, upon deeper analysis, it seems that lutein and zeaxanthin have a more positive effect than first noted. The researchers determined that the addition of lutein and zeaxanthin to the original formula decreased the incidence of disease progression by 10%.

Further, if the beta carotene was removed and replaced with lutein and zeaxanthin, the risk reduction

increased to 18%. Lastly, those patients with the lowest quintile of dietary lutein and zeaxanthin intake experienced the greatest reduction in disease progression when taking supplemental lutein and zeaxanthin.<sup>7</sup> So, based on these findings, it seems clear that it is beneficial to replace beta carotene in the original AREDS formulation with 10mg lutein and 2mg zeaxanthin.

### Anti-VEGF Trials

• **VISION.** In December 2004, the anti-VEGF agent Macugen (pegaptanib sodium, Valeant) secured FDA approval for the treatment of neovascular AMD. The VEGF Inhibition Study in Ocular Neovascularization (VISION) showed that 70% of patients who received a series of intravitreal Macugen injections lost fewer than 15 letters of acuity vs. just 55% of controls.<sup>8</sup> Macugen also reduced the risk of severe vision loss by more than 50%. Further, 33% of treated patients maintained or gained acuity after two years of injections vs. just 23% of untreated patients.<sup>8</sup>

VISION researchers recommended injection every six weeks for two years.<sup>8</sup> Over that period, Macugen appeared to be relatively safe, with few adverse events (i.e., mild anterior chamber reaction). More serious events, such as endophthalmitis, traumatic lens injury and retinal detachment were very rare.<sup>8</sup> However, following the introduction of both Lucentis (ranibizumab, Genentech/Roche) and Avastin (bevacizumab, Genentech/Roche), Macugen quickly lost its standing as the anti-VEGF agent of choice for the treatment of wet AMD.

• **ANCHOR.** In the summer

of 2006, Lucentis received FDA approval for the treatment of wet AMD. Early studies of Lucentis showed an actual improvement in visual acuity following treatment—the first wet AMD study to do so.<sup>8,9</sup>

In the Anti-VEGF Antibody for the Treatment of Predominantly Classic Choroidal Neovascularization in AMD (ANCHOR) study, researchers evaluated 423 patients with predominantly classic CNV. At 12-month follow-up, 94% of patients who received serial Lucentis injections remained stable, with a mean acuity loss of fewer than 15 Snellen letters.<sup>8</sup>

Impressively, more than one-third of the patients improved by 15 or more letters from baseline.<sup>9</sup> ANCHOR researchers recommended intravitreal injection every four weeks for two years.

• **MARINA.** The Minimally Classic/Occult Trial of the Anti-VEGF Antibody Ranibizumab in the Treatment of Neovascular Age-Related Macular Degeneration (MARINA) was the second study to evaluate anti-VEGF therapy on occult lesions.<sup>10</sup> Researchers documented findings that were similar, but slightly less impressive, than those published in the ANCHOR study.<sup>10</sup>

• **PRONTO.** In 2007, one research group evaluated whether adjusting the dosing schedule of Lucentis (one injection every four weeks) could affect treatment results.<sup>11</sup> In the two-year Prospective Optical Coherence Tomography Imaging of Patients with Neovascular Age-Related Macular Degeneration Treated with Intravitreal Lucentis (PRONTO) study, participants received three consecutive monthly injections of Lucentis as a loading dose, followed by additional

treatments if there was a change in optical coherence tomography (OCT) appearance or a new hemorrhage.

At 12 months, mean acuity in the treated group improved by nine letters, with an average central retinal thickness decrease of 178 $\mu$ m.<sup>3</sup> Acuity improved by 15 letters or more in 35% of patients, with an average of 5.6 injections over a 12-month period.<sup>11</sup>

Following the publication of these results, most retinal specialists have adopted an injection schedule similar to that employed by PRONTO researchers—three consecutive monthly injections as a loading dose, followed by individual treatment based on clinical findings.<sup>11</sup>

• **SANA.** The Systemic Avastin for Neovascular Age-Related Macular Degeneration (SANA) study was the first trial that analyzed the clinical efficacy of Avastin for the treatment of CNV.<sup>12</sup>

The researchers administered systemic (*not* intravitreal) Avastin to nine wet AMD patients, and determined that the drug was well tolerated and yielded improved visual acuity, optical coherence tomography results and fluorescein angiography outcomes in all subjects.<sup>12</sup>

Considering the favorable results of systemic Avastin use, surgeons began administering intravitreal Avastin off-label for the treatment of wet AMD (*see “Avastin: The Off-Label Alternative,” below*). It should be noted that due to the lack of a large, multicenter, controlled study, Avastin’s safety profile and administration schedule is less substantiated than those of Lucentis.

Many published reports—as well as clinical experience—indicate that it is a very effective agent for the treatment of wet AMD.<sup>12,13</sup> Nonetheless, all patients must be informed that intravitreal Avastin use for AMD is an off-label application that’s not approved by the FDA. Similarly to Lucentis, most retinal specialists advocate one Avastin injection per month for three months, then PRN retreatment based upon clinical, OCT or fluorescein angiography findings.

• **CATT.** In 2007, officials from the National Eye Institute and National Institutes of Health announced that they would conduct a two-year study to evaluate the relative safety and efficacy of Avastin and Lucentis in the Comparison of Age-Related Macular Degeneration Treatment Trials (CATT).<sup>13</sup> The researchers intended to determine if Avastin

### Avastin: The Off-Label Alternative

Avastin (bevacizumab, Genentech/Roche) is a full-length, recombinant, humanized, monoclonal vascular endothelial growth factor antibody. The drug is not FDA approved for the treatment of AMD, but is available as a systemic medication for metastatic colorectal cancer and certain lung cancers. Avastin is essentially the parent drug of Lucentis—but researchers initially believed that, due to its large molecular size, it would be unable to penetrate the retina. Therefore, it was genetically engineered to be about one-third the size of the original molecule and was entered into clinical trials for the treatment of neovascular AMD. While waiting for Lucentis to secure approval, some retinal specialists began to evaluate Avastin’s role in the treatment of neovascular AMD, and discovered that it could slow, stop or even reverse vision loss.

Even after the approval of Lucentis, many eye care providers have preferred to treat their wet AMD patients with compounded intravitreal Avastin because of its significantly smaller price tag. Specifically, CATT researchers determined that treating patients with Lucentis PRN cost \$13,800 per year vs. just \$385 per year for PRN Avastin.<sup>13</sup>



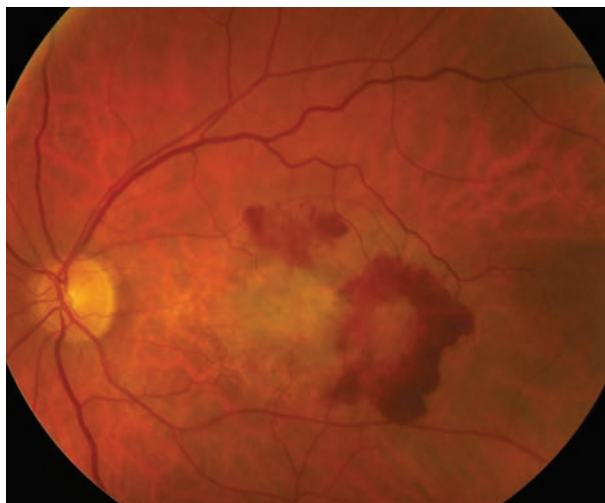and Lucentis were clinically equivalent for the treatment of wet AMD.

CATT researchers randomly assigned more than 1,200 patients to receive Avastin or Lucentis, either on a monthly or PRN basis.<sup>13</sup> The results indicated that patients who received monthly Avastin injections gained 8.0 letters vs. 8.5 letters in those who received monthly Lucentis.<sup>13</sup>

Further, patients who received PRN Avastin injections gained 5.9 letters vs. 6.8 letters in those who received PRN Lucentis.<sup>13</sup> Other relevant findings included slightly better anatomic results with Lucentis, such as a greater mean decrease in central retinal thickness, as well as a higher rate of serious systemic adverse events following Avastin administration (24.1% vs. 19.0% for Lucentis).<sup>13</sup>

In short, however, the CATT researchers determined that Avastin and Lucentis demonstrated clinically equivalent effects on visual acuity when administered in accordance with the same dosing schedule. Thus, due to the substantial cost savings with similar results, the majority of clinicians have accepted Avastin as the primary treatment for wet AMD patients, with Lucentis reserved for those who do not respond favorably to Avastin.

• **VIEW 1 and 2.** Eylea (afibercept, Regeneron) is the latest FDA-approved agent for the treatment of neovascular AMD. Two similarly designed, Phase III studies—VEGF Trap-eye: Investigation of Efficacy and Safety in Wet AMD 1 and 2 (VIEW 1 and 2)—compared monthly and bimonthly dosing of intravitreal aflibercept with monthly Lucentis for wet AMD.<sup>14</sup>



This patient presented with wet AMD. We referred him to a retinal specialist to initiate anti-VEGF therapy.

Essentially, VIEW 1 and 2 indicated that bimonthly Eylea administration was clinically equivalent to monthly injections of Lucentis.<sup>14</sup> More specifically, approximately 95% of Eylea patients exhibited stable vision during a 52-week evaluation period vs. 94% for Lucentis patients. Further, mean change in best-corrected acuity documented in all Eylea treatment groups was within 0.5 letters of that documented in all Lucentis treatment groups. Ocular and systemic adverse events were similar in all treatment groups, as well.

Based on these findings, Eylea secured FDA approval for wet AMD in November 2011, and is indicated for bimonthly dosing.

The data collected from these studies have helped delay or prevent devastating vision loss in hundreds of thousands of wet AMD patients. While the trials mentioned were among the most groundbreaking, many others also were instrumental in the evolution of AMD treatment.

This journey will continue, however, with many new studies evaluating such considerations as the

genetics of AMD, intravitreal injections of new drugs and novel sustained-release delivery mechanisms for current agents. ■

*Dr. Ferrucci is chief of optometry and residency director at the Sepulveda VA Ambulatory Care Center and Nursing Home in North Hills, Calif. He's also a professor at the Southern California College of Optometry at Marshall B. Ketchum University in Fullerton, Calif.*

1. Macular Photocoagulation Study Group: Laser photocoagulation of subfoveal neovascular lesions in age-related macular degeneration. Results of a randomized trial. *Arch Ophthalmol.* 1991 Sep;109(9):1220-31.

2. Treatment of age-related macular degeneration with photodynamic therapy (TAP) Study Group. Photodynamic therapy of subfoveal choroidal neovascularization in age-related macular degeneration with verteporfin: one-year results of 2 randomized clinical trials—TAP report. *Arch Ophthalmol.* 1999 Oct;117(10):1329-45.

3. Treatment of age-related macular degeneration with photodynamic therapy (TAP) Study Group. Verteporfin therapy of subfoveal choroidal neovascularization in age-related macular degeneration: two-year results of a randomized clinical trial including lesions with occult with no classic choroidal neovascularization—verteporfin in photodynamic therapy report 2. *Am J Ophthalmol.* 2001 May;131(5):541-60.

4. Bressler NM; Treatment of Age-Related Macular Degeneration with Photodynamic Therapy (TAP) Study Group. Photodynamic Therapy of Subfoveal Choroidal Neovascularization in Age-Related Macular Degeneration with Verteporfin: Two Year Results—TAP report number 2. *Arch Ophthalmol.* 2001 Feb;119(2):198-207.

5. Complications of Age-Related Macular Degeneration Prevention Trial Research Group. Laser treatment in patients with bilateral large drusen: the complications of age-related macular degeneration-prevention trial. *Ophthalmology.* 2006 Nov;113(11):1974-86.

6. Age-Related Eye Disease Study Research Group. A randomized, placebo-controlled, clinical trial of high-dose supplementation with vitamins C and E, beta-carotene, and zinc for age-related macular degeneration and vision loss: AREDS report no. 8. *Arch Ophthalmol.* 2001 Oct;119(10):1417-36.

7. Age-Related Eye Disease Study 2 Research Group. Lutein + zeaxanthin and omega-3 fatty acids for age-related macular degeneration: the Age-Related Eye Disease Study 2 (AREDS 2) randomized clinical trial. *JAMA.* 2013 May 15;309(19):2005-15.

8. Gragoudas ES, Adamis AP, Cunningham ET Jr, et al. Pegaptanib for neovascular age-related macular degeneration. *N Engl J Med.* 2004 Dec 30;351(27):2805-16.

9. Brown DM, Kaiser PK, Michels M, et al. Ranibizumab versus verteporfin for neovascular age-related macular degeneration. *N Engl J Med.* 2006 Oct 5;355(14):1432-44.

10. Rosenfeld PJ, Brown DM, Heier JS, et al. Ranibizumab for neovascular age-related macular degeneration. *N Engl J Med.* 2006 Oct 5;355(14):1419-31.

11. Fung AE, Rosenfeld PJ, Dubovy SR, et al. An optical coherence tomography-guided, variable dosing regimen with intravitreal ranibizumab (Lucentis) for neovascular age-related macular degeneration. *Am J Ophthalmol.* 2007 Apr;143(4):566-83.

12. Michels S, Rosenfeld PJ, Puliafito CA, et al. Systemic bevacizumab (Avastin) therapy for neovascular age-related macular degeneration. *Ophthalmology.* 2005 Jun;112(6):1035-47.

13. The CATT Research Group. Ranibizumab and bevacizumab for neovascular age-related macular degeneration. *N Engl J Med.* 2011 May 19;364(20):1897-908.

14. Heier JS, Brown DM, Chong V. Intravitreal aflibercept (VEGF trap-eye) in wet age-related macular degeneration. *Ophthalmology.* 2012 Dec;119(12):2537-48.

# Diabetic Eye Disease

By Carlo J. Pelino, OD, FAAO, and Joseph J. Pizzimenti, OD, FAAO

**DIABETIC RETINOPATHY (DR)** is the leading cause of blindness among adults living in the western world. Proliferative DR (PDR) is characterized by new vessel formation in the retina and at the level of the optic disc that results from hypoxia, microangiopathy and capillary occlusion. In addition to PDR, associated diabetic macular edema (DME) and tractional retinal detachment may result in severe vision loss.

As the number of people living with type 2 diabetes mellitus (DM) increases in proportion with higher overall levels of obesity, eye care providers will diagnose and manage more cases of DR and DME than ever before. This article will review how research from more than a dozen landmark clinical trials helped shape the way in which we currently treat the most visually devastating forms of diabetic eye disease.

## NPDR Treatment

Evidence of nonproliferative diabetic retinopathy (NPDR) is of tremendous significance to eye care providers, because it clinically signifies that retinal changes are occurring secondary to inadequate glucose control. If NPDR is unmanaged in patients with poor systemic control, the likelihood of progression to PDR increases significantly.

• **ETDRS.** The Early Treatment Diabetic Retinopathy Study (ETDRS) showed that patients with mild NPDR have a 5% risk of progressing to PDR within one year following diagnosis, and 15% risk of progressing to high-risk PDR (neovascularization of the disc or neovascularization elsewhere with vitreous hemorrhage) within five

years.<sup>1-3</sup> Additionally, the ETDRS researchers also determined that the stage of NPDR at the time of initial diagnosis should largely dictate the patient's follow-up and/or treatment schedule.

• **DCCT.** Improved systemic control is essential for proper NPDR management. The Diabetes Control and Complications Trial (DCCT) research group showed that intensive glycemic control involving multiple, daily blood sugar measurements; nutritional counseling; and medical evaluations every three months with gly-

cosylated hemoglobin evaluation decreased the risk of retinopathy development and progression.<sup>4</sup>

## PDR Treatment

Cases of PDR usually involve panretinal laser photocoagulation (PRP) surgery to seal leaking vessels and prevent neovascularization. Fluorescein angiography can be used to visualize the perfusion status of the retina and identify whether macular edema coexists. This is important because focal laser treatment is used to clear macular edema before photocoag-

## Understanding DR: Research on its Pathogenesis

Most individuals with diabetes develop some degree of retinopathy.<sup>21,22</sup> DR results from biochemical processes that damage vessels, alter retinal blood flow and degrade the retina's nutritional supply. As the highly vascular tissue becomes undernourished and ischemic, its neuronal and vascular elements break down and cause vascular distortions, leakage, intraretinal bleeding and fluid accumulation. DR inhibits retinal capillary function first, then it affects larger vessels.<sup>5,23,24</sup>

The exact cause of microvascular complications associated with DM is unknown.<sup>5,23</sup> Supportive capillary pericyte loss is an early histologic finding associated with DR. It induces leakage and precipitates capillary endothelial cell dysfunction.<sup>5,23</sup> Researchers believe that excess glucose contained within the retinal capillary leads to the production of potentially harmful biochemicals, such as vascular endothelial growth factor (VEGF), protein kinase C (PKC) and advanced glycation end-products (AGEs), which alter capillary pericyte integrity.<sup>5,25</sup>

The production of reactive oxygen species (ROS) likely is the unifying mechanism behind the pathological pathways triggered by hyperglycemia.<sup>26</sup> AGEs appear to play a central role in this process. Hyperglycemia promotes microvascular damage via an influx of glucose and other sugars through the polyol pathway, increased intracellular AGE formation, and interaction between AGEs and their receptors (termed RAGEs). This, in turn, causes intracellular signaling and subsequent cell function disruption. At the extracellular level, soluble RAGEs in plasma are implicated in diffuse micro- and macrovascular damage. Through the actions of ROS, AGE accumulation leads to vessel thickening, hypertension, endothelial dysfunction and loss of pericytes. AGEs also reduce platelet survival and increase aggregation, fostering a pro-coagulant state, causing ischemia and the development of growth factors. These processes result in angiogenesis and neovascularization. Thus, the roles of AGEs may help explain the clinical link between micro- and macrovascular disease and diabetes.<sup>26</sup>

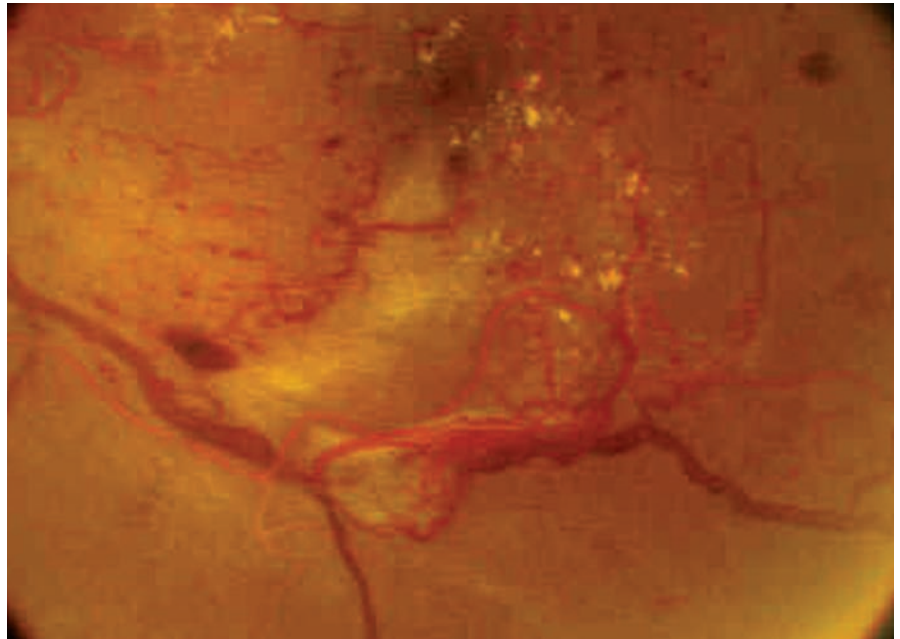
Capillary out-pouchings, called microaneurysms, frequently are the earliest clinically detectable signs of DR. Over time, poor circulatory perfusion weakens the capillary walls, resulting in bulging, leaking or scarring. Subsequently, affected individuals experience tissue ischemia and angiogenic growth factor upregulation and release. These processes foster new blood vessel formation (neovascularization) and increased vascular permeability, which cause retinal edema.<sup>23,27,28</sup>

When leakage from the perifoveal vessels affects the area centralis (fovea), patients develop diabetic macular edema (DME)—one of the most common causes of central vision loss and decreased quality of life in American adults.<sup>29,30</sup>

ulation is indicated in patients with concomitant macular edema and PDR.<sup>5</sup> In PDR, weaker blood vessels can rupture, scar, compromise healthy retinal tissue function and induce tractional retinal detachment.

• **DRS.** The Diabetic Retinopathy Study (DRS) indicated that pan-retinal laser photocoagulation reduced the incidence of severe vision loss (i.e., 5/200 or worse) in 60% of PDR patients.<sup>6</sup> PRP treatment is not without its consequences, however. The retinal tissue scarring inherent in thermal laser photocoagulation may cause reduced contrast sensitivity, poor dark adaptation and visual field loss. Intravitreal injections of anti-VEGF agents (e.g., pegaptanib, bevacizumab, ranibizumab and aflibercept), have proven to be effective as first-line or adjunctive proliferative diabetic retinopathy treatments.<sup>7</sup>

• **DRVS.** As PDR develops, it scaffolds across a thickened posterior vitreous cortex. Consequent posterior vitreous cortex shrinkage leads to the development of preretinal hemorrhages, vitreous hemorrhages and tractional retinal detachments. In some cases of PDR, three-port pars plana vitrectomy surgery is performed. Indications for vitrectomy include a vitreous hemorrhage that blocks the view of the retina, dense premacular hemorrhage, com-



Intensive control of blood sugar, blood pressure and serum lipids may prevent or reduce complications of diabetic retinopathy, as seen in this patient.

plicated retinal detachment and severe neovascular proliferation that's non-responsive to laser.

The Diabetic Retinopathy Vitrectomy Study (DRVS) results showed that early vitrectomy was beneficial in restoring and preserving vision in patients with PDR who presented either with or without associated vitreous hemorrhage.<sup>8</sup>

### Conventional Laser for DME

The most common cause of functional visual loss (worse than 20/40) in patients with DR is DME—specifically, clinically significant macular edema (CSME).<sup>9</sup> So,

it's essential to treat CSME as soon as possible to prevent irreversible functional vision loss.

• **Wisconsin study.** Early results from the 1984 Wisconsin Epidemiologic Study of Diabetic Retinopathy suggested that laser photocoagulation might slow the progression of DME.<sup>9</sup> Focal or grid laser photocoagulation yields coagulation necrosis—the arrest of vessel leakage by heat-induced closure. The strategy for treating macular edema with laser depends on both the type and extent of vessel leakage. Even today, some clinicians still regard laser photocoagulation as the “gold standard” treatment for diabetic macular edema.

If the edema is due to leakage from specific microaneurysms, the offending vessels are treated directly with focal laser photocoagulation. In cases where the foci of leakage are nonspecific, however, grid laser treatment is indicated. In this procedure, medium-intensity burns (100µm to 200µm) are

## Glucose Control and DR

The Diabetes Control and Complications Trial (DCCT) and the United Kingdom Prospective Diabetes Study (UKPDS) showed that intensive control of blood sugar, blood pressure and serum lipids may prevent DR or reduce complications associated with DR, including DME.<sup>4,31</sup> DCCT researchers clearly documented that tight control of blood sugar and a glycosylated hemoglobin [HbA1c] of less than 7% was associated with a lower incidence of DR. Additionally, both studies indicated that improved glucose control significantly reduced the incidence of severe vitreal hemorrhage and proliferative retinopathy, as well as limited the extent of renal disease and failure.



placed one burn-diameter apart, covering the affected area. Focal laser treatment is intended to close the leaking microaneurysms, while grid laser is used to treat more diffuse edema.<sup>3,9</sup>

The goal of laser treatment for DME is not to improve vision, but to slow or prevent central visual loss secondary to chronic edema and resultant tissue damage.<sup>3</sup> It is worth noting that a secondary ETDRS report published in 1991 indicated that focal or grid laser photocoagulation reduced the risk of moderate visual loss due to clinically significant macular edema by 50%.<sup>10</sup>

### Pharmacologic Treatments for DME

Although laser therapy may slow DME progression, it does not often yield visual gain. Thus, intravitreal injections of anti-VEGF agents or steroids currently are used either alone or in concert with laser treatment.

• **RISE and RIDE.** Pharmacologic agents with VEGF-inhibiting properties have been shown to treat CSME effectively.<sup>11</sup> In 2012, intravitreal ranibizumab became the first medication to secure FDA clearance for the treatment of DME. This approval was based on the results of the RISE and RIDE studies—two identically designed, parallel, double-blind, placebo-controlled, three-year clinical trials.<sup>12</sup>

In RISE and RIDE, 759 patients were randomized to receive monthly injections of 0.3mg ranibizumab or 0.5mg ranibizumab, or a sham injection. The results showed that subjects who received 0.3mg ranibizumab experienced significant, early and sustained improvements in vision.<sup>12</sup>

Further, the researchers recommended that diabetic macular

### The Right Combination

In 2010, the Diabetic Retinopathy Clinical Research Network (DRCR.net) conducted a randomized controlled trial to assess whether intravitreal injection of ranibizumab combined with prompt or deferred laser, or intravitreal triamcinolone acetonide combined with prompt laser, would yield better visual outcomes than focal/grid photocoagulation in DME patients.<sup>35</sup>

This Phase III study clearly showed that intravitreal ranibizumab, with either prompt or deferred laser, provided better anatomic and functional outcomes after two years of treatment than laser alone.

edema patients with an OCT-measured central subfield thickness of greater than or equal to 250µm and an entering visual acuity measurement of 20/40 to 20/320 were most appropriate candidates for ranibizumab treatment.

• **RESOLVE.** Similarly to RISE and RIDE, 151 patients enrolled in the Safety and Efficacy of Ranibizumab in Diabetic Macular Edema (RESOLVE) study were randomized to receive either 0.3mg or 0.5mg of intravitreal ranibizumab monotherapy, or a sham injection.<sup>13</sup> However, laser photocoagulation was offered to patients who exhibited persistent disease activity after three months of dosing.

Patients initially received three consecutive monthly injections, then were retreated PRN for the next nine months. At one-year follow-up, patients in the 0.3mg treatment group experienced a mean increase in best-corrected visual acuity of 11.8 ETDRS letters; subjects in the 0.5mg treatment group gained 8.8 letters; and those in the sham group lost 1.4 letters.

Additionally, the researchers recommended that DME patients with a central retinal thickness of greater than or equal to 300µm and an entering visual acuity measurement of 20/40 to 20/320 should be referred for intravitreal ranibizumab therapy.<sup>13</sup>

• **READ-1 and 2.** The Ranibizumab for Edema of the Macula in Diabetes study 1 (READ-1), was

the first major trial to show that intravitreal anti-VEGF injections could be used to treat DME.<sup>14</sup> Specifically, the READ-1 researchers documented a 12.3-letter increase in chronic DME patients who received five 0.5mg ranibizumab injections over a seven-month period.

Three years later, READ-2 evaluated 126 patients who were randomized to receive 0.5mg of ranibizumab, focal/grid laser coagulation or a combination of

### Micropulse Laser Technology

The anatomical and visual benefits of laser photocoagulation are effective over the long term; however, the procedure often causes adjacent retinal tissue damage. Fortunately, micropulse laser technology (MPLT) has been shown to be as effective as conventional argon laser for DME, without yielding intraretinal damage during or after treatment.<sup>32,33</sup> With MPLT, the temperature increases in the target tissue remain sublethal, widely limiting visible lesions and scar formation.

One study indicated that MPLT appeared to be as effective as modified-ETDRS laser photocoagulation for the treatment of DME, while causing far less damage to the retinal pigment epithelium.<sup>34</sup> In comparison to conventional laser, however, MPLT does have a few disadvantages, including:

- *It takes twice as long to yield the therapeutic effect.*
- *The laser burns cannot be visualized clinically, making treatment and retreatment more challenging.*

## The Optometrist's Role in DR Management

- **Prevention.** This includes patient education about the fundamental importance of proper nutrition and healthy lifestyle.
- **Evaluation.** Perform a comprehensive ophthalmic workup and annual dilated fundus examination.
- **Early Detection.** Achieved via regular monitoring of ocular complications.
- **Comanagement.** Provide a timely referral to an endocrinologist, certified diabetes educator, podiatrist, dentist or retinal specialist, when appropriate.
- **Rehabilitation.** Arrange low vision care for patients who experience significant vision loss.

ranibizumab and laser therapy. At six-month follow-up, patients in the ranibizumab monotherapy group gained seven ETDRS letters; subjects in the combination treatment group gained 3.8 letters; and those in the laser monotherapy group actually lost 0.4 letters.<sup>2,15</sup>

• **RESTORE.** In the Rani-bizumab Monotherapy or Combined with Laser Versus Laser Monotherapy for Diabetic Macular Edema (RESTORE) study, 345 patients were randomized to receive 0.5mg ranibizumab plus sham laser, 0.5mg ranibizumab plus active laser or sham injections with active laser.<sup>16</sup> A treatment initiation phase included three consecutive monthly intravitreal injections of either ranibizumab or a placebo. Then, from months four

to 12, injections were administered as needed.

The mean improvement in best-corrected visual acuity from baseline was 6.1 ETDRS letters in the ranibizumab monotherapy group, 5.9 letters in the combined therapy group and 0.8 letters in the laser monotherapy group.<sup>16</sup>

• **BOLT.** Bevacizumab (Avastin, Genentech/Roche) is a systemic anti-VEGF agent that exhibits chemical similarities to ranibizumab. Because compounded bevacizumab is markedly less expensive than ranibizumab, retinal specialists often use it as an off-label DME treatment.

The intravitreal Bevacizumab or Laser Therapy in the Management of Diabetic Macular Edema (BOLT) study was a prospective, single-center, randomized, two-year trial of 80 CSME patients.<sup>17</sup> All enrolled subjects received at least one previous macular laser treatment.

The BOLT researchers compared the clinical efficacy of monthly intravitreal bevacizumab injections with four monthly modified macular laser treatments. At two-year follow-up, patients in the bevacizumab group gained 8.6 ETDRS letters, while those in the laser therapy group lost 0.5 letters.<sup>17</sup>

• **DA VINCI.** Aflibercept (Eylea, Regeneron [previously known as VEGF Trap-eye]) is a recombinant

fusion protein that exhibits activity against VEGF and placental growth factor (PLGF). It received FDA approval for the treatment of DME in July 2014.

The DME and VEGF Trap-Eye Investigation of Clinical Impact (DA VINCI) study showed that aflibercept produced a statistically significant and clinically relevant improvement in visual acuity when compared to macular laser photocoagulation in DME patients.<sup>18</sup>

• **MEAD.** Before the increased use of anti-VEGF therapy, intravitreal triamcinolone acetonide was frequently used to treat DME. However, due in part to the agent's capacity to induce cataract formation and increase intraocular pressure, its use has declined during the last few years. Additionally, one large trial reported that, for most patients, intravitreal triamcinolone acetonide yielded generally poorer visual outcomes than photocoagulation.<sup>19</sup>

In June 2014, Allergan's Ozurdex (dexamethasone intravitreal insert) received FDA approval for the treatment of DME in pseudophakic patients or those scheduled for cataract surgery. The insert's approval was based on results of the Macular Edema: Assessment of Implantable Dexamethasone in Diabetes (MEAD) trial.

This study evaluated 1,048 DME patients in two multicenter, three-year, sham-controlled, masked, randomized clinical trials.<sup>20</sup> MEAD researchers randomized patients to receive an 0.7mg dexamethasone implant, and 0.35mg implant or a sham implant. At three-year follow-up, all patients in both treatment groups experienced an improvement in best-corrected visual acuity. While the implant exhibited a good safety profile, approximately

### Vitrectomy: No Sense of Humor

Vitrectomy surgery could potentially aid in the resolution of diabetic macular edema. The rationale for vitrectomy was established following the publication of several epidemiologic studies.<sup>36</sup> Researchers observed that the incidence of complete posterior vitreous detachment was lower in patients with DME than in those without. This suggested that a partially attached vitreous is a risk factor for DME.

Today, it is believed that vitrectomy removes the tractional forces at the retinal surface in DME patients, as well as decreases oxygen consumption in the vitreous and reduces hypoxia in the retina.<sup>36</sup>

one-third of patients in both treatment groups experienced a clinically significant increase in intraocular pressure.<sup>20</sup>

Based upon further evaluation of the safety data collected from the MEAD study, Ozurdex secured FDA approval for use in all DME patients on September 29, 2014.

• **FAME.** In late September 2014, the FDA approved Iluvien (fluocinolone acetonide intravitreal implant, Alimera Sciences) for the treatment of DME in patients who've previously been treated with corticosteroids and did not experience a clinically significant intraocular pressure (IOP) increase. Each implant is designed to release submicrogram levels of fluocinolone acetonide for up to 36 months.

In the Fluocinolone Acetonide in Diabetic Macular Edema (FAME) study, a total of 956 patients were randomized to receive 0.2µg of fluocinolone acetonide per day, 0.5µg of fluocinolone acetonide per day or a sham injection for 24 months. At the three-year follow-up, 28.7% of patients in the low-dose group and 27.8% of those in the high-dose group gained at least 15 ETDRS letters, compared to just 18.9% in the sham group.

It is worth noting that the incidence of incisional glaucoma surgery secondary to IOP increase was 4.8% in the low-dose group, 8.1% in the high-dose group and 0.5% in the sham group. Therefore, Iluvien should not be considered as a first-line therapy for DME patients who have moderate to advanced glaucoma.

Diabetic retinopathy is a significant public health problem in the United States. While DR is a widely preventable condition, prolifera-

tive retinopathy diabetic macular edema can lead to severe vision loss.

The vision-threatening complications of PDR can be avoided via proper systemic control and timely PRP treatment. Intravitreal anti-VEGF administration ensures greater visual stability in DME patients than laser treatment, and often can help restore lost function. Going forward, micropulse laser and combination laser/pharmacological therapies may provide the best visual outcomes for patients with severe DME. ■

*Dr. Pelino is an assistant professor at Pennsylvania College of Optometry at Salus University in Elkins Park, Pa.*

*Dr. Pizzimenti is an associate professor at Nova Southeastern University College of Optometry in Fort Lauderdale, Fla.*

1. Klein R, Klein BE, Moss SE, Cruickshanks KJ. The Wisconsin Epidemiologic Study of diabetic retinopathy. XIV. Ten-year incidence and progression of diabetic retinopathy. *Arch Ophthalmol.* 1994 Sep;112(9):1217-28.
2. American Optometric Association. Guidelines for Care of the Patient with Diabetes, 2002. Available at: [www.aoa.org/optometrists/tools-and-resources/clinical-care-publications/clinical-practice-guidelines?ssoc=y](http://www.aoa.org/optometrists/tools-and-resources/clinical-care-publications/clinical-practice-guidelines?ssoc=y). Accessed September 24, 2014.
3. Early Treatment Diabetic Retinopathy Study Research Group. (1985). Photocoagulation for diabetic macular edema. Early Treatment Diabetic Retinopathy Study report number 1. *Arch Ophthalmol.* 1985 Dec;103(12):1796-806.
4. Diabetes Control and Complications Trial Research Group. The relationship of glycemic exposure (HbA1c) to the risk of development and progression of retinopathy in the Diabetes Control and Complications Trial. *Diabetes.* 1995 Aug;44(8):968-83.
5. Ciulla TA, Amador AG, Zinman B. Diabetic retinopathy and diabetic macular edema: Pathophysiology, screening, and novel therapies. *Diabetes Care.* 2003 Sep;26(9):2653-64.
6. Retinopathy Study Research Group. *Am J Ophthalmol.* 1976 Apr;81(4):383-96.
7. Neubauer AS, Ulbig MW. Laser treatment in diabetic retinopathy. *Ophthalmologica.* 2007;221(2):95-102.
8. The Diabetic Retinopathy Vitrectomy Study Research Group. Early vitrectomy for severe vitreous hemorrhage in diabetic retinopathy: Four-year results of a randomized trial. *Diabetic Retinopathy Vitrectomy Study Report Number 5. Arch Ophthalmol.* 1990 Jul;108(7):958-64.
9. Klein R, Klein BE, Moss SE, et al. The Wisconsin epidemiologic study of diabetic retinopathy. IV. Diabetic macular edema. *Ophthalmology.* 1984 Dec;91(12):1464-74.
10. Grading diabetic retinopathy from stereoscopic color fundus photographs—an extension of the modified Airlie House classification. ETDRS report number 10. Early Treatment Diabetic Retinopathy Study Research Group. *Ophthalmology.* 1991 May;98(5 Suppl):786-806.
11. Chun DW, Heier JS, Topping TM, et al. A pilot study of multiple intravitreal injections of ranibizumab in patients with center-involving clinically significant diabetic macular edema. *Ophthalmology.* 2006 Oct;113(10):1706-12.
12. Nguyen QD, Brown DM, Marcus DM, et al. Ranibizumab for diabetic macular edema: results from 2 phase III randomized trials: RISE and RIDE. *Ophthalmology.* Apr 2012;119(4):789-801.
13. Massin P, Bandello F, Garweg JG, et al. Safety and efficacy of ranibizumab in diabetic macular edema (RESOLVE Study): a

- 12-month, randomized, controlled, double-masked, multicenter phase II study. *Diabetes Care.* Nov 2010;33(11):2399-405.
14. Nguyen QD, Tatlipinar S, Shah SM, et al. Vascular endothelial growth factor is a critical stimulus for diabetic macular edema. *Am J Ophthalmol.* 2006 Dec;142(6):961-9.
15. Nguyen QD, Shah SM, Heier JS. Primary end point (six months) results of the ranibizumab for edema of the macula in diabetes (READ-2) study. *Ophthalmology.* 2009;116(11):2175-81.e1.
16. Lang G. Safety and efficacy of ranibizumab as monotherapy or adjunctive to laser photocoagulation in diabetic macular edema: 12-month results of the RESTORE study. Late-breaker presentation at European Association for the Study of Diabetes Meeting, Stockholm; May 22, 2010.
17. Rajendram R, Fraser-Bell S. A 2-year prospective randomized controlled trial of intravitreal bevacizumab or laser therapy (BOLT) in the management of diabetic macular edema: 24-month data: report 3. *Arch Ophthalmol.* 2012 Aug;130(8):972-9.
18. Do DV, Schmidt-Erfurth U, Gonzalez VH. The DA VINCI study: Phase 2 Primary results of VEGF trap-eye in patients with diabetic macular edema. *Ophthalmology.* 2011 Sep;118(9):1819-26.
19. Beck RW, Edwards AR, Aiello LP, et al. Three-year follow-up of a randomized trial comparing focal/grid photocoagulation and intravitreal triamcinolone for diabetic macular edema. *Arch Ophthalmol.* 2009 Mar;127(3):245-51.
20. Boyer DS, Yoon YH, Belfort R Jr. Three-year, randomized, sham-controlled trial of dexamethasone intravitreal implant in patients with diabetic macular edema. *Ophthalmology.* 2014 Jun 4. pii: S0161-6420(14)00378-9.
21. Fong DS, Aiello L, Gardner TW, et al. Position statement: retinopathy in diabetes. *Diabetes Care.* 2004 Jan;27 Suppl 1:S84-7.
22. Aiello LM. Perspectives on diabetic retinopathy. *Am J Ophthalmol.* 2003 Jul;136(1):122-35.
23. Hammes HP, Lin J, Renner O. Pericytes and the pathogenesis of diabetic retinopathy. *Diabetes.* 2002 Oct;51(10):3107-12.
24. Haller JA, Bandello F, Belfort R Jr, et al. Dexamethasone intravitreal implant in patients with macular edema related to branch or central retinal vein occlusion twelve-month study results. *Ophthalmology.* 2011 Dec;118(12):2453-60.
25. Saishin Y, Saishin Y, Takahashi K, et al. Inhibition of protein kinase C decreases prostaglandin-induced breakdown of the blood-retinal barrier. *J Cell Physiol.* 2003 May;195(2):210-9.
26. Chieffelli NC et al. AGEs, rather than hyperglycemia, are responsible for microvascular complications in diabetes: a "glycoxidation-centric" point of view. *Nutr Metab Cardiovasc Dis.* 2013;23(10):913-9.
27. Joussen AM, Poulaki V, Le ML, et al. A central role for inflammation in the pathogenesis of diabetic retinopathy. *FASEB J.* 2004 Sep;18(12):1450-2.
28. Shen WY, Lai CM, Graham CE, et al. Long-term global retinal microvascular changes in a transgenic vascular endothelial growth factor mouse model. *Diabetologia.* 2006 Jul;49(7):1690-701.
29. Pitcher JD, Hubschman JP. Succeeding with combination therapy for DME. Treatment options must be tailored to the individual patient. *Retinal Physician.* Oct 2011;60-6.
30. Hariprasad SM, Mieler WF, Grassi M, et al. Vision-related quality of life in patients with diabetic macular edema. *Br J Ophthalmol.* 2008 Jan;92(1):89-92.
31. UK Prospective Diabetes Study Group. (1998a). Tight blood pressure control and risk of macrovascular and microvascular complications in type 2 diabetes (UKPDS 38). *BMJ.* 1998 Sep 12;317(7160):703-13.
32. Figueira J, Khan J, Nunes S. Prospective randomised controlled trial comparing sub-threshold micropulse diode laser photocoagulation and conventional green laser for clinically significant diabetic macular oedema. *Br J Ophthalmol.* 2009 Oct;93(10):1341-4.
33. Kiire C, Sivaprasad S, Chong V. Subthreshold micropulse laser therapy for retinal disorders. *Retina Today.* Available at: <http://retinatoday.com/2011/01/subthreshold-micropulse-laser-therapy-for-retinal-disorders>. Accessed September 24, 2014.
34. Vujosevic S, Bottega E, Casciano M, et al. Microperimetry and fundus autofluorescence in diabetic macular edema: Subthreshold micropulse diode laser versus modified early treatment diabetic retinopathy study laser photocoagulation. *Retina.* 2010 Jun;30(6):908-16.
35. Elman MJ, Aiello, LP, Beck RW, et al. Randomized trial evaluating ranibizumab plus prompt or deferred laser or triamcinolone plus prompt laser for diabetic macular edema. *Ophthalmology.* 2010 Jun;117(6):1064-1077.e35.
36. Hartley KL, Smiddy WE, Flynn HW, Murray TG. Pars plana vitrectomy with internal limiting membrane peeling for diabetic macular edema. *Retina.* 2008 Mar;28(3):410-9.



Up to  
**12 CE**  
Credits\*

**SAVE THE DATE:**  
**DECEMBER 4-5, 2015**  
**ANAHEIM, CA**

**THE OPTOMETRIC RETINA SOCIETY  
AND REVIEW OF OPTOMETRY PRESENT:**

# RETINA UPDATE 2015

## ORS Mission Statement

"The mission of the Optometric Retina Society (ORS) is to promote the advancement of vitreoretinal knowledge for clinicians, ophthalmic educators, residents, and students. The ORS is dedicated to posterior segment disease prevention, diagnosis, management and co-management."

## Registration Information Coming Soon!

## Course Topics

- Nutrition and Genetics in Retinal Wellness
- New Paradigms in Retinal Vascular Disease
- Vitreoretinal Grand Rounds
- Medical and Surgical Retina Update
- Macular Holes and Epiretinal Membranes.
- What's New in Retinal Imaging?

### For Additional Information

**Contact:**

Lois DiDomenico

**Email:**

ReviewMeetings@Jobson.com

Administered by

**Review of Optometry**



\*Approval Pending

**REVIEW OF OPTOMETRY**  
EDUCATIONAL MEETINGS OF CLINICAL EXCELLENCE

New Technologies and Treatments  
**NT & T**  
IN VISION CARE  
2015

PAUL KARPECKI, OD  
PROGRAM CHAIR

**SAN DIEGO, CA • APRIL 10-12**

**CHARLESTON, SC • JUNE 12-14**

**MAUI, HI • JULY 23-26**

**PHILADELPHIA, PA • NOVEMBER 6-8**

**NEW** Includes hands-on workshops

For more information, visit [www.reviewofoptometry.com](http://www.reviewofoptometry.com)



\*Approval pending

Up to  
**19 CE**  
Credits  
(COPE approval pending)

# Genetic Retinal Disease

By Charles M. Wormington, OD, PhD, FAAO

**DURING THE LAST DECADE**, the volume of published research on ocular genetics has increased exponentially. Much of this work centers on identifying the genetic mutations principally responsible for congenital retinal disorders, and how eye care providers might be able to delay or prevent devastating vision loss.

Because it would be nearly impossible to summarize this body of research here, I'll specifically focus the discussion upon the pathogenesis of inherited retinopathies; new innovations in genetic sequencing, gene and stem cell therapy; and the pharmacogenetics associated with age-related macular degeneration (AMD).

## Genetic Sequencing Innovations

It took Human Genome Project (HGP) researchers nearly 13 years and almost \$3 billion to determine the complete nucleotide base sequence of our DNA. Today, however, a complete human genome can be sequenced in just a few hours for less than \$1,000 using advanced devices, such as Illumina's MiSeqDx. As genomic testing becomes increasingly more affordable, eye care providers will be able to determine which specific genetic variants are responsible for the most common retinal diseases.

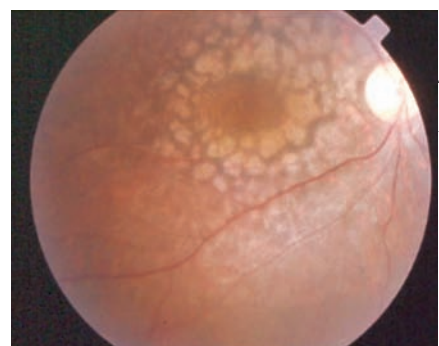• **Next-generation sequencing.** The HGP was completed using Sanger (also known as first-generation) sequencing, which is slow, expensive and labor intensive. On the other hand, next-generation sequencing (NGS) is the term used to describe a variety of modern, high-throughput sequencing technologies.<sup>1</sup> NGS permits "massively parallel sequencing," in which

millions of DNA fragments are sequenced in unison.

Because of its tremendous efficiency, NGS also has been used for whole-exome sequencing (WES)—a process that determines the DNA sequence specific to a given genome's protein-coding regions (exons). Because exons comprise less than 2% of genomic DNA, WES is less expensive and much faster than whole-genome sequencing (WGS). As the cost of sequencing continues to plummet, however, WGS will become much more common.<sup>2</sup> This will make it possible to identify more disease-causing variants—including those contained inside and outside of the exons, as well as those that are either common or rare variants.

• **Genome-wide association studies.** NGS has revolutionized the role of sequencing in the diagnosis of inherited retinopathies.<sup>3</sup> Additionally, it has facilitated the development and implementation of several genome-wide association studies (GWASs) that have helped uncover which genes are associated with retinal diseases. In fact, one of the first genes to be discovered following the completion of a GWAS was complement factor H (CFH), which is associated with AMD development.<sup>4,5</sup>

The fundamental basis of GWASs is the "common disease/common variant" hypothesis.<sup>6-8</sup> This assumes that complex diseases, like AMD, are caused by common variants (i.e., those that occur in more than 5% of the population). GWAS researchers look for single nucleotide polymorphisms (SNPs), which are the most prevalent genetic variants. SNPs are then used as markers for identifying the most common disease-



Leber congenital amaurosis, as documented in this patient, typically causes severe vision loss during infancy or early childhood.

Photo: Sherry J. Bass, OD

causing mutations.

The most common type of SNP is a single nucleotide base change in the DNA sequence. However, for the most part, GWASs have identified SNPs that do not account for more than a fraction of the causal variants. Thus, genomic researchers have shifted to a "common disease/rare variant" hypothesis, which uses NGS to look for more obscure mutations that may have a large effect.<sup>9</sup>

It would appear that a combination of the two hypotheses would be most appropriate in accounting for the heritability of complex diseases.

## Gene Therapy for Retinal Disorders

The conventional approach to gene therapy for retinal disorders is to insert a normal gene into an affected cell. This can be accomplished via insertion of a genetically engineered adeno-associated virus.<sup>10,11</sup> The viral vector carries the normal gene to the cell, where it is then released and can code for the normal protein.

The retina has several advantages with respect to its ability to respond to gene therapy:

- *It is easy to deliver the vector into the eye.*



## Congenital Retinal Disease 101

Inherited retinopathies are relatively common disorders that affect about one in 2,000 people.<sup>36</sup> More than 220 genes are known to be responsible for these inherited retinal diseases. Most inherited retinal diseases are monogenic conditions that cause significant vision loss secondary to retinal pigment epithelium (RPE) and/or photoreceptor degeneration.<sup>10</sup> Some are complex retinal disorders, such as age-related macular degeneration—a multifactorial disorder caused by a combination of susceptibility genes and non-genetic risk factors like advanced age and smoking.

Inherited retinal conditions are highly heterogeneous.<sup>36</sup> For example, mutations in several different genes may ultimately cause a single disorder, while different mutations of a single gene may cause a variety of disorders. Additionally, it is important to note that a specific genetic mutation in one patient may produce different signs and symptoms than those caused by the exact same genetic mutation in another patient.

About half of all inherited retinopathy cases are due to retinitis pigmentosa (RP).<sup>37</sup> This is a highly heterogeneous group of disorders. Mutations in more than 50 genes may cause non-syndromic RP, and variants in a number of genes may cause syndromic forms of RP (i.e., at least 12 genes can cause Usher syndrome, which involves hearing loss and RP). There is also significant heterogeneity in RP, because different mutations in the same gene can cause different retinal disorders.

Many of the causative genes for retinal disorders have not yet been identified, but the advent of next-generation sequencing holds tremendous promise for finding those genes.

- *The retina has some degree of immune privilege.*

- *The retina is easy to observe, and thus can be monitored for any adverse effects.*

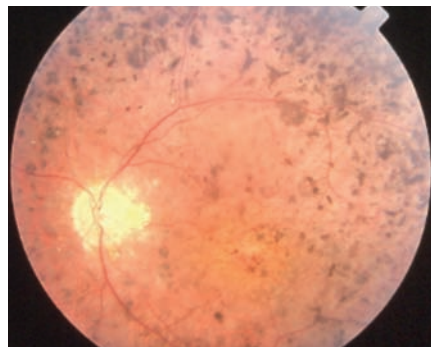
• **LCA/RPE65 disorders.** Leber congenital amaurosis (LCA) is a group of hereditary retinal dystrophies that cause early-onset vision loss. These conditions result from mutations in any one of at least 18 different genes.<sup>12,13</sup> The LCA2 form of the disease is caused by mutations in the retinal pigment epithelium-specific protein gene RPE65.

LCA2 is an autosomal recessive disorder, meaning that both copies of the RPE65 gene have mutations. Normal RPE65 genes encode a protein that is necessary to regenerate 11-cis-retinal, the chromophore of the rod and cone opsins.<sup>14,15</sup> However, patients with LCA2 only produce abnormal protein. Thus, affected individuals frequently exhibit moderate visual impairment in infancy that progresses to complete blindness by

mid- to late adulthood.

The primary objective of gene therapy is to insert a good copy of the RPE65 gene into the retinal pigment epithelial cells so that normal RPE65 protein can be made. One of the unique qualities of LCA2 is that, even with profound early visual impairment, retinal cells are relatively preserved. This suggests that early gene therapy may rescue both photoreceptors and RPE cells.

Currently, ClinicalTrials.gov indicates that eight clinical trials in the US, England, Israel



About half of all inherited retinopathies are caused by retinitis pigmentosa, as seen here.

and France are evaluating gene therapy for LCA2. In early experiments, the viral vector containing normal RPE65 genes was injected subretinally into the worse eye. Three independent clinical trials suggested that this approach was safe, well tolerated and somewhat effective.<sup>14,16,17</sup>

In one trial of 12 LCA2 patients, researchers noted dramatic improvement in vision.<sup>18</sup> In fact, all school-age children in the trial moved from braille classrooms to sighted classrooms. Because visual recovery was more pronounced in the children than in the adults, the researchers suggested that greater recovery will occur if treatment is initiated before retinal degeneration has progressed. The documented improvement in vision has lasted for at least three years. Injection of the viral vector and normal RPE65 gene in the contralateral eye was performed in three patients 1.7 to three years after the initial injection. Preliminary results have indicated that the second administration was both safe and efficacious.<sup>19</sup>

Spark Therapeutics, a spin-off of the Children's Hospital of Philadelphia (CHOP), was involved in these early trials. Currently, it is sponsoring three of the ongoing clinical trials for LCA2 RPE65 ([visit www.sparktx.com](http://www.sparktx.com) for more information). The organization intends to commercialize the gene therapy for LCA2, as well as successful gene therapies for other inherited retinal diseases. The company plans to seek marketing approval for the RPE65 treatment at the conclusion of its Phase III study, which is expected to be completed in 2015.

• **Choroideremia.** This monogenic, X-linked recessive disorder occurs secondary to mutations in



the CHM gene, which encodes for Rab escort protein 1 (REP1).<sup>20</sup> In this case, the targeted gene is located in the photoreceptors—unlike RPE65, which is contained in the RPE. In the normal disease process, central islands of neuronal tissue typically can be maintained until the fifth decade of life.<sup>21</sup> So, the intent of gene therapy for choroideremia is to try to rescue those areas from further degeneration.

In a Phase I clinical trial, a subretinal injection of an adeno-associated viral vector containing REP1 was administered to patients.<sup>20</sup> The study is still recruiting subjects, but the initial report suggests that, despite an initial retinal detachment occurring during the injection, there was significant visual acuity improvement in two of the six patients, with the others recovering to within one to three letters of their initial acuity. ClinicalTrials.gov indicates that another choroideremia gene therapy trial is scheduled to begin near the end of 2014.

### Stem Cell Therapy for Retinal Disorders

At least 14 stem cell trials currently are recruiting subjects for several visually devastating retinal diseases. Three of these studies are enrolling by invitation, one is active and not recruiting, and another three are not yet recruiting. The retinal disorders being investigated include both wet and dry AMD, RP, Stargardt disease, myopic macular degeneration, diabetic retinopathy, retinal vein occlusion and retinoblastoma. Across all studies, the emphasis of therapy is to replace faulty photoreceptors and retinal pigment epithelial cells.<sup>22,23</sup>

There are two primary options for obtaining stem cells for retinal

disease therapy. One method is to use human embryonic stem cells (hESCs) from four- to five-day-old embryos after in vitro fertilization.<sup>24</sup> The other is to use induced pluripotent stem cells (iPSCs).<sup>26</sup> They can be used to produce just about any type of cell, and can be generated from the patient's own cells (e.g., dermal fibroblasts or keratinocytes).<sup>25,26</sup>

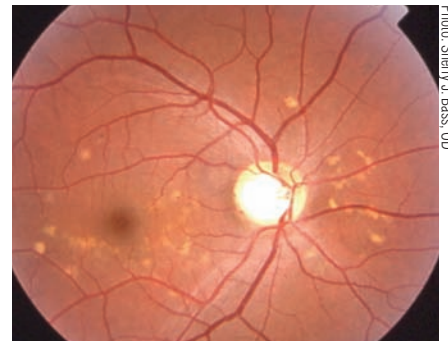Researchers from Advanced Cell Technology are currently recruiting subjects for a Phase I/II clinical trial using hESC-derived RPE cells to treat Stargardt disease and dry AMD.<sup>27</sup> Both disorders involve RPE loss, which in turn causes photoreceptor cell compromise.

The Advanced Cell Technology trial is the first study involving transplantation of hESC-derived cells into human patients. A preliminary report on this trial indicated that the lowest dose was safe, and that both subjects—one with Stargardt disease and one with dry AMD—exhibited some functional visual improvement.<sup>27</sup> One of the future goals will be to treat patients earlier in the disease process to increase the possibility of photoreceptor survival.

### Pharmacogenetics and AMD

• **Anti-VEGF therapy.** Since the mid 2000s, retinal specialists have been treating wet AMD patients with anti-vascular endothelial growth factor (VEGF) therapy. Interestingly, however, some of the most recent studies specifically designed to evaluate the pharmacogenetics of anti-VEGF treatment for AMD have yielded inconsistent and contradictory results.<sup>28,29</sup>

Further, many of the AMD pharmacogenetic studies involved retrospective analyses of patient subsets from clinical trials that were not designed to address pharma-



Stargardt disease can present with a macular lesion with flecks, no flecks or flecks with no macular lesion, as seen in this patient.

cogenetic questions. For example, two such studies analyzed subsets of patients enrolled in AREDS and came to different conclusions.<sup>30-32</sup>

In another large, prospective study that compared visual outcomes following intravitreal injections of either bevacizumab or ranibizumab—the Comparison of AMD Treatments Trials (CATT)—researchers found no statistically significant differences in treatment responses due to genotype.<sup>33</sup> The same conclusion was reached in a separate large-cohort study using data collected from the Inhibition of VEGF in Patients with Age-Related Choroidal Neovascularisation (IVAN) study, a randomized, controlled clinical trial of neovascular AMD and anti-VEGF treatment.<sup>34</sup>

• **Nutritional supplementation.** In 2014, Emily Chew, MD, and associates from the Age-Related Eye Disease Research Group performed an “unplanned retrospective evaluation of a prospective, randomized, placebo-controlled clinical trial of vitamins and minerals for the treatment of AMD.”<sup>35</sup> The study included 1,237 white, genotyped subjects with a mean follow-up of 6.6 years. The investigators confined their analysis to patients for which AREDS supplementation was recommended (i.e., those with intermediate AMD in

one or both eyes, or late-stage AMD in one eye). The genotypes evaluated were CFH and age-related maculopathy susceptibility 2 (ARMS2). These two genes are associated with an increased risk of advanced AMD.

The investigators' analysis found no statistically significant relationship between the effect of AREDS-formulated vitamin supplementation and the subjects' genotype status. These findings do not support those documented by Carl C. Awh, MD, and associates, which suggested that patients' genotypes could reveal which nutritional supplements would specifically provide the greatest protection against disease progression.<sup>31</sup>

Dr. Chew's group indicated that the differences between its analysis and that conducted by Dr. Awh's team included a larger sample size, differences in subgroup analyses and a slight variation in statistical methods.<sup>31,35</sup> There was also a difference in the time covered by the two studies—Dr. Chew's team confined its data to the randomized portion of the study, while Dr. Awh's group continued its research after patients in the placebo group were instructed to add the AREDS formula to their diets.<sup>31,35</sup>

Dr. Awh's study needs to be validated in a different cohort. In addition, more research with larger, better-designed prospective studies will be necessary to determine whether specific SNPs can help predict if a particular treatment will be effective in preventing significant disease progression.

Next-generation sequencing will streamline and accelerate researchers' efforts in finding the mutations or polymorphisms that can cause and/or increase susceptibility for retinal disorders. Once

## Gene Therapy for Other Retinal Disorders

- ClinicalTrials.gov indicates that there are two ongoing gene therapy studies for patients with wet AMD in the US and Australia. The trial researchers administered an intravitreal injection of an adeno-associated virus containing the FLT1 gene, which codes for a protein that inhibits abnormal blood vessel growth.
- A variety of other trials are also currently ongoing—two for Stargardt disease; one for RP; and one for the RP syndromic variant, Usher syndrome type 1B (RP with hearing deficits).<sup>38</sup>

these gene variants are found, they can be used either to diagnose or infer the risk of certain retinal disorders.

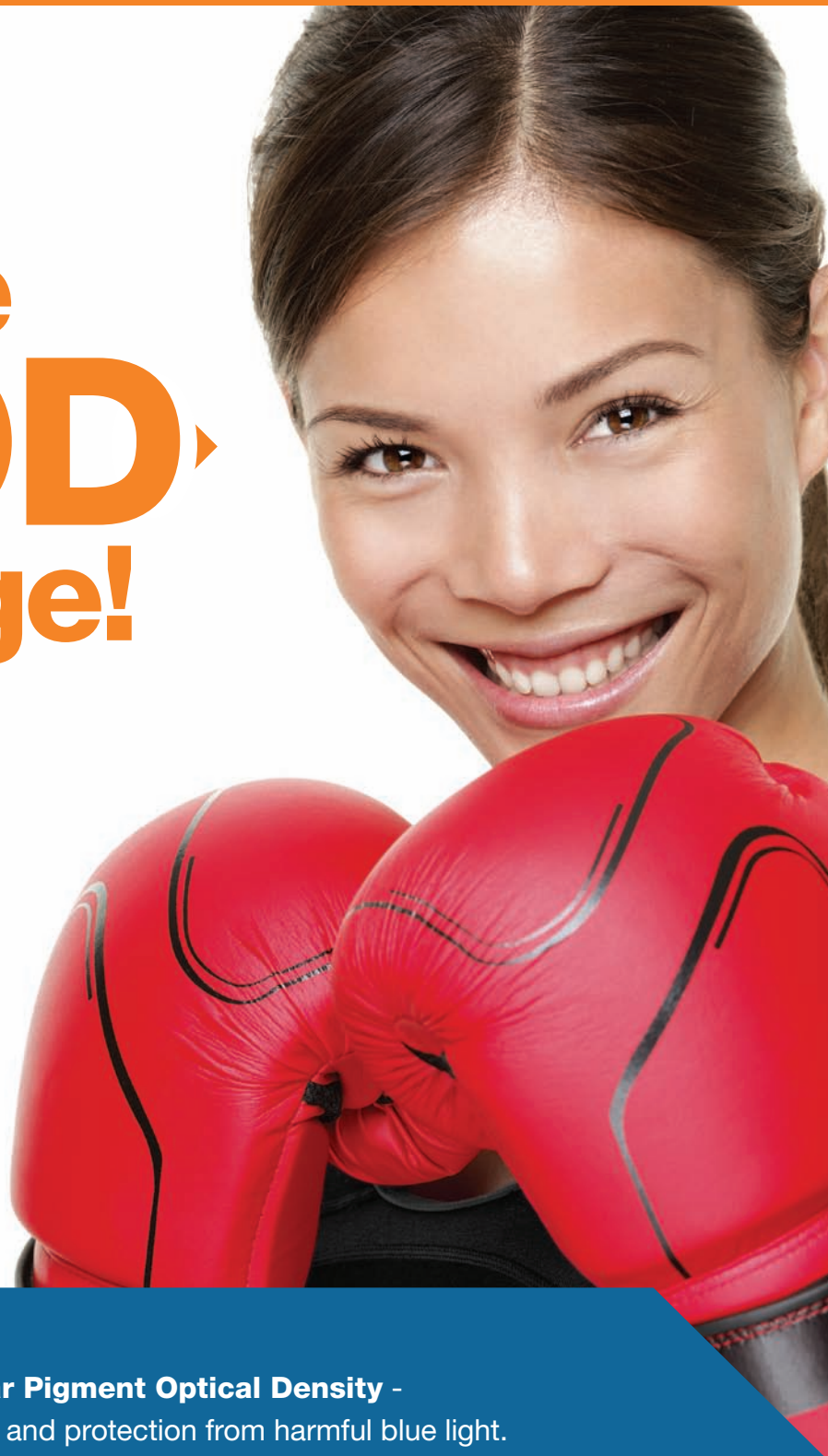In the future, knowledge of these gene variants may help researchers develop novel treatment approaches. ■

*Dr. Wormington is a professor of biophysics and optometry at Salus University in Elkins Park, Pa., and serves as the staff biophysicist at its Light and Laser Institute.*

1. Mardis ER. Next-generation DNA sequencing methods. *Annu Rev Genomics Hum Genet.* 2008;9:387-402.
2. Feero WG. Clinical application of whole-genome sequencing: proceed with care. *JAMA* 2014 Oct;311(10):1017-9.
3. Davies WI. Challenges using diagnostic next-generation sequencing in the clinical environment for inherited retinal disorders. *Personal Med.* 2014;11(1):99-111.
4. Klein RJ, Zeiss C, Chew EY, et al. Complement factor H polymorphism in age-related macular degeneration. *Science.* 2005 Apr 15;308(5720):385-9.
5. Fritsche LG, Fariss RN, Stambolian D, et al. Age-Related Macular Degeneration: Genetics and Biology Coming Together. *Annu Rev Genomics Hum Genet.* 2014 Aug 31;15:151-71.
6. Gibson G. Rare and common variants: twenty arguments. *Nat Rev Genet.* 2011;13(2):135-45.
7. Li B, Liu DJ, Leal SM. Identifying rare variants associated with complex traits via sequencing. *Curr Protoc Hum Genet.* 2013 Jul;Chapter 1:Unit 1.26.
8. Marian AJ. Challenges in medical applications of whole exome/genome sequencing discoveries. *Trends Cardiovasc Med.* 2012;22(8):219-23.
9. Schork NJ, Murray SS, Frazer KA, Topol EJ. Common vs. rare allele hypotheses for complex diseases. *Curr Opin Genet Dev.* 2009;19(3):212-9.
10. McClements ME, MacLaren RE. Gene therapy for retinal disease. *Transl Res.* 2013;161(4):241-54.
11. Fischer A. Gene therapy: Repair and replace. *Nature.* 2014 Jun 12;510(7504):226-7.
12. Sahel JA, Roska B. Gene therapy for blindness. *Annu Rev Neurosci.* 2013 Jul 8;36:467-88.
13. Zaneveld J, Wang F, Wang X, Chen R. Dawn of ocular gene therapy: implications for molecular diagnosis in retinal disease. *Sci China Life Sci.* 2013;56(2):125-33.
14. Maguire AM, Simonelli F, Pierce EA, et al. Safety and efficacy

- of gene transfer for Leber's congenital amaurosis. *N Engl J Med.* 2008 May 22;358(21):2240-8.
15. Redmond TM, Yu S, Lee E, et al. RPE65 is necessary for production of 11-cis-vitamin A in the retinal visual cycle. *Nat Genet.* 1998 Dec;20(4):344-51.
16. Bainbridge JW, Smith AJ, Barker SS, et al. Effect of gene therapy on visual function in Leber's congenital amaurosis. *N Engl J Med.* 2008 May 22;358(21):2231-9.
17. Hauswirth WW, Aleman TS, Kaushal S. Treatment of leber congenital amaurosis due to RPE65 mutations by ocular subretinal injection of adeno-associated virus gene vector: short-term results of a phase I trial. *Hum Gene Ther.* 2008 Oct;19(10):979-90.
18. Maguire AM, High KA, Auricchio A, et al. Age-dependent effects of RPE65 gene therapy for Leber's congenital amaurosis: a phase 1 dose-escalation trial. *Lancet.* 2009 Nov 7;374(9701):1597-605.
19. Testa F, Maguire AM, Rossi S, et al. Three-year follow-up after unilateral subretinal delivery of adeno-associated virus in patients with Leber congenital Amaurosis type 2. *Ophthalmology.* 2013 Jun;120(6):1283-91.
20. MacLaren RE, Groppa M, Barnard AR, et al. Retinal gene therapy in patients with choroideremia: initial findings from a phase 1/2 clinical trial. *Lancet.* 2014 Mar 29;383(9923):1129-37.
21. Scholl HP, Sahel JA. Gene therapy arrives at the macula. *Lancet.* 2014 Mar 29;383(9923):1105-7.
22. Kvant A. Stem cell-based treatment in geographic atrophy: promises and pitfalls. *Acta Ophthalmol.* 2014 Feb;92(1):21-6.
23. Tucker BA, Mullins RF, Stone EM. Stem cells for investigation and treatment of inherited retinal disease. *Hum Mol Genet.* 2014 Sep 15;23(R1):R9-R16.
24. Thomson JA, Itskovitz-Eldor J, Shapiro SS, et al. Embryonic stem cell lines derived from human blastocysts. *Science.* 1998 Nov 6;282(5391):1145-7.
25. Wernig M, Meissner A, Foreman R, et al. In vitro reprogramming of fibroblasts into a pluripotent ES-cell-like state. *Nature.* 2007 Jul 19;448(7151):318-24.
26. Takahashi K, Tanabe K, Ohnuki M, et al. Induction of pluripotent stem cells from adult human fibroblasts by defined factors. *Cell.* 2007 Nov 30;131(5):861-72.
27. Schwartz SD, Hubschman JP, Heilwell G, et al. Embryonic stem cell trials for macular degeneration: a preliminary report. *Lancet.* 2012 Feb 25;379(9817):713-20.
28. Lazzeri S, Nardi M. Pharmacogenetic labyrinth of neovascular age-related macular degeneration therapy: how to escape and move forward? *Pharmacogenomics.* 2013 Aug;14(11):1239-42.
29. Park UC, Shin JY, Kim SJ, et al. Genetic factors associated with response to intravitreal ranibizumab in Korean patients with neovascular age-related macular degeneration. *Retina.* 2014 Feb;34(2):288-97.
30. Awh CC, Lane AM, Hawken S, et al. CFH and ARMS2 genetic polymorphisms predict response to antioxidants and zinc in patients with age-related macular degeneration. *Ophthalmology.* 2013 Nov;120(11):2317-23.
31. Klein ML, Francis PJ, Rosner B, et al. CFH and LOC387715/ARMS2 genotypes and treatment with antioxidants and zinc for age-related macular degeneration. *Ophthalmology.* 2008 Jun;115(6):1019-25.
32. Schwartz SG. Re: Awh, et al.: CFH and ARMS2 genetic polymorphisms predict response to antioxidants and zinc in patients with age-related macular degeneration. (*Ophthalmology* 2013;120:2317-23). *Ophthalmology.* 2014 Aug;121(8):e38.
33. Hagstrom SA, Ying GS, Pauer GJ, et al. Pharmacogenetics for genes associated with age-related macular degeneration in the Comparison of AMD Treatments Trials (CATT). *Ophthalmology.* 2013 Mar;120(3):593-9.
34. Lotery AJ, Gibson J, Cree AJ, et al. Pharmacogenetic associations with vascular endothelial growth factor inhibition in participants with neovascular age-related macular degeneration in the IVAN Study. *Ophthalmology.* 2013 Dec;120(12):2637-43.
35. Chew EY, Klein ML, Clemons TE, et al. No Clinically Significant Association between CFH and ARMS2 Genotypes and Response to Nutritional Supplements: AREDS Report Number 38. *Ophthalmology.* 2014 Jun 26. [Epub ahead of print]
36. Berger W, Kloeckener-Gruissem B, Neidhardt J. The molecular basis of human retinal and vitreoretinal diseases. *Prog Retin Eye Res* 2010;29(5):335-75.
37. Daiger SP, Sullivan LS, Bowne SJ. Genes and mutations causing retinitis pigmentosa. *Clin Genet.* 2013;84(2):132-41.
38. Petrs-Silva H, Linden R. Advances in gene therapy technologies to treat retinitis pigmentosa. *Clin Ophthalmol.* 2014;8:127-36.

# Take the **MPOD** Challenge!



Knowing your patients' MPOD - **Macular Pigment Optical Density** - is important as a key risk factor for AMD and protection from harmful blue light.

**START TODAY!** Measure MPOD with *QuantifEye*, and supplement with *EyePromise* - the **ONLY** brand **Guaranteed to Increase MPOD!**



**SCRATCH AND PLAY**  
at [www.MPODChallenge.com!](http://www.MPODChallenge.com)

Win great prizes and get a free MPOD Awareness Kit!





# Retinal Venous Occlusion

By Julie Hutchinson McGinnis, OD, FAAO, and Andrew S. Gurwood, OD, FAAO, Dipl. (Supplement Editor)

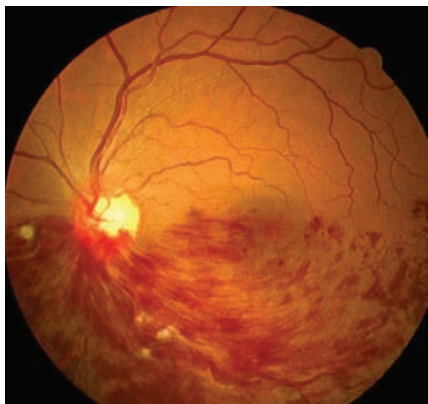
**RETINAL VEIN OCCLUSIONS (RVOs)** are among the common visually disabling intraretinal vascular events. While they do occur spontaneously and idiopathically, those with systemic vascular disease are at the greatest risk. Early diagnosis with prompt referral to retinology can facilitate timely intervention, which can improve the likelihood of anatomic and functional recovery. The evolution of RVO treatment, from observation and laser photocoagulation to today's protocols that employ injected pharmaceuticals, has yielded reduced RVO-related visual disability.

## Pathogenesis of RVOs

The etiology of central retinal vein occlusion (CRVO) is quite complex. The literature points to a combination of vascular, anatomic and inflammatory influences that induce arterial rigidity and vascular compression at a point located along the central retinal vein as it courses within the optic nerve.<sup>1</sup> The result is turbulent blood flow, damage to the vascular endothelium and thrombosis formation.<sup>1,2</sup>

Branch retinal vein occlusions (BRVOs) are believed to result secondary to venous compression following overlying arteriole hardening within the shared adventitial sheath.<sup>3,5</sup> A broadened retinal arteriolar reflex can be seen on ophthalmoscopy following BRVO, which is indicative of ongoing vascular arteriolar and atheromatous vascular decompensations.<sup>3</sup> Venous nicking is a second observable sign of the mechanical forces shared by the conjoined vessels.<sup>3,5</sup>

Another contributory mecha-



This patient presented with a significant hemiretinal vein occlusion.

nism is hyperviscosity and/or coagulopathy blood dyscrasias, which leads to platelet aggregation and vascular perfusion interference.<sup>3,5</sup> When the system becomes interrupted—as excess blood volume fills the vascular lumen—vascular decompensation occurs, permitting venous blood to be spilled into the neurosensory retina's nerve fiber layer.<sup>3,5</sup> Resultant venous stasis interrupts arterial movement, forcing blood to flow into any local anastomoses.<sup>1,3,8</sup> Deoxygenated blood within the neurosensory retina promotes the release of inflammatory mediators, which are necessary to initiate tissue repair.<sup>1,4,5,7-10</sup> Vasoproliferative messengers, such as vascular endothelial growth factor (VEGF), also may be released, depending on the level of tissue ischemia.<sup>4,11,12</sup>

RVOs are painless and may or may not cause vision loss. Associated symptoms usually manifest in the early phases of the pathology. Reduced visual function can result directly from blockage of light to the retinal photoreceptors or indirectly secondary to tissue disorganization provoked by fluid influx.

Tissue death also may occur following chronic, inner-retinal ischemia precipitated by capillary occlusion. In this instance, failed vascular “push” results from the increased hydrostatic (back) pressure in the occluded vessels.<sup>4</sup> The pressure is transmitted back to the capillary bed, disabling arterial perfusion.<sup>4,5</sup> This environment is conducive to cellular death and persistent edema, which can severely compromise visual function.<sup>4,5</sup>

## Vein Occlusion Types

Retinal vein occlusions are categorized by the degree of vascular tree involvement:

- *CRVOs* result from a blockage of the central retinal vein at the level of the optic disc prior to its bifurcation into the major arcades.

- *BRVOs* are caused by an occlusion at the level of a single vascular arcade (e.g., superior temporal), typically located just distal to the central retinal vein's bifurcation.

- *Hemiretinal vein occlusions (HRVOs)* are caused by an obstruction of the central retinal vein at a level that affects the entire superior or inferior retina.

- *Twig retinal vein occlusions (TRVOs)* characterize an occlusion at a more distal point of a vascular arcade, commonly at a lesser bifurcation.

Retinal vein occlusions are further subdivided by vascular perfusion status. A non-ischemic RVO is an occlusive event without interruption of vascular perfusion, whereas an ischemic RVO is characterized by vascular stasis and the consequences of limited blood circulation.<sup>4</sup>

Retinal observations seen in RVOs include dilated, tortuous retinal veins, flame-shaped intraretinal hemorrhages (i.e., “blood and thunder” in CRVO), local patches of retinal ischemia (i.e., constipated axonal flow with axonal death, cotton-wool infarcts), intraretinal exudates and variable retinal and/or macular edema.<sup>3,4,8</sup> Retinal complications customarily observed following an ischemic RVO include capillary nonperfusion, retinal neovascularization, vitreous hemorrhage and tractional retinal detachment.<sup>5</sup> In the anterior segment, ischemia can induce neovascularization of the iris (NVI) and angle (NVA). It is important to note that NVA can “zipper” the angle closed, and cause anterior segment inflammation and secondary neovascular angle-closure glaucoma.

Symptomology, clinical signs and prognosis are largely dictated by the location of the event and the

## Alternative Treatments for RVO-induced Macular Edema

- **Suprathreshold micropulse diode laser photocoagulation (SMD)** has been explored as an alternative to standard grid or focal argon-laser treatment for RVO-related macular edema.<sup>35-37</sup> SMD is a low-intensity, high-density laser procedure that largely spares the retinal tissue and photoreceptors from harmful thermal damage.<sup>35</sup> In comparison to conventional laser therapy, SMD typically requires longer treatment times to achieve a similar reduction in anatomic edema.<sup>35</sup> However, because of significantly lower rates of collateral damage to the photoreceptors, long-term visual acuity gain is approximately two times more likely in eyes treated with SMD.<sup>35,38</sup>

- **Thrombolytic agents**, particularly recombinant tissue plasminogen activator (rt-PA), have been explored as potential mediators for improving venous blood flow following RVO. As expected, however, intravenous administration frequently resulted in numerous adverse effects, including vitreous hemorrhage and systemic bleeding.<sup>20,39-45</sup> Local administration, including direct cannulation of a peripapillary retinal vein, also has been attempted, yielding mixed reports of complications and adverse events.<sup>20,39-45</sup>

- **Injectable and implantable steroidal treatments**, such as Ozurdex (dexamethasone, Allergan) and Iluvien (flucinolone acetonide, Alimera Sciences), have been evaluated in several clinical trials.<sup>46-48</sup> These relatively new agents are also being used to arrest fluid accumulation, reverse the pathologic processes of inflammation associated with macular edema, and help complete the restoration of visual function in cases that do not completely respond to more traditional therapies.<sup>46-48</sup>

size of any ischemic area. Those who develop large, ischemic RVOs may present with an afferent pupillary defect and markedly decreased vision.<sup>4,8</sup> By contrast, patients with non-ischemic RVOs, especially BRVOs and TRVOs, may experience only minor visual symptoms.

## Evidence-Based Treatment

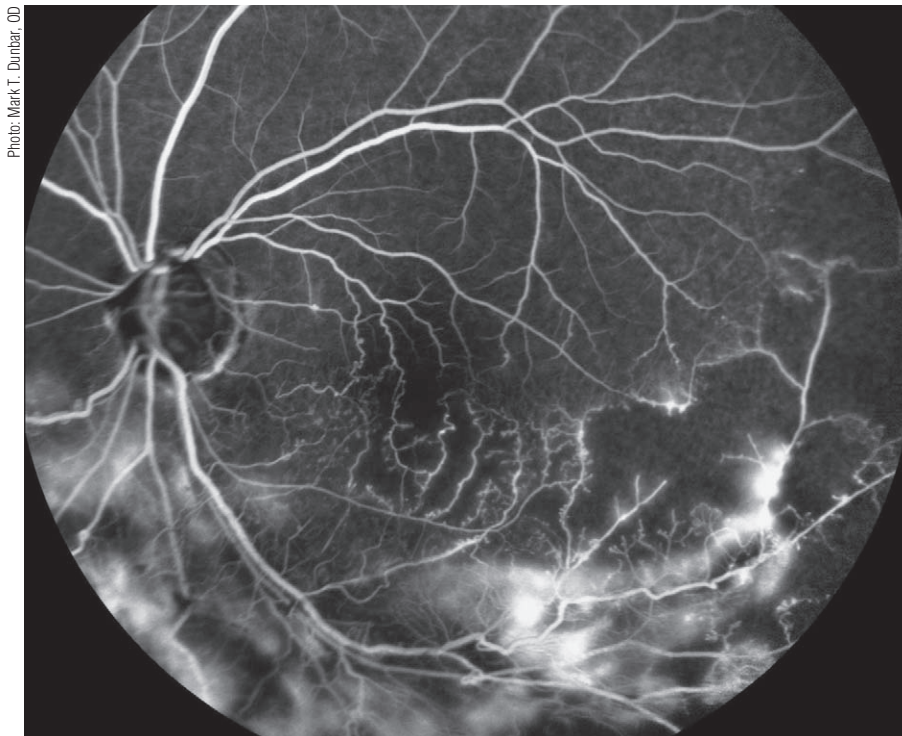
Ophthalmic management of RVOs has evolved as diagnostic technology and pharmaceutical treatments have become more advanced. Nonetheless, the necessity of uncovering the underlying systemic cause is just as critical now as it was several decades ago.

- **BVOS and CVOS.** The earliest understanding of RVO treatment is derived from the National Eye Institute’s Branch Vein Occlusion Study (BVOS) and Central Vein Occlusion Study (CVOS).<sup>13-18</sup>

In the mid 1980s, BVOS researchers determined that prophylactic scatter argon laser photocoagulation (i.e., panretinal photocoagulation [PRP]) in cases of BRVO would not prevent the development of neovascularization or vitreous hemorrhage.<sup>13</sup>

Further, they noted that macular argon laser photocoagulation (i.e., either grid or focal photocoagulation) could improve visual acuity in eyes with persistent macular edema and 20/40 vision or worse following complete BRVO resolution.<sup>4,13,14</sup>

In 1994, the CVOS researchers found that prophylactic PRP would not prevent the development of



A late-phase fluorescein angiography revealed extensive areas of non-perfusion in this glaucoma patient who presented with a resolving branch retinal vein occlusion.

Photo: Mark T. Dunbar, OD

## Comprehensive RVO Work-Up

<b>In-Office</b>	Blood pressure
	Fundus photography
	Optical coherence tomography (OCT)
	Amsler grid/automatic perimetry
<b>Blood Work</b>	Complete blood count (CBC)
	Westergren sedimentation rate (ESR)
	Lipid profile
	Fasting blood sugar/HbA1C
	Fasting treponemal antibody absorption test (FTA-Abs)
	Reactive plasma reagin (RPR)
	Homocysteine
	Protein S and C
	Lupus anticoagulant
	SickleDex
	Rheumatoid factor
	Purified protein derivative (PPD)
	Lyme titer
	Angiotensin converting enzyme (ACE)
Antinuclear antibody (ANA)	
<b>Ancillary Testing</b>	Carotid Doppler
	Electrocardiogram (EKG)
	Chest X-ray

neovascularization in cases of CRVO and that grid laser photocoagulation could reduce macular edema, but could not improve visual acuity following CRVO resolution.<sup>16-18</sup>

Because some patients are allergic to fluorescein dye and could experience life-threatening idiosyncratic events, National Eye Institute officials recommended that retinologists not treat macular edema in this capacity, as the benefits did not outweigh the risks (fluorescein angiography is required for the treatment of macular edema, because it illuminates the location of the leakage).

Both BVOS and CVOS indicated that PRP was beneficial once neovascularization was observed following either BRVO or CRVO.<sup>4,13,17</sup> However, because CVOS research-

ers did not recommend focal laser for the treatment of macular edema—and only recommended scatter PRP for cases that demonstrated visible neovascularization—no sanctioned treatment for CRVO existed at the time, except observation.

• **SCORE.** In the mid-to-late 2000s, investigators began to study the effect of intravitreal steroid injections in patients with retinal vein occlusions. The Standard Care versus Corticosteroid for Retinal Vein Occlusion (SCORE) study was designed to compare the safety and efficacy of 1mg or 4mg intravitreal triamcinolone injection vs. grid and focal laser photocoagulation for macular edema associated with both BRVO and CRVO.<sup>4,15</sup>

For BRVO, the SCORE research-

ers concluded that intravitreal steroid injection wasn't more visually beneficial than conventional laser therapy—particularly because of the associated risk of intraocular pressure increase and cataract formation following triamcinolone use.<sup>4,15</sup> Thus, they recommended that grid or focal photocoagulation remain the standard of care for macular edema secondary to BRVO.<sup>14,15</sup>

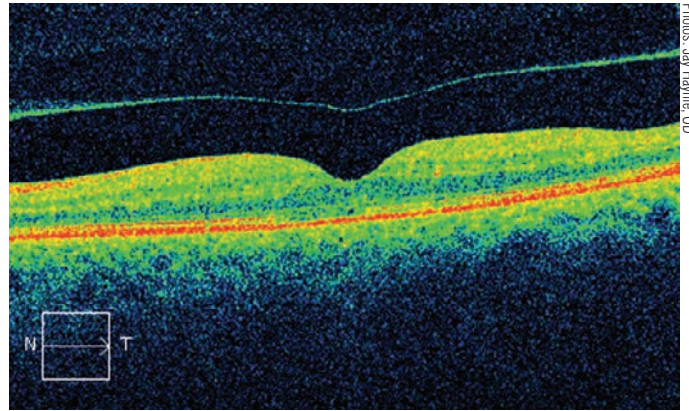
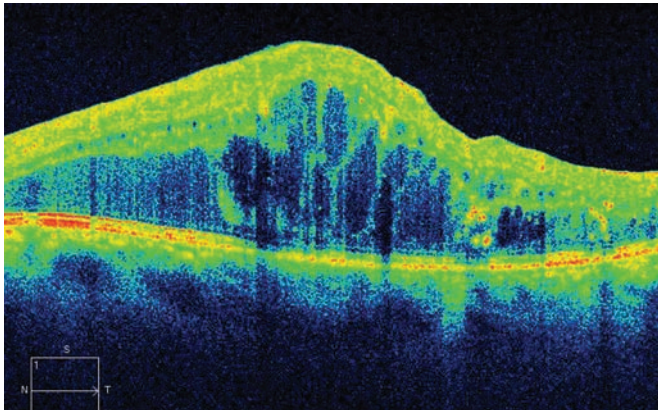
On the other hand, the researchers determined that intravitreal steroid injection was superior to observation alone in patients with macular edema following CRVO.<sup>19</sup> Because patients who received either 1mg or 4mg triamcinolone injections exhibited comparable improvements in visual acuity level, the SCORE researchers suggested that lower steroid doses likely would reduce the risk of adverse events.<sup>19</sup>

## Modern Approaches to Treatment

Many studies published during the last decade have explored the viability of intravitreal anti-VEGF therapy for the treatment of RVOs.<sup>20-27</sup> In most instances, the benefit of this treatment strategy is immediate pathology stasis and improved recovery of visual function. However, the greatest single advantage is avoidance of the collateral damage often precipitated by laser photocoagulation.

Intravitreal anti-VEGF administration, however, is not free from potential side effects, including retinal detachment, retinal pigment epithelial detachment and infection. Further, the treatment doesn't actually resolve the patient's underlying issue, so multiple reinjections often are required. It's also worth noting that repeated treatments can be highly impractical and cost prohibitive for the patient.





Photos: Jay Hamie, OD

At left, pronounced cystoid macular edema observed in a patient with an underlying central retinal vein occlusion prior to treatment with Ozurdex (dexamethasone) intravitreal implant, Allergan). Following Ozurdex implantation, the cystoid edema rapidly cleared.

• **BRAVO and CRUISE.** The Ranibizumab for the treatment of Macular Edema following Branch Retinal Vein Occlusion (BRAVO) study was designed to assess the safety and efficacy of monthly intraocular injections of 0.3mg or 0.5mg ranibizumab for macular edema secondary to BRVO.<sup>28,29</sup>

The study found that each dose of ranibizumab was statistically superior to the sham at achieving improvement in macular edema and visual acuity, with a low rate of side effects (cataract and vitreous hemorrhage were amongst the most frequently documented ocular adverse events). The study made no recommendation in favor of either dosage, leaving the option open to the treating surgeon.<sup>28</sup>

The Central Retinal Vein Occlusion Study: Evaluation of Safety and Efficacy (CRUISE) study was designed to answer the same question for CRVO.<sup>29,30</sup> The researchers concluded that intraocular ranibizumab injections safely and effectively reduced macular edema following CRVO.<sup>28-30</sup>

• **HORIZON and RETAIN.** These studies assessed long-term follow-up data sampled from BRAVO and CRUISE participants who received intravitreal ranibi-

zumab injections.<sup>31,32</sup> HORIZON researchers determined that the follow-up and injection schedule during year two should be individualized, and that CRVO patients may require more than four follow-up evaluations per year.<sup>31</sup> The RETAIN study indicated that after four years of dosing, ranibizumab's long-term efficacy profiles were excellent for BRVO—however, roughly half of patients still required periodic reinjections.<sup>32</sup> Additionally, RETAIN researchers noted that more than half of CRVO patients have a guarded prognosis and reduced functionality, despite frequent injections.<sup>32</sup>

• **COPERNICUS and GALILEO.** One group of American researchers (COPERNICUS) and a second group of European and Asian researchers (GALILEO) explored the efficacy of aflibercept (Eylea, Regeneron) for the treatment of macular edema secondary to CRVO.<sup>33,34</sup>

The COPERNICUS researchers concluded that CRVO patients benefit from 2mg intravitreal aflibercept administered every four weeks between weeks zero and 24.<sup>33</sup> Then, from weeks 24 to 52, anatomical and functional improvements diminished slowly

upon PRN dosing.<sup>33</sup> The GALILEO researchers found that patients benefit from early intervention with 2mg intravitreal aflibercept administered every four weeks from weeks zero to 20.<sup>34</sup> Unlike the COPERNICUS researchers, however, the GALILEO team noted that anatomical and functional improvements were largely maintained with PRN dosing in accordance with a four- to eight-week follow-up schedule.<sup>34</sup>

Retinal vein occlusion, whether initiated by mechanical or coagulopathic/inflammatory processes, is one of the more common causes of severe visual compromise in adults. In conjunction with the patient's primary care physician, you should arrange for a prompt referral to retinology to investigate the potential for immediate intervention.

While previously established treatment strategies have employed observation as an initial approach—especially in cases that do not yield functional vision loss—the latest research clearly indicates that prompt, appropriate intervention is a better option. ■

*Dr. McGinnis practices in St. Louis and is an assistant clinical professor at the University of Missouri-St. Louis*

## Sample Correspondence to Primary Care Provider for a Patient with a Retinal Vein Occlusion

Dear Dr. Smith,

Dilated fundus examination revealed a non-ischemic branch retinal vein occlusion in the superior temporal quadrant of the patient's right eye. We also noted macular edema. While retinal vein occlusions are often associated with diabetes mellitus, hypertension, hypercoagulopathy and hyperviscosity syndromes, inflammatory, infectious, cardiac and carotid artery disease are also plausible etiologies.

We are referring the patient back to you for a complete laboratory work-up with an assay (if not already done), including complete blood count with differential and platelets, Sickledex, fasting blood sugar, lipid panel, homocysteine, proteins S and C, lupus anticoagulant, erythrocyte sedimentation rate, C-reactive protein, 2D echocardiogram and Doppler testing. A chest X-ray, angiotensin converting enzyme and antinuclear antibody testing also may be indicated.

We have referred the patient to retinology to confirm our diagnosis and rule out the need for immediate intervention with an intravitreal injection of an anti-vascular endothelial growth factor agent. We will see the patient back for a dilated fundus examination in two weeks to rule out anterior and/or posterior segment neovascularization, which may require treatment with scatter laser photocoagulation. Depending on the rate of resolution and the persistence of pathologic macular fluid, focal laser photocoagulation also may be required. We will rely on retinology to make that decision, however.

Please contact me with any questions or concerns.

Respectfully,  
Joe Doe, MD

### College of Optometry.

*Dr. Gurwood is a professor at Salus University in Elkins Park, Pa.*

*They acknowledge Kevin J. Blinder, MD, of The Retina Institute in St. Louis for his review of the manuscript.*

1. Hayreh SS. Prevalent misconceptions about acute retinal vascular occlusive disorders. *Prog Retin Eye Res.* 2005;24(4):493-519.
2. Hamid S, Mirza SA, Shokh I. Branch retinal vein occlusion. *J Ayub Med Coll Abbottabad.* 2008 Apr-Jun;20(2):128-32.
3. Opremac EM, Bruce RA. Surgical decompression of branch retinal vein occlusion via arteriovenous crossing sheathotomy: a prospective review of 15 cases. *Retina.* 1999;19(1):1-5.
4. Sowka JW, Gurwood AS, Kabat AG. *The Handbook of Ocular Disease Management*, 12th ed. *Rev Optom.* 2010 Apr;147(4):1A-64A.
5. Funk M, Kriechbaum K, Prager F, et al. Intraocular concentrations of growth factors and cytokines in retinal vein occlusion and the effect of therapy with bevacizumab. *Invest Ophthalmol Vis Sci.* 2009 Mar;50(3):1025-32.
6. Hayreh SS, Zimmerman MB, Beri M, et al. Intraocular pressure abnormalities associated with central and hemicentral retinal vein occlusion. *Ophthalmology.* 2004 Jan;111(1):133-41.
7. Steinbrugger I, Haas A, Maier R, et al. Analysis of inflammation- and atherosclerosis-related gene polymorphisms in branch retinal vein occlusion. *Mol Vis.* 2009;15(3):609-18.
8. Margolis R, Singh RP, Kaiser PK. Branch retinal vein occlusion: clinical findings, natural history, and management. *Compr Ophthalmol Update.* 2006;7(6):265-76.
9. Bek T. Inner retinal ischaemia: current understanding and needs for further investigations. *Acta Ophthalmol.* 2009 Jun;87(4):362-7.
10. Rehak J, Rehak M. Branch retinal vein occlusion: pathogenesis, visual prognosis, and treatment modalities. *Curr Eye Res.* 2008 Feb;33(2):111-31.
11. Chappell JC, Taylor SM, Ferrara N, et al. Local guidance of emerging vessel sprouts requires soluble Flt-1. *Dev Cell.* 2009 Sep;17(3):377-86.

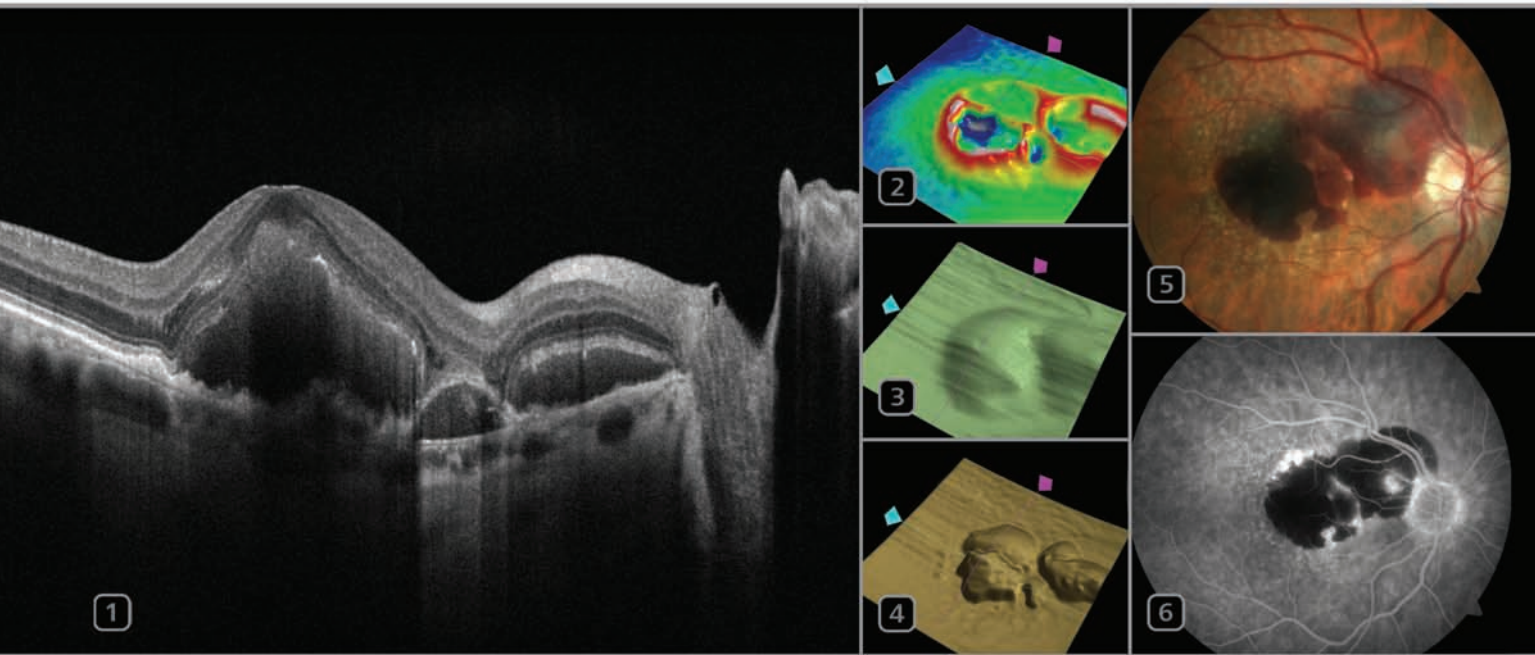
12. Pournaras CJ, Rungger-Brändle E, Riva CE, et al. Regulation of retinal blood flow in health and disease. *Prog Retin Eye Res.* 2008 May;27(3):284-330.
13. Branch Vein Occlusion Study Group. Argon laser scatter photocoagulation for the prevention of neovascularization and vitreous hemorrhage in branch vein occlusion. *Arch Ophthalmol.* 1986 Jan;104(1):34-41.
14. Branch Vein Occlusion Study Group. Argon Laser Photocoagulation for Macular Edema in Branch Vein Occlusion. *Am J Ophthalmol.* 1984 Sep 15;98(3):271-82.
15. Scott IU, Ip MS, VanVeldhuisen PC, et al. A randomized trial comparing the efficacy and safety of intravitreal triamcinolone with standard care to treat vision loss associated with macular edema secondary to branch retinal vein occlusion: the Standard Care vs Corticosteroid for Retinal Vein Occlusion (SCORE) study report 6. *Arch Ophthalmol.* 2009 Sep;127(9):1115-28.
16. The Central Vein Occlusion Study Group. Evaluation of grid pattern photocoagulation for macular edema in central vein occlusion. *The CVOS Group M Report. Ophthalmol.* 1995 Oct;102(10):1425-1433.
17. The Central Vein Occlusion Study Group. A randomized clinical trial of early panretinal photocoagulation for ischemic central vein occlusion. *The CVOS Group N Report. Ophthalmol.* 1995 Oct;102(10):1434-44.
18. The Central Vein Occlusion Study Group. Natural history and clinical management of central retinal vein occlusion. *Arch Ophthalmol.* 1997 Apr;115(4):486-91.
19. Ip MS, Scott IU, VanVeldhuisen PC, et al. A randomized trial comparing the efficacy and safety of intravitreal triamcinolone with observation to treat vision loss associated with macular edema secondary to central retinal vein occlusion: the Standard Care vs Corticosteroid for Retina Vein Occlusion (SCORE) study report 5. *Arch Ophthalmol.* 2009 Sep;127(9):1101-14.
20. Ehlers JP, Fekrat S. Retinal vein occlusion: beyond the acute event. *Surv Ophthalmol.* 2011 Jul-Aug;56(4):281-99.
21. Campochiaro PA, Bhisitkul RB. Vascular endothelial growth factor promotes progressive retinal nonperfusion in patients with retinal vein occlusion. *Ophthalmol.* 2013 Apr;120(4):795-802.
22. Costa RA, Jorge R, Calucci D, et al. Intravitreal bevacizumab (Avastin) for central and hemicentral retinal vein occlusions: IBeVO. *Retina.* 2007 Feb;27(2):141-9.
23. Ferrara DC. Early bevacizumab treatment of central retinal vein occlusion. *Am J Ophthalmol.* 2007 Jun;144(6):864-71.
24. Kriechbaum K, Michels S, Prager F, et al. Intravitreal Avastin for macular oedema secondary to retinal vein occlusion: a prospective study. *Br J Ophthalmol.* 2008 Apr;92(4):518-22.
25. Pal SA, Shetty R. Clinical, anatomic, and electrophysiologic evaluation following intravitreal bevacizumab for macular edema in retinal vein occlusion. *Am J Ophthalmol.* 2007 Apr;143(4):601-6.
26. Priglinger SG, Wolf AH, Kreuzer TC, et al. Intravitreal bevacizumab injections for treatment of central retinal vein occlusion: six-month results of a prospective trial. *Retina.* 2007 Oct;27(8):1004-12.
27. Stahl A, Agostini H, Hansen LL, et al. Bevacizumab in retinal vein occlusion – results of a prospective case series. *Graefes Arch Clin Exp Ophthalmol.* 2007 Oct;245(10):1429-36.
28. Brown DM, Campochiaro PA, Bhisitkul RB, et al. Sustained benefits from ranibizumab for macular edema following branch retinal vein occlusion: Twelve-month outcomes of a phase III study. *Ophthalmol.* 2011 Aug;118(8):1594-602.
29. Varma R, Bressler NM, Suner I, et al. Improved vision-related function after ranibizumab for macular edema after retinal vein occlusion: Results from the BRAVO and CRUISE trials. *Ophthalmology.* 2012 Oct;119(10):2108-18.
30. Campochiaro PA, Brown DM, Awh CC, et al. Sustained benefits from ranibizumab for macular edema following central retinal vein occlusion: Twelve-month outcomes of a phase III study. *Ophthalmol.* 2011 Oct;118(10):2041-49.
31. Heier JS, Campochiaro PA, Yao L, et al. Ranibizumab for macular edema due to retinal vein occlusions: Long-term follow-up in the HORIZON Trial. *Ophthalmol.* 2012 Apr;119(4):802-9.
32. The RETAIN Study Group. Long-term outcomes in patients with retinal vein occlusion treated with ranibizumab: The RETAIN study. *Ophthalmol.* 2014 Jan;121(1):209-19.
33. Brown DM, Heier JS, Clark WL, et al. Intravitreal aflibercept injection for macular edema secondary to central retinal vein occlusion: 1-year results from the phase 3 COPERNICUS study. *Am J Ophthalmol.* 2013 Mar;155(3):429-437.e7.
34. The GALILEO Study Group. Intravitreal Aflibercept for macular edema secondary to central retinal vein occlusion: 18-month results of the phase 3 GALILEO study. *Am J Ophthalmol.* 2014 Jul 25. [Epub ahead of print]
35. Majcher C, Gurwood AS. A review of micropulse laser photocoagulation. *Rev Optom* 2011 Nov;148(11):Suppl10-7.
36. Sivaprasad S, Elagouz M, McHugh D, et al. Micropulsed diode laser therapy: evolution and clinical application. *Surv Ophthalmol.* 2010 Nov-Dec;55(6):516-30.
37. Paulus YM, Palanker D, Blumenkranz MS. Short-pulse laser treatment: redefining retinal therapy minimizing side effects without compromising care. *Retinal Physician.* 2010 Jan/Feb:54-9.
38. Parodi JM, Spasse S, Iacono P, et al. Subthreshold grid laser treatment of macular edema secondary to branch retinal vein occlusion with micropulse infrared (810 nanometer) diode laser. *Ophthalmology.* 2006 Dec;113(12):2237-42.
39. Berker N, Batman C. Surgical treatment of central retinal vein occlusion. *Acta Ophthalmol.* 2008;86(3):245-52.
40. Bynoe LA, Hutchins RK, Lazarus HS, et al. Retinal endovascular surgery for central retinal vein occlusion: initial experience of four surgeons. *Retina.* 2005 May;25(5):625-32.
41. Feltgen N, Junker B, Agostini H, et al. Retinal endovascular lysis in ischemic central retinal vein occlusion: one-year results of a pilot study. *Ophthalmol.* 2007 Apr;114(4):716-23.
42. Glacet-Bernard A, Kuhn D. Treatment of recent onset central retinal vein occlusion with intravitreal tissue plasminogen activator: a pilot study. *Br J Ophthalmol.* 2000 Jun;84(6):609-13.
43. Lahay JM, Fong DS, Kearney J. Intravitreal tissue plasminogen activator for acute central retinal vein occlusion. *Ophthalmic Surg Lasers.* 1999 Jun;30(6):427-34.
44. Weiss JN, Bynoe LA. Injection of tissue plasminogen activator into a branch retinal vein in eyes with central retinal vein occlusion. *Ophthalmol.* 2001 Dec;108(12):2249-57.
45. Weizer JS, Fekrat S. Intravitreal tissue plasminogen activator for the treatment of central retinal vein occlusion. *Ophthalmic Surg Lasers Imaging.* 2003 Jul-Aug;34(4):350-2.
46. Haller JM, Bاندello F, Belfort R Jr, et al. Randomized, sham-controlled trial of dexamethasone intravitreal implant in patients with macular edema due to retinal vein occlusion. *Ophthalmology.* 2010 Jun;117(6):1134-46.e3.
47. Cabrera M, Yeh S, Albini TA. Sustained-release corticosteroid options. *J Ophthalmol.* 2014;2014:164692. [Epub ahead of print]
48. Comyn O, Lightman SL, Hykin PG. Corticosteroid intravitreal implants vs. ranibizumab for the treatment of vitreoretinal disease. *Curr Opin Ophthalmol.* 2013 May;24(3):248-54.








The right information, at the right time, all in one place.  
**CIRRUS photo – the multi-modality imager.**



**Insight, clarity, value.** CIRRUS™ photo combines a full mydriatic/non-mydriatic fundus camera with proven CIRRUS HD-OCT technology in one compact and highly versatile system.

**Diagnosis.** Exudative AMD with subretinal hemorrhage. Images courtesy of NC Retina Associates, Raleigh, NC, Bill Gavalier, Ophthalmic Photographer.



#### CIRRUS photo images

- |                                     |                               |
|-------------------------------------|-------------------------------|
| <b>1</b> High-resolution OCT B-scan | <b>4</b> RPE Segmentation Map |
| <b>2</b> Macular Thickness Map      | <b>5</b> Color Fundus         |
| <b>3</b> ILM Segmentation Map       | <b>6</b> Angiogram            |

Learn more at [www.meditec.zeiss.com/cirrus](http://www.meditec.zeiss.com/cirrus)

