

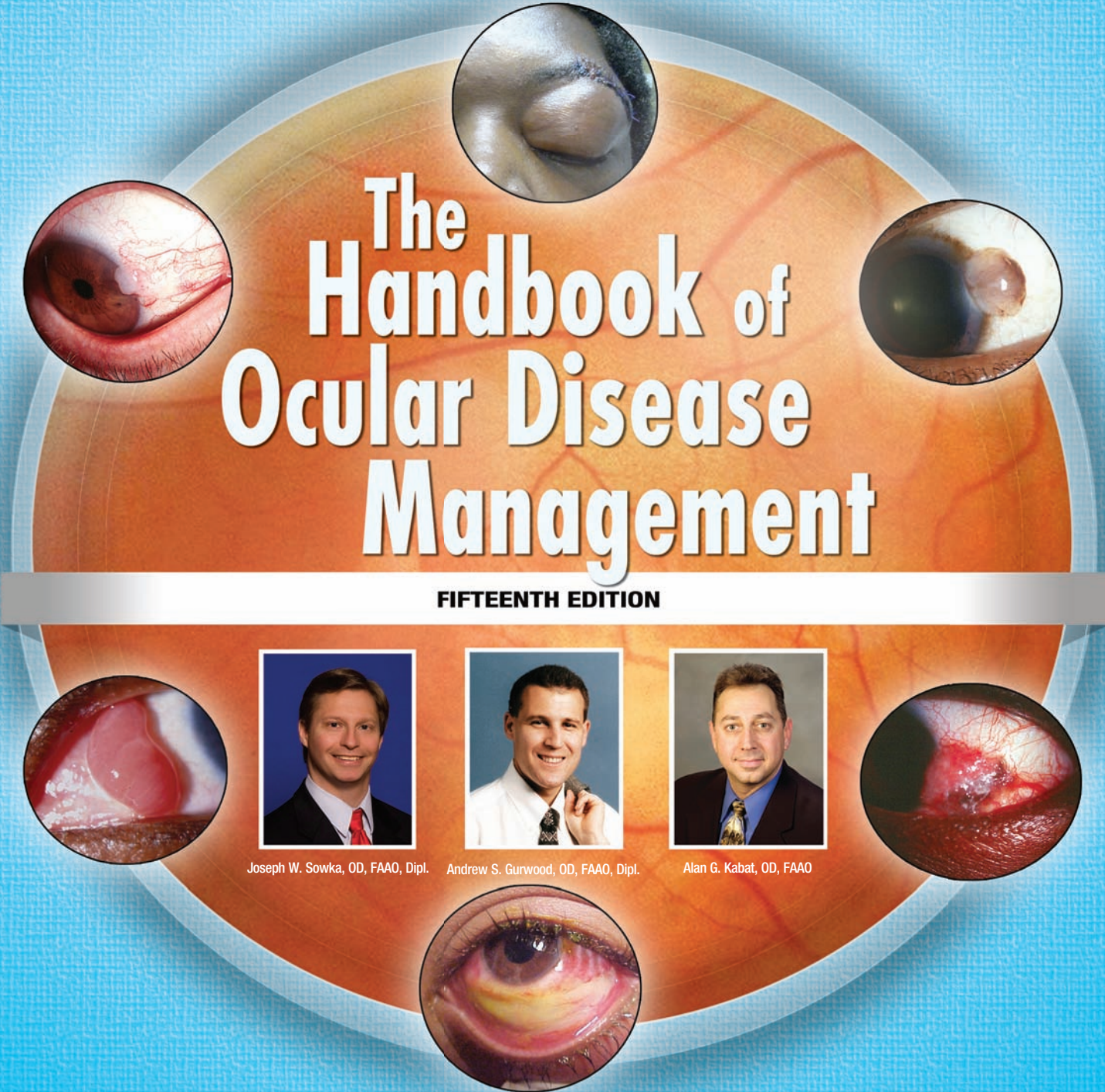


SUPPLEMENT TO

June 15, 2013

REVIEW[®] OF OPTOMETRY

www.revoptom.com



The Handbook of Ocular Disease Management

FIFTEENTH EDITION



Joseph W. Sowka, OD, FAAO, Dipl.



Andrew S. Gurwood, OD, FAAO, Dipl.



Alan G. Kabat, OD, FAAO

NEW

For the treatment of elevated IOP

UNLOCK NEW TREATMENT POSSIBILITIES



SIMBRINZA™ Suspension provided additional 1-3 mm Hg IOP lowering compared to the individual components¹

- IOP measured at 8 AM, 10 AM, 3 PM, and 5 PM was reduced by **21-35%** at Month 3²⁻⁴
- Efficacy proven in two pivotal Phase 3 randomized, multicenter, double-masked, parallel-group, 3-month, 3-arm, contribution-of-elements studies^{2,3}
- The most frequently reported adverse reactions (3-5%) were blurred vision, eye irritation, dysgeusia (bad taste), dry mouth, and eye allergy¹
- Only available beta-blocker-free fixed combination^{2,3}



INDICATIONS AND USAGE

SIMBRINZA™ (brinzolamide/brimonidine tartrate ophthalmic suspension) 1%/0.2% is a fixed combination indicated in the reduction of elevated intraocular pressure (IOP) in patients with open-angle glaucoma or ocular hypertension.

Dosage and Administration

The recommended dose is one drop of SIMBRINZA™ Suspension in the affected eye(s) three times daily. Shake well before use. SIMBRINZA™ Suspension may be used concomitantly with other topical ophthalmic drug products to lower intraocular pressure. If more than one topical ophthalmic drug is being used, the drugs should be administered at least five (5) minutes apart.

IMPORTANT SAFETY INFORMATION

Contraindications

SIMBRINZA™ Suspension is contraindicated in patients who are hypersensitive to any component of this product and neonates and infants under the age of 2 years.

Warnings and Precautions

Sulfonamide Hypersensitivity Reactions—Brinzolamide is a sulfonamide, and although administered topically, is absorbed systemically. Sulfonamide attributable adverse reactions may occur. Fatalities have occurred due to severe reactions to sulfonamides. Sensitization may recur when a sulfonamide is readministered irrespective of the route of administration. If signs of serious reactions or hypersensitivity occur, discontinue the use of this preparation.

Corneal Endothelium—There is an increased potential for developing corneal edema in patients with low endothelial cell counts.

References: 1. SIMBRINZA™ Suspension Package Insert. 2. Katz G, DuBiner H, Samples J, et al. Three-month randomized trial of fixed-combination brinzolamide, 1%, and brimonidine, 0.2% [published online ahead of print April 11, 2013]. *JAMA Ophthalmol*. doi:10.1001/jamaophthalmol.2013.188. 3. Nguyen QH, McMenemy MG, Realini T, et al. Phase 3 randomized 3-month trial with an ongoing 3-month safety extension of fixed-combination brinzolamide 1%/brimonidine 0.2%. *J Ocul Pharmacol Ther*. 2013;29(3):290-297. 4. Data on file, 2013.

Severe Hepatic or Renal Impairment (CrCl <30 mL/min)—SIMBRINZA™ Suspension has not been specifically studied in these patients and is not recommended.

Adverse Reactions

In two clinical trials of 3 months' duration with SIMBRINZA™ Suspension, the most frequent reactions associated with its use occurring in approximately 3-5% of patients in descending order of incidence included: blurred vision, eye irritation, dysgeusia (bad taste), dry mouth, and eye allergy. Adverse reaction rates with SIMBRINZA™ Suspension were comparable to those of the individual components. Treatment discontinuation, mainly due to adverse reactions, was reported in 11% of SIMBRINZA™ Suspension patients.

Drug Interactions—Consider the following when prescribing SIMBRINZA™ Suspension:

Concomitant administration with oral carbonic anhydrase inhibitors is not recommended due to the potential additive effect. Use with high-dose salicylate may result in acid-base and electrolyte alterations. Use with CNS depressants may result in an additive or potentiating effect. Use with antihypertensives/cardiac glycosides may result in additive or potentiating effect on lowering blood pressure. Use with tricyclic antidepressants may blunt the hypotensive effect of systemic clonidine and it is unknown if use with this class of drugs interferes with IOP lowering. Use with monoamine oxidase inhibitors may result in increased hypotension.

For additional information about SIMBRINZA™ Suspension, please see Brief Summary of full Prescribing Information on adjacent page.

NEW

SIMBRINZA™
(brinzolamide/brimonidine
tartrate ophthalmic suspension)
1%/0.2%

ONE BOTTLE. NEW POSSIBILITIES.

Alcon

a Novartis company

© 2013 Novartis 4/13 MG13003JAD

BRIEF SUMMARY OF PRESCRIBING INFORMATION INDICATIONS AND USAGE

SIMBRINZA™ (brinzolamide/brimonidine tartrate ophthalmic suspension) 1%/0.2% is a fixed combination of a carbonic anhydrase inhibitor and an alpha 2 adrenergic receptor agonist indicated for the reduction of elevated intraocular pressure (IOP) in patients with open-angle glaucoma or ocular hypertension.

DOSAGE AND ADMINISTRATION

The recommended dose is one drop of SIMBRINZA™ Suspension in the affected eye(s) three times daily. Shake well before use. SIMBRINZA™ Suspension may be used concomitantly with other topical ophthalmic drug products to lower intraocular pressure. If more than one topical ophthalmic drug is being used, the drugs should be administered at least five (5) minutes apart.

DOSAGE FORMS AND STRENGTHS

Suspension containing 10 mg/mL brinzolamide and 2 mg/mL brimonidine tartrate.

CONTRAINDICATIONS

Hypersensitivity - SIMBRINZA™ Suspension is contraindicated in patients who are hypersensitive to any component of this product.

Neonates and Infants (under the age of 2 years) - SIMBRINZA™ Suspension is contraindicated in neonates and infants (under the age of 2 years) *see Use in Specific Populations*

WARNINGS AND PRECAUTIONS

Sulfonamide Hypersensitivity Reactions - SIMBRINZA™ Suspension contains brinzolamide, a sulfonamide, and although administered typically is absorbed systemically. Therefore, the same types of adverse reactions that are attributable to sulfonamides may occur with topical administration of SIMBRINZA™ Suspension. Fatalities have occurred due to severe reactions to sulfonamides including Stevens-Johnson syndrome, toxic epidermal necrolysis, fulminant hepatic necrosis, agranulocytosis, aplastic anemia, and other blood dyscrasias. Sensitization may recur when a sulfonamide is re-administered irrespective of the route of administration. If signs of serious reactions or hypersensitivity occur, discontinue the use of this preparation *[see Patient Counseling Information]*

Corneal Endothelium - Carbonic anhydrase activity has been observed in both the cytoplasm and around the plasma membranes of the corneal endothelium. There is an increased potential for developing corneal edema in patients with low endothelial cell counts. Caution should be used when prescribing SIMBRINZA™ Suspension to this group of patients.

Severe Renal Impairment - SIMBRINZA™ Suspension has not been specifically studied in patients with severe renal impairment (CrCl < 30 mL/min). Since brinzolamide and its metabolite are excreted predominantly by the kidney, SIMBRINZA™ Suspension is not recommended in such patients.

Acute Angle-Closure Glaucoma - The management of patients with acute angle-closure glaucoma requires therapeutic interventions in addition to ocular hypotensive agents. SIMBRINZA™ Suspension has not been studied in patients with acute angle-closure glaucoma.

Contact Lens Wear - The preservative in SIMBRINZA™, benzalkonium chloride, may be absorbed by soft contact lenses. Contact lenses should be removed during instillation of SIMBRINZA™ Suspension but may be reinserted 15 minutes after instillation *[see Patient Counseling Information]*.

Severe Cardiovascular Disease - Brimonidine tartrate, a component of SIMBRINZA™ Suspension, has a less than 5% mean decrease in blood pressure 2 hours after dosing in clinical studies; caution should be exercised in treating patients with severe cardiovascular disease.

Severe Hepatic Impairment - Because brimonidine tartrate, a component of SIMBRINZA™ Suspension, has not been studied in patients with hepatic impairment, caution should be exercised in such patients.

Potentiation of Vascular Insufficiency - Brimonidine tartrate, a component of SIMBRINZA™ Suspension, may potentiate syndromes associated with vascular insufficiency. SIMBRINZA™ Suspension should be used with caution in patients with depression, cerebral or coronary insufficiency, Raynaud's phenomenon, orthostatic hypotension, or thromboangiitis obliterans.

Contamination of Topical Ophthalmic Products After Use - There have been reports of bacterial keratitis associated with the use of multiple-dose containers of topical ophthalmic products. These containers have been inadvertently contaminated by patients who, in most cases, had a concurrent corneal disease or a disruption of the ocular epithelial surface *[see Patient Counseling Information]*.

ADVERSE REACTIONS

Clinical Studies Experience - Because clinical studies are conducted under widely varying conditions, adverse reaction rates observed in the clinical studies of a drug cannot be directly compared to the rates in the clinical studies of another drug and may not reflect the rates observed in practice.

SIMBRINZA™ Suspension - In two clinical trials of 3 months duration 435 patients were treated with SIMBRINZA™ Suspension, and 915 were treated with the two individual components. The most frequently reported adverse reactions in patients treated with SIMBRINZA™ Suspension occurring in approximately 3 to 5% of patients in descending order of incidence were blurred vision, eye irritation, dysgeusia (bad taste), dry mouth, and eye allergy. Rates of adverse reactions reported with the individual components were comparable. Treatment discontinuation, mainly due to adverse reactions, was reported in 11% of SIMBRINZA™ Suspension patients.

Other adverse reactions that have been reported with the individual components during clinical trials are listed below.

Brinzolamide 1% - In clinical studies of brinzolamide ophthalmic suspension 1%, the most frequently reported adverse reactions reported in 5 to 10% of patients were blurred vision and bitter, sour or unusual taste. Adverse reactions occurring in 1 to 5% of patients were blepharitis, dermatitis, dry eye, foreign body sensation, headache, hyperemia, ocular discharge, ocular discomfort, ocular keratitis, ocular pain, ocular pruritus and rhinitis.

The following adverse reactions were reported at an incidence below 1%: allergic reactions, alopecia, chest pain, conjunctivitis, diarrhea, diplopia, dizziness, dry mouth, dyspnea, dyspepsia, eye fatigue, hypertension, keratoconjunctivitis, keratopathy, kidney pain, lid margin crusting or sticky sensation, nausea, pharyngitis, tearing and urticaria.

Brimonidine Tartrate 0.2% - In clinical studies of brimonidine tartrate 0.2%, adverse reactions occurring in approximately 10 to 30% of the subjects, in descending order of incidence, included oral dryness, ocular hyperemia, burning and stinging, headache, blurring, foreign body sensation, fatigue/drowsiness, conjunctival follicles, ocular allergic reactions, and ocular pruritus.

Reactions occurring in approximately 3 to 9% of the subjects, in descending order included corneal staining/erosion, photophobia, eyelid erythema, ocular ache/pain, ocular dryness, tearing, upper respiratory symptoms, eyelid edema, conjunctival edema, dizziness, blepharitis, ocular irritation, gastrointestinal symptoms, asthenia, conjunctival blanching, abnormal vision and muscular pain.

The following adverse reactions were reported in less than 3% of the patients: lid crusting, conjunctival hemorrhage, abnormal taste, insomnia, conjunctival discharge, depression, hypertension, anxiety, palpitations/arrhythmias, nasal dryness and syncope.

Postmarketing Experience - The following reactions have been identified during postmarketing use of brimonidine tartrate ophthalmic solutions in clinical practice. Because they are reported voluntarily from a population of unknown size, estimates of frequency cannot be made. The reactions, which have been chosen for inclusion due to either their seriousness, frequency of reporting, possible causal connection to brimonidine tartrate ophthalmic solutions, or a combination of these factors, include: bradycardia, hypersensitivity, iritis, keratoconjunctivitis sicca, miosis, nausea, skin reactions (including erythema, eyelid pruritus, rash, and vasodilation), and tachycardia.

Apnea, bradycardia, coma, hypotension, hypothermia, hypotonia, lethargy, pallor, respiratory depression, and somnolence have been reported in infants receiving brimonidine tartrate ophthalmic solutions *[see Contraindications]*.

DRUG INTERACTIONS

Oral Carbonic Anhydrase Inhibitors - There is a potential for an additive effect on the known systemic effects of carbonic anhydrase inhibition in patients receiving an oral carbonic anhydrase inhibitor and brinzolamide ophthalmic suspension 1%, a component of SIMBRINZA™ Suspension. The concomitant administration of SIMBRINZA™ Suspension and oral carbonic anhydrase inhibitors is not recommended.

High-Dose Salicylate Therapy - Carbonic anhydrase inhibitors may produce acid-base and electrolyte alterations. These alterations were not reported in the clinical trials with brinzolamide ophthalmic suspension 1%. However, in patients treated with oral carbonic anhydrase inhibitors, rare instances of acid-base alterations have occurred with high-dose salicylate therapy. Therefore, the potential for such drug interactions should be considered in patients receiving SIMBRINZA™ Suspension.

CNS Depressants - Although specific drug interaction studies have not been conducted with SIMBRINZA™, the possibility of an additive or potentiating effect with CNS depressants (alcohol, opiates, barbiturates, sedatives, or anesthetics) should be considered.

Antihypertensives/Cardiac Glycosides - Because brimonidine tartrate, a component of SIMBRINZA™ Suspension, may reduce blood pressure, caution in using drugs such as antihypertensives and/or cardiac glycosides with SIMBRINZA™ Suspension is advised.

Tricyclic Antidepressants - Tricyclic antidepressants have been reported to blunt the hypotensive effect of systemic clonidine. It is not known whether the concurrent use of these agents with SIMBRINZA™ Suspension in humans can lead to resulting interference with the IOP lowering effect. Caution is advised in patients taking tricyclic antidepressants which can affect the metabolism and uptake of circulating amines.

Monoamine Oxidase Inhibitors - Monoamine oxidase (MAO) inhibitors may theoretically interfere with the metabolism of brimonidine tartrate and potentially result in an increased systemic side-effect such as hypotension. Caution is advised in patients taking MAO inhibitors which can affect the metabolism and uptake of circulating amines.

USE IN SPECIFIC POPULATIONS

Pregnancy - *Pregnancy Category C*: Developmental toxicity studies with brinzolamide in rabbits at oral doses of 1, 3, and 6 mg/kg/day (20, 60, and 120 times the recommended human ophthalmic dose) produced maternal toxicity at 6 mg/kg/day and a significant increase in the number of fetal variations, such as accessory skull bones, which was only slightly higher than the historic value at 1 and 6 mg/kg. In rats, statistically decreased body weights of fetuses from dams receiving oral doses of 18 mg/kg/day (180 times the recommended human ophthalmic dose) during gestation were proportional to the reduced maternal weight gain, with no statistically significant effects on organ or tissue development. Increases in unossified sternbrae, reduced ossification of the skull, and unossified hyoid that occurred at 6 and 18 mg/kg were not statistically significant. No treatment-related malformations were seen. Following oral adminis-

tration of ¹⁴C-brinzolamide to pregnant rats, radioactivity was found to cross the placenta and was present in the fetal tissues and blood.

Developmental toxicity studies performed in rats with oral doses of 0.66 mg brimonidine base/kg revealed no evidence of harm to the fetus. Dosing at this level resulted in a plasma drug concentration approximately 100 times higher than that seen in humans at the recommended human ophthalmic dose. In animal studies, brimonidine crossed the placenta and entered into the fetal circulation to a limited extent.

There are no adequate and well-controlled studies in pregnant women. SIMBRINZA™ Suspension should be used during pregnancy only if the potential benefit justifies the potential risk to the fetus.

Nursing Mothers - In a study of brinzolamide in lactating rats, decreases in body weight gain in offspring at an oral dose of 15 mg/kg/day (150 times the recommended human ophthalmic dose) were observed during lactation. No other effects were observed. However, following oral administration of ¹⁴C-brinzolamide to lactating rats, radioactivity was found in milk at concentrations below those in the blood and plasma. In animal studies, brimonidine was excreted in breast milk.

It is not known whether brinzolamide and brimonidine tartrate are excreted in human milk following topical ocular administration. Because many drugs are excreted in human milk and because of the potential for serious adverse reactions in nursing infants from SIMBRINZA™ (brinzolamide/brimonidine tartrate ophthalmic suspension) 1%/0.2%, a decision should be made whether to discontinue nursing or to discontinue the drug, taking into account the importance of the drug to the mother.

Pediatric Use - The individual component, brinzolamide, has been studied in pediatric glaucoma patients 4 weeks to 5 years of age. The individual component, brimonidine tartrate, has been studied in pediatric patients 2 to 7 years old. Somnolence (50-83%) and decreased alertness was seen in patients 2 to 6 years old. SIMBRINZA™ Suspension is contraindicated in children under the age of 2 years *[see Contraindications]*.

Geriatric Use - No overall differences in safety or effectiveness have been observed between elderly and adult patients.

OVERDOSAGE

Although no human data are available, electrolyte imbalance, development of an acidotic state, and possible nervous system effects may occur following an oral overdose of brinzolamide. Serum electrolyte levels (particularly potassium) and blood pH levels should be monitored.

Very limited information exists on accidental ingestion of brimonidine in adults; the only adverse event reported to date has been hypotension. Symptoms of brimonidine overdose have been reported in neonates, infants, and children receiving brimonidine as part of medical treatment of congenital glaucoma or by accidental oral ingestion. Treatment of an oral overdose includes supportive and symptomatic therapy; a patent airway should be maintained.

PATIENT COUNSELING INFORMATION

Sulfonamide Reactions - Advise patients that if serious or unusual ocular or systemic reactions or signs of hypersensitivity occur, they should discontinue the use of the product and consult their physician.

Temporary Blurred Vision - Vision may be temporarily blurred following dosing with SIMBRINZA™ Suspension. Care should be exercised in operating machinery or driving a motor vehicle.

Effect on Ability to Drive and Use Machinery - As with other drugs in this class, SIMBRINZA™ Suspension may cause fatigue and/or drowsiness in some patients. Caution patients who engage in hazardous activities of the potential for a decrease in mental alertness.

Avoiding Contamination of the Product - Instruct patients that ocular solutions, if handled improperly or if the tip of the dispensing container contacts the eye or surrounding structures, can become contaminated by common bacteria known to cause ocular infections. Serious damage to the eye and subsequent loss of vision may result from using contaminated solutions *[see Warnings and Precautions]*. Always replace the cap after use. If solution changes color or becomes cloudy, do not use. Do not use the product after the expiration date marked on the bottle.

Intercurrent Ocular Conditions - Advise patients that if they have ocular surgery or develop an intercurrent ocular condition (e.g., trauma or infection), they should immediately seek their physician's advice concerning the continued use of the present multidose container.

Concomitant Topical Ocular Therapy - If more than one topical ophthalmic drug is being used, the drugs should be administered at least five minutes apart.

Contact Lens Wear - The preservative in SIMBRINZA™, benzalkonium chloride, may be absorbed by soft contact lenses. Contact lenses should be removed during instillation of SIMBRINZA™ Suspension, but may be reinserted 15 minutes after instillation.

©2013 Novartis

U.S. Patent No:

6,316,441

ALCON LABORATORIES, INC.

Fort Worth, Texas 76134 USA

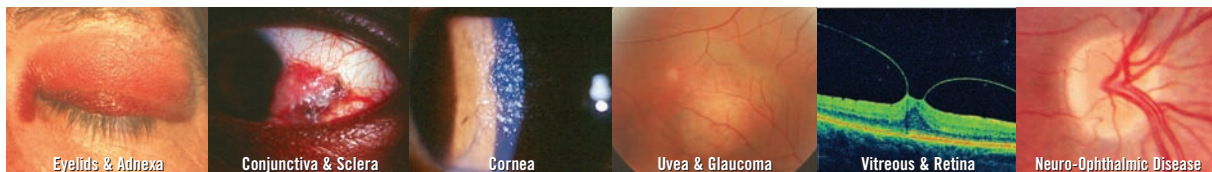
1-800-757-9195

alcon.medinfo@alcon.com

Alcon

a Novartis company

TABLE OF CONTENTS



EYELIDS & ADNEXA

Chronic Epiphora.....	6
Contact Dermatitis.....	7
Dacryocystitis	9
Orbital Cellulitis	12
Preseptal Cellulitis	14

CONJUNCTIVA & SCLERA

Ocular Surface Squamous Neoplasia.....	18
Conjunctival Abrasion and Laceration	19
Limbal Dermoid	21
Pyogenic Granuloma.....	24
Ocular Cicatricial Pemphigoid.....	26

CORNEA

Corneal Foreign Body	30
Band Keratopathy	32
Epithelial Basement Membrane Dystrophy.....	34
Granular Dystrophy.....	38
Understanding Corneal Collagen Crosslinking	39

UVEA & GLAUCOMA

Choroidal Nevus and Choroidal Melanoma	42
Herpetic Keratouveitis.....	45
Plateau Iris Syndrome	47
Angle Recession Glaucoma.....	50
2013 Medication Update	52

VITREOUS & RETINA

Idiopathic Polypoidal Choroidal Vasculopathy	56
Posterior Vitreous Detachment.....	58
Vitreomacular Traction Syndrome	61
Toxoplasmosis	63
Tractional Retinal Tears.....	66

NEURO-OPHTHALMIC DISEASE

Congenital Optic Disc Pit.....	70
Tonic Pupil	72
Optic Disc Drusen	75
Optic Nerve Head Hypoplasia.....	77
Skew Deviation.....	81

This publication addresses the management of various conditions with support from the best available peer-reviewed literature. This is done to provide the most up-to-date management of patients with various conditions and to indicate when patient referral is appropriate. In many cases, the management may necessitate treatment from a specialist or subspecialist. This manuscript does not recommend that any doctor practice beyond the scope of licensure or level of personal comfort. It is up to the reader to understand the scope of state licensure and practice only within those guidelines.

A Peer-Reviewed Supplement

The articles in this supplement were subjected to *Review of Optometry's* peer-review process. The magazine employs a double-blind review system for clinical manuscripts in which experts in each subject review the manuscript before publication. This supplement was edited by the *Review of Optometry* staff.



IN MEMORIAM: RICK BAY

Rick Bay impacted optometry in innumerable ways in his decades-long career, but mostly by being a consistent friend and advocate. As President and Publisher of the *Review* Group at Jobson Medical Information, he passionately approached each issue with due regard, exhibiting a loyal, consistent methodology balanced with sensibility and sensitivity. His optimism was contagious, often fueling an extended enthusiasm among his entire team and the many doctors who participate in *Review's* educational efforts. He managed his team by mentoring them and then standing out of their way. His persistence was admirable and palpable.

His charisma was unequalled, interlaced with a charm and focus that made everybody he addressed feel as though they were the most important person in the room. He was fun and clever, exhibiting a great sense of humor and a quick wit. Never was a bad word spoken by Rick and certainly not about Rick. Man or woman, young or old, you were always met with Rick's signature greeting, "Hey, Babe." For Rick, it was always about camaraderie and good times.

Rick enjoyed each day and used every minute from sun-up to sundown to accomplish his goals. He led others with a confident hand but was always able to reflect and learn from his colleagues. He served his fellow man over the course of a significant and storied career, enriching lives while continually innovating.

We remember his ingenuity, his creativity, his passion and his desire to make us all a little more competent and confident. The great accomplish more than everybody else because they are unencumbered when they see the imperfections in their plans. They know there is no such thing as failure, just a continuum of success. They drive forward, sometimes alone, with determination and verve and always with the goal in mind.

Rick Bay was a great man. He never sought admiration or adulation, though both came naturally to him. Every day his goal was to make us all a little better. Now, with his passing in December 2012, we must remember him by carrying the torch he lit, lighting the way for others, so that they might walk across a gentler path.

Rick had an unending enthusiasm for our project, *The Handbook of Ocular Disease Management*. He steadfastly supported its annual publication. He nudged and cajoled us year after year, edition after edition, so that we wouldn't give up writing. Though a consummate businessman, Rick always told us that he would publish the *Handbook* even if financial support or sponsorship was not in place and that he would pay out of his own pocket if he had to—such was his belief in us and this project. We can honestly say that if it weren't for Rick Bay, you wouldn't be reading this edition right now. We dedicate this edition to our dear friend Rick.

—Joseph Sowka, Andrew Gurwood & Alan Kabat



Joseph W. Sowka, OD, FAAO, Dipl., is a professor of optometry, program supervisor of the Primary Care with Emphasis in Ocular Disease residency and chair of the Clinical Sciences Department at Nova Southeastern University College of Optometry. At the college's Eye Care Institute, he is the director of the Glaucoma Service and chief of the Advanced Care Service. Dr. Sowka is a founding member of the Optometric Glaucoma Society (and its current vice president), the Optometric Retina Society and the Neuro-Ophthalmic Disorders in Optometry Special Interest Group. He can be reached at jsowka@nova.edu.



Andrew S. Gurwood, OD, FAAO, Dipl., is a professor of clinical sciences, an attending optometric physician in Module 3 of the Eye Institute of the Pennsylvania College of Optometry at Salus University and a member of the clinical staff of Albert Einstein Medical Center Department of Ophthalmology. He is a Founding member of the Optometric Retina Society and a member of the Optometric Glaucoma Society. Dr. Gurwood has lectured and published nationally and internationally on a wide range of subjects in ocular disease. He can be reached at agurwood@salus.edu.



Alan G. Kabat, OD, FAAO, is a professor at the Southern College of Optometry. His teaching responsibilities include didactic courses in ocular disease and clinical procedures. He also serves on the attending staff at the Eye Center in Memphis, where he supervises student clinicians and optometric residents in the primary and advanced care of patients. A recognized expert in the area of ocular surface disease, Dr. Kabat is a founding member of both the Optometric Dry Eye Society and the Ocular Surface Society of Optometry. He is also Associate Clinical Editor of *Review of Optometry*. He can be reached at akabat@sco.edu.

The authors have no direct financial interest in any product mentioned.

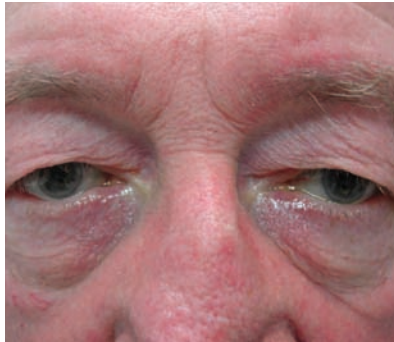CHRONIC EPIPHORA

Signs and Symptoms

Epiphora describes the spillover of tears from the eye onto the lids and ocular adnexa. It is not a diagnosis, but rather a clinical sign indicating insufficient tear drainage or, in some cases, overproduction. Numerous etiologic factors can lead to this phenomenon.¹⁻⁴ A distinction must be made, however, between chronic and acute epiphora. Chronic epiphora results from longstanding or unremitting disorders and presents a greater clinical challenge than acute epiphora. The acute variety most often results from irritative ocular conditions such as corneal foreign bodies or allergic conjunctivitis and usually resolves following the treatment of the associated disorder.

Patients with chronic epiphora report excessive lacrimation, in some cases to the point of tears actually streaming down their face. Symptoms may be exacerbated by environmental factors such as excessive cold, wind, pollen or other airborne particulate matter, sleep deprivation, near-point strain or emotional stress. Patients may report that they “cry very easily,” or that they are constantly wiping their eyes. Associated signs and symptoms of epiphora vary with the underlying etiology. Often, the patient complains of intermittently reduced acuity, owing to the excessive tears. Irritation to the lids, and in particular the inner canthus, is common because of the constant wetting of that area as well as the continuous mechanical abrasion of tissues, potentially leading to fissure formation.

Signs may include trichiasis, punctate epithelial keratopathy, lid-globe appositional abnormalities, punctal stenosis or other lacrimal outflow disorders (e.g., dacryocystitis or canaliculitis). Conjunctivochalasis—a condition in which redundant, “sagging” conjunctiva covers the lacrimal punctum and



A case of chronic epiphora associated with dermatochalasis.

impedes drainage through the nasolacrimal canaliculus—may also be observed on biomicroscopy.^{5,6}

Pathophysiology

Epiphora may result from a variety of conditions, but all presentations can be ascribed to one of four basic categories: (1) lid-globe appositional abnormalities, (2) obstructive lacrimal drainage disorders, (3) ocular surface disorders and (4) rarely, neurogenic lacrimal hypersecretory disorders.⁴

In conditions that alter the normal proximity of the lacrimal puncta to the ocular surface, elimination of tears is physically impeded. The most obvious illustration of this situation is acquired ectropion; other examples include entropion and floppy eyelid syndrome. Patients with chronic blepharitis may have punctal ectropion, which will be subtle compared to lid ectropion.

Obstructive disorders of the lacrimal system are similar to appositional abnormalities, except that in these conditions there is mechanical impediment of the outflow channel. Conditions that constitute obstructive disorders include acquired punctal stenosis, punctal atresia, canalicular stenosis or canaliculitis, retained or migrated punctal plugs, dacryocystitis, or lacrimal sac tumors. Occasionally, a large hordeolum or chalazion may induce punctal or canalicular stenosis. Additionally, they may also

impair lid-globe apposition with subsequent punctal ectropion. Congenital nasolacrimal obstruction is quite common and results from a lack of patency at the valve of Hasner.

Ocular surface disorders can, in some instances, induce excessive and symptomatic reflex tearing.^{2,7,8} While this is typically not significant enough to constitute epiphora, it should be considered when patients present with complaints of “excessive tearing.” Moderate to severe dry eye disease or exposure secondary to proptosis or facial nerve palsy are conditions that may induce reflex tear production resulting in epiphora.

Finally, hypersecretion of tears may be encountered in rare conditions affecting the nervus intermedius (that collection of nerves containing, among other things, parasympathetic lacrimal fibers, which joins the facial nerve at the level of the cerebellopontine angle). Compressive irritation of these fibers, or aberrant regeneration of cranial nerve VII after trauma may result in enhanced, inappropriate lacrimation, sometimes referred to as the gustolacrimal reflex or “crocodile tearing.”⁴ Neurogenic complications must be ruled out prior to initiating therapy for a lacrimal outflow problem.

Management

The treatment for the symptom of epiphora involves correcting the underlying disorder. For lid-globe appositional abnormalities (e.g., ectropion), the only cure is to physically reorient the punctum to be in proper alignment with the globe. Most often, this involves modified surgical resection of the lid tissue, or what is known as “horizontal lid shortening procedures.”^{9,10} Trichiasis and entropion can be corrected via serial eyelash epilation (or electrolysis) or by surgical repositioning, respectively. Obstructive disorders generally require invasive therapeutic measures.

Punctal and/or canalicular dilation

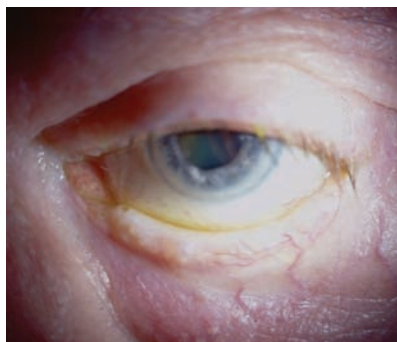
and irrigation is the most common management for stenosis of the lacrimal system; balloon canaliculoplasty may be performed in more severe instances.^{11,12} For cases of chronically flaccid or stenotic puncta, snip punctoplasty may be undertaken to more permanently enlarge the outflow orifice.^{12,13} If the blockade exists more distally within the nasolacrimal system, probing alone may be inadequate to alleviate the problem. In these cases, dacryocystorhinostomy (DCR) is often required; this creates a surgical bypass of the common canaliculus directly into the nasal mucosa, and is performed either with or without the use of a synthetic conduit (Lester Jones tube).¹⁴⁻¹⁶ Probing procedures are contraindicated in cases of inflammation, such as chronic dacryocystitis, or suspected neoplasm; DCR is used for these conditions.

When an ocular surface disorder is the etiology of chronic epiphora, treatment should be aimed at removing the provocative substance (foreign body, chemical) or replenishing the normal basal tear volume and improving the overall quality of the tear film. This may be achieved by using artificial tear preparations, immunomodulatory agents (e.g., Restasis, Allergan) or oral secretagogues (e.g., Salagen, Evoxac). Neurogenic hypersecretory disorders, when suspected, should be referred to a neurologist for evaluation and management.

Clinical Pearls

- “Tearing” is a common complaint in most optometric practices. For proper management, a clear distinction needs to be made between functional epiphora and occasional, symptomatic lacrimation.

- True epiphora constitutes a chronic problem warranting intervention, whereas normal tearing does not. Dilation and irrigation, the most common management strategy for punctal



Chronic epiphora associated with the presence of Bell's palsy.

and canalicular obstruction, is a quick and easy in-office procedure for managing appropriate cases. Realize, however, that this procedure is generally not permanent, and may need to be repeated several times each year to maximize patient comfort and satisfaction. Surgical intervention, when necessary, should be directed to an experienced oculoplastic specialist.

1. Narayanan K, Barnes EA. Epiphora with eyelid laxity. *Orbit*. 2005;24(3):201-3.
2. Singh Bhinder G, Singh Bhinder H. Reflex epiphora in patients with dry eye symptoms: role of variable time Schirmer-1 test. *Eur J Ophthalmol*. 2005;15(4):429-33.
3. Tu AH, Chang EL. Botulinum toxin for palliative treatment of epiphora in a patient with canalicular obstruction. *Ophthalmology*. 2005;112(8):1469-71.
4. Barañano DE, Miller NR. Long term efficacy and safety of botulinum toxin A injection for crocodile tears syndrome. *Br J Ophthalmol*. 2004;88(4):588-9.
5. Erdogan-Poyraz C, Mocan MC, Irkec M, Orhan M. Delayed tear clearance in patients with conjunctivochalasis is associated with punctal occlusion. *Cornea*. 2007;26(3):290-3.
6. Yokoi N, Komuro A, Nishii M, et al. Clinical impact of conjunctivochalasis on the ocular surface. *Cornea*. 2005;24(8 Suppl):S24-S31.
7. Blackmore KJ, Ainsworth G, Robson AK. Epiphora: an evidence based approach to the 12 minute consultation. *Clin Otolaryngol*. 2010;35(3):210-4.
8. Bielory L. Ocular allergy and dry eye syndrome. *Curr Opin Allergy Clin Immunol*. 2004;4(5):421-4.
9. Eliasoph I. Current techniques of entropion and ectropion correction. *Otolaryngol Clin North Am*. 2005;38(5):903-19.
10. Vick VL, Holds JB, Hartstein ME, Massry GG. Tarsal strip procedure for the correction of tearing. *Ophthalm Plast Reconstr Surg*. 2004;20(1):37-9.
11. Zoumalan CI, Maher EA, Lelli GJ Jr, Lisman RD. Balloon canaliculoplasty for acquired canalicular stenosis. *Ophthalm Plast Reconstr Surg*. 2010;26(6):459-61.
12. Soiberman U, Kakizaki H, Selva D, Leibovitch I. Punctal stenosis: definition, diagnosis, and treatment. *Clin Ophthalmol*. 2012;6:1011-8. doi: 10.2147/OPHTH.S31904. Epub 2012 Jul 3.
13. Kashkouli MB, Beigi B, Astbury N. Acquired external punctal stenosis: surgical management and long-term follow-up. *Orbit*. 2005;24(2):73-8.
14. Lee DW, Chai CH, Loon SC. Primary external dacryocystorhinostomy versus primary endonasal dacryocystorhinostomy: a review. *Clin Experiment Ophthalmol*. 2010;38(4):418-26.
15. Liarakos VS, Boboridis KG, Mavrikakis E, Mavrikakis I. Management of canalicular obstructions. *Curr Opin Ophthalmol*. 2009;20(5):395-400.
16. Hussain RN, Kanani H, McMullan T. Use of mini-monoka stents for punctal/canalicular stenosis. *Br J Ophthalmol*. 2012;96(5):671-3.

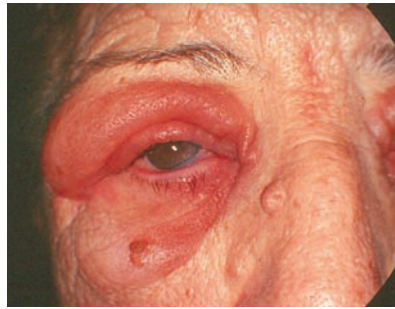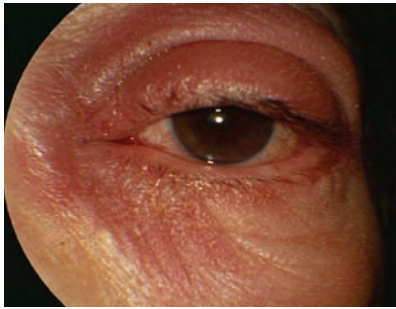
CONTACT DERMATITIS

Signs and Symptoms

Contact dermatitis is an inflammatory reaction of the skin, including the eyelid(s) and periocular adnexa. The presentation may occur unilaterally or bilaterally, depending upon the antigenic exposure. In acute cases, the patient may present with diffuse lid erythema and edema, as well as pruritic vesicles or bullae.¹ Chronic cases may show eczema, a characteristic thickening and scaling of the involved skin typically seen in atopic dermatitis.²

Common symptoms in both the acute and chronic forms of contact dermatitis include intense itching and burning of the skin and eyes, and associated tearing. The conjunctiva may also be involved, demonstrating variable bulbar injection and chemosis when included. Palpebral follicles may be seen in severe cases. Corneal involvement is rare, though chronic eye rubbing may lead to punctate keratopathy or epithelial erosion. Vision is not typically affected to any substantial degree, and preauricular lymphadenopathy is characteristically absent.

The history is of paramount importance in correctly diagnosing contact dermatitis. Many cosmetics, cleaning agents, fabrics, fragrances, medications, nickel and even metallic jewelry can be implicated in this skin reaction.²⁻⁴ Typically, since the reaction connotes some acute exposure to an offending allergen, it is assumed that the patient recently encountered something “new.”



Two presentations of contact dermatitis: mild (left) and severe (right).

However, many agents implicated in contact dermatitis represent weak sensitizers, and the exposure may occur over weeks, months or even years.⁴ In cases involving the ocular tissues, one should give particular consideration to those substances which are readily applied or coincidentally touch the skin around the eyes—particularly makeup (eyeliner, eye shadow, mascara) or makeup remover, sunscreen, contact lens solutions or metal spectacle frames. A wide range of ophthalmic medications may also have the capacity to induce allergic contact dermatitis.⁵

Pathophysiology

Contact dermatitis may be subdivided into several categories: irritant contact dermatitis, allergic contact dermatitis and photoallergic contact dermatitis.

Irritant contact dermatitis (ICD) accounts for nearly 80% of all cases of contact dermatitis seen clinically.¹ The condition, also referred to as non-allergic contact dermatitis, represents a non-preprogrammed, non-immunologic, local inflammatory reaction to a chemical or physical irritant. This may include substances such as soaps or detergents, solvents (e.g., paint thinner, acetone) or particulate matter such as fiberglass insulation. Typically, the severity of the ICD reaction is proportionate to the amount and duration of irritant exposure. The mechanism of action involves a direct, local cytotoxic effect on the

epidermis, leading to subsequent keratinocyte damage.⁶

The most important detail to recognize about ICD is that it can affect any individual, regardless of their immune status. A well-known example of ICD involves exposure to the plant *Toxicodendron radicans*, better known as poison ivy. Atopic individuals are especially susceptible to ICD, and may have a lower threshold for irritant exposure.

Allergic contact dermatitis (ACD), by its very definition, affects only individuals who are genetically preprogrammed toward allergic hypersensitivity. Like all allergic reactions, ACD occurs in two phases: a sensitization process, in which specific antibodies are generated toward the allergen, and an elicitation phase, in which the actual cellular response occurs. The mechanism of ACD involves a delayed, or Type IV, hypersensitivity reaction.⁶ This is a cell-mediated response, which employs discrete subpopulations of T-lymphocytes and immunoregulatory cytokines, including tumor necrosis factor alpha and interleukins 1, 13 and 18.⁷ Mast cells, which play a pivotal role in immediate Type I hypersensitivity reactions such as allergic conjunctivitis, are not central to Type IV reactions like ACD. However, the mast cell still has an important function, as it indirectly helps to control neutrophil recruitment.⁸

Photoallergic contact dermatitis (PACD) is an eczematous skin reaction initiated by an otherwise benign

substance on the skin that becomes noxious when exposed to ultraviolet light. We refer to substances that induce PACD as photosensitizing agents. PACD characteristically occurs only with areas of exposed skin, such as the hands and face. Known photosensitizing agents include tar-based products, octyl dimethyl PABA (an ingredient in some commercial sunscreen formulas), certain forms of vegetation (including carrot, lemon and mustard plants) some oral antibiotics, such as tetracycline, and topical NSAID medications, such as ketoprofen, diclofenac and indomethacin.^{9,10}

Management

In cases of contact dermatitis, attempts should be made to identify the causative agent. Often, this can be accomplished with a careful history, but in more challenging cases epicutaneous patch testing can help to isolate the offending substance. Patch testing involves standardized samples of known allergens, placed on small delivery vehicles and applied to the skin of the upper back for two days.^{11,12} The test is typically performed only by an experienced dermatologist.

Once identified, the ideal long-term solution is to remove or avoid the causative agent. Short-term management involves emollients, treatment of secondary infection (if present) and down-regulation of the immune response. The easiest method of arresting and reversing the outspilling of chemical modulators is the cold compress. Here, vasoconstriction slows the spread of edema and begins to limit the reaction.

Topical corticosteroids are the first-line medicinal therapy for most individuals, since these agents directly suppress the recruitment of polymorphonuclear leucocytes and reverse capillary permeability.¹² Low-potency steroids such as hydrocortisone and desonide may be safer for use on the face, though

stronger steroids such as clobetasol propionate (Olux, Stiefel Labs) or betamethasone dipropionate (Diprolene, Merck) can be employed for moderate to severe disease.¹³ Steroid creams or lotions (preferable to ointments) used twice daily for 10-14 days are usually very effective. Care must be taken to apply these preparations only to the skin of the lids and ocular adnexa, as they are not appropriate for use in the eye.

Stronger periocular steroids may precipitate intraocular pressure elevation and should be monitored carefully. Also, it is important to note that topical steroids may in some cases themselves be allergenic, confounding the management of these patients.¹⁴ Calcineurin inhibitors such as tacrolimus (Protopic ointment, Astellas) and pimecrolimus (Elidel cream, Medicis) may benefit subjects who are poor candidates for topical corticosteroid therapy.¹² More severe cases may require systemic corticosteroids. Oral prednisone (0.5-1mg/kg/d for 2-3 days, and tapered over 1-2 weeks) is the preferred course of therapy for recalcitrant contact dermatitis.^{1,6}

The use of antihistamines is somewhat controversial in managing contact dermatitis. Since histamine release from mast cells is not central to the pathophysiology of the disorder, antihistamines would seem to be superfluous. However, oral agents such as cetirizine 10mg (Zyrtec, McNeil) or desloratadine 5mg (Clarinx, Merck) once daily may help to curtail the itching to some extent, and hence may be beneficial in addition to topical corticosteroid therapy.

For conjunctivitis associated with contact dermatitis, supportive therapy is beneficial. This includes, first and foremost, cold compresses and liberal use of ocular lubricants. Topical antihistamine/mast cell stabilizer products (e.g., Pataday, Alcon; Lastacaft, Allergan) once daily may provide palliative relief of conjunctival itching, as well as ocular

swelling and hyperemia. More severe involvement, however, may warrant topical ophthalmic corticosteroids, such as prednisolone acetate 1% (Pred Forte, Allergan) or loteprednol etabonate 0.5% (Lotemax, Bausch + Lomb) every 2-4 hours for several days.

Clinical Pearls

- The skin of the eyelid, by virtue of its anatomically thin structure, is particularly susceptible to inflammation by irritant or allergic contact dermatitis. Profound reactions may be seen in this area.
- The differential diagnosis of contact dermatitis must include more extreme conditions such as preseptal cellulitis, orbital cellulitis, chlamydial infection, oculoglandular conjunctivitis and carotid cavernous fistula. A vesicular or pustular presentation warrants investigation for herpes zoster or simplex blepharitis.
- Contact dermatitis is self-limiting only in cases where the inciting agent is identified and removed. Therapy with anti-inflammatory agents and palliative anti-allergy products can hasten the recovery and provide significant amelioration of symptoms.
- Patients should be counseled that topical and oral steroids can raise intraocular pressure as well as thin the skin. Anyone placed on these agents must be reassessed to rule out these complications.

1. Mark BJ, Slavin RG. Allergic contact dermatitis. *Med Clin North Am.* 2006 Jan;90(1):169-85.
2. Watkins S, Zippin J. Allergic contact dermatitis and cosmetics. *Cutis.* 2012 Oct;90(4):201-4.
3. Brandão MH, Gontijo B. Contact sensitivity to metals (chromium, cobalt and nickel) in childhood. *An Bras Dermatol.* 2012 Mar-Apr;87(2):269-76.
4. Biehl KA, Warshaw EM. Allergic contact dermatitis to cosmetics. *Dermatol Clin.* 2006 Apr;24(2):215-32, vii.
5. Mughal AA, Kalavala M. Contact dermatitis to ophthalmic solutions. *Clin Exp Dermatol.* 2012 Aug;37(6):593-7; quiz 597-8.
6. Usatine RP, Riojas M. Diagnosis and management of contact dermatitis. *Am Fam Physician.* 2010 Aug 1;82(3):249-55.
7. Inorvaia C, Frati F, Verna N, et al. Allergy and the skin. *Clin Exp Immunol.* 2008 Sep;153 Suppl 1:27-9.

8. Biedermann T, Kneilling M, Mailhammer R, et al. Mast cells control neutrophil recruitment during T cell-mediated delayed-type hypersensitivity reactions through tumor necrosis factor and macrophage inflammatory protein 2. *J Exp Med.* 2000 Nov 20;192(10):1441-52.
9. Deleo VA. Photocontact dermatitis. *Dermatol Ther.* 2004;17(4):279-88.
10. Kerr A, Ferguson J. Photoallergic contact dermatitis. *Photodermatol Photoimmunol Photomed.* 2010 Apr;26(2):56-65.
11. White JM. Patch testing: what allergists should know. *Clin Exp Allergy.* 2012 Feb;42(2):180-5.
12. Morris S, Barlow R, Selva D, Malhotra R. Allergic contact dermatitis: a case series and review for the ophthalmologist. *Br J Ophthalmol.* 2011 Jul;95(7):903-8.
13. Li LY, Cruz PD Jr. Allergic contact dermatitis: pathophysiology applied to future therapy. *Dermatol Ther.* 2004;17(3):219-23.
14. Gonul M, Gul U. Detection of contact hypersensitivity to corticosteroids in allergic contact dermatitis patients who do not respond to topical corticosteroids. *Contact Dermatitis.* 2005 Aug;53(2):67-70.

DACRYOCYSTITIS

Signs and Symptoms

Acute dacryocystitis (lacrimal sac mucocele) is an infection of the lacrimal sac.¹⁻⁷ It can occur as result of the elements or remnants of trauma, acute or long-standing lacrimal system obstruction or from bacterial infection sourced to the contents of the tear film and or conjunctiva.¹⁻⁷ Dacryocystitis may also result from an extension of infective and inflammatory processes occurring within the nose or paranasal sinuses.^{3,4} In some instances, the infection (initially confined to the lacrimal sac) can extend to the soft tissues, causing preseptal cellulitis, or invade the orbital contents, resulting in orbital cellulitis.¹⁻⁷

Acute dacryocystitis is uncommon in children and young adults under age 30 without a history of congenital nasolacrimal duct obstruction, facial trauma or an underlying systemic condition such as infectious mononucleosis (Epstein-Barr).^{1,8} The condition is typically unilateral.

Dacryocystitis is more common in the 5th to 6th decade of life, with a mean age of 55.5 years, and can be acute or chronic in nature.¹⁻⁵ Women tend to have blockages in the nasolacrimal drainage system more often than men,

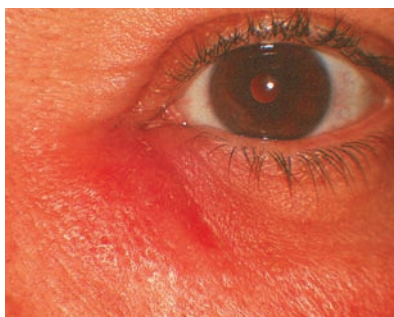
with the highest incidence found in postmenopausal women.¹⁻⁵ It is thought that this occurs because the bony lacrimal duct is smaller in women than in men.¹

Acute dacryocystitis often presents with symptoms of severe pain of the inner canthus in the area of the lacrimal sac just under the medial canthal ligament. Local redness, swelling, epiphora, secondary conjunctivitis, mucoid discharge in the morning and an enlarged, lacrimal sac that is tender to the touch are typical features. Highly diagnostic is mucopurulent discharge regurgitating from the puncta when palpated.¹⁻⁸ A firm round nodule is often palpable in the setting of adjacent orbital or preseptal cellulitis.¹⁻⁷ Patients with acute disease are rarely febrile.

Pathophysiology

The nasolacrimal ducts consist of the upper and the lower lacrimal canaliculus, the lacrimal sac and the nasolacrimal duct.⁹⁻¹⁸ They drain the tear fluid from the ocular surface into the lower meatus of the nose.⁹⁻¹⁸ The puncta define the outermost boundary and beginning of the nasolacrimal apparatus. Each punctum respectively leads into the superior and inferior canaliculus, which extends and expands 2mm in the vertical direction (the superior canaliculus directed superiorly and the inferior canaliculus directed inferiorly) to the ampulla—the reservoir-like anatomic landmark at the base of each 2mm canalicular arm. From there, the canaliculus makes its turn medially toward the nasolacrimal sac.^{11,12} In 90% of the population, the superior and inferior canaliculi come together to form a common canaliculus that drains into the lacrimal sac.¹¹ In 10% of the population, the superior and inferior canaliculi connect directly into the lacrimal sac.¹¹

The nasolacrimal apparatus continues through the lacrimal sac, which may have a vertical dimension of up



Dacryocystitis.

to 10mm and exits the sac inferiorly with its fluid flow regulated by both muscular contraction and the valve of Krause.¹¹⁻¹³ In the vicinity of the anterior lacrimal crest of the maxillary bone, the lacrimal sac becomes the nasolacrimal duct. It traverses through a bony duct bounded by the lacrimal bone medially and the maxillary bone laterally, encountering the regulatory valve of Rosenmüller.^{11,12,15} This portion of the duct measures approximately 12mm.^{11,12,15} An additional 5mm of the lacrimal duct is membranous and opens into the inferior meatus lateral to the inferior turbinate.

The valve of Hasner is situated at the distal end of the duct.^{11,12,15} This structure functions as a unidirectional valve that allows tears to freely drain out of the lacrimal system into the inferior nasal meatus, preventing retrograde flow.^{11,12} The valve also functions to block nasal material from entering the system by closing when there is a drastic increase in nasal pressure during events like coughing or sneezing.^{11,12}

The epithelial lining of the lacrimal sac and the nasolacrimal duct is covered by microvilli.⁹ Antimicrobial defense mechanisms are represented by antimicrobial peptides IgA and immunocompetent cells (lymphocytes and macrophages).⁹ Under normal circumstances, the embedded blood vessels of the system maintain vegetative control deep within the system in a landmark area referred to as the cavernous body.⁹

Malfunctions in the cavernous body and/or in its innervations may lead to disturbances in the tear flow cycle, creating ocular congestion or total occlusion of the lacrimal passage.¹⁻¹⁹

Any descending infection from the eye or ascending infection from the nose or sinuses can initiate swelling of the mucous membrane, remodeling of the tissues, creating malfunctions in the cavernous body with reactive immunomodulation and occlusion of the lacrimal passage.¹⁻¹⁹ Alterations in the ductal epithelium and the lamina propria, encompassing the lacrimal sac and nasolacrimal duct, can permit microbial growth.^{1-3,19}

The most common gram-positive infective organisms include *Streptococcus pneumoniae*, *Staphylococcus aureus* and *Staphylococcus epidermidis*, while *Haemophilus influenzae*, *Pseudomonas aeruginosa*, *Serratia marcescens* and *Klebsiella pneumoniae* are the leading gram-negative bacteria.^{1,2,20} Mononucleosis and coliform bacteria are rare but documented sources of dacryocystitis.^{5,21} One unique case documents the organism *Pantoea* presumed to be obtained through exposure to dog feces.²²

Management

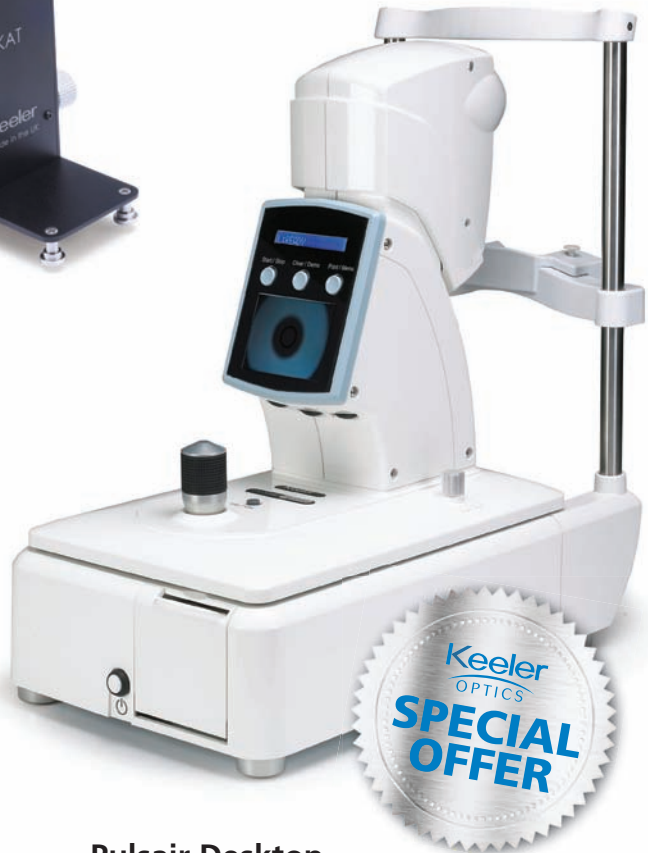Acute onset dacryocystitis in adults is initially managed conservatively with warm compresses, massage, topical antibiotic drops and ointments and a 7-10 day course of oral antibiotics.^{1-8,20-22} The topical antibiotics of first choice include the fourth-generation fluoroquinolones. However, organisms involved in acute dacryocystitis also respond well to gentamicin and chloramphenicol.^{1,20-22} The oral antibiotics of first choice include Augmentin (amoxicillin/clavulanoic acid, GlaxoSmithKline), Keflex (cephalexin) and Levaquin (levofloxacin, Ortho-McNeil).²¹

Gentle digital massage (to express the contents of the sac) can be

Tonometry Done Right



KAT
Keeler quality.



Pulsair Desktop
Smallest footprint and simple to use!

Purchase a Pulsair Desktop before July 31, 2013 and get a \$1,300 Instant Rebate!



Intellipuff
The standard for hand held mobility.

Buy Online!
keelerusa.com



Keeler
OPTICS

attempted for lesions discovered early.²² Unfortunately, this therapy tends to be ineffective, with less than 25% of lesions resolving spontaneously or with hot compresses alone.²²

Mild cases of dacryocystitis in children often self-resolves without any consideration of dacryocystorhinostomy (DCR) necessary.⁸ More severe forms of dacryocystitis in children are managed more aggressively as it has a high risk of causing sepsis secondary to an immature immune system.^{1,20,24} In these instances, admission to the hospital is common so that prompt blood culture, computed axial tomography (CT scan) and IV therapy can be instituted.^{1,20} Treatment in admitted cases is usually accomplished using intravenous Augmentin.

Probing and biopsy of the nasolacrimal system is not mandatory.²⁵ It must only be done in cases where there is poor return to function following event resolution or chronic, recurring issues. Standard culture studies can be obtained from discharge and should include blood and chocolate agar, Sabouraud's media (for fungi), Schaedler media and thioglycolate broth.¹

Surgical solutions are needed in both acute and chronic cases when conservative treatments fail.^{1-5,26}

Dacryocystorhinostomy is the gold standard for treating acute adult dacryocystitis.²⁰⁻²³ DCR involves resection of the bony area around the nasolacrimal canal for the purposes of gaining access to the stenotic area within the drainage system. The procedure facilitates the shunting of the tear flow around any blockage by creating a new anastomotic passageway.¹⁻⁴ The procedure is gaining popularity because it permits the surgeon the ability to immediately drain and culture the abscess. New techniques of completing DCR include endocanalicular laser and endoscopic intranasal surgical techniques.^{20,26} These revolutionary methods allow the cavity to be accessed without opening the entire passage.²⁶

Clinical Pearls

- Epiphora is the term for excessive tearing, which is a principal sign and symptom of nasolacrimal apparatus obstruction.
- Cases of epiphora should be evaluated for nasolacrimal apparatus obstruction using the Jones test and fluorescein dye disappearance test.
- Dilation and irrigation of the nasolacrimal system should never be attempted during an episode of active infection.

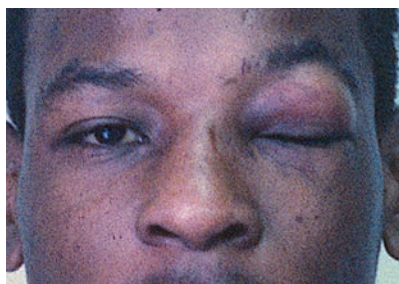1. Pinar-Sueiro, S, Sota, M, Lerchundi, T et al. Dacryocystitis: Systemic approach to diagnosis and Therapy. *Current Infectious Disease Reports*. 2012;14(2):137-146.
2. Pinar-Sueiro, S, Fernandez-Hermida, RV, Gibelalde, A, et al. Study on the effectiveness of antibiotic prophylaxis in external dacryocystorhinostomy: A review of 697 cases. *Ophthal Plast Reconstr Surg*. 2010;26(6):467-72.
3. Paulsen, FP, Thale, AB, Maune, S, Tillmann, BN. New insight into the pathophysiology of primary acquired dacryostenosis. *Ophthalmology*. 2001;108(12):2329-36.
4. Perry, LJP, Jakobiec, FA, Zakka, FA, et al. Giant dacryocystomucopycele in an Adult: A review of lacrimal sac enlargements with clinical and histopathologic differential diagnoses. *Surv Ophthalmol*. 2012;57(5):474-85.
5. Martins MC, Ricardo JR, Akaishi PM, Velasco e Cruz AA. Orbital abscess secondary to acute dacryocystitis: case report. *Arq Bras Oftalmol*. 2008;71(4):576-8.
6. Maheshwari R, Maheshwari S, Shah T. Acute dacryocystitis causing orbital cellulitis and abscess. *Orbit*. 2009;28(2-3):196-9.
7. Mauriello JA Jr, Wasseman BA. Acute dacryocystitis: an unusual cause of life-threatening orbital intraconal abscess with frozen globe. *Ophthal Plast Reconstr Surg* 1996 ;12(4):294-5.
8. Ghauri AJ, Keane PA, Scotcher SM, et al. Acute dacryocystitis associated with Epstein-Barr virus infection. *Orbit*. 2011;30(5):245-8.
9. Paulsen F. The human nasolacrimal ducts. *Adv Anat Embryol Cell Biol*. 2003;170:III-XI, 1-106.
10. Van Santvliet L., Ludwig A. Determinants of eye drop size. *Surv Ophthalmol* 2004;49(2):197-213.
11. Francisco FC, Carvalho AC, Francisco VF, et al. Evaluation of 1000 Lacrimal Ducts by Dacryocystography. *Br J Ophthalmol* 2007;91(1):43-6.
12. Oyster, CW. The Eyelids and the Lacrimal System. In: Oyster, C.W. *The Human Eye Structure and Function*. Sunderland Massachusetts, Sinauer Associates, Inc. 1999; 291-320.
13. Cher I. Fluids of the ocular surface: concepts, functions and physics. *Clin Experiment Ophthalmol*. 2012;40(6):634-43.
14. Zoumalan CI, Joseph JM, Lelli GJ Jr, et al. Evaluation of the canalicular entrance into the lacrimal sac: an anatomical study. *Ophthal Plast Reconstr Surg*. 2011;27(4):298-303.
15. Paulsen FP, Schaudig U, Thale AB. Drainage of tears: Impact on the ocular surface and lacrimal system. *The Ocular Surface*. 2003;1(4):180-91.
16. Johnson ME, Murphy PJ. Temporal changes in the tear menisci following a blink. *Experimental Eye Research*. 2006;83:517-25.
17. Sahlin S, Chen E, Kaugesaar T, et al. Effect of eyelid botulinum toxin injection on lacrimal drainage. *American Journal of Ophthalmology* 2000;129(4):481-486.
18. Zhuang L, Sylvester CL, Simons JP. Bilateral congenital lacrimal fistulae: a case report and review of the literature. *Laryngoscope*. 2010;120 Suppl 4:S230.
19. Jones LT. An anatomical approach to problems of the eyelids and lacrimal apparatus. *Archives of Ophthalmology*. 1961.66:137-50.
20. Mandal R, Banerjee AR, Biswas MC, et al. Clinico-bacteriological study of chronic dacryocystitis in adults. *J Indian Med Assoc*. 2008;106(5):296-8.
21. McKeag D, Kamal Z, McNab AA, Sheorey H. Combined coliform and anaerobic infection of the lacrimal sac. *Clin Experiment Ophthalmol*. 2002;30(1):52-4.
22. Zuberbuhler B, Carifi G, Leatherbarrow B. Acute dacryocystitis in a 2-year old child caused by *Pantoea*. *Orbit*. 2012;31(1):13-14
23. Deangelis D, Hurwitz J, Mazzulli T. The role of bacteriologic infection in the etiology of nasolacrimal duct obstruction. *Can J Ophthalmol*. 2001;36(3):134-39.
24. Pinar-Sueiro S, Fernandez-Hermida RV, Gibelalde A, et al. Study on the effectiveness of antibiotic prophylaxis in external dacryocystorhinostomy: A Review of 697 Cases. *Ophthal Plast Reconstr Surg*. 2010;26(6):467-72.
25. Merkonidis C, Brewis C, Yung M, Nussbaumer M. Is routine biopsy of the lacrimal sac wall indicated at dacryocystorhinostomy? A prospective study and literature review. *Br J Ophthalmol*. 2005;89(12):1589-91.
26. Saeed BM. Endoscopic DCR without stents: clinical guidelines and procedure. *Eur Arch Otorhinolaryngol*. 2012;269(2):545-9.

ORBITAL CELLULITIS

Signs and Symptoms

Orbital cellulitis is a vision-threatening infection of the tissues of the orbit.¹⁻⁵ The condition results from direct spread of infection from the ocular adnexa and adjacent orbital structures to the orbit.⁶⁻¹³ Signs and symptoms include exophthalmos (proptosis), ocular displacement with or without diplopia, conjunctival chemosis, eye lid edema with injection, palpable warmth, pain upon palpation, blurred vision, possible relative afferent pupillary defect, ophthalmoplegia, generalized malaise and fever.⁵⁻⁷

Rare in general ophthalmic practice, orbital cellulitis is more common in children than adults.^{14,15} It has been organized using the modified Chandler classification into two forms: the pre-septal form (Stage I-Preseptal cellulitis,



Orbital cellulitis.

Stage II-orbital cellulitis, anterior to the orbital septum) and the retroseptal form (Stage III-Subperiosteal abscess, Stage IV-Orbital abscess, Stage V-Cavernous sinus thrombosis) posterior to the orbital septum.^{2,8} Etiologies include spread of dental infection, frontal subperiosteal abscess associated with and without underlying frontal bone osteomyelitis (Pott's puffy tumor), dacryoadenitis, lacrimal gland abscess, sinusitis (rhinosinusitis), trauma, eyelid infection secondary to puncture wound, foreign body, meningitis and intraocular retinoblastoma.⁶⁻²¹ Documented systemic illnesses increasing the risk of an event include diabetes, septicemia, malignancy and immunosuppression.⁷ In adults, there may be a slight predilection for male gender.²²

Pathophysiology

The etiology of orbital cellulitis is secondary to one of two mechanisms: either direct invasion to the region or infection spread through the blood stream to the paranasal air sinuses, which communicate with orbital contents.¹⁹⁻²⁷ Ultimately, the condition induces its life- and vision-threatening complications by way of infection proliferation within the enclosed compartment of the orbit and cranium.¹⁻²⁷ The infection has the capability to dissect under the periosteum of the orbital bones and lead to subperiosteal abscess or intraorbital abscess with formed progressive cellulitis.²⁶⁻²⁸

The associated activation of immuno-

logical cytokines and chemoattractants impact visual function through mechanical compression. Vision loss in orbital cellulitis occurs via compressive optic neuropathy, where the volume of orbital edema and infection expands applying pressure against the nerve arresting its normal function and limiting its perfusion. Chronic perfusion interruption induced by mass effect can cause tissue death and permanent dysfunction.

Organisms involved in orbital cellulitis include anaerobic, aerobic and microaerophilic bacteria, fungi and parasites.²⁴⁻³⁶ The common organisms include *Staphylococcus aureus*, *Streptococcus pneumoniae*, *Haemophilus influenzae*, *Moraxella catarrhalis*, group A-hemolytic streptococci, other streptococcal species, anaerobes such as *Pseudomonas* and methicillin-resistant *Staphylococcus aureus* (MRSA).^{1-4,8-22,33,37}

Fungal infections of the orbit tend to occur primarily in immunocompromised individuals.³⁵ One particularly aggressive subtype of mucormycosis caused by *Apophysomyces elegans* has been reported as occurring in immunocompetent individuals after contamination from traumatic inoculation.^{35,36}

The medial orbital wall is thin and fenestrated, occupied by numerous small vessels and nerves along with natural communicative defects (Zuckerkandl dehiscences).^{24,26-28} The combination of thin bone, with foramina and naturally occurring defects, allows for communication of infectious material between the ethmoid air cells and the subperiosteal space.^{27,28} The periorbita (periosteal lining), in the region of the medial orbital wall is adherently loose. Infections taking root in this region may easily move laterally, superiorly and inferiorly within the subperiosteal space.^{24,26-28} Additionally, the intermuscular septa of the extraocular muscles along with adipose tissue extend from muscle insertions to their origins at the annulus of Zinn (posteriorly), making infection

extension between the extraconal and intraconal orbital spaces possible.²⁹⁻³¹

The fibroadipose tissue in the eyelid and eyebrow along with fibrous septa within the submuscular fibroadipose tissue become contiguous with more compact lamellae of the orbital septum posteriorly making spread of infection within the eyelid tissues possible. Since venous drainage from the middle third of the face, orbit and paranasal sinuses is mainly via the veins without valves that connect to the orbit, infections in the region may move antegrade or retrograde.²²⁻³¹

Management

The retroseptal form of orbital cellulitis, sometimes referred to as "true" orbital cellulitis, is the most severe presentation of the disease.¹ It has the ability to impact vision and survival.^{1-4,8-22,33,37} Clinical examination and urgent CT or MRI scanning with contrast are necessary in the evaluation of the extent and severity, surgical planning and antibiotic selection.^{1-4,8-22,33,37-40}

Orbital inflammation should be classified by the modified Chandler's criteria as preseptal or postseptal. Most preseptal cases (Chandler I, II) respond to oral antibiotics.^{1-4,8-22,33,37,38} Most cases of postseptal cellulitis (Chandler III, IV, V) are managed with intravenous antibiotics, although surgical therapy is required for some abscesses when improvement is not seen within 48 hours of intravenous treatment.^{26,38}

Children under nine years of age respond better to medical management than older patients, but recent studies confirm that even children over age nine with small or moderate-sized abscesses and normal vision should undergo medical antibiotics before surgical intervention.³⁸ Medial subperiosteal abscesses that fail medical therapy are usually drained endoscopically, whereas lateral or intraconal abscesses require an open procedure.³⁸

The oral antibiotics of first choice should be a broad spectrum agent with good central nervous system penetration such as clindamycin or third-generation cephalosporins.³⁸ Intravenous agents include the third-generation cephalosporin such as cefotaxime, ceftriaxone or cefuroxime.³⁸ Orbital cellulitis with any nasal origin or any spread to the ethmoidal region can impact breathing. Secondary nasal congestion can be treated with topical oxymetazoline or Afrin nasal spray QD.³⁸

Ocular aspects of orbital cellulitis that require local intervention include lowering elevated intraocular pressure occurring from compressive and congestive forces and treating any concomitant anterior uveitis.³⁹⁻⁴²

Clinical Pearls

- Orbital cellulitis is a leading cause of proptosis in children.
- Insect bites, especially those obtained via spiders are known etiologies of orbital cellulitis.
- Orbital cellulitis is a vision- and life-threatening condition. These patients should be referred to an infectious disease specialist for hospital admission.
- Prompt medical attention is required to preserve function and reduce the risk of extreme complications such as cavernous sinus thrombosis, meningitis, brain abscess and blood sepsis.⁴³

1. Mouriaux F, Rysanek B, Babin E, et al. Orbital cellulitis. *J Fr Ophthalmol*. 2012;35(1):52-7.
2. Uzcátegui N, Warman R, Smith A, et al. Clinical practice guidelines for the management of orbital cellulitis. *J Pediatr Ophthalmol Strabismus*. 1998;35(2):73-9.
3. Nageswaran S, Woods CR, Benjamin DK Jr, et al. Orbital cellulitis in children. *Pediatr Infect Dis J*. 2006;25(8):695-9.
4. Papier A, Tuttle DJ, Mahar TJ. Differential diagnosis of the swollen red eyelid. *Am Fam Physician*. 2007;76(12):1815-24.
5. Witteborn M, Mennel S. Restricted eyeball with proptosis. *Ophthalmology*. 2011;108(3):275-7.
6. Filips RF, Liudahl JJ. Asymptomatic posterior orbital cellulitis resulting from ethmoid/maxillary sinusitis. *J Am Optom Assoc*. 1997;68(1):55-60.
7. Hershey BL, Roth TC. Orbital infections. *Semin Ultrasound CT MR*. 1997;18(6):448-59.

8. Chandler JR, Langenbrunner DJ, Stevens ER. The pathogenesis of orbital complications in acute sinusitis. *Laryngoscope*. 1970;80(9):1414-28.
9. DeGroos FC, Liao JC, Ramey NA, et al. Management of odontogenic orbital cellulitis. *J Med Life*. 2011;4(3):314-7.
10. Nisa L, Landis BN, Giger R. Orbital involvement in Pott's puffy tumor: a systematic review of published cases. *Am J Rhinol Allergy*. 2012;26(2):e63-70.
11. Mathias MT, Horsley MB, Mawn LA, et al. Atypical presentations of orbital cellulitis caused by methicillin-resistant *Staphylococcus aureus*. *Ophthalmology*. 2012;119(6):1238-43.
12. Dewan MA, Meyer DR, Wladis EJ. Orbital cellulitis with subperiosteal abscess: demographics and management outcomes. *Ophthalm Plast Reconstr Surg*. 2011;27(5):330-2.
13. Chaudhry IA, Shamsi FA, Elzaridi E, et al. Outcome of treated orbital cellulitis in a tertiary eye care center in the middle East. *Ophthalmology*. 2007;114(2):345-54.
14. Dutton JJ. Orbital diseases. In: Yanoff M, Duker JS. *Ophthalmology*. Mosby-Elsevier, China, 2009:1450-64.
15. Ho CF, Huang YC, Wang CJ, et al. Clinical analysis of computed tomography-staged orbital cellulitis in children. *J Microbiol Immunol Infect*. 2007;40(6):518-24.
16. Sindhu K, Downie J, Ghabrial R, Martin F. Aetiology of childhood proptosis. *J Paediatr Child Health*. 1998;34(4):374-6.
17. Ben Simon GJ, Bush S, Selva D, McNab AA. Orbital cellulitis: a rare complication after orbital blowout fracture. *Ophthalmology*. 2005;112(11):2030-4.
18. Mullaney PB, Karcioğlu ZA, Huaman AM, al-Mesfer S. Retinoblastoma associated orbital cellulitis. *Br J Ophthalmol*. 1998;82(5):517-21.
19. Georgakopoulos CD, Eliopoulou MI, Stasinou S, et al. Periorbital and orbital cellulitis: a 10-year review of hospitalized children. *Eur J Ophthalmol*. 2010;20(6):1066-72.
20. Saetang S, Preechawai P, Hirunpat S. Retrograde cavernous sinus thrombosis and orbital cellulitis secondary to meningitis in immunocompetence child. *J Med Assoc Thai*. 2012;95(11):1485-8.
21. Suhaili DN, Goh BS, Gendeh BS. A ten year retrospective review of orbital complications secondary to acute sinusitis in children. *Med J Malaysia*. 2010;65(1):49-52.
22. Mahalingam-Dhingra A, Lander L, Preciado DA, et al. Orbital and periorbital infections: a national perspective. *Arch Otolaryngol Head Neck Surg*. 2011;137(8):769-73.
23. Snell RS, Lemp MA. The orbital blood vessels. In: Snell RS, Lemp MA. *Clinical anatomy of the eye*, 2nd Ed. Blackwell Science Inc., 1998: 277-293.
24. Oyster CW. The orbit. In: Oyster CW. *The human eye structure and function*. Cinar Associates Inc., 1999: 111-131.
25. Meyer DR, Linberg JV, Wobig JL, McCormick SA. Anatomy of the orbital septum and associated eyelid connective tissues. Implications for ptosis surgery. *Ophthalm Plast Reconstr Surg*. 1991;7(2):104-13.
26. Vairaktaris E, Moschos MM, Vassiliou S, et al. Orbital cellulitis, orbital subperiosteal and intraorbital abscess: report of three cases and review of the literature. *J Craniomaxillofac Surg*. 2009;37(3):132-6.
27. Mitchell R, Kelly J, Wagner J. Bilateral orbital complications of pediatric rhinosinusitis. *Arch Otolaryngol Head Neck Surg*. 2002;128(8):971-4.
28. Harris GJ. Subperiosteal abscess of the orbit. *Arch Ophthalmol*. 1983;101(5):751-7.
29. Kakizaki H, Takahashi Y, Nakano T, et al. Whitnall ligament anatomy revisited. *Clin Experiment Ophthalmol*. 2011;39(2):152-5.
30. Gentry LR. Anatomy of the orbit. *Neuroimaging Clin N Am*. 1998;8(1):171-94.
31. Turvey TA, Golden BA. Orbital anatomy for the surgeon. *Oral Maxillofac Surg Clin North Am*. 2012;24(4):525-36.
32. Brook I. Microbiology and antimicrobial treatment of orbital and intracranial complications of sinusitis in children and their management. *Int J Pediatr Otorhinolaryngol*. 2009;73(9):1183-6.
33. Pandian DG, Babu RK, Chaitra A, et al. Nine years' review on preseptal and orbital cellulitis and emergence of community-acquired methicillin-resistant *Staphylococcus aureus* in a tertiary hospital in India. *Indian J Ophthalmol*. 2011;59(6):431-5.
34. Tavakolizadeh S, Mobei I. Orbital dirofilariasis in Iran: a case report. *Korean J Parasitol*. 2009;47(4):397-9.
35. Peden MC, Neelakantan A, Orlando C, et al. Breaking the mold of orbital cellulitis. *Surv Ophthalmol*. 2008;53(6):631-5.
36. Fairley C, Sullivan TJ, Bartley P, et al. Survival after rhino-orbital-cerebral mucormycosis in an immunocompetent patient. *Ophthalmology*. 2000;107(3):555-8.
37. Seltz LB, Smith J, Durairaj VD, et al. Microbiology and antibiotic management of orbital cellulitis. *Pediatrics*. 2011;127(3):e566-72.
38. Bedwell J, Bauman NM. Management of pediatric orbital cellulitis and abscess. *Curr Opin Otolaryngol Head Neck Surg*. 2011;19(6):467-73.
39. Meara DJ. Sinonasal disease and orbital cellulitis in children. *Oral Maxillofac Surg Clin North Am*. 2012;24(3):487-96.
40. Zimmer A, Reith W. Inflammatory diseases of the orbit. *Radiologe*. 2008;48(12):1143-9.
41. Park JH, Jang JW, Kim SJ, Lee YJ. Traumatic optic neuropathy accompanying orbital grease gun injury. *Korean J Ophthalmol*. 2010;24(2):134-8.
42. Gottlieb CC, Mishra A, Bellevue D, et al. Ocular involvement in acute febrile neutrophilic dermatosis (Sweet syndrome): new cases and review of the literature. *Surv Ophthalmol*. 2008;53(3):219-26.
43. Pandian DG, Babu RK, A Chaitra, et al. Nine years' review on preseptal and orbital cellulitis and emergence of community-acquired methicillin-resistant *Staphylococcus aureus* in a tertiary hospital in India. *Indian J Ophthalmol*. 2011; 59(6):431-5.

PRESEPTAL CELLULITIS

Signs and Symptoms

Preseptal cellulitis is an infection within the eyelid anterior to the orbital septum.¹⁻⁵ Signs and symptoms include variable pain upon palpation, redness, swelling and red-purple skin coloration that is firm and warm to the touch.¹⁻⁵ Other ocular signs include conjunctival injection, edema and depending upon the extent and severity of the periorbital processes, corneal insult and in rare instances limited ocular motility.⁵⁻⁷

Eyelid infections involving the orbit and adnexa have been organized via the modified Chandler classification

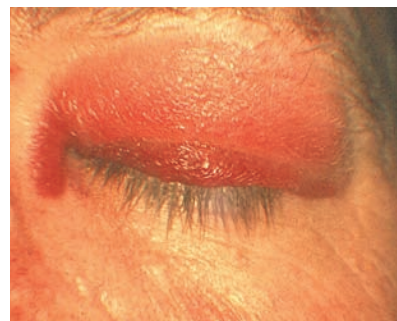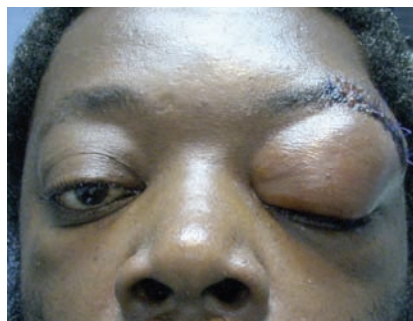
into two forms: the preseptal form (Stage I-Preseptal cellulitis, II-orbital cellulitis, anterior to the orbital septum) and the retroseptal form (Stages III-Subperiosteal abscess, IV-Orbital abscess, V-Cavernous sinus thrombosis) posterior to the orbital septum.^{8,9} The etiologies of preseptal cellulitis includes untreated hordeolum, dacryocystitis, sinusitis, eyelid trauma and eyelid infection secondary to puncture wound (foreign body, insect bite or sting) and subdermal exposure to the external environment as a result of communication with a sinus following orbital fracture.¹⁻¹³

The condition is not uncommon and most often occurs as a result of skin infection in children and dacryocystitis in adults.⁹⁻¹² Microbiologic cultures identify the most common pathogen as *Staphylococcus aureus*.⁹⁻¹² There is no predilection for gender, age or region. Immunosuppression may increase the risk.⁶

Pathophysiology

Preseptal cellulitis begins when inoculating microbes seed infection in the affected region. This can occur secondary to acute dacryocystitis, chronic sinusitis/upper-respiratory infection, puncture wound from a foreign body from blunt or projectile trauma, an insect bite or sting, or as a result of chronic hordeola or chalazia.^{10,14} Iatrogenic causes include dacryocystorhinostomy, nasolacrimal probing, nasolacrimal stenting, surgical reduction of orbital or eyelid abscess, chalazion and cilia epilation.^{10,14,15} The most common micro-organisms recovered included *Staphylococcus* (including methicillin-resistant *Staphylococcus aureus*-MRSA) and *Streptococcus* species followed by *Haemophilus influenzae* and *Klebsiella pneumoniae*.¹⁴⁻¹⁷

The vessels of the face and orbit are well connected with an interdigitating vascular web.¹⁸⁻²⁰ The major arcades situated in the eyelids are supplied through branches of the ophthalmic artery (lacrimal, medial palpebral arteries) and from



Two examples of preseptal cellulitis.

arteries within the face that are part of the external carotid system (infraorbital, zygomatico-facial, transverse facial arteries).¹⁸⁻²⁰ Branches of the ophthalmic system run to the face (supraorbital, supratrochlear and dorsal nasal).¹⁸⁻²⁰

The veins of the eyelid do not form definitive arcades. In fact, they are so vast and variable they are not recognized by specific name.²⁰ These vessels drain the eyelids by way of the superior and inferior ophthalmic veins along with the infraorbital vein, which drains into the cavernous sinus.²⁰

On the nasal aspect of the lids, the angular and facial veins drain inferiorly, forming anastomoses with the inferior ophthalmic and infraorbital veins.²⁰ Directly or indirectly, the orbital venous system is connected to the pterygoid plexus of veins in the face and the vascular system of the nose.²¹ These systems communicate with the external jugular system. Since there is no valve system restricting the direction of blood flow in the venous system and it is all connected, any infection in the region has access to the cranium.¹⁸⁻²⁰

In order for the eyelids to maintain functional movement, rigid anatomical landmarks must provide shape and stability.^{21,22} The tarsal plates are found in both the upper and lower lids, extending across the width the globe and maintaining a contoured margin to track with the eye's curvature.²¹ The

vertical extent of each plate measures 10mm in the superior lid and 5mm in the inferior.²¹ The tarsal plates are constructed of dense connective tissue into which the eye's meibomian glands are embedded.²¹

The muscles that help to elevate the lid are the levator palpebrae superioris and the muscle of Müller. The muscular portion of the levator terminates superiorly in a broad flat tendon known as the levator aproneurosis.²¹ The tendon runs the entire width of the lid, inserting into the tarsus or the connective tissue that surrounds it.²¹ There is fibrous connective tissue between the Müller's muscle and the palpebral conjunctiva creating a natural barrier.²² The pretarsal portion of the orbicularis oculi is situated within the eyelid anterior to the tarsal plates.²¹

The orbital septum is a connective tissue sheet that forms a barrier between the orbital contents and orbital fat and the eye lid.²¹ It extends circumferentially around the entire orbital rim inserting into the tarsal plate connective tissue.^{18,21} The only breaks in the orbital septum occur where vessels and nerves splice through it on their way to anterior structures and where the levator aponeurosis passes through it to insert on the connective tissue of the tarsal plates and dermis.^{18,21} The anatomy and blood supply of this region make it an ideal habitat for a pocket of infection to proliferate and potentially spread into the orbit, cavernous sinus, blood or brain.¹⁻²⁵

Management

Preseptal cellulitis can be conservatively managed with hot compresses at the site of infection to stimulate the body's immune repose to the local region as well as broad-spectrum oral antibiotics and oral analgesics.^{1-17,26-31} When lesions are small, focal, superficial and painful, they can be decompressed and allowed to passively drain by creating an opening with a small-gauge needle, epilating an obstructing eye lash, or opening a visibly blocked gland.^{30,31} The skin over the lesion can be anesthetized with topical anesthetic to aide in the comfort of the procedure; however, injectable anesthetic is never used as adding additional volume to an already congested region inhibiting diffusion is contraindicated.³²

The oral antibiotic classes that are commonly used include the penicillins (cloxacillin, dicloxacillin, flucloxacillin) 250-500mg BID-QID, the cephalosporins (cephalexin, cefadroxil, cephadrine) 250-500mg BID-QID, the macrolides (azithromycin as directed on Z-PAK, clarithromycin 500mg BID) and fluoroquinolones (ciprofloxacin, levofloxacin) 500mg BID-QID.²⁶⁻²⁸ Topical and oral antibiotics should never be tapered and the duration should be 7-10 days depending upon the severity of the infection or the area involved.

In more severe cases or cases with a larger area of infection, intravenous antibiotics can be initiated. In cases of concurrent dacryocystitis, epiphora may result, leading to a lateral canthus fissure or other ulcerative defects secondary to the drying effects of the sodium laden tears.³³ In these cases, a topical antibiotic ointment can augment a skin moisturizer to protect against infection and aid in lesion resolution.

Clinical Pearls

- Visualization with computed tomography (CT) or magnetic resonance imaging (MRI) may be required to understand the extent of larger infections.

- In cases where abscess is present, surgical excision may be required.
- In cases involving the nasolacrimal system, even after the infection has resolved, probing may be required to assay the system for patency. In many instances, nasolacrimal system stenting and dacryocystorhinostomy must be completed to reestablish complete communication and function.
- Any time the primary treatment fails, a culture and sensitivity along with additional testing for organisms such as methicillin-resistant *Staphylococcus* and fungi must be considered.³⁴
- If a lesion opens, it is not unreasonable, while a flow is established, to remove all of the mucopurulent discharge possible. These lesions may be susceptible to topical antibiotics, which should be included in the regimen. Since they will continue to drain, they should be kept clean and covered.
- Given the risk of infection spread, patients should not be instructed to massage an infected area or compress an infected area with the goal of expression.

1. Starska K, Lukomski M, Starska-Dawidowska D. Preseptal orbital abscess as a post-traumatic late complication--review of the literature and case report. *Otolaryngol Pol.* 2007;61(3):331-4.
2. Benton J, Karkanevatos A. Preseptal cellulitis due to *Mycobacterium marinum*. *J Laryngol Otol.* 2007;121(6):606-8.
3. Wong AC, Mak ST. Preseptal cellulitis in a child caused by *Megacopta centrosignatum*. *J AAPOS.* 2012;16(6):577-8.
4. Brughla RE, Abrahamson E. Ambulatory intravenous antibiotic therapy for children with preseptal cellulitis. *Pediatr Emerg Care.* 2012;28(3):226-8.
5. Pandian DG, Babu RK, Chaitra A, et al. Nine years' review on preseptal and orbital cellulitis and emergence of community-acquired methicillin-resistant *Staphylococcus aureus* in a tertiary hospital in India. *Indian J Ophthalmol.* 2011; 59(6): 431-435.
6. Im SK, Yoon KC. Corneal perforation with preseptal cellulitis in a patient with acute lymphocytic leukemia. *J Korean Med Sci.* 2010;25(8):1251-2.
7. Schielke KC, Hilton AJ, Brown R. Acquired Brown's syndrome associated with preseptal cellulitis. *Strabismus.* 2008;16(3):95-6.
8. Uzcátegui N, Warman R, Smith A, et al. Clinical practice guidelines for the management of orbital cellulitis. *J Pediatr Ophthalmol Strabismus.* 1998;35(2):73-9.
9. Chandler JR, Langenbrunner DJ, Stevens ER. The pathogenesis of orbital complications in acute sinusitis. *Laryngoscope.* 1970;80(9):1414-28.
10. Liu IT, Kao SC, Wang AG, et al. Preseptal and orbital cellulitis: a 10-year review of hospitalized patients. *J Chin Med Assoc.* 2006;69(9):415-22.
11. Bagheri A, Tavakoli M, Aletaha M, et al. Orbital and preseptal cellulitis: a 10-year survey of hospitalized patients in a tertiary eye hospital in Iran. *Int Ophthalmol.* 2012;32(4):361-7.
12. Babar TF, Zaman M, Khan MN, Khan MD. Risk factors of preseptal and orbital cellulitis. *J Coll Physicians Surg Pak.* 2009;19(1):39-42.
13. Sivori LA 2nd, de Leeuw R, Morgan I, Cunningham LL Jr. Complications of frontal sinus fractures with emphasis on chronic craniofacial pain and its treatment: a review of 43 cases. *J Oral Maxillofac Surg.* 2010;68(9):2041-6.
14. Chaudhry IA, Shamsi FA, Elzaridi E, et al. Inpatient preseptal cellulitis: experience from a tertiary eye care centre. *Br J Ophthalmol.* 2008;92(10):1337-41.
15. Elmann S, Pointdujour R, Blaydon S, et al. Periocular abscesses following brow epilation. *Ophthalm Plast Reconstr Surg.* 2012;28(6):434-7.
16. Jackson K, Baker SR. Periorbital cellulitis. *Head Neck Surg.* 1987;9(4):227-34.
17. Bababegy SR, Silva RA, Sun Y, Jain A. Rifampin and linezolid in the treatment of methicillin-resistant *Staphylococcus aureus* preseptal cellulitis. *Ophthalm Plast Reconstr Surg.* 2009;25(3):227-8.
18. Snell RS, Lemp MA. The orbital blood vessels. In: Snell RS, Lemp MA. *Clinical anatomy of the eye*, 2nd Ed. Blackwell Science Inc.;1998:277-93.
19. Oyster CW. The orbit. In: Oyster CW. *The human eye structure and function*. Cinaur Associates Inc.;1999: 111-31.
20. Oyster CW. Blood supply and drainage. In: Oyster CW. *The human eye structure and function*. Cinaur Associates Inc.;1999:247-89.
21. Oyster CW. The eyelids and lacrimal system. In: Oyster CW. *The human eye structure and function*. Cinaur Associates Inc.;1999:291-320.
22. Kakizaki H, Zako M, Nakano T, et al. Fibrous connective tissue between Müller's muscle and the palpebral conjunctiva as a reinforcement structure and a natural barrier for the upper eyelid. *Okajimas Folia Anat Jpn;*82(3):79-82.
23. Kakizaki H, Takahashi Y, Nakano T, et al. Whitnall ligament anatomy revisited. *Clin Experiment Ophthalmol.* 2011;39(2):152-5.
24. Gentry LR. Anatomy of the orbit. *Neuroimaging Clin N Am.* 1998;8(1):171-94.
25. Turvey TA, Golden BA. Orbital anatomy for the surgeon. *Oral Maxillofac Surg Clin North Am.* 2012;24(4):525-36.
26. Mandal R, Banerjee AR, Biswas MC, et al. Clinicobacteriological study of chronic dacryocystitis in adults. *J Indian Med Assoc.* 2008;106(5):296-8.
27. Ahrens-Palumbo MJ, Ballen PH. Primary dacryocystitis causing orbital cellulitis. *Ann Ophthalmol.* 1982;14(6):600-1.
28. Durán-Giménez-Rico MC, Boto-de-los-Bueis A, Alberto MJ, et al. Preseptal and orbital cellulitis in childhood: response to intravenous antibiotics. *Arch Soc Esp Oftalmol.* 2005;80(9):511-6.
29. Goawalla A, Lee V. A prospective randomized treatment study comparing three treatment options for chalazia: triamcinolone acetonide injections, incision and curettage and treatment with hot compresses. *Clin Experiment Ophthalmol.* 2007;35(8):706-12.
30. Lindsley K, Nichols JJ, Dickersin K. Interventions for acute internal hordeolum. *Cochrane Database Syst Rev.* 2010;(9):CD007742.
31. Panicharoen C, Hirunwiwatkul P. Current pattern treatment of hordeolum by ophthalmologists in Thailand. *J Med Assoc Thai.* 2011;94(6):721-4.
32. Ogle OE, Mahjoubi G. Local anesthesia: agents, techniques, and complications. *Dent Clin North Am.* 2012;56(1):133-48.
33. Deangelis D, Hurwitz J, Mazzulli T. The role of bacteriologic infection in the etiology of nasolacrimal duct obstruction. *Can J Ophthalmol.* 2001;36:134-39.
34. Velazquez AJ, Goldstein MH, Driebe WT. Preseptal cellulitis caused by trichophyton (ringworm). *Cornea.* 2002;21(3):312-4.



Go Further—Without Leaving Home



Expand your clinical skills and catch up on your CE requirements, all from the comfort of your own home.

Review offers **nearly 100 hours** of COPE-approved continuing education — right now! It's **just a click away**. Our extensive library of exams runs the gamut from keratoconus to fundus autofluorescence, and everything in between.



www.revoptom.com/continuing_education

Download a QR scanner app. Launch app and hold your mobile device over the code to view www.revoptom.com/continuing_education.

REVIEW[®]
OF OPTOMETRY

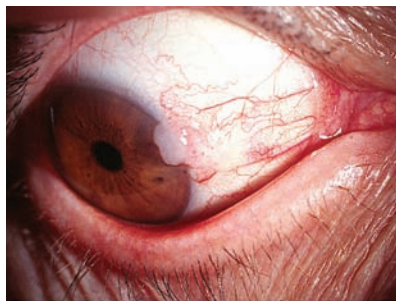OCULAR SURFACE SQUAMOUS NEOPLASIA

Signs and Symptoms

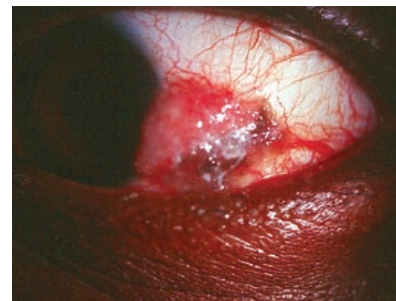Ocular surface squamous neoplasia (OSSN) refers to a spectrum of cancerous and precancerous lesions of the conjunctiva; the term encompasses several conditions, including conjunctival intraepithelial neoplasia (CIN), carcinoma-in-situ and invasive squamous cell carcinoma.¹ In industrialized nations such as the United States, the typical patient with OSSN tends to be over 50 years of age, Caucasian and male (by a ratio of about 3:1).² However, in the equatorial regions of Africa, younger individuals may display this condition, particularly those who are immunocompromised secondary to HIV infection.^{2,3}

The earliest stages of OSSN (CIN, carcinoma-in-situ) appear as a fleshy or gelatinous, slightly elevated mass of pink tissue, usually at the limbus in the interpalprebral space. At this stage, the lesion may be mistaken for a variety of benign conditions, including pinguecula, pterygium or conjunctival papilloma. As the lesion grows larger and more elevated, it may begin to take on an irregular shape. Characteristic “feeder vessels” may be seen within and surrounding the mass; these vessels represent a rich intrinsic blood supply, emanating from the adjacent conjunctiva and/or episclera. Significant extension onto the corneal surface should be viewed as highly suspicious for malignancy. Another pathognomonic sign of invasive squamous cell carcinoma is the presence of leukoplakia—overlying, placoid, white areas on the tumor surface, secondary to hyperkeratosis.⁴

Patients with OSSN may present in early stages with cosmetic concerns, or may be entirely asymptomatic. Larger lesions may interfere with lid function, causing dry eye complaints and pos-



Ocular surface squamous neoplasia of the conjunctiva.



sibly dellen formation on the adjacent cornea. Advanced, invasive lesions may compromise the episclera, sclera, cornea or angle structures. Pain may be a significant factor in later stages due to associated keratitis, uveitis or secondary glaucoma.⁵

Pathophysiology

Ocular surface squamous neoplasia, as the name implies, represents abnormal, excessive growth of the conjunctival tissue. Histologically, atypical squamous cells replace the normal epithelium, resulting in a loss of normal cell maturation. Depending upon the severity of the dysplasia, clinicians may use the term CIN or carcinoma-in-situ. After the dysplastic squamous cells encroach beyond the borders of the basement membrane, the lesion is referred to as invasive squamous cell carcinoma.¹

The pathophysiology of OSSN is believed to be multifactorial.² While a variety of potential etiologic factors have been linked to the development of squamous cell carcinoma, solar ultraviolet radiation remains the most significant.⁶⁻⁸ HIV seropositivity also appears to significantly increase the risk of developing OSSN.^{2,3,9,10} In Africa, rates of HIV infection as high as 79% have been found in patients diagnosed with these lesions.⁹ Other factors which have been associated with the development of OSSN include the human papilloma virus (HPV-16 and

-18, specifically), chronic inflammatory diseases (e.g., atopic keratoconjunctivitis) and exposure to arsenic or immunosuppressive drugs.^{1,2,11-13}

Management

Management of OSSN begins with identification of clinically suspicious conjunctival lesions. Any elevated mass of the ocular surface that is not easily identifiable as a benign entity should warrant further evaluation, particularly in at-risk individuals; this includes older patients with a history of chronic sun exposure as well as any individual with known HIV infection. Several non-invasive techniques can be performed, such as impression cytology or exfoliative cytology, in conjunction with Papanicolaou and Giemsa staining.¹⁴ In vivo confocal microscopy can also help differentiate OSSN from other benign and malignant lesions.¹⁵ However, only histopathologic evaluation of tissue biopsy can conclusively differentiate the three lesions in the spectrum of OSSN.¹

Management of biopsy-proven lesions usually consists of surgical excision, with wide margins (4-5mm) to increase the chance of complete removal. Advanced lesions in which there is involvement of the cornea or sclera may warrant deep lamellar keratectomy or sclerectomy. In all cases, a “no touch” technique is used to avoid direct manipulation of the mass and prevent tumor cell seeding.⁵ Still, sur-

gical excision alone appears to yield an unacceptably high recurrence rate.¹⁶

Adjunctive cryotherapy applied to the surrounding conjunctival tissue helps to destroy the tumor's microcirculation, and further improves the surgical outcome.^{1,5,16} Likewise, the adjunctive use of topical antimetabolites, including 5-fluorouracil (5-FU) or mitomycin-C (MMC) appears to be beneficial toward diminishing recurrence rates.^{2,17,18} The topical immunomodulatory agent interferon α -2b has proven to be equally effective in the adjunctive management of non-invasive OSSN as 5-FU and MMC.^{18,19} Topical cyclosporine 0.05% (Restasis, Allergan) in conjunction with MMC following surgical excision seems to further prevent tumor recurrence while improving visual outcome.¹⁶

In those rare cases where intraocular extension has occurred, surgical removal of the globe (enucleation) or even the entire orbital contents (exenteration) may be required to preserve life.²⁰

Clinical Pearls

- Clinicians must be suspicious of any rapidly growing mass on the conjunctival surface that fails to respond to antibiotic or anti-inflammatory therapies. Realize that two or more feeder vessels, leukoplakia, changes or variations in color or a predilection toward bleeding all constitute "red flags" for malignancy.

- Those patients who undergo non-surgical forms of treatment (e.g., chemotherapy or radiation therapy alone) tend to have higher rates of recurrence and greater complications. Chemotherapeutic agents typically induce a toxic keratoconjunctivitis, while irradiation of OSSN lesions poses a substantial risk for corneal burns and radiation retinopathy.

- Photodynamic therapy with systemically injected verteporfin has been investigated as a potential management

option for those with invasive squamous cell carcinoma of the conjunctiva.^{21,22} Preliminary reports are positive; however, additional research is required to determine if this treatment modality has long-term benefits.

- While most forms of OSSN carry a good prognosis, metastasis is always a possibility. Once a diagnosis has been made, patients should be comanaged with an experienced oncologist to be certain that the cancer has not spread to other organ systems. Since the liver is the single most common site of metastasis from ocular malignancies, it is important to consider testing liver enzymes in any patient with cancer of the eye.

1. Pe'er, J. Ocular surface squamous neoplasia. *Ophthalmol Clin North Am* 2005 18(1):1-13.
2. Kiire CA, Srinivasan S, Karp CL. Ocular surface squamous neoplasia. *Int Ophthalmol Clin*. 2010;50(3):35-46.
3. Nagaiah G, Stotler C, Orem J, et al. Ocular surface squamous neoplasia in patients with HIV infection in sub-Saharan Africa. *Curr Opin Oncol*. 2010;22(5):437-42.
4. Shields CL, Shields JA. Tumors of the conjunctiva and cornea. *Surv Ophthalmol* 2004; 49(1):3-24.
5. Nelson KD, McSoley JJ. Clinical findings and management of conjunctival intraepithelial neoplasia. *Optometry*. 2011;82(1):15-21.
6. Basti S, Macsai MS. Ocular surface squamous neoplasia: a review. *Cornea*. 2003;22(7):687-704.
7. Tulvatana W, Bhattarakosol P, Sansopha L, et al. Risk factors for conjunctival squamous cell neoplasia: a matched case-control study. *Br J Ophthalmol*. 2003;87(4):396-8.
8. Gallagher RP, Lee TK. Adverse effects of ultraviolet radiation: a brief review. *Prog Biophys Mol Biol*. 2006;92(1):119-31.
9. Spitzer MS, Batumba NH, Chirambo T, et al. Ocular surface squamous neoplasia as the first apparent manifestation of HIV infection in Malawi. *Clin Experiment Ophthalmol*. 2008;36(5):422-5.
10. Pradeep TG, Gangasagara SB, Subbaramaiah GB, et al. Prevalence of undiagnosed HIV infection in patients with ocular surface squamous neoplasia in a tertiary center in Karnataka, South India. *Cornea*. 2012;31(11):1282-4.
11. Di Girolamo N. Association of human papilloma virus with pterygia and ocular-surface squamous neoplasia. *Eye (Lond)*. 2012;26(2):202-11.
12. Flynn TH, Manzouri B, Tuft SJ. Ocular surface squamous neoplasia in an immunosuppressed patient with atopic keratoconjunctivitis. *Int Ophthalmol*. 2012;32(5):471-3.
13. Shields CL, Ramasubramanian A, Mellen PL, Shields JA. Conjunctival squamous cell carcinoma arising in immunosuppressed patients (organ transplant, human immunodeficiency virus infection). *Ophthalmology*. 2011;118(11):2133-2137.e1.

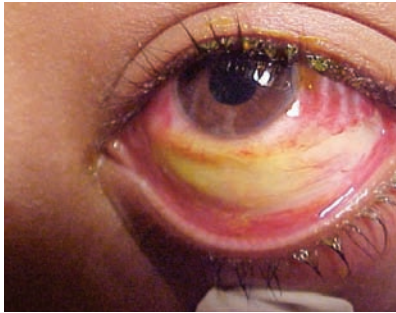
14. Ersoz C, Yagmur M, Ersoz TR, Yalaz M. Preoperative brush and impression cytology in ocular surface squamous neoplasms. *Acta Cytol* 2003; 47(1):13-5.
15. Xu Y, Zhou Z, Xu Y, et al. The clinical value of in vivo confocal microscopy for diagnosis of ocular surface squamous neoplasia. *Eye (Lond)*. 2012;26(6):781-7.
16. Zaki AA, Farid SF. Management of intraepithelial and invasive neoplasia of the cornea and conjunctiva: a long-term follow up. *Cornea*. 2009;28(9):986-8.
17. Chen C, Louis D, Dodd T, et al. Mitomycin C as an adjunct in the treatment of localised ocular surface squamous neoplasia. *Br J Ophthalmol*. 2004;88(1):17-18.
18. Sepulveda R, Pe'er J, Midea E, et al. Topical chemotherapy for ocular surface squamous neoplasia: current status. *Br J Ophthalmol*. 2010;94(5):532-5.
19. Holcombe DJ, Lee GA. Topical interferon alpha-2b for the treatment of recalcitrant ocular surface squamous neoplasia. *Am J Ophthalmol* 2006;142(4):568-71.
20. Othman IS. Ocular surface tumors. *Oman J Ophthalmol*. 2009;2(1):3-14.
21. Barbazetto IA, Lee TC, Abramson DH. Treatment of conjunctival squamous cell carcinoma with photodynamic therapy. *Am J Ophthalmol* 2004;138(2):183-9.
22. Ersoz C, Yagmur M, Ersoz TR, Yalaz M. Photodynamic therapy for conjunctival ocular surface squamous neoplasia. *J Ocul Pharmacol Ther*. 2011;27(2):205-7.

CONJUNCTIVAL ABRASION AND LACERATION

Signs and Symptoms

While corneal abrasions are among the most common presenting problems in the practice of primary eye care, conjunctival lacerations are uncommon.¹⁻¹³ Conjunctival abrasions and lacerations result secondary to mechanical rupture of the continuity of the tissue.¹¹⁻¹³ Patients almost always present with a history of external (sporting accident, assault, fall, poke, automobile crash, bungee cord injury) or self-induced trauma (rubbing, contact lens insertion or removal).

Symptoms include variable levels of blepharospasm and discomfort depending upon where the conjunctival injury has occurred, foreign body sensation, tearing, photophobia in cases that trigger substantial ocular inflammation and lacrimation.¹¹⁻¹³ If a concurrent uveitis is significant, the patient will be symptomatic for pain upon ocular movement.¹¹⁻¹³ Vision is typically only affected when the sclera is breached.¹⁴ Signs include sectoral conjunctival



Conjunctival laceration.

injection, subconjunctival hemorrhage and a visible conjunctival defect with retracted conjunctival edges and bare sclera that stains with sodium fluorescein dye.¹¹⁻¹³

Since both entities are the result of inadvertent trauma, they have no formal racial or gender predilection. With that said, workplace injuries affect males to a much greater degree, especially those between the ages of 17 and 30.¹⁵⁻¹⁹

Common sources of superficial household-associated eye injuries include chemicals, housewares, storage and organization paraphernalia and bed and bath items.²⁰ The garage, bathroom and laundry room are common sites of household misfortune.^{21,22} Eye injuries occurring outside the house are usually associated with landscaping activities and involve foreign debris stirred up by wind or motorized equipment.^{8,9} Eye injuries at work typically involve manufacturing or construction.^{16,18} Most superficial eye injuries both in the home and at work occur in the absence of proper eye protection.²¹⁻²³ The sporting activities commonly related to superficial eye injuries include boxing, hockey and racquet sports (tennis, racquetball, squash).¹⁷

Pathophysiology

The conjunctiva is an exposed mucous membrane covering the globe and the inner surface of the eyelid. The palpebral portion of the conjunctiva

is tightly adherent to the eyelid.²⁴ The bulbar portion is loosely adherent so that the globe has mobility. The conjunctiva is reflected upon itself so that it has the ability to stretch with ocular excursion.²⁴ The conjunctiva is composed of nonkeratinized stratified squamous epithelium overlying stromal tissue.²⁴ Because the conjunctiva is far less innervated than the cornea, conjunctival abrasions and lacerations are less symptomatic than corneal abrasions of the same severity. Given its position, the bulbar conjunctiva has the greatest chance of sustaining injury.²⁴⁻²⁷

In a conjunctival abrasion, the surface epithelial cells are physically “rubbed off.” In a conjunctival laceration, the tissue will stretch and wrinkle to its physical capacity, beyond which a full-thickness section of tissue will be torn out to reveal bare sclera beneath. In these cases, the trauma itself acts as an antigen and sets off an inflammatory cascade resulting in vasodilation and edema of the involved and surrounding tissues.^{24,28,29}

Management

Treatment for conjunctival laceration and/or abrasion begins with history. The time, place and activity surrounding the injury should be recorded. Visual acuity (VA) should be recorded before any procedures or drops are given. If the blepharospasm is sufficiently intense, a drop of topical anesthetic can be administered to lessen it. The eye examination should proceed in a logical fashion from external adenexa to fundus. The eyelids should be everted and fornices scrutinized for foreign material. Fluorescein dye (preferably without anesthetic) should be instilled to assist in identifying defects.

The lesion should be photographed, if possible, and measured using the height and width of the biomicroscope beam. The Seidel test (painting of the

wound with fluorescein dye observing for aqueous leakage) should be performed if a full-thickness corneal or globe perforation is suspected.³⁰ The lesion should be cleaned. The anterior chamber should be observed for any evidence of inflammation. Topical anesthesia will permit the clinician to use a forceps or moistened cotton-tipped applicators to manipulate the ragged areas of conjunctiva back into position. Bleeding can be arrested with direct pressure. A dilated examination should be completed (either at time of initial evaluation or at follow-up) to rule out any posterior effects from the trauma.

If the eye is not to be patched, treatment includes topical antibiotics QID, topical cycloplegia applied in the office or prescribed QD-BID depending upon the severity of the injury and may include topical nonsteroidal anti-inflammatory medication QD-QID for local analgesia.³¹⁻³⁴ Topical antibiotic ointments can be used for increased contact time and extra lesional cushioning but are often not tolerated well, as they blur vision. Topical steroids have the potential to retard healing and in the setting of trauma, may be postponed until initial tissue knitting takes place.³⁵

Topical antibiotic/steroid combination drops and/or ointments are a reasonable alternative in the event it is determined that inflammation must be addressed on the day of the injury. Another benefit of combination medications is that they simplify the regimen. The smallest lacerations (<1cm) will heal within a week without special attention. Larger lacerations, after appositional placement of the tissue edges, can be remediated with antibiotic ointment and pressure patching for 24 hours. Repair with either sutures or tissue glue are reserved for only the largest lesions (>2cm).³⁶

Bed rest, limited activity, cold compresses, artificial tear drops and over-the-counter analgesics such as acet-

aminophen or ibuprofen can be used to relieve acute pain. Acetaminophen can be recommended in cases where there is bleeding as it does not encourage antiplatelet effects.

Clinical Pearls

- Conjunctival lacerations are minor problems that typically resolve with minimal intervention, yet patients often present with great anxiety. The eye is very red and often hemorrhaging, which may be cause for great concern on the patient's part, even though there is little pain or other symptoms. While it's important to rule out a penetrating injury, you can safely reassure most patients that they have a simple "cut" on their eye, and that it will heal in a few days.

- While internal inflammation is typically minimal in these cases, any trauma with sufficient force so as to be capable of producing an abraded or lacerated conjunctiva deserves the consideration for cycloplegia.

1. Wipperman JL, Dorsch JN. Evaluation and management of corneal abrasions. *Am Fam Physician*. 2013;87(2):114-20.
2. Vetter TR, Ali NM, Boudreaux AM. A case-control study of an intraoperative corneal abrasion prevention program: holding the gains made with a continuous quality improvement effort. *Jt Comm J Qual Patient Saf*. 2012;38(11):490-6.
3. Whipple KM, Lim LH, Korn BS, Kikkawa DO. Blepharoplasty complications: prevention and management. *Clin Plast Surg*. 2013;40(1):213-24.
4. Reddy SC. Superglue injuries of the eye. *Int J Ophthalmol*. 2012;5(5):634-7.
5. Alphonse VD, Kemper AR, Rowson S, Duma SM. Eye injury risk associated with remote control toy helicopter blades. *Biomed Sci Instrum*. 2012;48(1):20-6.
6. Lee SY, Kim YH, Johnson D, et al. Contact lens complications in an urgent-care population: the University of California, Los Angeles, contact lens study. *Eye Contact Lens*. 2012 Jan;38(1):49-52.
7. Ojabo CO, Adeniyi OS, Ogili SA. Farm-related ocular trauma in Makurdi, Nigeria. *Niger J Med*. 2011;20(1):114-9.
8. Gordon KD. The incidence of eye injuries in Canada. *Can J Ophthalmol*. 2012;47(4):351-3.
9. Leinert J, Griffin R, Blackburn J, McGwin G Jr. The epidemiology of lawn trimmer injuries in the United States: 2000-2009. *J Safety Res*. 2012;43(2):137-9.
10. Pereira MG, Rodrigues MA, Rodrigues SA. Eyelid entropion. *Semin Ophthalmol*. 2010;25(3):52-8.
11. Dotorakis ET, Symvoulakis EK, Drakonaki E, et al. Unexpected finding in ocular surface trauma: a large intra-

- orbital foreign body (bullet). *Acta Medica (Hradec Kralove)*. 2012;55(2):100-3.
12. Hwang K, Kim DH, Lee HS. Orbital fracture due to high-pressure air injection. *J Craniofac Surg*. 2011;22(4):1506-7.
13. Luo Z, Gardiner M. The incidence of intraocular foreign bodies and other intraocular findings in patients with corneal metal foreign bodies. *Ophthalmology*. 2010;117(11):2218-21.
14. Locke LC. Conjunctival abrasions and lacerations. *J Am Optom Assoc*. 1987;58(6):488-93.
15. Ratnapalan S, Das L. Causes of eye burns in children. *Pediatr Emerg Care*. 2011;27(2):151-6.
16. McGwin G Jr, Owsley C. Incidence of emergency department-treated eye injury in the United States. *Arch Ophthalmol*. 2005;123(5):662-6.
17. MacEwen CJ, McLatchie GR. Eye injuries in sport. *Scott Med J*. 2010;55(2):22-4.
18. Forrest KY, Cali JM. Epidemiology of lifetime work-related eye injuries in the U.S. population associated with one or more lost days of work. *Ophthalmic Epidemiol*. 2009;16(3):156-62.
19. Blackburn J, Levitan EB, MacLennan PA, et al. A case-crossover study of risk factors for occupational eye injuries. *J Occup Environ Med*. 2012;54(1):42-7.
20. McGwin G Jr, Hall TA, Seale J. Consumer product-related eye injury in the United States, 1998-2002. *J Safety Res*. 2006;37(5):501-6.
21. Qazi K, Gerson LW, Christopher NC, et al. Curling iron-related injuries presenting to U.S. emergency departments. *Acad Emerg Med*. 2001;8(4):395-7.
22. Blackburn J, Levitan EB, MacLennan PA, et al. The epidemiology of chemical eye injuries. *Curr Eye Res*. 2012;37(9):787-93.
23. Arcury TA, Grzywacz JG, Anderson AM, et al. Employer, use of personal protective equipment, and work safety climate: Latino poultry processing workers. *Am J Ind Med*. 2013;56(2):180-8.
24. Snell RS, Lemp MA. The ocular appendages. In: Snell RS, Lemp MA. *Clinical anatomy of the eye*, 2nd Ed. Blackwell Science Inc., 1998: 90-131.
25. Marin MI, Tejero TR, Dominguez FM, et al. Ocular injuries in midfacial fractures. *Orbit*. 1998;17(1):41-46.
26. Muller L, Kohnen T. Scleral and corneal laceration with iris prolapse caused by an eagle claw. *Graefes Arch Clin Exp Ophthalmol*. 2005;243(4):377-9.
27. Margo CE. Tourette syndrome and iatrogenic eye injury. *Am J Ophthalmol*. 2002;134(5):784-5.
28. Oyster CW. Blood supply and drainage. In: Oyster CW. *The human eye structure and function*. Cinaur Associates Inc., 1999: 247-289.
29. Oyster CW. The eyelids and lacrimal system. In: Oyster CW. *The human eye structure and function*. Cinaur Associates Inc., 1999: 291-320.
30. Roy S, Mermoud A. Complications of deep nonpenetrating sclerectomy. *J Fr Ophthalmol*. 2006;29(10):1180-97.
31. Meek R, Sullivan A, Favilla M, et al. Is homatropine 5% effective in reducing pain associated with corneal abrasion when compared with placebo? A randomized controlled trial. *Emerg Med Australas*. 2010;22(6):507-13.
32. Fraser S. Corneal abrasion. *Clin Ophthalmol*. 2010;4(5):387-90.
33. Hua L, Doll T. A series of 3 cases of corneal abrasion with multiple etiologies. *Optometry*. 2010;81(2):83-5.
34. Turner A, Rabihi M. Patching for corneal abrasion. *Cochrane Database Syst Rev*. 2006;4(2):CD004764.
35. Bebawy JF. Perioperative steroids for peritumoral intracranial edema: a review of mechanisms, efficacy, and side effects. *J Neurosurg Anesthesiol*. 2012;24(3):173-7.
36. Freidman NJ, Kaiser PK. *The conjunctiva*. In:

Freidman NJ, Kaiser PK. *Essentials of Ophthalmology*. Philadelphia, PA, Saunders Inc 2007:149-159.

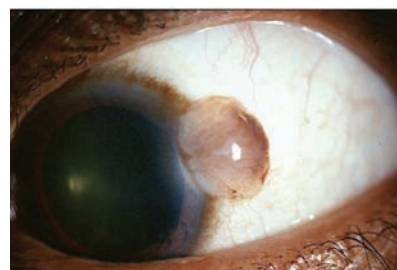
LIMBAL DERMOID

Signs and Symptoms

Limbal dermoids, also known as epibulbar or conjunctival dermoids, are generally seen as well-circumscribed oval mass lesions of the ocular surface. They may be unilateral or bilateral, arising from the bulbar conjunctiva and often encroaching across the limbus onto the corneal surface. A predilection for the inferotemporal limbus has been noted.¹ Dermoids are firm but "fleshy" in nature and their color may range from white to gray to pinkish yellow to brown, depending upon the specific tissue within the tumor mass. Often, blood vessels and/or hair follicles may be seen within or protruding from the dermoid.

Patients are typically quite young, with the majority of lesions diagnosed before puberty.² Dermoids are congenital in nature, but enlarge over time; hence, the lesion may not be given much regard until the individual reaches adolescence.^{3,4} Smaller lesions are usually asymptomatic, but larger dermoids may cause discomfort in the form of dry eye symptoms, conjunctival irritation, or incomplete lid closure (i.e., lagophthalmos).

Visual acuity may also be impacted by larger dermoids, since these lesions can contribute to the development of astigmatism or proceed to encroach



Pigmented limbal dermoid.

onto the visual axis. Amblyopia remains a distinct possibility in such cases.⁴

Pathophysiology

Dermoids are a form of choristoma, a benign, congenital tumor composed of tissue cells atypical to the organ in which they are found. Limbal dermoids consist of thick collagenous tissue and may also contain elements of skin, fat, gland, muscle, nerve, blood vessels, hair or bone. Even brain tissue has been found upon histologic analysis of some dermoids.⁵ The surface generally consists of simple corneal or conjunctival epithelium.

Dermoids may represent an isolated finding, or may be seen in conjunction with other ocular disorders such as scleral and/or corneal staphylomas, aniridia, congenital aphakia, cataract and microphthalmia. Dermoids are also sometimes associated with systemic abnormalities, including craniofacial abnormalities (e.g., Goldenhar-Gorlin syndrome, Franceschetti syndrome), nevus flammeus and neurofibromatosis.^{1,6} However, most limbal dermoids represent sporadic occurrences, and are not caused by known exposure to toxins or mechanical irritants.

An anatomical grading scale for limbal dermoids was proposed by Mann over a half-century ago, and is still used today.⁷ Grade I dermoids are recognized as superficial lesions measuring less than 5mm, and localized to the limbus. Grade II limbal dermoids are larger lesions covering most of the cornea and extending deep into the stroma, down to the level of Descemet's membrane without involving it. Grade III limbal dermoids, the least common of all the presenting dermoids, are large lesions covering the entire cornea and extending through the histological structures between the anterior surface of the eyeball and the pigmented epithelium of the iris.

Management

The preferred management of a limbal dermoid depends upon the extent of the lesion (i.e., Grade I, II or III) as well as the disposition of the patient. Small, asymptomatic grade I limbal dermoids can simply be left alone, since there is no likelihood of malignant transformation. Mild irritation can be managed with ocular lubricants or even a short course of topical corticosteroids (e.g., loteprednol etabonate 0.5% QID for 3-7 days), should there be recognizable signs of inflammation. Epilation of exposed hair follicles within the lesion may also help palliate the patient.

Surgical intervention is warranted in Grade I limbal dermoids when complications exist: chronic eye rubbing due to irritation and recurrent conjunctivitis; deprivational amblyopia unresponsive to management; progressive dellen, with corneal surface decompensation; growth and encroachment into the pupillary area or optical zone; unacceptable cosmesis; induction of irregular astigmatism; or inadequate lid closure.^{1,8,9} Surgery is universally indicated for all Grade II and III limbal dermoids.¹

Generally, the surgical procedure of choice is superficial sclerokeratectomy with excisional biopsy. When deeper excisions need to be performed, lamellar keratoscleroplasty has been shown to be safe and effective.⁸ The successful adjunctive use of amniotic membrane and pericardial graft tissue with this surgery has also been reported.^{9,10}

Clinical Pearls

- Limbal dermoids do not appear to show any specific predilections with regard to sex or race. The appearance may vary depending upon the patient's skin pigmentation, since melanosis oculi can certainly influence the dermoid's coloration.
- Young patients with limbal dermoids encroaching upon the visual axis

are at risk for the development of deprivation or meridional amblyopia. Specific testing, including potential acuity measurement or interferometry, should be performed on those youngsters with dermoids who also demonstrate reduced visual acuity. The finding of associated amblyopia is an absolute indication for excision of the lesion, followed by a subsequent course of vision therapy.

- The most notable systemic condition seen in association with limbal dermoids is Goldenhar syndrome, a craniofacial disorder that also presents with characteristic preauricular skin tags and associated hearing loss. In addition, these patients may show underdeveloped facial muscles, malformation of the mouth or ears, spinal or cervical vertebrae problems, cleft lip/palate, renal and/or cardiac disorders, and learning disabilities.¹¹

Families of pediatric patients with limbal dermoids should be alerted to the possibility of Goldenhar syndrome, and referred for appropriate testing.

1. Pirouzian A. Management of pediatric corneal limbal dermoids. *Clin Ophthalmol.* 2013;7:607-14.
2. Zhu J, Cheng HB, Fan N, et al. Studies of a pedigree with limbal dermoid cyst. *Int J Ophthalmol.* 2012;5(5):641-3.
3. Dey R, Dey S. Images in clinical medicine. Limbal dermoid. *N Engl J Med.* 2011;364(6):e9.
4. Mahdavi Fard A, Pourafkari L. Images in clinical medicine. The hairy eyeball—limbal dermoid. *N Engl J Med.* 2013;368(1):64.
5. Emamy H, Ahmadian H. Limbal dermoid with ectopic brain tissue. Report of a case and review of the literature. *Arch Ophthalmol* 1977; 95(12):2201-2.
6. Bhalli S, Benatiya I, El Abdouni O, et al. Goldenhar syndrome: ocular features. *Bull Soc Belge Ophthalmol.* 2010;(316):17-9.
7. Mann I. The modern approach to developmental abnormalities. *Aust N Z J Surg.* 1950;20(2):143-50.
8. Shen YD, Chen WL, Wang LJ, et al. Full-thickness central corneal grafts in lamellar keratoscleroplasty to treat limbal dermoids. *Ophthalmology.* 2005;112(11):1955.
9. Lazzaro DR, Coe R. Repair of limbal dermoid with excision and placement of a circumlimbal pericardial graft. *Eye Contact Lens.* 2010;36(4):228-9.
10. Pirouzian A, Holz H, Merrill K, et al. Surgical management of pediatric limbal dermoids with sutureless amniotic membrane transplantation and augmentation. *J Pediatr Ophthalmol Strabismus.* 2012;49(2):114-9.
11. Seymenolu G, Baer E, Tansu N, Demireli P. An unusual association of Goldenhar syndrome. *Int Ophthalmol.* 2013;33(1):91-4.

For patients with decreased tear production presumed to be due to ocular inflammation associated with Chronic Dry Eye

RESTASIS[®] MAKES MORE OF THEIR OWN REAL TEARS POSSIBLE

Prescribe RESTASIS[®] for your appropriate moderate and severe Dry Eye patients and increase their own real tear production over time with continued use

For local co-pays,
scan QR-code or visit
restasiscopay.com



Indication and Usage

RESTASIS[®] (cyclosporine ophthalmic emulsion) 0.05% is indicated to increase tear production in patients whose tear production is presumed to be suppressed due to ocular inflammation associated with keratoconjunctivitis sicca. Increased tear production was not seen in patients currently taking topical anti-inflammatory drugs or using punctal plugs.

Important Safety Information

Contraindications

RESTASIS[®] is contraindicated in patients with known or suspected hypersensitivity to any of the ingredients in the formulation.

Warnings and Precautions

Potential for Eye Injury and Contamination: To avoid the potential for eye injury and contamination, individuals prescribed RESTASIS[®] should not touch the vial tip to their eye or other surfaces.

Use With Contact Lenses: RESTASIS[®] should not be administered while wearing contact lenses. If contact lenses are worn, they should be removed prior to the administration of the emulsion.

Adverse Reactions

In clinical trials, the most common adverse reaction following the use of RESTASIS[®] was ocular burning (upon instillation)—17%. Other reactions reported in 1% to 5% of patients included conjunctival hyperemia, discharge, epiphora, eye pain, foreign body sensation, pruritus, stinging, and visual disturbance (most often blurring).

Please see Brief Summary of the full Prescribing Information on adjacent page.

RESTASIS® (Cyclosporine Ophthalmic Emulsion) 0.05%

BRIEF SUMMARY—PLEASE SEE THE RESTASIS® PACKAGE INSERT FOR FULL PRESCRIBING INFORMATION.

INDICATIONS AND USAGE

RESTASIS® ophthalmic emulsion is indicated to increase tear production in patients whose tear production is presumed to be suppressed due to ocular inflammation associated with keratoconjunctivitis sicca. Increased tear production was not seen in patients currently taking topical anti-inflammatory drugs or using punctal plugs.

CONTRAINDICATIONS

RESTASIS® is contraindicated in patients with known or suspected hypersensitivity to any of the ingredients in the formulation.

WARNINGS AND PRECAUTIONS

Potential for Eye Injury and Contamination

To avoid the potential for eye injury and contamination, be careful not to touch the vial tip to your eye or other surfaces.

Use with Contact Lenses

RESTASIS® should not be administered while wearing contact lenses. Patients with decreased tear production typically should not wear contact lenses. If contact lenses are worn, they should be removed prior to the administration of the emulsion. Lenses may be reinserted 15 minutes following administration of RESTASIS® ophthalmic emulsion.

ADVERSE REACTIONS

Clinical Trials Experience

Because clinical trials are conducted under widely varying conditions, adverse reaction rates observed in the clinical trials of a drug cannot be directly compared to rates in the clinical trials of another drug and may not reflect the rates observed in practice.

In clinical trials, the most common adverse reaction following the use of RESTASIS® was ocular burning (17%).

Other reactions reported in 1% to 5% of patients included conjunctival hyperemia, discharge, epiphora, eye pain, foreign body sensation, pruritus, stinging, and visual disturbance (most often blurring).

Post-marketing Experience

The following adverse reactions have been identified during post approval use of RESTASIS®. Because these reactions are reported voluntarily from a population of uncertain size, it is not always possible to reliably estimate their frequency or establish a causal relationship to drug exposure.

Reported reactions have included: hypersensitivity (including eye swelling, urticaria, rare cases of severe angioedema, face swelling, tongue swelling, pharyngeal edema, and dyspnea); and superficial injury of the eye (from the vial tip touching the eye during administration).

USE IN SPECIFIC POPULATIONS

Pregnancy

Teratogenic Effects: Pregnancy Category C

Adverse effects were seen in reproduction studies in rats and rabbits only at dose levels toxic to dams. At toxic doses (rats at 30 mg/kg/day and rabbits at 100 mg/kg/day), cyclosporine oral solution, USP, was embryo- and fetotoxic as indicated by increased pre- and postnatal mortality and reduced fetal weight together with related skeletal retardations. These doses are 5,000 and 32,000 times greater (normalized to body surface area), respectively, than the daily human dose of one drop (approximately 28 mcL) of 0.05% RESTASIS® twice daily into each eye of a 60 kg person (0.001 mg/kg/day), assuming that the entire dose is absorbed. No evidence of embryofetal toxicity was observed in rats or rabbits receiving cyclosporine at oral doses up to 17 mg/kg/day or 30 mg/kg/day, respectively, during organogenesis. These doses in rats and rabbits are approximately 3,000 and 10,000 times greater (normalized to body surface area), respectively, than the daily human dose.

Offspring of rats receiving a 45 mg/kg/day oral dose of cyclosporine from Day 15 of pregnancy until Day 21 postpartum, a maternally toxic level, exhibited an increase in postnatal mortality; this dose is 7,000 times greater than the daily human topical dose (0.001 mg/kg/day) normalized to body surface area assuming that the entire dose is absorbed. No adverse events were observed at oral doses up to 15 mg/kg/day (2,000 times greater than the daily human dose).

There are no adequate and well-controlled studies of RESTASIS® in pregnant women. RESTASIS® should be administered to a pregnant woman only if clearly needed.

Nursing Mothers

Cyclosporine is known to be excreted in human milk following systemic administration, but excretion in human milk after topical treatment has not been investigated. Although blood concentrations are undetectable after topical administration of RESTASIS® ophthalmic emulsion, caution should be exercised when RESTASIS® is administered to a nursing woman.

Pediatric Use

The safety and efficacy of RESTASIS® ophthalmic emulsion have not been established in pediatric patients below the age of 16.

Geriatric Use

No overall difference in safety or effectiveness has been observed between elderly and younger patients.

NONCLINICAL TOXICOLOGY

Carcinogenesis, Mutagenesis, Impairment of Fertility

Carcinogenesis: Systemic carcinogenicity studies were carried out in male and female mice and rats. In the 78-week oral (diet) mouse study, at doses of 1, 4, and 16 mg/kg/day, evidence of a statistically significant trend was found for lymphocytic lymphomas in females, and the incidence of hepatocellular carcinomas in mid-dose males significantly exceeded the control value.

In the 24-month oral (diet) rat study, conducted at 0.5, 2, and 8 mg/kg/day, pancreatic islet cell adenomas significantly exceeded the control rate in the low dose level. The hepatocellular carcinomas and pancreatic islet cell adenomas were not dose related. The low doses in mice and rats are approximately 80 times greater (normalized to body surface area) than the daily human dose of one drop (approximately 28 mcL) of 0.05% RESTASIS® twice daily into each eye of a 60 kg person (0.001 mg/kg/day), assuming that the entire dose is absorbed.

Mutagenesis: Cyclosporine has not been found to be mutagenic/genotoxic in the Ames Test, the V79-HGPRT Test, the micronucleus test in mice and Chinese hamsters, the chromosome-aberration tests in Chinese hamster bone-marrow, the mouse dominant lethal assay, and the DNA-repair test in sperm from treated mice. A study analyzing sister chromatid exchange (SCE) induction by cyclosporine using human lymphocytes *in vitro* gave indication of a positive effect (i.e., induction of SCE).

Impairment of Fertility: No impairment in fertility was demonstrated in studies in male and female rats receiving oral doses of cyclosporine up to 15 mg/kg/day (approximately 2,000 times the human daily dose of 0.001 mg/kg/day normalized to body surface area) for 9 weeks (male) and 2 weeks (female) prior to mating.

PATIENT COUNSELING INFORMATION

Handling the Container

Advise patients to not allow the tip of the vial to touch the eye or any surface, as this may contaminate the emulsion. To avoid the potential for injury to the eye, advise patients to not touch the vial tip to their eye.

Use with Contact Lenses

RESTASIS® should not be administered while wearing contact lenses. Patients with decreased tear production typically should not wear contact lenses. Advise patients that if contact lenses are worn, they should be removed prior to the administration of the emulsion. Lenses may be reinserted 15 minutes following administration of RESTASIS® ophthalmic emulsion.

Administration

Advise patients that the emulsion from one individual single-use vial is to be used immediately after opening for administration to one or both eyes, and the remaining contents should be discarded immediately after administration.

Rx Only



Based on package insert 71876US15

©2013 Allergan, Inc.

Irvine, CA 92612, U.S.A.

® marks owned by Allergan, Inc. APC74113

Patented. See www.allergan.com/products/patent_notices

Made in the U.S.A.

PYOGENIC GRANULOMA

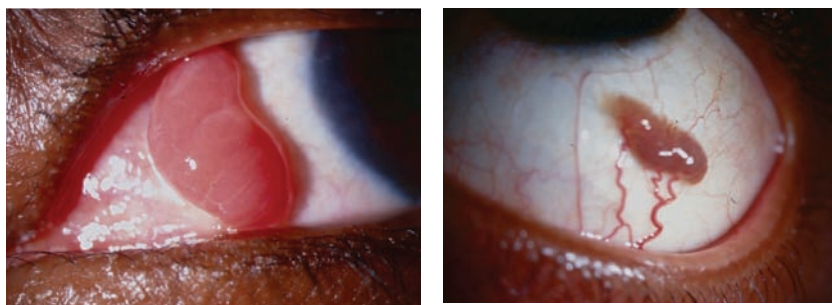
Signs and Symptoms

Pyogenic granulomas typically present as solitary, rapidly evolving papules or nodules on the skin of the face or lips, or the mucosal surfaces of the eyes or mouth.¹ Other areas of the body may be affected as well.¹⁻³ The lesions are soft in texture, usually smooth-surfaced, red to purple in coloration and may be pedunculated (i.e., stalked) in some instances.⁴

Patients may report various levels of discomfort, as well as a tendency for bleeding to occur with even the slightest manipulation.^{5,6} Often, the primary reason for presentation is a cosmetic concern.⁵ Patients with pyogenic granuloma may be of any age, but children and young adults appear to be affected more frequently.^{4,7} Similarly, there is no gender predilection overall, but pyogenic granulomas of the oral cavity do seem to be more common in women; in addition, there is a higher incidence of these lesions during pregnancy.^{1,8}

Ocular pyogenic granuloma may be seen to affect the adnexa, the eyelids and the bulbar or palpebral conjunctiva. In rare instances, the cornea may be impacted, though involvement seems to be limited to those layers anterior to Bowman's membrane, sparing the stroma.^{9,10} A number of cases have been found to occur in conjunction with punctal occlusion therapy, usually (but not always) involving intracanalicular plugs.^{11,12}

Common ocular complaints associated with pyogenic granuloma may include tearing, foreign body sensation or interrupted eyelid closure depending upon the location of the growth. Visual acuity is only affected if the lesion interrupts the visual axis or induces a keratopathy secondary to incomplete tear film spreading.



Two presentations of pyogenic granuloma of the bulbar conjunctiva.

Pathophysiology

The term “pyogenic granuloma” is a classic misnomer: these lesions are neither pyogenic (i.e., pus-producing) nor granulomatous (i.e., consisting of fibroblasts and macrophages surrounded by lymphocytes).^{4,5,7,13} In fact, pyogenic granulomas actually represent polypoidal vascular proliferations, and are sometimes referred to in the literature as lobular capillary hemangiomas.¹³⁻¹⁵ In addition to capillary proliferation, the lesions are accompanied by inflammatory cells in a myxoid stroma.¹³ Although the precise etiology of pyogenic granuloma is undetermined, these lesions often appear to follow episodes of trauma, surgery or chronic irritation.¹³⁻¹⁵ Hormonal influences, microorganisms (e.g., *Staphylococci*, *Bartonella*, viral particles), arteriovenous malformations and cytogenetic abnormalities have also been implicated.^{1,5,15-18}

Management

The initial step in the appropriate management of pyogenic granuloma involves ruling out other tumors and mass lesions. When the eyelids are involved, one must consider such entities as chalazia, internal hordeola, squamous cell carcinoma and sebaceous cell carcinoma in the differential. Once a definitive diagnosis has been made, a conservative attempt to regress tissue proliferation can be attempted by removing the inciting factor and pre-

scribing topical corticosteroid preparations.¹² Should these measures fail, or if the lesion is of substantial size and is compromising function of the involved tissues, medical and/or surgical intervention is warranted.

Surgical options may include such techniques as excision, curettage, shave and cautery, or combinations thereof.^{1,19} Other techniques that have been used successfully—whether alone or adjunctively to surgical intervention—include cryotherapy, electrodesiccation, cauterization with silver nitrate, microembolization, sclerotherapy (i.e., the injection of a vascular sclerosing agent into the lesion, such as tetracycline sulfate), imiquimod cream and laser therapy.¹⁹⁻²⁵ Various forms of laser have been employed in treating these lesions, including CO₂ laser, Nd:YAG laser, pulsed dye laser and even diode laser.^{14,26-28} Laser therapy offers excellent tolerability, few adverse effects and low recurrence rates.

Despite the many options, surgery remains the preferred technique for most pyogenic granulomas today. A meta-analysis of interventional studies dating from 1956 to 2009 concluded that surgical excision offers on average the lowest rates of recurrence, the least number of treatment sessions, and the best opportunity to retain the lesion in its entirety for pathologic examination.¹⁴ Those lesions that do not lend themselves to surgery because of size, number, location or disposition of the

patient may be treated by other means; of the remaining modalities, cryotherapy with liquid nitrogen carries the lowest overall recurrence rate.¹⁴

Clinical Pearls

- Pyogenic granulomas are considered to be among the most common acquired vascular growths of the eyelids.²⁹
- Pyogenic granulomas have also been reported to arise within congenital capillary malformations such as port-wine stain; however, in these cases they usually present following cosmetic laser treatments.³⁰
- Pyogenic granuloma development associated with punctal plugs are believed to be related to poorly fitted or poorly designed implants that create undue irritation.^{12,13}
- Pyogenic granulomas are not malignant, and have virtually no propensity for malignant conversion; however, they must always be differentiated from malignant lesions that may present with a similar appearance.^{6,16}

1. Giblin AV, Clover AJ, Athanassopoulos Am et al. Pyogenic granuloma - the quest for optimum treatment: Audit of treatment of 408 cases. *J Plast Reconstr Aesthet Surg.* 2007;60(9):1030-5.
2. Carmen González-Vela M, Fernando Val-Bernal J, Francisca Garjo M, et al. Pyogenic granuloma of the sigmoid colon. *Ann Diagn Pathol.* 2005;9(2):106-9.
3. Spinelli C, Di Giacomo M, Bertocchini A, et al. Multiple pyogenic granuloma of the penis in a four-year-old child: a case report. *Cases J.* 2009;2:7831.
4. Ting PT, Barankin B. Dermacase. Pyogenic granuloma. *Can Fam Physician.* 2006;52:35-6.
5. Ehmann DS, Schweitzer K, Sharma S. Ophthalmic problem. Can you identify this condition? Pyogenic granuloma. *Can Fam Physician.* 2010;56(6):553, 556.
6. Scheinfeld NS. Pyogenic granuloma. *Skinmed.* 2008;7(1):37-9.
7. Murthy SC, Nagaraj A. Pyogenic granuloma. *Indian Pediatr.* 2012;49(10):855.
8. Pagliai KA, Cohen BA. Pyogenic granuloma in children. *Pediatr Dermatol.* 2004;21(1):10-3.
9. Karatza EC, Calhoun JH, Eagle RC Jr. Pyogenic granuloma of the cornea in an infant with unilateral microphthalmia. *Arch Ophthalmol.* 2003;121(8):1197-200.
10. Mietz H, Arnold G, Kirchof B, et al. Pyogenic granuloma of the cornea: report of a case and review of the literature. *Graefes Arch Clin Exp Ophthalmol.* 1996; 234(2):131-6.

11. Chou TY, Perry HD, Donnerfeld ED et al. Pyogenic granuloma formation following placement of the Medennium SmartPLUG punctum plug. *Cornea*. 2006;25(4):493-5.
12. Kim BM, Osmanovic SS, Edward DP. Pyogenic granulomas after silicone punctal plugs: a clinical and histopathologic study. *Am J Ophthalmol*. 2005;139(4):678-84.
13. Yazici B, Ayvaz AT, Aker S. Pyogenic granuloma of the lacrimal sac. *Int Ophthalmol*. 2009;29(1):57-60.
14. Lee J, Sinno H, Tahiri Y, Gilardino MS. Treatment options for cutaneous pyogenic granulomas: a review. *J Plast Reconstr Aesthet Surg*. 2011;64(9):1216-20.
15. Demir Y, Demir S, Aktepe F. Cutaneous lobular capillary hemangioma induced by pregnancy. *J Cutan Pathol*. 2004;31(1):77-80.
16. Kamal R, Dahiya P, Puri A. Oral pyogenic granuloma: Various concepts of etiopathogenesis. *J Oral Maxillofac Pathol*. 2012;16(1):79-82.
17. da Silva AD, Silva CA, de Camargo Moraes P, et al. Recurrent oral pyogenic granuloma in port-wine stain. *J Craniofac Surg*. 2011;22(6):2356-8.
18. Hung CH, Kuo HW, Chiu YK, Huang PH. Intravascular pyogenic granuloma arising in an acquired arteriovenous malformation: report of a case and review of the literature. *Dermatol Surg*. 2004;30(7):1050-3.
19. Gilmore A, Kelsberg G, Safranek S. Clinical inquiries. What's the best treatment for pyogenic granuloma? *J Fam Pract*. 2010;59(1):40-2.
20. Mirshams M, Daneshpazhooch M, Mirshekari A, et al. Cryotherapy in the treatment of pyogenic granuloma. *J Eur Acad Dermatol Venereol*. 2006;20(7):788-90.
21. Quitkin HM, Rosenwasser MP, Strauch RJ. The efficacy of silver nitrate cauterization for pyogenic granuloma of the hand. *J Hand Surg [Am]*. 2003;28(3):435-8.
22. Moon SE, Hwang EJ, Cho KH. Treatment of pyogenic granuloma by sodium tetradeceyl sulfate sclerotherapy. *Arch Dermatol*. 2005;141(5):644-6.
23. Georgiou S, Monastirli A, Pasmatzis E, Tsambaos D. Pyogenic granuloma: complete remission under occlusive imiquimod 5% cream. *Clin Exper Dermatol*. 2008;33(4):454-6.
24. Ezzell TI, Fromowitz JS, Ramos-Caro FA. Recurrent pyogenic granuloma treated with topical imiquimod. *J Am Acad Dermatol* 2005;54(5 Suppl):s244-5.
25. Rai S, Kaur M, Bhatnagar P. Laser: a powerful tool for treatment of pyogenic granuloma. *J Cutan Aesthet Surg*. 2011;4(2):144-7.
26. Lindenmüller IH, Noll P, Mameghani T, Walter C. CO₂ laser-assisted treatment of a giant pyogenic granuloma of the gingiva. *Int J Dent Hyg*. 2010;8(3):249-52.
27. Hammes S, Kaiser K, Pohl L, et al. Pyogenic granuloma: treatment with the 1,064-nm long-pulsed neodymium-doped yttrium aluminum garnet laser in 20 patients. *Dermatol Surg*. 2012;38(6):918-23.
28. Sud AR, Tan ST. Pyogenic granuloma-treatment by shave-excision and/or pulsed-dye laser. *J Plast Reconstr Aesthet Surg*. 2010;63(8):1364-8.
29. Neff AG, Carter KD. Benign eyelid lesions. In: Yanoff M, Duker JS, Augsberger JJ, et al., eds. *Ophthalmology*, 3rd Edition. Edinburgh: Mosby Elsevier, 2009. 1422-33.
30. Sheehan DJ, Leshner JL. Pyogenic granuloma arising within a port-wine stain. *Cutis*. 2004;73(3):175-80.

OCULAR CICATRICAL PEMPHIGOID

Signs and Symptoms

Mucous membrane pemphigoid is a heterogeneous group of autoimmune

diseases.¹⁻¹⁰ It affects primarily the mucous membranes of both the oral and ocular tissues. While disease affecting the oral mucosa tend to have a benign outcome, the ocular disease can demonstrate resistance to treatment with potential scarring and blindness.¹⁻¹⁰ When the lesions are restricted to the conjunctiva, the term ocular cicatricial pemphigoid (OCP) is used.²

The risk of the development of ocular disease among patients who present at first with only oral mucous membrane pemphigoid is estimated at 15%-20% over five years.⁸

Signs include unilateral or bilateral recurrent conjunctival inflammation, chronic blepharitis, filamentary keratitis, non-healing corneal defects, raised intraocular pressure (IOP) with evidence of secondary open angle glaucoma, chronic subepithelial fibrosis of the eyelid which when left untreated may lead to fornix shortening, symblepharon formation, subsequent trichiasis and eventually entropion.¹⁻¹⁵

Cicatrization of the plica is considered a pathognomonic sign early in the disease.² Even in the absence of conjunctival inflammation, ankyloblepharon (adhesion of the ciliary margins of the upper and lower lids together) has been documented to form. The process can present differently with a varied course ranging from low-level chronic disease with a build up to more advanced stages with acute symptoms. Some cases are missed because they present with the nondescript signs of periodic conjunctival inflammation and minimal symptoms.¹⁰ The process is finally discovered when the more severe, chronic signs become visible. In cases exhibiting asymmetric presentation, the fellow eye typically begins to manifest signs within two years of the first.^{3,6}

Patients with the condition often present with a variable list of ongoing symptoms ranging from ocular dryness and foreign body sensation to frank pain,

photophobia, lacrimation, conjunctival blistering and vision loss.⁴ As the disease progresses, limbal stem cell deficiency, tear deficiency and lid malposition has the potential to produce total keratinization of the ocular surface.¹⁻¹⁰ The condition is rare in children and has an estimated incidence of one in 12,000 to one in 60,000 in adults over the age of 65.^{3,6} Unfortunately, this grossly underestimates the scope because cases are typically not reported until the disease has entered its later stages.^{3,6} OCP has a preponderance for women at a rate of 3:1.^{3,6} There is no racial predilection.¹⁻¹⁰

Pathophysiology

Ocular cicatricial pemphigoid is an autoimmune disease characterized by mucous membrane fibrosis and skin changes with resulting scarring.¹⁰ Its pathogenic mechanisms are not completely understood.¹⁰ Theories suggest that anti-basement membrane antibodies lead to subepithelial blistering and the formation of granulation tissue with inflammatory infiltrate depositing in the substantia propria layer at the dermal-epidermal junction of the affected region.¹⁰ Eosinophils and increased collagen type I and III along with human leukocyte antigens HLA-DR2, HLA-DR4 and DQw7 have been identified as conferring increased susceptibility.¹⁰

In the combination form (oral and ocular), lesions frequently develop in the oral cavity, followed by lesions in the conjunctiva, nasopharynx, the anogenital region, skin, larynx and esophagus.^{1,2}

The Foster staging system has been used in the literature to define the advancement of the disease.

Foster Stage 1: OCP displays chronic conjunctivitis with a characteristic subepithelial fibrosis.

Foster Stage 2: In this stage, noted subepithelial fibrosis has progressed and contracts to create shortening of the inferior fornix; this stage of the disease can be further subdivided according to

the percentage of fornical shortening.

Foster Stage 3: Symblephara form in the inferior fornix inducing more fornix shortening.

Foster Stage 4: Labeled end-stage OCP demonstrates debilitating ocular surface keratinization with complete absence of any inferior fornix and the initiation of processes that will result in corneal vascularization. While the inferior fornix is affected earlier in the disease than the superior, ultimately no aspect of the conjunctival surface is spared.^{3,6}

The pathophysiology related to the secondary open-angle glaucoma seen in patients with OCT may have multiple mechanisms.^{3,6,11-15} Patients with the combination of OCP and glaucoma typically present with a long history of raised intraocular pressure as well as a difficult battle with disease stabilization.^{3,6,11-15}

The elevated IOP condition is theorized to develop from, among other things, response to the systemic anti-inflammatory therapy (steroids), impaired outflow of aqueous humor created by chronic high-grade conjunctival inflammation and the anterior chamber congestion that accompanies it, a genetic susceptibility to glaucoma, and conjunctival cicatrization inducing alterations in aqueous outflow.¹²

The diagnosis of OCP requires direct immunofluorescence microscopy to demonstrate a linear deposition of immunoglobulin (Ig)G or IgA or complement component 3 (C3) at the epithelial basement membrane junction of a conjunctival biopsy.³ Although the target antigens vary, subsets of patients affected exclusively by oral and ocular mucosal diseases have autoantibodies that target α -6 and β -4 integrins, respectively.¹ Other useful diagnostic findings include the presence of tumor necrosis factor- α , autoantibodies against type XVII and VII collagen, laminin 5 and 6, alpha 6 beta 4 integrin.^{1-4,16}

Management

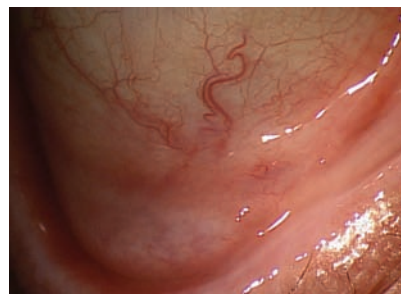Since OCP primarily destroys the support systems for the ocular surface, the priority must be lid, tear film and conjunctival preservation and protection. As the disease is a manifestation of autoimmune disease, concurrent systemic anti-inflammatory and immunomodulatory management with the internist and rheumatologist is mandatory.^{1-11,14,16-24}

Ocular management consists of copious artificial lubrication in combination with topical anti-inflammatory agents.²¹⁻²⁴ Cyclosporine BID in concert with topical steroids (prednisolone acetate or prednisolone sodium phosphate, difluprednate) QID can be used to decrease symptoms and surface inflammation, slowing or arresting scar development.²¹⁻²³

Topical non-steroidal anti-inflammatory medications BID-QID can also be used. Recently, other topically applied calcineurin inhibitors, namely tacrolimus and pimecrolimus have shown benefit.²² Punctal plugs can be installed to increase the lacrimal lake.²³ Filamentary keratopathy can be managed by removing the corneal filaments with a forceps or by bandaging them with a soft hydrogel contact lens.²⁵

Corneal defects can be prophylaxed with topical antibiotics until they heal. Persistent corneal defects can be managed with rigid gas permeable, soft hydrogel or scleral contact lenses.²⁶⁻²⁹ Scleral lenses are often underused because of inexperience.

The benefits of these larger-diameter devices include the creation of a substantial precorneal tear reservoir improving and maintaining corneal hydration while simultaneously providing complete coverage and protection of the corneal surface from external environmental stress and the iatrogenic effects of the lid margins and lashes.^{28,29} Contact lenses relieve pain, prevent exposure and enhance the surface



Ocular cicatricial pemphigoid. (Courtesy of TSI/ Paul Karpecki, OD.)

chemistry improving epithelial healing.²⁶⁻²⁹

Systemic immunomodulatory therapy is the treatment of choice for controlling disease activity and limiting progression, given the systemic nature of the disease and the poor efficacy of current local or topical therapies.^{1-22,30-32} The management should be accomplished using a multidisciplinary approach.¹⁷ Systemic cyclophosphamide with short-term adjunctive high-dose prednisone is the preferred treatment for severe and/or rapidly progressing OCP.^{17,30} Data suggests that cyclophosphamide provides an effective bridge to lowering the dose of systemic corticosteroids (10mg prednisone or less).³⁰ Oral low-dose weekly methotrexate is another useful first-line treatment for mild-to-moderate OCP.¹⁷ In many instances, disease remission can be induced with well-tolerated therapy.^{17,18,24} This aspect of therapy is best directed by a rheumatologist.

Ocular cicatricial pemphigoid can also be treated with cytoxan (a synthetic antineoplastic agent), dapsone (a sulfa antibacterial), minocycline, etanercept and azathioprine (an immunosuppressive agent).³² Etanercept is a recombinant human dimeric fusion protein that acts as a competitive inhibitor of TNF-alpha. Pentoxifylline added to doses of pulsed steroid and cyclophosphamide therapy is an alternative, effective and economical method of controlling OCP through reduction of TNF- α levels.^{16,32}

Mycophenolate mofetil (MMF) is a potent immunomodulatory drug that inhibits the function of T- and B-lymphocytes.²⁰ MMF can be used alone or in combination with other immunomodulatory drugs for moderate to severe cases of uveitis, scleritis and ocular cicatricial pemphigoid.²⁰

Recent developments on mucous membrane pemphigoid medical therapy include the additions of daclizumab (monoclonal antibody agent), intravenous immunoglobulin therapy and methotrexate (antimetabolite/antifolate agent).^{10,33}

Surgical therapies include keratolimbal allografts and amniotic membrane transplantation with or without penetrating keratoplasty.^{4,34} Amniotic membrane transplantation, in the setting of pre- and post-immunosuppressive therapy is very useful for reconstruction of the conjunctival fornices.^{4,34} Keratoprosthesis can be used in cases where the ocular surface is beyond repair or reconstruction.³⁵

Finally, ophthalmic plastic surgery is essential for the management of lid malposition and corneal exposure. Corneal and ocular surface reconstructive surgery may be required in the most advanced stages. All surgery must be integrated with ocular surface treatment and immunosuppressive treatment to avoid disease exacerbations.

Clinical Pearls

- Patients with OCP and disrupted lid/globe relationships become susceptible to microbial colonization from normal eyelid flora. Combination anti-infective and anti-inflammatory therapies are necessary for success.

- Severe dry eye is a late finding in ocular cicatricial pemphigoid. The disease induces conjunctival scarring that obstructs the meibomian gland ducts and lacrimal gland ducts, creating deficiencies in both the lipid and aqueous components of tears.

Goblet cell loss reduces the mucus component of the tear film, retarding the tears' ability to maintain surface contact. Without appropriate mitigation of all issues, the ocular surface will become permanently disfigured and functionally compromised.

- Other processes have the ability to produce cicatricial conjunctival changes, including mechanical trauma, chemical injury, ligneous conjunctivitis, adeno-viral conjunctivitis, Steven's-Johnson syndrome, Wegener's granulomatosis, chlamydia infection, sarcoidosis, Sjögren's syndrome, systemic lupus erythematosus, conjunctival cancers and drug-induced exposure to epinephrine and pilocarpine. Each of these conditions must be considered in the differential diagnosis.


1. Chan LS. Ocular and oral mucous membrane pemphigoid (cicatricial pemphigoid). *Clin Dermatol*. 2012;30(1):34-7.
2. Schmidt E, Meyer-Ter-Vehn T, Zillikens D, Geerling G. Mucous membrane pemphigoid with ocular involvement. Part I: Clinical manifestations, pathogenesis and diagnosis. *Ophthalmologie*. 2008;105(3):285-97.
3. Kirzhner M, Jakobiec FA. Ocular cicatricial pemphigoid: a review of clinical features, immunopathology, differential diagnosis, and current management. *Semin Ophthalmol*. 2011;26(4-5):270-7.
4. Foster CS, Sainz De La Maza M. Ocular cicatricial pemphigoid review. *Curr Opin Allergy Clin Immunol*. 2004;4(5):435-9.
5. Khari M, Khaled A, Anane R, et al. Early onset childhood cicatricial pemphigoid: a case report and review of the literature. *Pediatr Dermatol*. 2010;27(2):119-24.
6. Foster CS. Cicatricial pemphigoid. *Trans Am Ophthalmol Soc*. 1986;84(3):527-663.
7. Saw VP, Dart JK. Ocular mucous membrane pemphigoid: diagnosis and management strategies. *Ocul Surf*. 2008;6(3):128-42.
8. Daniel E, Thome JE. Recent advances in mucous membrane pemphigoid. *Curr Opin Ophthalmol*. 2008;19(4):292-7.
9. Mameletzi E, Hamedani M, Majo F, Guex-Crosier Y. Clinical manifestations of mucous membrane pemphigoid in a tertiary center. *Klin Monbl Augenheilkd*. 2012;229(4):416-9.
10. Brydak-Godowska J, Moneta-Wielgoś J, Pauk-Domańska M, et al. Diagnostics and pharmacological treatment of ocular cicatricial pemphigoid. *Klin Oczna*. 2005;107(10-12):725-7.
11. Satake Y, Higa K, Tsubota K, Shimazaki J. Long-term outcome of cultivated oral mucosal epithelial sheet transplantation in treatment of total limbal stem cell deficiency. *Ophthalmology*. 2011;118(8):1524-30.
12. Tauber J, Melamed S, Foster CS. Glaucoma in patients with ocular cicatricial pemphigoid. *Ophthalmology*. 1989;96(1):33-7.
13. Messmer EM, Hintschich CR, Partscht K, et al. Ocular cicatricial pemphigoid. Retrospective analysis of risk factors and complications. *Ophthalmologie*. 2000;97(2):113-20.
14. Miserocchi E, Baltatzis S, Roque MR, et al. The effect of treatment and its related side effects in patients with severe ocular cicatricial pemphigoid. *Ophthalmology*. 2002;109(1):111-8.
15. Daoud YJ, Letko E, Nguyen QD, et al. Aqueous humor outflow facility in ocular cicatricial pemphigoid. *Middle East Africa Journal of Ophthalmology*. 2007;14(2):41-45.
16. El Darouti MA, Fakhry Khattab MA, Hegazy RA, et al. Pentoxifylline (anti-tumor necrosis factor drug): effective adjuvant therapy in the control of ocular cicatricial pemphigoid. *Eur J Ophthalmol*. 2011;21(5):529-37.
17. Chang JH, McCluskey PJ. Ocular cicatricial pemphigoid: manifestations and management. *Curr Allergy Asthma Rep*. 2005;5(4):333-8.
18. Saw VP, Dart JK, Rauz S, et al. Immunosuppressive therapy for ocular mucous membrane pemphigoid strategies and outcomes. *Ophthalmology*. 2008;115(2):253-61.
19. Tauber J. Ocular cicatricial pemphigoid. *Ophthalmology*. 2008;115(9):1639-40.
20. Klisovic DD. Mycophenolate mofetil use in the treatment of noninfectious uveitis. *Dev Ophthalmol*. 2012;51(1):57-62.
21. Kaçmaz RO, Kempen JH, Newcomb C, et al. Cyclosporine for ocular inflammatory diseases. *Ophthalmology*. 2010;117(3):576-84.
22. Fistarol SK, Iltin PH. Anti-inflammatory treatment. *Curr Probl Dermatol*. 2011;40(1):58-70.
23. Kiire CA, Srinivasan S, Inglis A. Peripheral ulcerative keratitis after cataract surgery in a patient with ocular cicatricial pemphigoid. *Cornea*. 2011;30(10):1176-8.
24. Saw VP, Dart JK. Ocular mucous membrane pemphigoid: diagnosis and management strategies. *Ocul Surf*. 2008;6(3):128-42.
25. Gong X, Zhong X, Yang X, Wang M. The study of the therapeutic application of PV contact lens. *Yan Ke Xue Bao*. 2005;21(2):67-9, 81.
26. Schornack MM, Baratz KH. Ocular cicatricial pemphigoid: the role of scleral lenses in disease management. *Cornea*. 2009;28(10):1170-2.
27. Romero-Rangel T, Stavrou P, Cotter J, et al. Gas-permeable scleral contact lens therapy in ocular surface disease. *Am J Ophthalmol*. 2000;130(1):25-32.
28. Jacobs DS. Update on scleral lenses. *Curr Opin Ophthalmol*. 2008;19(4):298-301.
29. Pullum K, Buckley R. Therapeutic and ocular surface indications for scleral contact lenses. *Ocul Surf*. 2007;5(1):40-8.
30. Pujari SS, Kempen JH, Newcomb CW, et al. Cyclophosphamide for ocular inflammatory diseases. *Ophthalmology*. 2010;117(2):356-65.
31. Ford RM, Khalifa YM. Improvement in ocular cicatricial pemphigoid following treatment for porphyria cutanea tarda. *Clin Ophthalmol*. 2012;10(6):1709-12.
32. Kennedy JS, Devillez RL, Henning JS. Recalcitrant cicatricial pemphigoid treated with the anti-TNF-alpha agent etanercept. *J Drugs Dermatol*. 2010;9(1):68-70.
33. Papaliodis GN, Chu D, Foster CS. Treatment of ocular inflammatory disorders with daclizumab. *Ophthalmology*. 2003;110(4):786-9.
34. Liu J, Sheha H, Fu Y, Giegengack M, Tseng SC. Oral mucosal graft with amniotic membrane transplantation for total limbal stem cell deficiency. *Am J Ophthalmol*. 2011;152(5):739-47.
35. Ciralsky J, Papaliodis GN, Foster CS, ET AL. Keratoprosthesis in autoimmune disease. *Ocul Immunol Inflamm*. 2010;18(4):275-80.
36. Fania L, Giannico MI, Fasciani R, et al. Ocular mucous membrane pemphigoid after Lyell syndrome: occasional finding or predisposing event? *Ophthalmology*. 2012;119(4):688-93.

Who knew that Glaucoma Diagnosis would start with an Apple Drop?



Sometimes brilliant ideas just hit you in the head. Like determining glaucoma risk with corneal hysteresis. Reichert's Ocular Response Analyzer® (ORA) measures the biomechanical properties of the eye providing the most accurate data for predicting glaucoma progression. Make your next glaucoma decision with gravity minus the guesswork.

Learn more. Call 1-888-849-8955, or visit reichert.com/ora.



The New Physics of Glaucoma.

CORNEAL FOREIGN BODY

Signs and Symptoms

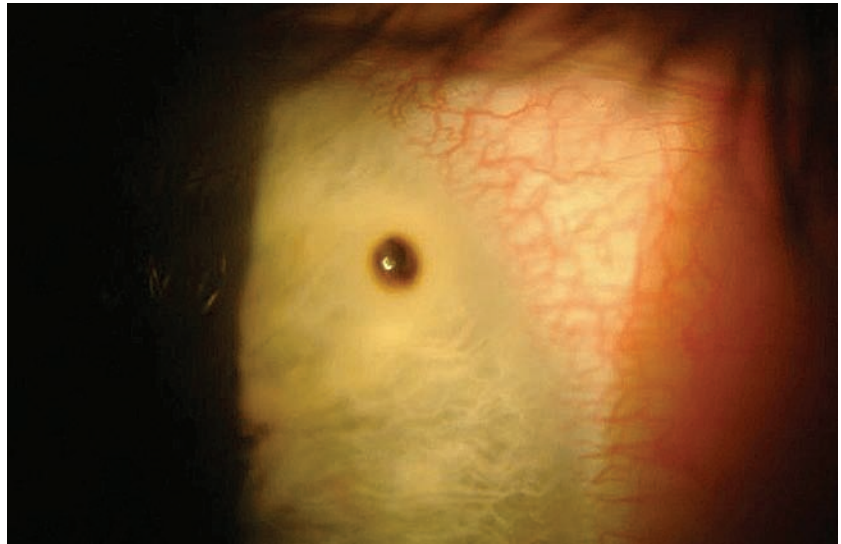
Typically, corneal foreign body injuries present as an emergency following acute injury, making them a common urgent clinical entity of ophthalmic practice.¹⁻¹² Patients present with acute pain, photophobia, pain upon extraocular muscle movement and blinking, lacrimation, blepharospasm, foreign body sensation, variably blurry vision (depending upon the location of the particle) and a history of having something “go in their eye.”¹⁻⁹ In rare cases, the patient may be asymptomatic.

Biomicroscopic examination often reveals diffuse corneal edema and epithelial disruption. In severe cases, when edema is excessive, folds in Descemet’s membrane may be present. Circumlimbal injection with a greater density of conjunctival erythema adjacent to the site of injury is common if the injury induces anterior uveitis. Cobalt blue light inspection, with the instillation of sodium fluorescein dye, will illuminate the damaged cornea.⁸

There is no gender predilection specifically; however, the majority of affected individuals are young, typically under age 20 and male.¹²⁻¹⁵ Workshop equipment, tools, the activity of construction and motorized lawn equipment are all notable sources of ocular injury.^{12,14,16,17} Inorganic foreign bodies (plastic, glass) tend to be better tolerated than organic material (wood).⁹

Pathophysiology

The cornea has five distinct layers: the corneal epithelium, Bowman’s membrane (a whirling structure designed to prevent penetrating injuries), the organized 250 lamellar sheet stroma, Descemet’s membrane and the metabolic endothelium.¹⁹⁻²⁴



High-magnification view of metallic corneal foreign body.

There are two categories in which corneal foreign bodies may injure the cornea: superficial (not involving Bowman’s membrane) and deep (penetrating Bowman’s but not rupturing Descemet’s membrane). Corneal foreign bodies typically enter the epithelium but are prevented from penetrating deep into the tissue by Bowman’s membrane.²³ Foreign objects piercing Bowman’s membrane will typically leave a permanent scar.^{15,16}

The cornea has remarkable healing properties. The epithelium adjacent to any insult expands in size to fill in the defect, usually within 24-48 hours.¹⁸ Below the epithelium, there is no mechanism for cellular replacement. Here, cells enlarge (polymegathism), change shape (pleomorphism) or move over.²⁴

Lesions that are purely epithelial often heal quickly and completely without scarring. Unfortunately, if there is any collateral destruction of limbal stem cells, superficial corneal injuries may develop into recurrent epithelial ulcerations, chronic stromal ulcers with deep stromal vascularization, or develop conjunctival over-

lap.²⁵⁻²⁷ Corneal avascularity is moderated by anti-angiogenic factors.^{26,27} These factors counterbalance pro-angiogenic/lymphangiogenic factors that are constantly available, becoming upregulated during wound healing.²⁷ Angiogenic proteins (vascular endothelial growth factor and basic fibroblast growth factor) and angiogenesis regulatory proteins, along with matrix metalloproteinases and lymphangiogenic regulatory proteins, all play vital roles during corneal wound healing.²⁷

All corneal injuries induce an inflammatory reaction that exerts trophic influences in the corneal epithelium, damaging sensory nerves.²⁸ Alterations in normal healing disrupts the integrity and function of the tissue with undesirable consequences, ranging from inability to wet with resultant loss of transparency to infectious ulceration and perforation.²⁸

Management

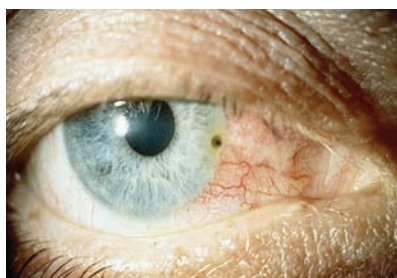Treatment of an injury due to corneal foreign body begins with a problem-oriented history. Since patients are often in distress, the process should be streamlined and

succinct. The time, place and activity surrounding the injury should be recorded. Visual acuity (VA) should be recorded, if possible, before any procedures or drops are given. If the blepharospasm and photophobia are sufficiently intense, one drop of topical anesthetic can be administered to allow for VA measurement.

The examination should include pupil testing and an external evaluation of the adnexa and then proceed to biomicroscopy. The eyelids should be everted and fornices scrutinized to rule out the presence of hidden foreign material. Fluorescein dye (preferably without anesthetic) should be instilled to assist in identifying corneal defects and locating potential debris. The Seidel test (painting of the wound with fluorescein dye and observing for aqueous leakage) should be performed if a full-thickness cornea/globe perforation is suspected or the foreign material hit the eye at high speed.

Any injury should be documented for size, shape, location and depth. Corneal abrasions should be cleaned and scrutinized for foreign matter. The anterior chamber should be evaluated for uveitis. A dilated examination should be completed (either at time of initial evaluation or soon at follow-up) to rule out any posterior effects from the trauma and rule out penetrating foreign body.

Corneal foreign bodies can be removed using stream lavage with sterile saline, forceps, a cotton-tipped applicator, or a foreign body spud or a loop. However, among the most popular instruments is a hypodermic needle mounted on a syringe.²⁹⁻³³ This method affords several advantages: sterility, reach, control over the size of the probe (23- to 30-gauge typically), sharpness for mild excavation, availability, inexpensive cost and ease of use.



Metallic corneal foreign body and associated redness of the conjunctiva.

Generally, the procedure is accomplished following the administration of one or two drops of a topical anesthetic such as proparacaine.^{32,33} If the patient is unable to maintain eyelid opening, a lid speculum may be required. The patient should maintain a gaze that affords the clinician the best lateral approach to the entrapped particle. If the corneal foreign body is a “corneal splinter,” the best approach may be with a forceps; however, the technique for reaching the foreign body is still safe and sound.

In the event the foreign body is metallic and has oxidized, the resultant ‘rust ring’ should be removed at the time of the foreign body, as long as it is determined to be safe from enlarging the potential scar zone. Some clinicians prefer the use of a motorized burr (Alger brush) to lift superficial rust rings; however, often these devices inadvertently enlarge the region of corneal abrasion around the residual crater and, in some cases, can penetrate a weakened cornea. If the risk-to-benefit ratio for rust removal is significant, the rust can be left to advance to the surface during the healing process where it can be more easily removed later.³⁴ Rust-ring infiltrate does not serve as an indicator of corneal infection.³⁵

The treatment for the residual superficial corneal injury is universal. Pain can be mitigated using cycloplegia (atropine 1% QD-TID, for the

worst and homatropine 5%, in the office, for the mildest), and topical non-steroidal anti-inflammatory medications BID-QID. Infection can be prevented using topical antibiotics.³⁶⁻⁴⁰ Bed rest, inactivity, cold compresses, artificial tear drops and over-the-counter analgesics (acetaminophen or ibuprofen) can be used to relieve acute pain. In cases where pain is severe or the abrasion extensive, a thin, low-water-content bandage contact lens can be applied.³⁸⁻⁴³ Pressure patching is not contraindicated, although it is no longer considered standard-of-care.³⁸⁻⁴³

Patients should be reevaluated every 24-48 hours until the injury demonstrates a restored epithelium.³⁷⁻³⁹ Topical lubricants and antibiotic ointment at bedtime can provide analgesia and cushioning to the lesion during the reparative process. Topical steroids can be added after the initial healing has taken place to prevent subepithelial infiltration and to mitigate inflammation. An alternative approach involves a fixed topical antibiotic/steroidal combination preparation where appropriate.

Clinical Pearls

- A peaked pupil, full-thickness corneal defect, focal lenticular opacity or disproportionate inflammation (hypopyon) may be indicative of a penetrating injury.
- High-speed particles that are hot have the potential to enter the cornea and produce self-sealing wounds. Here, particles may enter the interior areas of the eye without producing a Seidel sign.
- In cases where necrotic, loose epithelium impairs healing, a cotton-tipped applicator saturated with anesthetic may be used to debride the loose or excessive tissue.
- When significant uveitis is present or if subepithelial infiltration

occurs during the reparative process, topical steroids may be required.

- Rapid, aggressive subepithelial infiltration, increased pain and increased injection in the setting of an epithelial break may be a sign of infection. Lesions such as these should be considered vision threatening, warranting immediate treatment with a fourth-generation fluoroquinolone antibiotic (if one is not already employed).

1. Kumar NL, Black D, McClellan K. Daytime presentations to a metropolitan ophthalmic emergency department. *Clin Experiment Ophthalmol.* 2005;33(6):586-92.
2. Lubeck D, Greene JS. Corneal injuries. *Emerg Med Clin North Am.* 1988;6(1):73-94.
3. Agrawal R, Laude A, Taneja M. Fish-hook injury of the eye. *Int Ophthalmol.* 2012;32(3):269-71.
4. Yit O, Yürüktümen A, Arslan S. Foreign body trauma of the eye managed in an emergency department of a single-institution. *Ulus Travma Acil Cerrahi Derg.* 2012;18(1):75-9.
5. Wiwatwongwana D, Jariyapan N, Wiwatwongwana A. Eyelid bee sting with late migration onto the cornea after primary removal: the mystery of the bee stinger. *Arch Ophthalmol.* 2012;130(3):392-3.
6. Ramakrishnan T, Constantinou M, Jhanji V, Vajpayee RB. Corneal metallic foreign body injuries due to suboptimal ocular protection. *Arch Environ Occup Health.* 2012;67(1):48-50.
7. Gumus K, Karakucuk S, Mirza E. Corneal injury from a metallic foreign body: an occupational hazard. *Eye Contact Lens.* 2007;33(5):259-60.
8. Mansouri MR, Mirshahi A, Hosseini M. Domestic ocular injuries: a case series. *Eur J Ophthalmol.* 2007;17(4):654-9.
9. Covert DJ, Henry CR, Sheth BP. Well-tolerated intracorneal wood foreign body of 40-year duration. *Cornea.* 2009;28(5):597-8.
10. Eiferman RA, O'Neill KP, Forgey DR, Cook YD. Excimer laser photorefractive keratectomy for myopia: six-month results. *Refract Corneal Surg.* 7(5):344-7.
11. Negussie D, Bejiga A. Ocular emergencies presenting to Menelik II Hospital. *Ethiop Med J.* 2011;49(1):17-24.
12. McGwin G Jr, Owsley C. Incidence of emergency department-treated eye injury in the United States. *Arch Ophthalmol.* 2005;123(5):662-6.
13. MacEwen CJ, McLatchie GR. Eye injuries in sport. *Scott Med J.* 2010;55(2):22-4.
14. Forrest KY, Cali JM. Epidemiology of lifetime work-related eye injuries in the U.S. population associated with one or more lost days of work. *Ophthalmic Epidemiol.* 2009;16(3):156-62.
15. Blackburn J, Levitan EB, MacLennan PA, et al. A case-crossover study of risk factors for occupational eye injuries. *J Occup Environ Med.* 2012;54(1):42-7.
16. Zhao J, Nagasaki T. Mechanical damage to corneal stromal cells by epithelial scraping. *Cornea.* 2004;23(5):497-502.
17. Gordon KD. The incidence of eye injuries in Canada. *Can J Ophthalmol.* 2012;47(4):351-3.

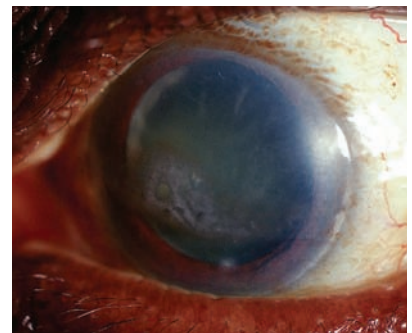
18. Leinert J, Griffin R, Blackburn J, McGwin G Jr. The epidemiology of lawn trimmer injuries in the United States: 2000-2009. *J Safety Res.* 2012;43(2):137-9.
19. Angelini TE, Dunn AC, Urueña JM, et al. Cell friction. *Faraday Discuss.* 2012;156:31-9.
20. Ellenberg D, Azar DT, Hallak JA, et al. Novel aspects of corneal angiogenic and lymphangiogenic privilege. *Prog Retin Eye Res.* 2010;29(3):208-48.
21. Kaiser PK. The Corneal Abrasion Patching Study Group. A comparison of pressure patching versus no patching for corneal abrasions due to trauma or foreign body removal. *Ophthalmology.* 1995;102(12):1936-42.
22. Fujikawa LS, Nussenblatt RB. Recurrent and Chronic Corneal Epithelial Defects. In: Abbott, R.L. *Surgical Intervention in Corneal and External Diseases.* New York: Grune & Stratton, Inc. 1987: 59-67.
23. Snell RS, Lemp MA. The eyeball. In: Snell RS, Lemp MA. *Clinical anatomy of the eye, 2nd Ed.* Blackwell Science Inc.;1998:132-213.
24. Oyster CW. The cornea and sclera. In: Oyster CW. *The human eye structure and function.* Cinar Associates Inc., 1999: 325-378.
25. Merle H, Gérard M, Schrage N. Ocular burns. *J Fr Ophtalmol.* 2008;31(7):723-34.
26. Azar DT. Corneal angiogenic privilege: angiogenic and antiangiogenic factors in corneal avascularity, vasculogenesis, and wound healing (An American Ophthalmological Society Thesis) *Trans Am Ophthalmol Soc.* 2006;104(12):264-302.
27. Ellenberg D, Azar DT, Hallak JA, et al. Novel aspects of corneal angiogenic and lymphangiogenic privilege. *Prog Retin Eye Res.* 2010;29(3):208-48.
28. Kenchegowda S, Bazan HE. Significance of lipid mediators in corneal injury and repair. *J Lipid Res.* 2010;51(5):879-91.
29. Erakgün T, Ates H, Akkin C, Kaskaloglu M. A simple "lasso" for intraocular foreign bodies. *Ophthalmic Surg Lasers.* 1999;30(1):63-6.
30. Ramakrishnan T, Constantinou M, Jhanji V, Vajpayee RB. Corneal metallic foreign body injuries due to suboptimal ocular protection. *Arch Environ Occup Health.* 2012;67(1):48-50.
31. Keeney AH. Evaluation and management of corneal foreign bodies. *J Fam Pract.* 1975;2(5):381-4.
32. Ferrera PC, Chandler R. Anesthesia in the emergency setting: Part II. Head and neck, eye and rib injuries. *Am Fam Physician.* 1994;50(4):797-800.
33. Abrahamson IA Jr. Management of ocular foreign bodies. *Am Fam Physician.* 1976;14(3):81-7.
34. Crowther KS, Ellingham RB. Complicated removal of corneal foreign bodies 18 months after laser in situ keratomileusis. *J Cataract Refract Surg.* 2005;31(4):851-2.
35. DeBroff BM, Donahue SP, Caputo BJ, et al. Clinical characteristics of corneal foreign bodies and their associated culture results. *CLAO J.* 1994;20(2):128-30.
36. Meek R, Sullivan A, Favilla M, et al. Is homatropine 5% effective in reducing pain associated with corneal abrasion when compared with placebo? A randomized controlled trial. *Emerg Med Australas.* 2010;22(6):507-13.
37. Fraser S. Corneal abrasion. *Clin Ophthalmol.* 2010;4(5):387-90.
38. Hua L, Doll T. A series of 3 cases of corneal abrasion with multiple etiologies. *Optometry.* 2010;81(2):83-5.
39. Turner A, Rabiu M. Patching for corneal abrasion. *Cochrane Database Syst Rev.* 2006;4(2):CD004764.
40. Kaiser PK, Pineda II R. A study of topical non-

- steroidal anti-inflammatory drops and no pressure patching in the treatment of corneal abrasions. *Ophthalmology.* 1997;104(8): 1353-9.
41. Holland S, Morck D, Schultz C. Treatment of corneal defects with delayed re-epithelization with a medical device/drug delivery system for epidermal growth factor. *Clin Experiment Ophthalmol.* 2012;40(7):662-8.
42. Kaiser PK. The Corneal Abrasion Patching Study Group. A comparison of pressure patching versus no patching for corneal abrasions due to trauma or foreign body removal. *Ophthalmology.* 1995;102(12):1936-42.
43. Willoughby CE, Batterbury M, Kaye SB. Collagen corneal shields. *Survey of Ophthalmology.* 2002;47(2):174-82.

BAND KERATOPATHY

Signs and Symptoms

Band keratopathy can afflict any patient regardless of age, sex or race. Early in the course of the disease, individuals tend to be asymptomatic. Glare, photophobia, foreign body sensation, ocular surface dryness and surface erosions gradually develop over time, and may evolve so as to cause significant pain. At this stage, patients are often visually symptomatic with acuity reduction, possibly to a level of 20/400 or worse. Fortunately, the majority of patients will maintain acuity in the 20/40 to 20/200 range.¹



Band keratopathy.

On biomicroscopic evaluation, patients with band keratopathy display a dense, opaque white accumulation of calcific material in the superficial cornea, usually within the interpalpebral zone.² The appearance has been described as that of frosted, ground

glass. Typically, the band begins in the limbal region and progresses centrally from both the nasal and temporal periphery; as such, the calcific material appears most dense near the limbus. Initially, there will be a sharp demarcation with a small band of normal cornea separating the peripheral edge of the keratopathy from the limbus.³

The key diagnostic feature is the presence of areas where clear cornea shows through the calcific opalescence. This has been described as a “Swiss cheese” appearance, and represents areas where corneal nerves penetrate Bowman’s membrane.^{1,2}

The majority of cases of band keratopathy are idiopathic.¹ However, there are also a great number of underlying conditions, both systemic and ocular, which can contribute to the development of band keratopathy. Systemically induced band keratopathy tends to be bilateral, whereas ocularly-induced or idiopathic forms are typically unilateral.¹ Often, there is a history of chronic, recurrent anterior uveitis, corneal ulceration, corneal burn or other ocular inflammatory disease.² The presence of uveitis and band keratopathy concurrently in a young person is highly indicative of juvenile idiopathic arthritis (JIA).^{1,2,4-9} Systemic conditions that cause increased blood calcium levels can also lead to the development of band keratopathy. Thus, there is often a history of hyperparathyroidism in these patients.¹⁰⁻¹²

Other systemic conditions associated with band keratopathy development include renal failure, gout and sarcoidosis.^{10,13-15} Other ocular conditions that have been seen in association with band keratopathy include chronic glaucoma and use of older glaucoma medications (e.g., pilocarpine), interstitial keratitis, dry eye, corneal exposure and intraocular silicone oil tamponade.^{2,7,16,17} Chronic corneal edema is a common cause of band keratopathy.¹

In addition, there is a recognized hereditary component and a form of the disease known as familial band keratopathy.^{18,19}

Pathophysiology

Band keratopathy represents a deposition of calcium salts into the anterior corneal stroma and Bowman’s layer. The precise mechanism appears to be multifactorial, but chronic inflammation and a modification of the ocular surface pH almost certainly play a role. Evaporation of tears increases the tonicity/osmolarity of the tear film, allowing for the potential of ionic salt precipitation.²⁰ Elevated serum calcium or phosphate can enhance this activity, as can increased alkalinity of the tear film (as seen in chronic dry eye states).

Interestingly, this type of tissue pH shift can also be seen in chronically inflamed eyes. Ultimately, the changes induce degeneration and abnormal cellular metabolism within the cornea, leading to the pathological changes in band keratopathy.^{21,22} Histological evaluation shows elevated peaks of calcium and phosphorus within the area of granular deposits, as well as dense material consistent with extracellular calcospherites.²¹

Hypercalcemia from systemic hyperparathyroidism is a common cause of band keratopathy.¹⁰⁻¹² Hyperparathyroidism results from excessive production of parathormone, usually due to parathyroid adenoma, but also from ectopic parathormone production related to pulmonary or renal cancer.²³ Band keratopathy is also frequently found in association with JIA, presumably due to the chronicity of anterior uveitis in this condition.⁴⁻⁹

Management

All patients with band keratopathy should be evaluated for abnormal cal-

cium metabolism. Referral to an endocrinologist for evaluation and parathyroid function testing is indicated. If the patient is of younger age, or particularly if there is concurrent cataract and uveitis, referral to a rheumatologist to evaluate for JIA is appropriate. It should be remembered that malignant disease can also cause abnormal calcium metabolism. Cases demonstrating unusual laboratory findings may merit evaluation by an oncologist.

Initially, band keratopathy should be managed with topical lubricants, particularly if tear dysfunction is evident. Eventually, however, more aggressive management is generally necessary. When the calcium plaque is thick, it can be debrided from the superficial cornea using a forceps, burr or foreign body spud. Chelation with 3% ethylenediaminetetraacetic acid (EDTA) has been a procedure of choice since it was described in the 1950s and will generally resolve band keratopathy.^{1,24}

In this procedure, the anesthetized epithelium is gently debrided with either a cotton-tipped applicator soaked in topical anesthetic or with a foreign body removal instrument. Next, a cotton-tipped applicator or wick sponge soaked in EDTA is brushed across the calcium-deposited cornea from five to 45 minutes, depending upon the thickness of the plaque. The eye is then bandaged with a soft contact lens and prophylactic topical antibiotics are prescribed QID until re-epithelialization is achieved. In these cases, the epithelium is slower to heal than for a similarly sized traumatic corneal abrasion as the abnormal corneal metabolism retards efficient repair.¹

Other, newer therapeutic modalities have also been explored. Surgical intervention via lamellar keratoplasty has been shown to help patients achieve both visual and structural success.^{25,26} Phototherapeutic keratectomy using

the excimer laser has also demonstrated high rates of visual and structural improvement, and can be considered a safe, front-line therapy for band keratopathy.²⁷⁻²⁹ The adjunctive use of amniotic membrane transplantation to promote epithelial healing, reduce inflammation and scarring, and provide a stable ocular surface has improved the success of the other treatment options.^{26,30-32}

Clinical Pearls

- The combination of band keratopathy, uveitis and cataract in juvenile idiopathic arthritis is termed Still's Triad.³³
- Band keratopathy in patients under 16 years of age is highly suggestive of JIA.
- Visual prognosis is guarded in patients with band keratopathy, as the underlying condition that promoted calcium deposition often causes recurrence.
- Band keratopathy can signal malignant processes and may indicate the need for evaluation in that area.

- Najjar DM, Cohen EJ, Rapuano CJ, et al. EDTA chelation for calcific band keratopathy: results and long-term follow-up. *Am J Ophthalmol.* 2004;137(6):1056-64.
- Jhanji V, Rapuano CJ, Vajpayee RB. Corneal calcific band keratopathy. *Curr Opin Ophthalmol.* 2011;22(4):283-9.
- Kwon YS, Song YS, Kim JC. New treatment for band keratopathy: superficial lamellar keratectomy, EDTA chelation and amniotic membrane transplantation. *J Korean Med Sci.* 2004;19(4):611-5.
- Heiligenhaus A, Niewerth M, Mingels A, et al. Epidemiology of uveitis in juvenile idiopathic arthritis from a national paediatric rheumatologic and ophthalmologic database. *Klin Monatsbl Augenheilkd.* 2005;222(12):993-1001.
- Carvounis PE, Herman DC, Cha S, et al. Incidence and outcomes of uveitis in juvenile rheumatoid arthritis, a synthesis of the literature. *Graefes Arch Clin Exp Ophthalmol.* 2006;244(3):281-90.
- Mahdavian S, Higgins GC, Kerr NC. Orbital pseudotumor in a child with juvenile rheumatoid arthritis. *J Pediatr Ophthalmol Strabismus.* 2005;42(3):185-8.
- Rosenberg KD, Feuer WJ, Davis JL. Ocular complications of pediatric uveitis. *Ophthalmology.* 2004;111(12):2299-306.
- Paroli MP, Speranza S, Marino M, et al. Prognosis of juvenile rheumatoid arthritis-associated uveitis. *Eur J Ophthalmol.* 2003;13(7):616-21.

- Zak M, Fledelius H, Pedersen FK. Ocular complications and visual outcome in juvenile chronic arthritis: a 25-year follow-up study. *Acta Ophthalmol Scand.* 2003;81(3):211-5.
- Galor A, Leder HA, Thorne JE, Dunn JP. Transient band keratopathy associated with ocular inflammation and systemic hypercalcemia. *Clin Ophthalmol.* 2008;2(3):645-7.
- Canellos HM, Cooper J, Paek A, Chien J. Multiple calcified deposits along the eyelid margins secondary to chronic renal failure and hyperparathyroidism. *Optometry.* 2005;76(3):181-4.
- Abeyasiri P, Sinha A. An unusual pattern of corneal calcification in tertiary hyperparathyroidism. *Arch Ophthalmol.* 2006;124(1):138-9.
- Mullaem G, Rosner MH. Ocular problems in the patient with end-stage renal disease. *Semin Dial.* 2012;25(4):403-7.
- Lo WR, Brooker G, Grossniklaus HE. Histopathologic examination of conjunctival tophi in gouty arthritis. *Am J Ophthalmol.* 2005;140(6):1152-4.
- Johnston RL, Stanford MR, Verma S, et al. Resolution of calcific band keratopathy after lowering elevated serum calcium in a patient with sarcoidosis. *Br J Ophthalmol.* 1995;79(11):1050.
- Pavčić-Astalos J, Lacmanović-Loncar V, Petric-Vicković I, et al. Eye drops preservative as the cause of corneal band keratopathy in long-term pilocarpine hydrochloride treatment. *Acta Clin Croat.* 2012;51(1):107-11.
- Sharma N, Mannan R, Sinha R, et al. Excimer laser phototherapeutic keratectomy for the treatment of silicone oil-induced band-shaped keratopathy. *Eye Contact Lens.* 2011;37(5):282-5.
- Schmid E, Lisch W, Philipp W, et al. A new, X-linked endothelial corneal dystrophy. *Am J Ophthalmol.* 2006;141(3):478-87.
- Arora R, Shroff D, Kapoor S, et al. Familial calcific band-shaped keratopathy: report of two new cases with early recurrence. *Indian J Ophthalmol.* 2007;55(1):55-7.
- Liu H, Begley C, Chen M, et al. A link between tear instability and hyperosmolarity in dry eye. *Invest Ophthalmol Vis Sci.* 2009;50(8):3671-9.
- Mihara E, Miyata H, Inoue Y, et al. Application of energy-dispersive X-ray microanalysis on the diagnosis of atypical calcific band keratopathy. *Okajimas Folia Anat Jpn.* 2005;82(1):19-24.
- Doostdar N, Manrique CJ, Hamill MB, Barron AR. Synthesis of calcium-silica composites: a route toward an in vitro model system for calcific band keratopathy precipitates. *J Biomed Mater Res A.* 2011;99(2):173-83.
- Cordellat IM. Hyperparathyroidism: primary or secondary disease? *Reumatol Clin.* 2012;8(5):287-91.
- Breinin GM, Devoe AG. Chelation of calcium with edathamil calcium-disodium in band keratopathy and corneal calcium affections. *AMA Arch Ophthalmol.* 1954;52(6):846-51.
- Saini JS, Jain AK, Sukhija J, et al. Indications and outcome of optical partial thickness lamellar keratoplasty. *Cornea.* 2003;22(2):111-3.
- Kwon YS, Song YS, Kim JC. New treatment for band keratopathy: superficial lamellar keratectomy, EDTA chelation and amniotic membrane transplantation. *J Korean Med Sci.* 2004;19(4):611-5.
- Najjar DM. Management of band keratopathy with excimer phototherapeutic keratectomy. *Eye.* 2006;20(2):252.
- Moniz N, Fernandez ST. Efficacy of phototherapeu-

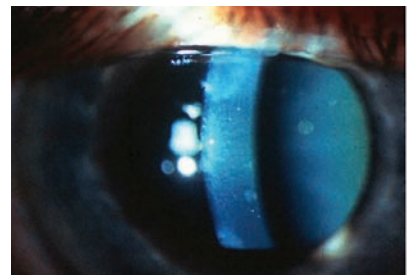
tic keratectomy in various superficial corneal pathologies. *J Refract Surg.* 2003;19(2 Suppl):S243-6.

- Stewart OG, Morrell AJ. Management of band keratopathy with excimer phototherapeutic keratectomy: visual, refractive, and symptomatic outcome. *Eye.* 2003;17(2):233-7.
- Anderson DF, Prabhawat P, Alfonso E, Tseng SC. Amniotic membrane transplantation after the primary surgical management of band keratopathy. *Cornea.* 2001;20(4):354-61.
- Esquenazi S, Rand W, Velazquez G, Grunstein L. Novel therapeutic approach in the management of band keratopathy using amniotic membrane transplantation with fibrin glue. *Ophthalmic Surg Lasers Imaging.* 2008;39(5):418-21.
- Im SK, Lee KH, Yoon KC. Combined ethylenediaminetetraacetic acid chelation, phototherapeutic keratectomy and amniotic membrane transplantation for treatment of band keratopathy. *Korean J Ophthalmol.* 2010;24(2):73-7.
- Multack RF, Genge MR, Skopin L, Jr. Juvenile rheumatoid arthritis. In: Onofrey BE, Skopin L, Jr., Holdeman NR, ed. *Ocular Therapeutics Handbook: A Clinical Manual*, 2nd Edition. Philadelphia: Lippincott Williams & Wilkins;2005:255-8.

EPITHELIAL BASEMENT MEMBRANE DYSTROPHY

Signs and Symptoms

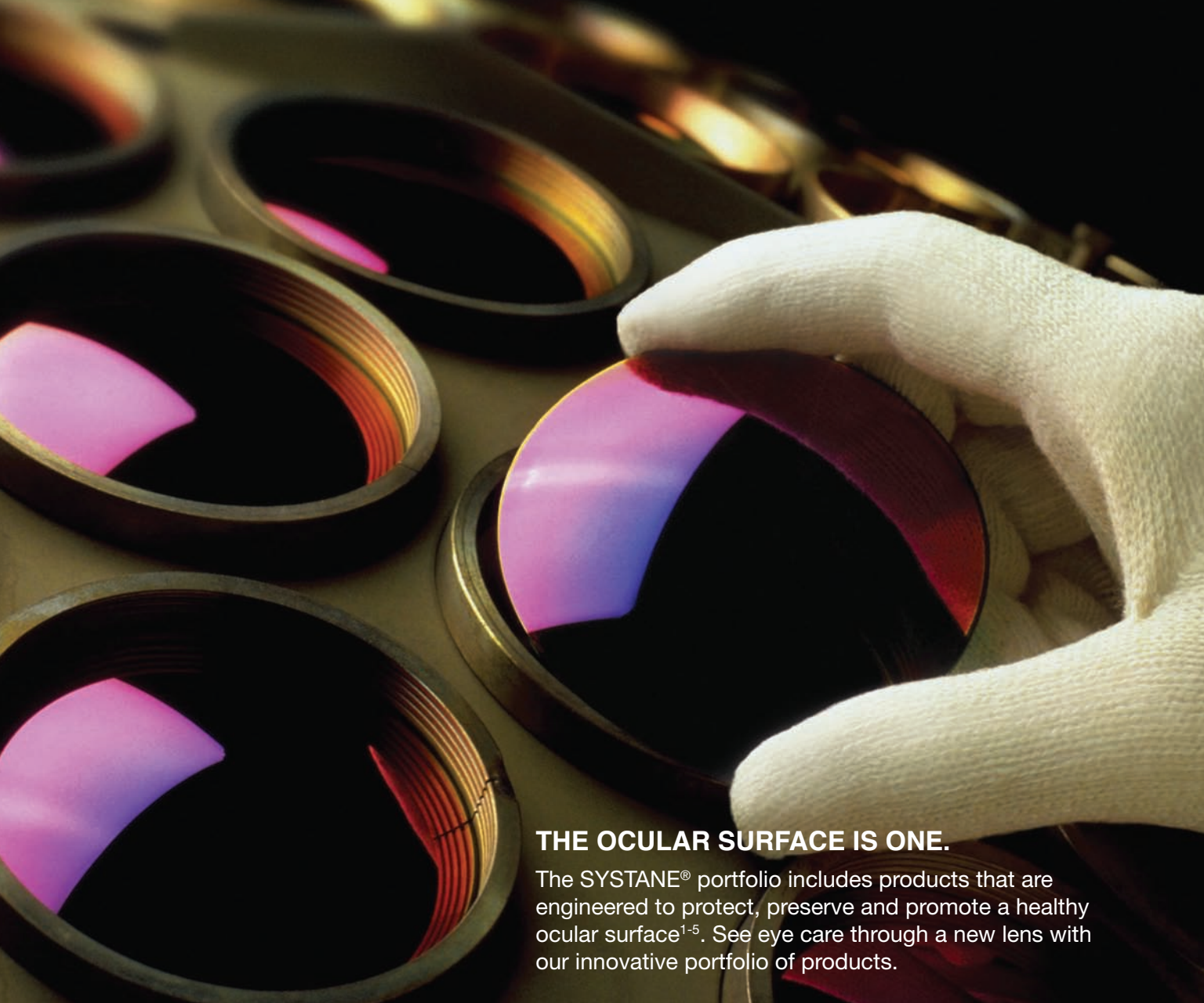Epithelial basement membrane dystrophy (EBMD), also known as anterior basement membrane dystrophy and Cogan's microcystic dystrophy, is one of the more commonly encountered corneal dystrophies in clinical practice.¹ Typically, it develops in adults between the ages of 20 and 40 years.² While EBMD is a bilateral disorder, some patients may show marked asymmetry.



Epithelial basement membrane dystrophy (map-dot-fingerprint).

EBMD is often described as map-dot-fingerprint dystrophy because of its classic biomicroscopic signs; these include "maps" (amorphous, grayish-

SOME SURFACES ARE WORTH PROTECTING



THE OCULAR SURFACE IS ONE.

The SYSTANE® portfolio includes products that are engineered to protect, preserve and promote a healthy ocular surface¹⁻⁵. See eye care through a new lens with our innovative portfolio of products.

References

1. Christensen MT, Blackie CA, Korb DR, et al. An evaluation of the performance of a novel lubricant eye drop. Poster D692 presented at: The Association for Research in Vision and Ophthalmology Annual Meeting; May 2-6, 2010; Fort Lauderdale, FL.
2. Davitt WF, Bloomstein M, Christensen M, et al. Efficacy in patients with dry eye after treatment with a new lubricant eye drop formulation. *J Ocul Pharmacol Ther.* 2010;26(4):347-353.
3. Data on file, Alcon.
4. Wojtowica JC., et al. Pilot, Prospective, Randomized, Double-masked, Placebo-controlled Clinical Trial of an Omega-3 Supplement for Dry Eye. *Cornea* 2011;30(3) 308-314.
5. Geerling G., et al. The International Workshop on Meibomian Gland Dysfunction: Report of the Subcommittee on Management and Treatment of Meibomian Gland Dysfunction. *IOVS* 2011;52(4).

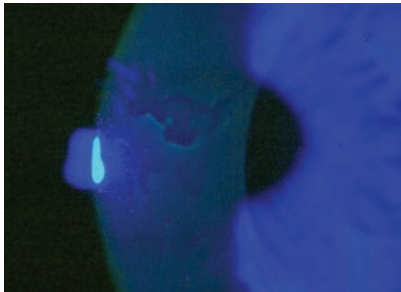
Alcon®

a Novartis company

Systane®
Family of Products



Surface Protection and More



Fluorescein staining helps to enhance the presentation of EBMD.

white geographic areas, often containing oval lacunae), “dots” (focal, grayish-white, round or comma-shaped opacities) and “fingerprints” (clusters of irregular concentric lines) within the cornea. The instillation of sodium fluorescein dye helps to delineate these areas, showing negative staining in association with the tissue elevation created by the “maps and dots.” Fingerprint lesions are best identified using retroillumination.

Patients with EBMD are often asymptomatic, with the condition being diagnosed upon routine ocular examination. Occasionally, individuals may display visual symptoms, including blurred vision, fluctuating vision, “ghosting” (i.e., monocular diplopia) or glare. Patients may complain of intermittent blurring or the clinician may note an unstable endpoint on attempted refraction. Less commonly, patients with EBMD report ocular discomfort, such as photophobia or a foreign body sensation. Advanced cases may be predisposed toward the development of recurrent corneal erosion (morning syndrome); in such instances, patients may relate a periodic history of awakening with profound eye pain, blurred vision, blepharospasm or tearing.¹⁻⁵

Pathophysiology

Corneal dystrophies are noninfectious, non-inflammatory tissue abnormalities related to faulty metabolism or malnutrition. Typically, dystrophies

are inherited, bilateral and progressive; however, EBMD deviates somewhat from this rule. Quite often there is no familial history of the disease, and it is not so much progressive as it is chronic, with exacerbations and remissions. In fact, some authorities have classified EBMD not as a dystrophy but rather as a form of corneal degeneration.⁶

In normal individuals, columnar basal cells represent the foundation of the corneal epithelium. These cells give rise to the corneal basement membrane, which adheres (via hemidesmosomal junctions) to Bowman’s layer, just anterior to the corneal stroma. Individuals with EBMD manifest a dysfunctional basement membrane, which becomes hypertrophied and misdirected.² The basal cells in these patients manufacture aberrant projections that protrude from an abnormally thickened basement membrane into the superficial epithelium, resulting in the classic clinical findings. The “maps” represent geographic areas of multilaminar basement membrane; the “dots” are intraepithelial microcystic inclusions of cells and cellular debris; “fingerprints” are irregular, fibrogranular ridges of thickened basement membrane that extend into the epithelial layer.^{1,2}

In addition to inducing visible changes in the cornea, the structural alterations associated with EBMD can result in impaired adherence of the overlying epithelium, prompting focal, intermittent “sloughing” of epithelial sheets.^{3,5} This enables the recurrent corneal erosion syndrome, which is often associated with advanced basement membrane disease.

Management

EBMD does not generally require significant intervention. For asymptomatic patients, periodic evaluation of the corneal changes is usually sufficient. This may be done in a variety of

ways, but the use of slit-lamp photography and/or corneal topography helps to provide objective documentation. In vivo confocal microscopy has also been shown to elucidate these anatomical alterations quite effectively, although the availability and cost of such instrumentation makes it impractical for the majority of practicing clinicians.^{1,2,7}

Most patients’ symptoms related to EBMD are similar to dry eye complaints. Ocular lubricants may help alleviate intermittent visual disturbances or discomfort. More substantial disease may warrant the use of hypertonic agents (e.g. 5% sodium chloride solution QID and ointment HS), as these help to deturgesce the epithelium and enhance the cellular adhesion between the epithelial cells and underlying stroma.^{3,8} An alternative to hypertonic solutions is FreshKote (Focus Laboratories), an ocular lubricant that does not contain sodium chloride, but rather large molecular weight colloidal particles that impart a high oncotic pressure. Hence, this agent may work in a similar capacity to hypertonic salt solutions, but with better overall lubricity and without the associated stinging upon instillation.

Contact lenses also have a role in the management of EBMD: an attempt to “resurface” the irregular epithelium and overcome visual disturbances that sometimes accompany this condition.³ Both hydrogel and rigid lenses may be used in this capacity; however, it is important to select a material with a high Dk/L to minimize corneal edema. Patients with visual symptoms may also be treated via prophylactic epithelial debridement. A study involving 74 eyes of 55 patients treated over 15 years showed that simple manual debridement helped to improve visual acuity by at least one line of Snellen acuity and diminish the incidence of recurrences.⁹

For those patients who suffer corne-

al erosions, acute care involves removal of the loose epithelium, topical cycloplegia (e.g., scopolamine 0.25% BID-TID), prophylactic topical antibiotics (e.g., moxifloxacin 0.5% or besifloxacin 0.6% TID) and oral or topical non-steroidal anti-inflammatory agents as needed for pain. Bandage contact lenses are often helpful in facilitating reepithelialization.^{8,10,11}

Following resolution of the erosion, particular care must be taken to protect the eye while sleeping, to prevent recurrences. Ointments, both bland and hypertonic, are beneficial in preventing abrupt detachment of the epithelium upon awakening.^{3,12,13} Likewise, sleep masks (or goggles) help prevent unconscious ocular trauma that could otherwise initiate a spontaneous erosion. Nocturnal bandaging is also an accepted modality.

Those individuals who do not respond to conservative management strategies may require more intensive therapy. Noninvasive treatment may involve the use of pharmaceutical agents that mitigate the effects of matrix metalloproteinase. The combination of oral doxycycline and topical corticosteroid drops has been effective in reducing symptoms associated with recurrent erosion.^{14,15} In one series, treatment with doxycycline 50mg BID and topical fluorometholone 0.1% TID for at least four weeks completely eliminated symptoms in 71% of patients.¹⁴

Anterior stromal puncture is a common technique used to manage recurrent corneal erosions. It is designed to initiate scar formation at the level of the basement membrane, which in theory facilitates better adhesion between the epithelium and corneal stroma.^{13,16} Using a 25-gauge needle under topical anesthesia, the physician places 0.1mm deep perforations, breaching Bowman's membrane at 0.25mm intervals, within the area of

concern. This technique can also be achieved using the Nd:Yag laser.¹⁷ Other surgical options include superficial keratectomy using a diamond burr or excimer laser phototherapeutic keratectomy (PTK).¹⁸⁻²¹ These two techniques appear to have equivalent efficacy, although diamond burr treatment reportedly has less tendency to induce secondary corneal haze and recurrence.²²

Clinical Pearls

- Many patients with EBMD present with vague, dry eye-type complaints. Establishing the timing of their symptoms can help to ascertain the true underlying etiology. Those individuals with true aqueous-deficient dry eye typically complain of discomfort and increasing symptoms toward the end of the day, as the tear film becomes more stressed. In contradistinction, patients with EBMD usually report maximum symptomatology in the morning. This is reflective of microcystic and intraepithelial edema, which tends to increase while the eyes are closed.

- Patients who describe dry eye-type symptoms that are predominant upon awakening and improve throughout the day should be examined closely for EBMD.

- The biomicroscopic signs of EBMD can be exceedingly subtle. In order to best observe the corneal changes, we recommend viewing the ocular surface both with and without fluorescein dye. Also, the cornea should be inspected with retroillumination through a dilated pupil.

- A number of older reports suggest that EBMD is a hereditary condition with an autosomal dominant inheritance pattern.²³ While many cases are sporadic, it may still be beneficial to suggest comprehensive examinations for all first-order family members of any EBMD patient.

1. Labbe A, Nicola RD, Dupas B, et al. Epithelial basement membrane dystrophy: evaluation with the HRT II Rostock Cornea Module. *Ophthalmology* 2006; 113(8):1301-8.
2. Kobayashi A, Yokogawa H, Sugiyama K. In vivo laser confocal microscopy findings in patients with map-dot-fingerprint (epithelial basement membrane) dystrophy. *Clin Ophthalmol.* 2012;6:1187-90.
3. Laibson PR. Recurrent corneal erosions and epithelial basement membrane dystrophy. *Eye Contact Lens.* 2010;36(5):315-7.
4. Itty S, Hamilton SS, Baratz KH, et al. Outcomes of epithelial debridement for anterior basement membrane dystrophy. *Am J Ophthalmol.* 2007;144(2):217-221.
5. Payant JA, Eggenberger LR, Wood TO. Electron microscopic findings in corneal epithelial basement membrane degeneration. *Cornea* 1991;10(5):390-4.
6. Sayegh RR, Kouyoumjian PB, Vedula GG, et al. Cocaine-assisted epithelial debridement for the treatment of anterior basement membrane dystrophy. *Cornea.* 2013 Apr 12. [Epub ahead of print]
7. Bozkurt B, Irkec M. In vivo laser confocal microscopic findings in patients with epithelial basement membrane dystrophy. *Eur J Ophthalmol.* 2009;19(3):348-54.
8. Watson SL, Lee MH, Barker NH. Interventions for recurrent corneal erosions. *Cochrane Database Syst Rev.* 2012;9:CD001861.
9. Itty S, Hamilton SS, Baratz KH, et al. Outcomes of epithelial debridement for anterior basement membrane dystrophy. *Am J Ophthalmol.* 2007;144(2):217-21.
10. Fraunfelder FW, Cabezas M. Treatment of recurrent corneal erosion by extended-wear bandage contact lens. *Cornea.* 2011;30(2):164-6.
11. Mourtray TN, Frazer DG, Jackson AJ. Recurrent erosion syndrome--the patient's perspective. *Cont Lens Anterior Eye.* 2011;34(3):139-43.
12. Hykin PG, Foss AE, Pavesio C, Dart JK. The natural history and management of recurrent corneal erosion: a prospective randomised trial. *Eye* 1994; 8 (Pt 1):35-40.
13. Ramamurthi S, Rahman MQ, Dutton GN, Ramaesh K. Pathogenesis, clinical features and management of recurrent corneal erosions. *Eye (Lond).* 2006;20(6):635-44.
14. Wang L, Tsang H, Coroneo M. Treatment of recurrent corneal erosion syndrome using the combination of oral doxycycline and topical corticosteroid. *Clin Experiment Ophthalmol.* 2008;36(1):8-12.
15. Dursun D, Kim MC, Solomon A, Pflugfelder SC. Treatment of recalcitrant recurrent corneal erosions with inhibitors of matrix metalloproteinase-9, doxycycline and corticosteroids. *Am J Ophthalmol.* 2001;132(1):8-13.
16. Malecha MA. Anterior stromal puncture for recurrent corneal erosion after laser in situ keratomileusis. *J Cataract Refract Surg.* 2004;30(2):496-8.
17. Tsai TY, Tsai TH, Hu FR, Hou YC. Recurrent corneal erosions treated with anterior stromal puncture by neodymium: yttrium-aluminum-garnet laser. *Ophthalmology.* 2009;116(7):1296-300.
18. Tzeilikis PF, Rapuano CJ, Hammersmith KM, et al. Diamond burr treatment of poor vision from anterior basement membrane dystrophy. *Am J Ophthalmol* 2005; 140(2):308-10.
19. Ryan G, Lee GA, Maccheron L. Epithelial debridement with diamond burr superficial keratectomy for the treatment of recurrent corneal erosion. *Clin Experiment Ophthalmol.* 2012 Dec 10. doi: 10.1111/ceo.12052.

[Epub ahead of print]

20. van Westenbrugge JA. Small spot phototherapeutic keratectomy for recurrent corneal erosion. *J Refract Surg.* 2007;23(7):721-4.

21. Pogorelov P, Langenbucher A, Kruse F, Seitz B. Long-term results of phototherapeutic keratectomy for corneal map-dot-fingerprint dystrophy (Cogan-Guerry). *Cornea.* 2006;25(7):774-7.

22. Sridhar MS, Rapuano CJ, Cosar CB, et al. Phototherapeutic keratectomy versus diamond burr polishing of Bowman's membrane in the treatment of recurrent corneal erosions associated with anterior basement membrane dystrophy. *Ophthalmology* 2002; 109(4):674-9.

23. Waring GO 3rd, Rodrigues MM, Laibson PR. Corneal dystrophies. I. Dystrophies of the epithelium, Bowman's layer and stroma. *Surv Ophthalmol.* 1978; 23(2):71-122.

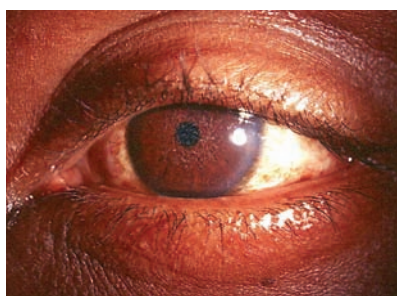
GRANULAR DYSTROPHY

Signs and Symptoms

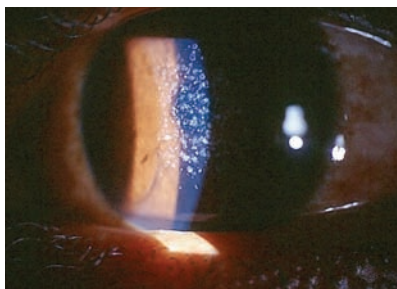
Granular corneal dystrophy is a bilateral condition that affects the central regions of the corneal stroma while sparing the periphery.¹⁻³ Two distinct classifications of this condition have been described: type 1 (GCD1), or classic granular dystrophy and type 2 (GCD2), more commonly known as Avellino corneal dystrophy.^{1,4} Clinically, both varieties present with multiple, discrete, white-to-gray corneal deposits that are non-uniform in size, most closely resembling snowflakes or breadcrumbs. Avellino dystrophy is distinguished by greater variability in the size of the opacities, as well as a tendency for the opacities to fuse and give rise to elongated and stellate shapes. In addition, Avellino dystrophy may present with amyloid lesions in the deeper stroma, a finding consistent with lattice corneal dystrophy.⁴

Patients with granular dystrophy may be diagnosed on routine examination during childhood or adolescence, although the condition does not typically become symptomatic until the third or fourth decade of life.^{1,4,5} Vision is usually not affected in the early stages; however, as the deposits become larger and more dense, visual acuity may drop off precipitously. It is

not unusual to see older patients with this condition manifesting vision of 20/200 or worse. Patients may also report varying degrees of ocular irritation, ranging from a mild foreign body sensation to pronounced pain. The most significant complication, aside from reduced vision, is the propensity toward recurrent epithelial erosions.^{6,7}



Granular corneal dystrophy.



Close-up of the snowflake-like corneal deposits characteristic of the disease.

Pathophysiology

Corneal dystrophies are non-infectious, non-inflammatory, hereditary disorders that involve abnormal deposition or retention of material within the cornea, usually due to faulty cellular metabolism or nutrition. The underlying etiology is often related to a specific genetic mutation.⁸ Such dystrophies are categorized by the layer of the cornea in which they are found, including the superficial anterior layers (epithelium and epithelial basement membrane), Bowman's layer, the corneal stroma, Descemet's membrane or the endothelium. Granular dystro-

phy occurs at the level of the stroma, although it is not the most common stromal corneal dystrophy seen in clinical practice.⁹ In vivo confocal microscopy shows that the deposits in granular dystrophy vary in shape from round to trapezoidal, and in size from 50-500µm in diameter.² The epithelial basement membrane and Bowman's layer are also altered, and this can lead to recurrent corneal erosion.

Granular dystrophy displays an autosomal dominant inheritance pattern with variable penetrance.¹ Both GCD1 and GCD2 are considered to be part of the TGFBI (Tissue Growth Factor Beta Inducible) dystrophies, along with lattice corneal dystrophy and Reis-Bucklers dystrophy.^{2,7} These conditions arise from mutations in the chromosome 5q31-related TGFBI gene.¹⁰ The majority of the mutations in TGFBI are located in the Fas1 domain 4 with the mutational hotspots being Arg124 and Arg555.⁷ Further studies suggest that GCD1 and GCD2 are primarily associated with accumulation of the R555W and R124H mutant TGFBI proteins in corneal stroma, respectively.¹¹

Management

There is no recognized medical therapy for granular corneal dystrophy. Patients typically endure the situation, relying on ocular lubricants and perhaps hypertonic solutions for palliative relief of irritation. When significant visual compromise ensues, however, surgical intervention may become necessary.

Phototherapeutic keratectomy (PTK) has been effectively used for removing central superficial corneal opacities and improving visual acuity in patients with granular corneal dystrophy.^{4,12,13} Alcohol epitheliectomy with mechanical debridement can be used to treat cases with a superficial

(Continued on page 40A)

UNDERSTANDING CORNEAL COLLAGEN CROSSLINKING

In recent years, there have been numerous reports in both the trade publications and refereed journals discussing the principles and implications of corneal collagen crosslinking.¹⁻⁴ Despite the recent flurry and fascination with this procedure, the concept of collagen crosslinking has been recognized for about 40 years.^{1,2} In 1974, Dr. Robert Siegel described the manner in which lysyl oxidase (i.e., hydroxylysine) in combination with aldehyde intermediates creates crosslinks during collagen fibril formation. He postulated that this activity may facilitate the biosynthesis of stable collagen fibrils and contribute to increased fibril tensile strength *in vivo*.^{1,2} A few years later, it was recognized that the corneas of patients with keratoconus display decreased crosslink formation involving hydroxylysine, and this change may be part of the reason for the propensity toward corneal ectasia.^{3,4}

In 2003, following successful studies in animal models, clinical researchers attempted to stimulate collagen crosslinking in patients with progressive keratoconus using an oxidative process.^{5,6} The results of this trial were encouraging; of the 23 eyes treated, 100% showed halted progression, 70% showed regression and flattening of the cornea, and 65% showed slight improvement in visual acuity.⁶ Since that time, thousands of patients have undergone the process of corneal collagen crosslinking (CXL) in facilities worldwide for keratoconus as well as other forms of corneal ectasia.

CXL is not intended to be a cure for keratoconus, nor should it be seen as a means to return the treated eye to "normal" status. Its indication is to help slow or stop the progression of corneal ectatic disorders, including keratoconus, pellucid marginal degeneration and ectasia after eventful refractive surgery such as LASIK or PRK.⁷

The process of CXL is surprisingly simplistic and noninvasive. In contradistinction to other corrective procedures for corneal ectasia, like penetrating keratoplasty, CXL requires no incisions, sutures or laser energy. The process uses ultraviolet light (UV-A at wavelengths of 360-370nm) combined with topical riboflavin (vitamin B2), which acts as a photoinitiator to absorb the UV energy and initiate the process of stimulating formation of intra- and interfibrillar covalent bonds.⁷ Similar procedures have been developed for both medical and non-medical purposes, such as the application of dental materials and cosmetic acrylic fingernail hardening treatments.^{8,9}

In a typical CXL session (which is conducted as a sterile, outpatient procedure), the patient first undergoes debridement of the central 7-9mm of the cornea under topical anesthesia. Removal of the epithelium allows for uniform diffusion of the photoinitiator.^{6,7} Following this, a solution of 0.1% riboflavin suspended in a 20% dextran T500 solution is applied to the cornea and allowed to rest for several minutes before introducing the light source.⁶ A treatment lamp consisting of multiple UV-A diodes is then placed in proximity to the eye to deliver an intended 3mW/cm surface

irradiance (5.4 J/cm surface dose) at a working distance of 6cm (2.36 inches). The eye is secured open with a lid speculum, and irradiance is performed for a period of 30 minutes, during which the topical anesthetic and riboflavin solution are reapplied every three to five minutes.^{6,7}

After the treatment is completed, a bandage soft contact lens is placed to enhance reepithelialization and ameliorate postoperative discomfort. Topical antibiotic drops (e.g., ofloxacin 0.3% QID) are used prophylactically while the lens is in place and the epithelium regenerates; typically, this takes about three days. Following removal of the contact lens, a topical corticosteroid (e.g., dexamethasone phosphate 0.1%) is prescribed four times daily and tapered over two months.

CXL has been approved for several years and is available throughout Canada, the European Union and the Asia-Pacific region. While the procedure is not presently approved for use in

the United States, in September 2011 the FDA did grant Avedro, Inc. orphan drug designation for its VibeX (riboflavin 0.1% ophthalmic solution), for use with its KXL System of UV-A irradiation. In FDA terms, "orphan status" allows a company to develop new therapies for a rare disease or medical disorder affecting fewer than 200,000 individuals in the United States.¹⁰

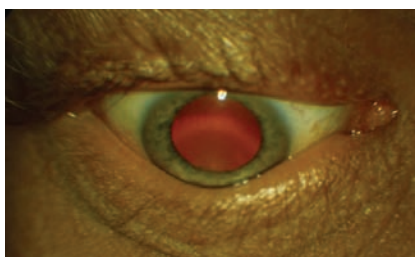
A large-scale, multicenter trial—The Corneal Collagen Cross-linking for Progressive Keratoconus (CXL) Study (ClinicalTrials.gov Identifier: NCT00647699)—was completed in April

2011, and other, similar studies are currently ongoing.

A variant of the traditional CXL procedure that may offer less discomfort and more rapid recovery is being investigated as well. Termed transepithelial or "epithelium-on" CXL, this procedure eliminates the need for debridement prior to the application of riboflavin, hence the moniker.

With conventional riboflavin solutions, there is insufficient penetration of the drug through an intact epithelium into the stroma to cause a crosslinking reaction when the UV light is applied.¹¹ But when other agents are employed to alter the surface permeability, transepithelial collagen crosslinking (TE-CXL) becomes possible. Some of these agents include well-known compounds such as benzalkonium chloride (BAK), ethylenediaminetetraacetic acid (EDTA), tetracaine and pilocarpine.¹¹⁻¹⁴ A new, commercially-available formulation called Ricrolin TE (SOOFT Italia SpA) has been specifically designed for TE-CXL, incorporating riboflavin along with two enhancing agents, trometamol and EDTA, in solution.¹¹

The only foreseeable drawback with TE-CXL is that it requires a longer riboflavin loading time of 30 minutes, as compared to about five minutes with standard CXL. However, in terms of the overall time to complete the procedure, the differences are negligible. Alternative methods for delivering riboflavin to the corneal stroma are also being explored, including direct application through a stromal pocket and corneal iontophoresis.^{15,16}



Advanced keratoconus, exhibiting Munson sign and Charleaux (oil droplet) sign. Will corneal crosslinking make this a thing of the past?

Although it is not yet FDA approved, corneal collagen cross-linking treatment is still widely available as an experimental procedure for patients with corneal ectatic disorders throughout the United States. For this reason, and because it is the only technique shown to potentially halt the progression of keratoconus, it is recommended that all patients with early to moderate disease be educated regarding CXL.

Participating physicians in the United States and clinical centers can be found online at cxlusa.com; those in Canada can be located by going to keratoconuscanada.org.

1. Siegel RC. Biosynthesis of collagen crosslinks: increased activity of purified lysyl oxidase with reconstituted collagen fibrils. *Proc Natl Acad Sci U S A*. 1974;71(12):4826-30.
2. Morgenstem AS. History of corneal cross linking. Available at: www.ocxls.org/about/history-of-cxl. Accessed May 1, 2013.
3. Cannon DJ, Foster CS. Collagen crosslinking in keratoconus. *Invest Ophthalmol Vis Sci*. 1978;17(1):63-5.
4. Andreassen TT, Simonsen AH, Oxlund H. Biomechanical properties of keratoconus and normal corneas. *Exp Eye Res*. 1980;31(4):435-41.
5. Spoerl E, Huhle M, Seiler T. Induction of cross-links in corneal tissue. *Exp Eye Res*. 1998;66(1):97-103.
6. Wollensak G, Spoerl E, Seiler T. Riboflavin/ultraviolet-a-induced collagen crosslinking for the treatment of keratoconus. *Am J Ophthalmol*. 2003;135(5):620-7.

7. Jankov li MR, Jovanovic V, Nikolic L, et al. Corneal collagen cross-linking. *Middle East Afr J Ophthalmol*. 2010;17(1):21-7.
8. Cova A, Breschi L, Nato F, et al. Effect of UVA-activated riboflavin on dentin bonding. *J Dent Res*. 2011;90(12):1439-45.
9. Madhani NA, Khan KJ. Nail cosmetics. *Indian J Dermatol Venereol Leprol*. 2012;78(3):309-17.
10. Food and Drug Administration. For Industry: Developing Products for Rare Diseases & Conditions. April 16, 2013. Available at: www.fda.gov/ForIndustry/DevelopingProductsforRareDiseasesConditions. Accessed: May 1, 2013.
11. Filippello M, Stagni E, O'Brart D. Transepithelial corneal collagen crosslinking: bilateral study. *J Cataract Refract Surg*. 2012;38(2):283-91.
12. Raiskup F, Spoerl E. Corneal crosslinking with riboflavin and ultraviolet A. I. Principles. *Ocul Surf*. 2013;11(2):65-74.
13. Wollensak G, Iomdina E. Biomechanical and histological changes after corneal cross-linking with and without epithelial debridement. *J Cataract Refract Surg*. 2009;35(3):540-6.
14. Kissner A, Spoerl E, Jung R, et al. Pharmacological modification of the epithelial permeability by benzalkonium chloride in UVA/Riboflavin corneal collagen cross-linking. *Curr Eye Res*. 2010;35(8):715-21.
15. Daxer A, Mahmoud HA, Venkateswaran RS. Corneal crosslinking and visual rehabilitation in keratoconus in one session without epithelial debridement: new technique. *Cornea*. 2010;29(10):1176-9.
16. Vinciguerra R, Spoerl E, Romano MR, et al. Comparative stress strain measurements of human corneas after transepithelial UV-induced cross-linking: impregnation with iontophoresis, different riboflavin solutions and irradiance power. *Invest Ophthalmol Vis Sci*. 2012;53. E-abstract #1518.

(Continued from page 38A)

variant of granular dystrophy where phototherapeutic keratectomy is not available.^{14,15} More severe cases may warrant anterior lamellar keratoplasty or even penetrating keratoplasty.¹⁶ However, even after surgical intervention, granular dystrophy may recur in a significant proportion of patients. Published reports suggest that the use of soft contact lenses postoperatively may diminish the likelihood of recurrence.¹⁷

Conventional treatment of corneal erosions associated with granular dystrophy involves lubrication, bandage contact lenses, prophylactic antibiotics and topical anti-inflammatory agents as needed for pain. Anterior stromal puncture is not advisable for recurrent erosions secondary to corneal dystrophies, and should be employed only in those cases of erosion associated with prior ocular trauma. PTK, on the other hand, has been successfully used in recalcitrant recurrent corneal erosions independent of the etiology.¹⁸

Clinical Pearls

- Since granular dystrophy is autosomal dominant, it is important to

examine family members (especially siblings or children) for similar ocular findings.

- In the palliative management of granular dystrophy, ocular lubricants are generally helpful. No published studies exist to demonstrate superiority of any particular product over the others; however, one of the authors (AGK) has had excellent success with FreshKote (Focus Laboratories), a product that has high oncotic pressure to reestablish the epithelial integrity and a lipid-restorative agent to increase lubricity and wettability.

1. Klintworth GK. Corneal dystrophies. *Orphanet J Rare Dis*. 2009;4:7.
2. Shukla AN, Cruzat A, Hamrah P. Confocal microscopy of corneal dystrophies. *Semin Ophthalmol*. 2012;27(5-6):107-16.
3. Lee ES, Kim EK. Surgical do's and don'ts of corneal dystrophies. *Curr Opin Ophthalmol*. 2003;14(4):186-91.
4. Han KE, Kim TI, Chung WS, et al. Clinical findings and treatments of granular corneal dystrophy type 2 (avellino corneal dystrophy): a review of the literature. *Eye Contact Lens*. 2010;36(5):296-9.
5. Moon JW, Kim SW, Kim TI, et al. Homozygous granular corneal dystrophy type II (Avellino corneal dystrophy): natural history and progression after treatment. *Cornea*. 2007;26(9):1095-100.
6. Han KE, Chung WS, Kim TI, et al. Changes of clinical manifestation of granular corneal deposits because of recurrent corneal erosion in granular corneal dystrophy types 1 and 2. *Cornea*. 2013;32(5):e113-20.
7. Poulaki V, Colby K. Genetics of anterior and stromal

8. Vincent AL, Patel DV, McGhee CN. Inherited corneal disease: The evolving molecular, genetic and imaging revolution. *Clin Experiment Ophthalmol*. 2005;33(3):303-16.
9. Musch DC, Niziol LM, Stein JD, et al. Prevalence of corneal dystrophies in the United States: estimates from claims data. *Invest Ophthalmol Vis Sci*. 2011;52(9):6959-63.
10. Eiberg H, Moller HU, Berendt I, Mohr J. Assignment of granular corneal dystrophy Groenouw type I (CDGG1) to chromosome 5q. *Eur J Hum Genet*. 1994;2(2):132-8.
11. Han YP, Sim AJ, Vora SC, Huang AJ. A unique TGFB1 protein in granular corneal dystrophy types 1 and 2. *Curr Eye Res*. 2012;37(11):990-6.
12. Mori H, Miura M, Iwasaki T, et al. Three-dimensional optical coherence tomography-guided phototherapeutic keratectomy for granular corneal dystrophy. *Cornea*. 2009;28(8):944-7.
13. Jung SH, Han KE, Stulting RD, et al. Phototherapeutic keratectomy in diffuse stromal haze in granular corneal dystrophy type 2. *Cornea*. 2013;32(3):296-300.
14. Garg P, Jabbar A. Alcohol epitheliectomy with mechanical debridement in a case of granular corneal dystrophy with r555w homozygous mutation of TGF B1 gene. *Indian J Ophthalmol*. 2010;58(4):328-9.
15. Ashar JN, Latha M, Vaddavalli PK. Phototherapeutic keratectomy versus alcohol epitheliectomy with mechanical debridement for superficial variant of granular dystrophy: a paired eye comparison. *Cont Lens Anterior Eye*. 2012;35(5):236-9.
16. Unal M, Arslan OS, Atalay E, et al. Deep anterior lamellar keratoplasty for the treatment of stromal corneal dystrophies. *Cornea*. 2013;32(3):301-5.
17. Roters S, Severin M, Konen W, Krieglstein GK. Treatment of granular dystrophy with soft contact lenses. *Ophthalmologica*. 2004;218(1):70-2.
18. Jain S, Austin DJ. Phototherapeutic keratectomy for treatment of recurrent corneal erosion. *J Cataract Refract Surg* 1999; 25(12):1610-4.



Review Meetings 2013

SAVE THESE DATES FOR 2013

Join us for 14-15 CE* credits!
Educational Chair: Paul Karpecki, OD



JULY 25-28, 2013

Fairmont Hamilton Princess, Bermuda



SEPTEMBER 20-22, 2013

Marriott Del Mar, San Diego



NOVEMBER 22-24, 2013

Westin Alexandria, Virginia

For more information: www.revoptom.com/conferences

Please contact Lois DiDomenico with questions at ReviewMeetings@Jobson.com or 1-866-658-1772.



*Approval Pending

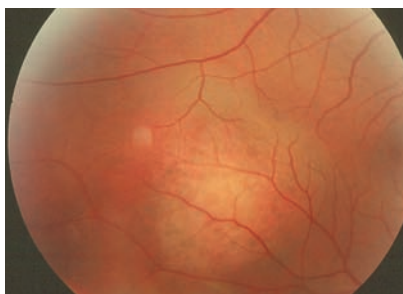
CHOROIDAL NEVUS AND CHOROIDAL MELANOMA

Signs and Symptoms

Both choroidal nevi and choroidal melanomas represent space-occupying masses of the uveal tract. Choroidal nevi appear as round or oval, flat or slightly elevated (1mm or less) lesions within the posterior fundus; the margins are typically detectable but indistinct. Nevi may present in a variety of hues, but most commonly they appear slate-blue or greenish-gray in coloration; there may be overlying areas of drusen noted as well.¹ Rarely, there may be associated subretinal neovascularization.² The vast majority of choroidal nevi remain under 5mm in size.³ Larger nevi, particularly those in excess of 4DD or 6mm carry increased suspicion of malignancy.^{3,4} Generally, patients with choroidal nevi are asymptomatic with the lesion detected on routine ophthalmoscopy.

Choroidal melanomas appear as thickened, dome-shaped lesions of the ocular fundus with widely variable coloration, ranging from complete amelanosis (i.e., white) to black. Most commonly, lesions are a non-uniform greenish-gray. There may be significant elevation in some cases. As they grow, melanomas may break through Bruch's membrane, taking on a "mushroom-shaped" appearance. Serous retinal detachments are commonly associated with this presentation.^{4,5} Overlying orange pigmentation known as lipofuscin may also be seen; this is considered by many to be a pathognomonic sign of malignancy.⁶

Patients with small choroidal melanomas may be asymptomatic or report vague visual complaints; in most cases, these lesions are detected via dilated indirect ophthalmoscopy on routine ophthalmic visits. Larger lesions or those in close proximity to

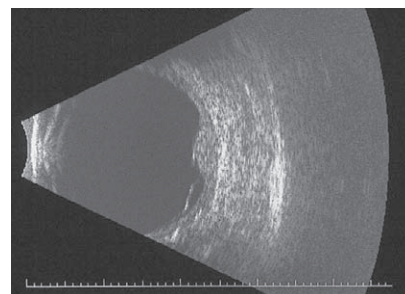


Amelanotic choroidal melanoma.

the macula typically induce symptoms such as photopsia, visual field deficit, metamorphopsia or decreased acuity secondary to subretinal fluid and/or hyperopic refractive shift.⁴

The vast majority of patients with choroidal melanoma are over the age of 50, with a peak incidence between the ages of 70 and 79.⁷ The tumor may rarely occur in childhood.⁸⁻¹⁰ Race also plays a significant role in the distribution of choroidal melanoma. Caucasians are perhaps three times more likely than Asians to manifest choroidal melanoma, with an incidence that is eight times more likely than those of African descent.¹¹⁻¹³ Not surprisingly, patients with light-colored irides (e.g., blue or gray) also seem to be at greater risk for developing uveal melanomas.^{14,15} The presence of numerous cutaneous nevi—particularly dysplastic nevi—is yet another risk factor.¹⁵

Recently, optical coherence tomography (OCT) has emerged as a valuable tool in the differentiation of choroidal nevi and melanomas. In one study, 3D spectral-domain OCT identified a higher prevalence of subretinal fluid (91% vs. 14%), retinal edema (61% vs. 14%), and subretinal deposits (61% vs. 11%) in choroidal melanoma as compared with nevi.¹⁶ In addition, Shields et al. suggested that the presence of subretinal fluid is a significant risk for metastasis after studying 8,033 cases of uveal melanoma.¹⁷



Ultrasound of choroidal melanoma.

Pathophysiology

Choroidal nevi and melanomas are both derived from uveal melanocytes. In the mid-1960s, Naumann and associates¹⁸ identified the four atypical cell types inherent in choroidal nevi; in order of prevalence, these include: plump polyhedral cells, slender spindle cells, intermediate cells and balloon cells.¹⁵

In contrast, melanomas are comprised of malignant melanocytes. The Callendar classification system for choroidal melanomas suggests that there are also four types of cells in these lesions: spindle A, spindle B, fascicular and epithelioid.^{19,20} In general, the presence of epithelioid cells within a melanoma heralds a poorer prognosis.²¹

There is some controversy regarding the precise pathogenesis of melanomas. It is believed that nevi may convert to malignancy in a small percentage of individuals; a recent study suggests a rate of one in 8,845.²² Risk factors for malignant transformation of nevi include diameter (>5mm) thickness (>2mm), the presence of subretinal fluid, lipofuscin, ultrasonographic hollowness and lack of an amelanotic halo.^{23,24}

Ultraviolet (UV) radiation has also been associated with the development of ocular and non-ocular melanoma.⁴ Some studies have suggested a causal relationship between UV exposure and the development of choroidal

melanoma, while others are less conclusive.²⁵⁻²⁸ It seems that the specifics of this variable are presently uncertain, but the prevailing opinion is that UV is not a significant factor in the pathogenesis of choroidal melanoma.

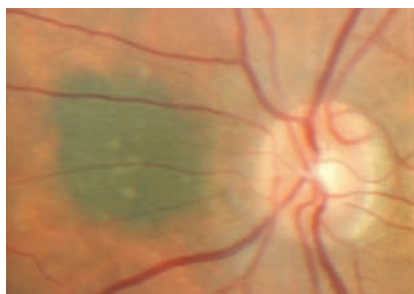
More than likely, the greatest prognostic indicator for choroidal melanoma development and malignant progression is a genomic variation in chromosomes 3, 6 or 8.^{4,29}

Management

While some choroidal nevi possess the capacity for malignant growth, the majority are completely benign and require only periodic monitoring. Of course, differentiating between a large, atypical nevus and a small choroidal melanoma requires experience and expertise. In 2009, Shields and associates proposed the following mnemonic to recall the most significant risk factors for choroidal melanoma: "To find small ocular melanomas, use helpful hints daily," or TFSOM-UHHD.²³

The first letter of each word in the phrase represents the characteristics that distinguish melanoma: *thickness* (melanomas are thicker than nevi on ultrasonography and OCT), *fluid* (melanomas are more likely to show subretinal fluid), *symptoms*, *orange* pigment, *margin* (the margins of melanomas are less distinct than those of nevi), *ultrasonographic hollowness*, absence of *halo* and absence of *drusen*.²³ The ancillary procedures that help to facilitate an accurate diagnosis include stereo photography, standardized ultrasonography, fluorescein angiography, fundus autofluorescence photography and OCT.³⁰ More invasive procedures, including transvitreal fine-needle aspiration biopsy, are also sometimes used to differentiate suspicious lesions.^{31,32}

Those patients diagnosed with or suspected of having choroidal melanoma should be referred for prompt medical evaluation by an ocular oncologist.



Choroidal nevus.

Specific medical testing is warranted to ascertain whether there are any additional primary or metastatic malignancies present. The systemic work-up should include a thorough medical and family history as well as a physical examination and directed laboratory evaluation.

Choroidal melanomas have been known to spread to numerous organ systems, including the lungs, skin, gastrointestinal tract and especially the liver, which is frequently the primary site of metastasis for uveal melanoma.⁴ Depending upon the physical findings, specific ancillary tests may consist of a chest X-ray or computed tomography (CT), cellular hematology and liver enzyme studies. The most sensitive tests of hepatic function include serum alkaline phosphatase, glutamic-oxaloacetic transaminase, lactic dehydrogenase and gamma-glutamyl transpeptidase. Genetic profile testing can also serve as a good prognostic indicator. Higher rates of metastasis have been found in those with chromosome 3 loss (i.e., monosomy 3), chromosome 8 gain, chromosome 6p gain and chromosome 1p loss.³³

Therapy for choroidal melanoma has changed radically in the last four decades. Until the late 1970s, enucleation was considered the only definitive treatment and the best option for survival among those with ocular melanoma. In 1978 a pivotal paper by Zimmerman and associates challenged conventional

thinking, suggesting that enucleation might actually contribute to systemic metastasis.^{30,34} This article and another subsequent publication³⁵ provided the impetus to develop alternative therapies for choroidal melanoma, most notably radiotherapy and tumor resection.

Today, therapy for choroidal melanoma is dictated primarily by the size of the lesion. The Collaborative Ocular Melanoma Study (COMS) defined tumors as small (5-16mm in basal diameter and 1.0-2.5mm in height), medium (<16mm diameter and 2.5-10.0mm in height) or large (>16mm diameter and/or >10mm in height).³⁶ The treatment recommendation of the study for small tumors was simple observation, with pharmacologic therapy initiated if any sign of growth or visual compromise is encountered. Focal laser photocoagulation, cryotherapy and more recently, transpupillary thermotherapy (TTT), have been employed successfully for selected small melanomas, although TTT as a stand-alone therapy is probably inadequate.³⁷⁻³⁹

For some small melanomas, as well as the majority of medium-sized choroidal melanomas, radiation remains the treatment of first choice.³⁷ Brachytherapy—in which a plaque with embedded radioactive material is temporarily sutured to the episclera overlying the tumor—is the most common method used today.⁴⁰ Another approach, employing charged particle irradiation (a.k.a., external beam irradiation) may also be employed for certain tumors. Overall, the success rates and complications (including radiation retinopathy and cataract formation) for plaque therapy and external beam therapy are similar. However, since external beam irradiation does not require surgery, it may be preferred in some cases.

Another treatment option for small- and medium-sized tumors is block excision, which involves a local resection of the tumor using a partial lamellar sclerouvectomy technique.³⁹ This procedure

may offer advantages over radiation therapy with regard to collateral tissue damage, but it is also quite involved and carries significant risk for surgical complications, including retinal detachment. Local resection of choroidal melanoma is preferred for smaller, more anteriorly located tumors.³⁹

Despite controversy, enucleation is still used for the treatment of some large uveal melanomas. It has been suggested that enucleation is indicated in the following settings: (1) in a patient who, after being informed of the diagnosis, requests this operation; (2) in a patient with a tumor involving over 40% of ocular volume; (3) after treatment with an alternative modality that has failed; and (4) in patients with significant ocular neovascularization before any therapy.⁴ As a matter of protocol, when enucleation is performed on an eye with melanoma, care is taken not to clamp the optic nerve or aggressively handle the eye, in an effort to reduce potential tumor seeding and metastasis.³⁷ For those advanced tumors that demonstrate massive extrascleral extension into the orbit, and in which the eye is blind and painful, eyelid-sparing orbital exenteration is typically justified.⁴¹

Clinical Pearls

- While the majority of choroidal melanomas occur in older, white individuals, younger patients and those of African or Asian descent are not immune. Our experience has shown that melanomas can affect a wide range of demographics. Delayed diagnosis can make the overall prognosis far worse.

- An emerging, valuable tool in the differential diagnosis and management of nevi and choroidal melanomas is enhanced depth imaging optical coherence tomography (EDI-OCT). EDI-OCT appears to have greater sensitivity than standardized ultrasonography

with regard to tumor thickness, and can also provide information regarding subretinal fluid, subretinal lipofuscin deposition, and retinal irregularities (e.g., “shaggy photoreceptors” which are consistent with melanoma).⁴²

- The Collaborative Ocular Melanoma Study, initiated in 1986, has yielded some interesting results. In one of the COMS trials, comparable survival rates were observed for individuals with medium-sized melanomas undergoing radiotherapy vs. enucleation.⁴³ In another trial, pre-enucleation radiotherapy for large tumors did not appear to significantly alter the rate of survival as compared to those who underwent enucleation alone.⁴⁴ These results have forced experts to again ponder the issues raised by Zimmerman in 1978—namely, whether enucleation, as a treatment option for choroidal melanoma, is a better or worse option in the long run.

- In recent years, intravitreal anti-VEGF agents such as bevacizumab have been widely administered for a variety of choroidal and retinal disorders, including “wet” macular degeneration, clinically significant macular edema and some proliferative vitreoretinopathies. In the case of choroidal melanoma, despite speculation and positive results from experimental animal models, these agents appear to be of little clinical value. In a recent report, three patients who were inadvertently treated with bevacizumab due to misdiagnosis experienced tumor progression with complications in the form of gliotic/fibrotic membrane formation.⁴⁵

1. Shields CL, Mashayekhi A, Materin MA, et al. Optical coherence tomography of choroidal nevus in 120 patients. *Retina*. 2005;25(3):243-52.
2. Zografos L, Mantel I, Schalenbourg A. Subretinal choroidal neovascularization associated with choroidal nevus. *Eur J Ophthalmol*. 2004 Mar-Apr;14(2):123-31.
3. Shields CL, Furuta M, Berman EL, et al. Choroidal nevus transformation into melanoma: analysis of 2514 consecutive cases. *Arch Ophthalmol*. 2009;127(8):981-7.

4. Char DH. Ocular melanoma. *Surg Clin North Am*. 2003; 83(2):253-74.
5. Kalkman E, Baxter G. Melanoma. *Clin Radiol*. 2004; 59(4):313-26.
6. Singh P, Singh A. Choroidal melanoma. *Oman J Ophthalmol*. 2012;5(1):3-9.
7. Keenan TD, Yeates D, Goldacre MJ. Uveal melanoma in England: trends over time and geographical variation. *Br J Ophthalmol*. 2012;96(11):1415-9.
8. Fong A, Lee L, Glasson W. Pediatric choroidal melanoma in a 13-year-old girl—a clinical masquerade. *J AAPOS*. 2011;15(3):305-7.
9. Grabowska A, Abelarias J, Peralta J, et al. Uveal melanoma in a 19-month-old child. *J AAPOS*. 2011;15(6):606-8.
10. Russo A, Coupland SE, O’Keefe M, Damato BE. Choroidal melanoma in a 7-year-old child treated by trans-scleral local resection. *Graefes Arch Clin Exp Ophthalmol*. 2010;248(5):747-9.
11. Biswas J, Krishnakumar S, Shanmugam MP. Uveal melanoma in Asian Indians: a clinicopathological study. *Arch Ophthalmol*. 2002;120(4):522-3.
12. Egan KM, Seddon JM, Glynn RJ, et al. Epidemiologic aspects of uveal melanoma. *Surv Ophthalmol*. 1988; 32(4):239-51.
13. Neugut AI, Kizelnik-Freilich S, Ackerman C. Black-white differences in risk for cutaneous, ocular and visceral melanomas. *Am J Public Health*. 1994;84(11):1828-9.
14. Regan S, Judge HE, Gragoudas ES, Egan KM. Iris color as a prognostic factor in ocular melanoma. *Arch Ophthalmol*. 1999;117(6):811-4.
15. Vajdic CM, Krickler A, Giblin M, et al. Eye color and cutaneous nevi predict risk of ocular melanoma in Australia. *Int J Cancer*. 2001;92(6):906-12.
16. Sayanagi K, Pelayes DE, Kaiser PK, Singh AD. 3D Spectral domain optical coherence tomography findings in choroidal tumors. *Eur J Ophthalmol*. 2011;21(3):271-5.
17. Shields CL, Furuta M, Thangappan A, et al. Metastasis of uveal melanoma millimeter-by-millimeter in 8,033 consecutive eyes. *Arch Ophthalmol*. 2009;127(8):989-98.
18. Naumann G, Yanoff M, Zimmerman LE. Histogenesis of malignant melanomas of the uvea: I. Histopathologic characteristics of nevi of the choroid and ciliary body. *Arch Ophthalmol*. 1966;76(6):784-96.
19. Callender GR. Malignant melanotic tumors of the eye: a study of histologic types in 111 cases. *Trans Am Acad Ophthalmol Otolaryngol*. 1931;36:131-42.
20. McLean IW, Foster WD, Zimmerman LE, Gamel JW. Modifications of Callender’s classification of uveal melanoma at the Armed Forces Institute of Pathology. *Am J Ophthalmol*. 1983; 96(4):502-9.
21. Augsburger JJ, Gonder JR, Amsel J, et al. Growth rates and doubling times of posterior uveal melanomas. *Ophthalmology*. 1984;91(12):1709-15.
22. Singh AD, Kalyani P, Topham A. Estimating the risk of malignant transformation of a choroidal nevus. *Ophthalmology*. 2005;112(10):1784-9.
23. Shields CL, Furuta M, Berman EL, et al. Choroidal nevus transformation into melanoma: analysis of 2514 consecutive cases. *Arch Ophthalmol*. 2009;127(8):981-7.
24. Sumich P, Mitchell P, Wang JJ. Choroidal nevi in a white population: the Blue Mountains Eye Study. *Arch Ophthalmol*. 1998;116(5):645-50.
25. Tucker MA, Shields JA, Hartge P, et al. Sunlight exposure as risk factor for intraocular malignant melanoma. *N Engl J Med*. 1985;313(13):789-92.
26. Lutz JM, Cree IA, Foss AJE. Risk factors for intraocular melanoma and occupational exposure. *Br J*

Ophthalmol. 1999;83(10):1190-3.

27. Seddon JM, Gragoudas ES, Glynn RJ, et al. Host factors, UV radiation, and risk of uveal melanoma: a case-control study. *Arch Ophthalmol.* 1990;108(9):1274-80.

28. Lai K, Di Girolamo N, Conway RM, et al. The effect of ultraviolet radiation on choroidal melanocytes and melanoma cell lines: cell survival and matrix metalloproteinase production. *Graefes Arch Clin Exp Ophthalmol.* 2007;245(5):715-24.

29. Damato B, Duke C, Coupland SE, et al. Cytogenetics of uveal melanoma: a 7-year clinical experience. *Ophthalmology.* 2007;114(10):1925-31.

30. Muscat S, Parks S, Kemp E, Keating D. Secondary retinal changes associated with choroidal naevi and melanomas documented by optical coherence tomography. *Br J Ophthalmol.* 2004;88(1):120-4.

31. Augsburger JJ, Correa ZM, Schneider S, et al. Diagnostic transvitreal fine-needle aspiration biopsy of small melanocytic choroidal tumors in nevus versus melanoma category. *Trans Am Ophthalmol Soc.* 2002;100:225-32.

32. McCannel TA. Fine-needle aspiration biopsy in the management of choroidal melanoma. *Curr Opin Ophthalmol.* 2013;24(3):262-6.

33. Damato B, Eleuteri A, Taktak AF, Coupland SE. Estimating prognosis for survival after treatment of choroidal melanoma. *Prog Retin Eye Res.* 2011;30(5):285-95.

34. Zimmerman LE, McLean IW, Foster WD. Does enucleation of the eye containing a malignant melanoma prevent or accelerate the dissemination of tumour cells. *Br J Ophthalmol.* 1978;62(6):420-5.

35. Zimmerman LE, McLean IW. An evaluation of enucleation in the management of uveal melanomas. *Am J Ophthalmol.* 1979;87(6):741-60.

36. Singh AD, Kivela T. The collaborative ocular melanoma study. *Ophthalmol Clin North Am.* 2005;18(1):129-42.

37. Shields CL, Shields JA. Recent developments in the management of choroidal melanoma. *Curr Opin Ophthalmol.* 2004;15(3):244-51.

38. Shields CL, Shields JA, Perez N, et al. Primary transpupillary thermotherapy for small choroidal melanoma in 256 consecutive cases: outcomes and limitations. *Ophthalmology.* 2002;109(2):225-34.

39. Robertson DM. Changing concepts in the management of choroidal melanoma. *Am J Ophthalmol.* 2003;136(1):161-70.

40. Damato B. Does ocular treatment of uveal melanoma influence survival? *Br J Cancer.* 2010;103(3):285-90.

41. Shields JA, Shields CL, Demirci H, et al. Experience with eyelid-sparing orbital exenteration. The 2000 Tullio O. Coston Lecture. *Ophthalmol Plast Reconstr Surg.* 2001;17(5):355-61.

42. Shields CL, Kaliki S, Rojanaporn D, et al. Enhanced depth imaging optical coherence tomography of small choroidal melanoma: comparison with choroidal nevus. *Arch Ophthalmol.* 2012;130(7):850-6.

43. Diener-West M, Earle JD, Fine SL, et al; Collaborative Ocular Melanoma Study Group. The COMS randomized trial of iodine 125 brachytherapy for choroidal melanoma. III. Initial mortality findings. COMS report no. 18. *Arch Ophthalmol.* 2001;119(7):969-82.

44. Collaborative Ocular Melanoma Study Group. The Collaborative Ocular Melanoma Study (COMS) randomized trial of pre-enucleation radiation of large choroidal

melanoma. II. Initial mortality findings. COMS report no. 10. *Am J Ophthalmol.* 1998;125(6):779-96.

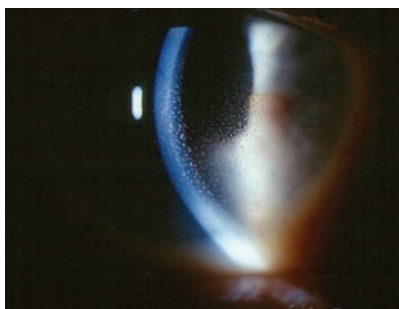45. Lima BR, Schoenfield LR, Singh AD. The Impact of Intravitreal Bevacizumab Therapy on Choroidal Melanoma. *Am J Ophthalmol.* 2011;151(2):323-8.e2.

HERPETIC KERATOUVEITIS

Signs and Symptoms

Herpetic keratouveitis, as the name implies, manifests anterior uveitis and some form of keratopathy in the presence, or with a history, of herpetic disease. Either herpes simplex or zoster may cause this condition.

The keratopathy may be dendritic keratitis, punctate epitheliopathy, stromal keratitis, epithelial edema, disciform stromal keratitis or endothelialitis.¹ Additionally, there will be an anterior chamber reaction with cells and flare, and possibly posterior synechiae. Granulomatous keratic precipitates (KPs) are commonly found, though occasionally the KPs will be non-granulomatous or stellate in appearance.



Pronounced keratic precipitates in a patient with recurrent herpetic keratouveitis.

There will also commonly be a secondary inflammatory glaucoma. Often, the rise in intraocular pressure (IOP) is disproportionate to the relatively mild anterior chamber reaction present.¹⁻⁵ Common presenting symptoms are pain, photophobia, and varying degrees of vision loss. Conjunctival injection is common. There is also commonly a sectoral atrophy of the iris in eyes with herpetic keratouveitis.^{6,7} Spontaneous hyphema may also occur.

Despite the name, both herpes simplex and zoster have the capability to cause uveitis even in the absence of keratopathy.^{6,7} Primary herpetic uveitis with no history of previous corneal disease seems to be more severe than the uveitis in patients with a history of previous herpetic keratopathy. This is true both for the inflammation as well as the secondary glaucoma.⁶

There is no racial or gender predilection for herpetic keratouveitis. Typically, the disease occurs in elderly patients, likely due to a declining immune system. However, rarely, children and young adults can develop herpetic keratouveitis.^{8,9} In these cases, the status of the immune system should be investigated.⁹

Pathophysiology

In herpetic keratouveitis, either live virus or viral byproducts induce an antigen-antibody response. Endothelialitis involves marked pleomorphism of the endothelial cells, suggesting direct herpes simplex virus invasion into the cells. This could be followed by an inflammatory cell attack against the endothelium.⁴ It is believed that the uveitic response is secondary to the resultant keratitis. However, in the absence of corneal infiltration or other keratopathy, assigning a primary and secondary site of inflammation is controvertible.

Cytokines mediate numerous tissue changes, among them vasodilation and increased vasopermeability. When the uveal vessels dilate an exudation of plasma, white blood cells and proteins traverse extravascular spaces such as the anterior chamber. Small molecular weight proteins may cloud the ocular media, but have little impact otherwise; however, as larger molecular weight proteins like fibrinogen accumulate in the aqueous and/or vitreous, pathological sequelae such as IOP elevation occur.^{10,11} Secondary IOP elevation

occurs from abnormal aqueous humor dynamics precipitated by increased protein content and increased aqueous viscosity. This, combined with other factors, leads to a reduction in outflow through the trabecular meshwork.

Trabecular meshwork outflow can be impeded both by the accumulation of inflammatory cells as well as the impairment of inherent outflow facility by proteinaceous aqueous humor in patients with excessive flare. Flare may be more of a factor in the development of IOP elevation than the amount of inflammatory cells, as outflow facility is greatly reduced in patients with excessive amounts of flare, irrespective of the number of inflammatory cells.^{12,13} This is due to increased viscosity of the aqueous humor.

Accumulation of inflammatory cells can unquestionably impede aqueous humor outflow through the trabecular meshwork. Inflammatory cellular debris leads to cellular depopulation of the trabecular meshwork. This is likely more significant than simple blockade of the trabecular meshwork by inflammatory cells.¹⁴

Though unsubstantiated by histological evaluation, there may be direct inflammation of the trabecular meshwork itself (trabeculitis), leading to a decreased ability to actively filter aqueous humor. This is suggested by conditions such as herpetic keratouveitis and glaucomatocyclitic crisis, where the IOP may be dramatically elevated in the face of relatively mild anterior chamber inflammation.

While the onset of herpetic keratouveitis outbreak typically happens from an endogenous reason, occasionally the nidus may be external and iatrogenic. Herpetic keratouveitis has been noted to be activated following laser peripheral iridotomy performed with either an argon or YAG laser.^{15,16} Also, herpetic keratouveitis has been seen to be medically induced both by prostaglandin

analogs as well as the antimetabolite mitomycin C.^{17,18}

Management

The cornerstone of management for herpetic keratouveitis involves topical cycloplegia and corticosteroids such as prednisolone acetate 1% or loteprednol etabonate 0.5% (Lotemax, Bausch + Lomb) at least on a QID basis. For recalcitrant cases, difluprednate 0.05% (Durezol, Alcon) may be used TID-QID, but close observation for IOP elevation is needed if used on a long-term basis. An adjunctive role for oral antiviral medications has been identified for patients using corticosteroids.¹⁹⁻²² Appropriate doses of oral antiviral agents for treating active ocular disease include acyclovir 400mg five times per day, valacyclovir 1,000mg twice per day and famciclovir 250mg three times per day.

Oral antiviral medications used in conjunction with topical antiviral medications and corticosteroids have long been advocated for the management of herpetic keratouveitis, though there was not much scientific evidence to support this practice. The Herpetic Eye Disease Study (HEDS) attempted to elucidate the benefit, if any, of oral acyclovir in the management of herpetic iridocyclitis in patients already using topical prednisolone sodium phosphate and trifluridine. This arm of the HEDS was discontinued early due to poor patient recruitment. However, while the number of patients recruited in this trial was too small to achieve statistically conclusive results, the trend in the results suggested a benefit of oral acyclovir 400mg, five times daily for the treatment of HSV iridocyclitis in patients receiving topical corticosteroids and trifluridine prophylaxis.²³ There is support for the use of prophylactic acyclovir 600mg QD in the prevention of recurrences of herpetic keratouveitis.²⁴

Aqueous suppressants are the mainstay treatment of uveitis related IOP rise. Topical beta-blockers are a viable option, though they may have poor effect in uveitic glaucoma.^{14,25} Topical carbonic anhydrase inhibitors have been seen to work especially well in lowering the IOP in uveitic glaucoma.^{14,25} An alpha-2 adrenergic agonist is also an acceptable option.^{14,25} Miotics must be avoided as they increase vascular permeability and can worsen inflammation.²⁶ Likewise, prostaglandin analogs should also be avoided whenever possible as they may potentiate inflammation.²⁷

Clinical Pearls

- Iris stromal atrophy associated with uveitis is highly suggestive of herpetic etiology.
- Elevated IOP that is disproportionately high compared to the degree of anterior chamber inflammation is highly indicative of herpetic disease.
- Herpes should be considered the primary cause of recurrent uveitis in individuals with a history of herpetic eye disease. A detailed medical evaluation is necessary only when other signs or symptoms indicate the potential for another disease.
- Unilateral uveitis associated with high intraocular pressure is almost always caused by herpes.
- Herpetic keratouveitis and glaucomatocyclitic crisis may be within the spectrum of the same disease process.

1. Udom UC, Idu FK. Clinical findings and management of herpetic keratouveitis with secondary glaucoma. *JNOA* 2005;12:30-3.
2. Merayo-Lloves J, Power WJ, Rodriguez A, et al. Secondary glaucoma in patients with uveitis. *Ophthalmologica*. 1999;213(5):300-4.
3. Schacher S, Garweg JG, Russ C, Bohnke M. Diagnosis of herpetic uveitis and keratouveitis. *Klin Monatsbl Augenheilkd*. 1998;212(5):359-62.
4. Vannas A, Ahonen R, Makitie J. Corneal endothelium in herpetic keratouveitis. *Arch Ophthalmol*. 1983;101(6):913-5.
5. Liesegang TJ. Herpes zoster ophthalmicus: natural history, risk factors, clinical presentation, and morbidity. *Ophthalmology*. 2008;115(2 Suppl):S3-12.

6. Santos C. Herpes simplex uveitis. *Bol Asoc Med P R*. 2004;96(2):71-4, 77-83.

7. Van der Lelij A, Ooijman FM, Kijlstra A, Rothova A. Anterior uveitis with sectoral iris atrophy in the absence of keratitis: a distinct clinical entity among herpetic eye diseases. *Ophthalmology*. 2000;107(6):1164-70.

8. Lin P, Yoon MK, Chiu CS. Herpes zoster keratouveitis and inflammatory ocular hypertension 8 years after varicella vaccination. *Ocul Immunol Inflamm*. 2009;17(1):33-5.

9. Gupta N, Sachdev R, Sinha R, et al. Herpes zoster ophthalmicus: disease spectrum in young adults. *Middle East Afr J Ophthalmol*. 2011;18(2):178-82.

10. Freddo TF. Shifting the paradigm of the blood-aqueous barrier. *Exp Eye Res*. 2001;73(5):581-92.

11. Casey R, Li WW. Factors controlling ocular angiogenesis. *Am J Ophthalmol*. 1997;124(4):521-9.

12. Souissi K, El Afrit MA, Trojet S, et al. Etiopathogeny of intraocular pressure modifications in uveitis. *J Fr Ophtalmol*. 2006;29(4):456-61.

13. Ladas JG, Yu F, Loo R, et al. Relationship between aqueous humor protein level and outflow facility in patients with uveitis. *Invest Ophthalmol Vis Sci*. 2001;42(11):2584-8.

14. Kok H, Barton K. Uveitic glaucoma. *Ophthalmol Clin North Am*. 2002;15(3):375-87.

15. Hou YC, Chen CC, Wang LJ, Hu FR. Recurrent herpetic keratouveitis following YAG laser peripheral iridotomy. *Cornea*. 2004;23(6):641-2.

16. Gaynor BD, Stamper RL, Cunningham ET Jr. Presumed activation of herpetic keratouveitis after Argon laser peripheral iridotomy. *Am J Ophthalmol*. 2000;130(5):665-7.

17. Kroll DM, Schuman JS. Reactivation of herpes simplex virus keratitis after initiating bimatoprost treatment for glaucoma. *Am J Ophthalmol*. 2002;133(3):401-3.

18. Rao A, Tandon R, Sharma N, et al. Herpetic keratitis and keratouveitis after mitomycin-C use in glaucoma filtering surgery: a short case series. *Eur J Ophthalmol*. 2009;19(6):1088-90.

19. Siverio Júnior CD, Imai Y, Cunningham ET Jr. Diagnosis and management of herpetic anterior uveitis. *Int Ophthalmol Clin*. 2002;42(1):43-8.

20. Gaynor BD, Margolis TP, Cunningham ET Jr. Advances in diagnosis and management of herpetic uveitis. *Int Ophthalmol Clin*. 2000;40(2):85-109.

21. Rihova E, Boguszakova J, Havlikova M, et al. Treatment of herpes simplex keratouveitis with systemic and local administration of acyclovir. *Cesk Slov Oftalmol*. 1996;52(2):109-14.

22. Bialasiewicz AA, Jahn GJ. Systemic acyclovir therapy in recurrent keratouveitis caused by herpes simplex virus. *Klin Monatsbl Augenheilkd*. 1984;185(6):539-42.

23. The Herpetic Eye Disease Study Group. A controlled trial of oral acyclovir for iridocyclitis caused by herpes simplex virus. *Arch Ophthalmol*. 1996;114(9):1065-72.

24. Rodriguez A, Power WJ, Neves RA, Foster CS. Recurrence rate of herpetic uveitis in patients on long-term oral acyclovir. *Doc Ophthalmol*. 1995;90(4):331-40.

25. Sung VC, Barton K. Management of inflammatory glaucomas. *Curr Opin Ophthalmol*. 2004;15(2):136-40.

26. Mori M, Araie M, Sakurai M, et al. Effects of pilocarpine and tropicamide on blood-aqueous barrier permeability in man. *Invest Ophthalmol Vis Sci* 1992; 33:416-23.

27. Sacca S, Pascotto A, Siniscalchi C, et al. Ocular

complications of latanoprost in uveitic glaucoma: three case reports. *J Ocul Pharmacol Ther*. 2001;17(2):107-13.

PLATEAU IRIS SYNDROME

Signs and Symptoms

Patients with plateau iris syndrome tend to be younger, typically ranging in age from 30 to 50 years, with a female predilection.¹ In a series of 67 patients with angle closure developing at age 40 or younger, 52% had plateau iris syndrome.² While pupil block angle closure glaucoma is associated with hyperopia, plateau iris configuration and syndrome can precipitate angle closure glaucoma even in myopic eyes.³

Patients are typically asymptomatic, not realizing they have this anatomic predisposition to angle closure unless diagnosed during an eye exam or having experienced an episode of angle closure (either spontaneously or following diagnostic mydriasis). Should this occur, the patient will then have the attendant signs and symptoms of ocular pain, redness, vision loss, headache and nausea. Plateau iris syndrome can, in other instances, instead result in asymptomatic chronic angle closure glaucoma with progressive disease in the absence of symptoms.⁴

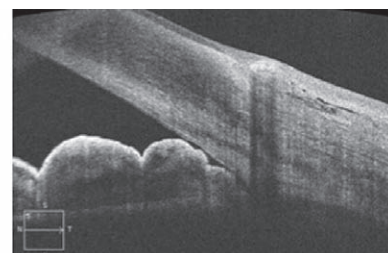
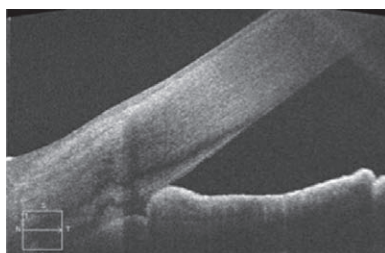
Biomicroscopically and gonioscopically, there is a steep iris approach into the angle recess with a visible, large roll(s) of the iris prior to the angle recess. The iris does not exhibit the classic iris bombé associated with pupil

block angle closure. Typically, the central anterior chamber is deep, differentiating this condition from the more common pupil block angle closure.⁵⁻⁷ The classic gonioscopic finding, in addition to a steep iris insertion, is a classic 'double hump' on indentation gonioscopy. The peripheral hump is created by the iris draping over an anteriorly located ciliary body and the central hump occurs from the iris curving over the anterior lens surface.⁸

Pathophysiology

Plateau iris configuration refers to the pre-iridotomy findings of a normal anterior chamber depth, flat iris plane and a narrow, or closed, angle. Plateau iris syndrome describes the post-iridotomy findings of either spontaneous or dilation-induced angle closure in patients with plateau iris configuration.⁵ Plateau iris syndrome is a less common condition than plateau iris configuration, which is itself an uncommon entity.⁵ Plateau iris syndrome can only be diagnosed following laser peripheral iridotomy (LPI) performed either in prophylaxis of an occludable angle or as part of therapy for angle closure glaucoma.⁹ Despite the presence of a patent LPI, the angle remains occludable or actually closed.¹⁰⁻¹²

In plateau iris configuration and syndrome, the ciliary processes are situated anteriorly compared to normal subjects and patients with angle closure caused by primary pupillary block.¹³ The



Anterior segment OCT demonstrating the plateau iris configuration.

ciliary processes provide structural support beneath the peripheral iris, preventing the iris root from falling away from the trabecular meshwork after iridotomy. An anatomical forward position of the ciliary processes keeps the peripheral iris root in apposition to the trabecular meshwork, consequently preventing the posterior repositioning of the iris following iridotomy, resulting in a persistent post-procedure narrow or closed angle.^{5,6,13-15}

Plateau iris is an anatomic variant of iris structure in which the iris periphery angulates sharply forward from its insertion point. It then again angulates centrally backward, along with an anterior positioning of the ciliary processes which can be demonstrated with ultrasound biomicroscopy.¹⁶ While plateau iris configuration and syndrome is considered an anatomic anomaly existing independently of other findings, there have been cases where multiple iris cysts have caused anterior rotation of the iris root and a plateau iris configuration.^{17,18}

Plateau iris syndrome is classified into a complete and incomplete form. In the incomplete form, intraocular pressure (IOP) does not elevate either spontaneously or following pharmacologic mydriasis. In contradistinction, the complete form will demonstrate an elevated IOP.¹⁹ However, the etiology of these distinctions remains unclear. It has been postulated that the lack of IOP elevation in the incomplete form is due to a difference in the extent or magnitude of circumferential angle closure.¹⁹

Another possibility is that the actual height of the plateau iris is the determining factor for IOP rise—that is, if only the posterior trabecular meshwork is blocked by the iris height, the IOP does not rise. However, if the plateau iris height is great enough to appose the anterior trabecular meshwork, a significant rise in IOP occurs.¹

Management

In a gonioscopically-verified occludable or closed angle secondary to anatomical etiology, without inflammatory synechiae or neovascularization, an LPI is performed to remove any pupil block component. In the majority of cases of occludable or closed angles due to pupil block, the anterior chamber deepens and angle structures become visible following the procedure. However, in plateau iris configuration, there typically is no discernible response to LPI and the angle remains closed or occludable. Thus, the diagnosis of plateau iris syndrome is made.^{20,21}

Optical coherence tomography can confirm a clinical suspicion of plateau iris configuration and syndrome. OCT can show a patent laser iridotomy and identify plateau iris syndrome after iridotomy.²²

Most cases of plateau iris syndrome have been historically managed conservatively with pilocarpine 1% QD-BID. Low dosing of this medication is more for the miotic effect rather than IOP lowering. Pilocarpine causes iris stretching and thinning and is an effective means to open the anterior chamber angle and has historically been successful in managing plateau iris syndrome.¹⁴ However, this option is not ideal as it inhibits dilated fundus evaluations and many patient will not tolerate pilocarpine side effects. Additionally, future dilation can still put the patient into angle closure.

Recently, argon laser peripheral iridoplasty (ALPI) has been shown to be a successful management tool for plateau iris configuration and syndrome.^{1,15,18,20} ALPI is a thermal laser-induced iridoretraction procedure where burns are placed at all clock hours about the peripheral iris, effectively causing tissue contraction throughout the peripheral iris. This in turn pulls the peripheral iris away from the trabecular meshwork, relieving

potentially occludable angles as well as actual angle closure. Thus, it is effective both in therapy for angle closure as well as in prophylaxis of potentially occludable angles. ALPI has become the treatment of choice both for plateau iris configuration and syndrome. This beneficial effect is maintained for years, though a small percentage of patients may eventually need retreatment.¹ One controlled study demonstrated that ALPI is more effective than conventional medical therapy for acute angle closure glaucoma, especially from plateau iris syndrome.²³

Clinical Pearls

- Plateau iris syndrome cannot be diagnosed without the performance of an LPI, wherein, after the procedure, the angle configuration remains unchanged. Prior to LPI, the patient with a steep iris and occludable angle is said to have plateau iris configuration.
- Gonioscopy must be performed on patients—even those with patent LPIs. The presence of a patent LPI does not necessarily mean that the patient is safe to dilate or does not still have a risk of angle closure.
- Plateau iris configuration is the condition most likely to respond to pharmacologic pupil dilation with closure of the angle.
- Plateau iris syndrome is considered primary angle closure without pupil block.
- Due to the anteriorly located ciliary processes, lens removal will not debulk the anterior chamber and open the angle as it would in primary pupil block angle closure. Therefore, cataract surgery is not a therapeutic option for plateau iris syndrome.

1. Ritch R, Tham CC, Lam DS. Long-term success of argon laser peripheral iridoplasty in the management of plateau iris syndrome. *Ophthalmology*. 2004;111(1):104-8.

2. Ritch R, Chang BM, Liebmann JM. Angle closure in younger patients. *Ophthalmology*. 2003;110(10):1880-9.



Haag-Streit Innovation Brought To Life.



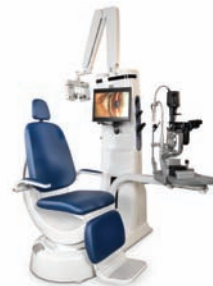Haag-Streit



Octopus



LENSTAR®



Xoma™



Surgical

Haag-Streit is more than the sum of its parts. Our mission is innovation, which leads to the development of important diagnostic devices and equipment. Used by doctors in nearly every country, they're noted for accuracy, durability and engineering. It's what your patients expect, and you demand. Watch for what's coming out of Haag-Streit next. Science. Brilliance. Certainty.

The Superior Practice.

3. Barkana Y, Shihadeh W, Oliveira C, et al. Angle closure in highly myopic eyes. *Ophthalmology*. 2006;113(2):247-54.
4. Besada E, Reynolds S. Evaluation and management of plateau iris syndrome: case report and review. *Optometry*. 2005;76(7):376-81.
5. Wand M, Grant WM, Simmons RJ, et al. Plateau iris syndrome. *Trans Sect Ophthalmol Am Acad Ophthalmol Otolaryngol*. 1977;83(1):122-30.
6. Mandell MA, Pavlin CJ, Weisbrod DJ, et al. Anterior chamber depth in plateau iris syndrome and pupillary block as measured by ultrasound biomicroscopy. *Am J Ophthalmol*. 2003;136(5):900-3.
7. Li PS, Lai JS, Lam DS. Anterior chamber depth in plateau iris syndrome and pupillary block as measured by ultrasound biomicroscopy. *Am J Ophthalmol*. 2004;137(6):1169.
8. Kiuchi Y, Kanamoto T, Nakamura T. Double hump sign in indentation gonioscopy is correlated with presence of plateau iris configuration regardless of patent iridotomy. *J Glaucoma*. 2009;18(2):161-4.
9. Hagadus R, Fabijanczyk B. Response to laser iridotomy in Hispanic and Caucasian patients with narrow, occludable filtration angles. *Klin Oczna*. 2005;107(1-3):39-42.
10. Ng WT, Morgan W. Mechanisms and treatment of primary angle closure: a review. *Clin Experiment Ophthalmol*. 2012;40(4):e218-28.
11. Razeghinejad MR, Kamali-Sarvestani E. The plateau iris component of primary angle closure glaucoma: developmental or acquired. *Med Hypotheses*. 2007;69(1):95-8.
12. Kumar RS, Tantisevi V, Wong MH, et al. Plateau iris in Asian subjects with primary angle closure glaucoma. *Arch Ophthalmol*. 2009;127(10):1269-72.
13. Pavlin CJ, Ritch R, Foster FS. Ultrasound biomicroscopy in plateau iris syndrome. *Am J Ophthalmol*. 1992;113(4):390-5.
14. Pavlin CJ, Foster FS. Plateau iris syndrome: changes in angle opening associated with dark, light, and pilocarpine administration. *Am J Ophthalmol*. 1999;128(3):288-91.
15. Leung CK, Chan WM, Ko CY, et al. Visualization of anterior chamber angle dynamics using optical coherence tomography. *Ophthalmology*. 2005;112(6):980-4.
16. Diniz Filho A, Cronemberger S, M rula RV, Calixto N. Plateau iris. *Arq Bras Oftalmol*. 2008;71(5):752-8.
17. Azuara-Blanco A, Spaeth GL, Araujo SV, et al. Plateau iris syndrome associated with multiple ciliary body cysts. Report of three cases. *Arch Ophthalmol*. 1996;114(6):666-8.
18. Crowston JG, Medeiros FA, Mosaed S, et al. Argon laser iridoplasty in the treatment of plateau-like iris configuration as result of numerous ciliary body cysts. *Am J Ophthalmol*. 2005;139(2):381-3.
19. Sekhar GC, Onam KS, Kunjam V. Incomplete and complete plateau iris syndrome. *Clin Experiment Ophthalmol*. 2004;32(2):222-4.
20. Ouazzani BT, Berkani M, Ecoffet M, Lachkar Y. Argon laser iridoplasty in the treatment of angle closure glaucoma with plateau iris syndrome. *J Fr Ophtalmol*. 2006;29(6):625-8.
21. Kumar RS, Baskaran M, Chew PT, et al. Prevalence of plateau iris in primary angle closure suspects an ultrasound biomicroscopy study. *Ophthalmology*. 2008;115(3):430-4.
22. Parc C, Laloum J, Berg s O. Comparison of optical coherence tomography and ultrasound biomicroscopy for detection of plateau iris. *J Fr Ophtalmol*. 2010;33(4):266.e1-3.

23. Lam DSC, Lai JSM, Tham CCY, et al. Argon laser peripheral iridoplasty versus conventional systemic medical therapy in treatment of acute primary angle-closure glaucoma: A prospective, randomized, controlled trial. *Ophthalmology* 2002; 109(9):1591-96.

ANGLE RECESSION GLAUCOMA

Signs and Symptoms

Patients with angle recession glaucoma are typically asymptomatic, unless the disease is advanced with profound visual field or fixation loss or intraocular pressure (IOP) that has become extremely elevated. Patients with significantly elevated intraocular pressure often are symptomatic with pain and visual disturbances secondary to corneal decompensation.

Angle recession glaucoma is more common in younger males, though any patient may develop this condition.¹⁻³ There is a history of antecedent blunt trauma to the involved eye, often occurring years earlier. Sports injuries and assault are the most common causes.⁴⁻⁶

In some instances, a history of ocular injury may not be available as the patient may either not remember the precipitating incident or, in the case of abuse or assault, may deny the trauma.⁶ Other signs of ocular trauma, including corneal scars, Descemet's membrane tears, corneal pigment, correctopia, iridodialysis, phacodonesis and cataract may be found in association with angle recession glaucoma.⁷

Hyphema is a very common comorbidity and many cases of angle recession glaucoma are associated with traumatic hyphema at inception.⁸⁻¹¹ The vast majority of patients with traumatic hyphema have some degree of angle recession.⁵ Many traumatic eye injuries produce angle recession without ever developing glaucoma.

The rise in IOP may be substantial. Interestingly, there is often an unexplained IOP rise in 50% of the untrau-

matized, fellow eyes, often years after trauma.¹² This could indicate a predisposition to primary open angle glaucoma and that traumatic angle recession only hastens the process rather than being the inciting agent.¹²

Gonioscopically, there will be a deepening of the angle recess, revealing a greater appearance of the ciliary body (excessive gray tissue posterior to the scleral spur). In minor recessions, there will be a disruption of the insertion of the iris into the ciliary body and the ciliary body will appear more notably compared with the rest of the angle or the fellow eye. In major recessions, the iris root may be torn away and a cleft may extend into the ciliary body with a more visible scleral spur.⁷ There may be a line of scleral tissue posterior to the ciliary body in severe cases of recession.

Generally, in angle recession, the ciliary body appears wider and the scleral spur appears whiter than the normal fellow eye.⁷ There may be areas of peripheral anterior synechiae at the lateral edges of the angle recession, which can obscure the total area that has been recessed. For these reasons, in cases when gonioscopy is deemed necessary, it is always recommended it is performed in both eyes. This allows for assessment of both angles as well as inter-eye comparison.

Pathophysiology

In angle recession, blunt trauma to the eye forces aqueous laterally and posteriorly within the anterior chamber. This hydrodynamic force produces a tear between the longitudinal and circular muscles of the ciliary body. The longitudinal muscles remain attached to the scleral spur. Frequently, there is hyphema at the time of trauma due to tearing of the anterior and posterior ciliary arteries.^{2,7} Direct damage to the trabecular meshwork may result in an early rise in IOP.⁷

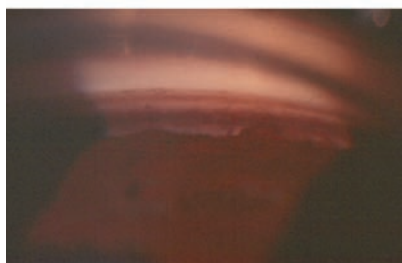In angle recession glaucoma, the trabecular meshwork may be damaged at the time of the trauma that causes angle recession, but often there is not enough functional compromise to cause outflow dysfunction. It isn't until there is a natural age-related decline in trabecular function that the damage is unmasked with IOP elevation.

While angle recession following blunt ocular trauma is rather common, only approximately 6% of patients will develop glaucoma.³ The likelihood of developing glaucoma is related to the extent that the angle is recessed. Typically, greater than 180° of angle recession will result in glaucoma while less than 180° will not.^{9,14,15}

The presence of hyphema at the time of injury greatly increases the risk of late onset open glaucoma angle either with or without angle recession.^{2,5,8} The presence of increased trabecular pigmentation, elevated baseline IOP, history of concurrent hyphema, lens displacement and recession of more than 180° of the angle are significantly associated with the occurrence of late traumatic and angle recession glaucoma.¹⁶

Minimal recession of the anterior chamber angle can heal without sequelae. With more significant angle recession, degeneration atrophy, fibrosis and scarring of the trabecular meshwork and Schlemm's canal occur. There can be obliteration of the inter-trabecular spaces and closure of Schlemm's canal years after injury with hyaline membrane development over the inner trabecular meshwork.⁷ Initially, there may be no increase in IOP. However, after many years, as the outflow facility naturally decreases, the IOP may begin to rise.

Of course, it must be remembered that this rule does not apply to every patient. The recession of the angle itself does not cause IOP elevation. Rather, widespread damage to the tra-



A case of angle recession glaucoma. Note the traumatically recessed anterior chamber angle with torn iris root.

becular meshwork at the time of trauma, with the long-term changes the injury provokes seems to be the cause. Hence, the trabecular meshwork is not just damaged in the area of the visible recession, but likely a larger portion has been impaired to some degree. Indeed, blunt trauma with minimal recession of the angle can cause glaucoma due to widespread, though not gonioscopically visible, trabecular damage.

Management

Glaucoma medications that reduce aqueous production, such as beta-blockers, alpha-2 adrenergic agonists and carbonic anhydrase inhibitors, are all very effective.

In that the genesis of glaucoma in angle recession is severe trabecular meshwork dysfunction, miotics typically are ineffective due to the disruption of the ciliary muscle-scleral spur dynamic.¹³ For this reason, laser trabeculoplasty is likewise ineffective.¹⁷⁻¹⁹ Prostaglandin analogs, which increase aqueous outflow through the uveoscleral meshwork, offer an excellent alternative for egress and can be very effective in IOP reduction.⁷

In cases of recent trauma involving angle recession, vitreous hemorrhage and severe IOP elevation, combined trabeculectomy and vitrectomy is a viable surgical option with no incidence of recurrent vitreous hemorrhage or retinal detachment in one study, though these complications are certain-

ly possible.²⁰ Overall as a sole surgery, trabeculectomy demonstrates a lower success rate in angle recession glaucoma compared to primary open angle glaucoma. Bleb fibrosis forms earlier and more significantly in cases with angle recession.²¹ For this reason, the use of antifibrotic agents are desirable in conjunction with trabeculectomy.²²

Clinical Pearls

- In cases of apparent unilateral or asymmetric glaucoma, a history of antecedent trauma should be sought.
- It can be difficult to identify a recessed angle. When performing gonioscopy, it is usually necessary to compare two sections of the angle in one eye or, occasionally, switch from eye to eye repeatedly to identify subtle recessions. If there is 360° of angle recession, comparison with the fellow eye is necessary. By examining only the suspect eye, the diagnosis can be elusive.

- IOP level in angle recession glaucoma can be quite dramatic. We have seen IOP exceed 70mm Hg.

- We have seen exceptional responses to prostaglandin analogs in patients with angle recession glaucoma.

- Due to the potential for IOP to rise years after trauma, patients with angle recession must be followed closely for their entire lives.

- Angle recession glaucoma may be an antiquated term. Early traumatic glaucoma can occur from microhyphema or angle structure damage without recession. More accurate and descriptive would be the term late-onset traumatic glaucoma with angle recession.

- Gonioscopy is never indicated immediately after blunt trauma. Late traumatic glaucoma and angle recession glaucoma typically occur months to years following the injury.

Gonioscopy at the time of the injury

(Continued on page 54A)

2013 Medication Update — Advancements and Enhancements

Since the publication of the 2012 edition of *The Handbook of Ocular Disease Management*, there have been several pharmaceutical developments. Pertinent to clinical eye care, the categories for these new medications include glaucoma and retinal disease. In one instance, an older medication is being reintroduced to the ophthalmic marketplace.

Glaucoma

Patients with glaucoma now have two new preservative-free options, a beta-blocker-free combination therapy as well as another medication that may exploit a seldom-used pressure reducing pathway.

• **Zioptan.** Glaucoma treatment can exacerbate or even cause ocular surface disease (OSD). Clinicians managing patients with glaucoma who also have pre-existing or developing OSD must act to improve patients' ocular health and enhance their satisfaction and quality of life. Much has been said about the role of preservatives, specifically benzalkonium chloride (BAK) and its relationship to the development of OSD. Decreasing the BAK load for patients being treated chronically for glaucoma is critical to enhance quality of life by minimizing OSD.

Other medications have approached this problem by developing preservatives that limit affect to the ocular surface. There now exists, for the first time, a preservative-free PGA: tafluprost 0.0015% (Zioptan, Merck), available in unit-dose vials. This preservative-free PGA has demonstrated efficacy and tolerability in patients being treated for glaucoma and ocular hypertension.¹⁻³

In a study on the efficacy and tolerability of tafluprost in 544 patients, Hommer et al.⁴ found that tafluprost was an effective, well tolerated and safe medication in a patient population with poor IOP control and/or tolerability issues with their former medication.⁴

In a study of tolerability and efficacy, Milla et al.⁵ found that switching treatment to tafluprost in patients already being treated with another PGA resulted in a statistically significant improvement of all symptoms evaluated, including stinging/burning/irritation, itching, foreign body sensation, tearing and dryness sensation. In these eyes, there was no difference noted in the IOP. In treatment-naïve eyes with either ocular hypertension or glaucoma that underwent tafluprost treatment as initial primary therapy, there was a reduction in IOP of 22%-30%, respectively.⁵

Tafluprost has been seen to be better tolerated than BAK-containing latanoprost, showing lower tear osmolarity levels while maintaining effective IOP control.⁶ Additionally, Ranno et al. noted that three months after switching patients intolerant of either travoprost, latanoprost, or bimatoprost to tafluprost experienced an overall IOP lowering effect similar to the other PGAs—however, when each PGA was individually compared with tafluprost, bimatoprost seemed to provide a statistically significant additional IOP lowering effect.⁷

Uusitalo and colleagues noted that tafluprost maintained IOP at the same level as latanoprost, but was better tolerated. In those patients, there was also a measurably improved quality of life and satisfaction with treatment using preservative-free tafluprost.⁸

• **Cosopt PF** There is now also a preservative-free fixed combination agent. The available combination is dorzolamide hydrochloride 2%/timolol maleate 0.5% ophthalmic solution, marketed under the name Cosopt-PF (Merck). Like Zioptan, it is supplied in single-use unit vials. While Cosopt itself is not a new medication, the preservative-free formulation represents another option to decrease BAK load for patients on chronic therapy. While removing BAK is very likely to reduce the impact of OSD, there exists trepidation that the preservative-free formulations may not lower intraocular pressure as well as the preservative-containing formulation. This does not appear to be a concern with Cosopt PF. A study comparing the efficacy and tolerability of preservative-free and preservative-containing (PC) formulations of Cosopt saw that the two formulations were equivalent in efficacy for change in trough and peak IOP, and had similar tolerability.⁹

• **Rescula.** Unoprostone isopropyl 0.15% (Sucampo Pharmaceuticals) was initially approved by the FDA in 2000 for lowering IOP in patients with glaucoma and ocular hypertension who were intolerant of other medications or who needed additional pressure reduction more than current drug therapy was providing. Labeled dosing was twice daily. Rescula disappeared from the US market, presumably due to competition from true prostaglandin analogs, which offered impressive reduction and once daily dosing. On December 7, 2012, the FDA approved a supplemental new drug application for Rescula with the same previous indications and dosing.

Unoprostone was developed from a prostaglandin metabolite, but the compound itself was considered to be a docosanoid in the prostone family with properties fundamentally different from prostaglandin analogs.

The drug's effects were studied on Ca(2+)-activated K(+) (BK, or Big Potassium) channels in the human trabecular meshwork as well as on prostaglandin receptors. It was seen that unoprostone was a potent BK channel activator but had no effect on prostaglandin receptors.

Further study of the effects of unoprostone compared to that of latanoprost showed that unoprostone has a distinctly different mechanism of action from latanoprost. It was not clear in this study if unoprostone affects the BK channel directly or through an unidentified mechanism.¹⁰ Though not clearly understood, it appears that the effects of unoprostone on BK and CIC-2 channels act to increase aqueous outflow through the trabecular meshwork.

It appears that Rescula may offer an alternate route to IOP reduction involving aqueous outflow through the trabecular meshwork, a mechanism currently enjoyed only by miotics. Rescula has a mean IOP reduction of 3-4mm Hg throughout the diurnal cycle in patients with a mean baseline IOP of approximately 23mm Hg. Rescula has been suggested an acceptable alternate for beta blocker therapy.¹¹

Additionally, it is noted that Rescula is an effective adjunct to patients already using topical beta-blockers.¹² In comparing additive effects of unoprostone 0.15% with brimonidine 0.2% in patients already using timolol maleate 0.5%, it was observed that

there was similar efficacy and safety between the two adjunctive medications throughout the daytime diurnal curve.¹³ When comparing the effects of monotherapy with either unoprostone 0.15% or brimonidine 0.2%, it was noted that twice-daily brimonidine demonstrates a statistically greater peak reduction in IOP than unoprostone, but unoprostone decreased IOP over the complete 12-hour daytime dosing cycle whereas brimonidine did not.¹⁴

It appears that Rescula has a favorable safety profile. There are no apparent adverse cardiovascular or pulmonary effects associated with Rescula use and no noted drug interactions.¹⁵⁻¹⁷

- **Simbrinza.** A novel combination therapy consisting of brinzolamide 1% and brimonidine 0.2%, Simbrinza suspension (Alcon) is designed to lower IOP in patients with open-angle glaucoma and ocular hypertension. Like its individual components, Simbrinza is labeled for TID dosing.

As Simbrinza is a suspension, the bottle should be shaken before use. Simbrinza suspension is supplied in an 8ml bottle. The two components of Simbrinza appear to have a complementary mechanism of IOP reduction in aqueous suppression as well as increased uveoscleral outflow.

Compared to the individual components, Simbrinza offers an additional 1-3mm Hg IOP reduction. When used as a sole agent, Simbrinza accounted for a 21-35% reduction in IOP from baseline depending upon the time of measurement.¹⁸⁻²⁰ In efficacy studies comparing Simbrinza to its individual components, the baseline IOP of study patients was stratified for each group so as to not confound the effects of the medications or inadvertently favor one treatment over another.

No additional risks were identified with Simbrinza suspension compared to those observed with the individual components.¹⁸⁻²⁰ The most frequently reported treatment-related adverse events, occurring in approximately 3-5% of patients, in descending order of incidence were blurred vision, eye irritation, dysgeusia (bad taste), dry mouth and ocular allergic reactions. Overall, Simbrinza suspension was well tolerated in clinical studies. Cardiovascular parameters (resting pulse rate and systolic and diastolic mean blood pressure) in patients using Simbrinza suspension were similar to those using brimonidine, with a modest, clinically insignificant decline.^{18,19}

Simbrinza suspension is approved as first-line therapy, adjunctive therapy and replacement therapy for patients who cannot use a prostaglandin analog.

Retina

Patients suffering from symptomatic vitreoretinal adhesion, macular edema and neovascular disease now have new advancements in therapies for their conditions.

- **Jetrea.** In October 2012, the FDA approved the proteolytic enzyme ocriplasmin 2.5mg/ml intravitreal injection (Jetrea, Thrombogenics) for patients with symptomatic vitreomacular adhesion; the therapy was introduced commercially in January 2013.

Vitreomacular adhesion and vitreomacular traction syndrome can lead to vision loss from pathologic traction and can progress on to macular hole development with even greater visual morbidity. Previously, such vitreomacular traction could

only be relieved through vitrectomy. Now it appears that success can be achieved in up to 25% of patients with vitreomacular traction syndrome with a single intravitreal injection of Jetrea.

Vitreoretinal adhesion and traction exists due to a fibrocellular proliferation at the macula. Ocriplasmin acts to cleave fibronectin and laminin at the vitreoretinal interface.^{21,22} In the largest study to date, 652 eyes with symptomatic vitreomacular adhesion were treated with a single intravitreal injection of either ocriplasmin or placebo with a goal of vitreoretinal traction resolution by day 28. Of these treated study eyes, vitreomacular adhesion resolved in 26.5% of ocriplasmin-injected eyes and in 10.1% of placebo-injected eyes ($P < 0.001$). Additionally, total posterior vitreal detachment was achieved in significantly more ocriplasmin-injected eyes than placebo.

Closure of pre-existing macular holes occurred at a significantly greater percentage in eyes injected with ocriplasmin compared to placebo. Also, visual acuity improvement (three lines or more) occurred more often in eyes injected with ocriplasmin compared to placebo. The most common adverse events associated with ocriplasmin injection were vitreous floaters, photopsia, injection-related eye pain and conjunctival hemorrhage.²³

- **Eylea.** Aflibercept (Eylea, Regeneron) is a soluble decoy receptor against vascular endothelial growth factor (VEGF) that offers greater potency and binding affinity than other anti-VEGF drugs.²⁴ Aflibercept has been shown to trap VEGF and inhibit multiple growth factors, giving it a commonly used moniker as a 'VEGF-trap.'²⁵ VEGF is well known to be a causative factor in the development of neovascularization, as well as macular edema. Aflibercept binds VEGF-A, VEGF-B, and placental growth factors 1 and 2 with high affinity.²⁶

Eylea was originally approved by the FDA in November 2011 for the treatment of choroidal neovascularization associated with age related macular degeneration (AMD). Anti-VEGF agents inhibit angiogenesis in the eye by suppressing abnormal blood vessel growth. Aflibercept given every eight weeks after a loading dose was clinically equivalent to the current FDA-approved therapy ranibizumab (Lucentis, Genentech), given every four weeks.²⁴ Thus, Eylea is appealing in that it has anti-VEGF activity similar to standard accepted therapies but requiring injection only every eight weeks rather than four.

The major update regarding Eylea is a new FDA indication for treatment of macular edema secondary to central retinal vein occlusion (CRVO). In a six-month study comparing monthly intravitreal injection of aflibercept with placebo in eyes with macular edema from CRVO, aflibercept treated eyes demonstrated improved visual acuity and reduced retinal thickness. Additionally, there was no development of neovascularization in the aflibercept treated eyes while 7% of placebo treated eyes developed this complication.²⁷

Carrying the results of this study out to a year with patients receiving 2mg of intravitreal aflibercept as needed for persistent macular edema resulted in a statistically significant improvement in visual acuity at week 24, which was largely maintained through week 52 with PRN dosing.²⁸ It remains to be seen if the frequency of Eylea injections may be reduced while treating CRVO-related macular edema.

It appears that Eylea is not only a viable treatment for macular edema arising from CRVO, but may also be used for

exudative AMD. It should be noted that the treatment for CRVO-related macular edema involved monthly injections of Eylea while the treatment for exudative AMD was bimonthly.

1. Hommer A, Kimmich F. Switching patients from preserved prostaglandin-analog monotherapy to preservative-free tafluprost. *Clin Ophthalmol.* 2011;5:623-31.
2. Pantcheva MB, Seibold LK, Awadallah NS, Kahook MY. Tafluprost: a novel prostaglandin analog for treatment of glaucoma. *Adv Ther.* 2011;28(9):707-15.
3. Ermi SS. Differential pharmacology and clinical utility of preservative-free tafluprost in the treatment of ocular hypertension and glaucoma. *Clin Ophthalmol.* 2012;6:673-8.
4. Hommer A, Mohammed Ramez O, Burchert M, Kimmich F. IOP-lowering efficacy and tolerability of preservative-free tafluprost 0.0015% among patients with ocular hypertension or glaucoma. *Curr Med Res Opin.* 2010;26(8):1905-13.
5. Milla E, Stirbu O, Rey A, et al. Spanish multicenter tafluprost tolerability study. *Br J Ophthalmol.* 2012;96(6):826-31.
6. Janulevicius I, Derka I, Grybauskienė L, et al. Effects of preservative-free tafluprost on tear film osmolarity, tolerability, and intraocular pressure in previously treated patients with open-angle glaucoma. *Clin Ophthalmol.* 2012;6:103-9.
7. Ranno S, Sacchi M, Brancato C, et al. A prospective study evaluating IOP changes after switching from a therapy with prostaglandin eye drops containing preservatives to nonpreserved tafluprost in glaucoma patients. *Scientific World Journal.* 2012;2012:804730.
8. Uusitalo H, Chen E, Pfeiffer N, et al. Switching from a preserved to a preservative-free prostaglandin preparation in topical glaucoma medication. *Acta Ophthalmol.* 2010;88(3):329-36.
9. Shedden A, Adamsons IA, Getson AJ, et al. Comparison of the efficacy and tolerability of preservative-free and preservative-containing formulations of the dorzolamide/timolol fixed combination (COSOPT™) in patients with elevated intraocular pressure in a randomized clinical trial. *Graefes Arch Clin Exp Ophthalmol.* 2010;248(12):1757-64.
10. Cuppoletti J, Malinowska DH, Tewari KP, et al. Cellular and molecular effects of unoprostone as a BK channel activator. *Biochim Biophys Acta.* 2007;1768(5):1083-92.
11. Chen CL, Tseng HY, Wu KY. Rescula as an alternative therapy for beta-blockers with long-term drift effect in glaucoma patients. *Kaohsiung J Med Sci.* 2006;22(6):266-70.
12. Leelachaikul Y, Euswas A. The efficacy of unoprostone isopropyl as an adjunct to topical beta-blocker in patients with open angle glaucoma: a 6-month study. *J Med Assoc Thai.* 2005;88 Suppl 9:S100-4.
13. Sharpe ED, Henry CJ, Mundorf TK, et al. Brimonidine 0.2% vs unoprostone 0.15% both added to timolol maleate 0.5% given twice daily to patients with primary open-angle glaucoma or ocular hypertension. *Eye (Lond).* 2005;19(1):35-40.

14. Stewart WC, Stewart JA, Day DG, Jenkins J. The safety and efficacy of unoprostone 0.15% versus brimonidine 0.2%. *Acta Ophthalmol Scand.* 2004;82(2):161-5.
15. Rescula package insert. Bethesda, MD: Sucampo Pharmaceuticals, Inc. 2012.
16. Inoue K, Shiokawa M, Higa R, et al. Adverse periocular reactions to five types of prostaglandin analogs. *Eye (Lond).* 2012;26(11):1465-72.
17. Inoue K, Shiokawa M, Wakakura M, Tomita G. Deepening of the upper eyelid sulcus caused by 5 types of prostaglandin analogs. *J Glaucoma.* 2012 Aug 29. [Epub ahead of print].
18. Katz G, Dubiner H, Samples J, et al. Three-Month Randomized Trial of Fixed-Combination Brinzolamide, 1%, and Brimonidine, 0.2% *JAMA Ophthalmol.* 2013 Apr 11:1-7.
19. Nguyen QH, McMenemy MG, Realini T, et al. Phase 3 randomized 3-month trial with an ongoing 3-month safety extension of fixed-combination brinzolamide 1%/brimonidine 0.2%. *J Ocul Pharmacol Ther.* 2013 Apr;29(3):290-7.
20. Realini T, Nguyen QH, Katz G, Dubiner H. Fixed-combination brinzolamide 1%/brimonidine 0.2% vs monotherapy with brinzolamide or brimonidine in patients with open-angle glaucoma or ocular hypertension: results of a pooled analysis of two phase 3 studies. *Eye (Lond).* 2013 May 3. doi: 10.1038/eye.2013.83. [Epub ahead of print]
21. Tsui I, Pan CK, Rahimy E, Schwartz SD. Ocriplasmin for vitreoretinal diseases. *J Biomed Biotechnol.* 2012;2012:354979. Epub 2012 Oct 14.
22. Kuppermann BD. Ocriplasmin for pharmacologic vitreolysis. *Retina.* 2012;32 Suppl 2:S225-8.
23. Stalmans P, Benz MS, Gandorfer A, et al. Enzymatic vitreolysis with ocriplasmin for vitreomacular traction and macular holes. *N Engl J Med.* 2012;367(7):606-15.
24. Xu D, Kaiser PK. Intravitreal aflibercept for neovascular age-related macular degeneration. *Immunotherapy.* 2013;5(2):121-30.
25. Thomas M, Mousa SS, Mousa SA. Comparative effectiveness of aflibercept for the treatment of patients with neovascular age-related macular degeneration. *Clin Ophthalmol.* 2013;7:495-501.
26. Browning DJ, Kaiser PK, Rosenfeld PJ, Stewart MW. Aflibercept for age-related macular degeneration: a game-changer or quiet addition? *Am J Ophthalmol.* 2012;154(2):222-6.
27. Boyer D, Heier J, Brown DM, et al. Vascular endothelial growth factor Trap-Eye for macular edema secondary to central retinal vein occlusion: six-month results of the phase 3 COPERNICUS study. *Ophthalmology.* 2012;119(5):1024-32.
28. Brown DM, Heier JS, Clark WL, et al. Intravitreal aflibercept injection for macular edema secondary to central retinal vein occlusion: 1-Year Results From the Phase 3 COPERNICUS Study. *Am J Ophthalmol.* 2013;155(3):429-37.

(Continued from page 51A)

adds to the patient's discomfort, has the potential to dislodge a clotted hyphema causing bleeding and serves no purpose toward the rendering of acute management. The examination can be completed after the sequelae of the blunt force injury have resolved.

1. Ellong A, Ebanu Mvogo C, Nyouma Moune E, et al. Post-traumatic glaucoma with irido-corneal angle injuries in Cameroon. *Bull Soc Belge Ophthalmol.* 2005;(298):21-8.
2. Jan S, Khan S, Mohammad S. Hyphaema due to blunt trauma. *J Coll Physicians Surg Pak.* 2003;13(7):398-401.
3. Salmon JF, Mermoud A, Ivey A, et al. The detection of post-traumatic angle recession by gonioscopy in a population-based glaucoma survey. *Ophthalmology.* 1994;101(11):1844-50.
4. Canavan YM, Archer DB. Anterior segment consequences of blunt ocular injury. *Br J Ophthalmol* 1982; 66:549-55.
5. Filipe JA, Barros H, Castro-Correia J. Sports-related ocular injuries. A three-year follow-up study. *Ophthalmology* 1997;104(2):313-8.

6. Mermoud A, Salmon JF, Barron A, et al. Surgical management of post-traumatic angle recession glaucoma. *Ophthalmology.* 1993;100(5):634-42.
7. Tumbocon JA, Latina MA. Angle recession glaucoma. *Int Ophthalmol Clinics.* 2002;42(3):69-78.
8. Girkin CA, McGwin G Jr, Long C, et al. Glaucoma after ocular contusion: a cohort study of the United States Eye Injury Registry. *J Glaucoma.* 2005;14(6):470-3.
9. Viestenz A, Kuchle M. Blunt ocular trauma. Part I: blunt anterior segment trauma. *Ophthalmologie.* 2004;101(12):1239-57.
10. Mortensen KK. Changes in anterior chamber depth and angle-recession, late complications to ocular contusion. *Acta Ophthalmol (Copenh).* 1978;56(6):876-82.
11. Herschler J. Trabecular damage due to blunt anterior segment injury and its relationship to traumatic glaucoma. *Trans Sect Ophthalmol Am Acad Ophthalmol Otolaryngol.* 1977;83(2):239-48.
12. Tesluk GC, Spaeth GL. The occurrence of primary open angle glaucoma in the fellow eye of patients with unilateral angle cleavage glaucoma. *Ophthalmology* 1985; 92(7):904-11.
13. Pilger IS, Khwarg SG. Angle recession glaucoma: review and two case reports. *Ann Ophthalmol.* 1985;17(3):197-9.
14. Charfi Ben Ammar O, Chaker N, Soukah M, et al. Posttraumatic glaucoma. *J Fr Ophtalmol.* 2002;25(2):126-9.

15. Sihota R, Sood NN, Agarwal HC. Traumatic glaucoma. *Acta Ophthalmol Scand.* 1995;73(3):252-4.
16. Sihota R, Kumar S, Gupta V, et al. Early predictors of traumatic glaucoma after closed globe injury: trabecular pigmentation, widened angle recess, and higher baseline intraocular pressure. *Arch Ophthalmol.* 2008;126(7):921-6.
17. Goldberg I. Argon laser trabeculoplasty and the open-angle glaucomas. *Aust N Z J Ophthalmol.* 1985;13(3):243-8.
18. Lieberman MF, Hoskins HD Jr, Hetherington J Jr. Laser trabeculoplasty and the glaucomas. *Ophthalmology.* 1983;90(7):790-5.
19. Robin AL, Pollack IP. Argon laser trabeculoplasty in secondary forms of open-angle glaucoma. *Arch Ophthalmol.* 1983;101(3):382-4.
20. Wang XY, Hu RR, Shen LP, et al. Combined trabeculectomy and vitrectomy for intractable glaucoma with severe ocular contusion involving the posterior segment. *Chin Med J (Engl).* 2011;124(15):2316-20.
21. Mermoud A, Salmon JF, Straker C, et al. Post-traumatic angle recession glaucoma: a risk factor for bleb failure after trabeculectomy. *Br J Ophthalmol.* 1993;77(10):631-4.
22. Manners T, Salmon JF, Barron A, et al. Trabeculectomy with mitomycin C in the treatment of post-traumatic angle recession glaucoma. *Br J Ophthalmol.* 2001;85(2):159-63.

I·Caps®
EYE VITAMIN
& MINERAL SUPPLEMENT

There's never been a better time to do something about macular health.*

ICaps® Lutein and Omega-3 Vitamin Help:

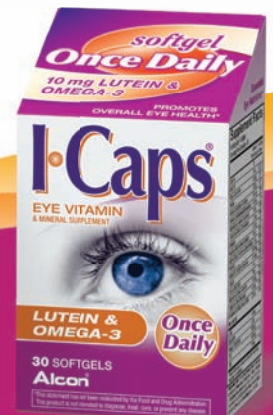- PROTECT the retina with lutein^{1*}
- PROMOTE macular health^{2*}
- SUPPORT the natural defense system of the eye^{3*}

Once-Daily

ICaps® L&O Vitamins have ingredients studied in AREDS2. It's the only once daily softgel with 10 mg of Lutein, 2 mg of Zeaxanthin and beneficial levels of Omega-3s to help support macular health.*

Recommend ICaps® Lutein & Omega-3 Vitamin to your patients before another minute goes by.

Visit icapsvitamins.com to learn more.



*These statements have not been evaluated by the Food and Drug Administration. This product is not intended to diagnose, treat, cure, or prevent any disease.

References: (1) Richer S, Stiles W, Statkute I, et al. Double-masked, placebo-controlled, randomized trial of lutein and antioxidant supplementation in the intervention of atrophic age-related macular degeneration: the Veterans LAST study (Lutein Antioxidant Supplementation Trial). *Optometry*. 2004;75:3-15. (2) SanGiovanni JP, Chew EY, Clemons TE, et al. The relationship of dietary lipid intake and age-related macular degeneration in a case-control study. *AREDS Report No. 20. Arch Ophthalmol*. 2007;125:671-679. (3) Chiu C, Taylor A. Nutritional antioxidants and age-related cataract and maculopathy. *Experimental Eye Research*. 2007;84:229-245.

Alcon®

FloraGLO®
LUTEIN

a Novartis company

© 2013 Novartis

2/13

ICP13001JAD

FloraGLO is a registered trademark of Kemin Industries, Inc.

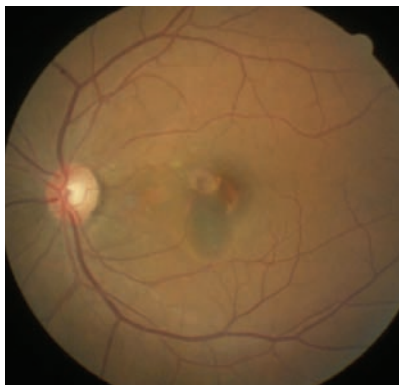IDIOPATHIC POLYPOIDAL CHOROIDAL VASCULOPATHY

Signs and Symptoms

Idiopathic polypoidal choroidal vasculopathy (IPCV), historically known as posterior uveal bleeding syndrome, is a typically unilateral disease that produces numerous periodic bouts of retinal pigment epithelium (RPE) detachment with or without hemorrhage secondary to serosanguinous leakage in the peripapillary region.¹⁻¹³ A macular variant has been identified.⁵⁻⁷ The disease has also been associated with the risk factor of smoking, myopic degeneration with the presence of staphyloma, and tilted disc syndrome.^{7,9,14}

Though frequently mistaken for age-related macular degeneration (AMD), its differentiation is based on age of onset (younger individuals), race (often non-white), lack of drusen, as well as its characteristic angiographic and optical coherence tomography (OCT) findings.^{1-6,14} Once believed to be a disease of middle-aged, African-American women, its presentation is now recognized to affect any people of color with some suggestion of a greater prevalence among Asians.¹⁻¹⁴ The entity has a documented incidence of only 8-13% in white patients with cases reported in Irish, French, German and Italian nationalities.³ IPCV has no obvious gender predilection.¹⁻⁶ The natural course of the disease often follows a remitting-relapsing course clinically associated with chronic, multiple, recurrent serosanguinous detachments of the retinal pigment epithelium, associated neurosensory retinal detachment, and subretinal neovascularization.⁴ Remarkably, the long-term visual prognosis is good as long as the macula is not involved.¹⁻¹³

Funduscopically, IPCV presents as subretinal orange nodules (polyps) within the choroidal vasculature.¹⁻¹⁴



Idiopathic polypoidal choroidal vasculopathy.

Intravenous fluorescein angiography (IVFA) poorly delineates the choroidal circulation. Indocyanine green angiography (ICGA) uses indocyanine green dye which fluoresces in the infrared spectrum, permitting enhanced imaging of structures below the RPE and overlying extravasated fluid. Its molecular size and capacity to bind to albumin allow the dye to remain in the choriocapillaris, providing the potential for detailed imaging of entities at this deep level.¹³⁻¹⁹ Active IPCV will angiographically appear as a hot spot at the location of the leaking polyps.¹³⁻¹⁹

Pathophysiology

Idiopathic polypoidal choroidal vasculopathy has been considered by many as a distinct choroidal abnormality characterized by an intrachoroidal vascular network of vessels ending in polyp-like structures.^{1-18,13} It is hypothesized that eyes with neovascular AMD are different than those with IPCV in that the new vascular formations exhibit substantially different structural alterations of the elastic layer in the Bruch's membrane.⁸ Elastin gene (EG) polymorphisms play a role in the development of neovascularization of both entities; however, genetic differences in the EG may be among the reasons for the histopathological differences.⁸

Researchers using indocyanine green angiography have been able to discern two different patterns of vascularization.^{2,20} The first demonstrates feeder and draining vessels along with network vessels creating the characteristic findings seen in choroidal neovascularization (CNV).^{2,10} Points of focal dilatation on marginal vessels were comprised of polypoidal lesions.² The second pattern demonstrated neither feeder nor draining vessels in the setting of far fewer network vessels.² Again, the points of deformation of the network vessels appeared as polypoidal lesions.²

The researchers believe the first pattern represents a variant of deformed CNV.^{2,10} The second pattern is more unique and postulated to result from abnormalities of the choroidal vessels such as abnormal dilatation and hyalinization of the vessels in the setting of exudative changes in the blood plasma.² Further changes in the basement membrane, showing deposits and granulomatous tissue suggests, at least in some cases, the condition arises from hyalinized arteriosclerosis of choroidal vessels.^{2,11,12}

The pathophysiology postulated to induce IPCV choroidal abnormalities in cases of myopic staphyloma and tilted disc syndrome are induced blood-flow disturbances to the region.⁶ Once the abnormal vessels invade Bruch's membrane to form a polypoidal network, the RPE is pushed upward by increased intravascular pressure created by the dilated vessels and exudation from the vessels in the choroidal network.^{2,20}

Management

In the event fluid and hemorrhage obscure observation of the choroidal detail, OCT, IVFA and ICGA can assist in diagnosis as well as guide treatment and improve post-treatment monitoring.^{13,21-26}

Indocyanine green angiography uses tricarboyanine dye that is injected intravenously and is imaged as it passes through ocular vessels. An excitation filter with a peak at 805nm and a barrier filter with a transmission peak of 835nm, corresponding to the maximum fluorescence emitted by the dye in whole blood permits the capture of its pooling or leakage.^{12,25-27} The large molecular characteristics of the dye itself and its ability to bind to albumin allow it to remain inside the large choroidal vessels. Its fluorescent properties enable viewing in the presence of choroidal bleeding.^{13,26-28} Choroidal neovascularization using ICG is observed as either focal hyperfluorescence (hot spot) or diffuse hyperfluorescence (plaque). Scanning laser ophthalmoscopy (SLO) imaging allows for better visualization of feeder vessels, allowing even more selective treatment.²⁰

Imaging the choroid with spectral-domain optical coherence tomography (SD-OCT) technology is often ineffective because of signal transmission limitations.²⁹⁻³² Modifications to the instrumentation has created enhanced-depth imaging optical coherence tomography (EDI-OCT).²⁹ This improved system permits imaging of the choroid with reasonable clarity.²⁹⁻³² Enhanced-depth imaging provides in vivo cross-sectional imaging of the choroid. It is a commercially available package on most spectral-domain OCT devices.^{29,30} EDI-OCT demonstrates solitary or multiple polypoidal lesions with local moderate reflectivity between the RPE and Bruch's membrane.^{31,32} Moderate reflectivity and an incomplete Bruch's membrane can be seen in the presence of dome-like RPE detachments which sometimes accompany polypoidal lesions.³²

Intravitreal therapy remains the standard-of-care treatment for polypoidal choroidal vasculopathy.^{25,33-37} Photodynamic therapy (PDT) can

be used by itself or in combination with an anti-vascular endothelial growth factor inhibitor (anti-VEGF) such as ranibizumab or bevacizumab.^{1-4,10,11,22-25,35-40} While the addition of an anti-VEGF agent has not significantly improved outcomes or reduced polypoidal lesion recurrence, the EVEREST and PEARL studies along with others demonstrated its assistance to PDT in treating subretinal hemorrhages.³⁴⁻³⁸ For this reason, dual therapy seems to be gaining favor over PDT alone.³⁴⁻³⁸ Continuous monthly intravitreal anti-VEGF treatment has also been studied.³⁹ While the results indicate the treatment is well tolerated with reduced polypoidal lesions, visual stabilization, resolution of subretinal hemorrhage and reduced macular edema are variable. Branching choroidal vessels remain.³⁹

Angiographically guided laser photocoagulation targeted exclusively to the feeder vessels supplying IPCV lesions and laser directed at extrafoveal IPCV lesions is also recognized as an effective method of treatment.^{6,40} Laser photocoagulation is used as a last resort when other therapies fail.⁴⁰

Clinical Pearls

- Since choroidal neovascular membranes have the capability to grow at a rate of 10-15 microns per day, prompt referral to the retinal specialist upon suspicion of any CNV is urgent.
- All modern imaging techniques such as IVFA, ICGA and OCT have a role in the accurate diagnosis and following of IPCV.
- Patients found to have exudative, hemorrhagic retinopathy, without signs of active inflammation or precursors to AMD, should be considered suspicious for IPCV.

1. Yannuzzi LA, Sorenson J, Spaide RF, Lipson B. Idiopathic polypoidal choroidal vasculopathy (IPCV). 1990. *Retina*. 2012;32 Suppl 1:1-8.

2. Yuzawa M. Polypoidal choroidal vasculopathy. *Nihon*

Ganka Gakkai Zasshi. 2012;116(3):200-31.

3. Ciardella AP, Donsoff IM, Huang SJ, et al. Polypoidal choroidal vasculopathy. *Surv Ophthalmol*. 2004;49(1):25-37.

4. McCleary CD, Guier CP, Dunbar MT. Polypoidal choroidal vasculopathy. *Optometry*. 2004;75(12):756-70.

5. Escañó MF, Fujii S, Ishibashi K, et al. Indocyanine green videoangiography in macular variant of idiopathic polypoidal choroidal vasculopathy. *Jpn J Ophthalmol*. 2000;44(3):313-6.

6. Stangos AN, Gandhi JS, Nair-Sahni J, et al. Polypoidal choroidal vasculopathy masquerading as neovascular age-related macular degeneration refractory to ranibizumab. *Am J Ophthalmol*. 2010;150(5):666-73.

7. Moororthy RS, Lyon AT, Rabb MF, et al. Idiopathic polypoidal choroidal vasculopathy of the macula. *Ophthalmology*. 1998;105(8):1380-5.

8. Kondo N, Honda S, Ishibashi K, et al. Elastin gene polymorphisms in neovascular age-related macular degeneration and polypoidal choroidal vasculopathy. *Invest Ophthalmol Vis Sci*. 2008;49(3):1101-5.

9. Mauget-Fayssie M, Cornut PL, Quaranta El-Maftouhi M, Leys A. Polypoidal choroidal vasculopathy in tilted disk syndrome and high myopia with staphyloma. *Am J Ophthalmol*. 2006;142(6):970-5.

10. Quaranta M, Mauget-Fayssie M, Coscas G. Exudative idiopathic polypoidal choroidal vasculopathy and photodynamic therapy with verteporfin. *Am J Ophthalmol* 2002;134(2):277-80.

11. Costa RA, Navajas EV, Farah ME, et al. Polypoidal choroidal vasculopathy: Angiographic characterization of the network vascular elements and a new treatment paradigm. *Prog Retin Eye Res* 2005;24(5):560-86.

12. Yuzawa M, Mori R, Kawamura A. The origins of polypoidal choroidal vasculopathy. *Br J Ophthalmol* 2005;89(5):602-7.

13. Stanga PE, Lim JL, Hamilton P. Indocyanine green angiography in chorioretinal diseases: indications and interpretation: an evidence-based update. *Ophthalmol*. 2003;110(1):15-21.

14. Laude A, Cackett PD, Vithana EN, et al. Polypoidal choroidal vasculopathy and neovascular age-related macular degeneration: same or different disease? *Prog Retin Eye Res*. 2010;29(1):19-29.

15. Kumar A, Nainiwal S, Prakash G. Indocyanine green angiography in age-related macular degeneration. *Bombay Hosp J*. 2002;44(3):333-9.

16. Alexander LJ. Exudative and nonexudative macular disorders. In: Alexander LJ, ed. *Primary care of the posterior segment*, 3rd Ed. New York, McGraw-Hill 2002:75-208.

17. Fernandes LH, Freund KB, Yannuzzi LA, et al. The nature of focal areas of hyperfluorescence or hot spots imaged with indocyanine green angiography. *Retina* 2002;22(5):557-68.

18. Berger JW, Maguire MC, Fine SL. The macular photocoagulation study. In: Kertes, P J, Conway MD, eds. *Clinical trials in ophthalmology: a summary and practice guide*, 1st Ed. Philadelphia; Lippincott, Williams and Wilkins 1998:71-96.

19. Nishijima K, Takahashi M, Akita J, et al. Laser photocoagulation of indocyanine green angiographically identified feeder vessels to idiopathic polypoidal choroidal vasculopathy. *Am J Ophthalmol* 2004;137(4):770-3.

20. Okubo A, Hirakawa M, Ito M, et al. Clinical features of early and late stage polypoidal choroidal vasculopathy characterized by lesion size and disease duration. *Graefes Arch Clin Exp Ophthalmol*. 2008;246(4):491-9.

21. Conrath J, Ridings B. Indocyanine green angiography in age-related macular degeneration. *J Fr Ophthalmol*. 2003;26(8):854-63.

22. Ueno C, Gomi F, Sawa M, Nishida K. Correlation of indocyanine green angiography and optical coherence tomography findings after intravitreal ranibizumab for polypoidal choroidal vasculopathy. *Retina*. 2012;32(10):2006-13.

23. Chae JB, Lee JY, Yang SJ, et al. Time-lag between subretinal fluid and pigment epithelial detachment reduction after polypoidal choroidal vasculopathy treatment. *Korean J Ophthalmol*. 2011;25(2):98-104.

24. Coppens G, Spielberg L, Leys A. Polypoidal choroidal vasculopathy, diagnosis and management. *Bull Soc Belge Ophthalmol*. 2011;(317):39-44.

25. Gomi F, Tano Y. Polypoidal choroidal vasculopathy and treatments. *Curr Opin Ophthalmol*. 2008;19(3):208-12.

26. Windisch R, Windisch BK, Cruess AF. Use of fluorescein and indocyanine green angiography in polypoidal choroidal vasculopathy patients following photodynamic therapy. *Can J Ophthalmol*. 2008;43(6):678-82.

27. Hutchinson JK, Street M, Gurwood AS, Myers MD. Face off: Fluorescein vs. OCT. *Review of Optometry* 2011; 148(9): 62-75.

28. Slakter JS, Yannuzzi LA, Guyer DR. Indocyanine-green angiography. *Curr Opin Ophthalmol*. 1995;6(3):25-32.

29. Noori J, Riazi Esfahani M, Hajizadeh F, Zaferani MM. Choroidal mapping; a novel approach for evaluating choroidal thickness and volume. *J Ophthalmic Vis Res*. 2012;7(2):180-5.

30. Nagase S, Miura M, Makita S, et al. High-penetration optical coherence tomography with enhanced depth imaging of polypoidal choroidal vasculopathy. *Ophthalmic Surg Lasers Imaging*. 2012;43(2):e5-9.

31. Ojima Y, Hangai M, Sakamoto A, et al. Improved visualization of polypoidal choroidal vasculopathy lesions using spectral-domain optical coherence tomography. *Retina*. 2009;29(1):52-9.

32. Li HY, Dai RP, Dong FT, Chen YX. Tomographic features of polypoidal choroidal vasculopathy lesions by spectral domain optical coherence tomography. *Zhonghua Yan Ke Za Zhi*. 2011;47(8):715-20.

33. Ziemssen F, Heimann H. Evaluation of verteporfin pharmacokinetics--redefining the need of photosensitizers in ophthalmology. *Expert Opin Drug Metab Toxicol*. 2012;8(8):1023-41.

34. Koh A, Lee WK, Chen LJ, et al. EVEREST Study: efficacy and safety of verteporfin photodynamic therapy with ranibizumab or alone versus ranibizumab monotherapy in patients with symptomatic macular polypoidal choroidal vasculopathy. *Retina*. 2012;32(8):1453-1464.

35. Gomi F, Sawa M, Wakabayashi T, et al. Efficacy of intravitreal bevacizumab combined with photodynamic therapy for polypoidal choroidal vasculopathy. *Am J Ophthalmol*. 2010;150(1):48-54.

36. Kim SJ, Yu HG. Efficacy of combined photodynamic therapy and intravitreal bevacizumab injection versus photodynamic therapy alone in polypoidal choroidal vasculopathy. *Retina*. 2011;31(9):1827-34.

37. Lee YH, Lee EK, Shin KS, et al. Intravitreal ranibizumab combined with verteporfin photodynamic therapy for treating polypoidal choroidal vasculopathy. *Retina*. 2011;31(7):1287-93.

38. Tomita K, Tsujikawa A, Yamashiro K, et al. Treatment of polypoidal choroidal vasculopathy with photodynamic therapy combined with intra-

vitreal injections of ranibizumab. *Am J Ophthalmol*. 2012;153(1):68-80.

39. Kokame GT, Yeung L, Lai JC. Continuous anti-VEGF treatment with ranibizumab for polypoidal choroidal vasculopathy: 6-month results. *Br J Ophthalmol*. 2010;94(3):297-301.

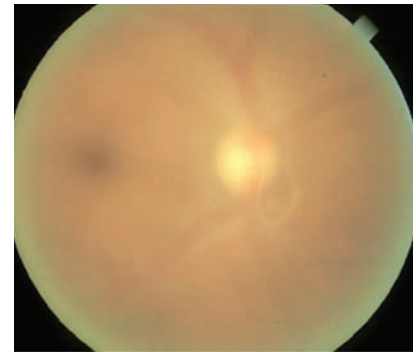
40. Gemmy Cheung CM, Yeo I, Li X, et al. Argon laser with and without anti-vascular endothelial growth factor therapy for extrafoveal polypoidal choroidal vasculopathy. *Am J Ophthalmol*. 2013;155(2):295-304.

POSTERIOR VITREOUS DETACHMENT

Signs and Symptoms

Posterior vitreous detachment (PVD) refers to the separation of the cortical vitreous from the internal limiting membrane (ILM) of the retina anywhere posterior to the vitreous base.¹⁻¹⁴ It may be localized, partial or complete.^{3,5} Symptoms include the appearance of floating spots in the visual field, particularly noticeable against the bright blue sky or light colored surfaces such as reading words on a white page or looking at a white wall. The floating spots are the result of shadows cast by collagen fibrils suspended and drifting through the liquefied portions of the vitreous gel. The result is the characteristic entoptic phenomenon known as “floaters.” The phenomenon is often accentuated in environments having fluorescent illumination.⁷

In cases where floaters are the result of acute PVD with accompanying vitreous hemorrhage, the floating spots may be large or may be numerous. In the event the vitreous hemorrhage is on the visual axis, a reduction of acuity may be present.^{13,14} In cases where there is an incomplete detachment and retinal traction, the symptom of flashing lights (photopsia) may occur.⁷⁻⁹ PVD has no racial or gender predilection and is common, occurring in approximately 50% of patients over the age of 50, increasing to approximately 75% by age 65.^{8,11,12} There is an increased risk of PVD in



Weiss ring in a case of PVD.

aphakic or pseudophakic eyes, myopes and eyes with a history of trauma or intraocular inflammation.^{9,12} Women may be prone to PVD at a younger age secondary to reduced hyaluronic acid synthesis associated with decreasing postmenopausal estrogen levels.^{2,8,11}

Biomicroscopic examination reveals an optically clear space filled with liquefied vitreous between the detached posterior hyaloid and the retina.^{1,5,10} The pathognomonic sign of a PVD is the presence of a clinically observable fibrous annulus of tissue (Weiss or Vogt ring) in the vicinity of the optic disc.⁹ This ring represents the remnants of the circular attachment of the posterior, primary cortical vitreous to the site encircling the nerve (Area of Martegiani).¹⁰ The presence of a Weiss ring does not indicate total separation of the posterior hyaloid membrane from the ILM, nor does its absence confirm that the posterior hyaloid membrane remains attached.⁴ While patients on anticoagulation therapy may have a larger incidence of vitreous hemorrhage following acute PVD, their risk for retinal tears and detachments does not seem to be any higher.^{13,14}

In cases where the detachment is incomplete, traction is produced by tangential mechanical forces caused by focal condensations and shrinkage of the vitreous.^{15,16} This causes vitreomacular traction (VMT) syndrome.^{15,16}

These patients may experience variable changes in visual acuity and metamorphopsia which has the potential to worsen as the tissue distorts.^{15,16}

Pathophysiology

The vitreous is comprised of water, inorganic salts, ascorbic acid and two major macromolecules: collagen and glycosaminoglycans (GAGs), particularly hyaluronic acid.¹⁷⁻²¹ The vitreous “gel” is formed by a dilute meshwork of collagen fibrils that provides a scaffold-like structure that is supported by hyaluronic acid.¹⁷ Attachments of the vitreous to the retina occur in areas where the ILM is the thinnest, including the vitreous base, the margins of the optic disc, the back of the crystalline lens in contact with the hyaloidocapsular ligament of Wieger, the foveola, along large retinal vessels and sites of abnormal vitreoretinal adhesion such as lattice margins or areas of chorioretinal scar formation.^{1,5,7} It was previously thought that the posterior vitreous collagen fibrils directly inserted into the ILM but recent findings suggest that an extracellular matrix composed of laminin, fibronectin and sulfated proteoglycans interface and act as a “molecular glue.”^{6,8} The balance of the posterior vitreous adherence is more diffuse.⁸

As aging occurs, progressive reorganization of the hyaluronic acid and collagen molecules induces two major vitreous changes: liquefaction and aggregation of collagen fibrils.^{11,21} Synchysis refers to liquefaction of the vitreous and is typically an aging process accelerated by myopia, inflammation, trauma, hereditary vitreoretinal syndromes such as Stickler’s and Marfan’s syndromes, retinal vascular diseases, aphakia and vitreous hemorrhage.^{1,11,19-23} Synchysis is the most common degenerative change in the vitreous and has been found to be present as early as four years of age.

Liquefied vitreous may account for approximately 20% of the vitreous volume by ages 14-18.^{1,3} The degeneration continues steadily after age 40 with more than half of the vitreous body becoming liquid by the age of 80.^{2,11,18}

The process of synchysis leaves pockets of liquefaction known as lacunae. Biomicroscopically, they are regions that develop centrally, devoid of collagen fibrils. These lacunae typically enlarge and coalesce over time.^{3,11,21,23,25} Syneresis refers to the process of vitreous collapse where collagen fibrils aggregate into macroscopic bundles of parallel fibrils.^{1,11,18,21,26}

When both synchysis and syneresis are present, the collagen aggregates become suspended and mobile within the lacunae.²¹ They create moving penumbra which, when large enough, can be detected by the patient. The aggregates can also be observed clinically as freely moving dark particles in the vitreous that scatter with ocular movement.^{1,5,21}

The process of PVD begins with synchysis of the vitreous and weakening of the vitreoretinal adhesions.¹⁸⁻²³ Enlargement of formed lacunae cause the posterior vitreal cortical wall overlying the involved area to become thinned.¹⁹ As the vitreoretinal adhesions dissolve, discontinuities form within the posterior hyaloid (either via fissure evolution or via a microbreak in the thin cortical vitreous layer).²⁷ This allows synchitic vitreous to enter the subhyaloid space, dissecting the posterior hyaloid from the ILM of the retina.^{1-5,10-21}

PVD typically begins in a single superior perifoveal quadrant. The vitreoretinal ILM attachments at the fovea and optic nerve head often remain attached.²⁸ Over time, as the perifoveal detachment enlarges, it completely surrounds the attachments at the fovea.²⁸ Finally, detachment of the vitreous from the foveal region

produces a funnel-shaped configuration with attachments at the optic disc and vitreous base.²⁶⁻²⁸ When the PVD releases from the optic nerve, the process is complete.²⁸⁻³⁰ A complete PVD occurs when the posterior cortical vitreous is detached from the entire retina, including its attachment to the optic nerve up to the posterior border of the vitreous base.³¹ Even healthy young eyes may begin to form incomplete or partial PVD beginning as early as the fourth decade of life.³⁰ These cases may remain asymptomatic but progress slowly for years before becoming a complete PVD.³⁰

An anomalous PVD results when synchysis occurs without sufficient detachment from the ILM. Here, gel liquefaction exceeds the degree of vitreoretinal dehiscence (separation).¹⁸ This results in tractional effects at the interface.¹⁸ Those with genetic collagen disease, such as Marfan’s, Ehlers-Danlos and Stickler’s syndromes have a higher incidence of anomalous PVD.^{11,18,32} The physics of anomalous PVD has the potential to generate forces which split the posterior vitreous cortex causing vitreoschisis.¹⁸ When this phenomenon occurs in the periphery, tractional forces increase the risk of retinal tears and detachments.^{16,18} When it occurs in or adjacent to the macula, it has the potential to induce wrinkling of the neurosensory retina referred to as macular pucker. The pathology is also known as cellophane maculopathy, epiretinal membrane, vitreoretinal interface maculopathy and VMT syndrome.^{16,18,33}

Vitreoschisis may contribute to the process of macular hole formation and increase the risk diabetic macular edema.^{16,33} When vitreoschisis occurs in the region of the optic disc, vitreopapillary traction may increase the risk of neovascularization of the disc.¹⁸ In susceptible patients, the process can increase the risk of proliferative vitreoretinopathy.¹⁸

Uchino et al. have proposed a grading system for age-related PVD:

Stage 1—incomplete perifoveal PVD in up to three quadrants

Stage 2—incomplete perifoveal PVD in all quadrants, with residual attachment to the fovea and optic disc

Stage 3—incomplete PVD over the posterior pole with residual attachment to the optic disc

Stage 4—complete PVD.³⁰

Management

The management for acute PVD is thorough examination of the posterior segment to rule out the presence of retinal holes, tears and detachments. The vitreous should be evaluated for “tobacco dust,” sometimes referred to as Schaffer’s sign (retinal pigment epithelial cells or red blood cells that are passed into the vitreous following a retinal tear) and hemorrhage.³⁴⁻³⁶ Dilated biomicroscopy (with and without a contact or non-contact fundus lens), three-mirror lens and binocular indirect ophthalmoscopy with and without scleral indentation should all be considered to examine for retinal breaks requiring immediate treatment.

Patients should be educated to the classic signs and symptoms of retinal detachment: repetitive flashing lights, sudden shower of additional new floating spots, cobwebs in the field of vision, visual acuity loss and missing visual field as if a curtain was blocking the view. Since patients initially diagnosed as having uncomplicated PVD have approximately a 3.4% chance of a retinal tear within the first six weeks following the event, they should be advised to limit their activity (no contact or competitive sports, no weight lifting, no jogging or running) over that period until they can be re-evaluated.^{7,11} Patients should be counseled that in most cases the symptoms disappear on their own. In the event symptoms remain and create a distract-

ing annoyance, pars plana vitrectomy can be discussed as an option, although the procedure is not routinely recommended.³⁷ Pharmacologic vitreolysis can be used for anomalous PVD leading to vitreomacular traction.

Clinical Pearls

- The Weiss ring, which results from a PVD, may be complete (circular) or broken and often casts a shadow during indirect ophthalmoscopic examination.

- Patients with posterior vitreous detachment with vitreous pigment granules or hemorrhage are much more likely to have a retinal tear compared with those who have normal findings on qualitative vitreous examination.

- Patients should be educated about the potential long-term complications of the pars plana vitrectomy option for the removal of floaters (i.e., potential for cataractogenesis in phakic patients, potential for prolonged healing course, potential for macular edema).

- Patients who develop late-onset retinal breaks and/or detachment (following retinal examination) after acute PVD typically are patients who complained of increased symptoms following the acute PVD event. Patients not reporting increased symptoms despite having a PVD are unlikely to have late-onset retinal complications.

1. KhuKhrana, AK. The Vitreous. In: KhuKhrana, AK. Comprehensive Ophthalmology. Daryaganj, Delhi, India, New Age International 2007:243-248.
2. Sebag J. Development and aging of the vitreous. In: Sebag J. The vitreous: structure, function, and pathobiology. New York: Springer-Verlag; 1989:73-92.
3. Le Goff MM, Bishop PN. Adult vitreous structure and postnatal changes. Eye. 2008;22(10):1214-1222.
4. Snead MP, Snead DR, James S, Richards AJ. Clinicopathological changes at the vitreoretinal junction: posterior vitreous detachment. Eye (Lond). 2008;22(10):1257-62.
5. Johnson MW. Posterior vitreous detachment: evolution and complications of its early stages. Am J Ophthalmol. 2010;149(3):371-82.
6. Serpetopoulos CN, Korakitis RA. An optical explanation of the entoptic phenomenon of ‘clouds’ in posterior vitreous detachment. Ophthalmic Physiol Opt. 1998;18(5):446-51.

7. Hollands H, Johnson D, Brox AC, et al. Acute-onset floaters and flashes: is this patient at risk for retinal detachment? JAMA. 2009;302(20):2243-9.
8. Sharma S, Walker R, Brown GC, Cruess AF. The importance of qualitative vitreous examination in patients with acute posterior vitreous detachment. Arch Ophthalmol. 1999;117(3):343-6.
9. Margo CE, Harman LE. Posterior vitreous detachment. How to approach sudden-onset floaters and flashing lights. Postgrad Med. 2005;117(3):37-42.
10. Tiedeman J, Mittra R, Han D, et al. Vitreous and retinal detachments. In: Regillo C, Brown G, Flynn H. Vitreoretinal disease: the essentials. New York: Thieme; 1999: 65-86.
11. Majcher CE, Gurwood, A.S. The role of the vitreous in retinal disease. Review of Optometry Retinal Supplement 2012; 149(4): 6s-14s.
12. Smiddy WE, Michels RG, Glaser BM, deBustros S. Vitrectomy for macular traction caused by incomplete vitreous separation. Arch Ophthalmol. 1988;106(1):624-8.
13. El-Sanhouri AA, Foster RE, Petersen MR, et al. Retinal tears after posterior vitreous detachment and vitreous hemorrhage in patients on systemic anticoagulants. Eye (Lond). 2011;25(8):1016-9.
14. Witmer MT, Cohen SM. Oral anticoagulation and the risk of vitreous hemorrhage and retinal tears in eyes with acute posterior vitreous detachment. Retina. 2012 Oct 26. [Epub ahead of print]
15. Kampik A. Pathology of epiretinal membrane, idiopathic macular hole, and vitreomacular traction syndrome. Retina. 2012;32 Suppl 2:S194-8.
16. Wylegala E, Woyna-Orlewicz A, Pilat J, et al. Traction maculopathies--pathogenesis and diagnostics. Klin Oczna. 2006;108(10-12):457-63.
17. Schubert H, Kincaid M, Green R, et al. Anatomy and physiology. In: Regillo C, Brown G, Flynn H. Vitreoretinal disease: the essentials. New York, Thieme, 1999: 3-25.
18. Sebag J. Anomalous posterior vitreous detachment: a unifying concept in vitreo-retinal disease. Graefes Arch Clin Exp Ophthalmol. 2004;42(8):690-8.
19. Johnson MW. Posterior vitreous detachment: evolution and complications of its early stages. Am J Ophthalmol. 2010;149(3):371-382.
20. Skeie JM, Mahaian VB. Dissection of the human vitreous body elements for proteomic analysis. J Vis Exp. 2011;23(47):2455-64.
21. Sebag J. Age-related changes in human vitreous structure. Graefes Arch Clin Exp Ophthalmol. 1987;225(2):89-93.
22. Maumenee IH. Vitreoretinal degeneration as a sign of generalized connective tissue diseases. Am J Ophthalmol 1979;88(9):432- 49.
23. Sebag J. Pathology of the vitreous. In: Sebag J. The vitreous: structure, function, and pathobiology. New York, Springer-Verlag, 1989: 97-147.
24. Bishop PN. Structural macromolecules and supra-molecular organization of the vitreous gel. Prog Retin Eye Res. 2000;19(3):323-44.
25. Bishop PN, Holmes DF, Kadler KE, et al. Age-related changes on the surface of vitreous collagen fibrils. Invest Ophthalmol Vis Sci 2004;45(4):1041-1046.
26. Bos KJ, Holmes DF, Kadler KE, et al. Axial structure of the heterotypic collagen fibrils of vitreous humour and cartilage. J Mol Biol 2001;306(5):1011-22.
27. Smiddy WE, Michels RG, Greene WR. Morphology, pathology, and surgery for idiopathic macular disorders. Retina. 1990;10(1):288-96.
28. MacDonald HR, Johnson RN, Schatz H. Surgical

results in the vitreomacular traction syndrome.

Ophthalmology. 1994;101(1):1397-1403.

29. Gandorfer A, Rohleder M, Kampik A. Epiretinal pathology of vitreomacular traction syndrome. *Br J Ophthalmol*. 2002;86(8):902-9.

30. Uchino E, Uemura A, Ohba N. Initial stages of posterior vitreous detachment in healthy eyes of older persons evaluated by optical coherence tomography. *Arch Ophthalmol*. 2001;119(10):1475-9.

31. Halfter W, Winzen U, Bishop PN, et al. Regulation of eye size by the retinal basement membrane and vitreous body. *Invest Ophthalmol Vis Sci*. 2006;47(8):3586-94.

32. Maumenee IH. Vitreoretinal degeneration as a sign of generalized connective tissue diseases. *Am J Ophthalmol* 1979;88:432-49.

33. Bottós J, Elizalde J, Arevalo JF, et al. Vitreomacular traction syndrome. *J Ophthalmic Vis Res*. 2012;7(2):148-61.

34. Machemer R. Pathogenesis and classification of massive periretinal proliferation. *Br J Ophthalmol*. 1978;62(11):737-47.

35. Khan Utman SA, Mahomed I, Baig HM. A case of atypical idiopathic choroidal effusion syndrome. *J Coll Physicians Surg Pak*. 2012;22(6):406-8.

36. Gupta M, Prasad S. Acute posterior vitreous detachment. *Br J Ophthalmol* 2001;85(4):504.

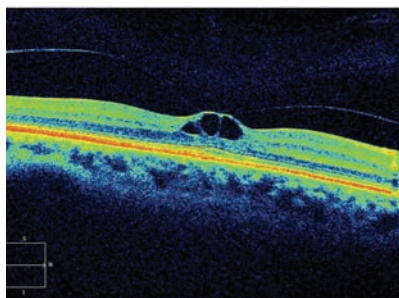
37. Stoffelns BM, Vetter J, Keicher A, Mirshahi A. Pars plana vitrectomy for visually disturbing vitreous floaters in pseudophacic eyes. *Klin Monbl Augenheilkd*. 2011;228(4):293-7.

VITREOMACULAR TRACTION SYNDROME

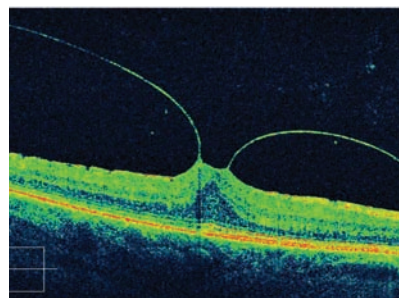
Signs and Symptoms

Vitreomacular traction (VMT) syndrome has no racial or age predilection, though there is a greater incidence in older women than men.^{1,2} Common symptoms include micropsia, metamorphopsia and vision decrease. These symptoms are often mild and their onset insidious.¹⁻⁴ In some cases, patients may be asymptomatic and VMT syndrome is discovered on optical coherence tomography (OCT) evaluation being done for other reasons. In other cases, mild symptoms and a subtle ophthalmoscopy appearance leads to performance and subsequent discovery on OCT. Several terms are used to describe this condition, including vitreomacular traction, vitreomacular adhesion (VMA) and vitreomacular traction syndrome (VMTS).

There may exist a discrepancy between signs and symptoms, with some patients demonstrating signifi-



Vitreomacular adhesion with tractional cystoid macular edema in vitreomacular traction syndrome. (Courtesy Diana Shechtman, OD.)



Broad vitreomacular adhesion in a case of vitreomacular traction syndrome. (Courtesy Diana Shechtman, OD.)

cant degrees of VMT yet manifesting excellent visual acuity while others with minimal VMT but with significant anterior-posterior vitreal traction having greatly diminished acuity.¹

Diagnosis of VMT syndrome is very challenging clinically. Adhesions of the vitreous at the macula may be difficult if not impossible to observe even with high-powered contact or non-contact lens biomicroscopy. More easily observed than the actual vitreal macular traction itself is the surface wrinkling it produces similar to epiretinal membrane (ERM). Other complications that are more observable include actual ERM, cystoid macular edema (CME) and macular pseudohole.¹ The definitive diagnosis of VMT syndrome is done through OCT analysis.⁵⁻⁸

Spectral-domain OCT will show a partial posterior vitreous detachment (PVD) with an adherent vitreous attached to the macular region of the retina. The posterior hyaloid space will be hyper-reflective and firmly adherent to the macular region. The adhesion and resultant traction may be focal and not disturb the normal foveal architecture. Alternately, there may be significant anterior traction on this focal adhesion with tenting of the macula, perifoveal macular detachment, tractional CME and lamellar or full-thickness macular hole. These focal adhesions are often termed vitreofoveal traction, where VMT syndrome

is often reserved for more broad areas of involvement. In these other cases, rather than a focal macular adhesion, the detaching vitreous may be broadly adherent. This type of broad VMT is commonly associated with ERM and diffuse retinal thickening.^{1,5}

Pathophysiology

VMT was first described in 1970 as an incomplete PVD exerting traction on the macula and accompanied by decreased visual acuity.⁹ Today, VMT can best be described as an anomalous PVD. VMT results from vitreoretinal adhesions at the macula and the onset of a partial PVD. The tractional forces imparted upon the macula have the potential to cause foveal deformation and cavitation, CME, macular detachment, ERM and macular hole formation.¹⁰ Indeed, VMT syndrome is within a spectrum of maculopathies caused by vitreoretinal traction.

Posterior vitreous detachment is a normal age-related phenomenon characterized by progressive vitreous liquefaction, resulting in a separation between the posterior vitreous cortex and the internal limiting membrane (ILM) of the retina. Complications of PVD are more likely to arise in eyes where accelerated vitreous liquefaction occurs prior to weakening of vitreoretinal adhesions. An anomalous PVD occurs most likely as a result of premature vitreous liquefaction associated

with insufficiently weakened vitreoretinal adhesion. At the posterior pole, vitreoretinal traction may induce VMT syndrome.¹

In VMT syndrome, there is a fibrocellular proliferation that accounts for the increased vitreoretinal adhesion at the macula. The most commonly found cells at the vitreoretinal interface in VMT syndrome are astrocytes, myofibroblasts and fibrocytes, though recently it appears that retinal pigment epithelial (RPE) cells may be present as well.¹⁰ These cells, especially RPE cells, are commonly found in ERM as well, hence the similarity between the two conditions.

The vitreous cortex adherent to the ILM provides the scaffolding for this fibrocellular proliferation and the development of firm vitreoretinal adhesion seen in VMT syndrome. The proliferating cells and their accompanying extracellular matrix fortify the attachment of the vitreous to the retina. Small defects in the ILM, possibly as a result of a slowly detaching posterior vitreous, have been proposed as the nidus for the proliferating cells to gain access to the ILM surface, although this does not seem to explain the presence of RPE cells.¹⁰

As the vitreous continues to detach, the fibrocellular proliferation forming a tight adhesion between the retinal surface and the posterior hyaloid allows for both lateral and anterior vitreoretinal traction. This results in VMT syndrome with possible subsequent macular tenting, foveal cyst formation, tractional CME, ERM, foveal detachment and macular hole formation.^{1,5,10}

Management

In cases where the patient is asymptomatic or minimally symptomatic with good visual acuity (>20/30), observation should be the first consideration as there may be no functional deficits induced by VMT.⁶ There exists the

possibility that complete vitreous separation may spontaneously ensue, with relief of the vitreomacular traction, restoration of normal macular architecture, and an excellent visual outcome.¹¹⁻¹⁴

In cases with reasonable acuity, observation is the preferred management. Here, the patient should be instructed on the use of Amsler grid for home monitoring and to report any visual changes immediately. Repeat OCT is recommended every three to six months. Any documented progression of the condition or loss of function should precipitate a discussion considering more invasive therapy.

Eyes with focal VMT syndrome (vitreofoveal traction) are more likely to progress to macular hole formation with worse visual outcomes than those eyes with broad VMT. These cases should be considered for surgical intervention earlier.

Vitreotomy has long been the procedure of choice to resolve VMT syndrome and prevent other macular complications.¹⁵⁻¹⁹ Vitrectomy will relieve vitreomacular traction and often prevents progression to more serious maculopathies such as macular hole. It has been demonstrated that vitrectomy can impart a significant improvement in visual acuity and central foveal thickness postoperatively. Eyes with lamellar separation of the inner and outer foveal layers preoperatively tend to have worse prognoses, whereas eyes with cystoid macular edema or broad VMT have better postoperative visual results.¹⁷ Preoperative foveal structure, macular thickness, and duration of symptoms are also correlated with post-operative visual outcome.¹⁸

A new method to relieve traction in VMT is the advent of pharmacologic vitreolysis using ocriplasmin (Jetrea, Thrombogenics).²⁰⁻²⁵ Ocriplasmin is a genetically engineered version of a plasmin proteolytic enzyme. Fibronectin and laminin are clinically relevant

plasmin receptors located at the vitreoretinal interface which are cleaved by ocriplasmin. Ocriplasmin has been shown in clinical trials to safely release vitreomacular adhesion and close Stage 2 macular holes in a significant number of patients.²⁵ A single intravitreal ocriplasmin injection can induce separation of the vitreous from the macular surface and thereby relieve the tractional changes that contribute to vision loss from VMT syndrome and macular hole. Due to the recent FDA approval and only recent clinical availability (January 2013), it is unclear where this new modality will fall in the treatment of VMT syndrome and whether or not it will replace vitrectomy.

Clinical Pearls

- Focal vitreofoveal traction more commonly leads to CME, foveal cyst formation, and macular hole development. Broad VMT will typically lead to ERM formation, tractional CME and increased foveal thickness, but is less likely to result in macular hole formation, thus a better overall visual prognosis.

- VMT is more common than expected, as many patients are either asymptomatic or minimally symptomatic and the condition is found surreptitiously on OCT scanning.

- In mild cases, it is difficult to separate the degree of vision loss due to VMT from that caused by co-existing cataract.

1. Bottós J, Elizalde J, Arevalo JF, et al. Vitreomacular traction syndrome. *J Ophthalmic Vis Res.* 2012;7(2):148-61.

2. Yonemoto J, Ideta H, Sasaki K, Tanaka S, Hirose A, Oka C. The age of onset of posterior vitreous detachment. *Graefes Arch Clin Exp Ophthalmol.* 1994;232(2):67-70.

3. Bottós JM, Elizalde J, Rodrigues EB, Maia M. Current concepts in vitreomacular traction syndrome. *Curr Opin Ophthalmol.* 2012;23(3):195-201.

4. Shechtman DL, Dunbar MT. The expanding spectrum of vitreomacular traction. *Optometry.* 2009;80(12):681-7.

5. Barak Y, Ilnen MA, Schaal S. Spectral domain optical coherence tomography in the diagnosis and

management of vitreoretinal interface pathologies. *J Ophthalmol.* 2012;2012:876472. Epub 2012 Jun 4.

6. Reibaldi M, Avitabile T, Uva MG, et al. Ten Years of Severe Vitreomacular Traction Syndrome without Functional Damage Demonstrated by Optical Coherence Tomography. *Case Rep Ophthalmol Med.* 2011;2011:931038. Epub 2011 Sep 8.

7. Zhang ZQ, Dong FT, Yu WH, et al. Features of vitreomacular traction syndrome assessed with three-dimensional spectral-domain optical coherence tomography. *Zhonghua Yan Ke Za Zhi.* 2010;46(2):106-12.

8. Brasseur G. Vitreomacular traction. *J Fr Ophtalmol.* 2008;31(2):208-13.

9. Reese AB, Jones IS, Cooper WC. Vitreomacular traction syndrome confirmed histologically. *Am J Ophthalmol.* 1970;69(6):975-977.

10. Chang LK, Fine HF, Spaide RF, et al. Ultrastructural correlation of spectral-domain optical coherence tomographic findings in vitreomacular traction syndrome. *Am J Ophthalmol.* 2008;146(1):121-7.

11. Selver OB, Parlak M, Soylomezoglu ZO, Saatci AO. Spontaneous resolution of vitreomacular traction: a case series. *Clin Exp Optom.* 2013 Jan 24. [Epub ahead of print].

12. Hung KH, Yang CS, Lin TC, et al. Optical coherence tomography in spontaneous resolution of vitreomacular traction syndrome. *J Chin Med Assoc.* 2010;73(6):334-7.

13. Weinand F, Jung A, Becker R, Pavlovic S. Spontaneous resolution of vitreomacular traction syndrome. *Ophthalmologie.* 2009;106(1):44-6.

14. Levy J, Klempere I, Belfair N, et al. Rapid spontaneous resolution of vitreomacular traction syndrome documented by optical coherence tomography. *Int Ophthalmol.* 2004;25(4):247-51.

15. Suárez Leoz M, Vidal Fernández P, Baeza Autillo A, et al. Vitrectomy for vitreomacular traction syndrome. *Arch Soc Esp Oftalmol.* 2001;76(1):37-41.

16. Toklu Y, Demirel S, Sarac O, et al. Anatomic and functional outcome of triamcinolone-assisted 23-gauge vitrectomy in vitreomacular traction syndrome. *Semin Ophthalmol.* 2012;27(3-4):73-7.

17. Witkin AJ, Patron ME, Castro LC, et al. Anatomic and visual outcomes of vitrectomy for vitreomacular traction syndrome. *Ophthalmic Surg Lasers Imaging.* 2010;41(4):425-31.

18. Sonmez K, Capone A Jr, Trese MT, Williams GA. Vitreomacular traction syndrome: impact of anatomical configuration on anatomical and visual outcomes. *Retina.* 2008;28(9):1207-14.

19. Jiang YR, Ma Y, Li XX. Analysis of the effect of surgical management on vitreomacular traction syndrome. *Zhonghua Yan Ke Za Zhi.* 2004;40(10):670-3.

20. Mitchell MD, Miller DM. Looking at ocriplasmin as a new option in eye disease. *Drugs Today (Barc).* 2012;48(8):519-24.

21. Stalmans P, Benz MS, Gandorfer A, et al. Enzymatic vitreolysis with ocriplasmin for vitreomacular traction and macular holes. *N Engl J Med.* 2012;367(7):606-15.

22. Tsui I, Pan CK, Rahimy E, Schwartz SD. Ocriplasmin for vitreoretinal diseases. *J Biomed Biotechnol.* 2012;2012:354979. Epub 2012 Oct 14.

23. de Smet MD, Jonckx B, Vanhove M, et al. Pharmacokinetics of ocriplasmin in vitreous. *Invest Ophthalmol Vis Sci.* 2012;53(13):8208-13.

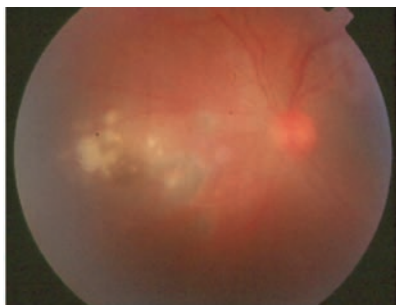
24. Wong SC, Capone A Jr. Microplasmin (ocriplasmin) in pediatric vitreoretinal surgery: Update and Review. *Retina.* 2013;33(2):339-48.

25. Kuppermann BD. Ocriplasmin for pharmacologic vitreolysis. *Retina.* 2012;32 Suppl 2:S225-8.

TOXOPLASMOSIS

Signs and Symptoms

Toxoplasma gondii is an intracellular obligate protozoan parasite.¹⁻¹⁵ In under-developed countries, untreated drinking water is considered a major source of the *Toxoplasma* organism.^{9,10} In the developed world, the major sources of the organism are via consumption of raw or undercooked meat (pork, lamb and wild game meat) and raw fruits and vegetables.¹⁻¹⁵ The organism can also be acquired through contact with soil contaminated with the feces of the cat or other small game.¹⁵ Worldwide exposure to *T. gondii* has been estimated at 30% in the US and 40-80% in Europe, India, countries in Africa and countries in South America.^{2,7-12}



“Headlights in a fog” characteristic of active toxoplasmosis. (Courtesy Barry Frauens, OD.)

Congenital cases (newborns with disease) are acquired through seropositive mothers.¹⁶ Congenital infection frequently results in systemic complications at birth: fever, jaundice, low birth weight, skin rash, pneumonia and hepatosplenomegaly.^{4,16} A unique complexity of the disease is that even when infection occurs at the time of birth, signs and symptoms may not become apparent for years.¹⁷

In disease acquired later in life, ocular symptoms are known to be variable according to the age when the infection blossoms and the ability to launch

a sustained immune response.^{1-9,14} Affected children (<12 years of age) frequently present with reduced visual acuity and may exhibit an acquired strabismus, nystagmus or evidence of previous or chronic episodes of inflammation.^{3,18-20} Teenagers and adults also present with decreased vision but may describe floaters secondary to more substantial vitreous reaction along with photophobia, pain, and hyperemia from a uveitic response.³⁻⁵ Individuals immunocompromised from either human immunodeficiency virus (HIV) or from iatrogenic suppression (organ transplantation, chemotherapy) are also highly susceptible.¹⁴

While the disease has the ability to nest itself in the deeper layers of the retina, active disease doesn't always present with an aggressive vitreous reaction.^{1-6,21-25} When the vitritis is heavy, patients may present with the chief complaint that their vision has taken on a red hue. *Toxoplasma* retinochoroiditis (choroid and retina affected) is most commonly encountered in the posterior pole.^{3,19,22} The lesions can be solitary, or multiple with satellite lesions.³⁻⁶ Active lesions present as gray-white foci of retinal necrosis with adjacent deep choroiditis, retinal vasculitis (sheathing of vessels), intraretinal hemorrhage and varying amounts of vitritis.^{3-6,8,22} When the optic disc demonstrates involvement, the condition is referred to as toxoplasma neuroretinitis.^{4-6,23-25}

The disease has been recognized as being among the common causes of granulomatous anterior uveitis with mutton-fat keratic precipitates, fibrin, cells, flare, iris nodules and posterior synechiae.^{3,5,6} Uveitis-based abnormality of intraocular pressure (either low or elevated) often occurs and in cases where inflammation is chronic from recalcitrant or recurrent disease, premature cataract formation is possible.^{21,26,27}

Scar formation occurs as each lesion becomes inactive and is signified by pigmentary hyperplasia.¹⁻⁶ Old retinal scars connote significant retinal destruction and leave corresponding dense scotomas which may affect vision depending upon location.^{3-6,28} As in any case of posterior inflammation, cystoid macular edema may develop.⁴⁻⁶ Other associated complications include punctate outer retinitis, papillitis, intraocular inflammation without retinohoroiditis, unilateral pigmentary retinopathy, Fuchs'-like anterior uveitis, scleritis, retinal artery occlusion and multifocal or diffuse necrotizing retinitis.^{3,29,30}

Finally, like any disease involving the subretinal tissues, cytokines and chemoattractants along with the stressor of the inflammation and pathology itself can induce the genesis of choroidal neovascularization, though this is uncommon.^{31,32}

Pathophysiology

Toxoplasmosis was initially identified and described by the team of Nicolle and Manceaux and by Splendore in Brazil in 1908.³³⁻³⁵ They named the organism *Ctenodactylus gundi* and recognized the source as rodents and rabbits.³³⁻³⁵ Today renamed as *Toxoplasma gondii*, the organism is among the most successful protozoan parasites, with an innate ability to manipulate the immune system of the host.¹⁻⁴⁰ The organism can be picked up by any number of mammals and some birds with a renewal lifecycle that is perpetuated in the host's small intestines. The cat is considered en masse to be the definitive host.^{1-5,33-40} Congenital transmission occurs from an infected mother to the fetus through the placenta.^{1-6,33-40} Raw or undercooked meat (lamb, chicken or beef) are also principle vectors.¹⁻⁶ When not contracted congenitally, the mode of transmission is through direct

contact with the organism.

Toxoplasma gondii is an apicomplexan intracellular protozoa (obligate organisms that have evolved complex developmental stages important for pathogenesis and transmission).³⁷⁻⁴² It is the most extensively studied organism of the coccidian group.³⁷⁻⁴² Cats acquire the organism through kills or by being fed raw meat.^{38,42} Upon ingestion, *T. gondii* commences the sexual stage by differentiating into male and female gametes which fuse in the intestinal epithelium of the host, forming a fertilized oocyst.³⁸ The oocyst is then shed in the feces.^{4,38} This living morphologic form can remain viable in soil for up to one year.^{4,38,39} The spontaneous process of sporulation (where the oocyst develops sporozoites) creates the infectious form of the organism which can be ingested intentionally or unintentionally by another animal or human.^{4,5,38,39} Once inside the intestines of the new host, asexual proliferation begins as the organism assumes the form of what is known as the proliferative tachyzoite.^{4,5,38-40}

Tachyzoites disseminate throughout the body via the circulatory and lymphatic systems carried by macrophages.^{38,39} Tachyzoites can penetrate virtually any nucleated cell.^{4,5,38,39} Central to the transmission and pathogenesis of the organism is its ability to convert from the proliferative stage (tachyzoite) into latent tissue cysts known as bradyzoites.^{38,39} Bradyzoites have the ability to accomplish encystment, becoming encapsulated.^{38,39} This biologic feature permits *Toxoplasma* to persist in the host and affords the parasite a unique opportunity to spread to new hosts through blood (placenta) or oral contact without proceeding through its sexual stages.^{39,40}

Bradyzoite tissue cysts can survive in brain, heart, skeletal muscle and retinal tissue.^{38,39,41} They can be reactivated into active toxoplasmosis whenever

host immunity becomes impaired.^{38,39} When the encapsulation breaks down, the organisms transform back into tachyzoites which invade neighboring cells.^{4,38-40} The resultant inflammatory response of the human immune system in the choroid, retina and nerve create the classic chorioretinal and neuroretinal appearance.^{1-6,37-40}

Management

Laboratory diagnosis of toxoplasmosis is based on isolation of the organism from body fluids and tissues; however, as its presentation is so distinctive, many make the diagnosis based on the observable clinical characteristics.⁴³⁻⁴⁵ Detection of *T. gondii* can be accomplished by direct identification using polymerase chain reaction (PCR) to uncover organism DNA and direct detection of the tachyzoites cysts and bradyzoites from tissues or smears obtained from biopsy of cerebral spinal fluid and blood.⁴³⁻⁴⁵ Another approach is indirect detection by checking for antibodies using the antitoxoplasma antibody test, indirect immunofluorescent antibody tests (IFAT), Sabin-Feldman methylene blue dye test (the standard for detecting *Toxoplasma* antibodies in humans) and complement fixation test.^{3,4,43-48}

Enzyme-linked immunosorbent assay and PCR are laborious, time-consuming, expensive studies.⁴³ Recently, loop-mediated isothermal amplification was developed using isothermal conditions (65°C) for DNA amplification.⁴³ The apparatus requires only a simple incubator and can amplify up to 109 copies in less than an hour, making its use more efficient.⁴³

Toxoplasmosis therapy in immunosuppressed individuals includes specific oral medication for the systemic infection and topical anti-uveitic medications for the ocular inflammatory component. There are several regimens, with different drug combi-

nations.^{22,24,49-53} Medications include pyrimethamine, sulfadiazine, clindamycin, trimethoprim-sulfamethoxazole, spiramycin, azithromycin, atovaquone and tetracycline.^{3,4,22,24,49-53} One classic approach includes pyrimethamine in combination with folinic acid to reduce the risk of drug-associated side effects, sulfadiazine and prednisone.^{24,49-53} A more convenient combination enlists Bactrim DS (trimethoprim 160mg/sulfamethoxazole 800mg, Roche) 1 tab PO BID for 4-6 weeks.⁵³ In patients who are allergic to sulfonamides, atovaquone (750mg, PO Q6H, over 2-6 months) can be substituted as an alternative to the pyrimethamine/sulfadiazine.⁵⁴

In cases where active disease does not threaten the macula or optic disc in an immunocompetent patient, observation without medical management can be offered.^{52,53} However, most clinicians continue to prescribe medications despite a lack of Level I evidence to support the efficacy of routine oral antibiotic or oral corticosteroid treatment for acute events in immunocompetent patients.^{24,55} There is Level II evidence suggesting that long-term prophylactic treatment (one tablet of Bactrim DS every three days) may reduce recurrences in chronic relapsing cases.^{55,56}

In all cases, topical uveitis management includes cycloplegia with atropine 1% or homatropine 5% QD-TID and topical steroids such as prednisolone acetate 1% or difluprednate QID-Q2H in accordance with the level of inflammation.^{3,4,49-51}

The prognosis for ocular toxoplasmosis in immunocompetent individuals is usually good, as long as the optic nerve and macula are not directly involved.^{3,4,21,22,24,43,52-56} As the disease can play a role in the provocation of other disorders, a full medical work up should be completed.⁵⁷ Since the infection and inflammation involve the choroid and retina, all lesions have the

potential to induce choroidal neovascularization requiring photodynamic therapy and anti-vascular endothelial growth factor injections.^{37,52-56,59,60} Laser photocoagulation is rarely considered.^{4,5,59,60}

Clinical Pearls

- Transmission from an infected pregnant woman to her fetus leading to congenital toxoplasmosis is referred to as vertical transmission.

- The risk of vertical transmission increases when infection occurs later in pregnancy. However, the consequences to the fetus are more severe when transmission occurs within the first trimester.

- Since acquired infection with *T. gondii* is currently a more important cause of ocular toxoplasmosis compared to congenital infection, prevention should be directed not only toward pregnant women but toward the general population.

- Other causes of granulomatous anterior uveitis with associated posterior inflammation include syphilis, tuberculosis, Lyme disease, *Toxocara* infection and HIV. Laboratory testing in unconfirmed cases should include these entities.

1. Sukthana Y. Toxoplasmosis: beyond animals to humans. *Trends Parasitol* 2006;22(3):137-42.
2. Rorman E, Zamir CS, Rilakis I et al. Congenital toxoplasmosis--prenatal aspects of *Toxoplasma gondii* infection. *Reprod Toxicol* 2006;21(4):458-72.
3. Bonfili AA, Orefice F. Toxoplasmosis. *Semin Ophthalmol* 2005;20(3):129-41.
4. Levinson RD, Rikkers SM. Ocular toxoplasmosis. In: Yanoff M, Duker JS. *Ophthalmology* 2nd Ed. Philadelphia, Mosby 2004:1167-1171.
5. Alexander LJ. Exudative and nonexudative macular disorders. In: Alexander LJ. *Primary Care of The Posterior Segment*. Norwalk, Conn, Appleton and Lange 1994 :277-344.
6. Dubey JP, Lago EG, Gemari SM, et al. Toxoplasmosis in humans and animals in Brazil: high prevalence, high burden of disease, and epidemiology. *Parasitology*. 2012;139(11):1375-424.
7. Dubey JP, Tiao N, Gebreyes WA, Jones JL. A review of toxoplasmosis in humans and animals in Ethiopia. *Epidemiol Infect*. 2012;140(11):1935-8.
8. Shahiduzzaman M, Islam R, Khatun MM, et al. *Toxoplasma gondii* seroprevalence in domestic animals and humans in Mymensingh District, Bangladesh. *J Vet Med Sci*. 2011;73(10):1375-6.
9. Petersen E, Kijlstra A, Stanford M. Epidemiology of ocular toxoplasmosis. *Ocul Immunol Inflamm*. 2012;20(2):68-75.
10. Jones JL, Dargelas V, Roberts J, et al. Risk factors for *Toxoplasma gondii* infection in the United States. *Clin Infect Dis*. 2009;49(6):878-84.
11. Garza-Leon M, Garcia LA. Ocular toxoplasmosis: clinical characteristics in pediatric patients. *Ocul Immunol Inflamm*. 2012;20(2):130-8.
12. London NJ, Hovakimyan A, Cubillan LD, et al. Prevalence, clinical characteristics, and causes of vision loss in patients with ocular toxoplasmosis. *Eur J Ophthalmol*. 2011;21(6):811-9.
13. Asano S. Granulomatous lymphadenitis. *J Clin Exp Hematop*. 2012;52(1):1-16.
14. Robert-Gangneux F, Dardé ML. Epidemiology of and diagnostic strategies for toxoplasmosis. *Clin Microbiol Rev*. 2012;25(2):264-96.
15. Jones JL, Dubey JP. Foodborne toxoplasmosis. *Clin Infect Dis*. 2012;55(6):845-51.
16. Montoya JG, Remington JS. Management of *Toxoplasma gondii* infection during pregnancy. *Clin Infect Dis*. 2008;47(4):554-66.
17. Russo M, Pergola G, Pedicini G. Ocular toxoplasmosis: our experience. *Infez Med*. 2005;13(3):160-7.
18. Jedari AS, Maliky Z, Daneshjou Kh. A 10 month old infant with nystagmus and strabismus. *Pak J Biol Sci*. 2008;11(5):817-8.
19. Gamio S, Tártara A. Sensorial strabismus due to congenital toxoplasmosis. Is it an eso- or exotropia? *Binocul Vis Strabismus Q*. 2010;25(3):138-48.
20. Vasconcelos-Santos DV, Dodds EM, Oréfice F. Review for disease of the year: differential diagnosis of ocular toxoplasmosis. *Ocul Immunol Inflamm*. 2011;19(3):171-9.
21. Delair E, Latkany P, Noble AG, et al. Clinical manifestations of ocular toxoplasmosis. *Ocul Immunol Inflamm*. 2011;19(2):91-102.
22. Antoniazzi E, Guagliano R, Meroni V, et al. Ocular impairment of toxoplasmosis. *Parassitologia*. 2008;50(1-2):35-6.
23. Wakefield D, Cunningham ET Jr, Pavesio C, et al. Controversies in ocular toxoplasmosis. *Ocul Immunol Inflamm*. 2011;19(1):2-9.
24. Butler NJ, Furtado JM, Winthrop KL, et al. Ocular toxoplasmosis II: clinical features, pathology and management. *Clin Experiment Ophthalmol*. 2013;41(1):95-108.
25. Fish RH, Hoskins JC, Kline LB. Toxoplasmosis neuroretinitis. *Ophthalmology* 1993;100(4): 1177-82.
26. Babizhayev MA. Biomarkers and special features of oxidative stress in the anterior segment of the eye linked to lens cataract and the trabecular meshwork injury in primary open-angle glaucoma: challenges of dual combination therapy with N-acetylcarnosine lubricant eye drops and oral formulation of nonhydrolyzed carnosine. *Fundam Clin Pharmacol*. 2012;26(1):86-117.
27. Bonfili AA, Curi AL, Orefice F. Fuchs' heterochromic cyclitis. *Semin Ophthalmol*. 2005;20(3):143-6.
28. Alvarenga DP, Couto MF, Pessoa VF. Perceptual visual filling-in of toxoplasmic retinochoroiditis scotomas. *Neuroreport*. 2007;18(16):1679-81.
29. Modrzejewska M, Lachowicz E, Karczewicz D, Zdanowska A. Chorioretinitis in infants. *Klin Oczna*. 2011;113(10-12):352-6.
30. Küçükdördönmez C, Yılmaz G, Akova YA. Branch retinal arterial occlusion associated with toxoplasmic chorioretinitis. *Ocul Immunol Inflamm*. 2004;12(3):227-31.

31. Mansour AM, Arevalo JF, Fardeau C, et al. Three-year visual and anatomic results of administering intravitreal bevacizumab in inflammatory ocular neovascularization. *Can J Ophthalmol*. 2012;47(3):269-74.

32. Rishi P, Venkataraman A, Rishi E. Combination photodynamic therapy and bevacizumab for choroidal neovascularization associated with toxoplasmosis. *Indian J Ophthalmol*. 2011;59(1):62-4.

33. Hill DE, Chirukandoth S, Dubey JP. Biology and epidemiology of *Toxoplasma gondii* in man and animals. *Anim Health Res Rev* 2005;6(1):41-61.

34. Ferguson DJ. *Toxoplasma gondii*: 1908-2008, homage to Nicolle, Manceaux and Splendore. *Mem Inst Oswaldo Cruz*. 2009;104(2):133-48.

35. Kim K, Weiss LM. *Toxoplasma*: the next 100 years. *Microbes Infect*. 2008;10(9):978-84.

36. Saeji JP, Boyle JP, Boothroyd JC. Differences among the three major strains of *Toxoplasma gondii* and their specific interactions with the infected host. *Trends Parasitol* 2005;21(10):476-81.

37. Mauget-Faysse M, Mimoun G, Ruiz-Moreno JM et al. Verteporfin photodynamic therapy for choroidal neovascularization associated with toxoplasmic retinochoroiditis. *Retina* 2006;26(4):396-403.

38. Wendte JM, Gibson AK, Grigg ME. Population genetics of *Toxoplasma gondii*: new perspectives from parasite genotypes in wildlife. *Vet Parasitol*. 2011;182(1):96-111.

39. Sullivan WJ Jr, Jeffers V. Mechanisms of *Toxoplasma gondii* persistence and latency. *FEMS Microbiol Rev*. 2012;36(3):717-33.

40. Skariah S, McIntyre MK, Mordue DG. *Toxoplasma gondii*: determinants of tachyzoite to bradyzoite conversion. *Parasitol Res*. 2010;107(2):253-60.

41. Feustel SM, Meissner M, Liesenfeld O. *Toxoplasma gondii* and the blood-brain barrier. *Virulence*. 2012;3(2):182-92.

42. Elmore SA, Jones JL, Conrad PA, et al. *Toxoplasma gondii*: epidemiology, feline clinical aspects, and prevention. *Trends Parasitol*. 2010;26(4):190-6.

43. Englander M, Young LH. Ocular toxoplasmosis: advances in detection and treatment. *Int Ophthalmol Clin*. 2011;51(4):13-23.

44. Hill DE, Chirukandoth S, Dubey JP. Biology and epidemiology of *Toxoplasma gondii* in man and animals. *Anim Health Res Rev* 2005;6(1):41-61.

45. Adán A, Sole M, Mateo C, et al. Cytologic identification of *Toxoplasma gondii* from subretinal aspirate. *Acta Ophthalmol*. 2012;90(4):392-3.

46. Štrhársky J, Klement C, Hrubá F. Seroprevalence of *Toxoplasma gondii* antibodies in the Slovak Republic. *Folia Microbiol (Praha)*. 2009;54(6):553-8.

47. Udonsom R, Buddhirongawatr R, Sukthana Y. Is Sabin-Feldman dye test using *T. gondii* tachyzoites from animal inoculation still the best method for detecting *Toxoplasma gondii* antibodies? *Southeast Asian J Trop Med Public Health*. 2010;41(5):1059-64.

48. Selseleh M, Keshavarz H, Mohebbi M, et al. Production and evaluation of *Toxoplasma gondii* recombinant GRA7 for serodiagnosis of human infections. *Korean J Parasitol*. 2012;50(3):233-8.

49. de-la-Torre A, Stanford M, Curi A, et al. Therapy for ocular toxoplasmosis. *Ocul Immunol Inflamm*. 2011;19(5):314-20.

50. Mulki L, Foster CS. Difluprednate for inflammatory eye disorders. *Drugs Today (Barc)*. 2011;47(5):327-33.

51. Meek R, Sullivan A, Favilla M, et al. Is homatropine 5% effective in reducing pain associated with corneal abrasion when compared with placebo? A randomized

controlled trial. *Emerg Med Australas*. 2010;22(6):507-13.

52. Pleyer U, Torun N, Liesenfeld O. Ocular toxoplasmosis. *Ophthalmologe*. 2007;104(7):603-15.

53. Holland GN. Ocular toxoplasmosis: a global reassessment. Part II: disease manifestations and management. *Am J Ophthalmol*. 2004;137(1):1-17.

54. Hughes LM, Lanteri CA, O'Neil MT. Design of anti-parasitic and anti-fungal hydroxy-naphthoquinones that are less susceptible to drug resistance. *Mol Biochem Parasitol*. 2011;177(1):12-9.

55. Kim SJ, Scott IU, Brown GC, et al. Interventions for toxoplasma retinochoroiditis: a report by the american academy of ophthalmology. *Ophthalmology*. 2013;120(2):371-8.

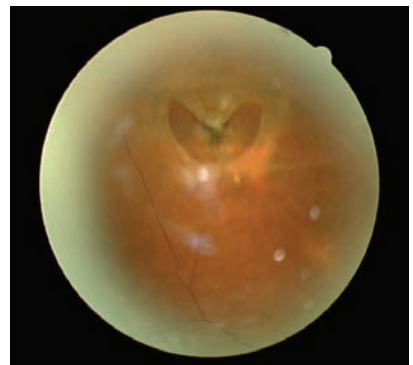56. Silveira C, Belfort R Jr, Muccioli C, et al. The effect of long-term intermittent trimethoprim/sulfamethoxazole treatment on recurrences of toxoplasmic retinochoroiditis. *Am J Ophthalmol*. 2002;134(1):41-6.

57. Tavakoli M, Roghaee S, Soheilian R, Soheilian M. Antiphospholipid syndrome following toxoplasma retinochoroiditis. *Ocul Immunol Inflamm*. 2011;19(5):311-3.

58. Kovačić-Pavičević D, Radosavljević A, Ilić A, et al. Clinical pattern of ocular toxoplasmosis treated in a referral centre in Serbia. *Eye (Lond)*. 2012;26(5):723-8.

59. Rishi P, Venkataraman A, Rishi E. Combination photodynamic therapy and bevacizumab for choroidal neovascularization associated with toxoplasmosis. *Indian J Ophthalmol*. 2011;59(1):62-4.

60. Neri P, Mercanti L, Mariotti C, et al. Long-term control of choroidal neovascularization in quiescent congenital toxoplasma retinochoroiditis with photodynamic therapy: 4-year results. *Int Ophthalmol*. 2010;30(1):51-6.



Tractional retinal tear.

TRACTIONAL RETINAL TEARS

Signs and Symptoms

Tractional retinal tears (TRT) have no specific racial, gender or laterality predilection; rather, they are produced by complications of other pathologies which induce preretinal tension.¹⁻³² Retinal tears are more common in the older population.

Tractional retinal tears are associated with posterior vitreous detachment (PVD), myopia with staphylomatous retinal stretching and vitreoretinal tension created by vitreoretinal interface abnormalities such as white with and without pressure, degenerative retinoschisis, cystic retinal tufts, epiretinal membrane, vitreomacular traction syndrome and rarely, zonular traction tufts on or near the border of lattice degeneration.^{7-10,13-16,32} Other vitreoretinal pathologies including Wagner's syndrome and Stickler's syndrome increase the risk of TRT.¹⁹

While intraretinal neovascular diseases such as proliferative diabetic retinopathy, ischemic venous occlusion and proliferative sickle-cell retinopathy can induce fibrovascular traction—which create retinal tears and tractional retinal detachment (TRD)—the typical cause is robust interaction of the vitreous along the border of vitreoretinal adhesion.¹⁻³⁰ In one study, the incidence of TRT in eyes with a symptomatic posterior vitreous detachment (PVD) was 8.2%.³¹ TRT are also associated with systemic diseases such as Marfan's syndrome, Ehlers-Danlos syndrome and homocystinuria.¹⁹ Tractional retinal tears may lead to rhegmatogenous retinal detachment (RRD).¹⁻²⁵

Patients with TRT often report a sudden onset of either a single or multiple floating spots, along with flashing lights (photopsia).¹⁰⁻¹² Unlike entoptic phenomena, which demonstrate exacerbations and remissions, or the scintillating scotoma produced in vasospastic events, the visual symptoms remain stable in the patient's visual field.¹⁰⁻¹² Pain is not a feature of any retinal detachment as the tissue has no pain receptors. There may be precipitating ocular or head trauma. If there has been a vitreous hemorrhage, there will be multiple large floaters or opacities which may take the form of "cobwebs."¹⁰⁻¹² There may be severe loss of vision if dense vitreous hemorrhage interrupts

the visual axis or if a resultant RRD involves the macula. It is also possible that the patient is asymptomatic and unaware anything has occurred.¹² The blood or retinal pigment epithelium (RPE) debris released from a TRT can be observed by the clinician during fundus examination and should be noted as “tobacco dust” or “Schaffer’s sign.”²⁹

Pathophysiology

Retinal breaks are defined as full-thickness defects in the neurosensory retina.^{1,2,7-10,11,19} They typically occur anterior to the equator. All retinal detachments involve a dissection of the neurosensory retina from its underlying RPE layer by subretinal fluid (SRF).^{4,5} The principle involved in RRD is that forces exerted by the vitreous at the site of their attachment to the retina overcome its tensile strength, creating a full-thickness discontinuity through which fluid can migrate, separating the neurosensory retina from the underlying RPE.^{3,5,13,14,19}

TRT often assume one of three forms: the flap tear (horseshoe-shaped tear), a retinal tear adjacent to an area of lattice degeneration or an operculated tear.^{1,2,4,14-19} The incidence of RRD without retinal breaks in the general phakic population is typically low (12/100,000).^{1-4,7,8,19} The natural prevalence of RRD increases to 14% with myopia greater than -3D; however, the risk increases dramatically when a symptomatic TRT is present.^{18,20} Byer notes that while the incidence of RRD from retinal breaks associated with lattice degeneration is low (0.3-0.5%), lattice degeneration may be associated with up to 60% of RRD.¹⁸ This is due to lattice degeneration being quite common and RRD uncommon in the general population.

The most common natural inciting process creating a TRT is posterior vitreous detachment.¹⁹⁻²⁴ The vitreous “gel” is formed by a meshwork of col-

lagen fibrils that provide a scaffold-like structure formed by hyaluronic acid.¹⁰ Firm attachments of the vitreous to the retina occur via chemical bonds through laminin, fibronectin and sulfated proteoglycans.¹⁰ The areas of firm adhesion include the vitreous base, the margin of the optic disc, the back of the crystalline lens (hyaloidocapsular ligament of Wieger), the fovea, along large retinal vessels and sites of abnormal vitreoretinal anatomy such as the margins surrounding lattice degeneration.^{10,13,32,33} PVD begins with synchysis (vitreous liquefaction). This weakens the vitreoretinal adhesions.¹⁰ As the vitreoretinal adhesions dissolve, discontinuities form within the posterior hyaloid (either via fissure evolution or via a microbreak in the thin cortical vitreous layer).²² This allows liquid vitreous to enter the subhyaloid space dissecting the posterior hyaloid from the ILM.^{1,11,20-23}

An anomalous PVD results when synchysis occurs without complete detachment from the ILM.²⁷ This results in tractional effects at the interface.^{1,11,20-23,32,33} The physics of PVD has the potential to generate forces which split the posterior vitreous cortex, causing vitreoschisis.¹⁰ When this phenomenon occurs, tractional forces increase the risk of TRT and RRD, especially at the margins of anatomically thin retina (lattice degeneration).^{1,13,32,33} The classic work of Foos identifies the pathogenic principles of TRT to include association with three topographical relationships to the vitreous base: intrabasal (caused by avulsion of zonular traction tufts) juxtabasal (related to traction of the posteriorly detached vitreous on irregularities in posterior border of vitreous base) and extrabasal (resulting from avulsion of cystic retinal tufts).³²

Traumatic retinal breaks are theorized to result from rapid globe distortion with expansion and contraction.

Here, vitreoretinal traction at the ora serrata and equator induces TRT, irregular breaks or retinal dialysis (circumferential breaks).^{19,26,27} Traumatic retinal breaks are documented to have an increased incidence in the inferotemporal and superonasal regions.^{19,27,28}

Horseshoe-shaped tractional tears are triangular in appearance. The apex of the tear (posterior edge) may remain attached to mobile vitreous and points towards the posterior pole.^{1,19} The base of the tear is anchored at the vitreous base. Mechanical traction of mobile vitreous to the retina may enlarge the tear and physically separate it from the RPE creating “tobacco dust.”^{1,19,30} If the tear bridges a blood vessel, there can be subsequent vitreous hemorrhage.¹⁶ If an area of retinal tissue is pulled completely free and is observed to be floating in the vitreous, the lesion is considered an operculated tear with the free retinal tissue, termed the operculum.¹⁹ Operculated tears often signal complete vitreoretinal traction release.¹⁹

Classic evidence suggests that the edges of retinal breaks are covered by smooth cellular membranes, merging peripherally with a meshwork of vitreous fibrils.¹⁶ These membrane cells have poorly defined borders, a pitted surface and a variable number of microvilli.¹⁶ Lattice surfaces and paravascular retinal degenerations seem to be covered by similar membranes with subtle microscopic differences.¹⁶

Management

The management of a TRT (observation vs. protective intervention) depends upon whether the risks of treatment outweigh the risks of retinal detachment.^{1,2,15,19,30} Tear location (superotemporal), size (larger TRT increase risk), symptoms (number one consideration), history of retinal detachment in the same eye or fellow eye, history of retinal detachment in the family, lifestyle (active vs. sedentary),

the presence of myopia (greater than six diopters), the patient's phakic status (phakic, pseudophakia, aphakia) and planned cataract surgery are all important factors.^{1,2,15,19,30}

One study reported the rate of retinal detachment in symptomatic phakic patients with TRT to be 35%, strongly recommending prophylactic treatment for any break presenting in a patient complaining of flashing lights.^{19,34} Symptomatology in the form of photopsia is long held as the most important criterion for therapeutic intervention to reduce the risk of RRD.^{15,19} The modalities used to create the protective barrier around TRT, preventing subretinal fluid (SRF) infiltration and subsequent RRD, are cryoretinopexy and barrier laser photocoagulation.^{19,30}

Cryoretinopexy involves transconjunctival cold application to create a seal between the chorioretinal tissues by destroying choriocapillaris, RPE and outer retinal elements and inducing retinal pigment epithelial hyperplasia.^{19,30-35} The hyperplastic RPE invades the sensory retina and creates a seal which makes migration of subretinal fluid and detachment of the retina difficult. The procedure requires three weeks for the seal to mature mandating reevaluation in that time period.^{19,30-33} Barrier laser photocoagulation uses argon blue-green, krypton red or diode delivery systems to create the same effect. Evidence suggests significant effects occur immediately with the maximal effect occurring in 10 days.^{19,30-35}

Clinical Pearls

- Tractional tears without symptoms or other risk factors may be safely monitored without treatment. However, a consult is advised.

- The retinal pigment epithelium often becomes hyperplastic following an insult that produces a retinal tear. This chorioretinal scar may act as a natural seal around the break. When this happens, there is a lower risk of

tractional/rhegmatogenous detachment.

- In lightly pigmented fundi, natural RPE hyperplasia often does not occur. Additionally, cryoretinopexy and laser photocoagulation may be less effective.

- Since eyes with a symptomatic posterior vitreous detachment develop retinal breaks in 8.2% of cases, patients presenting with new onset PVD with symptoms should be advised to limit strenuous activity and contact sports for a period of 3-6 weeks following the event. These patients should be re-examined with dilation and indirect ophthalmoscopy within 2-5 weeks of the initial presentation to confirm stable anatomy. Of course, patients developing increased floaters and flashes should be re-examined immediately. Patients with no increase in symptoms are highly unlikely to have any late retinal complications.

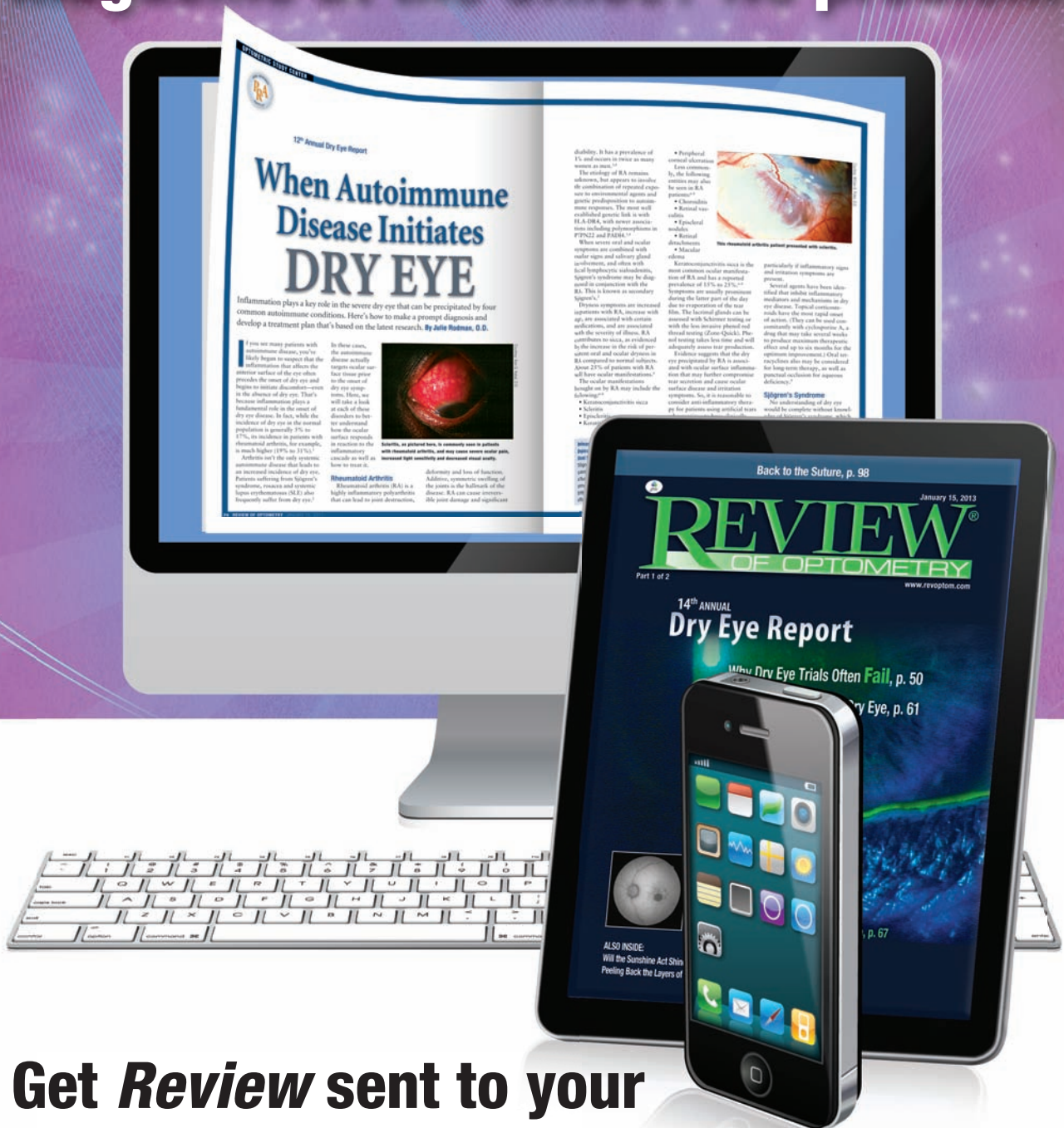- Asymptomatic atrophic retinal holes in lattice rarely lead to RRD and do not need prophylactic treatment.

- Evidence suggests cases of TRT exhibiting vitreous hemorrhage should be considered for early vitrectomy.

1. Wilkinson CP. Rhegmatogenous retinal detachment. In: Yanoff M, Duker JS. *Ophthalmology* 2nd Ed. Mosby, Philadelphia, 2004: 982-989.
2. Haimann MH, Burton TC, Brown CK. Epidemiology of retinal detachment. *Arch Ophthalmol*. 1982;100(2):289-92.
3. Saika S, Yamanaka O, Okada Y, et al. TGF beta in fibroproliferative diseases in the eye. *Front Biosci (Schol Ed)*. 2009;1(6):376-90.
4. Mity D, Fleck BW, Wright AF, Campbell H, et al. Pathogenesis of rhegmatogenous retinal detachment: predisposing anatomy and cell biology. *Retina*. 2010;30(10):1561-72.
5. Müller B, Jousseaume AM. Myopic traction maculopathy - vitreoretinal traction syndrome in high myopic eyes and posterior staphyloma. *Klin Monbl Augenheilkd*. 2011;228(9):771-9.
6. Carrero JL. Incomplete posterior vitreous detachment: prevalence and clinical relevance. *Am J Ophthalmol*. 2012;153(3):497-503.
7. Lewis H. Peripheral retinal degenerations and the risk of retinal detachment. *Am J Ophthalmol*. 2003;136(1):155-60.
8. Byer NE. Lattice degeneration of the retina. *Surv Ophthalmol*. 1979;23(4):213-48.
9. Iandiev I, Brington A, Wiedemann P. Proliferative vitreoretinopathy--pathogenesis and therapy. *Klin Monbl Augenheilkd*. 2010;227(3):168-74.
10. Hollands H, Johnson D, Brox AC, et al. Acute-onset floaters and flashes: is this patient at risk for retinal detachment? *JAMA*. 2009;302(20):2243-9.

11. Schweitzer KD, Eneh AA, Hurst J, et al. Predicting retinal tears in posterior vitreous detachment. *Can J Ophthalmol*. 2011;46(6):481-5.
12. Birda D, Tang EC. Visual hallucinations from retinal detachment misdiagnosed as psychosis. *J Psychiatr Pract*. 2011;17(2):133-6.
13. Wylegala E, Woyna-Orlewicz A, Pilat J, et al. Traction maculopathies--pathogenesis and diagnostics. *Klin Oczna*. 2006;108(10-12):457-63.
14. Byer NE. Cystic retinal tufts and their relationship to retinal detachment. *Arch Ophthalmol*. 1981;99(10):1788-90.
15. Byer NE. The natural history of asymptomatic retinal breaks. *Ophthalmology*. 1982;89(9):1033-9.
16. Robinson MR, Streeten BW. The surface morphology of retinal breaks and lattice retinal degeneration. A scanning electron microscopic study. *Ophthalmology*. 1986;93(2):237-46.
17. Burton TC. The influence of refractive error and lattice degeneration on the incidence of retinal detachment. *Trans Am Ophthalmol Soc* 1989;87(1):143-55.
18. Byer NE. Changes in and prognosis of lattice degeneration of the retina. *Trans Am Acad Ophthalmol Otolaryngol* 1974;78(1):114-25.
19. Greven CM. Retinal breaks. In: Yanoff M, Duker JS. *Ophthalmology* 2nd Ed. Mosby, Philadelphia, 2004: 978-81.
20. Skeie JM, Mahaian VB. Dissection of the human vitreous body elements for proteomic analysis. *J Vis Exp*. 2011;23(47):2455-64.
21. Sebag J. Age-related changes in human vitreous structure. *Graefes Arch Clin Exp Ophthalmol*. 1987;225(2):89-93.
22. Smiddy WE, Michels RG, Greene WR. Morphology, pathology, and surgery for idiopathic macular disorders. *Retina*. 1990;10(1):288-96.
23. Majcher CE, Gurwood AS. The role of the vitreous in retinal disease. *Review of Ophthalmology Retinal Supplement* 2012; 149(4): 6s-14s.
24. Bottós J, Elizalde J, Arevalo JF, et al. Vitreomacular traction syndrome. *J Ophthalmic Vis Res*. 2012;7(2):148-61.
25. Schubert H, Kincaid M, Green R, et al. Anatomy and physiology. In: Regillo C, Brown G, Flynn H. *Vitreoretinal disease: the essentials*. New York, Thieme, 1999: 3-25.
26. Snead DR, James S, Snead MP. Pathological changes in the vitreoretinal junction 1: epiretinal membrane formation. *Eye (Lond)*. 2008;22(10):1310-7.
27. Hagler WS, North AW. Retinal Dialyses and Retinal Detachment *Arch Ophthalmol*. 1968;79(4):376-388.
28. Hagler WS. Retinal dialysis: a statistical and genetic study to determine pathogenic factors. *Trans Am Ophthalmol Soc*. 1980;78(6):686-733.
29. Tanner V, Harle D, Tan J, et al. Original Article - Clinical science: Acute posterior vitreous detachment: the predictive value of vitreous pigment and symptomatology. *Br J Ophthalmol* 2000;84(11):1264-1268.
30. Wilkinson CP. Evidence-based analysis of prophylactic treatment of asymptomatic retinal breaks and lattice degeneration. *Ophthalmology*. 2000;107(1):12-5.
31. Coffee RE, Westfall AC, Davis GH, et al. Symptomatic posterior vitreous detachment and the incidence of delayed retinal breaks: case series and meta-analysis. *Am J Ophthalmol*. 2007;144(3):409-13.
32. Foos RY. Tears of the peripheral retina; pathogenesis, incidence and classification in autopsy eyes. *Mod Probl Ophthalmol*. 1975;15(1):68-81.
33. Spencer LM, Foos RY. Paravascular vitreoretinal attachments. Role in retinal tears. *Arch Ophthalmol*. 1970;84(5):557-64.
34. Davis MD. Natural history of retinal breaks without detachment. *Arch Ophthalmol*. 1974;92(3):183-94.
35. Framme C, Roider J, Brinkmann R, et al. Basic principles and clinical application of retinal laser therapy. *Klin Monbl Augenheilkd*. 2008;225(4):259-68.

Left your *Review of Optometry* magazine at the office? No problem!



Get *Review* sent to your desktop or mobile device!

Just simply go to www.revoptom.com and click on the digimag link to get your current issue.

CONGENITAL OPTIC DISC PIT

Signs and Symptoms

A congenital optic disc pit (CODP) appears as a small, hypopigmented, yellow or whitish, oval or round excavated defect, most often within the inferotemporal portion of the optic disc. However, as CODP is considered to be an atypical coloboma (in that it is not limited to just the inferior disc region), it can appear anywhere within the boundaries of the disc. CODP width may range from 150 to 1000 microns, with an average size of 500 microns (1/3 of a disc diameter) and depths reaching as much as 0.16mm.¹

CODP occur in one per 11,000 patients.¹ Typically, a CODP is seen unilaterally, but the presentation is bilateral in 10-15% of cases.^{1,2} A large percentage of discs with congenital optic pits also have cilioretinal arteries.³ Discs with congenital pits are larger than fellow eyes without pits in 85% of cases.^{2,3} There is no apparent predilection for sex. In that they are congenital, their discovery typically coincides with a patient's initial eye exam.⁴

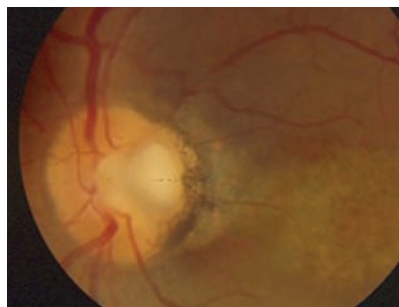
Most patients are unaware of the presence of a CODP. Although many optic pits demonstrate arcuate scotomas on threshold visual field testing corresponding to the loss of retinal ganglion cells in the area of the pit, acuity is rarely affected by the pit itself. Patients with CODP are at risk of developing serous maculopathy affecting visual acuity. Should this occur, patients will notice visual blur and metamorphopsia. Those with temporally located pits are at the greatest risk for developing serous maculopathy.⁵

Maculopathy compromises vision in 25-75% of patients, typically occurring between the ages of 30-40 years.^{1,5,6} CODP maculopathy appears as a serous macular detachment of the sensory retina.^{3,6-15} However, careful

observation aided by optical coherence tomography (OCT) has shown that the maculopathy caused by CODP is not limited to serous macular detachment, but also a retinoschisis-like splitting of the inner retinal layers.^{3,11,15-21}

Pathophysiology

The origin of CODP remains unclear. CODP have been associated with colobomatous lesions, implying that they result from incomplete closure of the fetal fissure. The optic nerve is comprised of retinal ganglion cells, neuroectodermal layers of the optic stalk and its associated mesoderm. Failed development of the lamina cribrosa and its associated structures contribute to pit development.²⁰ Arcuate visual field defects result secondary to the loss of the axons of the retinal ganglion cells, which correspond to the area of the pit or secondary atrophy of attenuated nerve fibers in the vicinity of the optic pit defect.



Optic disc pit with associated maculopathy.

While the CODP itself is an unchanging entity, concern is directed toward the potential for associated serous maculopathy that can develop in up to 75% of patients with this congenital condition. While ophthalmoscopically the maculopathy manifests as a non-undulating, serous macular detachment, the pathology appears to be either a secondary event or an epiphenomenon from the development of inner nuclear layer macular retinoschisis.^{15,17,18,21}

The origin of the serous submacular fluid is unknown, with hypotheses including cerebrospinal fluid from the subarachnoid space as well as liquefied vitreous from the vitreous cavity.^{16,22,23} It appears that an abnormal vitreoretinal interface inducing tangential tractional forces is the genesis behind the development of macular retinoschisis in CODP.^{16,19,24} Recently, optical coherence tomography (OCT) before and after vitreoretinal surgery for CODP maculopathy indicates that peripapillary vitreous traction with the passage of fluid into the retina through the pit is the cause of the schisis-like separation.²⁵ Other OCT reports have indicated that fluid from the optic pit can go directly to the subinternal limiting membrane space, ganglion cell layer, inner nuclear layer, outer nuclear layer, or the subretinal space, although the outer nuclear layer is most commonly affected.²⁶

Management

The management of asymptomatic CODP begins with threshold perimetry to document the existence of visual field loss. Photodocumentation is appropriate at this point.

Home acuity assessment and Amsler grid self-analysis should be used to monitor for the onset of maculopathy. Patients should be educated to the signs and symptoms of macular compromise (e.g., blurred vision, visual distortions and metamorphopsia) and instructed to return immediately should any occur.

The treatment for CODP-related maculopathy varies. Barrier thermal laser photocoagulation has been used in an attempt to halt the spread of subretinal fluid.^{8,10,14} However, most surgeons have abandoned thermal laser photocoagulation alone in favor of vitrectomy, either with or without adjunctive juxtapapillary barrier thermal laser photocoagulation.

There is no clear consensus on the management of CODP-related maculopathy. Due to the tangentially induced tractional forces by the posterior hyaloid causing foveal retinoschisis formation, pars plana vitrectomy with complete removal of all vitreoretinal adhesions is necessary for optimal treatment of macular detachment associated with optic pits.^{13,15,16,24} In several cases, serous maculopathy secondary to CODP resolved with spontaneous detachment of the posterior vitreous.²⁷ There are numerous reports on successful management with vitrectomy combined with retinal tamponade by either expansive gas or silicone oil.^{1,3,6,7,9,10,13-15,19,22-24,28-31}

Other studies have indicated the necessity of additionally peeling the internal limiting membrane (ILM) as part of the vitrectomy for optimal visual results.^{28,30-32} Another report, however, indicated ILM peeling is not necessary for good visual outcomes.³³ At this time, serous retinal detachment occurring from CODP will be surgically treated with a combination of vitrectomy, barrier juxtapapillary retinal laser photocoagulation, ILM peeling and expansive gas tamponade.³⁴ Visual and anatomical outcomes have been quite good, but can be slow. The restoration of the junction of the inner and outer photoreceptors is evident 6-12 months after surgery and is complete 24 months after fluid absorption. Improvement in vision is noticed only during the first two years of follow-up.³⁵

Clinical Pearls

- CODP may also appear in conjunction with other optic disc anomalies, including congenital coloboma and tilted disc syndrome.

- Any changing of the appearance of the optic pit over time indicates the possibility that the lesion is actually an acquired defect of the neuroretinal rim secondary to glaucoma.

- Due to the fact that the embryonic fetal fissure closes inferiorly last, typical colobomas occupy the inferior aspect of the disc. CODP are atypical colobomas in that they can occur anywhere on the disc.

- Temporally located CODP are ominous in that they are at most risk for maculopathy development.

1. Kranenburg EW. Craterlike holes in the optic disc and central serous retinopathy. *Arch Ophthalmol.* 1960; 64(12):912-24.
2. Jonas JB, Freisler KA. Bilateral congenital optic nerve head pits in monozygotic siblings. *Am J Ophthalmol.* 1997;124(6):844-6.
3. Kolar P. Maculopathy in case of the pit of the disc. *Cesk Slov Oftalmol.* 2005;61(5):330-6.
4. Johnson KL. Optic disc pit: primary diagnosis in a child. *Clin Exp Optom.* 2006;89(4):257-9.
5. Brown GC, Shields JA, Goldberg RE. Congenital pits of the optic nerve head, II: clinical studies in humans. *Ophthalmology.* 1980(1);87:51-65.
6. Chiu YT, Chen HY, Tsai YY, et al. Stratus optical coherence tomography for evaluating optic disc pits associated with maculopathy before and after vitrectomy: two case reports. *Kaohsiung J Med Sci.* 2006;22(5):229-34.
7. Fantaguzzi PM, Vasco A. Vitrectomy and silicone oil tamponade for serous macular detachment associated with an optic disk pit. *Eur J Ophthalmol.* 2006;16(2):330-4.
8. Rosa AA, Primiano HP Jr, Nakashima Y. Pneumatic retinoplexy and laser photocoagulation for treatment of optic disc pit detachment: case report. *Arq Bras Oftalmol.* 2006;69(1):101-5.
9. Hirakata A, Okada AA, Hida T. Long-term results of vitrectomy without laser treatment for macular detachment associated with an optic disc pit. *Ophthalmology.* 2005;112(8):1430-5.
10. Bakri SJ, Beer PM. Vitreoretinal surgery for optic pit associated serous macular detachment: a discussion of two cases. *Int Ophthalmol.* 2004;25(3):143-6.
11. Hassenstein A, Richard G. Optical coherence tomography in optic pit and associated maculopathy. *Ophthalmologie.* 2004;101(2):170-6.
12. Munteanu M, Munteanu G, Zolog I, et al. Colobomatous pits of the optic nerve papilla associated with serous retinal detachment. The clinical and pathogenic aspects. *Oftalmologia.* 2000;51(2):54-61.
13. Bartz-Schmidt KU, Heimann K, Esser P. Vitrectomy for macular detachment associated with optic nerve pits. *Int Ophthalmol.* 1995-96;19(6):323-9.
14. Montenegro M, Bonnet M. Optic nerve pits: clinical and therapeutic review of 21 cases. *J Fr Ophthalmol.* 1989;12(6-7):411-9.
15. Hirakata A, Hida T, Ogasawara A, et al. Multilayered retinoschisis associated with optic disc pit. *Jpn J Ophthalmol.* 2005;49(5):414-6.
16. Ishikawa K, Terasaki H, Mori M, et al. Optical coherence tomography before and after vitrectomy with internal limiting membrane removal in a child with optic disc pit maculopathy. *Jpn J Ophthalmol.* 2005;49(5):411-3.
17. Meirelles RL, Aggio FB, Costa RA, et al. STRATUS optical coherence tomography in unilateral colobomatous excavation of the optic disc and secondary retinoschisis. *Graefes Arch Clin Exp Ophthalmol.* 2005;243(1):76-81.
18. Morales Bertrand J, Teus Guezala MA, Perez Saldaña P, et al. Congenital optic nerve pit associated with foveolar retinoschisis. *Arch Soc Esp Oftalmol.* 2001;76(5):327-30.
19. Kalvodova B, Ricarova R, Kuthan P, et al. Vitrectomy in optic nerve disc pit with maculopathy. *Cesk Slov Oftalmol.* 1999;55(3):123-7.
20. Krivoy D, Gentile R, Liebmann JM, et al. Imaging congenital optic disc pits and associated maculopathy using optical coherence tomography. *Arch Ophthalmol.* 1996;114(2):165-70.
21. Lincoff H, Schiff W, Krivoy D, et al. Optical coherence tomography of optic disk pit maculopathy. *Am J Ophthalmol.* 1996;122(2):264-6.
22. Kuhn F, Kover F, Szabo I, et al. Intracranial migration of silicone oil from an eye with optic pit. *Graefes Arch Clin Exp Ophthalmol.* 2006 Mar 8; [Epub ahead of print]
23. Johnson TM, Johnson MW. Pathogenic implications of subretinal gas migration through pits and atypical colobomas of the optic nerve. *Arch Ophthalmol.* 2004;122(12):1793-800.
24. Gandorfer A, Kampik A. Role of vitreoretinal interface in the pathogenesis and therapy of macular disease associated with optic pits. *Ophthalmologie.* 2000;97(4):276-9.
25. Hirakata A, Inoue M, Hiraoka T, McCuen BW 2nd. Vitrectomy without laser treatment or gas tamponade for macular detachment associated with an optic disc pit. *Ophthalmology.* 2012;119(4):810-8.
26. Imamura Y, Zweifel SA, Fujiwara T, et al. High-resolution optical coherence tomography findings in optic pit maculopathy. *Retina.* 2010 Jul-Aug;30(7):1104-12.
27. Bonnet M. Serous macular detachment associated with optic nerve pits. *Graefes Arch Clin Exp Ophthalmol.* 1991; 229(6):526-32.
28. Rizzo S, Belting C, Genovesi-Ebert F, et al. Optic disc pit maculopathy: the value of small-gauge vitrectomy, peeling, laser treatment, and gas tamponade. *Eur J Ophthalmol.* 2012;22(4):620-5.
29. Georgalas I, Petrou P, Koutsandrea C, et al. Optic disc pit maculopathy treated with vitrectomy, internal limiting membrane peeling, and gas tamponade: a report of two cases. *Eur J Ophthalmol.* 2009;19(2):324-6.
30. Pichi F, Morara M, Veronesi C, et al. Double-vitrectomy for optic disc pit maculopathy. *Case Report Ophthalmol.* 2012;3(2):156-61.
31. Sandali O, Barale PO, Bui Quoc E, et al. Long-term results of the treatment of optic disc pit associated with serous macular detachment: a review of 20 cases. *J Fr Ophthalmol.* 2011;34(8):532-8.
32. Shukla D, Kalliath J, Tandon M, Vijayakumar B. Vitrectomy for optic disc pit with macular schisis and outer retinal dehiscence. *Retina.* 2012;32(7):1337-42.
33. Diab F, Al-Sabah K, Al-Mujaini A. Successful surgical management of optic disc pit maculopathy without internal membrane peeling. *Middle East Afr J Ophthalmol.* 2010;17(3):278-80.
34. Georgalas I, Ladas I, Georgopoulos G, Petrou P. Optic disc pit: a review. *Graefes Arch Clin Exp Ophthalmol.* 2011;249(8):1113-22.
35. Theodosiadis GP, Grigoropoulos VG, Liarakos VS, et al. Restoration of the photoreceptor layer and improvement of visual acuity in successfully treated optic disc pit maculopathy: a long follow-up study by optical coherence tomography. *Graefes Arch Clin Exp Ophthalmol.* 2012;250(7):971-9.

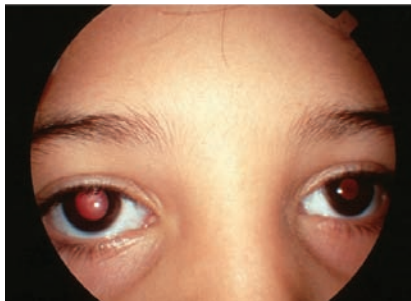
TONIC PUPIL

Signs and Symptoms

Tonic pupils (sometimes referred to as internal ophthalmoplegia) result from damage to the parasympathetic innervation to the eye, resulting in decreased function of the iris sphincter as well as the ciliary body.¹⁻¹⁰ A tonic pupil responds to both light and near stimuli with extremely slow constriction and re-dilation. Patients typically present with a chief complaint of unilaterally reduced near vision and anisocoria. When first noted by the patient in ambient light, the tonic pupil is often the larger of the two. However, if viewed in dim illumination, it may reverse and become the smaller pupil.^{1,2} Interestingly, the anisocoria may diminish as the tonic pupil becomes more miotic over time.^{1-3,5-7,9} The tonic pupil is typically unilateral (90%), but may become bilateral at a rate of 4% per year.^{1-3,7} The iris margin may be irregular and the pupil misshapen due to a sector paralysis of the iris.

Along with the pupil anomaly, parasympathetic damage may result in dysfunction of the ciliary body, causing accommodative spasm, accommodative insufficiency and induced astigmatism, generating complaints of blur at both distance and near.^{1,2} Accommodation, like pupillary responses, is tonic as the patient changes fixation from distance to near and back again. As a result, patients with tonic pupil often complain that vision transiently blurs (until the ciliary muscle catches up or relaxes) during attempts at focusing. Accommodative amplitude is also found to be reduced.^{1,2} Over time, the tonicity of both the accommodative and pupillary responses increase.

Tonic pupils can be found at any age and in both sexes; however, 70% are found in otherwise healthy females between the ages of 20 and 50.¹⁻⁷



Right pupil mydriasis in tonic pupil syndrome.

Pathophysiology

Afferent input to the parasympathetic pathway results in pupillary constriction (the direct light reaction). The pathway originates in the photoreceptors and retinal ganglion cells and travels via the optic nerve, chiasm and optic tract. Some fibers leave the tract prior to the lateral geniculate body via the superior colliculus and the brachium conjunctivum. These fibers synapse in the pretectum and are distributed bilaterally to the Edinger-Westphal nucleus adjacent to the oculomotor nerve in the dorsal mesencephalon.¹⁻⁷

Parasympathetic tone of the irides originates in this complex group of paired midline nuclei. The efferent fibers travel with the third cranial nerve, entering the orbit and synapsing in the ciliary ganglion.¹⁻⁷ Postsynaptic fibers leave the ganglion traveling as the short ciliary nerves, piercing the sclera to arrive at their end organ destinations, the iris and ciliary body.^{1,2}

The vast majority (93-97%) of these parasympathetic fibers go on to supply the ciliary body, resulting in the stimulation of accommodation. The remaining 3-7% of parasympathetic fibers innervate the pupillary sphincter, allowing constriction of the pupil in response to light.^{1,2,5-7} The hypothesized reason for this uneven distribution is the unequal masses of the ciliary muscle and the iris sphincter.^{1,2,5,6}

Interruption of the above pathway anywhere along its route can result in

incomplete parasympathetic innervation, causing pupillary dilation, decreased speed and amplitude of constriction and decreased speed and amplitude of accommodation. Since the input to the Edinger-Westphal nucleus is crossed and innervation of the pupillary sphincters is bilateral, the pupils are expected to be equal in size.⁵ Pupil size is determined by the interaction of the parasympathetic and the sympathetic nervous system. The parasympathetic system conducts the light reaction. The sympathetic nervous system acts either directly on the dilator muscle or by inhibiting the Edinger-Westphal nucleus.¹¹ Acquired anisocoria indicates a lesion in one of the efferent pathways or the iris muscle.

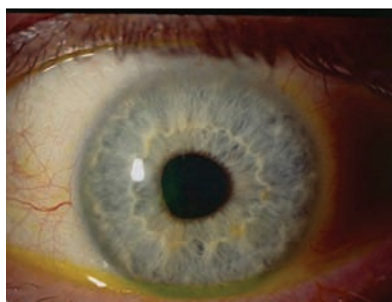Also playing a role in pupillary constriction are three synkinetic reactions: (1) the near reflex (miosis, accommodation and convergence), (2) Bell's phenomenon (levator inhibition, superior rectus activation and miosis) and (3) the Westphal-Piltz reaction (orbicularis contraction and miosis).^{2,3,5,7}

Following injury to the ciliary ganglion or the short ciliary nerves, clinical signs may be seen. These include light-near dissociation, tonicity of both the pupillary light reaction and accommodation, segmental palsy of the iris sphincter, and denervation hypersensitivity to dilute cholinergic agents.¹⁻¹⁰ In the 8-12 weeks following injury to the ciliary ganglion, surviving nerve cells sprout collaterals to re-innervate both the ciliary body and the pupil.^{1,2,4,6} Because of the unequal ratio of fibers originally favoring the ciliary muscle, this re-innervation results in a pupil that constricts more when accommodation is stimulated (a target held near) than to light and is termed a light-near dissociated pupil.¹⁻⁷ Unlike light-near dissociation, which takes weeks to months to develop, hypersensitivity can be observed in days to weeks.^{1,2,5,6}

In addition, the re-established connections are less efficient, further contributing to the latency and slow pupillary constriction.^{1,2} The tonic pupil also dilates poorly due to inappropriate tone secondary to aberrant reinnervation.^{5,6} The tonic characteristic of both constriction/redilation is also in part due to the decreased number of intact neuromuscular junctions following injury. Segmental palsy results from the fact that the sphincter is made up of 70-80 separate motor units, each served by a separate parasympathetic nerve fiber.⁸ Partial denervation will then result in partial or segmental constriction of the iris in response to both light and near stimuli.

Bilateral tonic pupils have been found in association with other dysfunctions of the autonomic nervous system including Ross syndrome (hyporeflexia, tonic pupil and progressive segmental anhidrosis), orthostatic hypotension, and Riley Day Syndrome (familial dysautonomia).^{1,2,12-15} There appear to be reports of Ross syndrome variants, including tonic pupil and anhidrosis with preservation of deep tendon reflexes as well as tonic pupil, hyporeflexia and segmental compensatory hyperhidrosis where hypohidrosis or anhidrosis is not even noticed.^{15,16}

William John Adie has long been credited with describing benign non-syphilitic tonic pupils (Adie's tonic pupil) and a syndrome involving tonic pupil and absent deep tendon reflexes (Adie's syndrome). However, Adie was not the first to describe the pupil abnormality and it is more appropriate to refer to tonic pupils simply as such and leave the Adie name to describe the syndrome.¹⁷ It is important to note that this benign pupil abnormality and syndrome are largely isolated and have no discernible cause. There are numerous etiologies that can result in a tonic pupil, either unilaterally or bilaterally. The discovery of a tonic pupil should



Sector paralysis in tonic pupil syndrome.

not be presumed to be benign.

It is well known that migraine can result in a tonic pupil.¹⁸⁻²³ The pathophysiology is not well understood, but this association may be caused by infarction of parasympathetic fibers secondary to prolonged vasospasm which sometimes occurs in migraine.

Damage to the ciliary nerves through surgery or laser photocoagulation can also cause tonic pupil to develop.²⁴ Infectious diseases such as herpes zoster, HIV, neurosyphilis and cytomegalovirus have been implicated as causes of tonic pupil.²⁵⁻²⁷ Obstructive hydrocephalus has been noted to cause tonic pupil.²⁸ Iris and ciliary body ischemia occurring from giant cell arteritis has also been implicated in tonic pupil development.²⁹ Various reports have also implicated sarcoidosis as a causative etiology.^{30,31} Blunt trauma to the globe may cause segmental iridoplegia, which can be mistaken for a tonic pupil.⁸ Thus, it is important to try to discern a cause when encountering a patient with a tonic pupil(s).

Management

The first step in proper diagnosis is determining if the anisocoria is benign and physiologic or acquired and pathologic. This is accomplished by comparing the amount of anisocoria in bright and then dim illumination. Pupils that possess physiological anisocoria will show a relative size difference that typically does not vary

from one illumination level to the next. However, in very bright illumination, the degree of anisocoria may become so imperceptible that the pupils may seem isocoric. Pupils suffering from sympathetic pathway lesions (i.e., Horner's syndrome) will possess anisocoria that is greater in dim illumination, due to failure of the iris dilator.^{1-5,9,10} There will also be a dilation lag in dim light, further separating this from physiologic anisocoria. Pupils suffering from parasympathetic pathway interruptions will demonstrate anisocoria that measures larger in bright light.^{1-5,9,10}

The second step is to measure the pupil's ability to react to light (both the direct and consensual response). The third step is to measure the amount of constriction accompanying an accommodative effort compared to the light response, checking for light-near dissociation. It is also helpful to know how long the anisocoria has been present, as a more acute onset is more likely to warrant evaluation. If the patient cannot delineate a time frame, inspection of old photographs may be helpful.

A tonic pupil can be diagnosed upon examination with the biomicroscope.⁸ With the slit beam opened wide and directed from a 60° angle, the details of the iris can be easily observed. When a tonic pupil is present, as the light source is turned on and off, sectors of the iris will be found paralyzed and not constricting to light. These fibers can be observed being dragged by neighboring functional segments.⁸ This phenomenon, referred to as "stromal streaming," is due to sectoral palsy of the sphincter muscle.^{1,2,4,6-9}

Thompson observed 122 patients with tonic pupil, noting that every pupil exhibited this sectoral paralysis.⁸ He also observed a tendency for sphincter function to decrease over time. The near reaction in tonic pupils is often segmental as well. Segments which are reactive during accommodation may

not be the same segments that react to light.⁸ The pupillary constriction that accompanies accommodation is slow and after the near effort is relaxed, redilation may take minutes to hours.²

Pharmacological testing aids tonic pupil diagnosis. In 80-90% of patients with tonic pupil, dilute pilocarpine (0.125%) will induce pupillary constriction after 30-45 minutes while normal pupils will not respond.^{1,2,5-7} To accurately test for hypersensitivity, the corneal epithelium must be intact. Any compromise to integrity may produce a false positive result. Alternatively, profuse tearing or blinking may dilute the already weak pilocarpine, resulting in false negative findings.¹⁻³ Observations of pupil diameter should be made while fixation is directed at distance to eliminate any contribution of the near synkinetic response.^{1,2}

If denervation hypersensitivity is present, one of two things will be observed: The involved pupil will constrict more than 0.5mm relative to the fellow eye, or the suspicious pupil, larger in size prior to the instillation of the drop, will become the smaller pupil following instillation.^{1,2} If the pupil fails to constrict to 0.125% pilocarpine, the next step is to instill a 1% pilocarpine solution. If the pupil also fails to constrict to 1% pilocarpine, the dilation is likely due to pharmacological mydriasis, traumatic iridoplegia, sphincter ischemia or iatrogenic damage from prior intraocular surgery.^{1,2,4-6,10}

No definitive treatment for the tonic pupil exists. Patients primarily seek relief from glare associated with mydriasis and cosmetic improvement related to anisocoria. In these cases, an opaque cosmetic contact lens may provide the solution. Visual complaints associated with ciliary body dysfunction occasionally respond to low concentrations of cholinergic drugs. In some cases, accommodative lag can be helped by a near addition.

Clinical Pearls

- Light-near dissociation, irregular pupil shape and miosis with dilute concentrations of pilocarpine are characteristic of tonic pupils.

- The light-near dissociation response may be difficult to observe. It is best to examine the suspect pupil biomicroscopically. In this manner, it is easier to see the stromal streaming and poor light response. While at the biomicroscope, direct the patient to look at an accommodative target with the fellow eye. You should see a brisk near response compared to a minimal light response.

- Most cases of isolated internal ophthalmoplegia (tonic pupil) are found to be idiopathic and referred to as Adie's tonic pupil, though it may be more appropriate to simply call them 'tonic pupils.'

- An idiopathic tonic pupil in concert with loss of deep tendon reflexes is termed Adie's syndrome.

- In the absence of other signs and symptoms, a tonic pupil is a benign finding. However, until other etiologies have been ruled out, it is inappropriate to refer to the tonic pupil as Adie's tonic pupil. This is actually a diagnosis of exclusion.

1. Slamovits TL, Glaser JS. The Pupils and Accommodation. In: Tasman W, Jaeger EA, eds. *Duane's Clinical Ophthalmology CD ROM*. Philadelphia: JB Lippincott;1998:1-24.
2. Slamovits TL, Glaser JS. The pupils and accommodation. In: Glaser JS, ed. *Neuro-Ophthalmology*. Philadelphia: JB Lippincott;1990:459-83.
3. Tantom LA. Pupil Anomalies. In: Onofrey BE, ed. *Clinical Optometric Pharmacology and Therapeutics*. Philadelphia: JB Lippincott, 1994:1-13.
4. Kardon RH. The Pupils. In: Yanoff M, Duker JS, eds. *Ophthalmology*. Philadelphia: Mosby International; 1999;(11)20.1-20.10.
5. Newman NM. The Pupil. In: Newman NM, ed. *Neuro-Ophthalmology, A Practical Text*. Norwalk, CT: Appleton and Lange;1992:239-252.
6. Kardon RH, Thompson HS. The Pupil. In: Rosen ES, Thompson HS, Cumming WJK, eds. *Neuro-Ophthalmology*. Philadelphia: Mosby International; 1998:13.1-13.19.
7. Burde RM, Savino PJ, Trobe JD. Anisocoria and Abnormal Pupillary Light Reactions. In: Burde RM, Savino PJ, Trobe JD, eds. *Clinical Decisions in Neuro-Ophthalmology*. Philadelphia: Mosby, 1992:321-46.9

8. Thompson HS. Segmental palsy of the iris sphincter in Adie's syndrome. *Arch Ophthalmol*. 1978;96(9):1615-20.
9. Thompson HS, Pilley SFJ. Unequal pupils: a flow chart for sorting out the anisocorias. *Surv Ophthalmol*. 1976; 21(1):45-8.
10. Lee AG, Taber KH, Hayman LA, et al. A guide to the isolated dilated pupil. *Arch Fam Med*. 1997; 6(4):385-8.
11. Wilhelm H. Disorders of the pupil. *Handb Clin Neurol*. 2011;102:427-66.
12. Wolfe GI, Galetta SL, Teener JW, et al. Site of autonomic dysfunction in a patient with Ross' syndrome and postganglionic Horner's syndrome. *Neurology*. 1995;45(11):2094-6.
13. Pérez-García P, Bernat-García J, Mateu-Puchades A. Ross syndrome in a 38-year-old male. *Dermatol Online J*. 2013;19(1):6.
14. Nolano M, Provitera V, Donadio V, et al. Ross syndrome: A lesson from a monozygotic twin pair. *Neurology*. 2013;80(4):417-8.
15. Yar S, Aslan C, Serdar ZA, et al. Ross syndrome: Unilateral hyperhidrosis, Adie's tonic pupils and diffuse areflexia. *J Dtsch Dermatol Ges*. 2010;8(12):1004-6.
16. Kalapesi FB, Krishnan AV, Kiernan MC. Segmental facial anhidrosis and tonic pupils with preserved deep tendon reflexes: a novel autonomic neuropathy. *J Neuroophthalmol*. 2005;25(1):5-8.
17. Kelly-Sell M, Liu GT. "Tonic" but not "Adie" pupils. *J Neuroophthalmol*. 2011;31(4):393-5.
18. Sobreira I, Sousa C, Raposo A, et al. Ophthalmoplegic migraine with persistent dilated pupil. *J Child Neurol*. 2013;28(2):275-6.
19. Tafakhori A, Aghamolai V, Modabbernia A, Pourmahmoodian H. Adie's pupil during migraine attack: case report and review of literature. *Acta Neurol Belg*. 2011;111(1):66-8.
20. Millar E, Habib M, Gnanaraj L. Bilateral tonic pupil secondary to migraine in a child. *J Pediatr Ophthalmol Strabismus*. 2010;47 Online:e1-2.
21. Barriga FJ, López de Silanes C, Gili P, Pareja JA. Ciliary ganglioplegic migraine: migraine-related prolonged mydriasis. *Cephalalgia*. 2011;31(3):291-5.
22. Iannetti P, Spallice A, Iannetti L, et al. Residual and persistent Adie's pupil after pediatric ophthalmoplegic migraine. *Pediatr Neurol*. 2009;41(3):204-6.
23. Drouet A, De Carvalho A, Mage F, et al. Adie's tonic pupil and migraine: a chance association? *J Fr Ophtalmol*. 2008;31(2):e5.
24. Ebrahim B, Frohman L, Zarbin M, Bhagat N. Tonic pupil following pars plana vitrectomy and endolaser. *Case Report Med*. 2009;2009:970502. Epub 2009 Jul 8.
25. Nagane Y, Utsugisawa K. Ross syndrome associated with cytomegalovirus infection. *Muscle Nerve*. 2008;38(1):924-6.
26. Cerny R, Rozsypal H, Kozner P, Machala L. Bilateral Holmes-Adie syndrome as an early manifestation of the HIV neuropathy. *Neurol Sci*. 2010;5(5):661-3.
27. Camoriano GD, Kassab J, Suchak A, Gimbel HV. Neurosyphilis masquerading as an acute adie's tonic pupil: report of a case. *Case Report Ophthalmol*. 2011;2(2):205-10.
28. Han SW, Ryu JH, Baik JS, et al. Early dorsal mid-brain syndrome mimicking an Adie's tonic pupil. *J Clin Neurol*. 2010;6(1):38-40.
29. Prasad S, Baccon J, Galetta SL. Mydriatic pupil in giant cell arteritis. *J Neurol Sci*. 2009;15;284(1-2):196-7.
30. Koczman JJ, Rouleau J, Gaunt M, et al. Neuro-ophthalmic sarcoidosis: the University of Iowa experi-

ence. *Semin Ophthalmol.* 2008;23(3):157-68.
31. Lamirel C, Badelon I, Gout O, et al. Neuro-ophthalmologic initial presentation of sarcoidosis. *J Fr Ophthalmol.* 2006;29(3):241-9.

OPTIC DISC DRUSEN

Signs and Symptoms

Optic disc drusen (ODD) represent a condition involving retained hyaline bodies (products of degenerated retinal ganglion cell axoplasmic transport, also known colloid bodies) in the anterior, prelaminar portion of the optic nerve.

ODD and the clinical presentation they create have been referred to in the literature by many diverse and confusing names, including congenitally elevated or anomalous discs, pseudopapilledema, pseudoneuritis, buried disc drusen and disc hyaline bodies.¹⁻⁷ ODD are relatively uncommon, occurring in less than 2% of the general population.¹ As an entity, it has also been described as occurring exclusively in Caucasians; however, these authors have occasionally encountered ODD in patients of color.²

Typically, patients with ODD present and remain without symptoms, with the finding disclosed only upon routine ocular evaluation. In some instances, the condition can present with mildly decreased visual acuity and visual field defects.²⁻⁵ An afferent pupillary defect may be noted if the condition is both significant and unilateral or asymmetric.² Reports of recurrent, transient visual obscurations associated with disc drusen have also been documented.^{6,7}

The classic appearance of ODD involves unilateral or bilaterally elevated optic discs with irregular or "scalloped" margins, a small or nonexistent cup and unusual vascular branching patterns (i.e., marked bifurcations and trifurcations) that arise from a central vessel core. Often there are small, refractile hyaline deposits visible on the surface of the disc and/or in the per-

papillary area. ODD most often manifests on the nasal disc margin, but can be found within any part of the nerve head. In younger patients, the disc elevation tends to be more pronounced and the drusen less calcified and discrete, making them less visible ophthalmoscopically and hence offering a more challenging diagnostic dilemma. Unlike true disc edema, ODD does not present with juxtapapillary nerve fiber edema, exudates or cotton-wool spots.

One report on 100 eyes with ODD noted the following ophthalmoscopic features: visible drusen (52%), blurred edges (84%), raised optic disc (74%), absence of optic disc cupping (69%), absence of venous pulse (54%), abnormal vascular branching (81%), presence of cilioretinal vessels (42%), peripapillary atrophy (56%) and hemorrhages (2%).⁸

Pathophysiology

ODD are bilateral in 70-80% of cases. They have been purported to demonstrate an autosomal dominant inheritance pattern with incomplete penetrance.^{2,9,10} Clinicians should realize that there is no histopathological correlation between drusen of the optic nerve head and retinal drusen; the former represent acellular laminated concretions, often partially calcified, possibly related to accumulation of axoplasmic derivatives of degenerating retinal nerve fibers.

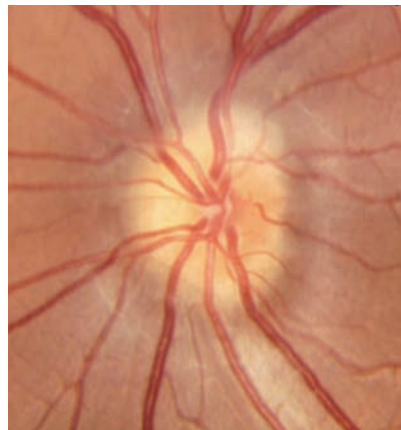
ODD are "buried" in children, but slowly become visible as they enlarge toward the disc surface and as the overlying retinal nerve fiber layer progressively thins.^{10,11} They are usually ophthalmoscopically detectable by the early to mid-teens, although these authors have seen patients in their mid-twenties who continue to display "buried drusen." Within the optic nerve, the hyaline bodies are confined anterior to the lamina cribrosa and thus can compress and compromise

the nerve fibers and vascular supply, leading to visual field defects and disc hemorrhages.^{2,4,7,12,13}

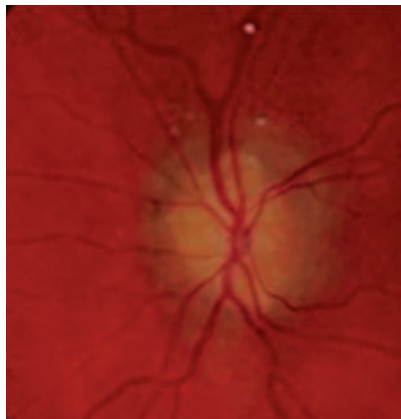
Along with slowly developing optic atrophy in extreme cases and possible venous occlusion, disruption of the juxtapapillary tissue can result in choroidal neovascular membrane formation, leading to subretinal hemorrhage with its attendant complications.¹⁴⁻¹⁷

Management

While ODD is typically considered a benign condition, it can lead to modest visual compromise and in rare instances, devastating vision loss.¹⁸⁻²⁰ First and foremost, ODD must be clearly differentiated from acquired disc edema, a situation that warrants



Buried optic disc drusen.



Exposed surface optic disc drusen.

prompt neurologic investigation and treatment. This is facilitated by careful evaluation of optic nerve, observing for a spontaneous venous pulse and the absence of vascular obscuration by an edematous nerve fiber layer. Nerve function must likewise be assessed, with particular attention to visual acuity assessment, contrast sensitivity, color vision testing, brightness testing and threshold perimetry.

While visual fields are an important method of documenting and monitoring optic nerve compromise secondary to ODD, they are neither uniform nor diagnostic. The more common patterns encountered include nasal step defects, enlargement of the physiologic blind spot, arcuate scotomas, sectoral field loss, and altitudinal defects.^{4,5,9-11} Photodocumentation should be obtained for future monitoring. Uncomplicated cases should be monitored every six to 12 months.

In indeterminate or ambiguous cases, the diagnosis of ODD may be aided by the use of several ancillary procedures. These include: (1) red-free ophthalmoscopic evaluation, which reveals autofluorescence of visible hyaline bodies; (2) confocal scanning laser ophthalmoscopy, which can demonstrate focal elevations and associated, focal nerve fiber thinning, (3) computed tomography of the orbits, which can identify calcified drusen within the optic nerves, and (4) ocular ultrasound testing.^{21,22} Ultrasonography is one of the most productive and least invasive in-office procedures that can be used to identify ODD. The high reflectivity of the calcified hyaline bodies is dramatically evident on B-scan testing, even with deeply buried drusen.^{21,23}

Monochromatic fundus photography also assists in the differentiation of ODD from optic disc edema with good sensitivity and very high specificity. The best results are obtained when using autofluorescence and red filters.²⁴

Optical coherence tomography (OCT) can be used to differentiate ODD from optic disc edema.²⁵⁻²⁸ Both ODD and optic disc edema will show an elevated optic disc with a hyporeflective area beneath the elevated topography of the disc. In cases of optic disc edema, there will be a smooth inner contour of this hyporeflective area within the disc. In contrast, there will be irregularity of the internal contour in ODD, demonstrating a 'lumpy-bumpy' appearance. Additionally, there is a hyporeflective space located between the sensory retina and the retinal pigment epithelium and choriocapillaris complex in cases of optic disc edema. This hyporeflective subretinal space will extend beyond the edge of the optic disc and have what is termed a recumbent 'lazy V' pattern. In contrast, there is very little hyporeflective space beyond the edge of the optic disc in ODD. Finally, nasal retinal nerve fiber layer thickness greater than 86 microns is more diagnostic of optic disc edema than ODD.

Qualitative criteria for optic disc edema include an elevated optic nerve head with smooth internal contour and subretinal hyporeflective space extending beyond the edge of the disc. Optic nerve head drusen displays a 'lumpy-bumpy' internal optic nerve contour and a rapid decline in subretinal hyporeflective space beyond the edge of the optic disc.²⁶

While many patients with ODD remain asymptomatic throughout life, all individuals with this diagnosis should continue to periodically self-monitor their vision. Although the condition is typically very slow to advance, there is a risk of progressive vision loss or visual field loss over time. Also, abrupt visual changes can be associated with choroidal neovascular membrane formation and/or subretinal hemorrhage. In cases where neovascularization is noted or

suspected, fluorescein angiography is typically employed to assess the location and size of the subretinal net, and determine if the neovascularization is classic (well defined) or occult (poorly defined). Treatment for choroidal neovascularization associated with ODD includes a variety of techniques, such as focal laser photocoagulation, photodynamic therapy and treatment with intravitreal injection of anti-VEGF medications.^{16,29-32}

It has been reported that eyes with ODD and concurrent ocular hypertension are at greater risk of visual field loss. However, it is unknown if lowering IOP in these cases reduces the risk of progression of visual field loss. Should any eye with significant ODD develop elevated intraocular pressure (IOP), then prophylactic pressure reduction should be strongly considered and perhaps offered to the patient. In the absence of elevated IOP, there is no evidence that IOP reduction will have any effects on preventing visual morbidity.¹⁸

Clinical Pearls

- It has been suggested that the vast majority of congenitally anomalous, elevated optic discs are likely associated with ODD. Often, younger patients who are diagnosed in this capacity will be found to have disc drusen later in life.

- It is important to recognize the clinical features associated with ODD in comparison to those features indicative of true optic disc edema. In ODD, one can expect a typically "normal" pink to pinkish-yellow color, rather than a pale waxy disc or a hyperemic disc. In addition, a spontaneous venous pulsation is present in about 80% of patients with ODD, but is absent in cases of true disc edema. Most importantly, while the disc margins may be irregular in ODD, rarely are they blurred or obscured.

• B-scan ultrasonography and OCT analysis are probably the most important ancillary tests to perform when evaluating suspected ODD. It is recommended that these procedures be conducted on all adult patients presenting with elevated optic discs that are not definitively identifiable as ODD based upon ophthalmoscopic observation. Keep in mind, however, that optic disc drusen are generally not calcified in children and adolescents; hence, ultrasonography may prove to be of little help in diagnosis.

- Friedman AH, Gartner S, Modi SS. Drusen of the optic disc: a retrospective study in cadaver eyes. *Br J Ophthalmol*. 1975;59(8):413-21.
- Rosenberg MA, Savino PJ, Glaser JS. A clinical analysis of pseudopapilledema: I, population, laterality, acuity, refractive error, ophthalmoscopic characteristics, and coincident disease. *Arch Ophthalmol*. 1979; 97(1):65-70.
- Savino PJ, Glaser JS, Rosenberg MA. A clinical analysis of pseudopapilledema: II, visual field defects. *Arch Ophthalmol*. 1979;97(1):71-5.
- Katz BJ, Pomeranz HD. Visual field defects and retinal nerve fiber layer defects in eyes with buried optic nerve drusen. *Am J Ophthalmol*. 2006;141(2):248-53.
- Lee AG, Zimmerman MB. The rate of visual field loss in optic nerve head drusen. *Am J Ophthalmol*. 2005; 139(6):1062-6.
- Sarkies NJ, Sanders MD. Optic disc drusen and episodic visual loss. *Br J Ophthalmol*. 1987;71(7):537-9.
- Purvin V, King R, Kawasaki A, Yee R. Anterior ischemic optic neuropathy in eyes with optic disc drusen. *Arch Ophthalmol*. 2004;122(1):48-53.
- Flores-Rodríguez P, Gili P, Martín-Ríos MD. Ophthalmic features of optic disc drusen. *Ophthalmologica*. 2012;228(1):59-66.
- Mustonen E. Pseudopapilloedema with and without verified optic disc drusen. A clinical analysis I. *Acta Ophthalmol (Copenh)* 1983; 61(6):1037-56.
- Auw-Haendrich C, Staubach F, Witschel H. Optic disc drusen. *Surv Ophthalmol*. 2002;47(6):515-32.
- Spencer TS, Katz BJ, Weber SW, Digre KB. Progression from anomalous optic discs to visible optic disc drusen. *J Neuroophthalmol*. 2004;24(4):297-8.
- Wilkins JM, Pomeranz HD. Visual manifestations of visible and buried optic disc drusen. *J Neuroophthalmol*. 2004; 24(2):125-9.
- Giuffrè G. Optic disc drusen in tilted disc. *Eur J Ophthalmol* 2005;15(5):647-51.
- Brown SM, Del Monte MA. Choroidal neovascular membrane associated with optic nerve head drusen in a child. *Am J Ophthalmol*. 1996;121(2):215-7.
- Diduszyn JM, Quillen DA, Cantore WA, Gardner TW. Optic disc drusen, peripapillary choroidal neovascularization, and POEMS syndrome. *Am J Ophthalmol*. 2002;133(2):275-6.
- Mateo C, Moreno JG, Lechuga M, et al. Surgical removal of peripapillary choroidal neovascularization

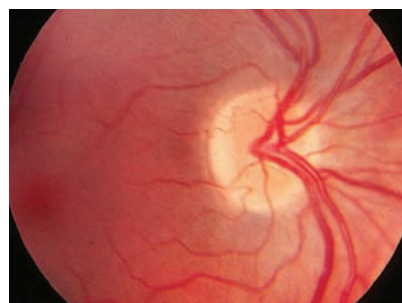
associated with optic nerve drusen. *Retina* 2004; 24(5):739-45.

- Romero J, Sowka J, Shechtman D. Hemorrhagic complications of optic disc drusen and available treatment options. *Optometry*. 2008;79(9):496-500.
- Grippo TM, Shihadeh WA, Schargus M, et al. Optic nerve head drusen and visual field loss in normotensive and hypertensive eyes. *J Glaucoma*. 2008;17(2):100-4.
- Gili Manzanaro P, Yangüela Rodilla J, Rodríguez Caravaca G, et al. Decreased visual acuity from optic disc drusen. *Arch Soc Esp Ophthalmol*. 2010;85(2):64-9.
- Morris RW, Ellerbrock JM, Hamp AM, et al. Advanced visual field loss secondary to optic nerve head drusen: case report and literature review. *Optometry*. 2009;80(2):83-100.
- Davis PL, Jay WM. Optic nerve head drusen. *Semin Ophthalmol* 2003; 18(4):222-42.
- Kuchenbecker J, Wecke T, Vorwerk CT, Behrens-Baumann W. Quantitative and objective topometrical analysis of drusen of the optic nerve head with the Heidelberg retina tomography. (German) *Ophthalmologe*. 2002;99(10):768-73.
- McNicholas MM, Power WJ, Griffin JF. Sonography in optic disc drusen: imaging findings and role in diagnosis when funduscopic findings are normal. *AJR Am J Roentgenol*. 1994;162(1):161-3.
- Gili P, Flores-Rodríguez P, Yangüela J, et al. Sensitivity and specificity of monochromatic photography of the ocular fundus in differentiating optic nerve head drusen and optic disc oedema. *Optic disc drusen and oedema*. *Graefes Arch Clin Exp Ophthalmol*. 2012. [Epub ahead of print]
- Sarac O, Tasci YY, Gurdal C, Can I. Differentiation of optic disc edema from optic nerve head drusen with spectral-domain optical coherence tomography. *J Neuroophthalmol*. 2012;32(3):207-11.
- Johnson LN, Diehl ML, Hamm CW, et al. Differentiating optic disc edema from optic nerve head drusen on optical coherence tomography. *Arch Ophthalmol*. 2009;127(1):45-9.
- Lee KM, Woo SJ, Hwang JM. Differentiation of optic nerve head drusen and optic disc edema with spectral-domain optical coherence tomography. *Ophthalmology*. 2011;118(5):971-7.
- Flores-Rodríguez P, Gili P, Martín-Ríos MD. Sensitivity and specificity of time-domain and spectral-domain optical coherence tomography in differentiating optic nerve head drusen and optic disc oedema. *Ophthalmic Physiol Opt*. 2012;32(3):213-21.
- Delyfer MN, Rougier MB, Fourmaux E, et al. Laser photocoagulation for choroidal neovascular membrane associated with optic disc drusen. *Acta Ophthalmol Scand* 2004;82(2):236-8.
- Chaudhry NA, Lavaque AJ, Shah A, Liggitt PE. Photodynamic therapy for choroidal neovascular membrane secondary to optic nerve drusen. *Ophthalmic Surg Lasers Imaging*. 2005;36(1):70-2.
- Knape RM, Zavaleta EM, Clark CL 3rd, et al. Intravitreal bevacizumab treatment of bilateral peripapillary choroidal neovascularization from optic nerve head drusen. *J AAPOS*. 2011;15(1):87-90.
- Gregory-Evans K, Rai P, Patterson J. Successful Treatment of Subretinal Neovascularization with Intravitreal Ranibizumab in a Child with Optic Nerve Head Drusen. *J Pediatr Ophthalmol Strabismus*. 2009. Epub 2009 Aug 21.

OPTIC NERVE HEAD HYPOPLASIA

Signs and Symptoms

As optic nerve head (ONH) hypoplasia is congenital in nature, it is typically diagnosed in younger patients at the time of their initial eye examination, though the condition in mild form may escape detection until adulthood. Patients present with variable symptoms, depending upon the severity and laterality of the condition. Visual acuity may range from normal to no light perception in the affected eye.¹⁻³



Hypoplastic optic disc with characteristic double ring sign.

Other dysfunctions of the afferent system, such as diminished color vision, red desaturation and brightness perception, may also be variably present. Nystagmus, amblyopia and strabismus (with esotropia being more prevalent) are encountered in a high percentage when patients are visually impaired.^{3,4} Visual field defects may also be elicited, but vary considerably. Inferior visual field loss has commonly been documented.⁵⁻⁹

There appears to be no gender predilection.³ ONH hypoplasia is typically bilateral, but may be asymmetric or unilateral in some cases.^{3,6,7,10,11} Myopic refractive error, which may be high, is very common.² Examination reveals the optic nerve in the affected eye(s) to be smaller than expected, with the vasculature appearing very large relative to the disc.^{12,13} If the case is

unilateral, there is a notable size difference in the affected nerve head when compared to the fellow eye. The affected optic disc is frequently encircled by a yellow-white peripapillary halo, bordered by a dark pigmented ring.² This circumpapillary ring of scleral tissue creates what is termed “double-ring sign.” The normally bright reflex from the nerve fiber layer is characteristically diminished.

Commonly found in association with ONH hypoplasia is a history of maternal diabetes.^{7-9,14} Optic nerve head hypoplasia can also be found as part of fetal alcohol syndrome and a history of maternal drug or alcohol use during pregnancy.¹⁵⁻¹⁸ Endocrine abnormalities commonly manifest as growth hormone deficiency with small stature, and panhypopituitarism.¹¹ There may also be concomitant renal maldevelopment and subsequent renal disease, which is termed papillorenal syndrome.¹⁹

There exists a variant of ONH hypoplasia termed superior segmental optic hypoplasia (SSOH).²⁰⁻²⁵ In this variant, optic nerve hypoplasia is sectorial rather than total and involving only the superior aspect of the optic disc with corresponding inferior visual field loss. Due to this superior hypoplasia, the condition has been referred to as the ‘topless disc syndrome’ and has been mistaken for optic atrophy and normal tension glaucoma.

Pathophysiology

ONH hypoplasia is one of the most common of the congenital optic nerve abnormalities.^{1,2} ONH hypoplasia is characterized by a lower number of optic nerve axons.

The exact mechanism responsible for ONH hypoplasia is not completely understood, but the condition is believed to represent a dysplasia of the retinal ganglion cell layer with an associated loss of the nerve fiber

layer, secondary to some interruption in the development of the fetus.² Consequently, underdevelopment of the optic nerve ensues with the posterior scleral foramen “filling in” with connective and scleral tissues. This all seems to result from defective closure of the embryonic fetal fissure.

Many disorders have been implicated in this disorder, including gestational diabetes, maternal infection by cytomegalovirus, syphilis and rubella, fetal alcohol syndrome and other drug use by the mother while pregnant as well as young maternal age.³

Approximately 50% of patients with ONH hypoplasia have associated systemic abnormalities.² ONH hypoplasia may be part of a larger clinical syndrome historically known as septo-optic dysplasia, which is associated with concurrent hypopituitarism and an absence of the septum pellucidum and corpus callosum. This is marked by shortness of stature, congenital nystagmus, and a hypoplastic disc.

ONH hypoplasia and hypopituitarism historically has been termed de Morsier’s syndrome.^{2,3,11} However, recent evidence suggests that ONH hypoplasia, hypopituitarism and other endocrine abnormalities are independent of septum pellucidum development. Further, it appears that Georges de Morsier never described a case of ONH hypoplasia or recognized its association with hypopituitarism or missing septum pellucidum. In fact these associations should be attributed to William Hoyt.^{26,27} Thus, “Septo-optic dysplasia” and “de Morsier’s syndrome” are historically inaccurate and clinically misleading terms.

Management

ONH hypoplasia is a congenital condition that does not change over time. Appropriate management begins with proper diagnosis, which may be made by appearance alone in some

cases. If there are questions as to the exact nature of the disc appearance, visual field testing, scanning laser tomography, optical coherence tomography (OCT) and MRI may help confirm the diagnosis.

It has been shown that there is pronounced thinning of the retinal nerve fiber layer and disc abnormalities in ONH hypoplasia, which is easily demonstrated by scanning laser tomography and OCT.^{20-22,24,28} In addition, many clinicians will photograph the posterior pole of the affected eye and measure the disc-macula/disc-disc (DM/DD) ratio; this compares the horizontal diameter of the nerve head to the distance between the fovea and the center of the nerve. In the normal eye, the DM/DD measures between 2:1 and 3.2:1. Ratios greater than this are very indicative of hypoplasia.¹³ The presence of circumpapillary scleral crescent or “double ring sign” is highly diagnostic.

In adult patients who have impaired vision in the affected eye, management includes patient education and the prescribing of protective eyewear. If the history or examination is indicative of any associated systemic manifestations, the patient should be referred for studies, including MRI, to rule out neurodevelopmental and endocrine disease. Upon diagnosis in a child, such evaluation should be strongly considered due to the high prevalence of associated systemic abnormalities.

Patients with unilateral and bilateral optic nerve hypoplasia frequently have concomitant neurologic, endocrine and systemic abnormalities needing evaluation by pediatric specialists in neurology and endocrinology.^{29,30} In more profound cases in which both eyes are affected, visual rehabilitation services should be recommended to improve functional abilities.

Most visual debilitation in ONH hypoplasia stems from a congenital

absence of optic nerve axons and dysplasia of the retinal ganglion cell layer. Any structural abnormality of the optic nerve that reduces visual ability and acuity in infancy can lead to developmental vision loss beyond that which can be explained solely by the hypoplasia.

It has been reported that these patients have a degree of "amblyopia" superimposed upon the visual deficits imparted by ONH hypoplasia.² However, in this setting, "amblyopia" is not an appropriate term. Amblyopia is defined as vision loss in the absence of organic causes.

Despite the misuse of the term "amblyopia," there may be some visual benefit to occlusion therapy and other visual system managements for improving the development of vision. These programs should be attempted as early as possible. However, in that there are anatomical limitations, the success of therapy should be assessed quickly and continuation of therapy should be based upon the clinical response. Electrophysiologic testing can give insight into visual prognosis. Visual evoked potential (VEP) and pattern electroretinogram (PERG) are useful in identifying future visual prognosis in infants with ONH hypoplasia.³¹

In cases with concurrent or resultant strabismus, surgery can enhance the patient's quality of life, though visual improvement may be minimal. Patients with vision loss and strabismus secondary to ONH hypoplasia may achieve some limited visual improvement from therapy, but not as much as would be expected in patients without this underlying condition. Prolonged therapy in the absence of clinical improvement is inappropriate.

Clinical Pearls

- It is essential that the clinician clearly distinguish vision loss secondary to ONH hypoplasia from pure

amblyopia. Although both amblyopia and ONH hypoplasia can present with reduced acuity, strabismus and significant refractive error, the former remains a diagnosis of exclusion. In cases of ONH hypoplasia, the associated refractive and/or binocular findings are secondary findings rather than primary causes of the problem.

- If a child with ONH hypoplasia undergoing visual therapy shows no initial improvement within three months, therapy should be discontinued. Longer duration of therapy in these patients will not be met with late success.

- The ring of scleral tissue surrounding a hypoplastic disc can be misleading and difficult to identify. In some cases it can be misdiagnosed as optic atrophy in a normally sized nerve. Always look for centrally located "normal" colored disc tissue as well as subtle topographic changes that mark the delineation of disc tissue from scleral tissue.

- Dutton GN. Congenital disorders of the optic nerve: excavations and hypoplasia. *Eye*. 2004;18(11):1038-48.
- Kim MR, Park SE, Oh SY. Clinical feature analysis of congenital optic nerve abnormalities. *Jpn J Ophthalmol*. 2006;50(3):250-5.
- Hellstrom A, Wiklund LM, Svensson E. The clinical and morphologic spectrum of optic nerve hypoplasia. *J AAPOS*. 1999;3(4):212-20.
- Lempert P. Optic nerve hypoplasia and small eyes in presumed amblyopia. *J AAPOS*. 2000;4(5):258-66.
- Unoki K, Ohba N, Hoyt WF. Optical coherence tomography of superior segmental optic hypoplasia. *Br J Ophthalmol*. 2002;86(8):910-4.
- Purvin VA. Superior segmental optic nerve hypoplasia. *J Neuroophthalmol*. 2002;22(2):116-7.
- Hashimoto M, Ohtsuka K, Nakagawa T, et al. Topless optic disk syndrome without maternal diabetes mellitus. *Am J Ophthalmol*. 1999;128(1):111-2.
- Landau K, Bajka JD, Kirchsclager BM. Topless optic disks in children of mothers with type I diabetes mellitus. *Am J Ophthalmol*. 1998;125(5):605-11.
- Petersen RA, Walton DS. Optic nerve hypoplasia with good visual acuity and visual field defects: a study of children of diabetic mothers. *Arch Ophthalmol*. 1977;95(2):254-8.
- Weiss AH, Kelly JP. Acuity, ophthalmoscopy, and visually evoked potentials in the prediction of visual outcome in infants with bilateral optic nerve hypoplasia. *J AAPOS*. 2003;7(2):108-15.
- Siatkowski RM, Sanchez JC, Andrade R, et al. The clinical, neuroradiographic, and endocrinologic profile of patients with bilateral optic nerve hypoplasia. *Ophthalmology*. 1997;104(3):493-6.
- Hellstrom A, Wiklund LM, Svensson E. Diagnostic value of magnetic resonance imaging and planimetric measurement of optic disc size in confirming optic nerve hypoplasia. *J AAPOS*. 1999;3(2):104-8.
- Barr DB, Weir CR, Purdie AT. An appraisal of the disc-macula distance to disc diameter ratio in the assessment of optic disc size. *Ophthalmic Physiol Opt*. 1999;19(5):365-75.
- Nelson M, Lessell S, Sadun AA. Optic nerve hypoplasia and maternal diabetes mellitus. *Arch Neurol*. 1986;43(1):20-5.
- Pinazo-Duran MD, Renau-Piqueras J, Guerri C, et al. Optic nerve hypoplasia in fetal alcohol syndrome: an update. *Eur J Ophthalmol*. 1997;7(3):262-70.
- Stromland K, Pinazo-Duran MD. Optic nerve hypoplasia: comparative effects in children and rats exposed to alcohol during pregnancy. *Teratology*. 1994;50(2):100-11.
- Stromland K. Ocular abnormalities in the fetal alcohol syndrome. *Acta Ophthalmol Suppl*. 1985;171:1-50.
- Stromland K. Alcohol during pregnancy damages eye and vision development. *Nord Med*. 1992;107(12):313-5.
- Khan AO, Nowlaty SR. Early diagnosis of the papillorenal syndrome by optic disc morphology. *J Neuroophthalmol*. 2005; 25(3):209-11.
- Fuse N, Aizawa N, Yokoyama Y, et al. Analysis of retinal nerve fiber layer thickness in superior segmental optic hypoplasia (SSOH). *Nihon Ganka Gakkai Zasshi*. 2012;116(6):575-80.
- Lee HJ, Kee C. Optical coherence tomography and Heidelberg retina tomography for superior segmental optic hypoplasia. *Br J Ophthalmol*. 2009;93(11):1468-73.
- Hayashi K, Tomidokoro A, Konno S, et al. Evaluation of optic nerve head configurations of superior segmental optic hypoplasia by spectral-domain optical coherence tomography. *Br J Ophthalmol*. 2010;94(6):768-72.
- Yamada M, Ohkubo S, Higashide T, et al. Differentiation by imaging of superior segmental optic hypoplasia and normal-tension glaucoma with inferior visual field defects only. *Jpn J Ophthalmol*. 2013;57(1):25-33.
- Miki A, Shirakashi M, Yaeoda K, et al. Optic nerve head analysis of superior segmental optic hypoplasia using Heidelberg retina tomography. *Clin Ophthalmol*. 2010;4:1193-9.
- Sowka J, Vollmer L, Reynolds S. Superior segmental optic nerve hypoplasia: The topless disc syndrome. *Optometry*. 2008;79(10):576-80.
- Garcia-Filion P, Borchert M. Optic nerve hypoplasia syndrome: A review of the epidemiology and clinical associations. *Curr Treat Options Neurol*. 2012 Dec 13. [Epub ahead of print].
- Borchert M. Reappraisal of the optic nerve hypoplasia syndrome. *J Neuroophthalmol*. 2012;32(1):58-67.
- Pang Y, Frantz KA. Value of the Heidelberg Retinal Tomograph in optic nerve hypoplasia. *Optom Vis Sci*. 2008;85(7):508-11.
- Fink C, Vedin AM, Garcia-Filion P, et al. Newborn thyroid-stimulating hormone in children with optic nerve hypoplasia: associations with hypothyroidism and vision. *J AAPOS*. 2012;16(5):418-23.
- Garcia ML, Ty EB, Taban M, et al. Systemic and ocular findings in 100 patients with optic nerve hypoplasia. *J Child Neurol*. 2006;21(11):949-56.
- McCulloch DL, Garcia-Filion P, Fink C, et al. Clinical electrophysiology and visual outcome in optic nerve hypoplasia. *Br J Ophthalmol*. 2010;94(8):1017-23.



JOBSON HEALTHCARE LLC
PRESENTS

THE RICK BAY FOUNDATION

for Excellence in Eyecare Education

www.rickbayfoundation.org



About Rick

Rick Bay served as the publisher of *The Review* Group since 1991.

To those who worked for him, he was a leader whose essence was based in a fierce and boundless loyalty.




To those in the industry and the professions he served, he will be remembered for his unique array of skills and for his dedication to exceeding the expectations of his customers, making many of them fast friends.

Scholarships will be awarded to advance the education of students in both **Optometry** and **Ophthalmology**, and will be chosen by their school based on qualities that embody Rick's commitment to the profession, including integrity, compassion, partnership and dedication to the greater good.

Interested in being a partner with us?

Visit www.rickbayfoundation.org



THE RICK BAY FOUNDATION
for Excellence in Eyecare Education

SKEW DEVIATION

Signs and Symptoms

Patients will present with a vertical ocular strabismic imbalance. There will also likely demonstrate some ocular torsion along with a head tilt. The head tilt will be in the direction of the hypotropic eye and the torsion will be in the direction of the head tilt. This combination of skew deviation, ocular torsion and head tilt has been termed ocular tilt reaction (OTR).¹⁻⁴ Based upon this OTR, the patient may not complain of diplopia; when they perceive it, they often feel it is a minor issue. Disequilibrium is uncommon.

The phenomenon of OTR produces a synkinetic rotation of the eyes and head tilt designed to align with what the patient perceives as being vertical. The patient typically will not complain that the world appears tilted though what the patient perceives as being vertical is actually truly tilted.

The vertical dissociation of the eyes may be comitant, non-comitant, intermittently comitant or alternating with the hypertropia reversing in lateral gaze positions.⁵⁻⁷ There often will be concurrent internuclear ophthalmoplegia (INO) with an adduction deficit and an abducting nystagmus, giving a horizontal eye movement disorder compounding the vertical imbalance.^{3,4,8}

In that skew deviation represents complex disturbance of supranuclear input from lesions in the brainstem, cerebellum and peripheral vestibular system, additional associated neurologic complications may include gaze-evoked nystagmus, gaze palsy, dysarthria, ataxia, hemiplegia and INO.^{3,4} Skew deviation has neither racial or gender predilection. Though skew deviation can occur at any age, the main causes of multiple sclerosis, infarction, tumor, abscess, intracranial hemorrhage and increased intracranial pressure tend to afflict an older age group.

Pathophysiology

Skew deviation is caused by a supranuclear lesion. Skew deviation can result from any insult within the posterior cranial fossa, including multiple sclerosis, ischemic infarct, tumor trauma, hemorrhage, syringobulbia and neurosurgical procedures.^{3,5,8,9} Unilateral vestibular lesions can cause skew deviation as well. The main function of the vestibulo-ocular system is to maintain eye position and fixation with head movement.³ This otolith-ocular response to rotation is impaired due to brainstem lesions. The majority of causes come from brainstem stroke.³

INDICATIONS AND USAGE

PATADAY[®] solution is indicated for the treatment of ocular itching associated with allergic conjunctivitis.

CONTRAINDICATIONS

None.

WARNINGS

For topical ocular use only. Not for injection or oral use.

PRECAUTIONS

Information for Patients

As with any eye drop, to prevent contaminating the dropper tip and solution, care should be taken not to touch the eyelids or surrounding areas with the dropper tip of the bottle. Keep bottle tightly closed when not in use. Patients should be advised not to wear a contact lens if their eye is red.

PATADAY[®] (olopatadine hydrochloride ophthalmic solution) 0.2% should not be used to treat contact lens related irritation. The preservative in **PATADAY**[®] solution, benzalkonium chloride, may be absorbed by soft contact lenses. Patients who wear soft contact lenses and whose eyes are not red, should be instructed to wait at least ten minutes after instilling **PATADAY**[®] (olopatadine hydrochloride ophthalmic solution) 0.2% before they insert their contact lenses.

Carcinogenesis, Mutagenesis, Impairment of Fertility

Olopatadine administered orally was not carcinogenic in mice and rats in doses up to 500 mg/kg/day and 200 mg/kg/day, respectively. Based on a 40 µL drop size and a 50 kg person, these doses were approximately 150,000 and 50,000 times higher than the maximum recommended ocular human dose (MROHD). No mutagenic potential was observed when olopatadine was tested in an *in vivo* bacterial reverse mutation (Ames) test, an *in vivo* mammalian chromosome aberration assay or an *in vivo* mouse micronucleus test. Olopatadine administered to male and female rats at oral doses of approximately 100,000 times MROHD level resulted in a slight decrease in the fertility index and reduced implantation rate; no effects on reproductive function were observed at doses of approximately 15,000 times the MROHD level.

Pregnancy

Teratogenic effects: Pregnancy Category C

Olopatadine was found not to be teratogenic in rats and rabbits. However, rats treated at 600 mg/kg/day, or 150,000 times the MROHD and rabbits treated at 400 mg/kg/day, or approximately 100,000 times the MROHD, during organogenesis showed a decrease in live fetuses. In addition, rats treated with 600 mg/kg/day of olopatadine during organogenesis showed a decrease in fetal weight. Further, rats treated with 600 mg/kg/day of olopatadine during late gestation through the lactation period showed a decrease in neonatal survival and body weight.

There are, however, no adequate and well-controlled studies in pregnant women. Because animal studies are not always predictive of human responses, this drug should be used in pregnant women only if the potential benefit to the mother justifies the potential risk to the embryo or fetus.

Nursing Mothers

Olopatadine has been identified in the milk of nursing rats following oral administration. It is not known whether topical ocular administration could result in sufficient systemic absorption to produce detectable quantities in the human breast milk. Nevertheless, caution should be exercised when **PATADAY**[®] (olopatadine hydrochloride ophthalmic solution) 0.2% is administered to a nursing mother.

Pediatric Use

Safety and effectiveness in pediatric patients below the age of 2 years have not been established.

Geriatric Use

No overall differences in safety and effectiveness have been observed between elderly and younger patients.

ADVERSE REACTIONS

Symptoms similar to cold syndrome and pharyngitis were reported at an incidence of approximately 10%. The following adverse experiences have been reported in 5% or less of patients:

Ocular: blurred vision, burning or stinging, conjunctivitis, dry eye, foreign body sensation, hyperemia, hypersensitivity, keratitis, lid edema, pain and ocular pruritus.

Non-ocular: asthenia, back pain, flu syndrome, headache, increased cough, infection, nausea, rhinitis, sinusitis and taste perversion.

Some of these events were similar to the underlying disease being studied.

DOSAGE AND ADMINISTRATION

The recommended dose is one drop in each affected eye once a day.

HOW SUPPLIED

PATADAY[®] (olopatadine hydrochloride ophthalmic solution) 0.2% is supplied in a white, oval, low density polyethylene DROP-TAINER[®] dispenser with a natural low density polyethylene dispensing plug and a white polypropylene cap. Tamper evidence is provided with a shrink band around the closure and neck area of the package.

NDC 0065-0272-25

2.5 mL fill in 4 mL oval bottle

Storage

Store at 2°C to 25°C (36°F to 77°F)

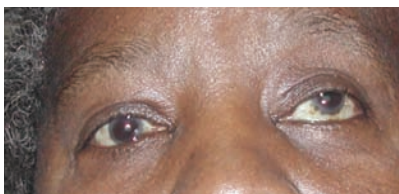
U.S. Patents Nos. 5,641,805; 6,995,186; 7,402,609

Rx Only

Alcon[®]

Most skew deviations arise from lesions in the posterior cranial fossa, especially those involving the brainstem tegmentum from the diencephalon to the medulla. Lesions in the utricle or vestibular nerve can also cause skew deviation. It has been suggested that disruption of the utriculo-ocular pathway is a mechanism.^{10,11} Focal cerebellar lesions can also cause skew deviation. Monocular or binocular imbalance of the utriculo-ocular reflex leads to cerebellar skew deviation.^{10,11}

The medial longitudinal fasciculus (MLF) is also a prime location for a lesion producing both skew deviation as well as INO. When skew deviation accompanies INO, the hypertrophic eye is on the side of the lesion. This suggests a rostral lesion of the MLF after crossing in the pons.³ In these cases, demyelinating disease and ischemic stroke are likely causes.³



Skew deviation.

Management

When patients present with a vertical deviation or vertical diplopia, there are several steps to ascertain the etiology. First, a mechanical restriction must be ruled out. This can be tested using the forced duction test. If mechanical restriction is suspected, orbital CT scan or MRI is recommended. Once mechanical restriction is eliminated as a possible cause, a Parks-Bielschowsky 3-Step Test should be performed. This is important because the most common differential diagnosis of skew deviation is cranial nerve (CN) IV palsy. This is especially true for non-comitant skew deviations. In fact, skew deviation can mimic CN IV palsy.⁴

If the 3-Step test does not indicate CN IV palsy, order MRI with gadolinium to rule out a lesion of the posterior cranial fossa as well as examine for evidence of demyelinating disease.

Other methods can further differentiate skew deviation from CN IV palsy. The patient should be examined for additional neurological signs in the form of gaze-induced nystagmus, gaze palsy, facial nerve palsy, hemiplegia, ataxia and dysarthria. These findings, common in skew deviation, are absent in cranial nerve IV palsy unless it was caused by trauma or a brainstem lesion. MRI is also recommended.⁴

Indirect ophthalmoscopy and double Maddox rod testing can also yield clues in differentiating skew deviation from CN IV palsy. In skew deviation, the hypertrophic eye will be incyclotorted whereas the hypertrophic eye in CN IV palsy will be excyclotorted.

Another simple test can give information to differentiate from CN IV palsy.^{4,12} In skew deviation, abnormal torsion and ocular vertical deviation are head position dependent but not so in CN IV palsy. After performing the 3-Step Test, the ocular torsion and vertical misalignment should be measured using a double Maddox rod and penlight and prism neutralization with alternate cover test with a 12-point font near target, both at one meter, respectively. Once done, the patient should be reclined to the supine position. The ocular torsion and vertical misalignment should again be measured in the same manner while supine.

In skew deviation, there will be a significant improvement or even complete disappearance of the torsional and vertical abnormalities; by contrast, there will be little change if CN IV palsy is the diagnosis. If there is less than a 50% improvement of the vertical deviation with supination, this part of the test is considered negative and skew deviation is the diagnosis. This

upright-supine test is very sensitive and highly specific. In one report, no cases of vertical imbalance due to CN IV palsy, restrictive myopathy, childhood strabismus or myasthenia gravis demonstrated positive results (>50% improvement) with supination.¹² Thus, it can be argued that the 3-Step test should now become a 4-Step test.

Clinical Pearls

- In vertical diplopia and vertical ocular misalignment, the cause is CN IV palsy until proven otherwise.
- In patients with vertical imbalance, should the 3-Step test fail to identify CN IV palsy, skew deviation must be strongly considered as the likely alternate diagnosis.
- After performing the 3-Step test, recline the patient and recheck the vertical imbalance. If there is more than 50% improvement upon supination, then skew deviation is present and the patient should be referred for an MRI including the posterior cranial fossa.

1. Fu T, Lu W. Clinical manifestations and treatment of Skew deviation. *Zhonghua Yan Ke Za Zhi*. 2012;48(9):856-60.
2. Sharpe JA, Kumar S, Sundaram AN. Ocular torsion and vertical misalignment. *Curr Opin Neurol*. 2011;24(1):18-24.
3. Brodsky MC, Donahue SP, Vaphiades M, Brandt T. Skew deviation revisited. *Surv Ophthalmol*. 2006;51(2):105-28.
4. Wong AM. Understanding skew deviation and a new clinical test to differentiate it from trochlear nerve palsy. *J AAPOS*. 2010;14(1):61-7.
5. Tsuda H, Nagamata M, Tanaka K. Alternating skew deviation due to hemorrhage in the cerebellar vermis. *Intern Med*. 2012;51(19):2793-6.
6. Moster ML, Schatz NJ, Savino PJ, et al. Alternating skew on lateral gaze (bilateral abducting hypertropia). *Ann Neurol*. 1988;23(2):190-2.
7. Zee DS. Considerations on the mechanisms of alternating skew deviation in patients with cerebellar lesions. *J Vestib Res*. 1996;6(6):395-401.
8. Pandey PK, Singh A, Kumar B. Ocular tilt reaction, internuclear ophthalmoplegia, and torsional nystagmus following mitral commissurotomy. *J AAPOS*. 2012;16(5):484-6.
9. Cosetti MK, Tawfik K, Fouladvand M, et al. Diplopia due to skew deviation following neurotologic procedures. *Otol Neurotol*. 2012;33(5):840-2.
10. Chandrakumar M, Blakeman A, Goltz HC, et al. Static ocular counterroll reflex in skew deviation. *Neurology*. 2011;77(7):638-44.
11. Wong AM, Sharpe JA. Cerebellar skew deviation and the torsional vestibuloocular reflex. *Neurology*. 2005;65(3):412-9.
12. Wong AM, Colpa L, Chandrakumar M. Ability of an upright-supine test to differentiate skew deviation from other vertical strabismus causes. *Arch Ophthalmol*. 2011;129(12):1570-5.

TelScreen

EDO Slit Lamps & Anterior Segment Imaging

Exceptional Education drives Compliance and improves Outcomes.

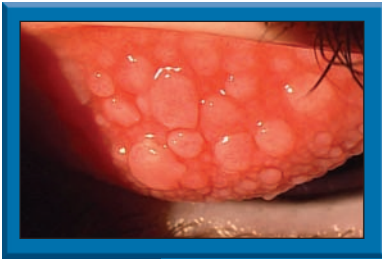

"I use TelScreen's imaging system as the backbone for optimizing patient outcomes. The videos that I capture are amazing for monitoring my patients' conditions, for educating patients and ultimately for encouraging compliance."



Meibomian Gland Expression

Mile Brujic, O.D.

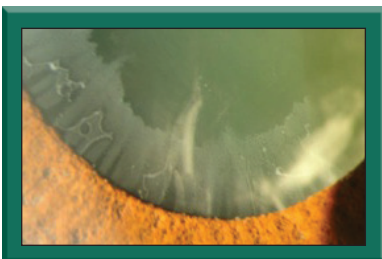


"The image quality is fantastic. One of the most impressive items for me is the efficiency it provides. My goal is to see 50+ patients per day while maintaining patient satisfaction. The TelScreen system allows me to eliminate seeing patients twice during the exam and to educate efficiently. I do anterior-segment photography during the slit-lamp exam. Patients leave feeling they spent ample time with the doctor because image-based education increases their understanding."



Vernal Keratoconjunctivitis

Paul Karpecki, O.D.



"TelScreen's system is a medically-useful tool that also makes great business sense. My practice now has 7 systems. These EyeRes systems serve as the backbone for patient communication in the lane, improve patients' understanding of their conditions and produce a positive impact on patient behavior."



Exfoliation Syndrome Affecting the Lens

I. Ben Gaddie, O.D.

Contact TelScreen to add this important tool to your practice.

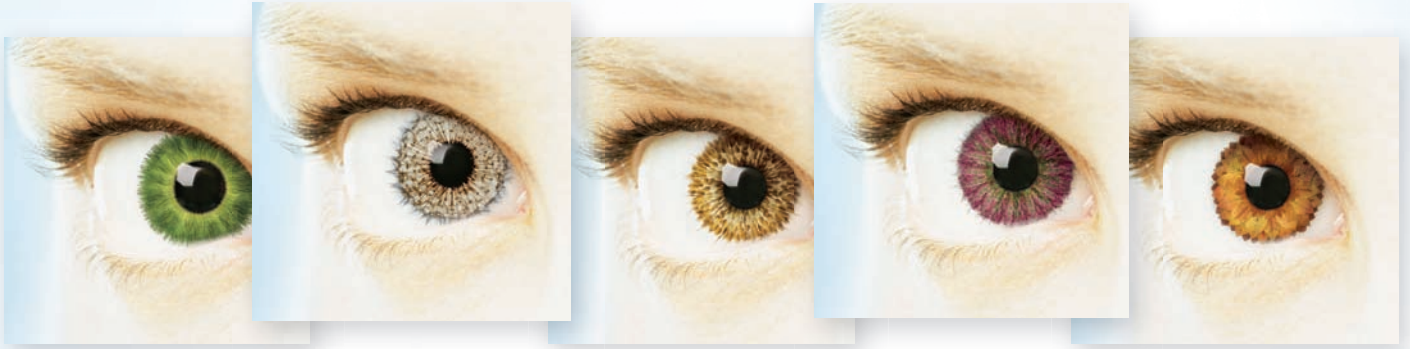TelScreen

©TelScreen, Louisville, KY 40222

800.769.4933
www.TelScreen.com



PATADAY® Solution: The #1 Prescription Allergy Eye Drop¹



THE SOLUTION YOU'VE TRUSTED, YEAR AFTER YEAR AFTER YEAR

Season after season, your allergic conjunctivitis patients can rely on PATADAY® Solution for proven ocular itch relief² with excellent payer coverage and affordability

- Broad Tier 2 formulary coverage for both commercial and Medicare Part D plans³
- Patient Rebate Programs for eligible patients*

*This offer is not valid for patients who are enrolled in Medicaid, Medicare, or other federal or state prescription benefit programs including medical assistance programs. Please refer to the terms and conditions on the rebate materials.

INDICATION AND DOSING

PATADAY® Solution is a mast cell stabilizer indicated for the treatment of ocular itching associated with allergic conjunctivitis. The recommended dose is one drop in each affected eye once a day.

IMPORTANT SAFETY INFORMATION

PATADAY® Solution is for topical ocular use only. It is not for injection or oral use.

To prevent contaminating the dropper tip and solution, care should be taken not to touch the eyelids or surrounding areas with the dropper tip of the bottle. Keep the bottle tightly closed when not in use.

References: 1. IMS Health, IMS National Prescription Audit™, August 2010 to December 2012, USC 61500 OPTH ANTI-ALLERGY. 2. PATADAY® Solution package insert. 3. Formulary data provided by Pinsonault Associates, LLC, PathfinderRx, April 2013.

Patients should be advised not to wear contact lenses if their eyes are red.

PATADAY® Solution should not be used to treat contact lens-related irritation. The preservative in PATADAY® Solution, benzalkonium chloride, may be absorbed by soft contact lenses. Patients who wear soft contact lenses and **whose eyes are not red** should be instructed to wait at least ten minutes after instilling PATADAY® Solution before they insert their contact lenses.

Symptoms similar to cold syndrome and pharyngitis were reported at an incidence of approximately 10%.

For additional information about PATADAY® Solution, please refer to the brief summary of prescribing information on adjacent page.

Alcon

a Novartis company

©2013 Novartis 5/13 PAT13131JAD

Visit PatadayToday.com

Pataday® 
(olopatadine hydrochloride
ophthalmic solution) 0.2%