



February 15, 2013

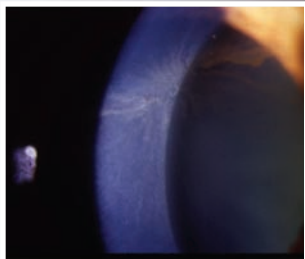
# REVIEW<sup>®</sup> OF OPTOMETRY

Part 1 of 2

www.revoptom.com

## Pharmaceuticals Issue

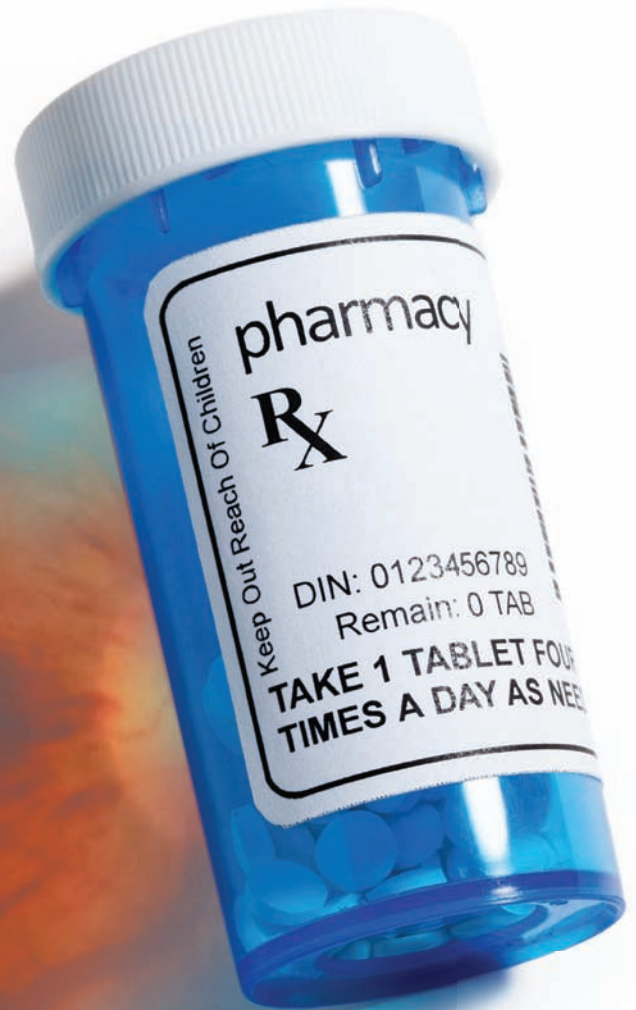# Which Side Effects are Lurking in the Shadows?



p. 60

Anti-Inflammatories in Ocular Allergy  
Treatment, p. 52

Earn 2 CE Credits: Varicella Zoster Virus:  
From Chickenpox to Shingles, p. 76



### ALSO INSIDE:

Keep an Eye Out for OSA, p. 26

Sharpen Your Visual Field Interpretation Skills, p. 36

How and Why to Get Behind Health Exchanges, p. 46

# WHY THAT FIRST PAIR MEANS EVERYTHING.



You, Hailey, and Hailey's Mom

**+** 1-DAY ACUVUE<sup>®</sup>  
**MOIST**<sup>®</sup>  
BRAND CONTACT LENSES

Fact: 58% of new contact lens wearers report they are likely to stop wearing contact lenses and return to glasses.\* That's why it's critical to start your new wearers off right in 1-DAY ACUVUE<sup>®</sup> MOIST<sup>®</sup> Brand Family, with exceptional comfort, handling, stability, and UV protection.† No wonder 88% of parents with teens in 1-DAY ACUVUE<sup>®</sup> MOIST<sup>®</sup> said they were likely to refer others to you. Start new wearers off right and grow your practice.

[ACUVUEprofessional.com](http://ACUVUEprofessional.com)

\*Gallup Study of The Consumer Contact Lens Market, conducted by Multi-Sponsor Surveys, Inc. "Likely" is comprised of net respondents that selected "Very" or "Somewhat" likely.

† **WARNING:** UV-absorbing contact lenses are NOT substitutes for protective UV-absorbing eyewear such as UV-absorbing goggles or sunglasses, because they do not completely cover the eye and surrounding area. You should continue to use UV-absorbing eyewear as directed. **NOTE:** Long-term exposure to UV radiation is one of the risk factors associated with cataracts. Exposure is based on a number of factors such as environmental conditions (altitude, geography, cloud cover) and personal factors (extent and nature of outdoor activities). UV-blocking contact lenses help provide protection against harmful UV radiation. However, clinical studies have not been done to demonstrate that wearing UV-blocking contact lenses reduces the risk of developing cataracts or other eye disorders. Consult your eye care practitioner for more information.

ACUVUE<sup>®</sup> Brand Contact Lenses are indicated for vision correction. As with any contact lens, eye problems, including corneal ulcers, can develop. Some wearers may experience mild irritation, itching or discomfort. Lenses should not be prescribed if patients have any eye infection, or experience eye discomfort, excessive tearing, vision changes, redness or other eye problems. Consult the package insert for complete information. Complete information is also available from VISTAKON<sup>®</sup> Division of Johnson & Johnson Vision Care, Inc., by calling 1-800-843-2020 or by visiting [acuvueprofessional.com](http://acuvueprofessional.com).

ACUVUE<sup>®</sup>, 1-DAY ACUVUE<sup>®</sup> MOIST<sup>®</sup>, and VISTAKON<sup>®</sup> are trademarks of Johnson & Johnson Vision Care, Inc.

© Johnson & Johnson Vision Care, Inc. 2013 ACU-39307G January 2013



Hailey and Mom



Hailey's Classmate



Mom's Dentist



Mom's Plumber



Mom's Student



Hailey's Cousin



Hailey's Best Friend



Mom's Mechanic



Hailey's Classmate



Mom's Neighbor



Hailey's Uncle



Hailey's Friend



Hailey's Brother



Mom's Manicurist



## IN THE NEWS

**Southern California College of Optometry** announced that **Stan Woo, OD, MS**, will serve as the new **dean of optometry** beginning in July 2013. Currently, Dr. Woo is chief of the Vision Rehabilitation Service, founding director of the Center for Sight Enhancement and director of the Residency in Low Vision Rehabilitation at **University of Houston College of Optometry**.

Among children with **poor literacy** skills, as many as **one in six** (nearly 17%) also have **poor stereoacuity**, according to a study in January's *Optometry & Vision Science*. Investigators in Tasmania tested a total of 490 primary school children who scored below the 10th percentile for literacy at a third grade level. They found that children with poor stereoacuity had a higher frequency of convergence insufficiency symptoms. **Poor stereopsis** was also associated with prematurity and bottom shuffling. In addition, children with poor stereopsis demonstrated squint, migraine and attention deficit disorder. These associations require further investigation, the researchers say.

**Pacific University**, Forest Grove, Ore., recently opened an administrative office in **Honolulu** to better serve its large number of current students, prospective students and alumni who have ties to **Hawaii**. Approximately 20% of students attending the university hail from Hawaii and more than 1,300 Pacific alumni reside on the islands. Pacific has also developed an agreement that will establish a seamless degree pathway for Hawaii's community college students to earn their bachelor's degree at the university.

## FDA Panel Advises Restricting Pain Meds

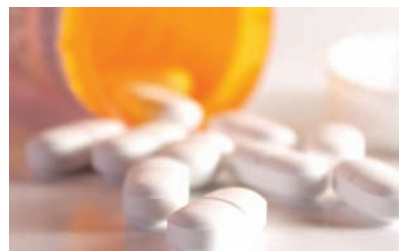If approved, hydrocodone-based drugs would become Schedule II medications. **By Colleen Mullarkey, Senior Editor**

**H**ydrocodone-combination drugs, such as Vicodin (hydrocodone/acetaminophen, Abbott) and Lortab (hydrocodone/acetaminophen, UCB Pharma) could be moving from Schedule III to the more restrictive Schedule II category, based on the recommendation of an FDA advisory panel. If this change happens, it could block many ODs from prescribing these drugs.

On January 25, the FDA Drug Safety and Risk Management Advisory Committee voted 19 to 10 in favor of the reclassification—over the objections of the American Optometric Association and national groups representing dentists, nurse practitioners, physician assistants and others.

Several experts advocated for the scheduling change, arguing that hydrocodone drugs are too frequently abused and misused. Sharon Walsh, PhD, from the Center on Drug and Alcohol Research, University of Kentucky, presented evidence from human studies that hydrocodone has similar potential for dependency and abuse as Schedule II controlled substances, such as morphine and oxycodone.

But Jimmy Bartlett, OD, who testified on behalf of AOA, warned that simply moving hydrocodone-combination drugs into Schedule II would have harmful health consequences for patients



**An FDA panel finds that drugs with hydrocodone should be better regulated.**

and would limit proven treatment options for providers. Dr. Bartlett suggested maintaining hydrocodone drugs as Schedule III, but with safety restrictions equal to Schedule II drugs.

The advisory committee's recommendations will now be delivered to FDA leaders, who will in turn make a recommendation to US Department of Health and Human Services. HHS will then make its official medical and scientific evaluation on this issue to the US Drug Enforcement Administration, which has the ultimate authority on the scheduling of controlled substances.

*The AOA has begun urging the federal officials who will review this decision to discuss the modifications needed to safeguard optometry patients. If you are interested in working with Dr. Bartlett and the AOA Advocacy Group, contact Matt Willette of the AOA Washington, DC office at [mwillette@aoa.org](mailto:mwillette@aoa.org).*



# JETREA™

(ocriplasmin)

Intravitreal Injection, 2.5 mg/mL

**NOW AVAILABLE**

**FOR ORDERING INFORMATION,  
VISIT: [www.JETREACARE.COM](http://www.JETREACARE.COM)**

©2013 ThromboGenics, Inc. All rights reserved.  
ThromboGenics, Inc., 101 Wood Avenue South, Suite 610, Iselin, NJ 08830 - USA

JETREA and the JETREA logo are trademarks or registered trademarks of ThromboGenics NV in the United States, European Union, Japan, and other countries.

THROMBOGENICS and the THROMBOGENICS logo are trademarks or registered trademarks of ThromboGenics NV in the United States, European Union, Japan, and other countries.

 **ThromboGenics®**

02/13 OCRVMA0055 JA5

## Florida ODs Push for Oral Meds

As the 2013 session of the Florida Legislature is about to kick off next month, optometrists in the Sunshine State are pushing for an expanded scope of practice bill that would allow Florida ODs to prescribe oral medications.

If approved, the legislation would allow optometrists to use “those pharmaceutical agents which are appropriate to treat and diagnose ocular diseases and disorders and which the certified optometrist is qualified to use in the practice of optometry.” This does not include Schedule I or Schedule II drugs. Optometrists in Florida would have to take a pharmaceuticals course and pass an exam before they can prescribe oral drugs, the bill stipulates.

The bill—SB 278 in the Florida Senate and HB 239 in the Florida

House of Representatives—will save money, increase access to eye care and save people from losing vision due to treatment delays, according to the Florida Optometric Association. Currently, only two other states—New York and Massachusetts—do not allow ODs to prescribe any oral meds.

“During a time that we, as a state, are focused on providing access to quality care to all Floridians, this is a much-needed and simple fix to current law,” said Senator Garrett Richter (R), who introduced SB 278 on January 14.

The Florida Optometric Association has a video on its website to illustrate the need for this legislation. In the video, a female patient and her optometrist recount how the woman sustained permanent damage to her cornea and subsequent vision loss since her OD was

unable to prescribe her an oral anti-shingles medication at the time of her visit.

In addition to better and more immediate patient care, the FOA says this bill will provide significant cost savings of up to \$70 million, according to a recent study of Florida Medicaid claims.

The bill also would allow Florida optometrists to be reimbursed for in-office eye infection lab cultures. Currently, optometrists can perform the test. However, under Florida law, optometrists can't be reimbursed.

In addition, if contact lens delivery systems are approved for administering eye medications, optometrists would be permitted to prescribe these delivery systems as well. At present, Florida optometrists are strictly limited to eye drop and eye ointment medicines.

## Anti-VEGF Tx Harms Ciliary Body?

Aggressive anti-VEGF therapy could impair proper ciliary body function, according to an animal study published in *Investigative Ophthalmology & Visual Science*.

In this study, investigators at Schepens Eye Research Institute/Massachusetts Eye and Ear Infirmary evaluated the effect of sustained VEGF-A inhibition in a mouse model. They found that blocking VEGF-A expression led to nonpigmented epithelium thinning, pigmented epithelium vacuolization, capillary fenestration loss, thrombosis and a mean IOP decrease of nearly 3.5mm Hg—evidence of impaired ciliary body function.

“Very little is known about the factors that regulate the integrity and function of this tissue [the ciliary body] in the adult,” says lead author Patricia A. D'Amore, PhD, MBA, director of research and senior scientist at Schepens. “Our finding indicates that VEGF-A is at least one of the molecules that play a role in keeping the ciliary body healthy and functioning properly.”

Dr. D'Amore noted that current anti-VEGF administration techniques do not seem to interfere with ciliary body function. This includes the intravitreal administration of Lucentis (ranibizumab, Genentech/Roche), Eylea (aflibercept, Regeneron) and Avastin

(bevacizumab, Genentech/Roche) that are used to treat neovascular AMD, diabetic retinopathy and macular edema.

“However, there is a move toward developing methods to continuously deliver anti-VEGF to the eye and to have drugs that are more potent inhibitors of VEGF,” she says. “I am hoping that revealing the possible negative side effects of VEGF inhibition in the eye will motivate research into new ways to block edema and blood vessel growth in the eye that does not require continuous inhibition of intraocular VEGF.”

Ford KM, Saint-Geniez M, Walshe TE, D'Amore PA. Expression and role of VEGF-a in the ciliary body. *Invest Ophthalmol Vis Sci*. 2012 Nov 7;53(12):7520-7.

# ...less has never meant more.



Easiest To Use  
Smallest Footprint  
Lowest Price

### *Less is more.*

Pulsair Desktop is uncomplicated and therefore quick to use for the novice and professional alike. Taking control of tonometry has never been easier or faster. Clear user controls and a color video alignment screen combine to set a new standard in usability.

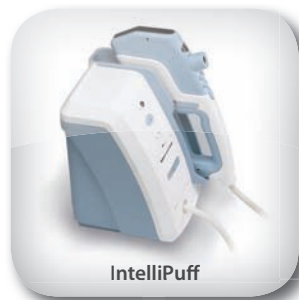The Pulsair Desktop has a small and space saving footprint that combined with the elegant, slim optical mainframe allows it to blend seamlessly into the clinical environment. The openness of the design increases the confidence of both patient and clinician.

Contact Keeler or your preferred Keeler distributor today to learn more about the Pulsair Desktop and the rest of the Keeler family of tonometers.

The Keeler Family of Tonometers offers your practice the choice of technology that's right for you!



Keeler K.A.T.



IntelliPuff

Great Low Price!

~~\$6,250.00~~

**\$4,950.00**

With Instant Rebate!

No trade-ins allowed.

Buy Online!  
[keelerusa.com](http://keelerusa.com)



# Keeler

[www.keelerusa.com](http://www.keelerusa.com) | 800-523-5620

A HALMA COMPANY

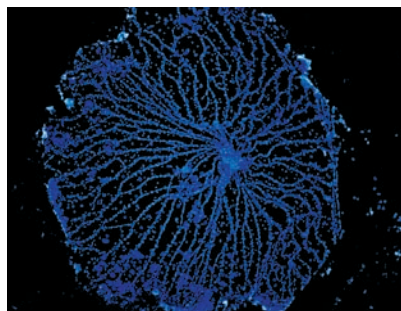
# Light Needed for Healthy Babies' Eyes

**M**others need light exposure during pregnancy for healthy eye development in babies, according to a study in the January 16 online edition of *Nature*.

Using a mouse model, investigators found that activation of a light-response pathway must happen during pregnancy to initiate the carefully choreographed program that produces a healthy eye. Specifically, they say it is important for a sufficient number of photons to enter the mother's body by late gestation.

Before this, scientists had assumed that if light played a role in the development of the eye, it would happen only after birth.

"This fundamentally changes our understanding of how the retina develops," says study co-author Richard Lang, PhD, a researcher in the Division of Pediatric Ophthalmology at Cincinnati Children's Hospital Medical Center. "We have identified a light-



**Insufficient light during pregnancy can lead to unchecked blood vessel growth in the retina, seen here in a mouse's eye.**

response pathway that controls the number of retinal neurons. This has downstream effects on developing vasculature in the eye and is important because several major eye diseases are vascular diseases."

One of those eye disorders in particular is retinopathy of prematurity.

The study involved several experiments in groups of laboratory mice raised either in the dark or in a normal day-night cycle.

Mice reared from late gestation under dark conditions exhibited expansion of hyaloid vessels and abnormal retinal vascular growth. The unchecked vascular growth was driven by vascular endothelial growth factor (VEGF-A).

In normal circumstances, the light-response pathway modulates VEGF-A to help prevent uninhibited vascular growth. These vessels naturally regress in mice before the eyelids open 10 days after birth, but they persist if the mouse fetus receives insufficient light in the womb—which shows that the eye needs light to develop during pregnancy.

The research team will now study how the light-response pathway might influence the susceptibility of pre-term infants to retinopathy of prematurity and other diseases of the eye, Dr. Lang says. ■

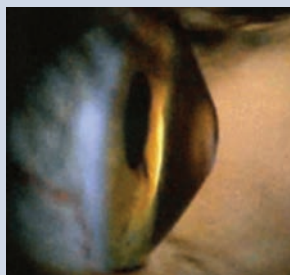
Rao S, Chun C, Fan J, et al. A direct and melanopsin-dependent fetal light response regulates mouse eye development. *Nature*. 2013 Jan 16. [Epub ahead of print]

## Genes for Central Corneal Thickness May Predict Glaucoma and Keratoconus

Optometrists may one day be able to identify patients at high risk for glaucoma and keratoconus based on their genetic profiles, thanks to a discovery by scientists at the Singapore Eye Research Institute and the Association for Science, Technology and Research's Genome Institute of Singapore.

The team identified genes for central corneal thickness (CCT) associated with potentially blinding conditions, including glaucoma and keratoconus. With an estimated heritability of up to 95%, CCT may determine the severity of one's glaucoma and assist ODs in identifying patients with high risk for progression.

The authors identified a total of 26 CCT-associated genetic loci, including six for keratoconus. Their multicenter study involved 55 hospitals and research centers across the globe, and they



**Certain corneal thickness genes confer an increased risk for keratoconus.**

performed a meta-analysis on data from more than 20,000 individuals in European and Asian populations.

"This paper identified six novel genetic variants that confer increased risk of keratoconus, a condition for which genes were not very forthcoming prior to this study," says co-author Eranga Vithana, PhD, associate professor and associate director of Basic and Experimental Sciences at Singapore Eye Research Institute. "It once again underlined the inevitability of large scale collaborative studies to unravel genes for common complex diseases and also the advantage of having well-characterized

large cohorts."

Yi L, Vitart V, Burdon KP, et al. Genome-wide association analyses identify multiple loci associated with central corneal thickness and keratoconus. *Nat Genet*. 2013 Feb;45(2):155-63.



**REVIEW**<sup>®</sup>  
OF OPTOMETRY

**Jobson**  
Professional Publications Group

**BUSINESS OFFICES**  
11 CAMPUS BLVD., SUITE 100  
NEWTOWN SQUARE, PA 19073

**SUBSCRIPTION INQUIRIES**  
1-877-529-1746 (USA ONLY);  
OUTSIDE USA, CALL (847) 763-9630

**SALES MANAGER, NORTHEAST, OHIO**  
JAMES HENNE  
(610) 492-1017 • JHENNE@JOBSON.COM

**SALES MANAGER, SOUTHEAST, WEST**  
MICHELE BARRETT  
(610) 492-1014 • MBARRETT@JOBSON.COM

**CLASSIFIED ADVERTISING**  
888-498-1460

**VICE PRESIDENT OF OPERATIONS**  
CASEY FOSTER  
(610) 492-1007 • CFOSTER@JOBSON.COM

**EDUCATION/CONFERENCE MANAGER**  
MEG McDONALD  
(610) 492-1045 • MMCDONALD@JOBSON.COM

**PRODUCTION MANAGER**  
SCOTT TOBIN  
(610) 492-1011 • STOBIN@JOBSON.COM

**SENIOR CIRCULATION MANAGER**  
ANTHONY GUADAGNINO  
(212) 219-7870 • AGUADAGNINO@JOBSON.COM

**SUBSCRIPTIONS**  
\$56 A YEAR, \$88 (U.S.) IN CANADA,  
\$209 (U.S.) IN ALL OTHER COUNTRIES.

**CIRCULATION**  
PO Box 2025  
SKOKIE, IL 60076  
TEL: (TOLL FREE) 1-877-529-1746  
OUTSIDE USA: (847)763-9630  
FAX: (847)763-9631



**CHIEF OPERATING OFFICER**  
JEFF MACDONALD

**CEO, INFORMATION GROUP SERVICES**  
MARC FERRARA

**SENIOR VICE PRESIDENT, HUMAN RESOURCES**  
LORRAINE ORLANDO

**VICE PRESIDENT, CREATIVE SERVICES & PRODUCTION**  
MONICA TETTAMANZI

**VICE PRESIDENT, CIRCULATION**  
EMELDA BAREA

Elevating The Quality Of Care In Ophthalmology



## Rhein Fire & Ice Mask

Product #85-9005



- **For Heat Therapy: Place It In A Microwave For 15 Seconds, Warm Relief Lasts 15 Minutes.**
- **For Cold Therapy: After Placing In The Freezer 2 Hours, Cool Relief Lasts 15 Minutes.**
- **Includes Cloth Sleeve For Additional Lid Protection.**
- **Easy To Use, And Can Be Cleaned And Reused Multiple Times.**
- **Available 5 Units Per Box.**

**For More Information Call 727-209-2244**



3360 Scherer Drive, Suite B, St. Petersburg, FL 33716  
800-637-4346 • Tel: 727-209-2244 • Fax: 727-341-8123  
Email: [Info@RheinMedical.com](mailto:Info@RheinMedical.com) Website: [www.RheinMedical.com](http://www.RheinMedical.com)



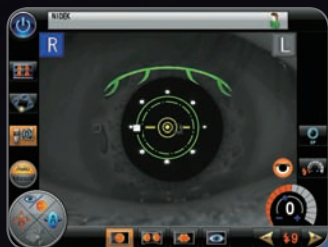Woman Wearing Dry Eye Heat Mask

# The Power to Simply Perform

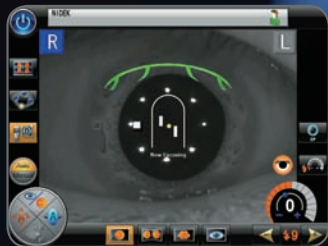# AUTO

# NOW

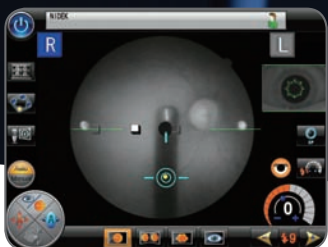## know the difference between 'auto' & 'ought-to'



3D AutoAlign in X-Y-Z



AutoSwitching



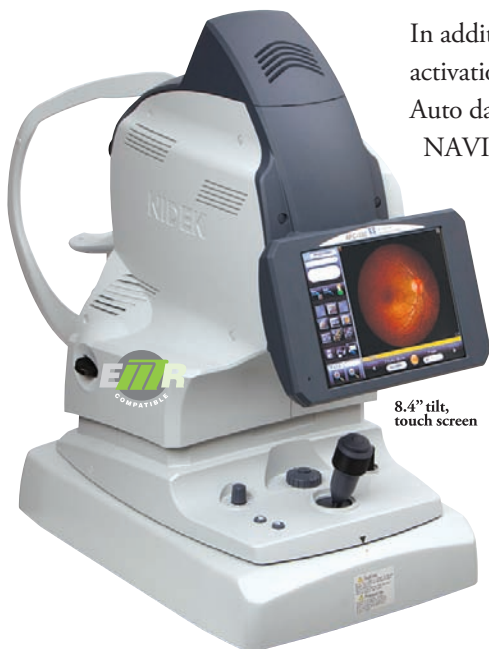AutoFocus

Experience a fundus camera with auto 3D alignment in X-Y-Z axes, AutoSwitching, AutoFocus, AutoShot, AutoPanoramic images, and AutoStereo Pairs.

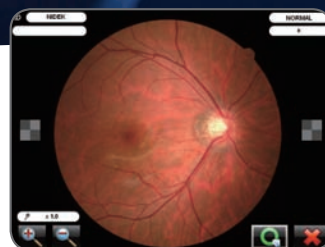In addition, the **AFC-330** delivers Auto small pupil detection/activation of small pupil mode, Auto blink detection, Auto data transfer options, and is fully networkable with NAVIS-EX data management software.

If your Retinal Camera doesn't provide these 'auto' features...it 'ought-to'.

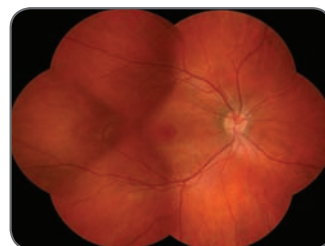
Arrange your free product demonstration at [www.marco.com](http://www.marco.com), and realize how simple fundus photography should be.



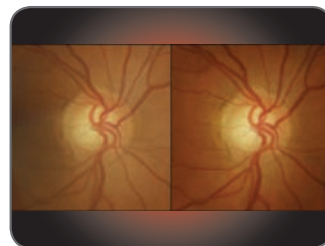
8.4" tilt, touch screen



AutoShot



AutoPanorama (2-7)



AutoStereo Pairs

The Difference is Marco™



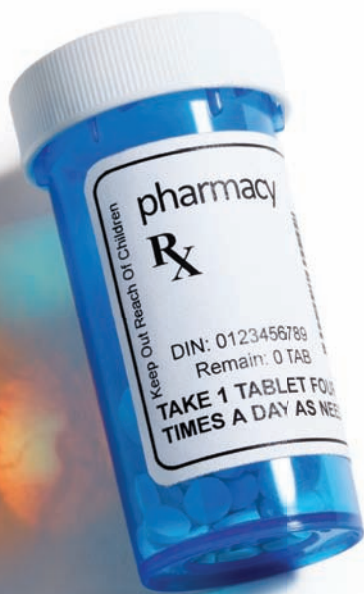Designed and Manufactured by NIDEK - Represented by MARCO

SECO • 1149  
800.874.5274  
[www.marco.com](http://www.marco.com)



# Contents

Review of Optometry February 2013



## 60 Which Side Effects are Lurking in the Shadows?

You can't afford to stay in the dark regarding the ocular and systemic side effects of the most commonly used drugs in America. **By Bruce G. Muchnick, OD**

## 52 Anti-Inflammatories in Ocular Allergy Treatment

Steroids used to be reserved for non-responsive cases. But now many optometrists are using them as a first-line therapy for allergic conjunctivitis. **By A.J. DeVivo, OD, and Terry Scheid, OD**

## 76 Earn 2 CE Credits: Varicella Zoster Virus: From Chickenpox to Shingles

VZV affects patients both young and old. Here's how to manage the associated ocular complications. **By William Marcolini, OD**



## 26 Keep an Eye Out for OSA

What does obstructive sleep apnea have to do with eye care? A lot, actually. Make sure you're staying on top of the many ophthalmic complications associated with OSA.

**By Brad Sutton, OD**

## 36 Sharpen Your Visual Field Interpretation Skills

Understanding visual fields is not black and white—not even shades of gray. But new analyses can provide powerful information, if you can interpret them. **By Michael Chaglasian, OD**

## 46 How and Why to Get Behind Health Exchanges

It took decades for optometrists to achieve drug prescribing rights. Now, ODs face another challenge: not getting shut out of Obamacare. **By Cheryl G. Murphy, OD, Contributing Editor**

## 84 SECO 2013: Celebrating 90 Years of Education

This year's 90th annual Southern Congress will offer plenty for everyone. **By Paul C. Ajamian, OD**

## 86 Sneak Peek at Vision Expo East 2013

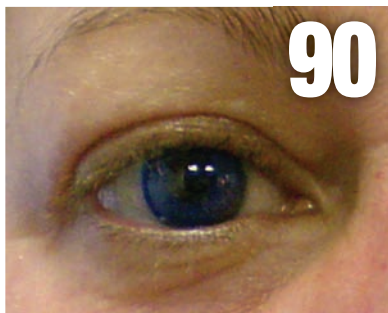
New York City is the place where you can find the trendiest eye-wear fashions, cutting-edge equipment, and hundreds of hours of top-notch continuing education.

**By Cheryl G. Murphy, OD, Contributing Editor**

# Departments

Review of Optometry February 2013

- 4** News Review
- 16** Letters to the Editor
- 20** Editor's Page  
Pride and Prejudice  
**JACK PERSICO**
- 22** Chairside  
A Sore Site for Eyes  
**MONTGOMERY VICKERS, OD**
- 24** Coding Abstract  
T Minus 11 and Counting...  
**JOHN RUMPAKIS, OD, MBA**
- 88** Comanagement Q+A  
When to Send Out Sjögren's  
**PAUL C. AJAMIAN, OD**
- 90** Cornea + Contact Lens Q+A  
Rigid Lens Makes Eye Go Slack  
**JOSEPH P. SHOVLIN, OD**
- 92** Glaucoma Grand Rounds  
A New Hint for Glaucoma Risk  
**JAMES L. FANELLI, OD**
- 94** Retina Quiz  
Half Way There  
**MARK T. DUNBAR, OD**
- 96** Therapeutic Review  
A Big Bag of Hot Air  
**ALAN G. KABAT, OD**  
**JOSEPH W. SOWKA, OD**
- 100** Research Review  
Color Me Curious  
**PAUL M. KARPECKI, OD**  
**DIANA L. SHECHTMAN, OD**
- 102** Product Review
- 106** Meetings + Conferences
- 107** Advertisers Index
- 108** Classifieds
- 113** Surgical Minute  
Temporal Artery Biopsy  
**DEREK N. CUNNINGHAM, OD**  
**WALTER O. WHITLEY, OD, MBA**
- 114** Diagnostic Quiz  
A Painfully Large Cataract  
**ANDREW S. GURWOOD, OD**



## On The Web >>

Check out our multimedia and continuing education @ [www.revoptom.com](http://www.revoptom.com)

### Digital Edition



Left your *Review of Optometry* at the office? No problem! Access *Review* on your computer or mobile device!

Go to [www.revoptom.com](http://www.revoptom.com) and click on the digimag link to for the current issue.

### Facebook and Twitter



For daily updates, "Like" our page on Facebook or "Follow" us on Twitter!

- [www.facebook.com/revoptom](http://www.facebook.com/revoptom)
- <http://twitter.com/#!/revoptom>

# REVIEW<sup>®</sup>

OF OPTOMETRY



PRINTED IN U.S.A.

**FOUNDING EDITOR**  
FREDERICK BOGER  
1891-1913

#### EDITORIAL OFFICES

11 CAMPUS BLVD., SUITE 100  
NEWTOWN SQUARE, PA 19073

EMAIL • [REVIEWOFOPTOMETRY@JOBSON.COM](mailto:REVIEWOFOPTOMETRY@JOBSON.COM)

WEBSITE • [WWW.REVOPTOM.COM](http://WWW.REVOPTOM.COM)

#### SUBSCRIPTION INQUIRIES

1-877-529-1746

#### CONTINUING EDUCATION INQUIRIES

1-800-825-4696

**EDITOR-IN-CHIEF** • JACK PERSICO  
(610) 492-1006 • [JPERSICO@JOBSON.COM](mailto:JPERSICO@JOBSON.COM)

**EXECUTIVE EDITOR** • JOHN MURPHY  
(610) 492-1021 • [JMURPHY@JOBSON.COM](mailto:JMURPHY@JOBSON.COM)

**MANAGING EDITOR** • MICHAEL HOSTER  
(610) 492-1028 • [MHOSTER@JOBSON.COM](mailto:MHOSTER@JOBSON.COM)

**SENIOR EDITOR/WEB EDITOR** • COLLEEN MULLARKEY  
(610) 492-1005 • [CMULLARKEY@JOBSON.COM](mailto:CMULLARKEY@JOBSON.COM)

**DIRECTOR ART/PRODUCTION** • JOE MORRIS  
(610) 492-1027 • [JMORRIS@JOBSON.COM](mailto:JMORRIS@JOBSON.COM)

**ART DIRECTOR** • JARED ARAUJO  
(610) 492-1032 • [JARAUJO@JOBSON.COM](mailto:JARAUJO@JOBSON.COM)

**GRAPHIC DESIGNER** • ALICIA CAIRNS  
(610) 492-1029 • [ACAIRNS@JOBSON.COM](mailto:ACAIRNS@JOBSON.COM)

**DIRECTOR OF CE ADMINISTRATION** • REGINA COMBS  
(212) 274-7160 • [RCOMBS@JOBSON.COM](mailto:RCOMBS@JOBSON.COM)

**SPECIAL PROJECTS** • JANE COLE  
(610) 492-1043 • [JCOLE@JOBSON.COM](mailto:JCOLE@JOBSON.COM)

#### EDITORIAL BOARD

- CHIEF CLINICAL EDITORS** • PAUL M. KARPECKI, OD;  
CHRISTINE W. SINDT, OD
- ASSOCIATE CLINICAL EDITORS** • JOSEPH P. SHOVLIN, OD;  
ALAN G. KABAT, OD
- DIRECTOR OPTOMETRIC PROGRAMS** • ARTHUR EPSTEIN, OD  
**CLINICAL & EDUCATION CONFERENCE ADVISOR** •  
PAUL M. KARPECKI, OD
- CASE REPORTS COORDINATOR** • ANDREW S. GURWOOD, OD
- CLINICAL CODING EDITOR** • JOHN RUMPAKIS, OD, MBA
- CONSULTING EDITOR** • FRANK FONTANA, OD
- EMERITUS CLINICAL EDITOR** • ROBERT M. COLE, III, OD


#### COLUMNISTS

- CHAIRSIDE** • MONTGOMERY VICKERS, OD
- COMANAGEMENT Q+A** • PAUL C. AJAMIAN, OD
- CORNEA & CONTACT LENS Q+A** • JOSEPH P. SHOVLIN, OD
- DIAGNOSTIC QUIZ** • ANDREW S. GURWOOD, OD
- GLAUCOMA GRAND ROUNDS** • JAMES L. FANELLI, OD
- RESEARCH REVIEW** • PAUL M. KARPECKI, OD;  
DIANA L. SHECHTMAN, OD
- RETINA QUIZ** • MARK T. DUNBAR, OD
- REVIEW OF SYSTEMS** • CARLO J. PELINO, OD;  
JOSEPH J. PIZZIMENTI, OD
- SURGICAL MINUTE** • DEREK N. CUNNINGHAM, OD;  
WALTER O. WHITLEY, OD, MBA
- THERAPEUTIC REVIEW** • JOSEPH W. SOWKA, OD;  
ALAN G. KABAT, OD

**Jobson**  
Professional Publications Group

JOBSON MEDICAL INFORMATION LLC





For patients with decreased tear production presumed to be due to ocular inflammation associated with Chronic Dry Eye

# RESTASIS® MAKES MORE OF THEIR OWN REAL TEARS POSSIBLE

Prescribe RESTASIS® for your appropriate moderate and severe Dry Eye patients and increase their own real tear production over time with continued use

For local co-pays,  
scan QR-code or visit  
[RESTASIScopay.com](http://RESTASIScopay.com)



**Indication and Usage:** RESTASIS® ophthalmic emulsion is indicated to increase tear production in patients whose tear production is presumed to be suppressed due to ocular inflammation associated with keratoconjunctivitis sicca. Increased tear production was not seen in patients currently taking topical anti-inflammatory drugs or using punctal plugs.

### Important Safety Information

**Contraindications:** RESTASIS® is contraindicated in patients with active ocular infections and in patients with known or suspected hypersensitivity to any of the ingredients in the formulation.

**Warning:** RESTASIS® has not been studied in patients with a history of herpes keratitis.

**Precautions:** The emulsion from one individual single-use vial is to be used immediately after opening for administration to one or both eyes, and the remaining contents should be discarded immediately after administration. Do not allow the tip of the vial to touch the eye or any surface, as this may contaminate the emulsion. RESTASIS® should not be administered while wearing contact lenses. If contact lenses are worn, they should be removed prior to the administration of the emulsion.

**Adverse Reactions:** The most common adverse event was ocular burning (upon instillation)—17%. Other events reported in 1% to 5% of patients included conjunctival hyperemia, discharge, epiphora, eye pain, foreign body sensation, pruritus, stinging, and visual disturbance (most often blurring).

Please see brief prescribing information on adjacent page.



©2012 Allergan, Inc., Irvine, CA 92612  
\*marks owned by Allergan, Inc. APC74CS12 120416



[restasisprofessional.com](http://restasisprofessional.com)

## RESTASIS®

(cyclosporine ophthalmic emulsion) 0.05%  
Sterile, Preservative-Free

### INDICATIONS AND USAGE

**RESTASIS®** ophthalmic emulsion is indicated to increase tear production in patients whose tear production is presumed to be suppressed due to ocular inflammation associated with keratoconjunctivitis sicca. Increased tear production was not seen in patients currently taking topical antiinflammatory drugs or using punctal plugs.

### CONTRAINDICATIONS

**RESTASIS®** is contraindicated in patients with active ocular infections and in patients with known or suspected hypersensitivity to any of the ingredients in the formulation.

### WARNING

**RESTASIS®** ophthalmic emulsion has not been studied in patients with a history of herpes keratitis.

### PRECAUTIONS

General: For ophthalmic use only.

#### Information for Patients

The emulsion from one individual single-use vial is to be used immediately after opening for administration to one or both eyes, and the remaining contents should be discarded immediately after administration.

Do not allow the tip of the vial to touch the eye or any surface, as this may contaminate the emulsion.

**RESTASIS®** should not be administered while wearing contact lenses. Patients with decreased tear production typically should not wear contact lenses. If contact lenses are worn, they should be removed prior to the administration of the emulsion. Lenses may be reinserted 15 minutes following administration of **RESTASIS®** ophthalmic emulsion.

#### Carcinogenesis, Mutagenesis, and Impairment of Fertility

Systemic carcinogenicity studies were carried out in male and female mice and rats. In the 78-week oral (diet) mouse study, at doses of 1, 4, and 16 mg/kg/day, evidence of a statistically significant trend was found for lymphocytic lymphomas in females, and the incidence of hepatocellular carcinomas in mid-dose males significantly exceeded the control value.

In the 24-month oral (diet) rat study, conducted at 0.5, 2, and 8 mg/kg/day, pancreatic islet cell adenomas significantly exceeded the control rate in the low dose level. The hepatocellular carcinomas and pancreatic islet cell adenomas were not dose related. The low doses in mice and rats are approximately 1000 and 500 times greater, respectively, than the daily human dose of one drop (28 µL of 0.05% **RESTASIS®** BID into each eye of a 60 kg person (0.001 mg/kg/day), assuming that the entire dose is absorbed.

Cyclosporine has not been found mutagenic/genotoxic in the Ames Test, the V79-HGPRT Test, the micronucleus test in mice and Chinese hamsters, the chromosome-aberration tests in Chinese hamster bone-marrow, the mouse dominant lethal assay, and the DNA-repair test in sperm from treated mice. A study analyzing sister chromatid exchange (SCE) induction by cyclosporine using human lymphocytes in vitro gave indication of a positive effect (i.e., induction of SCE).

No impairment in fertility was demonstrated in studies in male and female rats receiving oral doses of cyclosporine up to 15 mg/kg/day (approximately 15,000 times the human daily dose of 0.001 mg/kg/day) for 9 weeks (male) and 2 weeks (female) prior to mating.

#### Pregnancy-Teratogenic Effects

Pregnancy category C.

**Teratogenic Effects:** No evidence of teratogenicity was observed in rats or rabbits receiving oral doses of cyclosporine up to 300 mg/kg/day during organogenesis. These doses in rats and rabbits are approximately 300,000 times greater than the daily human dose of one drop (28 µL) 0.05% **RESTASIS®** BID into each eye of a 60 kg person (0.001 mg/kg/day), assuming that the entire dose is absorbed.

**Non-Teratogenic Effects:** Adverse effects were seen in reproduction studies in rats and rabbits only at dose levels toxic to dams. At toxic doses (rats at 30 mg/kg/day and rabbits at 100 mg/kg/day), cyclosporine oral solution, USP, was embryo- and fetotoxic as indicated by increased pre- and postnatal mortality and reduced fetal weight together with related skeletal retardations. These doses are 30,000 and 100,000 times greater, respectively than the daily human dose of one drop (28 µL) of 0.05% **RESTASIS®** BID into each eye of a 60 kg person (0.001 mg/kg/day), assuming that the entire dose is absorbed. No evidence of embryofetal toxicity was observed in rats or rabbits receiving cyclosporine at oral doses up to 17 mg/kg/day or 30 mg/kg/day, respectively, during organogenesis. These doses in rats and rabbits are approximately 17,000 and 30,000 times greater, respectively, than the daily human dose.

Offspring of rats receiving a 45 mg/kg/day oral dose of cyclosporine from Day 15 of pregnancy until Day 21 postpartum, a maternally toxic level, exhibited an increase in postnatal mortality; this dose is 45,000 times greater than the daily human topical dose, 0.001 mg/kg/day, assuming that the entire dose is absorbed. No adverse events were observed at oral doses up to 15 mg/kg/day (15,000 times greater than the daily human dose).

There are no adequate and well-controlled studies of **RESTASIS®** in pregnant women. **RESTASIS®** should be administered to a pregnant woman only if clearly needed.

#### Nursing Mothers

Cyclosporine is known to be excreted in human milk following systemic administration but excretion in human milk after topical treatment has not been investigated. Although blood concentrations are undetectable after topical administration of **RESTASIS®** ophthalmic emulsion, caution should be exercised when **RESTASIS®** is administered to a nursing woman.

#### Pediatric Use

The safety and efficacy of **RESTASIS®** ophthalmic emulsion have not been established in pediatric patients below the age of 16.

#### Geriatric Use

No overall difference in safety or effectiveness has been observed between elderly and younger patients.

#### ADVERSE REACTIONS

The most common adverse event following the use of **RESTASIS®** was ocular burning (17%).

Other events reported in 1% to 5% of patients included conjunctival hyperemia, discharge, epiphora, eye pain, foreign body sensation, pruritus, stinging, and visual disturbance (most often blurring).

#### Rx Only



Based on package insert 71876US14B Revised February 2010

©2010 Allergan, Inc., Irvine, CA 92612, U.S.A.

®marks owned by Allergan, Inc. APC74CS12

U.S. Patent 5,474,979

Made in the U.S.A.

## CONTRIBUTING EDITORS

PAUL C. AJAMIAN, OD, ATLANTA

JEFFREY R. ANSHEL, OD, CARLSBAD, CALIF.

JILL AUTRY, OD, RPH, HOUSTON

SHERRY J. BASS, OD, NEW YORK

MILE BRUJIC, OD, BOWLING GREEN, OHIO

WALTER L. CHOATE, OD, MADISON, TENN.

ROBERT M. COLE, III, OD, BRIDGETON, NJ

DEREK N. CUNNINGHAM, OD, AUSTIN, TEXAS

ANTHONY S. DIECIDUE, OD, STROUDSBURG, PA.

MARK T. DUNBAR, OD, MIAMI

S. BARRY EIDEN, OD, DEERFIELD, ILL.

ARTHUR B. EPSTEIN, OD, PHOENIX

JAMES L. FANELLI, OD, WILMINGTON, NC

FRANK FONTANA, OD, ST. LOUIS

GARY S. GERBER, OD, HAWTHORNE, NJ

ANDREW S. GURWOOD, OD, PHILADELPHIA

MILTON HOM, OD, AZUSA, CALIF.

ALAN G. KABAT, OD, FORT LAUDERDALE, FLA.

PAUL M. KARPECKI, OD, LEXINGTON, KY.

JEROME A. LEGERTON, OD, MBA, SAN DIEGO

THOMAS L. LEWIS, OD, PHD, PHILADELPHIA

DOMINICK MAINO, OD, MED, CHICAGO

JASON R. MILLER, OD, MBA, POWELL, OHIO

PAMELA J. MILLER, OD, JD, HIGHLAND, CALIF.

CHERYL G. MURPHY, OD, HOLBROOK, NY

JOHN W. POTTER, OD, MA, DALLAS

CHRISTOPHER J. QUINN, OD, ISELIN, NJ

JOHN L. SCHACHET, OD, ENGLEWOOD, COLO.

JACK SCHAEFFER, OD, BIRMINGHAM, ALA.

CAROL SCHWARTZ, OD, MBA, SAN JOSE DEL CABO, MEXICO

JEROME SHERMAN, OD, NEW YORK

JOSEPH P. SHOVLIN, OD, SCRANTON, PA.

JOSEPH W. SOWKA, OD, FORT LAUDERDALE, FLA.

LORETTA B. SZCZOTKA, OD, PHD, CLEVELAND

MONTGOMERY VICKERS, OD, ST. ALBANS, W.VA.

KATHY C. WILLIAMS, OD, SEATTLE

## EDITORIAL REVIEW BOARD

EDWARD S. BENNETT, OD, ST. LOUIS

MARC R. BLOOMENSTEIN, OD, SCOTTSDALE, ARIZ.

CHRIS J. CAKANAC, OD, MURRYSVILLE, PA.

JERRY CAVALLERANO, OD, PHD, BOSTON

BRIAN CHOU, OD, SAN DIEGO

A. PAUL CHOUS, MA, OD, TACOMA, WASH.

GLENN S. CORBIN, OD, WYOMISSING, PA.

STEVEN FERRUCCI, OD, SEPULVEDA, CALIF.

MURRAY FINGERET, OD, HEWLETT, NY

IAN BEN GADDIE, OD, LOUISVILLE, KY.

MATTHEW J. GARSTON, OD, BOSTON

ROBERT M. GROHE, OD, HOMEWOOD, ILL.

ANDREW S. GURWOOD, OD, PHILADELPHIA

NICKY HOLDEMAN, OD, MD, HOUSTON

MILTON HOM, OD, AZUSA, CALIF.

WILLIAM L. JONES, OD, ALBUQUERQUE, NM

ALAN G. KABAT, OD, FORT LAUDERDALE, FLA.

PAUL M. KARPECKI, OD, LEXINGTON, KY.

RICHARD B. MANGAN, OD, RICHMOND, IND.

RON MELTON, OD, CHARLOTTE, NC

BRUCE MUCHNICK, OD, COATESVILLE, PA.

MARC MYERS, OD, COATESVILLE, PA.

CARLO J. PELINO, OD, JENKINTOWN, PA.

JOSEPH PIZZIMENTI, OD, FORT LAUDERDALE, FLA.

WILLIAM B. POTTER, OD, FREEHOLD, NJ

JOHN RUMPAKIS, OD, MBA, PORTLAND, ORE.

MICHAEL C. RADOIU, OD, STAUNTON, VA.

LEO P. SEMES, OD, BIRMINGHAM, ALA.


DIANA L. SHECHTMAN, OD, FORT LAUDERDALE, FLA.

LEONID SKORIN, JR., OD, DO, ROCHESTER, MINN.

JOSEPH W. SOWKA, OD, FORT LAUDERDALE, FLA.

RANDALL THOMAS, OD, CONCORD, NC

WALTER O. WHITLEY, OD, MBA, VIRGINIA BEACH, VA.



# IMAGINE THE ABILITY TO UNLOCK NEW TREATMENT POSSIBILITIES

Alcon is dedicated to developing  
pharmaceutical treatments for  
patients with glaucoma.

**Alcon**<sup>®</sup>

a Novartis company

© 2013 Novartis 1/13 MG12134JAD

## Optometry in Nepal

*Editor's note: This letter, written by an optometry student in Nepal, provides US optometrists with a perspective on optometric professional status in a very different country.*

The only optometry program in the country of Nepal is run at the Institute of Medicine, in Kathmandu, in collaboration with the University of Auckland, New Zealand. This is a four-year bachelor's program that began in 1998 and has graduated 70 optometrists to date—the sum total of optometrists in Nepal. The institute is now having a greater impact than ever.

The first year consists of basic sciences. The second and third years consist of rigorous clinical hours, including special clinics such as glaucoma, neuro-ophthalmology, retina, contact lenses, low vision, etc. The final year consists of a thesis, as

*Currently, Nepal is short of an estimated 534 optometrists ... Annual income of an optometrist is \$3,000 [in US dollars] on average.*

well as two months of [internship] and one month of community diagnosis. Also, PowerPoint presentations are conducted every morning before the start of outpatient rounds.

Many graduating optometrists enter into private practice, while some work in hospitals or opt for further education. Currently, Nepal is short of an estimated 534 optometrists, according to “Mid Term Review of Vision 2020: The Right to Sight, Government of Nepal 2011.” Regarding the investment and the course of study, annual income of an optometrist is \$3,000 [in US dollars] on average, which in comparison to other health professionals in Nepal is quite low.

Some of the major [professional] constraints faced by optometrists right now include confinement of optometrists as refractionists in hospitals, shortage of diagnostic instruments in private practice, and fewer chances of scholarship outside the country for further studies.

However, optometrists are well equipped to play a major role as front line eye care practitioners. But perception among other specialists, such as ophthalmologists, neurologists, pediatricians and general physicians, is quite variable. They are unaware of the role an optometrist can play in the multispecialty consultation and as a primary eye care physician.

Due to the lack of an optometry council, optometrists are registered with the Nepal Health Professional Council, a government organization, before starting professional life. The Nepalese Association of Optometrists (NAO), a self-regulating body established to accredit practitioners against a set of guidelines, passed a code of ethics in 2011 and has started administering a licensing examination to regulate the profession.

The NAO faces several challenges, such as establishing a peer review optometry council of Nepal, actively lobbying the government to obtain independent status for optometry, creating public awareness about optometry and its contribution to society, and

## Sight Gags

By Scott Lee, O.D.

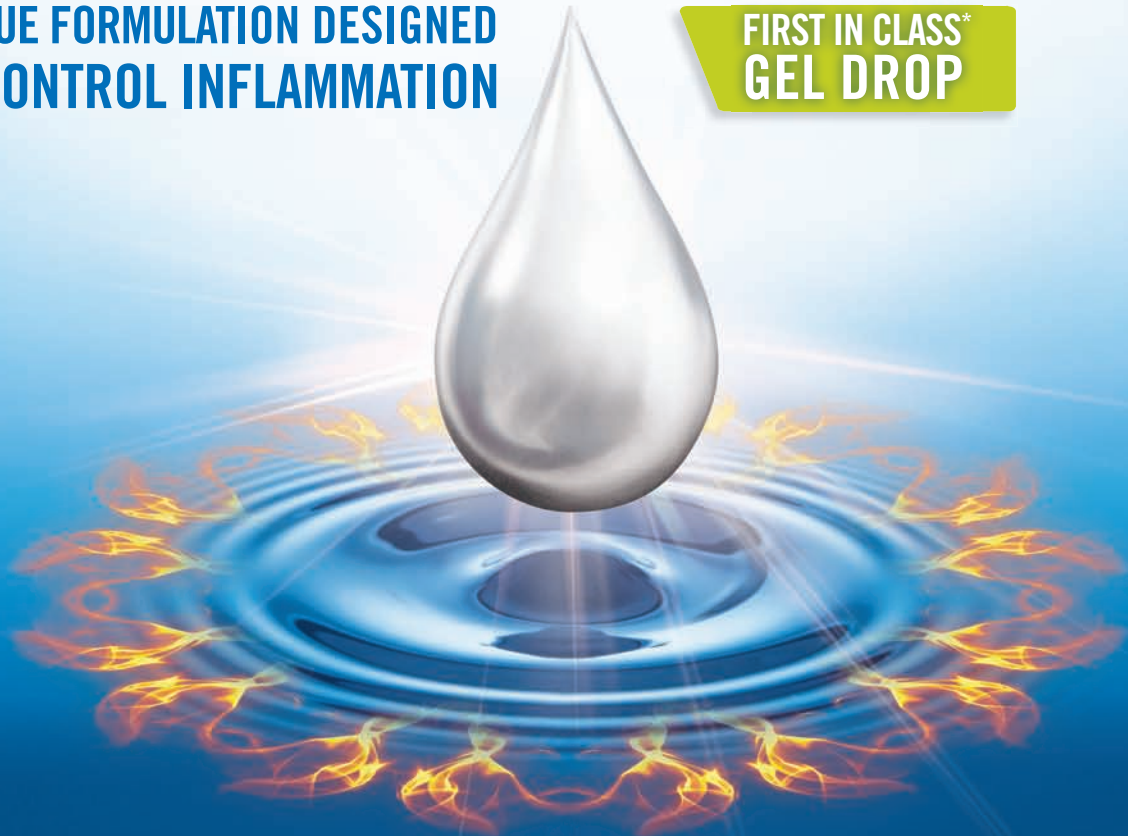




# NOW AVAILABLE LOTEMAX® GEL

**UNIQUE FORMULATION DESIGNED  
TO CONTROL INFLAMMATION**

**FIRST IN CLASS\*  
GEL DROP**



#### Indications and Usage

- LOTEMAX® GEL is a corticosteroid indicated for the treatment of post-operative inflammation and pain following ocular surgery

#### Important Risk Information about LOTEMAX® GEL

- LOTEMAX® GEL is contraindicated in most viral diseases of the cornea and conjunctiva including epithelial herpes simplex keratitis (dendritic keratitis), vaccinia, and varicella, and also in mycobacterial infection of the eye and fungal diseases of ocular structures
- Intraocular pressure (IOP) increase—Prolonged use of corticosteroids may result in glaucoma with damage to the optic nerve, defects in visual acuity and fields of vision. If this product is used for 10 days or longer, IOP should be monitored
- Cataracts—Use of corticosteroids may result in posterior subcapsular cataract formation
- Delayed healing—Use of steroids after cataract surgery may delay healing and increase the incidence of bleb formation and occurrence of perforations in those with diseases causing corneal and scleral thinning. The initial prescription and renewal of the medication order should be made by a physician only after examination of the patient with the aid of magnification

- Bacterial infections—Prolonged use of corticosteroids may suppress the host response and thus increase the hazard of secondary ocular infection. In acute purulent conditions, steroids may mask infection or enhance existing infections
- Viral infections—Use of corticosteroid medication in the treatment of patients with a history of herpes simplex requires great caution. Use of ocular steroids may prolong the course and exacerbate the severity of many viral infections of the eye (including herpes simplex)
- Fungal infections—Fungal infections of the cornea are particularly prone to develop coincidentally with long-term local steroid application. Fungus invasion must be considered in any persistent corneal ulceration where a steroid has been used or is in use
- Contact lens wear—Patients should not wear contact lenses when using LOTEMAX® GEL
- The most common ocular adverse drug reactions were anterior chamber inflammation (5%), eye pain (2%) and foreign body sensation (2%)

Please see brief summary of full prescribing information on adjacent page.

\*Ophthalmic corticosteroid.

References: 1. LOTEMAX GEL Prescribing Information, September 2012. 2. Fong R, Leitritz M, Siou-Mermet R, Erb T. Loteprednol etabonate gel 0.5% for postoperative pain and inflammation after cataract surgery: results of a multicenter trial. *Clin Ophthalmol*. 2012;6:1113-1124. 3. Data on file, Bausch & Lomb Incorporated.

©/™ are trademarks of Bausch & Lomb Incorporated or its affiliates. ©2012 Bausch & Lomb Incorporated. US/LGX/12/0066 [12/12]



**LOTEMAX® GEL**  
loteprednol etabonate  
ophthalmic gel 0.5%  
DISCOVER THE POWER OF GEL

**BAUSCH + LOMB**

**BAUSCH + LOMB**

**LOTEMAX<sup>®</sup>**

loteprednol etabonate  
ophthalmic gel 0.5%

**Brief Summary:** Based on full prescribing information.

To report SUSPECTED ADVERSE REACTIONS, contact Bausch & Lomb at 1-800-323-0000 or FDA at 1-800-FDA-1088 or [www.fda.gov/medwatch](http://www.fda.gov/medwatch)

#### INDICATIONS AND USAGE

LOTEMAX is a corticosteroid indicated for the treatment of post-operative inflammation and pain following ocular surgery.

#### DOSAGE AND ADMINISTRATION

Invert closed bottle and shake once to fill tip before instilling drops.

Apply one to two drops of LOTE MAX into the conjunctival sac of the affected eye four times daily beginning the day after surgery and continuing throughout the first 2 weeks of the post-operative period.

#### CONTRAINDICATIONS

LOTE MAX, as with other ophthalmic corticosteroids, is contraindicated in most viral diseases of the cornea and conjunctiva including epithelial herpes simplex keratitis (dendritic keratitis), vaccinia, and varicella, and also in mycobacterial infection of the eye and fungal diseases of ocular structures.

#### WARNINGS AND PRECAUTIONS

##### Intraocular Pressure (IOP) Increase

Prolonged use of corticosteroids may result in glaucoma with damage to the optic nerve, defects in visual acuity and fields of vision. Steroids should be used with caution in the presence of glaucoma. If this product is used for 10 days or longer, intraocular pressure should be monitored.

##### Cataracts

Use of corticosteroids may result in posterior subcapsular cataract formation.

##### Delayed Healing

The use of steroids after cataract surgery may delay healing and increase the incidence of bleb formation. In those diseases causing thinning of the cornea or sclera, perforations have been known to occur with the use of topical steroids. The initial prescription and renewal of the medication order should be made by a physician only after examination of the patient with the aid of magnification such as slit lamp biomicroscopy and, where appropriate, fluorescein staining.

##### Bacterial Infections

Prolonged use of corticosteroids may suppress the host response and thus increase the hazard of secondary ocular infections. In acute purulent conditions of the eye, steroids may mask infection or enhance existing infection.

##### Viral Infections

Employment of a corticosteroid medication in the treatment of patients with a history of herpes simplex requires great caution. Use of ocular steroids may prolong the course and may exacerbate the severity of many viral infections of the eye (including herpes simplex).

##### Fungal Infections

Fungal infections of the cornea are particularly prone to develop coincidentally with long-term local steroid application. Fungus invasion must be considered in any persistent corneal ulceration where a steroid has been used or is in use. Fungal cultures should be taken when appropriate.

##### Contact Lens Wear

Patients should not wear contact lenses during their course of therapy with LOTE MAX.

#### ADVERSE REACTIONS

Adverse reactions associated with ophthalmic steroids include elevated intraocular pressure, which may be associated with infrequent optic nerve damage, visual acuity and field defects, posterior subcapsular cataract formation, delayed wound healing and secondary ocular infection from pathogens including herpes simplex, and perforation of the globe where there is thinning of the cornea or sclera.

The most common adverse drug reactions reported were anterior chamber inflammation (5%), eye pain (2%), and foreign body sensation (2%).

#### USE IN SPECIFIC POPULATIONS

##### Pregnancy

##### Teratogenic Effects: Pregnancy Category C.

Loteprednol etabonate has been shown to be embryotoxic (delayed ossification) and teratogenic (increased incidence of meningocele, abnormal left common carotid artery, and limb flexures) when administered orally to rabbits during organogenesis at a dose of 3 mg/kg/day (35 times the maximum daily clinical dose), a dose which caused no maternal toxicity. The no-observed-effect-level (NOEL) for these effects was 0.5 mg/kg/day (6 times the maximum daily clinical dose). Oral treatment of rats during organogenesis resulted in teratogenicity (absent innominate artery at  $\geq 5$  mg/kg/day doses, and cleft palate and umbilical hernia at  $\geq 50$  mg/kg/day) and embryotoxicity (increased post-implantation losses at 100 mg/kg/day and decreased fetal body weight and skeletal ossification with  $\geq 50$  mg/kg/day). Treatment of rats with 0.5 mg/kg/day (6 times the maximum clinical dose) during organogenesis did not result in any reproductive toxicity. Loteprednol etabonate was maternally toxic (significantly reduced body weight gain during treatment) when administered to pregnant rats during organogenesis at doses of  $\geq 5$  mg/kg/day.

Oral exposure of female rats to 50 mg/kg/day of loteprednol etabonate from the start of the fetal period through the end of lactation, a maternally toxic treatment regimen (significantly decreased body weight gain), gave rise to decreased growth and survival, and retarded development in the offspring during lactation; the NOEL for these effects was 5 mg/kg/day. Loteprednol etabonate had no effect on the duration of gestation or parturition when administered orally to pregnant rats at doses up to 50 mg/kg/day during the fetal period.

There are no adequate and well controlled studies in pregnant women. LOTE MAX should be used during pregnancy only if the potential benefit justifies the potential risk to the fetus.

##### Nursing Mothers

It is not known whether topical ophthalmic administration of corticosteroids could result in sufficient systemic absorption to produce detectable quantities in human milk. Systemic steroids appear in human milk and could suppress growth, interfere with endogenous corticosteroid production, or cause other untoward effects. Caution should be exercised when LOTE MAX is administered to a nursing woman.

##### Pediatric Use

Safety and effectiveness in pediatric patients have not been established.

##### Geriatric Use

No overall differences in safety and effectiveness have been observed between elderly and younger patients.

#### NONCLINICAL TOXICOLOGY

##### Carcinogenesis, Mutagenesis, Impairment Of Fertility

Long-term animal studies have not been conducted to evaluate the carcinogenic potential of loteprednol etabonate. Loteprednol etabonate was not genotoxic *in vitro* in the Ames test, the mouse lymphoma tk assay, or in a chromosome aberration test in human lymphocytes, or *in vivo* in the single dose mouse micronucleus assay. Treatment of male and female rats with up to 50 mg/kg/day and 25 mg/kg/day of loteprednol etabonate, respectively, (600 and 300 times the maximum clinical dose, respectively) prior to and during mating did not impair fertility in either gender.

#### PATIENT COUNSELING INFORMATION

##### Administration

Invert closed bottle and shake once to fill tip before instilling drops.

##### Risk of Contamination

Patients should be advised not to allow the dropper tip to touch any surface, as this may contaminate the gel.

##### Contact Lens Wear

Patients should be advised not to wear contact lenses when using LOTE MAX.

##### Risk of Secondary Infection

If pain develops, redness, itching or inflammation becomes aggravated, the patient should be advised to consult a physician.

#### FOR MORE DETAILED INFORMATION, PLEASE READ THE PRESCRIBING INFORMATION.

Bausch & Lomb Incorporated

Tampa, Florida 33637 USA

US Patent No. 5,800,807

©Bausch & Lomb Incorporated

®/™ are trademarks of Bausch & Lomb Incorporated or its affiliates.

opening a new optometry school with a common minimum optometry curriculum to meet the increasing demand.

Uncorrected refractive error being the major cause of visual impairment in the world and the integration of eye health into general health now on anvil, optometrists in Nepal are in a pivotal state of bearing huge responsibility to provide comprehensive eye and vision care at all levels, freeing up ophthalmologists for surgery and treatment of complex cases. This, ultimately, plays a vital role in inter-professional communication through a common referral system. [*Editor's note: Nepal currently has only 150 ophthalmologists serving a population of nearly 27 million.*]



**Optometry students and faculty at the Institute of Medicine, in Kathmandu, Nepal.**

In Nepal, optometry is in its adolescence and needs further regulation and standardization to fulfill the responsibilities bestowed upon it. Considering the primary access by the public, the skills and services provided by the optometrists, and the contribution to knowledge by optometric research, optometry must be considered an independent profession and be afforded an independent government-controlled council, such as those of pharmacy and dentistry. The optometrist, being the first line of contact in eye care, must be legislated to work independently in order to provide essential eye care services across the country to detect various systemic diseases in the population and to work in collaboration with ophthalmologists and other medical and rehabilitation professionals.

Some of our graduates are pursuing higher de-

*I am guilty of a poor word choice in suggesting we convert optometry schools into med schools. Apparently that already has been done. All that's required is just renaming or rebranding.*

grees at several world-renowned universities in eye care, such as SUNY College of Optometry in New York, University of New South Wales and Flinders University in Australia, London School of Hygiene and Tropical Medicine in the UK, and the University of Auckland in New Zealand. But due to poor job security, low incentives, a shortage of facilities and a lack of opportunities in the research field in Nepal, these optometrists are facing a hard time returning to their own country.

—Sudarshan Khanal, fourth-year student  
Bachelor of Optometry, Institute of Medicine,  
Kathmandu, Nepal

### More Medical Model Muddle Trouble

First, I want to thank Dr. Brittany Schauer for proving that someone actually reads the Letters to the Editor column. (“Medical Model Muddle Rebuttal,” December 2012.) I was beginning to think otherwise, as her rebuttal is the only indication that anyone actually read either of my two published letters.

Second, it is a bit discouraging to realize that I am such a poor communicator. The sole purpose of my letter was not to belittle recent and current optometry school graduates, but quite the opposite. It’s my opinion that someone who graduates from a med school should be awarded a medical degree, i.e. Brittany G. Schauer, OD, should really be Brittany G. Schauer, MD. Any anyone who doesn’t agree that the MD degree is far more prestigious is not bright enough to own either degree.

Lastly, I am guilty of a poor word choice in suggesting we *convert* optometry schools into med schools. Apparently that already has been done. All that’s required is just renaming or rebranding.

Thanks again Dr. Schauer for reading the column.

—John Clark Moffett, OD  
Dallas

To send a Letter to the Editor, e-mail Jack Persico, editor-in-chief, [jpersico@jobson.com](mailto:jpersico@jobson.com), with “Letter to the Editor” as the subject line. ■



# Pride and Prejudice

Optometrists can, and should, play a key role in the new health exchanges. It will be an uphill battle, but one worth waging. **By Jack Persico, Editor-in-Chief**

One of my guilty pleasures is *Downton Abbey*, PBS's upper-crust costume drama about the waning years of the British aristocracy. Usually, the plots concern whether Robert Crawley and his family will remain obscenely wealthy or might end up just "comfortably" wealthy. But a recent heart-breaking episode hinged on a dispute between two doctors, a generalist from Yorkshire and a specialist from London, with life-or-death consequences for a pregnant woman.

The country doctor—kindly Dr. Clarkson, a generalist—had known the patient all her life and was attuned to changes that the fancy-pants city doctor missed. The Lord of the manor, himself a slave

to the rigors of the social pecking order, refused to second-guess the esteemed obstetrician. And the prideful specialist dismissed the warnings of the generalist out of hand. All watched in horror as the patient died of eclampsia, just as Dr. Clarkson had predicted. The Crawleys learned, too late, that titles don't matter—results do.

It reminded me a bit of the battle ODs have fought for over 40 years to expand their scope of practice, which began in 1971 and continues to this day. To many, especially laypersons with no knowledge of the day-to-day workings of health care, a title automatically confers authority and stature. It's a bias optometry has worked tenaciously to neutralize in every battle over TPA laws.

While important in its own right (to say the least), scope of practice expansion might even be eclipsed by the importance of ensuring a place for optometry in the health exchanges that will arise as part of the Patient Protection and Affordable Care Act (PPACA), which goes into effect in just under a year.

The stakes are high. As Cheryl Murphy, OD, discusses this month (see "How and Why to Get Behind Health Exchanges," page 46), millions of patients will join the insurance rolls, and expanding primary/preventive care is a key goal of the legislation. Clearly, optometric involvement—indeed, leadership—in this facet of the PPACA makes sense in many ways: the manpower advantage over MDs, the cost effectiveness argument and the eminent suitability of optometrists for the responsibilities of primary eye care.

But optometry isn't guaranteed a place on the provider panels of the health exchanges; rather, these must be fought for. Once on board, you cannot be discriminated against—thanks to the Harkin Amendment of the PPACA—but it will require effort, individually and collectively, for ODs to participate to the full extent of their capabilities.

Rights that come by way of the statehouse are tedious to obtain, and tenuous to maintain. The legislature giveth and the legislature can taketh away. Optometry scored a huge victory with the Harkin Amendment. Don't let it go to waste.

As Dr. Clarkson found, skills are only of value when put to use. ■

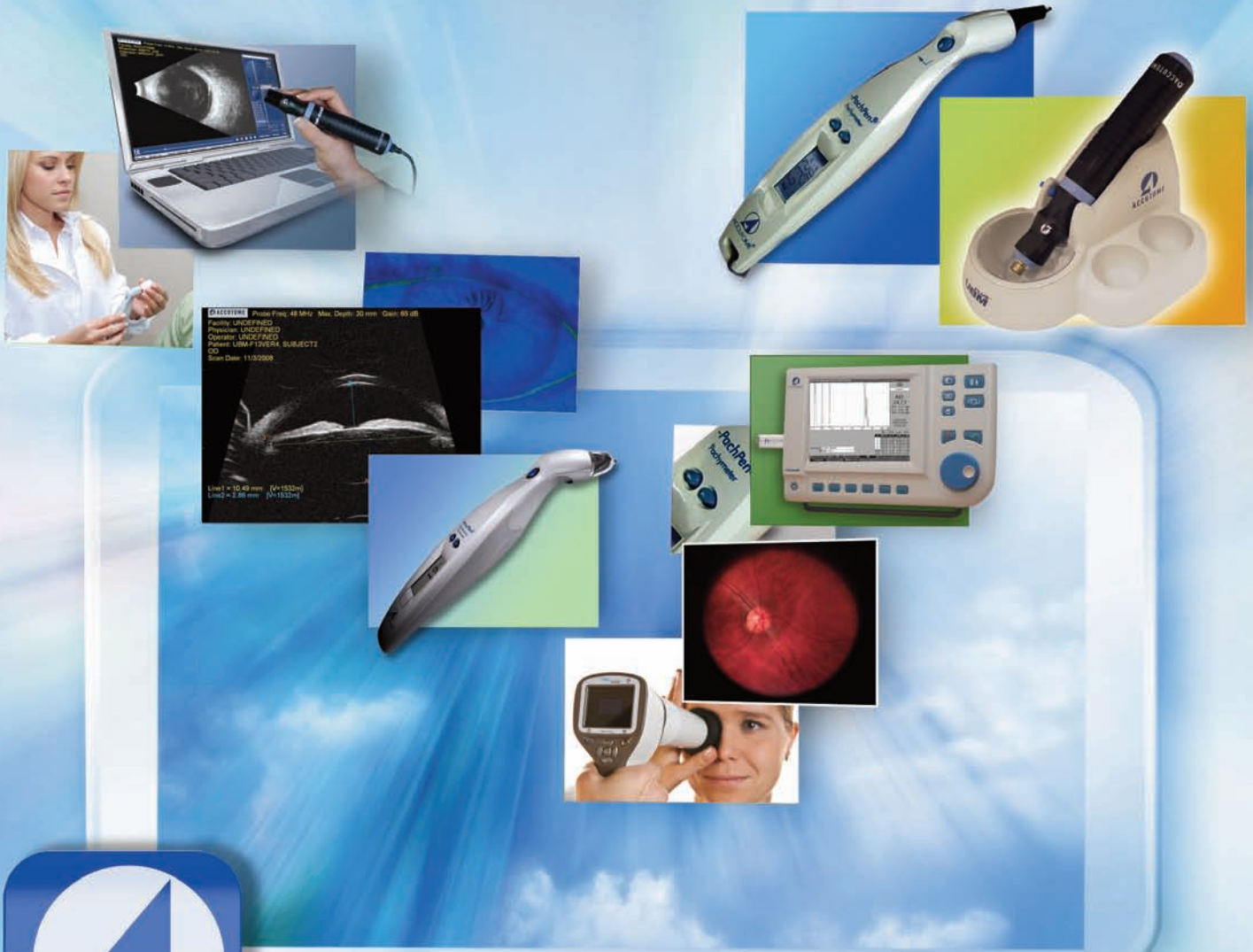## Honoring an Eyecare Education Visionary

We are pleased to announce that Jobson Healthcare is establishing a non-profit foundation in memory of Rick Bay, Publisher/President of *Review of Optometry* and *Review of Ophthalmology*, who succumbed to illness in late 2012 after a decades-long career of tireless dedication to the betterment of eyecare through publishing and live educational events.

The Rick Bay Foundation for Excellence in Eyecare Education will provide annual scholarships in both optometry and ophthalmology education. Each of the selected students will be chosen by their school based on qualities that embody Rick's commitment to the profession, including integrity, compassion, partnership and dedication to the greater good.

The Rick Bay Excellence in Eyecare Education Scholarship in Optometry will be awarded to a student at Pennsylvania College of Optometry at Salus University, Elkins Park, PA, and The Rick Bay Excellence in Eyecare Education Scholarship in Ophthalmology will be awarded to a student at Wills Eye Institute, Thomas Jefferson University Hospital, Philadelphia, PA.

Those who wish to honor Rick's memory and to help establish a lasting legacy with a contribution to the Foundation should contact Lois DiDomenico for details at [ldidomenico@jobson.com](mailto:ldidomenico@jobson.com).



## Our Portable Solutions are like an App for Your Entire Office.

Accutome specializes in high-quality, portable diagnostic equipment that can be easily transported from lane-to-lane or office-to-office. Call to find out how you can improve your practice's versatility.

- AccuPen® Handheld Tonometer
- PachPen® Handheld Pachymeter
- Pictor Handheld Retina and Anterior Segment Camera
- B-Scan Plus®
- UBM Plus®
- A-Scan Plus®



# A Sore Site for Eyes

Building a website is exciting—like training to be a NAVY Seal. Of course, I'm not a NAVY Seal, but I bet it's exciting—like building a website! **By Montgomery Vickers, OD**

Optometric gurus tell us that we all need a web presence. So far, my web presence consists of old high school photos that some well-meaning Class of 1971 alumnus felt the need to post on Facebook. They show me as a nerdy, dirty-haired, skinny, hippie wannabe. I have changed completely since then. Now I am not skinny.

I've tried the deal where you join an optometry group and they build the website. This is not very patient friendly, as your business cards are too small to hold the website name, which is always something like this: [www.eyeprotectorsoftheworldwhojusthappenedtojointhisorganizationsoewouldbuildthemawebsite-causetheyare2lazy2doagoodjob-themselves/drmonty.vickers.com](http://www.eyeprotectorsoftheworldwhojusthappenedtojointhisorganizationsoewouldbuildthemawebsite-causetheyare2lazy2doagoodjob-themselves/drmonty.vickers.com).

Patients tend to not want to spend 20 minutes typing just to see a page that lists your address, except they got the town wrong.

I've also had phone book type websites. These are wonderful vehicles for making more money... for the phone book advertising company. Also, if you say the words "phone book" to anyone under 45 years old, they will immediately text you, "Is that where you illegally bet on which cell phone will win?" Or, even better, "What's a 'book'?" This is not a great way to bring younger, sophisticated, stylish smartphone addicts into your office. Oh, and they also got my address wrong in the ad, but will fix it in one year. The good news is they can track how often somebody

calls you from the special number in the phone book and I want to thank my Mom for calling me 300 days in a row from the special number in the phone book. (In case Mom reads this column because my cousin tells her how to turn on the computer again: Yes, Mom, you do need to take the eye drop every day, so please don't call.)

So, we're starting anew with fresh, innovative ideas, such as listing our address and phone number correctly.

## Get a 'Social' Life

Now, I've been warned that a website is not enough. We must also have a social media presence and I've been advised that my high school pictures don't count. We need professional content that helps tell our own story in our own words that the company will supply so I will not screw it up with bad optometry jokes. They did ask me if I had ever been published in a professional journal because that, apparently, carries some weight with search engines and with prospective patients who might randomly search for "optometrists named Monty." They carefully researched my 22 years of "Chairside" and concluded that the only articles I ever wrote that would attract Internet-savvy patients would be either the one on

Thor, God of Thunder—and it would even be better if I would somehow blend these two important optometric articles into something like, "Thor Needs Toilets."

Now, I'm busy collecting professional photos of me doing what optometrists love to do—taking care of patients and eating hot wings—for the new website, which should be up and running about two weeks after I retire.

This is an exciting time in our profession and I urge all of you to enjoy the next patient who comes in as much as you were terrified by the previous patient who asked about online glasses. Take a deep breath and build your web presence so your patients, for the first time, can see who you truly are, deep down inside your soul, according to website builders who do not know you from Adam.

Mom, text me. ■



# EYEDESIGNS.COM



Lake Oswego Vision Clinic Lake Oswego, OR



Visual Eyes At Mizner Park Boca Raton, FL



Lord Eye Center Brunswick, GA



GET STARTED



VISIT US TODAY

SPACE PLANNING

INTERIOR DESIGN

DISPLAY INNOVATION

MANUFACTURING

## EYEDESIGNS®

VISIT [WWW.EYEDESIGNS.COM](http://WWW.EYEDESIGNS.COM) OR CALL 800.346.8890



# T Minus 11 and Counting...

So, you say you met the standards for meaningful use? Well, here comes the audit.

By **John Rumpakis, OD, MBA, Clinical Coding Editor**

It's T minus 11 months until the Affordable Care Act (ACA) fully kicks in. So, let's visit another timely issue: meaningful use. A year or two ago, those phrases were music to the average doctor's ears... "What's that you said? All I have to do is upgrade my EHR software, and attest that I'm doing certain things in my practice on a continuous basis for 90 days in my first year and then the whole year for each of the remaining, and I can get up to 75% of my Medicare billings or \$44,000 per doctor? Holy crap, where do I sign up?" February 28, 2013, is the last day for Medicare-eligible professionals (EPs) to register and attest to receive an incentive payment for calendar year (CY) 2012.

that you are actually doing what you said you were doing, or else. Yep, the attestation audits have begun. If you're not doing what you claimed you were doing to meet the standards of Phase I meaningful use requirements, that money is now in jeopardy.

If you've forgotten what "attestation" is, here's a reminder: Attestation means you have met the thresholds and all of the requirements of the Medicare EHR Incentive Program. The process of attestation happened through an Internet-based CMS system that allowed you to enter information on all of the following:

- 15 core objectives
- Five out of 10 menu objectives
- Three core (or three alternate

development costs to ensure that their systems could get certified for meaningful use, and you had to make sure that you did your part in using that extended functionality on a continuous basis.

Well, the government is now finding out that many practitioners said they were meeting the standards but actually weren't, and it may start asking for its money back.

So, what can you do? First, check out this website that CMS has created for FAQs regarding its guidelines for documentation and proof: <https://questions.cms.gov/faq.php?faqId=7711>.

If you're just now attesting, please make sure that you document everything and retain it.

If you've already attested, make sure that you're doing everything (and I really mean *everything*) that you said you were doing to meet the requirements. If you aren't doing everything, then document a plan to solve the problem and document your progress on fixing it. You need to be bulletproof.

For these audits, it may not be a question of *if* it will happen, but a question of *when*. So, should you get that letter for a meaningful use attestation, be sure your house is in order and you can survive to work another day. ■

1. Centers for Medicare & Medicaid Services website. Medicare EHR Incentive Program, Physician Quality Reporting System and e-Prescribing Comparison. March 2011. Available at: [www.cms.gov/Outreach-and-Education/Medicare-Learning-Network-MLN/MLNProducts/downloads/EHRIncentivePayments-ICN903691.pdf](http://www.cms.gov/Outreach-and-Education/Medicare-Learning-Network-MLN/MLNProducts/downloads/EHRIncentivePayments-ICN903691.pdf). Accessed January 31, 2013.

## Calendar Year (CY) for Which EP Receives an Incentive Payment<sup>1</sup>

	CY 2011	CY 2012	CY 2013	CY 2014	CY 2015 and later
<b>CY 2011</b>	\$18,000				
<b>CY 2012</b>	\$12,000	\$18,000			
<b>CY 2013</b>	\$8,000	\$12,000	\$15,000		
<b>CY 2014</b>	\$4,000	\$8,000	\$12,000	\$12,000	
<b>CY 2015</b>	\$2,000	\$4,000	\$8,000	\$8,000	\$0
<b>CY 2016</b>		\$2,000	\$4,000	\$4,000	\$0
<b>TOTAL</b>	\$44,000	\$44,000	\$39,000	\$24,000	\$0

And now the government is coming to check on you to see that its money was well spent. Yes, folks, the days of "easy money" are over. Remember, the purpose of meaningful use is to demonstrate that you are using your EHR to positively affect the care and outcomes of your patients. Now the Centers for Medicare & Medicaid Services (CMS) will make you demonstrate

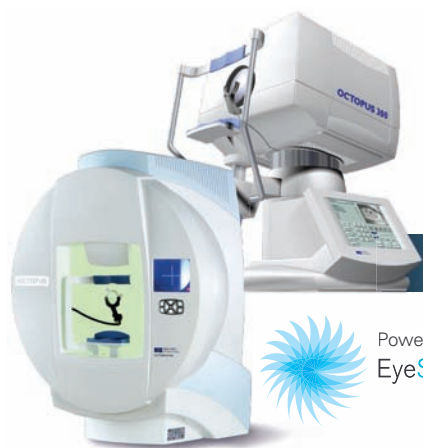core) clinical quality measures

- Three out of 38 additional clinical quality measures

In order to get this money, one of the things that you had to do was to certify that you had met the standards and that your office management system and EHR system were up to the task of doing so. The software manufacturers had to spend significant dollars in



Your Octopus  
data will connect  
with your satellite  
office 37,000  
times faster.



Octopus connectivity launches a new era in perimetry. One where doctors are always linked in real time to crucial patient data. Wherever you are online, your expertise can go to work instantly. From a satellite office, exam room, or somewhere more far out.

**Call 1-800-787-5426 and schedule an online demo.**



**The Superior Practice.**

# Keep an Eye Out for OSA

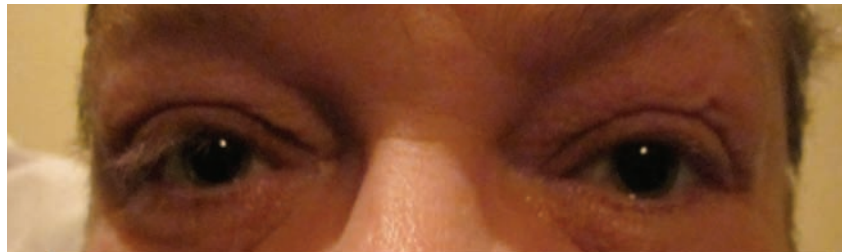What does obstructive sleep apnea have to do with eye care? A lot, actually. Make sure you're staying on top of the associated ophthalmic complications. **By Brad Sutton, OD**

First recognized nearly 50 years ago, obstructive sleep apnea has become an increasingly common condition in the United States.<sup>1</sup> The reported incidence rate varies substantially—with a high of 9% in the female Caucasian population and 24% in the male Caucasian population.<sup>2</sup> More than 80% of patients with OSA are believed to be undiagnosed, and many more are diagnosed but go untreated for a variety of reasons; just 10% of all OSA sufferers receive treatment.<sup>3</sup>

What does this potentially deadly sleep disorder have to do with eye care? Well, the increasing prevalence of this condition in the US means you will more than likely see many patients with diagnosed, undiagnosed and/or untreated OSA in your office. And untreated sleep apnea leads to a host of systemic and ocular complications, so proper diagnosis and management are critical to the patient's overall health.

While it is possible that you could play a role in spotting the condition, it is certain that you will have to deal with some of the complications that accompany the disease.

In this article, we'll look at what OSA is and which patients may be at higher risk, as well as common



**1. Floppy eyelid syndrome in a patient with obstructive sleep apnea.**

systemic and ophthalmic conditions associated with sleep apnea.

## What's the Problem?

In patients with sleep apnea, the tissue of the soft palate collapses during sleep, partially occluding the airway. This obstruction leads to lapses in breathing and decreased oxygen saturation in the blood, which the brain senses. The body feels as if it needs to take a breath, so the patient gasps in an attempt to draw in more oxygen. Substantial snoring is almost universally present, and snoring that stops during prolonged periods of apnea (a Greek word meaning “without breath”) is a particularly distinctive symptom of OSA.

The typical OSA patient tends to possess a distinguishing set of traits, sometimes referred to as “Pickwick syndrome”—after an overweight, chronically sleepy character in the

Charles Dickens novel, *The Pickwick Papers*.<sup>1,4</sup> Sleep apnea is highly associated with the obesity epidemic facing our nation—as many, but certainly not all, OSA sufferers are also obese. The majority of patients with OSA are overweight individuals with a large neck circumference (usually greater than 17 inches). In addition, this condition afflicts males twice as often as females. African Americans are 2.5 times more likely to present with OSA than Caucasians.<sup>5</sup> In general, the risk significantly increases with age and is higher in smokers.

Sufferers are often sleepy and tired during the day, and report feeling as if they did not sleep even when they have gotten the seven to nine hours of rest recommended for adults. What these patients don't realize is that their sleep is often fragmented—disrupted each time the patient experiences an apneic

# If your presbyopic patients aren't experiencing clear binocular vision, they may not be in AIR OPTIX® AQUA Multifocal contact lenses.

## AIR OPTIX® AQUA Multifocal contact lenses:

- Are preferred by patients over other multifocal contact lenses<sup>1,2,3\*\*†</sup>
- Allow for a smooth transition from center-near to intermediate and distance zones
- Deliver improved binocular vision, predictable clinical results, and decreased fitting time due to a consistent ADD effect

## AIR OPTIX® AQUA Multifocal Contact Lenses

Make a smooth transition with a great multifocal lens

Learn more at [myalcon.com](http://myalcon.com)

#1  
multifocal  
lens<sup>4</sup>



\*Dk/t = 138 @ -3.00D. \*\*Among those with a preference. †As compared to PureVision® Multi-Focal and ACUVUE® OASYS® for PRESBYOPIA contact lenses. \*Trademarks are the property of their respective owners.

**Important information for AIR OPTIX® AQUA Multifocal (lotrafilcon B) contact lenses:** For daily wear or extended wear up to 6 nights for near/far-sightedness and/or presbyopia. Risk of serious eye problems (i.e. corneal ulcer) is greater for extended wear. In rare cases, loss of vision may result. Side effects like discomfort, mild burning or stinging may occur.

**References:** 1. In a randomized, subject-masked clinical study at 20 sites with 252 patients; significance demonstrated at the 0.05 level; Alcon data on file, 2009. 2. Rappon J. Center-near multifocal innovation: optical and material enhancements lead to more satisfied presbyopic patients. *Optom Vis Sci.* 2009;86:E-abstract 095557. 3. In a randomized, subject-masked clinical trial at 6 sites with 47 patients; significance demonstrated at the 0.05 level; Alcon data on file, 2008. 4. Based on a third-party industry report, 12 months ending October 2012; Alcon data on file.

See product instructions for complete wear, care and safety information.

**Alcon**

Rx only

© 2013 Novartis 12/12 AOM13003JAD

a Novartis company

# Sleep Apnea

event. Most OSA patients do not completely wake up during their nighttime episodes, so they are often unaware of what they are experiencing. Other individuals who sleep in the same room or share a home with these sufferers are more likely to be able to report the symptoms the patient is experiencing (e.g., snoring, waking up in the middle of the night and gasping for air).

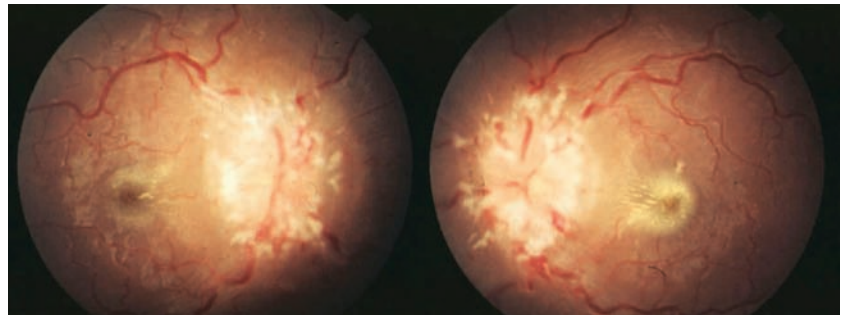
## Diagnostic Screening/Testing

Suspicion of OSA typically arises when patients experience the signs and symptoms previously discussed. Many different methods are used to make a formal diagnosis:

- **Epworth Sleepiness Scale.** This simple questionnaire is a very useful and cost-effective screening device. The patient self-reports the likelihood of dozing or falling asleep during various activities, such as reading, watching TV, riding in a car, etc. Each activity is assessed on a scale that ranges from never sleeping or dozing during the activity to having a high chance of doing so. An overall score is then tabulated and compared to a risk table.

- **At-home sleep testing.** At-home diagnostic testing for sleep disorders has become much more common in the past few years as more devices have become FDA approved and eligible for reimbursement. However, not all patients are good candidates for this type of testing and few insurance carriers cover it.

- **Polysomnography.** Polysomnography testing conducted in a sleep laboratory remains the gold standard in diagnosing OSA.<sup>6</sup> The patient will need to stay overnight in a sleep laboratory and will be hooked up to sensors that measure various parameters regarding their sleep and oxygen levels. One of the most useful diagnostic measures obtained during polysomnography



**2. Papilledema is fairly common in individuals with OSA.**

is the apnea-hypopnea index, or AHI. This index scores the number of disordered breathing events per hour and then assigns a ranking that ranges from not clinically significant to severe OSA.

## Common Treatment Options

The diagnosis of OSA is merely the beginning of the management challenge faced by health care providers and their patients. The most common intervention, use of a continuous positive airway pressure (CPAP) device, has a variable compliance rate due to a variety of factors.<sup>7</sup> With CPAP therapy, the patient is fit with a mask that is connected to a machine creating a continuous flow of air. This continuous airflow forces the airway to remain open by preventing the soft palate from collapsing.

While CPAP devices can be very effective, they often require a great deal of fine-tuning to find a comfortable fit with the mask and the airflow pressure. In combination with a number of factors—such as uncomfortable mask wear, machine noise, nasal congestion, irritation of nose and throat—this adjustment process often leads to frustration and poor adherence to therapy.<sup>7</sup>

Some patients cannot exhale effectively against the pressurized airflow created by their CPAP device and must turn to the use of bilevel positive airway pressure

(BiPAP) systems.<sup>8</sup> These systems have a different setting for the airflow pressure during inhalation and exhalation.

Fortunately, there are other therapeutic options available for OSA sufferers who need them. These include dental devices that thrust the lower jaw forward, and various surgical procedures designed to strengthen the soft palate or reduce the volume of the tongue. In addition, patients may alleviate symptoms by making lifestyle modifications, such as losing weight, increasing physical activity, avoiding sleeping pills and alcohol before bed, and changing body positions during sleep.<sup>6</sup>

## Systemic Conditions Associated with OSA

Because OSA leads to poor oxygen delivery to tissue and organs throughout the body, it is associated with a wide array of systemic conditions. These include many common cardiovascular, endocrine and ischemic vascular diseases, such as heart disease, hypertension, stroke and diabetes.<sup>9</sup> Some estimates suggest alarmingly high rates of OSA in common disease populations:<sup>5</sup>

- 50% of heart disease patients
- 60% of stroke patients
- 80% of patients with difficult to control hypertension
- 70% of obese individuals (often leading to type 2 diabetes)

For patients starting or changing PGA therapy

# Drop IOP. Keep monotherapy.



**Indication:** LUMIGAN® (bimatoprost ophthalmic solution) 0.01% is indicated for the reduction of elevated intraocular pressure in patients with open-angle glaucoma or ocular hypertension.

## Important Safety Information

**Warnings and Precautions:** LUMIGAN® causes changes to pigmented tissues, mostly increased pigmentation of the iris, eyelid, and eyelashes as long as LUMIGAN® is administered. Iris color change may not be noticeable for several months to years. After discontinuation of bimatoprost, iris pigmentation is likely to be permanent, while eyelid and eyelash changes have been reported to be reversible in some patients. Patients should be informed of the possibility of increased pigmentation. The long-term effects of increased pigmentation are not known.

LUMIGAN® should be used with caution in patients with active intraocular inflammation (eg, uveitis) because the inflammation may be exacerbated. Macular edema, including cystoid macular edema, has been reported with LUMIGAN®. LUMIGAN® should be used with caution in aphakic patients, in pseudophakic patients with a torn posterior lens capsule, or in patients with known risk factors for macular edema.

**Adverse Reactions:** The most common (25%-45%) adverse event with LUMIGAN® was conjunctival hyperemia. Approximately 0.5% to 3% of patients discontinued therapy due to conjunctival hyperemia. Other common events (> 10%) included growth of eyelashes and ocular pruritus.

**Please see Brief Summary of the full Prescribing Information on adjacent page.**



**LUMIGAN® 0.01%**  
(bimatoprost ophthalmic solution) 0.01%



# LUMIGAN® 0.01% AND 0.03%

(bimatoprost ophthalmic solution)

**Brief Summary—Please see the LUMIGAN® 0.01% and 0.03% package insert for full Prescribing Information.**

## INDICATIONS AND USAGE

LUMIGAN® 0.01% and 0.03% (bimatoprost ophthalmic solution) is indicated for the reduction of elevated intraocular pressure in patients with open angle glaucoma or ocular hypertension.

## CONTRAINDICATIONS

None

## WARNINGS AND PRECAUTIONS

**Pigmentation:** Bimatoprost ophthalmic solution has been reported to cause changes to pigmented tissues. The most frequently reported changes have been increased pigmentation of the iris, periorbital tissue (eyelid) and eyelashes. Pigmentation is expected to increase as long as bimatoprost is administered. The pigmentation change is due to increased melanin content in the melanocytes rather than to an increase in the number of melanocytes. After discontinuation of bimatoprost, pigmentation of the iris is likely to be permanent, while pigmentation of the periorbital tissue and eyelash changes have been reported to be reversible in some patients. Patients who receive treatment should be informed of the possibility of increased pigmentation. The long term effects of increased pigmentation are not known.

Iris color change may not be noticeable for several months to years. Typically, the brown pigmentation around the pupil spreads concentrically towards the periphery of the iris and the entire iris or parts of the iris become more brownish. Neither nevi nor freckles of the iris appear to be affected by treatment. While treatment with LUMIGAN® 0.01% and 0.03% (bimatoprost ophthalmic solution) can be continued in patients who develop noticeably increased iris pigmentation, these patients should be examined regularly.

**Eyelash Changes:** LUMIGAN® 0.01% and 0.03% may gradually change eyelashes and vellus hair in the treated eye. These changes include increased length, thickness, and number of lashes. Eyelash changes are usually reversible upon discontinuation of treatment.

**Intraocular Inflammation:** LUMIGAN® 0.01% and 0.03% should be used with caution in patients with active intraocular inflammation (e.g., uveitis) because the inflammation may be exacerbated.

**Macular Edema:** Macular edema, including cystoid macular edema, has been reported during treatment with bimatoprost ophthalmic solution. LUMIGAN® 0.01% and 0.03% should be used with caution in aphakic patients, in pseudophakic patients with a torn posterior lens capsule, or in patients with known risk factors for macular edema.

**Angle-closure, Inflammatory, or Neovascular Glaucoma:** LUMIGAN® 0.01% and 0.03% has not been evaluated for the treatment of angle-closure, inflammatory or neovascular glaucoma.

**Bacterial Keratitis:** There have been reports of bacterial keratitis associated with the use of multiple-dose containers of topical ophthalmic products. These containers had been inadvertently contaminated by patients who, in most cases, had a concurrent corneal disease or a disruption of the ocular epithelial surface.

**Use With Contact Lenses:** Contact lenses should be removed prior to instillation of LUMIGAN® 0.01% and 0.03% and may be reinserted 15 minutes following its administration.

## ADVERSE REACTIONS

**Clinical Studies Experience:** Because clinical studies are conducted under widely varying conditions, adverse reaction rates observed in the clinical studies of a drug cannot be directly compared to rates in the clinical studies of another drug and may not reflect the rates observed in practice.

In clinical studies with bimatoprost ophthalmic solutions (0.01% or 0.03%) the most common adverse reaction was conjunctival hyperemia (range 25%–45%). Approximately 0.5% to 3% of patients discontinued therapy due to conjunctival hyperemia with 0.01% or 0.03% bimatoprost ophthalmic solutions. Other common reactions (>10%) included growth of eyelashes, and ocular pruritus.

Additional ocular adverse reactions (reported in 1 to 10% of patients) with bimatoprost ophthalmic solutions included ocular dryness, visual disturbance, ocular burning, foreign body sensation, eye pain, pigmentation of the periocular skin, blepharitis, cataract, superficial punctate keratitis, periorbital erythema, ocular irritation, eyelash darkening, eye discharge, tearing, photophobia, allergic conjunctivitis, asthenopia, increases in iris pigmentation, conjunctival edema, conjunctival hemorrhage, and abnormal hair growth. Intraocular inflammation, reported as iritis, was reported in less than 1% of patients.

Systemic adverse reactions reported in approximately 10% of patients with bimatoprost ophthalmic solutions were infections (primarily colds and upper respiratory tract infections). Other systemic adverse reactions (reported in 1 to 5% of patients) included headaches, abnormal liver function tests, and asthenia.

**Postmarketing Experience:** The following reactions have been identified during postmarketing use of LUMIGAN® 0.01% and 0.03% in clinical practice. Because they are reported voluntarily from a population of unknown size, estimates of frequency cannot be made. The reactions, which have been chosen for inclusion due to either their seriousness, frequency of reporting, possible causal connection to LUMIGAN® or a combination of these factors, include: dizziness, eyelid edema, hypertension, nausea, and periorbital and lid changes associated with a deepening of the eyelid sulcus.

## USE IN SPECIFIC POPULATIONS

**Pregnancy:** Pregnancy Category C

Teratogenic effects: In embryo/fetal developmental studies in pregnant mice and rats, abortion was observed at oral doses of bimatoprost which achieved at least 33 or 97 times, respectively, the maximum intended human exposure based on blood AUC levels.

At doses at least 41 times the maximum intended human exposure based on blood AUC levels, the gestation length was reduced in the dams, the incidence of dead fetuses, late resorptions, peri- and postnatal pup mortality was increased, and pup body weights were reduced.

There are no adequate and well-controlled studies of LUMIGAN® 0.01% and 0.03% (bimatoprost ophthalmic solution) administration in pregnant women. Because animal reproductive studies are not always predictive of human response LUMIGAN® should be administered during pregnancy only if the potential benefit justifies the potential risk to the fetus.

**Nursing Mothers:** It is not known whether LUMIGAN® 0.01% and 0.03% is excreted in human milk, although in animal studies, bimatoprost has been shown to be excreted in breast milk. Because many drugs are excreted in human milk, caution should be exercised when LUMIGAN® is administered to a nursing woman.

**Pediatric Use:** Use in pediatric patients below the age of 16 years is not recommended because of potential safety concerns related to increased pigmentation following long-term chronic use.

**Geriatric Use:** No overall clinical differences in safety or effectiveness have been observed between elderly and other adult patients.

**Hepatic Impairment:** In patients with a history of liver disease or abnormal ALT, AST and/or bilirubin at baseline, bimatoprost 0.03% had no adverse effect on liver function over 48 months.

## OVERDOSAGE

No information is available on overdosage in humans. If overdose with LUMIGAN® 0.01% and 0.03% (bimatoprost ophthalmic solution) occurs, treatment should be symptomatic.

In oral (by gavage) mouse and rat studies, doses up to 100 mg/kg/day did not produce any toxicity. This dose expressed as mg/m<sup>2</sup> is at least 70 times higher than the accidental dose of one bottle of LUMIGAN® 0.03% for a 10 kg child.

## NONCLINICAL TOXICOLOGY

**Carcinogenesis, Mutagenesis, Impairment of Fertility:** Bimatoprost was not carcinogenic in either mice or rats when administered by oral gavage at doses of up to 2 mg/kg/day and 1 mg/kg/day respectively (at least 192 and 291 times the recommended human exposure based on blood AUC levels respectively) for 104 weeks.

Bimatoprost was not mutagenic or clastogenic in the Ames test, in the mouse lymphoma test, or in the *in vivo* mouse micronucleus tests.

Bimatoprost did not impair fertility in male or female rats up to doses of 0.6 mg/kg/day (at least 103 times the recommended human exposure based on blood AUC levels).

## PATIENT COUNSELING INFORMATION

**Potential for Pigmentation:** Patients should be advised about the potential for increased brown pigmentation of the iris, which may be permanent. Patients should also be informed about the possibility of eyelid skin darkening, which may be reversible after discontinuation of LUMIGAN® 0.01% and 0.03% (bimatoprost ophthalmic solution).

**Potential for Eyelash Changes:** Patients should also be informed of the possibility of eyelash and vellus hair changes in the treated eye during treatment with LUMIGAN® 0.01% and 0.03%. These changes may result in a disparity between eyes in length, thickness, pigmentation, number of eyelashes or vellus hairs, and/or direction of eyelash growth. Eyelash changes are usually reversible upon discontinuation of treatment.

**Handling the Container:** Patients should be instructed to avoid allowing the tip of the dispensing container to contact the eye, surrounding structures, fingers, or any other surface in order to avoid contamination of the solution by common bacteria known to cause ocular infections. Serious damage to the eye and subsequent loss of vision may result from using contaminated solutions.

**When to Seek Physician Advice:** Patients should also be advised that if they develop an intercurrent ocular condition (e.g., trauma or infection), have ocular surgery, or develop any ocular reactions, particularly conjunctivitis and eyelid reactions, they should immediately seek their physician's advice concerning the continued use of LUMIGAN® 0.01% and 0.03%.

**Use with Contact Lenses:** Patients should be advised that LUMIGAN® 0.01% and 0.03% contains benzalkonium chloride, which may be absorbed by soft contact lenses. Contact lenses should be removed prior to instillation of LUMIGAN® and may be reinserted 15 minutes following its administration.

**Use with Other Ophthalmic Drugs:** Patients should be advised that if more than one topical ophthalmic drug is being used, the drugs should be administered at least five (5) minutes between applications.

©2012 Allergan, Inc., Irvine, CA 92612

® marks owned by Allergan, Inc

Patented. See: [www.allergan.com/products/patent\\_notices](http://www.allergan.com/products/patent_notices)

Made in the U.S.A.

APC70EN12 based on 71807US13.

Rx only

 ALLERGAN

With undetected and/or untreated sleep apnea, properly managing these comorbidities can be challenging to say the least.

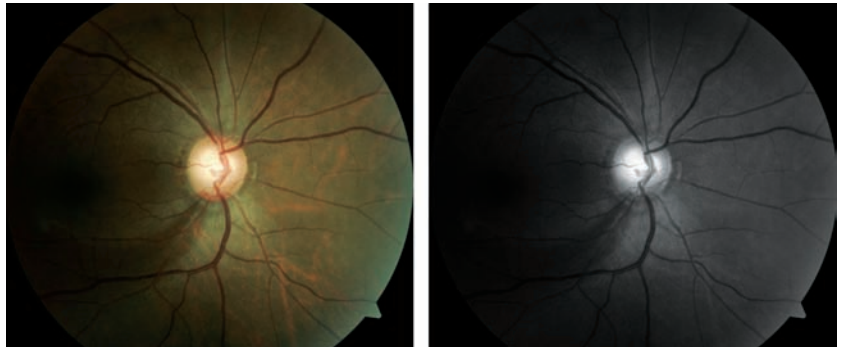
### OSA and the Eye

Failure to identify and manage underlying sleep apnea can also make it very difficult to appropriately manage secondary ocular concerns. A number of anterior and posterior eye conditions are associated with OSA, including floppy eyelid syndrome (FES), optic neuropathy, glaucoma, non-arteritic anterior ischemic optic neuropathy (NAION) and papilledema (disc edema secondary to raised intracranial pressure).<sup>10</sup> Let's take a look at how these conditions may present in the sleep apnea patient, as well as helpful treatment interventions.

### Floppy Eyelid Syndrome

OSA is highly associated with both keratoconus and FES.<sup>10</sup> While the direct link between these conditions and OSA remains elusive, the etiology may hinge upon increased matrix metalloproteinase.<sup>11</sup> The decreased oxygen supply with OSA can lead to an increased production of matrix metalloproteinase, which, in turn, tends to decrease tissue elasticity.<sup>11,12</sup> This is especially important in cases of FES.

While less than 5% of OSA patients develop FES, nearly 100% of individuals with FES suffer from OSA.<sup>13</sup> Therefore, it is imperative that all patients with FES be evaluated for OSA if they have not already been diagnosed, especially if they report any of the commonly experienced signs or symptoms. Patients with FES have extremely loose, rubbery eyelids, which evert very easily upon contact with the pillow during sleep (*figure 1*). This leads to exposure keratitis and dryness, as well as mechanical kerato-



**3. Normal-tension glaucoma with a retinal nerve fiber layer wedge defect in a patient with sleep apnea.**

conjunctivitis, as a result of direct contact with surfaces. Patients experience irritation and dryness that is at its worst upon awakening but improves as the day goes on.

Another common finding with FES is lash ptosis, where the upper eyelashes point downward as the result of chronic lid eversion at night. Unfortunately, FES is underappreciated and often goes undetected, which leads to frustration in patients who cannot get relief from their symptoms. Because similar symptoms are also seen with dry eye syndrome and blepharitis, patients are commonly diagnosed with—and treated for—those conditions with limited success.

Appropriate management of FES is multi-modal. Patient education is critical, as is appropriate management of the underlying OSA. Nighttime lubricating ointments are applied to protect the ocular surface from both exposure and mechanical abrasion. A stiff sleep mask can be used to help keep the lids from everting when the face contacts the pillow. Wearing a sleep mask, however, can be difficult for patients who are already wearing a CPAP mask.

Also consider the benefits of a cylindrical or “dog bone” pillow—the design allows the patient to rest their cheek on the pillow without

direct eyelid contact. The lids can be taped closed each evening to prevent eversion, but anecdotally, patients often do not comply with this recommendation long term due to inconvenience, discomfort or skin irritation from the tape. Some practitioners have reported success in recommending that their patients secure their lids closed with commercially available strips designed to open the nasal passages. In severe cases, surgical intervention may be warranted—lid tissue can be removed to tighten the lids and help to prevent spontaneous nighttime eversion. Unfortunately, in some patients the improvement is not permanent and the condition returns at some point after surgery.<sup>14</sup>

### Papilledema

Papilledema is not a generic term that can be applied to any type of optic nerve swelling. Rather, papilledema is an optic nerve head swelling, most often bilateral, that is specifically the result of elevated intracranial pressure (*figure 2*). Optic nerve swelling that arises from any other etiology cannot be accurately referred to in this manner. Elevated intracranial pressure during the overnight hours can be seen in patients suffering from OSA.<sup>15</sup> The elevated pressure, in turn, may result in mild to moderate

papilledema with headaches experienced upon awakening.<sup>10</sup>

Most authors postulate that the elevated intracranial pressure overnight is the result of venous dilation caused by hypoxia and hypercapnia from apneic events.<sup>10</sup> While the optic nerve swelling is easily visualized, the underlying phenomenon can be particularly challenging to detect because the intracranial pressure often returns to normal during waking hours.<sup>16</sup> Therefore, confirmation may only be possible with lumbar taps performed during the middle of the night. Clearly this is a significant practical concern. Thankfully, intracranial pressure may return to normal with appropriate management of the underlying OSA using CPAP therapy.<sup>17,18</sup>

Clinicians should be particularly suspicious of OSA in males with papilledema and normal neuroimaging studies. These findings are often indicative of idiopathic intracranial hypertension, also known as pseudotumor cerebri. However, idiopathic intracranial hypertension is encountered far more frequently in females than it is in males, making it very important to consider alternative etiologies of increased intracranial pressure in male patients, especially older male patients.

## Glaucoma

Though there are some contradictory studies, primary open-angle glaucoma and normal-tension glaucoma seem to be encountered more frequently in patients with OSA than in the general population.<sup>19-21</sup> This is particularly true in the case of normal-tension glaucoma.<sup>22</sup> At least one study has shown that the intraocular pressure does not elevate at night in OSA patients, so it is believed that the increased likelihood of developing glaucoma is the result of ischemia from poor oxygen

## Ophthalmic Complications Associated with CPAP Devices

While most of the conditions we've discussed are associated with sleep apnea itself, some complications can be encountered in the treatment for this condition. For example, use of CPAP therapy can be associated with ocular complications. Air can leak from around the edge of the mask and be directed toward the eyes, leading to dryness and irritation. Exposure of the eye to this air that has passed over the mouth and nose also results in a higher rate of bacterial conjunctivitis.<sup>34</sup>

Certain studies have shown that the use of a CPAP mask can elevate IOP by up to 5mm Hg to 8mm Hg.<sup>25</sup> These studies were performed on patients who were not taking pressure-lowering eye drops, so it is possible that this substantial elevation in pressure would not occur in patients on glaucoma therapy. It is important to review any ocular irritation complaints, particularly with CPAP, and to encourage your patient to talk to their sleep specialist about making adjustments to the mask and air pressure to reduce such issues.

delivery.<sup>23</sup> Other reports, however, indicate that patients with OSA may experience significant 24-hour variations in their IOP with elevation possible at night.<sup>24</sup> It is important for clinicians to consider OSA in patients with glaucoma, especially those with normal-tension glaucoma that is progressing in spite of optimal IOP control (*figure 3*). It is also wise to keep in mind the association between CPAP therapy and elevated IOP in some individuals.<sup>25</sup>

## NAION

NAION has proven over time to be very highly associated with OSA, with multiple studies showing a clear correlation between the two processes.<sup>26,27</sup> One study examined 27 consecutive patients diagnosed with NAION. Upon testing, the researchers found that 24 of them suffered from OSA.<sup>26</sup> Another report revealed that 12 of 17 patients with NAION were diagnosed with sleep apnea after being evaluated, while just three of 17 matched controls were found to suffer from OSA.<sup>27</sup> It is not surprising that sleep apnea is encountered with such regularity in patients afflicted with NAION. The damage to the optic nerve is the result of an ischemic event caused by poor per-

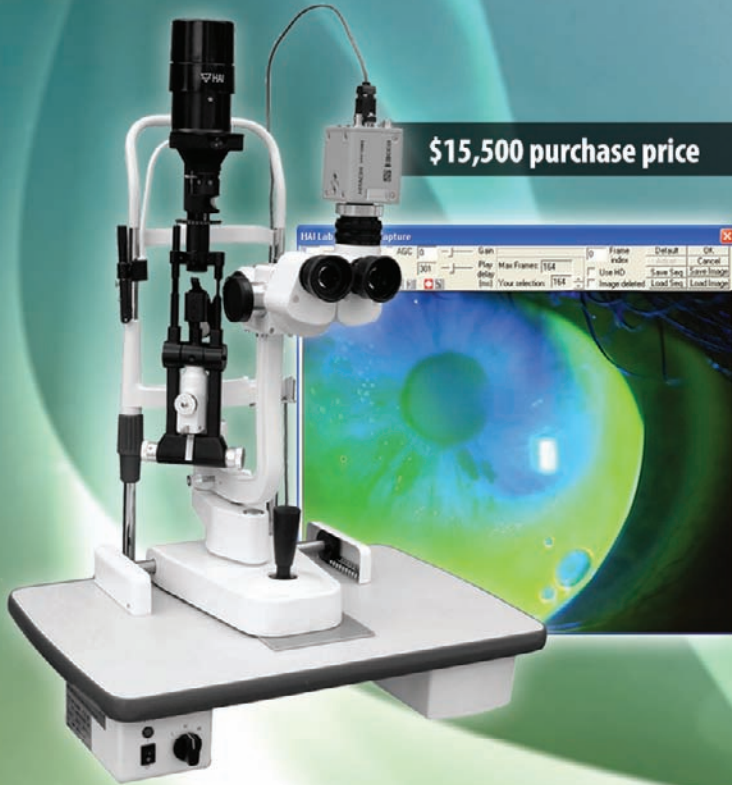
fusion, often in anatomically predisposed optic nerves with little or no cupping (*figures 4 and 5*).

The majority of NAION patients first notice vision loss upon awakening in the morning.<sup>27,28</sup> The decreased nighttime blood oxygen saturation OSA patients experience could contribute to acute ischemic events involving the blood supply of the optic nerve. All patients who are diagnosed with NAION should be questioned regarding a history of OSA, and sleep studies should be strongly considered if no previous diagnosis has been made.

## Miscellaneous Retinal Conditions

There are at least three other retinal conditions that are more frequently present in patients with sleep apnea. Multiple reports have found retinal vein occlusions to present more commonly in patients suffering from OSA.<sup>29</sup> In addition, diabetic patients with retinopathy are more likely to exhibit proliferative disease and macular edema when they concomitantly have sleep apnea, and those with proliferative disease have a greater chance of developing iris neovascularization.<sup>30,31</sup> Recent reports have also linked idiopathic central serous





**\$15,500 purchase price**

- ▼ American quality engineering
- ▼ Manufacturer-direct pricing
- ▼ On-site installation & training
- ▼ Purchase, rent or rent-to-own

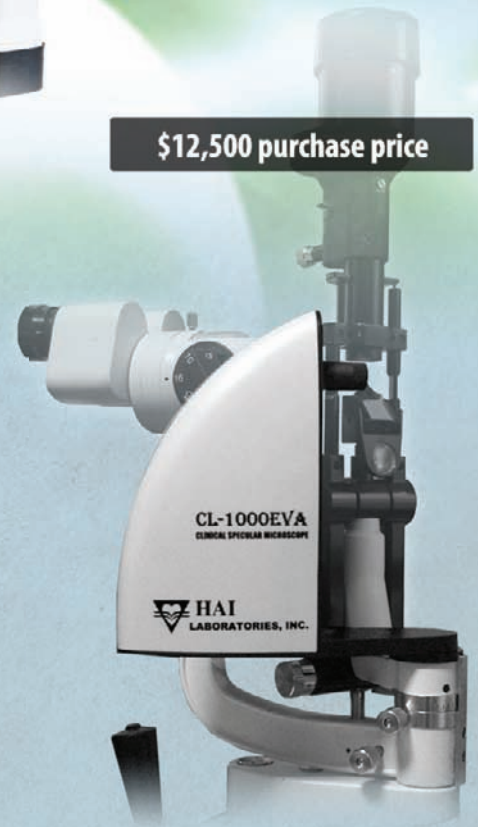

**\$2,995 purchase price**

**VISIT US**  
SECO BOOTH #348  
VEE BOOTH #6869

## Upgrade your exam capabilities with new diagnostic equipment, at prices that fit your budget.

Open up a world of possibilities with the HAI SL-5000 Digital Video Slit Lamp, the only anterior segment camera system that allows you to stream real-time high resolution video of the eye to an LCD monitor, big screen, projector, or over a network<sup>†</sup>. Capture clips or still photos with ease for education and documentation. With the addition of a HAI CL-1000eva Endothelium Viewing Attachment for slit lamps, get all the diagnostic power of a specular microscope in the smallest form factor (and price tag) available anywhere. On the go? The lightweight and ergonomic SL-5000h Handheld Slit Lamp with built-in 10x and 16x magnification is the perfect solution for your mobile needs.



**\$12,500 purchase price**

**Hightech American Industrial Laboratories, Inc.**  
320 Massachusetts Ave, Lexington, MA 02420, USA  
Tel: (781) 862-9884 Web: www.hailabs.com

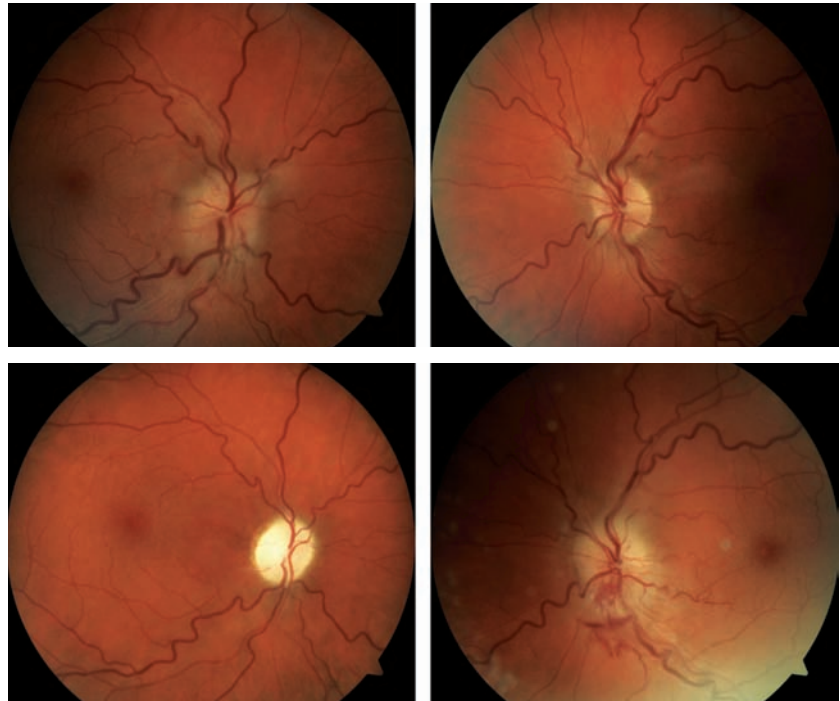
<sup>†</sup>Network streaming capability available with HAI IMS/CL Server Suite. Additional hardware required.

# Sleep Apnea

chorioretinopathy to this condition, with treatment of OSA leading to rapid resolution of the chorioretinopathy.<sup>32,33</sup>

Obstructive sleep apnea has become a substantial health concern in the United States and many other countries. It has a significant, harmful effect on the entire body and the eye, and it is associated with a host of systemic and ocular conditions. Failure to diagnose and manage underlying sleep apnea can make it very difficult to properly control these associated conditions. It is imperative that eye care practitioners be aware of the signs and symptoms of sleep apnea, and of the effect that the disease has on the body and the eye. ■

*Dr. Sutton is a clinical professor at Indiana University School of Optometry and Service Chief of the Indianapolis Eye Care Center in Indianapolis, Ind.*



**4, 5. Sequential NAION in a patient with sleep apnea. The patient presented with NAION OD (top) and upon work-up was subsequently determined to have OSA. She could not tolerate CPAP therapy, and several weeks later experienced NAION OS (bottom).**

- Gastaut H, Tassinari CA, Duron B. Polygraphic study of the episodic diurnal and nocturnal (hypnic and respiratory) manifestations of the Pickwick syndrome. *Brain Res.* 1966 Feb;1(2):167-86.
- Young T, Palta M, Dempsey J, et al. The occurrence of sleep-disordered breathing among middle-aged adults. *N Engl J Med.* 1993 Apr 29;328(17):1230-5.
- Young T, Evans L, Finn L, Palta M. Estimation of the clinically diagnosed proportion of sleep apnea syndrome in middle-aged men and women. *Sleep.* 1997 Sep;20(9):705-6.
- Mokhlesi B, Tulaimat A. Recent advances in obesity hypoventilation syndrome. *Chest.* 2007 Oct;132(4):1322-36.
- Nablii ST, Marks JW, ed. Sleep apnea. Available at: [http://www.medicinenet.com/sleep\\_apnea/article.htm](http://www.medicinenet.com/sleep_apnea/article.htm). Accessed December 2012.
- Usmani ZA, Chai-Coetzer CL, Antic NA, McEvoy RD. Obstructive sleep apnoea in adults. *Postgrad Med J.* 2012 Nov 17. [Epub ahead of print]
- Selvaraj S, Humphreys J, Wilson J, et al. A retrospective study of factors contributing to the non-adherence and failure of treatment with continuous positive airway pressure (CPAP) in obstructive sleep apnoea (OSA) syndrome patients. *Am J Respir Crit Care Med.* 2012 May;185(1MeetingAbstracts):A6458.
- Schafer H, Ewig S, Hasper E, Luderitz B. Failure of CPAP therapy in obstructive sleep apnoea syndrome: predictive factors and treatment with bilevel positive airway pressure. *Respir Med.* 1998 Feb;92(2):208-15.
- Caples SM, Gami AS, Somers VK. Obstructive sleep apnea. *Ann Intern Med.* 2005 Feb 1;142(3):187-97.
- McNab AA. The eye and sleep apnea. *Sleep Med Rev.* 2007 Aug;11(4):269-76.
- Schlötzer-Schrehardt U, Stojkovic M, Hofmann-Rummelt C, et al. The pathogenesis of floppy eyelid syndrome: involvement of matrix metalloproteinases in elastic fiber degradation. *Ophthalmology.* 2005 Apr;112(4):694-704.
- Tazaki T, Minoguchi K, Yokoe T, et al. Increased levels of

- activity and matrix metalloproteinase-9 in obstructive sleep apnea syndrome. *Am J Respir Crit Care Med.* 2004 Dec 15;170(12):1354-9.
- Waller EA, Bendel RE, Kaplan J. Sleep disorders and the eye. *Mayo Clin Proc.* 2008 Nov;83(11):1251-61.
- Ezra DG, Beaconsfield M, Sira M, et al. Long-term outcomes of surgical approaches to the treatment of floppy eyelid syndrome. *Ophthalmology.* 2010 Apr;117(4):839-46.
- Sugita Y, Iijima S, Teshima Y, et al. Marked episodic elevation of cerebrospinal fluid pressure during nocturnal sleep in patients with sleep apnea hypersomnia syndrome. *Electroencephalogr Clin Neurophysiol.* 1985 Mar;60(3):214-9.
- Bloomfield RL, Felts JH, Burkhart JM, Cashwell FL. Optic disc edema in a pickwickian man mimicking hypertensive crisis. *J Clin Hypertens.* 1987 Mar;3(1):27-30.
- Lee AG, Golnik K, Kardon R, et al. Sleep apnea and intracranial hypertension in men. *Ophthalmology.* 2002 Mar;109(3):482-5.
- Javaheri S, Golnik K. Resolution of papilledema associated with OSA treatment. *J Clin Sleep Med.* 2011 Aug 15;7(4):399-400.
- Geyer O, Cohen N, Segev E, et al. The prevalence of glaucoma in patients with sleep apnea syndrome: same as in the general population. *Am J Ophthalmol.* 2003 Dec;136(6):1093-6.
- McNab AA. Floppy eyelid syndrome and obstructive sleep apnea. *Ophthalmol Plast Reconstr Surg.* 1997 Jun;13(2):98-114.
- Mojon DS, Hess CW, Goldblum D, et al. High prevalence of glaucoma in patients with sleep apnea syndrome. *Ophthalmology.* 1999 May;106(5):1009-12.
- Mojon DS, Hess CW, Goldblum D, et al. Normal-tension glaucoma is associated with sleep apnea syndrome. *Ophthalmologica.* 2002 May-Jun;216(3):180-4.
- Goldblum D, Mathis J, Bohnke M, et al. Nocturnal measurements of intraocular pressure in patients with normal-tension glaucoma and sleep apnea syndrome. *Klin Monbl Augenheilkd.* 2000 May;216(5):246-9.
- Lundmark PO, Trope GE, Flanagan JG. The effect of simulated obstructive apnoea on intraocular pressure and pulsatile

- ocular blood flow in healthy young adults. *Br J Ophthalmol.* 2003 Nov;87(11):1363-9.
- Kiekens S, Veve De Groot, Coeckelbergh T, et al. Continuous positive airway pressure therapy is associated with an increase in intraocular pressure in obstructive sleep apnea. *Invest Ophthalmol Vis Sci.* 2008 Mar;49(3):934-40.
- Palombi K, Renard E, Levy P, et al. Non-arteritic ischaemic optic neuropathy is nearly systematically associated with obstructive sleep apnoeas. *Br J Ophthalmol.* 2006 Jul;90(7):879-82.
- Mojon DS, Hedges TR 3rd, Ehrenberg B, et al. Association between sleep apnea syndrome and nonarteritic anterior ischemic optic neuropathy. *Arch Ophthalmol.* 2002 May;120(5):601-5.
- Hayreh SS, Podhajsky PA, Zimmerman B. Nonarteritic anterior ischemic optic neuropathy: time of onset of vision loss. *Am J Ophthalmol.* 1997 Nov;124(5):641-7.
- Chou KT, Huang CC, Tsai DC, et al. Sleep apnea and risk of retinal vein occlusion: a nationwide population-based study of Taiwanese. *Am J Ophthalmol.* 2012 Jul;154(1):200-5.
- Shiba T, Sato Y, Takahashi M. Relationship between diabetic retinopathy and sleep-disordered breathing. *Am J Ophthalmol.* 2009 Jun;147(6):1017-21.
- Shiba T, Takahashi M, Hori Y, et al. Relationship between sleep-disordered breathing and iris and/or angle neovascularization in proliferative diabetic retinopathy cases. *Am J Ophthalmol.* 2011 Apr;151(4):604-9.
- Sancho-Chust JN, Chiner E, Lopex-Lizzcano R. Central serous chorioretinopathy as first sign of sleep apnea-hypopnea syndrome. *Arch Bronconeumol.* 2010 Aug;46(8):449-50.
- Jain AK, Kaines A, Schwartz S. Bilateral central serous chorioretinopathy resolving rapidly with treatment of obstructive sleep apnea. *Graefes Arch Clin Exp Ophthalmol.* 2010 Jul;248(7):1037-39.
- Sutton B, Alexander L. Sleep apnea and ocular issues: An Optometric Retina Society white paper. *Optometric Retina Society website.* Available at: [www.optometricretinasociety.org](http://www.optometricretinasociety.org). Accessed December 2012.

# Monthly Multifocal Pearl



## The Aging Eye and Contact Lens Wear

By Jordan Kassalow, OD

Presbyopia is inevitable and highly prevalent, taking its toll on individuals who cross the threshold of their forties. It's a big deal to patients, as the effects of presbyopia are an unmistakable sign that they are getting older.

Presbyopes are projected to be the single largest group of potential contact lens wearers by 2018 (28% of all potential lens wearers or approximately 13.5 million people).<sup>1</sup> Keeping this group of patients in contact lenses is a challenge because of their complex nearpoint demands and comfort issues. Let's look at the role these two factors play in fitting presbyopic patients with contact lenses.

### CHANGES IN NEAR DEMAND

With the widespread use of computers, tablets and handheld devices, the gradual loss of intermediate and near vision has created considerable difficulty for presbyopic patients. Finding a contact lens that works well at all distances has been a challenge to eye care practitioners. Interestingly, Richdale, et al, found that despite good visual acuity at distance and near, the majority of monovision patients would prefer more normal biocular vision, if given the choice.<sup>2</sup>

Enter Alcon's AIR OPTIX® AQUA Multifocal contact lens. Its Precision Profile Lens Design allows patients to achieve binocular vision and smooth, uninterrupted transitions from one activity to the next. The adaptive minus power profile helps to minimize aberrations and allows for a smooth progression of power gradients from center-near, to intermediate and distance. This smart design enables presbyopic patients to transition from checking their handheld devices, to working on their computers, to seeing the TV, to driving their cars without compromise.

### TIPS FOR MULTIFOCAL SUCCESS

The right approach can make all the difference. These pointers pave the way for successful multifocal contact lens fitting.

- Ask all patients if they would like to try multifocal lenses
- Set expectations
- Allow the lens to equilibrate
- Test binocular acuity first
- Use normal room illumination
- Over-refract using trial lenses
- Re-check near and distance acuities through the over-refraction.

With all of life's visual demands, it's important to have a lens to turn to that can be prescribed to meet our patients' needs. AIR OPTIX® AQUA Multifocal contact lenses can be fit directly from the fitting set with only minor adjustments needed throughout their presbyopic years and without the need to refit a new material and design. The lens is available in LO, MED and HI ADD ranges for different stages of presbyopia.

### ONE LENS FOR EVERY PRESBYOPE

AIR OPTIX® AQUA Multifocal contact lenses are designed to transition patients smoothly through the different stages of presbyopia for longer retention. See below how the lens' three ADD ranges cater to patients as their condition progresses.

#### Emerging Presbyopes

LO ADD (spectacle add up to +1.25D)

#### Established Presbyopes

MED ADD (spectacle add +1.50D to +2.00D)

HI ADD (spectacle add +2.25D to +2.50D)

### COMFORT

AIR OPTIX® AQUA Multifocal contact lenses are made from a silicone hydrogel material (lotrafilcon B) that provides both high oxygen transmissibility (with a Dk/t of 138 @ -3.00D) and a low lipid-depositing surface. The lens offers high oxygen transmissibility, deposit resistance and increased wettability, as well as comfort from insertion to the end of the wear cycle. Additionally, recommending a compatible contact lens solution such as OPTI-FREE® PureMoist® Multi-Purpose Disinfecting Solution, can help ensure patient comfort so patients stay in their lenses longer.

### CONCLUSION

The presbyopic population continues to grow, as do our multifocal contact lens options. With an 85% first lens fit success,<sup>3</sup> and visual performance that exceeds competitors' multifocal lenses,<sup>3\*</sup> AIR OPTIX® AQUA Multifocal contact lenses have become my first reach lens for presbyopic patients. It could also be the answer for your growing presbyopic population.

*Dr. Kassalow practices in New York, where he specializes in contact lenses. He is Director of the River Blindness programs at Helen Keller International and is a consultant to the World Health Organization.*

\*Based on subjective ratings; compared to ACUVUE® OASYS® for PRESBYOPIA contact lenses. ^Trademarks are the property of their respective owners.

1. Studebaker J. Soft multifocals: practice growth opportunity. Contact Lens Spectrum. June 2009; Available at: [www.clspectrum.com/article.aspx?article=103013](http://www.clspectrum.com/article.aspx?article=103013) (Accessed January 2013).

2. Richdale K, Mitchell GL, Zadnik K. Comparison of multifocal and monovision soft contact lens corrections in patients with low-astigmatic presbyopia. Optom Vis Sci. 2006;83(5):266-273.

3. In a randomized, subject-masked clinical study at 20 sites with 252 patients; significance demonstrated at the 0.05 level; Alcon data on file, 2009.

Important information for AIR OPTIX® AQUA Multifocal (lotrafilcon B) contact lenses: For daily wear or extended wear up to 6 nights for near/far-sightedness and/or presbyopia. Risk of serious eye problems (i.e., corneal ulcer) is greater for extended wear. In rare cases, loss of vision may result. Side effects like discomfort, mild burning or stinging may occur.

See product instructions for complete wear, care and safety information.

**Rx only** contact lenses

Sponsored by

**Alcon**

a Novartis company



# Sharpen Your Visual Field Interpretation Skills

Understanding visual fields is not black and white—not even shades of gray. But new analyses can provide powerful information, if you can interpret them.

By Michael Chaglasian, OD

Visual field testing is an important diagnostic consideration in the evaluation of patients with many different types of pathologies. Most commonly, it is used for conditions affecting the optic nerve and other forms of neurological disease; but it's also helpful for retinal conditions and instances when visual field function needs to be measured.

Automated, computerized and threshold static perimetry became available about 30 years ago. While some of the basic principles of interpretation remain, advances in software and hardware have shortened test-taking time and improved accuracy and reliability. Given the subjective nature of the test, it's essential to differentiate true, disease-related defects and abnormalities from artifact and noise.

Evaluating visual field results from any perimeter can be confusing and daunting at times, especially when attempting to

cohesively link all the data together. Good interpretation skills start with a methodical assessment of several key plots, graphs and indices. By following a standardized process on all visual field printouts, clinicians can ensure they are accurately diagnosing ocular disease and/or detecting progression.

For individuals, such as glaucoma patients, who have had a series of visual fields, new analyses are available that greatly help our ability to detect a change in VF

defects. In addition, we can measure the rate of disease change as well, giving us powerful insight to our management.

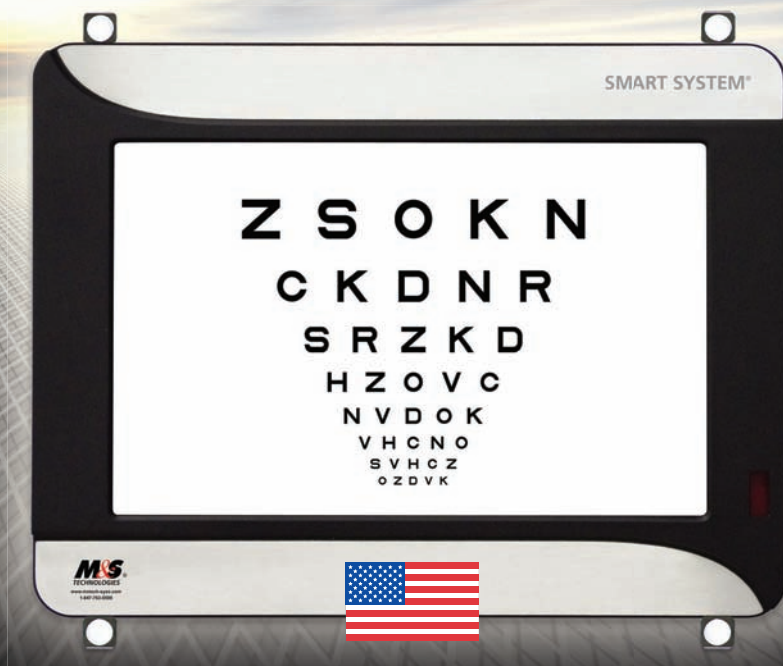## Start at the Top

While the printouts from different perimeters do not look identical, much of the displayed content and information is the same. Regardless of the instrument used, start at the top by locating information about the test parameters (*figure 1*) and reliability indices.

Single Field Analysis		Eye: Right	
Name: [REDACTED]	ID: 602451	DOB: 12-20-1953	
Central 24-2 Threshold Test			
Fixation Monitor: Gaze/Blind Spot	Stimulus: III, White	Pupil Diameter:	Date: 07-18-2012
Fixation Target: Central	Background: 31.5 ASB	Visual Acuity:	Time: 2:36 PM
Fixation Losses: 4/15 xx	Strategy: SITA-Standard	RX: +4.00 DS DC X	Age: 58

**1. The top of the VF printout page contains key information about patient demographics and the type of test that was performed. Always review this portion for accuracy. On the Humphrey Field Analyzer (shown here), the best threshold test is the SITA-Standard. The standard test is better for early detection, while the SITA-Fast test tends to show variable results and is less sensitive.<sup>1</sup> The fixation losses are also noted here.**

# Technology That Shines



**Introducing the New M&S® American-Made  
All-in-One Smart System®**

*(shown with optional Glare Light Kit)*

## M&S SMART SYSTEM SOFTWARE FEATURES INCLUDE:

- Customization by log-in, from system preferences to tests
- New eLVT testing, from screening to complete automated tests; objective and comprehensive
- Operated with wireless tablet or remote control
- Automated Linear Contrast Sensitivity Testing delivers a standardized protocol that provides results with normative data

## TECHNOLOGY THAT WILL STAND OUT IN YOUR PRACTICE.

Experience a computerized vision testing system that responds to your commands, as if you designed it yourself. Your M&S tablet or remote control adjusts to your system settings as you enter the exam room. Experience our adaptive technology that precisely aligns with your examination style and procedures.

Call us for a one-on-one consultation on how the M&S Smart System Computerized Vision Testing System can be configured to your style, your process.

**M&S**  
TECHNOLOGIES®

**The First Choice in  
Vision Testing Systems**

[www.mstech-eyes.com](http://www.mstech-eyes.com)  
1-877-225-6101

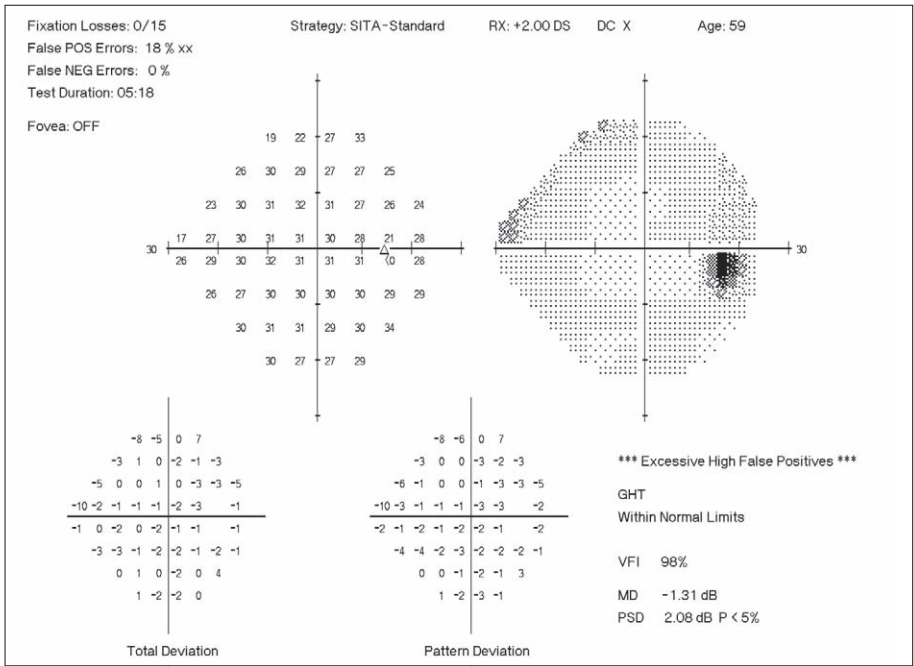
Scan this QR code with your smart phone to learn more about M&S Technologies, Inc.



©2013 M&S Technologies, Inc.  
Smart System and M&S are registered trademarks of  
M&S Technologies, Inc. Patents Pending. All Rights Reserved.

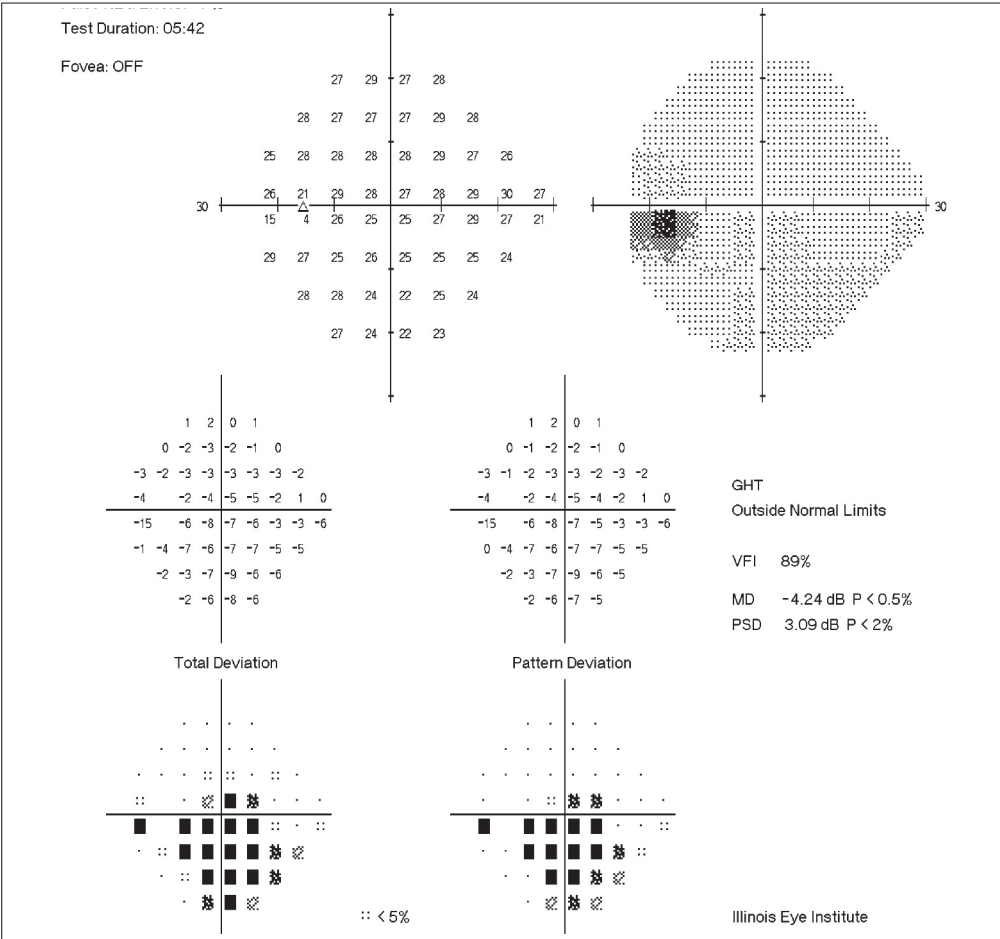
@mstecheyes  
 mstecheyes  
 M&S Technologies, Inc.

*Demo the new American-Made  
All-in-One at SECO, Feb 27-Mar 3!  
Booth #1242*



**2. Confirming the validity of the VF is the second step. Fixation losses, false positives and false negatives are recorded—with false positives often being the most critical. An error rate of 5% to 10% significantly affects the appearance, making the gray scale and other plots appear better than they really are.<sup>1</sup> Do not follow old published guidelines of up to a 33% acceptance rate.<sup>1</sup>**

**3. In this classic example, the patient has moderate to advanced stage glaucoma. The large inferior defect is clearly depicted and appears similar on both the total and pattern deviation plots. Of note, the gray scale does not show the defect, which is due to an interpolation error in the scaling. Remember, do not rely solely on the gray scale when evaluating visual fields.**



"I find my Vision Source consultants are supportive and provide the motivation to help me excel."

Huyen Trinh, OD

# OUTSHINE YOUR COMPETITION

## THE SECRET IS OUT.

Only Vision Source® offers all the tools you need to enter and succeed in private practice – to not just survive, but to thrive. We do it with the **lowest cost of goods** in the business. With a **consultative member services program** to help you at every step. With turnkey **marketing tools** and support that drive traffic. With **practice support programs** to keep everything running smoothly. All so you can provide the absolute best care.

We are single-mindedly committed to the success of independent optometry – this is why we are proud of our **98% member retention** rate since 1991. So don't sit quiet, discover what **5300 member colleagues**, including 13 former AOA Presidents, have come to enjoy – speak up and inquire about membership today.



Now accepting new membership inquiries at [VSforYou.com](http://VSforYou.com)

**VISION  
SOURCE**



- **Test parameters.** Make sure the patient's birthdate is accurate, because the test results are compared to a normative database. Identify that the proper trial lens was calculated and utilized. Although a standard test program and pattern (e.g., 24-2, Threshold) is often selected for the majority of patients, be sure to confirm that the correct test was selected.

- **Reliability indices.** Examining the reliability indices is the next key step in visual field interpreta-

tion (figure 2). High fixation losses (more than 15% to 20%) are a strong indication that the test results are likely inaccurate. One way to reduce fixation losses is to make sure your technician properly aligns the patient and monitors their attention during the test.

False positives, another key index, help to identify a “trigger happy” patient who is pushing the response button even when no light stimuli are presented. The field may often look normal or “cleaner”

(with fewer defects depicted) on patients with values of 5% to 10% or higher.

False negatives are identified when the patient does not respond to a light stimulus that should have been detected, based upon earlier responses. Values of 10% to 15% or more are indicative of a patient who is not paying good attention during the course of the test; the results may look worse than they really are.

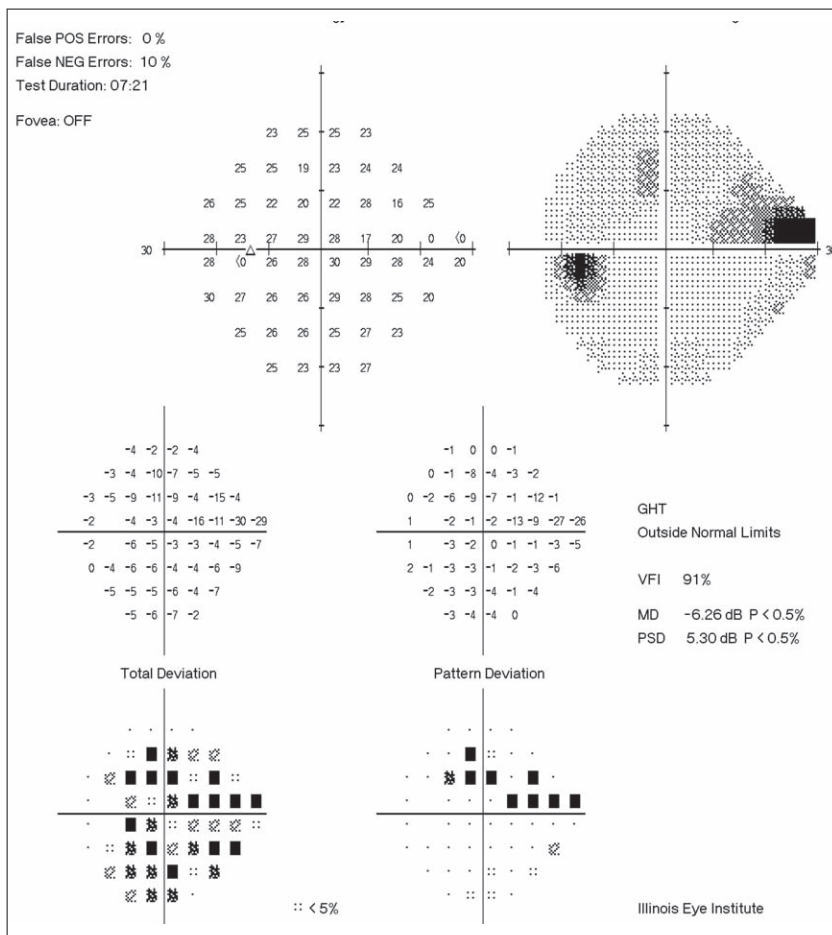
After reviewing these key data points, the next part of the page can be evaluated.

## Don't Get Lost in the Middle

The middle part of any visual field printout page can be confusing, with its multiple graphs and plots. There are plots that display the “raw data” in decibels (dB) from the patient's test. While the dB values can be helpful when there is conflicting information on the printout, they often don't need to be examined in detail.

- **Gray scale.** The gray scale of the VF printout is an easy plot to use for quick identification of potential scotomas and depressions, as well as getting a general assessment about the location and size of any defect. One common mistake in VF interpretation is that the clinician looks *only* at the gray scale (figure 3). Doing this can lead to inaccurate identification of VF loss. Rather, the gray scale should be viewed as a starting point, as two other plots—total deviation (TD) and the pattern deviation (PD)—must be assessed to get the full and accurate clinical picture.

- **Total deviation.** The TD plot shows all the portions of the patient's visual field that are different from a “normal” patient's field of the same age. It is a key graph that can be best assessed by



**4. This patient has a mild cataract and glaucoma. The generalized depression from the cataract is evident on the TD plot (lower left). The localized defect—a superior nasal step with an arcuate component—caused by the glaucoma is seen on the PD plot. Additional key indicators—the global indices—are on right side of the page. The glaucoma hemifield test (GHT) is a sensitive indicator of differences between the superior and inferior hemifields. The VFI is an overall marker of field loss similar to the MD. Patients with values below 70% may begin to notice functional defects.**





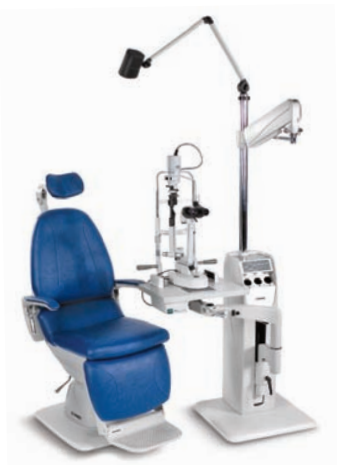800.735.0357  
haag-streit-usa.com

# Set an Example for the Next Generation. Invest in Reliance.



**Reliance**Durable.com

Looking for a new chair or stand? Consider Reliance Medical Products in Mason, Ohio. Not because our products are Made in America, but because they're just better. Buy Reliance and send a message to the next generation that buying American is good for the bottom line, and our country.



The Superior Practice.

using the probability plots with the shaded boxes at each test location, and not the numerical dB plot. Solid, fully black squares indicate test points that are statistically more likely to be abnormal compared to the other, lighter shades of gray.

When examining the TD plot, look at the size, shape and location of any abnormal points/boxes. Often, a generalized depression (perhaps from a cataract) is noted on this plot, with darkly shaded squares uniformly filling up the grid (figure 4). However, when trying to identify a visual field defect related to glaucoma or lesions along the visual pathway, localized defects (not generalized) are the key finding. Localized defects will appear on the TD plot, but may be hidden by a generalized depression caused by a corneal or lenticular opacity. To separate the localized defect (likely the true disease-related defect) from any defect

caused by a media opacity, the PD plot must be examined.

• **Pattern deviation.** As with the TD plot, the PD plot is best analyzed by using the shaded boxes on the probability plot. The PD plot is designed to highlight localized defects by “removing” generalized visual field loss (likely due to a cataract). True defects on the PD should be characterized by their shape and location (i.e., nasal steps, central and arcuate scotomas). Clusters of adjacent points can be grouped together so that their particular shape can be associated with the correlating disease or lesion.

## The Final Step

The key indicators that remain are often found on the right side of the printed page. Thus, the middle part of the printout should be read from left to right, proceeding from total to PD plots and then to the global indices. The global indices

give a numerical quantification in decibels of the visual field loss that appears on the page.

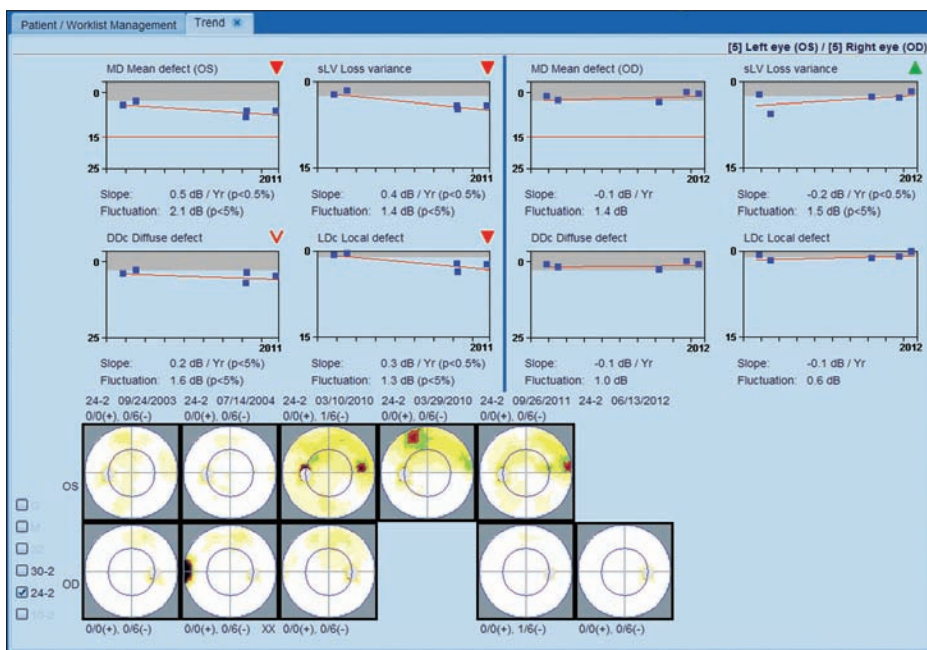
The mean deviation or mean defect (MD) gives an overall value of the total amount of visual field loss, with normal values typically within 0dB to -2dB. The MD value becomes more negative as the overall field worsens—a common example is when a cataract progresses.

Using MD for tracking changes to localized field loss (as in glaucoma) is limited. For patients with a localized visual field defect, the pattern standard deviation (PSD) best quantifies the amount of loss as well any progression of glaucoma in the early stages. Note that the PSD is not helpful in tracking advanced glaucomatous defects. Despite its limitations, the MD value can be helpful in tracking moderate stage glaucomatous visual field loss (-6dB to 12dB), because at this point the amount of localized loss is significant enough to be tracked.

On the Humphrey Field Analyzer, the visual field index (VFI)—a value similar to the MD—was added to the printout several years ago. The VFI is a staging index for the total amount of field loss. It is reported to be less sensitive to cataracts.<sup>1</sup> Values range from 100% (normal) to 0% (perimetrically blind). The percentage value can be tracked over a series of tests and used as one indicator for progression.

## New Data Analysis for Chronic Disease

Accurate progression analysis of VF changes is essential to monitor patients with optic nerve



**5. This is a progression analysis printout (EyeSuite, Haag-Streit) for a patient with advancing glaucoma in the left eye. EyeSuite uses the mean defect (same as mean deviation) value, among others, to plot the rate of change. In this example with visual field tests from 2003 to 2011, there is a negative slope to the MD. Red triangles generated by the software alert the clinician.**



#1 PRESCRIPTION  
ALLERGY EYE DROP<sup>1</sup>

# Zero-itch

Starts Here

Once Daily  
**Pataday**<sup>TM</sup>  
(olopatadine hydrochloride  
ophthalmic solution) 0.2%

Prescribe the Number One prescription allergy eye drop to Start and Finish the day with Zero-itch.<sup>1,2</sup>

- **Start:** As soon as 3 minutes following allergen challenge, 60% of patients achieved Zero-itch\*\*
- **Finish:** At 16 hours, 60% of patients had Zero-itch\*\*†

\*Post-hoc analysis of combined data from two studies using a contralateral conjunctival allergen challenge (CAC). Based on a scale of itching scores of 0-4, with 0 as no itching and 4 as severe itching. Ocular itching was evaluated 3 minutes after allergen challenge at onset and at 16 hours. †(N=85; 95% CI=48.8, 70.5) ‡(N=82; 95% CI=48.3, 70.4)

## BRIEF SUMMARY OF PRESCRIBING INFORMATION

**INDICATIONS AND USAGE:** PATADAY<sup>TM</sup> solution is a mast cell stabilizer indicated for the treatment of ocular itching associated with allergic conjunctivitis.

**DOSAGE AND ADMINISTRATION:** The recommended dose is one drop in each affected eye once a day.

**DOSAGE FORMS AND STRENGTHS:** Ophthalmic solution 0.2%: each ml contains 2.22 mg of olopatadine hydrochloride.

**CONTRAINDICATIONS:** None.

**WARNINGS AND PRECAUTIONS:** For topical ocular use only; not for injection or oral use. **Contamination of Tip and Solution:** As with any eye drop, to prevent contaminating the dropper tip and solution, care should be taken not to touch the eyelids or surrounding areas with the dropper tip of the bottle. Keep bottle tightly closed when not in use.

**Contact Lens Use:** Patients should be advised not to wear a contact lens if their eye is red. PATADAY<sup>TM</sup> (olopatadine hydrochloride ophthalmic solution) 0.2% should not be used to treat contact lens related irritation. The preservative in PATADAY<sup>TM</sup> solution, benzalkonium chloride, may be absorbed by soft contact lenses. Patients who wear soft contact lenses and whose eyes are not red, should be instructed to wait at least ten minutes after instilling PATADAY<sup>TM</sup> (olopatadine hydrochloride ophthalmic solution) 0.2% before they insert their contact lenses.

**ADVERSE REACTIONS:** Symptoms similar to cold syndrome and pharyngitis were reported at an incidence of approximately 10%. The following ocular adverse experiences were reported in 5% or less of patients: blurred vision, burning or stinging, conjunctivitis, dry eye, foreign body sensation, hyperemia, hypersensitivity, keratitis, lid edema, pain and ocular pruritus. The following non-ocular adverse experiences were reported in 5% or less of patients: asthenia, back pain, flu syndrome, headache, increased cough, infection, nausea, rhinitis, sinusitis and taste perversion. Some of these events were similar to the underlying disease being studied.

**USE IN SPECIFIC POPULATIONS: Pregnancy: Teratogenic effects: Pregnancy Category C.** Olopatadine was found not to be teratogenic in rats and rabbits. However, rats treated at 600 mg/kg/day, or 150,000 times the MROHD and rabbits treated at 400 mg/kg/day, or approximately 100,000 times the MROHD, during organogenesis showed a decrease in live fetuses. In addition, rats treated with 600 mg/kg/day of olopatadine during organogenesis showed a decrease in fetal weight. Further, rats treated with 600 mg/kg/day of olopatadine during late gestation through the lactation period showed a decrease in neonatal survival and body weight. There are, however, no adequate and well-controlled studies in pregnant women. Because animal studies are not always predictive of human responses, this drug should be used in pregnant women only if the potential benefit to the mother justifies the potential risk to the embryo or fetus. **Nursing Mothers:** Olopatadine has been identified in the milk of nursing rats following oral administration. It is not known whether topical ocular administration could result in sufficient systemic absorption to produce detectable quantities in the human breast milk. Nevertheless, caution should be exercised when PATADAY<sup>TM</sup> (olopatadine hydrochloride ophthalmic solution) 0.2% is administered to a nursing mother. **Pediatric Use:** Safety and effectiveness in pediatric patients below the age of 2 years have not been established. **Geriatric Use:** No overall differences in safety and effectiveness have been observed between elderly and younger patients.

**NONCLINICAL TOXICOLOGY:** Olopatadine administered orally was not carcinogenic in mice and rats in doses up to 500 mg/kg/day and 200 mg/kg/day, respectively. Based on a 40 µL drop size and a 50 kg person, these doses were approximately 150,000 and 50,000 times higher than the maximum recommended ocular human dose (MROHD). No mutagenic potential was observed when olopatadine was tested in an in vitro bacterial reverse mutation (Ames) test, an in vitro mammalian chromosome aberration assay or an in vivo mouse micronucleus test. Olopatadine administered to male and female rats at oral doses of approximately 100,000 times MROHD level resulted in a slight decrease in the fertility index and reduced implantation rate; no effects on reproductive function were observed at doses of approximately 15,000 times the MROHD level.

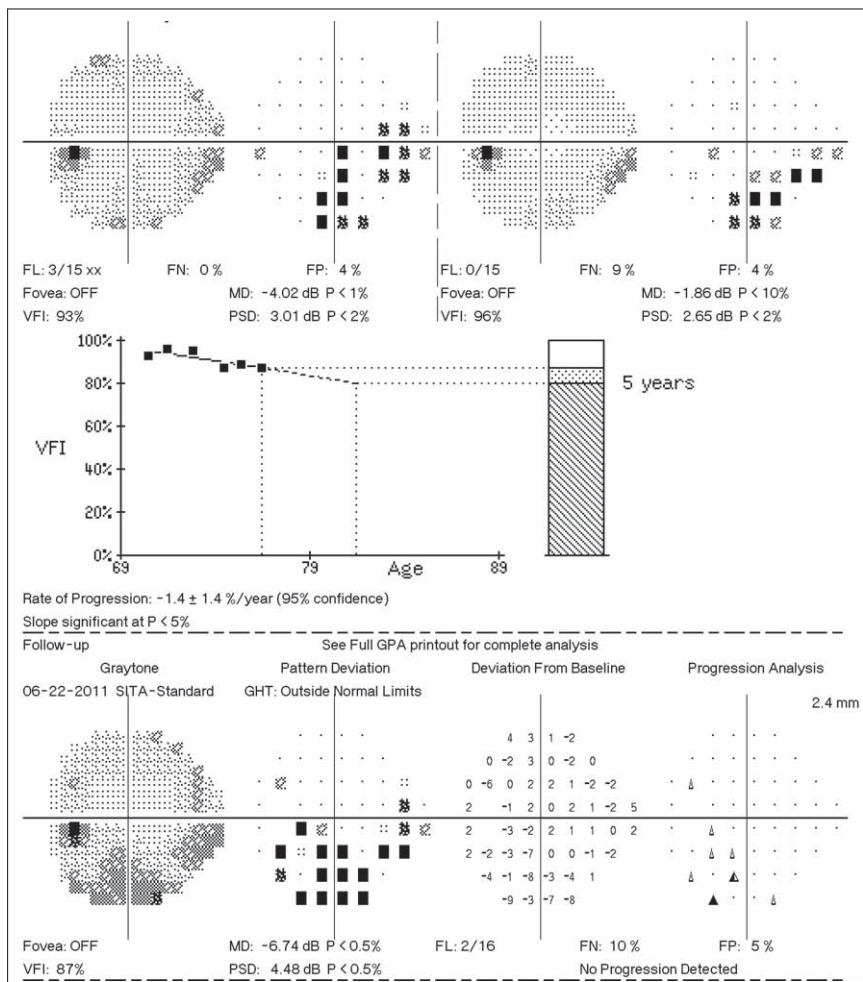
U.S. Patents Nos. 5,641,805; 6,995,186; 7,402,609

**References:** 1. IMS Health, IMS National Prescription Audit<sup>TM</sup>, August 2010 to September 2012, USC 61500 OPTH ANTI-ALLERGY. 2. Blaiss MS, Torf MJ. Zero itch in eyes treated with olopatadine hydrochloride ophthalmic solution, 0.2% in bilateral conjunctival allergen challenge studies. Poster presented at: World Allergy Conference; December 2011; Cancun, Mexico.

**Alcon**

a Novartis company

© 2013 Novartis 11/12 PAT13002JAD



**6. This is a progression analysis printout (Guided Progression Analysis, or GPA, Humphrey Field Analyzer) for a patient with advancing glaucoma in the left eye. The two baseline fields are on the top while the most recent test is on the bottom. In the middle is a trend line analysis, which is a regression line of the VFI values for the series of tests. The slope of this line is plotted as a rate of change indicator. While many variables must be considered, values of -1.5% or more should be considered high, and more aggressive therapy may be indicated.<sup>1</sup>**

disease, particularly glaucoma. In the past, the trend or change analysis provided on the printout was very limited. Clinicians resorted to looking back over multiple VF pages scattered within the patient's chart. They could also try to track the MD or PSD to see if individual values got worse or stayed the same. Practically speaking, this was a tedious and time-consuming task. Instead, some doctors simply

looked only at the gray scale to see if the defect got larger or darker—but doing so could lead to major errors in VF interpretation.

New perimeters incorporate a much more accurate tracking system for decibel values. Using the most recent software packages, they are able to display trend lines that can quantify the rate of change to the visual field defect (figure 5). These trend lines are a statistical

regression line analysis of the MD value or a similar value that reflects the overall field sensitivity. New perimeters can produce graphs with a regression line based upon a series of visual fields over a time period. A line with a negative slope indicates worsening of the VF defect. The slope of this line can be calculated by the perimeter and provide the rate of loss. Identifying the rate of change (loss) in a glaucoma patient is a new piece of information that allows differentiation of “slow” progressors that have a shallow, sloped trend line as compared to “rapid” progressors with a very steep slope trend line.

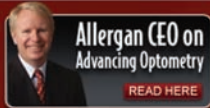Some progression analysis plots can also provide a five-year projection of VF loss, assuming no change in treatment or underlying disease. An example of this is seen in the Humphrey Field Analyzer GPA printout that uses the VFI (figure 6).

These progression plots have had the largest impact on patient management for chronic disease, significantly improving any clinician's ability to identify change. With a little experience, they are easily read and understood. Unfortunately, their use is not widespread, either from lack of awareness or from doctors and clinics using outdated software.

Practitioners should evaluate their current perimeter and investigate options for upgrading hardware and or software so that they can use the newest tools. ■

*Dr. Chaglasian is an associate professor at Illinois College of Optometry and chief of staff of the Illinois Eye Institute, in Chicago.*

1. Heijl A, Patella VM, Bengtsson B. The Field Analyzer Primer: Effective Perimetry. 4th ed. Dublin, CA: Carl Zeiss Meditec; 2012.



# Allergan and Your Practice...

## Proud to Be a Part of Your World

When you thrive, we thrive. That's how opportunity brings us together.

### Register for Updates and Our e-Newsletter

Enter your information below to sign up!

First Name

Last Name

E-mail

Yes, I would like to receive future communications from Allergan.

**SUBMIT**

### Calendar of Commitment

Las Vegas, NV  
September 21-24, 2011

Great Western Council Optometry  
Portland, OR  
October 6-9, 2011

American Academy of Optometry



Visit [allerganoptometry.com](http://allerganoptometry.com) today

# One Website. A World of Resources.

## Proud to Be a Part of Your World

Allergan offers the optometry community quality products, educational programs, and practice support. Our goal is to be your partner in patient care. When you thrive, we thrive; that's how opportunity brings us all together.

Visit our optometry-dedicated website for more information.



Get the free mobile app at <http://gettag.mobi>

- RESTASIS® (Cyclosporine Ophthalmic Emulsion) 0.05% • LASTACFT™ (alcaftadine ophthalmic solution) 0.25%  
 • ALPHAGAN® P (brimonidine tartrate ophthalmic solution) 0.1% • COMBIGAN® (brimonidine tartrate/timolol maleate ophthalmic solution) 0.2%/0.5%  
 • LUMIGAN® (bimatoprost ophthalmic solution) 0.01% • ACUVAIL® (ketorolac tromethamine ophthalmic solution) 0.45%  
 • REFRESH® OPTIVE™ Lubricant Eye Drops • ZYMAXID® (gatifloxacin ophthalmic solution) 0.5% • LATISSE® (bimatoprost ophthalmic solution) 0.03%

# How and Why to Get Behind Health Exchanges

It took more than two decades for optometrists to achieve drug prescribing rights. Now, ODs face another challenge: not getting shut out of Obamacare.

By Cheryl Murphy, OD, Contributing Editor

Providing the highest possible quality eye care to our patients has been something optometrists have always found to be worth fighting for. After an uphill battle fought and waged by ODs nationwide for almost 17 years, each state in the US obtained DPA privileges, beginning with Rhode Island in 1971

and ending with Maryland in 1989. TPA rights took even longer—22 years.

Right now, for instance, optometrists in Florida are seeking prescriptive authority for oral medications. This reminds us that we are a legislated profession; we have to earn our privileges through legislation. Likewise, legislation supported

by our opponents could potentially revoke those privileges—privileges that we perhaps take for granted.

## Automatic Privileges?

Considering the decades' long struggle to gain DPA and TPA rights, it is amazing to think that since 1998, optometry students in the US graduate with DPA and TPA rights automatically. Yet, for some optometrists outside of the 50 states, the fight for prescriptive privileges is still being waged.

- **Puerto Rico.** In summer 2012, optometrists in Puerto Rico tried to obtain the right to deliver the level and quality of care matching that of other US ODs who have TPA rights. But once again, the bill was defeated—it was the seventh attempt in 15 years to pass such a bill. ODs in Puerto Rico may have lost this round, but vow to continue to fight for TPA rights.

- **Virgin Islands.** In July 2012, the US Virgin Islands joined all 50 states to become the latest jurisdiction to acquire therapeutic

## What Exactly is a Health Insurance Exchange?

“A health insurance exchange is an online marketplace targeted toward the individual market and those who work in a company of less than 100 employees who do not currently have insurance coverage or sufficient insurance coverage to purchase health insurance,” says Brian Reuwer, associate director of Advocacy and Affiliate Outreach for the American Optometric Association.

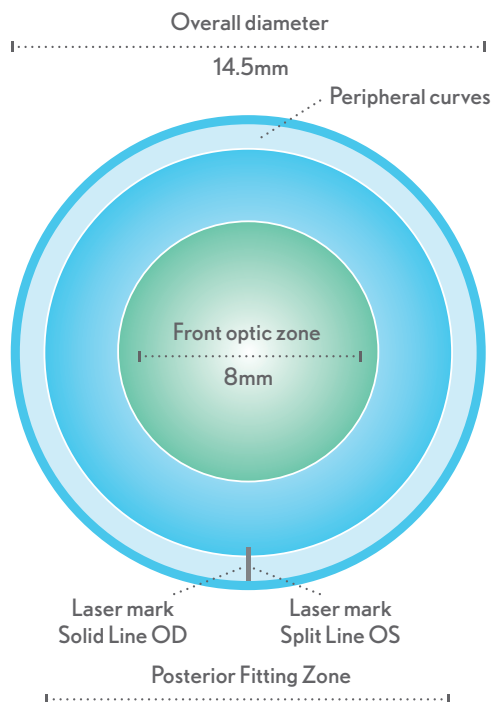
“The idea is that these two groups [the individual market and small group market], who are among the highest percentage of uninsured individuals, would be able to purchase reasonably affordable insurance if they were put into large insurance pools and given tax subsidies,” Mr. Reuwer says.

These two exchanges—the exchange for individuals and the Small Business Health Options Program (SHOP) exchange—are technically separate but each state will have the choice to keep them separate or to combine them together and run them as one exchange (which is what most states are doing).

Mr. Reuwer adds, “The exchange can be run in one of three ways: by the state, as a partnership between the federal government and a state, or as a federally-facilitated exchange.” Exchanges must be operational by January 1, 2014.

# BAUSCH + LOMB KERASOFT® IC

## A revolutionary design for keratoconus and other irregular corneas.



KeraSoft® IC soft contact lenses feature:

- Anterior aspheric optics which correct corneal irregularity rather than mask it with thickness of material.
- Adjustable periphery which fits any corneal shape
- Silicone hydrogel for excellent comfort and a higher level of oxygen

Available from authorized KeraSoft IC laboratories:

ABB CONCISE

800-772-3911  
abbconceive.com

Art Optical Contact Lens, Inc.

800-253-9364  
artoptical.com

Metro Optics

800-223-1858  
metro-optics.com

All trademark information pertains to the U.S. only.  
© Bausch & Lomb Incorporated. ®/™ are trademarks of Bausch & Lomb Incorporated or its affiliates. Definitive is a trademark of Contamac Ltd. GLOBAL-0970

privileges. But it wasn't easy. They suffered strong opposition from both local ophthalmologists and others nationwide. But, the persistence of the Virgin Island ODs paid off. The bill was passed on July 18.

## The Fight Has Just Begun

Maintaining and expanding the scope of optometry in the US requires continued support, persistence and a drive forward. Ensuring that each and every person in the United States is able to receive high quality eye care is our next fight, and it's already being waged.

Following the approval of President Obama's Patient Protection and Affordable Care Act of 2010 (PPACA), essential health benefits packages and health insurance exchanges are now being set up in order to ensure that each individual will be able to get the health care they need.

Optometrists want and need to be included on the provider panels for these newly insured individuals. (See *"What Exactly is a Health Insurance Exchange?"* page 46.) Currently, 18 states have been conditionally approved to operate state-based health insurance exchanges, and two states have been conditionally approved to operate state partnership exchanges.

It's important for optometrists to understand that "this is a new insurance marketplace for those who do not currently have insurance, so these are new patients and nobody who currently has insurance will lose it," says the AOA's Brian Reuwer. "This also means that the health plans sold in the exchange will be subject to state insurance laws that prohibit discriminatory behavior by insurance companies, including the prohibitions under the Harkin Amendment—the first-of-its-kind federal nondiscrimination law that applies to health plans inside and outside of the exchange."

The Harkin Amendment was the landmark provision that "bars health insurers from discriminating in plan coverage and participation against ODs and other providers," according to the AOA. This means that once ODs are included on the medical panel, they should not be discriminated against because of the type of license they have. It also means that newly insured patients will have access to ODs when they buy their insurance through the health insurance exchange. The Harkin Amendment, which is part of the PPACA, is set to go into effect in 2014.

The plans that participate in each

state's health insurance exchange are required to include certain health care benefits. These mandatory benefits are referred to as an essential health benefits package. (See *"What is the Essential Health Benefits Package?"* below.)

For eye doctors, one of the most important categories in the essential health benefits package is the inclusion of the pediatric vision benefit.

"A specific pediatric vision benefit has not necessarily been standard in commercial health plans," says Mr. Reuwer. "So, in order to help states create a definition of the pediatric vision benefit, HHS said they could supplement the benefit with the largest Federal Employees Dental and Vision Insurance Program (FEDVIP) or the Children's Health Insurance Program (CHIP). The largest FEDVIP plan [includes] a yearly comprehensive eye examination with a materials benefit for glasses or contacts."

In addition, he says, "other medical eye services are included in another category—generally ambulatory patient services—but optometrists' services could be covered in other categories, as well."

While an adult eye exam is not considered an essential benefit, some of the plans include the exam as part of its benchmark, says Mr. Reuwer. "In states where it is not included, there may be an opportunity for the local affiliates to add that to the plan," he says.

## Show 'Em Your Stuff

This is where optometrists come in. Health plans will need to ensure there are a sufficient number of providers on the health panels to provide the pediatric vision benefit.

"While the law does not specify which professionals patients must see to receive their new benefits, because the majority of the services

### What is the Essential Health Benefits Package?

Health plans that participate in each state's health insurance exchange are required to include 10 essential health care benefits. Among these benefits are ambulatory patient services, emergency services, hospitalization, maternity/newborn care, mental health/substance abuse services, prescription drugs, laboratory services and more.

One of those mandatory benefits: pediatric services, including vision and dental care.

"The federal government recently issued a proposed rule that allowed a state to choose a benchmark health plan to base the essential health benefit (EHB) package for a transition period of two years. Afterwards, the federal government may develop another process for determining the essential health benefit package," Mr. Reuwer says.

EHBs are all set for 2014 and 2015, he adds. "Each state was given the opportunity to choose a commercial health plan that would be the basis for the EHB. If they did not, then the federal government would choose a plan for them."



will be primary eye care in nature, the bulk of the patients will be getting their eye care through optometrists,” says Mr. Reuwer.

He adds that, “while this does mean that insurance companies will have a lot of influence on the health care system, current state law, the Harkin Amendment and strong advocacy by the profession will help optometrists work towards fair and equitable treatment with a health plan.”

Optometrists, along with the AOA, will work with state affiliates to make certain that those plans “are opening their networks and including optometrists—not just ophthalmologists—to ensure the newly insured are getting access to high quality eye care,” Mr. Reuwer says.

This is where US optometrists

should focus our efforts. In addition to showing global support for full-scope optometric rights and privileges, we have to be sure that optometrists are front and center in the medical arena. We need to show other health care professionals and those in government that we are competent, ready and willing to do our part to provide each and every person with the quality eye care that they deserve and need.

How exactly do we do that? Optometrists around the country need to start monitoring health plans that are applying to sell in the exchanges; when the opportunity arises, and if it is a smart business decision for your practice, try to sign up for these health plans.

“With the influx of the newly insured and children across the country getting access to a strong

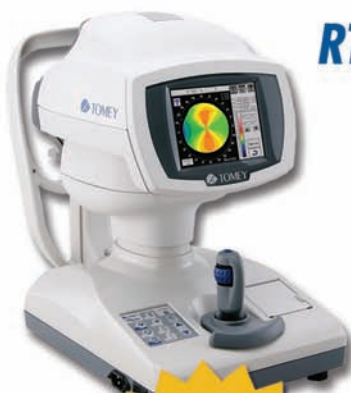vision and materials benefit, there will be opportunities for optometrists to see these newly-insured patients,” Mr. Reuwer says.

Also, “because the new coverage will be embedded in health plans and access to these patients will be through the health plans, it’s more important than ever for optometrists to be vigilant and to report to their state affiliates and the AOA if there is any discriminatory activity by health plans, so that it can be dealt with,” he adds. “The PPACA and current state law, including the Harkin Amendment, gives organized optometry some very powerful tools to combat discriminatory behavior by health plans. So, we must ensure that patients continue to have access to high quality services—and that we continue to fight to keep it that way.” ■



# TOMEY®

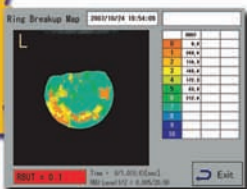
## TOMEY USA proudly presents the RT-7000 and EM-3000!



### RT-7000 (3-in-1)

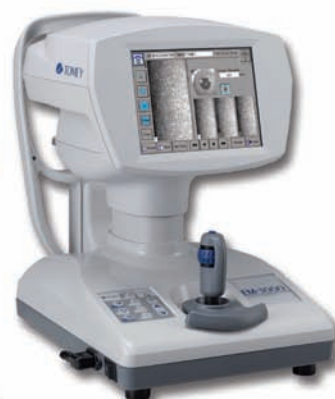- 3 Functions in 1 Instrument: Auto Refractor, Keratometer, & Topographer
- Easy & Fast Touch Screen
- Auto Alignment/Shot
- Tear Stability Analysis System-Mode for Dry Eye
- Diameter Measurement of Cornea & Pupil

**Dry Eye Software Included!**



### EM-3000 Specular Microscope

- Automated Cell Counter
- Progression and Manual Count
- 7 Fixation Targets
- More Cells used for calculation means more accuracy
- LED Light Source: Easy on the eyes and warranted for the life of the unit
- Pachymetry without contact
- Used in studies across the country



888-449-4045 • WWW.TOMEYUSA.COM

# Review Meetings 2013

## SAVE THESE DATES FOR 2013

Join us for up to 15 CE\* credits!  
Educational Chair: Paul Karpecki, OD

**Maui 2013**  
... a meeting of clinical excellence

**JUNE 13-16, 2013**

Wailea Beach Marriott, Maui

**BERMUDA 2013**  
...a meeting of clinical excellence

**JULY 25-28, 2013**

Fairmont Hamilton Princess, Bermuda

**New Technology  
& Treatments**  
IN VISION CARE  
WEST COAST

**SEPTEMBER 20-22, 2013**

Marriott Del Mar, San Diego

**NEW TECHNOLOGY  
& TREATMENTS** IN VISION CARE  
EAST COAST

**NOVEMBER 22-24, 2013**

Westin Alexandria, Virginia

More information and registration available shortly.

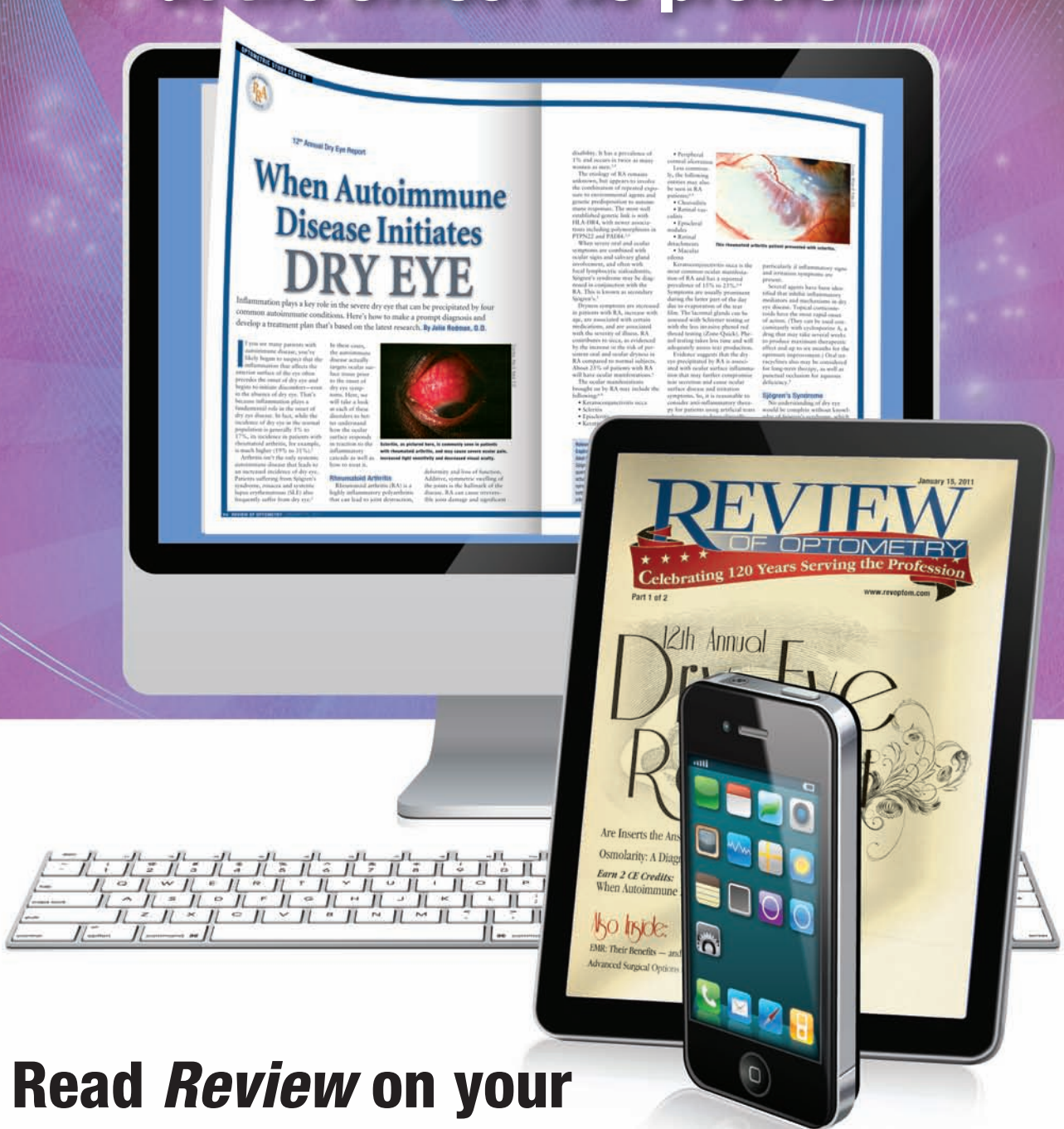Please contact Lois DiDomenico with questions at [ReviewMeetings@Jobson.com](mailto:ReviewMeetings@Jobson.com) or 1-866-658-1772.

Check back for more information: [www.revoptom.com/conferences](http://www.revoptom.com/conferences)



\*Approval Pending

# Left your issue of *Review of Optometry* at the office? No problem!



Read *Review* on your desktop or mobile device!

Simply go to [www.revoptom.com](http://www.revoptom.com) and click on the digital edition link to read the current issue online.



# Anti-inflammatory in Ocular Allergy Treatment

Steroids used to be reserved for non-responsive cases. But now many optometrists are using them as a first-line therapy for allergic conjunctivitis.

By A.J. DeVivo, OD, and Terry Scheid, OD

A patient presents after being exposed to dust mites in her office building. The allergen exposure causes substantial amounts of histamine to be released, dilating her conjunctival microvasculature and creating conjunctival hyperemia and chemosis. She's suffering with intense ocular itching, burning and profuse tearing, and she wants relief now.

It's likely you encounter patients like this in your office frequently—some recent studies suggest that up to 40% of the population in developed countries experience symptoms of ocular allergy, or allergic conjunctivitis (AC).<sup>1</sup> Unfortunately, this common condition is often underdiagnosed and undertreated until it reaches severe levels.<sup>2</sup>

Just a decade ago, mast cell stabilizers and antihistamines were the primary therapy for AC—with steroids reserved for non-responsive cases. Today, with our understanding of ester steroids and their efficacy of breaking the allergic cascade in both early and late phases of the allergic response, many astute optometrists are using steroids as first-line therapy.

In this article, we'll review the use of anti-inflammatory therapy for ocular allergies, particularly the judicious use of topical steroids and nonsteroidal anti-inflammatories (NSAIDs) in AC.

## Stepping It Up

When patients present with rhinitis, itching, foreign body sensation, conjunctival chemosis, hyperemia, papillary conjunctivitis, tearing and discharge, we need to consider AC. Acute and chronic symptoms and signs need to be evaluated by thorough patient history and exam.

Because ocular allergies can present with such a wide array of symptoms at varying levels of severity, the best route to take is often a stepwise approach to treatment—from non-medical treatment, including cold compresses and artificial tears, to antihistamine/mast cell stabilizers, NSAIDs and ester-based steroids. Typically used as the first line of defense, antihistamine/mast cell stabilizers are fast and effective. These dual-acting medications block the effects of histamine and prohibit mast cells from releasing the chemicals responsible for allergy

symptoms. When symptoms continue to persist or are particularly severe, adding an anti-inflammatory can help enhance the effects of the antihistamine/mast cell stabilizers until the patient's condition improves.

For severe symptoms, a top-down approach or combination therapy allows you to target symptoms effectively without overmedicating the patient.

## Steroids

For mild, chronic AC, continuous use of combination antihistamine/mast cell stabilizers typically is the treatment of choice because of its safety profile. However, when the patient is experiencing more frequent or more severe symptoms, that's when you may want to consider a steroid. Because of its safety profile and efficacy against inflammatory cells, loteprednol etabonate in ophthalmic suspensions of 0.2% (Alrex, Bausch + Lomb) or 0.5% (Lotemax, Bausch + Lomb) is a steroid of choice for many doctors.<sup>3</sup>

A new addition to the market, Lotemax gel has quickly become another popular choice because of

FOR PATIENTS WITH ITCHING DUE TO ALLERGIC CONJUNCTIVITIS

ITCHY ALLERGY EYES CAN BREAK UP THEIR DAY AT ANY TIME



## GIVE THEM A DROP THAT LASTS

Proven effective through 16 hours<sup>1-3</sup>

### INDICATIONS AND USAGE

LASTACRAFT® (alcaftadine ophthalmic solution) 0.25% is an H<sub>1</sub> histamine receptor antagonist indicated for the prevention of itching associated with allergic conjunctivitis.

### MECHANISM OF ACTION

Alcaftadine is an H<sub>1</sub> histamine receptor antagonist and inhibitor of the release of histamine from mast cells. Decreased chemotaxis and inhibition of eosinophil activation have also been demonstrated.

### IMPORTANT SAFETY INFORMATION

#### WARNINGS AND PRECAUTIONS

To minimize contaminating the dropper tip and solution, care should be taken not to touch the eyelids or surrounding areas with the dropper tip of the bottle. Keep bottle tightly closed when not in use.

Patients should be advised not to wear a contact lens if their eye is red.

LASTACRAFT® should not be used to treat contact lens-related irritation.

Remove contact lenses prior to instillation of LASTACRAFT® (alcaftadine ophthalmic solution) 0.25%. The preservative in LASTACRAFT®, benzalkonium chloride, may be absorbed by soft contact lenses. Lenses may be reinserted after 10 minutes following administration of LASTACRAFT®.

LASTACRAFT® is for topical ophthalmic use only.

#### ADVERSE REACTIONS

The most frequent ocular adverse reactions, occurring in < 4% of LASTACRAFT® treated eyes, were eye irritation, burning and/or stinging upon instillation, eye redness, and eye pruritus.

The most frequent non-ocular adverse reactions, occurring in < 3% of subjects with LASTACRAFT® treated eyes, were nasopharyngitis, headache, and influenza. Some of these events were similar to the underlying disease being studied.

Please see Brief Summary of full Prescribing Information on adjacent page.

Visit [Lastacraft.com](http://Lastacraft.com) for money-saving offers

Once-daily dosing<sup>1</sup>

1. LASTACRAFT® Prescribing Information. 2. Torkildsen G, Shedden A. The safety and efficacy of alcaftadine 0.25% ophthalmic solution for the prevention of itching associated with allergic conjunctivitis. *Curr Med Res Opin.* 2011;27(3):623-631. 3. Data on file, Allergan, Inc., 2005.



©2013 Allergan, Inc., Irvine, CA 92612  
® marks owned by Allergan, Inc.  
[www.Lastacraft.com](http://www.Lastacraft.com) APC24XK12 123382

 **LASTACRAFT®**  
(alcaftadine ophthalmic solution) 0.25%

**LAST ON**

## Brief Summary of the full Prescribing Information

### INDICATIONS AND USAGE

LASTACRAFT<sup>®</sup> is an H<sub>1</sub> histamine receptor antagonist indicated for the prevention of itching associated with allergic conjunctivitis.

### DOSE AND ADMINISTRATION

Instill one drop in each eye once daily.

### CONTRAINDICATIONS

None.

### WARNINGS AND PRECAUTIONS

#### Contamination of Tip and Solution

To minimize contaminating the dropper tip and solution, care should be taken not to touch the eyelids or surrounding areas with the dropper tip of the bottle. Keep bottle tightly closed when not in use.

#### Contact Lens Use

Patients should be advised not to wear a contact lens if their eye is red. LASTACRAFT<sup>®</sup> should not be used to treat contact lens-related irritation.

LASTACRAFT<sup>®</sup> should not be instilled while wearing contact lenses. Remove contact lenses prior to instillation of LASTACRAFT<sup>®</sup>. The preservative in LASTACRAFT<sup>®</sup>, benzalkonium chloride, may be absorbed by soft contact lenses. Lenses may be reinserted after 10 minutes following administration of LASTACRAFT<sup>®</sup>.

#### Topical Ophthalmic Use Only

LASTACRAFT<sup>®</sup> is for topical ophthalmic use only.

### ADVERSE REACTIONS

Because clinical trials are conducted under widely varying conditions, adverse reaction rates observed in the clinical trials of a drug cannot be directly compared to rates in the clinical trials of another drug and may not reflect the rates observed in clinical practice.

#### Ocular Adverse Reactions

The most frequent ocular adverse reactions, occurring in < 4% of LASTACRAFT<sup>®</sup> treated eyes, were eye irritation, burning and/or stinging upon instillation, eye redness and eye pruritus.

#### Non-ocular Adverse Reactions

The most frequent non-ocular adverse reactions, occurring in < 3% of subjects with LASTACRAFT<sup>®</sup> treated eyes, were nasopharyngitis, headache and influenza. Some of these events were similar to the underlying disease being studied.

### USE IN SPECIFIC POPULATIONS

#### Pregnancy

Pregnancy Category B. Reproduction studies performed in rats and rabbits revealed no evidence of impaired female reproduction or harm to the fetus due to alcaftadine. Oral doses in rats and rabbits of 20 and 80 mg/kg/day, respectively, produced plasma exposure levels approximately 200 and 9000 times the plasma exposure at the recommended human ocular dose. There are however, no adequate and well controlled studies in pregnant women. Because animal reproduction studies are not always predictive of human response, this drug should be used during pregnancy only if clearly needed.

#### Nursing Mothers

It is not known whether this drug is excreted in human milk. Because many drugs are excreted in human milk, caution should be exercised when LASTACRAFT<sup>®</sup> is administered to a nursing woman.

#### Pediatric Use

Safety and effectiveness in pediatric patients below the age of 2 years have not been established.

#### Geriatric Use

No overall differences in safety or effectiveness were observed between elderly and younger subjects.

### NONCLINICAL TOXICOLOGY

#### Carcinogenesis, Mutagenesis, Impairment of Fertility

Alcaftadine was not mutagenic or genotoxic in the Ames test, the mouse lymphoma assay or the mouse micronucleus assay.

Alcaftadine was found to have no effect on fertility of male and female rats at oral doses up to 20 mg/kg/day (approximately 200 times the plasma exposure at the recommended human ocular dose).

### PATIENT COUNSELING INFORMATION

#### Sterility of Dropper Tip

Patients should be advised to not touch dropper tip to any surface, as this may contaminate the contents.

#### Concomitant Use of Contact Lenses

Patients should be advised not to wear a contact lens if their eye is red. Patients should be advised that LASTACRAFT<sup>®</sup> should not be used to treat contact lens-related irritation. Patients should also be advised to remove contact lenses prior to instillation of LASTACRAFT<sup>®</sup>. The preservative in LASTACRAFT<sup>®</sup>, benzalkonium chloride, may be absorbed by soft contact lenses. Lenses may be reinserted after 10 minutes following administration of LASTACRAFT<sup>®</sup>.

#### Topical Ophthalmic Use Only

#### Rx only

©2012 Allergan, Inc.  
Irvine, CA 92612, U.S.A.  
® marks owned by Allergan, Inc.  
Based on 72409US11C  
APC47PL12

several advantages it offers: It does not require shaking; contains 70% less preservatives than its suspension; and contains two moisturizers, propylene glycol and glycerin.<sup>4,6</sup> The engineered mucoadhesive technology turns the gel into a liquid when placed on the eye, helping it to adhere and reducing gel-related blur.<sup>4,5,7,8</sup>

Another option is fluorometholone, a steroid with low intraocular absorption. In a study of patients with seasonal AC, fluorometholone was found to be highly effective in reducing itching, tearing and conjunctival hyperemia over time and did not exhibit any statistically significant changes in IOP.<sup>9</sup>

Steroids block most mediators of inflammation and work effectively in the acute phase of AC. By inhibiting phospholipase A, they block the arachidonic acid pathway, preventing the synthesis of prostaglandins and leukotrienes.<sup>10</sup> They impede the migration of leukocytes to inflammatory sites, minimizing the release of inflammatory mediators from macrophages.

## NSAIDs

But what do you do when a steroid is contraindicated and an antihistamine/mast cell stabilizer just isn't effective enough to treat acute severe symptoms? Here's where a combination approach may work best. Topical NSAIDs can be a useful, short-term treatment option for AC, relieving the pain associated with inflammation.<sup>11</sup> Using topical NSAIDs along with cold compresses for one week can help make the patient more comfortable, while you can manage the chronic allergies with antihistamines and antihistamine/mast cell stabilizers, such as Bepreve (bepotastine besilate, Bausch + Lomb), Lastacraft (alcaftadine, Allergan), Patanol and Pataday (olopatadine hydrochloride, Alcon) and Elestat (epinastine, Allergan).

NSAIDs relieve itching, but they don't block histamine and hamper only a portion of the inflammatory cascade. They inhibit cyclooxygenase, an enzyme that converts arachidonic acid into lipid mediators of inflammation, such as prostaglandins.<sup>11</sup> This mechanism of action reduces prostaglandin synthesis.<sup>12,13</sup>

Research has shown that Acular LS and Acuvail (ketorolac tromethamine, Allergan) is effective for allergy treatment because of its secondary effects on the production of lipid inflammatory mediators and itch symptoms.<sup>14,15</sup>

In 2009, researchers in Japan looked at Bromday (bromfenac, Bausch + Lomb), an NSAID indicated for the treatment of postoperative inflammation and reduction of ocular pain in patients who have undergone cataract extraction.<sup>16</sup> This examiner-blinded

**Table 1. Topical Ophthalmic Corticosteroids**

Brand Name	Generic Name	Manufacturer	Dosing
Alrex	Loteprednol 0.2%	Bausch + Lomb	QID
Durezol	Difluprednate 0.05%	Alcon	QID x 7d, then BID x 7d, then taper
FML (suspension)	Fluorometholone alcohol 0.1%	Allergan	1 drop q1-12hrs up to q4h x 48hrs, then taper
FML (ointment)	Fluorometholone ophthalmic ointment 0.1%	Allergan	1/2-inch ribbon q4-24 hrs
Lotemax	Loteprednol etabonate 0.5%	Bausch + Lomb	1 drop QID x 7d, then BID x 7d, then taper
Lotemax (preservative-free ointment)	Loteprednol etabonate ointment 0.5%	Bausch + Lomb	1/2-inch ribbon up to BID for 14d
Lotemax (gel)	Loteprednol etabonate gel 0.5%	Bausch + Lomb	1 drop QID for up to 14d
Pred Forte	Prednisolone acetate suspension 1%	Allergan	BID to QID x up to 48hrs, then taper
Prednisolone Sodium Phosphate	Prednisolone sodium phosphate solution 1% or 1/8%	Bausch + Lomb	1 drop QH during the day, Q2H during the night initially, then QID then taper

study involved 22 patients with seasonal AC signs and symptoms. They treated one eye with bromfenac and the other eye with Alamast (pemirolast potassium, Vistakon), a standard mast cell stabilizer. Their results indicated that bromfenac is as safe and effective as pemirolast potassium for the treatment of seasonal AC.<sup>16</sup> (Note: This does not constitute endorsement by the manufacturers outside of the approved indication. Consult package insert for important safety information.)

### How Much and How Often?

Dosage and frequency should be based on inflammatory severity. Pulsed therapy is appropriate if a more aggressive approach is needed—an effective dose must be used for the shortest time course. Pulse dosing for no longer than 14 days with steroids is efficacious for severe AC, but there are some patients who are resistant and require other forms of initial therapy.

NSAIDs can be used successfully for moderate to severe AC if steroids are contraindicated. However, NSAIDs are not as effective as steroids because they do not directly decrease histamine release from mast cells.<sup>15</sup> They can successfully reduce pain associated with inflammation and, when used syn-

ergistically with an antihistamine/mast cell stabilizer, can serve as an effective therapy. Acular used QID has shown effectiveness for allergic conjunctivitis.<sup>17</sup>

### Clinical Presentations

Vernal keratoconjunctivitis (VKC), atopic keratoconjunctivitis (AKC), giant papillary conjunctivitis (GPC), seasonal allergic conjunctivitis (SAC) and perennial allergic conjunctivitis (PAC) are the main types of ocular allergies that challenge eye care providers.

only in males than females. Manifesting conjunctival chemosis and hyperemia of the lower eyelid more than the upper palpebral conjunctiva, in extreme cases VKC can scar the cornea and lead to vision loss, if not treated. Symptoms include itching, burning, discharge, cobblestone appearance of the tarsal conjunctiva, and Horner-Trantas dots at the limbal area.<sup>18</sup>

Oral and topical antihistamines and mast cell stabilizers are indicated, but are most useful after initial inflammation is minimized.<sup>19</sup>

**Table 2. Topical Ophthalmic NSAIDs**

Brand Name	Generic Name	Manufacturer	Dosing
Acular LS	Ketorolac tromethamine 0.4%	Allergan	1 drop QID
Acuvail	Ketorolac tromethamine 0.45%	Allergan	QID x 14d
Bromday	Bromfenac	Bausch + Lomb	1 drop x 14d
Nevanac	Nepafenac 0.1%	Alcon	TID x 14d

### Keratoconjunctivitis

VKC and AKC are usually chronic, bilateral and severe—in extreme cases, these conditions can cause damage to the ocular surface resulting in corneal scarring. Aggressive treatment is recommended for both of these forms of allergic conjunctivitis.

- **VKC.** Usually diagnosed in the juvenile and teen years during the springtime, VKC occurs more com-

Depending on presentation severity, Lotemax or Pred Forte may be used QID for several weeks, followed by BID or TID dosing for several weeks. Alrex may be used longer term due to its improved safety profile and/or initially in cases of less severity.<sup>3</sup>

- **AKC.** AKC may be a hereditary condition, an allergic hypersensitivity to an allergen prompting an IgE-mediated reaction. It can affect patients year round, particularly

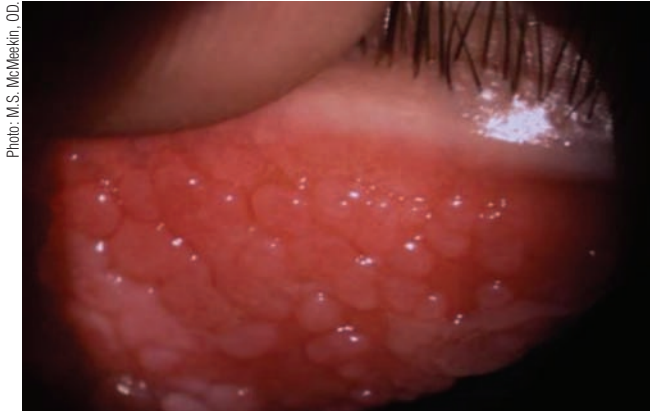


Photo: M.S. McMeekin, OD.

**1. Vernal keratoconjunctivitis.**

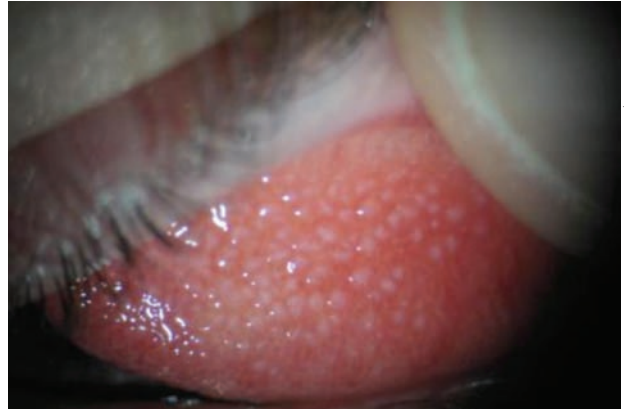

Photo: Tim Walton, OD.

**2. Giant papillary conjunctivitis.**

those who are hypersensitive or hyperallergenic. Atopic syndrome patients often have asthma, food allergies, eczema or atopic dermatitis, involving the eyelids and face. Conjunctival chemosis and papillae are common, and aggressive treatment is recommended because of the potential for conjunctival scarring and loss of vision due to frequent corneal complications.<sup>18,20-22</sup>

While this is a rare condition, it is the most debilitating type of allergic conjunctivitis—patients suffer with AKC for many years and have high rates of visual impairment.<sup>22</sup> In addition to prophylactic use of antihistamine/mast cell stabilizers, topical corticosteroids remain the standard treatment for AKC in addressing acute symptoms and exacerbations.<sup>22</sup>

However, because of the chronic nature of this disease, there is concern about the complications of long-term topical steroid use in these patients. Recent research has suggested that topical cyclosporine A may be useful as a corticosteroid-sparing agent and effective in improving AKC symptoms.<sup>22,23</sup>

### Giant Papillary Conjunctivitis

GPC may occur in the presence of soft, silicone hydrogel and gas-permeable contact lens wear,

exposed sutures, scleral and prosthetic contact lenses, and with floppy eyelid syndrome. Papillae occur on the upper lids' tarsal plate area. Papillae larger than 0.3mm in diameter are considered abnormal, and are considered giant at 1mm diameter or more. Symptoms and signs include itching and redness, mucous discharge, contact lens discomfort and intolerance, and contact lens coating and excessive movement.

The causative factor must be addressed. If the condition is contact lens induced, standard care involves refitting the patient into daily disposables or recommending hydrogen peroxide care systems with frequent lens replacement. Mast cell stabilizers were once the mainstay of topical medication therapy. Today, antihistamine/

mast cell stabilizers and short-term steroid use are preferred treatments. In moderate, severe or persistent cases, topical steroids effectively reduce the inflammatory response. Typical dosage of Lotemax is four to six times per day for one week or longer, followed by BID dosing until the condition is effectively controlled. FML also has demonstrated effectiveness in treating GPC.<sup>24</sup>

### Seasonal Allergic Conjunctivitis

SAC is mostly due to airborne pollens produced by plants that cause hay fever. The allergens attach to IgE receptors, releasing histamine and other inflammatory mediators that cause hyperemia, itching, burning, swelling and tearing of the eyes and often irritation of the nasal mucosa.<sup>19</sup> Allergic rhinoconjunctivitis is more common in patients who have other allergic conditions or atopy.<sup>25</sup>

Severe symptoms often require the use of topical NSAIDs or steroids, along with antihistamine/mast cell stabilizers. Alrex is valuable for the temporary relief of seasonal allergies, and is the only topical steroid approved for the relief of SAC and PAC.<sup>3</sup> If patients have trouble instilling drops or have medication preservative issues, nighttime application of Lotemax

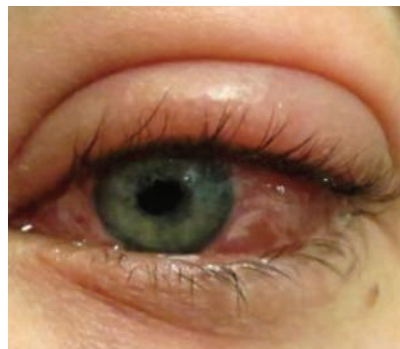

Photo: Michael Murphy, OD.

**3. Seasonal allergic conjunctivitis.**



**I·Caps®**  
EYE VITAMIN  
& MINERAL SUPPLEMENT

There's never been a better time to do something about macular health.

**ICaps® Lutein and Omega-3 Vitamin Help:**

- PROTECT the retina with lutein\*
- PROMOTE macular health\*
- SUPPORT the natural defense system of the eye\*

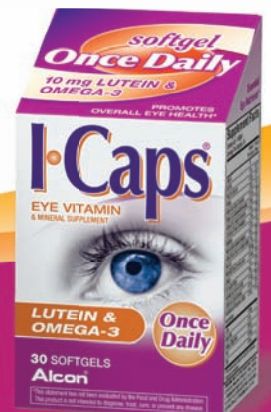**Once-Daily**



ICaps® L&O Vitamins have ingredients studied in AREDS2. It's the only once daily softgel with 10 mg of Lutein, 2 mg of Zeaxanthin and beneficial levels of Omega-3s to help support macular health.\*

Recommend ICaps® Lutein & Omega-3 Vitamin to your patients before another minute goes by.

Visit [icapsvitamins.com](http://icapsvitamins.com) to learn more.



\*These statements have not been evaluated by the Food and Drug Administration. This product is not intended to diagnose, treat, cure, or prevent any disease.

© 2012 Novartis 1/12 ICP12100JAD

**Alcon®**

**FloraGLO®**  
LUTEIN

preservative-free ointment can be used as an alternative.

## Perennial Allergic Conjunctivitis

While PAC tends to be milder than the seasonal variety, it is a chronic condition. Because it is commonly related to indoor allergens like dust mites, molds, detergents, carpeting, fabrics, indoor plants and animal dander, consulting an allergy specialist is often recommended to help identify potential causes and triggers.

Environmental modifications are the mainstay of treatment—helping the patient avoid or limit exposure to the allergen. In the home, this may include the use of indoor air filters, air conditioning, isolating pets to certain areas and thoroughly cleaning dust, dander and molds. On the road, replacing auto cabin air filters can help reduce indoor air pollution and driving with the windows up can help reduce exposure to other types of allergens.

Teaching patients not to rub their eyes and to use copious amounts of artificial tears and cool compresses can help reduce initial ocular allergy symptoms, but many patients require medical intervention during allergy distress, including short-term pulse therapy (three to four days) with a steroid or an NSAID.

The array of available anti-inflammatory medications has enhanced the treatment of ocular allergies. Combining the advantages of anti-inflammatory therapy with traditional antihistamine/mast cell stabilizers has evolved the treatment protocol. Severe ocular allergies presentations can be “tamed” with anti-inflammatory application, allowing effective use of antihistamine/mast cell stabilizers. Less severe presentations may also achieve maximal therapy with

## Under Pressure

One of the concerns for many practitioners in treating allergic conjunctivitis with steroids is the potential for IOP increase. You should monitor IOP after 10 days when prescribing any steroid—even those we affectionately know as “kinder, gentler” ester-based steroids, such as loteprednol. Any topical steroid use, including use of ester-based steroids, with contact lenses can cause a rise in IOP with prolonged use. While it’s always best to err on the side of caution by taking these safety measures, some recent research has suggested that IOP elevation is not a major problem with ester steroids.<sup>3</sup>

In 2012, a two-week, randomized, double-masked study, involving 300 patients with moderate to severe SAC symptoms, compared treatment with Alexx to Patanol, a standard antihistamine and mast cell stabilizer.<sup>26</sup> The findings indicated that there was no significant increase in IOP over a two-week time period of treatment comparing Alexx QID to Patanol BID. (Clinically significant IOP increases were defined as greater or equal to 10mm Hg relative to the initial baseline IOP measurement.) Adverse effects were similar and few in both patient treatment groups.

these full topical medication combinations. Ophthalmic practitioners and patients can benefit from these newer therapeutic techniques. ■

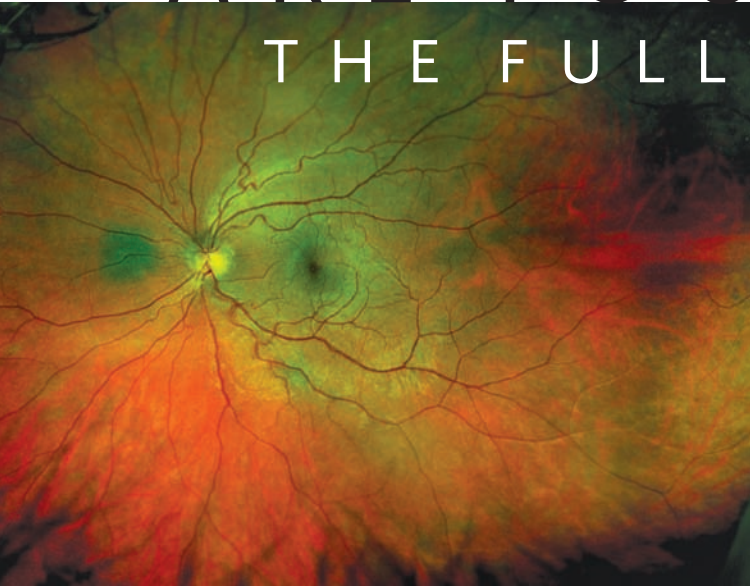*Dr. DeVivo is a clinical director of Lasik Vision Centers of Cleveland in Independence, Ohio, and the staff optometrist at Ophthalmic Physicians Inc., a private group ophthalmology practice in Mentor, Ohio. Dr. Scheid is an associate clinical professor at SUNY College of Optometry in New York and is in private practice in Merrick, NY.*

- Bartlett J. Treatment of seasonal allergic conjunctivitis [Promotional supplement supported by Bausch + Lomb. 2011. Available at: [http://walmartod.com/suppliers/bausch-and-lomb/pdf/Alexx\\_ODinsertion.pdf](http://walmartod.com/suppliers/bausch-and-lomb/pdf/Alexx_ODinsertion.pdf).
- Singh K, Axelrod S, Bielory L. The epidemiology of ocular and nasal allergy in the United States, 1988-1994. *J Allergy Clin Immunol.* 2010 Oct;126(4):778-83.
- Ilyas H, Slonim CB, Braswell GR, et al. Long-term safety of loteprednol etabonate 0.2% in the treatment of seasonal and perennial allergic conjunctivitis. *Eye Contact Lens.* 2004 Jan;30(1): 10-3.
- Fong R, Leitritz M, Siou-Mermet R, Erb, T. Loteprednol etabonate gel 0.5% for postoperative pain and inflammation after cataract surgery: results of a multicenter trial. *Clin Ophthalmol.* 2012;6:1113-24.
- Lotemax gel [package insert]. Tampa, FL: Bausch + Lomb; 2012.
- Lotemax [package insert]. Tampa, FL: Bausch + Lomb; 2006.
- Shaikh R, Singh TR, Garland MJ, et al. Mucoadhesive drug delivery systems. *J Pharm Biotechnol Sci.* 2011 Jan-Mar;3(1):89-100.
- Coffey MJ, Davio SR. Viscoelastic and sedimentation characterization of loteprednol etabonate ophthalmic gel 0.5%. Poster presented at: Association for Research in Vision and Ophthalmology (ARVO) meeting; May 6-9, 2012; Fort Lauderdale, Fla.
- Leonardi A, Papa V, Milazzo G, Secchi AG. Efficacy and safety of desonide phosphate for the treatment of allergic conjunctivitis. *Cornea.* 2002 Jul;21(5):476-81.
- Sorenson DK, Kelly TM, Murray DK, Nelson DH.

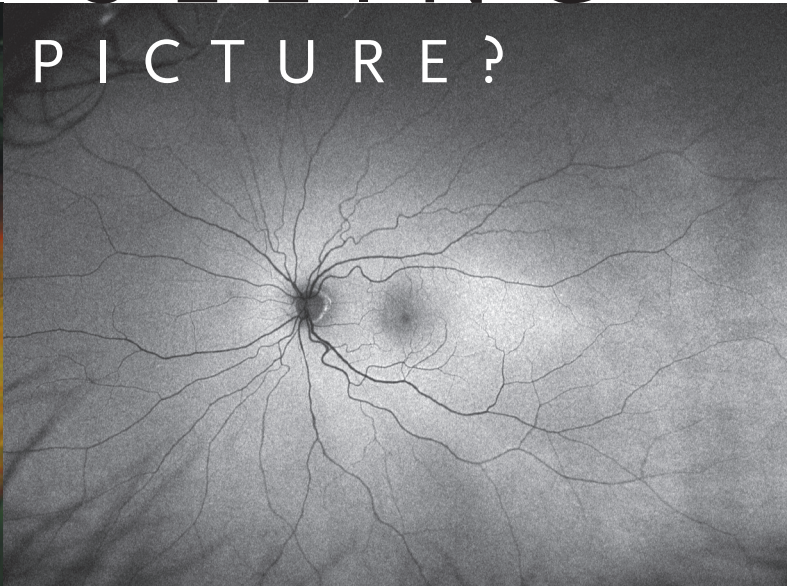
Corticosteroids stimulate an increase in phospholipase A2 inhibitor in human serum. *J Steroid Biochem.* 1988 Feb;29(2):271-3.

- McAuley DF. Ophthalmic—nonsteroidal anti-inflammatories, 1993-2012. GlobalRPh Inc. Available at: [www.globalrph.com/ophthalmic\\_nsaid.htm](http://www.globalrph.com/ophthalmic_nsaid.htm). Accessed January 24, 2013.
- Kim SJ, Flach AJ, Jampol LM. Nonsteroidal anti-inflammatory drugs in ophthalmology. *Surv Ophthalmol.* 2010 Mar-Apr;55(2):108-33.
- Mieler WF. Update regarding use and benefit of NSAIDs in ophthalmology. Presented at: the International Symposium on Ocular Pharmacology and Therapeutics (ISOPT); December 9-11, 2010; Macau, China.
- Raizman MD. Results of a survey of patients with ocular allergy treated with topical keratolac tromethamine. *Clin Ther.* 1995 Sept-Oct;17(5): 882-90.
- Pflugfelder S, O'Brien TP, Donnenfeld ED, Karpecki PM, et al. Prevention and management of ocular inflammation across the ophthalmic spectrum: proceedings from expert roundtable discussion. Georgetown, Conn: MedEdicus. Nov 1, 2012.
- Miyake-Kashima M, Takano Y, Tanaka M, et al. Comparison of efficacy of bromfenac sodium 0.1% ophthalmic solution and 0.1% pemirolast potassium for the treatment of allergic conjunctivitis. *Jpn J Ophthalmol.* 2004 Nov-Dec;48(6):587-90.
- Raizman MB. Results of a survey of patients with ocular allergy treated with topical keratolac tromethamine. *Clin Ther.* 1995 Sept-Oct;17(5):882-90.
- Khurana AK. Comprehensive Ophthalmology. 4th ed. Kent, UK: Anshan Publishers;2007.
- Bielory L, Friedlaender MH. Allergic conjunctivitis. *Immunol Allergy Clin North Am.* 2008 Feb;28(1):43-58, vi.
- Ono SJ, Abelson MB. Allergic conjunctivitis: update on pathophysiology and prospects for future treatment. *J Allergy Clin Immunol.* 2005 Jan;115(1):118-22.
- Bielory L. Allergic and immunologic disorders of the eye. Part II: ocular allergy. *J Allergy Clin Immunol.* 2000 Dec;106(6):1019-32.
- Akpek EK, Dart JK, Watson S, et al. A randomized trial of topical cyclosporin 0.05% in topical steroid-resistant atopic keratoconjunctivitis. *Ophthalmology.* 2004 Mar;111(3):476-82.
- González-López JJ, López-Alcalde J, Morcillo Laiz R, et al. Topical cyclosporine for atopic keratoconjunctivitis. *Cochrane Database Syst Rev.* 2012 Sep 12; 9:CD009078. doi: 10.1002/14651858.CD009078.pub2.
- Khurana S, Sharma N, Agarwal T, et al. Comparison of olopatadine and fluorometholone in contact lens-induced papillary conjunctivitis. *Eye Contact Lens.* 2010 Jul;36(4):210-4.
- Sullivan JB, Jr., Krieger GR. (2001). *Clinical Environmental Health and Toxic Exposures*. 2nd ed. Philadelphia: Lippincott Williams & Wilkins; 2001:341.
- Gong L, Sun X, Qu J, et al. Loteprednol etabonate suspension 0.2% administered QID compared with olopatadine solution 0.1% administered BID in the treatment of seasonal allergic conjunctivitis: a multicenter, randomized investigator-masked, parallel group study in Chinese patients. *Clin Ther.* 2012 Jun;34(6):1259-72.

# ARE YOU SEEING THE FULL PICTURE?



optomap® Ultra-Widefield Color Image



optomap® *af* Ultra-Widefield Autofluorescence Image



## Daytona

- Up to 200° of the retina in a single capture
- Ultra-high resolution digital images
- Non-mydrriatic, through 2mm pupils
- In less than a second
- Color, red-free, autofluorescence images

For more information

call **800-854-3039**

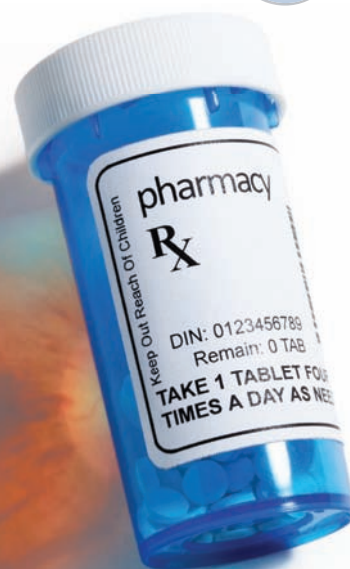or email: **BDS@optos.com**

Building *The* Retina Company





# Which Side Effects are Lurking in the Shadows?



You can't afford to stay in the dark regarding the ocular and systemic side effects of the most commonly used drugs in America.

By **Bruce G. Muchnick, OD**

If medications only yielded one specific action, prescribing drugs would be easy. In essence, a clinician would only need to monitor the patient for the desired effect and modify the dosage accordingly to achieve the preferred outcome.

In reality, however, every medication has an effect on a multitude of organ systems. In rare instances, there may be an unexpected and/or beneficial effect

of medication use. But, in many cases, side effects are dangerous or even deadly.

Package inserts rarely help us understand the totality of these unwanted consequences because each medication includes a lengthy, exhaustive list of precautions that's nearly impossible to memorize. Such extensive information may lead patients, and even practitioners, to believe that *every* drug can potentially be

associated with *every* side effect imaginable.

With more than four billion prescriptions written in the US each year, we must familiarize ourselves with the ocular and non-ocular side effects of the most commonly prescribed systemic medications.<sup>1,2</sup>

## Cholesterol Medications

Because nearly 40 million Americans (about one in eight) are considered to have elevated cholesterol levels, lipid-lowering agents, such as statins, remain the most frequently prescribed medications in the US.<sup>3,4</sup> Additionally, statins may be prescribed in cases of atherosclerosis and/or elevated triglycerides and C-reactive protein levels. Clinical trials have documented the efficacy of statins in preventing coronary heart disease, stroke and death from hypercholesterolemia-related

### Clinical Pearls for Cholesterol Medications

- Eye care practitioners should be on the lookout for unexplained diplopia, extraocular muscle palsy and ptosis in patients with a history of statin use.<sup>16</sup> Notify the prescribing physician so that a management plan, including medication discontinuation, can be considered. A subsequent modification of the patient's health care treatment may be needed to prevent cardiovascular and cerebrovascular events in the absence of a lipid-controlling medication.

- Statins should not be given concomitantly with oral macrolide antibiotics, such as erythromycin, because of an increased risk for myopathy.<sup>17</sup> Also, one rodent study showed an increased risk of rapidly developing cataract when systemic erythromycin was used concurrently with simvastatin.<sup>18</sup>

For allergic conjunctivitis<sup>1</sup>

# THE POWER TO CALM THE ITCH



**BEPREVE®—FIRST-LINE, YEAR-ROUND,  
WITH BROAD-SPECTRUM ALLERGEN COVERAGE**

## **INDICATION AND USAGE**

BEPREVE® (bepotastine besilate ophthalmic solution) 1.5% is a histamine H<sub>1</sub> receptor antagonist indicated for the treatment of itching associated with signs and symptoms of allergic conjunctivitis.

## **IMPORTANT RISK INFORMATION**

BEPREVE® is contraindicated in patients with a history of hypersensitivity reactions to bepotastine or any of the other ingredients. BEPREVE® is for topical ophthalmic use only. To minimize risk of contamination, do not touch the dropper tip to any surface. Keep the bottle closed when not in use. BEPREVE® should not be used to treat contact lens-related irritation. Remove contact lenses prior to instillation of BEPREVE®.

The most common adverse reaction occurring in approximately 25% of patients was a mild taste following instillation. Other adverse reactions occurring in 2%-5% of patients were eye irritation, headache, and nasopharyngitis.

**Made by the trusted eye-care  
specialists at BAUSCH + LOMB**

Please see the accompanying prescribing information  
for BEPREVE® on the following page.

Reference: 1. BEPREVE [package insert]. Irvine, CA: ISTA Pharmaceuticals, Inc; 2012.

## **BAUSCH + LOMB**

For product-related questions and concerns, call 1-800-323-0000 or visit [www.bepreve.com](http://www.bepreve.com).

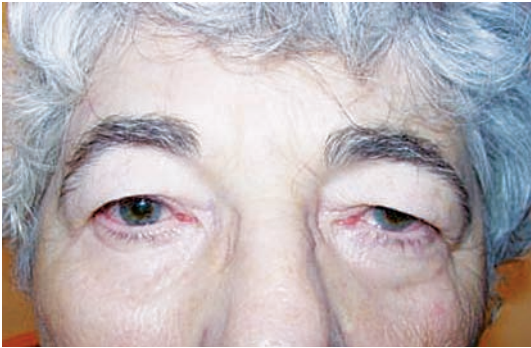
®/TM are trademarks of Bausch & Lomb Incorporated or its affiliates.

©2013 Bausch & Lomb Incorporated. US/BEP/12/0026 1/13

**BEPREVE®**  
(bepotastine besilate  
ophthalmic solution) 1.5%



Photo: Mary E. Boname, OD



**Patients on long-term statin therapy have an elevated risk of new-onset ptosis, as seen in this patient.**

disease.<sup>5</sup> The result: In 2010, 255.4 million prescriptions for lipid-lowering drugs were filled in the US.<sup>6</sup>

Lipitor (atorvastatin calcium, Pfizer), which became generic in 2011, was the 12th most commonly prescribed medication in 2010, with 51 million scripts.<sup>6</sup> Additionally, Zocor (simvastatin, Merck) was prescribed 83 million times in 2011—the second overall most frequently prescribed medication that year.<sup>7,8</sup> Other cholesterol medications include Mevacor (lovastatin, Merck), Pravachol (pravastatin sodium, Bristol-Myers Squibb), Lescol (fluvastatin sodium, Novartis) Vytorin (exetimibe/simvastatin, Merck) and Crestor (rosuvastatin calcium, AstraZeneca).

- *Systemic side effects.* Although considered somewhat rare, possible side effects of statin use include chronic fatigue and muscle pain, which may be significant

### Clinical Pearl for Psychogenic Medications

- Today, antidepressants are being prescribed to an increasingly younger demographic. This may explain unexpected dry eye complaints in children and adolescents during the contact lens fitting process.

signs of skeletal muscle breakdown (e.g., myopathy). Further, liver enzyme elevation is possible. Patients who use statin medications should avoid drinking grapefruit juice, because of an increased risk for liver and kidney damage secondary to excessive drug absorption.<sup>9</sup>

- *Ocular side effects.*

Only one published case report has surfaced regarding myopathy-induced unilateral ptosis following atorvastatin use.<sup>10</sup> The ptosis resolved upon medication discontinuation.

In 2008, Fredrick T. Fraunfelder, MD, authored a report on eye disorders related to statin use.<sup>11</sup> In this retrospective study, his research group reported 256 cases of new-onset diplopia, ptosis and ophthalmoplegia within eight months following statin administration. In all instances, the signs or symptoms resolved following drug cessation.

Conjunctival yellowing may occur in cases of jaundice secondary to statin use, but ocular side effects are rare.<sup>12</sup> Unexplained visual blur and non-specific eye irritation have been reported in patients who use using lovastatin.<sup>13</sup> Cataract development also has been documented as a rare side effect of simvastatin use.<sup>13</sup>

Additionally, atorvastatin and simvastatin have been associated with pseudo-cystoid macular edema.<sup>14</sup> So, patients on ator-

vastatin who experience unexplained reduced visual acuity should undergo OCT evaluation. Elevated IOP and an increased incidence of intraocular hemorrhages were reported infrequently in statin users.<sup>15</sup>

## Psychogenic Medications

Antidepressants and anti-psychotics are the second most commonly prescribed class of medications in the US, with more than 250 million scripts filled in 2010.<sup>6</sup> Some of the more regularly prescribed antidepressants include Celexa (citalopram, Forest Laboratories), Cymbalta (duloxetine, Eli Lilly), Effexor XR (venlafaxine,

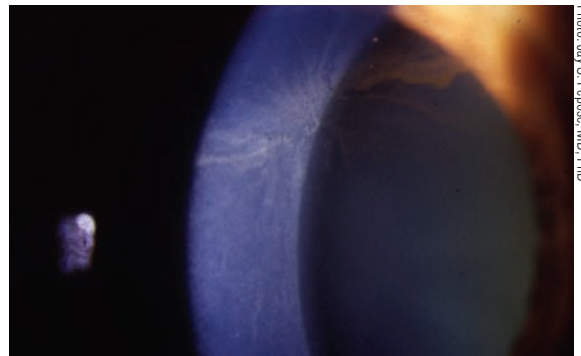


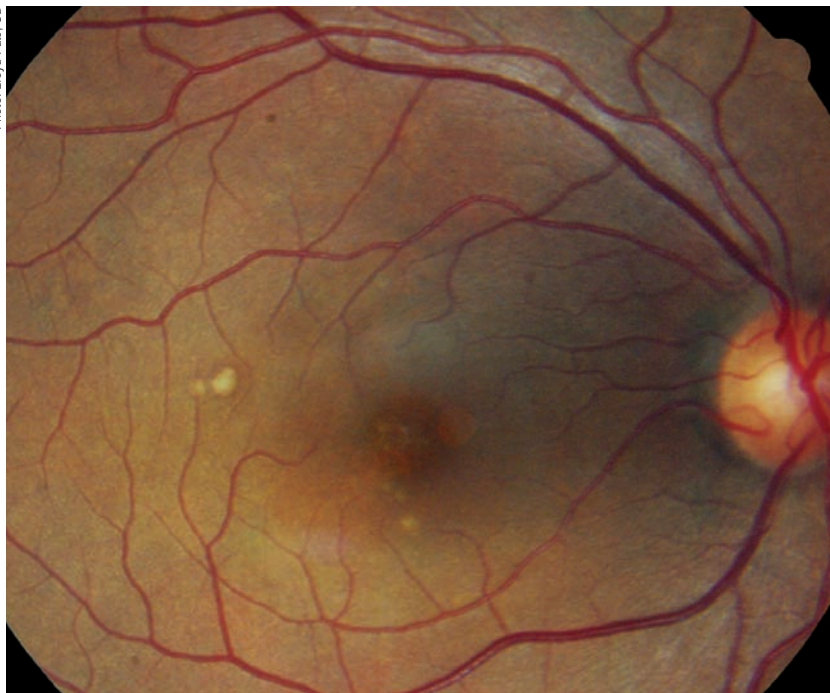
Photo: Jay S. Pepose, MD, PhD

**Vortex keratopathy often presents with a whorl-like pattern in some patients who are on long-term Nexeterone (amiodarone, Baxter Healthcare Corporation) therapy.**

Pfizer), Lexapro (escitalopram, Forest Laboratories), Nardil (phenelzine, Pfizer), Paxil (paroxetine, GlaxoSmithKline), Prozac (fluoxetine, Eli Lilly), Pristiq (desfenlafaxine, Pfizer), Sinequan (doxepin, Pfizer), Wellbutrin (bupropion, GlaxoSmithKline) and Zoloft (sertraline, Pfizer).

In addition, the antipsychotic agents Abilify (aripiprazole, Bristol-Myers Squibb), Seroquel XR (quetiapine, AstraZeneca) Zyprexa (olanzapine, Eli Lilly), Mellaril (thioridazine, Novartis) and chlorpromazine often are

Photo: Lloyd Pate, OD



**Lupus patients who use Plaquenil (Sanofi-Aventis) should be monitored for the development of hydroxychloroquine maculopathy, as seen in this individual.**

used in combination with antidepressants.

- *Systemic side effects.* Antipsychotics have been associated with an increased incidence of suicidal thoughts in children, adolescents and young adults.<sup>19</sup> Aripiprazole is associated with neuroleptic malignant syndrome, which is characterized by fever, convulsions, fast breathing, sweating and rapid heartbeat.<sup>20</sup> Tardive dyskinesia is a group of severe side effects associated with all antipsychotic medications, and includes lip smacking, cheek puffing, worm-like tongue movements, and uncontrolled jaw, arm and leg motions.<sup>21</sup> The use of

antipsychotic medications is associated with an increased risk of diabetes, liver and kidney disease as well as a higher incidence of seizures.<sup>19-21</sup>

- *Ocular side effects.* The most common ocular side effects of psychogenic drugs are blurred vision and photophobia as well as nonspecific visual complaints.<sup>22</sup> But, of particular concern is the association between antidepressant use and dry eye. Patients with unexplained dry eye symptoms, such as complaints of grittiness, foreign-body sensation, conjunctivitis and corneal epithelial staining, should be asked about antidepressant use. Such drug-induced dry eye also may inhibit successful contact lens wear in some patients.

Thioridazine and chlorpromazine are both associated with night blindness, a “browning of vision,” cataract development and

a salt-and-pepper pigmentation of the fundus. Also, selective serotonin reuptake inhibitors, including citalopram and escitalopram, have been implicated in angle-closure glaucoma—with attacks typically occurring within six months of therapeutic initiation.<sup>22</sup>

## Pain Medications

Narcotic analgesics were the third most commonly prescribed medications in the US in 2011—with Vicodin (hydrocodone/acetaminophen, Abbott) being the country’s most frequently prescribed medication overall.<sup>23</sup> In fact, of the more than 250 million pain medication prescriptions in 2011, almost half were written for Vicodin. Other commonly prescribed pain medications include OxyContin (oxycodone, Purdue Pharma), Percocet (oxycodone/acetaminophen, Endo Pharmaceuticals) and Neurontin (gabapentin, Pfizer).

- *Systemic side effects.* The most common side effects of patients who use hydrocodone include lightheadedness, nausea, vomiting and increased sweating.<sup>31</sup> Less common side effects include weakness, tiredness, headache, dizziness, dry mouth, constipation and rapid heartbeat.<sup>24,25</sup>

- *Ocular side effects.* Infrequently, hydrocodone users report nonspecific visual distortions, minor hallucinations and conjunctival yellowing.<sup>26</sup> Double vision and transient blur are commonly reported in patients using gabapentin.<sup>25</sup>

## Antihypertensive Medications

The risk of systemic hypertension increases with age, eventually affecting 66% of Americans older than 60 years of age.<sup>27</sup> Because

### Clinical Pearl for Pain Medications

- Unexplained diplopia and blurred vision mandates a detailed history of prescription painkiller use.

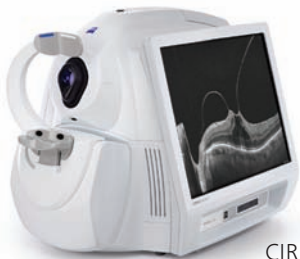

The moment a subtle change in pathology becomes a turning point in care.  
**This is the moment we work for.**

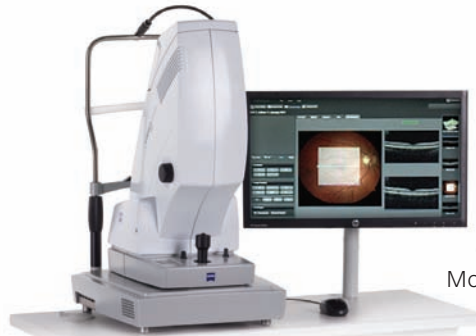Visit us and take advantage of  
**Exclusive Show-Only Special Offers!**



// CIRRUS  
MADE BY CARL ZEISS



CIRRUS™ HD-OCT  
Models 5000 and 500



CIRRUS™ photo  
Models 800 and 600

### Introducing the NEW CIRRUS™ Family

- Clinical Powerhouse OCT with FastTrac™ – CIRRUS HD-OCT 5000
- The Essential OCT – CIRRUS HD-OCT 500
- Versatile multi-modality imaging with angiography – CIRRUS photo 800
- The smart combo of camera and OCT – CIRRUS photo 600

Discover a CIRRUS that's right for you today.  
Visit us at the upcoming Spring shows.

SECO Booth 1337B | Vision Expo East Booth LP7403

[www.meditec.zeiss.com/cirrus](http://www.meditec.zeiss.com/cirrus)  
CIR.4890 © 2013 Carl Zeiss Meditec, Inc. All rights reserved.



We make it visible.

77 million Americans will turn 65 this year, it is no surprise that antihypertensive drugs are some of the most frequently prescribed medications in the US.

Systemic beta blockers, angiotensin-converting enzyme (ACE) inhibitors and the calcium-channel blockers were respectively the fourth, fifth and 13th most commonly prescribed drugs in 2010.<sup>6</sup>

Beta blockers are used in the treatment of heart disease and, in particular, high blood pressure. Commonly prescribed systemic beta blockers include Coreg (carvedilol, GlaxoSmithKline), Inderal (propranolol, AstraZeneca), Lopressor (metoprolol, Novartis), Toprol-XL (metoprolol, AstraZeneca) and Tenormin (atenolol, AstraZeneca).

### Clinical Pearl for Antihypertensive Drugs

- Patients with chronic dry eye secondary to beta blocker and diuretic use may benefit from nasolacrimal plugs.

Common ACE inhibitors include Lotensin (benazepril, Novartis), Capoten (captopril, Bristol-Myers Squibb), Vasotec (enalapril, Biovail Pharmaceuticals Inc.), Prinivil (lisinopril, Merck), Zestril (lisinopril, AstraZeneca), Accupril (quinapril, Pfizer) and Altace (ramipril, King Pharmaceuticals).

Norvasc (amlodipine besylate, Pfizer) is the most commonly prescribed calcium-channel blocker, with 57 million scripts written in 2010.<sup>6</sup> Additionally, diuretics—such as Esidrex (hydrochlorothiazide, Novartis) and Lasix (furosemide, Sanofi-Aventis)—are often prescribed for systemic hypertension.<sup>6</sup>

- *Systemic side effects.* Side

### Clinical Pearl for Thyroid Medications

- A patient who presents with unexplained diplopia, ptosis or extraocular motility issues requires a detailed history, including levothyroxine use.

effects of beta blockers include central nervous system depression, impotence, hypoglycemia, lipidemia and alopecia.<sup>28</sup>

- *Ocular side effects.* The most significant side effects of systemic beta blocker and diuretic use are dry eye, conjunctivitis, corneal epithelial damage and staining secondary to decreased tear production. Furthermore, patients on beta blockers and diuretics may experience difficulty wearing contact lenses due to significant ocular surface dryness.

Ocular side effects of ACE inhibitors include decreased vision, photophobia and conjunctivitis. Further, the anemia associated with ACE inhibitors can cause retinal hemorrhaging.<sup>29</sup>

### Thyroid Medications

The thyroid preparation Synthroid (levothyroxine sodium, Abbott) was the fourth overall most commonly prescribed medication of 2010, with 70 million scripts.<sup>6</sup> Levothyroxine is used as hormonal replacement therapy (HRT) in cases of hypothyroidism caused by an underactive thyroid gland. Use of thyroid replacement hormone increases metabolism, but may worsen the symptoms of diabetes.

- *Systemic side effects.* Within the first month of hypothyroidism treatment initiation, HRT may rarely cause heart palpitations, rapid heartbeat, weight loss, tremor, headache, diarrhea, nervousness, hair loss and sweating.<sup>30</sup>

- *Ocular side effects.* Although ocular side effects associated with levothyroxine use are extremely rare, ptosis, diplopia and ophthalmoplegia have been reported.<sup>31</sup> Thyroid hormone toxicity may mimic the symptoms of myasthenia gravis, including ptosis and diplopia. Be aware that the use of topical beta blockers may interfere with the body's response to thyroid replacement hormones. If you start a patient on a topical beta blocker, be sure to contact his or her primary care physician for a thyroid hormone level evaluation. The dose of levothyroxine may have to be adjusted once the blood serum levels of the beta blocking agent are stabilized.<sup>31</sup>

### Antibiotics

Zithromax (azithromycin, Pfizer), Amoxil (amoxicillin, GlaxoSmithKline) and several systemic fluoroquinolones are being prescribed with greater frequency for the treatment of various colds and infections.<sup>32</sup> Fluoroquinolones are broad-spectrum antibiotics that have a side effect profile that isn't seen in other antibiotics.

- *Systemic side effects.* Reports of new-onset myasthenia gravis, including symptoms of muscle weakness and difficulty swallowing, have surfaced in patients who use Zithromax.<sup>33</sup> Other common side effects of Zithromax include diarrhea, nausea, vomiting, heart palpitations and headache.<sup>33</sup>

Additionally, one report indicated that systemic fluoroquinolone use might be associated with tendonitis and tendon rupture.<sup>34</sup>

### Clinical Pearl for Antibiotics

- A new onset of unexplained diplopia mandates a detailed history, including systemic antibiotic use.

### Clinical Pearl for Diabetes Drugs

• Any large, bilateral, unexplained refractive shift warrants referral for a diabetes work-up. Consider asking the patient if he or she has experienced a recent increase in hunger, thirst or urination—three of the most common symptoms of diabetes.

• *Ocular side effects.* Patients on Zithromax may, on rare occasion, develop photophobia or conjunctival yellowing secondary to jaundice. In one study, diplopia was reported in 171 patients.<sup>35</sup> In most of these cases, the diplopia resolved following drug discontinuation. However, subsequent dosing of Zithromax caused diplopia to reoccur in five individuals.<sup>35</sup>

Tetracycline has been associated with non-pupillary block angle-closure glaucoma, most likely due to an allergic response to the sulphamolecule.<sup>36</sup> This reaction may trigger edema and swelling of the ciliary body, causing the anterior chamber to shallow.<sup>36</sup>

### Diabetes Drugs

The type 2 diabetes medication Glucophage (metformin, Merck) was the ninth most commonly prescribed drug in 2010, with 52 million scripts written.<sup>6</sup> Metformin lowers the amount of glucose produced by the liver, reduces the amount of sugar absorbed from food and helps cells utilize glucose.

• *Systemic side effects.* Gastrointestinal issues are the most common side effects of metformin.<sup>37</sup>

• *Ocular side effects.* Patients on metformin therapy may experience transient refractive shifts while serum glucose levels stabilize.<sup>38</sup>

### Respiratory Medications

The two most common types of asthma medications are inhaled steroids and bronchodilators.<sup>6</sup> The most popular and useful way to deliver asthma medication is via inhaler. Steroids are the single most important treatment for asthma. They are used to decrease the airway's sensitivity to asthma

### Clinical Pearl for Respiratory Medications

• All asthmatic and pulmonary patients on inhaled steroids must be followed regularly for the development of cataract and glaucoma.

# The Next Generation of AMD Genetic Testing

**Macula Risk<sup>®</sup> NXG**  
PREDICT AND PROTECT™



- Improved clinical utility with 2, 5 and 10 year risk estimates
- Higher predictive power at 89.5%<sup>1</sup>
- Sensitivity and specificity >80%
- Combines extensive SNP genotyping\* with phenotype and environment in a comprehensive AMD risk stratification tool

Visit us at SECO 2013 • Feb 27-Mar 3 • Booth #1713

To learn more about the unprecedented performance of Macula Risk<sup>®</sup> NXG call **1-866-964-5182** or email [info@macularisk.com](mailto:info@macularisk.com)



<sup>1</sup> Yu Y, Reynolds R, Rosner B, Daly M, Seddon J. Prospective Assessment of Genetic Effects on Progression to Different Stages of Age-Related Macular Degeneration Using Multistate Markov Models. *IOVS*. 2012;53(3):1548-1553.

\*CFH rs1048663, rs412852, rs3766405; CFI rs10033900; C3 rs2230199; C2 rs9332739; CFB rs541862; LIPC rs10468017; ABCA1 rs1883025; CETP rs3764261; COL8A1 rs13095226; APOE rs7412, rs429358; TIMP3 rs9621532; ARMS2 NM\_001099667.1:c.\*372\_815del443ins54

## Common Ocular Side Effects of Less Frequently Prescribed Systemic Drugs

- **Flomax** (tamsulosin, Boehringer Ingelheim) is used to treat benign prostatic hyperplasia (BPH). However, it is extremely well known that patients who use Flomax are at increased risk for floppy iris syndrome.<sup>44</sup> Always notify the ophthalmic surgeon if a patient is on Flomax or an alpha-adrenergic agonist.



- **Viagra** (sildenafil, Pfizer), **Cialis** (tadalafil, Ely Lilly) and **Levitra** (vardenafil, Bayer Healthcare Pharmaceuticals) are used for the management of erectile dysfunction. In 2012, Fredrick T. Fraunfelder, MD, concluded that, "to date, there is no proof of any permanent damage from any of these agents on the visual system."<sup>11,45</sup>

Further, he suggested that rare vascular effects cannot be distinguished from those that would ordinarily occur

from the increased blood pressure and pulse rate associated with normal sexual activity.

Color perception problems, blurred vision, central haze and decreased vision were reported infrequently.<sup>11,45</sup> There is a possible association between Viagra use and non-arteritic ischemic optic neuropathy (NAION) in patients with a history of unilateral optic neuropathy.<sup>11,45</sup> Take note that there is no association between Viagra and an increased risk for glaucoma.<sup>11,45</sup>

- **Plaquenil** (hydroxychloroquine, Sanofi-Aventis) is used to treat rheumatoid arthritis and lupus erythematosus. Plaquenil enters the tear film and may contribute to corneal deposits, dry eye and contact lens intolerance. Retinal changes also may occur, including bull's eye maculopathy.<sup>46</sup> Further, Plaquenil use should be avoided in patients with Stargardt's disease.<sup>46</sup>

- **Hormonal contraceptives** used to prevent unwanted pregnancy carry a range of side effects. The ocular side effects of such estrogen- and/or progesterone-based agents include optic

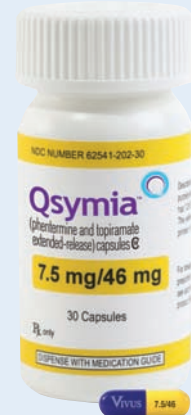neuritis, pseudotumor cerebri, dry eye and retinal thrombosis.<sup>47</sup> These medications also may increase the risk of cardiovascular and cerebrovascular events.<sup>47</sup>

- **Coumadin** (warfarin, Bristol-Myers Squibb) is an oral anti-coagulant that is used to prevent blood clot formation and reduce the risk of recurrent heart attack or stroke. It is often associated with subconjunctival and retinal hemorrhage.<sup>48</sup>

- **Topamax** (topiramate, Janssen Pharmaceuticals) is prescribed to treat patients with epilepsy and migraine headaches. Additionally, the medication is used off label to manage obesity, bipolar disorder and clinical depression. By 2012, there were almost 100 reported cases of acute angle-closure glaucoma associated with Topamax use.<sup>49</sup>

- **Qsymia** (phentermine/topiramate extended-release, Vivus), a new prescription obesity medication, received FDA approval in July 2012. Patients who use Qsymia are at an increased risk for drug-induced myopia and angle-closure glaucoma.<sup>50</sup>

- **Fosamax** (alendroic acid, Merck) inhibits bone reabsorption in the management of hypercalcemia of malignancy, bone metastasis in cancer patients, and Paget's disease of the bone. Anterior uveitis and conjunctivitis are the most common ocular side effects.<sup>51</sup> Further, one study indicated an association with scleritis and retrobulbar neuritis.<sup>51</sup>



- **Myambutol** (ethambutol, Stat-Trade, Inc.) is used in the treatment of pulmonary tuberculosis. Its ocular side effects include bilateral retrobulbar optic neuropathy, which typically manifests within two to five months of dosing initiation.<sup>52</sup>

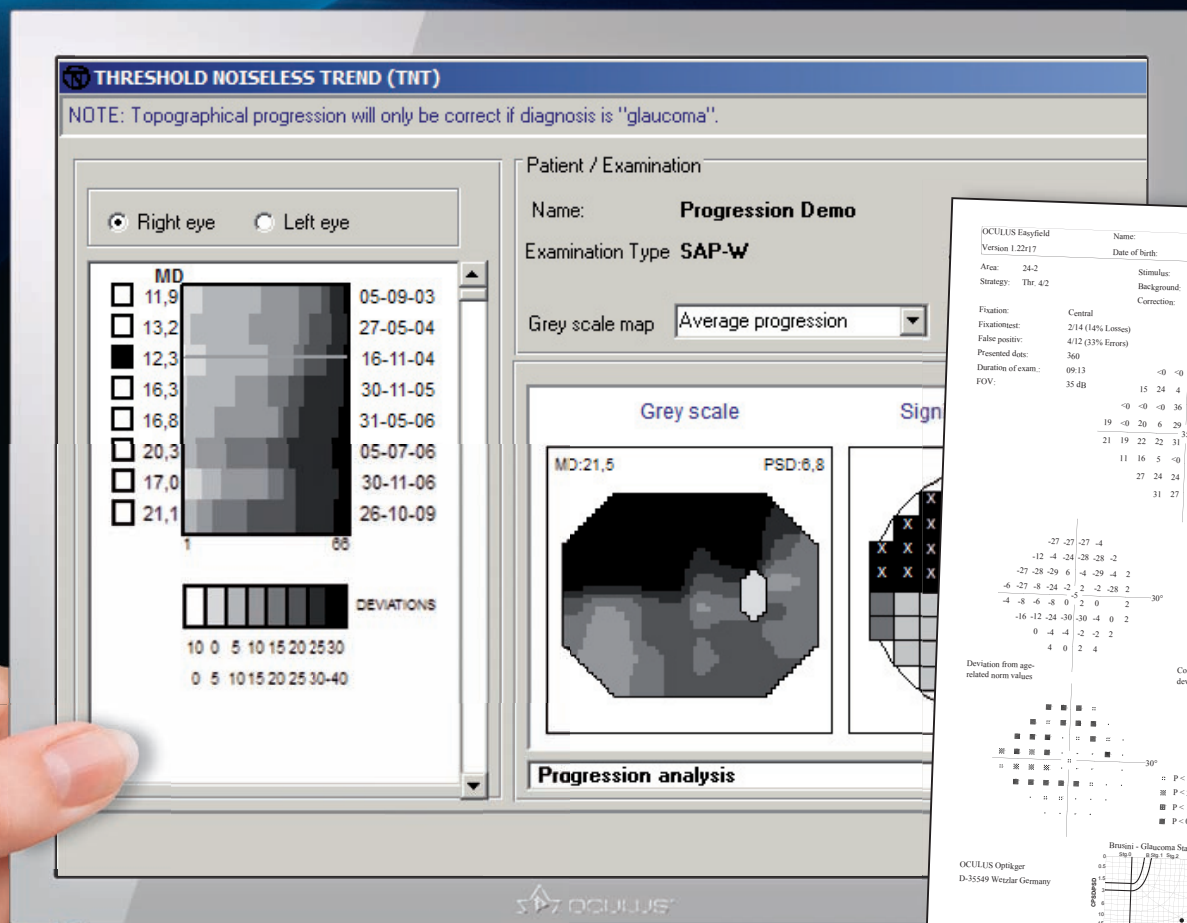
- **Nexterone** (amiodarone, Baxter Healthcare Corporation) can produce a whorl-shaped keratopathy and optic neuropathy.<sup>53</sup> The keratopathy typically resolves within one year of medication discontinuation. Nexterone also may cause loss of eyelash and eyebrow follicles as well as photophobia.<sup>53</sup>

triggers, and to reduce swelling and mucus production within the airways. Following a serious asthma attack, oral steroids may be prescribed; however, the longer the steroid is used, the greater the risk of serious and permanent side effects.<sup>39</sup>

Bronchodilators can help make breathing easier by relaxing the muscles that tighten the airway in asthma patients. Inhaled agents can be used to promptly rescue a patient in an asthmatic attack, or can be used prophylactically to prevent exercise-induced asthma.<sup>40</sup>

Inhaled steroids and bronchodilators are also useful in the treatment of chronic obstructive pulmonary disease (COPD). The three types of bronchodilating agents include beta<sub>2</sub>-agonists (both short- and long-acting), short-acting anticholinergics and long-acting theophylline.

Beta<sub>2</sub>-agonists are emergency medications that act quickly to give rapid, temporary relief of acute asthmatic episodes. Albutarol can relieve bronchospasm and may yield fewer systemic and cardiac side effects



## Threshold perimetry in less than 3 minutes!



- SPARK strategy for fast and reproducible results
- Glaucoma Staging Program (GSP) for early glaucoma detection
- Threshold Noiseless Trend (TNT) for high sensitivity progression analysis
- NEW chinrest and eye-shields for maximum patient comfort

Visit us at SECO – Booth #1443



# vision for everyone... everywhere

Brien Holden Vision Institute is one of the largest and most successful non-profit social enterprises in the history of eye care. By applying commercial strategies to vision research and product development the Institute has generated income for research and public health programs that provide quality eye care solutions and sustainable services for the most disadvantaged people in our world.

The concern for the devastating shortfall in eye care education in developing communities, especially for correction of refractive error, became action in 1998 for those at the Institute. The lack of training institutes and educational opportunities was creating a human resource gap and a critical eye care shortage for hundreds of millions of people in need of services. The concern and willingness to address the issue gave rise to the International Centre for Eyecare Education (ICEE).

Almost 15 years later, and acknowledging that 640 million people are still without access to permanent eye care, concern has galvanised into action again. To advance the process of addressing the challenge, both ICEE and Brien Holden Vision Institute will more closely align, share one common purpose and one name.

Together, we believe if we harness our efforts and broaden our scope we can achieve much more.

Together, we aim to drive, innovate, educate, collaborate, advocate and negotiate what is needed so that hundreds of millions, even billions, of people worldwide can enjoy the right to sight. Whether it's research to develop the technology to slow the progress of myopia, investment in new systems for diagnosis of disease, delivery of sustainable access to services or provision of eye care education in the most marginalised and remote communities in the world, the Institute will focus on the quality of vision people experience and equity in eye care access worldwide.

We believe in vision for everyone...everywhere.

Share the vision

[brienholdenvision.org](http://brienholdenvision.org)



BrienHoldenVisionInstitute

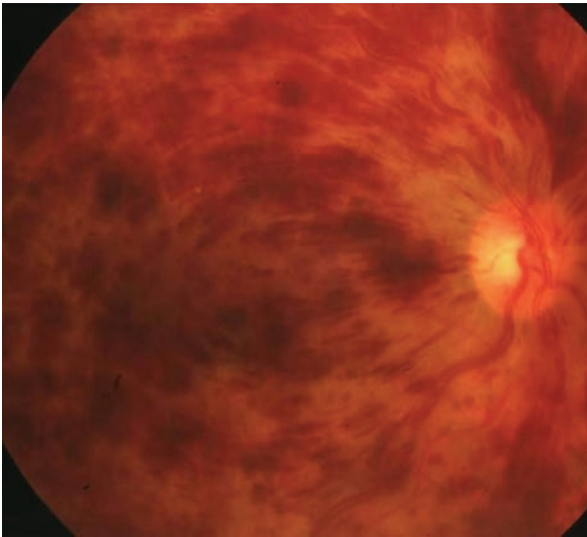**Education Research Technology Public Health**

Brien Holden Vision Institute Foundation (formerly ICEE) is a Public Health Division of Brien Holden Vision Institute



# Systemic Drugs

Photo: Mark T. Dunbar, OD



**Significant retinal hemorrhage is one potential side effect of Coumadin (warfarin, Bristol-Myers Squibb) use.**

than epinephrine. Short-acting anticholinergics include Spiriva (tiotropium, Pfizer), which is used to treat bronchospasm associated with COPD.<sup>41</sup>

- *Systemic side effects.* Inhaled steroid use can cause dry mouth, fungal infections of the mouth and depression as well as increase the risk of respiratory infections.<sup>6</sup> Spiriva is associated with upper respiratory infection and headache; albuterol is associated with those symptoms and stuffy nose as well.<sup>41,42</sup>

- *Ocular side effects.* The ocular side effects of inhaled steroid use are well known and include the development of posterior subcapsular cataract and glaucoma as well as reduced corneal wound healing time.<sup>6</sup> Epinephrine may be used in a severe asthmatic attack, and this has been linked to angle-closure glaucoma.<sup>6</sup> The use of albuterol is associated with non-specific visual changes.<sup>41</sup> Because Spiriva is related to atropine, a common ocular side effect is photophobia due to pupil mydriasis.<sup>43</sup> ■

*Dr. Muchnick is chief of optometry at the Coatesville Veterans Affairs Medical Center in Pennsylvania. He is the author of "Clinical Medicine in Optometric Practice, 2nd Edition."*

1. Lindsley CW. The top prescription drugs of 2011 in the United States: antipsychotics and antidepressants once again lead CNS therapeutics. ACS Chem Neurosci. 2012 Aug 15;3(8):630-1.

2. Medical News Today. Record 4.02 billion prescriptions in United States in 2011. Available at: [www.medicalnewstoday.com/releases/250213.php](http://www.medicalnewstoday.com/releases/250213.php). Accessed January 30, 2013.

3. Pan A, Sun Q, Okereke OI, et al. Depression and risk of stroke morbidity and mortality: a meta-analysis and systematic review. JAMA. 2011 Sep 21;306(11):1241-9.



## Introducing a Breakthrough in Subjective Refraction

Voice Guided

# PSF Refractor™

The voice guided PSF Refractor™ from Vmax Vision enables your practice to:

- Dramatically reduce refraction training to a few days with new voice guided instruction. Turn a novice technician into a refractionist in a few weeks\*
- Achieve 5X greater accuracy than the phoropter
- Satisfy an unmet patient need with a true solution for nighttime vision correction

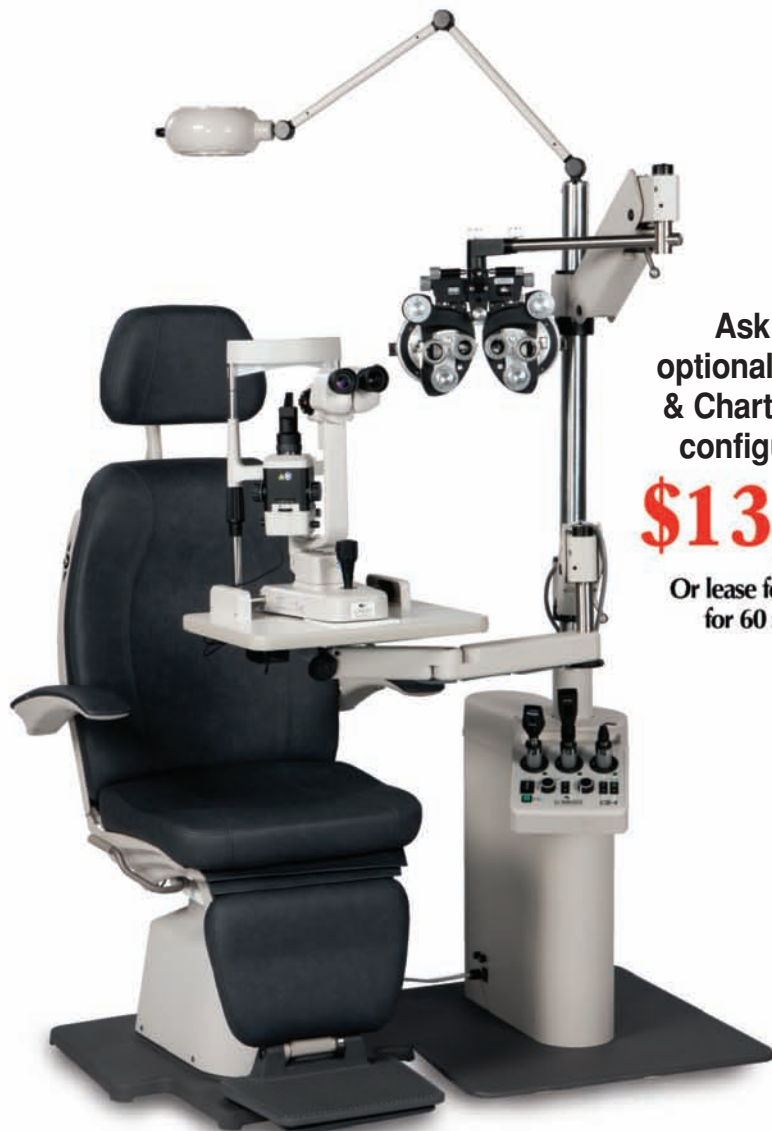Patient vision is maximized when PSF Refractor™ results are combined with Enception™ Lenses. To schedule a demonstration of these products, call 888.413.7038 or visit [www.vmaxvision.com](http://www.vmaxvision.com).

vmax  
VISION, INC.™

See the PSF Refractor™ and Enception™ Lens at SECO Booth 520, MOA and VEE Booth LP 7074.

# Invest In Your Practice And Get A Guaranteed Positive Return.

**Lombart's CS-4 Package Offers Quality, Style & Value.**



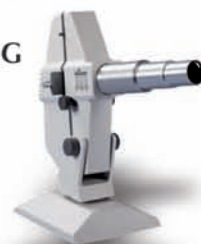Ask about  
optional Slit Lamp  
& Chart Projector  
configurations.

**\$13,595**

Or lease for \$269/mo.  
for 60 months \*

Package includes:

- The Lombart CS-4 Chair & Stand
- Topcon VT-10 Refractor
- Topcon SL-2G Slit Lamp
- Reichert LongLife Chart Projector with mount, slide & screen
- Upgrade to the Lombart CVSi21 for only \$2000 more or to the CVS-PC for only \$1500 more — Additional upgrades & configurations available.



(1-800-566-2278)

**Call 1-800-Lombart**

Or Your Local Lombart Representative.

Corporate Office - 5358 Robin Hood Road, Norfolk, VA 23513-2430  
757-853-8888 | FAX 757-855-1232 | 800-566-2278 | 800-446-8092  
[www.lombartinstrument.com](http://www.lombartinstrument.com)

ATLANTA•BALTIMORE/WASHINGTON D.C.•BOSTON•BOYNTON BEACH/MIAMI•BRADENTON•CHARLOTTE  
CHICAGO•CINCINNATI•DALLAS•DENVER•DETROIT•GREENSBORO•HOUSTON•KANSAS CITY•KNOXVILLE•LOS ANGELES  
MILWAUKEE•MINNEAPOLIS•NEW JERSEY/NEW YORK•NORFOLK•PORTLAND•SACRAMENTO•SAN DIEGO•SAN FRANCISCO

\*Lease rate subject to credit approval, 1st payment is paid for by leasing company at signing with 59 remaining rental payments of \$269 and a \$1.00 purchase option. Taxes, freight and installation additional. Hand Instruments optional. Quantities limited. Subject to change without notice.



# Systemic Drugs

4. Farmer JA. Aggressive lipid therapy in the statin era. *Prog Cardiovasc Dis.* 1998 Sep-Oct;41(2):71-94.
5. Tonelli M, Lloyd A, Clement F, et al. Efficacy of statins for primary prevention in people at low cardiovascular risk: a meta-analysis. *CMAJ.* 2011 Nov 8;183(16):E1189-202.
6. IMS Institute for Healthcare Informatics. The Use of Medicines in the United States: Review of 2010. Available at: [www.imshealth.com/deployedfiles/imshealth/Global/Content/IMS%20Institute/Static%20File/HIIL\\_UseOfMed\\_report.pdf](http://www.imshealth.com/deployedfiles/imshealth/Global/Content/IMS%20Institute/Static%20File/HIIL_UseOfMed_report.pdf). Accessed January 30, 2013.
7. IMS Institute for Healthcare Informatics. The Use of Medicines in the United States: Review of 2011. Available at: [www.imshealth.com/ims/Global/Content/Insights/IMS%20Institute%20for%20Healthcare%20Informatics/HIIL\\_Medicines\\_in\\_US\\_Report\\_2011.pdf](http://www.imshealth.com/ims/Global/Content/Insights/IMS%20Institute%20for%20Healthcare%20Informatics/HIIL_Medicines_in_US_Report_2011.pdf). Accessed January 30, 2013.
8. U.S. National Library of Medicine. Medline Plus. Simvastatin. Available at: [www.nlm.nih.gov/medlineplus/druginfo/meds/a692030.html](http://www.nlm.nih.gov/medlineplus/druginfo/meds/a692030.html). Accessed January 30, 2013.
9. Reamy BV, Stephens MB. The grapefruit-drug interaction debate: role of statins. *Am Fam Physician.* 2007 Jul 15;76(2):190,192.
10. Ertas FS, Ertas NM, Gulec S, et al. Unrecognized side effect of statin treatment: unilateral blepharoptosis. *Ophthalm Plast Reconstr Surg.* 2006 May-Jun;22(3):222-4.
11. Fraunfelder FW, Fraunfelder FT. Drug related adverse effects of clinical importance to the ophthalmologist. Course presented at the American Academy of Ophthalmology Annual Meeting, Chicago. November 10-13, 2012.
12. Russo MW, Scobey M, Bonkovsky HL. Drug-induced liver injury associated with statins. *Semin Liver Dis.* 2009 Nov;29(4):412-22.
13. Mills EJ, Wu P, Chong G, et al. Efficacy and safety of statin treatment for cardiovascular disease: a network meta-analysis of 170,255 patients from 76 randomized trials. *QJM.* 2011 Feb;104(2):109-24.
14. Kiortsis DN, Filippatos TD, Mikhailidis DP, et al. Statin-associated adverse effects beyond muscle and liver toxicity. *Atherosclerosis.* 2007 Nov;195(1):7-16.
15. Fraunfelder FW. Ocular hemorrhage possibly the result of HMG-CoA reductase inhibitors. *J Ocul Pharmacol Ther.* 2004 Apr;20(2):179-82.
16. Fraunfelder FW, Richards AB. Diplopia, blepharoptosis, and ophthalmoplegia and 3-hydroxy-3-methyl-glutaryl-CoA reductase inhibitor use. *Ophthalmology.* 2008 Dec;115(12):2282-5.
17. Pasternak RC, Smith SC Jr, Bairrey-Merz CN, et al. ACC/AHA/NHLBI clinical advisory on the use and safety of statins. *J Am Coll Cardiol.* 2002 Aug 7;40(3):567-72.
18. Cenedella RJ. Beware of combining erythromycin with a statin. *J Am Osteopath Assoc.* 2003 Mar;103(3):117.
19. Biederman J, Faraone SV, Wozniak J, et al. Clinical correlates of bipolar disorder in a large, referred sample of children and adolescents. *J Psychiatr Res.* 2005 Nov;39(6):611-22.
20. Molina D, Tingle LE, Lu X. Aripiprazole as the causative agent of neuroleptic malignant syndrome: a case report. *Prim Care Companion J Clin Psychiatry.* 2007;9(2):148-50.
21. Correll CU, Schenk EM. Tardive dyskinesia and new antipsychotics. *Curr Opin Psychiatry.* 2008 Mar;21(2):151-6.
22. Costagliola C, Parmeggiani F, Sebastiani A. SSRIs and intraocular pressure modifications, evidence, therapeutic implications and possible mechanisms. *CNS Drugs.* 2004 Aug;18(8):475-84.
23. The United States Centers for Disease Control and Prevention: Morbidity and Mortality Weekly Report. CDC Grand Rounds: CDC Grand Rounds—Prescription Drug Overdoses. January 13, 2012. Available at: [http://bsd.dli.mt.gov/license/bsd\\_boards/pha\\_board/pdf/cdc\\_rx\\_overdose\\_epidemic.pdf](http://bsd.dli.mt.gov/license/bsd_boards/pha_board/pdf/cdc_rx_overdose_epidemic.pdf). Accessed January 30, 2013.
24. Zacny JP, Gutierrez S, Bolbolan SA. Profiling the subjective, psychomotor, and physiological effects of a hydrocodone/acetaminophen product in recreational drug users. *Drug Alcohol Depend.* 2005 Jun 1;78(3):243-52.
25. Bookwala T, Gitlin M. Gabapentin-induced neurologic toxicities. *Pharmacotherapy.* 2005 Dec;25(12):1817-9.
26. Richa S, Yazbek J. Ocular adverse effects of common psychotropic agents: a review. *CNS drugs.* 2010 Jun;24(6):501-26.
27. Dohi Y, Thiel MA, Bühler FR, Lüscher TF. Activation of endothelial L-arginine pathway in resistance arteries. Effect of age and hypertension. *Hypertension.* 1990 Aug;16(2):170-9.
28. Ko DT, Hebert PR, Coffey CS, et al. Beta-blocker therapy and symptoms of depression, fatigue, and sexual dysfunction. *JAMA.* 2002 Jul 17;288(3):351-7.
29. Petrounis AD, Akritopoulos P. Influence of topical and systemic beta-blockers on tear production. *Int Ophthalmol.* 1989 Jan;13(1-2):75-80.
30. Kronenberg HM. *Williams Textbook of Endocrinology*, 11th ed. Philadelphia: Saunders Elsevier; 2008:227-29.



## Introducing the Exceptional, Ultra-Personalized Lens

# ENCEPTION™ LENS

The premium Enception™ Lens from Vmax Vision enables your practice to:

- Achieve exceptional optics with precision Diamond Point™ free-form cutting technology and 0.01D cutting accuracy
- Offer ultra-personalized lens for specific tasks, angle of gaze and frame factors
- Optimize patient vision day and night with lower distortion and wider field of view

Patient vision is maximized when Enception™ Lenses are combined with PSF Refractor™ results. To schedule a demonstration of these products, call 888.413.7038 or visit [www.vmaxvision.com](http://www.vmaxvision.com).



See the Enception™ Lens and PSF Refractor™ at SECO Booth 520, MOA and VEE Booth LP 7074.



THE COMPLETE  
**EYECARE**  
EVENT

## EXPAND YOUR FIELD OF VISION

### A COMPREHENSIVE CONFERENCE

More than 325 hours of Continuing Education for every role and experience level

### AN AFFORDABLE SOURCE FOR STAFF TRAINING

Boot Camps and Flexible Package Pricing jumpstart competency and add value

### EDUCATES MORE OPTOMETRISTS THAN ANY OTHER EYECARE CONFERENCE

Delivers the knowledge and information to ensure you practice to the fullest extent of your license

### AN AFFORDABLE AND FUN EXPERIENCE

Discounts for hotels, travel, entertainment and free parties

**FOR THE HEALTH OF YOUR PATIENTS. FOR THE HEALTH OF YOUR PRACTICE.**



**EDUCATION: MARCH 14-17, 2013**

**EXHIBITION: MARCH 15-17, 2013**

New York, NY | Javits Center

**[www.visionexpoeast.com](http://www.visionexpoeast.com)**

JOIN US ON SOCIAL MEDIA



#visionexpo

## Systemic Drugs

31. Crilly M. Thyroid function tests and hypothyroidism: reducing concentrations further would be harmful. *BMJ*. 2003 May 17;326(7398):1086.
32. The American Medical Association. Antibiotic resistance a major public health problem. June 9, 2010. Available at: [www.ama-assn.org/ama/pub/news/news/antibiotic-resistance-public-health.page](http://www.ama-assn.org/ama/pub/news/news/antibiotic-resistance-public-health.page). Accessed January 30, 2013.
33. Moore B, Safani M, Keesey J. Possible exacerbation of myasthenia gravis by ciprofloxacin. *Lancet*. 1988 Apr 16;1(8590):882.
34. Muzi F. Fluoroquinolones-induce tendinitis and tendon rupture in kidney transplant recipients: 2 cases and a review of the literature. *Transplant Proc*. 2007 Jun;39(5):1673-5.
35. Fraunfelder FW, Fraunfelder FT. Diplopia and fluoroquinolones. *Ophthalmology*. 2009 Sep;116(9):1814-7.
36. Tripathi RC, Tripathi BJ, Haggerty C. Drug-induced glaucomas. *Drug Saf*. 2003 Nov;26(11):749-67.
37. Andr s E. Metformin-associated vitamin B12 deficiency. *Arch Intern Med*. 2002 Oct 28;162(19):2251-2.
38. Klein BE, Lee KE, Klein R. Refraction in adults with diabetes. *Arch Ophthalmol*. 2011 Jan;129(1):56-62.
39. Ito K, Lim S, Caramori G, et al. A molecular mechanism of action of theophylline: Induction of histone deacetylase activity to decrease inflammatory gene expression. *Proc Natl Acad Sci U S A*. 2002 Jun 25;99(13):8921-6.
40. McFadden ER Jr, Gilbert IA. Exercise-induced asthma. *N Engl J Med*. 1994 May 12;330(19):1362-7.
41. Freeman D, Lee A, Price D. Efficacy and safety of tiotropium in COPD patients in primary care—the SPIRIVA Usual Care (SPRUCE) study. *Respir Res*. 2007 Jul 2;8:45.
42. Kerstjens HA, Engel M, Dahl R, et al. Tiotropium in asthma poorly controlled with standard combination therapy. *N Engl J Med*. 2012 Sep 27;367(13):1198-207.
43. Razeghinejad MR, Pro MJ, Katz LJ. Non-steroidal drug-induced glaucoma. *Eye*. 2011 Aug;25(8):971-80.
44. Tiwari A. Floppy iris syndrome associated with tamsulosin: What are the implications for urologists? *Clin Pract Urol*. 2005 Dec;2(12):594-5.
45. Fraunfelder FW, Pomerantz H, Egan RA. Non-arteritic ischemic optic neuropathy and sildenafil. *Arch Ophthalmol*. 2006 May;124(5):733-4.
46. Easterbrook M. Detection and prevention of maculopathy associated with antimalarial agents. *Int Ophthalmol Clin*. 1999 Spring;39(2):49-57.
47. Candela V, Castagna I. Modification of conjunctival mucus secretion by pregnancy and oral contraceptives. *Boll Oculist*. 1989;68(suppl 1):19-23.
48. Lewis H. Massive intraocular hemorrhage associated with anticoagulation and age-related macular degeneration. *Graefes Arch Clin Exp Ophthalmol*. 1988;226(1):59-64.
49. Fraunfelder FW, Fraunfelder FT, Keates EU. Topiramate-associated acute, bilateral, secondary angle-closure glaucoma. *Ophthalmology*. 2004 Jan;111(1):109-11.
50. Murphy J. New drug for obesity carries ocular risks. *Rev Optom*. 2012 Aug;149(8):4.
51. Fraunfelder FW, Fraunfelder FT. Bisphosphonates and ocular side effects. *N Engl J Med*. 2003 Mar 20;348(12):1187-8.
52. Fraunfelder FW, Sadun AA. Update on ethambutol optic neuropathy. *Expert Opin Drug Saf*. 2006 Sep 5(5):615-8.
53. Jafari-Fesharaki M, Scheinman MM. Adverse effects of amiodarone. *Pacing Clin Electrophysiol*. 1998 Jan;21(1pt1):108-20.

Odyssey

 **PARASOL**<sup>®</sup>

★★★★★ 92% Retention Rate<sup>†</sup>

**ORDER NOW**

Treat your patients with the Parasol punctal occluder, the permanent application for chronic dry eye.

**THE #1 APP**  
FOR TREATMENT OF CHRONIC DRY EYE

SIMPLE SIZING | EASY INSERTION | GUARANTEED RETENTION\*



2975 Brother Blvd | Bartlett TN 38133 USA | 888.905.7770 | [odysseymed.com](http://odysseymed.com)

© 2012 Odyssey Medical, Inc. All rights reserved. †McCabe, C. (2009). Punctal occlusion reduces dry eye symptoms and improves vision. *Review of Ophthalmology*, 16(1), 55-58. \*Certain conditions apply; call for details.



# Varicella Zoster Virus: From Chickenpox to Shingles

VZV affects patients both young and old. Here's how to manage the associated ocular complications. **By William Marcolini, OD**

**A**s primary care optometrists, we often see pediatric patients with chickenpox or older individuals with herpes zoster—commonly known as shingles. Despite the relatively recent advent of multiple vaccines for both chickenpox and shingles, the overall incidence of herpes zoster is on the rise.<sup>1</sup>

In an effort to provide the best possible care, this article will review the ocular complications associated with varicella zoster virus (VZV) in both children and adults, as well as discuss potential treatment options for shingles and postherpetic neuralgia.

## Chickenpox

Upon primary infection, VZV causes the development of chickenpox in children and young teenagers. Most children become infected

with VZV between the ages of five and 10 years.<sup>2</sup> Typically, this initial infection—coupled with intermittent environmental exposure—provides the patient with a lifetime of immunity against the recurrence of chickenpox.<sup>2</sup>

VZV is one of eight strains of herpes viruses known to infect humans. Most often, the primary infection persists for two weeks and causes vesicular, macular and papular eruptions on the face and trunk that crust over within a few weeks. Fever and general malaise are the most common symptoms, with the potential for long-term cutaneous scarring.

Although the course of chickenpox is usually benign, there are exceptions. In fact, associated cases of pneumonia, encephalitis and even death have been reported in the literature.<sup>2</sup>

VZV is highly contagious. In the past, parents have hosted “pox parties” in an effort to expose their kids to other infected children. This would ensure simultaneous infection throughout the household and confer immunity going forward.

## Shingles

Shingles manifest following the reactivation of latent VZV during adulthood. The Centers for Disease Control and Prevention (CDC) estimates that 500,000 to one million cases of shingles are reported each year. Shingles typically present with a characteristic rash that respects the midline. Typically, this rash is found in the lower thoracic region, but also may be located on the scalp, forehead and periorbital structures.

Both chickenpox and shingles

**Release Date:** February 2013

**Expiration Date:** February 1, 2016

**Goal Statement:** Despite the relatively recent advent of multiple vaccines for both chickenpox and shingles, the overall incidence of herpes zoster is on the rise. This article will review the ocular complications associated with varicella zoster virus (VZV) in both children and adults, as well as discuss potential treatment options for shingles and postherpetic neuralgia.

**Faculty/Editorial Board:** William Marcolini, OD

**Credit Statement:** COPE approval for 2 hours of CE credit is pending for this course. Check with your local state licensing board to see if this counts toward your CE requirement for relicensure.

**Joint-Sponsorship Statement:** This continuing education course is joint-sponsored by the Pennsylvania College of Optometry.

**Disclosure Statement:** Dr. Marcolini has no relationships to disclose.

are caused by VZV. A child is first infected when the virus enters the respiratory mucosa or the conjunctiva. After the initial varicella infection, the virus becomes dormant. Subsequent reactivation is predicated on certain triggers. Such triggers are heavily influenced by the condition of the host, and are believed to include the presence of an immunocompromising condition, use of immunosuppressive medications or long-standing emotional stress.<sup>2,3</sup>

During the latency period, the virus remains in the dorsal root ganglia. The dorsal root ganglia are located throughout the body and along the spinal cord, and are part of the afferent sensory system. This explains how the virus can travel via axonal transport to the skin or mucous membranes. As optometrists, we are most concerned with eruptions along the trigeminal dermatome. However, just 13% to 20% of all cases involve one of the 12 cranial nerves, including the trigeminal (CN V).<sup>3</sup>

The primary clinical trial for the herpes zoster vaccine Zostavax (live zoster virus, Merck) included more than 38,000 adults aged 60 to 80 years who had previous history of shingles.<sup>4</sup> Subjects who were treated with Zostavax were 51% less likely to develop shingles and 66% less likely to experience postherpetic neuralgia.<sup>4</sup> Further, patients who still developed shingles following treatment with Zostavax exhibited less severe signs and symptoms.<sup>4</sup> The researchers also determined that the efficacy of Zostavax declined proportionately with advanced age.

Another study of 22,000 adults aged 50 through 59 years showed that the risk of shingles was reduced by 69.8% following the administration of Zostavax.<sup>2</sup>

### How to Differentiate Herpes Simplex from Varicella Zoster<sup>6</sup>

Similarly to herpes simplex virus keratitis, an active varicella zoster infection of the epithelium subsequently may invade neighboring epithelial cells. Fortunately, however, there are a few distinguishing characteristics:

Feature	Herpes Simplex	Varicella Zoster
Epithelium	Linear defect with bare stroma that is surrounded by edematous epithelial cells	Elevated, painted-on appearance
Staining	Ulcer base stains with fluorescein; diseased borders of epithelial cells stain with rose bengal	Minimal fluorescein staining
Terminal bulbs	Frequent	None

Although the FDA approved Zostavax for individuals age 50 years and older in March 2011, CDC officials recommended that the vaccine only be used in patients 60 years and older.<sup>2</sup> This recommendation likely is explained, in part, by lingering concerns about vaccine supply and a lower overall risk of herpes zoster in the 50 to 59 years of age cohort.

### Ocular Manifestations of Chickenpox

Eighty-five percent of chickenpox infections occur before age 15.<sup>2</sup> Optometrists with significant pediatric populations will see a larger volume of ocular complications. Vesicular eruptions can occur externally, along the periorbital skin around the eyelids. The eyelids often become infected, and scarring and/or pockmarks may result. Further, the conjunctiva can be infected by vesicles as well as a non-specific papillary conjunctivitis.

Most significantly, the cornea can be scarred by vesicular eruption.<sup>5</sup> Similar to the dendritic appearance caused by herpes simplex virus (HSV) keratitis, active

varicella can invade the cornea and cause punctate or dendritic keratitis (see “How to Differentiate Herpes Simplex from Varicella Zoster,” above).<sup>5</sup>

An immune-mediated disciform keratitis, with or without uveitis, may be documented.<sup>5</sup> Cases of cranial nerve palsies, retinopathy and optic neuropathy also have been reported. Carefully examine each ocular structure—from the cornea to the retina—in all pediatric patients who present with chickenpox.

### Ocular Manifestations of Shingles

In most instances, herpes zoster patients who present to my office have already been diagnosed with active shingles. Occasionally, the patient exhibits the characteristic unilateral, dermatomal rash on the forehead, periorbital region and nose. If the rash is present on the nose, the virus has spread sufficiently enough along the V1 nasociliary branch of the trigeminal nerve. This presentation, known as Hutchinson’s sign, indicates a high probability of ophthalmic involvement.<sup>5</sup> It must be noted that

the absence of Hutchinson's sign should in no way be reassuring, as significant ocular involvement is often seen without frank evidence of this indicator.

Because the outbreak occurs along the trigeminal dermatome, the rash respects the midline and manifests on only one side of the patient's face or scalp.<sup>5</sup>

Whether you make the initial diagnosis or participate in a consult, your clinical responsibilities are the same. The eye must be inspected from cornea to retina, with a special emphasis on intraocular pressure. The goal is to arrest viral replication, control inflammation, prevent scarring and educate the patient about the possibility of postherpetic neuralgia.

- *Symptoms.* Shingles presents with prodromal symptoms a few days before the onset of a macular rash, which rapidly progresses to papular and vesicular eruptions within 24 hours.<sup>5</sup> The prodromal symptoms include pain, redness, hypesthesia, fever, malaise and headache.<sup>5</sup> While these symptoms can be associated with a host of diseases, it is the characteristic rash and respect of the midline that makes the diagnosis straightforward. Occasionally, an immunologic test from vesicular fluid or a serologic workup that reveals a high IgM titer against VZV is necessary to confirm a confusing case.

Inform the patient that the rash usually continues to develop and proliferate for three to four days. The acute phase often lasts two weeks or more, until the rash crusts over.<sup>5</sup> Acute pain tends to lessen during the course of the disease; however, pain may persist in the affected dermatome for months to years—a condition known as postherpetic neuralgia.<sup>6</sup>

- *Pertinent anatomy.* Typically, shingles reactivation occurs in

the thoracic region. Less commonly, it may affect the trigeminal nerve. Herpes zoster ophthalmicus (HZO) is defined as a reactivation of VZV that originates from the trigeminal ganglion and includes ocular involvement. The trigeminal nerve provides both sensory and motor functions. It is primarily responsible for facial sensation.

The trigeminal nerve has three main branches: the V1 ophthalmic branch (sensory), the V2 maxillary branch (sensory) and the V3 mandibular branch (motor for chewing). The V1 ophthalmic relays sensory information from the scalp, forehead, eyelids, periorbital skin, nose and, most importantly, the cornea and conjunctiva.

The V1 branch is further divided into the frontal, nasociliary and lacrimal nerves. The frontal nerve is most commonly affected by VZV reactivation, which is why shingles often appears on the forehead. The nasociliary branch innervates the skin of both eyelids as well as the tip of the nose, conjunctiva, sclera, cornea, iris and choroid.<sup>5</sup>

Considering the extensive nerve involvement, it becomes increasingly evident that the virus easily can spread to any nearby ophthalmic component. That's why I examine herpes zoster patients in a similar fashion as victims of blunt force trauma—from the adnexa to optic nerve.

When the forehead and scalp are affected (indicative of frontal nerve involvement), the upper eyelid may exhibit vesicles and edema. These symptoms often resolve without sequelae; however, if scarring results, lid retraction and exposure may develop.<sup>6</sup> Associated conjunctivitis can be follicular or necrotizing, and may occasionally yield conjunctival vesicles and potential scarring.<sup>6</sup> Also, the sclera

can be involved with a scleritis or an episcleritis.

- *Herpes zoster ophthalmicus.* Approximately two-thirds of HZO cases have corneal involvement.<sup>7</sup> All layers of the cornea potentially can be infected—from the epithelium to the endothelium. Further, corneal involvement can occur during the acute event or years after the infection has subsided.<sup>7</sup>

The epithelial dendrite present in HZO often is termed a "pseudodendrite." The pseudodendrite may begin as clusters of swollen epithelial cells that are infected with live zoster virus. At this stage, the inflamed lesion commonly is referred to as punctate epithelial keratopathy. Over time, the lesion resolves, develops anterior stromal infiltrates, or coalesces to form into a dendritiform pattern.<sup>6</sup> In most instances, though, these lesions tend to resolve spontaneously over weeks without topical treatment.

A neurotrophic keratitis can be seen in patients who have corneal nerve damage. Because of decreased innervation and sensation, the cornea can develop a non-healing neurotrophic ulcer that is neither infectious nor inflammatory, and therefore must be managed differently. In general, patients with HZO are more likely to experience severely reduced corneal sensitivity than those with HSV keratitis.<sup>6</sup> During evaluation, test corneal sensitivity with a simple cotton wisp to detect areas of denervation.

Stromal disease represents an immune reaction to retained viral antigen in the corneal epithelium, and is not a sign of active HZO. Nonetheless, resultant inflammation can yield devastating visual consequences. This immune reaction can occur within three to four months following the reactivation

of varicella, or it may present several years later.<sup>6,7</sup> So, you may think of HZO as a reactivation of VZV, and stromal disease as a subsequent immune response to the reactivation.

HZO can cause anterior uveitis, iris atrophy, choroiditis, retinitis, optic neuritis and even acute retinal necrosis.<sup>6,7</sup> A dilated fundus examination is of paramount importance in any suspected case of HZO. Be certain to investigate for inflammatory lesions or necrosis in the retina as well as optic nerve edema.

Additionally, it is essential to inspect the anterior chamber for the presence of cells and flare, because significant iridocyclitis can develop. Iridocyclitis usually presents within the first week of herpes zoster infection, but can be seen months after.<sup>6</sup>

HZO is notorious for causing chronic complications associated with recurrent inflammation, including increased intraocular pressure and/or trabeculitis.<sup>8</sup> Such persistent inflammation is believed to be caused by the presence of inactivated viral antigens in the eye or ongoing low-grade viral replication.<sup>8-10</sup>

## Treatment for Shingles

Primary treatment for active herpes zoster should be aimed at curtailing viral replication, minimizing inflammation, preventing secondary infection and limiting the potential for future postherpetic neuralgia. Ultimately, the location and the extent of ocular involvement will drive your treatment regimen.

- *Oral antiviral therapy* is a mainstay treatment for HZO, and should be initiated within the first 72 hours following diagnosis of herpes zoster.<sup>6</sup> This accelerates resolution of the skin rash and

## Varivax: The Chickenpox Vaccine

The first vaccine for VZV, Varivax (live varicella virus, Merck) received FDA approval in March 1995. There were an estimated four million new cases of VZV annually before the development of Varivax, and virtually everyone acquired varicella by adulthood.<sup>2</sup> Of those four million cases, 11,000 individuals required hospitalization per year—with death occurring in one in 60,000 cases.<sup>2</sup>

Those at the highest risk for serious complications secondary to VZV infection include persons older than 15 years, infants younger than one year and immunocompromised individuals.<sup>2</sup>

Following massive research efforts by the Advisory Committee on Immunization Practices, the Centers for Disease Control and Prevention (CDC) and the American Academy of Pediatrics, investigators determined that 90% of children in the United States aged 19 to 35 months underwent vaccination for VZV by 2007.<sup>2</sup> Since 1995, the number of hospitalizations and deaths from VZV has declined by more than 90%. Further, the CDC also estimates that overall incidence of VZV infection decreased between 83% and 93% from 1995 to 2004.<sup>2</sup>

After receiving just one dose of Varivax, 97% of children aged 12 months to 12 years exhibit detectable VZV antibodies.<sup>2</sup> Immunity is long lasting, and breakthrough infections following inoculation are generally mild with fewer lesions. An estimated 10% of people over age 15 remain susceptible to VZV following Varivax administration.<sup>19</sup>

lesions, shortens the period of lesion formation and viral shedding, and reduces the incidence of episcleritis, keratitis and iritis.<sup>6</sup> Oral antiviral agents also appear to limit, but not prevent, the symptoms of postherpetic neuralgia. For patients who have scalp involvement or ocular complications that are limited to the eyelids, prescribe one of the following systemic treatment regimens:

- 800mg acyclovir five times a day for seven to 10 days.
- 1,000mg valacyclovir TID for seven days.
- 500mg famciclovir QD for seven days.

- *Systemic corticosteroids*, such as oral prednisone, are a useful adjunct to antiviral agents in patients who have moderate to severe pain. Patients on combination systemic steroids/antiviral therapy have been shown to experience shorter healing times and decreased pain during the acute infection period.<sup>6</sup> But remember, immunocompromised patients are at risk for disseminated disease and should not be placed on systemic steroids.

Additionally, posterior uveitis and/or acute retinal necrosis must be managed aggressively with a combination of intravenous/oral antivirals and systemic steroids. These patients require immediate referral to a retina specialist for proper management.

- *Topical agents* in conjunction with oral antiviral therapy may be necessary if a herpes zoster patient exhibits conjunctival or corneal involvement, or develops a keratouveitis. However, because patient circumstances vary and viral response is not always predictable, there is no consensus on the clinical utility of topical treatment.

In the presence of conjunctival lesions, conjunctivitis or a corneal pseudodendrite, antibiotic ointments, such as erythromycin or bacitracin, may be used TID. In the past, antiviral ointments, such as Vira-A (vidarabine, Monarch Pharmaceuticals) QID, sometimes were used. (Vira-A ointment is no longer available in the US and has no generic equivalent.) Viroptic (trifluridine, Monarch Pharmaceuticals)

## Currently Available Vaccines

Today, there are three commercially available vaccines for VZV: Varivax, ProQuad (live measles, mumps, rubella and varicella viruses, Merck) and Zostavax (live zoster virus, Merck).

- **Varivax** is a live, attenuated viral vaccine approved for children aged 12 months and older. Currently, children receive the first Varivax vaccine between 12 and 15 months. Then, a booster is administered between the ages of four and six years.

- **ProQuad** is a live, attenuated virus vaccine for measles, mumps, rubella and varicella (MMRV). It first received FDA approval in 2005, and is intended for children aged 12 months to 12 years.<sup>2</sup> It is interesting to note that ProQuad contains a higher titer of VZV than Varivax.<sup>2</sup> Thus, unlike Varivax, a subsequent booster shot is not required.

- **Zostavax** received FDA approval in May 2006 for the prevention of herpes zoster. Initially, Zostavax was approved for persons 60 years of age or older. In March 2011, the FDA approved a label change to include individuals aged 50 through 59. However, the Advisory Committee on Immunization Practices does not recommend

vaccination for persons aged 60 years or less, because of a lower risk for herpes zoster in this age group and concerns about vaccine supply. Although Zostavax contains the same live, attenuated strain of VZV as Varivax and ProQuad, it is present at a much higher titer. In fact, its minimum concentration is 14 times more potent than that of Varivax.<sup>13</sup>

Be warned that patients who develop active shingles should not be treated with Zostavax. Treatment with Zostavax also is contraindicated in patients who are pregnant; immunocompromised due to HIV, leukemia or lymphoma; or in those taking more than 20mg of prednisone per day for more than two weeks.<sup>2</sup> The use of immunomodulators, such as methotrexate or azathioprine, is not an absolute contraindication—but may still require prior consultation with a rheumatologist.

All VZV-containing vaccines are administered subcutaneously. Additionally, dosing guidelines vary with respect to previous infection, patient age and occupation (e.g., health care workers may be at higher risk for infection).

also has been used in the past, but was not proven effective.

Generic ganciclovir ointment or Zirgan (0.15% ganciclovir ophthalmic gel, Bausch + Lomb) may be beneficial for individuals with active lesions; however, ganciclovir's role and clinical efficacy has not been formally established. Nonetheless, off-label applications of ganciclovir have demonstrated good activity against HSV, VZV, cytomegalovirus, Epstein-Barr virus and multiple strains of adenovirus.<sup>11</sup>

Once the corneal stroma is involved, permanent scarring and damage can occur. Thus, disciform keratitis must be treated promptly with topical corticosteroids. Prednisolone acetate 1% QID to Q4H is recommended, with a slow taper over a few months. Cycloplegic agents, such as scopolamine 0.25%, should be used two to four times daily.

Take note that topical antivirals have little to no effect on inflammation associated with elevated intraocular pressure and/or iridocyclitis. Instead, prescribe topical

hypotensive agents for pressure control, as needed.

## Postherpetic Neuralgia

After the patient has recovered from the acute rash that characterizes HZO, he or she may experience pain in the affected dermatome that persists for weeks, months or even years. The pain from postherpetic neuralgia is often unbearable.

Approximately half of patients with shingles or postherpetic neuralgia describe their pain as “horrible” or “excruciating,” ranging in duration from a few minutes to constant, on a daily or almost daily basis.<sup>1</sup> In fact, there have been reports of suicide in elderly patients because of the unbearable pain.<sup>12</sup>

The mechanism that causes postherpetic neuralgia is not well understood. Injury to peripheral nerves and altered central nervous system signal processing may contribute to its onset. According to the CDC, “Pathologic observations thought to distinguish postherpetic neuralgia from uncomplicated

zoster include axonal and cell body degeneration, atrophy of the spinal cord dorsal horn, scarring of the dorsal root ganglion and loss of epidermal innervation of the affected area.”<sup>13</sup> This neuronal damage might be caused by ongoing viral replication.<sup>13</sup> Regardless of the exact mechanism, you may see herpes zoster patients who present with postherpetic neuralgia. In many instances, these individuals require timely referral to a pain management specialist.

## Treatment for Postherpetic Neuralgia

While there is no specific treatment course for postherpetic neuralgia, several oral and topical pain management strategies could help alleviate patient discomfort. Use of Neurontin (gabapentin, Pfizer), Lyrica (pregabalin, Pfizer), NSAID analgesics, narcotics and/or tricyclic antidepressants (e.g., amitriptyline) may prove effective.

Further, topical options include: Zostrix (capsaicin cream 0.025%, Hi-Tech Pharmaceutical Co. Inc), Qutenza patch (capsaicin 8%,



NeurogesX) and Lidoderm patches (lidocaine 5.0%, Endo Pharmaceuticals) may be used as well.

## Explanations for Increased Incidence

So, why has the number of herpes zoster cases increased during the last two decades, despite the availability of vaccines for both chickenpox and shingles? The higher disease incidence seems to be independent of the population's advancing age.

Interestingly, several studies indicated that the overall incidence of shingles started increasing before the chickenpox vaccine Varivax (live varicella virus, Merck) was introduced in the United States.<sup>1,14-16</sup> Still, the underlying reasons for this increased prevalence are not well understood. Most importantly, however, no consistent evidence suggests that the increased incidence of shingles in the US has been accelerated by the widespread use of the varicella vaccine.<sup>1</sup>

It is worth mentioning that there have been cases of patients who actually have experienced a reactivation of herpes zoster following vaccination. Recently, researchers reported the case of a patient with a 3.5-year history of inactive herpes zoster who experienced a bout of keratouveitis two weeks after receiving Zostavax.<sup>17</sup> The authors proposed that an increase in cell-mediated immunity was augmented by vaccine administration.<sup>17</sup>

## Vexed by Vaccination?

Whether widespread vaccination for chickenpox and shingles ultimately is "good or bad" for patient care is beyond the scope of this article. Nonetheless, this point must—at the very least—be touched upon.

Critics have contended that

the recent increase in shingles incidence has been caused by not allowing children to be exposed to VZV naturally at a young age—effectively denying them a lifetime of immunity. According to this argument, widespread vaccinations may prevent both children and adults from having their natural immunity boosted because they no longer come into regular contact with infected individuals.

Additionally, some advocates believe that mass vaccination for what often is regarded as a benign childhood illness is neither necessary nor cost effective.<sup>18</sup> In a recent article in the journal *Vaccine*, the authors argued that the varicella vaccination is less effective than the natural immunity experienced in pre-vaccine communities. Further, the researchers noted that mass vaccination isn't a cost-effective measure, because more money now must be spent treating the increased number of herpes zoster patients.<sup>18</sup>

Evidence-based medicine shows that mass vaccination does indeed lower the overall incidence of chickenpox and shingles in treated individuals. However, experts across many fields of the medical community still are determining the long-term, widespread impact of VZV vaccination upon the population as a whole.

As a primary eye care provider, you will encounter patients who inquire about the benefits of vaccination. You can inform them confidently that Zostavax is recommended for patients who are over the age of 60 or for those who have a history of shingles.

Treating herpes zoster can be both rewarding and frustrating—for you and the patient. It is important to recognize the signs and symptoms, and begin treat-

ment promptly. You must then monitor these patients closely and taper their medications accordingly. Finally, always remain vigilant about the possibility of postherpetic neuralgia. ■

*Dr. Marcolini is in a group practice at Omni Eye Services in Iselin, N.J., and in private practice in Clinton, N.J.*

1. The United States Centers for Disease Control and Prevention. Shingles (Herpes Zoster). Available at: [www.cdc.gov/shingles/hcp/clinical-overview.html](http://www.cdc.gov/shingles/hcp/clinical-overview.html). Accessed January 16, 2013.
2. The United States Centers for Disease Control and Prevention. Varicella. Available at: [www.cdc.gov/vaccines/pubs/pinkbook/downloads/varicella.pdf](http://www.cdc.gov/vaccines/pubs/pinkbook/downloads/varicella.pdf). Accessed January 16, 2013.
3. Ragozzino MW, Melton LJ 3rd, Kurland LT, et al. Population-based study of herpes zoster and its sequelae. *Medicine (Baltimore)*. 1982 Sep;61(5):310-6.
4. Oxman MN, Levin MJ, Johnson GR, et al. A vaccine to prevent herpes zoster and postherpetic neuralgia in older adults. *N Engl J Med*. 2005 Jun 2;352(22):2271-84.
5. Lee WB, Liesegang TJ. Herpes Zoster Keratitis. In: Krachmer JH, Mannis MJ, Holland EJ, eds. *Cornea*, 2nd ed. Philadelphia: Elsevier Mosby; 2005:1075-89.
6. Yanoff M, Duker JS. Infectious Keratitis. In: *Ophthalmology*, 2nd ed. Philadelphia: Mosby; 2004:469-81.
7. Liesegang TJ. Corneal complications from herpes zoster ophthalmicus. *Ophthalmology*. 1985 Mar;92(3):316-24.
8. Foster CS, Vitale AT. Herpes Viruses. In: *Diagnosis and Treatment of Uveitis*. Philadelphia: WB Saunders; 2002:317-23.
9. Wenkel H, Rummelt V, Fleckenstein B, Naumann GO. Detection of varicella zoster virus DNA and viral antigen in human eyes after herpes zoster ophthalmicus. *Ophthalmology*. 1998 Jul;105(7):1323-30.
10. Zaal MJ, Maudgal PC, Rietveld E, Suij EP. Chronic ocular zoster. *Curr Eye Res*. 1991;10 Suppl:125-30.
11. Foster CS. Ganciclovir gel—a new topical treatment for herpetic keratitis. Available at: [www.touchbriefings.com/pdf/3200/foster.pdf](http://www.touchbriefings.com/pdf/3200/foster.pdf). Accessed January 28, 2013.
12. El-Ansary M. International Association for the Study of Pain. Chapter 24: Management of postherpetic neuralgia. Available at: [www.iasp-pain.org/AM/Template.cfm?Section=Home&Template=/CM/ContentDisplay.cfm&ContentID=12187](http://www.iasp-pain.org/AM/Template.cfm?Section=Home&Template=/CM/ContentDisplay.cfm&ContentID=12187). Accessed January 28, 2013.
13. Harpaz R, Ortega-Sanchez IR, Seward JF. The United States Centers for Disease Control and Prevention. Prevention of Herpes Zoster: Recommendations of the Advisory Committee on Immunization Practices. Available at: [www.cdc.gov/mmwr/preview/mmwrhtml/rr5705a1.htm](http://www.cdc.gov/mmwr/preview/mmwrhtml/rr5705a1.htm). Accessed January 16, 2013.
14. Yawn BP, Saddier P, Wollan PC, et al. A population-based study of the incidence and complication rates of herpes zoster before zoster vaccine introduction. *Mayo Clin Proc* 2007 Nov;82(11):1341-9.
15. Donahue JG, Choo PW, Manson JE, Platt R. The incidence of herpes zoster. *Arch Int Med* 1995 Aug 7-21;155(15):1605-9.
16. Hales CM, Harpaz R, Joesoef MR, Bialek SR. Herpes zoster in the Medicare population, 1991-2009: Assessment of trends, risk factors and the impact of the varicella vaccination program. Poster presented at: IDWeek 2012; San Diego; October 17-21 2012.
17. Hwang CW Jr, Steigleman WA, Saucedo-Sanchez E, Tuli SS. Reactivation of herpes zoster keratitis in an adult after varicella zoster vaccination. *Cornea*. 2012 Nov 26. [Epub ahead of print]
18. Goldman GS, King PG. Review of the United States universal varicella vaccination program: Herpes zoster incidence rates, cost-effectiveness, and vaccine efficacy based primarily on the Antelope Valley Varicella Active Surveillance Project data. *Vaccine*. 2012 Jun 1. [Epub ahead of print]
19. Prince A. Infectious diseases. In: Behrman RE, Lickigman RM (eds.). *Essentials of pediatrics*, 2nd ed. Philadelphia: WB Saunders; 1994:297-394.

## OSC QUIZ

**Y**ou can obtain transcript-quality continuing education credit through the Optometric Study Center. Complete the test form (page 83), and return it with the \$35 fee to: Optometric CE, P.O. Box 488, Canal Street Station, New York, NY 10013. To be eligible, please return the card within one year of publication.

You can also access the test form and submit your answers and payment via credit card at *Review of Optometry* online, [www.revoptom.com](http://www.revoptom.com).

You must achieve a score of 70 or higher to receive credit. Allow eight to 10 weeks for processing. For each Optometric Study Center course you pass, you earn 2 hours of transcript-quality credit from Pennsylvania College of Optometry and double credit toward the AOA Optometric Recognition Award—Category 1.

Please check with your state licensing board to see if this approval counts toward your CE requirement for relicensure.

1. Primary infection with the varicella zoster virus (VZV) causes:

- a. Chickenpox.
- b. Measles.
- c. Mumps.
- d. Shingles.

2. How old are most individuals upon primary infection with VZV?

- a. Less than one year.
- b. Five to 10 years.
- c. 13 to 19 years.
- d. 60 to 69 years.

3. Approximately how many new cases of shingles are diagnosed annually in the US?

- a. 500,000 to one million.
- b. One million to two million.
- c. Five million to 10 million.
- d. More than 10 million.

4. What is the most common anatomical location for the manifestation of shingles?

- a. The eye and adnexa.
- b. The scalp.
- c. The lower thoracic region.
- d. The lower leg and calf region.

5. What is a potential trigger for VZV reactivation?

- a. Immunocompromising conditions.
- b. Immunosuppressive medication use.
- c. Long-standing emotional stress.
- d. All of the above.

6. The primary clinical trial for Zostavax (live zoster virus, Merck) indicated that the vaccine reduced an individual's risk for shingles by what percentage?

- a. 25%.
- b. 51%.
- c. 66%.
- d. 95%.

7. The primary clinical trial for Zostavax indicated that the vaccine reduced an individual's risk for postherpetic neuralgia by what percentage?

- a. 25%.
- b. 51%.
- c. 66%.
- d. 95%.

8. Currently, Zostavax is indicated for which age group?

- a. Less than one year.
- b. Five to 10 years.
- c. 50 years and older.
- d. 60 years and older.

9. How long does the acute phase of shingles typically persist?

- a. Three days.
- b. One week.
- c. Two weeks.
- d. One month.

10. Which nerve located along the trigeminal's V1 ophthalmic branch is most commonly affected by VZV reactivation?

- a. Posterior.
- b. Frontal.
- c. Nasociliary.
- d. Lacrimal.

11. Which ocular complication is NOT usually caused by herpes zoster ophthalmicus (HZO)?

- a. Anterior uveitis.
- b. Choroiditis.
- c. Retinal detachment.
- d. Optic neuritis.

12. What dosing regimen is NOT a recommended treatment for HZO?

- a. 6mg oseltamivir phosphate for seven days.
- b. 500mg famciclovir QD for seven days.
- c. 800mg acyclovir five times a day for seven to 10 days.
- d. 1,000mg valacyclovir TID for seven days.

13. In patients with shingles, systemic corticosteroids in conjunction with oral antiviral therapy has been shown to:

- a. Shorten healing times and decrease pain during the acute infection period.
- b. Lengthen healing times, but decrease pain during the acute infection period.
- c. Lengthen healing times and increase pain during the acute infection period.
- d. Increase the patient's risk for posterior uveitis.

14. What medication should be used to treat disciform keratitis in shingles patients?

- a. Vidarabine.
- b. Trifluridine.
- c. Prednisolone acetate 1%.
- d. Moxifloxacin.

15. What is the hallmark symptom of postherpetic neuralgia?

- a. Dry skin.
- b. Excruciating pain.
- c. Longstanding fever.
- d. Severe alopecia.

16. Which medication is recommended to treat pain associated with postherpetic neuralgia?

- a. Zostrix (capsaicin cream 0.025%, Hi-Tech Pharmaceutical Co. Inc).
- b. Lyrica (pregabalin, Pfizer).
- c. Lidoderm patches (lidocaine 5.0%, Endo Pharmaceuticals).
- d. All of the above.

17. In which year did the chickenpox vaccine Varivax (live varicella virus, Merck) first become available?

- a. 1969.
- b. 1973.
- c. 1995.
- d. 2006.

## OSC QUIZ

18. Since the release of Varivax, the number of hospitalizations and deaths caused by primary VZV infection has declined by what percentage?

- a. 20%.
- b. 30%.
- c. 70%.
- d. 90%.

19. Which vaccine provides immunity to measles, mumps, rubella and varicella?

- a. Imovax (Sanofi Pasteur).
- b. ProQuad (Merck).
- c. Varivax.
- d. Zostavax.

20. What is NOT a contraindication for the Zostavax vaccine?

- a. HIV.
- b. Pregnancy.
- c. Lymphoma.
- d. Diabetes.

### Important Notice: Processing Answer Sheets and CE Certificates

*Review of Optometry* is strengthening our commitment to the environment and "going green."

Effective September 2012, we will send the results of any CE post-course test that is manually submitted (via mail or fax) to the email address provided on your answer sheet.

If you do not provide an email address OR if you prefer to receive a hard copy of your certificate of completion via mail, you will be charged a \$2.50 processing fee per certificate (via credit card or check payable to Jobson Medical Information LLC).

We cannot process your post-course test if neither an email address nor \$2.50 processing fee is provided. Any answer sheet will automatically be returned to you.

We appreciate your support of this new process. Please contact us via email at [cecus-tomerservice@jobson.com](mailto:cecus-tomerservice@jobson.com) with any questions. Thank you!

## Examination Answer Sheet

Valid for credit through February 1, 2016

This exam can be taken online at [www.revoptom.com](http://www.revoptom.com). Upon passing the exam, you can view your results immediately. You can also view your test history at any time from the website.

### Varicella Zoster Virus: From Chickenpox to Shingles

Directions: Select one answer for each question in the exam and completely darken the appropriate circle. A minimum score of 70% is required to earn credit.

Mail to: Jobson - Optometric CE, PO Box 488, Canal Street Station, New York, NY 10013

Payment: Remit \$35 with this exam. Make check payable to Jobson Medical Information LLC.

COPE approval for 2 hours of CE credit is pending for this course.

This course is joint-sponsored by the Pennsylvania College of Optometry

There is an eight-to-ten week processing time for this exam.

- 1 = Excellent 2 = Very Good 3 = Good 4 = Fair 5 = Poor
- Rate the effectiveness of how well the activity:
1.  A  B  C  D
  2.  A  B  C  D
  3.  A  B  C  D
  4.  A  B  C  D
  5.  A  B  C  D
  6.  A  B  C  D
  7.  A  B  C  D
  8.  A  B  C  D
  9.  A  B  C  D
  10.  A  B  C  D
  11.  A  B  C  D
  12.  A  B  C  D
  13.  A  B  C  D
  14.  A  B  C  D
  15.  A  B  C  D
  16.  A  B  C  D
  17.  A  B  C  D
  18.  A  B  C  D
  19.  A  B  C  D
  20.  A  B  C  D
21. Met the goal statement:  1  2  3  4  5
22. Related to your practice needs:  1  2  3  4  5
23. Will help you improve patient care:  1  2  3  4  5
24. Avoided commercial bias/influence:  1  2  3  4  5
25. How would you rate the overall quality of the material presented?  1  2  3  4  5
26. Your knowledge of the subject was increased:  
 Greatly  Somewhat  Little
27. The difficulty of the course was:  
 Complex  Appropriate  Basic
- How long did it take to complete this course?
- Comments on this course:
- Suggested topics for future CE articles:

Please retain a copy for your records. Please print clearly.

You must choose and complete one of the following three identifier types:

- ① SS #  -  -
- Last 4 digits of your SS # and date of birth      State Code and License #: (Example: NY12345678)
- ②  -       ③

First Name

Last Name

E-Mail

The following is your:  Home Address  Business Address

Business Name

Address

City  State

ZIP

Telephone #  -  -

Fax #  -  -

By submitting this answer sheet, I certify that I have read the lesson in its entirety and completed the self-assessment exam personally based on the material presented. I have not obtained the answers to this exam by any fraudulent or improper means.

Signature \_\_\_\_\_ Date \_\_\_\_\_



# SECO 2013: Celebrating 90 Years of Education

This year's 90th annual Southern Congress will offer plenty for everyone.

**By Paul C. Ajamian, OD, FAAO, SECO OD Education Committee Chair**

**F**or the past nine decades, SECO has been the leader in continuing education for optometric professionals—stretching an impressive timeline from the 1920s until today. As SECO gets ready to celebrate its 90th anniversary, this year's Congress, to be held in Atlanta from February 27 through March 3, is marking this milestone with over 240 high-quality OD and AOP continuing education courses, more than 100 world-renowned speakers and nearly 300 industry-leading exhibitors.

In honor of the 90th SECO event, the theme is “A Celebration of Education,” which will be prevalent throughout our innovative educational tracks and Special Sessions, the vast Optometry's Marketplace show floor, and our many social and networking events.

SECO 2013 will offer nearly 400 hours of continuing education for optometrists, opticians, paraoptometricians, ophthalmic technicians and administrative staff. The OD program will feature 109 courses, including three symposia, seven joint education courses and a special course titled “Teaming Up with Pediatric Ophthalmology.”

Here's a look at some of the

many courses you won't want to miss at this year's meeting:

***Score Big with the Right Drugs—Tammy Than, MS, OD, FAAO***

This Wednesday course will review the newest topical and systemic medications used in the treatment of ocular disease. Benefits of using the new drugs over existing medications will be discussed along with contraindications and potential side effects. Case examples will emphasize the clinical indications. Dr. Than will also discuss off-label and unlabeled drug use in addition to compounding pharmacies.

***Therapeutics: A Look Back, A Look Ahead—Paul Ajamian, OD, FAAO, Moderator; Jimmy Bartlett, OD, DOS, ScD; Louis Catania, OD.***

This Thursday Special Session will feature and honor two pioneers in optometric pharmacology and disease management. This “tribute” will include a look at “the old days,” and how we've gotten to where we are today. Current treatment modalities will be evaluated along with trends for the future. Presenters will discuss a variety of conditions including red eye, bacterial conjunctivitis, blepharitis and staph lid disease.

***Refractive/Cataract Surgery: The Future Revealed—Paul Karpecki, OD, FAAO, Moderator; Jason Brinton, MD; Tyrie Jenkins, MD***

Moderator Paul Karpecki will lead an expert panel of surgeons during this Thursday Special Session, including Jason Brinton and Tyrie Jenkins. They will discuss the latest research and techniques in cataract and refractive surgery, while conducting interactive polling to track the knowledge gained during the program.

Topics will include the latest in femtosecond lasers, UV light corneal cross-linking, drug delivery systems, nanotechnology, 3-D surgical systems, intraoperative aberrometry in addition to the future of accommodating IOLs.

***Hot Topics in Glaucoma: The Burning Questions Answered—Michael Chaglasian, OD, Moderator; John Flanagan, BSc, PhD, FAAO, MCOptom; Leo Semes, OD, FAAO***

An all-star-lineup will provide up-to-the-minute information in this Thursday Special Session, including how to best diagnose, treat and manage our glaucoma patients. Specific topics will include new medications, OCT and perimetry,

the role of cerebrospinal fluid pressure and new surgical approaches to glaucoma. A panel of experts will give short presentations followed by an audience question and answer session.

### *The Genetic Mysteries of Retinal Dystrophies—Sherry Bass, OD*

Join Sherry Bass on Friday as she reviews the characteristics and management of various hereditary retinal dystrophies. The state-of-the-art technology and genetic testing used to help define the type of dystrophy will be illustrated, along with challenging case presentations.

### *Everything You Wanted to Know About Diabetes—David Shein, MD; Joan Hill, RD, CDE, LDN*

The impact of diabetes in the US and worldwide continues to increase. This Friday course will review many key features of diabetes relevant to clinical practice. The focus will be on epidemiologic and diagnostic considerations, key complications of diabetes, as well as common tests and a rational approach to treatment. The speakers will also highlight key measures of diabetes quality.

### *EHR: Meaningful Use—Zachary McCarty, OD*

As Stage 1 Meaningful Use winds down, the time quickly approaches to learn about requirements for Stage 2. Are you prepared? What should you be asking your EHR vendor in advance? Learn this and more in this fact-packed, fast-paced Friday lecture.

### *Mayo Clinic Grand Rounds—Christian Guier, OD, FAAO; Muriel Schornack, OD, FAAO*

The Mayo Clinic has a long tradition of providing innovative health care to those most in need. This

Friday grand rounds format program will look at some recent clinical challenges seen at the Mayo Clinic—ranging from the subtle to the obvious. The course will review patient presentations, clinical and laboratory findings, management options and outcomes.

### *Alzheimer's Ocular Disease Connection—Stuart Richer, OD, PhD, FAAO*

On Saturday, Stuart Richer will review new research with respect to early diagnosis of Alzheimer's disease using the human lens and the association with glaucoma. The course will explore the pathophysiology of Alzheimer's disease and the new ophthalmic diagnostic research.

### *Enhance Your Understanding of Neuro-Imaging—Kelly Malloy, OD, FAAO*

Dr. Malloy will highlight neuro-imaging studies ordered in neuro-ophthalmic disease practice during this Saturday course. CT/CTA, MRI/MRA/MRV and angiography will be discussed in terms of indications, contraindication and ordering protocol. In addition, multiple images will contrast normal and abnormal studies. A case-based approach will tie in clinical applications, and strengthen your radiologic interpretation skills.

### *New Technologies for Management of the AMD Patient—Mohammad Rafieetary, OD*

This Saturday course will review the demographics and risk factors for age-related macular degenera-



**For 90 years, SECO has continued to provide outstanding education for optometrists, opticians, paraoptometrics, ophthalmic technicians and administrative staff.**

tion, as well as investigational and current available treatment options. The urgency of a timely diagnosis for new onset or recurrent neovascular AMD will be discussed, with emphasis on the various technologies now available to treat these patients.

In addition to world-class CE, SECO 2013 will house nearly 300 industry-leading companies showcasing new trends and the most recent product introductions, as well as breakthrough technologies and services—all on the exhibit hall floor. And you won't want to miss the more than 50 SECO signature social and affiliate events including Wednesday night's Downtown Dine-Around, Friday's AOP and Student Parties and Saturday night's President's Celebration featuring Better Than Ezra.

If you haven't registered yet, what are you waiting for? Go to <http://seco2013.com/>.

I look forward to seeing you in Atlanta for SECO 2013, your Education Destination! ■

# SNEAK PEEK at Vision Expo East 2013

New York City is the place where you can find the trendiest eyewear fashions, cutting-edge equipment, and hundreds of hours of top-notch continuing education.

By Cheryl G. Murphy, OD, Contributing Editor

**W**ith an ever-expanding roster of all-star speakers, exhibitors and designers, a ticket to this year's International Vision Expo East, March 14 to 17, could be your backstage all-access pass to experience the latest in trends, technology and education that the eye world has to offer.

Last year, Vision Expo East 2012 broke its own longstanding record for attendance (first set in 1986 at the event's inception). In the last four years, the number of Vision Expo East exhibitors and attendees filing into the Jacob Javits Center has expanded by more than 25%. With more than 350 hours of top-notch continuing education classes, 120 hours of social networking events and 5,000-plus brands sprawled out over more than 250,000 square feet of newly renovated, modern exhibit hall space in heart of New York City, Vision Expo East has quickly become the one-stop destination for up-to-the-minute information and products on everything eye care and eyewear related.

## Best Ticket in Town

Brush up your knowledge of the latest treatment guidelines and techniques. ODs, opticians, eye care professionals, optometric technicians and staff have a wide range of educational options designed to

help expand their expertise and sharpen their skills. Choose from a diverse list of more than 200 continuing education classes that are conveniently divided into five categories: clinical, contact lens, allied health, optical technology and business solutions.

These categories offer a wide range of topics such

as *Clinical Dermatology for the Optometrist*, *Developing Your Specialty Contact Lens Practice*, *The Importance of Photography and Other Diagnostic Studies*, *12 Point Primer on Polarized Lenses*, *The Art of Effective Conversation*, and much more.

Other courses offered can help your practice stay on top of compliance, incentive and government regulations such

as PQRS, EHR, e-prescribing and coding.

Forward-thinking practice management classes incorporate fresh business solutions and strategies, including the all-new Chief eXperience Officer (CXO) program, a four-hour course empowering personnel in your office with the tools they need to give extraordinary, personalized customer care.

## Hobnobbing with Other ECPs

VEE provides a great opportunity to meet and speak with ODs, opticians, eye care professionals and industry insiders from all over the nation, and all over the world. Vision Expo East offers more than 120



**In addition to the exhibits and education, Vision Expo East hosts dozens of social events, such as last year's Eyes on New York Gala.**



**TV's Carson Kressley has been the emcee of the Vision Expo Fashion Show for two years running.**

hours of social gatherings, parties and networking events. For instance, there's two big events to choose from on Friday night: The Eyes on New York Gala, hosted by SUNY College of Optometry, or a performance by The Bad Habits ("The Eye Docs of Rock") at Famous Dave's in Times Square.

Plan your schedule and check the Vision Expo website for more information and a list of these and other networking and social events.

### Behind the Velvet Rope

One more reason to come to Vision Expo East: You'll get a behind-the-scenes look at the newest eyewear styles and fashions, as well as a chance to see first-hand demonstrations of cutting-edge medical equipment and products. You can also preview the newest advancements in lens and processing technologies.

The exhibit hall can be a bit overwhelming, particularly if you are only planning to be at the Expo for one day or have limited time to see everything in between CE classes. So, plan ahead. The VEE website ([www.visionexpoeast.com](http://www.visionexpoeast.com)) has a My Show Planner application that features an interactive floor plan and map to help you stay organized, keep track of which exhibitors you want to be sure to visit and of appointments you've made.



**Check out the latest fashions and brands in eyewear and products from all over the world.**



**In the exhibit hall, hundreds of exhibitors show off the latest in cutting-edge diagnostic technology and ophthalmic equipment.**

Or do it all from your mobile device. The Vision Expo Mobile app, available at [www.visionexpoeast.com/Vision-Mobile](http://www.visionexpoeast.com/Vision-Mobile), allows you "to find exhibitors and new products quickly navigate the show floor via interactive maps, see show specials, view the full education schedule, download course handouts, contact exhibitors for appointments and get the latest show news and alerts," according to International Vision Expo.

Also, you can follow Vision Expo on Twitter [@VisionExpo](https://twitter.com/VisionExpo), Facebook at [www.facebook.com/visionexpo](http://www.facebook.com/visionexpo) and on YouTube at [www.youtube.com/user/IntlVisionExpo](http://www.youtube.com/user/IntlVisionExpo).

Can't plan a trip to NYC this March, but you still want behind-the-scenes, live updates from Vision Expo East? Don't fret. I'll be on the scene to Tweet and share pics from Vision Expo East on [@revoptom](https://twitter.com/revoptom) to bring you more insider info, footage and fun! ■



# When to Send Out Sjögren's

The OD is crucial to identify a patient with Sjögren's syndrome—and putting that patient on the right track to diagnosis and treatment. **Edited by Paul C. Ajamian, OD**

**Q** I see a lot of patients with dry eye who, upon questioning, also say they have dry mouth.

**What's my next step in ruling out Sjögren's syndrome?**

**A** "It's all about history," says Robert Prouty, OD, center director of Omni Eye Specialists in Denver. "There's no one specific sign or symptom that is uniquely diagnostic for Sjögren's syndrome."

That said, the hallmark symptoms of Sjögren's are dry eye and dry mouth (xerostomia). Indeed, a recent study found that almost 12% of patients with aqueous-deficient dry eye have Sjögren's syndrome.<sup>1</sup>

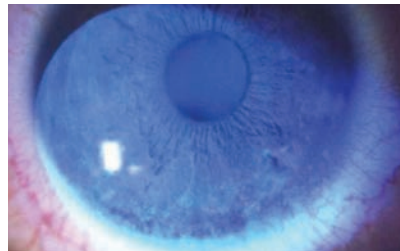
So, Dr. Prouty says, if you see a patient with dry eye who also reports dry mouth, or is holding onto a water bottle, ask about:

- Joint pain/dysfunction.
- Dental problems.
- Gastrointestinal issues.
- Neurological symptoms

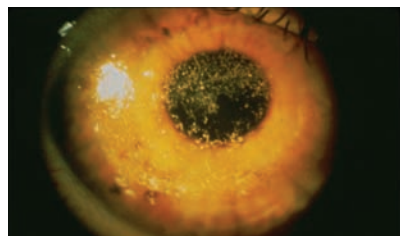
("brain fog").

Any of these conditions should prompt you to investigate further. Unfortunately, because the symptoms of Sjögren's are non-specific, it can take more than six years after the onset of symptoms before the patient is diagnosed, according to the Sjögren's Syndrome Foundation. Thus, the optometrist is in a key position to get these patients diagnosed early, and to help them obtain treatment.

Now, who do you refer them to? "I don't think that sending the patient to the primary care physi-



**Superficial punctate keratitis in a Sjögren's patient on Restasis therapy.**



**Severe filamentary keratitis in a mucus sheet in a patient with severe dry eye due to Sjögren's.**

cian or family doctor is always the best choice," Dr. Prouty says. The family doctor may not have the familiarity with the disease to put the patient on a quick course to diagnosis.

A better option is to send the patient to a rheumatologist or dentist who has experience or knowledge in diagnosing Sjögren's or other autoimmune diseases.

The time to find an experienced rheumatologist or dentist is *now*, before you have a patient with Sjögren's in your chair, Dr. Prouty says. "Ask around to find a qualified doctor you can work with—one who has the diagnostic know-how to do advanced workup and histologic testing," he says.

Diagnostic blood work usually

involves anti-nuclear antibody (ANA), autoantibodies (Anti-SSA or Anti-SSB) and rheumatoid factor tests. Additional dental testing may include measuring salivary gland function or salivary gland/lip biopsy ("lip punch") for lymphocytic infiltration.

While the patient may have no joint symptoms, referring to a rheumatologist is still the right call, Dr. Prouty says. That's because a rheumatologist is the one who is most likely to be familiar with the systemic medications to treat the patient. For Sjögren's, that means immunosuppressive medications such as methotrexate or Plaquenil (hydroxychloroquine, Sanofi-Aventis).

Meanwhile, the optometrist should be treating and monitoring the patient's ocular health. Dry eye is usually chronic in patients with Sjögren's, and can even be sight threatening if it becomes very severe, Dr. Prouty says. Treatment involves frequent administration of artificial tears (preferably non-preserved), and possibly Restasis (cyclosporine, Allergan) for long-term control of inflammation.

Last but not least, "the optometrist should be working in concert and inter-reporting with the rheumatologist, and the dentist as well, to confer about keeping the patient's condition stable," Dr. Prouty says. ■

1. Liew MS, Zhang M, Kim E, Akpek EK. Prevalence and predictors of Sjögren's syndrome in a prospective cohort of patients with aqueous-deficient dry eye. *Br J Ophthalmol.* 2012 Dec;96(12):1498-503.



# JOIN US AT SECO 2013

February 27 - March 3, 2013



## EDUCATION

- Recognizing 90 years of providing the very best in eye care education, SECO's theme this year is "Celebration of Education."
- Choose from nearly 400 hours of continuing education for eye care professionals.
- Celebrate education among 240 quality OD and AOP continuing education courses and more than 100 world-renowned speakers.



## EXHIBITS

- Be sure to visit Optometry's Marketplace®, one the largest exhibit halls in optometry.
- Visit nearly 300 industry leading companies to learn about the innovative technologies being developed in Optometry.
- Shop thousands of frame styles – from luxury eyewear to affordable styles to the most durable sport-specific frames.



## EVENTS

- Don't miss the President's Celebration at the historical Tabernacle — featuring Better than Ezra.
- Network with fellow eye care professionals throughout the entire conference at one of SECO's more than 50 social and affiliate functions.
- Enjoy the new Downtown Dine Around event on Wednesday evening.

# Register Today

[www.secointernational.com](http://www.secointernational.com)

**90** YEARS  
A CELEBRATION  
OF EDUCATION



The SECO Champion Program is an elite partnership between leaders of the ophthalmic industry and SECO International. Their goal is to provide optometric professionals with the tools to achieve the highest levels of clinical knowledge and performance.

Premier Partners

**ACUVUE**  
BRAND CONTACT LENSES  
INNOVATION FOR HEALTHY VISION™

**Alcon**

**ALLERGAN**

**vspglobal**  
SHAPING YOUR VISION

**BAUSCH + LOMB**  
See better. Live better.

Partners

**Abbott**  
Medical Optics

**Essilor**  
Seeing the world better



# Rigid Lens Makes Eye Go Slack

While not all rigid lens wearers experience aponeurotic ptosis, it's not an uncommon condition in this patient population. **Edited by Joseph P. Shovlin, OD**

**Q** I have a rigid contact lens wearer who has experienced a significant ptosis on the left side—could this be a disinsertion of the levator aponeurosis? What is the patient's necessary hiatus from lens wear following surgical repair?

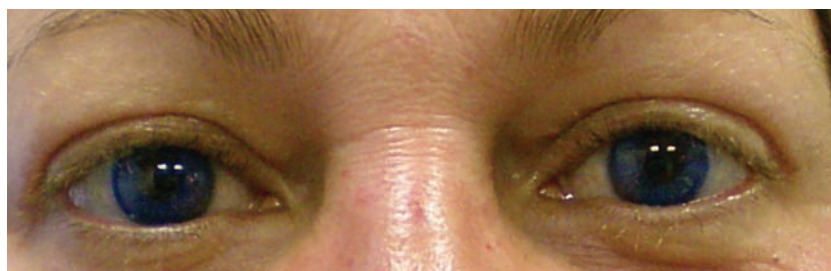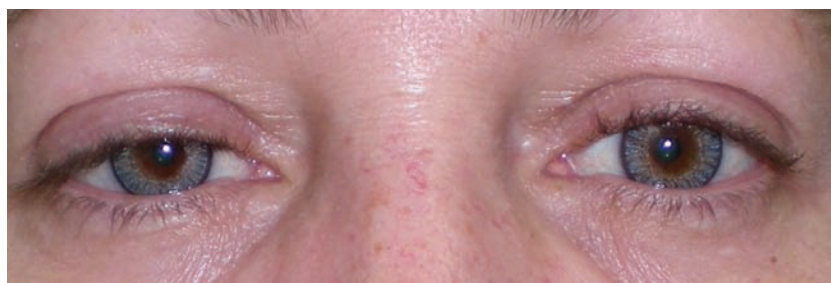**A** “Rigid lens-induced eyelid ptosis is a well-established condition,” says John Lee, MD, an ophthalmologist and oculoplastic surgeon practicing in Southeastern Pennsylvania and Maryland. “It is thought to be caused by years of mechanical traction from pulling the lids while removing the lens.”

The diagnosis of lens-induced levator disinsertion (aponeurotic ptosis) is made clinically. “An increased lid crease height with normal levator function is indicative of levator dehiscence,” Dr. Lee says. Another possible cause of eyelid ptosis may be irritation and/or inflammation of the conjunctiva due to the lens itself.

So, inspect the conjunctiva for signs of papillary conjunctivitis associated with contact lens use, in addition to checking the patient's pupils for abnormalities to rule out Horner's (especially a smaller pupil on the side with ptosis).

Surgical options for aponeurotic ptosis include:

- An external levator resection, which involves making an external incision along the eyelid crease. “These patients typically use antibiotic ointment for several weeks (post-op),” Dr. Lee says. “The combination of antibiotic ointment



**A patient with right upper lid ptosis, before and after surgical correction.**

and postoperative swelling makes it difficult for patients to wear contact lenses immediately after surgery.” They typically resume wear two to six weeks after surgery.

- A Fasanella-Servat/Müller-ectomy procedure, which is performed on the conjunctiva. “These patients often use a soft bandage contact lens for one week after surgery and can return to their normal contact lenses during the second week,” Dr. Lee says. Antibiotic drops are used for two weeks after surgery.

“I tell patients to wait a minimum of three weeks before resuming lens wear, but it may take as long as six weeks for complete adherence of the levator muscle to the tarsal plate in its new position,” says Robert Penne, MD, director of the Oculoplastic and Orbital Sur-

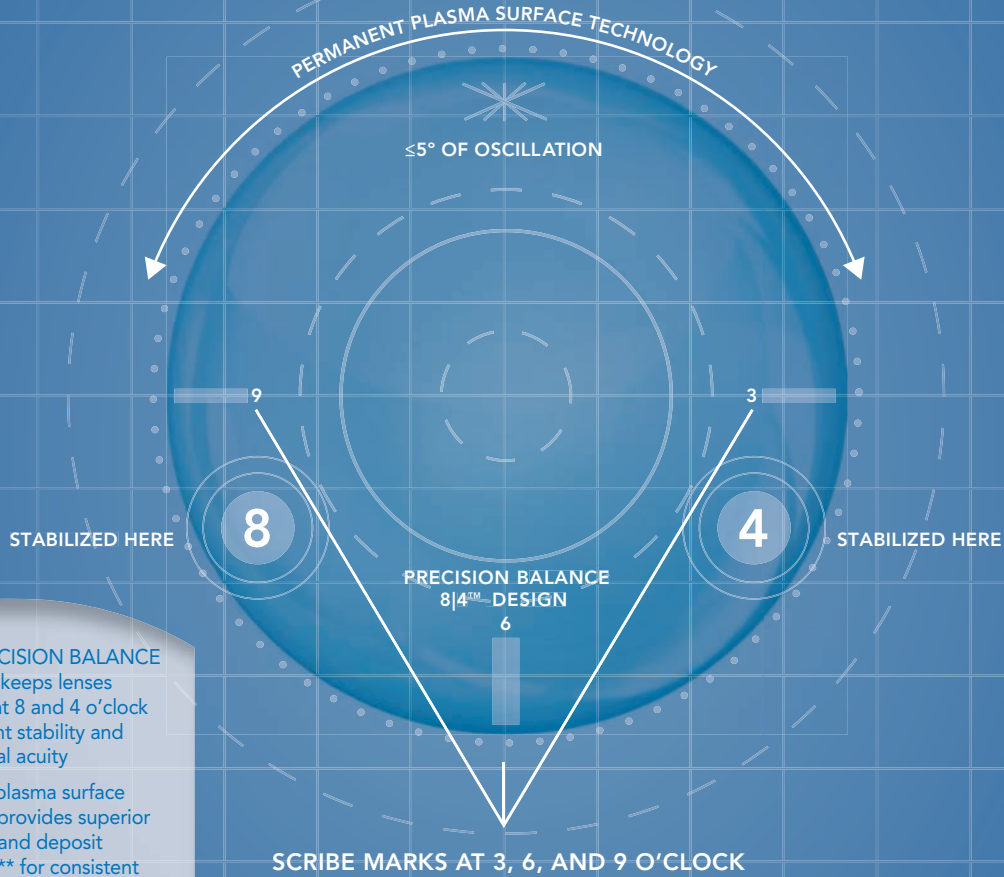
gery Service at the Wills Eye Institute in Philadelphia. “I usually also have them see their CL professional to get a plunger to remove their rigid lenses for another three weeks so they're not pulling on their eyelid.” Continued use of the plunger may be prudent to minimize the pulling effect on the lid with forceful removal. Some patients may be best suited for a soft lens re-fit.

An update in the contact lens parameters may be necessary after surgery due to the change in eyelid and lens dynamic. “Warn patients that their lenses may sit differently,” Dr. Penne says. “They may have more problems wearing their lenses, even if the lens is in exactly the same position (as it was before surgery), patients may feel drier and have more trouble wearing their lenses.” ■

Photos: John Lee, MD

# STABILITY

IS THE CORE OF OUR DESIGN



- Unique PRECISION BALANCE 8|4™ Design keeps lenses positioned at 8 and 4 o'clock for consistent stability and reliable visual acuity
- Permanent plasma surface technology provides superior wettability<sup>1</sup> and deposit resistance<sup>2,3\*\*</sup> for consistent comfort from Day 1 to Day 30<sup>4</sup>

## AIR OPTIX® for Astigmatism Contact Lenses

Visit [myalcon.com](http://myalcon.com) to learn why AIR OPTIX® for Astigmatism contact lenses are the lenses of choice for many ECPs



Engineered for sustained performance

\*Dk/t = 108 @ -3.00D, -1.25 x 180. \*\*Compared to Biofinity<sup>^</sup>, PureVision<sup>^</sup>, ACUVUE<sup>^</sup> OASYS<sup>^</sup>, ACUVUE<sup>^</sup> ADVANCE<sup>^</sup>, and Avaira<sup>^</sup> lenses. <sup>^</sup>Trademarks are the property of their respective owners.

**Important information for AIR OPTIX® for Astigmatism (Iotrafalcon B) contact lenses:** For daily wear or extended wear up to 6 nights for near/far-sightedness and astigmatism. Risk of serious eye problems (i.e. corneal ulcer) is greater for extended wear. In rare cases, loss of vision may result. Side effects like discomfort, mild burning or stinging may occur.

**References:** 1. In vitro measurement of contact angles on unworn spherical lenses; significance demonstrated at the 0.05 level; Alcon data on file, 2009. 2. Ex vivo measurement of lipid deposits on lenses worn daily through manufacturer-recommended replacement period; AOSept Plus used for cleaning and disinfection; significance demonstrated at the 0.05 level; Alcon data on file, 2008. 3. Nash W, Gabriel M, Mowrey-McKee M. A comparison of various silicone hydrogel lenses; lipid and protein deposition as a result of daily wear. *Optom Vis Sci.* 2010;87:E-abstract 105110. 4. Davis RL, Eiden SB. Evaluation of changes in comfort and vision during weeks 3 and 4 of monthly replacement silicone hydrogel contact lenses. *American Academy of Optometry*; 2012; E-abstract 125401.

See product instructions for complete wear, care and safety information.



# A New Hint for Glaucoma Risk?

A middle-aged man presents with moderate glaucoma in his right eye only. Were there telltale risk factors that may have resulted in earlier treatment? **By James L. Fanelli, OD**

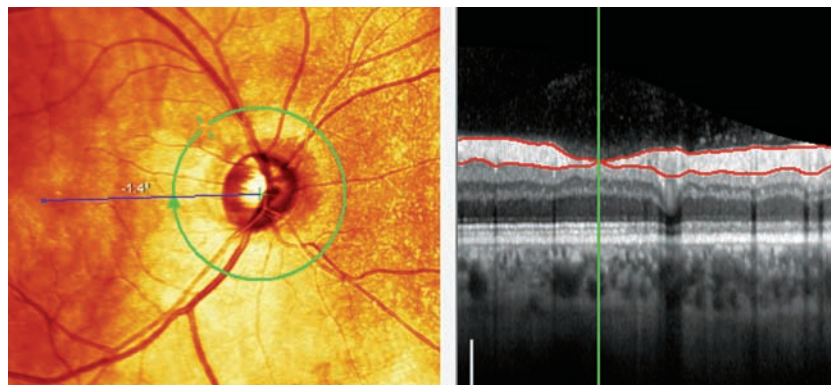
**A** 48-year-old white male presented as a new patient in January 2012 with a simple complaint of blurred vision with near tasks. He wore spectacles with a compound hyperopic, astigmatic and presbyopic correction that was two years old.

Systemic medical history was remarkable for hypertension, hypercholesterolemia and hyperlipidemia. He has a significant family history of cardiovascular disease, and he'd had a coronary artery bypass graft about two years earlier. Current medications included Prinivil (lisinopril, Merck), Lipitor (atorvastatin, Pfizer), Cardizem (diltiazem, Valeant) and Plavix (clopidogrel, Bristol-Myers Squibb). He reported no allergies to medications.

He said that at his last eye examination, the doctor mentioned that he had glaucoma in his right eye and that he should be "taking drops" to treat it. He reported that he did begin a drop (he couldn't remember which) once daily at bedtime in the right eye, but discontinued it after a week or so due to irritation. He admitted that he should have followed earlier recommendations, and that he was now prepared to do so.

## Diagnostic Data

Entering visual acuity was 20/25-OD and 20/25+ OS at distance and J3 OU at near; he was correctable to 20/20 OU. Pupils were equal, round and reactive to light with no afferent defect. Extraocular motilities were



**Note the retinal nerve fiber layer (RNFL) wedge defect seen at 10 o'clock (left). The RNFL thickness scan (right) shows the green line at the center of the wedge defect, where the RNFL was only 4µm thick.**

full in all positions of gaze.

Slit lamp examination of his anterior segments was unremarkable in both eyes, and his angles were estimated as grade 4 open OU. Central corneal thicknesses measured 531µm OD and 526µm OS. Intraocular pressure was 29mm Hg OD and 22mm Hg OS.

Upon dilation, his optic nerves showed glaucomatous optic neuropathy OD. Specifically, the cup-to-disc ratio of the right eye was 0.55 x 0.85 with marked thinning of the superior neuroretinal rim, where there was a notable nerve fiber layer wedge defect. Cup-to-disc ratio of the left eye was 0.45 x 0.50 with a plush, well-perfused neuroretinal rim.

The retinal vasculature showed moderate hypertensive and arteriosclerotic (AS) retinopathy (OD slightly worse than OS). Specifically, the retinal arterial tree in the right eye was characterized by thinned retinal arterioles

along the superior arcade, with grade 1 hypertensive retinopathy and grade 3 AS retinopathy. The vasculature of the left eye was comparable, with an overall decreased arteriole-to-venule (A/V) ratio, grade 1 hypertensive retinopathy and grade 2 AS retinopathy. The peripheral retinal examination revealed scattered areas of microcystoid OU.

At the initial visit, stereo optic nerve images were obtained as baseline. We scheduled the patient for optic nerve imaging and visual fields in two weeks, and prescribed new glasses.

At the follow-up, the patient's IOP measured 31mm Hg OD and 23mm Hg OS. Visual fields demonstrated paracentral areas of decreased sensitivity in the inferior arcuate area OD, consistent with the neuroretinal rim thinning. Gonioscopy revealed grade 4 open angles OU with minimal trabecular pigmentation.



## Management

I prescribed Travatan Z (travoprost, Alcon) OD HS, and asked him to follow up in three to four weeks. On this and further follow-up visits, the patient was compliant with his appointments and reported good compliance with his drop regimen. His average IOP during this time was 18mm Hg to 20mm Hg OD. I had set a target IOP of 16mm Hg or less in the right eye, so I ultimately added timolol 0.5% OD QD a.m.

Subsequent visits have shown that the IOP, neuroretinal rim, RNFL and visual fields in his right eye have stabilized. The left eye is also stable with no medical intervention.

## Discussion

This patient presented with three notable findings: glaucomatous optic neuropathy OD, notable asymmetry between the optic nerves, and a significant history of cardiovascular disease.

We know that patients with vasculospastic disease and poor ocular perfusion are at an increased risk of developing glaucoma. This patient's history of significant cardiovascular disease correlates with the possibility of poor perfusion to the eye. And the patient had undergone carotid Doppler imaging, which was normal right and left.

While various formulas exist to estimate ocular perfusion pressure, they all take into account blood pressure as measured in the arm. But, this does not always correlate to blood pressure and perfusion at the level of the central retinal artery—especially in the presence of carotid artery disease.

Also, we know that pressure in the optic nerve subarachnoid space plays a role in perfusion pressure-related mechanics of the optic nerve

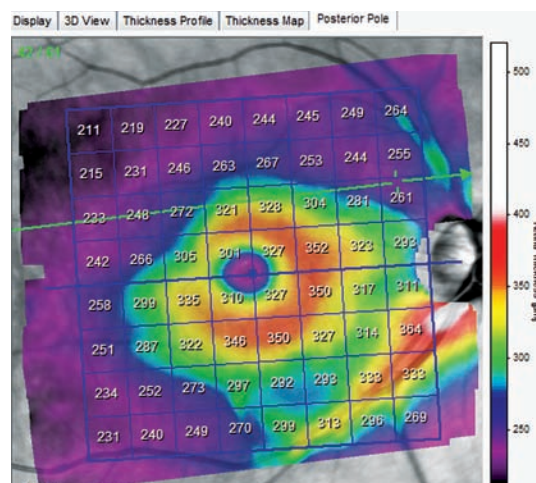
head—a pressure that's difficult at best to measure, and realistically can only be estimated via imaging. (See “Can High Pressure Be Helpful?” December 2012).

So, in the absence of definitive carotid artery disease, are there any other findings—at least from a vascular perspective—that suggest an increased risk of developing glaucoma?

The answer now seems to be yes. For many years, we've known that decreased retinal arterial diameter is often associated with glaucoma, but the data was confounded by other risk factors.<sup>1-3</sup> But recently, a 10-year study—part of the Blue Mountains Eye Study—examined the relationship between retinal vessel diameter (both arterioles and venules) and the risk of developing glaucoma.<sup>4</sup> After accounting for the correlation between IOP, elevated cholesterol and ocular perfusion pressure, the authors found a significant relationship between decreased retinal vessel caliber diameter and the risk of developing glaucoma.<sup>4</sup>

Importantly, this study showed a significant relationship between the risk of developing glaucoma and decreased retinal artery diameter after eliminating confounding factors. No relationship was found between decreased retinal vein diameter and glaucoma.

So, does the presence of decreased retinal arterial diameter play a role in determining the risk of developing glaucoma? Absolutely. But, further work is needed to specifically outline the significance of decreased retinal



**Significant thinning in the superior temporal arcuate area extends from the optic nerve beyond the temporal side of the foveal avascular zone.**

artery diameter. For the question still remains: Does the decreased retinal arterial diameter and, presumably, the concurrent decreased perfusion, cause the glaucomatous optic nerve damage that we see—or does the optic nerve damage of the neuroretinal rim and the retinal nerve fiber layer ultimately result in less need for perfusion?

In any case, we must be vigilant for signs of decreased optic nerve and peripapillary nerve perfusion, such as decreased arteriolar diameter. And, because retinal arterial thinning can cause loss of tissue at an area located “away” from the neuroretinal rim, maybe we need to look more closely there for early damage—especially because the technology to do so now exists. ■

1. Zheng Y, Cheung N, Aung T, et al. Relationship of retinal vascular caliber with retinal nerve fiber layer thickness: the Singapore Malay Eye Study. *Invest Ophthalmol Vis Sci.* 2009 Sep;50(9):4091-6.

2. Mitchell P, Leung H, Wang JJ, et al. Retinal vessel diameter and open-angle glaucoma: the Blue Mountains Eye Study. *Ophthalmology.* 2005 Feb;112(2):245-50.

3. Ikram MK, de Voogd S, Wolfs RC, et al. Retinal vessel diameters and incident open-angle glaucoma and optic disc changes: the Rotterdam study. *Invest Ophthalmol Vis Sci.* 2005 Apr;46(4):1182-7.

4. Kawasaki R, Wang JJ, Rochtchina E, et al. Retinal vessel caliber is associated with the 10-year incidence of glaucoma: the Blue Mountains Eye Study. *Ophthalmology.* 2013 Jan;120(1):84-90.

# Half Way There

This patient presented with evidence of two conditions. One largely resolved on its own. The other still requires treatment—but which treatment? **By Mark T. Dunbar, OD**

A 63-year-old Hispanic female presented with a chief complaint of decreased visual acuity in her left eye that had persisted for nearly a year. She began having trouble reading and noted that the vision in her left eye was blurry.

She reported that her acuity had been much worse when she first noticed the problem, but slowly improved to the current level. Her medical history was significant for hypertension, for which she was properly medicated.

Her best-corrected visual acuity measured 20/20 OD and 20/70 OS. Confrontation fields were full to careful finger counting OU. The pupils were equally round and reactive to light, without evidence of afferent defect. The anterior segment examination was un-

remarkable OU.

Dilated fundus exam showed small cups with good rim coloration and perfusion OU. The macula, vessels and peripheral retina in the right eye were normal (*figure 1*). However, we documented retinal changes in the left eye (*figure 2*). We also obtained a spectral domain optical coherence tomography (SD-OCT) scan of the left eye (*figure 3*).

## Take the Retina Quiz

- Based on the clinical appearance, what is your diagnosis?
  - Macular telangiectasia.
  - Retinal vein occlusion (RVO).
  - Valsalva retinopathy.
  - Ocular ischemic syndrome.
- What does the SD-OCT scan reveal?
  - Normal macula.

- Vitreomacular traction (VMT) syndrome.
- Serous retinal detachment.
- Cystoid macular edema (CME).

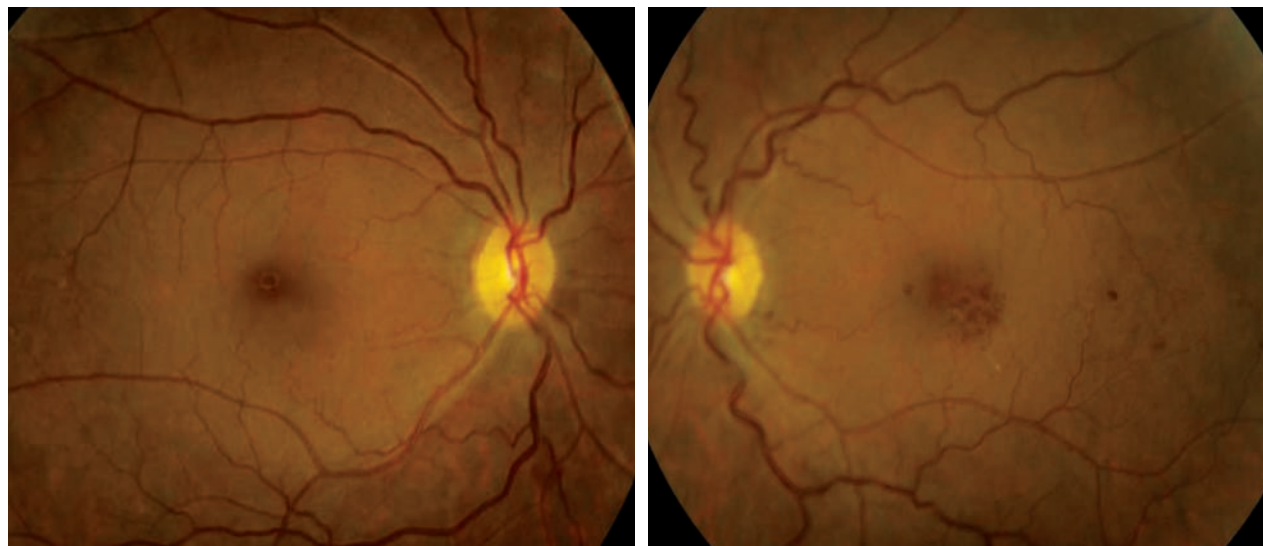
3. What additional testing might provide the most useful information?

- Visual fields.
- Fluorescein angiogram.
- Blood pressure.
- Carotid artery evaluation.

4. How would you manage this patient?

- Laser photocoagulation.
- Intravitreal anti-VEGF injection.
- Observation.
- Endarterectomy.

*For answers, go to page 114.*



**1, 2. Fundus images of our patient (OD left, OS right). Note the retinal hemorrhages located around the left macula.**



## Discussion

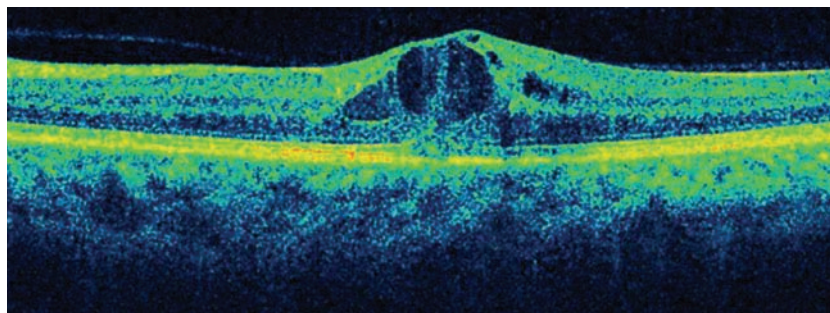
We detected focal areas of intraretinal hemorrhages located around the macula of her left eye, which seem to be more localized infero-temporally. On clinical exam, we noted the presence of CME and a large, centralized cyst in her fovea. This finding was confirmed on the SD-OCT scan.

So, why does she have CME in her left eye? It's not blatantly obvious, but there are several clues. The caliber of the retinal vessels may be one important indicator. In the right eye, she has normal retinal vessels, with an artery-to-vein (A/V) ratio of about three-to-four (3/4). In the left eye, however, the veins appear more dilated and tortuous, with an A/V ratio more like 3/5. This difference suggests that the CME is vascular in origin.

Two additional clues include the presence of a large blot hemorrhage located temporally in the left eye, and the evidence of subtle microvascular changes seen on clinical examination.

Given this information, we concluded that our patient likely had a nonischemic RVO in her left eye. It's difficult to determine if this was a branch or a central retinal vein occlusion (CRVO); however, considering the dilated and tortuous retinal veins, we assumed that this was a largely resolved CRVO. Nonetheless, the associated intraretinal hemorrhages and increased vascular permeability around the macula catalyzed the development of CME.

So, how should we manage this patient? Until the last five to 10 years, laser photocoagulation was considered the standard of care for macular edema associated with RVO.<sup>1</sup> While laser treatment improves macular edema on fluorescein angiography, signifi-



3. SD-OCT image through the macula of her left eye.

cant visual improvement is rarely achieved.<sup>1</sup> Fortunately, more effective treatments have emerged.

In the early 2000s, intravitreal Kenalog (triamcinolone, Bristol-Myers Squibb) became a popular and successful treatment for CME associated with RVO.<sup>2</sup> Despite its efficacy, many clinicians became concerned with the side effects of Kenalog injection, including IOP spikes and cataract development.

More recently, anti-VEGF agents emerged as a good—if not better—treatment option, without the side effects of steroids. In June 2010, Lucentis (ranibizumab, Genentech/Roche) became the first agent to receive FDA approval for the treatment of macular edema secondary to RVO.

Then, in September 2012, the latest anti-VEGF agent, Eylea (aflibercept, Regeneron Pharmaceuticals), was approved for the treatment of macular edema associated with CRVO (*see “Eylea Snares Second Approval,” December 2012*).

Additionally, most retinal specialists prefer to use off-label intravitreal Avastin (bevacizumab, Genentech/Roche), because of its significantly lower price tag.

In several clinical trials, Lucentis, Eylea and Avastin have each shown good results in the treatment of macular edema secondary to RVO due to their unique ability to decrease capillary permeability.<sup>3-8</sup>

We sent our patient to a retina specialist for an opinion on the most appropriate treatment option. At that visit, the patient received an intravitreal Avastin injection and was asked to return for follow-up in one month.

At the one-month follow-up, she demonstrated visual improvement. But, because complete CME resolution was not achieved, she received a second Avastin injection. We will continue to monitor her for signs of improvement. ■

1. The Central Vein Occlusion Study Group M report. Evaluation of grid pattern photocoagulation for macular edema in central vein occlusion. *Ophthalmology*. 1995 Oct;102(10):1425-33.
2. Park CH, Jaffe GJ, Fekrat S. Intravitreal triamcinolone acetate in eyes with cystoid macular edema associated with central retinal vein occlusion. *Am J Ophthalmol*. 2003 Sep;136(3):419-25.
3. Varma R, Bressler NM, Suner I, et al. Improved vision-related function after ranibizumab for macular edema after retinal vein occlusion: Results from the BRAVO and CRUISE trials. *Ophthalmology*. 2012 Oct;119(10):2108-18.
4. Campochiaro PA. Safety and efficacy of intravitreal ranibizumab (Lucentis) in patients with macular edema secondary to branch retinal vein occlusion: The BRAVO Study. Paper presented at: Retina Congress 2009. October 4, 2009; New York.
5. Brown DM. Safety and efficacy of intravitreal ranibizumab (Lucentis) in patients with macular edema secondary to central retinal vein occlusion: The CRUISE Study. Paper presented at: Retina Congress 2009. October 4, 2009; New York.
6. Boyer D, Heier J, Brown DM. Vascular endothelial growth factor Trap-Eye for macular edema secondary to central retinal vein occlusion: six-month results of the phase 3 COPERNICUS study. *Ophthalmology*. 2012 May;119(5):1024-32.
7. A randomized, double-masked, sham-controlled Phase 3 study of the efficacy, safety and tolerability of repeated intravitreal administration of VEGF Trap-Eye in subjects with macular edema secondary to central retinal vein occlusion (CRVO). Clinical trial identifier: NCT01012973. Available at: <http://clinicaltrials.gov/ct2/show/NCT01012973?term=edema+trap-eye&rank=7>. Accessed January 16, 2013.
8. Epstein DL, Algvere PV, von Wendt G, et al. Bevacizumab for macular edema in central retinal vein occlusion: a prospective, randomized, double-masked clinical study. *Ophthalmology*. 2012 Jun;119(6):1184-9.

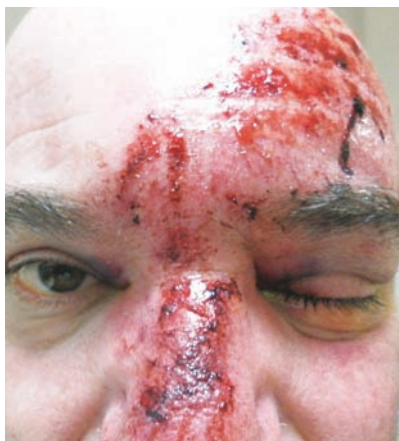# A Big Bag of Hot Air

Vehicle airbag systems save lives. However, severe ocular insult is one potential casualty of their deployment. **By Alan G. Kabat, OD, and Joseph W. Sowka, OD**

**H**opefully, none of us will ever need to rely on our vehicle's airbag system. Driving can be a hazardous activity, but airbags have become a crucial element for improving driver and passenger safety on our roadways. First mandated in 1984, it is estimated that tens of thousands of American lives have been saved by these devices over the last 30 years. In 2010 alone, an estimated 2,306 deaths were averted because of frontal airbags.<sup>1</sup>

Yet, despite their life-saving potential, airbag systems have the capacity to induce significant collateral damage. Consider the mechanism of airbag deployment: In order to facilitate device inflation, a solid propellant (sodium azide) is ignited by an electrical charge and converted to rapidly expanding hydrocarbon gases, filling the woven nylon "cushion" within 50 milliseconds of impact.<sup>2</sup> Essentially, the deployment system is similar to the pyrotechnic bursts used at sporting events and rock concerts, but in a much smaller, more confined area. Hence, drivers and passengers encountering such a situation may experience at least three unique types of injury.

Obviously, the first is blunt force trauma. As the airbag explodes at speeds approaching 150mph, the victim simultaneously is driven forward into the device. The resulting facial or ocular trauma can yield damage comparatively similar to that caused by a fist or a baseball.<sup>3</sup> The second form of trauma involves laceration or penetrating injury.



**This patient sought care in our clinical center after sustaining blunt facial trauma and chemical burns following vehicular airbag deployment.**

This occurs when an object in close proximity to the victim's face—such as a pair of spectacles—is thrust forward and perforates the tissue. Finally, the explosive nature of the deployment system itself creates the potential for both thermal and chemical burns to the face and eyes.<sup>3,4</sup>

As primary eye care providers, optometrists may well be the first individuals to encounter ocular injury associated with motor vehicle accidents (MVA), including those secondary to airbag deployment.

## Examine the Patient

When MVA patients first present, it is important to assess the situation grossly by inspecting the individual's general appearance. Address several pertinent questions: Is there swelling or bruising to the periorbital area? Is there a wound indicative of

penetrating injury? Is there evidence of a burn injury to the skin?

Then, carefully examine the ocular posture as well as the plane of the globes. Does one eye appear to be lower than the other, or sunken into the orbit? Is there diplopia? These signs could be suggestive of a blowout fracture, which requires radiologic imaging and possibly surgical repair. Palpation of the orbital rim may further reveal a step-down fracture, crepitus or localized paresthesia due to trigeminal nerve damage.

Next, examine the eyes themselves. Often, they may be partially or completely swollen shut due to edema and ecchymosis. If the patient resists you holding his or her eye open because of sensitivity, ask him or her to open the eye for you. Evaluate the damage to the anterior segment and obtain visual acuity, including corrected or pinhole acuity. This is crucially important, particularly for medicolegal purposes. Be aware that the patient eventually may be involved in a personal injury lawsuit. Establishing initial acuity after any sort of trauma not only sets the stage for recovery and realistic expectations, but also documents where a patient's clinical journey has begun.

Also, be sure to check ocular motility. But, don't be too concerned if the patient initially is diplopic or shows a generalized restriction of movement in the involved eye. Post-traumatic swelling of the orbital contents can hinder ocular motility to some degree;





### The Danger of Chemical Burns

One of the most crucial management considerations in dealing with airbag injuries is addressing associated ocular and facial burns. Hot gases can escape from deployed airbags, as can the particulate contents of the airbag itself (e.g., sodium hydroxide, sodium carbonate and other metallic oxides), which can lead to alkali injuries of the ocular and periocular tissue. Administer copious irrigation for thermal and chemical burns. Liberally rinse the area with saline for a minimum of 15 minutes with at least one liter of solution.<sup>6</sup> Also, test with pH paper to ensure neutrality in cases of chemical injury.

Carefully debride any loose, necrotic tissue from the lids or ocular surface that would serve to delay healing. This is best performed using a cotton-tipped applicator, spatula or spud. Sweep the conjunctival fornices to ensure that there is no residual particulate matter located in the superior or inferior cul-de-sac.

Treat periocular skin lesions by cleaning the area thoroughly with an antiseptic solution (e.g., povidone-iodine 10%) and applying a prophylactic antibiotic ointment, such as bacitracin 500 U/g QID. For more severe burns, silver sulfadiazine 1% cream is more appropriate and may be better tolerated. For patients who exhibit significant pain, consider the use of prescription narcotic analgesic agents,

such as hydrocodone/acetaminophen 5mg/300mg q4h for the first 24 to 48 hours.

Alkali injuries carry a guarded prognosis. These solutions saponify the fatty units of the cornea and other ocular tissues, thereby destroying the cell structure—not only of the epithelium, but also of the underlying stroma. While acids create an initial burn and then stabilize, alkalis may continue to penetrate into the eye long after the initial trauma.

Treat chemical burns to the cornea intuitively. Employ a strong cycloplegic agent (e.g., 0.25% scopolamine BID) and a broad-spectrum antibiotic (e.g., 0.5% moxifloxacin TID) for prophylaxis. Treat concurrent uveitis with a topical corticosteroid, used judiciously during the first week following trauma (e.g., 0.05% difluprednate QID or 1% prednisolone acetate q2h). Be aware, however, that prolonged steroid use (>10 days) in cases of alkali injury raises the possibility of a corneal melt.<sup>7</sup> Chemical ocular burns need to be monitored daily as the cornea re-epithelializes, as well as periodically thereafter for potential IOP elevation. Severe burns that fail to respond to conventional therapy may warrant consideration for amniotic membrane transplantation.<sup>8</sup>

## Connect With Patients... on their terms with the EyeDocApp!

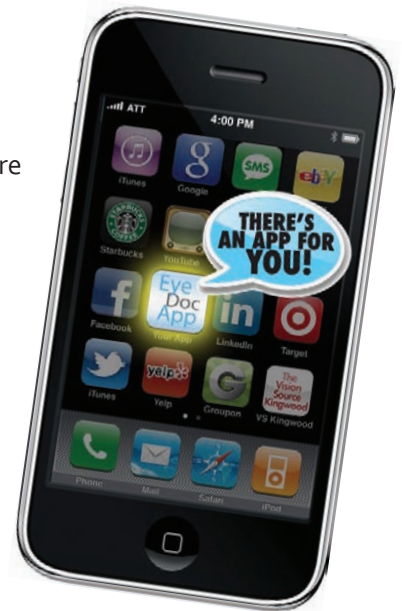EyeDocApp is the first customized mobile application designed specifically for eye care professionals. Now, your patients can instantly schedule appointments, share their experiences with others via Facebook and Twitter, access unique offers and updates about your practice, and much more!

EyeDocApp is an innovative and affordable way for eye care professionals to impact core business metrics such as:

- Higher Patient Retention
- Attracting New Patients
- Increasing Office Traffic

For a low monthly cost and one time set-up fee, your customized EyeDocApp bridges the communication gap between annual patient visits and adds that 'wow' factor to your business!

Visit [EyeDocApp.com](http://EyeDocApp.com) to Order Today!



Marketed exclusively by:



EyeDocApp

## Therapeutic Review

however, this often resolves completely within a week or so. Look for specific motility deficits, such as an inability to elevate, depress, adduct or abduct the eye. This can be an indication of nerve damage or, more likely, muscle entrapment.

Slit lamp evaluation and funduscopy also are crucial in any case of ocular trauma. Some of the more common disorders associated with airbag injury include eyelid laceration, corneal abrasion, uveitis, hyphema, angle recession and lens dislocation. Damage to the posterior segment can result in vitreous or retinal hemorrhage, commotio retinae, retinal tear or detachment, and macular hole formation.<sup>5</sup>

Further, while uncommon, global rupture or scleral or corneal perforation can result from airbag injuries. Be certain that the globe is

not compromised before attempting any manipulation of the eye. Ensure that the anterior chamber is formed, and that there is no fluid leakage or uveal tissue exposure.

Once the integrity of the eye has been established, perform a systematic evaluation of the ocular structures from front to back. And, always dilate the pupil unless a contraindication is observed (e.g., a dislocated lens). Tonometry should be performed if the globe is intact, but gonioscopy to rule out angle recession typically is not conducted until evidence of healing has been documented at a subsequent visit.

Ocular injury can be caused by a host of sources. Ironically, one of the greatest innovations designed to limit the severity of bodily harm—the vehicle airbag—represents a

great potential hazard to ocular health. Being able to understand, recognize and promptly address the sequelae of airbag-related ocular injuries is essential for the comprehensive or medically oriented optometrist. ■

1. Traffic Safety Facts: 2010 Data. National Highway Traffic Safety Administration. Available at: [www-nrd.nhtsa.dot.gov/Pubs/811619.pdf](http://www-nrd.nhtsa.dot.gov/Pubs/811619.pdf). Accessed January 17, 2013.
2. Barnes SS, Wong W Jr, Affeldt JC. A case of severe airbag related ocular alkali injury. *Hawaii J Med Public Health*. 2012 Aug;71(8):229-31.
3. Kenney KS, Fanciullo LM. Automobile air bags: friend or foe? A case of air bag-associated ocular trauma and a related literature review. *Optometry*. 2005 Jul;76(7):382-6.
4. Lehto KS, Sulander PO, Tervo TM. Do motor vehicle airbags increase risk of ocular injuries in adults? *Ophthalmology*. 2003 Jun;110(6):1082-8.
5. Ball DC, Bouchard CS. Ocular morbidity associated with airbag deployment: a report of seven cases and a review of the literature. *Cornea*. 2001 Mar;20(2):159-63.
6. Rihawi S, Frenzt M, Schrage NF. Emergency treatment of eye burns: which rinsing solution should we choose? *Graefes Arch Clin Exp Ophthalmol*. 2006 Jul;244(7):845-54.
7. Davis AR, Ali QK. Topical steroid use in the treatment of ocular alkali burns. *Br J Ophthalmol*. 1997 Sep;81(9):732-4.
8. Clare G, Suleman H, Bunce C, Dua H. Amniotic membrane transplantation for acute ocular burns. *Cochrane Database Syst Rev*. 2012 Sep 12;9:CD009379.

# Powerful Hiring Made Simple.



Post your Eye Care Job on  
**LocalEyeSite.com**  
and experience effective hiring  
through the **LES Power Network**



# REVIEW<sup>®</sup> OF OPTOMETRY

**Introduces a New  
Exclusive Service for  
Eye-Care Professionals**



## Eyecare Resources Online

This **service** allows you to capture needed measures for two meaningful use objectives:

- 1) *electronic transmission of patient prescriptions*
- 2) *distribution of patient-specific education materials*

ECP Resources and ePrescribing from *Review of Optometry* and Healthcare Resources Online enable you to provide patient education, electronic prescribing and generate reports that allow you to attest for meaningful use incentives; however, determination of your bonus payments from CMS depends on other factors and qualifications specific to your practice.

**For More Information, Visit Our OD E-Prescribing Resources Website Page:**

**[www.revoptom.com/ecp\\_resources\\_erx/](http://www.revoptom.com/ecp_resources_erx/)**



*Download a QR scanner app.  
Launch app and hold your mobile  
device over the code and get ready  
to view our website.*

# Color Me Curious

Did you know that color vision testing has the potential not only to uncover optic neuropathy, but also glaucoma? **By Paul M. Karpecki, OD, and Diana L. Shechtman, OD**

**F**or years, color testing was used to determine the presence of various color vision deficiencies (CVDs). But, in the future—as technology improves and subtle anatomic changes become increasingly more measurable—color vision testing could be employed to help detect potential glaucoma and retinal disease.

## Color Vision Testing

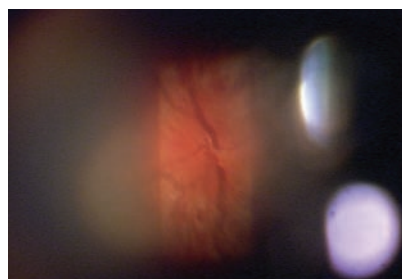
Traditionally, Ishihara color testing was the most commonly used metric in the evaluation of color perception. Dr. Shinobu Ishihara at the University of Tokyo first designed the test in 1917. Ishihara testing includes the use of color plates with various dots to determine the presence and type of CVD.

In addition to Ishihara plates, there are several other useful CVD tests. Hardy-Rand-Rittler plates can be helpful in uncovering tritan deficiencies associated with macular pathologies. The Farnsworth arrangement test may assist in the assessment of acquired CVD. Finally the Nagel anomaloscope may help to more specifically diagnose and grade color vision anomalies.

Unfortunately, most of these CVD tests are subject to operator error, including lighting differences, plate fading, inability to grade condition severity and poor reproducibility.<sup>1</sup>

## Congenital and Acquired CVDs

Because genetic CVDs typically are caused by X-linked mutations, men are much more likely to have color vision anomalies than women.<sup>2</sup> Men



**This patient presented with reduced color vision caused by optic nerve damage secondary to papilledema.**

only have one X chromosome (XY), while women have two (XX). So, in females, a mutation on one X chromosome can be overridden by the other normal X chromosome.<sup>3</sup>

Color vision anomalies are surprisingly common, with green deficiency (deuteranopia) affecting approximately 8% of the male population with Northern European ancestry.<sup>4</sup> Another form of color deficiency is protanopia, which affects only 1% of US males.<sup>2,3</sup> In protanopia, the red retinal receptors are weak or absent, which causes all red colors to appear black. Tritanopia, an even rarer form of CVD, is defined as the absence or deficiency of blue retinal receptors.<sup>3</sup> This is the only form of CVD that isn't X-linked, but rather is related to a pigment gene mutation located on chromosome 7.<sup>3</sup>

The primary difference between congenital and acquired CVDs is that genetic deficiencies present bilaterally at birth. Acquired CVDs, on the other hand, can be unilateral, asymmetric or even transient. Furthermore, the prevalence of acquired CVD is nearly equal between males

and females.<sup>5</sup> It is interesting to note that most genetic CVDs often are deutan or protan in nature, but acquired CVDs typically are tritan.

## Not Just for CVD Detection

Color vision testing actually may help eye care providers uncover a host of other conditions, including glaucoma, optic neuropathy and Duchenne muscular dystrophy.

Researchers have estimated that as many as 30% to 50% of patients with primary open-angle glaucoma (POAG) have tritan deficiencies, 20% to 30% have general loss of color discrimination and 5% have deuteran deficiencies.<sup>6</sup> One study indicated that loss of color hue perception is much higher in patients with glaucoma, even when adjusting for an aging retina or lenticular changes.<sup>6</sup> In addition to POAG, patients with acute angle-closure glaucoma are more likely to exhibit tritan deficiencies than those with no history of glaucoma.<sup>6</sup>

Other ocular conditions that affect color vision testing include Leber's congenital optic neuropathy, arteritic anterior ischemic optic neuropathy and nonarteritic anterior ischemic optic neuropathy.<sup>7-9</sup> Further, patients with optic neuritis typically experience reduced color vision (particularly red desaturation) in the affected eye.<sup>10-12</sup>

Even the diagnosis of certain systemic diseases can be guided by color vision testing. For example, 66% of all patients with Duchenne muscular dystrophy exhibit red-green color deficiencies.<sup>13</sup>



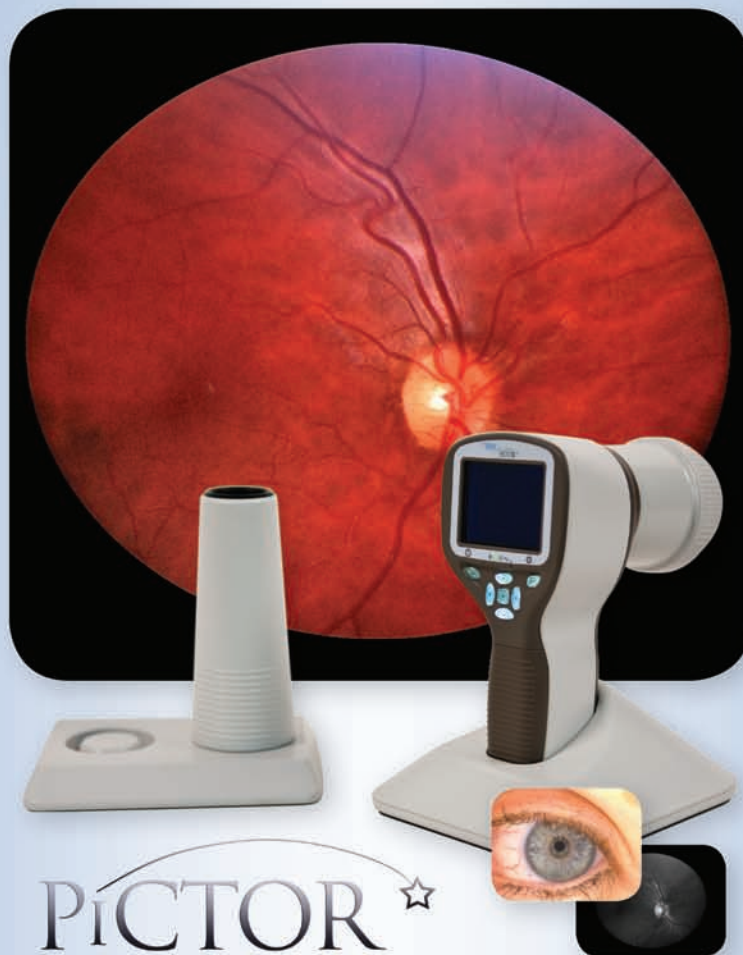Keep in mind that color testing results can be affected by more than a dozen medications, including digoxin, ethambutol, clioquinol, isoniazid, amiodarone, linezolid, methotrexate, sildenafil, oxymetazoline, infliximab, cisplatin or tamoxifen.<sup>14-17</sup> So, be sure to question patients about prescription drug use prior to color vision testing.

Color vision testing has an important place in primary-care disease diagnosis. When using color testing to screen for potential optic nerve or retinal disease, it is essential to test pupillary function, visual acuity and visual fields as well. Once a full assessment is made, you may determine the most appropriate management strategy. ■

1. Hovis JK, Ramaswamy S. The effect of test distance on the CN lantern results. *Vis Neurosci*. 2006 May-Aug;23(3-4):675-9.
2. Deeb SS. Molecular genetics of color vision deficiencies. *Clin Exp Optom*. 2004 Jul;87(4-5):224-9.
3. Drummond-Borg M, Deeb S, Motulsky AG, et al. Molecular basis of abnormal red-green color vision: a family with three types of color vision defects. *Am J Hum Genet*. 1988 Nov;43(5):675-83.
4. Albrecht M. Color blindness. *Nat Methods*. 2010 Oct;7(10):775.
5. Pinckers A, Marre M. Basic phenomena in acquired colour vision deficiency. *Doc Ophthalmol*. 1983 May 1;55(3):251-71.
6. Sit AJ, Medeiros FA, Weinreb RN. Short-wavelength automated perimetry can predict glaucomatous standard visual field loss by ten years. *Semin Ophthalmol*. 2004 Sep-Dec;19(3-4):122-4.
7. Jung JJ, Baek SH, Kim US. Analysis of the causes of optic disc swelling. *Korean J Ophthalmol*. 2011 Feb;25(1):33-6.
8. Luneau K, Newman NJ, Biouesse V. Ischemic optic neuropathies. *Neurologist*. 2008 Nov;14(6):341-54.
9. Hayreh SS. Anterior ischaemic optic neuropathy. Differentiation of arteritic from non-arteritic type and its management. *Eye (Lond)*. 1990;4(Pt 1):25-41.
10. Hoorbakht H, Bagherkashi F. Optic neuritis, its differential diagnosis and management. *Open Ophthalmol J*. 2012;6:65-72.
11. Katz B. The dyschromatopsia of optic neuritis: a descriptive analysis of data from the optic neuritis treatment trial. *Trans Am Ophthalmol Soc*. 1995;93:685-708.
12. Dooley MC, Foroozan R. Optic neuritis. *J Ophthalmic Vis Res*. 2010 Jul;5(3):182-7.
13. Costa MF, Oliveira AG, Feitosa-Santana C, et al. *Am J Hum Genet*. Red-green color vision impairment in Duchenne muscular dystrophy. 2007 Jun;80(6):1064-75.
14. Novack GD. *Curr Opin Ophthalmol*. Ocular toxicology. 1995 Dec;6(6):108-12.
15. Cordell WH. Retinal effects of 6 months of daily use of tadalafil or sildenafil. *Arch Ophthalmol*. 2009 Apr;127(4):367-73.
16. Ayuso Blanco T, Aliseda D, Ajuría I, et al. Inflammatory optic neuritis. *An Sist Sanit Navar*. 2009 May-Aug;32(2):249-63.
17. Eisner A, Luoh SW. Breast Cancer Medications and Vision: Effects of Treatments for Early-stage Disease *Curr Eye Res*. 2011 Oct;36(10):867-85.

# A Logical Choice

For Versatile, Portable Ophthalmic Imaging



## PICTOR

Versatility: Use for mobile situations, pediatrics or any patient with difficult access

Functionality: Image both the posterior (non-mydratic) and anterior segments with one camera

Economical: Tax incentives and full reimbursement may apply

To Arrange a Trial  
Call (440) 510-0743  
or email [volk@volk.com](mailto:volk@volk.com)



[www.volk.com](http://www.volk.com)

Copyright © 2012 Volk Optical Inc.

# Product Review

## Contact Lenses

### Icuity H<sub>2</sub>O

Hydrogel Vision Corp. has expanded its product line with a new lens and new modality—Icuity H<sub>2</sub>O one-week replacement. This soft contact lens offers patients a more frequent replacement schedule without the cost of a daily disposable lens, the company says.

Made with hioxiflcon A, a non-ionic ultra hydrating material that retains 99% of its water content throughout the wearing time, Icuity H<sub>2</sub>O is designed to keep lens comfort, movement and fit stable throughout the day. This material keeps lenses clear and free of unhealthy protein deposits and features a thin and smoothly contoured edge for improved fit and comfort, the manufacturer says.

Icuity H<sub>2</sub>O is available in a median (8.6) base curve with powers of +6.00 to -10.00 and a steep (8.3) base curve with powers of -0.25 to -10.00.

You can order free diagnostic sets of Icuity H<sub>2</sub>O directly through Hydrogel Vision or through any of its authorized distributors.

Visit [www.hydrogelvision.com](http://www.hydrogelvision.com).

## Optical Display

### Sol Sun Center

The new Sol Sun Center by Eye Designs allows you to create a designated selling area for sunwear within your optical. This stylish, modern display unit show-



cases sunwear, cases and point of purchase materials. Patients understand exactly where to browse and shop for sunwear, which allows them to make decisions quicker and leads to a more efficient selling time for the optical staff and the patient, the company says.

Featuring backlit illumination with LED lighting, the three columns of frosted adjustable shelves, plus the

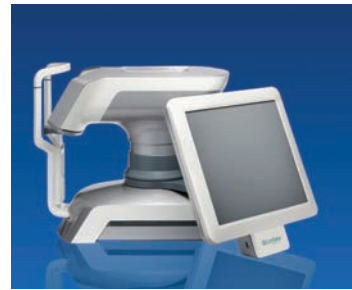panel of Wave frame holders, display a total of 92 frames. The Sol Sun Center can be made to match any existing Eye Designs furniture collection or it can be incorporated into any optical interior.

Visit [www.eyedesigns.com](http://www.eyedesigns.com).

## Dry Eye Measurement

### Lipiview Ocular Surface Interferometer

By granting clearance to Lipiview's second generation software, the FDA also approved additional features and broadened the indication for use of the TearScience's Lipiview ocular surface interferometer.



TearScience can now claim Lipiview measures the absolute thickness of the tear film lipid layer in nanometers.

By identifying lipid layer deficiency (the most common cause of dry eye), physicians can use Lipi-

view as part of a full dry eye assessment to determine which type of dry eye a patient has, the company says.

The upgraded Lipiview software also assesses a patient's blinking process during examination, which enables physicians to identify patients who are partial blinkers—a condition that may limit lipid production and impact the ocular surface.

Lipiview v2.0 software will be available to all new customers, and current customers will be upgraded by the second quarter of 2013.

Visit [www.tearscience.com](http://www.tearscience.com).

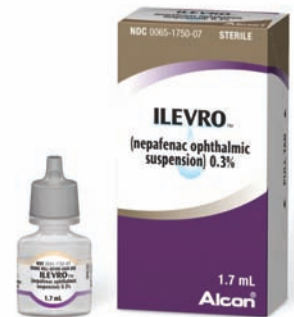## NSAID Ophthalmic Drop

### Ilevro Suspension

Alcon launched Ilevro (nepafenac 0.3% ophthalmic suspension), a new once-daily treatment option for pain and inflammation associated with cataract surgery. In two double-masked, randomized clinical trials, this nonsteroidal, anti-inflammatory prodrug demonstrated superior clinical efficacy compared to its vehicle, Alcon says.

In the studies, patients treated with Ilevro were less likely to have ocular signs of inflammation (cells and flare) at the end of treatment than those treated with its vehicle.

Visit [www.alcon.com](http://www.alcon.com) for full prescribing info. ■





VM <sup>global</sup> leadership  
**SUMMIT**  
2013



**imagination**  **invention**  
SUCCEEDING IN A CULTURE OF CHANGE

## PROGRAM

### Tapping Imagination and Creativity

- ▶ **FRANK MOSS**, Director of New Media Medicine group at MIT Media Lab

### EYE2 Vision Technology to the Next Power

- ▶ **AMI DROR**, Co-Founder and Chief Strategy Officer, XPand
- ▶ **KEVIN RANKIN**, CEO, eSight Corp.
- ▶ **KEITH P. THOMPSON**, MD, CEO, Digital Vision Systems

### New Healthcare Influencers

- ▶ **ANNEMARIE HAGAN**, President and General Manager, Specialty, WellPoint

### Omni-channel Retailing On the Rise

### Imagination and Creativity

- ▶ KEYNOTE SPEAKER: **ROBERT SAFIAN**, Editor, Fast Company

MORE SPEAKERS TO BE ANNOUNCED...

---

March 13, 2013  
**The Times Center**  
242 W. 41st Street  
New York, NY 10036

**REGISTRATION: \$395**

Registration includes full day conference,  
continental breakfast and lunch.

**adlens**  
Variable Focus Eyewear | A Different Way To See The World

  
**essilor**  
Seeing the world better

**LUXOTTICA**

  
**vsp global**  
SHARING YOUR VISION

**Alcon**

 **CareCredit**  
Making care possible...today.

**DAC**  
VISION

  
INTERNATIONAL  
**VISION EXPO**  
& CONFERENCE  
NEW YORK

**For Full Program Information or to Register Visit: [visionmonday.com/summit](http://visionmonday.com/summit)**

**14 CE Credits**  
(COPE approval pending)

Register by April 23, 2013 to receive \$100 OFF Registration Fee!

# June 13-16 Maui 2013

... a meeting of clinical excellence  
Wailea Beach Marriott Resort & Spa

[www.revoptom.com/Maui2013](http://www.revoptom.com/Maui2013)

## Faculty



Paul Karpecki, OD (Chair)



Marc Bloomenstein, OD



Diana Shechtman, OD



Robert Wooldridge, OD

## Course Topics

- Posterior Segment/Retina Disease Diagnosis and Management
- Anterior Segment/Glaucoma Diagnosis and Treatment
- Technological Innovations in Eye Care
- Advances in Contact Lenses
- Ocular Manifestations of Systemic Disease Including Diabetes
- Ocular Surface Disease Diagnosis and Treatment



  
**REVIEW**  
OF OPTOMETRY

For more information or to register, contact Lois DiDomenico  
at 866-658-1772 or [ReviewMeetings@Jobson.com](mailto:ReviewMeetings@Jobson.com).



# Wailea Beach Marriott Resort & Spa

## June 13-16, 2013

**14 COPE-Approved CE Credits**  
(COPE approval pending)

### 4 Ways to Register

Online: [www.revoptom.com/Maui2013](http://www.revoptom.com/Maui2013)

Mail: Review of Optometry Conferences  
11 Campus Blvd, Ste. 100  
Newtown Square, PA 19073

Fax: 610-492-1039

Phone: 866-658-1772

#### HOTEL INFORMATION

**Discounted Room Rate:**  
Standard View \$279/night  
Ocean View \$299/night

**For reservations, call: 877-622-3140**

Discounted room rates available pre- and post-conference based on hotel availability

Discounted Room Rates Limited!

**Mention *Review of Optometry* for Group Rate!**

## Registration Information

Name _____		License # (License numbers are now required for HCP reporting and will only be used for this purpose.) _____	
Practice Affiliation _____			
Mailing Address _____	City _____	State _____	Zip Code _____
Telephone _____	Fax _____	Email _____	

## Name Badge Information (please print clearly)

My Name _____	My Guest _____	Additional Guests _____
---------------	----------------	-------------------------

## Payment Information

OD Registration - \$595 **(\$100 OFF by April 23, 2013)**  
(includes 14 hours of CE, breakfasts, receptions)

*Call for daily rates.*

Additional Guest(s) - \$95 (12 years and older, includes receptions)

Optional Activity: Glass Bottom Boat Catamaran Sail & Snorkel  
Saturday, June 15 - \$85 (includes lunch)

Check enclosed (make checks payable to *Review of Optometry*)

Charge my:  American Express  Mastercard  Visa

Credit Card Number _____	Exp Date _____
Cardholder (print name) _____	
Signature _____	

	Rate per person	No. in party	Subtotal
OD Registration	\$595	x _____	= \$ _____
Additional Guest(s)	\$95	x _____	= \$ _____
Optional Activity	\$85	x _____	= \$ _____
		TOTAL	= \$ _____

#### CONFERENCE CANCELLATION POLICY

- Full refund on registration fee until May 24, 2013
- 50% refund on registration fee until June 7, 2013
- No refund past June 7, 2013

For more information or to register, contact Lois DiDomenico at 866-658-1772 or [ReviewMeetings@Jobson.com](mailto:ReviewMeetings@Jobson.com).



## February 2013

■ **27-March 3.** *SECO International 2013.* Building A, Georgia World Congress Center, Atlanta. CE hours: 300+. Contact Bonny Fripp at [bfripp@secostaff.com](mailto:bfripp@secostaff.com) or (770) 451-8206, ext. 13. Visit [www.seco2013.com](http://www.seco2013.com).

■ **28-March 2.** *MOA Big Sky Conference.* Huntley Lodge, Big Sky Conference Center, Big Sky, Mont. Hosted by: Montana Optometric Association. Contact Executive Director Sue Weingartner at [sweingartner@rmsmanagement.com](mailto:sweingartner@rmsmanagement.com) or (406) 443-1160. Visit [www.mteyes.com](http://www.mteyes.com).

## March 2013

■ **3-4.** *COVD at SECO 2013.* Time: 8 a.m. - 5 p.m. OMNI Hotel at CNN Center, Atlanta. Hosted by: College of Optometrists in Vision Development. Featured speakers: Carl G. Hillier, OD, FCOVD, W.C. Maples, OD, FCOVD, and Ashley Reddell, OD, FCOVD. Visit [www.covd.org](http://www.covd.org). \*Registration is separate from SECO 2013.

■ **3-8.** *27th Annual Eye Ski Conference.* The Lodge at Mountain Village, Park City, Utah. CE hours: 20. Contact Tim Kime, OD, at [tandbkime@buckeye-express.com](mailto:tandbkime@buckeye-express.com). Visit [www.eyeskiutah.com](http://www.eyeskiutah.com).

■ **10.** *6th Annual Evidence Based Care in Optometry Conference.* BWI Marriott, Linthicum Heights, Md. Hosted by: Maryland Optometric Association and the Wilmer Eye Institute. Email [moa@assnhqtrs.com](mailto:moa@assnhqtrs.com) or call (410) 727-7800. Visit [www.marylandeyes.com](http://www.marylandeyes.com).

■ **14-17.** *International Vision Expo & Conference East 2013.* Jacob K. Javits Convention Center, New York, NY. CE hours: 350. Visit [www.visionexpoeast.com](http://www.visionexpoeast.com).

■ **16-17.** *7th Annual Conference on Comprehensive Eye Care.* The Sheraton Hotel, Niagara Falls, NY. Hosted by: PSS EyeCare. Featured speakers: Ron Melton, OD, Randall Thomas, OD, Paul Karpecki, OD, and Deepak Gupta, OD. CE hours: 18. Email [education@psseyecare.com](mailto:education@psseyecare.com) or call (203) 415-3087. Visit [www.psseyecare.com](http://www.psseyecare.com).

■ **24.** *"Practicing Full Scope Primary Care Optometry: 2013 and Beyond."* Tinley Park Convention Center, Tinley Park, Ill. Hosted by: Illinois Optometric Association. Featured speaker: Pamela Lowe, OD. Email [joa@ioaweb.org](mailto:joa@ioaweb.org) or visit [www.psseyecare.com](http://www.psseyecare.com).

## April 2013

■ **12.** *American Conference on Pediatric Cortical Visual Impairment.* Time: 7:30 a.m. - 5:00 p.m. Children's Hospital & Medical Center, Omaha, Nebr. Contact CME Coordinator Sara M. Olsen, MEd, at [solsen@childrensomaha.org](mailto:solsen@childrensomaha.org) or (402) 955-6070.

■ **12-13.** *OAOP Annual Spring Congress 2013.* Embassy Suites & Conference Center, Norman, Okla. Hosted by: Oklahoma Association of Optometric Physicians. Visit [www.aoop.org](http://www.aoop.org).

■ **12-14.** *American Optometric Society 4th Annual Meeting & CE Seminar.* Westin Riverwalk Hotel, San Antonio, Texas. Hosted by: American Optometric Society. CE hours: 12. Email [janis@optometricsociety.org](mailto:janis@optometricsociety.org) or visit [www.optometricsociety.org](http://www.optometricsociety.org).

■ **13-14.** *5th Annual Symposium on Ocular Disease.* Crowne Plaza, Tyson's Corner, Va. Hosted by: PSS EyeCare. Featured speakers: Deepak Gupta, OD, and Kimberly Reed, OD. CE hours: 18. Email [education@psseyecare.com](mailto:education@psseyecare.com) or call (203) 415-3087. Visit [www.psseyecare.com](http://www.psseyecare.com).

■ **13-14.** *Nutrition and the Eye VI.* JCPenney Conference Center, North Campus, University of Missouri–St. Louis. Hosted by: Ocular Nutrition Society and UMSL School of Optometry. CE hours: 12. Call Jennifer Clemente at (314) 516-5994 or visit [www.umsl.edu/divisions/optometry/Continuing Education/Nutrition2013.html](http://www.umsl.edu/divisions/optometry/Continuing%20Education/Nutrition2013.html).

■ **19-20.** *Educational Meeting 2013.* Mission Inn, Howey-in-the-Hills, Fla. Hosted by: the Florida Chapter of the American Academy of Optometry. Featured speakers: Carlo Pelino, OD, Albert Woods, OD, and John McClane, OD. CE hours: 10. Contact Arthur T. Young, OD, at [eyeguy4123@msn.com](mailto:eyeguy4123@msn.com) or (239) 542-4627.

■ **19-21.** *WFOA Spring Seminar 2013.* Hilton Sandestin Beach Golf Resort & Spa, Destin, Fla. Hosted by: West Florida Optometric Association. Contact Jennifer Major, OD, at [wfoatreasurer@gmail.com](mailto:wfoatreasurer@gmail.com). Visit [www.wfoameeting.com](http://www.wfoameeting.com).

■ **20-21.** *21st Annual Suncoast Seminar.* Hyatt Regency Clearwater Beach Resort & Spa, Clearwater, Fla. Hosted by: Pinellas Optometric Association. CE hours: 14 (including medical errors and jurisprudence). Email [ldoc1@aol.com](mailto:ldoc1@aol.com) or call (727) 446-8186.

■ **24-28.** *11th Annual Education Conference.* Hilton Embassy Suites Kingston Plantation, Myrtle Beach, SC. Hosted by: New Jersey Chapter of the American Academy of Optometry. CE hours: 16. Featured speakers: Diana Shechtman, OD, and Carlo Pelino, OD. Contact Dennis H. Lyons, OD, at [dhl2020@aol.com](mailto:dhl2020@aol.com) or (732) 920-0110.

■ **26-28.** *28th Annual Morgan/Sarver Symposium.* DoubleTree Hotel, Berkeley Marina, Berkeley, Calif. Hosted by: University of California, Berkeley, School of Optometry. CE hours: 20. Email [optoCE@berkeley.edu](mailto:optoCE@berkeley.edu) or call (800) 827-2163. Visit <http://optometry.berkeley.edu/ce/morgan-sarver-symposium>.

■ **27-28.** *18th Annual Miami Nice Symposium 2013.* Westin Colonnade Hotel, Coral Gables, Fla. Hosted by: Miami-Dade Optometric Physicians Association. CE hours: 17. Email [mdopa.board@gmail.com](mailto:mdopa.board@gmail.com) or call Dr. Steve Morris at (305) 668-7700. Visit [www.miamieyes.org](http://www.miamieyes.org).

## May 2013

■ **1-4.** *2013 Annual Educational Conference & Exposition.* Hilton Garden Inn, Missoula, Mont. Hosted by: Montana Optometric Association. Contact Executive Director Sue Weingartner at [sweingartner@rmsmanagement.com](mailto:sweingartner@rmsmanagement.com) or (406) 443-1160. Visit [www.mteyes.com](http://www.mteyes.com).

■ **2-4.** *MWCO Annual Congress.* Caesar's Palace, Las Vegas. Hosted by: Mountain West Council of Optometrists. Contact Tracy

# Advertisers Index

Abel, CMP, at [tracyabel@earthlink.net](mailto:tracyabel@earthlink.net) or call (888) 376-6926. Visit [www.mwco.org](http://www.mwco.org).

■ **9-10.** *117th Annual Meeting and Spring Seminar.* DeVos Place, Grand Rapids, Mich. Hosted by: Michigan Optometric Association. Contact Amy Possavino, at [amy@themoa.org](mailto:amy@themoa.org) or call (517) 482-0616. Visit [www.themoa.org](http://www.themoa.org).

■ **17-19.** *2013 AZOA Spring Congress.* Hilton Tuscon El Conquistador Golf & Tennis Resort, Tucson, Ariz. Hosted by: Arizona Optometric Association. Contact Kate Diedrickson, at [kate@azoa.org](mailto:kate@azoa.org) or call (602) 279-0055. Visit [www.azoa.org](http://www.azoa.org).

■ **17-29.** *Nova Southeastern University's 17th Annual Eye Care Conference & Alumni Reunion.* NSU College of Optometry, Fort Lauderdale, Fla. Contact Vanessa McDonald at [oceaa@nova.edu](mailto:oceaa@nova.edu) or visit <http://optometry.nova.edu/ce>.

## June 2013

■ **7-9.** *Ocular Symposium: Pearls in Ocular Diagnosis.* Holiday Inn Golden Gateway, San Francisco. CE hours: 24. Contact Lorraine Geary at [ocularsymp@aol.com](mailto:ocularsymp@aol.com) or call (415) 278-9940.

■ **13-16.** *Maui 2013.* Wailea Beach Marriott Resort & Spa, Maui, Hawaii. Hosted by: *Review of Optometry*. Meeting chair: Paul Karpecki, OD. CE hours: 14. Contact Lois DiDomenico at [ReviewMeetings@Jobson.com](mailto:ReviewMeetings@Jobson.com) or (866) 658-1772. Visit [www.revoptom.com/conferences](http://www.revoptom.com/conferences).

## July 2013

■ **25-28.** *Bermuda 2013.* Fairmont Hamilton Princess, Bermuda. Hosted by: *Review of Optometry*. Meeting chair: Paul Karpecki, OD. CE hours: 14. Contact Lois DiDomenico at [ReviewMeetings@Jobson.com](mailto:ReviewMeetings@Jobson.com) or (866) 658-1772. Visit [www.revoptom.com/conferences](http://www.revoptom.com/conferences).

## August 2013

■ **3-5.** *Annual Educational Retreat 2013.* South Seas Island Resort, Sanibel, Fla. Hosted by: Southwest Florida Optometric Association Inc. CE hours: 14. Contact Brad Middaugh, OD, at [swfoa@att.net](mailto:swfoa@att.net) or (239) 481-7799. Visit [www.swfoa.com](http://www.swfoa.com).

## September 2013

■ **20-22.** *New Technology & Treatments West Coast 2013.* Marriott Del Mar, San Diego. Hosted by: *Review of Optometry*. Contact Lois DiDomenico at [ReviewMeetings@Jobson.com](mailto:ReviewMeetings@Jobson.com) or (866) 658-1772. Visit [www.revoptom.com/conferences](http://www.revoptom.com/conferences). ■

### To list your meeting, contact:

Colleen Mullarkey, Senior Editor

E-mail: [cmullarkey@jobson.com](mailto:cmullarkey@jobson.com)

Phone: (610) 492-1005

<b>Accutome, Inc.</b> .....21 Phone ..... (800) 979-2020 Fax..... (610) 889-3233	<b>Marco Ophthalmic</b> .....10 Phone ..... (800) 874-5274 Fax..... (904) 642-9338
<b>Alcon Laboratories</b> .....15, 27 .....35, 43, 51 A-H, 57, 91, 116 Phone ..... (800) 451-3937 Fax..... (817) 551-4352	<b>Oculus, Inc.</b> .....69 Phone ..... (888) 284-8004 Fax..... (425) 867-1881
<b>Allergan, Inc.</b> .....13, 14 ..... 29, 30, 45, 53, 54 Phone ..... (800) 347-4500	<b>Odyssey Medical</b> .....75 Phone ..... (888) 905-7770 Fax..... (901) 382-2712
<b>Bausch + Lomb</b> .....17, 18 ..... 47, 61, 62 Phone ..... (800) 323-0000 Fax..... (813) 975-7762	<b>Optos North America</b> .....59 Phone .....(877) 455-8855 x 100 Fax..... (508) 486-9310
<b>Brien Holden Vision Institute</b> .....70 ..... info@brienholdenvision.org ..... www.brienholdenvision.org	<b>Reliance Medical</b> .....41 Phone ..... (800) 735-0357 Fax..... (513) 398-0256
<b>Carl Zeiss Meditec Inc.</b> .....65 Phone ..... (877) 486-7473 Fax..... (925) 557-4101	<b>Rhein Medical</b> .....9 Phone ..... (800) 637-4346 Fax..... (727) 341-8123
<b>Eye Designs</b> ..... 23 Phone ..... (800) 346-8890 Fax..... (610) 489-1414	<b>ThromboGenics Inc.</b> .....5 Phone ..... (732) 590-2901 Fax..... (866) 936-6676
<b>Haag-Streit</b> .....25 Phone ..... (800) 627-6286 Fax..... (603) 742-7217	<b>Tomey</b> .....49 Phone ..... (888) 449-4045 .....www.tomeyusa.com
<b>HAI Laboratories</b> .....33 Phone ..... (781) 862-9884 Fax..... (781) 860-7722	<b>Vision Source</b> .....39 Phone ..... (281) 312-1111 Fax..... (281) 312-1153 ..... www.visionsource.com
<b>Keeler Instruments</b> .....7, 115 Phone ..... (800) 523-5620 Fax..... (610) 353-7814	<b>Vistakon</b> .....2, 3 Phone ..... (800) 874-5278 Fax..... (904) 443-1252
<b>Lombart Instruments</b> .....72 Phone ..... (800) 446-8092 Fax..... (757) 855-1232	<b>Vmax Vision, Inc.</b> .....71, 73 Phone ..... (888) 413-7038 .....Info@VmaxVision.com .....www.VmaxVision.com
<b>M&amp;S Technologies</b> .....37 Phone ..... (877) 225-6101 Fax..... (847) 763-9170	<b>Volk Optical, Inc.</b> .....101 Phone ..... (800) 345-8655 Fax..... (440) 942-2257
<b>Macula Risk - The Genetic Test for AMD</b> .....67 Phone ..... (866) 964-5182 Fax..... (866) 964-5184 customerservice@macularisk.com	<i>This advertiser index is published as a convenience and not as part of the advertising contract. Every care will be taken to index correctly. No allowance will be made for errors due to spelling, incorrect page number, or failure to insert.</i>

**Merchandise Offered**

**OPTICAL DISPENSARY  
MAKEOVER  
In Less Than 4 Weeks**

**COMPLETE NEW DISPENSARY for \$49/Month\***  
\* First 6 Months at \$49 through financing. Any Size Dispensary. Call for Details.

**COMPLIMENTARY DISPENSARY DESIGN SERVICE**  
\*free if products are purchased from CNS

[www.framedisplays.com](http://www.framedisplays.com)  
**Call 1-877-274-9300**

**frame displays.com**

**Practice Consulting**

**PRACTICE SALES & APPRAISAL**

Expert Services for:

- ✓ **Buying or Selling a Practice**
- ✓ **Practice Appraisal**
- ✓ **Practice Financing**
- ✓ **Partner Buy-in or Buy-out**

Call for a Free Consultation  
**(800) 416-2055**  
[www.TransitionConsultants.com](http://www.TransitionConsultants.com)

**Continuing Education**

**SCUBA & CE IN THE CARIBBEAN**

**4<sup>TH</sup> ANNUAL CE IN BELIZE  
JULY 1-5, 2013  
SAN PEDRO, AMBERGRIS CAYE  
16 HOURS OF COPE-APPROVED CE**

**WWW.CEINBELIZE.COM**

MEETING SPONSOR: INTERNATIONAL ACADEMY OF OPTOMETRY  
CONTACT DR. EDWARD PAUL  
910-256-6364

**Merchandise Offered**

**www.eyewear4less.com**

**TIRED OF RISING FRAME PRICES?  
MAXIMIZE YOUR PROFIT**

**FRAME BUYERS - VIEW OUR COLLECTIONS**

**BRAND NAME EYEWEAR AT 40 TO 80% OFF LIST PRICE**

**YOUR PRACTICE YOUR PROFITS**

**1-800-294-4127**

**Products and Services**

**ACCESS**   
**HEALTHCARE CAPITAL**

Access Healthcare Capital is your key to practice financing. Specialized loans tailored to meet your professional practice needs. We specialize in the Optometry Field with over 75 years of combined management, ownership, and financing. Let us help you realize your dream!

- 100% Financing plus Working Capital
- Practice Improvements & Equipment
- Practice Acquisitions
- Fixed Rate Terms up to 15 years
- Practice Start Ups
- Flexible Payment Options
- Partnership Buy-In Programs

**www.accesshealthcarecapital.com • info@narxeye.com**

Access Healthcare Capital • 1-888-727-4470 • P.O. Box 349, Gladwyne, PA 19035

**Practice For Sale**



Practice Sales • Appraisals • Consulting  
[www.PracticeConsultants.com](http://www.PracticeConsultants.com)

**PRACTICES FOR SALE  
 NATIONWIDE**

Visit us on the Web or call us to learn more about our company and the practices we have available.  
[info@PracticeConsultants.com](mailto:info@PracticeConsultants.com)  
**800-576-6935**

[www.PracticeConsultants.com](http://www.PracticeConsultants.com)

**Equipment and Supplies**




It's What the Best  
 Pretest on!  
**(800) 522-2275**  
[www.optinomics.com](http://www.optinomics.com)  
[sales@optinomics.com](mailto:sales@optinomics.com)

**SOFTWARE**



**QUIKEYES ONLINE  
 WEB-BASED OPTOMETRY EHR**

- \$99 per month after low cost set-up fee
- Quick Set-Up and Easy to Use
- No Server Needed
- Corporate and Private OD practices
- 14 Day Free Demo Trial
- Users Eligible for 44K incentives

[www.quikeyes.com](http://www.quikeyes.com)



**Merchandise Offered**

Come See Our **NEW REVOLUTIONARY DISPLAY SYSTEM**  
 © VISION EXPO EAST!



**ADD an element to draw in customers**



**ADD an element to connect with customers**





**ADD an element to market to customers**



- Frame Risers
- Merchandising Components
- Decorative Accents & More

**opticaldisplays.com™**

**Equipment and Supplies**

**The Leading Reseller of Premium  
 Preowned Diagnostic Equipment in the U.S.**



**EYE CARE ALLIANCE®**

**800-328-2020**  
[www.eyecarealliance.com](http://www.eyecarealliance.com)



**Repair Services Available!**

**We also buy used equipment  
 Call 1-800-328-2020 for a quote today!**

**SOFTWARE**

Secure Access Anytime  
EHR Certified  
Industry Experts

**Eyecom® EHR**  
WEB-BASED OPTOMETRIC SOFTWARE

2012-2013  
**Drummond**  
>>> certified  
ONC-ATCB  
COMPLETE EHR AMBULATORY

**Web-based Platform  
Certified Complete Exam Module  
Secure & Scalable**

800.788.3356  
www.eyecom3.com

**Equipment and Supplies**

**MAGNETIC SPUDS**  
*Foreign Body  
Remover*

- Saves Time
- Less Tissue Damage
- Strong Magnetic Field
- No Energy Source Needed

**GuldenOphthalmics**  
time saving tools  
800-659-2250 www.guldenophthalmics.com

**Visit our new website search" 16108 or 16109"**

**REVIEW**  
OF OPTOMETRY

**Do you have CE or  
CME Programs?**

CONTACT US TODAY  
FOR CLASSIFIED ADVERTISING  
Toll free: 888-498-1460  
E-mail: sales@kerhgroup.com

**Used & Rebuilt  
Equipment**

www.UsedLabs.com

- Surfacing equipment
- Pattern-less edgers
- Finishing equipment
- AR equipment

Telephone 714-963-8991

**Buy or sell**

**Professional Opportunities**

**Ophthalmology  
Retina Practice**

is offering **fellowship** training for aspiring OD as well as having open full time position for **fellowship trained** OD. Competitive salary, benefits and bonus.

Please send CV to  
hiring4you@yahoo.com

**SIMON EYE ASSOCIATES**

**\*DELAWARE\***

Established and growing 6 location, 15 O.D., group practice seeking an additional full time associate. Opportunity in the greater Wilmington/ New Castle County area. Practice full scope, primary care therapeutic optometry in a professional, private practice setting.

*Delaware is close to Philadelphia, Baltimore, the Chesapeake Bay and the Atlantic Beach resorts.*

Contact Dr. Joseph Senall at  
(302) 528-0656 or  
jsenall@simoneye.net

**Continuing Education**

**Medical Facility  
Optometrists**

The American Board of Certification in Medical Optometry is utilized at accredited medical facilities to verify specialist-level competence in medical optometry. ABCMO certifies specialized competence of a higher level than that required for licensure and general practice.

Visit [www.abcmo.org](http://www.abcmo.org) to learn why medical facilities require board certification of specialists and why only ABCMO board certification in the specialty of medical optometry is accepted. Questions? [myers.kenj@gmail.com](mailto:myers.kenj@gmail.com).

**NOTICE:** After August 1, 2003, all applicants for ABCMO board certification must have completed an ACOE residency in medical optometry and passed the Advanced Competence in Medical Optometry examination of the NBEO.

[www.abcmo.org](http://www.abcmo.org)



*Scientia est Potentia*

Contact Lenses



# Impressions

Color Contact Lens

*Unleash your true color!*

Amethyst Brown \* Grey \* Green Turquoise Hazel \* Honey \* Pure Hazel \* True Sapphire

Impressions colored contacts blend naturally with your patients eyes to create a beautiful look. Available in nine dazzling opaque colors of which Grey, Green, Honey, Pure Hazel and True Sapphire are available in RX Pl to -6.00. Impressions are fun, hip, fashionable and very competitively priced to help your bottom line. POP materials and posters are available upon request.

Available Exclusively at

## National Lens

America's Leading Discount Optical Distributor  
1-866-923-5600 • 1-866-923-5601 Fax  
www.national-lens.com



Continuing Medical Education

### American Academy of Optometry New Jersey Chapter 11th Annual Educational Conference

**April 24-28, 2013**  
Myrtle Beach, South Carolina  
*Hilton Embassy Suites at Kingston Plantation*

Carlo Pelino, OD FAAO  
Diana Shechtman, OD FAAO  
Sponsored by **essilor**

**16 HOURS  
COPE CE**

**Registration: \$475.00**  
One, Two or Three Bedroom Suites  
Accommodations Include a Daily Breakfast Buffet  
and Evening Cocktail Reception

**PACK YOUR CLUBS!**  
*Golf details to follow.*

For Accommodation and Additional Information, contact:  
**Dennis H. Lyons, OD, F.A.A.O.**  
Phone: (732) 920-0110  
E-Mail: dhl2020@aol.com



### MIAMI NICE SYMPOSIUM 2013

**April 27-28, 2013**

17 Hours COPE Approved CE  
12 Hours FL Transcript Quality  
FL Requirements for Jurisprudence, Medical Errors, & HIV

- Lee Ball, O.D.
- Heather McBryar, O.D.
- Diana Schectman, O.D.
- John McClane, O.D.
- Kim Reed, O.D.
- Albert Woods, O.D.

Early registration before 3/1/13  
Late registration after 3/1/13  
**NOTE: ONSITE REGISTRATION ADD \$25.00**  
*(Onsite registration not available online)*

- Early MDOPA/BCOA \$240.00
- Late MDOPA/BCOA \$290.00
- Early AOA \$340.00
- Late AOA \$390.00
- Early non-AOA \$500.00
- Late non-AOA \$550.00

*(Note: Registration includes education, meals, and parking)*

**Westin Colonnade Hotel • Coral Gables, Florida**  
**Room Rate is \$189.00 plus tax until March 29, 2013**

For reservation please call 305-441-2600 and ask to be transferred to reservations where a Westin associate will assist you. *(Please be sure to mention Miami Nice when making your reservation.)*

For more information visit [www.MiamiEyes.org](http://www.MiamiEyes.org)  
Or email at [MDOPA.Board@gmail.com](mailto:MDOPA.Board@gmail.com)  
Or call Dr Steve Morris @ (305)668-7700




Products and Services

Are you *STILL* asking people to place hot towels on their eyes and scrub their lashes with baby shampoo?

Excellent... There's a lot of science behind it: this works!

Introducing

**EYE-PRESS™**

Self-heating, REUSABLE warm compresses for the eyes, pre-moistened with baby shampoo & natural lavender extract...

- INSTANT, Temperature-controlled, Steady-state heat that won't burn the eyes
- pH-controlled soap-free hypo-allergenic baby shampoo
- Refreshing Natural Lavender Scent
- Convenient, Hygienic, Safe, & EFFECTIVE!
- FDA cleared, patented technology




#1 effective treatment for:

- Sties & Chalazia
- Blepharitis
- Meibomian-gland Dysfunction

#1 supplement to artificial tears for dry eyes

- Promotes outstanding ocular hygiene

Now available online and nationwide at Rite-Aid! 

For samples or to order for your own office shelf, please call (855) EYE-7377  
[www.eye-press.com](http://www.eye-press.com)

Frames



**SPECIAL LIMITED TIME OFFER**  
 BUY 12 FRAMES  
 GET 3 FREE!!  
Valid through 5/1/2013

**NATIONAL LENS**

America's Leading Optical Distributor

Visit us at Vision Expo  
 Booth #222

**OUR MISSION STATEMENT**

National Lens is dedicated to fulfilling the needs of the optical profession by providing the Guaranteed Lowest Prices on Contact Lenses, Frames, and Finished Spectacle Lenses.

**Know how to profit and thrive in today's environment!**

**CONTACT LENSES**

**TREVI COLISEUM 100% ITALIAN FRAMES  
 FINISHED SPECTACLE LENSES  
 FREE FIRST CLASS SHIPPING\***

Call for our current price list or visit our website to register

**866.923.5600 • 866.923.5601 FAX**

**www.national-lens.com**



\*in stock products (when available)





# Temporal Artery Biopsy

This delicate procedure is pivotal in the diagnosis of temporal arteritis.

By **Derek N. Cunningham, OD, and Walter O. Whitley, OD, MBA**

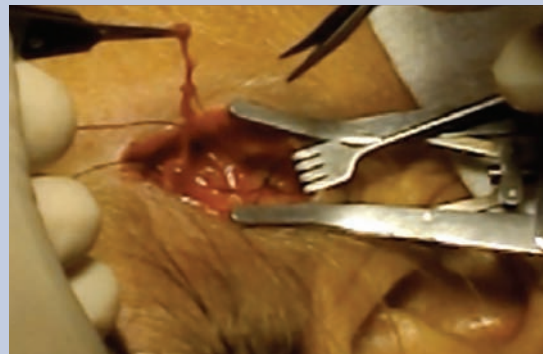


Photo and video courtesy of oculoplastics surgeon Thomas Joly, MD, PhD.



Go to [www.revoptom.com](http://www.revoptom.com) or scan the QR code at left to see video footage of the procedure.

**On The Web >> View a narrated video of a temporal arterial biopsy.**

**T**emporal arteritis (TA), a systemic vasculitis affecting medium- to large-sized arteries, typically occurs in patients older than 50 years of age, which should be considered in the differential diagnosis. Patients over age 60 have a higher risk, while younger patients are more likely to have optic neuritis or non-arteritic ischemic optic neuropathy.

TA suspects should have an immediate work up, including pupil assessment, color vision, dilated exam and blood work (CBC w/differential, ESR and CRP). The CBC can rule out other causes of inflammation (e.g., infection, anemia, leukocytosis) and/or may yield the diagnosis due to elevated platelet levels. If the ESR is elevated, refer for a temporal artery biopsy to conclusively diagnose TA. Also consider biopsy if the ESR is normal and the CRP is high, along with associated clinical findings—a small number of cases do not manifest elevated ESR. The biopsy should be performed by a neurologist or neuro-ophthalmologist within one week after starting systemic steroids. A biopsy is especially important in diabetics because corticosteroids have relative contraindications.

The procedure is typically performed in a minor operating room. After topical and injectable anesthesia, the superficial temporal artery is marked by palpating the pulse or using a Doppler ultrasound, followed by antisepsis and draping. Using a #15 blade, an incision is made directly over the artery, penetrating only skin and subcutaneous tissue to avoid injuring the underlying vessel. Further dissection with a hemostat is carried out into the superficial temporal fascia, where the temporal artery is found.

Hemostats with electrocautery are used to minimize hematoma risk. The vessel is clamped, exposing a 2cm-to-5cm length of the artery. The two ends of the artery are tied with suture and the intervening segment is removed and sent to pathology, where it is checked for both acute inflammation and disruption of the internal elastic lamina (indicating healed chronic inflammation). Once adequate hemostasis is ensured, the subcutaneous tissue is closed, followed by the superficial wound, which is dressed with petroleum ointment for several days until sutures dissolve.

Potential risks and complications include hematoma, incisional alopecia, nerve damage, scar formation and wound infection. Negative results from the biopsy (likely due to small sample size) may necessitate an additional biopsy to the opposite artery.

Once TA is diagnosed, systemic steroids are required to preserve vision; untreated, it can progress to bilateral vision loss. Start steroids immediately, either intravenously (methylprednisolone 250mg IV, Q6H for 12 doses) or orally (prednisone 80mg to 100mg PO, QD). Patients will continue prednisone for six to 12 months, depending on the ESR levels and disease suppression. Antiulcer meds are often given along with systemic steroids to manage GI issues.

Patient education is of the utmost importance, due to the potentially visually devastating consequences. Let your patient know that you will call them with the results and communicate your findings with the consulting physician and their primary care doctor. In cases of high suspicion or abnormal lab findings, a TA biopsy will confirm or rule out the diagnosis. ■



## A Painfully Large Cataract

By Andrew S. Gurwood, OD

### History

A 68-year-old white female presented for an urgent visit with a chief complaint of severe ocular pain and reduced visual acuity in her left eye. She reported that her symptoms manifested fairly suddenly and persisted for one day. She denied any history of recent ocular trauma.

Her ocular history was significant for progressive bilateral cataracts; however, we documented no acute abnormalities at her previous routine ocular health examination eight months earlier. She did not use any ocular medications.

Her systemic history was significant for hypertension, which was controlled with oral beta blockers. She reported no allergies.

### Diagnostic Data

Her best-corrected visual acuity measured 20/25 OD and 20/400 OS at distance through

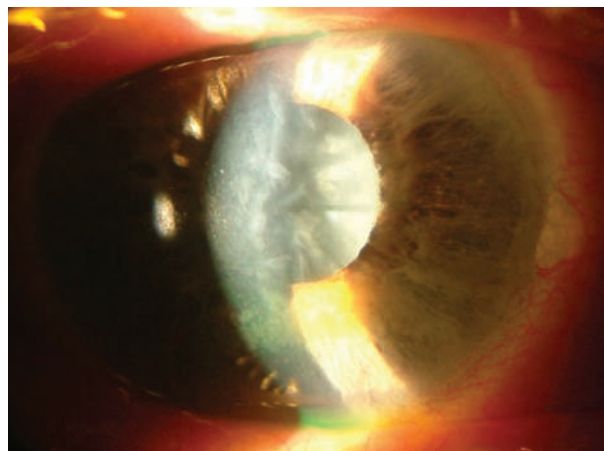
habitual +1.25D sphere/+2.50D bifocal spectacles. Refraction revealed no changes to her spectacle prescription.

External examination was unremarkable, with no evidence of afferent pupillary defect.

Her intraocular pressure measured 16mm Hg OD and 51mm Hg OS. Undilated 90D funduscopy examination revealed quiet grounds and normal posterior poles, with a cup-to-disc ratio of 0.40 x 0.40 OU.

### Your Diagnosis

How would you approach this case? Does the patient require any



The left eye of our 68-year-old patient who complained of severe pain and reduced visual acuity.

additional tests? What is your diagnosis? How would you manage this patient? What is the likely prognosis?

To find out, please visit [www.revoptom.com](http://www.revoptom.com). Click on the cover icon for this month's issue, and then click "Diagnostic Quiz" under the table of contents. ■

**Retina Quiz Answers** (from page 94): 1) b; 2) d; 3) b; 4) b.

### Next Month in the Mag

Our March issue features the 18th Annual Comanagement Report.

Topics include:

- *Keep it All in the Family: Comanaging with Other ODs*
- *Optometry's Increased Role in Cataract Surgery*
- *Patient Nailed with NAION After Cataract Extraction*

Also in March:

- *Optometric Study Center: The Impact of Traumatic Brain*

*Injury on Vision* (earn 2 CE credits)

- *Tips and Tricks from an Allergist*
- *How to Up-sell in a Down Economy*

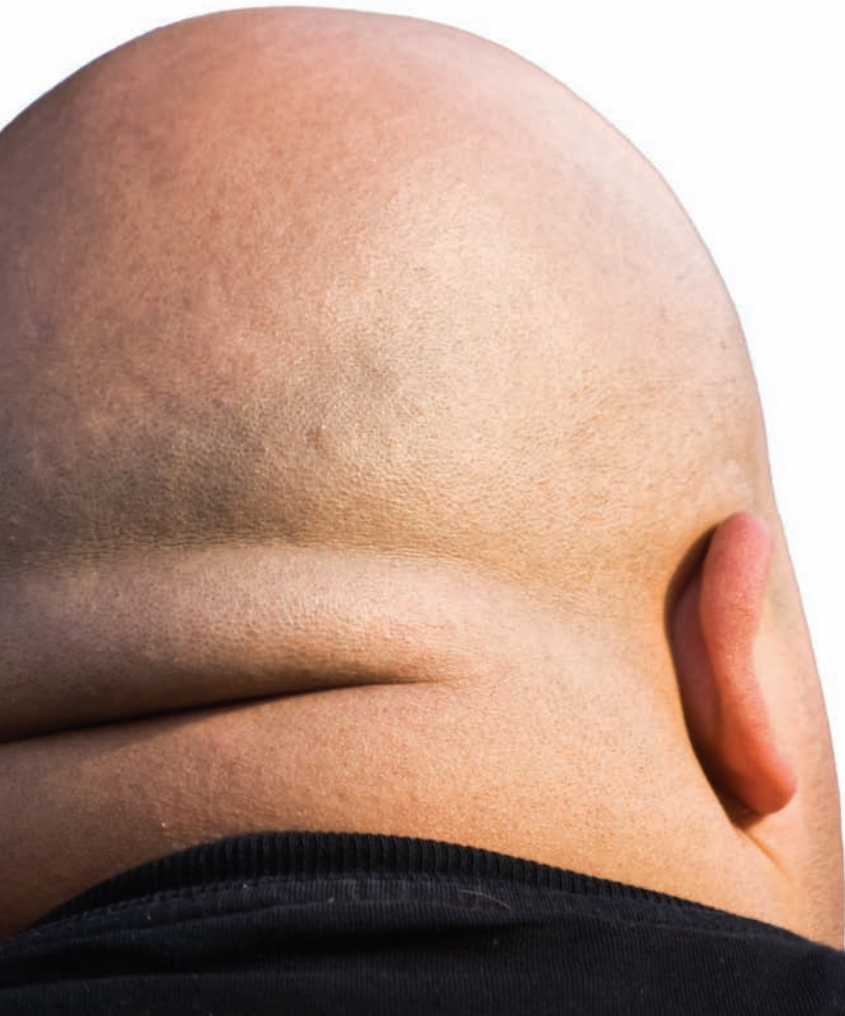### Feedback

*Review of Optometry* welcomes questions and comments. E-mail Jack Persico, editor-in-chief, [jpersico@jobson.com](mailto:jpersico@jobson.com), with "Letter to the Editor" as the subject line.

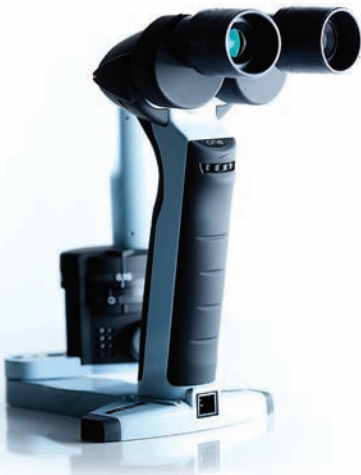REVIEW OF OPTOMETRY (ISSN 0147-7633) IS PUBLISHED MONTHLY, 12 TIMES A YEAR BY JOBSON MEDICAL INFORMATION LLC, 100 AVENUE OF THE AMERICAS, NEW YORK, NY 10013-1678. PERIODICALS POSTAGE PAID AT NEW YORK, NY AND ADDITIONAL MAILING OFFICES. POSTMASTER: SEND ADDRESS CHANGES TO REVIEW OF OPTOMETRY, PO BOX 2025, SKOKIE, IL 60076. SUBSCRIPTION PRICES: US: ONE YEAR \$56; TWO YEARS \$97, CANADA: ONE YEAR \$88, TWO YEARS \$160, INT'L: ONE YEAR \$209, TWO YEARS \$299. FOR SUBSCRIPTION INFORMATION CALL TOLL-FREE (877) 529-1746 (USA ONLY); OUTSIDE USA, CALL (847) 763-9630 OR FAX (847) 763-9631. PUBLICATIONS MAIL AGREEMENT NO: 40612608. CANADA RETURNS TO BE SENT TO BLEUCHIP INTERNATIONAL, P.O. BOX 25542, LONDON, ON N6C 6B2.

# One Size Finally Fits All

## The Keeler PSL1 Portable Slit Lamp



Snap the code to  
watch it in use!



### Large or small...the PSL fits them all!

We understand that having the best instrumentation is critical to delivering high quality care to all of your patients. Keeler developed the PSL with flexibility and outstanding optical clarity so that each of your patients can have the very best.

Don't allow an obstacle (small or large) stop you from delivering the very best care possible.

Make the PSL your standard for quality eye care for all your patients.

Buy Online!  
[keelerusa.com](http://keelerusa.com)



# Keeler

[www.keelerusa.com](http://www.keelerusa.com) | 800-523-5620

# THIS IS WHY YOU CAN give your patients comfort that lasts.




ATTACHING AND  
FORMING A HYDROPHILIC ENVIRONMENT  
across the surface of the lens<sup>1,2,4</sup>



CREATING A UNIQUE BARRIER  
that reduces lipid deposition  
and removes protein deposits<sup>1-3</sup>



PROVIDING MOISTURE  
from morning till night<sup>1,2,4</sup>



Proprietary **HydraGlyde®**  
Moisture Matrix

## OPTI-FREE® PureMoist® MPDS with HydraGlyde® Moisture Matrix

TALK TO YOUR PATIENTS ABOUT THE BENEFITS OF OPTI-FREE® BRAND PRODUCTS.  
LEARN MORE AT [MYALCON.COM](http://MYALCON.COM)



#### REFERENCES:

1. Data on file, Alcon Research Ltd. 2. Lally J, Ketelson H, Borazjani R, et al. A new lens care solution provides moisture and comfort with today's CLs. *Optician* 4/1/2011, Vol 241 Issue 6296, 42-46. 3. Campbell R, Kame G, Leach N, et al. Clinical benefits of a new multi-purpose disinfecting solution in silicone hydrogel and soft contact lens users. *Eye & Contact Lens* 2012;38(2):93-101. 4. Davis J, Ketelson HA, Shows A, Meadows DL. A lens care solution designed for wetting silicone hydrogel materials. Poster presented at: ARVO; May 2010; Fort Lauderdale, FL.

© 2012 Novartis 11/12 OPM12201JAD

**Alcon®**  
a Novartis company