

REVIEW[®] OF OPTOMETRY

www.revoptom.com

35th Annual DIAGNOSTIC TECHNOLOGY REPORT



The ABCs of OCT, p. 52

Top 10 Most Wanted Diagnostic Instruments, p. 60

Image Management Systems: What Can They Offer?, p. 65

ALSO INSIDE:

New Drugs in the Ophthalmic Pipeline, p. 32

SECO's Summer Session: Hot CE in Cool Vancouver, p. 48

Review Takes Maiden Voyage to Puerto Rico, p. 68

MARCHON

WORLD SIGHT DAY CHALLENGE

OPTOMETRYGIVINGSIGHT

An estimated 600 million people in the world are blind or vision impaired simply because they don't have access to an eye exam and glasses. World Sight Day is a global event that focuses on bringing attention to blindness and vision impairment. It is observed on the 2nd Thursday of October each year.

Marchon is inviting you to take part in the World Sight Day Challenge by participating in an upcoming event in your area. Not only will you be having fun, but you will be raising valuable funds for Optometry Giving Sight which transforms lives through the gift of vision.

GETTING INVOLVED IS EASY

Choose an event in your area, set up a donation page, click here https://givingsight.myetap.org/fundraiser/wsdc2012_usa/. To start raising money & awareness for Optometry Giving Sight, e-mail, Facebook, Tweet or snail mail your link to friends, family, coworkers and neighbors.

Not ready to be an athlete, you can still support World Sight Day. Simply click on this link https://givingsight.myetap.org/fundraiser/wsdc2012_usa/ and make a donation.

Visit marchon.com/cms/sightday to see a full list of suggested events in your area.



WORLD
SIGHT
DAY



MARCHON IS PROUD TO SUPPORT
THE HASEMEYER FAMILY AND
THE WALK YOUR TALK WALK



© 2012 Marchon Eyewear, Inc. Styles: X Games Variat, M-217, M-855, Disney 114, X Games Lodge, M-222, M-115, M-205, M-951

EYE MAKE A DIFFERENCE™

Marchon Eyewear is proud to honor and support ordinary people who've made extraordinary differences in the lives of children. Jaci Hasemeyer (in M-222) and her husband Eric (in M-115) grew their family of 5 by fostering 30 children and eventually adopting 10. Their journey began when they recognized that older children have a more difficult time in the Foster care system and soon, with open arms, provided a home for them. To help with their vision and compassion for these children, the Hasemeyers established the "Walk Your Talk Walk" Foundation, which raises funds and awareness for the Foster community. They've dedicated their lives to their children and to those in need of family, truly making a difference in their community and the youth of America.

KNOW SOMEONE WHO MAKES A DIFFERENCE? NOMINATE THEM AT MARCHON.COM

MARCHON®

IN THE NEWS

Amendments to optometric regulations will allow optometrists in **British Columbia** to prescribe medications to treat **glaucoma**. "It's not uncommon for rural patients to wait over a year or travel hundreds of kilometers to receive treatment," says **Surjinder Sahota, O.D.**, president of the **British Columbia Association of Optometrists**. "By allowing doctors of optometry to prescribe anti-glaucoma medications, patients will have greater access to timely and appropriate eye care in all areas of the province."

Cataract surgery may reduce the risk of **hip fractures** among **elderly people** by up to 23%, according to a recent study in *Journal of the American Medical Association*. Researchers looked at more than one million Medicare patients age 65 and older who were diagnosed with cataracts between 2002 and 2009. Results suggest cataract surgery may be a **cost-effective** way to reduce the risk of falls and hip fractures among older adults.

People who take **cholesterol-lowering statin drugs** have a 57% increased risk for **cataracts**, according to a new study in *Optometry and Vision Science*. Statistically, the increase in cataract risk with statins is similar to that associated with diabetes. However, the authors emphasize that the known benefits of statin treatment for patients with **type 2 diabetes** probably outweigh any increased risk of cataracts. These findings serve to encourage further research on alternative cholesterol-lowering drugs that are not associated with an increased risk of cataracts, the authors wrote.

World's First Bionic Eye Implant is a Success

The patient sees only flashes of light and vague shapes, but it's a start. **By Cheryl Murphy, O.D., Contributing Editor**

Researchers in Australia made history last month after confirming the first successful "bionic eye" implant in the world.

Scientists at Bionic Vision Australia (BVA) surgically implanted a prototype of the bionic eye in 54-year-old Dianne Ashworth, who suffers vision loss due to retinitis pigmentosa. When the implant was first switched on and stimulated last month, Ms. Ashworth saw a flash of light and shapes in her previously blind eye. The device, placed between the choroid and the sclera, is equipped with 24 electrodes and a small wire that extends from the back of the eye to a receptor behind the ear. When stimulated, the electrodes signal the surviving retinal cells in the eye, giving the patient the ability to "see" once again.

"The bionic eye technology relies on the patient having a healthy optic nerve and a developed visual cortex," the researchers said. "Patients need to have been able to see in the past for this device to be of benefit to them." They expect the bionic eyes to have the greatest benefit in people with retinitis pigmentosa and macular degeneration.

Next, the team at BVA will

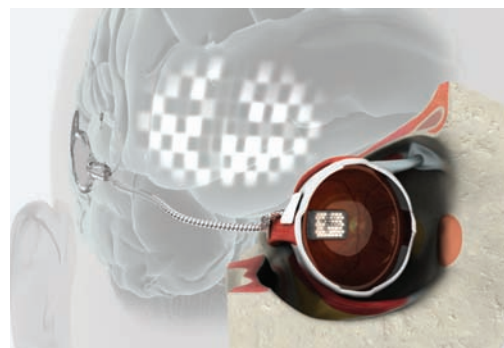


Image: Bionic Vision Australia

Artist's rendering of the bionic eye shows the electrode array implant at the back of the retina.

work with Ms. Ashworth to gather measurements and feedback, which will help them develop a visual processor and build better images using the flashes of light. Ultimately they will attach a pair of eyeglasses with a mounted digital camera to the device and refine the vision using an implant with more electrodes.

Scientists at BVA are already developing two additional devices—a 98-electrode wide-view bionic eye implant and a 1024-electrode high acuity implant. The wide-view device would allow patients who have severe vision loss to see the contrast between light and dark shapes, helping to aid mobility and enhance their independence. The high acuity version would greatly enhance central vision, allowing patients to once again recognize faces and even read large-print books.

...less has never meant more.



Easiest To Use
Smallest Footprint
Lowest Price

Less is more.

Pulsair Desktop is uncomplicated and therefore quick to use for the novice and professional alike. Taking control of tonometry has never been easier or faster. Clear user controls and a color video alignment screen combine to set a new standard in usability.

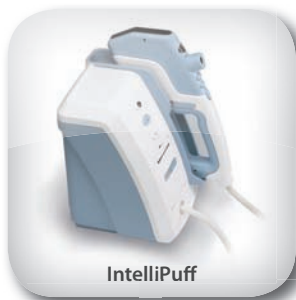The Pulsair Desktop has a small and space saving footprint that combined with the elegant, slim optical mainframe allows it to blend seamlessly into the clinical environment. The openness of the design increases the confidence of both patient and clinician.

Contact Keeler or your preferred Keeler distributor today to learn more about the Pulsair Desktop and the rest of the Keeler family of tonometers.

The Keeler Family of Tonometers offers your practice the choice of technology that's right for you!



Keeler K.A.T.



IntelliPuff

Great Low Price!
\$6,250.00

Buy Online!
keelerusa.com



Keeler

www.keelerusa.com | 800-523-5620

A HALMA COMPANY

Lawsuit Ends: Judge Rules Against ‘Falsity’ of Board Certification

In late August, Judge A. Howard Matz, of the U.S. District Court of the Central District of California, released his final ruling in favor of the American Board of Optometry (ABO) in the false advertising lawsuit brought by the American Optometric Society (AOS).

At issue: The AOS alleged that the ABO’s use of the term “board certification” is “false, misleading, confusing, deceptive or unfair.” In its suit, the AOS argued that the ABO’s use of board certification “convey[s] the false impression that an ABO-certified optometrist has extensive specialized education and training beyond optometry school and beyond that required for licensure.”

In his decision, though, Judge Matz ruled that the AOS failed to prove the “falsity, deception, materiality and injury” of ABO’s use of board certification.

Following the judge’s ruling, the ABO claimed victory in the case.

“The Judge’s ruling unambiguously states that our use of the term board certified is not confusing to the public,” said ABO Chairman of the Board Paul Ajamian, O.D. “The AOS’s attempt to put a cloud over our program has failed. This ruling ends a bitter chapter in the history of optom-

etry. We are moving ahead, and look forward to continuing to serve the profession with a credible board certification program.”

The AOS, meanwhile, accepted the ruling on the false advertising litigation, but did not back down from its stance against board certification in general. Specifically, the AOS argued, the judge’s ruling did not alter an earlier injunction that prohibits the ABO from claiming its program represents competence above and beyond optometric licensure.

“Judge Matz did not address whether or not the ABO is a legitimate board certification program,” said AOS President Pamela Miller, O.D., J.D. “While an injunction would have been preferable, there is still no evidence that a misleading general board certification program in optometry is necessary or will be required by third-party payers or the government’s Medicare and Medicaid programs. As the AOS has been saying for over two years, there’s simply no value in the ABO’s program, and certainly no reason to pay them \$1,800.”

Call for Unity

Following the judge’s ruling, many optometrists on both sides of the issue bemoaned the divisive-

ness that this lawsuit—and the civil war over board certification—has caused for the profession, as well as the time and money it has taken away from tackling other important problems.

In an editorial in the e-newsletter *Optometric Physician*, Art Epstein, O.D., a founding member of the AOS (who has since retired from the organization), wrote, “Mere words will not be enough to heal the deep wounds or narrow what is a still-growing divide. The only way is to sit down and work through them together—face-to-face. We need a summit where all stakeholders can openly explore real pathways toward reconciliation and discuss their future vision for our profession.”

He added, “Continuing conflict is a cancer that, if left unchecked, will consume our organizations and eventually our profession. Ultimately, we must find a way back to unity. We have no other choice.”

AOA President Ronald Hopping, O.D., M.P.H., stated, “Now we have much bigger challenges ahead of us. We can wallow in this board certification turmoil while the rest of the world moves forward or, if we are going to be successful, we can move on. We must move on ... I welcome the participation of every optometrist in moving our profession forward. Our future now depends on what we all do together.”

How exactly will the profession move forward together? Perhaps a brand new board should be created just for that.

FDA Approves Lucentis for Diabetic Macular Edema

The FDA has approved Genentech’s Lucentis (ranibizumab injection) for the treatment of diabetic macular edema. Two Phase III clinical studies showed that 34%-45% of patients treated with monthly Lucentis (0.3mg dose) gained at least three lines of vision. In comparison with patients who did not receive Lucentis, only 12%-18% had the same result.

Getting Patients to Comply with Lens Replacement

By Craig Wood, OD

What many patients fail to recognize is the correlation between reduced contact lens satisfaction and over-extending the life of their contact lenses. We have many patients who have grown frustrated with their contact lenses and inquire about laser vision correction or consider giving up on lenses all together. I like to ask these people about their lens replacement habits, lens care solutions they have used, and how often they sleep in their lenses. This can open dialogue and it's evident that most patients really don't want to give up their contact lenses – they just want something that works for them. So we take these as opportunities to educate patients on preferred lens replacement schedules and appropriate lens care solutions.

I don't believe there is one single indicator that will tell if a patient is being compliant with lens replacement. Certainly I look at their chart and take note of how long it has been since their previous visit. My staff will also

make notations in the chart indicating the number of boxes of lenses that have been ordered. But with the presence of online ordering and big box stores selling lenses – it can be hard to gauge how frequently someone is actually replacing lenses.

I comment to the patient when they are in the exam chair about the presence of neovascularization or other microscopic changes that I may see and use that as a point of discussion. One tool I use extensively in my practice is corneal topography. We obtain topographies on all of our contact lens patients and then compare these scans annually. This is a great way for the doctor to point out subtle (and sometimes not so subtle) changes in the corneal shape and emphasize the medical nature of what happens to the eye when wearing contact lenses. I often use the evidence of topographical change to refit patients to a different lens.

In my practice the most compliant patients are our daily disposable lens wearers.

Compliance diminishes with 2 week replacement lens wearers because they simply forget when to replace them. With DAILIES® brand lenses, it is quite obvious that they need to be replaced daily and when they aren't, the lenses become uncomfortable. With monthly replacement lens wearers, it is easy for people to associate paying their bills, or using the 1st of each month as a reference point to remind them to change their lenses. If you ask wearers of 2 week replacement lenses, they will often state they simply forget when to replace the lenses.

I follow the manufacturer's recommended replacement schedule almost without fail and I review the replacement schedule when discussing contact lens care with my patients during the annual exam. I have also trained my staff to remind the patients of proper lens replacement when they are discussing lens care solutions. We have our patients return for a one-week contact lens check and at that time again reinforce when to replace their lenses.

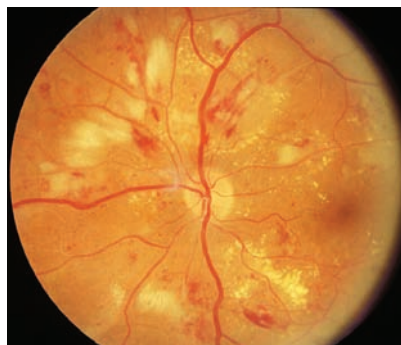Blacks at Higher Risk for Diabetic Retinopathy at Lower HbA1c Levels

Blacks are more likely to develop diabetic eye damage at lower blood glucose thresholds than whites, according to a recent study in the *Annals of Internal Medicine*. The results suggest that black people may be more vulnerable than whites to high HbA1c levels.

Researchers at Beth Israel Deaconess Medical Center in Boston evaluated the association between elevated HbA1c levels and the risk for retinopathy development using National Health and Nutrition Survey data from 2,804 whites and 1,008 blacks.

“We looked at the data to determine if a higher diagnostic cutoff of A1c level should be used to diagnose diabetes in blacks than in whites, or if there should be a single cutoff for all races,” said lead author Yusuke Tsugawa, M.D., M.P.H.

The World Health Organization and American Diabetes Association have recommended that an



Blacks may be more vulnerable to higher HbA1c levels, and thus at greater risk for diabetic retinopathy.

HbA1c level of 6.5% is diagnostically significant for diabetes, compared to an HbA1c level of 5% in healthy individuals. Given the evidence of inherently elevated HbA1c percentages in blacks, the researchers initially hypothesized that diabetic retinopathy would begin to manifest at proportionately higher blood glucose levels.

However, the evidence indicated that the exact opposite was true. They found the risk of diabetic

retinopathy is higher for blacks at HbA1c levels between 5% and 7%. In fact, the higher risk at an HbA1c level of 5.5% to 5.9% for blacks was comparable to the risk at an HbA1c level of 6% to 6.4% for whites.

“This indicates that black people may be more vulnerable to high A1c status than whites,” Dr. Tsugawa said.

He added, “It may be appropriate for doctors to more closely monitor for early diabetic complications for their black patients than for their white patients, and black patients with diabetes may benefit from retinal exams at an earlier stage of their disease.”

Further research may be able to confirm whether blacks should have a lower diagnostic threshold of HbA1c than whites, the authors concluded.

Tsugawa Y, Mukamal KJ, Davis RB, et al. Should the hemoglobin A1c diagnostic cutoff differ between blacks and whites? A cross-sectional study. *Ann Intern Med*. 2012 Aug 7;157(3):153-9.




Image: Francesco Aieta

Flat Lens Offers a Clear View

Can you imagine a microscope as thin as a dime—or maybe a pair of glasses with lenses thinner than a sheet of paper?

Scientists have designed a new ultrathin flat lens that focuses light without imparting the distortions of conventional lenses. They say it eliminates optical aberrations, such as the “fish-eye” effect that results from conventional wide-angle lenses.

The ultrathin wafer of silicon and gold, created by applied physicists at the Harvard School of Engineering and Applied Sciences, is essentially two-dimensional at just 60nm thick. This new device operates at the range commonly used in fiber-optic communications and is completely scalable and simple to manufacture.

“In the future we can potentially replace all the bulk components in the majority of optical systems with just flat surfaces,” says lead author Francesco Aieta, a visiting graduate student from the Marche Polytechnic University in Italy. “It certainly captures the imagination.”

Aieta F, Genevet P, Kats MA, et al. Aberration-free ultrathin flat lenses and axicons at telecom wavelengths based on plasmonic metasurfaces. *Nano Lett*. 2012 Aug 21. [Epub ahead of print.]

A new ultrathin, flat lens focuses light without imparting the optical distortions of conventional lenses.

Leave your phoropter behind.

Go to the next level of refraction.



PSF Refractor™ with Voice Guided Subjective Refraction

Voice
Guided

PSF Refractor™

The Vmax Vision PSF Refractor™ featuring **NEW** Voice Guided Subjective Refraction capability and proprietary Point Spread Function (PSF) method enables you to:

- Refract even challenging patients with **increased confidence** knowing that audio instructions are guiding the process with consistency and accuracy
- Dramatically **reduce refraction training** to 2 days or less*
- Achieve superior vision with **5X greater accuracy** than the phoropter
- Offer a true **nighttime vision test** to satisfy an unmet patient need

Patient vision is maximized when PSF refraction is combined with Vmax Vision Enception™ Lenses – which can be precision cut to 0.01 D and customized for all variables including patient optics, gaze, life styles and frame factors.

See and hear the PSF Refractor™ at the Review of Optometry: New Technology & Treatments, OCRT and AAO Booth 220. For an in-office demonstration, call 888.413.7038 or visit www.vmaxvision.com

* Average training time. Actual training time may vary.

© 2012 Vmax Vision. All rights reserved. PSF Refractor and Enception are trademarks of VMax Vision, Inc. #1002_09/12

vmax
VISION, INCORPORATED

1.888.413.7038
www.vmaxvision.com

Back-to-School Special

Several recent developments happened at different optometry schools around the country. Here's a recap:

• **Illinois College of Optometry.** ICO will soon be the first optometric institution with a center for vision and aging. The college recently announced the founding of the Alfred and Sarah Rosenbloom Center on Vision and Aging in honor of the doctor and his wife. Dr. Rosenbloom served as dean of ICO from 1955 to 1972, president from 1972 to 1982, and remains a distinguished professor emeritus.

The new facility will be located within the Illinois Eye Institute on ICO's campus and will be devoted to the vision care needs of the aging population.

"ICO's reputation in terms of current and future education offers the opportunity to elevate standards and raise awareness for providing professional vision care to this age group," Dr. Rosenbloom said. "This may lead in time to the development



Photo: Dominic M. Marino, O.D., M.Ed.

Illinois College of Optometry's new Alfred and Sarah Rosenbloom Center on Vision and Aging is named after former dean, president and distinguished professor emeritus Dr. Alfred Rosenbloom and his wife Sarah.

of a geriatric care patient service model, including care for many underserved individuals in assisted living facilities and in nursing homes."

• **Northeastern State University Oklahoma College of Optometry.** The Practice Management Club of NSUOCO recently became the first-ever recipient of the Preston Cup. The Student Optometric Leadership Network (SOLN) created the award in honor of Preston Smith, a fourth-year student at NSUOCO and founding member of SOLN who died tragically in a car accident last November.

The Preston Cup is to be awarded each year to the most deserving SOLN private practice or practice management club. SOLN members who attend the annual Student Private Practice Symposium and Leadership Conference vote on which of their fellow organizations have gone above and beyond during the year.

• **State University of New York College of Optometry.** With a three-year, \$421,160 grant from the Lavelle Fund for the Blind, SUNY's College of Optometry will expand the clinic at the Center of Excellence in Low Vision Rehabilitation at the Wenzhou Medical College in China.

Established in 2008 with an initial three-year Lavelle Fund grant, the low vision clinic will now expand to include new patient populations in order to achieve full sustainability in three years. The recent grant money will be used to implement a new computer-based system of data collection and analysis. The funds will also pay for a training program at the medical college for faculty and staff from other locations in China.

"With this generous support, this model for the delivery of low and vision rehabilitative care can be replicated throughout China," said project director Michael Heiberger, O.D.

• **Michigan College of Optometry-Ferris State University.** MCO has appointed Bruce Morgan, O.D., as interim dean. Dr. Morgan is a professor at MCO as well as the director of residencies. He succeeds Michael Cron, O.D., who announced his retirement last fall.

In addition to his 25 years of experience as an optometrist and educator, Dr. Morgan is currently president of the Association of Contact Lens Educators. He's also been involved in numerous accreditation processes for both college and residency programs, including serving as a member of the Accreditation Council on Optometric Education.



NSUOCO Practice Management Club Vice President Benjamin Lynch accepts the Preston Cup trophy, donated by VSP. He is joined by VSP's Dana Beards (left) and Vision Source's Kelly Kerksick-Frisella, O.D. (right).

EYEDESIGNS.COM



The Eye Place Windermere, FL



Visual Eyes At Mizner Park Boca Raton, FL



Lord Eye Center Brunswick, GA



GET STARTED



VISIT US TODAY

- SPACE PLANNING
- INTERIOR DESIGN
- DISPLAY INNOVATION
- MANUFACTURING

EYEDESIGNS®

VISIT WWW.EYEDESIGNS.COM OR CALL 800.346.8890

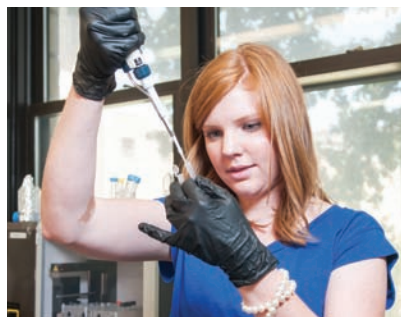
New Glue to Improve Post-op LASIK Safety

A new adhesive composite could improve the long-term postoperative safety of LASIK surgery, according to a recent study in *Investigative Ophthalmology & Visual Science*.

Researchers at the University of Kansas have developed a glue mixture of fibrinogen and riboflavin that, when combined with ultraviolet light, could be used to further stabilize the surgically induced corneal flap after LASIK. Sealing the flap with this nontoxic biodegradable composite could help to reduce postsurgical risks and complications, they say.

“Although LASIK produces a flap that remains clear and normally lays smoothly on the modified corneal surface, if the eye is hit with blunt force trauma—from an auto airbag or a tennis ball, for example—the flap simply peels open again, resulting in contamination inside the cornea and requiring immediate medical attention, which can include corneal transplantation,” says principal investigator, Gary Conrad, Ph.D., distinguished professor of biology at the University of Kansas.

To test the glue, Dr. Conrad and associates measured its adhesive strength on experimental flaps



Stacy Littlechild, a recent graduate in biology, is the lead author of studies that describe a new glue involving fibrinogen, riboflavin and ultraviolet light to improve the safety of LASIK surgery.

that were cut into the corneas of dogfish sharks and rabbits. Then the researchers exposed the corneas to UV light to further bind the composite and seal the corneal flap in place.

“The idea is that if you use the glue, you’ll either reduce or alleviate the risk associated with LASIK surgery,” says lead author Stacy Littlechild. “If we can decrease the need for [corneal] transplants by using a glue, then we won’t impede lives as much and protect patients from having future surgeries.”

Littlechild SL, Brummer G, Zhang Y, Conrad GW. Fibrinogen, riboflavin, and UVA to immobilize a corneal flap—conditions for tissue adhesion. *Invest Ophthalmol Vis Sci*. 2012 Jun 26;53(7):4011-20.

Ocriplasmin to Treat Vitreomacular Adhesion

Results from two Phase III studies found that the investigational eye treatment ocriplasmin (ThromboGenics/Alcon) significantly resolved vitreomacular traction and closed macular holes in patients with vitreomacular adhesion (VMA). This comes on the heels of the FDA’s Dermatologic and Ophthalmic Drugs Advisory Committee recommendation that the FDA grant ocriplasmin approval for treatment of symptomatic VMA. If approved, ocriplasmin would be the first pharmaceutical therapy to treat patients with VMA. ■

REVIEW[®]
OF OPTOMETRY

Jobson
Professional Publications Group

PRESIDENT & PUBLISHER
RICHARD D. BAY
(610) 492-1020 • RBAY@JOBSON.COM

BUSINESS OFFICES
11 CAMPUS BLVD., SUITE 100
NEWTOWN SQUARE, PA 19073

SUBSCRIPTION INQUIRIES
1-877-529-1746 (USA ONLY);
OUTSIDE USA, CALL (847) 763-9630

SALES MANAGER, NORTHEAST, OHIO
JAMES HENNE
(610) 492-1017 • JHENNE@JOBSON.COM

SALES MANAGER, SOUTHEAST, WEST
MICHELE BARRETT
(610) 492-1014 • MBARRETT@JOBSON.COM

CLASSIFIED ADVERTISING
888-498-1460

VICE PRESIDENT OF OPERATIONS
CASEY FOSTER
(610) 492-1007 • CFOSTER@JOBSON.COM

EDUCATION/CONFERENCE MANAGER
MEG McDONALD
(610) 492-1045 • MMCDONALD@JOBSON.COM

PRODUCTION MANAGER
SCOTT TOBIN
(610) 492-1011 • STOBIN@JOBSON.COM

SENIOR CIRCULATION MANAGER
ANTHONY GUADAGNINO
(212) 219-7870 • AGUADAGNINO@JOBSON.COM

SUBSCRIPTIONS
\$56 A YEAR, \$88 (U.S.) IN CANADA,
\$209 (U.S.) IN ALL OTHER COUNTRIES.

CIRCULATION
PO Box 2025
SKOKIE, IL 60076
TEL: (TOLL FREE) 1-877-529-1746
OUTSIDE USA: (847) 763-9630
FAX: (847) 763-9631



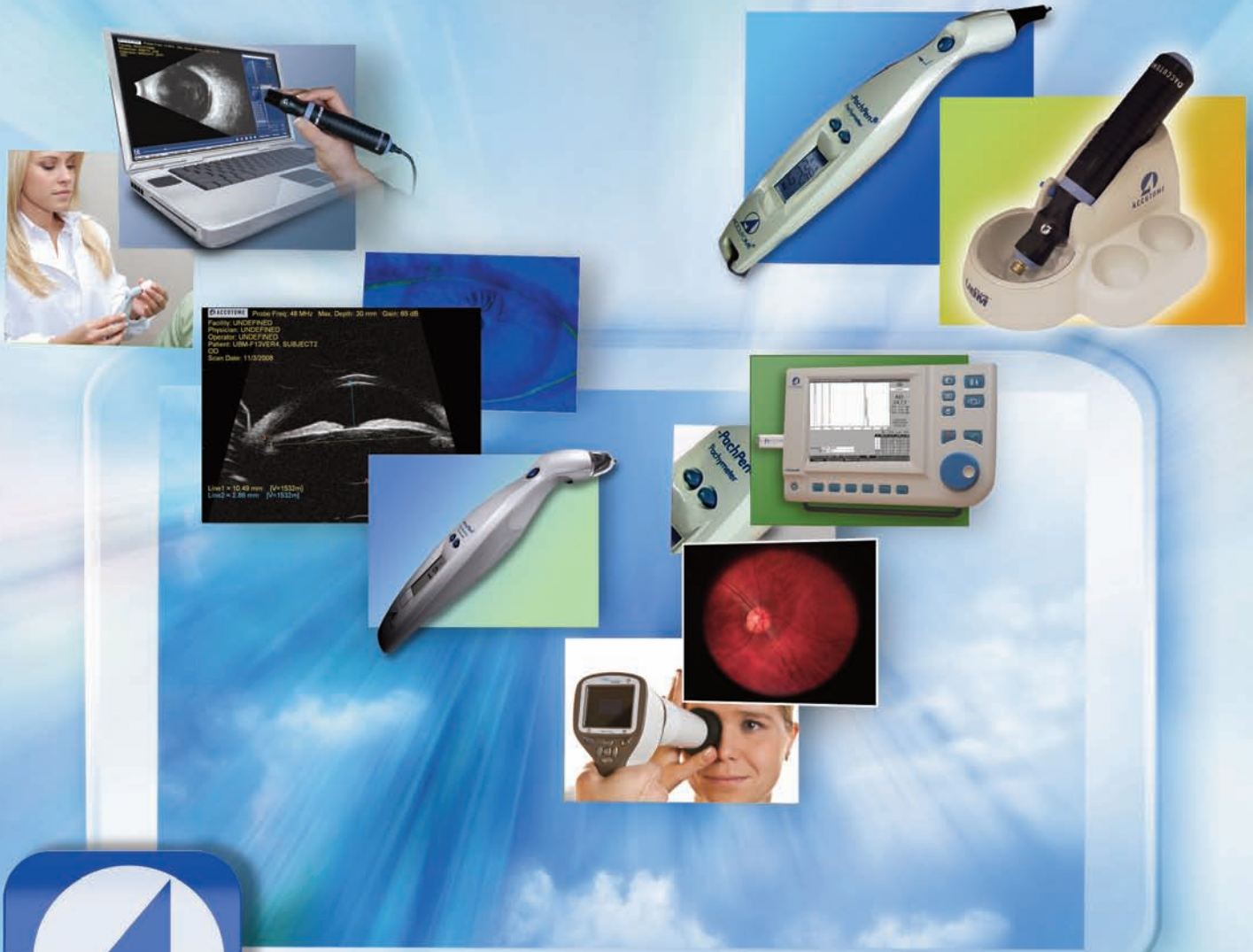CHIEF OPERATING OFFICER
JEFF MACDONALD

CEO, INFORMATION GROUP SERVICES
MARC FERRARA

SENIOR VICE PRESIDENT, HUMAN RESOURCES
LORRAINE ORLANDO

VICE PRESIDENT, CREATIVE SERVICES & PRODUCTION
MONICA TETTAMANZI

VICE PRESIDENT, CIRCULATION
EMELDA BAREA

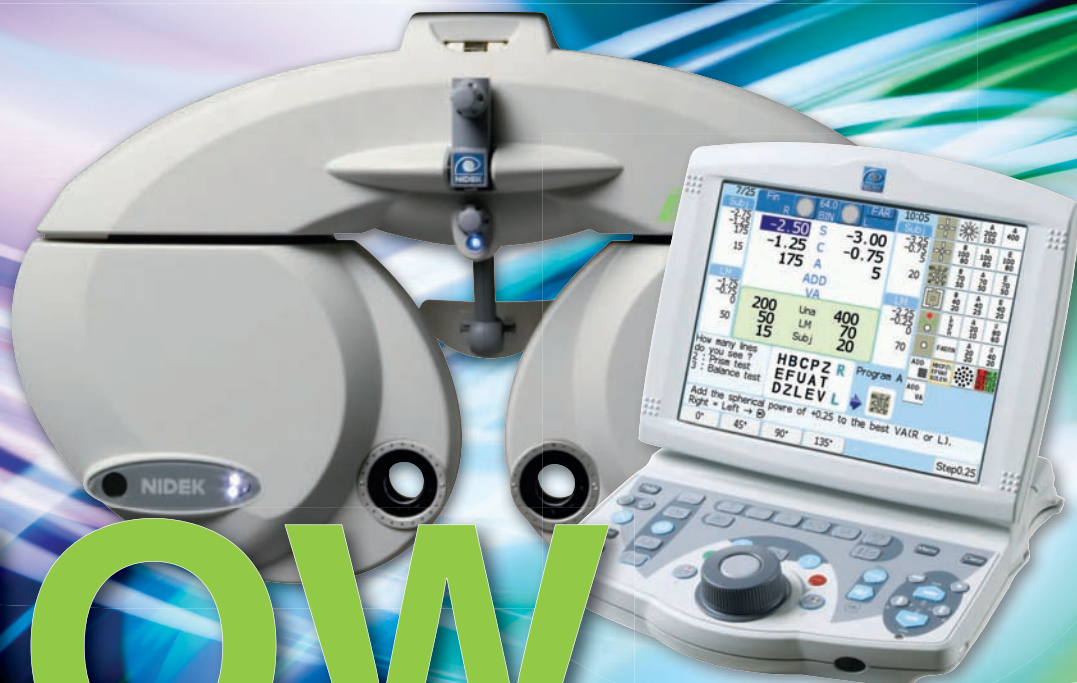

Our Portable Solutions are like an App for Your Entire Office.

Accutome specializes in high-quality, portable diagnostic equipment that can be easily transported from lane-to-lane or office-to-office. Call to find out how you can improve your practice's versatility.

- AccuPen® Handheld Tonometer
- PachPen® Handheld Pachymeter
- Pictor Handheld Retina and Anterior Segment Camera
- B-Scan Plus®
- UBM Plus®
- A-Scan Plus®

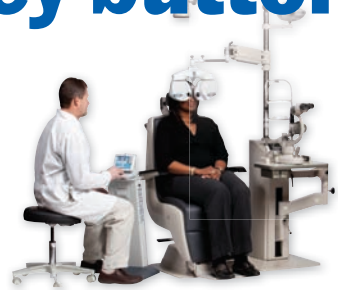



NOW

you **KNOW** where to find the money button

- Easily integrate on any chair and stand
- Shave minutes off every refraction
- See more patients daily
- Gain greater practice efficiencies
- Display old and new Rx instantly
- Achieve seamless EHR integration
- Generate patient time for optical
- Provide more quality time for doctor consultation
- Eliminate transcription error and reduce costly lens remakes
- Sustain less staff turnover and provide higher quality of practice life
- Eliminate down time from repetitive stress injuries to staff
- Elevate patient experience for greater satisfaction and referrals



TRS-5100 Total Refraction System

Are you pushing the right buttons?

Arrange your **free** practice assessment or product demonstration at www.whosincontrol.info and receive your **free** NOW button.



The Difference is Marco™



Designed and Manufactured by NIDEK - Represented by MARCO

www.marco.com
800.874.5274



Contents

Review of Optometry September 2012



52

The ABCs of OCT

Take a guided tour of this innovative technology to better understand its relevance to your practice. **By Jerome Sherman, O.D., and Daniel Epshtein**

60

Top 10 Most Wanted Diagnostic Instruments

Electronic medical records, digital cameras and OCTs are this year's most popular technologies, according to our annual survey. They're changing the way you practice. **By John Murphy, Executive Editor**

65

Image Management Systems: What Can They Offer?

Software that integrates your diagnostic images might simplify your workflow and improve patient care. Here, a few early adopters share their experiences. **By Robert Murphy, Contributing Editor**

32

New Drugs in the Ophthalmic Pipeline

ROCK inhibitors, SEGRA compounds and SIRT proteins might be unfamiliar to you now. But you may soon see them in topical drops.

By Freddy W. Chang, O.D., Ph.D.

48

SECO's Summer Session: Hot CE in Cool Vancouver

Canadian optometrists shared insights with their U.S. counterparts on hot topics during SECO's July meeting. **By Jane Cole, Contributing Editor**

68

Review Takes Maiden Voyage to Puerto Rico

Attendees at *Review of Optometry's* Puerto Rico 2012 meeting garnered clinical insights on contact lenses, glaucoma and retinal disease from some of the profession's leading experts.

By Paul M. Karpecki, O.D., Clinical & Education Conference Advisor



72

Earn 2 CE Credits:



Explanations for Sudden Vision Loss

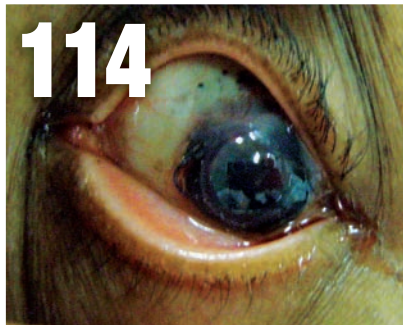
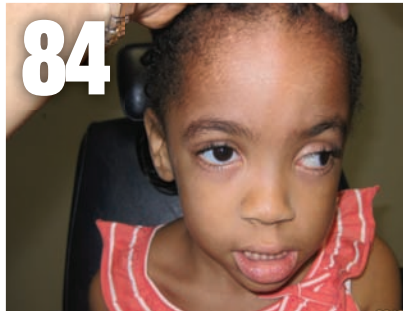Here, we examine non-traumatic causes of sudden vision loss as well as discuss diagnostic testing procedures and management strategies.

By Denise Goodwin, O.D.

Departments

Review of Optometry September 2012

- 4** News Review
- 20** Letters to the Editor
- 22** Editor's Page
Penny-wise but Pound-foolish?
JACK PERSICO
- 24** Chairside
Available: One Slightly Used O.D.
MONTGOMERY VICKERS, O.D.
- 26** Coding Abstract
Protect Yourself with an ABN
JOHN RUMPAKIS, O.D., M.B.A.
- 84** Comanagement Q+A
Double Take on Double Vision
PAUL C. AJAMIAN, O.D.
- 86** Cornea + Contact Lens Q+A
Cross-linking Conundrums
JOSEPH P. SHOVLIN, O.D.
- 88** Review of Systems
Mind and Body
CARLO J. PELINO, O.D.
JOSEPH J. PIZZIMENTI, O.D.
- 91** Retina Quiz
An Underlying Infection?
MARK T. DUNBAR, O.D.
- 94** Therapeutic Review
Double Trouble
JOSEPH W. SOWKA, O.D.
ALAN G. KABAT, O.D.
- 97** Research Review
Anti-VEGF Dials Up the Pressure
DIANA L. SHECHTMAN, O.D.
PAUL M. KARPECKI, O.D.
- 100** Product Review
- 106** Meetings + Conferences
- 107** Advertisers Index
- 108** Classifieds
- 112** Surgical Minute
Corneal Collagen Cross-linking
DEREK N. CUNNINGHAM, O.D.
WALTER O. WHITLEY, O.D., M.B.A.
- 114** Diagnostic Quiz
His Eyes Aren't the Problem
ANDREW S. GURWOOD, O.D.



On The Web >>

Check out our web exclusives and continuing education @ www.revoptom.com

Digital Edition



Left your *Review of Optometry* at the office? No problem! Access *Review* on your computer or mobile device!

Go to www.revoptom.com and click on the digimag link to for the current issue.

Facebook and Twitter



For daily updates, "Like" our page on Facebook or "Follow" us on Twitter!

- www.facebook.com/revoptom
- <http://twitter.com/#!/revoptom>

REVIEW
OF OPTOMETRY



PRINTED IN U.S.A.

FOUNDING EDITOR
FREDERICK BOGER
1891-1913

EDITORIAL OFFICES
11 CAMPUS BLVD., SUITE 100
NEWTOWN SQUARE, PA 19073
EMAIL • REVIEWOFOPTOMETRY@JOBSON.COM
WEBSITE • WWW.REVOPTOM.COM

SUBSCRIPTION INQUIRIES
1-877-529-1746
CONTINUING EDUCATION INQUIRIES
1-800-825-4696

EDITOR-IN-CHIEF • JACK PERSICO
(610) 492-1006 • JPERSICO@JOBSON.COM

EXECUTIVE EDITOR • JOHN MURPHY
(610) 492-1021 • JMURPHY@JOBSON.COM

MANAGING EDITOR • MICHAEL HOSTER
(610) 492-1028 • MHOSTER@JOBSON.COM

SENIOR EDITOR/WEB EDITOR • COLLEEN MULLARKEY
(610) 492-1005 • CMULLARKEY@JOBSON.COM

DIRECTOR ART/PRODUCTION • JOE MORRIS
(610) 492-1027 • JMORRIS@JOBSON.COM

ART DIRECTOR • JARED ARAUJO
(610) 492-1032 • JARAJO@JOBSON.COM

GRAPHIC DESIGNER • ALICIA CAIRNS
(610) 492-1029 • ACAIRNS@JOBSON.COM

DIRECTOR OF CE ADMINISTRATION • REGINA COMBS
(212) 274-7160 • RCOMBS@JOBSON.COM

SPECIAL PROJECTS • JANE COLE
(610) 492-1043 • JCOLE@JOBSON.COM

EDITORIAL BOARD

CHIEF CLINICAL EDITORS • ROBERT M. COLE, III, O.D.
CHRISTINE W. SINDT, O.D.
ASSOCIATE CLINICAL EDITOR • JOSEPH P. SHOVLIN, O.D.
DIRECTOR OPTOMETRIC PROGRAMS • ARTHUR EPSTEIN, O.D.
CLINICAL & EDUCATION CONFERENCE ADVISOR •
PAUL M. KARPECKI, O.D.

CASE REPORTS COORDINATOR • THOMAS L. LEWIS, OD, PhD
CLINICAL CODING EDITOR • JOHN RUMPAKIS, O.D., M.B.A.
CONSULTING EDITOR • FRANK FONTANA, O.D.

COLUMNISTS

CHAIRSIDE • MONTGOMERY VICKERS, O.D.
COMANAGEMENT Q+A • PAUL C. AJAMIAN, O.D.
CORNEA & CONTACT LENS Q+A • JOSEPH P. SHOVLIN, O.D.
DIAGNOSTIC QUIZ • ANDREW S. GURWOOD, O.D.
GLAUCOMA GRAND ROUNDS • JAMES L. FANELLI, O.D.
RESEARCH REVIEW • PAUL M. KARPECKI, O.D.;
DIANA L. SHECHTMAN, O.D.
RETINA QUIZ • MARK T. DUNBAR, O.D.
REVIEW OF SYSTEMS • CARLO J. PELINO, O.D.;
JOSEPH J. PIZZIMENTI, O.D.
SURGICAL MINUTE • DEREK N. CUNNINGHAM, O.D.;
WALTER O. WHITLEY, O.D., M.B.A.
THERAPEUTIC REVIEW • JOSEPH W. SOWKA, O.D.;
ALAN G. KABAT, O.D.

PROFESSIONAL PUBLISHING GROUP
JOBSON MEDICAL INFORMATION LLC





#1 PRESCRIPTION
ALLERGY EYE DROP¹



Zero-itch

Starts Here

Once Daily
PatadayTM
(olopatadine hydrochloride
ophthalmic solution) 0.2%

Prescribe the **Number One** prescription allergy eye drop to **Start** and **Finish** the day with **Zero-itch**.^{1,2}

- **Start:** As soon as 3 minutes following allergen challenge, 60% of patients achieved Zero-itch*†
- **Finish:** At 16 hours, 60% of patients had Zero-itch*†

INDICATION AND DOSING

PATADAYTM Solution is a mast cell stabilizer indicated for the treatment of ocular itching associated with allergic conjunctivitis. The recommended dose is one drop in each affected eye once a day.

IMPORTANT SAFETY INFORMATION

PATADAYTM Solution is for topical ocular use only. It is not for injection or oral use.

To prevent contaminating the dropper tip and solution, care should be taken not to touch the eyelids or surrounding areas with the dropper tip of the bottle. Keep the bottle tightly closed when not in use.

PATADAYTM Solution should not be used to treat contact lens-related irritation. The preservative in PATADAYTM Solution, benzalkonium chloride, may be absorbed by soft contact lenses. Patients who wear soft contact lenses should be instructed to wait at least ten minutes after instilling PATADAYTM Solution before they insert their contact lenses.

Symptoms similar to cold syndrome and pharyngitis were reported at an incidence of approximately 10%.

For additional information about PATADAYTM Solution, please refer to the brief summary of prescribing information on the following page.

*Post-hoc analysis of combined data from two studies using a contralateral conjunctival allergen challenge (CAC). Based on a scale of itching scores of 0-4, with 0 as no itching and 4 as severe itching. Ocular itching was evaluated 3 minutes after allergen challenge at onset and at 16 hours.

†(N=85; 95% CI=48.8, 70.5)

‡(N=82; 95% CI=48.3, 70.4)

References: 1. IMS Health, IMS National Prescription AuditTM, August 2010 to February 2011, USC 61500 OPTH ANTI-ALLERGY. 2. Data on file.



Alcon[®]

©2011 Novartis 11/11 PAT12500JAD

Pataday™

(olopatadine hydrochloride ophthalmic solution) 0.2%

BRIEF SUMMARY OF PRESCRIBING INFORMATION

INDICATIONS AND USAGE

PATADAY™ solution is a mast cell stabilizer indicated for the treatment of ocular itching associated with allergic conjunctivitis.

DOSAGE AND ADMINISTRATION

The recommended dose is one drop in each affected eye once a day.

DOSAGE FORMS AND STRENGTHS

Ophthalmic solution 0.2%: each ml contains 2.22 mg of olopatadine hydrochloride.

CONTRAINDICATIONS

None.

WARNINGS AND PRECAUTIONS

For topical ocular use only: not for injection or oral use.

Contamination of Tip and Solution: As with any eye drop, to prevent contaminating the dropper tip and solution, care should be taken not to touch the eyelids or surrounding areas with the dropper tip of the bottle. Keep bottle tightly closed when not in use.

Contact Lens Use: Patients should be advised not to wear a contact lens if their eye is red. PATADAY™ (olopatadine hydrochloride ophthalmic solution) 0.2% should not be used to treat contact lens related irritation. The preservative in PATADAY™ solution, benzalkonium chloride, may be absorbed by soft contact lenses. Patients who wear soft contact lenses and whose eyes are not red, should be instructed to wait at least ten minutes after instilling PATADAY™ (olopatadine hydrochloride ophthalmic solution) 0.2% before they insert their contact lenses.

ADVERSE REACTIONS

Symptoms similar to cold syndrome and pharyngitis were reported at an incidence of approximately 10%. The following ocular adverse experiences were reported in 5% or less of patients: blurred vision, burning or stinging, conjunctivitis, dry eye, foreign body sensation, hyperemia, hypersensitivity, keratitis, lid edema, pain and ocular pruritus. The following non-ocular adverse experiences were reported in 5% or less of patients: asthenia, back pain, flu syndrome, headache, increased cough, infection, nausea, rhinitis, sinusitis and taste perversion. Some of these events were similar to the underlying disease being studied.

USE IN SPECIFIC POPULATIONS

Pregnancy: Teratogenic effects: Pregnancy Category C. Olopatadine was found not to be teratogenic in rats and rabbits. However, rats treated at 600 mg/kg/day, or 150,000 times the MROHD and rabbits treated at 400 mg/kg/day, or approximately 100,000 times the MROHD, during organogenesis showed a decrease in live fetuses. In addition, rats treated with 600 mg/kg/day of olopatadine during organogenesis showed a decrease in fetal weight. Further, rats treated with 600 mg/kg/day of olopatadine during late gestation through the lactation period showed a decrease in neonatal survival and body weight. There are, however, no adequate and well-controlled studies in pregnant women. Because animal studies are not always predictive of human responses, this drug should be used in pregnant women only if the potential benefit to the mother justifies the potential risk to the embryo or fetus.

Nursing Mothers: Olopatadine has been identified in the milk of nursing rats following oral administration. It is not known whether topical ocular administration could result in sufficient systemic absorption to produce detectable quantities in the human breast milk. Nevertheless, caution should be exercised when PATADAY™ (olopatadine hydrochloride ophthalmic solution) 0.2% is administered to a nursing mother.

Pediatric Use: Safety and effectiveness in pediatric patients below the age of 2 years have not been established.

Geriatric Use: No overall differences in safety and effectiveness have been observed between elderly and younger patients.

NONCLINICAL TOXICOLOGY

Olopatadine administered orally was not carcinogenic in mice and rats in doses up to 500 mg/kg/day and 200 mg/kg/day, respectively. Based on a 40 µL drop size and a 50 kg person, these doses were approximately 150,000 and 50,000 times higher than the maximum recommended ocular human dose (MROHD). No mutagenic potential was observed when olopatadine was tested in an *in vitro* bacterial reverse mutation (Ames) test, an *in vitro* mammalian chromosome aberration assay or an *in vivo* mouse micronucleus test. Olopatadine administered to male and female rats at oral doses of approximately 100,000 times MROHD level resulted in a slight decrease in the fertility index and reduced implantation rate; no effects on reproductive function were observed at doses of approximately 15,000 times the MROHD level.

U.S. Patents Nos. 5,641,805; 6,995,186; 7,402,609

Alcon®

©2011 Novartis 11/11 PAT12500JAD

CONTRIBUTING EDITORS

PAUL C. AJAMIAN, O.D., ATLANTA
JEFFREY R. ANSHEL, O.D., CARLSBAD, CALIF.
JILL AUTRY, O.D., R.PH., HOUSTON
SHERRY J. BASS, O.D., NEW YORK
MILE BRUJIC, O.D., BOWLING GREEN, OHIO
WALTER L. CHOATE, O.D., MADISON, TENN.
ROBERT M. COLE, III, O.D., BRIDGETON, N.J.
ANTHONY S. DIECIDUE, O.D., STROUDSBURG, PA.
MARK T. DUNBAR, O.D., MIAMI
S. BARRY EIDEN, O.D., DEERFIELD, ILL.
ARTHUR B. EPSTEIN, O.D., ROSLYN, N.Y.
JAMES L. FANELLI, O.D., WILMINGTON, N.C.
FRANK FONTANA, O.D., ST. LOUIS
GARY S. GERBER, O.D., HAWTHORNE, N.J.
ANDREW S. GURWOOD, O.D., PHILADELPHIA
MILTON HOM, O.D., AZUSA, CALIF.
ALAN G. KABAT, O.D., FORT LAUDERDALE, FLA.
PAUL M. KARPECKI, O.D., LEXINGTON, KY.
JUDITH LEE, ATGLEN, PA.
JEROME A. LEGERTON, O.D., M.B.A., SAN DIEGO
THOMAS L. LEWIS, O.D., PH.D., PHILADELPHIA
DOMINICK MAINO, O.D., M.ED., CHICAGO
JASON R. MILLER, O.D. M.B.A., POWELL, OHIO
PAMELA J. MILLER, O.D., J.D., HIGHLAND, CALIF.
JOHN W. POTTER, O.D., M.A., DALLAS
CHRISTOPHER J. QUINN, O.D., ISELIN, N.J.
JOHN L. SCHACHET, O.D., ENGLEWOOD, COLO.
JACK SCHAEFFER, O.D., BIRMINGHAM, ALA.
CAROL SCHWARTZ, O.D., M.B.A., SAN JOSE DEL CABO, MEXICO
JEROME SHERMAN, O.D., NEW YORK
JOSEPH P. SHOVLIN, O.D., SCRANTON, PA.
JOSEPH W. SOWKA, O.D., FORT LAUDERDALE, FLA.
LORETTA B. SZCZOTKA, O.D., M.S., CLEVELAND
MONTGOMERY VICKERS, O.D., ST. ALBANS, W.VA.
KATHY C. WILLIAMS, O.D., SEATTLE

EDITORIAL REVIEW BOARD

EDWARD S. BENNETT, O.D., ST. LOUIS
MARC R. BLOOMENSTEIN, O.D., SCOTTSDALE, ARIZ.
CHRIS J. CAKANAC, O.D., MURRYSVILLE, PA.
JERRY CAVALLERANO, O.D., PH.D., BOSTON
BRIAN CHOU, O.D., SAN DIEGO
A. PAUL CHOUS, M.A., O.D., TACOMA, WASH.
GLENN S. CORBIN, O.D., WYOMISSING, PA.
STEVEN FERRUCCI, O.D., SEPULVEDA, CALIF.
MURRAY FINGERET, O.D., HEWLETT, N.Y.
IAN BEN GADDIE, O.D., LOUISVILLE, KY.
MATTHEW J. GARSTON, O.D., BOSTON
ROBERT M. GROHE, O.D., HOMEWOOD, ILL.
ANDREW S. GURWOOD, O.D., PHILADELPHIA
NICKY HOLDEMAN, O.D., M.D., HOUSTON
MILTON HOM, O.D., AZUSA, CALIF.
WILLIAM L. JONES, O.D., ALBUQUERQUE, N.M.
ALAN G. KABAT, O.D., FORT LAUDERDALE, FLA.
PAUL M. KARPECKI, O.D., EDGEWOOD, KY.
RON MELTON, O.D., CHARLOTTE, N.C.
BRUCE MUCHNICK, O.D., PHILADELPHIA
MARC MYERS, O.D., COATESVILLE, PA.
CARLO J. PELINO, O.D., JENKINTOWN, PA.
JOSEPH PIZZIMANTI, O.D., FORT LAUDERDALE, FLA.
WILLIAM B. POTTER, O.D., FREEHOLD, N.J.
JOHN RUMPAKIS, O.D., M.B.A., PORTLAND, ORE.
MICHAEL C. RADOIU, O.D., STAUNTON, VA.
LEO P. SEMES, O.D., BIRMINGHAM, ALA.
DIANA L. SHECHTMAN, O.D., FORT LAUDERDALE, FLA.
LEONID SKORIN, JR., O.D., D.O., ROCHESTER, MINN.
JOSEPH W. SOWKA, O.D., FORT LAUDERDALE, FLA.
RANDALL THOMAS, O.D., CONCORD, N.C.

The New American-Made M&S® Smart System® 20/20

SMART SYSTEM 20/20 FEATURES INCLUDE:

- Precisely built with industrial-grade hardware
- Expert local support directly from the manufacturer
- Flexible enough to use any M&S input device
- Delivers longer product life-cycle than other All-in-One systems



Shown here: The New M&S American-Made Smart System 20/20 displaying Letter Contrast Sensitivity Testing

M&S Smart System 20/20 – Made Even Better In the U.S.A.

By selecting the New American-Made Smart System 20/20, you can be assured your examination rooms are equipped with not only the most up-to-date and cutting-edge vision testing software but also the **highest performing hardware technology** on the market today – not commodity hardware built on the other side of the globe for the short-lived consumer market.

Reliability, Expandability, Serviceability. Contact M&S to learn more about the complete Vision Testing System developed specifically for the forward-thinking Vision Care Professional.



Scan this QR code with your smart phone to learn more about M&S Technologies, Inc.

M&S
TECHNOLOGIES®

The First Choice in
Vision Testing Systems

www.mstech-eyes.com
1-877-225-6101



Medical Model Muddle

A common saying is “the times, they are a-changin’.” In optometry they have already changed. When I graduated from Illinois College of Optometry in 1977, my classmates and I were really good at refracting and fitting contact lenses, and some were really proficient with vision therapy and low vision. And we all knew to whom to refer when we encountered pathology, trauma, anomalies, etc. We were very well qualified optometrists.

Today’s graduates’ skills are somewhat suspect regarding refraction and they have little or no knowledge in fitting firm contact lenses. Their main interests are in what they are being taught—pathology, therapeutics, pharmacology, laser surgery, etc. Basically, they are junior M.D.s and no longer optometrists. And all the consultants are recommending adopting the “medical model” style practice. The only thing

wrong with this new situation is the designation “O.D.”—and thus being junior M.D.s.

But why would anyone want to be a junior anything?

The obvious solution is to convert all the optometry schools to med schools and start awarding the more prestigious M.D. degree. With some of the new automatic refractors written about in glowing terms in some of our journals—accurate refraction down to 1/100th of a diopter and tied into free-form lenses ground to the same exact power—refracting ability appears far less important. And contact lens fitting has become so much easier that even some ophthalmologists could probably do it if they really tried.

This would eliminate all the O.D./M.D. controversy and would be a win-win situation for all—except patients, who would probably have to pay more for eye care.

But then, who really cares about patients anyway?

—John Clark Moffett, O.D.
Dallas, Texas

Sight Gags

By Scott Lee, O.D.



Before Man used violence, disputes were settled with staring contests.

Getting Into Integrated Care

Regarding the olive branch from ASCRS, you make some excellent points. (“An Olive Branch from ASCRS,” July 2012.) For decades I have had the strong belief that patient care and patient satisfaction are enhanced when optometry and ophthalmology practice cohesively. This is becoming an increasing reality as the number of optometrists and ophthalmologists who are in practice together continues to grow. Also, the future demand for eye care services will necessitate a market-driven approach to the delivery of care.

I have the distinct privilege of having been asked to join the IOMED (Integrated Ophthalmic-Managed Eye Care Delivery) task force committee, formed by ASCRS to help determine how this entire process will work, along with several highly respected and clear thinking optometrists and ophthalmologists.

Regardless of the outcome, you are exactly right: This is a promising first step.

Additionally, I am a big fan of Groucho Marx.

—Richard C. Edlow, O.D.
Lutherville, Md.

To send a Letter to the Editor, e-mail Jack Persico, editor-in-chief, jpersico@jobson.com, with “Letter to the Editor” as the subject line. ■

**Coming Soon
CONTROVERSIES IN CARE**

A live interactive event where you are invited to join the conversation! Click here for a recap on our July discussion on the judicious uses of steroids.

TOPICS

- Allergy
- Disease
- Dry Eye
- IOLs
- Irregular Cornea
- Practice Management
- RGP Lenses
- Soft Lenses
- Solutions and Lens Care
- Specialty Lenses
- Technology
- Therapeutics
- Trauma

- E-Newsletter
- Submit a Manuscript

Become a Fan on Facebook Follow Us On Twitter



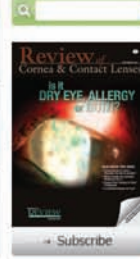Contact Lens Prescribing: USA vs. the World
A look at how contact lens prescribing in the United States compares with other world markets.



Keeping Up with Technology: Old vs. New
Practitioners will find that new does not always mean better when it comes to technology.



Are Phospholipids the Critical Ingredient?
Anionic phospholipids can enhance lipid layer thickness and help patients find relief from dry eye.



WHAT'S NEW IN REVIEW



Are Four Weeks Better Than Two?
Here is a review of the literature and compliance studies ...



Are Phospholipids the Critical Ingredient?
Anionic phospholipids can enhance lipid layer thickness and ...



Redux: Corticosteroids and Bacterial Keratitis
New research suggests that the role of topical ...



Get Charged Up: A New Lubricating Drop
Retaine MGD is the first available cationic emulsion ...



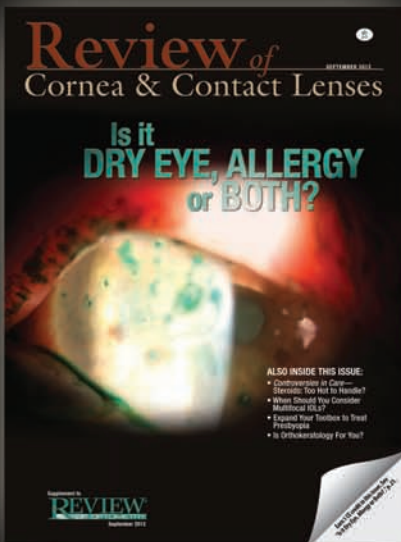
The Case for Eyeglasses
You know your contact lens-wearing patients need up-to-date ...



Achieve Compliance: Inform, Instruct, Inspire

CONTINUING EDUCATION

Introducing the new www.reviewofcontactlenses.com



- View Current Issue + Latest News
- Get Expanded Coverage on Your Favorite Topics
- Participate in Online Discussions on Controversial Topics

Review of
Cornea & Contact Lenses



Penny-wise but Pound-foolish?

Sticker shock might keep you from splurging on new equipment, but it's probably the best marketing investment you can make. **By Jack Persico, Editor-in-Chief**

A few years ago, while interviewing candidates for an opening on my staff, I almost let the best person for the job slip through my fingers. He was a very bright young guy, fresh out of college, with lots of enthusiasm for his first professional position. I offered him the job, and he took it. But later he told me that he almost didn't. Not because the position didn't appeal to him—it was because of the huge old-fashioned CRT computer monitor sitting on my desk during the interview, and the message it conveyed about our company.

This was just after flat-screen computer monitors had become the norm. Sure, my trusty old monitor was big and bulky, but it still worked just fine, so I didn't see any reason to waste good money replacing it. As a co-owner of a small business, where cash is always tight, I was being financially prudent. But to the job candidate, we looked behind the times. We looked like cheapskates. It didn't create a very positive first impression of the company we were asking him to join.

Looking over the results of this month's annual technology survey, I wondered if some practices might be in danger of creating the same sense of unease—in staff members and also patients. *Especially* patients.

The majority of survey respondents (54%) tell us they're going to spend \$20,000 or less next year on new equipment, and in fact 35% will spend zero to \$10,000. Practice sizes vary wildly, of course, but according to our most recent income survey

(October 2011), the average gross revenue of a self-employed O.D. practice was about \$500,000. That means over a third of respondents will invest only 2% or less of their gross revenue in new equipment. (Apologies to the statistics sticklers who noticed that I combined two different datasets just now.)

It's never easy to spend freely in a tight economy, so sometimes you have to make sacrifices—we've all been there. But that fiscal prudence didn't jibe with another finding in the survey: 83% of respondents said that their latest technology investment increased their profitability ("somewhat" for 74% and "dramatically" for 9% of respondents). If you can make at least some money from an investment—and it'll help improve patient care at the same time *and* it'll boost your image as a contemporary, cutting-edge practice—why wouldn't you?

Still, I know that the "if it ain't broke, don't fix (or replace) it" impulse is strong. Speaking with an equipment manufacturer at the Vision Expo West meeting earlier this month, I asked if he had any data on how often optometrists replace their fundus cameras. Indeed he did. He said their data showed the replacement cycle was 89 months on average. That's a product life of about seven and a half years, for a product that evolves pretty rapidly. Are you using the same computer you had in April 2005? How about cell phone? I sure hope not.

There's certainly nothing wrong with using equipment that has served

you well and has long since been paid off. (The equipment vendor also said that it takes about 24 months for a practice to recoup the instrument cost via billings.) But one of the exciting things about being in a technology-driven field like optometry is the opportunity to periodically reinvent and refine your craft, using the latest gizmos. Your job gets easier and, frankly, more fun. Sometimes that alone can overcome the sticker shock.

And the cachet value of using the very latest technology cannot be denied. When the original iPad came out in 2010, I bought one that first month—and headed down to the ARVO conference the next day. In meeting after meeting with doctors and industry representatives, all anyone wanted to talk about was the iPad. In fact, for a whole year that was still the first topic of conversation at all my meetings. I'm sure it left a positive impression with people. (Yes, I've come a long way since my "vintage" CRT monitor days.)

But none of this means you should go easy on the equipment vendors. Times are tough, so they need to be explicit with you about how their fancy new device will: (a) improve patient care and (b) pay for itself. You, your patients and your practice won't gain anything if it's just a white elephant. ■

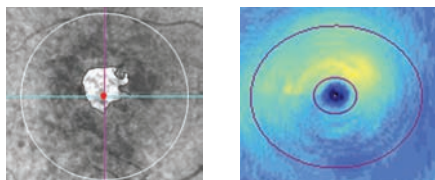
Jack Persico
Editor-in-Chief

The moment your diagnostic certainty
inspires your patient's trust.
This is the moment we work for.



CIR-4261 Rev.B © 2012 Carl Zeiss Meditec, Inc. 0412

Immediately, the clarity and depth of the image is apparent. With the most accurate segmentation overall and a high density of cube data, you know that Cirrus™ HD-OCT will deliver a diagnostic analysis you can trust. Cirrus goes beyond the scan – from automated progression analysis that tracks change, to comprehensive and efficient workflow solutions. Choose the OCT provider that more eye care professionals trust – both now and for the years ahead.



NEW Advanced Dry AMD and Glaucoma applications. Learn more today.
www.meditec.zeiss.com/cirrus



We make it visible.

Available: One Slightly Used O.D.

I'm looking for a new job, so I'm working on my resume. Do you think 'Which is better—one or two?' applies to selling extra value meals? **By Montgomery Vickers, O.D.**

I'm getting my resume together. One calls it one's *curriculum vitae* when one is being learned (and that's when one pronounces "learned" with two syllables).

Now, why in the world would a slightly burned out, but still successful, middle-aged, small-town optometrist write a resume? Well, there are several reasons:

1. Obamacare. We all thought that three "Os" were enough, right? Nope. Now we have the biggest "O" of all. But nobody can decide what the newest "O" on the block means. Will it lead to more patients? Will it lead to lower fees? Will it remove ring around the collar? Nobody knows. I may need to work for a living soon. Maybe they need a new greeter at a big mart store somewhere.

2. I have grandchildren. One of the things I loved about raising my own children in West Virginia was that they built relationships with their grandparents and extended family members. Now, my family is in Texas, California, Ohio...everywhere but here. I would kinda like to know my grandchildren before they start texting me for money.

3. Technology. Will you guys stop inventing new stuff? You're driving me nuts with all the eye analyzers, teardrop measurers, scleral assassins, and on and on. Phoropters that make espresso? Ophthalmoscopes that roam Mars? Contact lenses that heal the lame? Stereogastronomiciridofascialfries-withthatliftandseparators? OK, I did buy one of those. Didn't you?

Hire me and I'll bring my own to work every day.

4. Sleep aids. I love the commercial that tells you to take a pill so you can sleep and/or commit suicide or, if you're lucky, homicide. Maybe if I did not have to pay a late lab bill one month it would work just as well and nobody would have to die for me to rest easy. As my friend Dr. Nibert once asked, "How much of a pay cut would you take to not have to hire, fire, deal with insurance, and pay bills?" Of course, my wife does all that, not me. No wonder she hasn't slept since we hired her. Remind me to hide the shotgun.

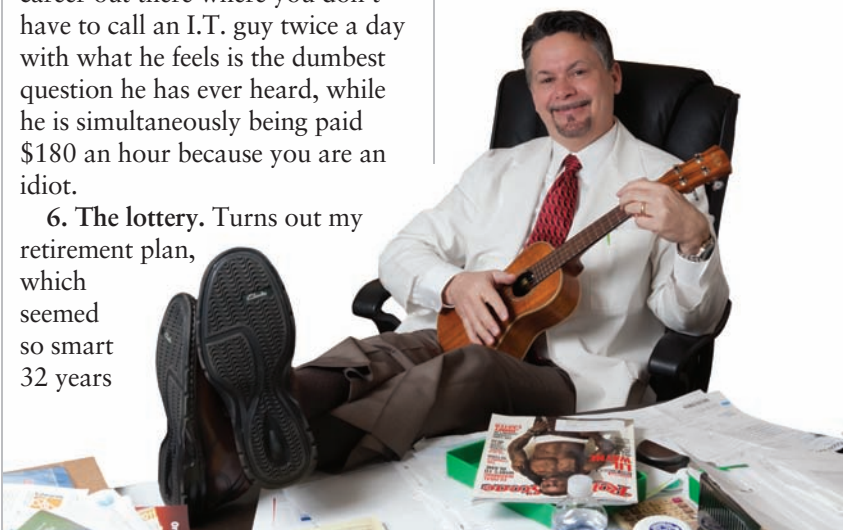5. Bill Gates. It's all his fault. He's the one who convinced us that we should do nothing except pound on computers all day. Unfortunately, there is no career in the world that can free you of doing just that. Surely there is one career out there where you don't have to call an I.T. guy twice a day with what he feels is the dumbest question he has ever heard, while he is simultaneously being paid \$180 an hour because you are an idiot.

6. The lottery. Turns out my retirement plan, which seemed so smart 32 years

ago, just never seems to gain ground. I thought Amalgamated Dirt would be huge by now. So, I have gone to plan B: Powerball. I keep getting closer to winning, and by "closer" I mean I got one number right one time about six months ago. I've analyzed the situation and am pleased to tell you that I will finally retire when I am 99 years old.

Until then, I still do love optometry. All I need is some enterprising young doctor to hire me for the looooooonnngggg haul.

So, I'm writing my resume. All you have to do is pay me a huge six-figure salary while I work 20 hours a week (no weekends, no computers) and all of my many, many years of experience is at your disposal. Oh, is it OK if I bring my grandchildren to work every day? Thanks! You are the best (i.e., only) employer I have ever had! ■



Name *Your Practice*

Rx



ClearChart® 2
Digital Acuity
System

Auto Phoropter RS®
Auto Refraction System

CT210
Contact
Tonometer

XCEL®
Slit Lamps

Endurance™
Tilt Chair & Stand

Signature *Reichert Technologies*

The perfect prescription for your practice.

Everything you need for an automated, connected and long-lasting exam lane.

Reichert®
TECHNOLOGIES
Advancing Eye Care. Preserving Sight.™



See the complete line of exam lane products at www.reichert.com/lane

AMETEK®
ULTRA PRECISION TECHNOLOGIES

© 2012 AMETEK, Inc. All rights reserved. 08/12. Reichert, Reichert Technologies, Auto Phoropter RS, ClearChart and XCEL are registered trademarks of Reichert, Inc. Endurance and "Advancing Eye Care. Preserving Sight." are trademarks of Reichert, Inc. AMETEK is a registered trademark of AMETEK, Inc.

Follow us:
@ReichertTech





Protect Yourself with an ABN

Here's how to give the patient an Advanced Beneficiary Notice when you think a carrier won't pay for a test or service. **By John Rumpakis, O.D., M.B.A., Clinical Coding Editor**

Last month, we discussed the importance of establishing medical necessity prior to ordering or performing any special ophthalmological tests on a patient with diabetes.

With the focus of this month's issue being on new technology and diagnostic testing, let's revisit the topic of the Advanced Beneficiary Notice of Noncoverage (ABN) and how it applies when you suspect that a procedure or test may not be paid for by the carrier.

Know When You Need an ABN

Every doctor should know the importance of issuing an ABN to a Medicare patient. And, by the end of this column, you'll know which of the four modifiers—GA, GX, GY or GZ—is most appropriate to append to the CPT code of the procedure or test in question.

When a provider thinks that Medicare will not pay for some or all of the services or items, the ABN is a written notice that the provider gives to the Medicare beneficiary before those items or services are furnished. The ABN is a formal document required by Medicare, but the concepts here often apply to other commercial medical carriers as well. (The most current ABN form and instruction set can be downloaded at www.cms.gov/Medicare/Medicare-General-Information/BNI/ABN.html.)

There are four common modifiers that can be appended to the CPT codes for procedures that may be denied by the carrier. Depending

on the service provided and specific circumstances, the modifier may be required by Medicare or voluntarily appended to the CPT code.

Modifiers for an ABN

- **GA.** Modifier GA indicates that the ABN is required by the payer policy. It is appended to a CPT code to report that a required ABN was issued for a service and is on file. If the service is denied, CMS will assign financial liability to the beneficiary. Because ABN was properly obtained, the financial liability is legally transferred to the patient and the physician can bill the patient for this service.

- **GX.** When modifier GX is appended to a CPT code, it is used to report that a voluntary ABN was issued for a service that is statutorily excluded from Medicare reimbursement. Medicare rejects non-covered services appended with GX and assigns liability to the beneficiary. Because this is a voluntary ABN, the patient always has financial responsibility for the procedure or test being conducted.

- **GZ.** Modifier GZ indicates that a service or item is expected to be denied as unreasonable or unnecessary. It is appended to a CPT code to report that an ABN was not issued for this service. CMS will automatically deny these services and indicate that the beneficiary is not responsible for payment. Because the doctor did not obtain an ABN prior to performing the service, he cannot bill the patient.

- **GY.** Modifier GY is appended

to a CPT code to report when a service is specifically excluded by Medicare and an ABN was not issued to the beneficiary. This indicates that the service is statutorily excluded or does not meet the definition of any Medicare benefit. CMS will deny these claims and the beneficiary will be totally responsible for all financial liability.

Modifiers GA and GZ are used, for example, if a procedure does not meet medical necessity as determined by a Medicare Local Coverage Determination (LCD) or National Coverage Determination (NCD), or occurs more frequently than stipulated in your carrier's guidelines.

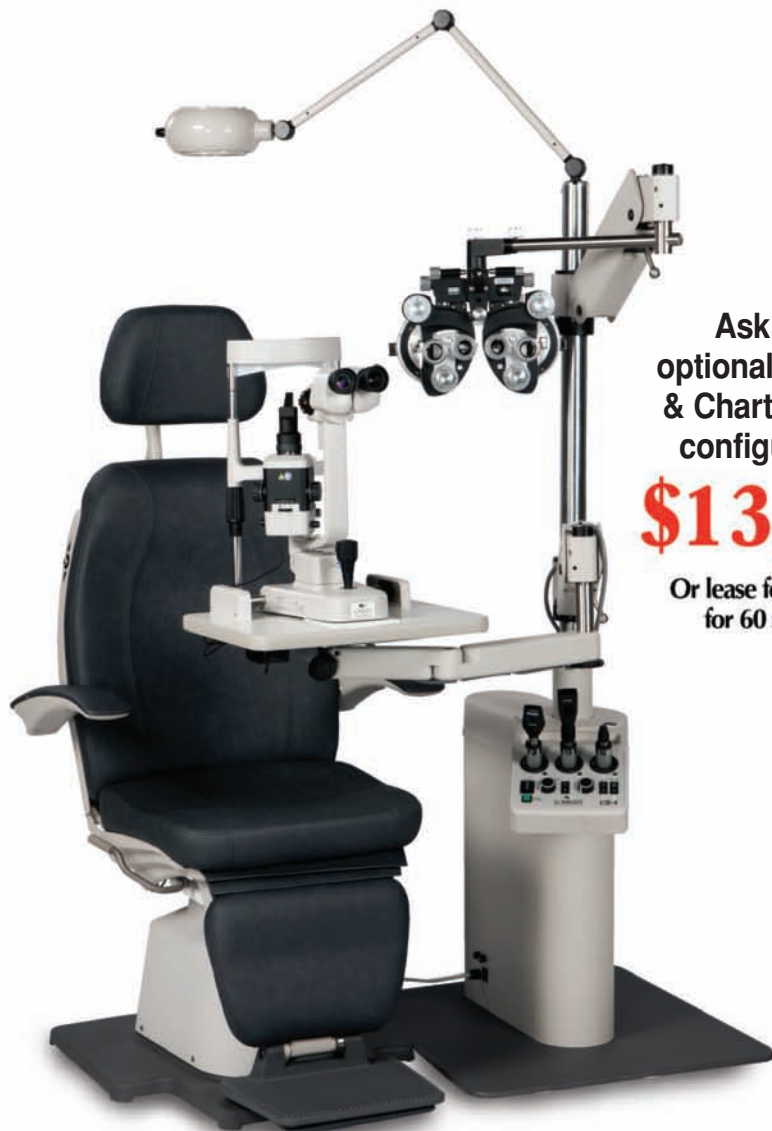Modifiers GX and GY are used for items or services statutorily excluded from the Medicare program. Here, the use of an ABN is optional, but provides proof that the beneficiary understands he will be liable for payment for these services. In other words, modifiers GX and GY are informational only. When using either modifier, the provider should bill the patient for the services provided.

Understanding how to use an ABN will allow you to incorporate new technologies into your practice and provide the highest level of care to your patients without having to be financially at risk. Knowing which modifier to use in the appropriate case will save you time and make you money. ■

Please send your comments to CodingAbstract@gmail.com.

Invest In Your Practice And Get A Guaranteed Positive Return.

Lombart's CS-4 Package Offers Quality, Style & Value.



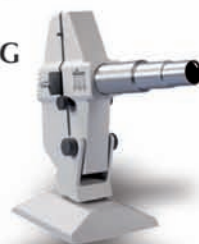Ask about optional Slit Lamp & Chart Projector configurations.

\$13,595

Or lease for \$269/mo. for 60 months *

Package includes:

- The Lombart CS-4 Chair & Stand
- Topcon VT-10 Refractor
- Topcon SL-2G Slit Lamp
- Reichert LongLife Chart Projector with mount, slide & screen
- Upgrade to the Lombart CVSi21 for only \$2000 more or to the CVS-PC for only \$1500 more — Additional upgrades & configurations available.



(1-800-566-2278)

Call 1-800-Lombart

Or Your Local Lombart Representative.

Corporate Office - 5358 Robin Hood Road, Norfolk, VA 23513-2430
757-853-8888 | FAX 757-855-1232 | 800-566-2278 | 800-446-8092
www.lombartinstrument.com

ATLANTA•BALTIMORE/WASHINGTON D.C.•BOSTON•BOYNTON BEACH/MIAMI•BRADENTON•CHARLOTTE
CHICAGO•CINCINNATI•DALLAS•DENVER•DETROIT•GREENSBORO•HOUSTON•KANSAS CITY•KNOXVILLE•LOS ANGELES
MILWAUKEE•MINNEAPOLIS•NEW JERSEY/NEW YORK•NORFOLK•PORTLAND•SACRAMENTO•SAN DIEGO•SAN FRANCISCO

*Lease rate subject to credit approval, 1st payment is paid for by leasing company at signing with 59 remaining rental payments of \$269 and a \$1.00 purchase option. Taxes, freight and installation additional. Hand Instruments optional. Quantities limited. Subject to change without notice.

New Developments in the Pharmacologic Management of MGD

By Jimmy D. Bartlett, O.D., D.Sc.

Meibomian gland dysfunction (MGD) is a common clinical condition that can lead to alterations in the normal lipid composition of meibomian gland secretions. Lipid abnormalities can cause altered tear film composition and function, resulting in evaporative dry eye.^{1,2} Affected patients have associated discomfort, visual disturbances and possible contact lens intolerance.

Although we have observed and treated meibomian gland abnormalities for many decades, recognition of the condition's importance—and particularly, its therapeutic options—has been quite limited until recently.

This article explores contemporary developments in the treatment of MGD, and places a particular emphasis on its pharmacologic management.[#]

Use the Correct Terminology

The recommended definition of MGD is "a chronic, diffuse abnormality of the meibomian glands, commonly characterized by terminal duct obstruction and/or qualitative/quantitative changes in the glandular secretion. This may result in alteration of the tear film, symptoms of eye irritation, clinically apparent inflammation and ocular surface disease."²

Despite introduction of the term *meibomian gland dysfunction* in the early 1980s, many clinicians, unfortunately, still cling to the terms *posterior blepharitis*, *meibomitis* or *meibomianitis*. Although these designations are meaningful for the clinicians who still use them, the terms are often erroneously regarded as synonyms for MGD.

Posterior blepharitis, for example, refers more broadly to inflammatory conditions of the posterior eyelid margin, which may include—but are not limited to—MGD. Moreover, MGD is not always associated with inflammation.² The term MGD is appropriate to describe functional abnormalities of the meibomian glands, and it also emphasizes the important role meibomian glands play in tear film and ocular surface health.

Diagnose the Condition

Although meibography and confocal microscopy are used in the research laboratory to obtain objective assessments of meibomian gland structure, simple and standard clinical procedures are perfectly sufficient to make a diagnosis in most optometric offices.^{2,5} These assessments include tear film break-up time (TFBUT); evaluation of morphologic lid margin features, such

as thickening, meibomian gland orifice architecture, and vascularization; and lid expression to observe the quantity and quality of meibum (*Figure 1*).⁶

It is important to note, however, that many patients will have less obvious or "nonobvious" hyposecretory obstructive MGD, in which inflammation and other signs of pathology may be clinically absent unless specific examination procedures are employed. In fact, nonobvious MGD may actually be the most common form of the condition.⁷

Provide Effective Therapy

You must recognize that MGD treatments are designed to restore the normal flow of meibomian gland secretions, thus increasing the likelihood of a healthy tear film lipid layer and consequently reducing tear evaporation. This outcome will be achieved more effectively by physically removing material that is obstructing the gland ducts rather than by using pharmacologic therapies.⁸

However, clinical experience has taught us that a combination of interventions seems to be more effective than any one approach alone.

One or more of the following treatment modalities typically will

be required in any given patient:⁸

- *Physical gland expression to remove the obstructive material.*
- *Application of warm compresses to soften or liquefy solidified and obstructive gland contents.*
- *Lid scrubs to relieve external meibomian gland orifice blockage.*
- *Topical or systemic medications to suppress infection and inflammation, and to improve the lipid profile of the glands.*

In addition to standard therapy that includes warm compresses, lid massage and eyelid scrubs several times daily for at least two to four weeks, recently developed in-office treatments incorporate physical therapeutic measures that are designed to relieve meibomian gland obstruction.⁹ Invasive meibomian orifice penetration and intraductal probing seems to provide rapid and lasting symptom relief for many patients with obstructive MGD.¹⁰

Additionally, other patients are exhibiting a therapeutic benefit from a new procedure known as the LipiFlow Thermal Pulsation System (TearScience). This thermodynamic instrument applies heat directly to the conjunctival surfaces of the upper and lower inner eyelids while simultaneously applying pulsatile pressure to the outer eyelid surfaces to express the meibomian glands.¹¹ A single, 12-minute LipiFlow treatment can yield up to nine months of sustained improvement in meibomian gland function, TF BUT and ocular comfort.¹¹⁻¹⁴

Although systemic antibiotics may improve patient symptoms and meibomian gland lipid quality, there is no evidence that antibiotics can actually relieve the gland obstruction.

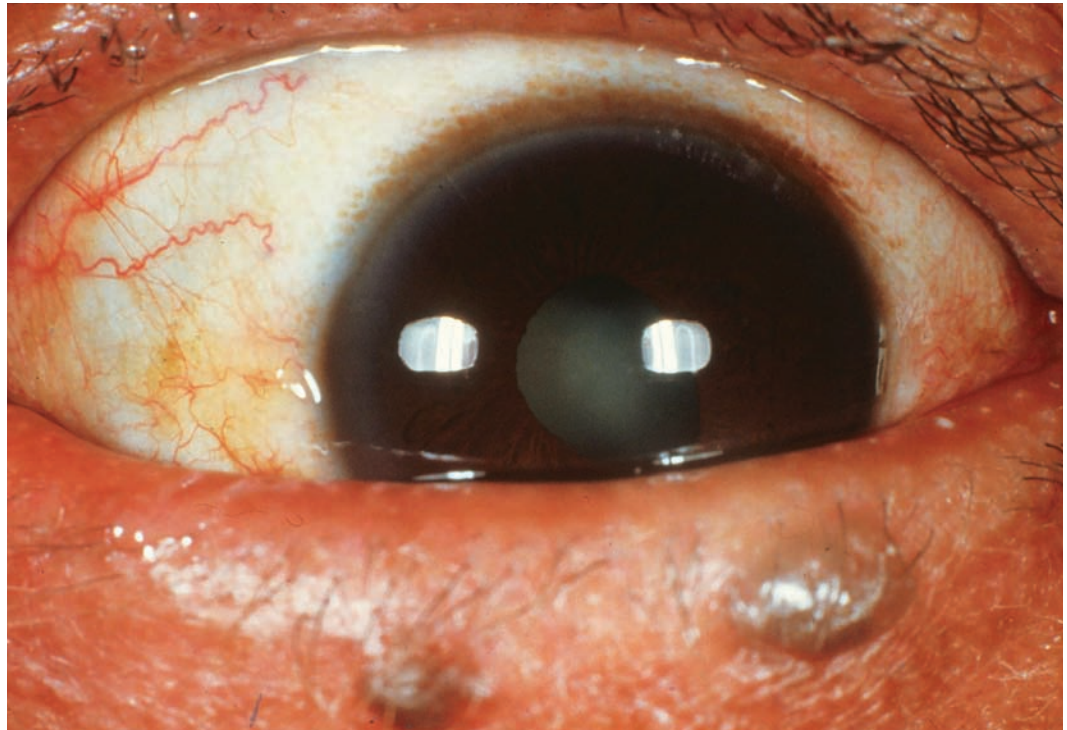


Figure 1. Stage 3 MGD. Note the rounded, thickened lid margin and thick, white meibum plugs present at several gland orifices in the lower lid.

Thus, antibiotics are best employed after—or in combination with—physical procedures such as heat and massage, which serve as the primary therapy.⁸

The pathophysiology of MGD is complex, and whether bacterial infection is an actual cause of MGD remains controversial.¹⁵ Most authorities believe there is no active bacterial infection involved in the pathogenesis of MGD; yet, bacterial products, such as lipases and various toxins (in the absence of infection), are believed to play a significant role.

Bacterial lipases alter lipid composition of the normal meibomian secretions, producing free fatty acids that have toxic and inflammatory effects on the ocular surface, which eventually leads to evaporative dry eye. Systemic antibiotics, such as tetracycline, doxycycline and minocycline, have been used widely in the management of MGD, because there is significant evidence that these medications—when used in doses that are non-antimicrobial—have suppressive effects on lipases and other inflammatory processes (e.g.,

expression of matrix metalloproteinases [MMPs] and tumor necrosis factor).^{15,16}

When used for the treatment of MGD or ocular rosacea, oral tetracycline commonly is prescribed in 250mg dosage q.i.d. Recently, however, 50mg to 100mg of doxycycline q.d. to b.i.d. has supplanted the use of tetracycline. Clinicians prefer doxycycline over tetracycline because it can be taken less frequently and its therapeutic effect isn't marginalized as significantly by the consumption of dairy products and antacids.¹⁷

In cases that are refractory to treatment, minocycline may be useful. This drug can promote a stable tear film, and has been shown to have a substantial biologic effect on meibomian fatty acid composition in patients with MGD.¹⁸ Minocycline typically is prescribed in a dosage of 50mg b.i.d.

When prescribing tetracyclines, it is important to advise patients regarding potential gastrointestinal side effects and the occurrence of photosensitivity. Doxycycline, in particular, should not be taken within 30 minutes of bedtime due to its potential to induce esopha-

Graded Treatment Algorithm for MGD

Stage	Clinical Description	Treatment
1	<ul style="list-style-type: none"> Minimally altered expressability and secretion quality. No symptoms. No corneal staining. 	<ul style="list-style-type: none"> Inform patient. Educate regarding diet, environmental factors for tear evaporation, and possible drying effects of systemic drugs. Consider warm compresses followed by lid expression.
2	<ul style="list-style-type: none"> Mildly altered expressability and secretion quality. Minimal to mild symptoms. None to limited corneal staining. 	<ul style="list-style-type: none"> Improve ambient humidity, increase dietary omega-3 intake. Warm compresses followed by lid massage and expression. Artificial tears. Topical azithromycin. Consider oral tetracycline derivatives.
3	<ul style="list-style-type: none"> Moderately altered expressability and secretion quality. Moderate symptoms. Mild to moderate corneal staining. 	<i>All of the above, plus:</i> <ul style="list-style-type: none"> Oral tetracycline derivatives. Lubricant ointment at bedtime. Anti-inflammatory therapy for dry eye, as needed.
4	<ul style="list-style-type: none"> Severely altered expressability and secretion quality. Marked symptoms. Marked corneal staining, including central. Increased signs of inflammation. 	<i>All of the above, plus:</i> <ul style="list-style-type: none"> Anti-inflammatory therapy for dry eye.

Adapted from: Geerling G, Tauber J, Baudouin C, et al. The international workshop on meibomian gland dysfunction: report of the subcommittee on management and treatment of meibomian gland dysfunction. *Invest Ophthalmol Vis Sci* 2011;52:2050-64.

gitis. Remember to avoid these antibiotics in children younger than eight years of age due to the risk of teeth discoloration. It is also important to warn females of childbearing age about the dangers of tetracycline use during pregnancy, as well as the disruptive effect that these antibiotics may have on oral contraception. Further, oral erythromycin may serve as a suitable alternative to tetracyclines in younger children.¹⁷ Recommended dosages for erythromycin range from 50mg/kg daily (divided every six to eight hours) to 250mg b.i.d.^{19,20} In general, these systemic antibiotics often require several weeks to exhibit a therapeutic effect and may need to be used for several months at a time.

Recently, there has been interest in the use of essential fatty acids in the management of MGD. When combined with eyelid hygiene, a group of patients who received once-daily omega-6 fatty acid supplementation (28.5mg of linoleic acid and 15mg of gamma-linolenic acid) demonstrated improved symptoms and reduction of eyelid

margin inflammation over a six-month period.²¹

Similarly, oral omega-3 fatty acid dietary supplementation also has been shown to benefit patients with MGD. One study showed that two 1,000mg capsules t.i.d. improved ocular comfort, TFBUT and quality of meibomian secretions.²²

In another pilot study, patients were placed on a daily commercial formulation of fish oil that contained 450mg, 300mg of DHA and 1,000mg of flaxseed oil (TheraTears Nutrition, Advanced Vision Research) for 90 days.²³ There was no significant effect in the meibum lipid composition or aqueous tear evaporation rate, but mean tear production and volume increased.

Consider Topical Therapy

Various topical medications have been found to have potential benefit in the treatment of MGD, including azithromycin, acetylcysteine and cyclosporine. Similar to the tetracycline class, macrolide antibiotics, such as azithromycin, exhibit anti-inflammatory

properties. Macrolides can inhibit the production of proinflammatory cytokines as well as the expression of MMPs.²⁴ When used alone or in conjunction with eyelid hygiene measures, topical azithromycin may have value in treating the signs and symptoms of MGD. However, inadequate research designs and low patient numbers in the published studies have hampered progress.²⁵⁻²⁷

The use of topical acetylcysteine represents a novel approach in the treatment of MGD and may offer a therapeutic benefit in some patients. When used q.i.d. for one month, acetylcysteine 5% solution can improve TFBUT and increase Schirmer scores.²⁸

Several published reports have illustrated the potential value of topical cyclosporine in the treatment of MGD.^{29,30} One study directly compared the efficacy of cyclosporine 0.05% (Restasis, Allergan) to that of tobramycin 0.3%/dexamethasone 0.1% (TobraDex, Alcon). After 12 weeks of treatment, cyclosporine provided a greater improvement in meibomian

secretion quality, lid telangiectasia, Schirmer scores, TFBUT and MGD-related symptoms.²⁹

In another study, researchers found that topical cyclosporine may be helpful in the treatment of MGD; however, the medication did not provide any improvement in symptoms after three months of dosing.³⁰ Specifically, improvements were limited to a reduction in the number of meibomian gland inclusions, lid margin vascular injection, tarsal telangiectasis and fluorescein staining.

Topical corticosteroids often are used to treat severe signs or symptoms in patients with inflammatory lid margin disease, including MGD. Take note, however, that while these drugs may provide immediate relief, they do not treat the underlying pathophysiology of MGD. Instead, topical corticosteroids are best reserved for short-term use or acute exacerbations during treatment.³¹ And of course, any patient on topical corticosteroid therapy requires regular IOP monitoring.

Finally, you must not forget that MGD is the most common cause of evaporative dry eye. So, almost all patients will benefit from the daily use of artificial tears. With our developing knowledge that MGD is associated with lipid deficiency and tear film instability, it is logical to conclude that patients may receive greater benefit from a lipid-based artificial tear. In fact, such formulations have been shown to both enhance and stabilize the lipid layer of the precorneal tear film, potentially providing improved ocular comfort when compared to non-lipid containing products.³²

For the eye doctor who is looking for a reasonable, evidence-based treatment protocol, the International Workshop on Meibomian Gland Dysfunction recently developed a staged management algorithm (see "Graded Treatment Algorithm for MGD," left).³¹ The algorithm characterizes the disease's progressive stages as well as provides appropriate treatment strategies.

Because the precise mechanism

of MGD remains elusive, it is unclear whether any of these current therapeutic interventions are palliative, provide indirect benefit, or directly mitigate underlying disease pathophysiology.³¹ Our limited understanding of the disease has hampered the development of pharmacologic interventions.

Presently, nevertheless, there is considerable enthusiasm among both clinicians and researchers alike to uncover the basic mechanisms of MGD in an effort to accelerate the development of new products, formulations or treatments that will address the unmet needs of our current and future patients.

Disclosure: There has been no specific regulatory approval of any pharmaceutical product or drug formulation for MGD. All drug dosing recommendations mentioned in this article must be considered an "off-label" application.

1. Foulks GN, Borchman D. Meibomian gland dysfunction: the past, present, and future. *Eye Contact Lens*. 2010 Sep;36(5):249-53
2. Nelson JD, Shimazaki J, Benitez-del-Castillo JM, et al. The international workshop on meibomian gland dysfunction: report of the definition and classification subcommittee. *Invest Ophthalmol Vis Sci*. 2011 Mar 30;52(4):1930-7.
3. Pult H, Nichols JJ. A review of meibography. *Optom Vis Sci*. 2012 May;89(5):E760-9.
4. Arita R, Itoh K, Maeda S, et al. Proposed diagnostic criteria for obstructive meibomian gland dysfunction. *Ophthalmology*. 2009 Nov;116(11):2058-63.e1.
5. Ibrahim OM, Matsumoto Y, Dogru M, et al. The efficacy, sensitivity, and specificity of in vivo laser confocal microscopy in the diagnosis of meibomian gland dysfunction. *Ophthalmology*. 2010 Apr;117(4):665-72.
6. Tomlinson A, Bron AJ, Korb DR, et al. The international workshop on meibomian gland dysfunction: report of the diagnosis subcommittee. *Invest Ophthalmol Vis Sci*. 2011 Mar 30;52(4):2006-49.
7. Blackie CA, Korb DR, Knop E, et al. Nonobvious obstructive meibomian gland dysfunction. *Cornea*. 2010 Dec;29(12):1333-45.
8. Blackie CA, Korb DR. MGD: Getting to the root cause of dry eye. *Rev Optom* 2012 Jul;149(7):30-9.
9. Foulks GN, Lemp MA. Meibomian Gland Dysfunction and Seborrhea. In: Krachmer JH, Mannis MJ, Holland EJ (eds.). *Cornea*. 3rd ed. St. Louis: Elsevier; 2011:407-13.
10. Maskin SL. Intraductal meibomian gland probing relieves symptoms of obstructive meibomian gland dysfunction. *Cornea*. 2010 Oct;29(10):1145-52.
11. Lane SS, DuBiner HB, Epstein RJ, et al. A new system, the LipiFlow, for the treatment of meibomian gland dysfunction. *Cornea*. 2012 Apr;31(4):396-404.
12. Korb DR, Blackie CA. Case Report: A successful LipiFlow treatment of a single case of meibomian gland dysfunction and dropout. *Eye Contact Lens*. 2012 Mar 12. [Epub ahead of print]
13. Korb DR, Blackie CA. Restoration of meibomian gland functionality with novel thermodynamic treatment device—a case report. *Cornea*. 2010 Aug;29(8):930-3.
14. Greiner JV. A single LipiFlow(R) Thermal Pulsation

System treatment improves meibomian gland function and reduces dry eye symptoms for 9 months. *Curr Eye Res*. 2012 Apr;37(4):272-8.

15. Knop E, Knop N, Millar T, et al. The international workshop on meibomian gland dysfunction: report of the subcommittee on anatomy, physiology, and pathophysiology of the meibomian gland. *Invest Ophthalmol Vis Sci*. 2011 Mar 30;52(4):1938-78.
16. Federici TJ. The non-antibiotic properties of tetracyclines: clinical potential in ophthalmic disease. *Pharmacol Res*. 2011 Dec;64(6):614-23.
17. Ganatra JB, Goldstein MH. Blepharitis. In: Yanoff M, Duker JS (eds.). *Ophthalmology*. St. Louis: Elsevier; 2009:307-36.
18. Souchier M, Joffre C, Gregoire S, et al. Changes in meibomian fatty acids and clinical signs in patients with meibomian gland dysfunction after minocycline treatment. *Br J Ophthalmol*. 2008 Jun;92(6):819-22.
19. Meisler DM, Raizman MB, Traboulsi EI. Oral erythromycin treatment for childhood blepharokeratitis. *J AAPOS*. 2000 Dec;4(6):379-80.
20. Hammersmith KM, Cohen EJ, Blake TD, et al. Blepharokeratoconjunctivitis in children. *Arch Ophthalmol*. 2005 Dec;123(12):1667-70.
21. Pinna A, Piccinini P, Carta F. Effect of oral linoleic and gamma-linolenic acid on meibomian gland dysfunction. *Cornea*. 2007 Apr;26(3):260-4.
22. Macsai MS. The role of omega-3 dietary supplementation in blepharitis and meibomian gland dysfunction (an AOS thesis). *Trans Am Ophthalmol Soc*. 2008;106:336-56.
23. Wojtowicz JC, Butovich I, Uchiyama E, et al. Pilot, prospective, randomized, double-masked, placebo-controlled clinical trial of an omega-3 supplement for dry eye. *Cornea*. 2011 Mar;30(3):308-14.
24. Luchs J. Azithromycin in DuraSite for the treatment of blepharitis. *Clin Ophthalmol*. 2010 Jul 30;4:681-8.
25. Luchs J. Efficacy of topical azithromycin ophthalmic solution 1% in the treatment of posterior blepharitis. *Adv Ther*. 2008 Sep;25(9):858-70.
26. Haque RM, Torkildsen GL, Brubaker K, et al. Multicenter open-label study evaluating the efficacy of azithromycin ophthalmic solution 1% on the signs and symptoms of subjects with blepharitis. *Cornea*. 2010 Aug;29(8):871-7.
27. Foulks GN, Borchman D, Yappert M, et al. Topical azithromycin therapy for meibomian gland dysfunction: clinical response and lipid alterations. *Cornea*. 2010 Jul;29(7):781-8.
28. Akyol-Salman I, Azizi S, Mumcu U, Baykal O. Efficacy of topical N-acetylcysteine in the treatment of meibomian gland dysfunction. *J Ocul Pharmacol Ther*. 2010 Aug;26(4):329-33.
29. Rubin M, Rao SN. Efficacy of topical cyclosporin 0.05% in the treatment of posterior blepharitis. *J Ocul Pharmacol Ther*. 2006 Feb;22(1):47-53.
30. Perry HD, Doshi-Carnevale S, Donnenfeld ED, et al. Efficacy of commercially available topical cyclosporine A 0.05% in the treatment of meibomian gland dysfunction. *Cornea*. 2006 Feb;25(2):171-5.
31. Geerling G, Tauber J, Baudouin C, et al. The international workshop on meibomian gland dysfunction: report of the subcommittee on management and treatment of meibomian gland dysfunction. *Invest Ophthalmol Vis Sci*. 2011 Mar 30;52(4):2050-64.
32. Korb DR, Scaffidi RC, Greiner JV, et al. The effect of two novel lubricant eye drops on tear film lipid layer thickness in subjects with dry eye symptoms. *Optom Vis Sci*. 2005 Jul;82(7):594-601.

The opinions expressed in this supplement to Review of Optometry do not necessarily reflect the views, or imply endorsement, of the editor or publisher.

Copyright 2012, Review of Optometry®. All rights reserved.

New Drugs in the Ophthalmic Pipeline

ROCK inhibitors, SEGRA compounds and SIRT proteins might be unfamiliar to you now. But you may soon see them in topical drops. **By Freddy W. Chang, O.D., Ph.D.**

The search for more potent, efficacious and target-selective drugs with minimal side effects remains an ongoing quest. It is a perpetual battle in the fight against diseases and, in the case of infections, the constant struggle against the development of resistant microorganisms.

We aim to target different mechanisms of the disease and

microorganisms to create a drug that is more efficacious, potent and selective with minimal adverse or side effects. We can accomplish this by synthesizing new drugs, modifying the molecule or the preparation of existing drugs, as well as by improving the kinetics, spectrum, efficacy, potency and adverse effect profile. Fortunately, investigators are making progress.

part of various important cellular functions, such as contraction of vascular smooth muscle cells, organization of the actin cytoskeleton, cell adhesion and motility, and gene expression.¹

ROCK inhibitors differ from the prostaglandin analogs—currently the first-line drugs in glaucoma therapy—in that their mechanism of action targets the conventional outflow facility through the trabecular meshwork in the anterior segment, rather than the uveoscleral outflow in the posterior segment. One study reported that treatment with a ROCK inhibitor, Y-27632, affected human trabecular meshwork and Schlemm’s canal cells to produce reversible changes in cell shape, focal adhesions and decreases in stress of the actin fibers. This resulted in an increase in permeability of the Schlemm cells’ monolayer by 80%.² Also, Y-27632 increased aqueous outflow facility by 40% to 80% in enucleated porcine eyes. This effect was due to the increase in extracellular spaces of the juxtacanalicular tissue.²

ROCK inhibitors have been shown to decrease intraocular

Here is a preview of some of the drugs in development in the ophthalmic pipeline.

Glaucoma

In glaucoma treatment, a new class of compounds—the Rho-kinase inhibitors (ROCK)—are at the forefront of promising drugs under study.

The Rho-kinase pathway is an integral

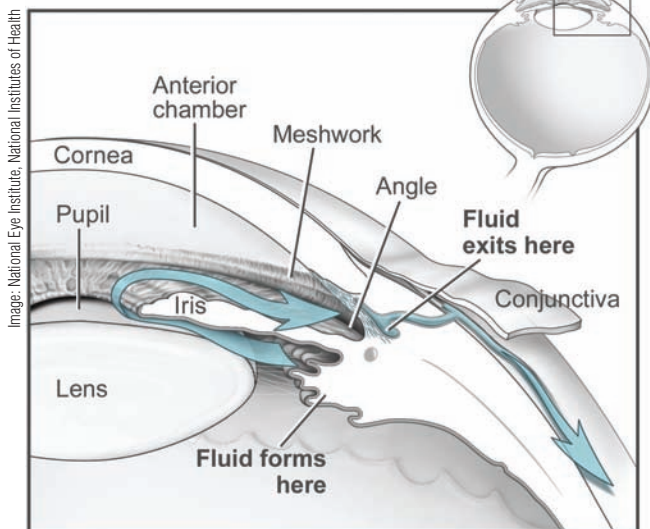


Image: National Eye Institute, National Institutes of Health

ROCK inhibitors differ from prostaglandin analogs because their mechanism of action targets outflow through the trabecular meshwork rather than the prostaglandin’s uveoscleral outflow.

Save the Date!



Mark your calendars for the

3rd Annual

West Coast Optometric Glaucoma Symposium



Course Director:
Murray Fingeret, OD

Speakers:

Michael Chaglasian, OD
John Flanagan, MCOptom, PhD
I. Ben Gaddie, OD
Sameh Mosaed, MD
Tony Realini, MD
Robert N. Weinreb, MD

3 WAYS TO REGISTER

Online: www.revoptom.com/2012WCOGS

Email: ReviewMeetings@Jobson.com

Call: Lois DiDomenico 877-451-6514

For questions, please email Denette Holmes at ReviewLogistics@jobson.com or call 866-627-0714.

December 14-15, 2012
Fairmont Newport Beach
Newport Beach, California

Limited time reservations for \$143/night
Call (949) 476-2001 and mention this program

Identify yourself as a participant of the West Coast
Optometric Glaucoma Symposium (WCOGS)

12 COPE Credits* for only \$125!

I invite you to join us for this comprehensive glaucoma symposium that will take place at the Fairmont Newport Beach in Newport Beach, California. We will have a group of renowned doctors who specialize in glaucoma. The program will consist of short talks and Q&A panels. Interaction with the faculty is a large part of the program. The agenda will cover the steps taken in establishing the diagnosis of glaucoma, information on new instrumentation and changing paradigms with regard to glaucoma therapy. The program runs Friday from 9:00 am – 6:00 pm, and Saturday from 8:00 am – 1:30 pm.

I look forward to seeing you in Newport Beach!
Murray Fingeret, OD

Partially supported by an educational grant from

Sponsored by

REVIEW
OF OPTOMETRY



*COPE approval pending

Alcon

Ophthalmic Drugs

pressure by 25% to 32% and have a duration of action of 10 to 12 hours, which suggests that the drug will be administered twice a day vs. once daily like the prosta-

glandin analogs. Nevertheless, this type of drug may be a great addition to the medication regimen for patients on a prostaglandin who fail to achieve the target pressure

Further Up the Pipeline

Here are just a few of the many promising ophthalmic medicines that are worth noting, although they're still in the early stages of development:

- **MC-1101.** This proprietary topical drop, developed by MacuClear, aims to stop dry AMD from progressing to wet AMD. A Phase Ib proof-of-concept trial found that topical instillation of MC-1101 was not only safe and well tolerated, but it also reached the macula, relaxed the epithelial lining of the vasculature, dilated choroidal blood vessels by stimulating nitric oxide production, and increased choroidal blood circulation.²⁶

The drop is administered with a novel delivery system (the VersiDoser, developed by Mystic Pharmaceuticals) that employs unit-dose, micro-pump “blisters” that are inserted into a small handheld pump sprayer to deliver a preservative-free uniform spray dose to the ocular surface.

The FDA has given MC-1101 official “Fast Track” status. A Phase II trial is in the works that will evaluate both the drug (dosed t.i.d.) as well as the vehicle.

- **EBI-005.** Eleven Biotherapeutics is developing EBI-005, an interleukin-1 receptor inhibitor for the treatment of dry eye syndrome.

In an inflammatory reaction, an abundance of cytokines, interleukin-1 and tumor necrosis factor are released, which stimulates the attached T-helper cell to secrete another cytokine, interleukin-2. The interleukin-2 stimulates the helper cell to multiply and develop specific antibodies to ward off the foreign objects. But by inhibiting the interleukin-1 receptor, EBI-005 halts the cascade and cuts short the inflammatory response. It was found to be more active than topical cyclosporine in a mouse model of dry eye syndrome.²⁷

- **SIRT1460.** The SIRT1 protein is an enzyme (histone deacetylase) that has the ability to suppress the expression of a variety of genes and thus influence a wide variety of biological processes.²⁸

Activating the SIRT1 protein together with a coenzyme (NAD) causes a deacetylation of the histone protein, which in turn silences the expression of the gene, which decreases the function of the proteins that promote the aging process. Thus, activation of the SIRT1 protein may play a significant role in metabolic, cardiovascular, neurodegenerative diseases and in inflammation. In short, this process is believed to extend lifespan.

SIRT1 activators may have potential as a novel class of compounds for the treatment of dry eye disease. For instance, investigators tested SIRT1460, dosed b.i.d., in a dry eye study in mice and significantly decreased corneal fluorescein staining (by 26% in the low-dose group and by 49% in the high-dose group).²⁹



Photos: Mystic Pharmaceuticals



MC-1101 will be administered with a novel pump sprayer, which is filled with a cartridge of unit-dose blisters.

required to prevent progression of the disease. Also, it may be indicated for patients who cannot tolerate the prostaglandin analogs.

Several ROCK inhibitors and other glaucoma drugs are now in development:

- **ATS907.** Atheos Inc. is running a Phase IIa clinical trial of ATS907, a ROCK-selective inhibitor for the reduction of intraocular pressure in ocular hypertensive and primary open angle patients. (ATS907 is one of a series of ROCK inhibitor compounds licensed from Asahi Kasei Pharma.) Preclinical data suggest that, in addition to its anti-inflammatory ability, ATS907 may have a neuroprotective effect and increase perfusion of the optic nerve.³

- **ATS8535.** Researchers reported on the efficacy of ATS8535 on IOP decrease in monkeys and in rabbits. Following a single dose of ATS8535 0.2% in monkeys, IOP decreased by 5mm Hg two to four hours post-dosing (from a mean baseline of 21.5-22.5mm Hg), and lasted for 10 to 12 hours. Similarly, one drop of ATS8535 0.08% produced a decrease of 7mm Hg in rabbits (from a mean baseline of 21.5-22.5mm Hg).⁴ Atheos has classified this drug as a candidate for development.

- **AR-12286.** This ROCK inhibitor, developed by Aerie Pharmaceuticals, is advancing to Phase III clinical trials. It demonstrated good efficacy, safety and tolerability in early trials.⁵ AR-12286 is also being developed in a fixed-dose combination with travoprost, which is in Phase III clinical trials; it demonstrated good additive effect with travoprost without producing the excessive hyperemia.⁶

- **AR-13324.** This lowers IOP by a dual mechanism—by increasing the outflow through the trabecular meshwork and by inhibiting

SWITCH TO THE POWER OF BEPREVE

For the treatment of itching associated with allergic conjunctivitis

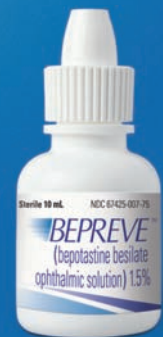Turn off itch—turn on comfort.



Discover the power to turn off ocular itching associated with allergic conjunctivitis—even for severe patients.

BEPREVE (bepotastine besilate ophthalmic solution) is indicated for the treatment of itching associated with allergic conjunctivitis. BEPREVE is for topical ophthalmic use only. To minimize risk of contamination, do not touch the dropper tip to any surface. Keep the bottle closed when not in use. BEPREVE should not be used to treat contact lens-related irritation. Remove contact lenses prior to instillation of BEPREVE. The most common adverse reaction occurring in approximately 25% of patients was a mild taste following instillation. Other adverse reactions occurring in 2%-5% of patients were eye irritation, headache, and nasopharyngitis.

Rx only. Please see full prescribing information.



Prescribe the Power.™

BEPREVE®

(bepotastine besilate
ophthalmic solution) 1.5%

HIGHLIGHTS OF PRESCRIBING INFORMATION

These highlights do not include all the information needed to use BEPREVE (bepotastine besilate ophthalmic solution) 1.5% safely and effectively.

See full prescribing information for BEPREVE.

BEPREVE
(bepotastine besilate ophthalmic solution) 1.5%

Initial U.S. Approval: 2009

INDICATIONS AND USAGE

BEPREVE is a histamine H₁ receptor antagonist indicated for the treatment of itching associated with allergic conjunctivitis. (1)

DOSAGE AND ADMINISTRATION

Instill one drop into the affected eye(s) twice a day (BID). (2)

DOSAGE FORMS AND STRENGTHS

Solution containing bepotastine besilate, 1.5%. (3)

FULL PRESCRIBING INFORMATION:

CONTENTS*

- 1 INDICATIONS AND USAGE
- 2 DOSAGE AND ADMINISTRATION
- 3 DOSAGE FORMS AND STRENGTHS
- 4 CONTRAINDICATIONS
- 5 WARNINGS AND PRECAUTIONS
 - 5.1 Contamination of Tip and Solution
 - 5.2 Contact Lens Use
 - 5.3 Topical Ophthalmic Use Only
- 6 ADVERSE REACTIONS
- 8 USE IN SPECIFIC POPULATIONS
 - 8.1 Pregnancy
 - 8.3 Nursing Mothers
 - 8.4 Pediatric Use
 - 8.5 Geriatric Use

WARNINGS AND PRECAUTIONS

- To minimize the risk of contamination, do not touch dropper tip to any surface. Keep bottle tightly closed when not in use. (5.1)
- BEPREVE should not be used to treat contact lens-related irritation. (5.2)
- Remove contact lenses prior to instillation of BEPREVE. (5.2)

ADVERSE REACTIONS

The most common adverse reaction occurring in approximately 25% of patients was a mild taste following instillation. Other adverse reactions which occurred in 2-5% of subjects were eye irritation, headache, and nasopharyngitis. (6)

To report SUSPECTED ADVERSE REACTIONS, contact ISTA Pharmaceuticals, Inc. at 1-877-788-2020, or FDA at 1-800-FDA-1088 or www.fda.gov/medwatch.

See 17 for PATIENT COUNSELING INFORMATION

Revised: 01/2010

11 DESCRIPTION

- 12 CLINICAL PHARMACOLOGY
 - 12.1 Mechanism of Action
 - 12.3 Pharmacokinetics
- 13 NONCLINICAL TOXICOLOGY
 - 13.1 Carcinogenesis, Mutagenesis and Impairment of Fertility
- 14 CLINICAL STUDIES
- 16 HOW SUPPLIED/STORAGE AND HANDLING
- 17 PATIENT COUNSELING INFORMATION
 - 17.1 Topical Ophthalmic Use Only
 - 17.2 Sterility of Dropper Tip
 - 17.3 Concomitant Use of Contact Lenses

*Sections or subsections omitted from the full prescribing information are not listed.

FULL PRESCRIBING INFORMATION

1 INDICATIONS AND USAGE

BEPREVE (bepotastine besilate ophthalmic solution) 1.5% is a histamine H₁ receptor antagonist indicated for the treatment of itching associated with signs and symptoms of allergic conjunctivitis.

2 DOSAGE AND ADMINISTRATION

Instill one drop of BEPREVE into the affected eye(s) twice a day (BID).

3 DOSAGE FORMS AND STRENGTHS

Topical ophthalmic solution containing bepotastine besilate 1.5%.

4 CONTRAINDICATIONS

None.

5 WARNINGS AND PRECAUTIONS

5.1 Contamination of Tip and Solution

To minimize contaminating the dropper tip and solution, care should be taken not to touch the eyelids or surrounding areas with the dropper tip of the bottle. Keep bottle tightly closed when not in use.

5.2 Contact Lens Use

Patients should be advised not to wear a contact lens if their eye is red. BEPREVE should not be used to treat contact lens-related irritation.

BEPREVE should not be instilled while wearing contact lenses. Remove contact lenses prior to instillation of BEPREVE. The preservative in BEPREVE, benzalkonium chloride, may be absorbed by soft contact lenses. Lenses may be reinserted after 10 minutes following administration of BEPREVE.

5.3 Topical Ophthalmic Use Only

BEPREVE is for topical ophthalmic use only.

6 ADVERSE REACTIONS

The most common reported adverse reaction occurring in approximately 25% of subjects was a mild taste following instillation. Other adverse reactions occurring in 2-5% of subjects were eye irritation, headache, and nasopharyngitis.

8 USE IN SPECIFIC POPULATIONS

8.1 Pregnancy

Pregnancy Category C. Teratogenicity studies have been performed in animals. Bepotastine besilate was not found to be teratogenic in rats during organogenesis and fetal development

at oral doses up to 200 mg/kg/day (representing a systemic concentration approximately 3,300 times that anticipated for topical ocular use in humans), but did show some potential for causing skeletal abnormalities at 1,000 mg/kg/day. There were no teratogenic effects seen in rabbits at oral doses up to 500 mg/kg/day given during organogenesis and fetal development (>13,000 times the dose in humans on a mg/kg basis). Evidence of infertility was seen in rats given oral bepotastine besilate 1,000 mg/kg/day; however, no evidence of infertility was observed in rats given 200 mg/kg/day (approximately 3,300 times the topical ocular use in humans). The concentration of radiolabeled bepotastine besilate was similar in fetal liver and maternal blood plasma following a single 3 mg/kg oral dose. The concentration in other fetal tissues was one-third to one-tenth the concentration in maternal blood plasma.

An increase in stillborns and decreased growth and development were observed in pups born from rats given oral doses of 1,000 mg/kg/day during perinatal and lactation periods. There were no observed effects in rats treated with 100 mg/kg/day.

There are no adequate and well-controlled studies of bepotastine besilate in pregnant women. Because animal reproduction studies are not always predictive of human response, BEPREVE (bepotastine besilate ophthalmic solution) 1.5% should be used during pregnancy only if the potential benefit justifies the potential risk to the fetus.

8.3 Nursing Mothers

Following a single 3 mg/kg oral dose of radiolabeled bepotastine besilate to nursing rats 11 days after delivery, the maximum concentration of radioactivity in milk was 0.40 µg-eq/mL 1 hour after administration; at 48 hours after administration the concentration was below detection limits. The milk concentration was higher than the maternal blood plasma concentration at each time of measurement.

It is not known if bepotastine besilate is excreted in human milk. Caution should be exercised when BEPREVE (bepotastine besilate ophthalmic solution) 1.5% is administered to a nursing woman.

8.4 Pediatric Use

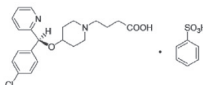
Safety and efficacy of BEPREVE (bepotastine besilate ophthalmic solution) 1.5% have not been established in pediatric patients under 2 years of age. Efficacy in pediatric patients under 10 years of age was extrapolated from clinical trials conducted in pediatric patients greater than 10 years of age and from adults.

8.5 Geriatric Use

No overall difference in safety or effectiveness has been observed between elderly and younger patients.

11 DESCRIPTION

BEPREVE (bepotastine besilate ophthalmic solution) 1.5% is a sterile, topically administered drug for ophthalmic use. Each mL of BEPREVE contains 15 mg bepotastine besilate. Bepotastine besilate is designated chemically as (+)-4-[[[S]-p-chloro-alpha -2-pyridylbenzyl]oxy]-1-piperidine butyric acid monobenzenesulfonate. The chemical structure for bepotastine besilate is:



Bepotastine besilate is a white or pale yellowish crystalline powder. The molecular weight of bepotastine besilate is 547.06 daltons. BEPREVE ophthalmic solution is supplied as a sterile, aqueous 1.5% solution, with a pH of 6.8.

The osmolality of BEPREVE (bepotastine besilate ophthalmic solution) 1.5% is approximately 290 mOsm/kg.

Each mL of BEPREVE (bepotastine besilate ophthalmic solution) 1.5% contains:

- Active:** Bepotastine besilate 15 mg (equivalent to 10.7 mg bepotastine)
- Preservative:** benzalkonium chloride 0.005%
- Inactives:** monobasic sodium phosphate dihydrate, sodium chloride, sodium hydroxide to adjust pH, and water for injection, USP.

12 CLINICAL PHARMACOLOGY

12.1 Mechanism of Action

Bepotastine is a topically active, direct H₁-receptor antagonist and an inhibitor of the release of histamine from mast cells.

12.3 Pharmacokinetics

Absorption: The extent of systemic exposure to bepotastine following topical ophthalmic administration of bepotastine besilate 1% and 1.5% ophthalmic solutions was evaluated in 12 healthy adults. Following one drop of 1% or 1.5% bepotastine besilate ophthalmic solution to both eyes four times daily (QID) for seven days, bepotastine plasma concentrations peaked at approximately one to two hours post-instillation. Maximum plasma concentration for the 1% and 1.5% strengths were 5.1 ± 2.5 ng/mL and 7.3 ± 1.9 ng/mL, respectively. Plasma concentration at 24 hours post-instillation were below the quantifiable limit (2 ng/mL) in 11/12 subjects in the two dose groups.

Distribution: The extent of protein binding of bepotastine is approximately 55% and independent of bepotastine concentration.

Metabolism: *In vitro* metabolism studies with human liver microsomes demonstrated that bepotastine is minimally metabolized by CYP450 isozymes.

In vitro studies demonstrated that bepotastine besilate does not inhibit the metabolism of various cytochrome P450 substrate via inhibition of CYP3A4, CYP2C9, and CYP2C19. The effect of bepotastine besilate on the metabolism of substrates of CYP1A2, CYP2C8, CYP2D6 was not studied. Bepotastine besilate has a low potential for drug interaction via inhibition of CYP3A4, CYP2C9, and CYP2C19.

Excretion: The main route of elimination of bepotastine besilate is urinary excretion (with approximately 75-90% excreted unchanged in urine).

13 NONCLINICAL TOXICOLOGY

13.1 Carcinogenesis, Mutagenesis and Impairment of Fertility

Long-term dietary studies in mice and rats were conducted to evaluate the carcinogenic potential of bepotastine besilate. Bepotastine besilate did not significantly induce neoplasms in mice receiving a nominal dose of up to 200 mg/kg/day for 21 months or rats receiving a nominal dose of up to 97 mg/kg/day for 24 months. These dose levels represent systemic exposures approximating 350 and 200 times that achieved with human topical ocular use.

The no observable adverse effect levels for bepotastine besilate based on nominal dose levels in carcinogenicity tests were 18.7 to 19.9 mg/kg/day in mice and 9.6 to 9.8 mg/kg/day in rats (representing exposure margins of approximately 60 and 20 times the systemic exposure anticipated for topical ocular use in humans).

There was no evidence of genotoxicity in the Ames test, in CHO cells (chromosome aberrations), in mouse hepatocytes (unscheduled DNA synthesis), or in the mouse micronucleus test.

When oral bepotastine was administered to male and female rats at doses up to 1,000 mg/kg/day, there was a slight reduction in fertility index and surviving fetuses. Infertility was not seen in rats given 200 mg/kg/day oral bepotastine besilate (approximately 3,300 times the systemic concentration anticipated for topical ocular use in humans).

14 CLINICAL STUDIES

Clinical efficacy was evaluated in 2 conjunctival allergen challenge (CAC) studies (237 patients). BEPREVE (bepotastine besilate ophthalmic solution) 1.5% was more effective than its vehicle for relieving ocular itching induced by an ocular allergen challenge, both at a CAC 15 minutes post-dosing and a CAC 8 hours post dosing of BEPREVE.

The safety of BEPREVE was evaluated in a randomized clinical study of 861 subjects over a period of 6 weeks.

16 HOW SUPPLIED/STORAGE AND HANDLING

BEPREVE (bepotastine besilate ophthalmic solution) 1.5% is supplied in a white low density polyethylene plastic squeeze bottle with a white controlled dropper tip and a white polypropylene cap in the following size:

5 mL (NDC 67425-007-50)
10 mL (NDC 67425-007-75)

STORAGE

Store at 15° – 25°C (59° – 77°F).

17 PATIENT COUNSELING INFORMATION

17.1 Topical Ophthalmic Use Only

For topical ophthalmic administration only.

17.2 Sterility of Dropper Tip

Patients should be advised to not touch dropper tip to any surface, as this may contaminate the contents.

17.3 Concomitant Use of Contact Lenses

Patients should be advised not to wear a contact lens if their eye is red. Patients should be advised that BEPREVE should not be used to treat contact lens-related irritation.

Patients should also be advised to remove contact lenses prior to instillation of BEPREVE. The preservative in BEPREVE, benzalkonium chloride, may be absorbed by soft contact lenses. Lenses may be reinserted after 10 minutes following administration of BEPREVE.

Rx only

Manufactured for: ISTA Pharmaceuticals®, Inc.
Irvine, CA 92618

By: Bausch & Lomb Incorporated
Tampa, FL 33637

Under license from:
Sanju Pharmaceutical Co., Ltd.
Osaka, Japan 541-004

® and ™ marks owned by ISTA Pharmaceuticals, Inc.
U.S. Patents: 6,307,052; 6,780,877

© 2010 ISTA Pharmaceuticals, Inc.

BRV859-7/10

the norepinephrine transporter to decrease aqueous production. In a 10-day rabbit study, a once-daily drop of AR-13324 0.04% reduced IOP by up to 7.1mm Hg at four hours post-dosing (from a mean baseline of 24.8-28.0mm Hg).⁷ A study in normotensive monkeys reported that a single-dose administration of AR-13324 0.04% increased outflow facility by 53% after six hours, while the aqueous inflow decreased by 23%, and IOP decreased by 25%.⁸

- **AMA0076.** This potent ROCK inhibitor, being developed by Amakem NV, is intended to permit high-dose topical administration with minimal systemic side effects.⁹ Investigators recently presented the results of their study on the effect of benzalkonium chloride (BAK) on the pressure-lowering ability of AMA0076 in rabbits. They compared AMA0076 0.1%, 0.3% and 0.5% with and without 0.015% BAK. After the administration of one drop of AMA0076 with and without BAK unilaterally, IOP declined by 21%, 28% and 37% for 0.1%, 0.3% and 0.5% respectively without BAK, while IOP decreased by 38%, 45% and 53% with BAK.⁹

- **BOL-303259-X.** This is not a ROCK inhibitor, but a novel nitric oxide-donating prostaglandin F2-alpha analog developed by NicOx S.A. and now investigated by Bausch + Lomb. Nitric oxide has vasodilatory properties and plays a role in inflammatory and immune responses, reproductive functions, bronchodilation and other processes.

Top-line results from a Phase IIb study that compared once-nightly BOL-303259-X vs. once-nightly latanoprost 0.005% showed notable reduction in mean diurnal IOP at one month.¹⁰ Two of the

four doses tested showed greater IOP reduction than that achieved with latanoprost. The most efficacious dose of BOL-303259-X also showed consistently better IOP control over 24 hours, as well as a statistically significant greater percentage of responders (patients who achieved an IOP of 18mm Hg or less) compared to latanoprost. The responder rate was 68.7% for the most efficacious dose of BOL-303259-X compared to 47.5% for latanoprost.¹⁰ The drug's safety and adverse events (i.e., hyperemia) were comparable to latanoprost. Bausch + Lomb anticipates a Phase III trial in the future.

Anti-Infectives

- **NVC-422.** This aganocide compound, developed by NovaBay, is beginning a Phase IIb clinical trial to treat adenoviral conjunctivitis.

Aganocides belong to a novel class of compounds that mimic the body's natural defense against infection. The aganocides have demonstrated a greater in vitro therapeutic index than existing topical antiseptics. Aganocides also possess a reduced likelihood to develop resistance to bacteria or viruses.

NVC-422 is the first synthetic N-chlorinated taurine molecule to maintain antimicrobial activity and improved stability over the body's naturally occurring N-chlorinated taurine. It exhibits a broad spectrum of activity against bacteria, viruses, yeasts and fungi. It is also effective against multi-drug resistant bacteria, such as methicillin-resistant *Strep. aureus* (MRSA) and vancomycin-resistant *Enterococcus* (VRE).¹¹ NVC-422 is fast acting; it can eradicate bacteria in minutes, even at low doses.

NovaBay Pharmaceuticals is investigating a topical ophthalmic formulation of NVC-422 for viral conjunctivitis.¹² The drug is also being developed for dermatology, urology and hospital-based infections.

- **FST-100.** This is another antibiotic for the treatment of adenoviral conjunctivitis. Developed by Foresight Biotherapeutics, FST-100 is a combination suspension that targets microbial eradication (using povidone-iodine) while decreasing the inflammation associated with ocular infections (using dexamethasone).¹³ Povidone-iodine is

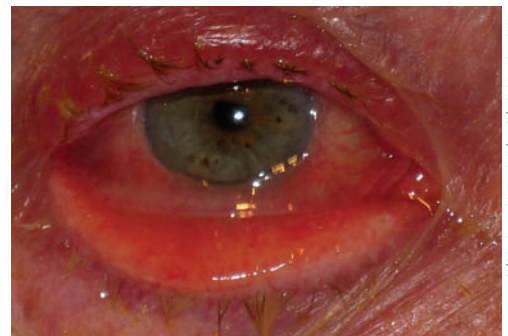

Photo: Ron Melton, O.D., and Randall Thomas, O.D.

Different antimicrobial topical drops are being developed to target adenoviral conjunctivitis.

a broad-spectrum antiseptic with antimicrobial activity; it is widely used as a surgical scrub and as a prophylactic for neonatal conjunctivitis. Its mechanism of action is iodination of lipids and oxidation of cytoplasmic and membrane compounds, and it has minimal development of resistance.¹³ While the dexamethasone is not synergistic with the antiviral effect of the povidone-iodine, it minimizes the irritating and associated inflammatory effect of the povidone-iodine solution. A Phase II trial is scheduled to begin in October.

Anti-Inflammatory Agents

Several novel anti-inflammatory agents have been developed to

Some Things Are Supposed To Come in



3's

Is Your Eye Care Practice **Missing** Something?

If your practice is just doing exams and running a dispensary, you're missing out on your third profit center – in-office processing. Offer your patients faster turnaround, better quality control and increase your profitability at the same time.

Not convinced? Visit www.inofficeprocessing.com to calculate your ROI, figure out how much space you'll need and more!

Ophthalmic Drugs

deliver the power of corticosteroids, but without the adverse effects.

- **Luveniq.** Lux Biosciences has completed Phase III trials of Luveniq (voclosporin, formerly LX211) an oral capsule for the treatment of non-infectious uveitis. Voclosporin, a novel immunomodulatory drug that inhibits the calcineurin enzyme, was originally developed to prevent organ graft rejection and to treat autoimmune diseases. The chemical structure of voclosporin is similar to that of cyclosporine A, but with a difference in one amino acid, leading to superior calcineurin inhibition and less variability in plasma concentration.¹⁴

Lux Biosciences anticipates that data from the Phase III trials will be available in early 2013. (The company had previously submitted a New Drug Application for Luveniq in 2010, but the FDA requested additional clinical data. This trial aims to satisfy the FDA's request.)

- **ESBA105.** This is a single-chain antibody fragment that targets tumor necrosis factor-alpha (TNF-alpha), a major mediator of inflammation.¹⁵ Selective inhibition of TNF-alpha has the potential of modulating the inflammatory and immune response. ESBA105 will be indicated in non-infective inflammatory diseases of the eye.

Preclinical studies have demonstrated that topically administered ESBA105 attains therapeutic levels in both the anterior and posterior segments of the eye, and may have potential for the treatment of ocular diseases mediated by TNF-alpha.¹⁶

A Phase IIa study of the drug, conducted by developer ESBA Tech, is directed at patients with acute anterior uveitis. The company has since been acquired by Alcon, which is conducting a Phase II trial of ESBA105 for severe dry eye. Topical application of ESBA105 also reduced the formation of choroidal neovascularization, indicating its use in the prevention and treatment of age-related macular degeneration.¹⁷

- **Mapracorat.** Mapracorat (ZK 245186/BOL-303242-X, developed by Bausch + Lomb) is a new type of anti-inflammatory with a non-steroidal chemical structure for the treatment of anterior segment conditions. It is a selective glucocorticoid receptor agonist (SEGRA)—it is designed with similar anti-inflammatory and immunosuppressive effects as the glucocorticoids but with a decreased potential of the steroid side effects.¹⁸

Currently, a Phase II study is evaluating its effectiveness in preventing the signs and symptoms of allergic conjunctivitis. In addition, a Phase III study is

The Complete Digital Eye Exam

SIMPLIFIED • DIGITIZED • PERSONALIZED



OWRx

Digital Screening



Quickly acquire precise patient's Rx with OWRx Digital Screening and the Huvitz HRK-8000A

- Combines aberrometer, auto-refractor/keratometer
- HOA blended correction with advanced OWR algorithm
- Rx accuracy up to 0.01 Diopter
- Prescribe Digital Freeform Lenses

Enhanced IMAGE

SPECIAL
Limited Time Offer
\$14,995.00
with qualified trade-in



136 W. Orion Street | Suite 3 | Tempe, Arizona | 85283

888.315.1256

www.voi2020.com

He's known for precision
and outstanding performance.
So are his lenses.

A lens that provides outstanding performance with an easy fit

- Outperforms ACUVUE[^] OASYS[^] for ASTIGMATISM contact lenses in overall comfort, vision, and handling^{1,2**}
- Precision Balance 8I4[™] Lens Design allows for exceptional lens stability
- 95% first-fit success rate³

Visit myalcon.com to learn more.



*AIR OPTIX[®] for Astigmatism (Iotrafilcon B) contact lenses: Dk/t = 108 @ -3.00D -1.25 X 180. [^]Trademarks are the property of their respective owners. ^{**}Based on patient ratings at 2 weeks.

Important information for AIR OPTIX[®] for Astigmatism (Iotrafilcon B) contact lenses: For daily wear or extended wear up to 6 nights for near/far-sightedness, and astigmatism. Risk of serious eye problems (i.e. corneal ulcer) is greater for extended wear. In rare cases, loss of vision may result. Side effects like discomfort, mild burning or stinging may occur.

References: **1.** Brobst A, Wang C, Rappon J. Clinical comparison of the visual performance of silicone hydrogel toric lenses with different stabilization systems. *Cont Lens Ant Eye.* 2009;32:243. **2.** In a subject-masked, randomized clinical study at 14 sites with 154 patients; significance demonstrated at the 0.05 level; Alcon data on file, 2008. **3.** In a randomized, subject-masked, multi-site clinical study with over 150 patients; significance demonstrated at the 0.05 level; Alcon data on file, 2005.

See product instructions for complete wear, care, and safety information.

Alcon[®]

© 2012 Novartis 2/12 AOT12002JAD

Rx only

Ophthalmic Drugs

underway for the treatment of ocular inflammation after cataract surgery.

- **Nepafenac 0.3%.** Alcon Laboratories has completed a Phase III clinical trial of a new 0.3% formulation of its NSAID Nevanac (currently approved as nepafenac 0.1%) for the treatment and prevention of pain and inflammation following cataract surgery.¹⁹ Although this is the same active ingredient as in Nevanac, the formulation is being changed to improve the pharmacokinetics and/or to modify or change the preservative. No study results have been posted yet.

- **BromSite.** InSite Vision announced favorable results from Phase I/II clinical trials of BromSite (or ISV-303, 0.075% bromfenac in its patented DuraSite polymer vehicle), a topical anti-inflammatory agent for the reduction of pain and inflammation after cataract surgery.²⁰ The Phase II pharmacokinetic study compared BromSite vs. bromfenac 0.09% alone, and found BromSite dosed b.i.d. had more than twice the mean concentration in the aqueous humor compared to bromfenac b.i.d. InSite Vision is now recruiting subjects for a Phase III trial.

- **DexaSite.** The active ingredient in InSite Vision's DexaSite (or ISV-305) is low-dose (0.1%) dexamethasone formulated in its DuraSite vehicle. DexaSite is intended to decrease the signs and symptoms of non-infectious blepharitis. So far, results show that it is a safe and efficacious therapy for blepharoconjunctivitis.²¹ The start date for its Phase III trial is March 2013, with completion expected in January 2014.

- **AzaSite Plus.** Another entry from InSite Vision, AzaSite Plus (or ISV-502) is topical azithromycin 1% (like regular AzaSite) with the addition of dexamethasone 0.1%. Besides their antimicrobial activity, the macrolide antibiotics (including azithromycin) also have been shown to possess anti-inflammatory properties.²² The addition of dexamethasone to this formulation should provide a genuine anti-inflammatory effect.²³ InSite Vision currently is recruiting participants for a new Phase III study for the treatment of non-bacterial blepharitis.

Dry Eye Drugs

In the area of dry eye treatment, new pharmaceutical development is targeting aspects of the inflammatory cascade.

- **CF101.** Adenosine is a neurotransmitter with a very short half-life that not only acts peripherally, but also has a role in the central nervous system. Adenosine has been shown to inhibit leukotriene B4 (LTB4), which is part of the arachidonic acid cascade for the

The Complete Digital Eye Exam

SIMPLIFIED • DIGITIZED • PERSONALIZED



OWRx Digital Eye Exam



Enjoy Refracting Again!

- Reduce stress and strain
- Increase patient throughput
- Increase revenues
- Blended HOA correction
- Patient WOW factor!



Special Limited Time Offer
FREE
Digital Camera
or \$3,000 Phoropter trade-in*
with Digital Eye Exam Purchase
*On qualified models

Enhanced REFRACTING



136 W. Orion Street | Suite 3 | Tempe, Arizona | 85283

888.315.1256

www.voi2020.com



Celebrate 90 Years with the American Academy of Optometry!

Engage in scientific dialogue and debate on the latest practices at Academy 2012 Phoenix. Actively develop your knowledge and skills as a vision scientist or practitioner. As always, the Academy brings you unparalleled education, now in the radiant beauty of Phoenix. See you there!

Academy 2012 Phoenix
October 24-27, 2012

Register today!
www.aaopt.org

Ophthalmic Drugs

synthesis of prostaglandins and leukotrienes.

An adenosine A3 receptor agonist, CF101, is a small molecule drug that has shown efficacy and an excellent safety profile in Phase II trials.²⁴ Dosed orally once daily, the drug is now in a multi-centered Phase III clinical trial of patients with moderate to severe dry eye. It is concurrently being developed for uveitis and glaucoma. The dry eye and uveitis indications take advantage of the anti-inflammatory effects of the drug. The rationale for conducting the glaucoma study (now in Phase II) is due to an unexpected IOP decrease of 1.1mm Hg in its Phase II dry eye trial.²⁴

• **Lifitegrast.** Previously known as SAR 1118, developed by SARcode Bioscience, lifitegrast is a potent and selective small molecule drug being investigated for the treatment of dry eye and ocular allergy. It inhibits T-cell inflammation by blocking the binding of two key cellular surface proteins that mediate the chronic inflammatory cascade.

In a Phase II trial of 230 dry eye patients, lifitegrast was well tolerated with mild ocular adverse events, and demonstrated significant improvements in tear production and symptoms within two weeks.²⁵ A Phase III trial for dry eye is currently recruiting subjects. The Phase II study for allergic conjunctivitis has been completed, but no results have yet been announced.

There are a number of other new and emerging ophthalmic drugs in the pipeline—too many to include in this article.

Sometimes we get frustrated with the many conditions we can't treat or have difficulty treating. But if you stop to consider the various drugs currently available and the number of new meds coming our way, this really is a good time to be in eye care. ■

Dr. Chang is a professor at Southern College of Optometry and teaches courses and laboratories in the areas of pharmacology, ocular physiology, systemic health and contact lenses.

1. Shimokawa H, Takeshita A. Rho-kinase is an important therapeutic target in cardiovascular medicine. *Arterioscler Thromb Vasc Biol.* 2005 Sep;25(9):1767-75.
2. Rao PV, Deng PF, Kumar J, Epstein DL. Modulation of aqueous humor outflow facility by the Rho kinase-specific inhibitor Y-27632. *Invest Ophthalmol Vis Sci.* 2001 Apr;42(5):1029-37.
3. Altheos website. Altheos Announces Initiation of Phase 2a Clinical Trial for its Lead Glaucoma Drug Candidate, ATS907. Available at: <http://alltheos.net/9-February-2012-Phase-2a-Clinical-Trial.html>. Accessed August 23, 2012.
4. Wirosko BM, Umeno H, Hsu H, Kengatharan M. Safety and efficacy of a novel topical Rho kinase inhibitor ATS8535 in vivo. #5079/A220. Poster presented at Association for Research in Vision and Ophthalmology meeting, May 9, 2012; Ft. Lauderdale, Fla.
5. Williams RD, Novack GD, van Haarlem T, Kocpzyński C. AR-12286 Phase 2A Study Group. Ocular hypotensive effect of the Rho kinase inhibitor AR-12286 in patients with glaucoma and ocular hypertension. *Am J Ophthalmol.* 2011 Nov;152(5):834-41.
6. Kocpzyński CC. Rho kinase inhibitors for glaucoma. Presentation at 4th Ocular Diseases

The Complete Digital Eye Exam

SIMPLIFIED • DIGITIZED • PERSONALIZED



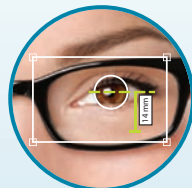
OWRx

Digital Dispensing



Image Capture

- Sonar based
- Ergonomic
- User Friendly



Digital Measurements

- Sonar based
- No frame attachments
- Reduce remakes



Digital Demonstrations

- High index lenses
- Anti-reflective coatings
- Frame try on

Enhanced REVENUES

SPECIAL
Introductory Offer
\$7,695.00



136 W. Orion Street | Suite 3 | Tempe, Arizona | 85283

888.315.1256

www.voi2020.com

Ophthalmic Drugs

& Drug Discovery meeting, Feb. 27, 2012; Las Vegas.

7. Kocpzyński C, Lin C-W, deLong M, et al. IOP lowering efficacy and tolerability of AR-13324, a dual mechanism kinase inhibitor for the treatment of glaucoma. #5080/A221. Poster presented at Association for Research in Vision and Ophthalmology meeting, May 9, 2012; Ft. Lauderdale, Fla.
8. Wang RF, Serle J, Kocpzyński C. Effect of 0.04% AR-13324 on aqueous humor dynamics in normotensive monkey eyes. #1994/D838. Poster presented at Association for Research in Vision and Ophthalmology meeting, May 7, 2012; Ft. Lauderdale, Fla.
9. Hollanders KP, Sijnave D, Van Bergen, et al. The effect of benzalkonium chloride on the intraocular pressure lowering efficacy of a local ROCK-inhibitor (AMA0076). #1974/D818. Poster presented at Association for Research in Vision and Ophthalmology meeting, May 7, 2012; Ft. Lauderdale, Fla.
10. Bausch + Lomb website. NicOx, Bausch + Lomb glaucoma candidate BOL 303259 X meets primary endpoint in Phase 2b study. March 13, 2012. Available at: www.bausch.com/en/Our-Company/Recent-News/2012-Archive/NicOx. Accessed August 28, 2012.
11. Wang L, Belisle B, Bassiri M, et al. Chemical characterization and biological properties of NVC-422, a novel, stable N-chlorotaurine analog. Antimicrob Agents Chemother. 2011 Jun;55(6):2688-92.
12. Yoon J, Jekle A, Najafi R, et al. Virucidal mechanism of action of NVC-422, a novel antimicrobial drug for the treatment of adenoviral conjunctivitis. Antiviral Res. 2011 Dec;92(3):470-8. Epub 2011 Oct 15.
13. Clement C, Capriotti JA, Kumar M, et al. Clinical and antiviral efficacy of an ophthalmic formulation of dexamethasone povidone-iodine in a rabbit model of adenoviral keratoconjunctivitis. Invest Ophthalmol Vis Sci. 2011 Jan 21;52(1):339-44.
14. Roessel M, Tappeiner C, Heiligenhaus A, Heinz C. Oral

- voclosporin: novel calcineurin inhibitor for treatment of non-infectious uveitis. Clin Ophthalmol. 2011;5:1309-13.
15. Furrer E, Berdugo M, Stella C, et al. Pharmacokinetics and posterior segment biodistribution of ESBA105, an anti-TNF-alpha single-chain antibody, upon topical administration to the rabbit eye. Invest Ophthalmol Vis Sci. 2009 Feb;50(2):771-8.
16. Ottiger M, Thiel MA, Feige U, et al. Efficient intraocular penetration of topical anti-TNF-alpha single-chain antibody (ESBA105) to anterior and posterior segment without penetration enhancer. Invest Ophthalmol Vis Sci. 2009 Feb;50(2):779-86.
17. Lichten P, Lam TT, Nork TM, et al. Relative contribution of VEGF and TNF-alpha in the cynomolgus laser-induced CNV model: comparing the efficacy of bevacizumab, adalimumab, and ESBA105. Invest Ophthalmol Vis Sci. 2010 Sep;51(9):4738-45.
18. Ehrchen J, Steinmüller L, Barczyk K, et al. Glucocorticoids induce differentiation of a specifically activated, anti-inflammatory subtype of human monocytes. Blood. 2007 Feb 1;109(3):1265-74.
19. ClinicalTrials.gov website. Confirmatory Study Nepafenac 0.3%. Last Updated on July 17, 2012. Available at: <http://clinicaltrials.gov/ct2/show/NCT01109173>. Accessed August 30, 2012.
20. InSite Vision website. InSite Vision Initiates the First Phase 3 Clinical Study of BromSite for the Reduction of Pain and Inflammation after Cataract Surgery. July 31, 2012. Available at: <http://phx.corporate-ir.net/phoenix.zhtml?c=86061&p=irol-newsArticle&ID=1720524>. Accessed August 30, 2012.
21. Hosseini K, Hutcheson J, Bowman LM. Clinical response of dexamethasone 0.1% formulated in DuraSite on blepharokeratoconjunctivitis patients. #4247/D991. Poster presented at Association for Research in Vision and Ophthalmology meeting, May 4, 2011; Ft. Lauderdale, Fla.
22. Ianaro A, Ialenti A, Maffia P, et al. Anti-inflammatory activity of macrolide antibiotics. J Pharmacol Exp Ther. 2000 Jan;292(1):156-63.
23. Si EC, Hutcheson J, Hosseini K. Antimicrobial efficacy of azithromycin/dexamethasone combination in blepharokeratoconjunctivitis patients, a Phase 3 study. #2888/D1112. Poster presented at Association for Research in Vision and Ophthalmology meeting, May 4, 2010; Ft. Lauderdale, Fla.
24. Avni I, Garozzi HJ, Barequet IS, et al. Treatment of dry eye syndrome with orally administered CF101: data from a phase 2 clinical trial. Ophthalmology. 2010 Jul;117(7):1287-93.
25. Semba CP, Torkildsen GL, Lonsdale JD, et al. A phase 2 randomized, double-masked, placebo-controlled study of a novel integrin antagonist (SAR 1118) for the treatment of dry eye. Am J Ophthalmol. 2012 Jun;153(6):1050-60.
26. Ralston PG Jr., Sloan D, Waters-Honcu D, et al. A pilot, open-label study of the safety of MC-1101 in both normal volunteers and patients with early nonexudative age-related macular degeneration. #913/A196. Paper presented at Association for Research in Vision and Ophthalmology meeting, May 2, 2010; Ft. Lauderdale, Fla.
27. Furfine ES, Hou J, Collins K, et al. EBI-005: an interleukin-1 receptor inhibitor designed for the treatment of dry eye syndrome. #2340/A357. Poster presented at Association for Research in Vision and Ophthalmology meeting, May 7, 2012; Ft. Lauderdale, Fla.
28. Herranz D, Muñoz-Martin M, Cañamero M, et al. Sirt1 improves healthy ageing and protects from metabolic syndrome-associated cancer. Nat Commun. 2010 Apr 12;1:3.
29. Krauss AH, Amparo F, Okanobo A, et al. Improvement of corneal staining by a Sirt1 activator in a mouse model of dry eye. #2343/A360. Poster presented at Association for Research in Vision and Ophthalmology meeting, May 7, 2012; Ft. Lauderdale, Fla.

22. Ianaro A, Ialenti A, Maffia P, et al. Anti-inflammatory activity of macrolide antibiotics. J Pharmacol Exp Ther. 2000 Jan;292(1):156-63.
23. Si EC, Hutcheson J, Hosseini K. Antimicrobial efficacy of azithromycin/dexamethasone combination in blepharokeratoconjunctivitis patients, a Phase 3 study. #2888/D1112. Poster presented at Association for Research in Vision and Ophthalmology meeting, May 4, 2010; Ft. Lauderdale, Fla.
24. Avni I, Garozzi HJ, Barequet IS, et al. Treatment of dry eye syndrome with orally administered CF101: data from a phase 2 clinical trial. Ophthalmology. 2010 Jul;117(7):1287-93.
25. Semba CP, Torkildsen GL, Lonsdale JD, et al. A phase 2 randomized, double-masked, placebo-controlled study of a novel integrin antagonist (SAR 1118) for the treatment of dry eye. Am J Ophthalmol. 2012 Jun;153(6):1050-60.
26. Ralston PG Jr., Sloan D, Waters-Honcu D, et al. A pilot, open-label study of the safety of MC-1101 in both normal volunteers and patients with early nonexudative age-related macular degeneration. #913/A196. Paper presented at Association for Research in Vision and Ophthalmology meeting, May 2, 2010; Ft. Lauderdale, Fla.
27. Furfine ES, Hou J, Collins K, et al. EBI-005: an interleukin-1 receptor inhibitor designed for the treatment of dry eye syndrome. #2340/A357. Poster presented at Association for Research in Vision and Ophthalmology meeting, May 7, 2012; Ft. Lauderdale, Fla.
28. Herranz D, Muñoz-Martin M, Cañamero M, et al. Sirt1 improves healthy ageing and protects from metabolic syndrome-associated cancer. Nat Commun. 2010 Apr 12;1:3.
29. Krauss AH, Amparo F, Okanobo A, et al. Improvement of corneal staining by a Sirt1 activator in a mouse model of dry eye. #2343/A360. Poster presented at Association for Research in Vision and Ophthalmology meeting, May 7, 2012; Ft. Lauderdale, Fla.



Discover the Luxvision Digital Practice and see the benefits that the LRK-2600 Auto Refractor/Keratometer, LCP-2600 Chart Projector and the LDR-2600 Digital Refractor have to offer. Making life much easier.

Distributed By:



www.usophthalmic.com
info@usophthalmic.com
 Toll Free: 888-334-4640



Scan QR Code To
view more information



vision for everyone... everywhere

Brien Holden Vision Institute is one of the largest and most successful non-profit social enterprises in the history of eye care. By applying commercial strategies to vision research and product development the Institute has generated income for research and public health programs that provide quality eye care solutions and sustainable services for the most disadvantaged people in our world.

The concern for the devastating shortfall in eye care education in developing communities, especially for correction of refractive error, became action in 1998 for those at the Institute. The lack of training institutes and educational opportunities was creating a human resource gap and a critical eye care shortage for hundreds of millions of people in need of services. The concern and willingness to address the issue gave rise to the International Centre for Eyecare Education (ICEE).

Almost 15 years later, and acknowledging that 640 million people are still without access to permanent eye care, concern has galvanised into action again. To advance the process of addressing the challenge, both ICEE and Brien Holden Vision Institute will more closely align, share one common purpose and one name.

Together, we believe if we harness our efforts and broaden our scope we can achieve much more.

Together, we aim to drive, innovate, educate, collaborate, advocate and negotiate what is needed so that hundreds of millions, even billions, of people worldwide can enjoy the right to sight. Whether it's research to develop the technology to slow the progress of myopia, investment in new systems for diagnosis of disease, delivery of sustainable access to services or provision of eye care education in the most marginalised and remote communities in the world, the Institute will focus on the quality of vision people experience and equity in eye care access worldwide.

We believe in vision for everyone...everywhere.

Share the vision

brienholdenvision.org



BrienHoldenVisionInstitute

Education Research Technology Public Health

Brien Holden Vision Institute Foundation (formerly ICEE) is a Public Health Division of Brien Holden Vision Institute



MULTIPLY YOUR PATIENT BASE



You and Sally



ACUVUE[®]
BRAND CONTACT LENSES

INNOVATION FOR HEALTHY VISION[™]

Your ACUVUE[®] patients are not only happy, they refer: on average, they've already told 6.5 people about you. Grow your practice with happy patients. Fit more ACUVUE[®].

ACUVUE[®] Brand Contact Lenses are indicated for vision correction. As with any contact lens, eye problems, including corneal ulcers, can develop. Some wearers may experience mild irritation, itching or discomfort. Lenses should not be prescribed if patients have any eye infection, or experience eye discomfort, excessive tearing, vision changes, redness or other eye problems. Consult the package insert for complete information. Complete information is also available from VISTAKON[®] Division of Johnson & Johnson Vision Care, Inc., by calling 1-800-843-2020 or by visiting jnvisioncare.com. ACUVUE[®], INNOVATION FOR HEALTHY VISION[™], and VISTAKON[®] are trademarks of Johnson & Johnson Vision Care, Inc.

© Johnson & Johnson Vision Care, Inc. 2012. ACU-28564G August 2012



Sally



Sally's Co-worker



Sally's Electrician



Sally's Niece



Sally's Banker



Sally's Teacher



Sally's Mechanic



Sally's Grocery Clerk



Sally's Hairstylist



Sally's Brother



Sally's Dentist



Sally's Manicurist



Sally's Yoga Instructor



Sally's Neighbor



Sally's Neighbor

SECO's Summer Session: Hot CE in Cool Vancouver

Canadian optometrists shared insights with their U.S. counterparts on hot topics during SECO's July meeting. **By Jane Cole, Contributing Editor**

SECO is well known for its annual Congress in Atlanta each winter, but its summer CE offering has quickly become a popular venue for optometrists to gain the latest insights on new treatments, technologies and a look at what's ahead in optometry. SECO held its latest summer summit in Vancouver July 26-29, where optometrists were able to take advantage of 14 hours of world-class education, including enlightening sessions on collagen cross-linking, recent advances in cataract surgery, and nutrition from AMD to Z.

"This was a unique meeting in

a beautiful city... another SECO first!" says Paul C. Ajamian, O.D., General Chairman of the SECO CE Committee. "I hope that many more doctors will make the SECO Summer Meeting a part of their education and family vacation plans."

Cutting-Edge Surgery

Dr. Ajamian kicked off the meeting Thursday and presented his course "Cataract Surgery: A Look Ahead" in which he offered his expert perspective on the latest techniques for managing cataract patients, with an emphasis on the pluses and minuses of the femtosecond laser. Some cataract surgeons expect "femto-phaco" to be a game-changer that improves outcomes, particularly in patients receiving premium IOLs to correct astigmatism or presbyopia. These lenses are chosen by patients who have high expectations,

and precise refractive outcomes may be more easily attained with femto-based procedures. Other surgeons are reluctant to adopt the technology, citing concerns about decreased productivity and a yet-to-be-determined financial model to pay for the equipment.

Then, education Co-Chair Paul Karpecki, O.D., took the baton for a memorable presentation on another cutting-edge topic in eye care: collagen cross-linking, an investigational procedure that strengthens collagen bonds in the corneas of patients affected by keratoconus or post-LASIK ectasia by applying riboflavin followed by UV light. His discussion highlighted important clinical pearls in the diagnosis of keratoconus and forme fruste keratoconus and contrasted their typical clinical presentations with other findings, such as ocular surface disease, that can also cause an irregular corneal surface. With international research and current U.S. trials holding significant promise, Dr. Karpecki updated attendees on this new treatment.

"The participants for this program were a mix of both Canadian and American optometrists," notes



SECO held its summer session in Vancouver and offered O.D.s 14 hours of world-class education from renowned speakers.

Dr. Karpecki. “Since the Canadian optometrists had experience with cross-linking, they were able to share insights into the technology that will likely help our U.S. patients with corneal ectasia conditions as the treatment becomes more widespread.”

Food for Thought

Friday was also a stellar day for non-surgical CE as Kim Reed, O.D., and Steven Ferrucci, O.D., engaged in a lively back and forth look at the role of nutrition in ocular health and eye disease. Dr. Reed presented a course titled “You Are What You Eat” and shed some light on food allergies, sensitivities and intolerances, explaining how these conditions affect systemic and ocular health, including a review of all pertinent current literature about inflammatory responses to food and environmental substances. Then Drs. Reed and Ferrucci joined forces to present “Nutrition from AMD to Z,” a rapid-fire review of micronutrients involved in the pathogenesis of age-related macular degeneration and other ocular diseases.

“The speakers explained how the foods we eat affect systemic and ocular health, and continued in that vein by detailing how certain micronutrients are related to AMD and other ocular diseases,” Dr. Karpecki says. “Once again, our attendees came away with new and thought-provoking ideas in treating their patients.”

On Saturday, it was another SECO first, “Paul and Paul in the Morning,” as Drs. Ajamian and Karpecki, both leading comanagement experts, discussed a variety of anterior segment cases that highlighted new technologies and therapeutic modalities.

Following that session, Michael



Following a day of education, attendees and presenters cooled down in Vancouver during SECO's social events, including the welcoming and sponsor receptions.

Chaglasian, O.D., took to the podium for “Keeping Up with the Chaglasians: Glaucoma 2012,” in which he discussed keeping up in glaucoma by understanding risk analysis for ocular hypertension, sleep apnea, treatment of pre-perimetric glaucoma, new glaucoma severity codes, visual field progression and adjunctive medications.

The last day of SECO's summer meeting did not disappoint. Sunday's session opened with Drs. Chaglasian and Ferrucci presenting a timely review of OCT technology and its role in optometric practice, including current approaches to the diagnosis and management of patients using the latest technology.

Then Dr. Ferrucci took to the stage alone for “Comanagement of Retinal Procedures,” where he described the optometrist's role—including pre-operative and post-operative care where appropriate—in patients undergoing both surgical and in-office retinal procedures, with an emphasis on intravitreal injections.

The summer meeting wrapped up with Dr. Ajamian's “Know Your IOLs” talk, in which he enlightened audience members on lens implants

and what optometrists need to know to ensure their cataract patients are fully informed about the latest options. He also covered the many choices patients have in IOLs and how optometrists can play a key role in educating patients during the IOL selection process.


“Sunday's courses culminated an amazing week of education,” says Dr. Ajamian, who cites diverse topics such as “Comanagement of Retinal Procedures,” “All About the OCT” and “Know Your IOLs” that attendees rated highly. “The Vancouver 2012 program delivered world-class education in a first-class location. Attendees got to cool down in this lovely waterfront city as they geared up for better patient care with useful information that they could immediately implement in their practices.”

Coming Next

After the conference returns to Atlanta once again next winter for its long-running annual meeting (February 7-March 3), the mid-year program will head westward, with the summer CE conference slated for San Francisco next July. Keep your eyes peeled for details! ■

CAN'T WAIT UNTIL NEXT MONTH?

Optometric Physician delivers **UP-TO-DATE** news and research to your inbox every Monday morning, allowing you to view all of the latest clinical information on a convenient and consistent basis.



Subscribing to Optometric Physician is an efficient and easy way to stay current with all of the information and events going on in the field. To order your free subscription, e-mail: optometricphysician@jobson.com today.

Optometric
Physician™

ENRICH YOUR PRACTICE

OUR FLAGSHIP TITLE, *REVIEW OF OPTOMETRY*, IS THE MARKET'S LEADING RESOURCE FOR ALL OF YOUR OPTOMETRY NEEDS.

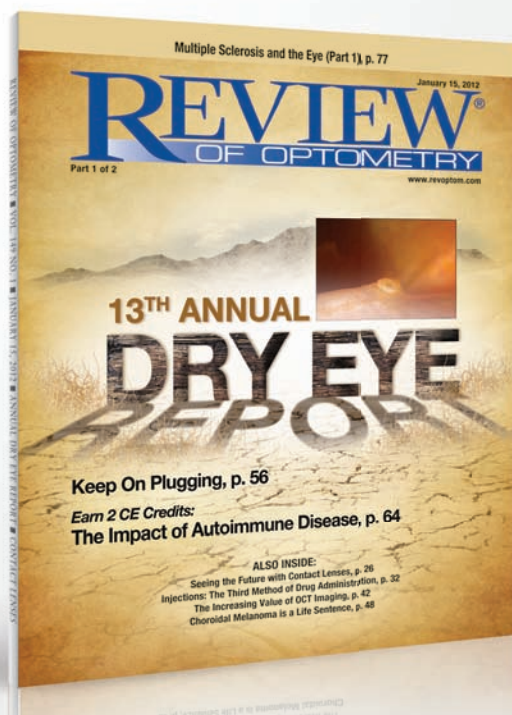
Review of Optometry is your primary source for ground-breaking clinical information as well as timely news, market trend information and continuing education programs.

Review of Cornea & Contact Lenses serves as a valuable resource for all practitioners and features detailed articles focusing on various fitting methods, solutions and corneal cases. Also available is the *Review of Cornea & Contact Lenses "Annual Contact Lenses & Lens Care" Guide*, a yearly publication detailing the newest lenses and lens care products.

The *Review* Group's *Ophthalmic Product Guide* brings you the newest and most innovative products on the market. Published every February and July, the guide provides concise information about new literature, drugs and equipment designed to help your practice thrive.

The *Review* Group also offers valuable **Continuing Education** sessions in both print and online formats, allowing a convenient way for you to earn **CE credits**. In addition, *Review* also offers an impressive fleet of **free e-newsletters**, such as *Optometric Physician*, the *Optometric Retina Society* quarterly e-newsletter and the *Optometric Glaucoma Society E-Journal* so you can keep up to date on breaking news and the latest research online.

The Review Group is dedicated to the constant growth and education of the profession. Review offers many different publications and services to help enhance your practice and patient care.



On top of these products, the *Review* Group also spearheads meetings and conferences, bringing together experts in the field and providing a forum for practitioners to earn CE credits and learn from others in the profession.

www.revoptom.com



Jobson Medical Information LLC
Review Professional Publications Group



35th Annual Diagnostic Technology Report

The ABCs of OCT

Take a guided tour of this innovative technology to better understand its relevance to your practice. **By Jerome Sherman, O.D., and Daniel Epshtein**

One can argue that ophthalmoscopy and OCT are the two landmark developments in observing and diagnosing retinal disorders. Most credit Hermann von Helmholtz with the invention of the ophthalmoscope more than 150 years ago. Today, virtually all eye clinicians perform ophthalmoscopy on all patients. Nearly all forms of fundus photography, including ultra-widefield imaging, accurately capture what we view directly with the ophthalmoscope. In contrast, OCT yields information about retinal anatomy and histopathology that is often entirely invisible to ophthalmoscopy.

The undeniable fact that photoreceptors cannot be observed via ophthalmoscopy exemplifies the importance of OCT. The normal eye has about 120 million rods and six million cones. Histologically, half the retinal thickness is composed of the various components of the photoreceptors. Dr. von Helmholtz, and every subsequent observer, has failed to detect these vital cells with an ophthalmoscope. A patient may lose 100 million photoreceptors, and yet the clinician will document an unremarkable ophthalmoscopic exam. However, as we will soon demonstrate, OCT can reveal a loss of rods or cones or even a complete

compromise of all photoreceptors.

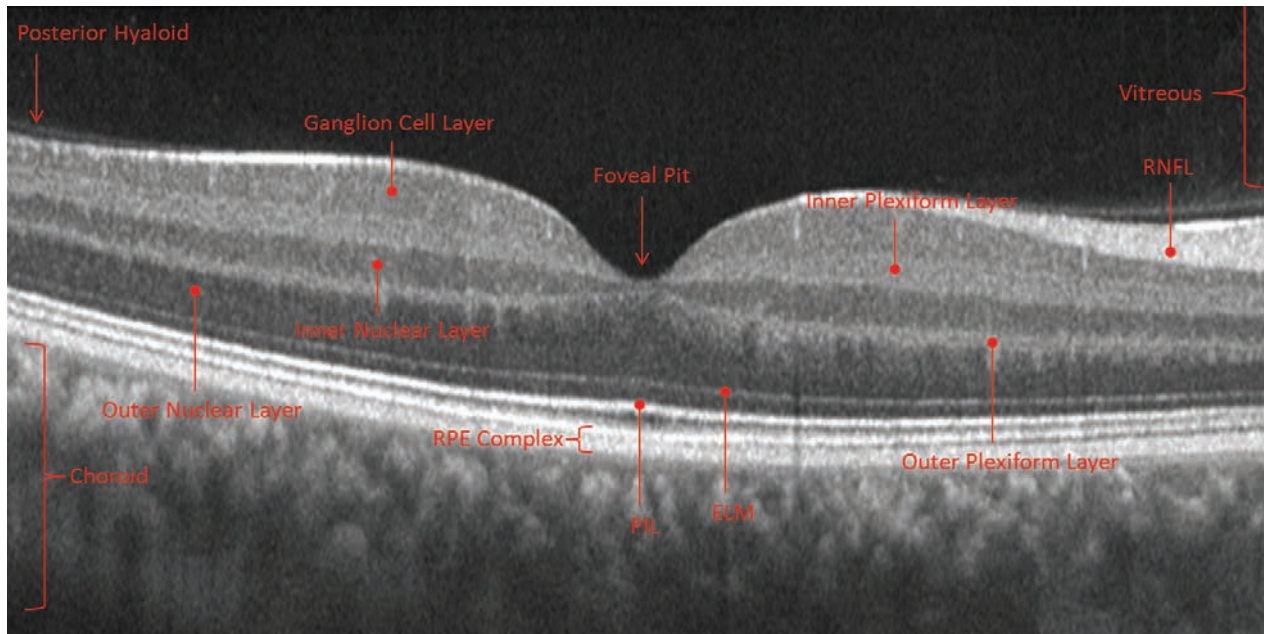
OCT, especially high-resolution spectral-domain (SD-OCT), permits the visualization of all retinal layers, as well as the vitreous and the choroid. Localization of an abnormal finding to a specific layer of the retina often leads to a diagnosis that would not be otherwise possible. For example, exudates and drusen often look similar with an ophthalmoscope, but can be differentiated 100% of the time with OCT. The technology indicates that exudates are located in the middle of the retina (specifically in or adjacent to the outer plexiform layer), and drusen are located under (or occasionally

Don't Miss This Exciting New Offering

Beginning in October, *Review of Optometry* will begin publishing a one-page e-newsletter called *The ABCs of OCT*, authored by our group at the State University of New York College of Optometry. Each will include an OCT scan that illuminates a particular clinical condition. Whenever possible, we will also include a normal OCT for comparison purposes, as well as a fundus photo to better elucidate the pathology. It will likely take just 60 seconds to view the images and read the brief text. The goal is to help novices and experts alike to better understand OCT's capabilities in clinical practice.

Most installments of the newsletter will link to a *Retina Revealed* case that includes many additional images and a more comprehensive discussion. Information on the relevant technology used in the case will also be provided.

We are confident that you will find *The ABCs of OCT* to be a simple but effective way to learn more about this increasingly useful technology! To sign up for the e-newsletter, please visit www.revoptom.com and click on the "E-Newsletters" tab at the bottom of the page.



Case 1. High resolution OCT of a normal right eye.

immediately above) the retinal pigment epithelium (RPE). OCT, only a laboratory curiosity just 20 years ago, is projected to be the new standard of care in both optometry and ophthalmology in the not-too-distant future.

The ABCs of OCT, a new e-newsletter to debut in October, will not only cover the fundamentals of OCT technology and its diagnostic interpretation, but will also go beyond the basics. Each brief discussion will focus on a single concept in OCT—with optional links to related images and cases contained in the free *Retina Revealed* website (www.retinarevealed.com), which now has 52 educational sessions listed in the case study archive as well as more than 2,200 labeled retinal images.

Using 10 case examples culled from the *Retina Revealed* archive, this article will introduce some of the key concepts that *The ABCs of OCT* will elaborate upon on a regular basis.

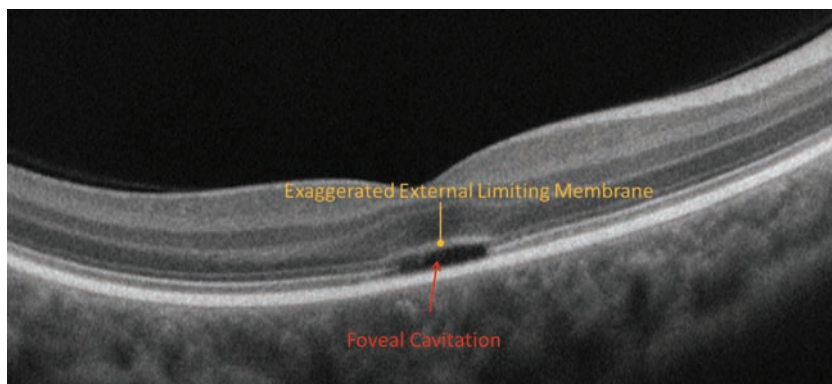
Start with a Good Foundation

To take full advantage of the remarkable images revealed by SD-OCT, let's first learn to meaningfully interpret the various lines, layers, contours and shapes in normal eyes. Once the findings in normal eyes are appreciated, the transition to detecting variations in different retinal, choroidal and vitreal abnormalities will be simplified greatly.

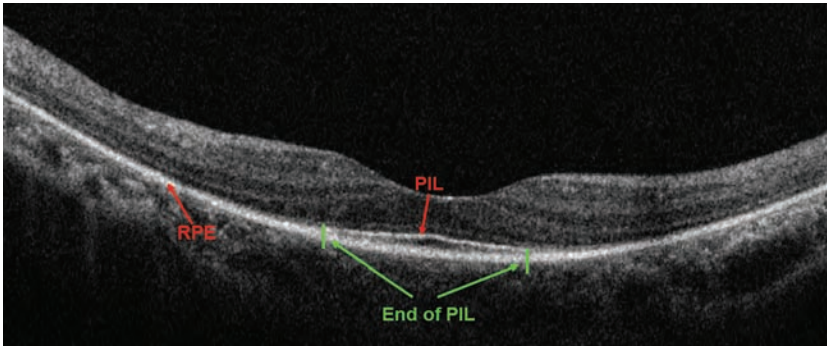
SD-OCT scans most often are presented as a cross-section of the

retina, which appears as a typical histological slice in anatomy textbooks. By convention, the inner retina is close to the center of the eye—the vitreous—and the outer retina is close to the choroid and sclera. Remember that the outer retina contains the RPE and the photoreceptors, and the inner retina contains the retinal nerve fiber layer (RNFL) and the ganglion cells.

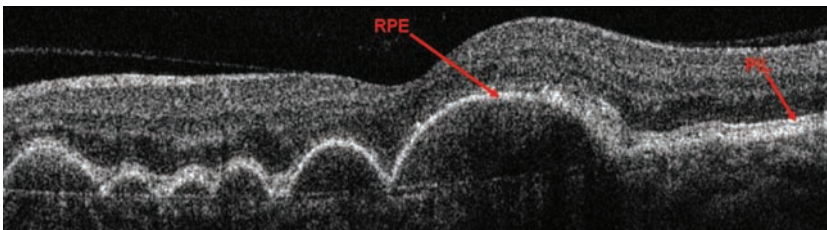
Think of OCT technology's role as identifying changes in optical density, which are depicted either



Case 2. The absence of the PIL (photoreceptor integrity line) under the fovea results in a characteristic hypo-reflective rectangle.



Case 3. The PIL is present under the macula but fades outside the macula, a pattern characteristic of rod degeneration.



Case 4. The dome-shaped RPE elevations are due to drusen of various sizes.

in color or grayscale. When two adjacent structures demonstrate large differences in their refractive indices, more light is reflected upon their interface. By convention, large reflections are depicted by vivid colors such as red, whereas less reflective structures are depicted in the blue part of the spectrum. Zones without reflections are black or nearly so. Hence, a normal vitreous in a young patient will appear dark or even black.

10 Revealing Cases

Case 1. This SD-OCT section through the fovea of a normal right eye reveals a dozen retinal layers, along with the choroid and posterior hyaloid. Note the marked change in reflectivity between the vitreous and the internal limiting membrane/RNFL complex, which depicts the vitreoretinal interface. The outer and inner nuclear layers appear relatively dark due to the lack of change in optical density, because light traverses the tightly

and uniformly packed nuclei. In contrast, the inner and outer plexiform layers show increased reflectivity.

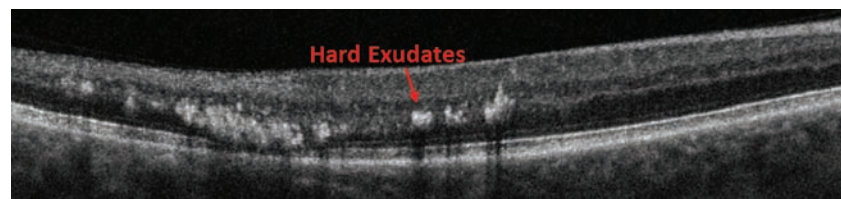
In this instance, the RPE—the outermost of the retinal layers—is labeled as the “RPE complex.” Although the RPE often appears as a single layer, the RPE complex appears to have three relatively distinct layers when viewed at high resolution. As will be illustrated in a future *Retina Revealed* case, the

innermost reflection, previously termed the *Verhoeff membrane* and more recently described as the *inner RPE border* (IRB), becomes attenuated early in Plaquenil (hydroxychloroquine, Sanofi) toxicity.

The prominent bright band anterior to (or above) the RPE is labeled the photoreceptor integrity line (PIL) and has had several names over the past decade: Initially it was termed the *connecting cilia*, then later the *junction of the inner and outer segments of the photoreceptors*, followed by the PIL and, most recently, as the *inner segment ellipsoid*.

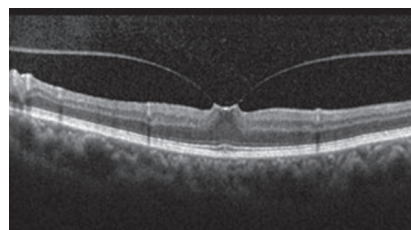
We prefer the previous designation PIL because it is the biomarker of photoreceptor integrity (both rod and cone); moreover, the term PIL does not limit the usefulness of the concept of a biomarker, regardless of the precise anatomical location, which is subject to debate and change. (By the way, who is going to remember the concept of the “inner segment ellipsoid,” anyway? Just remember the PIL—i.e., the “pill” you take in the a.m. or p.m.) In case 1, the bright PIL has the dark inner segments of the photoreceptors above it and the dark outer segments below it (two layers that are not labeled in this image).

Note that in this cross section of



Case 5 (above). Hyper-reflective dots and spots in and around the outer plexiform layer of the retina are exudates.

Case 6 (right). A symmetric VMT. Visual acuity is still normal, since the PIL under the fovea is intact.



WHEN NIGHT FALLS, IOP RISES.¹⁻³

AZOPT[®] Suspension, an adjunctive partner to a PGA that has IOP-lowering efficacy all day and all night⁴

INDICATIONS AND USAGE

AZOPT[®] Brinzolamide Ophthalmic Suspension 1% is a carbonic anhydrase inhibitor indicated in the treatment of elevated intraocular pressure in patients with ocular hypertension or open-angle glaucoma.

DOSAGE AND ADMINISTRATION

- Instill one drop in the affected eye(s) three times daily
- If more than one topical ophthalmic drug is being used, the drugs should be administered at least ten (10) minutes apart

IMPORTANT SAFETY INFORMATION

CONTRAINDICATIONS

- Hypersensitivity to any component of this product

WARNINGS AND PRECAUTIONS

- Sulfonamide hypersensitivity reactions
- Corneal edema may occur in patients with low endothelial cell counts

ADVERSE REACTIONS

Most common adverse reactions are blurred vision and bitter, sour or unusual taste.

Before prescribing AZOPT[®] Suspension, please read full prescribing information on adjacent page.

References:

1. Liu JHK, Weinreb RN. Monitoring intraocular pressure for 24 h. *Br J Ophthalmol*. doi:10.1136/bjo.2010.199737.
2. Bagga H, Liu JH, Weinreb RN. Intraocular pressure measurements throughout the 24 h. *Curr Opin Ophthalmol*. 2009;20(2):79-83.
3. Liu JHK, Zhang X, Kripke DF, Weinreb RN. Twenty-four-hour intraocular pressure pattern associated with early glaucomatous changes. *Invest Ophthalmol Vis Sci*. 2003;44(4):1586-1590.
4. Liu JHK, Medeiros FA, Slight JR, Weinreb RN. Comparing diurnal and nocturnal effects of brinzolamide and timolol on intraocular pressure in patients receiving latanoprost monotherapy. *Ophthalmology*. 2009;116(3):449-454.

Alcon[®]



Azopt®

(brinzolamide ophthalmic suspension) 1%

BRIEF SUMMARY OF PRESCRIBING INFORMATION

1 INDICATIONS AND USAGE

AZOPT® (brinzolamide ophthalmic suspension) 1% is a carbonic anhydrase inhibitor indicated in the treatment of elevated intraocular pressure in patients with ocular hypertension or open-angle glaucoma.

2 DOSAGE AND ADMINISTRATION

The recommended dose is one drop of AZOPT® (brinzolamide ophthalmic suspension) 1% in the affected eye(s) three times daily. If more than one topical ophthalmic drug is being used, the drugs should be administered at least ten (10) minutes apart.

3 DOSAGE FORMS AND STRENGTHS

Solution containing 10 mg/mL brinzolamide.

4 CONTRAINDICATIONS

AZOPT® (brinzolamide ophthalmic suspension) 1% is contraindicated in patients who are hypersensitive to any component of this product.

5 WARNINGS AND PRECAUTIONS

5.1 Sulfonamide Hypersensitivity Reactions

AZOPT® (brinzolamide ophthalmic suspension) 1% is a sulfonamide and although administered topically it is absorbed systemically. Therefore, the same types of adverse reactions that are attributable to sulfonamides may occur with topical administration of AZOPT® (brinzolamide ophthalmic suspension) 1%. Fatalities have occurred, although rarely, due to severe reactions to sulfonamides including Stevens-Johnson syndrome, toxic epidermal necrolysis, fulminant hepatic necrosis, agranulocytosis, aplastic anemia, and other blood dyscrasias. Sensitization may recur when a sulfonamide is re-administered irrespective of the route of administration. If signs of serious reactions or hypersensitivity occur, discontinue the use of this preparation.

5.2 Corneal Endothelium

Carbonic anhydrase activity has been observed in both the cytoplasm and around the plasma membranes of the corneal endothelium. There is an increased potential for developing corneal edema in patients with low endothelial cell counts. Caution should be used when prescribing AZOPT® (brinzolamide ophthalmic suspension) 1% to this group of patients.

5.3 Severe Renal Impairment

AZOPT® (brinzolamide ophthalmic suspension) 1% has not been studied in patients with severe renal impairment (CrCl < 30 mL/min). Because AZOPT® (brinzolamide ophthalmic suspension) 1% and its metabolite are excreted predominantly by the kidney, AZOPT® (brinzolamide ophthalmic suspension) 1% is not recommended in such patients.

5.4 Acute Angle-Closure Glaucoma

The management of patients with acute angle-closure glaucoma requires therapeutic interventions in addition to ocular hypotensive agents. AZOPT® (brinzolamide ophthalmic suspension) 1% has not been studied in patients with acute angle-closure glaucoma.

5.5 Contact Lens Wear

The preservative in AZOPT® (brinzolamide ophthalmic suspension) 1%, benzalkonium chloride, may be absorbed by soft contact lenses. Contact lenses should be removed during instillation of AZOPT® (brinzolamide ophthalmic suspension) 1%, but may be reinserted 15 minutes after instillation.

6 ADVERSE REACTIONS

6.1 Clinical Studies Experience

Because clinical studies are conducted under widely varying conditions, adverse reaction rates observed in the clinical studies of a drug cannot be directly compared to the rates in the clinical studies of another drug and may not reflect the rates observed in practice.

In clinical studies of AZOPT® (brinzolamide ophthalmic suspension) 1%, the most frequently reported adverse events reported in 5-10% of patients were blurred vision and bitter, sour or unusual taste. Adverse events occurring in 1-5% of patients were blepharitis, dermatitis, dry eye, foreign body sensation, headache, hyperemia, ocular discharge, ocular discomfort, ocular keratitis, ocular pain, ocular pruritus and rhinitis.

The following adverse reactions were reported at an incidence below 1%: allergic reactions, alopecia, chest pain, conjunctivitis, diarrhea, diplopia, dizziness, dry mouth, dyspnea, dyspepsia, eye fatigue, hypertonia, keratoconjunctivitis, keratopathy, kidney

pain, lid margin crusting or sticky sensation, nausea, pharyngitis, tearing and urticaria.

7 DRUG INTERACTIONS

7.1 Oral Carbonic Anhydrase Inhibitors

There is a potential for an additive effect on the known systemic effects of carbonic anhydrase inhibition in patients receiving an oral carbonic anhydrase inhibitor and AZOPT® (brinzolamide ophthalmic suspension) 1%. The concomitant administration of AZOPT® (brinzolamide ophthalmic suspension) 1% and oral carbonic anhydrase inhibitors is not recommended.

7.2 High-Dose Salicylate Therapy

Carbonic anhydrase inhibitors may produce acid-base and electrolyte alterations. These alterations were not reported in the clinical trials with brinzolamide. However, in patients treated with oral carbonic anhydrase inhibitors, rare instances of acid-base alterations have occurred with high-dose salicylate therapy. Therefore, the potential for such drug interactions should be considered in patients receiving AZOPT® (brinzolamide ophthalmic suspension) 1%.

8 USE IN SPECIFIC POPULATIONS

8.1 Pregnancy

Pregnancy Category C: Developmental toxicity studies with brinzolamide in rabbits at oral doses of 1, 3, and 6 mg/kg/day (20, 62, and 125 times the recommended human ophthalmic dose) produced maternal toxicity at 6 mg/kg/day and a significant increase in the number of fetal variations, such as accessory skull bones, which was only slightly higher than the historic value at 1 and 6 mg/kg. In rats, statistically decreased body weights of fetuses from dams receiving oral doses of 18 mg/kg/day (375 times the recommended human ophthalmic dose) during gestation were proportional to the reduced maternal weight gain, with no statistically significant effects on organ or tissue development. Increases in unossified sternebrae, reduced ossification of the skull, and unossified hyoid that occurred at 6 and 18 mg/kg were not statistically significant. No treatment-related malformations were seen. Following oral administration of ¹⁴C-brinzolamide to pregnant rats, radioactivity was found to cross the placenta and was present in the fetal tissues and blood.

There are no adequate and well-controlled studies in pregnant women. AZOPT® (brinzolamide ophthalmic suspension) 1% should be used during pregnancy only if the potential benefit justifies the potential risk to the fetus.

8.3 Nursing Mothers

In a study of brinzolamide in lactating rats, decreases in body weight gain in offspring at an oral dose of 15 mg/kg/day (312 times the recommended human ophthalmic dose) were seen during lactation. No other effects were observed. However, following oral administration of ¹⁴C-brinzolamide to lactating rats, radioactivity was found in milk at concentrations below those in the blood and plasma.

It is not known whether this drug is excreted in human milk. Because many drugs are excreted in human milk and because of the potential for serious adverse reactions in nursing infants from AZOPT® (brinzolamide ophthalmic suspension) 1%, a decision should be made whether to discontinue nursing or to discontinue the drug, taking into account the importance of the drug to the mother.

8.4 Pediatric Use

A three-month controlled clinical study was conducted in which AZOPT® (brinzolamide ophthalmic suspension) 1% was dosed only twice a day in pediatric patients 4 weeks to 5 years of age. Patients were not required to discontinue their IOP-lowering medication(s) until initiation of monotherapy with AZOPT®. IOP-lowering efficacy was not demonstrated in this study in which the mean decrease in elevated IOP was between 0 and 2 mmHg. Five out of 32 patients demonstrated an increase in corneal diameter of one millimeter.

8.5 Geriatric Use

No overall differences in safety or effectiveness have been observed between elderly and younger patients.

10 OVERDOSAGE

Although no human data are available, electrolyte imbalance, development of an acidotic state, and possible nervous system effects may occur following oral administration of an overdose. Serum electrolyte levels (particularly potassium) and blood pH levels should be monitored.

13 NONCLINICAL TOXICOLOGY

13.1 Carcinogenesis, Mutagenesis, Impairment of Fertility

Carcinogenicity data on brinzolamide are not available. The following tests for mutagenic potential were negative: (1) *in vivo* mouse micronucleus assay; (2) *in vivo* sister chromatid exchange assay; and (3) Ames *E. coli* test. The *in vitro* mouse lymphoma forward mutation assay was negative in the absence of activation, but positive in the presence of microsomal activation. In reproduction studies of brinzolamide in rats, there were no adverse effects on the fertility or reproductive capacity of males or females at doses up to 18 mg/kg/day (375 times the recommended human ophthalmic dose).

Alcon®

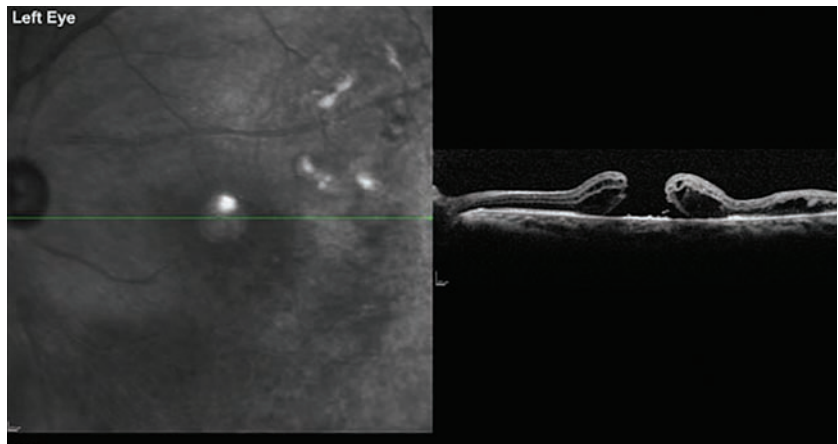
ALCON LABORATORIES, INC.
Fort Worth, Texas 76134 USA

AAA-006-0711

© 2011 Novartis 8/11 AZT11500JAD-A

the right eye, the RNFL is thicker on the right side than on the left. This is because of the relatively thick papillomacular bundle, which is the RNFL from the fovea to the optic disc. The zone labeled *choroid* reveals cross sections through some of the large choroidal vessels. Also note that the posterior hyaloid—most posterior part of the vitreous—is slightly separated from the retina.

Case 2. Under the fovea, there is an optically empty cavity in the shape of a rectangle. This “foveal cavitation” is due to the absence of the PIL in this location. Because the cones are highly concentrated within the central 1mm of this 6mm section, this eye will have reduced visual acuity and color vision. Even though the fundus exam was normal, the OCT immediately leads to a diagnosis of a dramatic reduction of foveal cones. This can occur in rod monochromatism, cone dystrophy and occasionally in Stargardt’s disease. Note that when the PIL is absent, the external limiting membrane (ELM) is exaggerated; this can be explained by the greater dif-



Case 7. This full-thickness macular hole may have been due to a previous VMT.

ference in refractive index when the cones are reduced.

(See www.retinarevealed.com case study archive #24 for many more images, differential diagnoses and discussion.)

Case 3. In this case, the PIL appears present within the central 1mm to 1.5mm of this 6mm scan, but absent outside of the central zone. The normal PIL correlates with the patient’s 20/20 visual acuity, and the absence of the PIL outside this central zone explains the patient’s symptoms of very

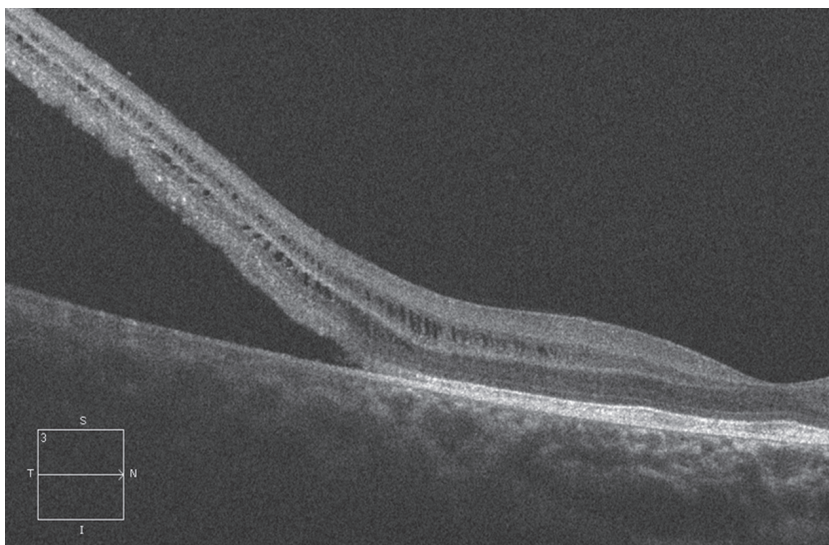
poor night vision and limited side vision. The fundus can be normal, such as in retinitis pigmentosa sine pigmento, but the OCT can reveal essentially normal cones with a very reduced number of rods.

(See www.retinarevealed.com case study archive #25 for many more images, including ultra-wide-field FAs, differential diagnoses and discussion.)

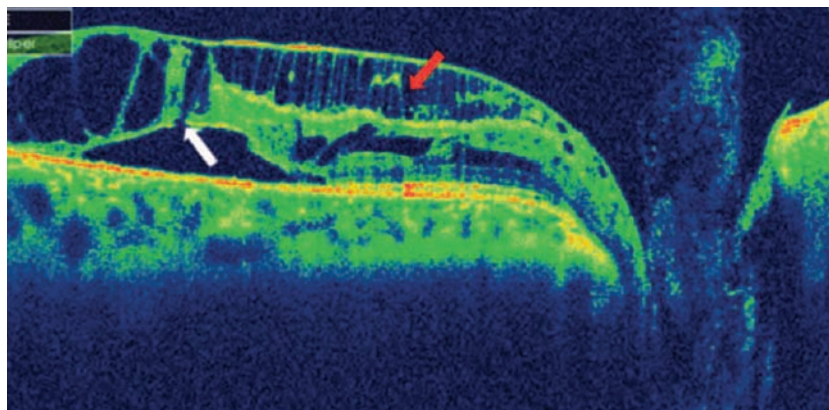
Case 4. Here we observe multiple areas of RPE elevation due to drusen of various sizes. Drusen are found in most cases of AMD. The genetic analysis is highly correlated with the patient’s risk of experiencing significant vision loss and can differentiate a risk of 13% (in Macula Risk category 1) to 73% in MR (in category 5) and various risks in the other three categories.

(See www.retinarevealed.com case study archive #27 for many more images, differential diagnoses and discussion of various forms of AMD, and the most recent diagnostic approaches, including genetic testing for the various AMD genes.)

Case 5. The dots and spots in this OCT are in the middle of the retina, specifically in or around the outer plexiform layer. The location is highly characteristic of exudates—the presence of which



Case 8. A high-resolution OCT of a retinal detachment that requires immediate treatment, since the macula is threatened.



Case 9. Multiple retinal splits in this patient with an optic pit is typical of a macula retinoschisis.

provide indirect evidence that blood vessels are leaking. As in this case, diabetes is a common etiology of such exudates, but myriad other disorders can be the culprit. Note the unmistakable difference of the OCTs in cases 4 and 5. As noted, OCT can differentiate drusen from exudates in 100% of the cases.

(See www.retinarevealed.com case study archive #44 for many more images, differential diagnoses and discussion of the various etiologies of white dots and spots.)

Case 6. Although often invisible to ophthalmoscopy, vitreomacular traction (VMT) is conspicuously illustrated on this OCT, which can explain the patient's symptoms of flashing lights straight ahead.

(See www.retinarevealed.com case study archive #6 for many more images and discussion of various forms of VMT and the often associated or eventual finding of a full-thickness macular hole.)

Case 7. The OCT reveals a full-thickness macular hole as the explanation of the patient's reduced visual acuity.

(See www.retinarevealed.com case study archive #6 to learn about the relationship between VMT and risk of macular hole formation, plus the new pharmacological

approaches to prophylactic treatment of VMT known as vitreolysis.)

Case 8. The OCT in this case reveals the separation of the entire neurosensory retina from the RPE temporal to the fovea in this right eye. The VA is still 20/20 because the macula is still attached and the PIL is present. Hence, this is a "macula on" retinal detachment that requires immediate treatment.

(See www.retinarevealed.com case study archives #22 and #26 for many more images, differential diagnoses and discussion of retinal detachment, retinoschisis and both in the same eye.)

Case 9. The OCT reveals multiple splits in the retina of this patient with an optic pit-induced retinoschisis (RS). Visual acuity is reduced because the RS includes

the entire macula. Various breaks are visualized. Note the distinctions between retinal detachment (Case #8) and retinoschisis (Case #9) that are made possible by OCT.

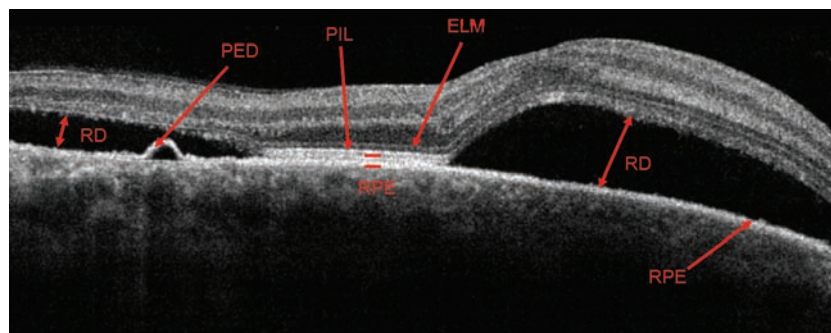
(See www.retinarevealed.com case study archives #4 and #8 for related cases and images.)

Case 10. The OCT reveals an RPE detachment as well as a serous detachment of the neurosensory retina in this patient with central serous chorioretinopathy.

(See www.retinarevealed.com case study archives #3, #20, #39 and #45 for various presentations of this and related disorders.)

Clinicians welcome any new advance that helps to illuminate and better inform our patient care efforts. OCT technology is evolving rapidly, and our diagnostic protocols as well. By staying current, we can benefit to the fullest from its ample capabilities. ■

Dr. Sherman is a distinguished teaching professor at State University of New York College of Optometry and the Schnurmacher Institute of Vision Research. He also practices at The Eye Institute and Laser Center, New York City, and is vice president of the Optometric Retina Society. Mr. Epstein is a second-year professional student at SUNY.



Case 10. The OCT of this patient with central serous chorioidopathy reveals a PED and two neurosensory detachments.



More people are
sleeping in their contact lenses
than you think.

Nearly 1 in 5.¹

For those people, choose the next best thing to not sleeping
in lenses—AIR OPTIX® NIGHT & DAY® AQUA contact lenses



- FDA approved for up to 30 nights of continuous wear**
- #1 ECP-recommended brand for patients who sleep overnight in their contact lenses²
- Delivers the highest oxygen transmissibility* of any available soft contact lens³
- Monthly replacement schedule promotes patient compliance^{4†} and may increase practice profitability⁵

Visit myalcon.com to learn more.

*AIR OPTIX® NIGHT & DAY® AQUA (Iotrafilcon A) contact lenses: Dk/t = 175 @ -3.00D. Other factors may impact eye health. **Extended wear for up to 30 continuous nights as prescribed by an eye care practitioner. †Compliance with manufacturer-recommended replacement frequency.

Important information for AIR OPTIX® NIGHT & DAY® AQUA (Iotrafilcon A) contact lenses: AIR OPTIX® NIGHT & DAY® AQUA contact lenses are indicated for vision correction for daily wear (worn only while awake) or extended wear (worn while awake and asleep) for up to 30 nights. **Relevant Warnings:** A corneal ulcer may develop rapidly and cause eye pain, redness or blurry vision as it progresses. If left untreated, a scar, and in rare cases loss of vision, may result. The risk of serious problems is greater for extended wear vs daily wear and smoking increases this risk. A 1-year post-market study found 0.18% (18 out of 10000) of wearers developed a severe corneal infection, with 0.04% (4 out of 10000) of wearers experiencing a permanent reduction in vision by two or more rows of letters on an eye chart. **Relevant Precautions:** Not everyone can wear for 30 nights. Approximately 80% of wearers can wear the lenses for extended wear. About two-thirds of wearers achieve the full 30 nights continuous wear. **Side Effects:** In clinical trials, approximately 3-5% of wearers experience at least one episode of infiltrative keratitis, a localized inflammation of the cornea which may be accompanied by mild to severe pain and may require the use of antibiotic eye drops for up to 1 week. Other less serious side effects were conjunctivitis, lid irritation or lens discomfort including dryness, mild burning or stinging. **Contraindications:** Contact lenses should not be worn if you have: eye infection or inflammation (redness and/or swelling); eye disease, injury or dryness that interferes with contact lens wear; systemic disease that may be affected by or impact lens wear; certain allergic conditions or using certain medications (ex. some eye medications). **Additional Information:** Lenses should be replaced every month. If removed before then, lenses should be cleaned and disinfected before wearing again. Always follow the eye care professional's recommended lens wear, care and replacement schedule. Consult package insert for complete information, available without charge from Alcon at (800) 241-5999 or myalcon.com.

References: 1. Alcon data on file, 2009. 2. In a survey of 203 optometrists in the U.S.; Alcon data on file, 2011. 3. Based on the ratio of lens oxygen transmissibilities; Alcon data on file, 2009, 2010. 4. Dumbleton K, Richter D, Woods C, et al. Compliance with contact lens replacement in Canada and the United States. *Optom Vis Sci.* 2010;87(2):131-139. 5. Compared to 2-week replacement lenses; based on self-reported lens replacement times and third-party industry pricing information; Alcon data on file, 2012.

See product instructions for complete wear, care, and safety information.

Alcon

© 2012 Novartis 2/12 AND12017JAD

Rx only



35th Annual Diagnostic Technology Report

Top 10 Most Wanted Diagnostic Instruments

Electronic medical records, digital cameras and OCTs are this year's most popular technologies, according to our annual survey. They're changing the way you practice.

By John Murphy, Executive Editor

An electronic medical records system may be helpful if used correctly, but can be disastrous if something goes wrong. Meanwhile, an optical coherence tomographer is quickly becoming a tool that optometrists simply cannot do without.

These are just a couple of the findings from our Annual Diagnostic Technology Survey, based on responses from 260 optometrists to an email questionnaire.

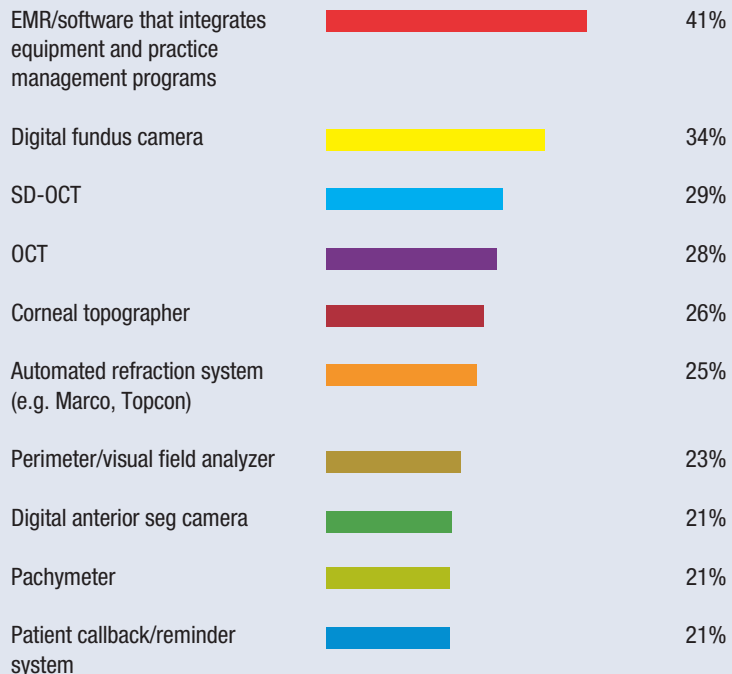
Among our questions, we asked our readers which instruments or equipment they currently want to buy or have purchased in the past three years.

The top 10 most bought or most wished-for items are:

1. EMR

EMR systems are not diagnostic equipment, of course. Still, they elbowed out the other technology-related products on our survey by a wide margin—41% of our respondents say they've recently bought or are looking to buy an EMR system and/or software that integrates equipment and practice

What type of new technology are you now considering purchasing (or have purchased in the past three years?)



management programs.

“EMR has without a doubt been the most significant improvement in the practice,” says optometrist James Budd, of Monroeville, Pa.

“There are some growing pains, but it's infinitely better than paper.”

Indeed, as many as 64% of respondents now use an EMR

system. Compare that to just 39% in 2009—which was the year that Congress passed the Health Information Technology for Economic and Clinical Health (HITECH) Act to promote the adoption and “meaningful use” of health information technology.

As you know by now, the HITECH Act provides financial incentives for those who use a certified EMR system. On the other hand, the act will reduce Medicare and Medicaid reimbursements for those who cannot document “meaningful use” of such a system by 2015.

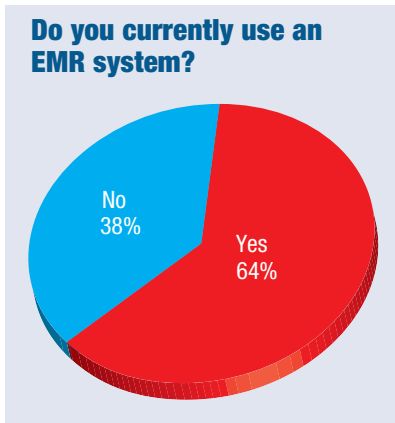
The HITECH Act is worthy in spirit; but in practical terms, reaction to the requirement that doctors embrace this technology has been hit or miss.

“Eight new computers and [a leading EMR/practice management system] were purchased in the last quarter of 2011 to take advantage of certain Federal tax deductions and tax credits,” says Ira J. Cohen, O.D., of his Lake Worth, Fla., practice. “So far, it has created a lot of stress in the office and dissension among the staff members.”

Many doctors complain of losing days of data if the system goes down. Optometrist Larry Gunnell of Wichita Falls, Texas, voices another common complaint: “Sometimes I feel more like a proofreader than a clinician. Auto-fill is a real problem when it comes to lens prescriptions.”

Fortunately for many practitioners, the technology actually does what it’s supposed to do.

“I wanted to be more organized, with better capability to recall charts and data,” says William Jackson, O.D., of Lake Jackson, Texas. “This purchase has done just that. It has also allowed the office to be more organized and



more consistent in billing and coding.”

2. Digital Fundus Camera

About one-third (34%) of O.D.s who responded to our survey now own or are considering a digital fundus camera.

Robert Buonfiglio, O.D., of Saugus, Mass., recently bought one. “While I’m hoping it enhances revenue, it also allows me to show patients the insides of their eyes,” he says. “For patients with diabetes, I now send photos with any changes labeled to their primary care doctors. It’s my hope that doing this will produce more referrals, not only for diabetic evaluations but for red eyes, foreign bodies, etc.”

Lamont P. Freeman, O.D., sees a large number of patients with diabetes at his clinic in Brooklyn. “The adage, ‘A picture is worth a thousand words,’ is not just a saying. It’s very real,” he says of his digital fundus camera. “All [of our] recommendations are accepted by patients after they view their fundus.” Additional benefits include increased income, better patient flow, increased number of patients and increased utilization of services, he says.

Kenneth R. Mueller, O.D., of Hannibal, Mo., appreciates the use-

fulness of the Pictor (Volk Optical), a new handheld, portable anterior and posterior camera. “It offers nice photographic capabilities for mobility-challenged patients in an ergonomic and affordable device,” he says.

3. & 4. SD-OCT and TD-OCT

Optical coherence tomography is not officially part of the standard operating equipment for optometric practices—yet. But once optometrists get an OCT, they wonder how they got along without it.

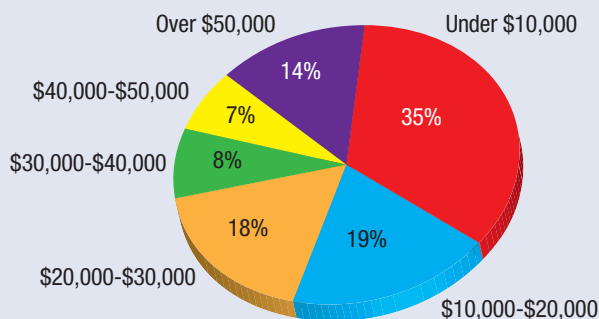
Specifically, 28% of our respondents own or want to own a time-domain (TD) OCT, and 29% voiced the same interest in a spectral-domain (SD) OCT. (Respondents were allowed to choose more than one option in the survey.)

Paul Heersink, O.D., of Monte Vista, Colo., says the SD-OCT is the single best instrument purchase he’s ever made. “It gives me unparalleled confidence in managing retinal conditions. It improves my ability to educate my patients on their retinal condition [by] showing the problem in a way that they can more easily understand,” he says.

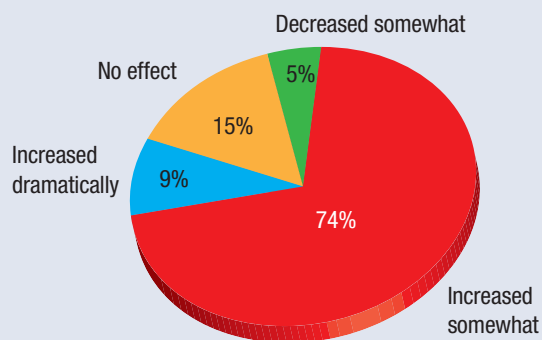
Furthermore, Dr. Heersink adds, “as a rural practitioner in solo practice, it has been invaluable to me because I often have to make the call to send someone three to four hours away for a referral. Now I know whether it’s necessary or not because I’ve already sent it to the retina specialist for his opinion.”

Unfortunately, the billing for an OCT changed in 2011 from a single-eye test to a bilateral one, effectively cutting the reimbursement fee in half. “With the cut in reimbursement, the instrument is not paying for itself,” says optometrist Bob Day, of Garland, Texas. “But I am able to better care for my patients.”

How much will you be spending on instruments and equipment this year?



Has your latest technology investment increased your profitability?



Expanded indications for OCT can help to defray the cost while continuing to improve care. Although OCT traditionally had been reserved for retinal disease diagnosis, it has lately made inroads in the management of other conditions. For instance, newer software modules can analyze retinal nerve fiber layer dropout and ganglion cell loss in glaucoma, as well as corneal thickness and the anterior segment angle.

“The OCT that we bought last year has increased referrals and has improved patient care dramatically,” says Todd Cohan, O.D., of Long Grove, Ill. “We have been diagnosing glaucoma suspects way ahead of time and are able to provide more preventative eye care. The patients have been more than impressed. As a result, our medical billing has increased with more medical follow-up exams.”

5. Corneal Topographer

Some 26% of our respondents recently have purchased or are considering a corneal topographer.

Optometrist Michael Raff of Brockport, N.Y., got one last year. “We increased contact lens fit/refit fees by \$5, which offset the cost for the instrument while upgrading the technology,” he says.

Jared Hadlock of Montrose, Colo., bought a three-in-one topographer/autorefractor/keratometer. “We needed a new AR and wanted a topo, so it was a great way to knock out two birds with one stone for not much more in price than just an AR,” he says. “We’ve been able to find more keratoconus patients than we originally thought we had. It has definitely added a ‘wow’ factor for patients as well. It’s easy and does all the measurements at one time, so it’s quick, too.”

6. Automated Refraction System

Twenty-five percent of optometrists have bought or want to buy an automated refraction system. Matthew Stanley, O.D., recently added it to two exam lanes in his Manhattan, Kan., office. “I save nearly five minutes per patient on refraction,” he says. “The patients are wowed by the technology and love seeing the difference between their old and new Rx.” This effect has boosted his optical sales, he adds.

Carlton Chan, O.D., of Solana Beach, Calif., realized a dramatically different benefit: “The Marco TRS saved my career. It solved all my back problems.”

7. Perimeter/Visual Field Analyzer

If you want to diagnose and treat glaucoma, you need a perimeter. And 23% of our respondents are “scouting the field” for one. Some doctors, such as Michael Lange, O.D., of Ocala, Fla., went for the added investment of a visual field analyzer. “It’s highly sensitive for detecting early glaucoma field loss,” he says. “Patients love it and I trust it. It can perform a billable full-threshold test on a new patient in around four minutes, get better dependability indices for many patients, and give me better decision-making data on those ‘iffy’ early suspects.”

8. Digital Anterior Seg Camera

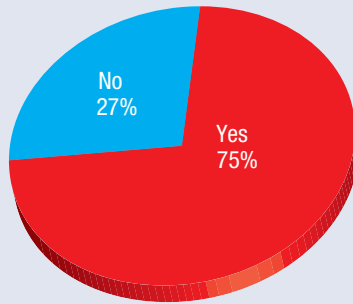
“We have done posterior segment photos for many years, and anterior seg photography is a logical and practical extension of posterior seg documentation,” says Larry Cusma, O.D., of Scotia, N.Y. Other optometrists appear to think the same—about one in five (21%) have recently bought an anterior seg camera or are looking to buy one. “It’s a great device for showing patients their ocular pathology of the anterior seg, and reinforcing the need for regular exams and follow-up monitoring,” Dr. Cusma says.

9. Pachymeter

Three out of four optometrists (75%) say they now have a pachymeter (or other instrument that measures corneal thickness). That's up from about two-thirds (68%) who reported they had one in our 2010 survey. About 21% of our respondents are in the market for one.

"It's amazing how the pachymeter affects how I view whether or not someone is a glaucoma suspect," says Lorelei Zeiler, O.D., of Caledonia, Ontario. "If the patient has large discs, large cupping or higher IOPs (20mm Hg to 24mm Hg) but thick corneas—no worries. Thin corneas? Yes, worry!"

Do you have a pachymeter (or other instrument that measures central corneal thickness)?



10. Patient Callback/Reminder System

About one in five (21%) respondents recently obtained or are shopping for one of these patient retention systems. The connectivity with EMR systems and the high-tech advancements—such as sending a text message to a patient's smartphone—has led to renewed interest and savings in this practice management technology.

Ten percent of our respondents say that increasing revenue is their most important reason for buying new equipment. While adding revenue is always an important consideration, this statistic takes a distant second place compared to improving patient care—77% of O.D.s say this is their primary reason for investing in new technology. ■

Other Hot Items

- **Wide-field scanning laser ophthalmoscope.** "The Optomap (Optos) has greatly impacted my practice," says Marcia Leverett, O.D., of Virginia Beach, Va. "It has increased my revenues, helped in diagnosing retinal disease and helped me to start thinking in an even more medically-oriented way for my whole practice. I would not want to practice without it now."
- **Specular microscope.** "The utilization and reimbursement make this technology a financial 'home run,'" Dr. Gunnell says.
- **Handheld tonometer.** "We bought the Icare tonometer to replace the non-contact tonometer (NCT) as a screening device used by the technician. Patients love it," says Suzanne Corbitt of St. Johnsbury, Vt. "It is so much easier to get an IOP reading on children (and adults alike) who are very apprehensive about the NCT or even the Goldmann tonometer. It gets the technician more involved with the exam and it has made the overall exam that much more efficient for the doctors."
- **Patient education system.** "I can create or upload practice or product info into these displays, and people love to watch them—no one can resist a TV screen [in the waiting room]," Dr. Lange says. "Now I get asked about new products or services by an open-minded patient instead of having to 'pitch' a product or treatment...[and] I don't have to waste chair time doing it."

Update:

Advances in Refractive Surgery. 'Learn about the latest modalities of optimizing the ocular surface and new frontiers in the correction of presbyopia'

Saturday October 13th, 2012
2:00pm to 5:00pm

Gordon Balazsi MD and Marc Mullie MD will present the advances in lasers (excimer and femtosecond), ablation patterns (wavefront vs. aspheric vs. topography guided), keratoconus screening, new modalities of presbyopia correction, phakic IOL's, and others.
3 hours Cope credits

Sunday October 14th, 2012
9:00am to 11:00am

Dr Donald Korb OD from Boston will present his vast experience with the treatment of dry eye, specifically the diagnosis and treatment of meibomian gland dysfunction (evaporative dry eye).
2 hours COPE credits

Venue:
Marriott Chateau Champlain, Montreal, RSVP by September 29th, 2012

Contact

Danièle Louette, COA
laservue@laservue.net
514-738-6666

Laservue Clinic,
lasik eye correction :
1100, Ave Beaumont, suite 201,
Montreal, Qc., H3P 3H5

Tel: 514-738-6666
Toll free: 1-888-734-6666
Fax: 514-738-1769
E-Mail: laservue@laservue.net

Monthly Multifocal Pearl



AIR OPTIX® AQUA Multifocal Contact Lenses: The Natural Choice for Presbyopes

By Glenda B. Secor, OD, FAO

Presbyopia is no picnic. Patients can't ignore the fact that they're older and need reading glasses to use their cell phones, read their e-mail and see menus. And for us as professionals, we have to deal with these previously happy patients who now hate their contact lenses and are dropping out because they can't read and their lenses are less comfortable. Fortunately, there's hope. The newest generation of silicone hydrogel multifocal contact lenses addresses the unmet needs of these patients and offers solutions to the presbyopic paradigm.

Silicone hydrogel contact lenses made soft lens patients happier, and the material's increased oxygen transmissibility reduced corneal hypoxia and inflammation, which reduced subjective dryness and discomfort. And thanks to newer lens material technology, previously unhappy wearers may enjoy the benefits of whiter-looking eyes, enhanced wearing times and less discomfort. The only barrier to glorious contact lens wear was vision, as spherical lenses lacked the multifocal magic to offer outstanding vision at all viewing distances.

THE PATIENT BENEFITS OF MULTIFOCAL MAGIC

The paradigm shift with multifocals occurred with the introduction of AIR OPTIX® AQUA Multifocal contact lenses, which combine the benefits of silicone hydrogels with a Precision Profile Design that provides clear vision near through far. Precision Profile Design is composed of three significant features, including a center-near design, a bi-aspheric surface, and an adaptive minus power profile. The center-near design works synergistically with the eye's natural binocular function and the front aspheric surface enhances image quality, while the aspheric back surface facilitates centration and fit.

The adaptive minus power profile helps to minimize aberrations. And with more minus at the periphery of the optic zone, you can "push plus" at distance. When appropriate, the outcome improves the near acuity without sacrificing distance vision. AIR OPTIX® AQUA Multifocal contact lenses are available in three different ADD ranges (LO, MED, HI), which results in consistent, reliable success and correlates well with most spectacle prescriptions.

Additionally, the proprietary lotrafilcon B lens material and unique plasma surface treatment of AIR OPTIX® AQUA contact lenses have also been incorporated into the multifocal design, thus improving comfort. AIR OPTIX® AQUA Multifocal contact lenses, with their unique plasma-surface treatment, allow for high oxygen transmissibility, deposit resistance and wettability for comfort from insertion to the end of the wear cycle.

CLINICAL BENEFITS ABOUND

Many practitioners believe that multifocals are more difficult to fit than monovision lenses and require additional chair time, but the latest lenses are so predictable that they do not increase the fitting time necessary to achieve the desired outcome. Woods, et al. reported that

low ADD multifocal lenses outperformed in a cross-over study involving AIR OPTIX® AQUA Multifocal contact lenses, monovision, habitual correction and optimized distance vision correction.² The multifocal contact lenses were preferred for real-life situations such as driving and watching television when compared to monovision.² There was also a statistical advantage with subjective distance and intermediate vision.² In a separate study, when queried on their personal experience with AIR OPTIX® AQUA Multifocal lenses, practitioners were impressed with the ease of fitting. Regardless of presbyopic power, 95% felt the lenses were "easy to fit" and achieved over 75% success with an average of 2.4 patient visits and less than four lenses per patient.³

Clinical performance of multifocals can vary within the category and subtle differences can impact our clinical outcomes. Several large, prospective randomized cross-over clinical trials have compared the AIR OPTIX® AQUA Multifocal lenses to ACUVUE® OASYS® for Presbyopia (Johnson & Johnson Vision Care, Inc.) and Bausch + Lomb's PureVision® Multi-Focal.^{4,5} In all cases, the quality of vision was found to be superior with AIR OPTIX® AQUA Multifocal.^{4,5}

SET YOURSELF UP FOR SUCCESS

The best way to achieve success with minimal distress is to follow the manufacturer's suggested fitting guidelines. After several patients respond to the recommended changes, your ability to troubleshoot will improve. Furthermore, confidently communicating the benefits of multifocal contact lenses is imperative, as is understanding the occupational and lifestyle needs of your patients. As in most cases, setting goals and expectations will optimize the experience for motivated patients who will become incredibly loyal to your practice and refer their friends and family.

Dr. Secor is in private practice in Huntington Beach, Calif. She has been a clinical investigator for numerous manufacturers and has lectured, served on editorial boards, and published extensively.

1. In vitro measurement of contact angles on unworn lenses; significance demonstrated at the 0.05 level; Alcon data on file, 2009.
2. Woods J, Woods CA, Fonn D. Early symptomatic presbyopes—what correction works best? *Eye Contact Lens*. 2009;35(5):221–226.
3. Rappon J, Bergenske P. Air Optix Aqua Multifocal Contact Lenses in Practice. *Contact Lens Spectrum*. March 2010. Available at: www.clspectrum.com/article.aspx?article=103980; Accessed July 2012.
4. Rappon J. Center-near multifocal innovation: optical and material enhancements lead to more satisfied presbyopic patients. *Optom Vis Sci*. 2009;86:E-abstract 095557.
5. Alcon data on file, 2009.

AIR OPTIX® AQUA Multifocal (lotrafilcon B) contact lenses: Dk/t = 138 @ -3.00D.

* Compared to ACUVUE® OASYS®, PureVision® and Biofinity® contact lenses.

^ Trademarks are the property of their respective owners.

Important information for AIR OPTIX® AQUA Multifocal (lotrafilcon B) contact lenses: For daily wear or extended wear up to 6 nights for near/far-sightedness and/or presbyopia. Risk of serious eye problems (i.e., corneal ulcer) is greater for extended wear. In rare cases, loss of vision may result. Side effects like discomfort, mild burning or stinging may occur.

See product instructions for complete wear, care, and safety information.



Sponsored by

Alcon®



35th Annual Diagnostic Technology Report

Image Management Systems: What Can They Offer?

Software that integrates your diagnostic images might simplify your workflow and improve patient care. Here, a few early adopters share their experiences.

By Robert Murphy, Contributing Editor

Imagine you sit down for a consultation with a glaucoma patient and you want to show printouts of various imaging results over time. You open the manila folder to find an avalanche of paper tumbling onto your desk, which you scramble to organize quickly for discussion. *Careful:* there's a field printout that's out of order chronologically. *Whoops:* another field test appears to be missing altogether. Meantime, the patient looks on, wondering how a highly renowned local eye care provider can appear so disorganized while fumbling over apparently haphazard record keeping.

This was precisely the cumbersome manner in which Robert Stutman, O.D.—who practices with another optometrist plus four ophthalmologists at the two-location Select Eye Care in Towson, Md.—educated his patients... until about three ago when he and his colleagues finally said, *enough*. They researched the burgeoning market for clinical image management systems (IMS), and purchased one that, he says, has increased practice efficiency and workflow, saved time in

each exam, improved patient education, and presented a more professional image of the practice to patients.

What exactly are these systems? Approaches vary, but all seek to create a central repository of diagnostic imaging and data that come from diverse sources—cameras, perimeter, OCTs, topographers and more—so that they might yield more sophisticated clinical insights. They also help itinerant doctors stay in touch by providing access to their patient records while on the go.

While many practitioners have put plans to transition to electronic health records on hold—citing uncertainties as to how the Office of the National Coordinator will administer the health care stipulations of the American Reinvestment Act—others see a more pressing need to organize their clinical images now and display them in a



patient-friendly way. Dr. Stutman's experience affirms the clinical utility and favorable cost-benefit profile associated with today's image management systems.

Who Needs it?

Let's say you've yet to consider an image management system, much less take the EHR plunge. Consider how your office currently manages its clinical images. Maybe paper printouts of images stored in file folders serves your practice's needs. If so, an obvious question arises: Why bother with an image management system? If your image record-keeping doesn't appear to

Image Management System Vendors

System	Vendor	For More Information
Forum Eye Care Data Management	Carl Zeiss Meditec	www.meditec.zeiss.com/forum
iViews Imaging System	Chase & Associates	www.iviewsimaging.net
IMS/CL Clinical Image Management System	Hai Laboratories	http://hailabs.com/software/image-management
DigiVersal	Kowa	www.kowa-usa.com/kowanewweb/medical/solutions.html
Medflow Imaging	Medflow	www.medflow.com/imaging.php
Axis Image Management	Sonomed Escalon	www.topconmedical.com/products/synergy.htm
Synergy Ophthalmic Data Management	Topcon Medical Systems	www.topconmedical.com/products/synergy.htm

be broken, why fix it? And at a cost that's nothing to sneeze at, where's the cost-benefit payoff?

Let's revisit Dr. Stutman's office. His multidisciplinary practice includes glaucoma and retina specialists, generating many workups for macular degeneration and diabetic eye disease. The special testing used for these and other conditions yields a large quantity and wide variety of clinical imaging results.

"We had paper charts, [but they were] just getting out of control," Dr. Stutman says.

Given the increasingly central role that imaging plays in eye care, the process seemed untenable for the long-term. To that end, they obtained an image management system. "Our clients want to have everything in one place so they can look at progressive disease, observing change over time, with all the data right there in front of them," says one industry representative about the benefits to clinical care.

What's So Good About it?

Among Dr. Stutman's chief goals was to digitally organize his images, store them and retrieve them when necessary—and *wherever* necessary. No longer are images confined to a single device; any computer terminal or tablet in the office can be used as an image viewer, which helps add flexibility to the office workflow. Doctors and techs no longer compete for turns at the fundus cam-

era; one patient's findings can be reviewed at the same time another patient is being imaged.

"In terms of organizing and accessing the patient's special testing, it's much more efficient than I ever thought," Dr. Stutman says. And that's saying something, given the practice's volume of glaucoma, macular degeneration and diabetic eye disease, among other conditions. The sheer volume of images captured in the office signaled the need ultimately to organize all those pictures in a digital format.

"The nice thing about the system is that it has special filters that you can customize," Dr. Stutman says. Users can confine a search to one category, such as visual fields. "You can just look at visual fields and scroll through them all." That gives doctors the ability to observe the progression of a specific questionable field defect over time. "It's just much easier, much more efficient, much less time-consuming," he says.

These systems are the latest advance in a more general transition to digital images and software that facilitates swift migration of images and data from one site to another. "Image management systems are specific software programs that run outside of the EHR and are specifically designed to handle digital images," says Michael Chaglasian, O.D., chief of staff at the Illinois Eye Institute and associate professor at the Illinois College of Optometry.

Systems also combine multiple imaging modalities onscreen simultaneously, giving you a better appreciation of the patient's condition.

"A new module of patient care has developed where the O.D. has the opportunity to bring all diagnostic imaging together, even from instruments of different companies," Dr. Chaglasian says. "This allows us to easily and quickly view visual fields alongside the OCT and retinal photos, or to view a multi-year series of visual fields. Having quick and easy access to data that is centrally stored on the office PC network is a significant improvement over searching through paper charts."

IMS Meets EHR

Do image management systems and EHR systems play well together? No problem, says Dr. Stutman, whose practice's recent EHR implementation and coordination with the image management system was seamless. It didn't hurt that a staff well on its way to being computer-savvy came to the table with powerful pre-existing skills.

In Dr. Stutman's practice, the IMS preceded its EHR adoption. He says they weren't quite ready to transition to EHR, but saw the value of streamlining the imaging. In a sense, the IMS adoption was a warm-up to the larger and more formidable task of implementing EHR. It was right around then that Dr. Stutman and his colleagues put

computers in every room and signed on to e-prescribing, so the staff already had a head start.

“It made the transition to EHR easier,” Dr. Stutman says. “Our staff was already used to using the computers. And we already had the image part of our records, which were well taken care of. We didn’t have to make accommodations in our EHR system for all the pictures and the special testing.”

Dr. Chaglasian sees growing improvement in IMS/EHR compatibility. “EHR vendors and IMS vendors are working to create a seamless linkage between the patient’s EHR record and their IMS record,” Dr. Chaglasian says. “At present, I’ve been able to use the two side by side without a significant loss of efficiency. I’ve been working with my EHR and

IMS vendor, and in the near future they will be connected for an even quicker transition.”

Putting It Into Practice

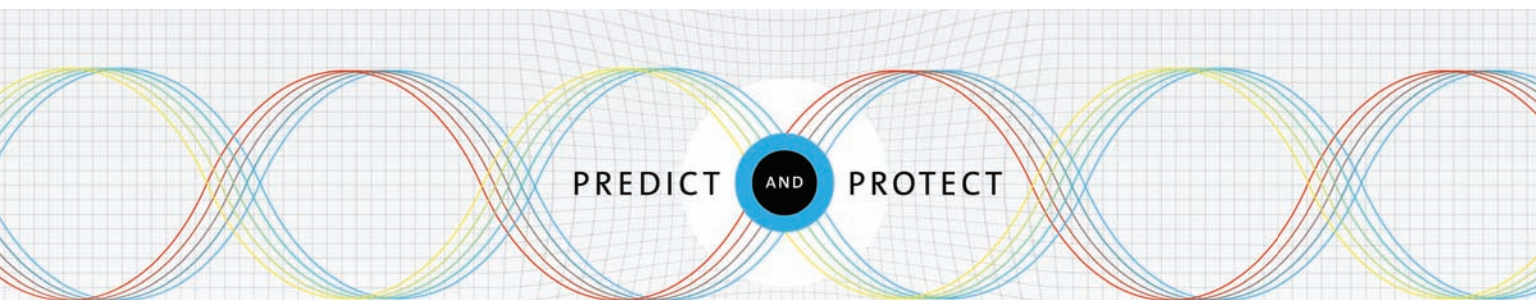
From anecdotal reports, it sounds like anyone who’s reasonably tech-savvy can adjust to use of such a system. The techs just take a picture, make one or two clicks on the source machine, and the image is sent to the server. “It happens immediately,” Dr. Stutman says. “When they bring that patient into the exam room, they pull it up on the screen for the doctor.”

You might expect a steep learning curve with a system of this sophistication, but Dr. Stutman says his is a very user-friendly system. And given the relative newness of these software packages, the vendors tend to roll out upgrades with new features

fairly rapidly. Systems are also scalable—they can expand or diminish as your practice’s usage dictates.

Is it worth it? Upfront costs vary widely, depending on the capabilities of the IMS and number of office locations involved—from about \$10,000 for a basic image viewer at a solo practice to perhaps a six-figure price tag for a multi-office setup that links dozens of devices.

Not everyone will find that the convenience of a high-tech solution to a practice’s deluge of data justifies the investment. But Dr. Stutman points out the impression it creates with patients. “I think you deliver better patient care, and you look better doing it,” he says. “It definitely has made our operation look more efficient as well as more patient-friendly. It’s also a lot easier to educate patients.” ■



AMD genetic testing

Macula Risk® is a prognostic DNA test intended for patients who have a diagnosis of early or intermediate AMD

- Macula Risk uses the complete combination of AMD genes and smoking history to identify those most likely to progress to advanced AMD with vision loss.
- A patient sample (cheek swab) is taken in your office, collected by FedEx and delivered to the testing lab.
- Most insurance providers including Medicare reimburse the test, and there is no cost to the doctor.

Visit us at Academy 2012 in Phoenix • October 24-27 • Booth #217

Find out more about becoming a Macula Risk Testing Center
www.macularisk.com • 1 866 964 5182





Review Takes Maiden Voyage to Puerto Rico

Attendees at *Review of Optometry's* Puerto Rico 2012 meeting garnered clinical insights on contact lenses, glaucoma and retinal disease from some of the profession's leading experts. **By Paul M. Karpecki, O.D., Clinical & Education Conference Advisor**

With standards of care evolving so quickly and new pharmaceuticals and instruments continually moving eye care forward, the collaborative experiences available to us at well-focused CE conferences are precisely how we improve and hone our clinical acumen—both individually and collectively as a profession. Education flourishes in the informal setting of a comfortable venue. And, when the meeting concludes, we return to our practices invigorated with renewed fervor for patient care.

Such is the premise of the ongoing educational series put on by *Review of Optometry*, for which I have the pleasure of serving as Education Chair. Our most recent program, *Review of Optometry's* Puerto Rico 2012 Meeting of Clinical Excellence, showcased an exceptional combination of interactive discussion, audience participation and professional partnership with several key industry sponsors to create a one-of-a-kind educational experience. Appropriately themed around “Pirates of the Caribbean,” *Review's* first-ever gathering in Puerto Rico was host to more than

200 attendees at the spectacular Ritz-Carlton San Juan from July 19-22. The beautiful tropical location was just a few steps from the ocean, and the Ritz-Carlton service was typical of its reputation.

From an education standpoint, *Review's* Puerto Rico 2012 meeting was highly unique in that all of the presentations truly were interactive, with the intention of enhancing attendees' clinical acumen. In turn, the attendees participated enthusiastically in each presentation, posing insightful questions and comments—increasing the overall interactive experience.

Best of all, this meeting provided attendees the opportunity to learn more about management strategies for a variety of ocular conditions

from some of the top lecturers in the country—all while earning 14 COPE-approved CE credits in the process. Here is a brief overview of several presentations:

- In “Learn to Treasure the Benefits of Premium IOLs,” I described useful tips for comanaging cataract surgery candidates who present with pre-existing corneal disease, such as Fuchs' dystrophy or herpes simplex keratitis. Additionally, I reviewed the potential benefits and inherent limitations of several premium IOL options, including torics, multifocals and accommodating lenses.

- Then, in “Captain Jack's Guide to Contact Lens Selection,” contact lens specialist Jack Schaeffer, O.D., reviewed some of the key considerations that you must account for when deciding upon various lens modalities for your patients, with an emphasis on how to convey the benefits of specialty lenses and other premium options. Additionally, he discussed the latest developments in lens material technology, as well as how patients with ocular surface disease may benefit from the use of bandage or scleral lenses.

- Diana Shechtman, O.D., and Robert Wooldridge, O.D., teamed

This Year's Industry Sponsors

- **Gold Level**
Carl Zeiss Vision
- **Silver Level**
Hydrogel Vision Corporation
- **Bronze Level**
Allergan
Bruder Healthcare
Essilor
SpecialEyes
- **Educational Grant Support**
Alcon
Bausch + Lomb

JUST
NOT JUST
SURE

Does your lab have commitment issues?

**PRODUCT
QUALITY**

**PERSONAL
SERVICE**

INDEPENDENCE

COMMITMENT

Three Rivers Optical is committed to your success. You need a partner who is committed to exceeding your expectations.

We do that—we never settle for adequate materials and technology, we source the best, we never ask you to compromise your prescription requirements, we will meet your specifications from our extensive lens options. We never bounce you around customer service if you have a problem, we want you to call our CEO, Steve Seibert,

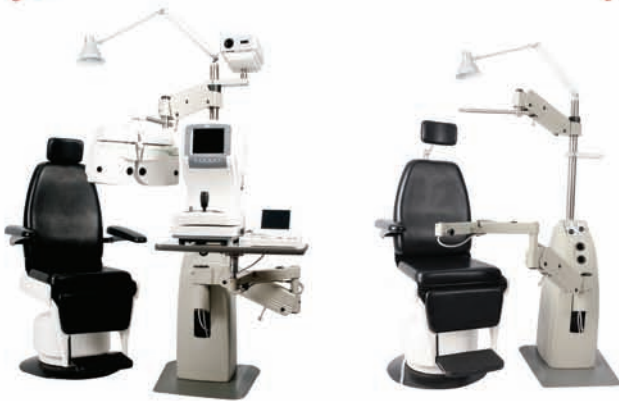So take the plunge and get a partner for the long haul.



**Why Wait Till Black Friday,
Take Advantage of this Amazing
Savings this Month of September!**



Scan Here to View
More Information



Purchase Ezer's
Autorefractor/Keratometer
Chart Projector &
Digital Refractor
& Receive

**FREE
ERU-7200**



Distributed By:



Toll Free: 888-334-4640
info@usophthalmic.com
www.usophthalmic.com

up to deliver a fast-paced, interactive presentation, “X Marks the Spot of Macular Disease and Glaucoma,” which reviewed a host of differential diagnoses for various retinal disease states and glaucomatous presentations.

- In “A Pirate’s Adventures in Anterior Segment Disease,” Jimmy Bartlett, O.D., and I reviewed essential diagnostic procedures for some of the most common anterior segment conditions, including dry eye disease and allergic conjunctivitis. Then, we discussed optimal treatment strategies, as well as prompted the audience to provide us with clinical insight based upon their unique experiences in daily practice.

- Dr. Shechtman delivered one of the most important presentations of the entire meeting: “Don’t Walk the Plank: Know When to Refer.” During her lecture, she emphasized why it’s essential to understand precisely when you must refer a patient to an ophthalmologist or another specialist. Not only does a prompt referral ensure that a patient will receive optimal medical care, it can also help protect you against potential legal complications. Throughout this course, Dr. Shechtman spent considerable time reviewing visually devastating retinal conditions that often require a timely referral, such as retinal vein and artery occlusions.

- Later in the day, Dr. Wooldridge introduced new evidence-based medicine to support novel methods of glaucoma detection and diagnosis, disease progression monitoring and intraocular pressure regulation in “You’ll Need All Hands on Deck to Manage IOP.”

- Finally, Drs. Bartlett, Schaeffer and I provided a review of the allergic cascade in “Break the Curse of the Dreaded Allergic Reaction.” In addition to describing the impact of allergic conjunctivitis, we discussed the potential systemic ramifications associated with seasonal and perennial allergies. Additionally, we offered many clinical pearls on how to most effectively help your patients avoid repeated exposure to common allergens, such as pollen, animal dander and dust mites, in an effort to improve their quality of life.

Review of Optometry’s Puerto Rico 2012 Meeting of Clinical Excellence truly was a one-of-a-kind gathering. I hope you have the opportunity to attend a future *Review of Optometry* meeting throughout the remainder of 2012—including the New Technology and Treatments Conference at Torrey Pines in San Diego from September 21-23 and the inaugural Northeast New Technology and Treatments Conference in Philadelphia from November 30 to December 2. ■

If your presbyopic patients aren't in AIR OPTIX® AQUA Multifocal contact lenses,

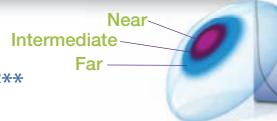
they may **NOT** be seeing the full picture.



Make a smooth transition with a great multifocal lens—
AIR OPTIX® AQUA Multifocal contact lenses



• AIR OPTIX® AQUA Multifocal contact lenses outperform monovision for superior vision with emerging presbyopes,^{2**} and are preferred by patients over PureVision[^] Multi-Focal^{3†} and ACUVUE[^] OASYS[^] for PRESBYOPIA contact lenses^{4††}



- Precision Profile™ Lens Design has a smooth transition from center near to intermediate and distance zones
- 96% of eye care practitioners agreed AIR OPTIX® AQUA Multifocal contact lenses are easy to fit⁵

Visit myalcon.com to learn more.

*AIR OPTIX® AQUA Multifocal (lotrafilcon B) contact lenses: Dk/t = 138 @ -3.00D. **Based on subjective ratings of intermediate and distance vision, and vision for daytime driving, night driving, and TV viewing. †In emerging presbyopes, among those with a preference. ††Among those with a preference. ^Trademarks are the property of their respective owners.

Important information for AIR OPTIX® AQUA Multifocal (lotrafilcon B) contact lenses: For daily wear or extended wear up to 6 nights for near/far-sightedness and/or presbyopia. Risk of serious eye problems (i.e. corneal ulcer) is greater for extended wear. In rare cases, loss of vision may result. Side effects like discomfort, mild burning or stinging may occur.

References: 1. Based on third-party industry report, Alcon data on file, Jan 2010-Sep 2011. 2. Woods J, Woods C, Fonn D. Early symptomatic presbyopes—What correction modality works best? *Eye Contact Lens*. 2009;35(5):221-226. 3. Rappon J. Center-near multifocal innovation: optical and material enhancements lead to more satisfied presbyopic patients. *Optom Vis Science*. 2009;86:E-abstract 095557. 4. In a randomized, subject-masked clinical study at 20 sites with 252 patients; significance demonstrated at the 0.05 level; Alcon data on file, 2009. 5. Rappon J, Bergenske P. AIR OPTIX® AQUA Multifocal contact lenses in practice. *Contact Lens Spectrum*. 2010;25(3):S7-S9.

See product instructions for complete wear, care, and safety information.

Alcon

© 2012 Novartis 2/12 AOM12002JAD

Rx only



Explanations for Sudden Vision Loss

Here, we examine non-traumatic causes of sudden vision loss as well as discuss diagnostic testing procedures and management strategies. **By Denise Goodwin, O.D.**

Sudden vision loss is a common complaint in eye care practices. Often, such a situation requires urgent attention. It can represent something relatively benign such as dry eye, or be a warning sign of a stroke. Depending on the etiology, vision loss can be permanent. Other times, however, it is transient—lasting for seconds to hours.

Proper diagnosis and management of sudden vision loss requires a methodical case history and examination, which can prevent permanent vision loss and, in some cases, save lives.

Patient History

There are many causes of sudden vision loss, making diagnosis some-

what difficult. Therefore, the value of a careful case history in identifying the underlying cause cannot be overstated. The history alone should be suggestive of the diagnosis prior to actual testing. Onset, laterality, duration and associated symptoms are particularly important in determining the nature of the condition.

In some situations, sudden vision loss is not actually of recent onset; but rather, the patient just recently became aware of the vision loss. We have all experienced the patient who, by chance, covers an eye and finds that vision “suddenly” is very blurry in the opposite eye. In these cases, a careful case history, refraction and ocular health examination are necessary to determine the cause of the vision loss. Obtaining prior

examination records also can be helpful in managing these cases. Don't assume that something is benign just because it was noticed suddenly. For example, figure 1 depicts a patient who presented for a comprehensive vision examination with no complaints. When covering her left eye to perform visual acuity testing, the patient realized that she suddenly could not see with her right eye. The patient had choroidal neovascularization and subretinal hemorrhages in the macular area O.D. The left eye exhibited trace drusen from macular degeneration.

When a patient presents with sudden vision loss, it is important to clarify whether the loss is monocular or binocular. Patients commonly confuse a homonymous hemianopia

Release Date: September 2012

Expiration Date: September 1, 2015

Goal Statement: Sudden vision loss is a common complaint in eye care practices. It can represent something relatively benign such as dry eye, or be a warning sign of a stroke. Depending on the etiology, vision loss can be permanent. Other times, however, it is transient—lasting for seconds to hours. Proper diagnosis and management of sudden vision loss requires a methodical case history and examination, which can prevent permanent vision loss.

Faculty/Editorial Board: Denise Goodwin, O.D.

Credit Statement: COPE approval for 2 hours of CE credit is pending for this course. Check with your local state licensing board to see if this counts toward your CE requirement for relicensure.

Joint-Sponsorship Statement: This continuing education course is joint-sponsored by the Pennsylvania College of Optometry.

Disclosure Statement: Dr. Goodwin has no relationships to disclose.

with monocular vision loss on the side of the hemianopia. Therefore, objective determination of the laterality is important. Also, in addition to laterality, the duration of vision loss can give important clues to the cause (see “Duration, Causes and Associated Findings of Sudden Vision Loss,” page 77).

Associated medical conditions, such as hypertension, hyperlipidemia or diabetes, raise suspicion that a vascular disease could be the cause of vision loss. Patients with painless vision loss and significant cardiovascular risk factors should be evaluated with particular attention for retinal artery or vein occlusion. Further, a vitreous hemorrhage is a common cause of sudden vision loss in a patient with diabetes.

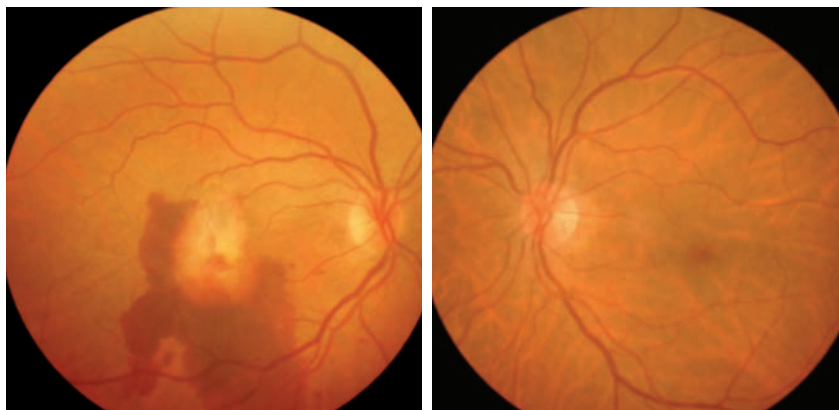
Examination and Testing

Numerous diagnostic evaluations can help you determine the fundamental cause of your patients’ vision loss. Here’s what you should know:

- **Basic testing.** Rudimentary examination techniques are vital to confirm the proper diagnosis. The first task is to determine the best-corrected visual acuity. Additionally, pinhole testing is crucial in narrowing down the potential causes of vision loss. Color vision should be performed monocularly with pseudoisochromatic plates. Also, checking for red desaturation can aid in determining the presence or absence of optic nerve involvement.

- **Pupil testing.** Pupil reactions—especially the presence of a relative afferent pupillary defect (RAPD)—are important when evaluating vision loss. Significant retinal dysfunction or any asymmetric optic nerve dysfunction will result in an RAPD. In addition, a fixed, mid-dilated pupil is suggestive of angle-closure glaucoma.

- **Visual fields.** Visual field testing is necessary to determine the



1. Choroidal neovascularization and subretinal hemorrhage in the right eye of a patient with age-related macular degeneration (left). Note the subtle drusen formation in the macular area of the left eye (right).

extent and pattern of the vision loss. A monocular visual field defect should guide you to a lesion located anterior to the optic chiasm. Lesions posterior to the chiasm will cause visual field loss in both eyes in the form of a homonymous hemianopia. Use Amsler grid testing to look for metamorphopsia, which is indicative of a macular lesion. Additionally, confrontation visual fields are quick and should be done on all patients with vision loss.

- **Slit lamp exam.** Biomicroscopy, including fluorescein staining, detects corneal or anterior chamber irregularities that might contribute to the vision loss. Look for corneal edema or ulcers, as well as anterior chamber inflammation or hyphema. Lack of conjunctival inflammation in a patient with vision loss and ocular pain may lead to a diagnosis of optic neuritis. Furthermore, if the eye is inflamed and the anterior chamber is narrow, take an IOP measurement and perform gonioscopy to evaluate the patient for angle-closure glaucoma.

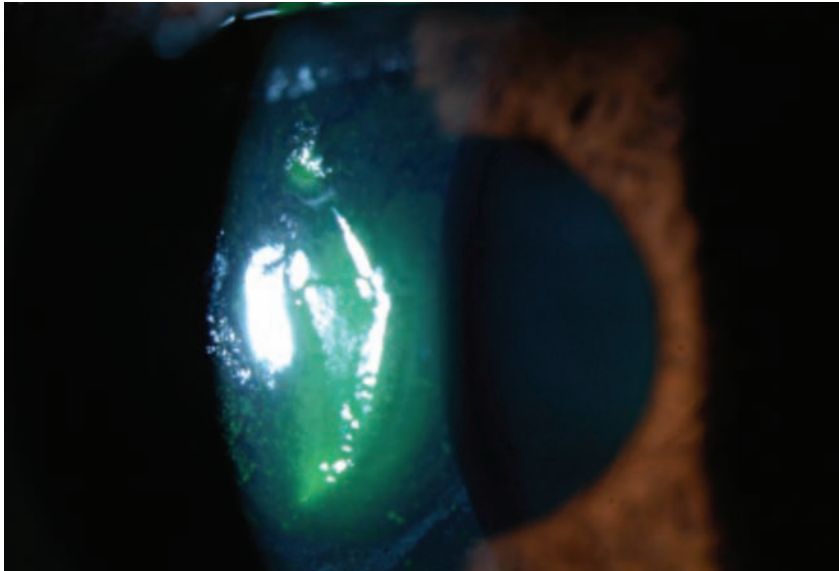
- **Fundus photography.** Most retinal disorders that are severe enough to produce vision loss are visible during a careful fundus examination. Scrutinize the optic disc to look for subtle optic nerve edema. If you

experience difficulty seeing a normal red pupil reflex despite the cornea and lens being clear, suspect a vitreous hemorrhage.

- **Lab testing.** Laboratory studies may be necessary, depending on the suspected cause of vision loss. Those with sudden vision loss who are over the age of 55 should undergo testing for giant cell arteritis (GCA), including a complete blood count (CBC), platelet count, erythrocyte sedimentation rate (ESR) and C-reactive protein (CRP). Screening for hyperlipidemia and diabetes is helpful

Laboratory Testing for Patients with a Suspected Hypercoagulable State

- Complete blood count (CBC)
- Erythrocyte sedimentation rate (ESR)
- Antinuclear antibody (ANA)
- Protein C and protein S
- Homocysteine levels
- Lupus anticoagulant
- Activated protein C resistance (factor V Leiden)
- Prothrombin time
- Partial thromboplastin time
- Antithrombin III
- Fibrinogen
- Anticardiolipin antibody
- Serum protein electrophoresis



2. Corneal abrasion with surrounding edema.

to find cardiovascular risk factors. Laboratory testing for a hypercoagulable state may be necessary for patients who experience a retinal vein occlusion or in younger patients who experience sudden vision loss. Also, in-office blood pressure measurement is indispensable for all patients with sudden vision loss.

- **Further screening.** Additional testing, including optical coherence tomography (OCT), fluorescein angiography, neuroimaging, carotid Doppler ultrasonography, echocardiography or temporal artery biopsy may be necessary, depending on the suspected cause of vision loss.

What Caused It?

The etiology of non-traumatic sudden vision loss usually can be classified into four main categories: media opacities, retinal abnormalities, neurologic disease or functional disorders. Trauma is a significant cause of sudden vision loss, so care should be taken to rule out any injury to the globe, such as blunt trauma, lacerations or penetrating injuries, as well as either open or closed head trauma. In addition, many drugs have been reported to

cause sudden vision loss, so it is important to review medications with any patient who experiences vision loss.

Media Opacities

Any substantial irregularity of the ocular media will cause decreased vision. Media opacities will not produce an RAPD and are usually easily visible with slit lamp examination.

- **Corneal edema.** Corneal infection, inflammation or abrasion can cause acute vision loss. Recurrent corneal erosion is a common cause of sudden pain and vision loss (*figure 2*). Patients should be questioned about contact lens use and previous ocular injuries. Consider corneal hydrops in patients who have a history of keratoconus.

Patients with corneal involvement often report pain and photophobia. The conjunctiva is hyperemic, and fluorescein staining typically will be present. Treatment may involve topical antibiotics or steroids, discontinuation of contact lens wear or a bandage contact lens, depending on the cause.

- **Angle-closure glaucoma.** Angle-closure glaucoma results in a

painful, red eye and increased IOP. Occasionally, patients have no pain, making the differential from transient difficult.^{1,2} Patients also report blurred vision, halos around lights, and nausea and vomiting.

The cornea is edematous, and the conjunctiva is hyperemic. The pupil is fixed in a mid-dilated position and the iris is bowed forward. Tonometry and gonioscopy should be performed to make this diagnosis.

Initial treatment consists of topical IOP-lowering medications, steroids and miotics, as well as systemic carbonic anhydrase inhibitors and hyperosmotic agents. Compression gonioscopy can be helpful to open the angle. Laser peripheral iridotomy is necessary for long-term control.

- **Hyphema.** A hyphema can cause reduced vision (*figure 3*). The most common cause of hyphema is trauma, but other causes such as rubeosis iridis, ocular tumor, intraocular surgery, carotid stenosis or blood dyscrasias can predispose a person to a hyphema.

Treatment involves bed rest with head elevation, topical steroids and cycloplegic agents, IOP-lowering medications, and treatment for the underlying cause. Surgical evacuation may be necessary if the IOP remains uncontrolled following anti-glaucoma medication use. The patient should be followed for associated secondary glaucoma, cataract, vitreous hemorrhage or retinal detachment.

- **Vitreous hemorrhage.** Vitreous hemorrhage (*figure 4*) may be caused by trauma, retinal vasculitis, retinal tear or detachment, or posterior vitreous detachment.³⁻⁶ Additionally, conditions that can cause retinal ischemia and neovascularization, such as diabetes or central retinal vein occlusion, predispose a person to a vitreous hemorrhage.⁶ A subarachnoid hemorrhage also can

be associated with a vitreous hemorrhage (Terson syndrome).⁷ This can occur with intracranial aneurysms, shaken baby syndrome, or other causes of sudden increase in intracranial pressure.

Those with a vitreous hemorrhage report sudden, painless vision loss. Patients may note floaters, a haze or a red hue in their vision. A dilated fundus exam should be performed. A vitreous hemorrhage is suspected if you are unable to view a red reflex of the fundus (without the presence of cataract).

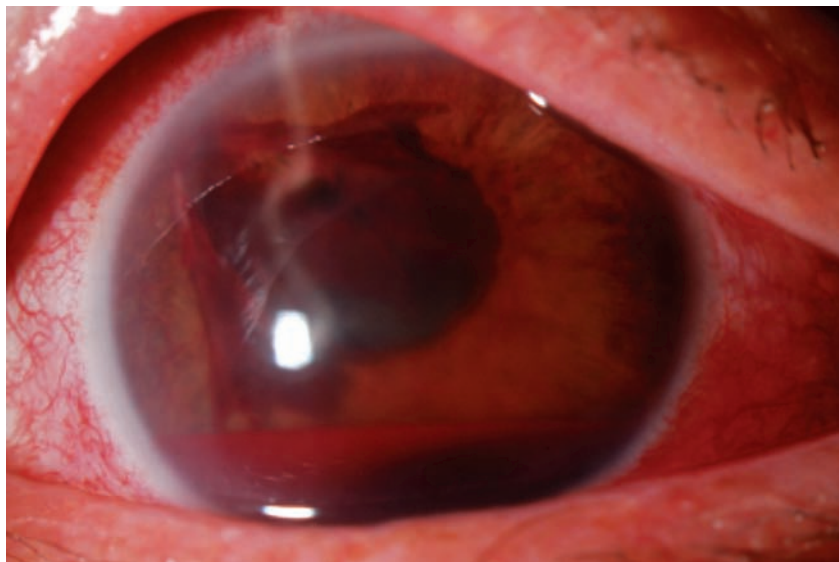
B-scan ultrasonography is warranted in these patients to rule out a retinal tear or detachment. The blood often will clear naturally, but the underlying cause should be treated appropriately. Keeping the head immobilized in an upright position permits faster resolution, especially if treatment of a superior retinal tear is necessary. Vitrectomy may be considered if the hemorrhage does not clear or the patient is at risk for progression to a retinal detachment.

Retinal Abnormalities

Sudden vision loss can occur due to retinal detachment, infection, inflammation or ischemia. Ophthalmoscopic findings are essential in differentiating the cause.

- **Retinal detachment.** A retinal detachment involving the macula will result in sudden and severe vision loss. A peripheral retinal detachment will cause more localized peripheral vision loss. Complaints include visual field defects, flashes of light, a lava-lamp or curtain-like appearance in the peripheral vision, increased floaters or even color vision changes.⁸⁻¹² Be more suspicious of a retinal detachment in older patients as well as in those with a history of ocular trauma, high myopia or previous cataract surgery.

An RAPD may be present if the retinal detachment is extensive.



3. Hyphema and iris neovascularization in a patient with diabetes.

On fundus examination, look for an elevated retina. Folds often will be present and the tissue may be pale and edematous. The choroidal background will be indistinct. These patients should be referred to a retinal specialist for immediate treatment.

- **Acute maculopathy.** Various maculopathies result in sudden vision loss. These include central serous retinopathy, clinically significant macular edema and choroidal neovascularization. Often, these patients report metamorphopsia and are slow to recover from bright light.

Lesions usually are found upon careful fundus examination, but may be subtle. An RAPD usually is not present. OCT and fluorescein angiography are invaluable in these patients. Treatment is dependent on the cause. Neovascularization may be treated with panretinal photocoagulation or anti-vascular endothelial growth factor (VEGF) injection.

- **Transient monocular blindness.** Transient monocular vision loss due to vascular insufficiency commonly is termed amaurosis fugax. Although the risk of stroke is not as great as that seen after a transient ischemic

attack (TIA) of the brain, patients who experience amaurosis fugax are at an increased risk of ischemic stroke.¹³

Vision loss is sudden and painless, and typically persists from one to 10 minutes. Rarely, it can last longer than 60 minutes.^{13,14} It may have an altitudinal onset and produce partial or complete vision loss. Occasionally, transient vision loss occurs after exposure to bright light. This is indicative of ocular ischemic syndrome and is associated with severe carotid artery stenosis.¹⁴

Examine the patient carefully for an embolus in a retinal arteriole. Emboli generally are composed of cholesterol, fibrin or calcified particles. The appearance of each embolus can give clues to the underlying cause.

Cholesterol emboli (Hollenhorst plaques) from an ulcerated atherosclerotic plaque in the internal carotid artery are found at retinal artery bifurcations and have a bright, yellow-orange, retractile appearance. Fibrin tissue is grayish white, non-refractile, and often fills a segment of an artery. Check these patients for a local process,

hypercoagulable state, or cardiac or carotid source. Calcified particles appear white and arise from calcified heart valves.

A referral should be made to a primary care physician for evaluation of cardiovascular risk factors, such as hypertension, hyperlipidemia and diabetes mellitus. Additionally, carotid duplex imaging and echocardiographic studies are warranted to look for sources of the embolism. A carotid artery ultrasound is useful to determine if surgical intervention is necessary. Patients with less than 50% stenosis can be treated for vasculopathic risk factors and then monitored.¹⁵ Antiplatelet therapy can help to reduce the risk of stroke in these patients.¹⁶

Referral to a vascular surgeon may be necessary for symptomatic patients with greater than or equal to 70% stenosis, because a carotid endarterectomy can reduce the risk of cerebral infarction. The North American Symptomatic Carotid Endarterectomy Trial established six criteria to aid in the identification of patients who would benefit from carotid endarterectomy.⁸ Following a transient retinal ischemic attack, a patient would benefit from a carotid endarterectomy if he or she exhibits at least three of the following risk factors:^{13,17}

- Older than age 75.
- Male gender.
- History of TIA or stroke.
- History of intermittent claudication.
- 80% to 94% stenosis.
- Lack of collateral vessels on angiography.

Screening for thrombophilia and hyperviscosity syndromes may be warranted if other cardiovascular risk factors are not present. In addition, be sure to rule out GCA in those over the age of 55. Further, if the patient is a smoker, strongly encourage cessation.

• **Retinal artery occlusion.** An embolus or thrombus occluding the central retinal artery, as occurs with central retinal artery occlusion (CRAO), can cause prolonged interruption of the blood supply to the retina and permanent damage to the retinal tissue. Vision loss is severe, sudden and painless. Visual acuity typically is finger counting or worse, and the patient will exhibit an RAPD. Often, patients have a history of vasculopathic risk factors.

Retinal appearance is dependent upon the amount of time that has passed since the event occurred. Within a few hours, the arteries will be attenuated and venous “boxcar-ing” will be evident. After several hours, the retina becomes edematous and semi-opaque. Because the macula is supplied by the intact choroidal blood supply, it assumes a very red appearance (in stark contrast to the pallorous nature of the ischemic surrounding retina). This produces the classic “cherry-red spot” that is associated with CRAO. Central vision may be preserved if the macula is supplied by a cilioretinal artery. Weeks later, a pale optic disc will be seen due to death of ganglion cells.

Emergency measures, including ocular massage, intravenous intraocular hypotensive medications and paracentesis of the anterior chamber, may be employed. Unfortunately, none of these methods have been shown to change the natural course and poor prognosis of the condition.^{18,19} Thrombolytic agents may have promise in dispersing a clot if delivered within the first four hours; but, a recent randomized clinical trial was discontinued early due to lack of efficacy and a high rate of adverse reactions.¹⁸⁻²²

Keep in mind that these patients have an increased risk of stroke and should undergo a systemic evaluation to determine the underlying

cause of the occlusion.^{19,23} Carotid artery duplex scan can be used to determine if surgical intervention is necessary. Echocardiography is also useful in finding the embolic source.²⁴ Younger patients should undergo testing for hypercoagulable states. Be sure to order ESR and CRP testing for all patients over the age of 55 to rule out GCA as an underlying cause.

• **Retinal vein occlusion.** Retinal vein occlusion is found most commonly in adults over age 60 who exhibit several vasculopathic risk factors, such as hypertension, hyperlipidemia, diabetes, and arteriosclerosis, as well as those with hyperviscosity syndromes.²⁵

Glaucoma is another important risk factor associated with retinal vein occlusion.^{25,26} In this capacity, it has been postulated that increased IOP may cause a shift in the lamina cribrosa (resulting in outflow blockage), induce central retinal vein compression or precipitate venous stasis.^{25,26}

Patients who experience a retinal vein occlusion may present with a small scotoma, which is indicative of a branch retinal vein occlusion (BRVO), or overall vision loss, which is indicative of a central retinal vein occlusion (CRVO). Vision loss is related to retinal perfusion.²⁵ The more common, non-ischemic form of CRVO presents with mild-to-moderate loss, whereas patients with ischemic CRVO often experience severe visual compromise. Those with ischemic CRVO also will have an RAPD.

CRVO has a very distinct appearance. Diffuse retinal hemorrhages, venous engorgement and tortuosity, cotton-wool spots and optic disc swelling may be present. OCT and fluorescein angiography are useful in evaluating the retina and macular edema.

Management should be aimed at

Duration, Causes and Associated Findings of Sudden Vision Loss

Duration	Potential Causes	Associated Findings
Seconds	Dry eye or other tear film abnormalities	Foreign body sensation, lacrimation
	Papilledema	Headache, tinnitus, bilateral disc edema
	Compressive optic neuropathy	Vision loss in certain positions of gaze, extraocular muscle restriction, proptosis
	Orthostatic hypotension	Near syncope
1 to 10 minutes	Amaurosis fugax	Cardiovascular risk factors, unilateral
	Transient ischemic attack of the brain	Cardiovascular risk factors, homonymous hemianopia, numbness or weakness of extremities, impaired speech or memory
	Giant cell arteritis	Elderly patient, headache, jaw claudication, temporal artery tenderness, myalgia, weight loss
10 to 60 minutes	Migraine	Scintillating scotoma, associated headache with photophobia, phonophobia, nausea/vomiting
Minutes to hours	Transient angle-closure glaucoma	Halos around lights, nausea, eye or head pain, narrow anterior chamber angle, conjunctival injection, corneal edema, high IOP
Days to Indefinite	Corneal infection, inflammation, abrasion	Eye pain, redness, photophobia
	Hyphema	History of trauma or cardiovascular disease
	Vitreous hemorrhage	Painless vision loss, floaters, hazy vision, view of the retina is obscured
	Acute maculopathy	Metamorphopsia
	Retinal detachment	Increase in floaters, photopsias, visual field defect
	Retinal artery occlusion	Painless, severe loss of vision, cardiovascular risk factors
	Retinal vein occlusion	Painless vision loss, retinal hemorrhages, venous engorgement and tortuosity, cotton-wool spots, optic disc edema
	Optic neuritis	Pain with eye movements, RAPD, abnormal color vision, vision starts to improve by two to four weeks
	Non-arteritic ischemic optic neuropathy	Painless, disc at risk, vasculopathic risk factors
	Arteritic ischemic optic neuropathy	Elderly patients, headache, jaw claudication, temporal artery tenderness, myalgia, weight loss

carrying for underlying causes, such as vasculopathic risk factors and glaucoma. Potentially blinding sequelae that are specifically associated with ischemic CRVO include neovascular glaucoma, cystoid macular edema, macula ischemia and vitreous hemorrhage.²² Treatment for these sequelae includes anti-VEGF therapy, panretinal laser and intravitreal corticosteroid injection.²⁷

Neurologic Disease

Without question, any disease that affects the optic nerve can result in sudden vision loss.

- **Papilledema.** Increased intracranial hypertension that results in papilledema can cause transient visual obscurations secondary to pos-

tural changes. Papilledema often is described as a graying out of vision, but can cause blur, total blindness or photopsias. Vision usually recovers within seconds. Also, these patients often have headaches, nausea, vomiting, pulsatile tinnitus or diplopia.

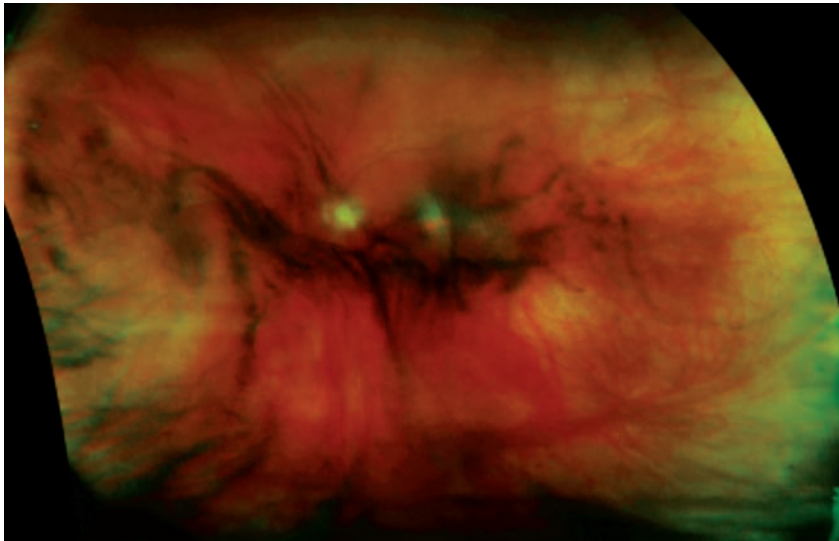
Visual acuity and pupils usually are normal. Visual field testing most commonly indicates an enlarged blind spot. However, the underlying cause of the papilledema may produce other visual field defects. Ophthalmoscopy will reveal bilateral optic disc swelling.

Although one common cause of papilledema is idiopathic intracranial hypertension (IIH), prompt neuroimaging is required to rule out other causes of increased intracranial pres-

sure. Magnetic resonance venography is necessary to rule out cerebral venous sinus thrombosis. Following negative neuroimaging, lumbar puncture should be performed.

Management of papilledema involves identifying and managing the underlying cause. Treatment for IIH includes carbonic anhydrase inhibitors and weight loss. If visual loss progresses despite medical treatment, optic nerve sheath decompression or a ventriculoperitoneal shunt may be necessary.

- **Optic neuritis.** Optic neuritis can be caused by infectious or inflammatory processes. The most common cause of optic neuritis is demyelinating disease (i.e., multiple sclerosis).



4. Vitreous hemorrhage following a posterior vitreous detachment.

Patients with demyelinating optic neuritis typically are white, female and between the ages of 20 and 50. Demyelinating optic neuritis causes complete monocular vision loss for several days. In most instances, vision will begin to recover within two to four weeks. Patients often report pain upon ocular movement, which improves at about the same time the vision loss occurs. They should be questioned about associated neurologic symptoms, such as double vision, tingling or numbness of the extremities, and bowel/bladder issues.

These patients experience color vision desaturation and an RAPD. Optic nerve inflammation is evident in just one-third of cases.²⁸ Neuroimaging is not necessary to confirm the diagnosis of demyelinating optic neuritis, but should be performed to determine the risk of developing multiple sclerosis. The visual prognosis is good for these patients, with up to 93% experiencing visual recovery to at least 20/40 and 74% achieving 20/20 or better.²⁹ Also, OCT is useful in monitoring the optic nerve over time.

• **Ischemic optic neuropathy.**
Non-arteritic ischemic optic

neuropathy (NAION) results in painless, monocular vision loss that may progress over hours to days in a patient with vasculopathic risk factors, such as diabetes or hypertension.

Most patients with NAION have visual acuity better than 20/200. Additionally, loss of color vision, an RAPD and visual field loss (most commonly altitudinal or arcuate) will be present. Typically, fundus examination reveals optic disc edema with flame-shaped retinal hemorrhages. The opposite disc exhibits a small physiologic cup (disc at risk). After four to six weeks, the affected disc develops pallor.

Unfortunately there is no definitive treatment for NAION. Although controversial, Sohan Singh Hayreh, M.D., Ph.D., and associates have suggested that the administration of high-dose systemic steroids during the acute phase may provide better visual acuity and field outcomes.³⁰⁻³² An ESR and CRP should be performed in those patients to rule out GCA as a cause of the ischemic optic neuropathy.

The patient should be referred to his or her primary care provider for

management of any vasculopathic risk factors. Patients with elevated blood pressure should be instructed not to take hypertensive medications at night. Some experts recommend aspirin.³⁰ Although aspirin's role in NAION has not yet been proven, it is effective in reducing the risk of stroke and myocardial infarction in such at-risk patients.²⁵

Vision loss associated with GCA can be transient or permanent. Patients may have a history of transient vision loss or diplopia. Systemic symptoms include headache, scalp tenderness, pain after chewing, fever, malaise, lack of appetite, weight loss, and tenderness of muscles or joints.

Arteritic anterior ischemic optic neuropathy (AAION) will cause sudden, profound, monocular or binocular vision loss with pallid optic nerve swelling. If vision loss is monocular, an RAPD will be present. Decreased or absent temporal artery pulse and firmness of the temporal artery may be seen.

Any patient over the age of 55 who presents with sudden vision loss should be tested to rule out GCA. An immediate ESR, CRP and CBC with platelet count should be obtained. Referral for a temporal artery biopsy should be considered if the suspicion for GCA is high. A temporal artery biopsy performed soon after the diagnosis will not be affected by corticosteroid treatment, and so treatment should be initiated immediately.

It is critical that patients suspected of GCA begin treatment with high-dose systemic steroids immediately in order to prevent vision loss in the contralateral eye as well as to reduce the risk of stroke or myocardial infarction.

• **Compressive optic neuropathy.**
Sudden vision loss can occur with changes in gaze in patients with an intraconal mass, orbital trauma or

thyroid eye disease.^{33,34} Vision will black out in eccentric positions of gaze and then come back rapidly when returning to primary position. An RAPD may be present if the condition is asymmetric. Proptosis or extraocular muscle restrictions may be present. The optic disc can be swollen, pallorous or normal, and choroidal folds may be visible. IOP can increase dramatically when it is acquired in varying positions of gaze. Magnetic resonance imaging (MRI) of the orbits and chiasm will reveal the cause of vision loss.

• **Chiasm or retrochiasmal disorder.** The most common cause of a homonymous hemianopia in adults is stroke.^{35,36} Other causes include trauma, tumor, demyelination, inflammation and migraine. A transient homonymous visual field defect should alert the doctor to a TIA.

Vision loss is bilateral, but central visual acuity usually is spared. Vision loss associated with a TIA typically has a more abrupt onset and shorter duration (three to 10 minutes), as well as negative features rather than photopsias. Also, remember to look for associated symptoms, such as numbness/weakness of the extremities or impaired memory or speech.

Patients who experience visual field loss that respects the vertical midline should have a CT scan or MRI in order to determine the cause. An occipital lobe infarction usually produces an isolated homonymous hemianopia without other neurological signs or symptoms. Occlusion of the middle cerebral arteries that affects the temporal or parietal lobe also can cause a homonymous hemianopia, but these patients often have other neurological signs and symptoms that are not visually related.

• **Migraine/idiopathic.** Many episodes of transient vision loss in people younger than are 45 are caused by migraine. Migraine aura

without headache is common in people over age 50. Usually these patients experience positive phenomena, such as flashing lights or scintillating scotoma, rather than the dark vision associated with amaurosis fugax or TIA. Because migraine and angle-closure glaucoma have similar symptoms—including recurring unilateral headache, photophobia and nausea—the anterior angle depth should be examined.

Monocular vision loss from a retinal migraine is very rare.³⁷ Here, there are repeatable episodes of reversible monocular scintillations or vision loss associated with a migraine headache. All other causes, especially angle-closure glaucoma and amaurosis fugax, must be excluded prior to making this diagnosis.

Functional Vision Loss

Differentiating organic from non-organic vision loss can be difficult. Testing often is inconsistent. Doubling the distance while testing visual acuity and/or performing visual fields using a tangent screen can aid in differentiating these conditions.

Visual field characteristics associated with functional vision loss include a tubular appearance, inward spiraling of the visual field as the test progresses, or generalized visual field constriction that manifests in a cloverleaf pattern.

The ability to perform stereoacuity tasks in the presence of monocular vision loss should heighten your suspicion that functional loss is present. Pupil reactions will be normal. If the diagnosis is in question, a visual evoked potential test may be warranted.

Sudden vision loss may be attributed to relatively benign causes, such as dry eye disease or migraine. However, more serious causes are common, including GCA, carotid artery

disease or retinal detachment. Familiarity with the different causes of acute vision loss will make it more likely that you arrive at the correct diagnosis. Timely diagnosis and management is crucial in obtaining a positive outcome for your patient. ■

Dr. Goodwin is an associate professor at Pacific University College of Optometry. She teaches functional neuroanatomy and neurobiology, ophthalmic imaging and optometric clinical procedures. She also advises third-year students in primary care clinic. She is coordinator of the neuro-ophthalmic disease referral service at Pacific University.

1. Abe A, Nishiyama Y, Kitahara I, et al. Painless transient monocular loss of vision resulting from angle-closure glaucoma. *Headache*. 2007;47(7):1098-9.
2. Sihota R. Classification of primary angle closure disease. *Curr Opin Ophthalmol*. 2011;22(2):87-95.
3. Takano M, Sugiura N, Yonemoto J, et al. Vitreous hemorrhage associated with acute posterior vitreous detachment—a case report. *Jpn J Ophthalmol*. 1993;37(2):199-203.
4. Tan HS, Mura M, Bijl HM. Early vitrectomy for vitreous hemorrhage associated with retinal tears. *Am J Ophthalmol*. 2010;150(4):529-33.
5. Yeung L, Chen TL, Kuo YH, et al. Severe vitreous hemorrhage associated with closed-globe injury. *Graefes Arch Clin Exp Ophthalmol*. 2006;244(1):52-7.
6. Sharma R, Joshi SN, Shrestha JK. Etiology of vitreous hemorrhage in a tertiary eye care center in nepal. *Nepal J Ophthalmol*. 2010 Jul;2(4):121-6.
7. Kuhn F, Morris R, Witherspoon CD, et al. Terson syndrome. results of vitrectomy and the significance of vitreous hemorrhage in patients with subarachnoid hemorrhage. *Ophthalmology*. 1998;105(3):472-7.
8. Abouzeid H, Wolfensberger TJ. Macular recovery after retinal detachment. *Acta Ophthalmol Scand*. 2006;84(5):597-605.
9. Hollands H, Johnson D, Brox AC, et al. Acute-onset floaters and flashes: Is this patient at risk for retinal detachment? *JAMA*. 2009;302(20):2243-9.
10. Banker AS, Freeman WR. Retinal detachment. *Ophthalmol Clin North Am*. 2001;14(4):695-704.
11. Kreissig I, Lincoff H, Witassek B, et al. Color vision and other parameters of macular function after retinal reattachment. *Dev Ophthalmol*. 1981;277-85.
12. Ozgur S, Esgin H. Macular function of successfully repaired macula-off retinal detachments. *Retina*. 2007;27(3):358-64.
13. Benavente O, Eliasziw M, Streifler JY, et al. Prognosis after transient monocular blindness associated with carotid-artery stenosis. *N Engl J Med*. 2001;345(15):1084-90.
14. Donders RC; Dutch TMB Study Group. Clinical features of transient monocular blindness and the likelihood of atherosclerotic lesions of the internal carotid artery. *J Neurol Neurosurg Psychiatry*. 2001 Aug;71(2):247-9.
15. Uretsky S. Carotid artery surgery and carotid stenting in prevention of strokes. *Curr Opin Ophthalmol*. 2008;19(6):485-92.
16. Current management of amaurosis fugax. the amaurosis fugax study group. *Stroke*. 1990;21(2):201-8.
17. Winterkorn JM, Mack P, Eggenberger E. Transient visual loss in a 60-year-old man. *Surv Ophthalmol*. 2008;53(3):301-5.
18. Chen CS, Lee AW. Management of acute central retinal artery occlusion. *Nature Clinical Practice Neurology*. 2008;4(7):376-83.
19. Rudkin AK, Lee AW, Aldrich E, et al. Clinical characteristics and outcome of current standard management of central retinal artery occlusion. *Clin Experiment Ophthalmol*. 2010;38(5):496-501.

20. Cohen JE, Moscovic S, Halpert M, et al. Selective thrombolysis performed through meningo-ophthalmic artery in central retinal artery occlusion. *J Clin Neurosci*. 2012 Mar;19(3):462-4.
21. Noble J, Weizblit N, Baerlocher MO, et al. Intra-arterial thrombolysis for central retinal artery occlusion: A systematic review. *Br J Ophthalmol*. 2008;92(5):588-93.
22. Schumacher M, Schmidt D, Jurklics B, et al. Central retinal artery occlusion: Local intra-arterial fibrinolysis versus conservative treatment, a multicenter randomized trial. *Ophthalmology*. 2010;117(7):1367,75.e1.
23. Dunlap AB, Kosmorsky GS, Kashyap VS. The fate of patients with retinal artery occlusion and hollenhorst plaque. *J Vasc Surg*. 2007;46(6):1125-9.
24. Ayati M, Gori T, Munzel T. Lesions of the mitral valve as a cause of central retinal artery occlusion: Presentation and discussion of two cases. *Echocardiography*. 2010;27(1):E1-3.
25. Ehlers JP, Fekrat S. Retinal vein occlusion: Beyond the acute event. *Surv Ophthalmol*. 2011;56(4):281-99.
26. Hayreh SS, Zimmerman MB, Beri M, et al. Intraocular pressure abnormalities associated with central and hemispherical retinal vein occlusion. *Ophthalmology*. 2004;111(1):133-41.
27. Laouri M, Chen E, Looman M, et al. The burden of disease of retinal vein occlusion: Review of the literature. *Eye*. 2011;25(8):981-8.
28. Beck RW, Trobe JD. The optic neuritis treatment trial. putting the results in perspective. the optic neuritis study group. *J Neuro-Ophthalmol*. 1995;15(3):131-5.
29. Beck RW, Gal RL, Bhatti MT, et al. Visual function more than 10 years after optic neuritis: Experience of the optic neuritis treatment trial. *Am J Ophthalmol*. 2004;137(1):77-83.
30. Atkins EJ, Bruce BB, Newman NJ. Treatment of nonarteritic anterior ischemic optic neuropathy. *Surv Ophthalmol*. 2010;55(1):47-63.
31. Hayreh SS, Zimmerman MB. Optic disc edema in non-arteritic anterior ischemic optic neuropathy. *Graefes Arch Clin Exp Ophthalmol*. 2007;245(8):1107-21.
32. Hayreh SS, Zimmerman MB. Non-arteritic anterior ischemic optic neuropathy: Role of systemic corticosteroid therapy. *Graefes Arch Clin Exp Ophthalmol*. 2008;246(7):1029-46.
33. Bremner FD, Sanders MD, Stanford MR. Gaze evoked amaurosis in dysthyroid orbitopathy. *Br J Ophthalmol*. 1999;83(4):501.
34. Otto CS, Coppit GL, Mazzoli RA, et al. Gaze-evoked amaurosis: A report of five cases. *Ophthalmology*. 2003;110(2):322-6.
35. Kedar S, Zhang X, Lynn MJ, et al. Pediatric homonymous hemianopia. *J AAPOS*. 10(3):249-52.
36. Zhang X, Kedar S, Lynn MJ, et al. Homonymous hemianopias: Clinical-anatomic correlations in 904 cases. *Neurology*. 2006;66(6):906-10.
37. Hill DL, Daroff RB, Ducros A, et al. Most cases labeled as "retinal migraine" are not migraine. *J Neuro-Ophthalmol*. 2007;27(1):3-8.

OSC QUIZ

You can obtain transcript-quality continuing education credit through the Optometric Study Center. Complete the test form (page 81), and return it with the \$35 fee to: Optometric CE, P.O. Box 488, Canal Street Station, New York, NY 10013. To be eligible, please return the card within one year of publication.

You can also access the test form and submit your answers and payment via credit card at *Review of Optometry* online, www.revoptom.com.

You must achieve a score of 70 or higher to receive credit. Allow eight to 10 weeks for processing. For each Optometric Study Center course you pass, you earn 2 hours of transcript-quality credit from Pennsylvania College of Optometry and double credit toward the AOA Optometric Recognition Award—Category 1.

Please check with your state licensing board to see if this approval counts toward your CE requirement for relicensure.

1. What basic information should be documented when taking a case history of a patient who presents with sudden vision loss?
 - a. Onset.
 - b. Laterality.
 - c. Associated medical conditions.
 - d. All of the above.
2. Which laboratory test is helpful in determining the underlying cause of sudden vision loss in patients over the age of 55?
 - a. Complete blood count (CBC).
 - b. Erythrocyte sedimentation rate (ESR).
 - c. C-reactive protein (CRP).
 - d. All of the above.
3. What is the most common cause of a hyphema?
 - a. Trauma.
 - b. Diabetes.
 - c. Ocular tumor.
 - d. Carotid stenosis.

4. An ophthalmic B-scan ultrasound can help rule out a retinal tear in patients who present with:
 - a. Vitreous hemorrhage.
 - b. Central retinal vein occlusion.
 - c. Non-arteritic ischemic optic neuropathy.
 - d. Hollenhorst plaque.

5. What is NOT a typical visual symptom associated with a retinal detachment?
 - a. Color vision changes.
 - b. Gradual vision loss.
 - c. Flashes and floaters.
 - d. A descending curtain-like appearance in the peripheral vision.

6. How long does an episode of transient monocular blindness (amaurosis fugax) typically last?
 - a. One to 10 minutes.
 - b. 10 to 20 minutes.
 - c. 20 to 30 minutes.
 - d. Longer than 30 minutes.

7. A bright, yellow-orange, refractile plaque located at a blood vessel bifurcation is highly indicative of what type of embolus?
 - a. Cholesterol.
 - b. Fibrin.
 - c. Calcification.
 - d. Blood.

8. What is the recommended treatment for a person who exhibits less than 50% stenosis of the carotid artery?
 - a. Carotid endarterectomy.
 - b. Management of vasculopathic risk factors.
 - c. High-dose intravenous steroids.
 - d. Acetazolamide.

9. Which is NOT one of the six criteria used to identify people who can benefit from a carotid endarterectomy?
 - a. History of transient ischemic attack or stroke.
 - b. 80% to 90% stenosis.
 - c. Female gender.
 - d. Older than 75 years of age.

10. Which treatment approach has proven effective for patients with a long-standing central retinal artery occlusion?
 - a. Ocular massage.
 - b. Paracentesis.
 - c. Intraocular hypotensive medications.
 - d. None of the above.

11. Which condition is a risk factor for retinal vein occlusion?
 - a. Glaucoma.
 - b. Hyphema.
 - c. Retinal detachment.
 - d. Central retinal artery occlusion.

12. Which condition typically will produce a relative afferent pupillary defect?
 - a. Corneal abrasion.
 - b. Papilledema.
 - c. Central serous retinoscopy.
 - d. Ischemic central retinal vein occlusion.

13. Momentary vision loss that is precipitated by postural changes likely is indicative of:
 - a. Transient monocular blindness.
 - b. Papilledema.
 - c. Optic neuritis.
 - d. Migraine.

14. What is the typical duration of vision loss associated with demyelinating optic neuritis?
 - a. One to 10 minutes.
 - b. 20 minutes.
 - c. Two to four weeks.
 - d. Permanent vision loss.

15. Approximately what percentage of patients achieve at least 20/20 visual acuity following an episode of optic neuritis?
 - a. 47%.
 - b. 53%.
 - c. 74%.
 - d. 93%.

OSC QUIZ

16. What is the most likely cause of painless vision loss in a 60-year-old male with diabetes and unilateral disc edema?

- a. Demyelinating optic neuritis.
- b. Non-arteritic ischemic optic neuropathy.
- c. Papilledema.
- d. Corneal inflammation.

17. What is the most appropriate treatment if a patient is suspected of having vision loss due to giant cell arteritis?

- a. Acetazolamide.
- b. Aspirin.
- c. Anti-VEGF therapy.
- d. High-dose systemic steroids.

18. Which finding is the most likely cause of vision loss secondary to eccentric gaze?

- a. Angle-closure glaucoma.
- b. Intraconal mass.
- c. Demyelinating optic neuritis.
- d. Transient monocular blindness.

19. What is the most common cause of homonymous hemianopia in an adult?

- a. Migraine.
- b. Tumor.
- c. Stroke.
- d. Trauma.

20. Which of the following can cause sudden vision loss associated with unilateral headache, nausea or photophobia?

- a. Angle-closure glaucoma.
- b. Migraine.
- c. Retinal detachment.
- d. Both a and b.

Important Notice: Processing Answer Sheets and CE Certificates

Review of Optometry is strengthening our commitment to the environment and "going green."

Effective September 2012, we will send the results of any CE post-course test that is manually submitted (via mail or fax) to the email address provided on your answer sheet.

If you do not provide an email address OR if you prefer to receive a hard copy of your certificate of completion via mail, you will be charged a \$2.50 processing fee per certificate (via credit card or check payable to Jobson Medical Information LLC).

We cannot process your post-course test if neither an email address nor \$2.50 processing fee is provided. Any answer sheet will automatically be returned to you.

We appreciate your support of this new process. Please contact us via email at cecustomerservice@jobson.com with any questions. Thank you!

Examination Answer Sheet

Valid for credit through September 1, 2015

This exam can be taken online at www.revoptom.com. Upon passing the exam, you can view your results immediately. You can also view your test history at any time from the website.

Explanations for Sudden Vision Loss

Directions: Select one answer for each question in the exam and completely darken the appropriate circle. A minimum score of 70% is required to earn credit.

Mail to: Jobson - Optometric CE, PO Box 488, Canal Street Station, New York, NY 10013

Payment: Remit \$35 with this exam. Make check payable to Jobson Medical Information LLC.

COPE approval for 2 hours of CE credit is pending for this course.

This course is joint-sponsored by the Pennsylvania College of Optometry

There is an eight-to-ten week processing time for this exam.

- 1 = Excellent 2 = Very Good 3 = Good 4 = Fair 5 = Poor
- Rate the effectiveness of how well the activity:
21. Met the goal statement: ① ② ③ ④ ⑤
22. Related to your practice needs: ① ② ③ ④ ⑤
23. Will help you improve patient care: ① ② ③ ④ ⑤
24. Avoided commercial bias/influence: ① ② ③ ④ ⑤
25. How would you rate the overall quality of the material presented? ① ② ③ ④ ⑤
26. Your knowledge of the subject was increased:
 Greatly Somewhat Little
27. The difficulty of the course was:
 Complex Appropriate Basic
- How long did it take to complete this course?

- Comments on this course:

- Suggested topics for future CE articles:

1. (A) (B) (C) (D)
2. (A) (B) (C) (D)
3. (A) (B) (C) (D)
4. (A) (B) (C) (D)
5. (A) (B) (C) (D)
6. (A) (B) (C) (D)
7. (A) (B) (C) (D)
8. (A) (B) (C) (D)
9. (A) (B) (C) (D)
10. (A) (B) (C) (D)
11. (A) (B) (C) (D)
12. (A) (B) (C) (D)
13. (A) (B) (C) (D)
14. (A) (B) (C) (D)
15. (A) (B) (C) (D)
16. (A) (B) (C) (D)
17. (A) (B) (C) (D)
18. (A) (B) (C) (D)
19. (A) (B) (C) (D)
20. (A) (B) (C) (D)

Please retain a copy for your records. Please print clearly.

You must choose and complete one of the following three identifier types:

① SS # _____ - _____ - _____

Last 4 digits of your SS # and date of birth State Code and License #: (Example: NY12345678)

② _____ - _____ ③ _____

First Name _____

Last Name _____

E-Mail _____

The following is your: Home Address Business Address

Business Name _____

Address _____

City _____ State _____

ZIP _____

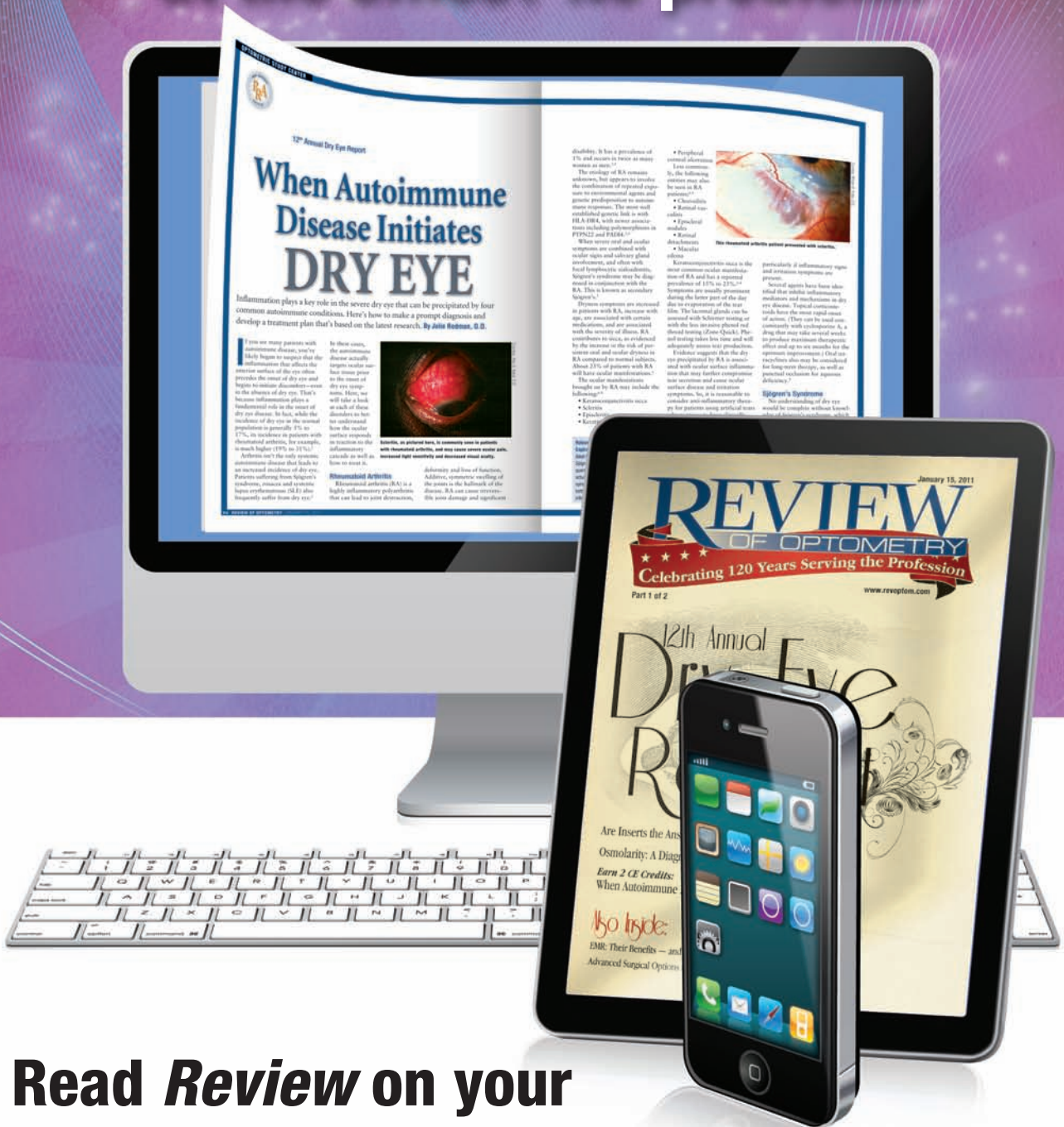Telephone # _____ - _____ - _____

Fax # _____ - _____ - _____

By submitting this answer sheet, I certify that I have read the lesson in its entirety and completed the self-assessment exam personally based on the material presented. I have not obtained the answers to this exam by any fraudulent or improper means.

Signature _____ Date _____

Left your issue of *Review of Optometry* at the office? No problem!



Read *Review* on your desktop or mobile device!

Simply go to www.revoptom.com and click on the digital edition link to read the current issue online.

9th Annual OCRT Refractive Symposium



**The meeting of the year for
ODs involved in refractive surgery**

October 23, 2012 • Phoenix, Arizona

8 CE Credits

(in two 4-hour sessions)

SCHEDULE

7:30am - 8:00am Breakfast
8:00am - 5:30pm **CE Program**

The OCRT will sponsor its 9th Annual Refractive Technology Symposium, bringing together some of the brightest minds in the refractive arena to discuss complication management, evolving technologies, management of dry eye and a new feature – an open forum to discuss cases submitted by you and other meeting attendees. The meeting, being held the day before the American Academy of Optometry meeting in Phoenix, Ariz., presents a unique forum to share your ideas, thoughts, and experiences with your colleagues. Eight hours of COPE-approved CE will be awarded to attendees. The registration fee includes a continental breakfast and lunch.

TO REGISTER ONLINE:

www.ocrt.org/Symposium

For more information, contact Josh Johnston at drj@gaeyepartners.com
or Deegan Lew, OD, at dlewod@yahoo.com

Sponsored by



Cancellation Policy: Full refund on registration fee until September 23, 2012; 50% refund on registration fee until October 9, 2012. No refund is available past October 9, 2012.



Double Take on Double Vision

Diplopia in children usually is a benign binocular vision issue. But what do you do when it isn't? **Edited by Paul C. Ajamian, O.D.**

Q I recently had a seven-year-old patient who said she was seeing double. Is there something serious going on? How do I handle it?

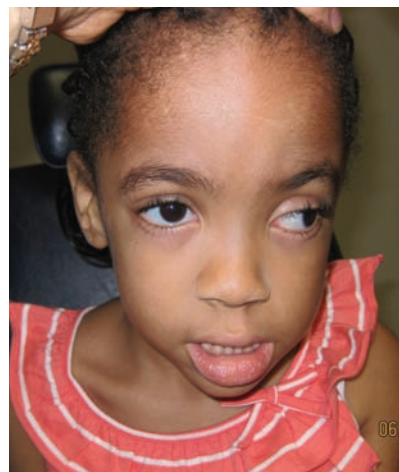A “When an older child (above the age of five) comes in with diplopia or strabismus that has never been documented before, the number one thing that the optometrist has to determine is whether it was of recent onset or recent discovery. In other words, is it new or longstanding?” says Valerie M. Kattouf, O.D., chief of pediatrics and associate professor at the Illinois College of Optometry.

“I see this every day with two-, three- and four-year-olds, but when I see this in a seven-year-old, my antennae go up,” Dr. Kattouf says of this case. It’s unusual for a seven-year-old to have undiscovered, longstanding and constant diplopia. On the other hand, sudden onset suggests pathology.

Rest assured that you have the tools to figure it out, she says:

- **History.** Start by asking the patient and/or the parent about the occurrence of the diplopia. Has it developed over time, or did it appear suddenly? Is it constant? Is it horizontal, vertical or both? Is there any past history of diplopia?

- **Testing.** Use a cover test to evaluate alignment and determine strabismus. If so, is it present in all gazes? Are there any muscle restrictions? Use the stereopsis test to determine whether the strabismus is of recent onset or is longstanding. A stereopsis response with prism neutralization indicates recent



Diplopia in children very often relates to strabismus. Usually, it’s not of recent onset but a recent discovery. This child, for instance, demonstrates intermittent exotropia.

diplopia. A suppression response (no stereopsis) indicates that it is longstanding.

- **Dilation.** “It’s rare that you’ll dilate the patient and see a retinal lesion or an optic nerve anomaly that is causing the diplopia,” Dr. Kattouf says. But that doesn’t mean you’ll *never* see such an etiology—and it’s certainly one that you don’t want to miss—so definitely dilate the patient.

Still, “diplopia in children almost universally relates to strabismus. I can’t tell you how often these cases are recent discovery and not recent onset,” Dr. Kattouf says. “But if it is recent onset, you have to consider a neurologic problem.”

That means a referral for an MRI or CT scan.

When bringing this up to the parents, “I try not to be too vague, but not too specific either,” Dr. Kattouf says. “I say, ‘We want to make sure

that there’s no underlying disease process that’s causing this, so we’re going to refer you for a neurologic scan.’ And that’s usually the most I’ll say initially, because you don’t want to plant the seed of an idea that it’s a tumor. Often the scan comes back completely clear.”

If it does, then it’s very likely that the child’s vision problem merely is something that caused decompensation over time. “In that case, you treat it just as you would a more longstanding strabismus,” she says.

To that end, you certainly can handle the case on your own. “Sometimes, the answer might be as simple as a spectacle correction to control the strabismus,” Dr. Kattouf says. “The next step is prism correction, if possible. Alternatively, some patients respond to vision therapy. Lastly, some children may do best with a surgical referral.” ■



JOSHUA MARC LAHIFF, OD

A Growing Practice Is Built on Happy Patients

Garnering new patients through **word-of-mouth referrals** is more than a great marketing strategy—it is the key to success that endures the test of time.

Successful practices see more patients

Focusing your practice on getting new patients rather than dollars per patient is a more pragmatic—and preferable—business approach. This is true for any practice. In a 2009 study of independent practices, it was reported that the practices with the greatest gross revenue see three times as many patients as the average practice. Furthermore, there is little difference in the gross revenue per exam between rural and urban settings, small and large practices.¹

Increased patient traffic and improved exam productivity have major impacts on practice revenue. In fact, another 2009 study found that, on average, 52% of a practice's gross revenues come from exam fees alone.² This constitutes nearly 2/3 of gross income.^{1,2}

According to Dr Josh LaHiff, practicing optometrist in Cheyenne, WY, increasing patient traffic is all about providing patients with an outstanding experience: "You want to be able to provide them [patients] with such an experience that they're going to invest more in your clinic." Dr LaHiff should know. He sees at least 30 patients per day. Which is impressive considering there are 28 other eye care professionals in Cheyenne, a town with a population of only 50,000.

Success is built on a happy patient experience

Increasing patient traffic through referrals is often as simple as delivering excellent service and the healthiest products. "To be the best, you have to use the best. If you wow the patient, treat them like gold, that's how you really generate those referrals," says Dr LaHiff.

That's why Dr LaHiff believes the most effective approach to achieving profitable, long-term patient relationships is to "do what's best for the patient, even if it may not be the most profitable option for the doctor initially, because it is what is right, and the profit will come as an annuity in return visits and the happiness of the patient."

High patient satisfaction inside and outside of the practice is the most effective catalyst for generating new patients. This can be especially true for contact lens patients. A survey of 1086 patients found that those who are happy in their contact lenses are nearly 2x more likely to recommend their eye doctor than those who are unhappy in their lenses.²

ACUVUE® Brand—proven to keep patients satisfied

The proven method to achieve satisfaction is to use a product with consistently successful results. Dr LaHiff believes that, "When you use a product that you know is going to work time and time again, it cuts your chair time down and it's easier for you, your staff, and your patients to put them in something that's comfortable."

ACUVUE® Brand delivers outstanding comfort and consistent patient satisfaction. In fact, 9 out of 10 ACUVUE® patients are satisfied in their contact lenses.²

And happy ACUVUE® wearers refer their eye doctor: 8 out of 10 satisfied ACUVUE® OASYS® Brand Contact Lens and 9 out of 10 1-DAY ACUVUE® MOIST® Brand Contact Lens wearers would recommend their doctor to others.²

According to Dr LaHiff, "The more you use a superior product, the better the experience is going to be for the patient." And that's been a proven strategy for the success of his practice. ■

Joshua Marc LaHiff, OD, is a partner and practicing optometrist at Cheyenne Vision Clinic in Cheyenne, WY, and clinical instructor for the Illinois College of Optometry in Chicago, IL. He received his doctor of optometry degree with honors from the Pacific University College of Optometry in Forest Grove, OR.

Dr LaHiff is a member of numerous associations and serves as a speaker and professional consultant for several medical companies, including VISTAKON® Division of Johnson & Johnson Vision Care, Inc. He was compensated for this article.



Cross-Linking Conundrums

Protocols are still evolving for this new procedure to strengthen the cornea. Are researchers finally arriving at any conclusions about safety and efficacy? **Edited by Joseph P. Shovlin, O.D.**


Q With collagen cross-linking for ectasias (especially keratoconus), is there a different level of safety regarding the endothelial's UV absorption in epithelium-on vs. epithelial removal treatment?

A Damage to tissues that undergo corneal collagen cross-linking using riboflavin and UVA light has been documented, and is associated with the UVA portion of the treatment. The corneal stroma acts as a filter of UV light that can be harmful to the endothelium. Unfortunately, there is more than a tenfold increase in toxicity when combined with riboflavin.¹

"The success of the treatment to induce cross-linking in the corneal stroma is excellent, while phototoxicity to the corneal endothelium is an undesirable potential side effect," says Andrew S. Morgenstern, O.D., president of the recently formed Optometric Cross-Linking Society.

Whether your patient is dealing with keratoconus, post-RK instability or post-refractive surgery ectasia, "based on all of the literature that I have read and in my personal experience, the endothelial safety level up to date has been based on the overall corneal thickness anterior to endothelium," Dr. Morgenstern says.

The endothelium reaches a cytotoxic level in response to combined treatment with riboflavin and UVA at 0.35mW/cm^2 . In a $400\mu\text{m}$ thick cornea with riboflavin saturation, just 6% of the initial energy



This keratoconic cornea (with prior insertion of Intacs) glows green from riboflavin application during epithelium-on collagen cross-linking.

is distributed to the endothelium. Considering that most instruments have an output of 3mW/cm^2 , typically the level would reach only 0.18mW/cm^2 .

"In an epithelium-off procedure, so long as the corneal thickness is maintained above $400\mu\text{m}$, the relative risk is quite low," says Scott G. Hauswirth, O.D., vice president of OCXLS. "When there is ample tissue for the UVA light to filter through, the toxic levels of UVA light that pass to the endothelium are rendered safe."

Some clinicians even remove the epithelium on a thin cornea so they have the ability to swell the remaining tissue to provide ample safety and protection to the endothelium. The relative risk to the endothelium in an epithelium-on procedure is even less, as the corneal epithelium also absorbs UV light and can

lower the energy level.²

"Based on evidence in various studies, as long as the procedure is done within the parameters outlined in their respective clinical trial outlines—with respect to corneal pachymetry—there seems to be no evidence of long-term endothelial damage," Dr. Morgenstern says.

Corneal collagen cross-linking currently is not FDA approved, but device manufacturers are pursuing indications. ■

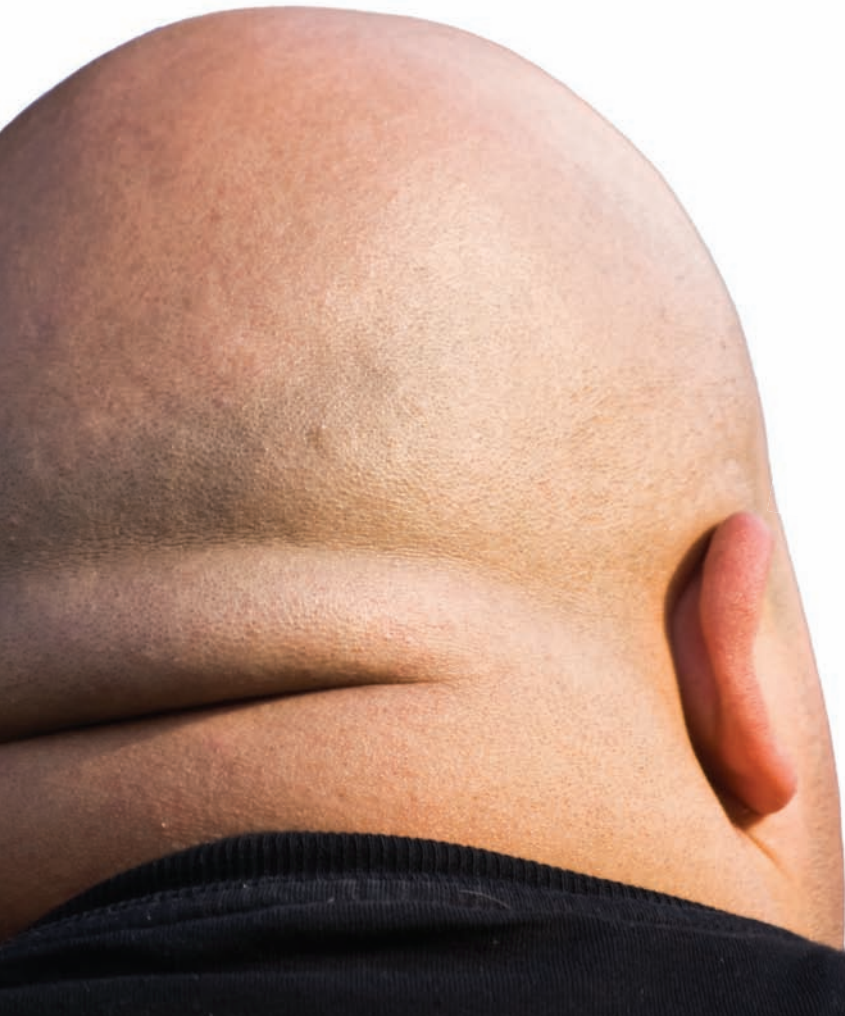1. Wollensak G, Spoerl E, Seiler T. Riboflavin/ultraviolet-a-induced collagen crosslinking for the treatment of keratoconus. *Am J Ophthalmol.* 2003;135:620-7.

2. Bottos KM, Schor P, Dreyfuss J, et al. Effect of corneal epithelium on ultraviolet-A and riboflavin absorption. *Arq Bras Oftalmol.* 2011;74(5):348-351.

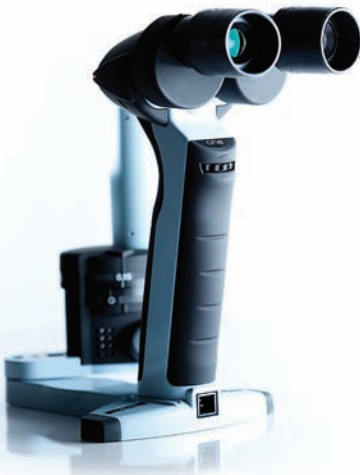For more information on cross-linking procedures, visit the new Optometric Cross-Linking Society (OCXLS) website at www.ocxls.org.

One Size Finally Fits All

The Keeler PSL1 Portable Slit Lamp



Snap the code to
watch it in use!



Large or small...the PSL fits them all!

We understand that having the best instrumentation is critical to delivering high quality care to all of your patients. Keeler developed the PSL with flexibility and outstanding optical clarity so that each of your patients can have the very best.

Don't allow an obstacle (small or large) stop you from delivering the very best care possible.

Make the PSL your standard for quality eye care for all your patients.

Buy Online!
keelerusa.com



Keeler

www.keelerusa.com | 800-523-5620

Mind and Body

Macular pigments (Part 3): Growing research links xanthophylls with a host of chronic conditions such as heart disease, diabetes and cognitive disorders.

By Joseph Pizzimenti, O.D., and Carlo Pelino, O.D.

In optometry, we've seen discussions about lutein and zeaxanthin make their way from the lab room to the exam room as we've become more aware of their role in preventive eye care. We may start to see this same transition happening in other areas of health care, as more research emerges about how xanthophylls contribute to systemic health and a number of common chronic conditions.

In part 1 of this three-part series (*"Add Color to Your Diet," May 2012*), we explained how xanthophylls protect the retina and enhance visual function. In the second installment (*"Beyond the Eye," July 2012*), we reviewed their protective role in skin damage and various types of cancer. In this third and final segment, we look at the relationship between xanthophylls and chronic conditions of the mind and body—including heart disease, metabolic syndrome, diabetes and cognitive impairment.

Heart Disease

A growing body of experimental evidence and observational studies suggest that lutein and zeaxanthin may play a role preventing coronary heart disease and stroke. The Los Angeles Atherosclerosis Study found lutein to be highly effective in reducing oxidation of low-density lipoproteins (LDL) and inhibiting the inflammatory response of monocytes to LDL trapped in the artery wall.¹

With in vitro experiments of human LDL, lutein and zeaxanthin have been shown to act as scavengers of peroxynitrite radicals. It has also been demonstrated that high plasma levels of lutein were associated with decreased risk of heart attack.²

Metabolic Syndrome and Diabetes

Using a cross-sectional survey to investigate the presumed association, Australian researchers found that serum carotenoids—including lutein and zeaxanthin—are inversely associated with type 2 diabetes and impaired glucose metabolism.³

Another survey revealed that the odds ratio for metabolic syndrome in the highest tertile of serum zeaxanthin/lutein was significantly lower than in the lowest tertile in Japanese women.⁴

In a U.K. study, subjects with type 2 diabetes had reduced macular pigment optical density (MPOD) compared to those in a group of control subjects. The authors suggest that the reduced macular pigment levels may result from increased oxidative stress in the diabetic macula.⁵

A more recent study reported that type 2 diabetes patients, with or without retinopathy, had reduced MPOD when compared with that in non-diabetic patients. In addition, researchers observed a significant inverse correlation

between MPOD and HbA1C levels.⁶ This growing evidence suggests that dietary changes or supplementation with lutein and zeaxanthin could benefit diabetic patients.

Brain and Cognitive Impairment

Over the past decade, there's been increasing interest in the relationship between xanthophylls and cognitive function. At last year's International Symposium on Carotenoids, preliminary research demonstrated for the first time that lutein is the predominant carotenoid present in key areas of the infant brain, including areas that regulate overall brain function, cognition, vision, hearing and speech.⁷

In addition to these findings, there's been a growing body of evidence supporting the role of these carotenoids in adult and elderly brains. In measuring the major carotenoids in the brain, researchers found that xanthophylls accounted for 66% to 77% of total carotenoids in all brain regions examined.⁸

Similar to the foveal center, the ratio of zeaxanthin to lutein was high and these two xanthophylls were significantly correlated. The frontal cortex—generally vulnerable in Alzheimer's disease—had higher concentrations of all the compounds studied than the occipital cortex, which is generally unaffected. Frontal lobes, but



not occipital lobes, exhibited an age-related decline in retinol, total tocopherols, total xanthophylls and total carotenoids.⁸

In an exploratory trial of docosahexaenoic acid (DHA) and lutein supplementation, nearly 50 women between the ages of 60 and 80 were randomly assigned to placebo, DHA, lutein, or lutein and a DHA supplement.⁹ Following supplementation, verbal fluency scores improved significantly in the DHA, lutein and combined treatment groups. Memory scores and rate of learning improved significantly in the combined treatment group, who also displayed a trend toward more efficient learning. Measures of mental processing speed, accuracy and mood were not affected by supplementation. These exploratory findings suggest that DHA and lutein supplementation may offer cognitive benefit for older adults.⁹

Similarly, the EVA Study in France measured plasma carotenoid levels and cognitive performance in an elderly population. Their results showed that participants with the lowest cognitive functioning (25th percentile) had a higher probability of having low levels of specific plasma carotenoids, lycopene and zeaxanthin.¹⁰

Earlier this year, researchers studied the relationship between markers of lutein, zeaxanthin and omega-3 fatty acid status (via serum and MPOD) and cognitive function in a cohort of healthy older adults. Of all variables tested, MPOD was the largest and most consistent predictor of cognitive function. The analysis suggested that both serum xanthophylls and omega-3 fatty acids account for small but significant proportions of variance in cognitive function.¹¹

Although it is not possible to affirm if low levels of carotenoids precede or are the consequence of cognitive impairment, these results suggest that low carotenoid levels could play a role in cognitive impairment. The importance of these differences and the role(s) of these antioxidants in the brain remain to be determined.

As the scientific community continues to investigate and elucidate the role of xanthophylls in systemic health, staying up to date on the latest findings will help us, as eye care providers, be better advocates for our patients and our colleagues in other health care specialties. ■

Drs. Pelino and Pizzimenti have no proprietary interest in any instrument, food product, supplement or vitamin. Dr. Pizzimenti serves on the scientific advisory board for ZeaVision.

For a complete list of references, please visit www.revoptom.com.

SECO 2013

February 27 – March 3, 2013

Georgia World Congress Center, Hall A
Atlanta, Georgia



Once again, the annual SECO event will deliver a stellar lineup of nearly 400 hours of continuing education. SECO 2013 is billed as a "Celebration of Education" to commemorate our 90th year of providing world-class optometric continuing education.

Just as enticing is the popular Optometry's Marketplace at SECO™, providing you exclusive access to as many as 275 of Optometry's most well-known and respected industry suppliers as well as up and coming companies offering the latest innovations in ophthalmic products, equipment and support services.

Make your plans now to meet, mingle and network with distinguished industry professionals. Whether you are relatively new to the SECO experience or have many SECO miles under your belt, the SECO 2013 "President's Celebration" will blow you away with a myriad of funky, jazzy, soulful, and down home entertainment at the historical Atlanta Tabernacle.

Produced by  SECO International, LLC
Providing world-class education for optometry since 1924

secointernational.com

EXPAND YOUR KNOWLEDGE

with the fourteenth edition of

The Handbook of Ocular Disease Management

This handy reference, complete with clinical photos, provides practitioners with the signs, symptoms, pathophysiology, management and clinical pearls for a wide variety of ocular conditions.


Subjects Include:

- **EYELIDS AND ADNEXA**
- **CONJUNCTIVA AND SCLERA**
- **CORNEA**
- **UVEA AND GLAUCOMA**
- **VITREOUS AND RETINA**
- **NEURO-OPHTHALMIC DISEASE**

Supported by an independent
medical educational grant from

Alcon[®]

optovue



This fourteenth edition, brought to you by Alcon and Optovue, contains updated disease conditions featured in the previous editions of the *Handbook*, as well as numerous new entries.



An Underlying Infection?

This HIV-positive patient presented with hand motion vision O.D. Was this caused by an active, but undocumented, disease process? **By Mark T. Dunbar, O.D.**

A 48-year-old black male presented with a three-month history of reduced visual acuity and discomfort in his right eye. He reported that, over the past month, his vision had declined to the point that he could “hardly see anything.” The left eye seemed fine. He never wore glasses.

His medical history was significant for HIV. He reported taking medications for the condition, but was uncertain of their names.

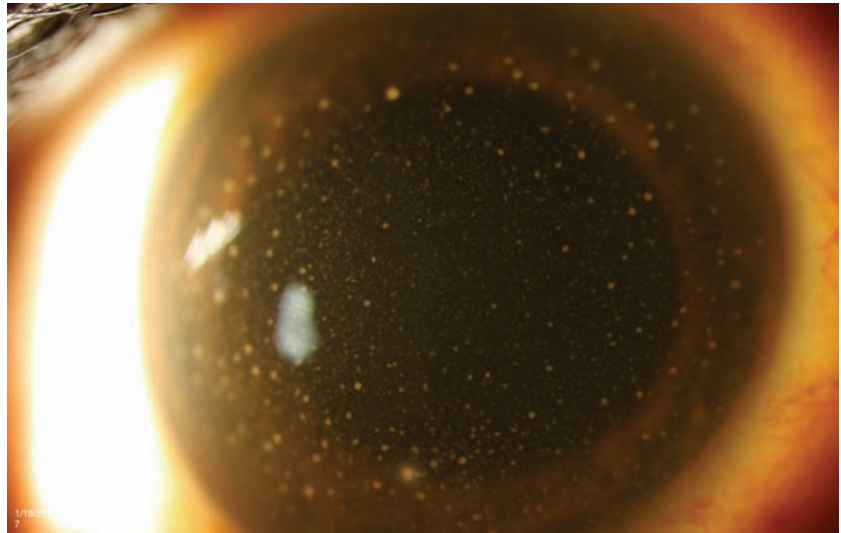
His entering visual acuity was hand motion O.D. and 20/200 O.S. Upon hyperopic correction, his acuity improved to 20/20 O.S. Confrontation fields in the left eye were full to careful finger counting. His pupils were equally round and reactive, with a 1+ afferent defect O.D. IOP measured 17mm Hg O.D. and 12mm Hg O.S.

The anterior segment evaluation of the right eye revealed significant changes (*figure 1*). The anterior segment examination of the left eye was completely unremarkable.

The right fundus appeared extremely hazy; however, changes could be seen in the posterior pole and superior nasal area (*figure 2*). The fundus examination of the left eye was completely normal.

Take the Retina Quiz

1. What do the changes seen on the right cornea represent?
 - a. Gutta.
 - b. Keratic precipitates (KP).
 - c. Infectious infiltrates.
 - d. Ulcerative keratitis.



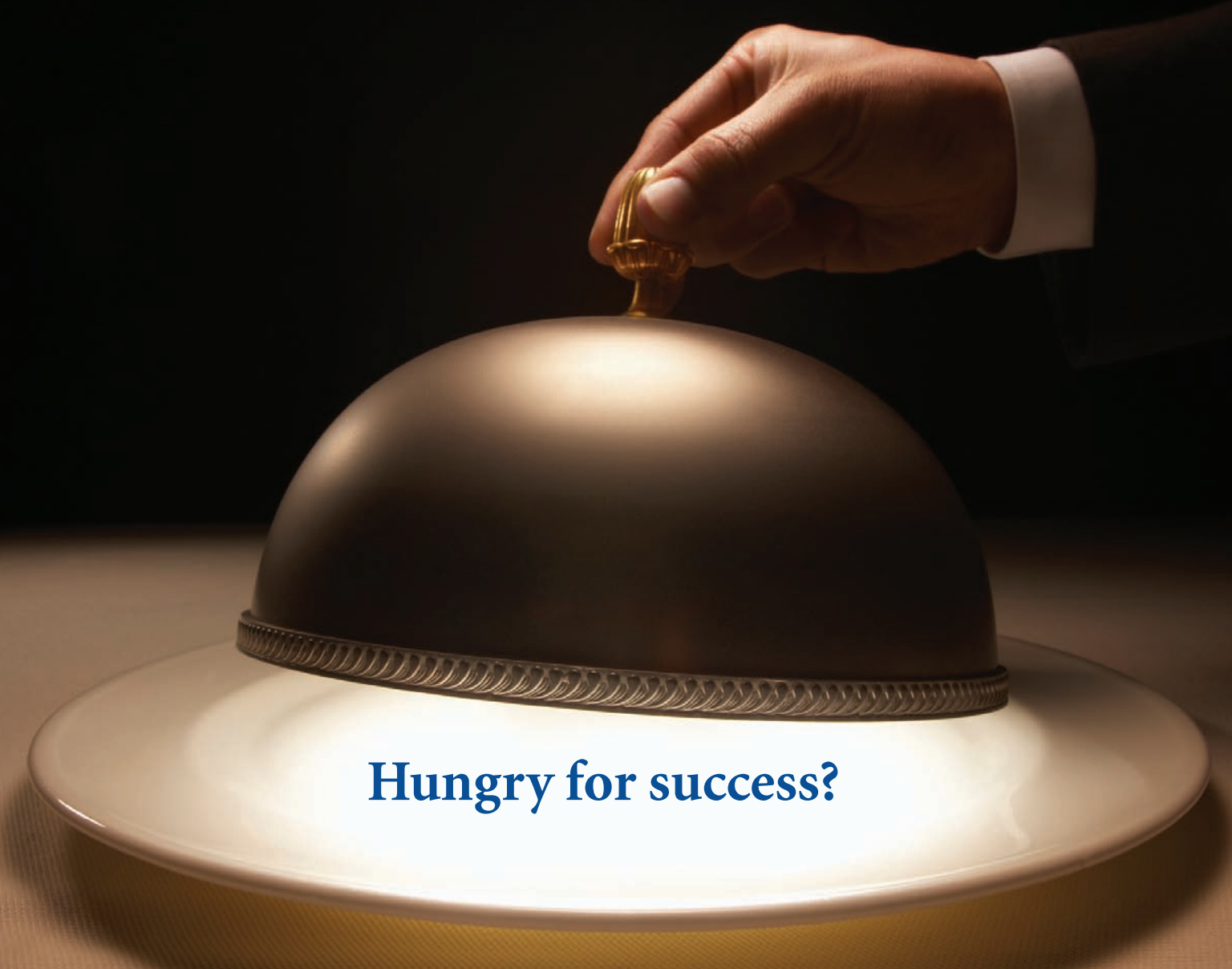1. Anterior segment image of our patient's right eye. What do you notice?

2. How would you classify the clinical presentation of the right eye?
 - a. Retinochoroiditis.
 - b. Endophthalmitis.
 - c. Posterior uveitis with anterior segment spillover.
 - d. Panuveitis.
3. Which screening test could yield a positive result in our patient?
 - a. Fluorescent treponemal antibody-absorption (FTA-ABS).
 - b. Rapid plasma reagin (RPR).
 - c. Toxoplasmosis IgM and IgG.
 - d. All of the above.
4. Based upon the patient history and clinical findings, what is the most likely diagnosis?
 - a. Active cytomegalovirus (CMV).
 - b. Active toxoplasmosis.
 - c. Active ocular syphilis.
 - d. All of the above.
5. How should this patient be managed initially?
 - a. Topical steroids and cycloplegics.
 - b. Topical steroids.
 - c. NSAIDs.
 - d. Intravitreal antibiotic injection.

For answers, go to page 114.

Discussion

Our patient had a panuveitis, which represents an inflammation of the entire uveal tract. Indeed, he exhibited an active anterior uveitis with cells in the anterior chamber and obvious KP on the endothelium. There also were cells in the anterior and posterior vitreous, which made the view of the retina appear very hazy. Finally, there was



Hungry for success?

At Jobson, we have more effective ways for you to reach the optical market than anyone. So our approach to serving clients is unique. First, we develop a thorough understanding of your specific goals. This understanding, plus our extensive offering of products and services, enables us to then suggest solutions that will help achieve those goals. This often includes innovative ideas and premium positions. For advertising information contact Michele Barrett (610-492-1014, mbarrett@jobson.com) or Jim Henne (610-492-1017, jhenne@jobson.com). Let us satisfy your hunger for success.

REVIEW[®]
OF OPTOMETRY

Review of
Cornea & Contact Lenses

REVIEW[®]
OF OPTOMETRY
www.revoptom.com

REVIEW[®]
of Ophthalmology
www.revophth.com

Jobson
Optical Group

The vision to help you succeed

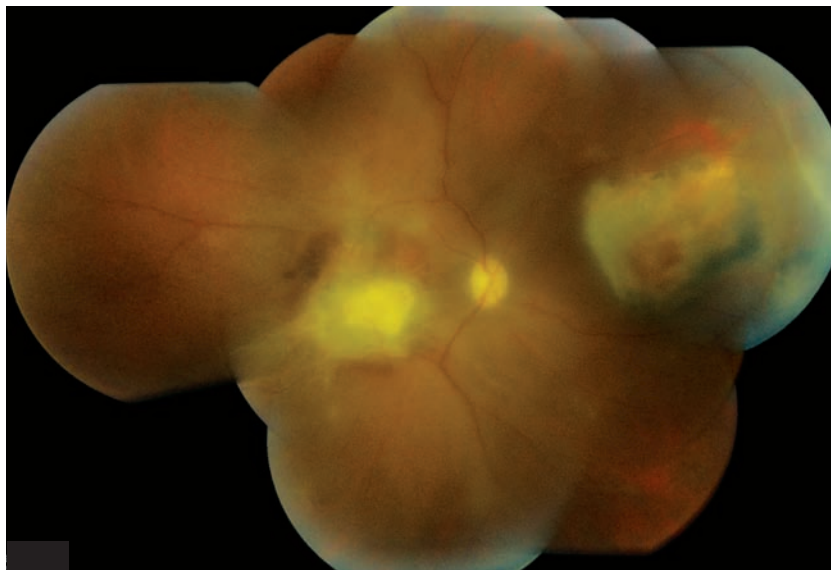
an active chorioretinal lesion that involved the macula as well as a less-active lesion located superior nasal O.D.

In his history, he indicated that the vision in his left eye had been reduced for at least three months. That explains the macular lesion; however, the more peripheral lesion would not cause the central vision loss that he experienced at the time of his examination. Additionally, given the amount of pigment surrounding the lesion, we speculated that it had been present for longer than three months.

So, what is the underlying cause? At first glance, the retinal lesions looked to be characteristic of active toxoplasmosis. To confirm our suspicions, we ordered a blood work-up that included a CBC and serology to rule out syphilis (FTA-ABS and RPR); toxoplasmosis IgG and IgM antibodies; a chest X-ray; and rheumatoid factor, antinuclear antibody and an angiotensin converting enzyme (ACE) testing to rule out the presence of other autoimmune diseases.

CMV retinitis was not really a consideration. Even though we didn't know his CD4 count, the amount of inflammation that we observed in our patient was not consistent with CMV. Traditionally, CMV occurs when the immune system is severely compromised. So, when patients develop CMV, their immune system is not strong enough to mount the kind of inflammatory response that we noted in our patient.

The results of the blood work didn't make it any easier. Both blood tests for syphilis were positive. Additionally, one of the tests for toxoplasmosis was positive (the IgG), indicating that he had been exposed to toxoplasmosis. (Fortunately, the IgM test was negative,



2. A wide-angle view of our patient's right eye.

suggesting that the toxoplasmosis infection was not recent.) And, if that wasn't confusing enough, the ACE test also came back as mildly positive.

So, could it have been that our patient had multiple active conditions? It was fairly unlikely. Without question, however, he did have active syphilis. Because syphilis is considered the "great masquerader," it certainly could have been the cause of his panuveitis. But, it was also possible that toxoplasmosis was the root cause—especially given the positive serology and the characteristic clinical appearance.

Both syphilis and toxoplasmosis are caused by parasites, so it seems logical that associated lesions exhibit a similar clinical appearance.

• *Toxoplasmosis* is caused by an intracellular parasite, *Toxoplasma gondii*. Active toxoplasmosis retinochoroiditis typically presents as a feathery-white or creamy-yellow lesion. The lesion may appear thick or have a slightly elevated appearance. Our patient's macular lesion fit this description; however, it appeared that fibrous scar tissue

was developing. In addition, he also may have developed choroidal neovascularization, because there was a subretinal hemorrhage surrounding the macular lesion.

• *Syphilis* is caused by *Treponema pallidum*, a highly infectious spirochete. Since the introduction of penicillin in the early 20th century, there has been a rapid decline in the incidence of syphilis. However, during the last 10 years, syphilis has made a resurgence.¹ Furthermore, since the beginning of the AIDS epidemic in the late 1980s, concomitant HIV and syphilis infections have been more prevalent in certain socioeconomic groups.¹ This seemed to be the case with our patient.

We started our patient on hourly 1% prednisolone acetate and homatropine b.i.d. O.D. He was admitted to the local hospital, where he received treatment for an active syphilis infection. The uveitis eventually quieted; however, because the macular lesion was fairly advanced, he never regained central vision. ■

1. Daskalakis D. Syphilis: continuing public health and diagnostic challenges. *Curr HIV/AIDS Rep.* 2008 May;5(2):72-7.

Double Trouble

This patient already was being managed for one ocular problem. Now he has another.

By Joseph W. Sowka, O.D., and Alan G. Kabat, O.D.

A 62-year-old black male, who was receiving care for primary open-angle glaucoma, presented urgently with a new and unrelated problem. He reported that, approximately one week earlier, he suddenly experienced horizontal double vision, which was worse when looking to the right. When he looked straight ahead, the double vision was less evident. Also, his symptoms seemed to disappear when looking left. Further, he believed that his right eye was turning in toward his nose. Finally, the patient noted an ache behind his right eye when the trouble first started.

Because he had hoped the problem was temporary, he delayed coming in for evaluation. He stated that the double vision worsened over several days, but had since stabilized and was not improving, so he decided to return for a check-up.

Upon examination, the patient had a right abduction deficit that worsened in right gaze. Forced duction testing showed that the right eye could be moved further out and was not physically restricted or tethered. His best-corrected visual acuity was unchanged at 20/25 O.D. and 20/30 O.S., and his pupils were reactive without afferent defect.

Upon questioning, he denied dysphagia, dysphasia, headache, paresis and paresthesia. Cranial nerve testing revealed no additional deficits beyond the abduction deficit. His optic nerves were

glaucomatous, but not edematous.

At this point, we diagnosed the patient with a neurologically isolated right cranial nerve (CN) VI palsy. His medical history was significant for medicated hypertension and hypercholesterolemia. At the time of examination, his blood pressure measured 155/95mm Hg. Based upon the diagnosis and associated medical history, we believed vascular ischemia was the basis of the CN VI palsy.

What is CN VI Palsy?

A patient with isolated, unilateral, acute-onset CN VI palsy will present with horizontal, uncrossed diplopia, which worsens at distance in either right or left gaze—depending upon the involved eye. The patient will have an abduction deficit in the involved eye and either a noncomitant esophoric or esotropic posture.^{1,2} If the palsy is isolated, the patient will not experience visual acuity/field loss or any other neurologic problems. However, there may be some degree of head or retro-orbital pain present, which is dependent upon the cause.

There are three distinct demographic groups that develop CN VI palsy:

- Most patients who develop acute CN VI palsy are older than 50 years of age. This group often has a concurrent history of hypertension and/or diabetes (as did our patient).³⁻⁵ The peak incidence occurs in the seventh decade of life.⁶
- Children are also prone to

develop CN VI palsy. The causes may range from benign (e.g., viral illness or trauma) to malignant etiologies.⁷⁻¹¹

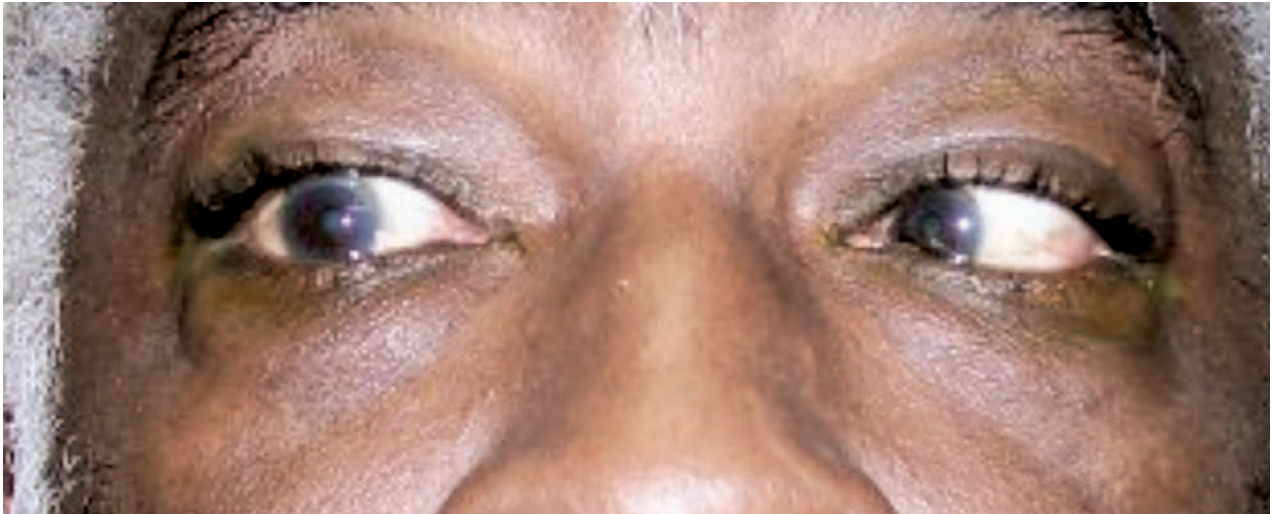- The third group consists of young adults aged 20 to 50 years. These individuals are more likely to have neurologically complicated CN VI palsies involving additional cranial nerves (such as III and IV) or other neurological signs (such as ataxia or intention tremors).^{12,13} In contrast to older adults, vascular diseases such as diabetes and hypertension are uncommon in this group. Instead, more serious conditions such as central nervous system (CNS) mass lesions and multiple sclerosis typically are found.¹³⁻¹⁵

Additionally, because various cancers have been associated with CN VI palsy, patients may present with a pre-existing history of malignant disease. However, CN VI palsy may be the premonitory sign of cancer in some patients.

Managing CN VI Palsy

The most important consideration when managing acute onset CN VI palsy is identifying the causative factor in an efficient, cost-effective manner. Doing so involves understanding common causes for each patient profile and palsy. In one large, population-based study, the four most common causes were idiopathic, hypertension alone, coexistent diabetes and hypertension, and trauma.⁶

A detailed medical history must be obtained as well as a neurologic



External view of the patient in right gaze. Note the abduction deficit in his right eye caused by CN VI palsy.

examination upon initial presentation. Each case of CN VI palsy should be classified as traumatic or non-traumatic. Non-traumatic cases should be subdivided as neurologically isolated or non-neurologically isolated (e.g., either the patient only has a CN VI palsy or a CN VI palsy in addition to other neurological problems).⁶ Additionally, patients should be categorized into one of three age-dependent management groups: children, young adults and older adults.⁶

A non-neurologically isolated CN VI palsy (involving other neurological structures concurrently) that shows any additional neurological signs (dysphasia, paresthesia, paresis, headache, disc edema or other cranial neuropathy) necessitates an MRI of the appropriate suspect area as well as cerebrospinal fluid analysis. Non-neurologically isolated CN VI palsies commonly are caused by cerebrovascular accidents that involve the pons, aneurysm (typically within the cavernous sinus) or neoplasm.⁶ While neurologically complicated CN VI palsy has a high likelihood of a serious cause (e.g., neoplasm), isolated

adult CN VI palsy actually has a very low risk (2% in one series) of being caused by a neoplasm.⁶

- In children, sixth nerve palsy can be caused by a presumed viral etiology and has an excellent prognosis.^{9,10} However, nearly half of all CN VI palsies in children are due to neoplastic disease—notably pontine glioma.^{8,11} Thus, a pediatric neurologic evaluation and consultation is urgent in this age group, and the cause of the palsy should not be presumed benign.¹¹

- In younger adults, CN VI palsy is likely to be caused by a serious underlying disease. In this group, CNS mass lesions account for 33% of CN VI palsies, and multiple sclerosis is responsible for another 24% of cases.¹³ Idiopathic CN VI palsies account for 13% of cases and vascular disease just 4%.¹³ It should be noted that CN VI palsy caused by CNS mass lesions in young adults often involve other cranial neuropathies and are not isolated. Thus, neuroimaging is highly recommended in this age group.

- In patients age 50 or older with an isolated sixth nerve palsy, a work-up for ischemic vascular

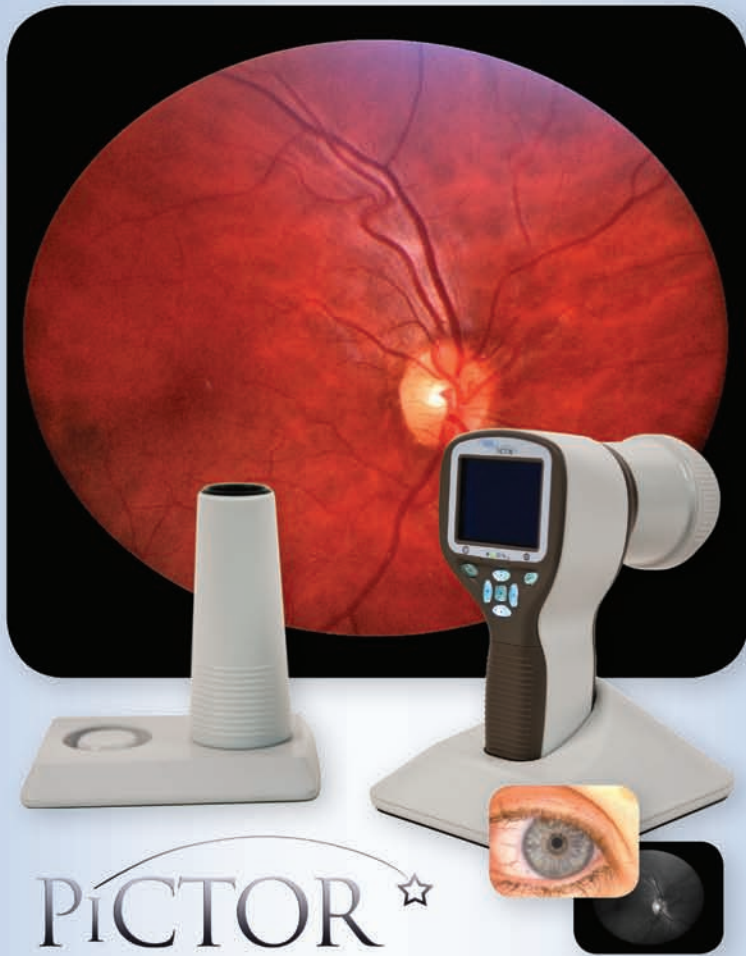
diseases, such as diabetes and hypertension, should be performed.²⁻⁶ If the patient is over age 60, an erythrocyte sedimentation rate (ESR) and C-reactive protein should be ordered to rule out giant cell arteritis (if the clinical case dictates).

In cases of isolated CN VI palsy in older adults with a history of diabetes or hypertension, neuroimaging and other extensive evaluation can be deferred—unless the palsy progresses for more than one week, fails to improve over three months, or other neurologic complications develop. Ischemic vascular palsies typically progress over several days and may be no better in one week, but progression over two weeks warrants neuroimaging.⁶

Spontaneous recovery of CN VI palsy is common, especially if the etiology is idiopathic, traumatic or microvascular.^{3,4,6,13} Resolution of CN VI palsy typically is complete by three to six months—although some cases may take longer. CN VI palsies associated with CNS mass lesions tend to have a worse prognosis for spontaneous recovery.^{6,13} In cases where complete recovery does not occur, Fresnel prism

A Logical Choice

For Versatile, Portable Ophthalmic Imaging



PICTOR

Versatility: Use for mobile situations, pediatrics or any patient with difficult access

Functionality: Image both the posterior (non-mydriatic) and anterior segments with one camera

Economical: Tax incentives and full reimbursement may apply

To Arrange a Trial
Call Jodie Cailotto at (440) 510-0743
or email jodie.cailotto@volk.com



www.volk.com


Copyright © 2012 Volk Optical Inc.

correction may alleviate diplopia and visual discomfort. More aggressive therapy in non-remitting cases includes strabismus surgery or medial rectus injection with botulinum toxin (Botox, Allergan).^{14,15}

In this case, we believed that the patient had an isolated CN VI palsy secondary to microvascular disease from hypertension. Because the patient believed that he had stabilized, neuroimaging was not ordered. However, we instructed the patient to call immediately if he noted any physical changes at all. The patient said that he was using an eye patch to ameliorate his symptoms, and we agreed that he should continue to do so.

At his most recent evaluation, 11 weeks after the onset of the double vision, he had completely resolved without complications and was happy. ■

1. Goodwin D. Differential diagnosis and management of acquired sixth cranial nerve palsy. *Optometry*. 2006 Nov;77(11):534-9.
2. Staubach F, Lagrèze WA. Oculomotor, trochlear, and abducens nerve palsies. *Ophthalmologie*. 2007 Aug;104(8):733-46.
3. Richards BW, Jones FR Jr, Younger BR. Causes and prognosis in 4,278 cases of paralysis of the oculomotor, trochlear, and abducens cranial nerves. *Am J Ophthalmol*. 1992 May;113(5):489-96.
4. Rush JA. Paralysis of cranial nerves III, IV, and VI. Cause and prognosis in 1,000 cases. *Arch Ophthalmol*. 1981 Jan;99(1):76-9.
5. Acaroglu G, Akinci A, Zilelioglu O. Retinopathy in patients with diabetic ophthalmoplegia. *Ophthalmologica*. 2008;222(4):225-8.
6. Patel SV, Mutyala S, Leske DA, et al. Incidence, associations, and evaluation of sixth nerve palsy using a population-based method. *Ophthalmology*. 2004 Feb;111(2):369-75.
7. Janssen K, Wojciechowski M, Poot S, et al. Isolated abducens nerve palsy after closed head trauma: a pediatric case report. *Pediatr Emerg Care*. 2008 Sep;24(9):621-3.
8. Broniscer A, Laningham FH, Sanders RP, et al. Young age may predict a better outcome for children with diffuse pontine glioma. *Cancer*. 2008 Aug 1;113(3):566-72.
9. Cohen HA, Nussinovitch M. Benign abducens nerve palsy of childhood. *Pediatr Neurol*. 1993 Oct;9(5):394-5.
10. Vallée L, Guilbert F, Lemaitre JF, et al. Benign paralysis of the 6th cranial nerve in children. *Ann Pediatr (Paris)*. 1990 May;37(5):303-5.
11. Lee MS, Galetta SL, Volpe NJ, et al. Sixth nerve palsies in children. *Pediatr Neurol*. 1999 Jan;20(1):49-52.
12. Brinar VV, Habek M, Ozreti D, et al. Isolated nontraumatic abducens nerve palsy. *Acta Neurol Belg*. 2007 Dec;107(4):126-30.
13. Peters GB 3rd, Bakri SJ, Krohel GB. Cause and prognosis of nontraumatic sixth nerve palsies in young adults. *Ophthalmology*. 2002 Oct;109(10):1925-8.
14. Kao LY, Chao AN. Subtenon injection of botulinum toxin for treatment of traumatic sixth nerve palsy. *J Pediatr Ophthalmol Strabismus*. 2003 Jan-Feb;40(1):27-30.
15. Holmes JM, Leske DA, Christiansen SP. Initial treatment outcomes in chronic sixth nerve palsy. *J AAPOS*. 2001 Dec;5(6):370-6.



Anti-VEGF Dials Up the Pressure

Anti-VEGF therapy is an effective treatment option for a variety of retinal conditions. However, it also may increase IOP. **By Diana L. Shechtman, O.D., and Paul M. Karpecki, O.D.**

A 57-year-old Hispanic female presented to the clinic with a history of decreased vision that had persisted for several months. Her medical and ocular histories were unremarkable.

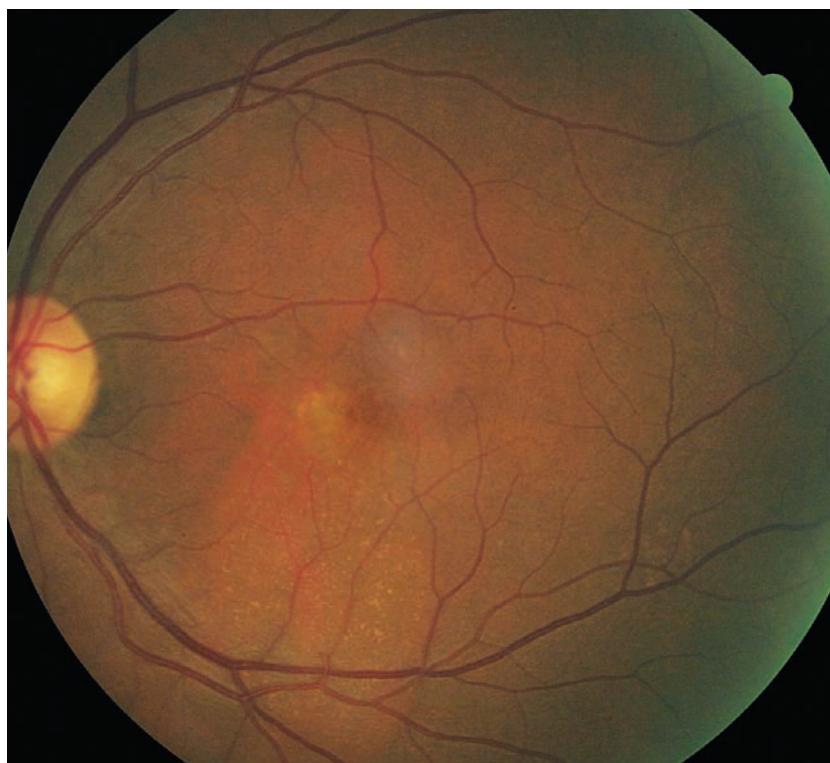Her best-corrected visual acuity measured 20/20 O.D. and 20/50 O.S. The slit lamp examination was unremarkable. Her intraocular pressure measured 12mm Hg O.U.

Dilated fundus examination revealed healthy and distinct optic nerves O.U. No retinal pathology was noted in her right eye. However, we detected a large neurosensory detachment located inferotemporal to the fovea with associated precipitates in her left eye. An associated small, greening lesion also was seen near the fovea (*figure 1*). We documented no associated retinal pigment changes or drusen in either eye.

Fluorescein angiography and OCT testing confirmed the presence of an idiopathic choroidal neovascular membrane O.S. We referred her for intravitreal Avastin (bevacizumab, Genentech/Roche) injection.

At the two-week follow-up, the patient showed both functional and structural improvement in her left eye. Her best-corrected visual acuity was 20/20 O.D. and 20/25 O.S. Furthermore, a dilated fundus examination of her left eye revealed a resolving neurosensory detachment (*figure 2*). However, her IOP measured 14mm Hg O.D. and 23mm Hg O.S.

This raised the question: Did



1. Fundus image revealed the presence of a small lesion located near the fovea O.S.

anti-VEGF therapy contribute to our patient's IOP increase?

Anti-VEGF Therapy and IOP

Use of intravitreal Avastin and Lucentis (ranibizumab, Genentech/Roche) has become a mainstream treatment option for several visually devastating retinal conditions, including macular edema secondary to vein occlusion, diabetic macular edema, age-related macular degeneration and other causes of choroidal neovascular membranes.

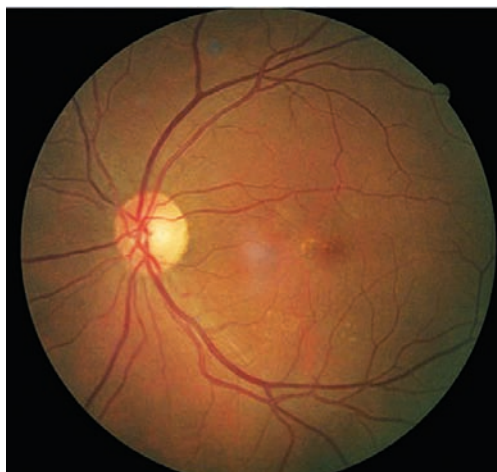The rapid expansion and widespread use of this pharmacologic therapy likely is attributed to its

effectiveness at halting neovascularization and consequently improving visual acuity.

Despite the therapeutic success of intravitreal anti-VEGF therapy, multiple case reports and clinical studies have documented both short- and long-term increases in IOP following the injection process.¹⁻⁵

- *Short-term IOP increases.*

Acute transient rise in IOP following intravitreal anti-VEGF injections may be a common phenomenon. Post-hoc analyses of both the MARINA and ANCHOR studies have shown a 6mm Hg increase in IOP following Lucentis injection.⁶



2. Following an intravitreal injection of Avastin, our patient's left eye showed improvement. However, her IOP level nearly doubled following treatment.

This pressure elevation likely occurs because of sudden fluid increase within the ocular globe following injection. Within 30 to 60 minutes

after injection, IOP typically returns to baseline.^{6,7} Ordinarily, no further management with IOP-lowering medications is necessary.^{6,7}

- *Long-term IOP increases.* The incidence of sustained IOP increase following anti-VEGF injection ranges from about 3% to 10%.^{3,8,9-11} One study documented a long-term IOP increase in 23 patients.

Pre-injection IOP readings were less than 20mm Hg and rose to an average of 35mm Hg following anti-VEGF therapy.⁸ Although sustained IOP increases are relatively infrequent, the

complication usually necessitates treatment with IOP-lowering medications, laser trabeculoplasty or glaucoma filter-

ing surgery.^{4,12}

Various theories have been proposed to explain the underlying cause of sustained post-injection IOP increase. These include the preparation/delivery of the anti-VEGF drug and damage to the trabecular meshwork (TM).

Additionally, blockage of the TM by silicone deposits that drain from the syringe may cause a sustained increase in IOP.¹³ Furthermore, several researchers have theorized that anti-VEGF drugs may directly damage the TM secondary to toxicity or inflammation.^{14,15}

It is worth mentioning that risk factors for IOP increase following intravitreal anti-VEGF injection have not been well documented. Primary risk factors for post-injection IOP increase include an elevated baseline IOP, a pre-existing diagnosis of glaucoma, increased

Powerful Hiring Made Simple.



Post your Eye Care Job on

LocalEyeSite.com

and experience effective hiring
through the **LES Power Network**



injection frequency, decreased time intervals between injections and axial length.^{2,8,16} Age and gender have not been shown to be potential risk factors.

All patients who undergo anti-VEGF therapy should have a baseline IOP measurement prior to treatment. Also, you must monitor these patients closely and perform periodic IOP evaluations.

Individuals with pre-existing glaucoma or ocular hypertension, as well as those receiving frequent injections, may require closer observation both prior to and after treatment. Finally, patients who experience a post-injection IOP increase may require ocular hypotensive medications to maintain normal IOP during the treatment period—especially if frequent retreatment is required.

Regarding our patient, we scheduled her for a follow-up evaluation to monitor her IOP levels and potentially intervene, if necessary. Unfortunately, however, she did not return to the office. ■

1. Bakri SJ, Pulido JS, McCannel CA, et al. Immediate intraocular pressure changes following intravitreal injections of triamcinolone, pegaptanib, and bevacizumab. *Eye (Lond)*. 2009 Jan;23(1):181-5.
2. Kim JE, Mantravadi AV, Hur EY, Covert DJ. Short-term intraocular pressure changes immediately after intravitreal injections of anti-vascular endothelial growth factor agents. *Am J Ophthalmol*. 2008 Dec;146(6):930-4.e1
3. Hoang QV, Mendonca LS, Della Torre KE, et al. Effect on intraocular pressure in patients receiving unilateral intravitreal anti-vascular endothelial growth factor injections. *Ophthalmology*. 2012 Feb;119(2):321-6.
4. Good TJ, Kimura AE, Mandava N, et al. Sustained elevation of intraocular pressure after intravitreal injections of anti-VEGF agents. *Br J Ophthalmol*. 2011 Aug;95(8):1111-4.
5. Bakri SJ, McCannel CA, Edwards AO, Moshfeghi DM. Persistent ocular hypertension following intravitreal ranibizumab. *Graefes Arch Clin Exp Ophthalmol*. 2008 Jul;246(7):955-8.
6. Bakri SJ, Moshfeghi DM, Rundle A, et al. IOP in eyes treated with monthly ranibizumab: A post-hoc analysis of data from the MARINA and ANCHOR trials. Paper presented at the annual American Academy of Ophthalmology meeting, October 15, 2010; Chicago.
7. Falkenstein IA, Cheng L, Freeman WR. Changes of intra-

ocular pressure after intravitreal injection of bevacizumab (Svastin). *Retina*. 2007 Oct;27(8):1044-7.

8. Tseng JJ, Vance SK, Della Torre KE, et al. Sustained increased intraocular pressure related to intravitreal anti-vascular endothelial growth factor therapy for neovascular age-related macular degeneration. *J Glaucoma*. 2012 Apr-May;21(4):241-7.
9. Horsley MB, Mandava N, Maycotte MA, et al. RNFL thickness in patients receiving chronic anti-vascular endothelial growth factor therapy. *Am J Ophthalmol*. 2010 Oct;150(4):558-61.e1.
10. Adelman RA, Zheng Q, Mayer HR. Persistent ocular hypertension following intravitreal bevacizumab and ranibizumab injections. *J Ocul Pharmacol Ther*. 2010 Feb;26(1):105-10.
11. Choi DY, Ortube MC, McCannel CA, et al. Sustained elevated intraocular pressures after intravitreal injection of bevacizumab, ranibizumab, and pegaptanib. *Retina*. 2011 Jun;31(6):1028-35.
12. Skalicky S, Ho I, Agar A, et al. Glaucoma filtering surgery following sustained elevation in IOP secondary to anti-VEGF injections. *Ophthalmic Surg Lasers Imaging*. 2012 Jul 1;43(4):328-34.
13. Liu L, Ammar DA, Ross LA, et al. Silicone oil microdroplets and protein aggregates in repackaged bevacizumab and ranibizumab: effects of long-term storage and product mishandling. *Invest Ophthalmol Vis Sci*. 2011 Feb 22;52(2):1023-34.
14. Kahook MY, Ammar DA. In vitro effects of anti-vascular endothelial growth factors on cultured human trabecular meshwork cells. *J Glaucoma*. 2010 Sep;19(7):437-41.
15. Sniogowski M, Mandava N, Kahook MY. Sustained intraocular pressure elevation after intravitreal injection of bevacizumab and ranibizumab associated with trabeculitis. *Open Ophthalmol J*. 2010 Jun 22;4:28-9.
16. Gismondi M, Salati C, Salveta ML, et al. Short-term effect of intravitreal injection of Ranibizumab (Lucentis) on intraocular pressure. *J Glaucoma*. 2009 Dec;18(9):658-61.

Connect With Patients... on their terms with the EyeDocApp!

EyeDocApp is the first customized mobile application designed specifically for eye care professionals. Now, your patients can instantly schedule appointments, share their experiences with others via Facebook and Twitter, access unique offers and updates about your practice, and much more!

EyeDocApp is an innovative and affordable way for eye care professionals to impact core business metrics such as:

- Higher Patient Retention
- Attracting New Patients
- Increasing Office Traffic

For a low monthly cost and one time set-up fee, your customized EyeDocApp bridges the communication gap between annual patient visits and adds that 'wow' factor to your business!

Visit EyeDocApp.com to Order Today! ←



Marketed exclusively by:



EyeDocApp

Product Review

Nutritional Supplements

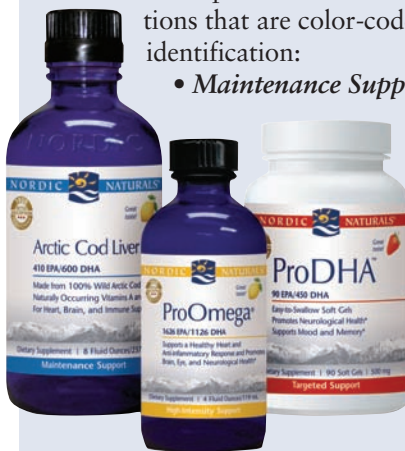Nordic Naturals

The Nordic Naturals professional line of omega-3 products rolls out new labeling this month to improve convenience and appeal for patients and practitioners. EPA and DHA amounts-per-serving are clearly indicated for dosing convenience, and support functions are prominently displayed to help with product selection.

The products fall within five classifications that are color-coded for easier identification:

- **Maintenance Support** (blue label) includes non-concentrated omega-3s and blends.
- **High-intensity Support** (yellow label) includes concentrated omega-3s with a minimum of 1,100mg of EPA and DHA per serving.
- **Targeted Support** (red label) includes concentrated omega-3s with high levels of either EPA or DHA for targeted health needs.
- **Condition-Specific Support** (green label) includes concentrated omega-3s that deliver high levels of EPA and DHA, with condition-specific nutrients added.
- **Pediatric Support** (orange label) includes unique delivery options and dosing tailored to children.

Visit www.nordicnaturals.com/professionals.php.



Ophthalmic Reimbursement Services

Corcoran Compliance Connection

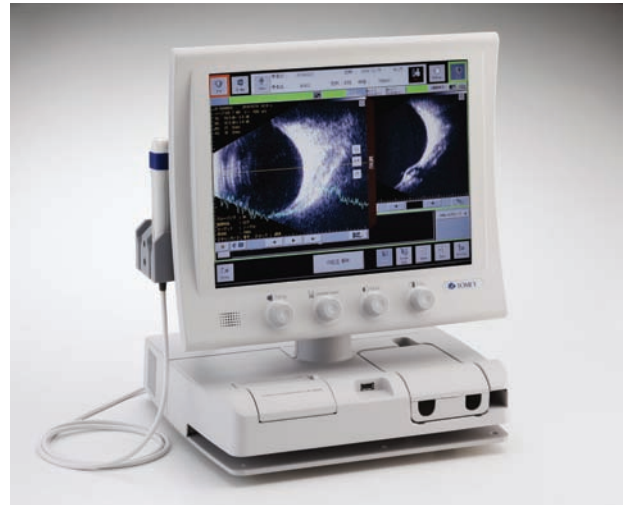Interested in improving the accuracy of your coding and reimbursement efforts, especially in the EMR age? A new service called the Corcoran Compliance Connection, from the practice management experts at Corcoran Consulting, might help. The online software program relies on the chart documentation in your EMR system as the basis for providing accurate, real-time coding recommendations.

The company says it has found that coding for eye exams is accurate and supported by the medical record in just 60% to 70% of all office visits, and believes that Corcoran Compliance Connection can help reduce errors and improve compliance in the other 30% to 40% of claims that aren't coded correctly or supported by chart notes.

Visit www.corcoranccg.com/c3.aspx.

Ultrasound Equipment

Tomey UD-8000 B-Scan



Tomey USA unveils the UD-8000 B-Scan, featuring a new generation of annual array probes, high-resolution touchscreen operation and data communication via USB or LAN. The touchscreen includes functions for video recording and analysis, and the standard probe is a multi-frequency unit that is switchable from 15MHz to 20MHz within the measurement.

Compared to standard linear scanners (with only one focus plane), the annual array technology provides detailed and clear B-Scan images of the entire eye thanks to its five focal planes.

Visit www.tomeyusa.com.

Frames

Nine West 2012 Fall/Winter Eyewear Collection

Nine West creates a vibrant and colorful sun and optical collection for the 2012 fall/winter season, with animal print-inspired patterns and textural details, as well as classic styles that have been revitalized with new colorations.

Sun

- **NW518S.** Featuring a scattered rhinestone pattern across temples, the rectangular frame shape is modified with a subtle butterfly effect on the all-plastic frame. Colors such as blue shimmer and plum shimmer create an iridescent effect; also available in black and tortoise.



- **NW519S.** Inspired by the 1970s, these sophisticated sunglasses feature ombre colorations to enhance the vintage appeal. This style is available in black white, blonde tortoise, blue ombre and rose ombre.



- **NW521S.** Metal studs form linear designs that extend down rich zyl temples, adding edge to an oversized rectangular frame shape. This style is available in black/white, dark tortoise, navy and red horn.



Optical

- **NW1014.** These glasses come in muted metallic colors and pops of gold that complement the animal pattern printed on to glossy zyl temples. Full-rimmed metal frames are a modified rectangular shape, available in satin black, satin brown, olive, lilac and golden.

- **NW1015.** A classic shape with a twist, this all-metal frame features tribal spotted temples. This full-rimmed, modified oval frame is available in satin black, dark brown, lilac and rose.



- **NW5006.** An all-plastic frame, NW5006 features geometric designs and is available in black, emerald pink, tortoise/green, green sky, royal bright, tortoise/purple and ruby orange.

- **NW5007.** Beautiful two-tone colorations define the modified rectangle NW5007, available in black, dark tortoise, emerald pink and green sky.

Visit www.marchon.com.

Not of This World Collection

Eyes of Faith recently debuted its latest ophthalmic collection for Not Of This World (NOTW), featuring seven acetate styles available in three colors.

- The Eyes of Faith signature stained-glass temples are paired with an elegant, classic front shape for style 1020, available in shiny bronze, brown and new aquamarine “glass” combination platinum sea, which incorporates lavender and blue with a bright, polished silver frame.

Product Review



• Style 1005 also has the platinum sea temple option, and the popular shiny bronze stained glass color treatment is available in the style 1004 palette.

For more information, visit www.eofoptical.com.

Twenty Stripes and Twenty Pins

In celebration of its first 20 years in business, Kirk Originals announces two new limited edition collections for autumn release: Twenty Stripes and Twenty Pins.

Each individual frame has its own “20-year” badge of authenticity hand-sunk into the tip and the Kirk Originals signature inside the frame.

Named after famous personalities from 1992 when Kirk Originals was launched, the collections hint at early Kirk Originals acetate styling from the 1990s with a modern twist.

Six styles are available: Paul, Rodney, Carlos, Fernando, Lennart and Roberta. The Stripe collection comes in vermilion, ice, jet and cobalt, while the Pins line is available in aubergine, moss, jet and cobalt.

Visit www.kirkoriginals.com.



Femtosecond Laser

Victus

The Victus Femtosecond Laser Platform, from Bausch + Lomb and Technolas Perfect Vision, received FDA 510(k) clearance and is now available for shipment in the U.S. It is the first femtosecond laser capable of supporting cataract and corneal procedures on a single platform, the companies say. Victus is designed to provide greater precision than manual cataract surgery techniques.

Research suggests that laser refractive cataract surgery, as offered by the Victus platform, may require less phaco energy and time during lens fragmentation, improve intraocular lens placement, and potentially enhance patient outcomes and experience, the companies say.

The platform is cleared for creation of a corneal flap in patients undergoing LASIK, or another surgery requiring initial lamellar resection of the cornea, and anterior capsulotomy during cataract surgery, with plans to submit additional indications to the FDA.

Visit www.technolaspv.com. ■



Do you have a new product or service you'd like to feature in Product Review? Please send a detailed press release and high-resolution images to:

Colleen Mullarkey, Senior Editor

cmullarkey@jobson.com

(610) 492-1005

Stay on top of the current clinical findings with the latest pearls for
Therapeutic Management and Managing Ocular Disease.

Practice Pearl of the Week

The screenshot shows the 'Practice Pearl of the Week' e-newsletter page. At the top, it features the 'REVIEW OF OPTOMETRY' logo, social media links for Facebook and Twitter, and a link to view the practice pearl archives. The issue is identified as 'VOLUME 1, NUMBER 41' and dated 'FEBRUARY 10, 2011'. The main title is 'PRACTICE PEARL OF THE WEEK' with a graphic of an eye. A welcome message from Review of Optometry's Practice Pearl of the Week Series is on the right. The main content is titled 'HERE'S THE SECOND "RULE" OF IRITIS MANAGEMENT:' and includes 'Rule 2. Determine the severity.' It provides a detailed explanation of how to determine severity based on clinical findings, accompanied by a photograph of an eye. A list of five questions to address is provided: 'Unilateral or bilateral?', 'Keratic precipitates (KPs) present on the endothelium?', 'Synechiae present?', 'Grade 3+ (or higher) cell and flare or the presence of a hypopyon?', and 'Number of occurrences?'. A paragraph explains that if two or more major findings are present, a medical work-up and laboratory testing are recommended. A final paragraph notes that the presentation's severity provides clues to the potential existence of an underlying systemic cause. On the right, there is a portrait of Optometrist Paul Karpecki and a quote from Kurt Goad: 'Sometimes we all need to realize that negative thoughts have no power. We empower them.' - Kurt Goad. A link to view the practice pearl archives is also present.

REVIEW
OF OPTOMETRY

FIND US ON FACEBOOK FOLLOW US ON TWITTER

CLICK HERE TO VIEW THE PRACTICE PEARL ARCHIVES!

VOLUME 1, NUMBER 41 FEBRUARY 10, 2011

Welcome to Review of Optometry's Practice Pearl of the Week Series

HERE'S THE SECOND "RULE" OF IRITIS MANAGEMENT:

Rule 2. Determine the severity.

Based on last week's pearl, you've already ruled out a keratouveitis. So now, you need to determine how you will manage the iritis. Generally, the severity of an iritis can be determined by addressing these five questions:

- Unilateral or bilateral?
- Keratic precipitates (KPs) present on the endothelium?
- Synechiae present?
- Grade 3+ (or higher) cell and flare or the presence of a hypopyon?
- Number of occurrences?

If two or more of the major findings are present, you should order a medical work-up and laboratory testing to rule out an underlying systemic disease cause (we'll discuss lab work in a future Pearl of the Week). For example, if a patient presents with a bilateral iritis, KPs on the endothelium and a hypopyon, it is best to recommend a medical work-up or order a battery of lab tests. Or, if you see a patient with synechiae and KPs, and this is the second occurrence of iritis in his or her given eye, then a lab work-up is recommended.

Remember, the presentation's severity provides clues to the potential existence of an underlying systemic cause. And, until that systemic cause is diagnosed and treated properly, an affected patient always is at risk for ocular complications secondary to associated inflammation.

Optometrist Paul Karpecki will provide you invaluable clinical information and management strategies for a host of ocular conditions—from dry eye and corneal infection to retinal artery occlusion and neuro-ophthalmic disease.

CLICK HERE TO VIEW THE PRACTICE PEARL ARCHIVES!

"Sometimes we all need to realize that negative thoughts have no power. We empower them." — Kurt Goad

An e-newsletter series by Paul Karpecki, O.D., that provides valuable information and management strategies for a host of clinical conditions.

Supported by **BAUSCH + LOMB**

REVIEW
OF OPTOMETRY



REVIEW[®]
OF OPTOMETRY

SAVE THE DATE: NOV 30 – DEC 2, 2012

\$100 OFF IF REGISTERED BY SEPT 30!



NEW TECHNOLOGY & TREATMENTS EAST COAST

IN VISION CARE

LOEWS HOTEL PHILADELPHIA

HOTEL INFORMATION

Loews Hotel Philadelphia

Discounted Room Rate: \$179/night

Hotel Reservations: 888.575.6397

DISCOUNTED ROOM RATES

Identify yourself as a participant of
"Review of Optometry" for group rate.

Discounted room rates also available 3 days pre-
and post-conference, based on hotel availability.

FACULTY

Meeting Chair:

→ Paul Karpecki, OD

Speakers:

→ Ben Gaddie, OD

→ Kelly Kerksick, OD

→ Ron Melton, OD

→ Randall Thomas, OD

CONFERENCE TOPICS

- New Therapeutics
- Anterior Segment New Technology
- Posterior Segment New Technology
- Glaucoma
- Ocular Surface Disease
- Anterior Segment Disease
- Posterior Segment Disease
- Contact Lenses
- Refractive Surgery/
Co-Management

REGISTER NOW www.revoptom.com/NewTechEast2012

15 CE Credits (COPE approval pending)

Loews Hotel Philadelphia

1200 Market Street ★ Philadelphia, PA 19107
888.575.6397 ★ www.loewshotels.com/Philadelphia

Registration Information (please print clearly)

Name _____

Practice/Affiliation _____

License # (License numbers are now required for HCP reporting and will only be used for this purpose.) _____

Mailing Address _____

City _____ State _____ Zip Code _____

Telephone _____ Fax _____

Email _____

Name Badge Information (please print clearly)

My Name _____

My Guest _____

Additional Guests _____

HOTEL RESERVATION INFORMATION

Discounted Room Rate

Only \$179 per night

Hotel contact: 888.575.6397

Discounted Room Rates Limited! Mention "Review of Optometry" for Group Rate!

Discounted room rates 3 days pre- and post-conference based on hotel availability.

4 WAYS to register

Online: www.revoptom.com/NewTechEast2012

Call: 866.658.1772

Fax: 610.492.1039

Mail: *Review of Optometry* Conferences
11 Campus Blvd, Ste. 100
Newtown Square, PA 19073

Payment Information

- Full Registration (**\$100 OFF by September 30, 2012 - only \$395**)
Includes tuition for 15 hours of education, breakfasts, breaks and reception.
- Friday Registration
Includes tuition for 5 hours of education, break and reception.
- Saturday Registration
Includes tuition for 5 hours of education, breakfast and break.
- Sunday Registration
Includes tuition for 5 hours of education, breakfast and break.

Rate per person	No. in party	Subtotal
\$495 x	_____	= \$_____
\$170 x	_____	= \$_____
\$170 x	_____	= \$_____
\$170 x	_____	= \$_____
TOTAL		= \$_____

Check enclosed (make checks payable to *Review of Optometry*)
Charge my: American Express Mastercard Visa

Credit Card Number _____ Exp. Date _____

Cardholder (print name) _____

Signature _____

CONFERENCE CANCELLATION POLICY

- Full refund on registration fee until October 25, 2012
- 50% refund on registration fee until November 9, 2012
- No refund past November 10, 2012

www.revoptom.com/NewTechEast2012



Questions? Contact Lois DiDomenico at ReviewMeetings@Jobson.com or 866.658.1772.

Meetings + Conferences

October 2012

- **4-7.** *EastWest Eye Conference.* Cleveland Convention Center, Cleveland. Hosted by: Ohio Optometric Association. Call (800) 999-4939 or e-mail info@ooa.org. Visit www.eastwesteye.org.
- **6-7.** *PSS 2012: 2nd Annual Forum on Ocular Disease.* The Castle Hotel & Resort, Orlando, Fla. Hosted by: PSS EyeCare. CE hours: 18. Call (203) 415-3087 or email education@psseyecare.com. Visit www.psseyecare.com.
- **10-11.** *44th Annual Fall Seminar.* The Lansing Center, Lansing, Mich. Hosted by: Michigan Optometric Association. Contact Amy Possavino at amy@themoa.org or (517) 482-0616. Visit www.themoa.org.
- **11.** *3rd North Jersey Optometric Seminar.* JCC MetroWest, West Orange, N.J. Presenters: Jai Parekh, M.D., and Mary Boname, O.D. CE hours: 4. Call William B. Potter, O.D., at (609) 947-8545 or email eyedoc2180@aol.com. Visit <http://optometryonwest44th.webs.com>.
- **12.** *HVOS Fall Seminar.* The Grandview, Poughkeepsie, N.Y. Hosted by: Hudson Valley Optometric Society. E-mail Robert Greenbaum, O.D., at robertgreenbaum58@gmail.com or call (845) 473-0220. Visit www.hvos.org.
- **12-13.** *Northwoods Education Events.* Black Bear Lodge, St. Germain, Wis. Hosted by: Wisconsin Optometric Association. Email joleenwoaoffice@tds.net or (800) 678-5357. Visit www.woa-eyes.org.
- **13-14.** *Fall Conference.* Lansdowne Resort, Leesburg, Va. Hosted by: Virginia Optometric Association. Call (804) 643-0309 or visit www.thevoa.org.
- **13-14.** *HSO Fall Classic 2012.* Intercontinental Tampa, Tampa, Fla. Hosted by: Hillsborough Society of Optometrists. CE hours: 15. Email exec@hillsods.com or visit www.hsoonline.org/fall-classic.
- **13-15.** *COA Annual Education Conference & Expo.* Mystic Marriott Hotel and Spa, Groton, Conn. Hosted by: Connecticut Association of Optometrists. Call (860) 529-1900 or email info@cteyes.org.
- **16-20.** *COVD 42nd Annual Meeting.* Omni Fort Worth Hotel, Fort Worth, Texas. Hosted by: College of Optometrists in Vision Development. Contact info@covd.org or (330) 995-0718. Visit www.cvod.org.
- **18.** *6th Central Jersey Optometric Seminar.* CentraState Medical Center, Freehold, N.J. Presenter: William Marcolini, O.D. CE hours: 4. Call William Potter, O.D., at (609) 947-8545 or email eyedoc2180@aol.com. For more information, visit <http://optometryonwest44th.webs.com>.
- **24-27.** *Academy 2012 Phoenix.* Phoenix Convention Center. Hosted by: American Academy of Optometry. Visit www.aaopt.org/meetings/academy2012.
- **25.** *1st SouthWest Jersey Optometric Seminar.* The Enterprise Center at Burlington County College, Mount Laurel, N.J. Presenter: William Potter, O.D. CE hours: 4. Call Dr. Potter at

(609) 947-8545 or email eyedoc2180@aol.com. For more info, visit <http://optometryonwest44th.webs.com>.

■ **27-28.** *VOSH International Annual Meeting.* Marriott Renaissance Phoenix Downtown Hotel. Hosted by: VOSH International. Contact Harry I. Zeltzer, O.D., at vosh@vosh.org. Visit vosh-california.org/voshinter/annual12.html.

■ **31.** *Advanced CE for Optometric Physicians.* Crowne Plaza Hotel, Natick, Mass. Hosted by: Eye-Sight 20/20, LLC. Presenters: Jerome Sherman, O.D., and Leo Semes, O.D. CE hours: 8. Call Dr. Antoinette Parvis at (508) 987-9679 or visit www.eyesightce.com.

November 2012

- **1-4.** *VT/Strabismus & Amblyopia.* Western University College of Optometry, Pomona, Calif. Hosted by: Optometric Extension Program. CE hours: 28. Contact Theresa Krejci at (800) 447-0370 or theresakrejcioep@verizon.net. Visit www.oepf.org.
- **2-4.** *2012 ALOA Annual Convention.* The Wynfrey Hotel, Birmingham, Ala. Hosted by: Alabama Optometric Association. Call (334) 273-7895 or visit www.alaopt.org.
- **8-11.** *Monterey Symposium.* Monterey Marriott Hotel & Conference Center, Monterey, Calif. Hosted by: California Optometric Association. Call Will Curtis at (916) 266-5037 or email wcurtis@coavision.org. Visit www.coavision.org.
- **9-10.** *C.E. Charleston.* Doubletree Charleston Historic District, Charleston, S.C. Hosted by: Pacific University College of Optometry. CE hours: 12. Call Jeanne Oliver at (503) 352-2740 or email jeanne@pacific.edu. Visit www.pacificu.edu/optometry.ce.
- **9-10.** *Primary Care Symposium.* Country Springs Hotel, Waukesha, Wis. Hosted by: Wisconsin Optometric Association. Call (800) 678-5357 or email joleenwoaoffice@tds.net. Visit www.woa-eyes.org.
- **9-11.** *FCO International 23rd Annual Educational Conference.* Abe Martin Lodge, Brown County State Park, Nashville, Ind. Hosted by: Fellowship of Christian Optometrists. Visit www.fcoint.org/services/annualConference.html.
- **29-Dec. 3.** *VT/Visual Dysfunctions.* Grand Rapids, Mich. Hosted by: Optometric Extension Program. Instructor: Robert A. Hohendorf, O.D. CE hours: 35. Contact Theresa Krejci at (800) 447-0370 or theresakrejcioep@verizon.net. Visit www.oepf.org.
- **30-Dec. 2.** *New Technology & Treatments in Vision Care East Coast.* Loews Hotel Philadelphia. Hosted by: *Review of Optometry*. Meeting chair: Paul Karpecki, O.D. CE hours: 15. Contact Lois DiDomenico at ReviewMeetings@jobson.com or (866) 658-1772. Visit www.revoptom.com/conferences.

December 2012

- **1-2.** *Glaucoma Grand Rounds Program with Live Patients.* Western University College of Optometry, Pomona, Calif. Call (909) 706-3493 or email ceoptometry@westernu.edu. Visit www.westernu.edu/optometry-continuing-education.

Advertisers Index

■ **1-2.** *29th Annual Cornea, Contact Lens & Contemporary Vision Care Symposium.* The Westin Memorial City, Houston, Texas. Hosted by: University of Houston College of Optometry. CE hours: 16. Call (713) 743-1900 or email optce@uh.edu. For more information, visit <http://ce.opt.uh.edu/live-events/ccls2012>.

■ **14-15.** *3rd Annual West Coast Optometric Glaucoma Symposium.* Fairmount Newport Beach, Newport Beach, Calif. Hosted by: *Review of Optometry*. Meeting chair: Murray Fingeret, O.D. CE hours: 12. Contact Lois DiDomenico at ReviewMeetings@jobson.com or (866) 658-1772. For more information, visit www.revoptom.com/conferences.

January 2013

■ **19-20.** *Gold Coast Educational Retreat.* Hyatt Regency Pier 66, Ft. Lauderdale, Fla. Hosted by: Broward County Optometric Association. CE hours: 17. Email browardeyes@gmail.com or visit www.browardeyes.org.

February 2013

■ **6.** *IOA Winter Seminar.* Ritz Charles, Carmel, Ind. Hosted by: Indiana Optometric Association. Call (317) 237-3560 or email blsims@ioa.org. For more information, visit www.ioa.org.

■ **6-7.** *MOA Winter Seminar.* Kellogg Hotel & Conference Center, East Lansing, Mich. Hosted by: Michigan Optometric Association. Contact Amy Possavino at (517) 482-0616 or amy@themoa.org. For more information, visit www.themoa.org.

■ **8-10.** *3rd Annual Final Eyes CE.* Baptist Hospital Conference Center, Jacksonville, Fla. CE hours: 16. Contact Valerie Fernandez at (904) 202-2080 or valerie.fernandez@bmcjax.com. For more information, visit FinalEyesCE.com.

■ **12-14.** *The Eye Show London 2013.* London ExCeL International Exhibition Centre, United Kingdom. Hosted by: Emergexpo plc. CE hours: 18. Email conference@theeyeshow.com or visit www.theeyeshow.com.

■ **15-17.** *52nd Annual Heart of America Contact Lens Society Contact Lens and Primary Care Congress.* Sheraton Kansas City Hotel and Crown Center, Kansas City, Mo. Contact Dr. Steve Smith at (918) 341-8211 or registration@thehoacsls.org. For more information, visit www.hoacsls.org.

■ **16-20.** *SkiVision 2013.* Viceroy Snowmass Luxury Mountain Resort, Snowmass Village, Colo. CE hours: 23. Call (888) SKI-2530 or email questions@skivision.com. For more information, visit www.skivision.com.

To list your meeting, contact:

Colleen Mullarkey, Senior Editor

E-mail: cmullarkey@jobson.com

Phone: (610) 492-1005

Accutome, Inc. 13	Luxvision 44
Phone (800) 979-2020	Phone (888) 881-1122
Fax..... (610) 889-3233info@luxvision.net
www.LUXVISION.com
Alcon Laboratories .. 7, 17, 18	M&S Technologies 19
..... 40, 55, 56, 59	Phone (877) 225-6101
..... 64, 71, 116	Fax..... (847) 763-9170
Phone (800) 451-3937	
Fax..... (817) 551-4352	Macula Risk - The Genetic Test
	for AMD 67
Bausch + Lomb 28-31, 115	Phone (866) 964-5182
Phone (800) 323-0000	Fax..... (866) 964-5184
Fax..... (813) 975-7762 customerservice@macularisk
 www.macularisk.com
Brien Holden Vision Institute	Marchon 2-3
..... 45	Phone (800) 645-1300
..... info@brienholdenvision.org	Fax..... (800) 544-1334
..... www.brienholdenvision.org	
Carl Zeiss Meditec Inc. 23	Marco Ophthalmic 14
Phone (877) 486-7473	Phone (800) 874-5274
Fax..... (925) 557-4101	Fax..... (904) 642-9338
Eye Designs 11	Reichert Technologies 25
Phone (800) 346-8890	Phone (888) 849-8955
Fax..... (610) 489-1414	Fax..... (716) 686-4545
EZER 70	Three Rivers Optical 69
Phone (305) 503-2729	Phone (800) 756-2020
..... info@EZERUSA.com	Fax..... (800) 756-0034
..... www.EZERUSA.com	
ISTA Pharmaceuticals .. 35, 36	Veatch 39, 41, 43
Phone (949) 788-6000	Phone (800) 447-7511
Fax..... (949) 789-3139	Fax..... (602) 838-4934
Keeler Instruments 5, 87	Vistakon 46-47, 85
Phone (800) 523-5620	Phone (800) 874-5278
Fax..... (610) 353-7814	Fax..... (904) 443-1252
Laservue 63	Vmax Vision, Inc. 9
Phone (888) 734-6666	Phone (888) 413-7038
Fax..... (514) 738-1769Info@VmaxVision.com
..... laservue@laservue.netwww.VmaxVision.com
..... www.laservue.net	
Lombart Instruments 27	Volk Optical, Inc. 96
Phone (800) 446-8092	Phone (800) 345-8655
Fax..... (757) 855-1232	Fax..... (440) 942-2257

This advertiser index is published as a convenience and not as part of the advertising contract. Every care will be taken to index correctly. No allowance will be made for errors due to spelling, incorrect page number, or failure to insert.

Merchandise Offered

14.1
PRODUCT CATALOG

NEW SLIDE SYSTEM

NEW SPHERE LED

NEW B-TWEEN

NEW SLIDE-ASIS

FRAME DISPLAYS
NEW CATALOG PREVIEW
NEW PRODUCTS + NEW DESIGNS

INTERNATIONAL VISION EXPO & CONFERENCE LAS VEGAS
September 6-8, 2012
Las Vegas, NV
Booth #22115

COMPLIMENTARY DESIGN SERVICE

Frame Displays
Frame Displays.com

Frame Displays USA
22821 Silverbrook Center Dr., Suite 140, Sterling, VA 20166
1-703-435-7770
www.framedisplays.com • info@framedisplays.com

Frame Displays CANADA
67 Mowat Ave, Suite 309, Toronto, ON M6K 3E3
416-877-7415
www.framedisplays.com • info@framedisplays.com

CALL 1-877-274-9300

Merchandise Offered

www.eyewear4less.com

TIRED OF RISING FRAME PRICES?
MAXIMIZE YOUR PROFIT

FRAME BUYERS - VIEW OUR COLLECTIONS

BRAND NAME EYEWEAR AT 40 TO 80% OFF LIST PRICE

YOUR PRACTICE YOUR PROFITS

1-800-294-4127

Equipment and Supplies

SOFT CONTACTS • SOFT PRICES

Bradford Optical, Inc.

800.435.5535

www.BradfordOpticalInc.com

REVIEW
OF OPTOMETRY

Do you have Products and Services to offer?

CLASSIFIED ADVERTISING WORKS

Contact us today for classified advertising:
Toll free: **888-498-1460**
E-mail: sales@kerhgroup.com



SOFTWARE



**QUIKEYES ONLINE
WEB-BASED OPTOMETRY EHR**

- \$99 per month after low cost set-up fee
- Quick Set-Up and Easy to Use
- No Server Needed
- Corporate and Private OD practices
- 14 Day Free Demo Trial
- Users Eligible for 44K incentives

www.quikeyes.com



Merchandise Offered

USE **displaydesigner** TO CREATE YOUR OWN OPTICAL WALL LAYOUT



CHECK OUT OUR **NEW DISPLAY GALLERY** FOR GREAT IDEAS...

opticaldisplays.com

REVIEW
OF OPTOMETRY



**Looking to
increase sales?**

Place Your Ad here.

Contact us today for
classified advertising:

888-498-1460

E-mail: sales@kerhgroup.com

SOFTWARE

Secure Access Anytime
EHR Certified
Industry Experts



**Web-based Platform
Certified Complete Exam Module
Secure & Scalable**

800.788.3356
www.eyecom3.com

Equipment and Supplies

YES YOU CAN STILL GET THEM!!!

Humphrey HARK 599 with Glare – Lens Analyzer 350 & 360
ECA has calibration systems, loaners and units in stock!



HUMPHREY 599
w/Glare

LENS
ANALYZER

800-328-2020
www.eyecarealliance.com

Refurbished Units with
Warranties In Stock

Full Repair and
Refurbishment Services

CALL FOR A FREE ESTIMATE

We will also buy your HARK 599 and LA 350/360 - Call for a quote today!

Practice For Sale



Practice Sales • Appraisals • Consulting
www.PracticeConsultants.com

**PRACTICES FOR SALE
NATIONWIDE**

Visit us on the Web or call us to learn
more about our company and the
practices we have available.

info@PracticeConsultants.com

800-576-6935


www.PracticeConsultants.com

Equipment and Supplies



It's What the Best
Pretest on!
(800) 522-2275
www.optinomics.com
sales@optinomics.com

NEW! Roto Chart



Replace your yellowing Roto Chart
with this new bright white Roto Chart.
This Phoropter Roto Chart is a
versatile near point roto chart for your
phoropter or hand hold. Contains a
wide variety of tests for the eye care
professional. Fits on a phoropter
using both the phoropter rod & clip.
Notched wheel for easy chart
selection.

GuldenOphthalmics
time saving tools
800-659-2250 **www.guldenophthalmics.com**

Visit our new website search "15151"

Do you have Equipment
and Supplies for Sale?



Contact us today for classified advertising:
Toll free: 888-498-1460 • E-mail: sales@kerhgroup.com



**Do you have CE or
CME Programs?**

**CONTACT US TODAY
FOR CLASSIFIED ADVERTISING**
Toll free: 888-498-1460
E-mail: sales@kerhgroup.com

Professional Opportunities

STAFF OPTOMETRIST

Bard Optical is a leading vision care organization based out of Peoria, IL with 19 offices throughout central IL. Once again this year we were named to the Top 50 Optical Retailers in the United States by Vision Monday – currently ranking 37th.

Currently we are accepting cv/resumes for our Canton, Springfield, Peoria and Sterling offices. Candidates must have an Illinois license with therapeutics. The practice includes (but is not limited to) general optometry, contact lenses, and geriatric care. Salaried, full-time positions are available with excellent growth programs and benefits.

Email to hr@bardoptical.com.

Come grow with us.

Bard Optical is a proud Associate Member of the Illinois Optometric Association.



www.bardoptical.com

Optometrist

Large and growing 7 office practice with state of the art diagnostic equipment seeking a well-trained personable and motivated Optometrist to join staff of 4 Ophthalmologists and 5 Optometrists.

Competitive salary and benefits.

Email resume/CV to mapharman@aol.com

Continuing Education

Seminars In Paradise™
Christmas CE Cruise from New Orleans

Edward L. Paul, Jr., OD, PhD

Current Trends in Contemporary Optometry

December 23 - 30, 2012

Post Cruise
New Orleans
New Year's Package
Available - Call



12 CE



Dr. TRAVEL, LLC
is a COPE approved provider

NCL Star Cruise Prices from \$784¹ pp / dbl. - Seminar \$595*

*¹Please add \$267.49 to cover port charges, taxes, and fees / *When purchased together with the cruise*

Presidents Week (February. 16 - 23, 2013) - Western Caribbean

Royal Caribbean Cruise Lines's Oasis - Roundtrip Ft. Lauderdale

"Expanding the Scope of Primary Care" - Blair Lonsberry, MS, OD, MEd, FFAO"

800 436 1028

Dr. TRAVEL, LLC

DrTravel.com

Products and Services

ACCESS 
HEALTHCARE CAPITAL

Access Healthcare Capital is your key to practice financing. Specialized loans tailored to meet your professional practice needs. We specialize in the Optometry Field with over 75 years of combined management, ownership, and financing. Let us help you realize your dream!

- 100% Financing plus Working Capital
- Practice Acquisitions
- Practice Start Ups
- Partnership Buy-In Programs
- Practice Improvements & Equipment
- Fixed Rate Terms up to 15 years
- Flexible Payment Options

www.accesshealthcarecapital.com • info@narxeye.com

Access Healthcare Capital • 1-888-727-4470 • P.O. Box 349, Gladwyne, PA 19035

REVIEW
OF OPTOMETRY



**Looking to
increase sales?**

Place Your Ad here.

Contact us today for
classified advertising:

888-498-1460

E-mail: sales@kerhgroup.com

REVIEW
OF OPTOMETRY

**DO YOU HAVE AN
EVENT TO PROMOTE?**

Contact us today for
classified advertising:
Toll free: **888-498-1460**
E-mail: sales@kerhgroup.com

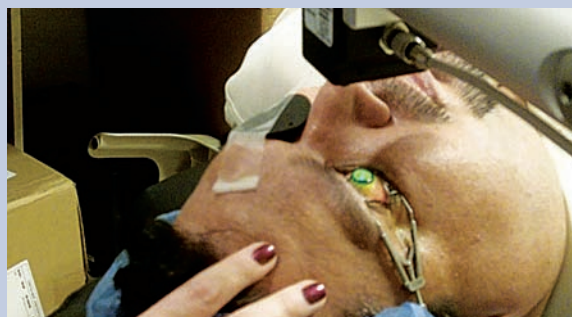



Corneal Collagen Cross-Linking

This innovative procedure might help keratoconus patients and others who suffer from ectasia. Here's an overview.

By Derek N. Cunningham, O.D., and
Walter O. Whitley, O.D., M.B.A.



After riboflavin is administered to the corneal surface and a flare check confirms it has reached the anterior chamber, the patient is exposed to UV light to catalyze the reaction.



Go to www.revoptom.com to see video footage of corneal collagen cross-linking being performed.

On The Web >> View a narrated video of this technique in an epithelium-off CXL procedure.

Corneal collagen cross-linking (CXL) is an investigational procedure that is used to arrest the progression of corneal ectasia secondary to keratoconus, pellucid marginal degeneration and/or LASIK surgery. Currently, CXL is not approved by the FDA; however, eye care specialists outside the United States have been performing the procedure successfully for more than a decade.

The fundamental purpose of CXL is to increase corneal rigidity, making it less prone to thinning and deformation. This is achieved by saturating the cornea with riboflavin, and then exposing it to ultraviolet-A (UVA) light. The UVA light interacts with the riboflavin to form chemical bonds both between and within the corneal collagen fibrils, which induces stiffening. The procedure preserves corneal transparency and, in essence, accelerates the aging of the cornea. As the collagen fibrils become compacted, mild corneal flattening and thinning may result.

There are two CXL techniques under investigation in the United States: epithelium-removed (epi-off) and epithelium-on. Initially, most clinicians preferred epi-off CXL, because it was believed that the patient would experience better riboflavin absorption. However, several studies currently are evaluating the clinical efficacy of epithelium-on CXL, which requires a shorter healing time and less intensive postoperative management. Nonetheless, at this time, the epi-off technique generally is considered more effective.

In either technique, the cornea is soaked in riboflavin until it can be detected in the anterior chamber via a flare check (usually about 30 minutes). If the corneal pachymetry measurement is thinner than 400 μ m following riboflavin saturation, the application of UVA light could potentially damage the endothelial cells. In this instance, neither form of CXL likely should be performed. And, because approximately 50 μ m of epithelial tissue is removed during epi-off CXL, patients with a corneal thickness of less than 350 μ m definitely are not considered candidates for the procedure.

There are several items for the comanaging O.D. to consider. Individuals who undergo epi-off CXL should be managed similarly to a post-PRK patient (e.g., monitored for complications associated with infection, delayed wound healing and prolonged pain). Additionally, all patients may develop mild haze or opaque streaking in the stroma after the procedure. Typically, haze is temporary and rarely visually significant. No additional management steps are required for these patients, unless the haze is severe and visually obstructive.

At around one year post-treatment, most patients will experience easier contact lens fittings and better vision (both corrected and uncorrected). The European success rate in halting ectasia is 92%. But if continued ectasia is documented after one year, a second CXL treatment may be necessary. Keep in mind that CXL does not actually reverse ectasia; it simply helps to curtail progression. ■



Review of Optometric Business

Your premier online source
for optimizing practice growth...
just got EASIER to use!

NEW design, NEW features

- More reader friendly—so you can find info quickly!
- New practice-building content weekly
- Interactive polls to measure your practice against others
- New comment boxes to jump into online dialogues with colleagues
- Social media links to help you share and receive stories and ideas
- Hundreds of archived articles on how to grow your practice—organized to help you capture opportunities

Join over 10,000 registered readers today at ReviewOB.com!

Platinum

LUXOTTICA®

eyefinity®

Silver



VisionOne
CREDIT UNION

vision)web™
Streamline. Simplify. Succeed.™

OPTI-FREE®
puremoist



Visiooffice
Acuvue



Management & Business
ACADEMY
Alcon

Gold

Alcon®

ACUVUE®
BRAND CONTACT LENSES
INNOVATION FOR HEALTHY VISION®



CareCredit®
25 Years of Caring.

ABB) CONCISE
The smart choice.

Vision Source



Watch Your Step

By Andrew S. Gurwood, O.D.

History

A 53-year-old white woman was transported to the emergency room following a fall. After gross inspection of her face, the attending physician ordered an ocular consult.

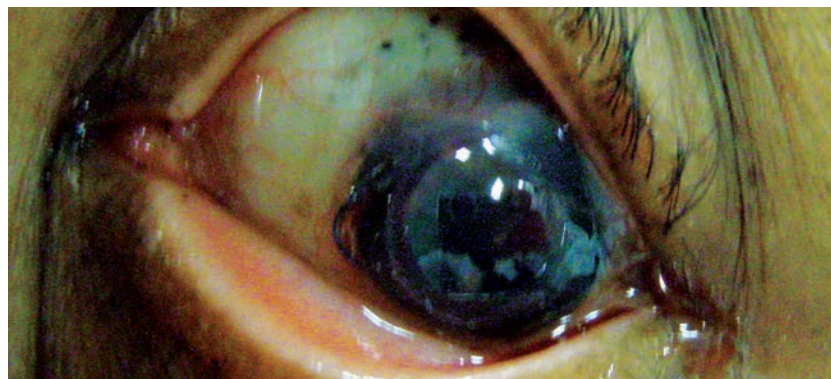
Her ocular history was significant for recent phacoemulsification with intraocular lens implant in her left eye. The IOL implantation resulted in chronic pseudophakic bullous keratopathy, which required treatment via penetrating keratoplasty.

Her systemic history was remarkable for hypertension, for which she was compliant and properly medicated. She reported no known allergies.

Diagnostic Data

Her best-uncorrected visual acuity measured 20/20 O.D. and 20/400 O.S. using a near point card.

Her extraocular muscles were



External view of our 53-year-old patient who was taken to the ER following a fall.

intact, with no obvious entrapment. There was no evidence of afferent pupillary defect. Her intraocular pressure measured 14mm Hg O.U.

The anterior and posterior segment examinations of the right eye were normal. We postponed the dilated fundus examination of the left eye, however, due to the acute nature of her injury.

Your Diagnosis

How would you approach this case? Does this patient require additional testing? What is your diagnosis? How would you manage this patient?

To find out, please visit www.revoptom.com. Click on the cover icon for this month's issue, and then click "Diagnostic Quiz" under the table of contents. ■

Retina Quiz Answers (from page 91): 1) b; 2) d; 3) d; 4) d; 5) a.

Next Month in the Mag

The October issue features our Practice Management Report.

Topics include:

- *Expert Legal Answers to Staff-Related Problems*
- *When is it Time to Add an Associate?*
- *EMR 'Horror' Stories*
- *Myths of Social Media*
- *Annual Salary Survey*
- *Adding an In-Office Lab: Is it the Right Move for Your Practice?*

Also in October:

- *Optometric Study Center: The Impact of Systemic Meds on IOP and Glaucoma* (earn 2 CE credits)
- *Case Report: Choroidal Mass Helps Uncover Throat Cancer*

Feedback

Review of Optometry welcomes questions and comments. E-mail Jack Persico, editor-in-chief, jpersico@jobson.com, with "Letter to the Editor" as the subject line.

REVIEW OF OPTOMETRY (ISSN 0147-7633) IS PUBLISHED MONTHLY, 12 TIMES A YEAR BY JOBSON PUBLISHING LLC., 100 AVENUE OF THE AMERICAS, NEW YORK, NY 10013-1678. JOBSON PUBLISHING LLC, A WHOLLY-OWNED SUBSIDIARY OF JOBSON MEDICAL INFORMATION, LLC. PERIODICALS POSTAGE PAID AT NEW YORK, NY AND ADDITIONAL MAILING OFFICES. POSTMASTER: SEND ADDRESS CHANGES TO REVIEW OF OPTOMETRY, PO BOX 2025, SKOKIE, IL 60076. SUBSCRIPTION PRICES: US: ONE YEAR \$56; TWO YEARS \$97, CANADA: ONE YEAR \$88, TWO YEARS \$160, INT'L: ONE YEAR \$209, TWO YEARS \$299. FOR SUBSCRIPTION INFORMATION CALL TOLL-FREE (877) 529-1746 (USA ONLY); OUTSIDE USA, CALL (847) 763-9630 OR FAX (847) 763-9631. PUBLICATIONS MAIL AGREEMENT NO: 40612608. CANADA RETURNS TO BE SENT TO BLEUCHIP INTERNATIONAL, P.O. BOX 25542, LONDON, ON N6C 6B2.

**Unmatched
Support**

+

**Quality
Materials**

=

**Unrivalled
Leadership**

**Maybe that's why Boston® lenses are
prescribed **3** times more often.***

The Boston team knows what it takes to be a leader in the GP lens market. For years we have provided products with excellent performance and high Dk. In addition, we offer education and fitter training for specialty lenses, both on our own and partnered with our authorized laboratories. It's what our customers tell us they need to provide better vision care. And it is exactly what they can expect from a leader.



Boston®
Materials

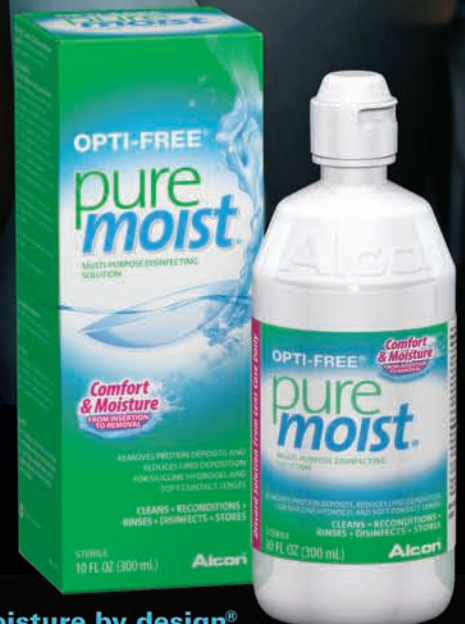www.fit-boston.com

BAUSCH+LOMB

* Boston lenses are prescribed 3 times more often than the closest GP competitor. Source: Survey conducted by Decision Analyst, March 2011.

© 2012 Bausch + Lomb Incorporated. ®/™ denote trademarks of Bausch + Lomb Incorporated. All other product/brand names are trademarks of their respective owners.
Global-0961 Rev Date: 08/2012

Extreme measures shouldn't be necessary for all-day lens comfort



Scan & See The Latest
Wetting Technology

More moisture by design®

Alcon®