

A Supplement to

# REVIEW<sup>®</sup> OF OPTOMETRY

May 15, 2012

## CLINICAL GUIDE TO OPHTHALMIC DRUGS



BY  
RON MELTON, O.D. AND RANDALL THOMAS, O.D.

Supported by an Unrestricted Grant from

**BAUSCH+LOMB**

# EDUCATORS IN PRIMARY EYECARE LECTURE SERIES

by Drs. Ron Melton and Randall Thomas

*Past recipients of the "Glaucoma Educator of the Year" Award  
by the American Academy of Optometry*

*Authors of Review of Optometry's annual Clinical Guide to Ophthalmic Drugs*

## CONTINUING EDUCATION

### OUR COURSES ON YOUR COMPUTER!

In keeping pace with the digital age, we are pleased to announce that many of our lectures are now available via the Internet at [www.OptSpace.com](http://www.OptSpace.com). For those of you interested in expanding your clinical knowledge through distance learning, you may access these online lectures as an enjoyable way to pursue continuing education with ease from your computer or mobile devices.

### CE IN CANADA!

**NOVEMBER 9 - 11, 2012**

The Vision Institute of Canada

Toronto, Ontario

Contact: Dr. Paul Chris, Executive Director: [vicanada@look.ca](mailto:vicanada@look.ca)

For those of you who prefer to attend a more traditional format of lectures, we are giving our famous 20-hour, comprehensive update course, *Current Therapy in Ocular Disease*, at The Vision Institute of Canada in 2012. This is a grand opportunity to visit nearby Niagara Falls and the world-class city of Toronto, and to interact with a terrific group of our Canadian optometric colleagues.

*Do note that a passport is now required to enter Canada.*



While our lecture series is not formally a Board-review course, many optometric professionals have told us that the information we covered enabled them to successfully pass their Board certification. Whether you are Board-eligible or have been practicing for many years, this 20-hour course will help you provide better patient care.

Visit our website: [www.eyupdate.com](http://www.eyupdate.com)

## A New Look for a New Year

Greetings for 2012!

We are grateful that you, the optometric community, find this annual work beneficial to your professional growth and of service to your patients. Thank you for the many encouraging words you share with us at our lecture programs.

While the pharmaceutical pipeline has been relatively quiet this past year, there have been several pertinent articles published that shed more light in clinical areas germane to patient care and have great relevance to practicing optometrists. This year, we are using many teaching slides from our lectures to highlight salient features of new research that should directly impact our practice patterns. We hope you find this slight format modification helpful in keeping you on the cutting edge of clinical knowledge.

Of note, Bausch + Lomb has recently announced it will buy ISTA Pharmaceuticals, which will expand its drug portfolio and pipeline. In regard to this publication, though, the medications are still listed under their respective companies because B+L and ISTA are still operating independently until the acquisition is officially completed.

On behalf of our fine profession, we sincerely thank *Review of Optometry* and Bausch + Lomb for teaming with us to enable the sharing of this knowledge with all of our colleagues.

Though stated a few years ago, human nature does not change, and we thought the following quotes might encourage and inspire:

### Patient Expectations Regarding Eye Care: Focus Group Results

"Honesty was not only the most frequent cited expectation among focus group participants as a whole, but also the most frequently cited expectation area among all subgroups as well."

"The observation that ophthalmology patients place greater emphasis on communication and interpersonal manner than technical interventions is consistent with a previous study, which found that patient satisfaction is more closely linked to patients' perceptions about whether they received nontechnical interventions, such as education, than technical interventions, such as diagnostic tests."

Dawn AG, Santiago-Turla C, Lee PP. Patient expectations regarding eye care: focus group results. *Arch Ophthalmol.* 2003 Jun;121(6):762-8.

Our very best wishes to you all,



Ron Melton, O.D.



Randall Thomas, O.D., M.P.H.

Disclosure: Drs. Melton and Thomas are consultants to, but have no financial interests in, the following companies: Alcon Laboratories, Bausch + Lomb, Carl Zeiss Meditec, Icare, and Rapid Pathogen Screening.

Supported by an unrestricted  
grant from

**BAUSCH + LOMB**

## CONTENTS

**Topical Antibiotics ..... 2A**

**Combination Drugs ..... 9A**

**Corticosteroids ..... 16A**

**'Off-Label' Use of  
Ophthalmic Medicines ..... 21A**

**Overview of Herpes  
Simplex Disease..... 24A**

**Glaucoma Review  
and Update..... 28A**

**Keeping Allergy  
Management Simple ..... 34A**

**Oral Medicine Update..... 36A**

**Inflammatory Ocular  
Surface Disease ..... 39A**

**Innovations in  
Instrumentation ..... 44A**

**Pearls, Pointers and  
Perspectives ..... 46A**

**Dress for Success!..... 49A**



**A Peer-Reviewed Supplement**

Note: The clinical views and advice expressed in this publication are those of the authors, and do not necessarily reflect those of the sponsor, Bausch + Lomb, or the publisher, *Review of Optometry*.

# Topical Antibiotics

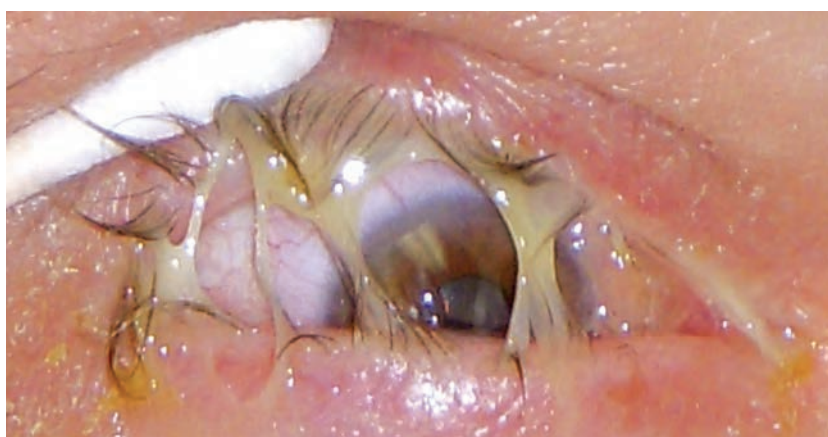More studies are indicating that we should use old drugs for new bugs. The “newer drugs” have grown increasingly resistant due to over-prescribing.

**B**efore you read this, you might want to be sitting down... Here goes: The four most effective, least resistant ophthalmic medicines to treat the two most common ocular pathogens—*Staph. aureus* and *Staph. epidermidis*—are gentamicin, trimethoprim with polymyxin B, besifloxacin, and vancomycin.<sup>1-4</sup>

Gentamicin and trimethoprim with polymyxin B are generically available. Besifloxacin is a chlorofluoroquinolone, and vancomycin (as an eyedrop) has to be compounded. Note that fluoroquinolones are not on the list! We’ve known this to be the case for several years now. Furthermore, excellent drugs against *Pseudomonas* are the fluoroquinolones, the aminoglycosides, and polymyxin B.

Unless a patient gives evidence (or history) of mucopurulent discharge, or unless there is a true threat to the cornea, the use of a topical antibiotic is usually of no clinical value. We have had the opportunity to see many hundreds of “red eyes” over the years. A hefty proportion of these have been treated elsewhere and have not gotten better. The reason: They have some variety of inflammatory eye condition that invariably responds to the steroid we prescribe...and we gain a new patient to our practice.

There are two things we wish



**A bug flew into this man's eye. Two days later, he developed an impressive acute bacterial blepharoconjunctivitis, which resolved quickly after a thorough in-office cleaning and antibiotic eyedrops q2h for two days, and then q4h for four more days.**

primary care physicians understood:

- If there is no discharge, the eye is not infected.
- If there is sector injection to the conjunctiva (i.e., episcleritis, etc.), the eye is not infected.

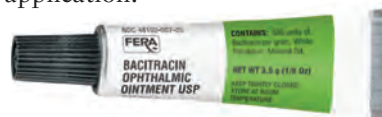Knowledge of these two concepts could save thousands of patients therapeutic misadventures every year.

But, bacterial infections do indeed occur, so let's examine how best to treat these.

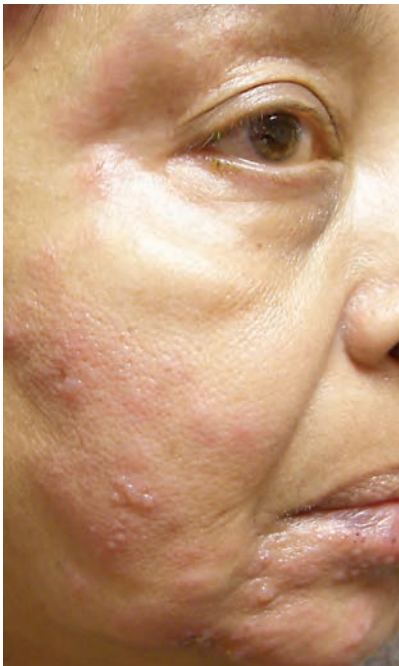## Bacitracin and Polysporin

Since 1948, bacitracin has been highly bactericidal against gram-positive bacteria. Its drawback is that it is only available as an oph-

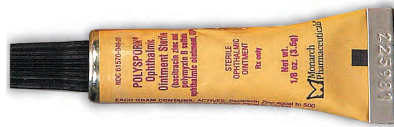thalmic ointment, which limits its clinical usefulness because patients typically do not like ointments in their eyes for obvious reasons. Thus bacitracin is limited to treating children and, in adults, staphylococcal blepharitis via nighttime application.



However, when one adds polymyxin B—a potent agent against gram-negative bacteria—to bacitracin, a wonderful, broad-spectrum antibiotic is created. Known originally as Polysporin ophthalmic ointment, this combination of bacitracin and poly-



**Patients with herpes zoster skin lesions may apply Polysporin antibiotic ointment to prevent secondary bacterial infection.**



myxin B is now generically available. It is much more readily available than bacitracin alone, and so we sometimes prescribe the combination formulation for staphylococcal blepharitis (ignoring the nontoxic, nonparticipating polymyxin B).

Its forté is nocturnal instillation to augment the treatment of any severe eye infection. That is, use eyedrops by day and Polysporin (or its generic) ophthalmic ointment at bedtime. Though both of these drugs are decades old, they remain excellent chemotherapeutic agents.

## Aminoglycosides

There are three aminoglycosides on the market: gentamicin, tobra-

## Antibiotic Use Causes Multidrug Resistance

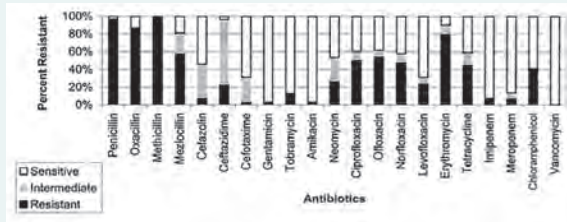
- “Conjunctival *S. epidermidis* repeatedly exposed to fluoroquinolone or azithromycin antibiotics rapidly develop resistance.”
- Gentamicin, Polytrim, doxycycline, and vancomycin remain very highly effective medicines in eradicating *S. epidermidis*.
- The fluoroquinolones and macrolide antibiotics exhibit high levels of resistance
- “These findings indicate the need for greater thought and more rational use of ophthalmic antibiotics to reduce the epidemic of antimicrobial resistance.”

Dave SB, Toma HS, Kim SJ. Ophthalmic antibiotic use and multidrug-resistant staphylococcus epidermidis: a controlled, longitudinal study. *Ophthalmology*. 2011 Oct;118(10):2035-40.

## Topical Antibiotic Drugs

BRAND NAME	GENERIC NAME	MANUFACTURER	PREPARATION	PEDIATRIC USE	BOTTLE/TUBE
<b>Fluoroquinolones</b>					
Besivance	besifloxacin 0.6%	Bausch + Lomb	suspension	≥ 1 yr.	5ml
Ciloxan, and generic	ciprofloxacin 0.3%	Alcon, and generic	sol./ung.	≥ 1 yr./ ≥ 2 yrs.	5ml, 10ml/3.5g
Iquix	levofloxacin 1.5%	Vistakon Pharm.	solution	≥ 6 yr.	5ml
Moxeza	moxifloxacin 0.5%	Alcon	solution	≥ 4 mos.	3ml
Ocuflox, and generic	ofloxacin 0.3%	Allergan, and generic	solution	≥ 1 yr.	5ml, 10ml
Quixin	levofloxacin 0.5%	Vistakon Pharm.	solution	≥ 1 yr.	5ml
Vigamox	moxifloxacin 0.5%	Alcon	solution	≥ 1 yr.	3ml
Zymaxid	gatifloxacin 0.5%	Allergan	solution	≥ 1 yr.	2.5ml
<b>Aminoglycosides</b>					
Tobrex, and generic	tobramycin 0.3%	Alcon, and generic	sol./ung.	≥ 2 mos.	5ml/3.5g
Garamycin, and generic	gentamicin 0.3%	Fera, and generic	sol./ung.	N/A	5ml/3.5g
<b>Polymyxin B Combinations</b>					
Polytrim	polymyxin B/trimethoprim	Allergan, and generic	solution	≥ 2 mos.	10ml
Polysporin	polymyxin B/bacitracin	generic	unguent	N/A	3.5g
Neosporin	polymyxin B/neomycin/gramicidin	generic	sol./ung.	N/A	10ml/3.5g
<b>Other Antibiotics</b>					
AzaSite	azithromycin 1%	Merck	solution	≥ 1 yr.	2.5ml
Ilotycin	erythromycin 0.5%	Fera	unguent	≥ 2 mos.	3.5g
Bacitracin	bacitracin 500u/g	Fera	unguent	N/A	3.5g

## Antibiotic Resistance Patterns of Ocular Bacterial Flora



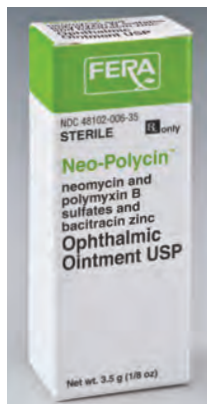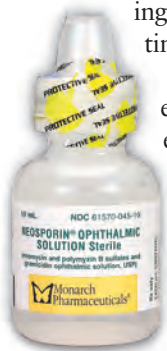
### Coagulase-negative *Staphylococcus* antibiotic susceptibility patterns

- “Our study suggests a disturbingly high percentage of resistance to all fluoroquinolones tested, except levofloxacin.”<sup>1</sup>
- “The antibiotics that seemed to be most effective in eliminating multiresistant CNS [coagulase-negative staphylococci] were vancomycin, [and] the aminoglycosides...”<sup>1</sup>
- Furthermore, and corroborating this 2003 article: “MRSA organisms may be resistant in vitro to all generations of fluoroquinolone antibiotics, but do seem to be sensitive to gentamicin and vancomycin.”<sup>2</sup>

1. Ta CN, Chang RT, Singh K, et al. Antibiotic resistance patterns of ocular bacterial flora: a prospective study of patients undergoing anterior segment surgery. *Ophthalmology*. 2003 Oct;110(10):1946-51.  
 2. Deramo VA, Lai JC, Winokur J, et al. Visual outcome and bacterial sensitivity after methicillin-resistant *Staphylococcus aureus*-associated acute endophthalmitis. *Am J Ophthalmol*. 2008 Mar;145(3):413-417.

mycin and neomycin. While the aminoglycosides are all highly effective antibiotics, they can occasionally cause a type 4 delayed hypersensitivity reaction. Although this reaction is not at all serious, it can cause an annoying contact blepharodermatitis, and sometimes a transient epithelial keratitis.

Of the three, neomycin has the greatest proclivity to cause a reaction, thus earning it a relatively undesirable reputation. However, the much beleaguered neomycin is actually inherently broad-spectrum (with the exception of *Pseudomonas*), and is an excellent drug. It has never been a stand-alone drug, but it is widely available in numerous combination products. Neomycin is most famous as the key ingredient in Neosporin, a superb broad-spectrum antibiotic that contains all three of the previously named antibiotics: bacitracin, polymyxin



## Sometimes Older is Better

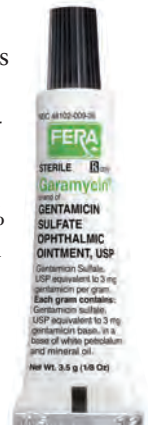“Antibiotic use should be appropriately limited, employing narrower spectrum or older agents whenever possible—particularly for mild or self-limiting infections. It should be recognized, further, that newer antimicrobials are not necessarily better than older ones: trimethoprim/polymyxin B, for example, maintains excellent activity against MRSA (>95% of strains susceptible) and most methicillin-resistant coagulase-negative staphylococci (>90% of strains susceptible).”

Hwang DG. Fluoroquinolone Resistance, MRSA, and the Empty Antimicrobial Pipeline: A Doomsday Scenario for Eyecare? *Refractive Eyecare*, September 2011.

and neomycin. It is a powerful, highly effective agent, but has the potential Achilles’ heel of neomycin allergy. These type 4 reactions are uncommon, and are transient. Unlike bacitracin and Polysporin, Neosporin is available generically as both solution and ointment. It is our opinion that Neosporin would outperform the fluoroquinolones in bacterial eradication, although there are no studies to prove this.

Regarding tobramycin and gentamicin, think just how many times these two drugs have been prescribed in both solitary and combination forms to fight bacterial infection. This observation alone should place them on our list of effective agents against these pathogens. Both drugs come in 0.3% concentrations and are readily available in both solution and ointment forms.

Many studies have shown that aminoglycosides outperform the fluoroquinolones. Gentamicin is a drug-of-choice for MRSA infections.<sup>2</sup> As a point of informa-



## Antimicrobial Resistance

- *Staph. epidermidis* was the most common pathogen in this study.
- 97% of all isolates were sensitive to gentamicin.
- Fluoroquinolone resistance ranged from 32% to 40%.
- “The high prevalence of fluoroquinolone-resistant organisms among ocular and nasal flora in our patient population raises concern with regard to the usefulness of topical fluoroquinolones as the best first-line agent in the setting of ophthalmic prophylaxis and for empiric use in acute ophthalmic infectious processes.”

Atiabi CR, Miller D, Schiffman JC, Davis JL. Antimicrobial resistance profiles of ocular and nasal flora in patients undergoing intravitreal injections. *Am J Ophthalmol*. 2011 Dec;152(6):999-1004.

## Azithromycin and Povidone-Iodine for Ophthalmia Neonatorum Prophylaxis

- “Topical azithromycin is likely as effective for the important causes of ophthalmia neonatorum as its fellow macrolide erythromycin.”
- “A controlled clinical trial comparing erythromycin, 0.5%, povidone-iodine, 2.5%, and silver nitrate, 1%, for ophthalmia neonatorum prophylaxis demonstrated that povidone-iodine was more effective than the other agents for preventing infectious conjunctivitis, including chlamydial conjunctivitis.”
- “We believe povidone-iodine would be a suitable and perhaps preferable alternative to azithromycin for ophthalmia neonatorum prophylaxis.”

Keenan JD, Eckert S, Rutar T. Cost analysis of povidone-iodine for ophthalmia neonatorum prophylaxis. *Arch Ophthalmol*. 2010 Jan;128(1):136-7.

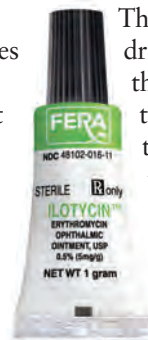tion, many pathogenic *Staph.* species are now “methicillin-resistant” (MRSA).<sup>4</sup> This means that these species are now much more resistant to antibiotics than were the *Staph.* populations of yesteryear, which were mostly methicillin-sensitive and therefore easy to subdue.

## Macrolides

There are three macrolide drugs: the prototypic erythromycin, azithromycin and clarithromycin.

Erythromycin has been used to death, and therefore it has a lot of resistance. It is nontoxic to the ocular surface tissues, and can be used as sort of a nocturnal “lubricant plus” because it does have some antibiotic activity. It is only available in ointment form, and therefore is limited in its clinical usefulness.

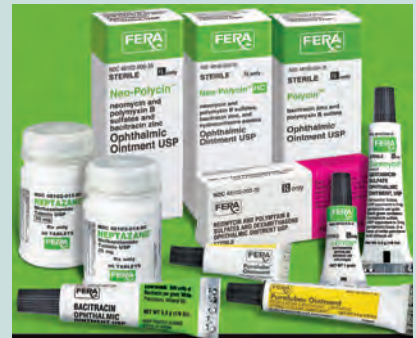While erythromycin is available as an ophthalmic ointment by the brand name Ilotycin (Fera), azithromycin is available as a topical



## Antibiotic Ointments

Most antibiotic and antibiotic/steroid combination ointments are now generically available, which is a big plus for many patients.

Fera Pharmaceuticals has acquired the rights to manufacture a number of these ophthalmic ointments, including erythromycin by its original brand name, Ilotycin. Its website, [www.ferapharma.com](http://www.ferapharma.com), provides a complete list of its products.



## Preventing Eye Infections (Intravitreal Injections)

- Kill time for Betadine (povidone iodine, any concentration) is 15 to 120 seconds!
- Anaphylaxis to iodine does not exist!
- “Topical moxifloxacin 0.5% had no additional effect on reducing conjunctival bacterial counts beyond the effect of 5% povidone iodine alone.”
- “Preinjection antibiotics either before the day of injection or immediately prior to injection are not generally recommended.”
- Gentamicin was vastly more effective than fluoroquinolones

Wykoff CC, Flynn HW Jr, Rosenfeld PJ. Prophylaxis for endophthalmitis following intravitreal injection: antisepsis and antibiotics. *Am J Ophthalmol*. 2011 Nov;152(5):717-9

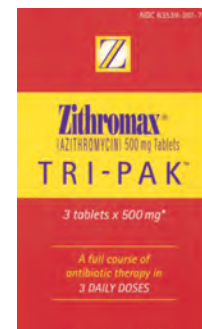eyedrop, AzaSite (Merck). Systemically, azithromycin is a relatively broad-spectrum antibiotic, but according to the TRUST (Tracking Resistance in the United States Today) data, it is not as effective as many other commonly used antibiotics, including the fluoroquinolones.<sup>5</sup>



Ophthalmic azithromycin, as well as ophthalmic besifloxacin (described below), has DuraSite as its vehicle. This makes for a very thick eyedrop. So, explain to the patient that the dropper bottle should be tapped or slung so that the contents are forced up in toward the tip of the bottle to facilitate delivery of the drop. Also, instruct the patient to not blink for five to 10 seconds after instillation to allow the drop to spread on the ocular

surface to enhance absorption.

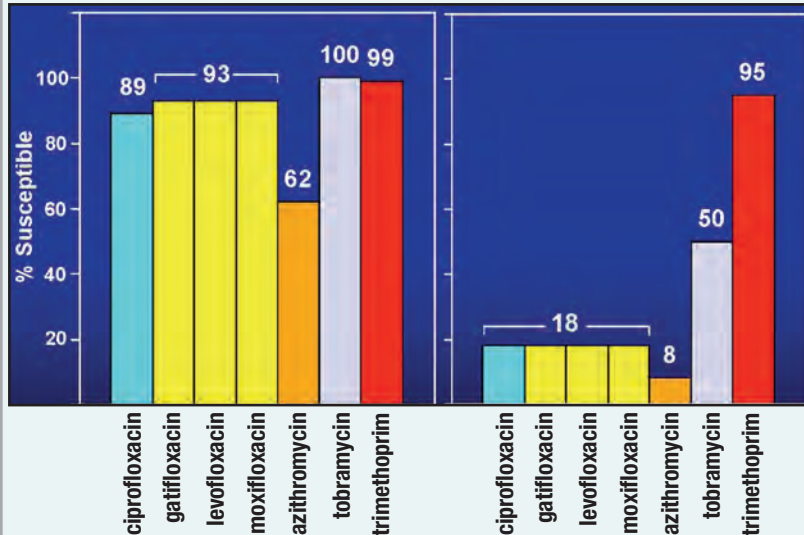
Azithromycin is most famous for its Z-Pak or Tri-Pak oral formulations. One of the beauties of topical ophthalmic azithromycin is its long-lasting clinical effectiveness, and thus its enhanced dosing schedule. The recommended dosing schedule of AzaSite is one drop every 12 hours for two days, then just one drop daily for five more days—a total of nine drops to treat bacterial conjunctivitis. So, this is a very patient-friendly dosing schedule with a drug that seems well-suited for treatment of bacterial conjunctivitis, especially in children who



## MSSA and MRSA in Ocular TRUST

Methicillin-sensitive  
*Staphylococcus aureus* (MSSA)

Methicillin-resistant  
*Staphylococcus aureus* (MRSA)

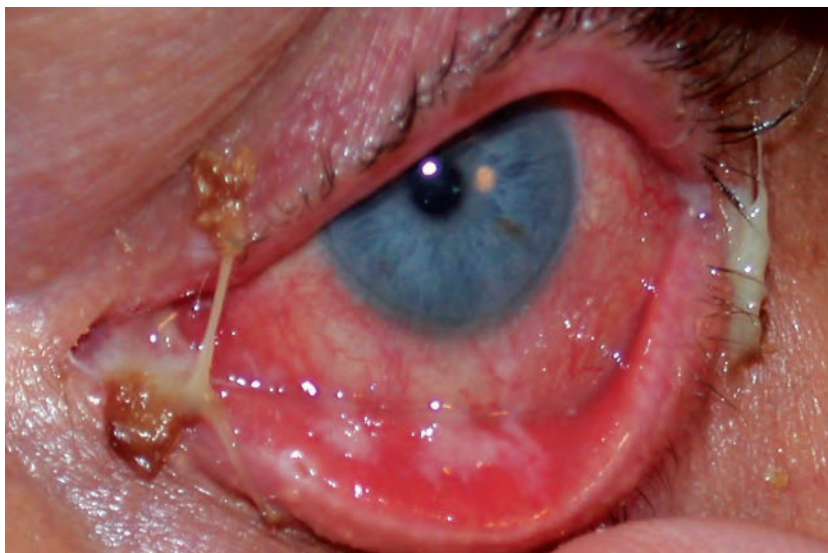

McDonnell PJ, Sahn DF. Longitudinal nationwide surveillance of antimicrobial susceptibility in ocular isolates (Ocular TRUST 2). Presented at the American Academy of Ophthalmology 2007 annual meeting, New Orleans, November 10-13, Poster P0052.

## ***Staphylococcus Aureus* Endophthalmitis: Antibiotic Susceptibilities, Methicillin Resistance, and Clinical Outcomes**

“Conclusions: Although all MSSA and MRSA isolates were sensitive to vancomycin, fewer than half of MRSA isolates were sensitive to the fourth-generation fluoroquinolones. Visual acuity outcomes between MRSA and MSSA eyes were not significantly different.”

Major JC Jr, Engelbert M, Flynn HW Jr, et al. *Staphylococcus aureus* endophthalmitis: antibiotic susceptibilities, methicillin resistance, and clinical outcomes. *Am J Ophthalmol.* 2010 Feb;149(2):278-283.



**For mucopurulent conjunctivitis (including MRSA infection), several topical antibiotic options are currently available. Trimethoprim, in particular, has demonstrated significant activity against MRSA, as shown in the Ocular TRUST study.**

sometimes put up quite a fight over the instillation of eyedrops! If eyedrop instillation is just not possible, then Polysporin ointment would be

a good alternative.

## Sodium Sulfacetamide

Bacteria synthesize folic acid

from para-aminobenzoic acid (or PABA). Folic acid is a necessary component for normal cell physiology. Sulfa drugs, which are bacteriostatic, inhibit the production of folic acid. Because sulfa drugs are chemically similar to PABA, competitive inhibition of folic acid production occurs, thus resulting in bacterial eradication.

Sulfas do not work well in infections that produce copious amounts of purulent exudate, probably because there is much PABA in these discharges, and thus tend to negate the drug's mechanism of PABA competition. Also, many patients are allergic to sulfa drugs. For these reasons, sulfa drugs, once a mainstay of treatment, are now poor choices. Much more effective are trimethoprim with polymyxin B, an aminoglycoside, or besifloxacin.

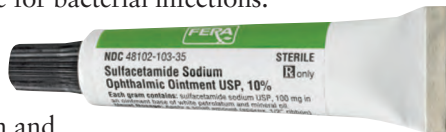
Most childhood bacterial infections are caused by *Streptococcus pneumoniae* or *Staph.* species, and 10% sodium sulfacetamide may not be effective against these pathogens. Though sulfas are broad-spectrum drugs, a large percentage of commonly encountered staphylococcal organisms are resistant to



them, as are most *Pseudomonas* species.<sup>6</sup> This is why Polytrim or AzaSite remain our choices for children who will accept eyedrops.

Sulfa drugs are rarely used in contemporary eye care; perhaps in a few more years they may recycle into effective chemotherapeutic agents. For now, they are not drugs-of-choice for bacterial infections.

Sodium sulfacetamide is available as a 10% solution and ointment. It is marketed by numerous companies.



## Trimethoprim

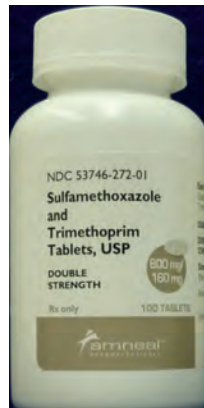
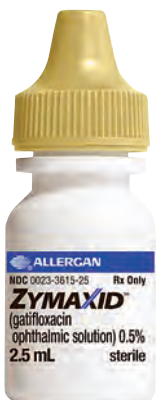Trimethoprim, sort of like bacitracin, is superb against gram-positive bacteria. However, in order to have a truly broad-spectrum antibiotic, adding polymyxin B to either of these medicines allows for effective treatment of gram-negative bacteria as well. Trimethoprim, while bacteriostatic, is still a drug-of-choice for treating MRSA species.<sup>3</sup> Of note, trimethoprim is not a sulfa-based drug.

Originally marketed as Polytrim (Allergan), trimethoprim is a very inexpensive drug that is a major player in ocular antibiosis. The Ocular TRUST study has shown trimethoprim to be substantially more efficacious than the fluoroquinolones in treating staphylococcal species. It is available as a 10mL ophthalmic solution.

As a side note, the generic oral medicine trimethoprim/sulfamethoxazole (known by the original brand names of Bactrim and Septra) is a drug-of-choice for the treatment of systemic MRSA infections.<sup>7</sup>

## Fluoroquinolones

Most eye doctors still think of the fluoroquinolone class of antibiotics as the “big guns,” when the peer-reviewed literature shows the sun setting on them. (Could it be that no one reads the lit-



## Topical Antibiotics in Perspective

• “In an era where products are heavily advertised by pharmaceutical companies, it is sometimes difficult to separate peer-reviewed scientific studies from promotional literature printed by the drug manufacturer.”

- “The fourth-generation fluoroquinolones demonstrated an in vitro efficacy of less than 80%.”
- “Many organisms, especially coagulase-negative staphylococci, are commonly resistant to the fourth-generation fluoroquinolones, which are the most popular topical antibiotics used in ophthalmology today.”

Scott IU, Flynn HW Jr. The role of topical antibiotic prophylaxis for intravitreal injections. Arch Ophthalmol. 2007 Jul;125(7):974-6.

## Surgical Perspective on Besifloxacin

“Preoperative treatment with povidone-iodine is now more important than ever. I still think that topical fluoroquinolones are our best option for surgical prophylaxis and also for treating post-surgical infections. But now I rely almost exclusively on besifloxacin, because ARMOR has demonstrated that it is the most effective of the fluoroquinolones against resistant organisms, particularly MRSA.”

McDonald MB. Antibiotic Resistance and Day-To-Day Practice. Refractive Eyecare, September 2011.

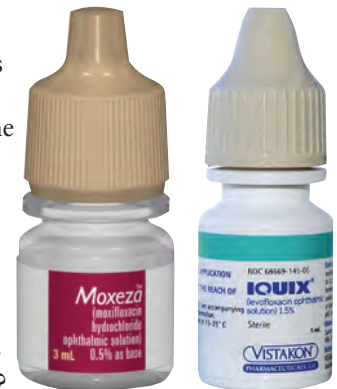## Besifloxacin and the ARMOR Study

“The ARMOR Study generally found besifloxacin—the newest ocular fluoroquinolone and the only one never to have been used in systemic or animal applications—to have lower MICs against MRSE and MRSA organisms compared to other current-generation fluoroquinolones.”

Donnenfeld ED. Cataract Surgery: Treat All Patients as if They Were Colonized by Resistant Bacteria. Refractive Eyecare, October 2011.

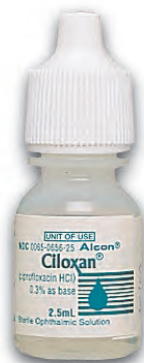erature?) For well over a decade, fluoroquinolones were indeed the “knights in shining armor,” but the armor has rusted from gross over-prescribing.

Remember years ago how we were told that because of “dual mechanisms” of action, resistance to the fluoroquinolones would be very rare?



# Antibiotics

Well, resistance has become a major problem, according to the evidence cited in the peer-reviewed journals. (See “*Staphylococcus Aureus Endophthalmitis*,” page 26A.) While it is possible that the high concentrations of topical antibiotics overwhelm some resistant species, such overpowering is not a guarantee of clinical success. Although these drugs still work well for conjunctivitis, we would be wary to use them (without culture and sensitivities) in the treatment of microbial keratitis.

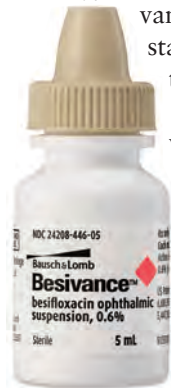


## Chlorofluoroquinolones

The only representative of this class is besifloxacin, a 0.6% ophthalmic suspension marketed as Besivance (Bausch + Lomb). For several years, we had the Ocular TRUST study to guide our prescribing, and now, more recently we have the ARMOR (Antibiotic Resistance Monitoring in Ocular microorganisms) study.<sup>4</sup> The research from this newer study showcases the antimicrobial prowess of besifloxacin, which is a bi-halogenated quinolone. As can be seen, it has MIC<sub>90</sub> effectiveness at the level of

vancomycin (the gold standard of gram-positive medicines).

Besivance has a very thick consistency, much like AzaSite, as they both contain the DuraSite vehicle. Be sure to advise patients that when instilling these thicker drops (Zirgan included), to wait at least five seconds before blinking to allow the medicine to spread out on the ocu-



## 2009 ARMOR Surveillance

All *S. aureus* (n=200)

Antibiotic	MIC Range	MIC <sub>50</sub>	MIC <sub>90</sub>
Vancomycin	0.25 – 2	0.5	1
Besifloxacin	≤0.008 – 4	0.03	1
Moxifloxacin	≤0.008 – 64	0.06	8
Ciprofloxacin	≤0.06 – 256	0.5	256
Tobramycin	≤0.06 – >256	0.5	256
Azithromycin	≤0.25 – >512	128	>512

- 39% of ocular *S. aureus* isolates were MRSA
- 38% of ocular *S. aureus* isolates were FQ-resistant

% resistance based on oxacillin and ciprofloxacin breakpoints.

Haas et al. Presented at ARVO, Fort Lauderdale, FL, May 2-6, 2010. Abstract #D965.

## ARMOR Study Methodology

“Two things—the strength of ARMOR’s methodology and the number of isolates tested—make it an extremely trustworthy study.”

“Among the fluoroquinolones tested, besifloxacin proved to be the most potent against staphylococci, particularly ciprofloxacin-resistant staphylococci; it was followed by moxifloxacin and gatifloxacin.”

McDonald MB. Antibiotic Resistance and Day-To-Day Practice. Refractive EyeCare, September 2011.

lar surface, or the blink may push some of the drop out of the eye.

In closing our discussion of topical antibiotics, gentamicin, trimethoprim, besifloxacin and vancomycin represent the four known (that is, studied) products that have good activity against MRSA bacteria. Numerous products are available on the market that may or may not be highly effective for any given clinical situation at hand.

In our practices, we generally stick with gentamicin, tobramycin, trimethoprim with polymyxin B, or besifloxacin for most patients with bacterial infection, most of the time. ■

1. Ta CN, Chang RT, Singh K, et al. Antibiotic resistance patterns of ocular bacterial flora: a prospective study of patients undergoing anterior segment surgery. *Ophthalmology*. 2003 Oct;110(10):1946-51.
2. Deramo VA, Lai JC, Winokur J, Luchs J, Udell IJ. Visual outcome and bacterial sensitivity after methicillin-resistant *Staphylococcus aureus*-associated acute endophthalmitis. *Am J Ophthalmol*. 2008 Mar;145(3):413-417.
3. Asbell PA, Colby KA, Deng S, et al. Ocular TRUST: Nationwide antimicrobial susceptibility patterns in ocular isolates. *Am J Ophthalmol*. 2008 Jun;145(6):951-958.
4. Haas W, Pillar CM, Torres M, et al. Monitoring antibiotic resistance in ocular microorganisms: results from the Antibiotic Resistance Monitoring in Ocular microorganisms (ARMOR) 2009 surveillance study. *Am J Ophthalmol*. 2011 Oct;152(4):567-574.
5. Karlowsky JA, Thornsberry C, Jones ME, et al; TRUST Surveillance Program. Factors associated with relative rates of antimicrobial resistance among *Streptococcus pneumoniae* in the United States: results from the TRUST Surveillance Program (1998-2002). *Clin Infect Dis*. 2003 Apr 15;36(8):963-70.
6. Fougere. Sulfacetamide Sodium Ophthalmic Ointment USP 10% package insert. Melville, NY.
7. Diaz E, Fernandez IM, Jimenez L, Rodriguez M, Surani S. Is methicillin-resistant *Staphylococcus aureus* pneumonia epidemiology and sensitivity changing? *Am J Med Sci*. 2012 Mar;343(3):196-8.

# Combination Drugs

With an intact epithelium, we almost always use a topical steroid. When there is significant corneal epithelial compromise, we almost always use a combination drug.

This class of prescription antibiotic-steroid drugs is highly useful and rivals the pure topical corticosteroids in the treatment of the acute red eye. As with most drugs, there are clear indications and clear contraindications, with a large gray zone in between.

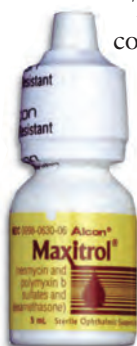In order to prescribe a combination drug with impeccable clinical skill, one has to have a masterful understanding of both antibiotics and corticosteroids. Looking at combination drugs, three varieties stand out:

- Combining neomycin/polymyxin B with dexamethasone.
- Combining tobramycin with dexamethasone.
- Combining tobramycin with loteprednol.

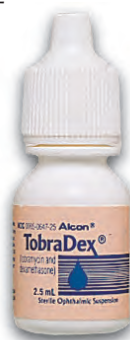Let's look at each, in turn.

The first highly effective combination antibiotic/corticosteroid blockbuster was Maxitrol, containing neomycin, polymyxin B and dexamethasone. Maxitrol became a real workhorse in primary eye care. However, the occasional neomycin reaction, while not a

major issue, prompted investigation into a "new and improved" combination drug.

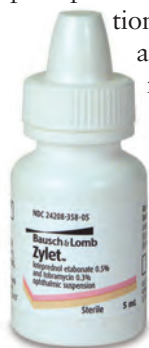

Thus was born Tobradex, which replaced the neomycin and polymyxin B with tobramycin. This drug, like Maxitrol, enjoyed market dominance, though from time to time, and again not a major issue, intraocular pressure increases prompted an investigation into a "new



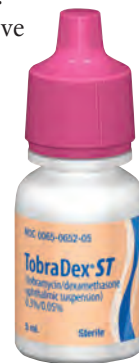and improved" combination drug.

Thus was born Zylet. Keeping the highly efficacious tobramycin, the dexamethasone was replaced with a new-generation, ester-



based corticosteroid, loteprednol. Now with Zylet, we have excellent antibiotics along with the safety and potency of loteprednol.

More recently we have Tobradex ST, which contains the same concentration of tobramycin (0.3%) but half of the dexamethasone (0.05%) of the original Tobradex. The vehicle of Tobradex ST contains xanthan gum, a thickening agent that allows the lower concentration of the medication to be as effective because it provides a longer residence time on the ocular surface. Indeed, at least one head-to-head study has shown that Tobradex ST has greater in

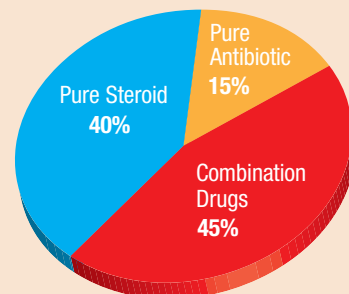


## Drug Class Selection in Treating the Acute Red Eye

If we constructed a pie chart to anecdotally depict the prevalence of eye diseases meriting the use of these three drug classes in our practices, it would look something like this. Obviously, the actual usage of these drug classes varies depending upon the character of each individual practice.

This chart suggests two clinical realities:

- The need for topical antibiotics alone is relatively low.
- Almost all acute red eyes are inflammatory in nature.



# Combination Drugs

vitro bactericidal activity and higher relative tissue concentrations for the conjunctiva, cornea and aqueous humor compared to TobraDex.<sup>1</sup>

There are numerous antibiotic-steroid drugs. However, these three are by far the most common ones we prescribe.

## Steroid vs. Combination

So, how does the astute clinician choose between a pure steroid and a combination drug? The answer is relatively straightforward but, as always, there are exceptions to generalizations.

The pivotal issue is the integrity of the corneal epithelium. If the corneal epithelium is intact, there is little or no reason to prophylax against opportunistic bacterial pathogens. This is because an intact epithelium is a virtual firewall of defense in and of itself. If there is significant epithelial compromise, then a combination drug may perfectly match the clinical need of inflammation suppression while simultaneously protecting against bacterial infection.

The clinician must remember that the eye(s) will be inflamed in any patient presenting with an acute red eye of any etiology. Simply put, the eye is red because it is inflamed. There are many dozens of common reasons why the conjunctiva may become inflamed. Also, the conjunctiva will be inflamed in almost all cases where keratitis is present.

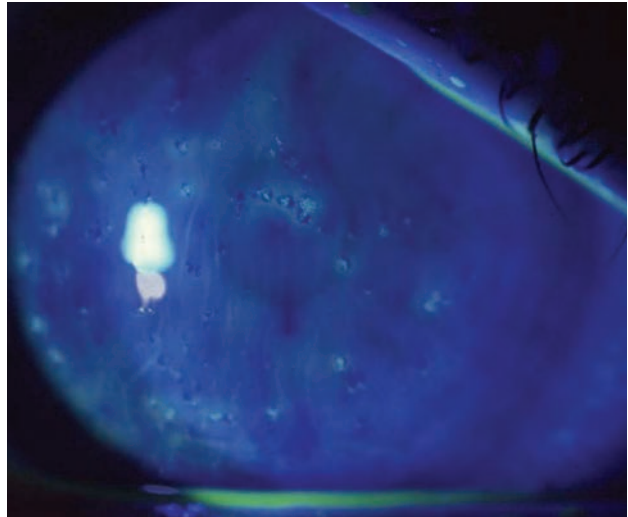
With either keratitis (with an intact epithelium) or conjunctivitis, we almost always use a topical steroid. In either instance, when there is significant corneal epithelial compromise, we almost always use a combi-

nation drug. For most cases, the choice of drug class is that simple.

With this in mind, let's look at a few specific clinical entities.

## Thygeson's Superficial Punctate Keratopathy (SPK)

This not-so-uncommon keratitis is seen in young to middle-aged patients. The classic symptoms are foreign body sensation, photophobia and lacrimation. This idiopathic condition has cycles of exacerbation and remissions over the course of 10 to 20 years, until it finally abates. It is during these exacerbations when symptoms prompt the patient to seek medical attention.



Thygeson's superficial punctate keratopathy.

## Corticosteroid/Antibiotic Combination Drugs

BRAND NAME	MANUFACTURER	STEROID	ANTIBIOTIC	PREPARATION	BOTTLE/TUBE
Blephamide *	Allergan	prednisolone acetate 0.2%	sodium sulfacetamide 10%	susp./ung.	5ml, 10ml/3.5g
Cortisporin *	Monarch	hydrocortisone 1%	neomycin 0.35%, polymyxin B 10,000u/ml	suspension	7.5ml
Maxitrol *	Alcon	dexamethasone 0.1%	neomycin 0.35%, polymyxin B 10,000u/ml	susp./ung.	5ml/3.5g
Poly-Pred	Allergan	prednisolone acetate 1%	neomycin 0.35%, polymyxin B 10,000u/ml	suspension	5ml, 10ml
Pred-G	Allergan	prednisolone acetate 1%	gentamicin 0.3%	susp./ung.	10ml/3.5g
TobraDex *	Alcon	dexamethasone 0.1%	tobramycin 0.3%	susp./ung.	5ml/3.5g
TobraDex ST	Alcon	dexamethasone 0.05%	tobramycin 0.3%	suspension	2.5ml, 5ml, 10ml
Zylet	Bausch + Lomb	loteprednol 0.5%	tobramycin 0.3%	suspension	5ml, 10ml

**PREGNANCY CATEGORY:** All drugs listed above are Category C.

\* = also available generically.

This usually bilateral keratitis shows several tiny, usually central, subtle (but readily seen) staining defects with fluorescein dye.

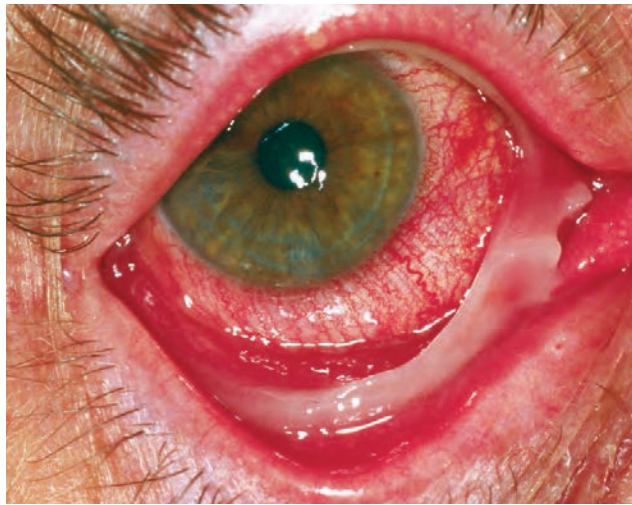If the patient is significantly symptomatic, a topical corticosteroid readily suppresses the keratitis and its attendant symptoms. If the presenting symptoms are tolerable, then artificial tears and patient education are likely all that is needed. However, the teaching point here is that even though there is some punctate staining in acute Thygeson's SPK, all that is needed is a topical steroid. This is the uniform recommendation in authoritative textbooks.<sup>2</sup>

While higher concentrations of topical steroids are indicated in most inflammatory eye conditions, Thygeson's is exquisitely steroid sensitive. Therefore, our drug of choice in these cases is Alex (loteprednol 0.2%, Bausch + Lomb). We generally treat symptomatic patients q.i.d. for one week, then b.i.d. for one to four weeks, until the phase of exacerbation subsides. Artificial tears complement virtually all acute ocular surface conditions, but there is no need for an antibiotic.

## Epidemic Keratoconjunctivitis (EKC)

If the EKC is severe, and especially if tarsal conjunctival membranes have formed, there can be epithelial compromise. The key here is to physically peel away these membranes, as they exert toxic and mechanical trauma to the epithelium. Be sure to wear gloves when performing this procedure, as minor bleeding often results.

These membranes are a marker



**Epidemic keratoconjunctivitis.**

of intense inflammation, and as such, corticosteroid therapy is of paramount importance. We generally use Lotemax (loteprednol 0.5%, Bausch + Lomb) q.i.d. for a week. By the end of this period, natural healing will likely have occurred and the steroid can be stopped, or tapered to b.i.d. for a few more days. While a combination drug, such as Zylet, Tobradex or generic Maxitrol, could be used here, we almost always use a pure topical steroid. Aminoglycoside toxicity on an already toxic ocular surface is probably not a practical concern, but could be in instances in which the patient has concurrent dry eye.

In many advanced cases of EKC, subepithelial infiltrates (which do not stain) can develop. When these cause symptomatic, visual compromise, a steroid will readily clear this unique, immune keratitis. This generally requires two to four months of tapering therapy. Our routine has been to use Lotemax q.i.d. for one month, t.i.d. for one month, b.i.d. for one month, and then once daily for one month. In our clinical experience, it usually takes two to four months for sufficient viral

antigen to be physiologically leached from stromal residence. So when the steroid taper is completed, any small infiltrates that might reform should be symptomatically minimal, or silent.

Of note, antibiotics and combination drugs have little or no role in treating patients with adenoviral infections because concurrent bacterial infection is exceedingly rare.

For several years now, we have successfully treated symptomatic patients with acute, grade 3 or higher EKC with a 60- to 90-second treatment of Betadine 5% Sterile Ophthalmic Prep Solution (povidone/iodine, Alcon) followed by ocular surface lavage. (For mild to moderate expressions of EKC, we treat with Zirgan five times daily for one week). This accomplishes two objectives. First, eradication of the bulk of the adenoviral load hastens acute symptomatic recovery. Second, since the virus particles' residence time has been considerably truncated, the potential for viral antigenic (stromal immune) keratitis is largely preempted.<sup>3</sup> Note: because Betadine stings, always pre-treat the cornea with a drop of proparacaine.

Following the in-office treatment as described above, we always prescribe a potent steroid, usually q.i.d. for four to six days, to dampen or eliminate any residual inflammatory keratoconjunctivitis.

Note: if patients present early in the disease process, then either Betadine 5% or Zirgan can be used because this is during the acute infectious phase. However, if patients delay in seeking care (perhaps after

# Combination Drugs

a week to 10 days), the infectious phase has likely passed, and now the clinical presentation is one of inflammatory sequelae, and corticosteroid suppression is now the most appropriate intervention.

## Herpes Simplex Keratitis

Here is another condition in which considerable epithelial compromise is commonly seen. Since corticosteroids cause local immunosuppression, their use is

contraindicated, an exceedingly well-known principle. No authoritative textbook recommends the use of a prophylactic antibacterial agent in such cases. As clinicians, we do not know why the herpetic

## Contact Lens-Associated Keratitis

Confusion abounds in eye care regarding the diagnosis and treatment of contact lens-related keratitis, although in most cases these clinical presentations are rather straightforward.

Of course, our greatest concern is vision loss from a central bacterial corneal ulcer. The good news is that such ulcers are exceedingly rare. The problem, however, is threefold:

- (1) Corneal infiltrates are quite common occurrences;
- (2) There is a lot of uncertainty among eye doctors as to the differentiation of corneal lesions; and
- (3) The ever-looming concern, "Is this the beginning of a potentially vision-threatening ulcerative process?"

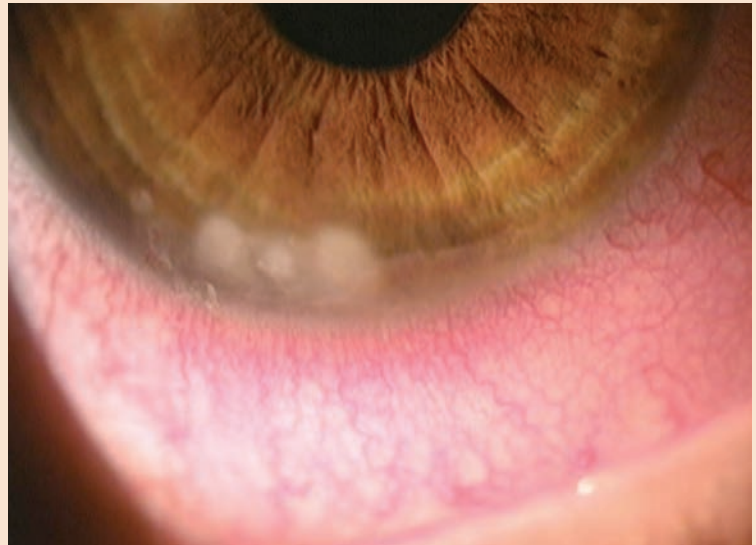
This last point is particularly worrisome when a positive epithelial defect is present.

Any number of stimuli can cause a cascade of events that may ultimately lead to leukocytic chemotaxis into the anterior stromal tissues. Once ample leukocytic recruitment occurs, exocytotoxic chemical mediators can lead to retrograde demise of some of the overlying epithelium as indicated by a relatively small positive fluorescein staining defect. It is these circumstances that lead many doctors to erroneously assume the worst and start the patient on a course of topical antibiotics. While this does no harm, it does no more good than simply discontinuing the use of the contact lenses, which of course, is the first step in treatment for all contact lens-related eye problems.

A steroid, in combination with an antibiotic, is perfectly suited to suppress the immune/inflammatory response, while protecting the cornea against any opportunistic bacterial infection.

If you truly feel your patient has an infectious lesion, then start him/her on besifloxacin, or generic Polytrim, or gentamicin every 15 minutes for three to six hours, then hourly until bedtime. We have our patients instill generic Polysporin (or Neosporin) ointment at bedtime. Follow the patient daily and modify therapy based on the clinical response.

There is a less intensive approach that can be used if you think your patient has a leukocytic infiltrate, but are still concerned about possible infection. Here, use one of the above-cited antibiotics hourly until the patient is seen back the next day to assess the clinical course.

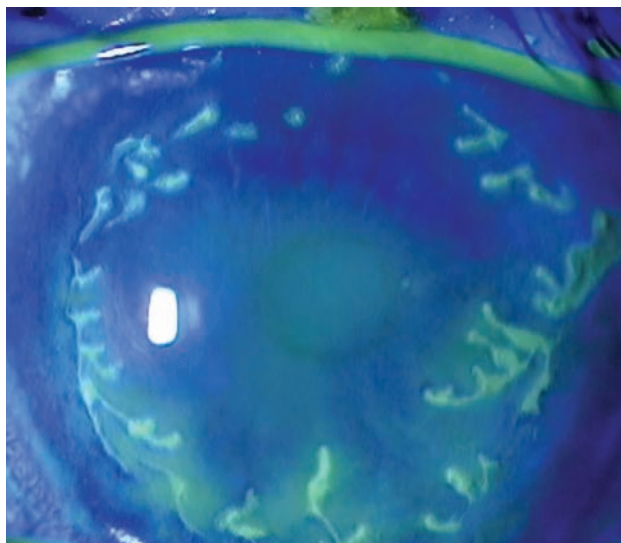


In either diagnostic circumstance (bacterial infection or leukocytic infiltration), improvement will most always be evident, mainly because lens wear has been discontinued. Naïve practitioners who prescribe an antibiotic and then witness improvement may wrongly deduce that the lesion must have been an infective process, and be glad they used an antibiotic. Once again, infiltrates are very common, and bacterial keratitis is very rare.

The most appropriate therapeutic response to an immune/inflammatory condition (e.g., a leukocytic/sterile infiltrate) is a steroid. Since a small epithelial defect may or may not be present, or clinical judgment may be wrong (if the lesion actually is an early infectious disease process), we always prescribe an antibiotic/steroid combination drug, such as Zylet, TobraDex or generic Maxitrol, to treat these conditions. To this day, aminoglycosides remain excellent broad-spectrum bacterial antibiotics, and have been proven to be superior to fluoroquinolones in treating common *Staph.* pathogens. (See "Topical Antibiotics," page 2A.)

Prescribe the combination drug to be used q2h for two days, then q.i.d. for four days (mainly to quiet the inflammation and allow the eye to calm down).

Each doctor must evaluate each patient's condition carefully and prescribe with as much clinical skill as possible. As stated at the outset, treatment of contact lens-associated keratitis is rather straightforward in most cases. In ambiguous cases, treat conservatively until the diagnosis becomes clear.



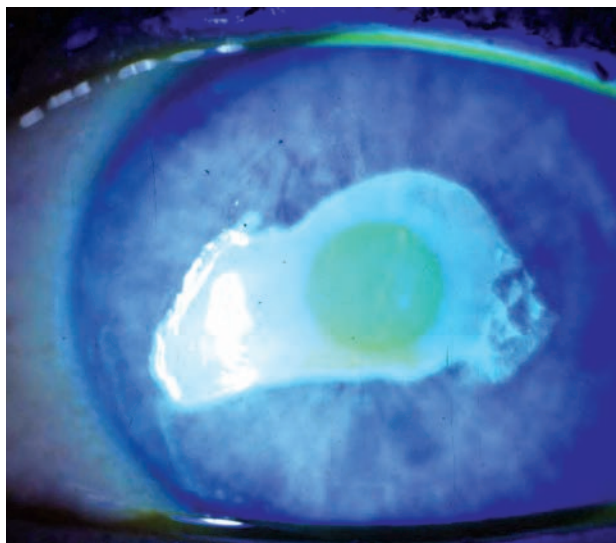
**Classic herpes simplex keratitis.**

corneal defect does not invite opportunistic bacterial pathogens; we just know that antibacterial therapeutic intervention is rarely indicated.

Topical (or oral) antiviral therapy, perhaps in conjunction with a premium-quality artificial tear, is the only therapeutic intervention warranted for herpes simplex epithelial keratitis. So, we now initiate therapy with Zirgan (ganciclovir gel, Bausch + Lomb) five times a day for seven to 10 days.

### Corneal Abrasions

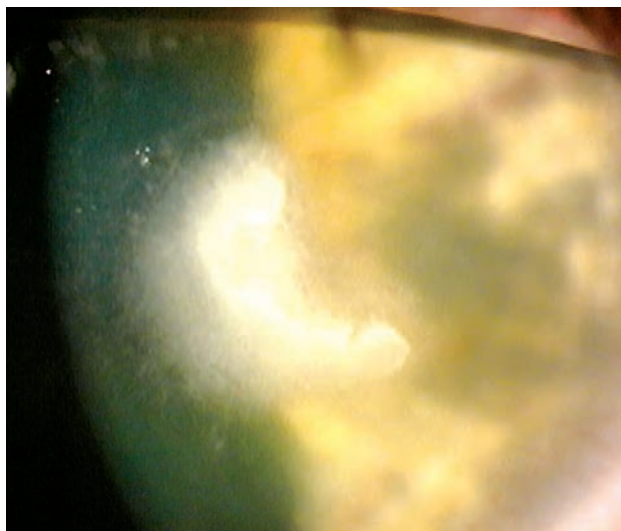
Most such defects heal within a day or two, regardless of any therapeutic maneuvers. To our knowledge,



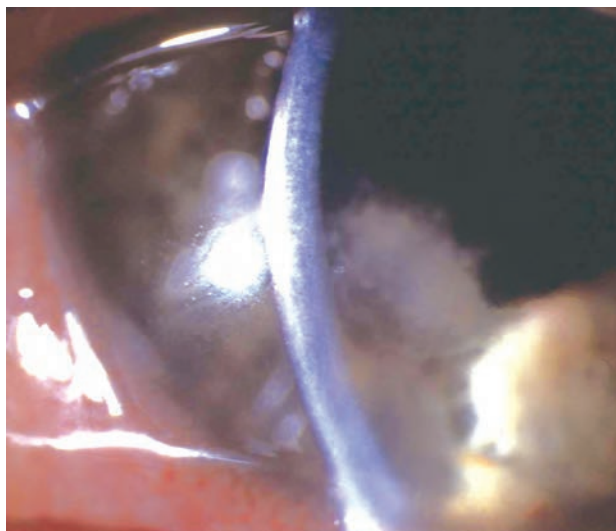
**Corneal abrasion.**

no studies have prospectively followed “no treatment” of abrasions, but it would be interesting to know the absolute need for prophylactic antibiotic use, which is common practice in these situations. We imagine the rate of infectious keratitis would be very small. However, since antibiotics are safe, there is no mandate to take chances.

Conservative therapy with antibiotics has evolved into the standard of care for corneal abrasions. There are, however, circumstances—most notably delay in seeking care—in which the abraded eye is considerably inflamed. While fungal infection is always a rare possibility if the traumatic agent was vegetative, 99.9% of



**Corneal abrasion and fungal keratitis. Note the feathery border.**



**Fungal keratitis—note the dirty-white infiltration.**

# Combination Drugs

the time fungal etiology is not the case.

That being said, we have occasionally used a short-acting cycloplegic agent and a combination drug in “hot” eyes with corneal abrasions. The steroid component calms the tissues and thus potentiates corneal re-epithelialization, in our experience. A further note for the fungal worriers out there: If the delay in seeking care is two to four days, fungal involvement at this point is unlikely because fungi are usually slow growing and would take many more days to proliferate to symptomatic proportions.

Now, if the patient gives a history of vegetative trauma, and reports that the abrasion initially healed up after a day or two, but is now (perhaps a week later) presenting with a hot eye and stromal infiltrates, consider fungal etiology. However, such symptoms are still most likely associated with a cell-mediated immune response to the initial trauma, rather than a fungal infection. The salient features of a fungal keratitis are:

- History of corneal injury (vegetative matter)

- Slowly progressive
- Hypopyon in advanced cases
- Not very painful (relatively)
- Feathery border (hyphate-like)
- Slightly raised, dirty-white infiltration

- Satellite lesions
- Partial or complete immune ring

For perspective, in our combined 60+ years of intense clinical experience, we have seen a grand total of six cases of fungal infection following corneal abrasion, which were treated successfully by corneal subspecialists.

If, however, the traumatic vector of the corneal abrasion was inorganic, and in the setting of marked inflammation, consider a combination product.

More conservatively, a pure antibiotic could be used for a day or two; if ocular surface inflammation occurs or fails to subside or if symptoms worsen, then add a steroid.

## Phlyctenular Keratoconjunctivitis (PKC)

More often seen in girls than in

boys, this staphylococcal hypersensitivity response commonly targets the limbal tissues as one or two raised whitish lesions, which stain lightly with fluorescein. Nothing else looks like a phlyctenule.

While one would think staphylococcal blepharitis would always be evident, such is not empirically the case. Certainly, if blepharitis is present, initiate proper care, but let’s treat the inflammatory keratoconjunctivitis first. When there is a staining defect at the corneolimbus, a prophylactic antibiotic is counterproductively conservative.

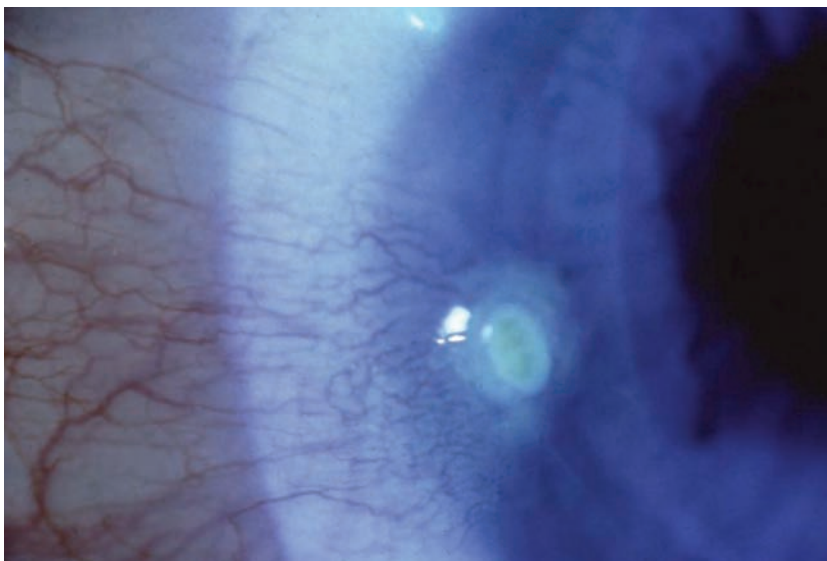
The key clinical feature is the inflammatory component—the eye is red. Here, a combination product is probably wise. Use a combination drug every two hours for a day or two, then q.i.d. for four to six days, and then stop.

## Peripheral Inflammatory Epithelial Defects (Staph. Marginal “Ulcers”)

These are uncommon events that have a similar pathophysiology to PKC. In these cases, the staphylococcal exotoxins begin to erode a section of the peripheral corneal epithelial tissues. The eye is red with accentuation of a sector of bulbar conjunctival inflammation adjacent to the affected cornea. The foci of compromised epithelium stains brightly with fluorescein dye. There may be a few cells in the anterior chamber. The epithelium stains as a secondary result of the anterior stromal inflammatory process.

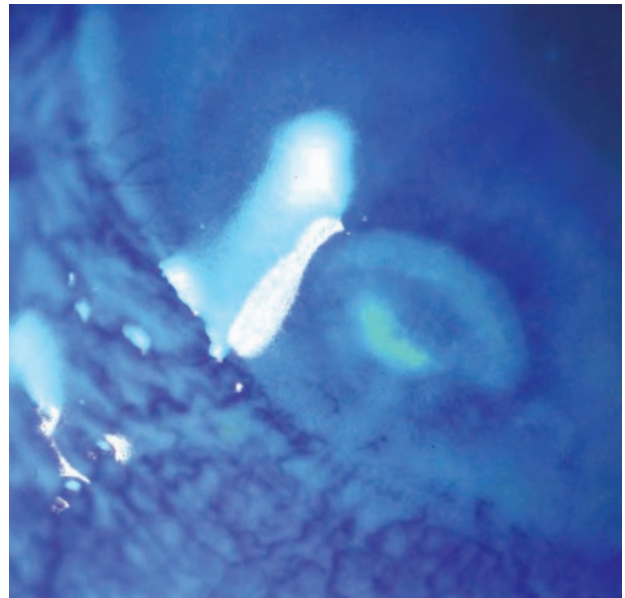
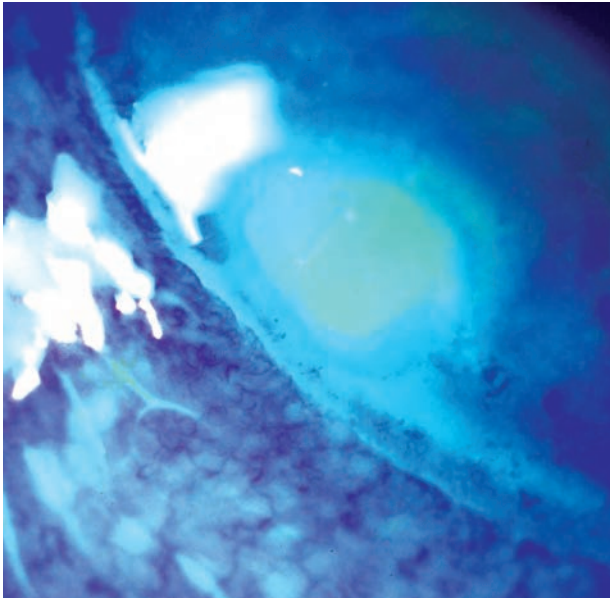
Once this subepithelial inflammation is subdued by the corticosteroid, re-epithelialization is potentiated.

An antibiotic alone in this case is almost worthless. While an antibiotic can serve to protect against bacterial opportunistic potential, it will do nothing to curb the inflam-



**Phlyctenular keratoconjunctivitis.**





**A “peripheral corneal ulcer”—The first photo was taken on the day of presentation. The follow-up photo is two days later after beginning Zylet q2h. This perfectly shows how vital steroid suppression is for these leukocytic infiltrates.**

matory process.

Therapeutic management is the same as described for PKC. As with PKC, a combination product is perfectly suited to address the inflammatory process while simultaneously guarding the cornea against the possibility of bacterial infection.

### Keratoconjunctivitis Sicca (KCS)

We have all seen dry eye patients with slit lamp-observable, coarse SPK. Also known as punctate epithelial erosions, SPK represents a break in epithelial integrity, which theoretically provides a foothold for

bacterial adherence and subsequent penetration. Yet, antibiotic intervention is rarely, if ever, indicated.

Acknowledging the participation of inflammation in the pathogenesis of many cases of dry eye-related SPK, we commonly employ topical steroid therapy (along with lipid-based artificial tears) in the successful management of KCS.<sup>4</sup> We have never read of an antibiotic role in the management of KCS.

In summary, select a pure antibiotic when the clinical picture is portrayed by evident mucopurulent

discharge or there is evident (or high risk for) corneal infection.

Select a combination drug in the absence of the above two findings, but there is mild to moderate epithelial compromise near the limbus along with considerable conjunctival inflammation.

Select a pure steroid if the eye is red and the corneal epithelium is intact.

We have discussed many exceptions to these general guidelines. The bottom line: Be aware that the cause of most red eyes is inflammatory in nature. ■

### Pearls For Using Combination Drugs

- Any time you see any round or oval-shaped process at or near the limbus, it is inflammatory in nature. Herpetic infection can present at this area, but it is usually linear (as opposed to oval) in morphology.
- In any acute, unilateral red eye with a serous discharge, be sure to rule out herpetic corneal lesions. Also, consider early adenoviral infection, especially if there is palpable lymphadenopathy on the initial or more involved side.
- In the context of a red eye with a mild secondary iritis, instill a short-acting cycloplegic agent, particularly if a pure antibiotic is used. A combination product will generally eliminate such an iritis without the need for a cycloplegic, though this is a fine clinical point.

1. Scoper SV, Kabat AG, Owen GR, et al. Ocular distribution, bactericidal activity and settling characteristics of TOBRADEX ST Ophthalmic Suspension compared with TOBRADEX Ophthalmic Suspension. *Adv Ther.* 2008 Feb;25(2):77-88.
2. Nagra PK, Rapuano CJ, Cohen EJ, Laibson PR. Thygeson's superficial punctate keratitis: ten years' experience. *Ophthalmology.* 2004 Jan;111(1):34-7.
3. Clement C, Capriotti JA, Kumar M, et al. Clinical and antiviral efficacy of an ophthalmic formulation of dexamethasone povidone-iodine in a rabbit model of adenoviral keratoconjunctivitis. *Invest Ophthalmol Vis Sci.* 2011 Jan 21;52(1):339-44.
4. Pflugfelder SC, Maskin SL, Anderson B, et al. A randomized, double-masked, placebo-controlled, multicenter comparison of loteprednol etabonate ophthalmic suspension, 0.5%, and placebo for treatment of keratoconjunctivitis sicca in patients with delayed tear clearance. *Am J Ophthalmol.* 2004 Sep;138(3):444-57.

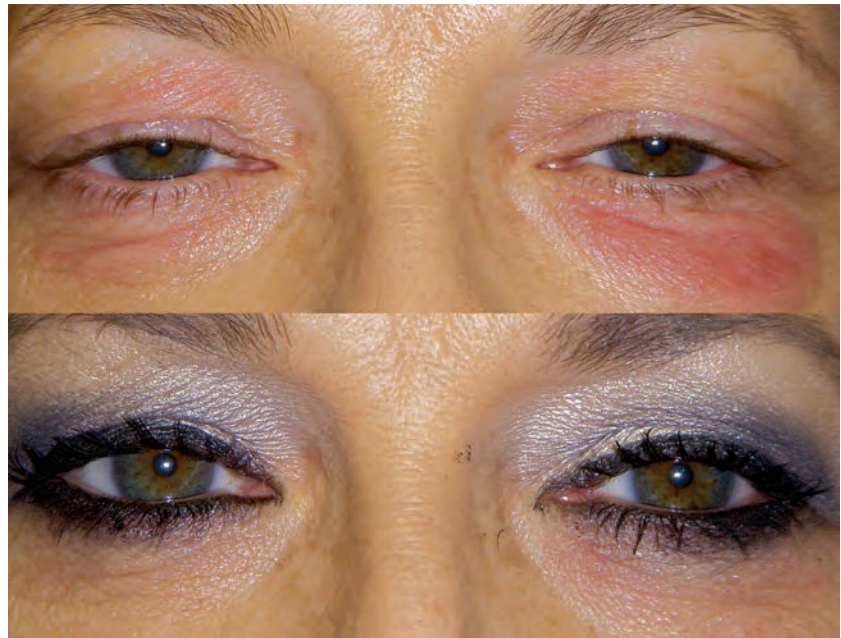# Corticosteroids

Without debate, this class of chemotherapeutic agents offers the greatest benefit to the vast majority of our patients with red eyes.

**M**ost cases of acute red eyes are inflammatory in nature. Even bacterial conjunctivitis, while primarily an infectious process, often exhibits significant secondary inflammation and may best be treated with a combination antibiotic-steroid. Because the treatment is usually less than a week in duration, it does not matter if the drop is a ketone- or ester-steroid combination.

Sterile infiltrative keratitis commonly exhibits a modicum of epithelial compromise, as evidenced by a small area of fluorescein staining (but relatively smaller than the underlying stromal leukocytic infiltrate). The use of a potent steroid will suppress the leukocytic infiltrate, and thus potentiate the healing of the overlying epithelial defect. We most often prescribe the steroid as a combination product with an antibiotic if there is an epithelial compromise.

In treating corneal inflammatory disease, as a general rule, if there is no breach in epithelial integrity, an antibiotic is not needed—just the steroid. Again, generally speaking, the subtype of steroid (ketone or ester) is immaterial when treating a condition for less than two weeks. However, if we anticipate using a



**This patient presented with red, itchy eyelid tissues. Three days of 0.1% triamcinolone cream used t.i.d. (along with her makeup!) had her looking good once again.**

steroid for longer than two weeks, we most always prescribe an ester-based corticosteroid.

When using a steroid, it is usually best to initiate therapy with frequent dosing (i.e., every one to two hours while the patient is awake), and only reduce the frequency of instillation once the inflammation has been largely controlled. While undertreatment can be done, it would be hard to over-treat—so be

aggressive initially, and then taper as indicated once the inflammation is under control.

Contrary to popular teaching, an epithelial defect is not a contraindication to the use of a steroid; but obviously, it depends upon the nature of the defect. For example, a curling iron burn to the eye merits corticosteroid suppression (usually with an antibiotic—largely for the benefit of the doctor!), whereas a

true corneal ulcer would best be treated with intensive, effective antibiotics. A steroid can be added in two to three days, once bacterial populations have been decimated (to diminish any secondary tissue inflammation).

Rarely is supplemental steroid ointment needed overnight. When treating severe uveitis or episcleritis, a steroid ointment may, on occasion, be employed, but these are unusual circumstances. There are two choices here: loteprednol or fluorometholone.

Now let's look at various topical therapies. There are roughly three categories: maximum strength, moderate strength and weak.

## Maximum Strength Steroid Options

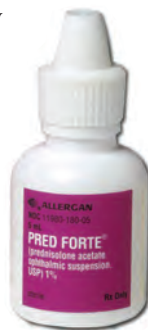Prednisolone, loteprednol, difluprednate, dexamethasone and rimexolone are highly efficacious corticosteroids. All of these drops perform about the same; however, there are some caveats that separate them. All are ketone-based steroids with the exception of loteprednol, which is ester-based. We try to avoid using ketone steroids long-

term because they have a propensity to raise the intraocular pressure. Because prednisolone and dexamethasone sodium phosphate are solutions, they require no shaking; neither does Durezol (difluprednate 0.05%, Alcon), even though it's an emulsion.

## Ketone-based steroids

- **Prednisolone** (acetate and sodium phosphate). Prednisolone acetate 1%, popularly known by its original brand name, Pred Forte (Allergan), has been a major workhorse for decades. It is an exquisite drug that works beautifully.

Unfortunately, Pred Forte is generically available and some pharmacists have demonstrated an insatiable behavior of dispensing the generic even when the brand name is prescribed. It is well accepted that generic Pred Forte is subpar; so although the generics are considerably less expensive, their performance is less effective.<sup>1</sup>



The acetate form is a suspension, and therefore must be shaken well. Generally speaking, suspensions are a high challenge to manufacture, whereas solutions are relatively easy to formulate.

Prednisolone sodium phosphate 1% (once known by its original brand name Inflammase Forte) is also available generically. As a solution, it does not require shaking, and it performs well. This is an excellent choice when a potent, relatively inexpensive steroid is needed, and may be an especially good choice for older people with arthropathies, for whom shaking a bottle can be a challenge.

As for the clinical use of ketone formulations, we do not recommend prescribing for beyond two weeks because of the accelerated risk of increased IOP and PSC cataract formation. Technically, the acetate formulations are known to have slightly enhanced intraocular penetration relative to the sodium phosphate formulations; but this may be a moot point when comparing these two generic formulations for the treatment of anterior uveitis.

While both the acetate and

## Topical Corticosteroid Drugs

BRAND NAME	GENERIC NAME	MANUFACTURER	PREPARATION	BOTTLE/TUBE
------------	--------------	--------------	-------------	-------------

### Maximum Strength Steroids

Durezol	difluprednate 0.05%	Alcon	emulsion	5ml
Lotemax	loteprednol etabonate 0.5%	Bausch + Lomb	suspension	5ml, 10ml, 15ml
Lotemax Ointment	loteprednol etabonate 0.5%	Bausch + Lomb	ointment	3.5g
Pred Forte, and generic	prednisolone acetate 1%	Allergan, and generic	suspension	5ml, 10ml, 15ml
generic	prednisolone sodium phosphate 1%	generic	solution	5ml, 10ml, 15ml
Vexol	rimexolone 1%	Alcon	suspension	5ml, 10ml

### Moderate and Lesser Strength Steroids

Alrex	loteprednol etabonate 0.5%	Bausch + Lomb	suspension	5ml, 10ml
Flarex, and generic	fluorometholone acetate 0.1%	Alcon	suspension	5ml, 10ml
FML, and generic	fluorometholone alcohol 0.1%	Allergan	suspension	5ml, 10ml, 15ml
FML S.O.P.	fluorometholone alcohol 0.1%	Allergan	ointment	3.5g
Pred Mild, and generic	prednisolone acetate 0.12%	Allergan	suspension	5ml, 10ml

## Difluprednate vs. Prednisolone Acetate

- “There is increased bioavailability and dose uniformity resulting from the formulation of difluprednate as an emulsion, rather than a suspension.”
- Steroid-induced hypertension is seen in 8% of the normal population, and is more common in patients with glaucoma.
- Steroid-induced hypertension is “generally not seen until three to six weeks of corticosteroid use.”
- “Difluprednate was shown to provide better results compared with prednisolone acetate... We believe the effects seen are the result of the greater anti-inflammatory potency of difluprednate.”

Donnenfeld ED, Holland EJ, Solomon KD, et al. A multicenter randomized controlled fellow eye trial of pulse-dosed difluprednate 0.05% versus prednisolone acetate 1% in cataract surgery. *Am J Ophthalmol.* 2011 Oct;152(4):609-617.

sodium phosphate varieties come in a 0.12% concentration in addition the 1% concentration, the 0.12% formulation has minimal clinical utility.

- **Difluprednate.** As a result of the relatively poor performance of the ubiquitous generic prednisolone acetate, in our experience, we have found Durezol to be our darling for treating uveitis and advanced cases of episcleritis. Durezol can be used with half the frequency of instillation as prednisolone formulations with equal

efficacy.<sup>2</sup> Durezol is available in a 5mL bottle (professional samples come in a four-unit foil pack of “unit-dose” vials).

While Durezol has been our favorite short-term, “high-powered” steroid, it can cause marked increases in IOP, especially in young people and children, so do be attentive and monitor the IOP at each follow-up visit. Other than this one thorn, Durezol is a fabulous rose.

- **Dexamethasone.** This product is similar to difluprednate in that it is potent and carries a somewhat higher risk for increased IOP. So, as with all ketone steroids, short-term

use is key to gaining maximum healing while minimizing the potential for unwanted side effects.

Dexamethasone is rarely used as monotherapy, but has been used in combination products for decades. The three best-known combination products in which dexamethasone is found are Maxitrol, TobraDex and TobraDex XT.

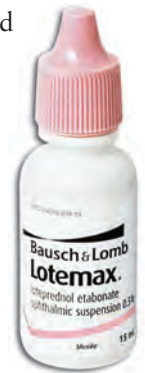Take note that all conditions for which a combination antibiotic-steroid is indicated are brief in clinical character, so use of a ketone steroid is reasonable.

The only remaining monotherapy dexamethasone product is Maxidex suspension (dexamethasone 1.0%, Alcon).

In situations when lower cost is critical for patients, we occasionally prescribe Maxitrol suspension as a means of getting the least expensive steroid, even though the antibiotic component is not needed. Maxitrol suspension costs about \$5, and sometimes that is all a patient can afford. We would really enjoy having steroid drop that is this inexpensive.

## Ester-based Steroid

- **Loteprednol.** This is the first and only ester-based corticosteroid formulation. While perhaps not as clinically effective as Pred Forte or Durezol, our estimate is that it is about 90% as effective. The best available evidence actually shows that Lotemax is as effective as Pred Forte for treatment of anterior uveitis, at least when measured head-to-head on a visit by visit basis.<sup>3</sup>



The “soft” steroid label refers only to its greatly enhanced safety profile when compared to the ketone class of steroids, not its therapeutic potency.

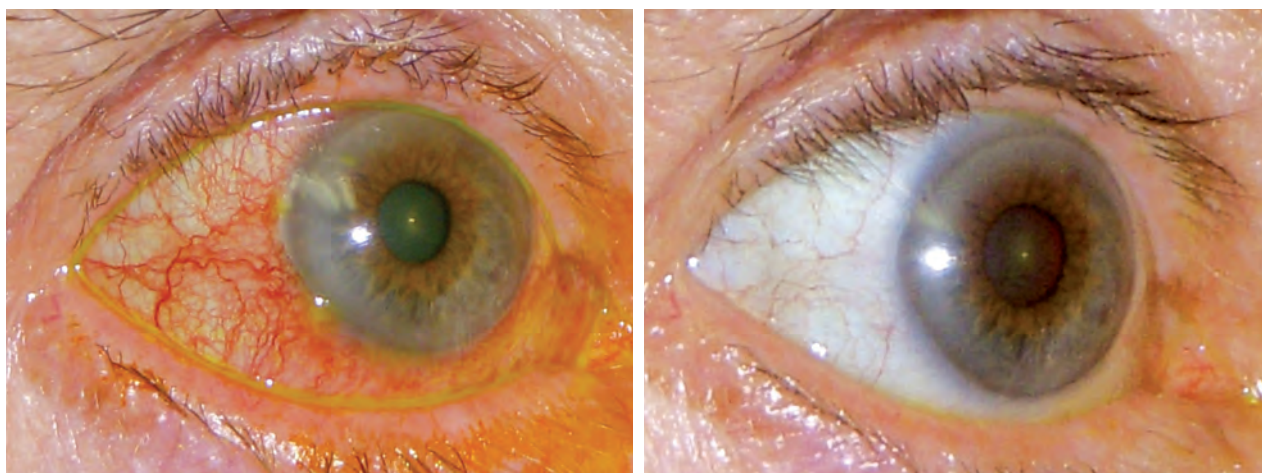
## Pulse Dosing of Corticosteroids

The management of many chronic inflammatory conditions is optimized (clinically and financially) using the concept of “pulse dosing.” In this manner, a patient may use a steroid q.i.d. for one to three weeks to gain initial control of the inflammatory component of a condition, and find relief for many weeks or even months. Then, should a flare-up or symptomatic awareness recur, repeat the q.i.d. pulse-dose for a week or two to regain control, etc.

The “pulse dose” technique is a highly effective, steroid-sparing, cost effective and patient-friendly way to gain and maintain control of most any chronic ocular surface inflammatory condition.

There are, however, some patients who may require daily instillation of a steroid. Clinical examples of such patients include those with corneal transplant, stromal-immune keratitis, chronic uveitis, etc. As always, patient care must be individualized.

Zeiger RS, Mauger D, Bacharier LB, et al; CARE Network of the National Heart, Lung, and Blood Institute. Daily or intermittent budesonide in preschool children with recurrent wheezing. *N Engl J Med.* 2011 Nov 24;365(21):1990-2001.



**Corneolimbus phlyctenular keratoconjunctivitis before and after using Lotemax q2h for two days, then q4h for four more days. The “after” photo was taken at a follow-up visit on the third day.**

Loteprednol comes in three formulations: 0.5% suspension, 0.2% suspension and the 0.5% preservative-free ophthalmic ointment. Other than cases of advanced uveitis or episcleritis, we most often prescribe the 0.5% loteprednol for most inflammatory conditions. This is especially true when treating any chronic conditions that typically last for more than two weeks.

We are especially pleased to have an ointment form of loteprednol available to us. With this modality, patients can enjoy having the inflammatory component (such as in postoperative care) of their condition addressed during the sleep cycle, which makes the daytime eyedrop schedule less onerous. We are also pleased that loteprednol ointment is a preservative-free formulation.

Because of the unique chemistry of loteprednol, tapering is not essential. We typically still taper the patient off the drug anyway, but only because we are creatures of habit.

### Moderate-Strength Corticosteroid Options

The moderate-strength corticosteroids are represented by the

fluorometholones. There are two subtypes, the alcohol (FML, Allergan) and the acetate (Flarex, Alcon). The acetate moiety gives the fluorometholone molecules some additional anti-inflammatory effectiveness over the alcohol moiety.<sup>4</sup>

The fluorometholone molecule is a fluorinated analog of progesterone. Fluorometholone ophthalmic comes in four varieties: 0.1% FML suspension, 0.25% FML Forte suspension, 0.1% Flarex and FML ointment. The 0.25% concentration is beyond the top of the dose-response curve (which is 0.1%) and because there is no additional anti-inflammatory effect, it has no role in clinical patient care.<sup>5</sup>

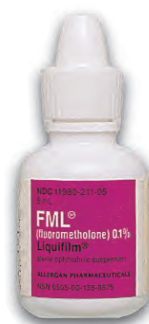FML is generic and thus reasonably inexpensive. While it has less tendency to increase intraocular pressure than the other ketone steroids, we are not nearly as comfortable using it long-term as we are with the ester-based loteprednol.

### Weak Corticosteroid Options

Lastly are the weaker corticoste-

roids of 0.2% or 0.25% prednisolone, and 0.2% loteprednol (Alrex, Bausch + Lomb). These are pretty much limited to the treatment of allergic conjunctivitis (where there are signs of inflammation accompanying symptomatic itch).

Another excellent use of such low-dose steroids is in the care of patients with Thygeson's SPK or for longer-term management of ocular surface inflammatory disease (dry eye). In both cases, we prefer the loteprednol because of its safety profile. ■



1. Roberts CW, Nelson PL. Comparative analysis of prednisolone acetate suspensions. *J Ocul Pharmacol Ther.* 2007 Apr;23(2):182-7.
2. Foster CS, Davanzo R, Flynn TE, et al. Durezol (difluprednate ophthalmic emulsion 0.05%) compared with Pred Forte 1% ophthalmic suspension in the treatment of endogenous anterior uveitis. *J Ocul Pharmacol Ther* 2010; 26:475-483.
3. Controlled evaluation of loteprednol etabonate and prednisolone acetate in the treatment of acute anterior uveitis. Loteprednol Etabonate US Uveitis Study Group. *Am J Ophthalmol.* 1999 May;127(5):537-44.
4. Leibowitz HM, Hyndiuk RA, Lindsey C, Rosenthal AL. Fluorometholone acetate: clinical evaluation in the treatment of external ocular inflammation. *Ann Ophthalmol.* 1984 Dec;16(12):1110-5.
5. Awan MA, Agarwal PK, Watson DG, et al. Penetration of topical and subconjunctival corticosteroids into human aqueous humour and its therapeutic significance. *Br J Ophthalmol.* 2009 Jun;93(6):708-13.

## Loteprednol Ophthalmic Ointment

The following select quotes are from a round table discussion on ocular inflammation offered by a group of expert ophthalmic surgeons and cornea specialists.<sup>1</sup>

“Originally, it was believed that steroids should not be used chronically. However, in many patients with chronic inflammation, long-term use of steroids is indicated and may be the only way to maintain visual function.”

“The mindset of ophthalmologists [and optometrists] should not be to avoid the side effects of steroids [the potential for IOP increases and cataract formation]; it should be to understand steroids and eliminate inflammation.”

“Loteprednol is a potent steroid, but it is associated with fewer and milder adverse events than expected based on its potency.”

As with all steroids, there is the potential to

exacerbate infectious processes and increase IOP. Approximately 2% of the general population receiving loteprednol had a high IOP increase (>10mm Hg), compared with about 7% using prednisolone or dexamethasone.<sup>2</sup> Among steroid responders, virtually all patients using loteprednol will have some increase in IOP, although the effect is much more muted compared with prednisolone or dexamethasone.<sup>3</sup> So monitor patients accordingly.

“In FDA trials, only one patient taking loteprednol 0.2% had a significant pressure spike, and the 0.2% concentration will effectively suppress inflammation for long-term management of chronic ocular surface disease.”

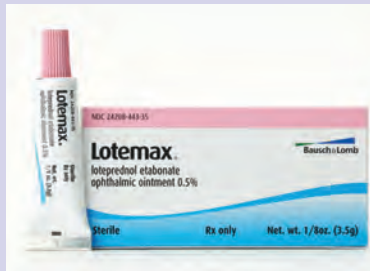“Regarding loteprednol ointment, the ideal treatment for managing the acute inflammation associated with tear dysfunction is a steroid that works mostly at the ocular surface, has a very manageable risk profile, yet has the bioavailability of an ointment. Loteprednol ointment will play an important role in treating the inflammatory nature of meibomian gland dysfunction and lid disease.”

“A steroid ointment would be extremely valuable in patients who have immune stromal keratitis from herpes simplex virus, or herpes zoster, who have a poor epithelial layer from the neurotrophic effect of the viral infection.”

Regarding the conjunctival injection associated with ocular surface disease, “a steroid ointment with a good safety profile for long-term use can treat underlying disease mechanisms and give the patient a better cosmetic result.”

“Periodic pulse-dosing may be required to control the inflammatory aspect of the disease process in some patients.”

“Patients who have significant inflammation often experience significant discomfort upon awakening despite steroid therapy



during the day; eyes that are closed overnight trap inflammatory mediators from the conjunctiva, lid margin and tear film. The addition of the loteprednol ointment extends steroid therapy overnight; patients subsequently feel more comfortable and are less inflamed upon awakening. I have used the ointment in this manner for patients with significant inflammation associated with blepharitis, specifically meibomian gland dysfunction.”

“For patients with blepharitis, if the ointment spills out onto the lid surface, I have them rub it into the lid because, with this ointment, we have the added benefit of being able to apply the drug into the lid tissue itself.”

The loteprednol ointment is comfortable and well-tolerated.<sup>4</sup>

“The significant anti-inflammatory effect of the ointment expedites healing and reduces inflammation, achieving superior surgical and medical response to therapy.”

“The ointment provides the strength of a potent steroid with the safety profile of loteprednol.”

### An Important Addition

In their article, “A New Pharmaceutical Tool,” in *Review of Cornea & Contact Lenses* (January/February 2012), Elyse Chaglasian, O.D., and Jill Autry, O.D., R.Ph., discussed the “on-label” use of loteprednol ophthalmic ointment:

- Its indication is to “treat inflammation and pain following (any type of) ocular surgery,” whereas the suspension formulation is “indicated for the treatment of steroid-responsive conditions of the palpebral and bulbar conjunctiva, cornea and anterior segment of the globe, as well as inflammation following ocular surgery.” It is our opinion that either formulation can be used interchangeably for any of these conditions. It just makes common sense.

- “It is the first preservative-free topical ophthalmic steroid preparation in the United States.” While largely unfounded, there is an over-exuberance regarding the use of preservative-free medicines, but for those who desire, or more importantly, for those patients who may benefit from a preservative-free steroid, loteprednol ointment should handily meet that need.

- Interestingly, of the approximately 400 patients using loteprednol ointment, three experienced an IOP increase of >10mm Hg, and one of the 400 did so in the vehicle group. “Lotemax ointment provides eyecare practitioners with a medication that has a proven track record that we can be confident in using on our postsurgical patients. For these reasons, it is an important addition to our pharmaceutical toolbox.”

1. Ophthalmic Care Strategies to Reduce Inflammation. Ocular Surgery News. 2011 Dec 10;29(23). Suppl. Available at: [www.healio.com/ophthalmology/cataract-surgery/news/online/%7B126809B9-7266-473B-969C-2A4DD88E33EC%7D/Ophthalmic-Care-Strategies-to-Reduce-Inflammation](http://www.healio.com/ophthalmology/cataract-surgery/news/online/%7B126809B9-7266-473B-969C-2A4DD88E33EC%7D/Ophthalmic-Care-Strategies-to-Reduce-Inflammation).

2. Novack GD, Howes J, Crockett R, et al. Change in intraocular pressure during long term use of loteprednol etabonate. *J Glaucoma* 1998; 7:266-269.

3. Bartlett J, Horwitz B, Laibovitz R, et al. Intraocular pressure response to loteprednol etabonate in known steroid responders. *J Ocul Pharmacol Ther* 1993; 9:157-165.

4. Comstock TL, Paterno MR, Singh A, Erb T, Davis E. Safety and efficacy of loteprednol etabonate ophthalmic ointment 0.5% for the treatment of inflammation and pain following cataract surgery. *Clin Ophthalmol*. 2011;5:177-86.

# 'Off-label' Use of Ophthalmic Medicines

The practice of off-label drug use is neither uncommon nor new. In many instances, off-label treatments may be the best, or the only, available treatment.

It is extremely important to have a firm understanding of the clinical implications of using FDA-approved medicines "off-label." This term denotes the use of a medicine for any purpose beyond its specific FDA-approved indications.


In 2010, the Alliance of Specialty Medicine released a position statement regarding off-label use of medical products.<sup>1</sup> It states in part: "Physician-directed applications, also known as 'off-label uses', are an integral component of the art and science of medical practice, particularly for specialty physicians."

"The Alliance of Specialty Medi-

cine recognizes that a specialty physician may prescribe or administer any legally marketed product for an off-label use within the authorized practice of medicine, where the physician exercises appropriate medical judgment, and it is in the best interest of the patient."

These physicians go on to say, "The FDA acknowledges that physicians may prescribe any legally marketed product for an off-label use, as long as it is in the best interest of the patient."

"We are limited as to what we can say in educational settings because of regulations surrounding



**Topamax is indicated for treating seizure disorders and the prevention of migraine headaches, yet is often used "off-label" to treat obesity, bipolar disorder and some forms of eating disorders.**

teaching on off-label medications. We must educate our colleagues the best we can within forums that allow us to discuss off-label usage."

"Off-label use is often the standard-of-care in the community. Not using medicines off-label could be considered malpractice in many circumstances."

## Off-Label Use of Drugs and Devices

"A drug or device becomes 'on-label', or approved, when a sponsor conducts a prospective multicenter clinical trial to show its safety and efficacy for a particular indication. Often these regulatory trials are of limited value, for several reasons. First, often the approved indication is of little value, whereas off-label indications are the primary use."

"Manufacturers often take the most direct route to an approval rather than demonstrating the best use of the product in a clinical trial. For example, topical ophthalmic antibiotics universally are approved only for the treatment of bacterial conjunctivitis, a self-limiting condition with little morbidity. However, their greatest value is in the treatment of bacterial keratitis and in prophylaxis after ophthalmic surgery. These applications are proven off-label uses. The use of these agents is entirely ethical."

Maloney RK. Off-label use of drugs and devices. [Correspondence]. Am J Ophthalmol. 2010 Jan;149(1):170.

## Our Brothers' Keepers

Within the guidelines and perspectives set forth above, we simply want our optometric colleagues to feel completely comfortable doing what is right to best serve their patients with FDA-approved medicines.

Drilling down to the ultimate foundation, remember that we are, in fact, our brothers' keepers.

## Aberration of Off-label Drug Use

Blepharitis is a chronic, usually staphylococcal-mediated, inflammatory affliction of the anterior eyelid tissues. Meibomian gland dysfunction by and large results from a keratinization of the acinar lining of the secretory glands with subsequent downstream glandular inflammation.

The treatment for blepharitis is meticulous eyelid hygiene, perhaps initially augmented with a drug that has demonstrated efficacy against staphylococcal species and possesses potent anti-inflammatory properties, such as Zylet, TobraDex or Maxitrol.<sup>1</sup>

The treatment of meibomian gland dysfunction is the aggressive application of heat followed by physical expression of these glands, perhaps augmented with oral doxycycline.<sup>2</sup>

Though heavily promoted to treat these conditions in an off-label fashion, topical azithromycin has poor anti-*Staph.* activity, as evidenced by the Ocular TRUST study.<sup>3</sup> And, has shown little to no clinically significant anti-inflammatory activity, as evidenced by this authoritative statement from the FDA, at right.


This is an excellent example where exuberant off-label promotion was likened to a house being built on sand.

It is important that any medical therapy have a sound scientific rationale. A careful read of scientific literature along with sound clinical judgment should steer decision-making in patient care.

## Letter from the FDA: Unsubstantiated Claims

An April 2011 letter from the FDA stated:

“The Journal Ad includes the claim, **“AzaSite® Can Restore a Healthy Ocular Surface By Delivering Significant Anti-Inflammatory and Antimicrobial Effects Directly to the Site of the Problem.”** (bolded emphasis in original; underlined emphasis added) This claim is misleading because it implies that AzaSite delivers anti-inflammatory effects, when this has not been demonstrated by substantial evidence or substantial clinical experience.”



1. White EM, Holland AR, MacDonald G. Comparison of the safety and efficacy of loteprednol 0.5%/tobramycin 0.3% with dexamethasone 0.1%/tobramycin 0.3% in the treatment of blepharokeratoconjunctivitis. *Biochemistry*. 2008 Jan 8;47(1):84-91.
2. Geerling G, Tauber J, Baudouin C, et al. The International Workshop on Meibomian Gland Dysfunction: Report of the subcommittee on management and treatment of meibomian gland dysfunction. *Invest Ophthalmol Vis Sci*. 2011 Mar 30;52(4):2050-64.
3. Asbell PA, Sahm DF, Shedden A. Ocular TRUST 3: Ongoing Longitudinal Surveillance of Antimicrobial Susceptibility in Ocular Isolates. Poster presented at annual ASCRS meeting, San Francisco; April 3-8, 2009.

## Perspective on ‘Off-Label’

“Treatment with any drug or therapy is based on a consensus between a well-informed patient and physician. This is no different in the case of the use of off-label ophthalmic medicines. The more scientifically sound the information supporting its use, the more confidently can the physician and patient assess the possible value of the proposed unapproved treatment.”

“The Ophthalmic Mutual Insurance Company recognizes that ‘off-label’ use of approved medications is a legal and necessary part of the practice of medicine.”

“The practice of ophthalmic off-label drug use is neither uncommon nor new.”

“The prevalence and clinical importance of prescribing drugs for unlabeled uses are substantial...thus the prescribing of drugs for unlabeled use is often necessary for optimal patient care.”

“Good medical practice and the best interests of the patient require that physicians use legally available drugs according to their best knowledge and judgment. If physicians use a product for an indication not in the approved labeling, they have the responsibility to be well informed about the product, to base its use on firm scientific rationale and on sound medical evidence, and to maintain records of the products’ use and effects.”

Parrish R 2nd, Sternberg P Jr. Does “off-label” mean off limits for patient care? *Am J Ophthalmol*. 2007 May;143(5):853-5.

## Off-Label Examples

An excellent systemic example of “off-label” use of a medicine is Topamax (topiramate, Janssen Pharmaceuticals). It is indicated for the treatment of seizure disorders and the prevention of migraine headaches, yet is often used “off-label” to treat obesity, bipolar disorder and some forms of eating disorders.

In the ophthalmic arena, moxifloxacin, gatifloxacin and besifloxacin are only approved for bacterial conjunctivitis, yet are excellent drugs for the treatment of bacterial keratitis, as well.

So, why are drugs with broad application often limited in their specific indication(s)?

The most common answer focuses on ease of drug approval. It





**Phosphodiesterase inhibitors—including Viagra (shown here)—were researched and approved first for intervention of cardiovascular disease.**

is very expensive to get drugs approved by the FDA to begin with, so trying to find the easiest route to market is the name of the game (i.e., the “low-hanging fruit” concept).

Furthermore, beneficial uses for a drug might only be realized once it is approved for its intended indication. Minoxidil, for instance, is approved as an antihypertensive, yet has been found to enhance hair growth in some individuals.

Another prominent example: The phosphodiesterase inhibitors (Viagra, Cialis and Levitra) were researched and approved first for cardiovascular disease intervention, but their beneficial effect on erectile dysfunction was realized, and subsequently approved for this condition.

Similarly, the prostaglandin bimatoprost was found to enhance eyelash growth as a side effect. That drug is now FDA approved as Latisse (Allergan) for this specific purpose.

An entire book could be written detailing similar stories on hundreds of drugs. We wanted to relate a few examples before we shared literature and opinion from authoritative sources. We are aware of some reluctance by some doctors to use medicines off-label. We hope the following quotes will enable the bold embrace of such practice.

It should now be abundantly evident that “off-label” use of many medicines can render a significant therapeutic benefit to many patients. As stressed above, such off-label use needs to be rational, be underpinned by a scientific rationale, preferably be discussed in the professional literature, and should

demonstrate an expected clinical outcome.

We recall a pediatrician we saw a few years back with acute epidemic keratoconjunctivitis. She was miserable and in full panic mode.

We explained to her that the Betadine treatment we would recommend was off-label.

She laughed!

She said, “90% of what I do is off-label; let’s get on with it.” This beautifully exemplifies the clinical virtue of off-label drug use. By the way, she was much better at her two-day follow-up visit, and was extremely thankful. ■

1. Alliance of Specialty Medicine. Physician Directed Applications (Off Label Use): A Position Statement of the Alliance of Specialty Medicine. October 14, 2011; Washington D.C. Available at: [www.specialtydocs.org/webdev/user\\_upload/Final\\_Alliance\\_offlabel\\_position\\_statement.pdf](http://www.specialtydocs.org/webdev/user_upload/Final_Alliance_offlabel_position_statement.pdf).

### Off-Label: Sometimes the Best Medicine

- “An estimated 50% of medications used routinely in ophthalmic practice are used off-label.”
- “Clinical practice should be guided by the best interest of the patient.”
- “In many instances, off-label treatments may be the best, or the only, available treatment, and withholding treatment would be unethical.”
- “Ophthalmologists must be aware of potential conflicts of interest with the use of off-label medications, including financial gain, notoriety or recognition, advancement of a personal research program or promotion of a third-party interest, and carefully assessing whether those interests are affecting treatment recommendations.”

Ask the Ethicist: Off-label Meds. EyeNet. 2011 May;15(5):55.

### Be Thoughtful When Prescribing

When prescribing, keep the drug’s cost-benefit ratio in mind.

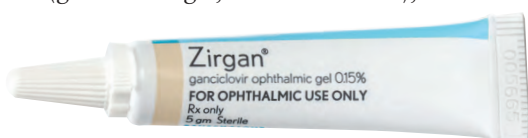For example: “A decade ago, definitive trials demonstrated that old-time, inexpensive thiazide diuretics were as effective for the initial treatment of systemic hypertension as new, more expensive classes of drugs. This has not had any perceptible impact on prescribing practices. Similarly, two highly promoted (and related) drugs for reducing the risk of cardiovascular disease, Zetia (ezetimibe) and Vytorin (which combines ezetimibe with a statin), have yet to demonstrate superior clinical outcomes to statins alone. These two prescription drugs nonetheless earned their manufacturers over \$3.5 billion last year.”

Sommer A. On the nature of, and response to, medical evidence. Am J Ophthalmol. 2010 Feb;149(2):182-3.

# Overview of Herpes Simplex Disease

Catch these disease processes early so that antiviral therapy can be started as soon as possible—then continue on prophylactic therapy to prevent recurrence.

**M**ost cases of herpes simplex disease are pretty straightforward: Treat with Zirgan (ganciclovir gel, Bausch + Lomb),



just block active viral replication—if such were to occur—they actually strengthen latency posture by enhancing the production of “latency-associated transcripts;” chemical compounds which induce the virions to stay latent.<sup>1</sup> An appreciation of the multifactorial aspects of latency can

help the clinician understand the importance of consistent, lifelong antiviral therapy for protecting patients who have experienced significant and/or recurrent ocular herpes simplex disease.

Dr. Foster goes on to say: “I typically prescribe lifelong prophylaxis with acyclovir or valacyclovir

Viroptic (trifluridine, Monarch), or an oral antiviral (and, uncommonly, with both topical and oral therapies).

However, recurrent herpes simplex viral keratitis is not always a benign epithelial disease. Recurrent bouts can result in stromal scarring, which can cause annoying,

lifelong blur; or, can be so severe as to require penetrating or lamellar keratoplasty. This has caused some world-class experts to modify their approach to herpetic eye disease. Stephen Foster, M.D., of the Massachusetts Eye and Ear Infirmary, has written some very thought-provoking statements that merit our contemplation.<sup>1</sup> Our paraphrase follows:

Low-dose oral antivirals do not

## Topical Antiviral Options

### Trifluridine

- Old drug
- Indiscriminate expression
- Potentially toxic
- More frequent dosing
- Refrigerate until opened
- Thiomersal preserved
- Solution (7.5ml bottle)
- Viroptic (Monarch) and generic

### Ganciclovir

- New drug
- Infected cell-specific
- Minimally toxic
- Less frequent dosing
- No refrigeration needed
- BAK preserved
- Gel (5g tube)
- Zirgan (Bausch + Lomb)

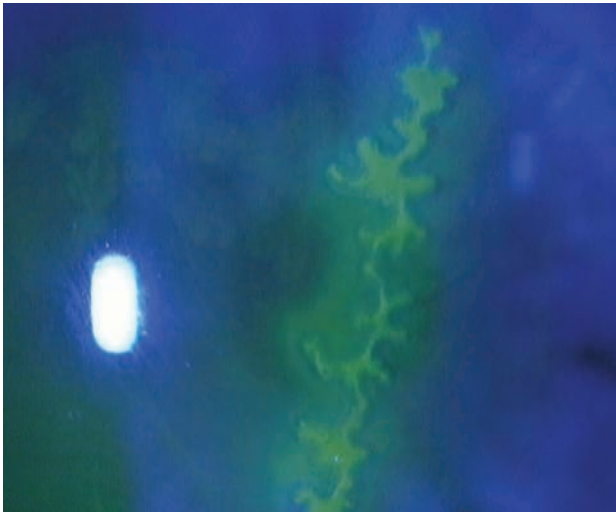
## Prevent HSV Disease Recurrences

• Patients treated with oral antiviral therapy were nine times less likely than untreated patients to develop recurrent keratitis.

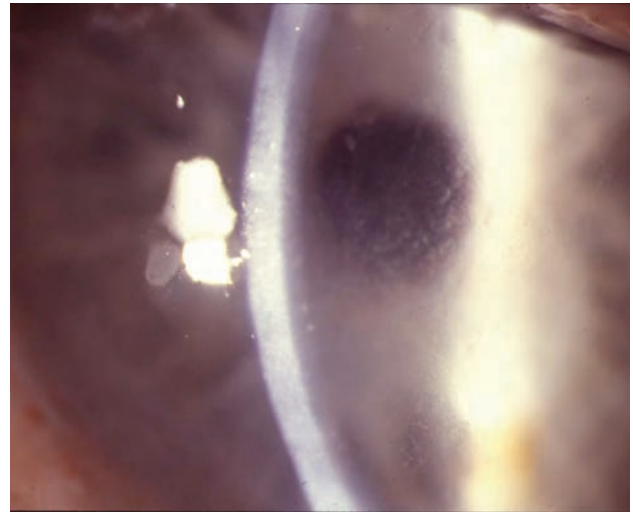
- Recurrence rates:
  - 27% at 1 year
  - 50% by 5 years
  - 57% by 10 years
  - 63% by 20 years

- Stromal disease is more likely to recur than epithelial disease.
- Length of prophylaxis: Generally five disease-free years.

Baratz KH. The role of antiviral therapy after the resolution of acute herpes simplex keratitis or acute herpes zoster ophthalmicus. Arch Ophthalmol. 2012 Jan;130(1):108-10.



**Herpes simplex keratitis.**



**Herpetic stromal immune keratitis.**

for any patient who has had a single episode of herpes keratitis. I base this on a simple risk/benefit calculation: I weigh the superb safety profile of these antiherpetic drugs against the potentially devastating consequences of recurrent herpes keratitis.” (Note: Many other authorities would disagree with this approach and would defer prophylactic treatment until after several additional recurrences and the onset of central or paracentral corneal scarring.)

If topical corticosteroids are needed to suppress any stromal inflammation along the way, Dr. Foster recommends a doubling of the prophylactic antiviral dose during the steroid treatment phase.

“The one rare, but significant, side effect associated with systemic antivirals is renal toxicity. This is not a significant risk in the patient with normal kidney function who takes the drug at recommended doses,” he says. So, it may be wise to obtain a complete blood count (CBC) and assays for liver enzymes, blood urea nitrogen (BUN), and creatinine occasionally, or via the patient’s primary care physician. A letter to the patient’s primary care physician regarding your therapeutic

intervention is recommended to enhance good patient care communication.

Keratitis is the most common manifestation of herpes simplex viral disease, however, “infected patients can experience recurrent conjunctivitis, episcleritis, scleritis and uveitis, though such atypical involvement often goes undiagnosed. As a result, my suspicion of recurrent ocular herpes is heightened whenever I uncover a history of recurrent ocular inflammation of undiagnosed cause,” Dr. Foster writes.

### Early Intervention

The key to minimizing the clinical impact of herpes simplex viral disease or the varicella zoster viral disease is to catch these disease processes early so that antiviral therapy

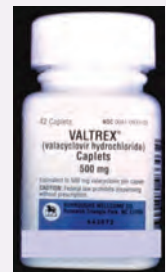can be started as soon as possible. We recently saw a 60-something-year-old lady who was seeing her internist for a stomach problem, and while there, her doctor pointed out to her a small reddish lesion on her forehead. The internist wasn’t sure what to make of it, but suggested she see an ophthalmologist for an opinion. Well, it was equally unclear to us (such is the real world of clinical patient care), but we recognized possibility of pre-clinical shingles.

Being cognizant of the virtue of rapid therapeutic intervention, we gave this lady a prescription for 800mg of acyclovir to take five times daily were she to “break out”... and she did, two days later! Within hours, she was on treatment and had an uneventful clinical course. The internist could/should

### Valacyclovir vs. Acyclovir for Recurrent HSV

“One-year suppression therapy with oral valacyclovir (500mg tablet daily) was shown to be as effective and as well-tolerated as acyclovir (400mg tablet twice daily) in reducing the rate of recurrent ocular HSV disease.”

Miserocchi E, Modorati G, Galli L, Rama P. Efficacy of valacyclovir vs. acyclovir for the prevention of recurrent herpes simplex virus eye disease: A pilot study. *Am J Ophthalmol.* 2007 Oct;144(4):547-51.



# Antiviral Drugs

## Ganciclovir 0.15% Gel: A New Treatment for EKC

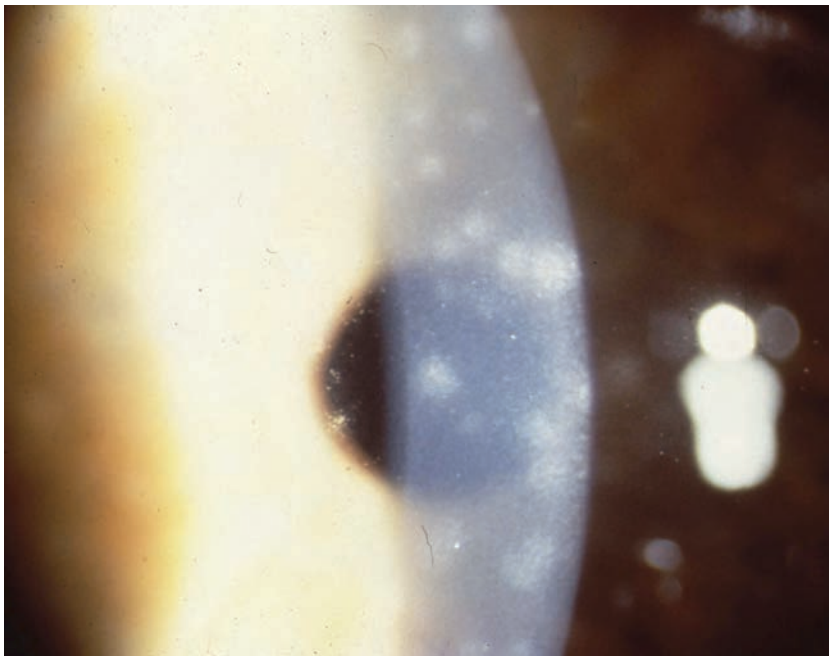
- “36 patients beginning an acute EKC were treated QID with ganciclovir 0.15% gel. All eyes were culture positive on 1-3 days.”
- “Ocular discomfort was alleviated in one week. No keratitis developed in any patient with this type 8 infection.”
- “Ganciclovir 0.15% gel must be prescribed as soon as possible. It does not blur vision owing to its water miscible property.”

Verin PH, Mortemousque B, Barach D. Ganciclovir 0.15% gel, a new treatment in epidemic keratoconjunctivitis (EKC). *Ophthalmic Res.* 1997;29(Suppl. 1):12-27.

## Ganciclovir Effects in EKC

- “Patients treated with topical ganciclovir 0.15% ointment showed resolution of EKC within 7.7 days (range 7-12 days) compared with 18.5 days (range 7-30 days) in the control group.”
- “22% of cases developed subepithelial opacities in the treatment group compared to 77% in the control group.”
- “Conclusions: Topical ganciclovir 0.15% ophthalmic ointment is safe and effective in the treatment of adenoviral keratoconjunctivitis.”

Tabbara KF, Goldschmidt PL, Nobrega R. Ganciclovir effects in adenoviral keratoconjunctivitis. Poster 3111-B253. Presented at ARVO; Fort Lauderdale, Florida. 2001.



**Classic subepithelial infiltrates following acute, untreated EKC.**

have made this call, but it fell to the optometrist to prescribe expectantly.

This same principle of early intervention applies to herpes simplex epithelial keratitis. The sooner the antiherpetic medicine can be started, the greater the likelihood of a positive clinical outcome.

Patients with a history of herpes simplex keratitis should always travel with an antiviral medicine, just in case.

Two reasons exist for being

quick on the trigger in treating herpes simplex virus and adenoviral infections (especially the serotypes that cause EKC):

- A quicker cure is desirable.
- Both the herpes and adenoviral viruses, if allowed to linger on the ocular surface, can set the stage for subsequent stromal-immune/inflammatory disease.

With the herpes simplex virus, permanent stromal scarring can occur; the subepithelial infiltrates of adenoviral origin are self-limiting,



but this can take many months. Both types of stromal disease are amenable to corticosteroid suppression. Antiviral prophylactic coverage is indicated in herpetic etiology, but not in adenoviral disease.

The advent of ganciclovir (Zirgan) is a most welcome addition to our antiviral armamentarium.

Anecdotally, we are hearing of good success in treating EKC with Zirgan. Years of success using Betadine 5% Ophthalmic Prep Solution for EKC still have us favoring this approach for more severe disease, but we are now having success with Zirgan in the setting of moderate disease expression.

Zirgan's advantages over trifluridine are many:

- From the patient's perspective,

using a drop only five times a day (as opposed to every two hours with trifluridine) is the most evident benefit.

- The issue of refrigeration is confusing to both patients and pharmacists (just like with latanoprost). Both trifluridine and latanoprost should be kept under refrigeration at the pharmacy; but once dispensed to the patient, these two medicines can be kept at room temperature.

- Because ganciclovir (like all the oral antivirals) is activated by viral enzymes, the potential corneal toxicity of trifluridine is minimized with ganciclovir, as is the potential reaction to the thimerosal-preserved trifluridine.

It should be evident that Zirgan is a major advance in caring for patients with herpetic epithelial keratitis and may well be so for adenoviral infections, as well.

## Additional Points

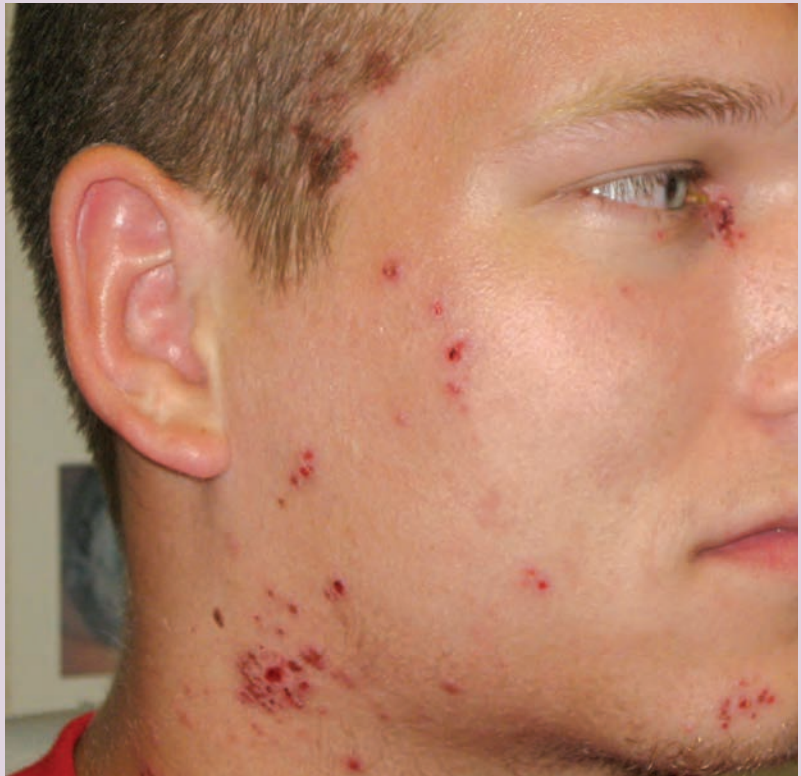Since it is well-established that herpes simplex viral keratitis can be treated with oral antivirals, as well as with topical antivirals, keep this in mind if cost is a barrier to appropriate treatment for some patients: 400mg of acyclovir taken five times a day for a week is, by far, the least expensive therapeutic approach.

There are many twists and turns in caring for patients with viral diseases; our duty is to be familiar with all of them. Keep in mind that kidney disease may require a reduced dosage of oral antivirals to achieve equivalent therapeutic efficacy.<sup>2</sup> Always inquire about renal impairment prior to prescribing.

A quick word on shingles: The dosage is 800mg of acyclovir five times a day for one week, or valacyclovir (Valtrex) 1,000mg t.i.d. for one week, or famciclovir (Famvir) 500mg t.i.d. for one

## Herpes Gladiatorum

- Occurs most commonly among young wrestlers, or in other sports where there is very close skin contact.
- First described in the 1960s (NEJM).
- It is an expression of HSV-I.
- Lymph nodes (preauricular and/or submandibular) are commonly present on one or both sides.
- Treated with oral antiviral for a week.
- Like all HSV infections, can become recurrent in nature.
- Temporary isolation from sports while being treated is key to breaking cycle of perpetuation.



**This young man developed herpes gladiatorum after direct physical contact with another wrestler during a collegiate college sports match. He was treated with oral valacyclovir 500mg three times a day for a week with complete resolution.**

week. These oral antivirals are all generically available, but acyclovir remains the least expensive of the three.

Remember to advise all of your over-50 patients to get the shingles vaccine, Zostavax. It can reduce the incidence of herpes zoster disease by 50% to 60%, and even if one subsequently develops disease

expression, that expression is likely to be considerably muted.<sup>3</sup> ■

1. Foster CS. Advances in the prevention of ocular herpes simplex disease and its recurrence. *Topics in Ocular Anti-infectives*. 2011(16);1-4.
2. Munar MY, Singh H. Drug dosing adjustments in patients with chronic kidney disease. *Am Fam Physician*. 2007 May 15;75(10):1487-96.
3. Update on Herpes Zoster Vaccine: Licensure for Persons Aged 50 Through 59 Years. *Morbidity and Mortality Weekly Report*. Centers for Disease Control and Prevention. November 11, 2011;60(44): 1528. Available at: [www.cdc.gov/mmwr/preview/mmwrhtml/mm6044a5.htm](http://www.cdc.gov/mmwr/preview/mmwrhtml/mm6044a5.htm).

# Glaucoma Review and Update

Mastering a knowledge of the glaucoma drugs is relatively simple. The challenge comes in knowing when to initiate medical therapy.

**G**laucoma patient care continues to be an entity of great need and great opportunity. So many patients are being treated unnecessarily, and yet, many people who have glaucomatous optic neuropathy remain undetected in the community at large, as well as in eye doctors' offices.<sup>1</sup>

We have found glaucoma diagnosis and subsequent therapeutic intervention to be very straightforward for most patients. Here is why: We do not focus a lot of energy agonizing over any single aspect of the diagnostic workup (ex-

cept for perhaps the optic nerve). We do not place extraordinary attention on the details of the visual fields, nor the optic nerve scan, nor the IOP, nor the central corneal thickness; but we do look at all the pieces of data from a larger, comprehensive perspective. (There are differences, of course. For instance, narrow angles are common among Asians, so we pay particular attention to gonioscopy in this subset of patients, or any patient with narrow Van Herick angles.)

The only saving grace in glaucoma is its slowly progressive nature.

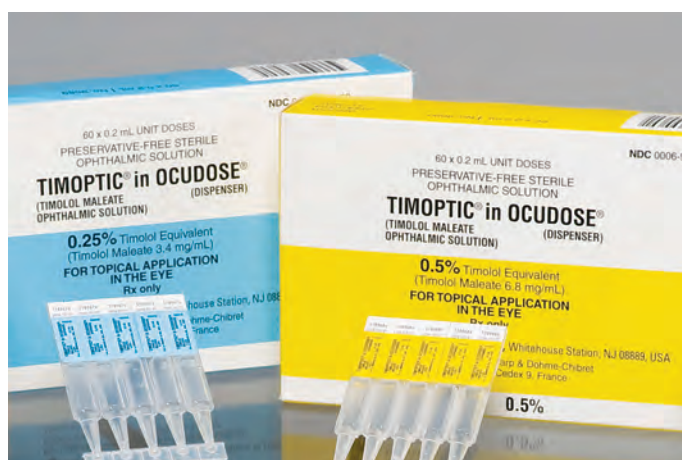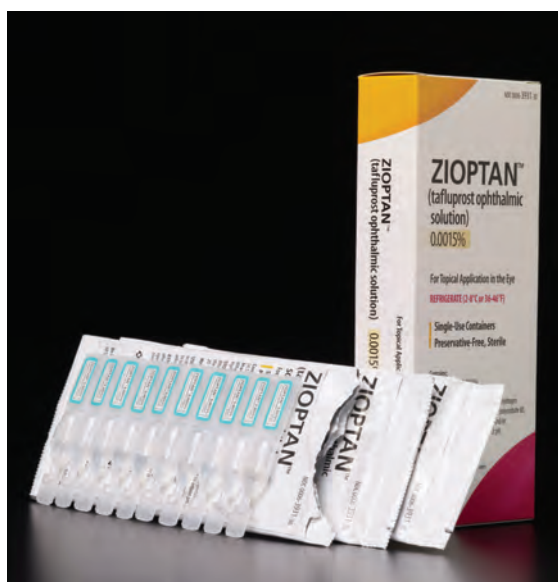Being cognizant of this reality allows us to relax, assess and attentively follow

our patients over many months or years before initiating or modifying therapy.

## New Developments

Now that latanoprost has joined beta-blockers, dorzolamide and brimonidine in the generic arena, we have a variety of cost-effective approaches to consider. Also, Alcon and Allergan have special promotional programs in which their branded products can be prescribed at generic pricing. This allows strict control over the quality of prostaglandin a patient receives, if there is concern concerning generic formulations and expense of therapy.

For those patients who need or want preservative-free drugs,

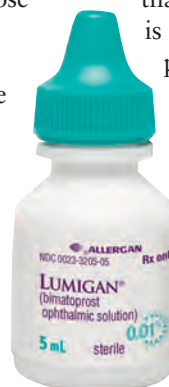

there are now three such unit-dose options: Timoptic (timolol maleate, Aton Pharma) and, new for 2012, Zioptan (tafluprost, Merck) and Cosopt PF (dorzolamide/timolol, Merck). These three come as preservative-free, unit-dose formulations. Understandably, they may be more expensive than traditional bottled products. Zioptan comes as a 0.0015% concentration and performs similarly to the other prostaglandins.

A recent study (in monkeys) suggests that tafluprost might be effective in patients who do not respond

to latanoprost.<sup>2</sup> Like latanoprost, tafluprost must be stored under refrigeration until dispensed to the patient. It comes in unit-dose packs of eight drops each, with 30 units per box. We hope such unique daily-use packaging might enhance compliance.

Note that Lumigan 0.03% is no longer available, and has been replaced with the updated 0.01%, which is more tolerable while maintaining similar efficacy.



## Primary and Additive Therapy

Let's look at the other IOP-lowering drugs. It's certainly not news that one of the four prostaglandins is used as first-line therapy for most patients most of the time. There is, however a new wrinkle that has been observed—orbital adipose tissue atrophy with associated erythema to the eyelids and conjunctiva; but more noticeable is the development of a recessed superior orbital sulcus. This relative enophthalmos can even make tonometry challenging because

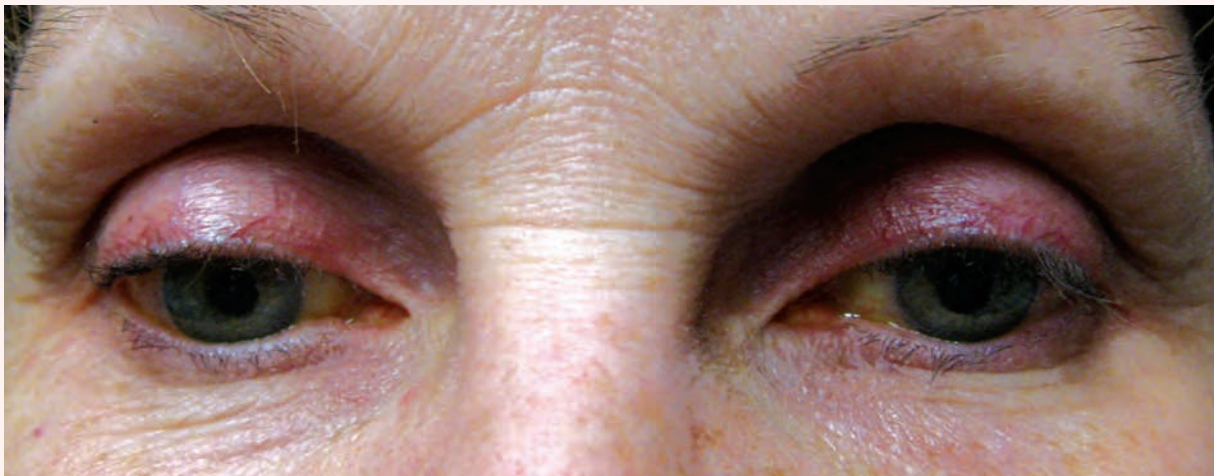
### Topical Glaucoma Drugs

BRAND NAME	GENERIC NAME	MANUFACTURER	CONCENTRATION	BOTTLE SIZE
<b>Beta Blockers</b>				
Betagan, and generic	levobunolol hydrochloride	Allergan, and generic	0.25% 0.5%	5ml, 10ml 5ml, 10ml, 15ml
Betimol	timolol hemihydrate	Vistakon Pharm.	0.25% 0.5%	5ml 5ml, 10ml, 15ml
Betoptic-S	betaxolol hydrochloride	Alcon	0.25%	5ml, 10ml, 15ml
Istalol	timolol maleate	ISTA	0.5%	5ml
Timoptic, and generic	timolol maleate	Aton Pharma, and generic	0.25% 0.5%	5ml, 10ml, 15ml 5ml, 10ml, 15ml
Timoptic (preservative-free)	timolol maleate	Aton Pharma	0.25% 0.5%	unit-dose unit-dose
Timoptic-XE, and generic	timolol maleate	Aton Pharma, and generic	0.25% 0.5%	2.5ml, 5ml 2.5ml, 5ml
<b>Prostaglandin Analogs</b>				
Lumigan	bimatoprost	Allergan	0.01%	2.5ml, 5ml, 7.5ml
Travatan Z	travoprost	Alcon	0.004%	2.5ml, 5ml
Xalatan, and generic	latanoprost	Pfizer, and generic	0.005%	2.5ml
Zioptan	tafluprost	Merck	0.0015%	unit-dose
<b>Alpha Agonists</b>				
Alphagan P, and generic	brimonidine brimonidine	Allergan generic	0.1%, 0.15%, 0.2%	5ml, 10ml, 15ml 5ml, 10ml, 15ml
<b>Carbonic Anhydrase Inhibitors</b>				
Azopt	brinzolamide	Alcon	1%	5ml, 10ml, 15ml
Trusopt, and generic	dorzolamide	Merck	2%	5ml, 10ml
<b>Combination Glaucoma Medications</b>				
Combigan	brimonidine/timolol	Allergan	0.2%/0.5%	5ml, 10ml
Cosopt	dorzolamide/timolol	Merck	2%/0.5%	5ml, 10ml
Cosopt PF	dorzolamide/timolol	Merck	2%/0.5%	unit-dose

## Prostaglandin-Associated Periorbitopathy

- A more newly recognized side effect of prostaglandin eyedrop therapy.
- Periorbital fat atrophy gives rise to marked deepening of the superior lid sulcus, which can result in ptosis and enophthalmos.
- Beyond the obvious cosmetic concerns, such altered lid/orbital anatomy, it can make applanation tonometry quite challenging.
- Probably expressed more in middle-aged patients than in older patients.
- Tends to be at least partially reversible over a few months.

Pasquale LR. Prostaglandin-Associated Periorbitopathy: A postmarketing surveillance observation. *Advanced Ocular Care*. July-August 2011. 21-25.



## After a Prostaglandin, What to Add?

- Is it brimonidine, a beta-blocker, or a CAI?
- Meta-analysis of studies regarding what drug to add to a prostaglandin.
- Conclusions: "All three classes are similarly effective in lowering mean diurnal IOP when used in combination with PGAs." Brimonidine is statistically less effective in reducing IOP at trough when compared with the beta-blockers and CAIs.
- Additional lowering of IOP was, on average, 2.5mm to 3mm Hg for all three.

Tanna AP, Rademaker AW, Stewart WC, Feldman RM. Meta-analysis of the efficacy and safety of alpha2-adrenergic agonists, beta-adrenergic antagonists, and topical carbonic anhydrase inhibitors with prostaglandin analogs. *Arch Ophthalmol*. 2010 Jul;128(7):825-33.

## When to Treat?

All glaucoma doctors struggle with the decision of whom to treat, and when. Remember: medical care is an art, and equally well-trained doctors commonly differ in clinical decision-making.

- "Patients with normal optic disc and visual field could tolerate an IOP of 30mm Hg for many years without need of treatment."
- "What it comes down to is . . . treat young patients who are in the high-risk group, and it is worth watching the elderly in a low-risk group. The problem remains what to do for those in the middle."

Sommer A. Glaucoma expert looks back to future: Classic paper noted observations on risk factors, including IOP, race, age, existing damage. *Ophthalmology Times*. January 1, 2011.

of the difficulty in holding up the upper lids without putting digital pressure on the globe. This adipose atrophy seems to be at least partially reversible upon discontinuation of the medicine.

Remember, while prostaglandins perform optimally when instilled in the evening, they work nearly as well when instilled in the morning.<sup>3</sup> Since compliance and cost are the main detriments to care, if a patient generally takes his/her medicines in the mornings, then by all means it is perfectly fine for that patient to use the prostaglandin eyedrop at that time. Do note that latanoprost is only refrigerated for "long-term storage," and once the patient is dispensed the bottle, it can be kept at room temperature, just like trifluridine.

The big question is, what can we add to a prostaglandin if the initial drug does not achieve target IOP? (There is no





## Beta Blocker in an Asthma Patient

Although still a contraindication, some patients with asthma can indeed be permitted to use a topical beta-blocker—as we found out to our surprise (*see communication below*). In ALL such cases, we directly communicate with the patient's asthma physician to discuss the appropriateness of such, and this correspondence is annotated in the patient's medical record. We always instruct these patients that if they develop any wheezing or shortness of breath, to simply stop the eyedrop and to contact their asthma doctor immediately. While we have had no problems using a once-daily beta-blocker in our asthma patients, we would never prescribe a beta-blocker drop without appropriately consulting the asthma doctor first.

Ms. N G is followed by me for asthma. She was last seen in our office on July 22, at which time her asthma was under control.

I see no absolute contraindication to starting Ms. G on 0.25% topical ophthalmic beta-blocker. I would advise her that it could cause an exacerbation of her asthma. If she develops any shortness of breath, chest tightness, cough or wheezing on the beta-blocker I would recommend that she stop the eyedrops and contact me.

If you have any further questions regarding this matter, please do not hesitate to contact me.

Sincerely,

MD

## Philosophy on Combination Drugs

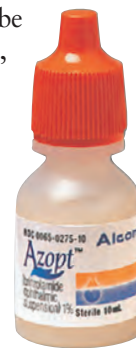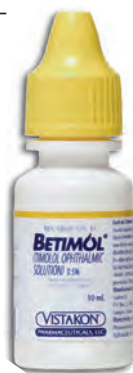- Rarely initiate therapy with a combination.
- Always try one of the ingredient drugs first.
- Add a second drug via a combination product if initial single drug failed to meet target pressure...
- ...Or also try the other ingredient drug as a therapeutic trial (if the initially selected ingredient drug was inadequate in achieving target pressure range).

reason to try a different prostaglandin. The XLT study of years past demonstrated that they all perform similarly.<sup>4</sup>) It is probably academically best to use either brimonidine or a topical carbonic anhydrase inhibitor (dorzolamide or brinzolamide), but these are at least twice-daily drops, and are probably most effective when used t.i.d.; this is simply not practical for most patients.

Therefore, we continue to favor a once-daily, nonselective beta-block-

er, such as timolol or levobunolol, as our additive therapy to a prostaglandin. Because beta-blockers have no measurable effect during the sleep cycle, it is important to instill a beta-blocker within thirty minutes of awakening to achieve the maximum benefit.<sup>5</sup>

We see brimonidine and a carbonic anhydrase inhibitor (CAI) as roughly clinical equivalents with regard to IOP-lowering ability, and we use these two medicine classes



## Combigan Ophthalmic Solution

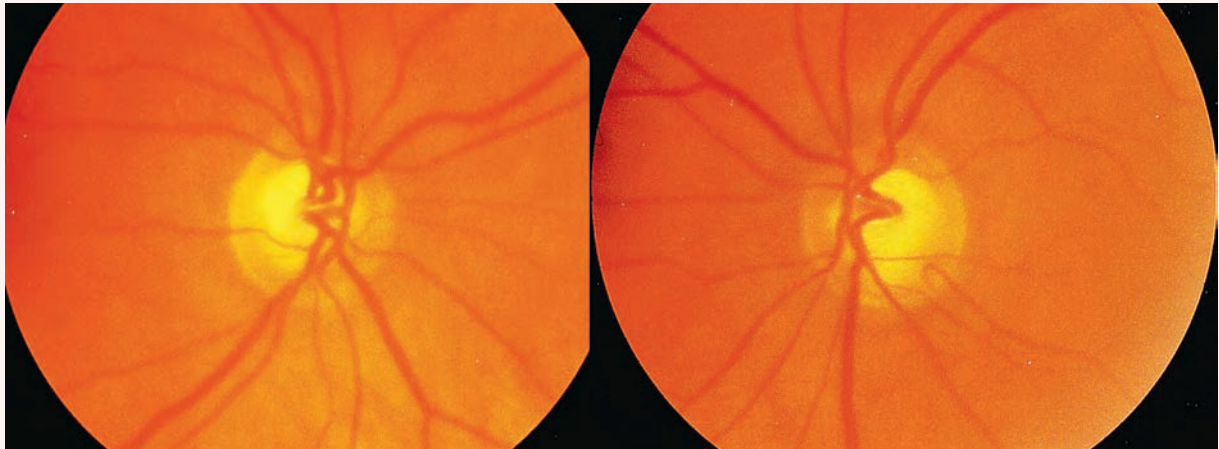
- Combination of brimonidine 0.2% and timolol 0.5%.
- Remember, most drugs have at least some minimal non-response rate, so there is a low but real chance that one of the components of any combination drug is not performing.
- If using timolol and the patient is not quite to target IOP, then it's rational to try Combigan.
- If using brimonidine and the patient is not quite to target IOP, then it's rational to try Combigan.
- If a prostaglandin does not reach target IOP, then try a once daily beta-blocker like timolol. If this two-drop therapy approaches, but does not achieve target IOP, then trying a combination drug is rational.
- With ANY combination drug, always try one of the component drugs as monotherapy, and only use the combination product if or when the monotherapy drug comes close, but does not achieve target IOP. "The IOP-lowering of Combigan dosed twice a day was slightly less than that seen with the concomitant administration of 0.5% timolol maleate ophthalmic solution dosed twice a day and 0.2% brimonidine tartrate ophthalmic solution dosed three times per day." — Combigan package insert. Allergan, Inc., Irvine, CA; 2011.

as third-line after a prostaglandin and/or a beta-blocker. We would generally prescribe the 0.15% brimonidine, as it is the least concentrated generic, or the 0.1% Alphagan P (Allergan), which is brand-name protected. The CAI we generally prescribe is dorzolamide, since it is available

## Factors Regarding Treatment Initiation

- Use of a “risk calculator,” and lack of glaucoma specialty training were associated with physicians being more likely to treat ocular hypertension.
- Two in 58 glaucoma specialists and four in 118 ophthalmologists reported treating all patients with an IOP >21 mm Hg—Most critical factors: IOP, C/D ratio, and CCT (both groups)
- Rational estimation of “risk of conversion” to OAG is essential for proper clinical decision-making.
- Treatment by default or faulty decision-making remains a healthcare crisis in glaucoma patient care management.

Boland MV, Quigley HA, Lehmann HP. The impact of physician subspecialty training, risk calculation, and patient age on treatment recommendations in ocular hypertension. *Am J Ophthalmol.* 2011 Oct;152(4):638-645.



When does the diagnosis change from ocular hypertension to glaucoma?

## Dorzolamide Hydrochloride 2%/Timolol Maleate 0.5% (Cosopt)

- Both components decrease IOP by reducing aqueous humor secretion.
- Because of the CAI, must be used b.i.d., which results in excessive beta-blocker therapy.
- Contraindications: patients with asthma, heart disease or COPD. (But it is no longer contraindicated in patients with an allergy to sulfa drugs.)
- Ocular side effects: burning/stinging and perversion in taste.

available from Merck in a brand-named protected, preservative-free, unit-dose formulation.

Mastering the “glaucoma drugs” is very simple; the challenge for ALL glaucoma doctors is to know when to initiate therapy.

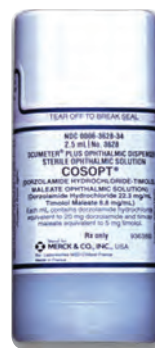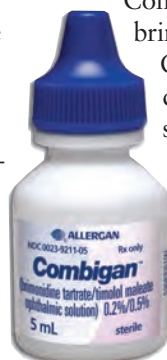Knowing when to begin treatment requires considerable thought, self-confidence and a modicum of clinical seasoning. Doctors with less experience, or those who use artificial intelligence (risk calculators), tend to over-prescribe.

In the end, caring for patients with glaucoma can be a challenging, yet rewarding part of what optometric physicians should be doing as an integral component of their daily practices. ■

generically. Brinzolamide (Azopt, Alcon) suspension is also available and is brand-name protected. It is expected to go generic in about a year.

There are two combination drugs available, Combigan (Allergan) and Cosopt (Merck). Both are expensive, and ironically are combinations of two very inexpensive generic drugs! The common ingredient in

both of these drugs is 0.5% timolol. Combigan contains 0.2% brimonidine, whereas Cosopt contains 2% dorzolamide in a preserved multiuse bottle (and is now generic). Obviously, the less expensive of the combination drugs is the generic version of Cosopt. Note that Cosopt is now also



## Glaucoma Patient Care Overview

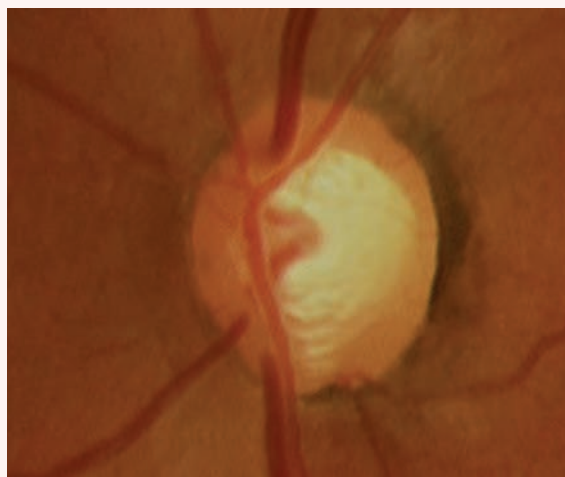
- The clinical work-up is driven by the anatomy of the optic nerve and/or the IOP. If the optic nerve(s) appear suspicious, then further evaluation (visual field testing, nerve fiber analysis, etc.) should certainly be performed.
- With exceedingly rare exception, glaucoma progresses slowly.
  - Do not micromanage any individual component of the glaucoma evaluation, except perhaps optic nerve appearance.
  - Keep good records; try to assure follow-up visits.
  - Show patients how to instill eye drops.
  - The line between “glaucoma” and “glaucoma suspect” is a highly subjectively variable.

1. Cassard SD, Quigley HA, Gower EW, et al. Regional variations and trends in the prevalence of diagnosed glaucoma in the Medicare population. *Ophthalmology*. 2012 Apr 3. [Epub ahead of print]
2. Kurashima H, Asai Y, Aihara M, et al. Ocular hypotensive effect of tafluprost in latanoprost low-responder cynomolgus monkeys. *J Glaucoma*. 2012 Feb;21(2):123-8.
3. Stewart WC, Konstas AG, Nelson LA, Kruff B. Meta-analysis of 24-hour intraocular pressure studies evaluating the efficacy of glaucoma medicines. *Ophthalmology*. 2008 Jul;115(7):1117-1122.
4. Parrish RK, Palmberg P, Sheu W, XLT Study Group. A comparison of latanoprost, bimatoprost, and travoprost in patients with elevated intraocular pressure: A 12-week, randomized, masked-evaluator multicenter study. *Am J Ophthalmol* 2003 May;135(5):688-703.
5. Strahlman E, Tipping R, Vogel R. A double-masked, randomized 1-year study comparing dorzolamide (Trusopt), timolol, and betaxolol. International Dorzolamide Study Group. *Arch Ophthalmol*. 1995 Aug;113(8):1009-16.

## Diagnosis Does Not Mandate Treatment

“Although decisions on treatment may not necessarily be made at an early stage, other appropriate measures, such as close monitoring, may be considered. It was generally agreed that early detection does not automatically imply early treatment and that early detection and early treatment should be considered separately.”

Leske MC, Heijl A, Hyman L, et al; EMGT Group. Predictors of long-term progression in the early manifest glaucoma trial. *Ophthalmology*. 2007 Nov;114(11):1965-72.



## Reality Check on Preservatives

Isn't it interesting that 0.01% bimatoprost is more tolerable, in terms of comfort and redness, than the 0.03% formulation, in spite of the fact that there is a fourfold increase in the concentration of BAK (from 0.005% to 0.02%)!

Theoretically, it seems probable that the 0.02% difference in the bimatoprost would make little or no clinically significant difference. Compared with the 0.03% solution, the 0.01% solution has one-third the exposure to the ocular surface. Yet, the ocular hypotensive effect of the 0.01% solution is equivalent to the 0.03% solution, and it has improved tolerability, including less frequent and less severe conjunctival hyperemia.<sup>1</sup>

So much has been made about the impact of preservatives on the ocular surface, yet there is little substance of clinical

relevance. Frank J. Holly, Ph.D., of Lubbock, Texas, a world-recognized artificial tear research scientist, made the statement below, with which we agree.

Certainly, potentially toxic preservatives like BAK should be minimized where practical in clinical patient care. More and

more ophthalmic preparations are now using newer, relatively nontoxic preservatives, and this is a welcome update. Obviously, preservative-free solutions would be ideal, but perhaps not imperative in clinical use.

We urge clinicians to focus on the overall benefit of a medicine rather than get caught up in preservative minutia.

1. Katz LJ, Cohen JS, Batoosingh AL, et al. Twelve-month, randomized, controlled trial of bimatoprost 0.01%, 0.0125%, and 0.03% in patients with glaucoma or ocular hypertension. *Am J Ophthalmol*. 2010 Apr;149(4):661-671.

## Perspective on Preservatives

“Often the use of preservative-free preparations is suggested regardless of the composition of the tear substitute. Harmful preservatives should certainly be excluded. However, the fact is that often a well-formulated artificial tear containing a benign preservative proves to be superior to a preservative-free drop if its only advantage of the latter is the lack of preservative. Solely the lack of preservative per se does not make the formulation efficacious. Unfortunately, the ‘preservative free label’ is often just a marketing tool.”

Young M. Pharmaceutical Corner: In-depth look at artificial tears. *EyeWorld*, September 2009. Available at: <http://eyeworld.org/article-in-depth-look-at-artificial-tears>.

# Keeping Allergy Management Simple

Allergy management can be straightforward. For ocular itching, use OTC ketotifen. If there are also signs, prescribe a steroid to quiet the eye.

For the most part, when a patient presents with symptoms of a dry, scratchy, itchy, burning and gritty feeling, this is a patient suffering from “dry eyes.” Even though itching is a component of the constellation of presenting symptoms, this subcomponent itching is likely an opportunistic expression resulting from ocular surface tear film dysfunction (i.e., dryness). This dry eye-associated symptomatic itching is best managed by treating the underlying primary dry eye.

On the other hand, if itching is the predominant symptom, drug selection is dichotomous:

1. If there are minimal associated signs of allergy, such as chemosis, conjunctival injection, and/or eyelid edema, along with the predominant itching, then an antihistamine/mast cell stabilizer is an excellent clinical approach. Within this class, there are five drugs:

- azelastine (Optivar, Meda Pharmaceuticals)
- bepotastine (Bepreve, ISTA Pharmaceuticals)
- epinastine (Elestat, Allergan)

- ketotifen (Zaditor, Alcon; now available generically and OTC)
- olopatadine (Patanol/Pataday, Alcon).

Notwithstanding fine differences, all of these antihistamine subtype 1 receptor blockers nicely suppress ocular itching. All are dosed initially b.i.d. (except Pataday, which is dosed once-daily).

We recommend after two weeks at b.i.d., try reducing these to once-daily as “maintenance” therapy. In our experience, once symptomatic itching has been brought under control, it takes less pharmacological intervention to maintain control.

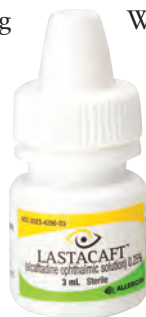Also, we now have Lastacraft (alcaftadine 0.25%, Allergan), which also has the benefit of once-daily dosing. Alcaftadine is a new chemical entity with an affinity for H<sub>1</sub>, a histamine receptor associated with the early phase of allergic conjunctivitis.

In addition, ketotifen is now available generically and

OTC. There are several brand-name OTC ketotifen preparations, such as Alaway (Bausch + Lomb), Claritin Eye (Schering-Plough), Refresh Eye Itch Relief (Allergan) and Zaditor. All come in 5mL bottles (except for Alaway, which comes as a 10mL bottle). Interestingly, our casual observations in a variety of pharmacies reveal that the cost of 10mL Alaway is very near (and occasionally cheaper) than the price of its 5mL competitors. So, it should be clearly evident that OTC Alaway is the most cost-effective way to suppress ocular itch.

2. If there are one or more concurrent signs of allergy, such as conjunctival redness, chemosis, and/or eyelid edema, along with the predominant itching, then a topical corticosteroid—such as Alex, Lotemax or FML ophthalmic suspension—would be a more appropriate treatment.

The only other decision tree involves frequency of instillation, which could be q2h for two days,



then q.i.d. for one week, followed by b.i.d. for one more week. Once the inflammatory signs are controlled, then consider switching the patient to an antihistamine/mast cell stabilizer for ongoing symptom control. Long-term treatment with Alex b.i.d. as maintenance therapy can be done, if need be.

According to a conversation we had with Mark Abelson, M.D., a world-renowned ocular allergist at Harvard Medical School, there is little or no clinical use for pure mast cell stabilizing drugs. He says that the antihistamine/mast cell stabilizer drugs more effectively stabilize the mast cell membranes than standalone mast cell stabilizers, such as pemirolast (**Alamast**, Vista-kon), nedocromil (**Alocril**, Allergan) or cromolyn sodium (generic). Based on this expert opinion, we no longer prescribe these pure mast cell stabilizers.

Remember, allergy is an expression of inflammation. Cold compresses can be helpful in almost all ocular surface inflammatory diseases. (Infectious processes, on the other hand, are commonly helped by the application of warm soaks.)

In summary, if itching is not the primary symptom, be sure to consider dry eyes as the foundational condition and treat accordingly.

If itching is primarily expressed, determine if it is an isolated symptom or if it is associated with concurrent inflammatory signs, and then treat accordingly.

Remember:

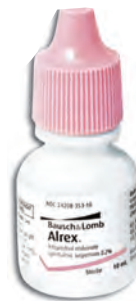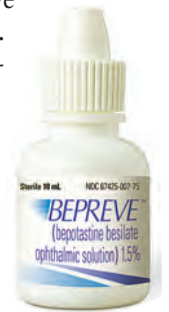- *Symptoms only*—use an antihistamine/mast cell stabilizer.
- *Symptoms with signs*—use a steroid such as Lotemax, Alex or FML.

Given all this, we

also look to the cost of these medicines, and because ketotifen is OTC and very inexpensive, we routinely recommend it.

Within both prescription and OTC options, bottle size is another consideration that has a marked impact on the value to the patient. Bepreve and OTC ketotifen (specifically Alaway) are both available in 10ml bottles (compared to 5ml bottles for the others), and therefore would offer the greatest value to our patients. These two medicines, and the other antihistamine/mast cell stabilizers, can be used b.i.d. for a week or two; after that time, once-daily administration can usually maintain absence of itch for virtually all patients.

Actually, allergy management is very straightforward. ■



## Ocular Allergy Medicine Profile

BRAND NAME	GENERIC NAME	MANUFACTURER	PEDIATRIC USE	BOTTLE SIZE(S)	DOSING
<b>Acute Care Products</b>					
Acular LS	ketorolac tromethamine 0.4%	Allergan	3 years	5ml, 10ml	q.i.d.
Alaway (OTC)	ketotifen fumarate 0.025%	Bausch + Lomb	3 years	10ml	b.i.d.
Alex	lodoxamide 1%	Bausch + Lomb	12 years	5ml, 10ml	q.i.d.
Bepreve	bepotastine besilate 1.5%	ISTA	2 years	10ml	b.i.d.
Claritin Eye (OTC)	ketotifen fumarate 0.025%	Schering-Plough	3 years	5ml	b.i.d.
Elestat	epinastine HCl 0.05%	Allergan	3 years	5ml	b.i.d.
Emadine	emedastine difumarate 0.05%	Alcon	3 years	5ml	q.i.d.
Lastacaft	alcaftadine 0.25%	Allergan	2 years	3ml	q.d.
Optivar	azelastine hydrochloride 0.05%	Meda	3 years	6ml	b.i.d.
Pataday	olopatadine hydrochloride 0.2%	Alcon	3 years	2.5ml	q.d.
Patanol	olopatadine hydrochloride 0.1%	Alcon	3 years	5ml	b.i.d.
Refresh (OTC)	ketotifen fumarate 0.025%	Allergan	3 years	5ml	b.i.d.
Zaditor (OTC)	ketotifen fumarate 0.025%	Alcon	3 years	5ml	b.i.d.
<b>Chronic Care Products</b>					
Alamast	pemirolast potassium 0.1%	Vistakon Pharm.	3 years	10ml	q.i.d./b.i.d.
Alocril	nedocromil sodium 2%	Allergan	3 years	5ml	b.i.d.
Alomide	lodoxamide tromethamine 0.1%	Alcon	2 years	10ml	q.i.d.
Crolom	cromolyn sodium 4%	Bausch + Lomb	4 years	10ml	q.i.d.
Opticrom	cromolyn sodium 4%	Allergan	4 years	10ml	q.i.d.

# Oral Medicine Update

Optometrists have authority to prescribe oral drugs in most states (47 states and the District of Columbia). So, knowledge of these useful medicines is essential.

**W**e have extensively reviewed oral drugs in previous editions of this Drug Guide. This year, we are providing a “highlights” overview of the key points.

## Oral Antibiotics

As more and more *Staph.* species become methicillin-resistant, it is important that when we prescribe an oral antibiotic, it is one that is capable of eradicating all common bacterial pathogens. Even more foundational is the realization that many ocular pathogens produce the enzyme penicillinase, which neutralizes the bactericidal effect of the penicillins. For this reason, we never prescribe any of the standard

penicillins. There are excellent “penicillinase-resistant” penicillins, such as dicloxacillin, but they are recommended to be taken four times a day; so we usually prescribe twice-daily cephalosporin (discussed below).

For MRSA infections, one of the most effective medicines is the old Bactrim or Septra (trimethoprim with sulfamethoxazole).<sup>1</sup> We prescribe this for most adults as two double-strength tablets/capsules b.i.d. for one week. (Note that “double-strength” is in fact the standard dosing strength of this medicine.)

The most common reason we prescribe an oral antibiotic in acute care is for the treatment of moder-

ate to advanced internal hordeola, and always in concert with the aggressive use of warm soaks. Subacute dacryocystitis is another indication for an oral antibiotic.

Of course, for more protracted conditions, such as rosacea-associated blepharitis or meibomian gland dysfunction, we may prescribe sub-bactericidal dosages of doxycycline, such as 50mg a day for two to four months. These lower dosages exert a mild anti-inflammatory effect that tends to augment the multifaceted interventions of lid hygiene, warm compresses and eyelid massage.

Now, back to acute care...

There are a number of effective oral antibiotics that can be helpful in the treatment of bacterial eyelid infections. Our favorite over the years has been Keflex (cephalexin), a first-generation cephalosporin, dosed at 500mg b.i.d. for one week.

### 21st Century Perspective on Penicillin Allergy

- “About 90% of patients with documented IgE antibodies to penicillin tolerate cephalosporins with identical or very similar side chains.”
- “Many patients with histories of penicillin or cephalosporin ‘allergy’ have actually had nonimmunologic drug-related side effects such as vomiting, diarrhea and nonspecific rash.”
- “First-generation cephalosporins have the potential for cross-reactivity, but the risk is less than the 10% rate that has been presumed. In fact, the risk is closer to 0.5%. Most second- or third-generation cephalosporins, specifically cefuroxime (Ceftin), cefpodoxime (Vantin), ceftriaxone [I.V. only] (Rocephin), and cefdinir (Omnicef) are unlikely to be associated with cross-reactivity.”

Pichichero ME, Casey JR. Safe use of selected cephalosporins in penicillin-allergic patients: a meta-analysis. *Otolaryngol Head Neck Surg.* 2007 Mar;136(3):340-7.

### Options for True Penicillin Allergy Patients

- 2nd or 3rd generation cephalosporin
- Sulfamethoxazole/trimethoprim (Bactrim or Septra)
- A fluoroquinolone (levofloxacin)
- Doxycycline
- Erythromycin

## Penicillin and Cephalosporin Cross-Sensitivity

- Both possess a beta-lactam ring.
- “Cephalosporins are first-line treatment for many infections and are used widely in ophthalmology.”
- “More than 90% of patients who report a history of penicillin allergy lack penicillin-specific IgE and can tolerate the antibiotic safely.”
- Penicillin allergy “should not prevent the use of second- and third-generation cephalosporins with distinct side-chains.” These are cefuroxime, cefprozil, ceftazidime and cefpodoxime.

Wykoff CC, Flynn HW Jr, Han DP. Allergy to povidone-iodine and cephalosporins: the clinical dilemma in ophthalmic use. *Am J Ophthalmol.* 2011 Jan;151(1):4-6.

However, a tiny percentage of patients have a true penicillin allergy, and these few may also exhibit an allergic response to the drugs of the cephalosporin class. More recent literature gives a more enlightened perspective of this rare possibility.

Based on this newer knowledge, and in consultation with a pharmacologist, it appears that the “pick of the litter” drug would be cefuroxime (Ceftin, GlaxoSmithKline) dosed at 500mg b.i.d. for one week. This drug is a second-generation cephalosporin with good efficacy against common ocular pathogens. It has distinctly different side chains that make it highly unlikely to result in a reaction in a person with true (i.e., authenticated) penicillin allergy.

Of course, perhaps an even safer approach would be to use a different class of antibiotic altogether. In true penicillin-allergic patients, we tend to favor levofloxacin (Levaquin and its generic) 500mg daily for one week, or Bactrim DS or Septra DS, one to two tablets b.i.d. for one week.

## Oral Antivirals

All three oral antivirals—acyclovir, valacyclovir and famciclovir—are superb for the treatment of herpes simplex and varicella zoster

disease. As with all medicines, the sooner the therapy is started, the greater the likelihood of an optimal outcome.

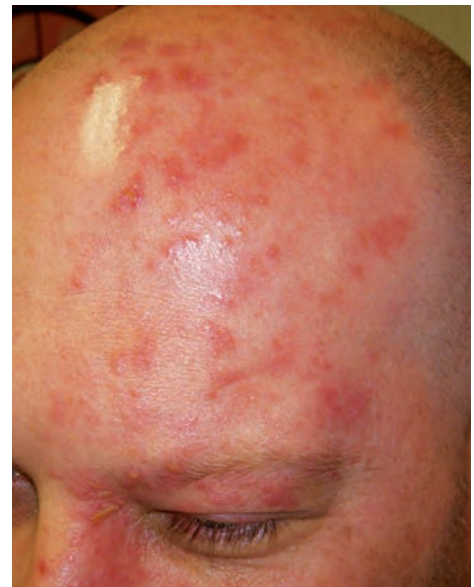Oral antivirals are incredibly safe and effective. The only real precaution is their use in patients with marked reduction in kidney function, since these drugs are renally excreted.<sup>2</sup> Doses in patients with poor kidney function need to be reduced. This will require consultation with the nephrologist/internist, and a pharmacist. Once the glomerular filtration rate and creatinine clearance parameters are known, pharmacists have software programs that can quickly determine the optimum dosage. We have never had a patient in this situation, but we are “at the ready” should the situation present.

The dosage for treating active herpes simplex disease is 400mg of acyclovir five times a day for seven to 10 days, or valacyclovir (Valtrex and generic) 500mg t.i.d. for seven to 10 days, or famciclovir (Famvir and generic) 250mg t.i.d. for seven to 10 days.

Like the prostaglandins, all three of these antivirals clinically perform identically. The difference is in the half-life behavior, which is why

valacyclovir and famciclovir can be used less frequently than acyclovir; however, acyclovir is the least expensive of the three and therefore the option we most commonly choose.

Such oral therapy effectively treats all expressions of acute herpes simplex disease. If the patient has a history of chronic, recurrent disease, then the literature guides us to prescribe either acyclovir 400mg b.i.d. or valacyclovir 500mg daily for many years.<sup>3</sup> This prophylactic intervention decreases the risk of recurrent disease by about 50%,



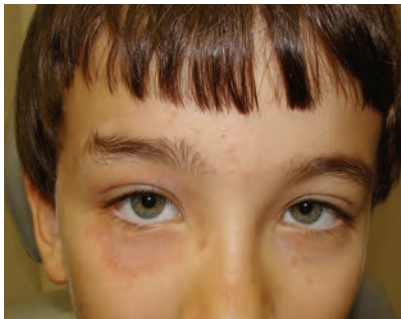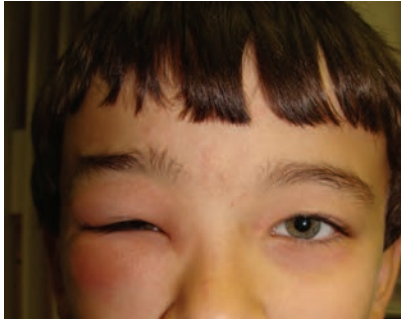**For shingles, double the drug dosage (of acyclovir, valacyclovir or famciclovir) that is recommended for herpes simplex disease.**

and even should disease recur, the clinical expression for these patients is significantly muted.<sup>4</sup>

For shingles, we simply double the dosages recommended for herpes simplex disease; that is, acyclovir 800mg five times daily for seven to 10 days, etc.

## Oral Corticosteroids

For most patients most of the time, a dosage of 40mg to 60mg



**Acute periocular inflammatory dermatitis in children calls for 20mg p.o. prednisone for three days, along with cold compresses.**

of oral prednisone for five to seven days is exceedingly well tolerated. Marked acute periocular inflammatory dermatitis is an excellent example of where oral steroids can exert a wonderful resolution. These acute periorbital allergic conditions generally respond very rapidly (within two or three days), so once the condition is controlled, we simply stop the oral prednisone. In children, we used 20mg p.o. prednisone for three days, along with cold compresses.

Take into account peptic ulcer disease, diabetes, pregnancy and active tuberculosis, or a history of prior adverse reaction to prednisone prior to prescribing. For perspective, patients with acute optic neuritis are commonly treated with 1,000mg of intravenous methylprednisolone for three days (with a short oral taper). The relatively lightweight doses that we prescribe

## Qnexa: A New Weight Loss Drug on the Horizon!

This headline may have caught your attention for personal reasons, but that is not the prime focus of this update. From all accounts, Qnexa (phentermine/topiramate, Vivus) can cause about a 10% weight loss over the course of a year.<sup>1</sup>

So why are we talking about weight loss in an optometric publication? Well, Qnexa is a combination of two older drugs: phentermine and topiramate. We have no problem with the phentermine; but topiramate, a sulfa-based medicine, can cause idiosyncratic ciliochoroidal effusion. This event results in iridocorneal angle closure, and because of a subsequent anterior shift of the crystalline lens, myopia is induced.

It is the rapid, painless, bilateral onset of blurred vision that brings people to seek eye care. The intraocular pressure increase tends to be moderate—about 30 to 40mm Hg. In classic unilateral angle closure, the intraocular pressure tends to be more like 50mm to 70mm Hg, and most certainly can be painful.

Topamax (topiramate, Janssen Pharmaceuticals) was FDA-approved in 1996 as an anti-convulsant, and later for the prevention of migraine headaches. It has long been known to have weight reducing property. Now, in combination with phentermine, it will have an indication for weight loss as well. Assuming Qnexa achieves final FDA approval—perhaps this summer—there will be a massive uptick in the exposure of topiramate to the American public.

Bear in mind that the anatomy of the iridocorneal angle is completely irrelevant with regard to one's risk of angle-closure with topiramate. Whether the angles are Van Herick 1 or 4 makes no difference; when an iatrogenic ciliochoroidal effusion occurs, any angle anatomy will be compromised. Such side effects are quite rare; but if they occur, they usually do so within three to four weeks of starting, or increasing the dosage of, topiramate.

Treatment of topiramate-induced angle-closure is very straightforward with one notable exception. First of all, stop the medicine. Medical intervention is the same as with classic angle-closure—except do not use pilocarpine. Instead, use a cycloplegic agent (to calm the ciliary body effusion). Depending upon the intraocular pressure level, a beta-blocker and/or brimonidine can be used for a day or two, since the intraocular pressure will return to normal levels upon discontinuation of the topiramate. Obviously, a nice telephone call to the prescribing doctor is in order, too.

1. Verrotti A, Scaparrotta A, Agostinelli S, et al. Topiramate-induced weight loss: a review. *Epilepsy Res.* 2011; 95:189-99.

in the office setting work well for most patients, and are very low-dose when compared to the dosages used for treatment of acute optic neuritis.

## Carbonic Anhydrase Inhibitors

Acetazolamide (Diamox and generic) is the most famous in this class, and is helpful in treating acute angle-closure cases, or idiopathic intracranial hypertension (formerly known as pseudotumor cerebri). However, for longer-term care, methazolamide (Neptazane and generic) is generally better

tolerated. For full prescribing information, consult the text (or electronic edition) of “Drug Facts and Comparisons” ([www.factsand-comparisons.com](http://www.factsand-comparisons.com)). ■

1. Hsiao CH, Chuang CC, Tan HY, et al. Methicillin-resistant *Staphylococcus aureus* ocular infection: a 10-year hospital-based study. *Ophthalmology.* 2012 Mar;119(3):522-7.  
2. Munar MY, Singh H. Drug dosing adjustments in patients with chronic kidney disease. *Am Fam Physician.* 2007 May 15;75(10):1487-96.  
3. Miserocchi E, Modorati G, Galli L, Rama P. Efficacy of valacyclovir vs. acyclovir for the prevention of recurrent herpes simplex virus eye disease: A pilot study. *Am J Ophthalmol.* 2007 Oct;144(4):547-51. Epub 2007 Aug 9.  
4. Young RC, Hodges DO, Liesegang TJ, Baratz KH. Incidence, recurrence, and outcomes of herpes simplex virus eye disease in Olmsted County, Minnesota, 1976-2007: the effect of oral antiviral prophylaxis. *Arch Ophthalmol.* 2010 Sep;128(9):1178-83.



# Inflammatory Ocular Surface Disease

Dry eye, while extremely common, is much more complicated than just a lack of tears. Newer strategies take aim at inflammation and lipid dysfunction.

It is now well established that most “dry eye” has a significant inflammatory component.<sup>1</sup> It is also well established that lipid layer dysfunction is the underpinning of symptomatic dry eye in most patients.<sup>2</sup> Given these two findings, a plausible, rational and sound approach to helping patients with dry eye can be developed.

## Start With a Steroid

Regarding inflammation (which results from tear film hyperosmolarity as a result of tear film evaporation), nothing suppresses inflammation like a steroid.

While some people may be helped with topical cyclosporine-A, our clinical experience in caring for patients with dry eye disease

has found that a short course of a potent topical corticosteroid q.i.d. for two weeks, then b.i.d. for two to four more weeks rapidly and efficiently suppresses the inflammatory component and helps patients feel much better more quickly.

## Employ a Lipid-Based Tear

Why meibomian glands lose optimum function over time is not known. Conjecture is the Western diet, our ambient air, and/or hormonal imbalance.

We do know there is keratinization of the acinar linings of these glands that lead to suboptimum lipid production. Further reduc-

## A Simple, Successful, Stepwise Approach to Treating Dry Eye

In summary, our extensive clinical experience in dry eye leads us to this highly successful approach:

- A steroid q.i.d. for two weeks, then b.i.d. for a month.
- A lipid-based artificial tear used frequently as needed.
- 2,000mg of fish oil by mouth every day, preferably with a meal.
- Punctal plugs (if indicated after two to four weeks of steroid therapy).
- If necessary, re-pulse the steroid q.i.d. for a week (usually once or twice throughout the year if/when the patient were to become symptomatic).

## Perspective on Therapeutic Approaches

- “The beneficial effects of cyclosporine A treatment in DED is well established; however, it is clear that many patients with DED do not show a consistent therapeutic response to topical cyclosporine A... [Also] some patients experience bothersome adverse effects (e.g., burning or irritation) that impair medication tolerability.”
- Clinical trials “have demonstrated the efficacy of topical corticosteroid treatment at diminishing symptom severity and minimizing ocular surface staining.”
- “Repetitive short-term pulsatile administration of topical corticosteroids is a promising method of harnessing their beneficial effects, while minimizing the risk of adverse events.”

Stevenson W, Chauhan SK, Dana R. Dry eye disease: an immune-mediated ocular surface disorder. *Arch Ophthalmol.* 2012 Jan;130(1):90-100.

## Cyclosporine vs. Corticosteroids

“Most anti-inflammatory molecules—e.g., cyclosporine—target one or two of the channels that contribute to the inflammatory process but leave the other arms unaffected. The exception is steroids, which are highly effective because they act on multiple arms of the inflammatory system simultaneously.”

Foulks GN. Dry Eye Therapeutics in the Pipeline. 2012 March. Available at: [www.refractiveeyecare.com/2012/03/dry-eye-therapeutics-in-the-pipeline](http://www.refractiveeyecare.com/2012/03/dry-eye-therapeutics-in-the-pipeline).

## Effectiveness of Artificial Tears in the Management of Evaporative Dry Eye

Seventy-five subjects with dry eye were randomly divided into three groups to compare the efficacies of sodium hyaluronate, hydroxypropyl methylcellulose (HPMC) and an emulsion in the management of lipid-deficient dry eye. Each was allocated sodium hyaluronate, HPMC or emulsion eyedrops to be used four times daily for 90 days. Parameters were measured at baseline, 30 days and 90 days.

The emulsion drops were shown to perform best, improving tear stability, and decreasing osmolarity and corneal staining. These results are consistent with improvements in the lipid layer of the tear film as a result of prolonged use of emulsion drops.

McCann LC, Tomlinson A, Pearce EI, Papa V. Effectiveness of artificial tears in the management of evaporative dry eye. *Cornea*. 2012 Jan;31(1):1-5.

## 'Ocular Surface Inflammatory Disease'

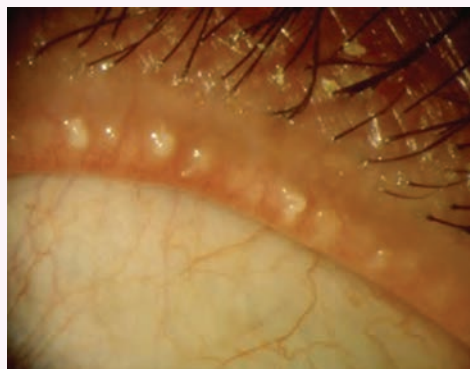"Ocular surface disease, including dry eye, blepharitis/meibomian gland dysfunction and ocular allergy, comprises the most common diagnosis encountered on a daily basis by the comprehensive ophthalmologist."

"The pathophysiology of each of the three ocular surface diseases includes inflammation. While classical teaching is to begin treatment with palliative therapy, such as artificial tears for ocular surface disease, I favor treating these patients more aggressively when I initiate therapy."

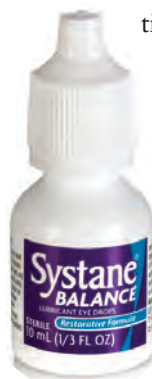"I have suggested we use the term "ocular surface inflammatory disease" to remind us that the core issue in these diseases is inflammation and to lead us to consider more aggressive initial therapy."

"Remissions and exacerbations (of ocular surface inflammatory disease) are common, and occasionally these require another short course of topical steroids. I believe ophthalmologists as a whole are relatively "steroid shy" because of potentially serious complications including steroid-induced glaucoma and secondary cataract, but newer steroids such as loteprednol, which is now also available in an ointment form along with two strengths of suspension, reduce these risks significantly. For the patient who requires a generic alternative for economic reasons, I find fluorometholone is an effective drop with a similar safety profile."

Lindstrom RL. Prophylaxis may be key in treating ocular surface disease, inflammation. *Ocular Surgery News*. 2012 Feb;30(3):3-4.



An eyelid manifesting both blepharitis as well as meibomian gland disease.



tion in meibum results from glandular obstruction.

Common thought would be that if we are not producing sufficient quantities of endogenous lipid, then perhaps exogenous lipid-based artificial tears could help fill this void.

Further realizing that not all patients will like any one brand or approach, we need to be prepared to recommend other products as needed. We initiate therapy with one of the following products:



## Perspective on Dry Eye Therapy

"Increasing the thickness of the tear lipid layer improves the stability of the tear film, suggesting that in selecting a dry eye therapy, an important feature would be the ability of the treatment to mimic the lipid layer of the tears."

"Overall, decades of research has shown a strong correlation between dry eye symptoms and the state of the tear film lipid layer, as well as a clear connection between the status of the lipid layer and the osmolarity of the tear film."

Foulks GN. The correlation between the tear film lipid layer and dry eye disease. *Surv Ophthalmol*. 2007 Jul-Aug;52(4):369-74.

Systane Balance (Alcon), FreshKote (Focus Laboratories) or Refresh Optive Advanced (Allergan).

We encourage patients to use the drops as frequently as they would like during the day, but to always

wait about 15 minutes between using any two different eyedrops.

## Recommend Fish Oil

It is also well established that essential fatty acids (as derived

from flaxseed, fish or krill oil) can enhance the function of the meibomian glands. For this reason, we encourage all of our dry eye patients to begin, and persist with, 2,000mg of fish oil every day. Taking the fish oil with a meal is recommended to aid compatibility with the digestive system.



Of note, these essential fatty acids are beneficial to RPE function, as well.<sup>3</sup> We do all we can to enhance meibomian gland function (which bolsters the lipid layer of the tears).

For those patients who have difficulty swallowing the fish oil capsules, we recommend either Coromega Orange Squeeze ([www.coromega.com](http://www.coromega.com)) or Nordic Naturals



([www.nordicnaturals.com](http://www.nordicnaturals.com)). (We have found Amazon.com to be the least expensive source for these products.) We tell each patient that it may take four to six months of consistent use of these fatty acid supplement products to realize their full benefit.

Regarding meibomian gland function, if the patient is quite symptomatic when first encountered, we often place them on doxycycline 50mg a day for two months. This seems to enhance meibomian

## Supplemental Therapeutic Approaches in Dry Eye Disease (DED)

- “Most of the available evidence suggests that administration of [omega 3] EFAs [essential fatty acids] can lessen DED severity.”
- Regarding omega 3 EFAs, “more evidence is needed to identify the most efficacious forms and doses.”
- “The evidence implicating inflammation in pathogenesis of DED has opened new avenues for the treatment of this complex disorder. The successful application of anti-inflammatory medications in the treatment of DED provides hope for the millions of individuals who daily experience this deleterious condition.”

Stevenson W, Chauhan SK, Dana R. Dry eye disease: an immune-mediated ocular surface disorder. Arch Ophthalmol. 2012 Jan;130(1):90-100.

## Optometric Perspective on Dry Eye

“Topical corticosteroids have been mainstays of the eye care field more so than the newer agent Restasis, and less potent corticosteroid formulations with few side effects are now available. Pulse therapy of corticosteroids has been shown to stave off dry eye symptoms for several months, and patients are more likely to notice the beneficial effects of corticosteroids earlier than with Restasis. For these reasons, and because of the lower cost, corticosteroids are an attractive option for treating dry eye.”

McCabe E, Narayanan S. Advancements in anti-inflammatory therapy for dry eye syndrome. Optometry. 2009 Oct;80(10):555-66.

## Dr. Lemp on Dry Eye

“Although the exact place of inflammation in the stream of events leading to ocular surface distress is not clear, its role is unmistakable.”

“In addition to the use of cyclosporine (Restasis) to modulate immune activity and to suppress inflammation in DED, there is increasing evidence that the use of topical corticosteroids as temporary or pulsed therapy can be useful in reducing the damaging effect of inflammation.”

Lemp MA. Advances in understanding and managing dry eye disease. Am J Ophthalmol. 2008 Sep;146(3):350-356.

## Tear Dysfunction Perspectives

- The term “tear dysfunction” encompasses changes in tear composition rather than tear volume.
- In dry eye, tear osmolarity is 20 to 40mOsm/L greater than normal: 314-364 mOsm/L.
- MMP-9 is increased in dry eye, and regulates epithelial shedding.
- “Over the past decade there has been a trend towards increased use of anti-inflammatory therapies to improve comfort, corneal smoothness and barrier function.”
- Corticosteroids, doxycycline and essential fatty acids have been found to decrease production of a variety of inflammatory mediators and improve corneal epithelial disease.

Pflugfelder SC. Tear dysfunction and the cornea: LXVIII Edward Jackson Memorial Lecture. Am J Ophthalmol. 2011 Dec;152(6):900-909.

gland function more rapidly than essential fatty acid supplementation, which usually takes four to six months to render a significant therapeutic enhancement.

After this initial treatment with doxycycline, we then have the patient begin fish oil supplementation indefinitely.

## Pulse Dose, If Needed

There are a couple of additional pearls here: Regarding corticosteroid suppression, an initial short course of therapy is all that is needed. However, patients tend to slack off their use of artificial tear and/or fish oil supplements therapies, and inflammation recurs.

This is where pulse-dose steroid use (i.e., q.i.d. for one week) can quickly bring symptoms back under control. Studies have shown that such “pulse-dosing” can provide many months of symptomatic relief. (See “*Perspective on Therapeutic Approaches*,” page 12.)

Based on these observations, we have found that a single 5mL bottle of the steroid should be all that is needed for a full year. A thoughtful cost analysis will also show such an approach to be highly cost-effective compared with daily cyclosporine therapy.

## Occlusion Therapy

Punctal plugs appear to be very much underutilized in the treatment of dry eye syndrome. Just make sure topical steroids are used for at least two weeks to quiet the ocular surface before placing the plugs. Otherwise, placement of the plugs could actually worsen symptoms by concentrating pro-inflammatory chemical mediators on the ocular surface.

We always use punctal plugs, and never use intracanalicular plugs or collagen dissolvable plugs. We

## CL Wear and Computer Use on Dry Eyes

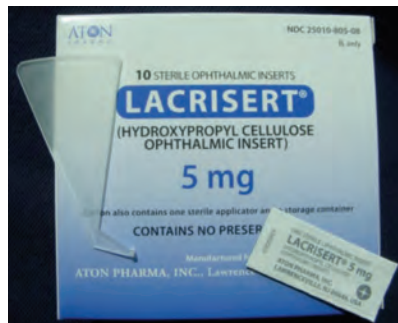“In terms of CL use, after being positioned on the ocular surface, a CL separates coarsely the precorneal tear film into prelens and postlens fractions, causing thinning of the tear film lipid layer, increasing tear evaporation, and eventual tear instability.”

Kojima T, Ibrahim OM, Wakamatsu T, et al. The impact of contact lens wear and visual display terminal work on ocular surface and tear functions in office workers. *Am J Ophthalmol*. 2011 Dec;152(6):933-940.

## Treatment of Sjögren's Syndrome-Associated Dry Eye

- Study used topical methylprednisolone on 53 patients with SS: Dosing was q.i.d. for two weeks, t.i.d. for two weeks, b.i.d. for two weeks, and once daily for two weeks.
- “Significantly improved TBUT and Schirmer test results were observed at the end of the treatment period. Impression cytology revealed a significantly increased number of conjunctival goblet cells. After the first pulse therapy mean drug-free remission time was 56.6 weeks: 11 patients (20.8%) had recurrence of symptoms and signs. After the second pulse therapy, mean drug-free remission time was 72.4 weeks; only 1 patient had recurrence. No serious complications, including intraocular pressure elevation and cataract formation, occurred during the entire follow-up period.”
- Summary: “Although the studies evaluating 1% topical methylprednisolone were open label and retrospective, the effect was robust.”

Akpek EK, Lindsley KB, Adyanthaya RS, et al. Treatment of Sjögren's syndrome-associated dry eye: an evidence-based review. *Ophthalmology*. 2011 Jul;118(7):1242-52.



usually occlude the lower punctum of the more symptomatic eye first to assess symptomatic relief, and then plug the lower punctum of the fellow eye if it is indicated and the patient is pleased with the result.

There are those occasions where we plug both lower puncta at the same visit, depending upon the needs of the individuals. With regard to plugging the upper puncta, this usually results in epiphora. Many companies make a “flow controller” plug that has a very

narrow lumen, and these seem to “Goldilocks” the situation. (Not too big; not too small; just right.) While all punctal plugs perform well, we have been most satisfied with the Odyssey plugs.

Ocular surface inflammatory disease is ubiquitous, and all of us should be highly competent to meet the challenges of these patients. We sincerely hope this approach will enable you to more effectively care for your patients with ocular surface inflammatory disease—or dry eye. ■

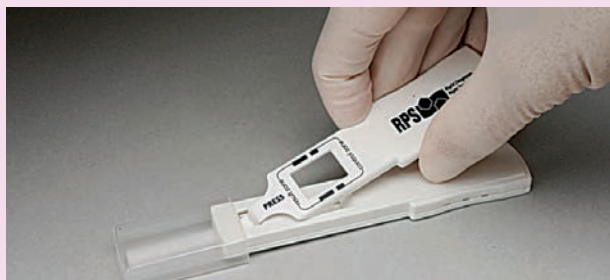1. Dana MR, Hamrah P. Role of immunity and inflammation in corneal and ocular surface disease associated with dry eye. *Adv Exp Med Biol*. 2002;506(Pt B):729-38.
2. Knop E, Knop N, Millar T, et al. The International Workshop on Meibomian Gland Dysfunction: report of the subcommittee on anatomy, physiology, and pathophysiology of the meibomian gland. *Invest Ophthalmol Vis Sci*. 2011 Mar 30;52(4):1938-78.
3. SanGiovanni JP, Chew EY. The role of omega-3 long-chain polyunsaturated fatty acids in health and disease of the retina. *Prog Retin Eye Res*. 2005 Jan;24(1):87-138.

## A New Indicator of Ocular Surface Inflammation on the Horizon

The healthy eye expresses little or no extracellular matrix metalloproteinase. These enzymes are a marker of tissue inflammation that can be assayed to help determine the level of inflammation in dry eye disease.

The InflammaDry Detector is the second in-office product that Rapid Pathogen Screening, Inc. ([www.rpsdetectors.com](http://www.rpsdetectors.com)) has developed to assist in ophthalmic clinical decision-making. This simple device can quickly provide a highly sensitive and specific assay of MMP-9, the specific MMP marker for inflammation in the setting of ocular surface inflammation. We anticipate that having this knowledge will allow us to know if significant inflammation is present, and then after a course of treatment with an anti-inflammatory medicine, to assess the medication's efficacy.

The InflammaDry Detector is currently pending FDA approval.



### RPS InflammaDry Detector

- Detects presence of MMP-9 (cytokine—a reliable marker for ocular surface inflammation).
- MMP-9 is not found in normal eyes.
- May predict response to cyclosporine, doxycycline and steroids.
- Procedure is simple, taking 10 minutes.
- Cost is approximately \$15.

Kent C. Inflammation Check: A New Test for Dry Eye. *Rev Ophthalmol.* 2011 July;18(7):22-5.

### Inflammation and Dry Eye Disease (DED)

- “Inflammation has a prominent role in the development and amplification of the signs and symptoms of DED.”
- “Regardless of the origin, a self-perpetuating cycle of inflammation develops that is central to the pathogenesis of DED.”
- “Doxycycline ameliorates DED by inhibiting the activity of MMPs, primary MMP-9, promoting ocular surface integrity.”

Pflugfelder SC. Tear dysfunction and the cornea: LXVIII Edward Jackson Memorial Lecture. *Am J Ophthalmol.* 2011 Dec;152(6):900-909.

## MGD Takes the Heat

Donald Korb, O.D., and his research team in Boston, have spent decades researching the entire realm of lipid-deficient tears. The culmination of this research is the FDA approval of their LipiFlow technology via TearScience, Inc. ([www.tearscience.com](http://www.tearscience.com)). This device precisely heats the meibomian glands from the inside of the eyelids (where the posteriorly-located glands reside). Once heated to the optimum temperature, the device then massages and expresses the glandular contents. This process only takes about 12 minutes, and has been shown to give significant relief from dry eye symptoms for many months. Whether omega-3 or doxycycline supplementation can extend this effect is worth further investigation, but is not known at this time.

Keep in mind that tear hyperosmolarity is what drives ocular surface inflammation, and it is a deficient lipid layer that gives rise to premature evaporation, which causes tear film to become hyperosmotic. The LipiFlow device, at least in 2012, is not a first-line intervention, but may be a “lifesaver” for many patients who are still symptomatic after standard medical intervention has been exhausted.



By understanding this cascade of events in dry eye disease, one can then devise a rational therapeutic intervention. The frustrating aspect of LipiFlow therapy for meibomian gland disease is that these marvelous devices are very expensive. That means that the bulk of initial acquisitions will likely

be made by corneal subspecialists and dry eye centers. Our hope is that in the near future, LipiFlow devices will be housed in offices within reasonable driving distances of all of our patients so that the optometric/ophthalmologic “comanagement” system can be utilized to provide state-of-the-art care for all of our patients with dry eyes. Hopefully, in time, most optometric offices will have these devices, as well. [Note: Bill Rafferty, O.D., at the Duke University Eye Center is one of the experts on the LipiFlow technology. Feel free to contact him for information at [wraff2004@aol.com](mailto:wraff2004@aol.com).]

Greiner JV. A single LipiFlow thermal pulsation system treatment improves meibomian gland function and reduces dry eye symptoms for 9 months. *Curr Eye Res.* 2012 Apr;37(4):272-8.

# Innovations in Instrumentation

Keeping current with technology can be rewarding. For example, OCT is not (yet) considered standard-of-care, but these instruments are certainly very helpful.

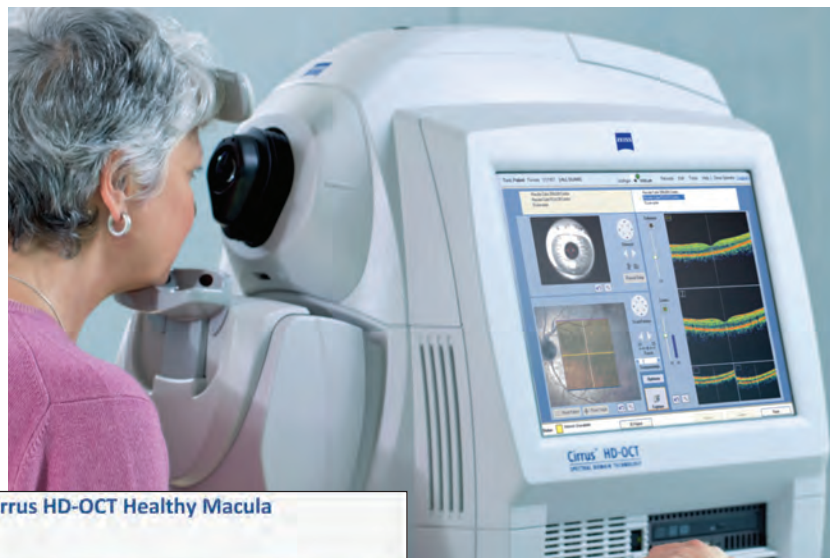
One-fourth of optometrists say that they have obtained, or are considering obtaining, a spectral-domain optical coherence tomographer, according to *Review of Optometry's* most recent Technology Survey.

In addition, here is more novel and helpful equipment for your consideration.

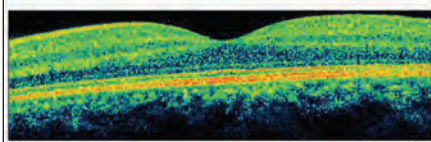
## HD-OCT

Optical coherence tomography (OCT) is arguably the single most important advance in ocular disease assessment in the past 10 years. (Another notable advance is the advent of corneal pachymeters, which have been an enormous help in assessing both the risk for development and the rate of progression of glaucomatous disease. Hopefully, all optometric physicians have a pachymeter in their offices by now.)

First came the time-domain technology, which revolutionized nerve fiber layer and macular tissue assessments. These are still wonderful instruments, but they have been superseded by the newer high-definition Fourier-domain instruments. Any one of these high-definition instruments is now recommended (in concert with a 10-2 visual field)



Cirrus HD-OCT Healthy Macula



**Spectral (or Fourier) domain optical coherence tomography has superseded time-domain OCT (though the latter is still wonderfully useful technology).**

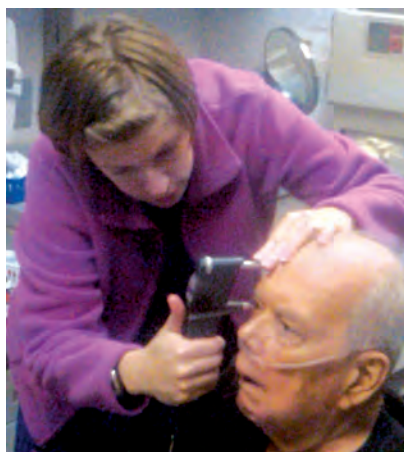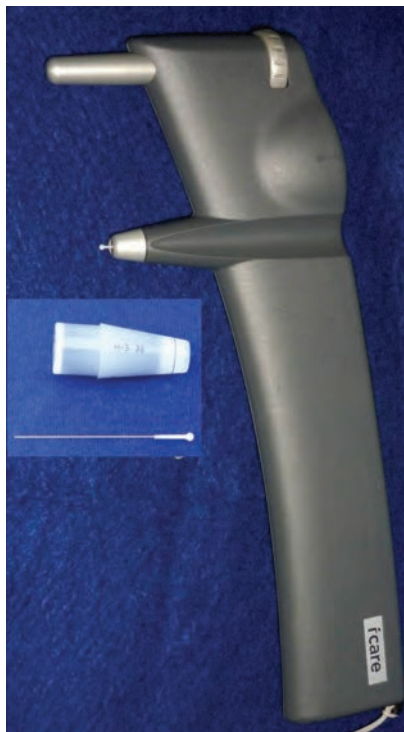in the assessment of patients taking Plaquenil (hydroxychloroquine, Sanofi-Aventis), based on recent articles.<sup>1,2</sup>

These HD-OCT instruments are absolutely amazing, and bring enormous diagnostic firepower to a broad array of eye diseases.

Bottom line: Plan to purchase one of these high-definition OCT instruments as soon as it is practical for you.

## Icare Tonometer

The Icare tonometer (Icare USA) is a magnificent upgrade from the aged air-puff device. This handheld device atraumatically touches the cornea, and gives a quick display of the intraocular pressure. No eye-drops are needed, and it can even be done with a soft contact lens in place (as a screening) for IOP. This “rebound” technology does not replace Goldmann applanation



**The Icare tonometer is literally handy, and a welcome improvement over the old air-puff instrument.**

tonometry, as it is not (at least yet) intended to be used in glaucoma patient care, but simply to upgrade the optometric screening of IOP to be much more patient-friendly. We encourage you to at least investigate this new technology ([www.icaretonometer.com](http://www.icaretonometer.com)).

Of note, the Icare company has

applied to the FDA for approval of a rebound tonometry technology that patients can perform themselves at home to collect IOP data outside of office hours. This may be a major breakthrough in obtaining a more accurate characterization of patients' IOP profiles. While not yet approved by the FDA, we certainly hope that this, or some similar technology, will become available soon.

### Own Eye Magnifier

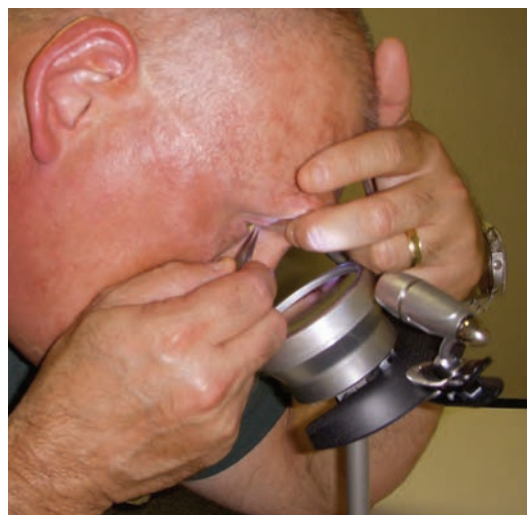The Own Eye magnifier is an ingenious device that was developed by a gentleman engineer in Australia to help his wife—who had chronic, recurrent, painful trichiasis—pluck her offending lashes herself.

The Own Eye magnifier view is very similar to that of a slit lamp view, and indeed can be immensely helpful to many such patients with trichiasis.

In addition to helping people “self-care” for their trichiasis, we use this magnifier in our examination rooms to quickly and efficiently allow selected patients their problems for themselves—e.g., trichiasis, blepharitis, foreign body, etc. We have found this very helpful.

So, if don't have a high-tech video system in your practice, this affordable magnifier is a wonderful device with a wide variety of clinical and personal applications.

Its light source is two (or three, if you wish) battery-powered side-view lights that very easily



**The Own Eye Magnifier was developed out of necessity. The inventor created it for his wife, who had painful trichiasis, and needed a better way to see her own eye.**

click on and off. We encourage you to explore the applicability of this technology for you, and more importantly, for your patients. The Own Eye magnifier costs about \$250 plus shipping from Australia ([www.owneye.com.au](http://www.owneye.com.au)). ■

1. Michaelides M, Stover NB, Francis PJ, Weleber RG. Retinal toxicity associated with hydroxychloroquine and chloroquine: risk factors, screening, and progression despite cessation of therapy. *Arch Ophthalmol.* 2011 Jan;129(1):30-9.

2. Marmor MF, Kellner U, Lai TY, et al; American Academy of Ophthalmology. Revised recommendations on screening for chloroquine and hydroxychloroquine retinopathy. *Ophthalmology.* 2011 Feb;118(2):415-22.

# Pearls, Pointers and Perspectives

You need to open a lot of oysters before you find a pearl. We've picked up a few of them in our combined 60+ years of clinical experience. Here we share them with you.

In our roles as optometrists and educators, we speak with many doctors and patients, and we receive many interesting questions by letter, by e-mail, and from our colleagues at our lectures.

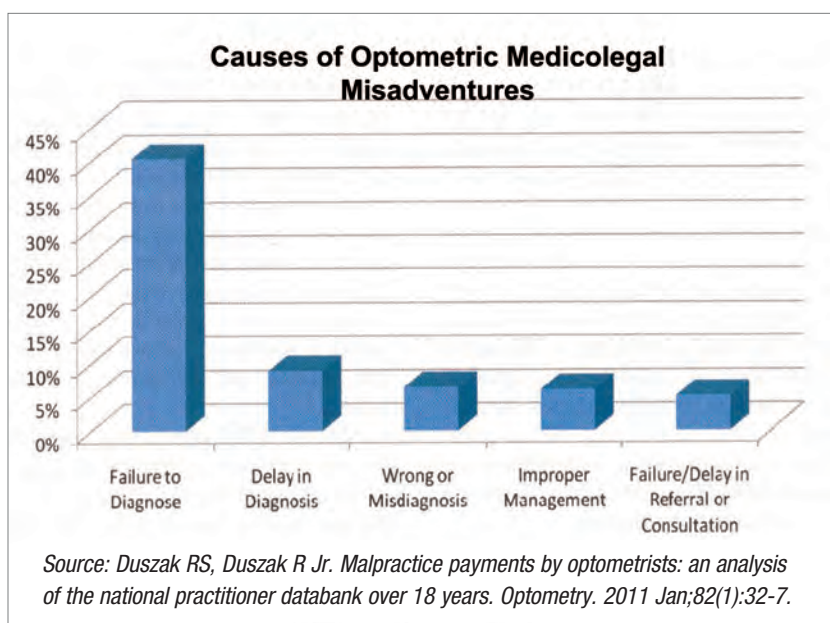
Here, we have selected numerous pearls, pointers and perspectives that we believe will benefit other clinicians who, like us, are in “the trenches” caring for patients every day.

- Be keenly attentive in your clinical examination. By far, the most common reason optometrists are successfully sued is “failure to diagnose.” (See bar graph below.)

- No clinical outcome is 100% assured, so verbally encourage your patient to call or follow up if his/her condition is not improving in two or three days. We have seen many patients over the years

who sought care elsewhere (that is, with us) when their condition failed to improve. This is most always a result of poor doctor/patient communication. Be sure to let your patients know you care and are readily available if they are not improving.

- Many patients are led to believe that if a contact lens is FDA-approved, and the manufacturers’



**The main reason optometrists are successfully sued is “failure to diagnose,” not for actively providing medical care.**

## Perspective on Overnight Contact Lens Wear

“From a public health perspective, it is important to recognize that the incidence of ulcerative keratitis in the United States is substantially higher than previously reported. Although it is well known that contact lens wear has been and continues to be a major risk factor for ulcerative keratitis, this knowledge has not effectively reduced the occurrence of the disease in contact lens wearers. Discouraging patients from sleeping while wearing extended-wear contact lenses, despite the fact that those lenses are approved for overnight wear, may also decrease the risk of ulcerative keratitis.”

Jeng BH, Gritz DC, Kumar AB, et al. Epidemiology of ulcerative keratitis in Northern California. *Arch Ophthalmol*. 2010 Aug;128(8):1022-8.



ads indicate one can sleep in them, then doing so for a month at a time must be a safe behavior. As compassionate eye physicians, we must share with these patients the clinical reality that when any soft contact lens is worn overnight, the risk of developing ulcerative keratitis is greatly increased over that of daily wearing schedules.

- Many patients complain of troublesome excessive mucus production. If after a trial of topical steroids and a good lipid-based artificial tear for a couple of weeks, the mucus remains problematic, we strongly suggest you prescribe a 5% ophthalmic solution of Mucomyst (acetylcysteine, Bristol-Myers Squibb) q.i.d. for a week or two.



This highly effective mucolytic must be formulated at an ophthalmic compounding pharmacy from systemic 10% or 20% acetylcysteine (which is used in pulmonary medicine to reduce bronchial mucus excess).

It does smell like rotten eggs, so warn the patient in advance. Storage in the refrigerator is recommended.

- As primary eyecare physicians, we should consistently do the following:

- Compassionately encourage your smoking patients to chat with their primary care physician about various medicines and options to help them stop.

- Have your staff check the blood pressure of your patients over a certain age (perhaps 35 or 40). This is especially important to do if the patient has a retinal or optic nerve event, or if the patient is a glaucoma suspect with lower IOPs.

### Contrary View on the Monocular Trial

The therapeutic monocular trial is an inexact, yet a very helpful, maneuver for most patients most of the time when initiating glaucoma therapy. While groups of “glaucoma pundits” keep this concept in controversy, our combined 60+ years of intensive glaucoma patient care have proved to us its practical utility in the clinical setting. The points from this article are worth considering:

- Spontaneous IOP variation might mask or mimic the true drug effect.
- IOP change in one eye may not adequately predict IOP effect in the fellow treated eye.
- “There is no useful information about drug efficacy to be gained by testing only one eye if both need to be treated.”
- “The most reliable method of assessing drug effectiveness is by performing a series of pre- and post-treatment IOP measurements, but in practice this has obvious resource implications.”
- “The monocular trial provides a significantly more accurate estimate of the therapeutic response when initiating prostaglandin monotherapy in untreated eyes. It is particularly helpful in avoiding overestimation of effectiveness and so reducing the number of patients on inadequate treatment.”
- And, just for perspective: “Glaucoma is a chronic and slowly progressive disease, and most patients do not require acute IOP reduction.”

King AJ, Uppal S, Rotchford AP, et al. Monocular trial of intraocular pressure-lowering medication: a prospective study. *Ophthalmology*. 2011 Nov;118(11):2190-5.

- Recommend patients discuss with their primary care physician the use of fish oil and diets rich in lutein.

- Remind patients to wear safety glasses when playing contact sports.

- Remind patients who wear soft contacts not to sleep in their lenses, and to adhere to the recommended schedule for replacing them. Remind them to replace the contact lens case quarterly.

We need to continually focus on our fiduciary responsibilities (i.e., trust and confidence) in the care of our patients, not just their eyes.

- We try to be cost-conscious when prescribing. There are times when we reluctantly allow a generic switch by the pharmacist. We say “reluctantly” because we have already exercised clinical judgment when initially prescribing, so had we felt a generic (or an alternate medicine) would be permissible, we

would have written for it in the first place. Still, as clinicians, we need to be aware of the cost of various medicines, so that we can counsel patients about the costs before they present to the pharmacy.

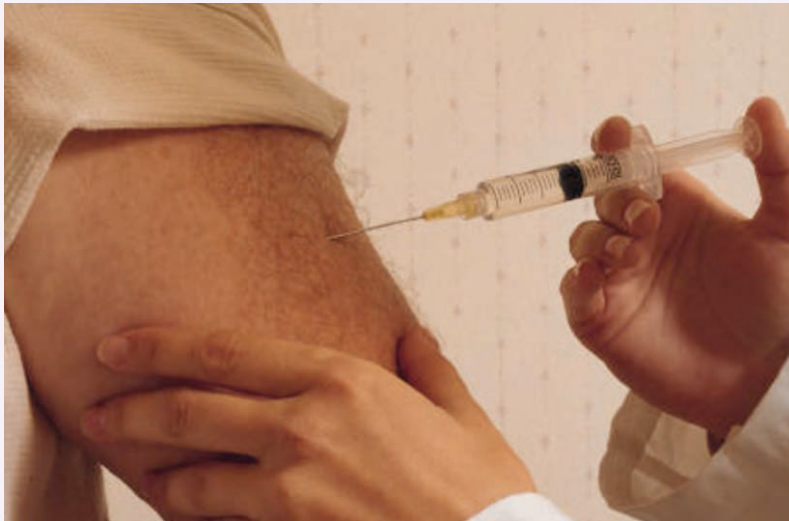- For all the talk about “evidence-based medicine,” most such proclamations are based on all sorts of studies with all sorts of shortcomings, most notably the ability to generalize the findings to the individual sitting in your chair.

- The terms “steroids” and “artificial tears” can no longer be intelligently used in isolation. There are two distinguishing separate subsets of both. There are *ketone* steroids and *ester* steroids, and there are *aqueous-based* artificial tears and *lipid-based* artificial tears. The unique pharmacological characteristics of these two classes require distinguishing language in most cases.

## Perspective on Medical Evidence

**“Most of what physicians do is based on ‘shared wisdom’; interventions for which we have rock-solid, definite data from randomized trials are very much in the minority. Since ‘experience’ and medical ‘culture’ vary, there are wide variations in the way perfectly well-meaning physicians treat the same condition.”**

Sommer A. On the nature of, and response to, medical evidence. *Am J Ophthalmol.* 2010 Feb;149(2):182-3.



### Zostavax

Encourage all patients over age 50 to speak with their primary care physician about getting the shingles vaccine, Zostavax (live attenuated zoster virus vaccine, Merck). This vaccine reduces the risk of getting shingles by 50% or more. And, even if the patient does have a varicella zoster outbreak, the vaccine dampens its clinical expression (as compared to not having had the vaccine).

- Vaccine for prevention of shingles in adults age 50 and older.
- Marketed by Merck as Zostavax and is given as a single dose by injection.
- Anyone who has been infected by chickenpox (more than 90% of adults in U.S.) is at risk for developing shingles.
- Zostavax reduced the risk for developing herpes zoster by 69.8% compared to placebo.
- Contraindicated if Hx of allergy to gelatin, neomycin; Hx of acquired immunodeficiency states; or pregnancy.
- Duration of protection after vaccination unknown.

Update on Herpes Zoster Vaccine: Licensure for Persons Aged 50 Through 59 Years. *Morbidity and Mortality Weekly Report.* Centers for Disease Control and Prevention. November 11, 2011;60(44):1528. Available at: [www.cdc.gov/mmwr/preview/mmwrhtml/mm6044a5.htm](http://www.cdc.gov/mmwr/preview/mmwrhtml/mm6044a5.htm).

- The best thing to do is read the journals consistently, and look for consistent corroborating studies over time to begin to get a sense of the best course of action for your patients.

Many of us do not devote ourselves to reading the literature as much as we should. ■

### Ophthalmic Journal References

- *Ophthalmology* (Journal of American Academy of Ophthalmology) ([aajournal.org](http://aajournal.org))
- *American Journal of Ophthalmology* ([ajo.com](http://ajo.com))
- *Archives of Ophthalmology* ([archophth.ama-assn.org](http://archophth.ama-assn.org))
- *Survey of Ophthalmology* ([www.elsevier.com](http://www.elsevier.com))
- *Audio-Digest Ophthalmology* ([audiodigest.org](http://audiodigest.org))
- *Review of Ophthalmology* ([revophth.com](http://revophth.com))
- OphSource ([ophsource.org](http://ophsource.org)), convenient online access to ophthalmology publications including:
  - *Ophthalmology*
  - *American Journal of Ophthalmology*
  - *Survey of Ophthalmology*
  - *Advanced Ocular Care* ([www.advancedocularcare.com](http://www.advancedocularcare.com))

# Dress for Success!

Like it or not, most patients prefer you to wear a white coat. The coat has advantages: Patients are more compliant and confident with doctors who dress the part.

**P**atients expect their doctors to...well, look like doctors! Yet we see many physicians looking less “doctor-like” now than in years past.

We were recently contacted by an optometric leader in the northwestern part of the U.S. to ask our permission to use some of our quotes in their state’s newsletter. This inquiry is what prompted us to revisit the always timely issue of appropriate professional dress.

So what do your patients prefer you to wear?

One study, which reviewed 31 other articles on this question, found that patients do indeed want their doctors to dress professionally, preferably in a white coat with a nametag.<sup>1</sup>

In addition to the white coat, patients tend to favor more formal dress, and give high ratings to a shirt and tie, dress pants, skirts or dresses, and dress shoes.<sup>2</sup>

Bottom line: We must look neat, clean, well-groomed and as healthy as we can—and wearing professional dress certainly doesn’t hurt. ■

1. Brandt LJ. On the value of an old dress code in the new millennium. *Arch Intern Med.* 2003 Jun 9;163(11):1277-81.

2. Rehman SU, Nietert PJ, Cope DW, Kilpatrick AO. What to wear today? Effect of doctor’s attire on the trust and confidence of patients. *Am J Med.* 2005 Nov;118(11):1279-86.

## First Impressions: Patients Trust the White Coat

Respondents overwhelmingly favor physicians in professional attire with a white coat...and have shown a strong intention to trust, to comply with their recommendations, and to return for follow-up to these physicians. Respondents also expressed the most confidence in physicians wearing professional attire with a white coat.

Rehman SU, Nietert PJ, Cope DW, Kilpatrick AO. What to wear today? Effect of doctor’s attire on the trust and confidence of patients. *Am J Med.* 2005 Nov;118(11):1279-86.

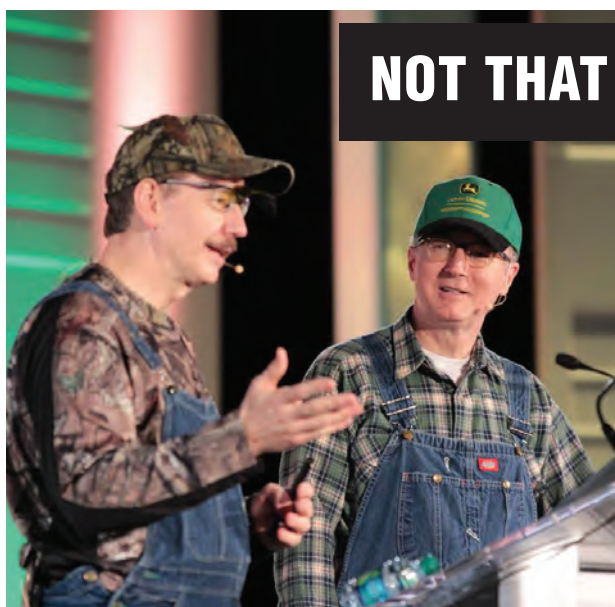

Photo: SECO International