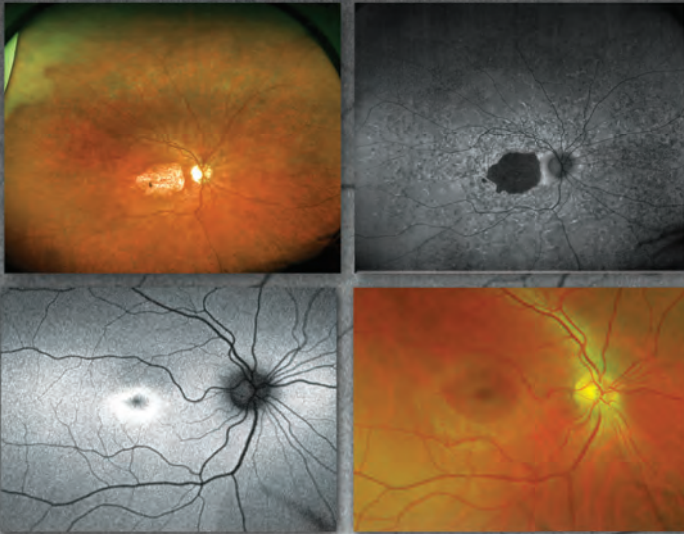


SUPPLEMENT TO

APRIL 2012

# REVIEW<sup>®</sup> OF OPTOMETRY

www.revoptom.com



## ▶▶ The Clinical Utility of Fundus Autofluorescence Imaging

*By Jeffrey D. Gerson, O.D., F.A.A.O.*

## ▶▶ The Role of the Vitreous in Retinal Disease

*By Carolyn E. Majcher, O.D., Andrew S. Gurwood, O.D., F.A.A.O., Dipl., and Julie K. Hutchinson, O.D.*

## ▶▶ Earn 1 CE Credit: A Case of Late-Onset Leber's Hereditary Optic Neuropathy

*By Carol Aune, B.S., O.D., and James Walters Ph.D., O.D.*

## ▶▶ A Case of Suspected Retinal Melanocytoma

*By W. Lee Ball, O.D., F.A.A.O.*

# The 9<sup>th</sup> Annual Guide to RETINAL DISEASE



## The Clinical Utility of Fundus Autofluorescence Imaging

By Jeffrey D. Gerson, O.D., F.A.A.O.

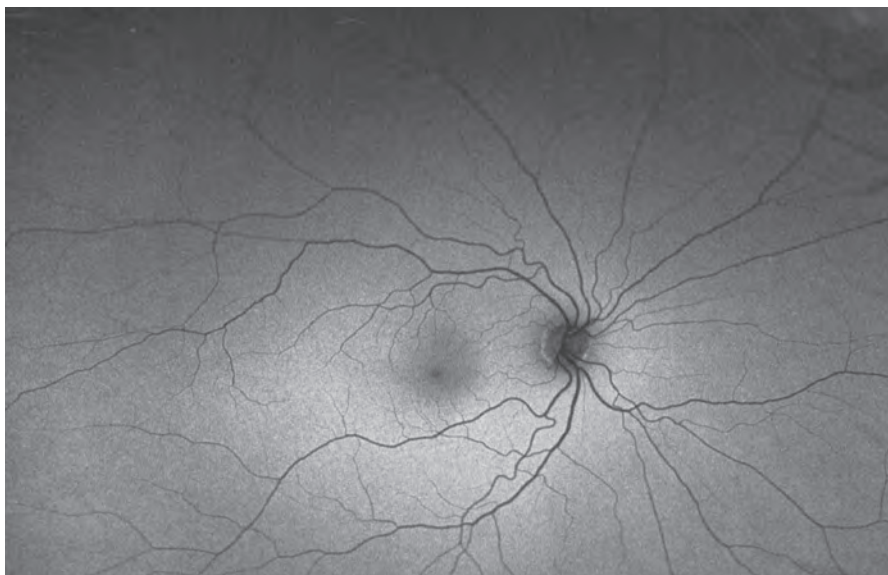
**THE HISTORIC STANDARD** for the documentation of posterior segment findings has been fundus photography. Generally, the need for fundus photography is substantiated by the detection of a clinical finding that warrants documentation for future reference. However, we are now learning that there is more to be seen than what conventional fundus photography can capture.

Although there have been references to fundus autofluorescence (FAF) in the medical literature for more than 35 years, this approach is only now becoming a more mainstream imaging technique.<sup>1</sup> Not only can FAF be an ideal tool for documentation, but also it will often serve as a diagnostic modality because the device can elucidate many conditions that are not visible through traditional means of examination or other technologies. Additionally, FAF can be used to detect structural abnormalities and predict functional deficits.<sup>2,3</sup> These abilities go beyond what optical coherence tomography (OCT), fluorescein angiography (FA), electrophysiology and other imaging technologies can provide.

### How does FAF Work?

FAF provides an objective, non-invasive measurement of the retinal pigment epithelium's (RPE's) metabolic activity. A measurement of FAF is decreased by a loss of photoreceptor cell integrity and is increased by abnormal RPE behavior and/or function.

Autofluorescence of the retina and macula typically will appear a uniform gray color, with darker vasculature due to blood absorption and a darker optic nerve head due to a lack of RPE. In the fovea, there is reduced FAF, or mild



Normal fundus autofluorescence (FAF) image of a patient's posterior pole.

hypo-FAF secondary to xanthophyll pigment absorbing the signal. Areas of hyper-autofluorescence or hypo-autofluorescence may be indicative of an abnormality in RPE activity that is either active or has already occurred. These changes in fluorescence are visually reminiscent of those found in FA (although they are caused by different fundamentals). More specifically, while FA reveals vascular leakage, FAF actually shows metabolic activity.

From a technical standpoint, FAF permits topographic mapping of lipofuscin distribution in the RPE as well as other fluorophores that occur in the outer retina and the sub-neurosensory space.<sup>4</sup> This is important, because accumulation of lipofuscin is a significant marker for aging of metabolically active cells, particularly those comprising the RPE.<sup>5</sup>

Excess lipofuscin has been indicted in a variety of retinal disorders—from inherited diseases, such as macular pattern

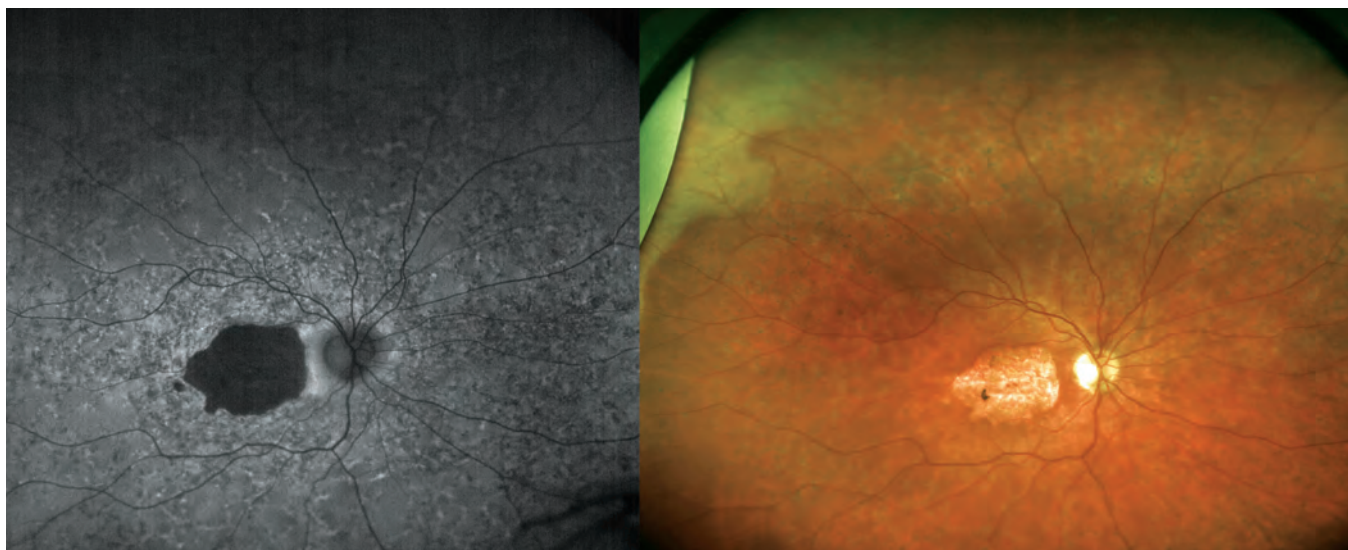
dystrophies and Stargardt's disease, to age-related macular degeneration and other conditions that involve impaired RPE cell function. Lipofuscin builds up through incomplete degradation of photoreceptor outer segments and incomplete release of degraded material.<sup>6</sup>

FAF, however, is not an "all-telling" diagnostic modality. In some cases of blinding pathology, the FAF appearance may be perfectly normal—even if the RPE-photoreceptor complex is unaffected.

### Clinical Applications of FAF

There are several areas of practical interest where FAF has the potential to change how we diagnose and/or treat patients:

- **Early macular disease detection.** Understanding the extent of RPE defects of the posterior pole as well as other macular diseases may be accomplished via peripheral FAF imaging, as evidenced in multiple clinical trials.<sup>7</sup> In fact,



This patient presented with Stargardt's macular dystrophy (FAF left, color fundus right). The FAF image illustrates the extent of macular disease more clearly.

peripheral changes may pre-date macular changes in AMD, central serous chorioretinopathy (CSCR) and many other diseases thought to be specific to the macula. Using peripheral FAF as a screening tool for such macular conditions may help to predict their future onset and permit early initiation of disease-modifying treatments. For instance, if peripheral changes are indicative of early macular degeneration, then lifestyle modification can be instituted to prevent visually significant changes associated with AMD.

• **Plaquenil retinopathy.** In 2011, the screening guidelines for Plaquenil (hydroxychloroquine, Sanofi-Aventis) toxicity were updated in an article published in *Ophthalmology*.<sup>8</sup> Screening for Plaquenil retinopathy is more accurately performed through FAF than conventional fundoscopic observation.<sup>9</sup> Historically, clinical observation and visual fields were thought to be adequate for timely diagnosis of macular toxicity secondary to Plaquenil use. However, we now know that these screening techniques will not facilitate

an early diagnosis, but rather the detection of an already advanced disease state.<sup>9</sup>

We also know that macular toxicity is more common than once believed, partially due to previous techniques not being accurate enough to detect mild pathologic changes. The updated guidelines call for objective testing, which is to include FAF, spectral domain OCT and/or multi-focal electroretinogram testing.<sup>8</sup> This updated screening protocol is particularly significant because of the sheer number of patients who use Plaquenil.

• **CSCR.** When we see patients with CSCR, we often wonder if it is a first occurrence or a recurrence, how much global RPE damage there is, and what their visual outcome will be. FAF can help us answer these questions, and even address the concern of whether the patient has CSCR.<sup>10</sup> If the individual has CSCR, FAF may be used to help guide our follow-up schedule and/or referral for treatment. Studies have shown that FAF appearance can be a predictor of visual outcome and function in patients with CSCR.<sup>11</sup> Additionally,

it may help educate a patient on the chronic and diffuse nature of this condition.

• **AMD and GA.** The extent and progression of AMD can be closely monitored with FAF. Further, FAF may potentially indicate which patients are at an increased risk for the development of geographic atrophy (GA).<sup>12</sup> FAF also may help evaluate the potential effectiveness of various treatment modalities—especially if the patient has GA.

Currently, several pharmaceutical companies are using FAF to evaluate the treatment efficacy of several developmental drugs for GA (oral, injectable and topical medications). This is an important consideration, because several studies have shown that changes documented on FAF imaging often precede GA or its expansion.<sup>13,14</sup> Areas of new GA expansion initially may appear bright on FAF imaging, and then subsequently exhibit a dark or “dead” appearance on various areas of the RPE.

Although we believe AMD to be a macular disease that only occurs in the posterior pole, results from the Reykjavik Eye Study show that

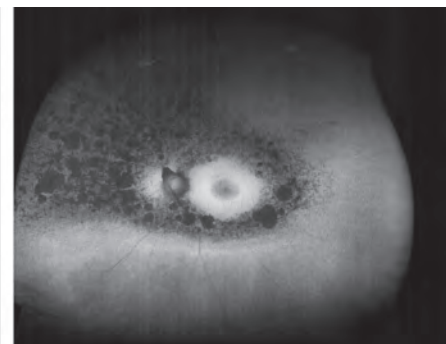
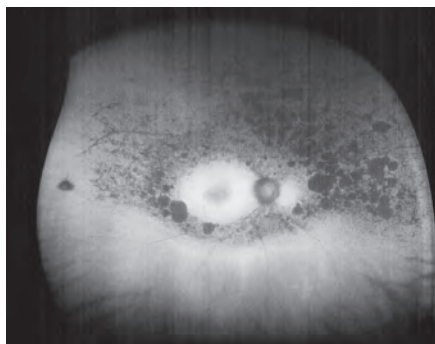
peripheral and posterior pole pathologies regularly coexist and are often signs of each other.<sup>15</sup> Additionally, there are advantages to having FAF documentation for patients with neovascular AMD, because the technology may help predict visual outcome—especially in patients who have developed choroidal neovascularization within six months or less of diagnosis.<sup>16</sup>

### A Glance at Current FAF Devices

Fortunately, it is now possible (and practical) to include this technology in your practice. The two primary companies that readily offer devices with FAF imaging capabilities are Heidelberg Engineering and Optos.

• **Spectralis (Heidelberg Engineering)** offers BluePeak blue laser autofluorescence technology that is being used in several clinical trials. In particular, the company is using BluePeak to evaluate the potential efficacy of drugs that prevent the onset or enlargement of GA in patients with AMD.

• **Daytona (Optos)** was first unveiled at the 2011 American Academy of Optometry meeting in Boston. This device incorporates FAF technology into its existing



We diagnosed this patient with retinitis pigmentosa (O.D. left, O.S. right).

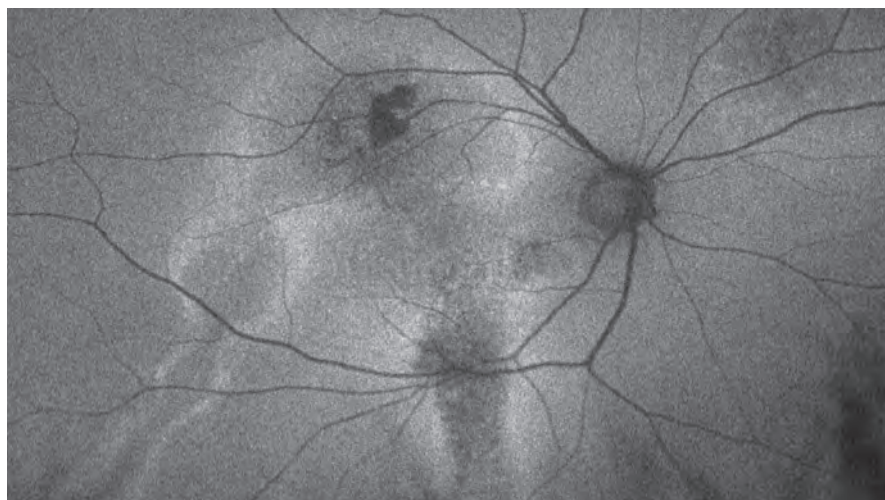
widefield imaging platform in a tabletop design that offer unprecedented views of peripheral changes.<sup>17</sup> Additionally, this device exhibits its strong sensitivity in the detection of macular-specific diseases, providing results that are in close agreement to those obtained via traditional fundus photography.<sup>17</sup>

Whether your practice currently has access to FAF imaging, this technology soon will become even more essential to the proper care and will be able to provide our patients with the most accurate information about their conditions as well as recommend the best treatment options available. ■

*Dr. Gerson is in private practice in Shawnee, Kans. He also sees patients*

*on a referral basis for colleagues. He is a fellow of both the American Academy of Optometry and the Optometric Retina Society.*

1. Miller SA. Fluorescence in Best's Vitelliform dystrophy, lipofuscin and fundus flammaculatus. *Br J Ophthalmol.* 1978 Apr;62(4):256-60.
2. Querques L, Querques G, Forte R, Souied EH. Microperimetric Correlations of Autofluorescence and Optical Coherence Tomography Imaging in Dry Age-Related Macular Degeneration. *Am J Ophthalmol.* 2012 Feb 7. [Epub ahead of print]
3. Seidensticker F, Neubauer AS, Wasfy T, et al. Wide-field fundus autofluorescence corresponds to visual fields in chorioretinitis patients. *Clin Ophthalmol.* 2011;5:1667-71.
4. Schmitz-Valckenberg S, Holz FG, Bird AC, Spaide RF. Fundus autofluorescence imaging: review and perspectives. *Retina.* 2008 Mar;28(3):385-409.
5. Terman A, Brunk UT. Oxidative stress, accumulation of biological garbage, and aging. *Antioxid Redox Signal.* 2006 Jan-Feb;8(1-2):197-204
6. Wing GL, Blanchard GC, Weiter JJ. The topography and age relationship of lipofuscin concentration in the RPE. *Invest Ophthalmol Vis Sci.* 1978 Jul;17(7):601-7.
7. Lois N. Fundus Autofluorescence in Stargardt macular dystrophy-fundus flavimaculatus. *Am J Ophthalmol.* 2004 Jul;138(1):55-63.
8. Marmor MF, Kellner U, Lai TY, et al. Revised recommendations on screening for chloroquine and hydroxychloroquine retinopathy. *Ophthalmology.* 2011 Feb;118(2):415-22.
9. Marmor M. Comparison of screening procedures in hydroxychloroquine toxicity. *Arch Ophthalmol.* 2011 Dec 22. [Epub ahead of print]
10. Lindner E, Weinberger A, Kirschkamp T, et al. Near-infrared autofluorescence and indocyanine green angiography in central serous chorioretinopathy. *Ophthalmologica.* 2012;227(1):34-8.
11. Imamura Y, Fujiwara T, Spaide RF. Fundus autofluorescence and visual acuity in central serous chorioretinopathy. *Ophthalmology.* 2011 Apr;118(4):700-5.
12. Csutak A, Lengyel I, Jonasson F, et al. Agreement between image grading of conventional (45°) and ultra wide-angle (200°) digital images in the macula in the Reykjavik eye study. *Eye (Lond).* 2010 Oct;24(10):1568-75.
13. Holz FG, Bellman C, Staudt S, et al. Fundus autofluorescence and development of geographic atrophy in age-related macular degeneration. *Invest Ophthalmol Vis Sci.* 2001 Apr;42(5):1051-6.
14. Schmitz-Valckenberg S, Bindewald-Wittich A, Dolar-Szczasny J, et al. Correlation between the area of increased autofluorescences surrounding geographic atrophy and disease progression in patients with AMD. *Invest Ophthalmol Vis Sci.* 2006 Jun;47(6):2648-54.
15. Lengyel I. AMD-like pathologies at the peripheral fundus: Reykjavik Eye Study: An ultra-wide angle (200°) and autofluorescence digital image grading study. Abstract presented at Association for Research in Vision and Ophthalmology 2009.
16. Dandekar SS, Jenkins SA, Peto T, et al. Autofluorescence imaging of choroidal neovascularization due to age-related macular degeneration. *Arch Ophthalmol.* 2005 Nov;123(11):1507-13.
17. Csutak A. Agreement between image grading of conventional (45°) and ultra wide-angle (200°) digital images in the macula in the Reykjavik Eye Study. *Eye (Lond).* 2010 Oct;24(10):1568-75.



We confirmed the presence of chronic central serous chorioretinopathy with FAF imaging.

## The Role of the Vitreous in Retinal Disease

By Carolyn E. Majcher, O.D., Andrew S. Gurwood, O.D., F.A.A.O., Dipl., and Julie K. Hutchinson, O.D.

**THE VITREOUS** is an extracellular matrix that forms a transparent hydrophilic gel. It is principally composed of water (98% to 99.7%).<sup>1,2</sup> The vitreous functions as a pathway for nutrients to reach the lens and retina; provides structural support that stabilizes the volume of the globe; and may regulate eye growth and shape during development.<sup>1,3</sup>

In order to maintain transparency, it functions as a barrier to cellular invasion and diffusion of macromolecules from surrounding intraocular tissues.<sup>2</sup> In the gel state, the vitreous lowers oxygen tension in the retina and the lens.<sup>2,4</sup> This becomes evident when cataract formation is hastened following pars plana vitrectomy (PPV). When the vitreous is removed, a sharp spike in lens oxygenation fuels lenticular opacification.<sup>2,4</sup>

Here, we'll examine the vitreous humor's role in the development and severity of several sight-threatening retinal conditions, including posterior vitreous detachment (PVD), age-related macular degeneration (AMD), retinal vein occlusion, diabetic macular edema (DME) and vitreomacular traction (VMT) syndrome.

### Vitreous Anatomy

The vitreous comprises about 80% of the total globe volume. It can be divided into two parts: the central nucleus and the posterior cortex.<sup>1,5</sup> The central nucleus is a true biological gel with a lower collagen fibril density than the cortex.<sup>1</sup> Collagen fibrils in this region generally run in an anterior-to-posterior direction. Anteriorly, the fibrils blend with those of the basal vitreous; posteriorly, they insert into the surrounding vitreous cortex shell

(cortical vitreous).<sup>2</sup>

The cortical vitreous is a thin layer (100µm to 300µm) that lies adjacent to the lens, ciliary body and zonules anteriorly, and adjacent to the retina posteriorly.<sup>1,2</sup> The cortical vitreous encircles the nuclear vitreous.

The posterior vitreous cortex consists of densely packed type II collagen fibrils and contains the highest vitreal concentration of hyaluronic acid (HA).<sup>6</sup> It is absent over the optic nerve head and thins over the macular region.<sup>2</sup> Here, the collagen fibrils run parallel to the retina and do not insert directly into the internal limiting membrane (ILM).<sup>2</sup>

The condensation of peripheral cortical collagen fibrils forms a false anatomic membrane. Anteriorly, it is termed the anterior hyaloid membrane (AHM). The AHM runs adjacent to the lens zonules adjacent to the posterior surface of the lens and anterior to the ora serrata. The false anatomic membrane located posterior to the ora serrata is termed the posterior hyaloid membrane (PHM). It runs adjacent to the retina.<sup>1,5</sup> The AHM is in direct contact with the aqueous humor and thus behaves like a membrane, separating these two ocular compartments.<sup>2,5</sup>

Cloquet's canal (or the hyaloid canal) is a remnant of the embryonic hyaloid system. It runs from the posterior pole of the lens to the optic nerve head.<sup>1,5</sup> This canal widens anteriorly to form the patellar fossa and posteriorly to form the Area of Martegiani over the optic disc.<sup>5</sup> The space formed between the lens and the patellar fossa is known as Berger's space.<sup>5</sup>

The vitreous is segregated into three distinct stages during

development.<sup>5</sup> The primary vitreous is the innermost segment that is derived from surface ectoderm. It provides support for the developing eye and serves as the primordial vascular supply. It reaches its most vascular stage near the ninth week of gestation. Shortly afterwards, these vessels begin to atrophy and are replaced by the clear, avascular, secondary adult vitreous that originates from neuroectoderm and mesoderm. Lastly, the tertiary vitreous forms the lens zonules. It is mainly derived from neuroectoderm.<sup>5</sup>

Attachments of the vitreous to the retina occur in areas where the ILM is the thinnest. Attachment locations include: the vitreous base; the margins of the optic disc (when this area detaches, it produces the classic circular Weiss or Vogt rings); the back of the crystalline lens in contact with the hyaloideocapsular ligament of Wieger; the 500µm-diameter foveola; along large retinal vessels; and at sites of abnormal vitreoretinal adhesion, such as lattice margins.<sup>1,5,7</sup>

The strongest attachment occurs at the vitreous base, which is located 3mm to 4mm across the ora serrata and pars plana.<sup>1</sup> Here, there is a high concentration of collagen fibrils oriented perpendicular to the base that insert into the pars plana and the anterior retina through defects in the ILM.<sup>2</sup>

A false ligament, the hyaloideocapsular ligament of Wieger, is a circular attachment between the margin of the patellar fossa and the posterior surface of the lens.<sup>1</sup> It was previously believed that the posterior vitreous collagen fibrils directly inserted into the ILM; but, recent findings suggest that an extracellular matrix composed of laminin,

fibronectin and sulfated proteoglycans that interface and act as a “molecular glue.”<sup>6,8</sup> The posterior vitreous adherence is more diffuse in nature than focal attachments at the disc, fovea and retinal blood vessels.<sup>8</sup>

### Vitreous Composition

In addition to water, the vitreous contains inorganic salts, ascorbic acid and two major macromolecules: collagen and glycosaminoglycans (GAGs).<sup>5,8</sup> Essentially, the vitreous gel is formed by a dilute meshwork of collagen fibrils, which provides a scaffold-like structure that is “inflated” by HA.<sup>8</sup> The vitreous contains a low concentration of collagen (300mg/ml) that is stable throughout life.<sup>2</sup> Most of the collagen is present in the form of thin and uniform fibrils that contain mixed amounts of collagen types (II, hybrid V/XI, VI, type IX).<sup>2,7,9,10</sup>

Vitreous type II collagen is a fibril-forming substance that provides the vitreous with its tensile strength and supportive structure.<sup>2,5</sup> The long, unbranched vitreous collagen fibrils have a uniform diameter of 10nm to 20nm, and are arranged in parallel bundles that form an interconnected network.<sup>2,11</sup> Chondroitin sulfate chains of type IX collagen on the surface of a fibril bridge adjacent collagen fibrils in a ladder-like configuration, connecting them and spacing them apart.<sup>8,9</sup> This spacing is important to prevent light scatter.<sup>8</sup> Type V collagen likely plays a role in linking HA with collagen fibrils.<sup>2,12</sup>

GAGs are charged carbohydrates that attract counterions and water.<sup>2</sup> HA is the chief GAG present in the vitreous. HA is found in the greatest concentration in the posterior vitreous cortex.<sup>2</sup> By filling the spaces between collagen fibrils, GAGs create a swelling pressure to inflate the gel, separate and cross-link the parallel fibrils, and provide resistance to

compressive forces.<sup>2</sup>

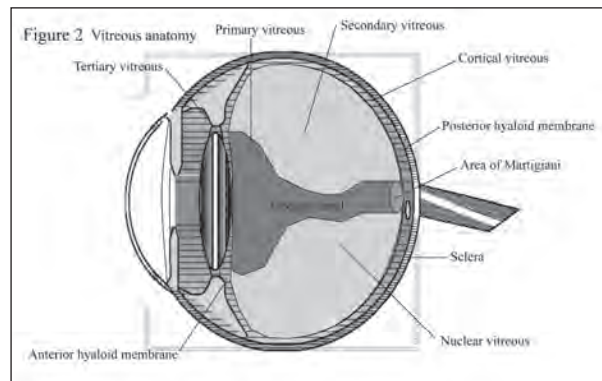
The cortical vitreous contains a small amount of organelle-containing hyalocytes that are thought to synthesize and secrete HA.<sup>5</sup> While minimal microfibrils of fibrillin have been isolated from the vitreous, they represent the major structural component of the lens zonules.<sup>2</sup>

### Essentials of Vitreous Degeneration

Postmortem studies of the vitreous structure confirm two primary degeneration states: liquefaction (synchysis) and aggregation of collagen fibrils (syneresis).<sup>8</sup>

• **Synchysis** refers to liquefaction of the vitreous, and is typically a senile process that is accelerated by myopia, inflammation, trauma, hereditary vitreoretinal syndromes (such as Stickler and Marfan syndromes), retinal vascular diseases, aphakia and vitreous hemorrhage.<sup>1,7,13,14</sup> Synchysis is the most common degenerative change in the vitreous and is present as early as age four; liquefied vitreous may account for approximately 20% of the vitreous volume by age 14 to 18 years.<sup>1,2</sup> There is a steady increase in synchysis after age 40. In fact, more than half of the vitreous body is liquid by the age of 80.<sup>2,8</sup>

Senile synchysis may be caused by aggregation and redistribution of the collagen fibrils. This phenomenon yields pockets of liquefaction known as lacunae, which are devoid of collagen fibrils.<sup>2,9,15</sup> These lacunae initially develop centrally; however, they enlarge and coalesce.<sup>2</sup> Lacunae are evident on slit-lamp biomicroscopy as pockets of optically empty space that lack the normal, fine fibrillar structure.<sup>1</sup>



Pertinent anatomy of the human vitreous.

• **Syneresis** is described as a collapse of the vitreous, with an aggregation of collagen fibrils into macroscopic bundles of parallel fibrils.<sup>1,8,11</sup> When both synchysis and syneresis are present, clinical observation shows collagen aggregates moving freely in the vitreous upon ocular movement.<sup>1</sup> The shadows cast on the retina create the symptoms of flashes and floaters.

### Posterior Vitreous Detachment

Posterior vitreous detachment (PVD) refers to the separation of the cortical vitreous from the ILM, and may be located anywhere posterior to the vitreous base.<sup>1,16</sup> It may be localized, partial or complete.<sup>2</sup> A complete PVD occurs when the posterior cortical vitreous is detached from the entire retina—including its attachment to the optic nerve up to the posterior border of the vitreous base.<sup>2</sup> At age 50, the incidence of PVD in phakic eyes is greater than 50%, increasing to approximately 75% by age 65.<sup>17</sup> There is an increased risk for PVD in aphakic or pseudophakic eyes, myopes and eyes with a history of trauma or intraocular inflammation.<sup>17</sup> Additionally, women are prone to PVD at a younger age secondary to reduced HA synthesis (reduced HA synthesis has been associated with decreased postmenopausal estrogen levels).<sup>7,16</sup>

Biomicroscopic examination reveals an optically clear space filled with liquefied vitreous between the detached posterior hyaloid and the retina.<sup>1</sup> The pathognomic sign of a PVD is the presence of a clinically observable fibrous annulus of tissue that overlies the optic disc.<sup>17</sup> A patient with an acute PVD may complain of newly visible floating spots that follow eye movement and continue to travel even after termination of ocular movement.<sup>17</sup> Photopsia is another common symptom, which is perceived as peripheral arcs or flashes of light, that is produced by mechanical retinal stimulation as the vitreous articulates with the area that the retina remains attached.<sup>17</sup>

The process of PVD begins with synchysis of the vitreous and weakening of posterior vitreoretinal adhesion.<sup>8</sup> Enlargement of formed lacunae cause the posterior vitreal cortical wall that overlies the involved area to become thinned.<sup>7,18</sup> In general, as the vitreoretinal adhesion dissolves, it forms discontinuities within the posterior hyaloid (either via fissure evolution or a microbreak in the thin cortical vitreous layer).<sup>7,8,16</sup> This allows synchytic vitreous to enter the subhyaloid space, which dissects the posterior hyaloid from the ILM of the retina.<sup>8</sup>

PVDs typically begin in a single quadrant of the perifovea (most often superior). Persistent attachments to the ILM remain at the fovea and optic nerve head.<sup>19</sup> Over time, the perifoveal detachment enlarges to completely surround the persistent attachment at the fovea.<sup>19</sup> Finally, detachment of the vitreous from the remaining foveal region produces a funnel-shaped configuration with attachments at the optic disc and vitreous base. When the PVD releases from the optic nerve, the process is complete.<sup>17,19</sup>

One study outlined the follow-

ing grading system for age-related PVD:<sup>19</sup>

- **Stage 1.** Incomplete perifoveal PVD in up to three quadrants.

- **Stage 2.** Incomplete perifoveal PVD in all quadrants, with residual attachment to the fovea and optic disc.

- **Stage 3.** Incomplete PVD over the posterior pole, with residual attachment to the optic disc.

- **Stage 4.** Complete PVD.

This research showed that even young, healthy eyes have incomplete or partial PVD beginning as early as the fourth decade of life, which may progress slowly for years before becoming a complete PVD.<sup>7,19</sup>

### Anomalous Posterior Vitreous Detachment

An anomalous PVD results when synchysis occurs without sufficient detachment from the ILM. This results in tractional effects at the interface.<sup>8</sup> Individuals with genetic collagen diseases, such as Marfan's, Ehlers-Danlos and Stickler's syndromes, have a higher incidence of anomalous PVD. These maladies also increase the risk of retinal complications at an early age.<sup>8,13,20</sup> Anomalous PVD may result in vitreoschisis, a splitting of the posterior vitreous cortex and forward displacement of the vitreous body, which leaves remnants of the outer layer firmly attached to the retina.<sup>21,22</sup>

Vitreoschisis is thought to play a role in the pathogenesis of macular pucker, macular holes and proliferative diabetic vitreoretinopathy.<sup>21-23</sup>

A common consequence of anomalous PVD is the development of vitreoretinal traction. Vitreoretinal traction, as opposed to vitreoretinal adherence without traction, is characterized as a vitreous attachment to the retina with associated tissue elevation, thickening and deformity that is visible on optical coherence

tomography (OCT).<sup>24</sup> Deflection of the posterior hyaloid or vitreous strands often can be observed at that site.<sup>24</sup>

Complications of anomalous PVD result from static, anteriorly directed tension induced by vitreous degeneration as well as dynamic traction associated with ocular movements.<sup>7</sup> Ocular movements localize traction to areas of firm vitreoretinal adhesion.<sup>7</sup> Most early-stage anomalous PVD complications occur insidiously, and are located in the posterior pole. Late-stage complications of complete anomalous PVD typically cause acute symptoms and usually occur in the periphery. Late-stage complications of anomalous PVD include: retinal or optic disc hemorrhage, vitreous hemorrhage, retinal break or tear, and rhegmatogenous retinal detachment.<sup>7</sup>

### The Role of the Vitreous in Retinal Disease

Tractional stress (force per unit area) seems to be inversely proportional to the size of vitreoretinal adhesion zones (as the size of the vitreoretinal adhesion zone decreases, the tractional forces increase).<sup>7</sup> Smaller diameters of vitreous attachment seem to play a more significant role in macular dehiscence/hole formation and localized cystoid foveal thickening.<sup>7</sup> Larger diameters of vitreous attachment typically result in diffuse macular thickening, tractional macular detachment or exacerbation of already existing macular pathology.<sup>7</sup>

One study classified vitreoretinal complications of early-stage anomalous PVD according to the size and location of the vitreomacular adhesion zone:<sup>7</sup>

- Complications associated with adhesion sizes of less than or equal to 500µm (approximately 1/3 disc diameter) included macular

microhole (50µm to 150µm), idiopathic macular hole, inner lamellar macular hole and tractional cystoid macular edema (CME).

- Adhesion zones of 1,500µm (1 disc diameter) or greater, commonly resulted in vitreomacular traction (VMT) syndrome, tractional diabetic macular edema (DME), myopic traction maculopathy and neovascular age-related macular degeneration (AMD).

When peripapillary adhesion occurred, vitreopapillary traction syndrome often resulted.<sup>7</sup> The researchers postulated that epiretinal membranes (ERM) were the result of Müller, glial and astrocyte proliferation through compromised regions of the ILM, and were associated with various vitreomacular adhesion sites of differing sizes.<sup>7</sup>

### Age-related Macular Degeneration

Many etiologic factors have been proposed for the development of AMD.<sup>25,26</sup> These include oxidative stress, ischemia, inflammation, genetic factors and aging of the retinal pigment epithelium.<sup>25,26</sup> Recent investigations suggest that mechanical and biochemical influences of the vitreous also may play an important role in AMD pathogenesis.<sup>25,27,31</sup> Whether VMT is a cause or a result of AMD remains unclear.<sup>27</sup> Local inflammation, scarring and disruption of the photoreceptor-RPE interface induced by AMD may activate Müller cells and possibly astrocytes, causing focal corresponding vitreous adhesions.<sup>28</sup> These connections induce tractional forces on the retina.<sup>28</sup>

Investigators have proposed several theories to explain the pathogenesis of VMT in AMD.<sup>28,31</sup> One hypothesis suggests that persistent vitreomacular adhesion may induce chronic, low-grade inflammation.<sup>28</sup> Another postulation implies that an adherent posterior vitreous cortex

may confine pro-angiogenic cytokines, such as vascular endothelial growth factor (VEGF) and free radicals, within the macula, which fosters the development of choroidal neovascularization (CNV).<sup>7,28,29</sup>

A third suggestion indicates that VMT may compromise the junctional proteins that are necessary for the barrier integrity of the RPE, which promotes CNV genesis.<sup>29</sup> A fourth proposal suggests that a thickened posterior vitreous cortex and abnormal tissue at the vitreomacular interface may prevent oxygen and nutrients from diffusing from the ciliary body into the macula, disrupting the choroidal supply of oxygen and nutrients that normally diffuse from the choriocapillaris to the macular photoreceptors.<sup>29,30</sup>

One final theory is that mechanical stress may cause both static and dynamic forces to induce secretion of signaling factors by Müller cells, which ignites a cascade of inflammatory factors and local vascular changes.<sup>28,31</sup> A recent study indicated that vacuum-induced pulsatile stretching of cultured rat RPE cells triggered the production and secretion of VEGF when compared to control cultures that were not subjected to mechanical stress.<sup>31</sup>

In general, it is believed that tractional forces generated by the vitreous are transmitted to the RPE via a physical bridge with the sensory retina.<sup>31</sup> Then, a stretch-induced VEGF secretion contributes to increased levels of the growth factor, which provokes angiogenesis and breakdown of the blood-retinal barrier.<sup>31</sup>

Several studies seem to confirm the aforementioned hypothesis regarding VEGF secretion.<sup>25,29</sup> These investigations indicate that eyes with AMD and complete PVD have a considerably lower incidence of CNV compared to eyes with no or incomplete PVD. In one report, the rate

of complete PVD in eyes with non-exudative AMD or no AMD ranged from 61% to 72%.<sup>25</sup> However, the rate of complete PVD in eyes with exudative AMD ranged from just 21% to 34%.<sup>25,29</sup> These results suggest that PVD may be protective against the development of wet AMD.<sup>25,29</sup>

A similar disparity was seen in subjects with end-stage AMD, where a lower incidence of complete PVD was detected in eyes with geographic atrophy (70%) compared to eyes with fibrotic (disciform) scarring (40%).<sup>29</sup> Furthermore, partial PVD (central vitreoretinal adhesion surrounded by shallow detachment of the posterior vitreous cortex) has been more frequently documented in eyes with exudative AMD (30%), than eyes with nonexudative AMD (12.3%) or no AMD (5.4%).<sup>25</sup>

Interestingly, PVD is more commonly found in eyes with end-stage AMD that exhibit disciform scarring than in eyes with active exudative AMD.<sup>29</sup> This suggests that the development of PVD either promotes CNV regression or that macular disciform scarring may facilitate vitreoretinal dehiscence by altering the integrity of the ILM.<sup>29</sup>

Using OCT imaging, one research group described posterior vitreomacular adhesion/traction to be approximately three to eight times more common in eyes with exudative AMD (36% to 38%) than in eyes with nonexudative AMD (7% to 10%) or no sign of AMD (11%).<sup>25,27,29</sup> Drawing from these results, the authors concluded that chronic VMT also may be a risk factor for the development of exudative AMD.

In subsequent studies that examined this evidence, CNV was present in far more eyes with AMD and vitreomacular adhesion than eyes without vitreomacular adhesion.<sup>25,27,29</sup> Likewise, vitreomacular adhesion seemed to be more fre-



quently observed in eyes with disciform scarring (20%) compared to eyes with geographic atrophy (0%).<sup>29</sup> In one report, a lower incidence of vitreomacular adhesion was discovered in eyes with disciform scars (20%) compared to eyes with active exudative AMD (38%), which supports the theory that the release of adhesion may promote regression of active disease.<sup>29</sup> Additionally, results from these studies suggested that vitreomacular adhesion was almost always found above the CNV area—regardless of its location—further illustrating the relationship between vitreomacular adhesion and exudative AMD.<sup>25,27,28</sup>

A research team at Duke University Medical Center in Durham, N.C., examined the variations in dynamic mechanical forces both during and after eye motion. They documented that, during normal eye movement, the RPE was under continuous shear stress when forces were physically transmitted to the underlying RPE by the vitreous. This traction, especially at the edges of RPE junctions, resulted in detectable RPE tears upon clinical examination that were confirmed with fluorescein angiography (FA).<sup>32</sup>

Consistent with these findings, the Duke researchers suggested that artificial induction of PVD via surgical or pharmacologic methods may provide prophylactic or therapeutic benefit against both CNV and inadequate retinal oxygenation.<sup>33</sup> Further, several other case studies that evaluated eyes with exudative AMD and vitreomacular adherence have shown CNV regression, decrease in foveal thickness and improvement in vision following PPV with artificial detachment of the posterior hyaloid.<sup>28,34</sup> Vitrectomy was shown to be of particular benefit in eyes with relatively small CNV lesions (less than 0.5 optic disc diameter).<sup>34</sup> This

research may redefine the role of PPV as an important option in the management of CNV that is poorly responsive to aggressive anti-VEGF therapy.<sup>28</sup>

One study indicated that tractional forces may reduce the effect of anti-VEGF treatment, causing pharmacological resistance in a subpopulation of patients.<sup>28</sup> Likewise, another study showed a potential benefit of combining vitrectomy with subretinal surgery in eyes with recurrent CNV following repeated sessions of photo-dynamic therapy.<sup>35</sup>

The surgeons who investigated the role of PPV in exudative AMD observed only mild liquefaction of the vitreous gel with remarkably firm attachments at the macula.<sup>34,35</sup> The surgeons theorized that reduction of tangential retinal traction would allow intraretinal macular edema (ME) to be absorbed.<sup>34</sup> Moreover, an increase in partial oxygen pressure within the vitreous cavity might have contributed to decreased rates of CNV.<sup>33,34</sup>

## Retinal Vein Occlusion

ME is one of the most frequent causes of visual impairment in patients who experience retinal vein occlusion.<sup>36,37</sup> It occurs as a result of increased venous pressure, which damages the capillary endothelium and breaks down the inner blood-retinal barrier.<sup>37</sup> Recent studies have focused on the role of the vitreous in persistent ME secondary to retinal vein occlusion.<sup>24,36,38-42</sup> The research indicated that the vitreous contributes to ME, both by containing metabolic agents that increase vascular permeability and by exerting vitreomacular traction.<sup>24,36,38-42</sup>

Cystic ME is characterized by OCT as round, intraretinal, hyporeflective lacunae with well-defined boundaries and hyper-reflective septa that separate the small cavi-

ties.<sup>24,39</sup> It likely begins as intracytoplasmic swelling of Müller cells that is incited by intrinsic metabolic agents, including VEGF and interleukin-6 (IL-6), that are released following any retinal ischemic event.<sup>36,38</sup> Elevated levels of both metabolic factors have been found in the aqueous humor and vitreous fluid of eyes with central retinal vein occlusion (CRVO) that exhibit macular edema.<sup>36</sup> Theories speculate that the vitreous may act as a reservoir, storing these agents and keeping them in constant contact with the neurosensory retina wherever vitreomacular adhesion is present.<sup>38</sup>

Recent research, however, points to the potential for vascular insult to promote accelerated vitreous liquefaction located proximal to the retinal area that is affected by vein occlusion before adequate weakening of the vitreoretinal adhesion ensues.<sup>24</sup> This process then causes increased vitreous traction in the area of the affected major vein, the adjoining vasculature or the optic nerve margin.<sup>24</sup> These forces are also transmitted to macular Müller cells, causing them to swell with simultaneous release of capillary fluid, which yields CME.<sup>38</sup>

Other reports have revealed that the incidence of partial PVD is significantly greater in eyes with branch retinal vein occlusion (BRVO) than in unaffected eyes.<sup>24,39,40,41</sup> In eyes with ME secondary to vein occlusion, 41% had associated vitreous traction with a similar incidence in both CRVO or BRVO eyes, suggesting that vitreous traction influences the evolution of chronic macular edema.<sup>24,40</sup> In these cases, the location of the traction was often extrafoveal, adjacent to the occlusion site, and less frequently foveal or papillary.<sup>24,39</sup> The researchers found that retinal edema and serous retinal detachment that impacted the

traction site was almost always in contact with the central macula, producing diffuse ME or combined diffuse ME and serous macular detachment.<sup>24,39</sup> Diffuse ME in these studies was identified via OCT as an ill-defined, widespread, hyporeflexive retinal thickness that resembled a porous sponge.<sup>39</sup> Further, current evidence suggests that eyes with vitreoretinal traction are more likely to develop diffuse ME, while eyes without traction are more likely to develop CME.<sup>39</sup>

In one report, researchers noted a subsequent resolution of ME and an improvement in visual acuity following spontaneous extrafoveal traction release associated with central ME and macular detachment in an eye affected by BRVO.<sup>24</sup> Another study suggested that ischemic CRVO may actually promote the development of papillary vitreous traction (disc elevation associated with either incomplete PVD or vitreopapillary fibrous membrane) with secondary peripapillary retinal traction and localized macular or retinal detachment.<sup>42</sup>

Given these outcomes and the discovery of the possible pathophysiologic advantages of 3-port PPV, the benefits of the procedure may now outweigh the risks. It has been extrapolated that removal of angiogenic cytokines, such as VEGF and IL-6, contained in the preoperative vitreous may help stabilize retinal vascular permeability and therefore decrease ME formation.<sup>36</sup>

This hypothesis is supported by reports in patients who experienced partial vitrectomy. In cases where vitrectomy was repeated, vitreous levels of VEGF were lower at the time of the second procedure.<sup>43</sup> Additionally, other surgical investigators have shown that high vitreous VEGF levels at the time of PPV have been associated with a greater postoperative improvement in ME. This

suggests that removal of VEGF via the procedure plays an important role in edema resolution.<sup>36</sup> In these studies, PPV was often combined with ILM peeling to reduce the risk of ERM formation as well as ME recurrence.<sup>44</sup>

Investigators theorize that PPV with ILM peeling “unroofs” the inner retina and allows the retained/compartmentalized intraretinal blood and extracellular fluid to drain out of the retina.<sup>44</sup> In addition, the peeling of a thickened ILM may improve retinal plasticity, facilitating fluid diffusion out of the retina.<sup>44</sup> Further, the increase in oxygen tension within the vitreous cavity and retina following vitrectomy likely reduces ischemia.<sup>34,38,45</sup> Finally, the benefit of PPV in cases of recalcitrant ME following grid laser or repeated intravitreal injections of anti-VEGF agents is thought to release mechanical vitreous traction, which acts as a natural obstacle to anatomic improvement.<sup>39</sup>

Today, identifying pre-existing vitreoretinal traction may be an important step when considering intravitreal treatments, because its presence may increase the likelihood of both tractional retinal detachment and ME progression.<sup>39,46</sup> Mounting data also seems to indicate that vitrectomy serves a protective role against the formation of retinal or disc neovascularization (NV) in eyes with CRVO.<sup>38</sup> This theory is substantiated by the observation that eyes with BRVO and complete PVD rarely develop pre-retinal neovascularization.<sup>40</sup> Likewise, the risk of vitreous hemorrhage following BRVO is greatest in patients with partial PVD, suggesting the increased risk of developing pre-retinal NV is aggravated by vitreous tractional effects on these new, fragile vessels.<sup>40</sup>

Numerous studies have reported beneficial results following PPV with

ILM peeling and artificial detachment/removal of the posterior hyaloid in eyes with ME secondary to retinal vein occlusion.<sup>36,38,44,47,48</sup> In these cases, ME resulting from either CRVO or hemiretinal vein occlusion (HVO) was significantly reduced as was central foveal thickness in all PPV eyes, with a documented maintained effect of at least five years.<sup>44</sup> These results were associated with improved corrected vision in eyes with non-ischemic CRVO (less than 10 disc areas of non-perfusion noted on FA and HVO, but not in eyes with ischemic CRVO).<sup>44</sup>

Such findings suggested that most vision loss in eyes with ischemic CRVO was likely secondary to macular ischemia, not ME. Similar findings were reported following PPV and ILM peeling in eyes with chronic CME secondary to BRVO, with a mean decrease in central macular thickness of 62% and associated mean improvement in visual acuity from 20/100 at baseline to 20/40 at the seven-month follow-up.<sup>48</sup>

### Diabetic Macular Edema

DME influences the vitreous in three possible ways:<sup>49</sup>

- Accumulation of angiogenic factors in the premacular vitreous gel, which increases vascular permeability.
- Abnormal glycation and cross-linking of vitreal collagen, which causes vitreous destabilization and increased macular traction.
- Increased epiretinal membrane formation.

Focal DME is defined by discrete areas of leakage on FA. It is produced by microaneurysms and typically is responsive to focal laser photocoagulation.<sup>50</sup> Diffuse DME is characterized by generalized areas of leakage and is associated with vitreomacular traction, vitreoretinal or vitreopapillary vitreous traction, and

epiretinal membrane formation.<sup>50</sup> Diffuse DME is less responsive to grid photocoagulation, which often yields merely temporary benefits.<sup>50,51</sup>

One report indicated that diabetes patients without ME (55%) have a significantly higher rate of complete PVD than those with ME (20%), suggesting that a complete PVD maybe protective against edema formation.<sup>52</sup> Moreover, approximately half of eyes with diffuse or focal DME involving the center of the macula have some sort of vitreoretinal traction located outside the fovea, either at the optic nerve head or in the posterior pole.<sup>50</sup> While vitreous traction at the fovea is less common, it is present in approximately 20% of eyes with DME and is accompanied by additional areas of traction outside of the fovea about half of the time.<sup>50</sup>

Vitreofoveal traction has the potential to induce focal ME with a peaked center, and is typically associated with a significantly greater macular thickness than that observed in eyes with extrafoveal or vitreopapillary traction.<sup>50,53</sup> Furthermore, researchers suggest that extrafoveal vitreous traction is present in approximately 35% of eyes with DME and commonly occurs at various vitreoretinal and/or papillary sites.<sup>50</sup> Additionally, vitreoretinal traction may cause localized serous retinal detachment or schisis-like clefts at the point of traction.<sup>53,54</sup>

Approximately one quarter of eyes with DME and vitreoretinal traction have identifiable ERM without PVD.<sup>50</sup> By contrast, ERM in non-diabetes patients is strongly associated with posterior vitreous detachment.<sup>50,55</sup>

It seems that partial PVD with vitreoretinal traction is a major risk factor for progression of proliferative diabetic retinopathy (PDR).<sup>56</sup> In one study, 80% of patients with PDR (but

without PVD) who were treated with pan-retinal photocoagulation (PRP) exhibited retinopathy that improved or remained unchanged at six-month follow-up.<sup>56</sup> However, in eyes with complete PVD, 93% remained stable or improved.<sup>56</sup> In contrast, the PDR worsened in 57% of eyes with partial PVD.<sup>56</sup> The study suggested that complete PVD or the absence of PVD reduces levels of vitreous traction and protects against the progression of PDR.<sup>56</sup> The suspected mechanism is elimination of the collagenous network of the cortical vitreous, which the new vessels require as a scaffold for growth.<sup>2</sup>

Even in non-tractional cases, vitrectomy seems to improve DME by increasing retinal oxygenation and removing growth factors that increase vascular permeability.<sup>34,49,53,57</sup> As seen in vein occlusion, vitrectomy for DME is often coupled with ILM peeling. This theory is supported by the fact that ILM in patients with DME have been found to be significantly thicker than those in eyes without DME.<sup>58,59</sup> Additionally, peeling of the ILM may activate Müller cell repair mechanisms.<sup>58,60</sup> ILM peeling also facilitates a more complete removal of the vitreous.<sup>58,61</sup>

A large study conducted by the Retinopathy Clinical Research Network included 241 eyes with DME involving the center of the macula that was associated with VMT (vitreomacular interface abnormality or traction in 71%) or was unresponsive to injection or laser treatment.<sup>62</sup> Eyes were treated with PPV and removal of the posterior hyaloid, with or without ERM or ILM peeling.<sup>62</sup> At six months, median central macular thickness decreased by one-third in eyes, but visual acuity remained unchanged.<sup>62</sup> The best results occurred in eyes with worse baseline acuity following

ERM removal.<sup>62</sup> A greater reduction in central retinal thickness occurred in eyes with worse baseline acuity, greater preoperative retinal thickness, removal of ILM at time of PPV and OCT evidence of vitreoretinal abnormalities.<sup>62</sup> But again, vision was not substantially improved.<sup>62</sup> The research team concluded that, while preoperative presence of vitreoretinal abnormalities appeared to be most amenable to surgical intervention, the functional outcomes were not always improved.<sup>62</sup>

Other studies have added to the controversy.<sup>63,64</sup> One paper suggested that PPV with separation of the posterior hyaloid was best for improving visual prognosis and encouraging resolution of edema.<sup>63</sup> Another commented that functional/surgical success was significantly better in eyes that had not undergone preoperative macular laser treatment.<sup>64</sup>

There is conflicting evidence as to the benefit of PPV in cases of DME without vitreous traction.<sup>57,58,65</sup> One study reported that PPV with artificial induction of PVD with or without ILM peeling improved vision in only half of cases.<sup>57</sup> Further, vision was stabilized in only one third of 486 eyes with diffuse non-tractional DME at six years post-op.<sup>57</sup> Another study suggested that standard PPV without peeling of the ILM provided little visual benefit compared to macular photocoagulation in eyes with central clinically significant ME that persisted for more than a year.

While there is unclear protocol, a body of evidence is being generated that suggests while surgical induction of PVD alone improves macular edema, it is markedly less effective than surgical induction of PVD with ILM removal.<sup>58</sup> Moreover, ILM delamination appears to be beneficial for chronic DME, even in eyes with pre-existing PVD.<sup>58</sup>

## Vitreomacular Traction and Macular Hole Formation

As the vitreous body changes overtime, liquefaction and collapse occurs.<sup>66-72</sup> At times, the resulting posterior vitreous detachment remains incomplete.<sup>66-72</sup> The residual stubborn adhesions between the posterior hyaloid and the underlying neurosensory retina create VMT.<sup>66-72</sup> The tractional force—thought to be either tangential or anteroposterior—exerted by the hyaloid face of the vitreous on the highly organized neuroretinal macular tissue can cause significant structural and functional changes.<sup>66</sup> VMT can lead to a constellation of macular pathologies.

Macular holes, first described by J. Donald M. Gass, M.D., traditionally have been graded on a scale, depending on the foveal appearance and the extent of tissue involved.<sup>22,66-68</sup> With the advent of OCT and spectral domain OCT, even greater anatomical detail can now be appreciated. The presence of VMT is often considered the earliest event of macular hole formation.<sup>22,66,68-72</sup>

Recent research suggested that eyes exhibiting small, focal macular adhesions with peripapillary attachments have a likelihood of macular hole formation.<sup>64</sup> Another study indicated that, as the vitreous begins to detach, liquefied vitreal gel escapes through any acquired small break in the posterior hyaloid face.<sup>66</sup> The most frequently documented site of escape is in the region of the glial ring over the optic disc.<sup>66</sup> The liquefied material enters the subhyaloid space and exerts pressure on the vitreous cortex, causing it to move anteriorly.<sup>66</sup> The traction exerted on the retina by the vitreous, which has attachments located at the macula and adjacent to the optic nerve head, begins the processes that induce macular hole formation.<sup>66,67,73</sup>

Spontaneous release of the vit-

reomacular adhesions can reverse early VMT-associated structural changes to the macula, thus restoring normal visual function.<sup>66,71,73</sup> Pharmacologically assisted vitreolysis may be an option worth considering to assist in breaking these vitreoretinal adhesions, allowing for the normal macular anatomy to be restored before later-stage macular hole pathogenesis.<sup>66,69-71</sup> Otherwise, surgical intervention via PPV has been the mainstay of treatment for these cases.<sup>70,71</sup>

## Treatment Options

With respect to macular edema, vitrectomy traditionally is reserved for recalcitrant disease, because the procedure can cause significant side effects, including rhegmatogenous retinal detachment, cataract development, hypotony, choroidal effusion and endophthalmitis.<sup>74,75</sup> Recent research has fueled interest in developing injectable pharmaceutical agents that could induce PVD in a less invasive and benign manner.

Pharmacologic vitreolysis refers to the use of exogenous agents to alter the biochemical and biophysical states of the macromolecules that are responsible for maintaining vitreous structure and vitreoretinal adhesion.<sup>8</sup> Most pharmacologic agents are enzymatic and include both substrate-specific and non-specific agents as well as broad-acting agents that are designed to simultaneously liquefy the vitreous while achieving dehiscence of all vitreoretinal adhesions.<sup>8</sup> Non-specific agents include plasmin, microplasmin (i.e., Ocriplasmin [ThromboGenics]) and dispase, while specific agents encompass chondroitinase, hyaluronidase and matrix metalloproteinases.<sup>8</sup>

Plasmin, typically acquired from the patient's own serum, has been tested mainly as an adjunct to vitrectomy in cases of advanced diabetic

retinopathy and macular holes.<sup>8,76,77</sup> Dispase—a relatively non-specific agent with proteolytic activity against type IV collagen and fibronectin—has been linked to retinal toxicity in human eyes, which suggests the need for more specific agents that spare retinal tissue.<sup>8,78</sup>

Specific molecules that have been tested in FDA human clinical trials include chondroitinase and hyaluronidase.<sup>8,79</sup> While hyaluronidase induces vitreous liquefaction, it usually does not simultaneously induce adequate vitreoretinal adhesion separation.<sup>8</sup> This is most likely the reason that phase III trials investigating the use of hyaluronidase to clear vitreous hemorrhage in eyes of patients with type I and type II diabetes were found to be unsuccessful.<sup>8,79</sup> Future investigations that focus on a combination of specific molecules likely will afford better results with fewer retinal side effects.<sup>8</sup> Inevitably, there is hope that these investigations will produce an agent that will eventually decrease the necessity of vitrectomy.

It is clear that the vitreous humor, with its complex anatomic structure and network of neurosensory retinal adhesions, plays a vital role in the homeostasis of retinal tissue. The majority of new retinal research concerning vitreoretinal pathology supports an association of more severe sequelae in cases exhibiting enhanced vitreoretinal adhesions.

Further, the discovery of reduced pathology in cases of both naturally occurring and induced (pharmacological or surgical) vitreoretinal separation has fueled novel ideas for managing recalcitrant ME secondary to intraretinal, subretinal and preretinal pathologies. Continuing research may permit the development of less invasive techniques for dissolving pathological vitreoretinal relationships in favor of reduced anatomic

## dysfunktion and improved visual outcomes. ■

*Dr. Majcher is a primary care resident at the Eye Institute at Salus University in Elkins Park, Pa. Dr. Gurwood is professor of clinical sciences at the Eye Institute at Salus University. Dr. Hutchinson practices in St. Louis and is an adjunct faculty member at the University of Missouri-St. Louis College of Optometry.*

1. Khurana AK. Comprehensive Ophthalmology. New Age International: Delhi, India; 2007:243-8.
2. Le Goff MM, Bishop PN. Adult vitreous structure and postnatal changes. *Eye (Lond)*. 2008 Oct;22(10):1214-22.
3. Halfter W, Winzen U, Bishop PN, et al. Regulation of eye size by the retinal basement membrane and vitreous body. *Invest Ophthalmol Vis Sci*. 2006 Aug;47(8):3586-94.
4. Holekamp NM, Shui YB, Beebe DC. Vitrectomy surgery increases oxygen exposure to the lens: a possible mechanism for nuclear cataract formation. *Am J Ophthalmol*. 2005 Feb;139(2):302-10.
5. Schubert H, Kincaid M, Green R, et al. Anatomy and physiology. In: Regillo C, Brown G, Flynn H. *Vitreoretinal disease: The essentials*. New York: Thieme; 1999:3-25.
6. Sebag J, Hageman GS. Interfaces. *Eur J Ophthalmol*. 2000 Jan-Mar;10(1):1-3.
7. Johnson MW. Posterior vitreous detachment: evolution and complications of its early stages. *Am J Ophthalmol*. 2010 Mar;149(3):371-82.e1
8. Sebag J. Anomalous posterior vitreous detachment: a unifying concept in vitreo-retinal disease. *Graefes Arch Clin Exp Ophthalmol*. 2004 Aug;42(8):690-8.
9. Bishop PN. Structural macromolecules and supramolecular organization of the vitreous gel. *Prog Retin Eye Res*. 2000 May;19(3):323-44.
10. Bishop P, Ayad S, Reardon A, et al. Type VI collagen is present in human and bovine vitreous. *Biochem Biophys Res Commun*. 1994 Aug 30;203(1):289-95.
11. Bos KJ, Holmes DF, Kadler KE, et al. Axial structure of the heterotypic collagen fibrils of vitreous humour and cartilage. *J Mol Biol*. 2001 Mar 9;306(5):1011-22.
12. Wenstrup RJ, Florer JB, Brunskill EW, et al. Type V collagen controls the initiation of collagen fibril assembly. *J Biol Chem*. 2004 Dec 17;279(51):53331-7.
13. Maumenee IH. Vitreoretinal degeneration as a sign of generalized connective tissue diseases. *Am J Ophthalmol*. 1979 Sep;88(3 Pt 1):432-49.
14. Sebag J. Pathology of the vitreous. In: Sebag J. *The vitreous: structure, function, and pathobiology*. New York: Springer-Verlag; 1989:97-147.
15. Bishop PN. Age-related changes on the surface of vitreous collagen fibrils. *Invest Ophthalmol Vis Sci*. 2004 Apr;45(4):1041-6.
16. Sebag J. Development and aging of the vitreous. In: Sebag J. *The vitreous: structure, function, and pathobiology*. New York: Springer-Verlag; 1989:73-92.
17. Tiedeman J, Mitra R, Han D, et al. Vitreous and retinal detachments. In: Regillo C, Brown G, Flynn H. *Vitreoretinal disease: The essentials*. New York: Thieme; 1999:65-86.
18. Kishi S, Hagimura N, Shimizu K. The role of the premacular liquefied pocket and premacular vitreous cortex in idiopathic macular hole development. *Am J Ophthalmol*. 1996 Nov;122(5):622-8.
19. Uchino E, Uemura A, Ohba N. Initial stages of posterior vitreous detachment in healthy eyes of older persons evaluated by optical coherence tomography. *Arch Ophthalmol*. 2001 Oct;119(10):1475-9.
20. Snead MP, Yates JR. Clinical and molecular genetics of Stickler syndrome. *J Med Genet*. 1999 May;36(5):353-9.
21. Sebag J. Classifying posterior vitreous detachment: a new way to look at the invisible. *Br J Ophthalmol*. 1997 Jul;81(7):521.
22. Sebag J, Gupta P, Rosen RR, et al. Macular holes and macular pucker: the role of vitreochisis as imaged by optical coherence tomography/scanning laser ophthalmoscopy. *Trans Am Ophthalmol Soc*. 2007;105:121-9; discussion 129-31.
23. Sebag J. Diabetic vitreopathy. *Ophthalmology*. 1996 Feb;103(2):205-6.
24. Martinez MR, Ophir A. Extrafoveal traction in retinal vein occlusion using spectral domain optical coherence tomography. *Graefes Arch Clin Exp Ophthalmol*. 2011 Jun;249(6):811-20.
25. Krebs I, Brannath W, Glittenberg C, et al. Posterior vitreomacular adhesion: A potential risk factor for exudative age-related macular degeneration? *Am J Ophthalmol*. 2007 May;144(5):741-6.
26. Spaide RF, Armstrong D, Browne R. Continuing medical education review: choroidal neovascularization in age-related macular degeneration—what is the cause? *Retina*. 2003 Oct;23(5):595-614.
27. Lee SJ, Lee CS, Koh HJ. Posterior vitreomacular adhesion and risk of exudative age-related macular degeneration: paired eye study. *Am J Ophthalmol*. 2009 Apr;147(4):621-6.
28. Mojana F, Cheng L, Bartsch DU, et al. The role of abnormal vitreomacular adhesion in age-related macular degeneration: Spectral optical coherence tomography and surgical results. *Am J Ophthalmol*. 2008 Aug;146(2):218-227.
29. Robison CD, Krebs I, Binder S, et al. Vitreomacular adhesion in active and end-stage age-related macular degeneration. *Am J Ophthalmol*. 2009 Jan;148(1):79-82.
30. Schulze S, Hoerle S, Mennel S, Kroll P. Vitreomacular traction and exudative age-related macular degeneration. *Acta Ophthalmol*. 2008 Aug;86(5):470-81.
31. Seko Y, Seko Y, Fujikura H, et al. Induction of vascular endothelial growth factor after application of mechanical stress to retinal pigment epithelium of the rat in vitro. *Invest Ophthalmol Vis Sci*. 1999 Dec;40(13):3287-91.
32. Meyer CH, Toth CA. Retinal pigment epithelial tear with vitreomacular attachment: a novel pathogenic feature. *Graefes Arch Clin Exp Ophthalmol*. 2001 Jun;39(5):325-33.
33. Stefansson E, Loftsson T. The Stokes-Einstein equation and the physiological effects of vitreous surgery. *Acta Ophthalmol Scand*. 2006 Dec;84(6):718-9.
34. Ikeda T, Sawa H, Koizumi K, et al. Pars plana vitrectomy for regression of choroidal neovascularisation with age-related macular degeneration. *Acta Ophthalmol Scand*. 2000 Aug;78(4):460-4.
35. Schmidt JC, Mennel S, Horle S, et al. High incidence of vitreomacular traction in recurrent choroidal neovascularisation after repeated photodynamic therapy. *Br J Ophthalmol*. 2006 Nov;90(11):1361-2.
36. Noma H, Funatsu H, Mimura T, et al. Visual acuity and foveal thickness after vitrectomy for macular edema associated with branch retinal vein occlusion: a case series. *BMC Ophthalmol*. 2010 Apr 29;10:11.
37. Michels RG, Gass JD. The natural course of retinal branch vein obstruction. *Trans Am Acad Ophthalmol Otolaryngol*. 1974 Mar-Apr;78(2):OP166-77.
38. Leizaola-Fernandez C. Vitrectomy with complete posterior hyaloid removal for ischemic central retinal vein occlusion: series of cases. *BMC Ophthalmol*. 2005 May 20;5:10.
39. Ophir A, Trevino A, Martinez MR. Extrafoveal vitreous traction associated with branch retinal vein occlusion. *Eur J Ophthalmol*. 2010 Jul-Aug;20(4):733-9.
40. Trempe CL, Takahashi M, Topilow HW. Vitreous changes in retinal branch vein occlusion. *Ophthalmology*. 1981 Jul;88(7):681-7.
41. Murakami K, Ho PC, Trempe CL, et al. Tractional detachment of the macula following branch retinal vein occlusion. *Ann Ophthalmol*. 1983 Aug;15(8):760-5.
42. Rumlert S. Optic disc traction syndrome associated with central retinal vein occlusion. *Arch Ophthalmol*. 2003 Aug;121(8):1093-7.
43. Noma H, Funatsu H, Mimura T, et al. Changes of vascular endothelial growth factor after vitrectomy for macular edema secondary to retinal vein occlusion. *Eur J Ophthalmol*. 2008 Nov-Dec;18(6):1017-9.
44. Park DH, Kim IT. Long-term effects of vitrectomy and internal limiting membrane peeling for macular edema secondary to central retinal vein occlusion and hemiretinal vein occlusion. *Retina*. 2010 Jan;30(1):117-24.
45. Stefansson E, Novack RI, Hatchell DL. Vitrectomy prevents retinal hypoxia in branch retinal vein occlusion. *Invest Ophthalmol Vis Sci*. 1990 Feb;31(2):284-9.
46. Arevalo JF, Maia M, Flynn HW Jr, et al. Tractional retinal detachment following intravitreal bevacizumab (Avastin) in patients with severe proliferative diabetic retinopathy. *Br J Ophthalmol*. 2008 Feb;92(2):213-6.
47. Raszewska-Steglinska M, Gozdek P, Cisiecki S, et al. Pars plana vitrectomy with ILM peeling for macular edema secondary to retinal vein occlusion. *Eur J Ophthalmol*. 2009 Nov-Dec;19(6):1055-62.
48. Ma J, Yao K, Zhang Z, Tang X. 25-gauge vitrectomy and triamcinolone acetate-assisted internal limiting membrane peeling for chronic cystoid macular edema associated with branch retinal vein occlusion. *Retina*. 2008 Jul-Aug;28(7):947-56.
49. Diabetic Retinopathy Clinical Research Network Writing Committee. Vitrectomy outcomes in eyes with diabetic macular edema and vitreomacular traction. *Ophthalmology*. 2010 Jun;117(6):1087-1093.
50. Ophir A, Martinez MR, Mosqueda P, et al. Vitreous traction and epiretinal membranes in diabetic macular edema using spectral-domain optical coherence tomography. *Eye (Lond)*. 2010 Oct;24(10):1545-53.
51. Solaiman KA, Diab MM, Abo-Elenin M. Intravitreal bevacizumab and/or macular photocoagulation as a primary treatment for diffuse diabetic macular edema. *Retina*. 2010 Nov-Dec;30(10):1638-45.
52. Nasrallah FP, Jalkh AE, Van Coppenolle F. The role of the vitreous in diabetic macular edema. *Ophthalmology*. 1988 Oct;95(10):1335-9.
53. Ophir A, Trevino A. Extrafoveal vitreous traction associated with diabetic diffuse macular edema. *Eye (Lond)*. 2010 Feb;24(2):347-53.
54. Karatas M, Ramirez JA, Ophir A. Diabetic vitreopapillary traction and macular edema. *Eye (Lond)*. 2005 Jun;19(6):676-82.
55. Appiah AP, Hirose T, Kado M. A review of 324 cases of idiopathic premacular gliosis. *Am J Ophthalmol*. 1988 Nov 15;106(5):533-5.
56. Jalkh A, Takahashi M, Topilow HW, et al. Prognostic value of vitreous findings in diabetic retinopathy. *Arch Ophthalmol*. 1982 Mar;100(3):432-4.
57. Kumagai K, Furukawa M, Ogino N, et al. Long-term follow up of vitrectomy for diffuse nontraction diabetic macular edema. *Retina*. 2009 Apr;29(4):464-72.
58. Hoerauf H, Brüggemann A, Muecke M, et al. Pars plana vitrectomy for diabetic macular edema. Internal limiting membrane delamination vs posterior hyaloid removal. A prospective randomized trial. *Graefes Arch Clin Exp Ophthalmol*. 2011 Jul;249(7):997-1008.
59. Matsunaga N, Ozeki H, Hirabayashi Y, et al. Histopathologic evaluation of the internal limiting membrane surgically excised from eyes with diabetic maculopathy. *Retina*. 2005 Apr-May;25(3):311-6.
60. Uckermann O, Uhlmann S, Pannicke T, et al. Ischemia-reperfusion causes exudative detachment of the rabbit retina. *Invest Ophthalmol Vis Sci*. 2005 Jul;46(7):2592-600.
61. Sonada KH, Sakamoto T, Enaida H, et al. Residual vitreous cortex after superior vitrectomy separation visualized by intravitreal triamcinolone acetate. *Ophthalmology*. 2004 Feb;111(2):226-30.
62. Flaxel CJ, Edwards AR, Aiello LP, et al. Factors associated with visual acuity outcomes after vitrectomy for diabetic macular edema: diabetic retinopathy clinical research network. *Retina*. 2010 Oct;30(9):1488-95.
63. Lewis H, Abrams GW, Blumenkranz MS, et al. Vitrectomy for diabetic macular traction and edema associated with posterior hyaloidal traction. *Ophthalmology*. 1992 May;99(5):753-9.
64. La Heij EC, Hendrikse F, Kessels AG, et al. Vitrectomy results in diabetic macular edema without evident vitreomacular traction. *Graefes Arch Clin Exp Ophthalmol*. 2001 Apr;39(4):264-70.
65. Patel JJ, Hykin PG, Schadt M, et al. Diabetic macular oedema: pilot randomised trial of pars plana vitrectomy vs macular argonphotocoagulation. *Eye (Lond)*. 2006 Aug;20(8):873-81.
66. Takezawa M. Clarifying the mechanism of idiopathic macular hole development in fellow eyes using spectra-domain optical coherence tomography. *Clin Ophthalmol*. 2011 Jan 20;5:101-8.
67. Johnson RN, Gass JD. Idiopathic macular holes. Observations, stages of formation, and implications for surgical intervention. *Ophthalmology*. 1988 Jul;95(7):917-24.
68. Huang LL, Levinson DH, Levine JP, et al. Optical coherence tomography findings in idiopathic macular holes. *J Ophthalmol*. 2011;2011:928205.
69. Schneider EW, Johnson MW. Emerging nonsurgical methods for the treatment of vitreomacular adhesion: a review. *Clin Ophthalmol*. 2011;5:1151-65.
70. Kumar N, Kandari JA, Sabti KA, et al. Partial-thickness macular hole in vitreomacular traction syndrome: a case report and review of the literature. *J Med Case Reports*. 2010 Jan 13;4:7.
71. Shechtman DL, Dunbar MT. The expanding spectrum of vitreomacular traction. *Optometry*. 2009 Dec;80(12):681-687.
72. Odobina D, Michalewska Z, Michalewski J, et al. Long-term evaluation of vitreomacular traction disorder in spectral-domain optical coherence tomography. *Retina*. 2011 Feb;31(2):324-31.
73. Reese AB, Jones IS, Cooper WC. Macular changes secondary to vitreous traction. *Trans Am Ophthalmol Soc*. 1966;64:123-34.
74. Akçay B. Outcomes of 23-gauge pars plana vitrectomy in vitreoretinal diseases. *Clin Ophthalmol*. 2011;5:1771-6.
75. Schoenberger SD, Miller DM, Riemann CD, et al. Outcomes of 25-gauge pars plana vitrectomy in the surgical management of proliferative diabetic retinopathy. *Ophthalmic Surg Lasers Imaging*. 2011 Nov-Dec;42(6):474-80.
76. Trese MT, Williams GA, Hartzler MK. A new approach to stage 3 macular holes. *Ophthalmology*. 2000 Aug;107(8):1607-11.
77. Williams JG, Trese MT, Williams GA, et al. Autologous plasmin enzyme in the surgical management of diabetic retinopathy. *Ophthalmology*. 2001 Oct;108(10):1902-5; discussion 1905-6.
78. Jorge R, Oyamauchi EK, Cardillo JA, et al. Intravitreal injection of dispase causes retinal hemorrhages in rabbit and human eyes. *Curr Eye Res*. 2003 Feb;26(2):107-12.
79. Bhavsar AR, Grillon LR, McNamara TR, et al. Vitrase for Vitreous Hemorrhage Study Groups. Predicting response of vitreous hemorrhage after intravitreal injection of highly purified ovine hyaluronidase (Vitrase) in patients with diabetes. *Invest Ophthalmol Vis Sci*. 2008 Oct;49(10):4219-25.

# A Case of Late-Onset Leber's Hereditary Optic Neuropathy

By Carol Aune, B.S., O.D., and James Walters Ph.D., O.D.



#### Release Date

April 2012

#### Expiration Date

March 1, 2015

#### Goal Statement

This article reviews the case of a 51-year-old man with Leber's Hereditary Optic Neuropathy (LHON). In addition, it discusses the role of genetic testing in LHON patients, where the diagnosis may be difficult to confirm.

#### Faculty/Editorial Board

Carol Aune, B.S., O.D., and James Walters, Ph.D., O.D.

#### Credit Statement

This course is COPE-approved for 1 hour of CE credit. COPE ID is 33938-PS. Please check your state licensing board to see if this approval counts toward your CE requirement for relicensure. There is a \$20 fee to take this course.

#### Joint Sponsorship Statement

This continuing education course is joint-sponsored by the Pennsylvania College of Optometry.

#### Disclosure Statement

Drs. Aune and Walters have no relationships to disclose.

**LEBER'S HEREDITARY OPTIC NEUROPATHY (LHON)** is a maternally inherited mitochondrial disorder that is characterized by painless, subacute, bilateral vision loss. The condition occurs primarily in young, adult males. The average age of onset ranges between 18 and 35 years; however, delayed onset has been reported in patients as old as 73 years of age.

When examining a patient with LHON, the fundus examination may appear normal at the onset of vision loss although the clinician may observe optic nerve and nerve fiber layer (NFL) swelling on optical coherence tomography; vascular tortuosity; arteriolar dilation; and peripapillary telangiectasias.

The atrophic phase demonstrates bilateral, temporal optic pallor that often progresses to complete optic atrophy. Cell death is limited to the retinal ganglion cells and is hypothesized to be a result of apoptosis secondary to oxidative stress caused by mitochondrial mutations.

LHON is largely a diagnosis of exclusion, and other causes of optic neuropathy (i.e., toxic/nutritional, compressive, ischemic, etc.) must be ruled out. Regardless of age, genetic testing in any individual suspected of LHON should be performed to confirm the diagnosis.

There is no available treatment for LHON, but low vision aids and counseling should be recommended. Also, you should advise LHON carriers to moderate their smoking and alcohol intake.

Here, we will examine the case of a 51-year-old man with LHON. Additionally, we will discuss the role of genetic testing in LHON patients who present with unex-

plained bilateral vision loss, where the diagnosis remains in doubt.

#### Patient History

A 51-year-old black male was referred for electrodiagnostic testing by his ophthalmologist as a result of unexplained bilateral vision loss. His chief complaint included loss of central vision in both eyes (O.S. > O.D.) and decreased color vision O.U.

The patient stated that the vision in his right eye became blurred three months earlier, followed by pronounced vision loss in his left eye one month later. He informed us that his vision gradually worsened over a two-month period and then stabilized. His blurred vision was constant, and affected all viewing distances. The patient denied pain while chewing, scalp tenderness or joint ache. He also denied any family history of vision loss.

Recently, the patient was diagnosed with type 2 diabetes mellitus and hypertension. His current medications included metformin, quinapril and verapamil.

At the most recent visit to his ophthalmologist one month earlier, he was diagnosed with unexplained vision loss O.U.; complete color blindness O.U.; mild, non-proliferative diabetic retinopathy with no clinically significant macular edema O.S.; and temporal pallor of the optic nerve heads O.U.

The patient was referred for MRI scans of the brain and orbits (with and without contrast), which were unremarkable. The patient reported discontinuing all alcohol intake four months prior, but he used to consume three to four beers per day. He denied any tobacco and/or illicit drug use. The patient was a truck driver for

27 years, but was on medical leave because of his reduced vision.

### Diagnostic Data

The patient's uncorrected entering visual acuity measured 20/400 O.D and 10/400 O.S., with no improvement upon pinhole testing or refraction. Confrontation fields revealed defects in the inferior quadrants of the right eye and all regions of the left eye except the superior temporal quadrant. Other preliminary testing, including pupillary response, ocular motility and biomicroscopy, were unremarkable.

His intraocular pressure measured 22mm Hg O.D. and 17mm Hg O.S. Fundus photography indicated thinning of the temporal rim of the right optic nerve and superior rim of the left optic nerve. We observed a wedge defect in the inferior NFL of the left eye as well as mild temporal optic nerve pallor in both eyes. We performed visually evoked response (VER) and documented no significant pattern. However, a flash VER at 2Hz and 8Hz showed a moderately strong outcome in the right eye and a severely compromised outcome in the left eye.

We believed that the patient had bilateral optic atrophy, with a suspected hereditary component. We told him to return to his ophthalmologist, and recommended genetic testing for LHON.

The patient returned nine months later for a low vision evaluation. He stated that his vision remained unchanged and reported that he had not returned to the original referring ophthalmologist for additional testing.

Instead, he went to a different ophthalmologist who diagnosed him with bilateral primary open-angle glaucoma; prescribed topical bimatoprost; and referred him to a neuro-ophthalmologist.

A review of the patient's records indicated that the neuro-ophthalmologist suspected nutritional amblyopia and ordered a complete blood count. The results revealed a slight decrease in hematocrit, hemoglobin, red blood cells and B<sub>1</sub> levels (for

testing or refraction. Preliminary testing included pupillary response, ocular motility and biomicroscopy, which were unremarkable. Humphrey 24-2 visual field threshold testing revealed a significant scotoma in both eyes (O.D. > O.S.). We also documented an inferior arcuate defect of the right eye and a superior arcuate defect of the left eye.

NFL analysis on optical coherence tomography revealed thinning of the inferior and superior temporal quadrants O.U. A high-definition scan of the macula showed loss of the papillomacular NFL bundle O.U., with no other macular pathology.

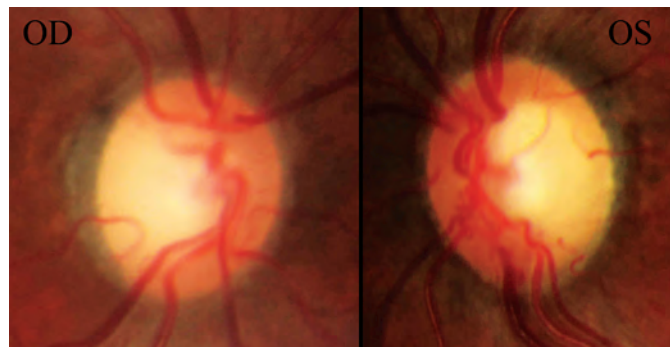
The pattern VER remained severely depressed, and the 2Hz and 8Hz flash VERs were repeated. The results indicated that the left eye was now more responsive than the right eye. Fundus photography documented increased temporal optic nerve pallor in both eyes as well as increased thinning of the superior temporal rim of the left optic nerve. The patient refused optical aids, although we observed a positive response to magnification. The patient was

counseled on a probable diagnosis of LHON, because the genetic testing results for the three primary mutations were still pending.

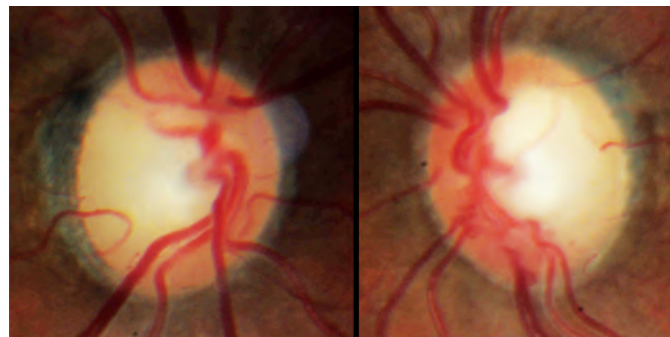
Two months later, the genetic testing results revealed a G>A nucleotide substitution at mitochondrial position 11778 in the patient's DNA. This finding was consistent with a definitive diagnosis of LHON.

### Discussion

LHON is one of the most common hereditary optic neuropathy



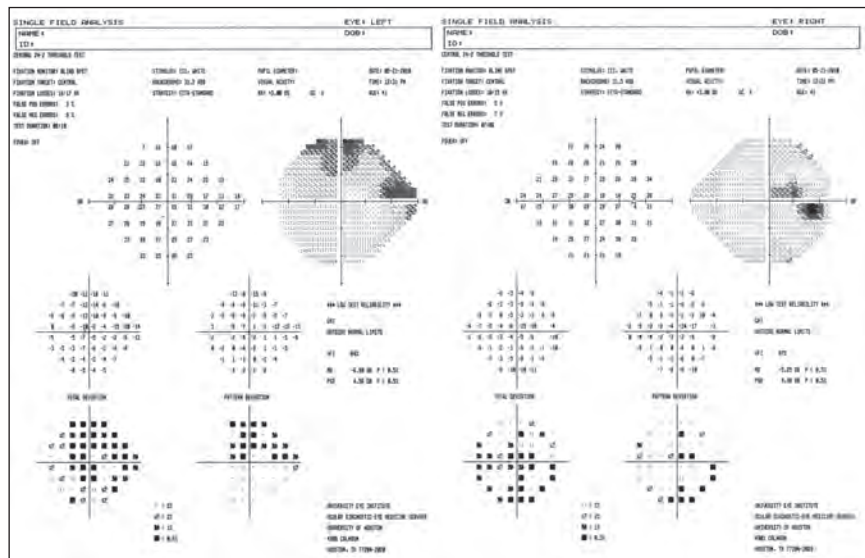
Initial presentation of our patient indicated mild temporal optic nerve pallor in both eyes.



Nine months later: Increased temporal optic nerve pallor in both eyes.

which the patient was started on B<sub>1</sub> oral supplements). However, routine chemistries, liver function studies, protein electrophoresis, lead, B<sub>12</sub> and folate levels were all normal ruling out nutritional amblyopia. At that time, the neuro-ophthalmologist suggested that LHON was the top differential diagnosis.

At the low vision evaluation, the patient's uncorrected entering visual acuity measured 10/80 O.D. and 10/60 O.S., with no improvement upon pinhole



Humphrey 24-2 visual field threshold testing revealed a significant secocentral scotoma (O.D. > 0.5.) and arcuate defects in both eyes.

thies.<sup>1</sup> Vision loss usually occurs in one eye first, and may occur either suddenly or progressively over two to three months.<sup>3</sup> Vision loss in the fellow eye typically occurs nine months later, with two months being the mean interval between vision loss in each eye.<sup>3</sup> Simultaneous onset may present in approximately 25% to 50% of occurrences.<sup>2,3</sup> Patients often have no family history of vision loss, with 40% of cases occurring in just one family member.<sup>2</sup> Males are four times more likely to be affected than females.<sup>2</sup> The worldwide prevalence of LHON is estimated to be one in 50,000.<sup>3</sup>

LHON carriers typically are asymptomatic until the onset of the acute phase, which causes central vision blurring as well as a central or secocentral scotoma on field testing.<sup>2,7</sup> During the pre-symptomatic phase, carriers may present with temporal NFL swelling and peripapillary telangiectatic vessels.<sup>2,8</sup> During the acute phase, fundus examination may be normal in 20% of patients.<sup>2</sup>

The atrophic phase demonstrates bilateral, symmetrical, temporal optic pallor that often progresses to complete optic

atrophy.<sup>2,7,8,10</sup> Optical coherence tomography frequently reveals preferential involvement of the papillomacular bundle and/or early involvement of the inferior NFL.<sup>8</sup>

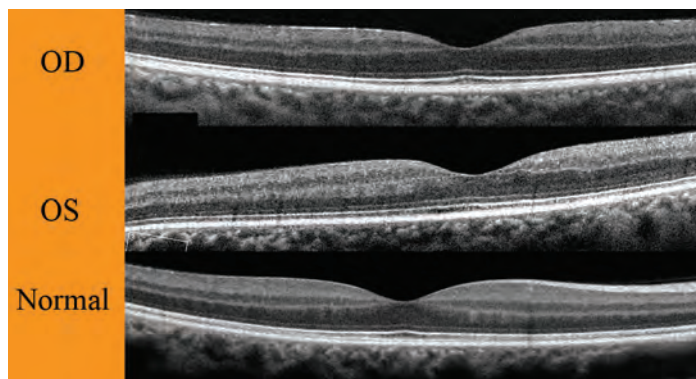
Final visual acuities usually are worse than 20/200; however, reports of mild, spontaneous recovery have been documented.<sup>2,3</sup> As with all optic neuropathies, color vision defects, especially red/green anomalies, may be observed. VER amplitudes often are found to be reduced or flat. Vision loss usually is the only symptom of LHON; but, associated neurological complications, such as peripheral neuropathy, postural tremor, movement disorders, multiple sclerosis and cardiac anomalies,

have been reported.<sup>2,4</sup>

LHON was the first mitochondrial disease to be discovered, and three primary mutations of the mitochondrial DNA (m.3460G>A, m.11778G>A, m.14484T>C) have been found in 90% of all LHON patients.<sup>1-3,8,11,12</sup> These mutations affect the first site of the mitochondrial respiratory chain.<sup>2,11</sup> It is important to note that these primary mutations are more common in patients with a family history of multigenerational vision loss, whereas patients with no known family history often do not have a primary mutation.<sup>11</sup>

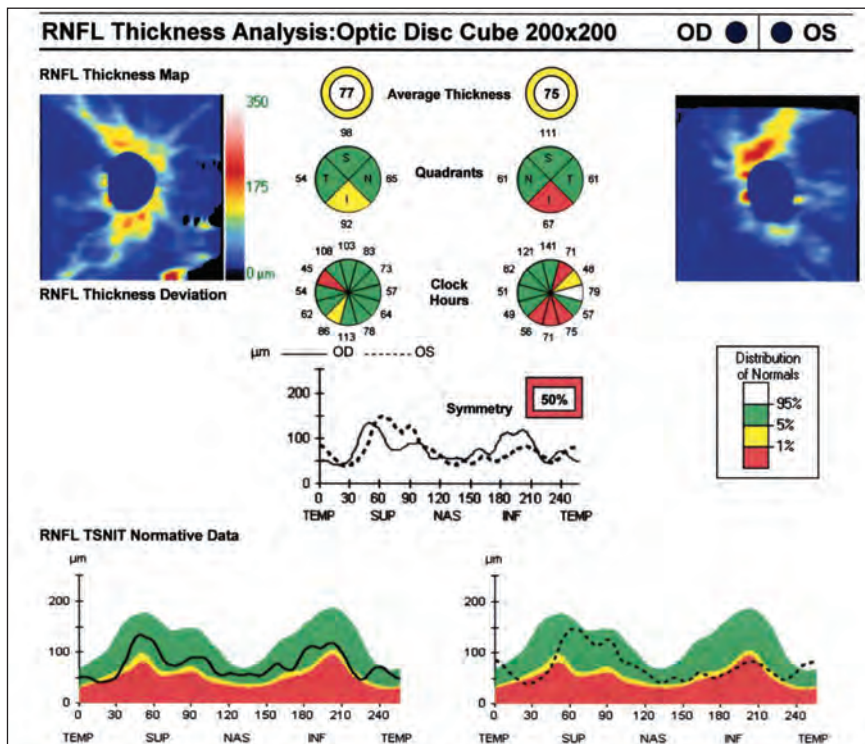
In recent years, 45 other mutations in mtDNA also have been associated with LHON.<sup>13</sup> Just 50% of males and 10% of females with the genetic defect develop optic neuropathy.<sup>4,12</sup> Due to this incomplete penetrance, it is likely that other factors are involved in disease expression. Smoking and high alcohol intake have been identified as triggers for visual loss in individuals carrying a known Leber's mutation.<sup>12</sup> Other factors, such as poor nutrition, stress, exposure to toxins and trauma, have been reported in clinical practice.<sup>12</sup>

The optic nerve is rich in mitochondria, and neurons are dependent on mitochondria for survival. Defects in the respiratory chain of the mitochondria lead to increased free radical proliferation and decreased ATP production, which cause oxidative stress.<sup>4</sup>



A high-definition optical coherence tomography (OCT) scan of the macula documented loss of the papillomacular nerve fiber layer in both eyes, with no other macular pathology.





Nerve fiber layer analysis on OCT revealed thinning of the inferior and superior temporal quadrants O.U.

It is theorized that neuronal degeneration is a result of oxidative damage caused by associated oxidation.<sup>4</sup>

Cell death is limited to the retinal ganglion cells, and is hypothesized to be a result of apoptosis secondary to oxidative stress (although it is unknown why only the ganglion cell layer is affected or why healthy individuals suddenly develop symptoms).<sup>2,13</sup> The preferential involvement of the papillomacular bundle is thought to occur because of its small axons.<sup>8</sup>

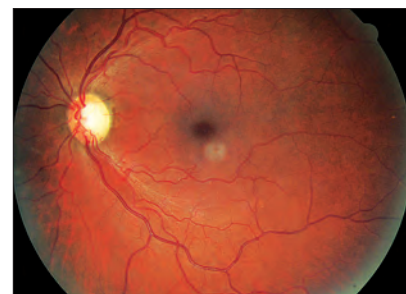As previously mentioned, there are no known treatments for LHON. The LHON Treatment Trial attempted to use topical brimonidine prophylactically to prevent vision loss in patients' unaffected eyes.<sup>7</sup> Brimonidine was used because of its antiapoptotic properties; however, it was unsuccessful. Other studies have shown that idebenone, minocycline, infrared light and multivitamin supplementation, were ineffective

in improving vision or preventing vision loss.<sup>2,3,7,14</sup> Currently, antioxidant gene therapy is under investigation.<sup>13</sup>

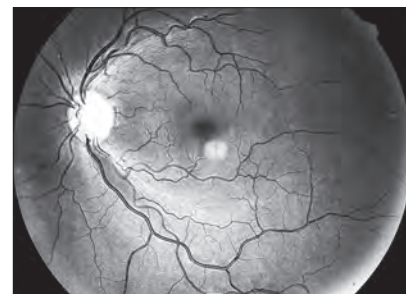LHON is largely a diagnosis of exclusion, and diagnostic confusion may occur with compressive, toxic, nutritional, ischemic or other hereditary optic neuropathies. All patients suspected of LHON should undergo MRI, VER and complete blood testing to rule out other etiologies.

Ultimately, all LHON suspects should be considered for genetic testing to confirm the diagnosis. Remember, however, absence of the mutation does not rule out LHON, because all the mutations attributed to the disease have not yet been identified. ■

*Dr. Aune is an optometrist practicing in Raleigh and Eastern N.C., where she focuses on ocular pathology, low vision and specialty contact lenses. Dr. Walters is an associate professor at the University of Houston College of Optometry and clinical director of the Ocular Diagnostic and Medical Clinic at the University Eye Institute. He has a background in*



Fundus photography of our patient's left eye at initial presentation. We located a wedge defect in the inferior nerve fiber layer. The posterior pole of the right eye was unremarkable.



The wedge defect in the inferior nerve fiber layer was more evident on red-free photography.

*clinical electrophysiology and a special interest in retinal pathology.*

1. Abu-Amero K, Bosley T. Mitochondrial Abnormalities in Patients with LHON-like Optic Neuropathies. *Invest Ophthalmol Vis Sci.* 2006 Oct;47(10):4211-20.
2. Yu-Wai-Man P, Chinnery P. Leber Hereditary Optic Neuropathy. In: *GeneReviews at GeneTests: Medical Genetics Information Resource.* Available at: [www.ncbi.nlm.nih.gov/books/NBK1174/](http://www.ncbi.nlm.nih.gov/books/NBK1174/) (accessed January 25, 2012).
3. Orsaud C. Leber's hereditary optic neuropathy. *Orphanet Encyclopedia.* Available at: [www.orpha.net/data/patho/GB/uk-LHON.pdf](http://www.orpha.net/data/patho/GB/uk-LHON.pdf) (accessed January 25, 2012).
4. Kumar M, Tanwar M, Saxena R, et al. Identification of novel mitochondrial mutations in Leber's hereditary optic neuropathy. *Mol Vis.* 2010 Apr 30;16:782-92.
5. Shah V, Randhawa S, Mizen T et al. You're too old for that. *Surv Ophthalmol.* 2008 Jul-Aug;53(4):403-10.
6. Ajax ET, Kardon R. Late-onset Leber's hereditary optic neuropathy. *J Neuroophthalmol.* 1998 Mar;18(1):30-1.
7. Newman N. Progression of visual field defects in leber hereditary optic neuropathy: experience of the LHON treatment trial. *Am J Ophthalmol.* 2006 Jun;141(6):1061-7.
8. Barboni P, Carbonelli M, Savini G, et al. Natural history of Leber's hereditary optic neuropathy: longitudinal analysis of the retinal nerve fiber layer by optical coherence tomography. *Ophthalmology.* 2010 Mar;117(3):623-7.
9. Borruat F, Green W, Graham E. Late onset Leber's optic neuropathy: a case confused with ischemic optic neuropathy. *Br J Ophthalmol.* 1992 Sep;76(9):571-3.
10. Trobe J, Glaser J, Cassidy J. Optic Atrophy: Optic atrophy. Differential diagnosis by fundus observation alone. *Arch Ophthalmol.* 1980 Jun;98(6):1040-5.
11. Ramos C, Bellusci C, Savini G, et al. Association of optic disc size with development and prognosis of Leber's hereditary optic neuropathy. *Invest Ophthalmol Vis Sci.* 2009 Apr;50(4):1666-74.
12. Kirkman M, Yu-Wai-Man P, Korsten A, et al. Gene-environment interactions in Leber hereditary optic neuropathy. *Brain.* 2009 Sep;132(Pt 9):2317-26.
13. Qi X, Sun L, Hauswirth W, et al. Use of mitochondrial antioxidant defenses for rescue of cells with a Leber hereditary optic neuropathy-causing mutation. *Arch Ophthalmol.* 2007 Feb;125(2):268-72.
14. Mashima Y, Kigasawa K, Wakakura M, Oguchi Y. Do idebenone and vitamin therapy shorten the time to achieve visual recovery in Leber hereditary optic neuropathy? *J Neuroophthalmol.* 2000 Sep;20(3):166-70.

## Questions

### 1. Which statement regarding the inheritance pattern of Leber's hereditary optic neuropathy (LHON) is true?

- It is an X-linked recessive disorder.
- It is a paternally inherited mitochondrial disorder.
- It is a maternally inherited mitochondrial disorder.
- Males can transmit this condition to their daughters only in very rare instances.

### 2. Which symptoms characterize a classic presentation of LHON?

- Painless, acute, unilateral vision loss that is seen primarily in the elderly.
- Painless, subacute, bilateral vision loss that is seen primarily in young adult males.
- Slowly progressive, unilateral or bilateral vision loss that is often accompanied by headaches.
- Severely impaired vision as an infant that is often accompanied by jerking, involuntary eye movements.

### 3. What clinical findings may be observed upon initial presentation?

- A normal fundus.
- Peripapillary telangiectasias.
- Leakage on fluorescein angiography.
- Both a and b.

### 4. What is an effective treatment option for LHON?

- No known treatments currently are available.
- Topical brimonidine.
- Antioxidant gene therapy.
- Nutritional supplements.

### 5. What is the appropriate management for a patient diagnosed with LHON?

- Counsel patient on condition; recommend fish oil and a diet rich in red meat.
- Counsel patient on condition; prescribe high-dose vitamin A; and refer for low vision devices.
- Counsel patient on condition; recommend moderate smoking and alcohol intake; and refer for low vision devices.
- Counsel patient on condition; inform him or her of probable resolution within three months.

### 6. Which condition should be ruled out when considering a diagnosis of LHON?

- Toxic or nutritional optic neuropathies.
- Compressive optic neuropathy.
- Ischemic optic neuropathy.
- All of the above.

### 7. Which test can provide a definitive diagnosis of LHON?

- Genetic testing for known LHON mutations.
- Optical coherence tomography (OCT).
- Magnetic resonance imaging (MRI).
- All of the above.

### 8. Why is OCT a useful tool when gathering data to support a diagnosis of LHON?

- During the acute phase, nerve fiber layer (NFL) swelling may be observed.
- Preferential involvement of the papillomacular bundle may be observed.
- Early involvement of the inferior NFL may be observed.
- All of the above.

### 9. What is a known trigger for the expression of LHON?

- Minocycline use.
- Smoking and high alcohol intake.
- Ultra violet light exposure.
- All of the above.

### 10. What is the proposed mechanism of action in LHON?

- Defects in the mitochondrial respiratory chain lead to oxidative stress, neuronal damage and apoptosis of the retinal ganglion cells.
- Defects in the retinal vessels due to arteriosclerosis and vascular disease lead to an ischemic event that affects the short posterior ciliary artery that supplies the optic nerve.
- Focal regions of breakdown in the choriocapillaris vasculature lead to degeneration of the retinal pigment epithelium, resulting in photoreceptor loss.
- Spontaneous apoptosis of the retinal ganglion cells occurs via a mechanism that is not well understood.

## Examination Answer Sheet

Valid for credit through March 1, 2015

### A Case of Late-Onset Leber's Hereditary Optic Neuropathy

Directions: Select one answer for each question in the exam and completely darken the appropriate circle. A minimum score of 70% is required to earn credit. There is a \$20 fee to take this course

Mail to: Optometric CE, PO Box 488, Canal Street Station, New York, NY 10013  
COPE-approved for 1 hour of CE Credit. COPE ID: 33938-PS.

There is an eight-to-ten week processing time for this exam.

- (A) (B) (C) (D) 11. The goal statement was achieved:  
Very Well  Adequately  Poorly
- (A) (B) (C) (D) 12. The information presented was:  
Very Useful  Useful  Not Very Useful
- (A) (B) (C) (D) 13. The difficulty of the course was:  
Complex  Appropriate  Basic
- (A) (B) (C) (D) 14. Your knowledge of the subject was increased:  
Greatly  Somewhat  Hardly
- (A) (B) (C) (D) 15. The quality of the course was:  
Excellent  Fair  Poor
- (A) (B) (C) (D) How long did it take to complete this course?  
\_\_\_\_\_
- (A) (B) (C) (D) Comments on this course:  
\_\_\_\_\_
- (A) (B) (C) (D) Topics you would like in the future CE articles:  
\_\_\_\_\_

Please retain a copy for your records. Please print clearly.

You must choose and complete one of the following three identifier types:

① SS # \_\_\_\_\_ - \_\_\_\_\_ - \_\_\_\_\_

Last 4 digits of your SS # and date of birth State Code and License #: (Example: NY12345678)

② \_\_\_\_\_ ③ \_\_\_\_\_

First Name \_\_\_\_\_

Last Name \_\_\_\_\_

E-Mail \_\_\_\_\_

The following is your:  Home Address  Business Address

Business Name \_\_\_\_\_

Address \_\_\_\_\_

City \_\_\_\_\_ State \_\_\_\_\_

ZIP \_\_\_\_\_

Telephone # \_\_\_\_\_ - \_\_\_\_\_ - \_\_\_\_\_

Fax # \_\_\_\_\_ - \_\_\_\_\_ - \_\_\_\_\_

By submitting this answer sheet, I certify that I have read the lesson in its entirety and completed the self-assessment exam personally based on the material presented. I have not obtained the answers to this exam by any fraudulent or improper means.

Signature \_\_\_\_\_ Date \_\_\_\_\_

Lesson 108143

RO-0412-2

## A Case of Suspected Retinal Melanocytoma

By W. Lee Ball, O.D., F.A.A.O.

**MELANOCYTOMA** is a neoplasm or hamartoma that is composed of melanocytes.<sup>1,2</sup> Most commonly found on the optic nerve, melanocytomas usually are asymptomatic.<sup>2</sup> However, in certain instances, they cause blurry vision. Here, we review a case report of a suspected presentation of retinal melanocytoma.

### History

A 23-year-old white female presented to the Beth Israel Deaconess Medical Center's Division of Ophthalmology in Boston on November 11, 2010. Her chief complaint was of a gray spot in her vision O.D. that had been evident for the past five years. Most recently, she noticed that the spot had increased in size. We noted no associated redness, itching or discharge. She denied the presence of flashes, floaters, transient visual obscurations or headache.

Excluding annual vision evaluations by her primary care physician, this was our patient's first comprehensive eye care examination. Her ocular and medical histories were negative for trauma or systemic disease. Additionally, her family medical and ocular histories were negative for systemic disease, glaucoma, retinal detachments, age-related macular degeneration or other hereditary retinal disorders.

Further, the patient's social history was noncontributory. She is a graduate student at a local university and denied a history of smoking, illicit drug use or ethanol consumption. The patient took no medications and reported a drug allergy to penicillin (rash). Although she was concerned about the change in vision, the patient was oriented to time, place and person, and had a generally pleasant demeanor.

### Diagnostic Data

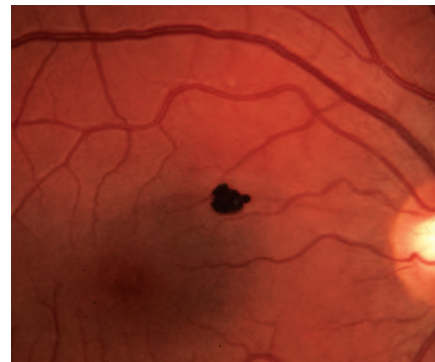
Best-corrected visual acuity measured 20/20 O.U. at distance and near. Amsler grid was remarkable for mild paracentral metamorphopsia O.D. On Ishihara pseudo-isochromatic testing, color vision was normal in both eyes. Pupillary responses were equal, round and reactive to light, with no afferent defect O.U. Extraocular muscle movements were full and unrestricted in all positions of gaze O.U. Cover testing revealed orthophoria at distance and four prisms of exophoria at near. Confrontation fields were full to careful finger counting in each eye.

Both gross inspection of the face and anterior segment evaluation of the lids were negative for lumps, bumps or other abnormalities. Her corneas were clear, with no scarring, edema, neovascularization, infiltrates or dendrites. The bulbar and palpebral conjunctivae were clear without evidence of injection, chemosis, melanosis, papillae or follicles. The anterior chambers were deep and quiet, with no trace of cells or flare, hyphema or hypopyon.

The irides were brown in color; flat; and without transillumination defects or other signs of atrophy, tears, nodules or neovascularization. We detected no posterior synechiae.

Gonioscopy was not performed. However, using Van Herick's method, we estimated her anterior chamber angles to be grade 4—both nasally and temporally O.U.

Both corneas were anesthetized with one drop of 0.5% proparacaine hydrochloride at 3:10 p.m. We also placed one strip of 0.6mg fluorescein sodium on the lower fornix of each eye. We noted no



1. Fundus image of a patient's right eye revealed the presence of a darkly pigmented lesion.

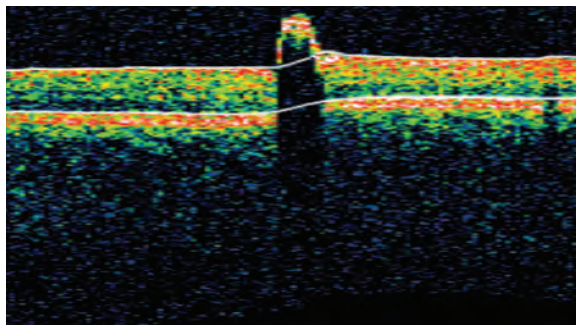
corneal staining O.U.

Her intraocular pressure measured 15mm Hg O.U. at 2:15 p.m. The patient was dilated at 2:20 p.m. with one drop of 2.5% phenylephrine hydrochloride and Tropicamide (tropicamide 1%, Bausch + Lomb) O.U.

A dilated posterior segment evaluation of each eye revealed clear crystalline lenses without opacification or congenital cataract. No red or white cells were found in the vitreous of either eye, and there was no evidence of posterior vitreous detachment or syneresis.

The optic nerve measured 0.5mm in the horizontal and vertical meridians and was pink, well perfused and round, with distinct margins O.U. No notching, bean-podding, Drance hemorrhage or retinal nerve fiber layer loss was noted in either eye. The disc had a normal appearance without tilting, crescents or peripapillary atrophy O.U. The retinal vasculature in each eye had a normal course and caliber, with an arteriole-to-venule ratio of 2:3. There were no signs of arteriovenous nicking or venous beeding O.U.

There were no signs of retinal neovascularization, retinitis or underlying choroidal processes



2. Optical coherence tomography scan revealed a superficial lesion O.D.

O.U. There were no retinal holes, tears or detachments, and we obtained clear views to the ora serrata at 360°.

We noted a darkly pigmented, well-defined lesion located nasal to the macula and along the superior arcade O.D. (*figure 1*). The left macula was unremarkable, and we noted a positive foveal reflex O.U.

We performed color fundus photography O.D. Additionally, we ordered an optical coherence tomography (OCT) scan, which revealed a superficial lesion with retinal shadowing O.D. (*figure 2*). Following the OCT scan, we called for a chair-side consultation with an in-office retinal specialist. He examined the patient and agreed with the working diagnosis of retinal melanocytoma.

We recommended observation and informed the patient that the lesion was benign in nature—although it could grow slowly with time. We did not provide the patient with a new spectacle prescription.

## Differential Diagnoses

The differential diagnoses considered in this case include:

- **Congenital hypertrophy of the retinal pigment epithelium (CHRPE).** The typical fundus lesion is a solitary, round, flat, hyperpigmented lesion that is well demarcated from normal-appearing retinal pigment epithelium (RPE). The color ranges from light brown to black. Clinically, the overlying retina and vasculature appears nor-

mal. The lesions vary in size from pinpoint to several disc diameters, and may be found anywhere in the retina.<sup>3</sup>

- **Choroidal melanoma.** These lesions almost always appear elevated and are not as uniformly pigmented or as sharply demarcated as CHRPE.<sup>3</sup> Also, cho-

roidal melanomas usually exhibit growth. On A-scan ultrasonography, the regular structure and low-to-medium reflectivity are indicative of the characteristic homogenous cellular structure.<sup>4</sup>

- **Choroidal nevus.** Choroidal nevi are located deep to the RPE. They appear flat, and may range from light to dark brown in color. The borders are less well defined than CHRPE, and often have a feathery appearance (because nevus cells extend along larger choroidal vessels). Drusen and pigmentary modeling are often seen on the surface of nevi, which suggests chronicity.<sup>3</sup>

- **Melanocytoma.** These entities have a similar appearance to that of nevi, save a jet-black color. Melanocytoma may be found in the choroid, on the optic nerve, or throughout the fundus.<sup>3</sup>

## Diagnosis

The final assessment of the patient is retinal melanocytoma.

## Treatment and Follow-up

Remember, there are no available treatments for retinal melanocytoma. Appropriate follow-up includes yearly observation to monitor for disease progression. Almost all cases of melanocytoma are benign with transformation into malignant melanoma occurring in only 1% to 2% of cases.<sup>2,5</sup> If malignant transformation does occur, enucleation of the eye may be considered.<sup>5</sup>

## Discussion

Melanocytomas are rare. In multiple published case studies, melanocytomas represented just five of 907 pigmented intraocular tumors examined.<sup>6</sup> Such darkly pigmented lesions are usually located at the optic nerve head, but may be found throughout the fundus.<sup>2,6</sup> Reflectivity on A-scan ultrasonography generally is high, with no significant vascularization.<sup>4</sup> These findings are significantly different from melanoma, making differentiation relatively easy.

This case illustrates the fundamental importance of patient history, clinical observation and OCT studies in the diagnosis of retinal melanocytoma. OCT supported the clinical impression that the jet-black lesion with sharp borders was superficial, as seen with retinal shadowing. No vascularization was present. Given the clinical findings, we believed that an A-scan was not warranted.

Again, there is no treatment for retinal melanocytoma. But, in any suspected case, be certain to schedule the patient for regular checkups to monitor progression. ■

*Dr. Ball is a graduate of the University of Houston College of Optometry and a Fellow of the American Academy of Optometry. He completed an optometric residency at the University of Miami Bascom Palmer Eye Institute. After residency, Dr. Ball joined the staff at Beth Israel Deaconess Medical Center, a teaching hospital of Harvard Medical School. He is also the associate director of medical affairs for Vistakon, a division of Johnson & Johnson Vision Care.*

1. Dorland WN. Dorland's Illustrated Medical Dictionary, 28th edition. Philadelphia: Elsevier; 1994.

2. Zou Y, Ni C. Clinical and histopathological studies of melanocytoma of the optic disc. *Yan Ke Xue Bao.* 2000 Jun;16(2):112-5.

3. Schachat AP, Murphy RP, Patz AP. *Retina Basic Science and Inherited Retinal Disease.* St. Louis: The CV Mosby Company; 1989.

4. Hodes BL, Choromokos E. Standardized A-scan echographic diagnosis of choroidal malignant melanomas. *Arch Ophthalmol.* 1977 Apr;95(4):593-7.

5. Murray TG. Bascom Palmer Eye Institute. Ocular Oncology: Melanocytoma. Available at: [www.eyecancercmd.org/eye\\_cancers.html#melanocytoma](http://www.eyecancercmd.org/eye_cancers.html#melanocytoma) (accessed March 26, 2012).

6. Howard GM, Forrest AW. Incidence and location of melanocytomas. *Arch Ophthalmol.* 1967 Jan;77(1):61-6.