

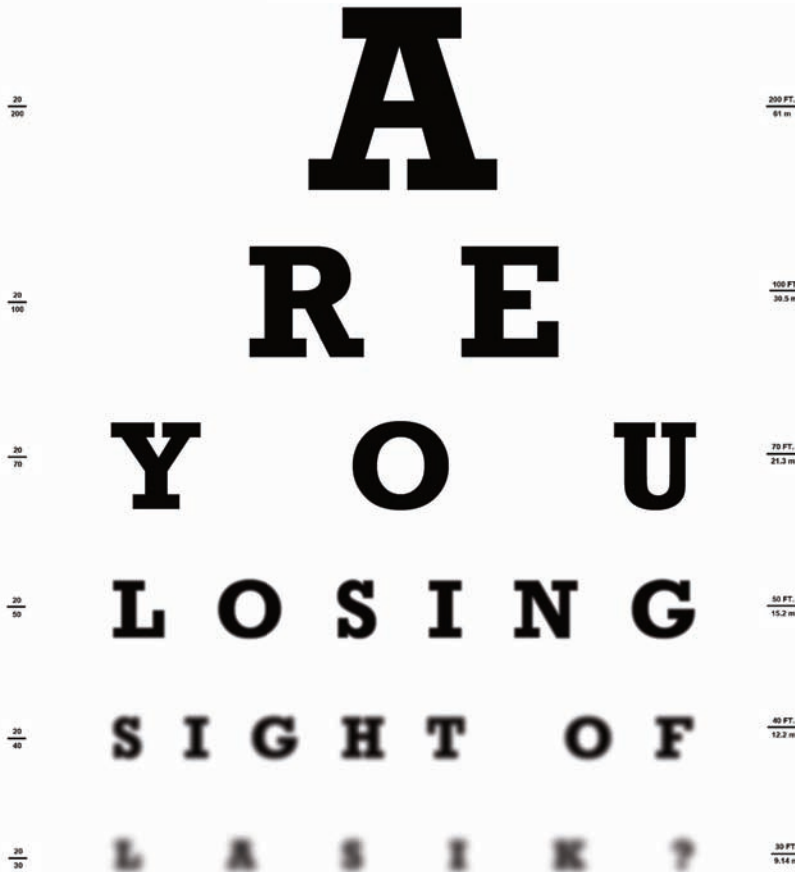

November 15, 2012

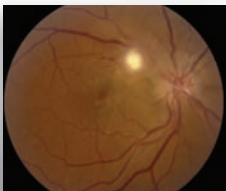# REVIEW<sup>®</sup> OF OPTOMETRY

www.revoptom.com

## 18<sup>TH</sup> ANNUAL REFRACTIVE SURGERY REPORT



As a flat-lining economy struggles to rebound, O.D.s give LASIK mixed reviews as a means to boost the bottom line, p. 53



**Also Inside:**  
**Ocular Complications  
in IV Drug Users, p. 40**

Slowing Myopia Progression in Children, p. 28

An O.D.'s View on the Latest Monofocal IOLs, p. 49

EHR: Embracing the Next Phase of Meaningful Use, p. 36

SUBTRACT LENS DRYNESS.

**ADD**  
NEW PATIENTS.



You and Sally

**ACUVUE**<sup>®</sup>  
**OASYS**<sup>®</sup>  
BRAND CONTACT LENSES  
WITH HYDRACLEAR<sup>®</sup> PLUS

“I never experience dryness.” That’s what more of your ACUVUE<sup>®</sup> OASYS<sup>®</sup> Brand patients said in a clinical study: at least 67% more than those wearing Biofinity<sup>®</sup> or AIR OPTIX<sup>®</sup> AQUA. No wonder that on average your ACUVUE<sup>®</sup> OASYS<sup>®</sup> patients have already told 6.5 people about you. Grow your practice. Fit more ACUVUE<sup>®</sup> OASYS<sup>®</sup>.

\*44% of ACUVUE<sup>®</sup> OASYS<sup>®</sup> and 25% of Biofinity<sup>®</sup> patients reported never experiencing dryness after 2 weeks’ wear, and in a separate study, 40% of ACUVUE<sup>®</sup> OASYS<sup>®</sup> and 24% of AIR OPTIX<sup>®</sup> AQUA patients reported never experiencing dryness after 2 weeks’ wear.

ACUVUE<sup>®</sup> Brand Contact Lenses are indicated for vision correction. As with any contact lens, eye problems, including corneal ulcers, can develop. Some wearers may experience mild irritation, itching or discomfort. Lenses should not be prescribed if patients have any eye infection, or experience eye discomfort, excessive tearing, vision changes, redness or other eye problems. Consult the package insert for complete information. Complete information is also available from VISTAKON<sup>®</sup> Division of Johnson & Johnson Vision Care, Inc., by calling 1-800-843-2020 or by visiting [jnvisioncare.com](http://jnvisioncare.com).

The third-party trademarks used herein are trademarks of their respective owners.

ACUVUE<sup>®</sup>, ACUVUE<sup>®</sup> OASYS<sup>®</sup>, HYDRACLEAR<sup>®</sup>, and VISTAKON<sup>®</sup> are trademarks of Johnson & Johnson Vision Care, Inc.

© Johnson & Johnson Vision Care, Inc. 2012. ACU-28759G October 2012



Sally



Sally's Co-worker



Sally's Dentist



Sally's Electrician



Sally's Hairstylist



Sally's Yoga Instructor



Sally's Niece



Sally's Mechanic



Sally's Brother



Sally's Neighbor



Sally's Banker



Sally's Teacher



Sally's Grocery Clerk



Sally's Manicurist



## IN THE NEWS

**Optometrist** is the **12th best job in America**, according to CNNMoney/PayScale.com's list of America's 100 best jobs. Among the perks is "**good pay**, without the frequent long hours and middle-of-the-night emergency calls." Median pay is \$105,000, top pay is \$149,000, and there's an expected 33.1% in job growth over the next 10 years. The report did note a few of the challenges, particularly the difficulty and **cost of an optometry degree** and the evening and weekend hours for some optometrists.

The FDA approved **Jetrea** (ocriplasmin, ThromboGenics) for symptomatic **vitreomacular adhesion**, making it the first pharmacological agent to be approved for this indication. The recommended dose of Jetrea is a single intravitreal injection of 0.125mg (0.1mL) of the diluted solution administered to the affected eye.

The global **diabetic macular edema market** is expected to climb exponentially in value in the near future—from \$43 million in 2011 to **\$985 million** in 2018, according to the latest report from GBI Research. The dramatic growth will be a result of lifestyle changes and the introduction of more effective, more expensive treatments.

Heavy **caffeinated coffee** consumption is associated with an increased risk of developing **exfoliation glaucoma**, according to researchers at Brigham and Women's Hospital in Boston. Superficially, people who drink three or more cups of caffeinated coffee a day have a higher risk of developing exfoliation glaucoma or becoming a glaucoma suspect.

# Hurricane Sandy Puts Practice Down, Not Out

Here's the story of one New Jersey practice hit hard by the recent "superstorm." **By John Murphy, Executive Editor**

**O**ptometrist Robert Snyder almost lost his "third and favorite child"—the term his wife and two actual children have named his beloved office in the small seaside town of Ship Bottom, N.J.

That "child" was severely damaged and nearly destroyed by Hurricane Sandy, which flooded and ravaged Ship Bottom and other towns on Long Beach Island, a narrow 18-mile-long barrier island along the New Jersey coastline.

Before the "Frankenstorm" hit the East Coast on October 29, Dr. Snyder had heeded the warnings. He filled about 100 sandbags to barricade water from entering the doorways. He taped up the cracks around his front and back doors. He picked up all his computer equipment and chairs off the floor and stacked them on tables.

"But I could have done better," he said afterward. "I was thinking, the water will never get in here. It never has in my 32 years of practice."

But it did get in. Up to a foot of murky seawater flooded into the building, located a block away from the beach but only a few feet above sea level.

"It's amazing what that much water can do," Dr. Snyder said. "You open up a drawer, and the whole drawer is full of dirty, stinking water. All of the carpeting and



**Robert Snyder, O.D., performs the heart-breaking—and noxious—task of cleaning up his office after Hurricane Sandy.**

flooring is ruined. Everything is warped—not one door will close properly. All the cabinetry is starting to delaminate. All my frame displays are shot. The motors in my [exam] chairs and stands are finished. Twelve inches of water got into the walls, so they need to be torn out, cleaned out and replaced. The sewer backed up and the bathrooms are a mess."

To add insult to injury, he had renovated the office only a few years ago. So all the work and expense of the renovation is literally down the drain.

But that's not all. "We're beginning to go to EMRs, but we're not there yet. So we still have thousands and thousands of files, and unfortunately the lower rack got hit. So if you're a patient whose name starts with a W, you're screwed," he said, only half-joking.

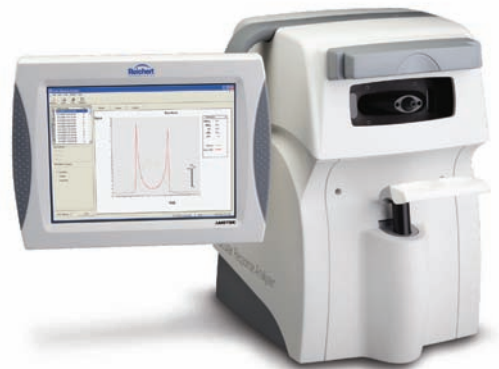
*Continued on page 8*

## *Who knew that Glaucoma Diagnosis would start with an Apple Drop?*



Sometimes brilliant ideas just hit you in the head. Like determining glaucoma risk with corneal hysteresis. Reichert's Ocular Response Analyzer® (ORA) measures the biomechanical properties of the eye providing the most accurate data for predicting glaucoma progression. Make your next glaucoma decision with gravity minus the guesswork.

Learn more. Call 1-888-849-8955, or visit [reichert.com/ora](http://reichert.com/ora).

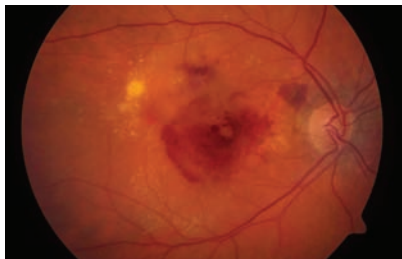


**The New Physics of Glaucoma.**

# Research Questions Safety of Long-Term Anti-VEGF Use

By Frank Celia, Contributing Writer

**Y**ou probably already know about the treatment burden posed by anti-VEGF therapy for AMD and other retinal diseases—namely, that the remarkable visual acuity gains come at the expense of a lifelong injection regimen. Less well known: Long-term anti-VEGF use may also pose structural risks to the retina—although it is unclear whether these arise from the therapy or the devastating effects of AMD itself.



**A new study questions whether anti-VEGF treatment does more harm than good.**

A study from the Scripps Research Institute, published in this month's *Journal of Clinical Investigation*, found mice with their VEGF-producing genes removed experienced deterioration of the choriocapillaris (the major supplier of nourishment to the retinal pigment epithelium), death of cone photoreceptors and corresponding visual loss. This led researchers to speculate that drastic VEGF reduction may do more harm than good. The Scripps team plans follow-up research on human AMD patients and to explore other potential targets for suppressing angiogenesis.

Because VEGF plays a role

in choroidal vascular development, it is widely believed to be a contributor to adult retinal health. Research suggests VEGF signaling may help maintain the choriocapillaris.

That gives some retina specialists pause. "It may be possible to induce too much VEGF suppression," says Pravin Dugel, M.D., a Phoenix-based retinal specialist. "Some neovascularization, some profusion may actually be beneficial, or else we risk trading in one problem for another." He notes that in the CATT year-two trial results, patients with the driest, thinnest retinas also showed higher incidence of geographic atrophy. Other studies have linked geographic atrophy and photoreceptor cell death with long-term AMD.

Combination therapy may help to ease treatment burden problems as well as maintain VEGF equilibrium, according to Dr. Dugel, who is involved in investigating Fovista (Ophthotech), an anti-PDGF (platelet-derived growth factor) agent, administered simultaneously with Lucentis (ranibizumab, Genentech) anti-VEGF therapy.

At this month's American Academy of Ophthalmology meeting, Dr. Dugel presented Phase II clinical data that involved 449 subjects. Patients who received Fovista 1.5mg combined with Lucentis 0.5mg experienced a mean increase of +10.6 letters of vision at six months—a 62% improvement over Lucentis monotherapy.

Anti-PDGF and anti-VEGF work

synergistically, Dr. Dugel says, with the former stripping a protective layer of pericytes from neovascular endothelial cells to allow the latter to work more effectively at fighting proliferation.

Despite the likely arrival of Fovista and other agents that might outperform anti-VEGF alone, no hard evidence exists to confirm that long-term anti-VEGF therapy poses health risks in humans.

"It is difficult if not impossible to distinguish between atrophic damage that occurs in the natural course of the disease and theoretical atrophic damage that might occur from anti-VEGF therapy, and I'm not aware of any such evidence in human studies," explains Robert Bhisitkul, M.D., professor of clinical ophthalmology at the University of California, San Francisco, who has studied the subject.

He makes a distinction between "geographic atrophy" that occurs in dry AMD, and non-specific damage to the retina and RPE that occurs in wet AMD.

"Geographic atrophy in dry AMD is like termites, whereas atrophic damage in wet AMD is like water or fire damage—both can result in damage to your house, but they are different processes," Dr. Bhisitkul says. In neovascular AMD, "you've got fluid and blood poured onto the retina, causing mechanical damage; you've got blood vessels burrowing into the RPE, causing destruction."

Kurihara T, Westenskow PD, Bravo S, et al. Targeted deletion of VEGFA in adult mice induces vision loss. *J Clin Invest*. 2012 Nov 1;122(11):4213-7.



JETREA™

(ocriplasmin)

Intravitreal Injection, 2.5 mg/mL

**NOW FDA APPROVED**

**...AVAILABLE FOR YOUR  
PATIENTS IN JANUARY 2013**

©2012 ThromboGenics, Inc. All rights reserved.  
ThromboGenics, Inc. 101 Wood Avenue South, 6th Floor, Iselin, NJ 08830 - USA

JETREA and the JETREA logo are trademarks or registered trademarks of ThromboGenics NV in the United States, European Union, Japan, and other countries.

THROMBOGENICS and the THROMBOGENICS logo are trademarks or registered trademarks of ThromboGenics NV in the United States, European Union, Japan, and other countries.

 **ThromboGenics®**

11/12 OCRVMA0015 A

# Hurricane Sandy Socks N.J. Practice

Continued from page 4

Fortunately, Snyder Eye Group has a smaller satellite office in the “mainland” town of Tuckerton, N.J. Dr. Snyder, along with his staff and the other optometrists in his practice—his wife Lauren Scharf-Snyder, O.D., and his associate Freddie Davis, O.D.—moved as many frames, files and exam and lab equipment as they could to the satellite office so the cleanup of the Ship Bottom office could begin. “In my [Tuckerton] exam room right now, I have four slit lamps in one corner, four phoropters in another corner, and I brought more instruments to my home,” he said.

His home is another story. It suffered no serious damage, but it too is located on Long Beach Island, which has been closed to inhabitants since a mandatory evacuation before the storm hit.

At press time, more than 12 days after the storm, residents were still not allowed to return to live in their homes—they were permitted only short “grab and go” visits. Electricity and water



**Workers from a cleaning crew tear up carpets, baseboards, drywall and anything else that got soaked in Dr. Snyder's Ship Bottom, N.J., office.**

service had not yet been restored, and natural gas for heat is shut down indefinitely to prevent fires and explosions.

So, the Snyders have been living in a Holiday Inn across the bridge from the island. But also at press time, their reservation was up, the hotel had no other rooms, and they are effectively homeless. Their cars are stuffed with whatever clothes and necessities will fit.

“I don’t know what to do,” he said. “Every day there’s a new story, a new rumor. That’s the frustrating thing—I don’t know what

to do next.”

That said, he’s got his hands full trying to connect with patients—most of whom are also residents and are now displaced—and following up with several different insurance companies. (See “Emergency Advice for Every Practice,” below.)

Meanwhile, it can take hours to perform everyday tasks that used to take minutes—buying gasoline, finding somewhere to do the laundry, tracking down the mail, even getting food to eat.

“I’m the last person to think I would ever need help from the Red Cross,” said Dr. Scharf-Snyder. “But the Red Cross fed me last night because there’s no restaurants—no place to eat if you want to be on the island.”

But, she said, “I know we’re going to be OK. Many other people have it much worse. Our receptionist lost her house.”

Nevertheless, the staff—and their spouses—are pitching in to keep the practice going.

“It’s very upsetting,” Dr. Snyder said, unable to hold back the emotion and the tears. “Just like that, your life is turned upside down. But my staff and everyone has been great. People are with me. They’re trying to help Snyder Eye Group keep moving.”

*The Snyders were pleased to report that many people have come forth to offer them assistance. If you want to help, Dr. Scharf-Snyder recommends donating to the American Red Cross ([www.redcross.org/hurricane-sandy](http://www.redcross.org/hurricane-sandy)). Another way to help: Donate to Optometry’s Fund for Disaster Relief ([www.aoa.org/disaster-relief.xml](http://www.aoa.org/disaster-relief.xml)).*

## Emergency Advice for Every Practice

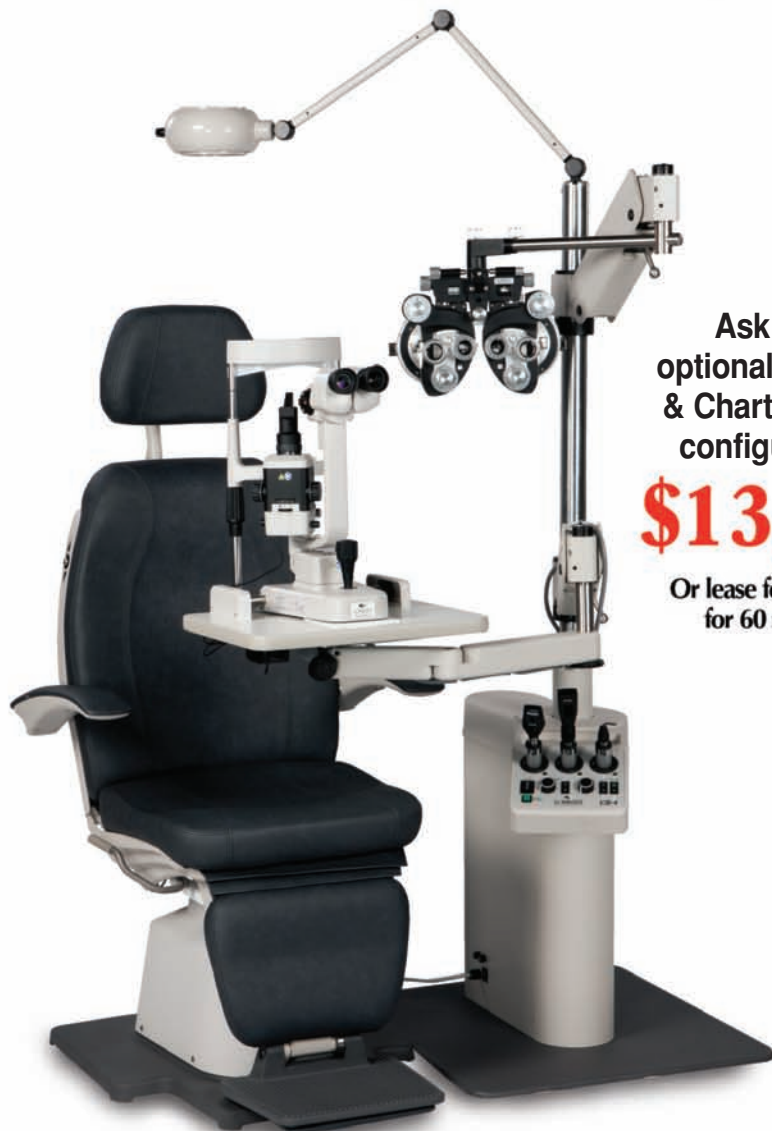It doesn’t take a superstorm—any office can be hit by a disaster. So Dr. Snyder, who has now learned the hard way, offers this advice for every practice.

- **Get organized.** “Put every insurance policy you have in one place so you can grab them if you need to leave in a hurry,” he says. “Don’t wait until the last minute to start looking for your flood policy in one place, your homeowner’s policy in another and your business owner’s policy somewhere else.”
- **Get one agent.** Dr. Snyder says the agents he has have been great so far. But still, he has a different agent for almost every policy. “It’s too many phone calls, too much to keep track of,” he says. “If you can have all your policies with one agent, then you only have to talk to one person.”
- **Get personal.** Dr. Snyder may have several agents, but they’re good ones who take his calls and know him by name. “My business insurance agent—the owner—calls me all the time. My flood guy I’ve known for 30 years. They’re going to take care of me.”



# Invest In Your Practice And Get A Guaranteed Positive Return.

**Lombart's CS-4 Package Offers Quality, Style & Value.**



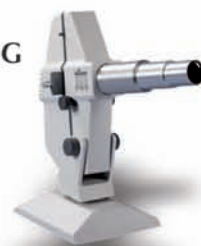Ask about  
optional Slit Lamp  
& Chart Projector  
configurations.

**\$13,595**

Or lease for \$269/mo.  
for 60 months \*

Package includes:

- The Lombart CS-4 Chair & Stand
- Topcon VT-10 Refractor
- Topcon SL-2G Slit Lamp
- Reichert LongLife Chart Projector with mount, slide & screen
- Upgrade to the Lombart CVSi21 for only \$2000 more or to the CVS-PC for only \$1500 more — Additional upgrades & configurations available.



(1-800-566-2278)

**Call 1-800-Lombart**

Or Your Local Lombart Representative.

Corporate Office - 5358 Robin Hood Road, Norfolk, VA 23513-2430  
757-853-8888 | FAX 757-855-1232 | 800-566-2278 | 800-446-8092  
[www.lombartinstrument.com](http://www.lombartinstrument.com)

ATLANTA•BALTIMORE/WASHINGTON D.C.•BOSTON•BOYNTON BEACH/MIAMI•BRADENTON•CHARLOTTE  
CHICAGO•CINCINNATI•DALLAS•DENVER•DETROIT•GREENSBORO•HOUSTON•KANSAS CITY•KNOXVILLE•LOS ANGELES  
MILWAUKEE•MINNEAPOLIS•NEW JERSEY/NEW YORK•NORFOLK•PORTLAND•SACRAMENTO•SAN DIEGO•SAN FRANCISCO

\*Lease rate subject to credit approval, 1st payment is paid for by leasing company at signing with 59 remaining rental payments of \$269 and a \$1.00 purchase option. Taxes, freight and installation additional. Hand Instruments optional. Quantities limited. Subject to change without notice.

## Bimatoprost to be a Boon for the Bald

Topical bimatoprost stimulates new hair growth in individuals with male pattern baldness and other forms of alopecia, according to an advance online article in *FASEB*, the journal of the Federation of American Societies for Experimental Biology.

Bimatoprost, the active ingredient in Allergan's Latisse and Lumigan, has been shown to enhance the length and thickness of eyelashes; however, the authors contend that this is the first published report to document the agent's effect on scalp hair re-growth.

"We hope this study will lead to the development of a new therapy for balding, which should improve

the quality of life for many people with hair loss," said lead researcher Valerie A. Randall, Ph.D., professor of biomedical sciences at the University of Bradford in the U.K.

In this study, the researchers conducted multiple trials on both human and rodent hair follicles. Human testing included hair follicles grown in organ culture as well as those harvested directly from the scalp. In rodent testing, the treatment was applied directly to bald patches of mouse skin.

The researchers concluded that topical application of bimatoprost stimulated hair growth in all experiments.

Milton M. Hom, O.D., of

Azusa, Calif., is intrigued by these results and welcomes another potential baldness treatment. "Past thinking was bimatoprost only worked on telogen [resting phase] follicles. And, because most scalp follicles are anagen [growth phase], minimal effect would be expected," he says. "But these new findings offer a different story."

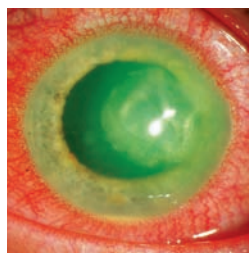
Meanwhile, Allergan recently completed a Phase II study comparing bimatoprost to minoxidil 5% (Rogaine, McNeil) for male pattern baldness, but has yet to release the findings.

Khidhir KG, Woodward DF, Farjo NP, et al. The prostamide-related glaucoma therapy, bimatoprost, offers a novel approach for treating scalp alopecias. *FASEB J.* 2012 Oct 26.

## Novel Antibody Therapy Inhibits Inflammation in *Pseudomonas*

Topical antibodies applied to ocular immune cells may help the eye protect itself from extensive secondary damage during a *Pseudomonas aeruginosa* infection, according to a study in the October issue of *Infection and Immunology*.

Microbial keratitis due to *Pseudomonas* can cause severe ocular damage or blindness, particularly in contact lens wearers. "*Pseudomonas* is everywhere in the environment, and can be unwittingly introduced into the lens cleaning solution, or directly onto the contact lens, so everyone who uses contact lenses is at risk," said principal investigator Gregory P.



***Pseudomonas* infection.**

Priebe, M.D., of Boston Children's Hospital.

In this study, Dr. Priebe's team evaluated the effect of inhibiting the inflammatory immune response of interleukin-17 (IL-17) in a mouse model of *Pseudomonas* ulcer-

ative keratitis. They suggested that while the IL-17 response facilitates isolation and destruction of infectious pathogens, it also causes collateral tissue damage and additional corneal inflammation.

Throughout the study, the researchers were concerned that blocking the IL-17 response could potentially limit the immune system's inherent bactericidal function.

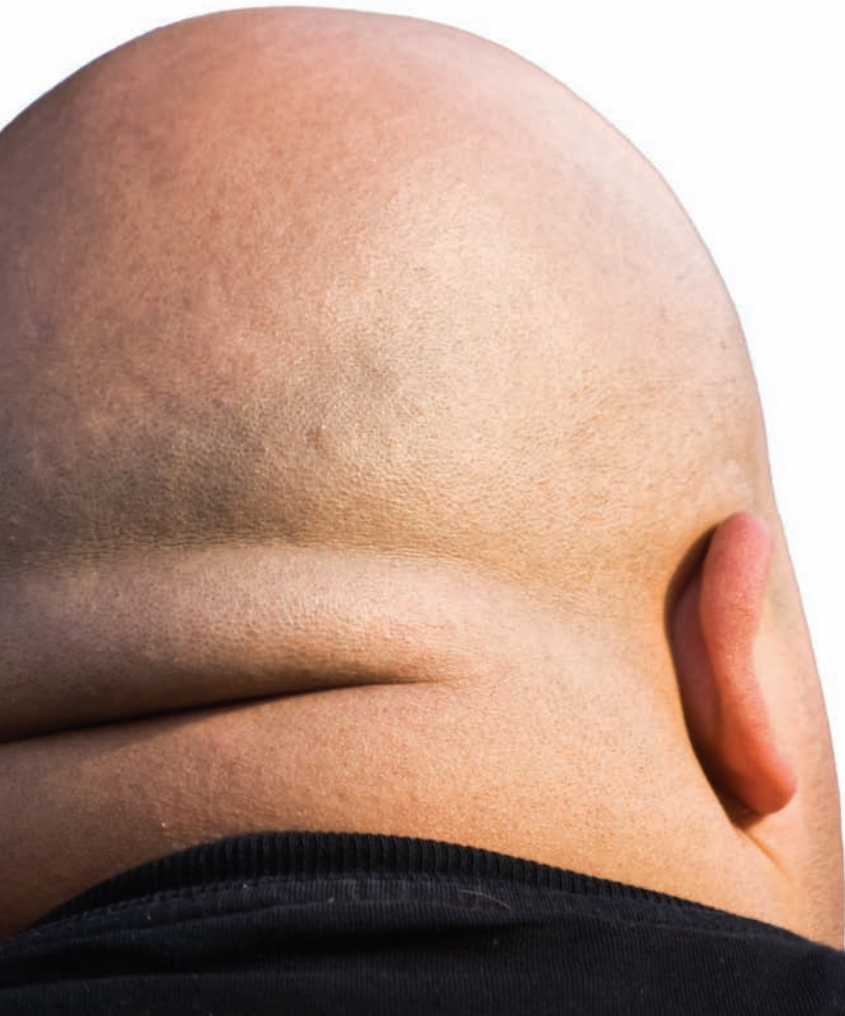"Surprisingly, just the opposite was seen," said Dr. Priebe. "Blocking IL-17 with antibodies led both to fewer neutrophils [immune cells] in the eye, and to fewer bacteria. Interestingly, this is a common pattern in eye infections—the body's responses that make the damage worse are often the same things needs to limit infections," he added.

The researchers concluded that this novel therapeutic approach, which limits secondary corneal damage but still promotes natural antibacterial function, could hold tremendous promise for patients who present with sight-threatening eye infections.

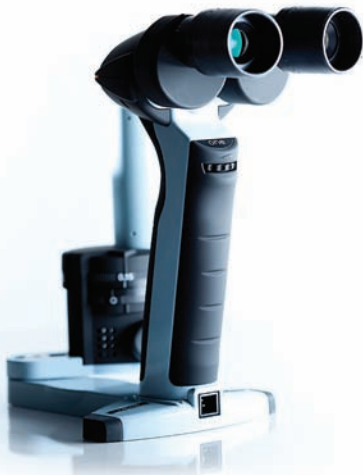Zaidi TS, Zaidi T, Pier GB, Priebe GP. Topical neutralization of interleukin-17 during experimental *Pseudomonas aeruginosa* corneal infection promotes bacterial clearance and reduces pathology. *Infect Immun.* 2012 Oct;80(10):3706-12.

# One Size Finally Fits All

## The Keeler PSL1 Portable Slit Lamp



Snap the code to  
watch it in use!



### Large or small...the PSL fits them all!

We understand that having the best instrumentation is critical to delivering high quality care to all of your patients. Keeler developed the PSL with flexibility and outstanding optical clarity so that each of your patients can have the very best.

Don't allow an obstacle (small or large) stop you from delivering the very best care possible.

Make the PSL your standard for quality eye care for all your patients.

Buy Online!  
[keelerusa.com](http://keelerusa.com)



# Keeler

[www.keelerusa.com](http://www.keelerusa.com) | 800-523-5620

# Antimicrobials—That Are Already in Your Eye

Sometimes Mother Nature has already created the best defense. Suzanne M. Fleiszig, O.D., Ph.D., and a team of scientists at University of California, Berkeley, found that small fragments of keratin protein in the eye play a key role in warding off pathogens.

The discovery could lead to the development of new, inexpensive antimicrobial drugs with implications well beyond the eye.

“What’s really exciting is that the keratins in our study are already in the body, so we know that they are not toxic, and that they are biocompatible,” says Dr. Fleiszig, who specializes in infectious diseases and microbiology.

Dr. Fleiszig and colleagues created synthetic versions of these keratin fragments and put them to the test against an array of nasty bacteria—they wiped out *Streptococcus pyogenes*, *E. coli*, *Staphylococcus aureus* and *Pseudomonas aeruginosa*.

The proteins were derived from

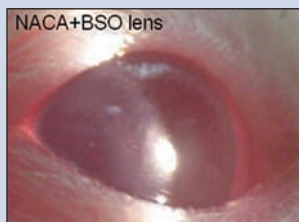
cytokeratin 6A, which can be found in the corneal epithelial cells and also in the skin, hair and nails. They’re also relatively easy to manufacture, making them good candidates for low-cost drugs.

“We are hoping that our findings will lead to new safe and inexpensive options for treating and possibly even preventing infection,” Dr. Fleiszig says. “While technically it would be feasible to utilize what we have found fairly quickly, we need to proceed with caution because of the potential for microbes to become resistant.”

Lead study author Connie Tam, Ph.D., plans to conduct research on how the body produces and regulates these peptides and which mechanisms they use to kill bacteria. “With more knowledge about these peptides, I believe we can minimize the chance of microbes becoming resistant to future therapeutics,” she says.

Tam C, Mun JJ, Evans DJ, Fleiszig SM. Cytokeratins mediate epithelial innate defense through their antimicrobial properties. *J Clin Invest.* 2012 Oct 1;122(10):3665-77.

## New Antioxidant Prevents Cataract Formation



**Compared to cataract-induced rats, those that received NACA showed markedly less opacity.**

Researchers at Missouri University of Science and Technology are working with an antioxidant—N-acetylcysteine amide (NACA)—that could prevent or cure cataracts, macular degeneration and other degenerative eye disorders.

In an experiment on rats, “the NACA solution prevented cataracts from forming,” says lead researcher Nuran Ercal, M.D. “Our research will build on [prior] research, to see if NACA can actually reverse the degeneration as well.”

Dr. Ercal says NACA is an improvement over another experimental treatment, the antioxidant N-acetylcysteine (NAC), because it passes more easily across cell membranes, allowing the medication to be used in lower doses.

**REVIEW**<sup>®</sup>  
OF OPTOMETRY

**Jobson**  
Professional Publications Group

**PRESIDENT & PUBLISHER**  
RICHARD D. BAY  
(610) 492-1020 • RBAY@JOBSON.COM

**BUSINESS OFFICES**  
11 CAMPUS BLVD., SUITE 100  
NEWTOWN SQUARE, PA 19073

**SUBSCRIPTION INQUIRIES**  
1-877-529-1746 (USA ONLY);  
OUTSIDE USA, CALL (847) 763-9630

**SALES MANAGER, NORTHEAST, OHIO**  
JAMES HENNE  
(610) 492-1017 • JHENNE@JOBSON.COM

**SALES MANAGER, SOUTHEAST, WEST**  
MICHELE BARRETT  
(610) 492-1014 • MBARRETT@JOBSON.COM

**CLASSIFIED ADVERTISING**  
888-498-1460

**VICE PRESIDENT OF OPERATIONS**  
CASEY FOSTER  
(610) 492-1007 • CFOSTER@JOBSON.COM

**EDUCATION/CONFERENCE MANAGER**  
MEG McDONALD  
(610) 492-1045 • MMCDONALD@JOBSON.COM

**PRODUCTION MANAGER**  
SCOTT TOBIN  
(610) 492-1011 • STOBIN@JOBSON.COM

**SENIOR CIRCULATION MANAGER**  
ANTHONY GUADAGNINO  
(212) 219-7870 • AGUADAGNINO@JOBSON.COM

**SUBSCRIPTIONS**  
\$56 A YEAR, \$88 (U.S.) IN CANADA,  
\$209 (U.S.) IN ALL OTHER COUNTRIES.

**CIRCULATION**  
PO Box 2025  
SKOKIE, IL 60076  
TEL: (TOLL FREE) 1-877-529-1746  
OUTSIDE USA: (847) 763-9630  
FAX: (847) 763-9631



**CHIEF OPERATING OFFICER**  
JEFF MACDONALD

**CEO, INFORMATION GROUP SERVICES**  
MARC FERRARA

**SENIOR VICE PRESIDENT, HUMAN RESOURCES**  
LORRAINE ORLANDO

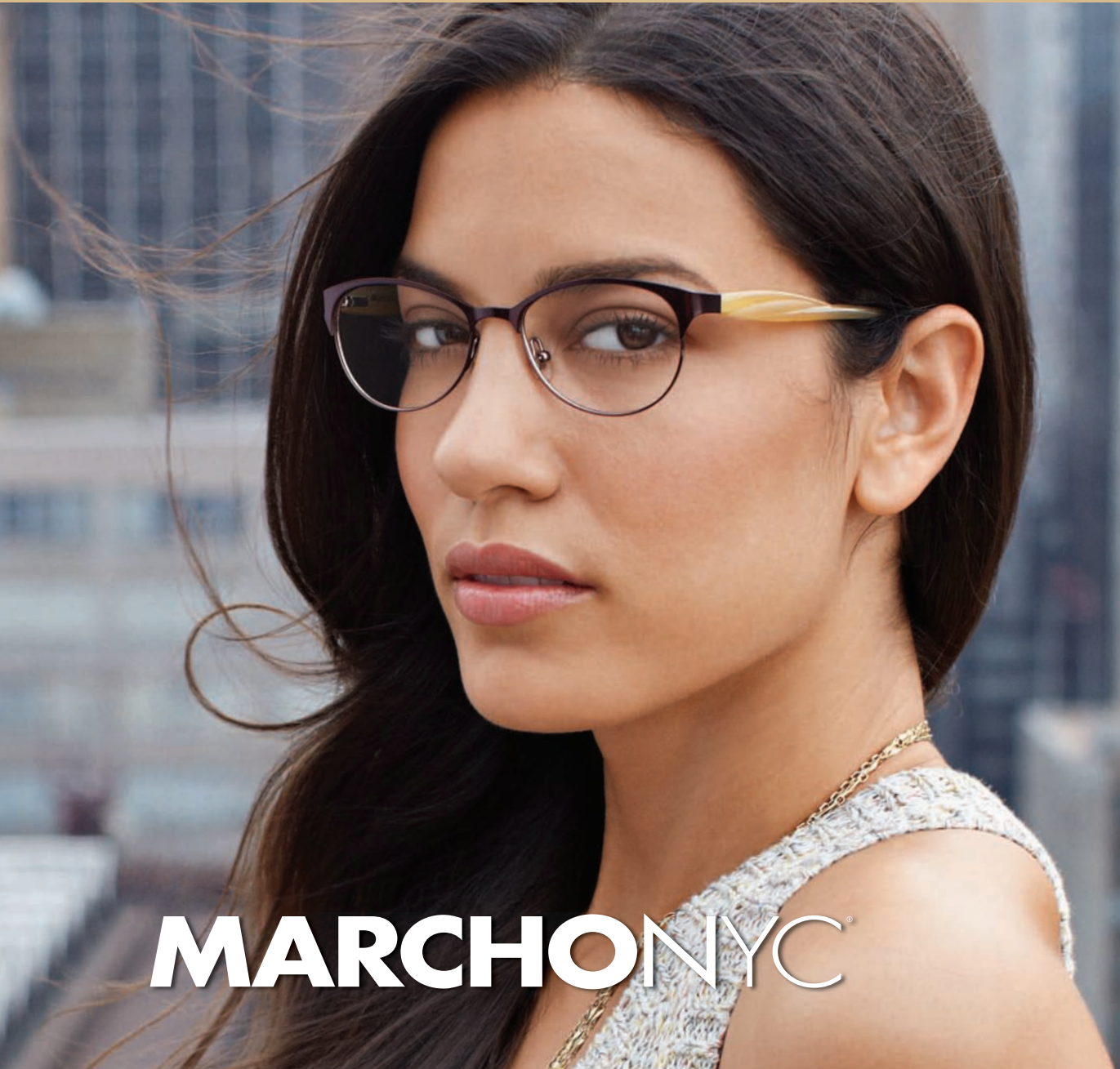**VICE PRESIDENT, CREATIVE SERVICES & PRODUCTION**  
MONICA TETTAMANZI

**VICE PRESIDENT, CIRCULATION**  
EMELDA BAREA



INSPIRED BY NEW YORK,  
THE REDEFINED COLLECTION FROM MARCHON

© 2012 Marchon Eyewear, Inc. Style: Grace



**MARCHON** NYC<sup>®</sup>

# XFRACTION<sup>SM</sup>

## Wavefront Optimized RefraXion

In under one minute, the unique wavefront technology of the OPD-Scan III determines which 80% of your patients qualify for basic refinement to achieve 20/20, or which will require a full traditional refraction, with the TRS-5100.

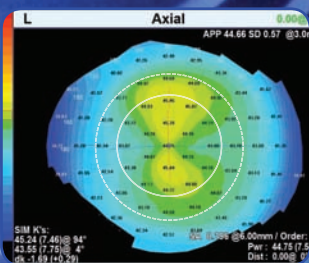
### Begin with the Marco OPD-Scan III Examination, and then finish with the TRS-5100 Digital Refractor

- Autorefractometry, Keratometry, Pupillometry, Corneal Topography, Wavefront Aberrometry, Retro Illumination, Day/Night Rx
- Mapping 2520 real data points up to 9.5mm
- Auto-Selects best refraction start point
- Decide if simple spherical refinement is sufficient

- Automation that saves 5-7 minutes per patient
- See 2-4+ added patients each day
- Instantly compare old vs. new Rx
- Accuracy that reduces costly lens remakes
- Eliminate repetitive stress injury
- Increase efficiency and practice profitability



OPD-Scan III Refractive Power/Corneal Analyzer assesses what degree of refraction is needed



Mesopic and photopic, wavefront mapping across 9.5mm pupil

HOA [μm]: @4.00mm / Order = 4				
	T.Sph	T.Coma	T.Tre	HO
Total:	0.020	0.040	0.025	0.059
Cornea:	0.061	0.108	0.073	0.155
Internal:	0.041	0.085	0.091	0.156

Refraction: VD = 13.75mm				
	Sph	Cyl	Axis	RMS
WF@4.00	+1.00	-0.50	105	0.07D
WF@5.42	+0.75	-0.50	111	0.19D
Diff	-0.25	0.00	6	

Simple reporting determines degree of refraction needed. "WF" patient has a clear optical system and needs only basic refinement.



Digital TRS-5100 Refraction System with remote, control console completes refraction for "WF" or "REF" candidates

### COMBINED, XFRACTION YIELDS:

- Refracting most patients\* in less than one minute
- Defining patients' total visual system most accurately
- Knowing which 20% patients\* will need full, traditional refractions—and why
- Maintaining full control to validate any refraction
- Growing optical revenue by more than 20-30%
- Increasing total practice efficiency and best patient eye care
- Elevating the total patient experience

Only Marco can offer a technology combination that assesses a patient's total visual system, while maximizing efficiencies, practice profitability, and best patient care.

### XFRACTION: WAVEFRONT OPTIMIZED REFRACTION



Designed and Manufactured by NIDEK - Represented by MARCO

www.marco.com  
800.874.5274

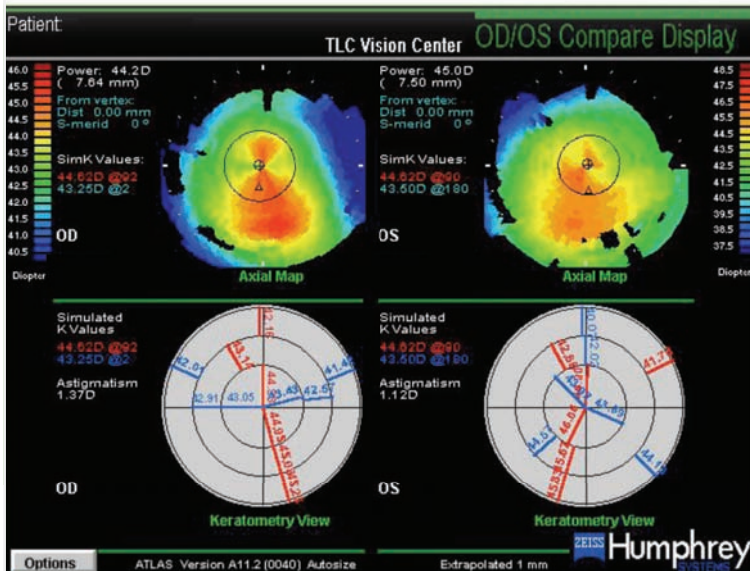


\*Data based on national averages.

# Contents

Review of Optometry November 2012

## 18<sup>TH</sup> ANNUAL REFRACTIVE SURGERY REPORT



## 49

### An O.D.'s View on the Latest Monofocal IOLs

Here's an overview of the features optometrists should consider when discussing single-vision cataract surgery with their patients. **By Jim Owen, O.D., M.B.A.**

## 53

### Are You Losing Sight of LASIK?

As a flat-lining economy struggles to rebound, O.D.s give LASIK mixed reviews as a means to boost the bottom line. **By Jane Cole, Contributing Editor**

## 28

### Slowing Myopia Progression in Children

Although you can't cure myopia, there are an increasing number of promising treatment options you can use to curtail it. **By David Kading, O.D., and Amber Mayberry**

## 36

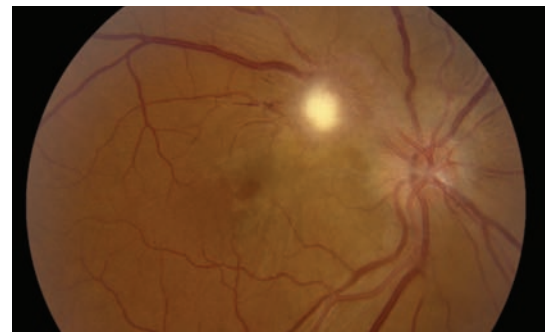### EHR: Embracing the Next Phase of Meaningful Use

The Final Stage 2 Rule for meaningful use and certification of EHR technology signals some new requirements for O.D.s, while scaling back on other proposed thresholds, so don't delay EHR adoption. **By Mark McGraw, Contributing Editor**

## 40

### Ocular Complications in IV Drug Users

Two case reports illustrate the visually devastating risks associated with the use of injectable street drugs. **By Amanda S. Legge, O.D.**



## 58

Earn 2 CE Credits



### Unlocking Leber's Hereditary Optic Neuropathy

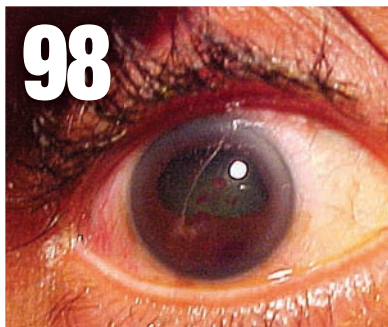
Promising new research offers a glimmer of hope for an otherwise intractable disease.

**By Jerome Sherman, O.D., and Jinyoung Choe, B.A.**

# Departments

Review of Optometry November 2012

- 4 News Review**
- 20 Editor's Page**  
After the Gold Rush  
**JACK PERSICO**
- 22 Chairside**  
How Do You Spell 'Success'?  
**MONTGOMERY VICKERS, O.D.**
- 24 Coding Abstract**  
5 Little Things Before 2013  
**JOHN RUMPAKIS, O.D., M.B.A.**
- 68 Comanagement Q+A**  
See Glaucoma from a New Angle  
**PAUL C. AJAMIAN, O.D.**
- 70 Cornea + Contact Lens Q+A**  
Why Isn't MK on the Decline?  
**JOSEPH P. SHOVLIN, O.D.**
- 72 Review of Systems**  
Cholesterol Check-In  
**CARLO J. PELINO, O.D.**  
**JOSEPH J. PIZZIMENTI, O.D.**
- 77 Retina Quiz**  
Fungal Meningitis a Factor?  
**MARK T. DUNBAR, O.D.**
- 79 Therapeutic Review**  
Double Trouble II  
**JOSEPH W. SOWKA, O.D.**  
**ALAN G. KABAT, O.D.**
- 82 Research Review**  
Why We're Stuck on *Pseudomonas*  
**PAUL M. KARPECKI, O.D.**  
**DIANA L. SHECHTMAN, O.D.**
- 84 Product Review**
- 88 Meetings + Conferences**
- 89 Advertisers Index**
- 91 Classifieds**
- 96 Surgical Minute**  
Small Pupils in Cataract Surgery  
**DEREK N. CUNNINGHAM, O.D.**  
**WALTER O. WHITLEY, O.D., M.B.A.**
- 98 Diagnostic Quiz**  
Cut at the Root  
**ANDREW S. GURWOOD, O.D.**



## On The Web >>

Check out our web exclusives and continuing education @ [www.revoptom.com](http://www.revoptom.com)

### Digital Edition



Left your *Review of Optometry* at the office? No problem! Access *Review* on your computer or mobile device!

Go to [www.revoptom.com](http://www.revoptom.com) and click on the digimag link to for the current issue.

### Facebook and Twitter



For daily updates, "Like" our page on Facebook or "Follow" us on Twitter!

- [www.facebook.com/revoptom](http://www.facebook.com/revoptom)
- <http://twitter.com/#!/revoptom>

**REVIEW**  
OF OPTOMETRY



PRINTED IN U.S.A.

**FOUNDING EDITOR**  
FREDERICK BOGER  
1891-1913

**EDITORIAL OFFICES**  
11 CAMPUS BLVD., SUITE 100  
NEWTOWN SQUARE, PA 19073  
**EMAIL** • [REVIEWOFOPTOMETRY@JOBSON.COM](mailto:REVIEWOFOPTOMETRY@JOBSON.COM)  
**WEBSITE** • [WWW.REVOPTOM.COM](http://WWW.REVOPTOM.COM)

**SUBSCRIPTION INQUIRIES**  
1-877-529-1746  
**CONTINUING EDUCATION INQUIRIES**  
1-800-825-4696

**EDITOR-IN-CHIEF** • JACK PERSICO  
(610) 492-1006 • [JPERSICO@JOBSON.COM](mailto:JPERSICO@JOBSON.COM)

**EXECUTIVE EDITOR** • JOHN MURPHY  
(610) 492-1021 • [JMURPHY@JOBSON.COM](mailto:JMURPHY@JOBSON.COM)

**MANAGING EDITOR** • MICHAEL HOSTER  
(610) 492-1028 • [MHOSTER@JOBSON.COM](mailto:MHOSTER@JOBSON.COM)

**SENIOR EDITOR/WEB EDITOR** • COLLEEN MULLARKEY  
(610) 492-1005 • [CMULLARKEY@JOBSON.COM](mailto:CMULLARKEY@JOBSON.COM)

**DIRECTOR ART/PRODUCTION** • JOE MORRIS  
(610) 492-1027 • [JMORRIS@JOBSON.COM](mailto:JMORRIS@JOBSON.COM)

**ART DIRECTOR** • JARED ARAUJO  
(610) 492-1032 • [JARAUJO@JOBSON.COM](mailto:JARAUJO@JOBSON.COM)

**GRAPHIC DESIGNER** • ALICIA CAIRNS  
(610) 492-1029 • [ACAIRNS@JOBSON.COM](mailto:ACAIRNS@JOBSON.COM)

**DIRECTOR OF CE ADMINISTRATION** • REGINA COMBS  
(212) 274-7160 • [RCOMBS@JOBSON.COM](mailto:RCOMBS@JOBSON.COM)

**SPECIAL PROJECTS** • JANE COLE  
(610) 492-1043 • [JCOLE@JOBSON.COM](mailto:JCOLE@JOBSON.COM)

### EDITORIAL BOARD

**CHIEF CLINICAL EDITORS** • ROBERT M. COLE, III, O.D.  
CHRISTINE W. SINDT, O.D.  
**ASSOCIATE CLINICAL EDITOR** • JOSEPH P. SHOVLIN, O.D.  
**DIRECTOR OPTOMETRIC PROGRAMS** • ARTHUR EPSTEIN, O.D.  
**CLINICAL & EDUCATION CONFERENCE ADVISOR** •  
PAUL M. KARPECKI, O.D.

**CASE REPORTS COORDINATOR** • THOMAS L. LEWIS, OD, PhD  
**CLINICAL CODING EDITOR** • JOHN RUMPAKIS, O.D., M.B.A.  
**CONSULTING EDITOR** • FRANK FONTANA, O.D.

### COLUMNISTS

**CHAIRSIDE** • MONTGOMERY VICKERS, O.D.  
**COMANAGEMENT Q+A** • PAUL C. AJAMIAN, O.D.  
**CORNEA & CONTACT LENS Q+A** • JOSEPH P. SHOVLIN, O.D.  
**DIAGNOSTIC QUIZ** • ANDREW S. GURWOOD, O.D.  
**GLAUCOMA GRAND ROUNDS** • JAMES L. FANELLI, O.D.  
**RESEARCH REVIEW** • PAUL M. KARPECKI, O.D.;  
DIANA L. SHECHTMAN, O.D.  
**RETINA QUIZ** • MARK T. DUNBAR, O.D.  
**REVIEW OF SYSTEMS** • CARLO J. PELINO, O.D.;  
JOSEPH J. PIZZIMENTI, O.D.  
**SURGICAL MINUTE** • DEREK N. CUNNINGHAM, O.D.;  
WALTER O. WHITLEY, O.D., M.B.A.  
**THERAPEUTIC REVIEW** • JOSEPH W. SOWKA, O.D.;  
ALAN G. KABAT, O.D.

**Jobson**  
Professional Publications Group

JOBSON MEDICAL INFORMATION LLC







# The new level of subjective refraction

Voice Guided

## PSF Refractor™

The Vmax Vision PSF Refractor™ featuring **NEW** Voice Guided Subjective Refraction capability and proprietary Point Spread Function (PSF) methodology enables you to:

- Refract even challenging patients with **increased confidence** knowing that audio instructions are guiding the process with consistency and accuracy
- Dramatically **reduce refraction training** to 2 days or less\*
- Achieve superior vision with **5X greater accuracy** than the phoropter
- Offer a true **nighttime vision test** to satisfy an unmet patient need

Patient vision is maximized when PSF refraction is combined with Vmax Vision Enception™ Lenses – which can be precision cut to 0.01 D and customized for all variables including patient optics, gaze, life styles and frame factors.

See and hear the PSF Refractor™ at the Maryland Optometric Association Symposium. For an in-office demonstration, call 888.413.7038 or visit [www.vmaxvision.com](http://www.vmaxvision.com)

\* Average training time. Actual training time may vary.

© 2012 Vmax Vision. All rights reserved. PSF Refractor and Enception are trademarks of Vmax Vision, Inc. #1004\_12/12

  
**vmax**<sup>™</sup>  
VISION, INCORPORATED

1.888.413.7038  
[www.vmaxvision.com](http://www.vmaxvision.com)

# SECO 2013

February 27 – March 3, 2013

In honor of its 90<sup>th</sup> anniversary, SECO is offering special rates for this year only that encourage optometrists and the entire ophthalmic team to experience a “**C**elebration of **E**ducation.”

## 90<sup>th</sup> Year Celebration Package

**OD AOP**

Pre-Registration

**\$90**

Registration

**\$140**

Includes: Access to events, exhibit hall and a lunch coupon. OD and AOP CE courses are available at an additional cost. (Symposium Series courses are included at no cost.)

## Special Session Package

**OD**

Pre-Registration

**\$349**

Registration

**\$399**

Includes: Access to events, exhibit hall, a lunch coupon, all Special Sessions (15 CE hours total) and Symposium Series (3 non-credit food and beverage courses). All other courses, board reviews and workshops are available at an additional cost.

### Special Sessions:

060, 061, 062, 063, 064, 065, 066

### Symposium Series:

300, 301, 302

VALUED UP TO  
**\$500**

## SECO Grand Experience Package

**OD**

Pre-Registration

**\$649**

Registration

**\$699**

Includes: Access to events, exhibit hall, a lunch coupon, all Special Sessions (15 CE hours total), Symposium Series (3 non-credit food and beverage courses), CE courses (22 total hours - excluding board reviews and workshops), and OD audio recordings.

### Special Sessions:

060, 061, 062, 063, 064, 065, 066

### Symposium Series:

300, 301, 302

VALUED UP TO  
**\$1400**

# REGISTRATION OPENS NOVEMBER 5<sup>TH</sup>, 2012



**90** YEARS  
A CELEBRATION  
OF EDUCATION

► Visit us on the web at [secointernational.com](http://secointernational.com)



facebook.com/SECOInternational  
twitter.com/seco\_intl



Premier Partners

VISTAKON

Division of  
Johnson & Johnson  
Vision Care, Inc.

Alcon

ALLERGAN

vspglobal  
SHARING YOUR VISION

BAUSCH + LOMB

See better. Live better.

Partners

Abbott  
Medical Optics

Essilor

Seeing the world better

Elevating The Quality Of Care In Ophthalmology



## Rhein Fire & Ice Mask

Product #85-9005



### CONTRIBUTING EDITORS

PAUL C. AJAMIAN, O.D., ATLANTA  
JEFFREY R. ANSHEL, O.D., CARLSBAD, CALIF.  
JILL AUTRY, O.D., R.PH., HOUSTON  
SHERRY J. BASS, O.D., NEW YORK  
MILE BRUJIC, O.D., BOWLING GREEN, OHIO  
WALTER L. CHOATE, O.D., MADISON, TENN.  
ROBERT M. COLE, III, O.D., BRIDGETON, N.J.  
ANTHONY S. DIECIDUE, O.D., STROUDSBURG, PA.  
MARK T. DUNBAR, O.D., MIAMI  
S. BARRY EIDEN, O.D., DEERFIELD, ILL.  
ARTHUR B. EPSTEIN, O.D., ROSLYN, N.Y.  
JAMES L. FANELLI, O.D., WILMINGTON, N.C.  
FRANK FONTANA, O.D., ST. LOUIS  
GARY S. GERBER, O.D., HAWTHORNE, N.J.  
ANDREW S. GURWOOD, O.D., PHILADELPHIA  
MILTON HOM, O.D., AZUSA, CALIF.  
ALAN G. KABAT, O.D., FORT LAUDERDALE, FLA.  
PAUL M. KARPECKI, O.D., LEXINGTON, KY.  
JUDITH LEE, ATGLEN, PA.  
JEROME A. LEGERTON, O.D., M.B.A., SAN DIEGO  
THOMAS L. LEWIS, O.D., PH.D., PHILADELPHIA  
DOMINICK MAINO, O.D., M.ED., CHICAGO  
JASON R. MILLER, O.D. M.B.A., POWELL, OHIO  
PAMELA J. MILLER, O.D., J.D., HIGHLAND, CALIF.  
JOHN W. POTTER, O.D., M.A., DALLAS  
CHRISTOPHER J. QUINN, O.D., ISELIN, N.J.  
JOHN L. SCHACHET, O.D., ENGLEWOOD, COLO.  
JACK SCHAEFFER, O.D., BIRMINGHAM, ALA.  
CAROL SCHWARTZ, O.D., M.B.A., SAN JOSE DEL CABO, MEXICO  
JEROME SHERMAN, O.D., NEW YORK  
JOSEPH P. SHOWLIN, O.D., SCRANTON, PA.  
JOSEPH W. SOWKA, O.D., FORT LAUDERDALE, FLA.  
LORETTA B. SZCZOTKA, O.D., M.S., CLEVELAND  
MONTGOMERY VICKERS, O.D., ST. ALBANS, W.VA.  
KATHY C. WILLIAMS, O.D., SEATTLE

### EDITORIAL REVIEW BOARD

EDWARD S. BENNETT, O.D., ST. LOUIS  
MARC R. BLOOMENSTEIN, O.D., SCOTTSDALE, ARIZ.  
CHRIS J. CAKANAC, O.D., MURRYSVILLE, PA.  
JERRY CAVALLERANO, O.D., PH.D., BOSTON  
BRIAN CHOU, O.D., SAN DIEGO  
A. PAUL CHOUS, M.A., O.D., TACOMA, WASH.  
GLENN S. CORBIN, O.D., WYOMISSING, PA.  
STEVEN FERRUCCI, O.D., SEPULVEDA, CALIF.  
MURRAY FINGERET, O.D., HEWLETT, N.Y.  
IAN BEN GADDIE, O.D., LOUISVILLE, KY.  
MATTHEW J. GARSTON, O.D., BOSTON  
ROBERT M. GROHE, O.D., HOMEWOOD, ILL.  
ANDREW S. GURWOOD, O.D., PHILADELPHIA  
NICKY HOLDEMAN, O.D., M.D., HOUSTON  
MILTON HOM, O.D., AZUSA, CALIF.  
WILLIAM L. JONES, O.D., ALBUQUERQUE, N.M.  
ALAN G. KABAT, O.D., FORT LAUDERDALE, FLA.  
PAUL M. KARPECKI, O.D., LEXINGTON, KY.  
RON MELTON, O.D., CHARLOTTE, N.C.  
BRUCE MUCHNICK, O.D., PHILADELPHIA  
MARC MYERS, O.D., COATESVILLE, PA.  
CARLO J. PELINO, O.D., JENKINTOWN, PA.  
JOSEPH PIZZIMENTI, O.D., FORT LAUDERDALE, FLA.  
WILLIAM B. POTTER, O.D., FREEHOLD, N.J.  
JOHN RUMPAKIS, O.D., M.B.A., PORTLAND, ORE.  
MICHAEL C. RADOIU, O.D., STAUNTON, VA.  
LEO P. SEMES, O.D., BIRMINGHAM, ALA.  
DIANA L. SHECHTMAN, O.D., FORT LAUDERDALE, FLA.  
LEONID SKORIN, JR., O.D., D.O., ROCHESTER, MINN.  
JOSEPH W. SOWKA, O.D., FORT LAUDERDALE, FLA.  
RANDALL THOMAS, O.D., CONCORD, N.C.

- For Heat Therapy: Place It In A Microwave For 15 Seconds, Warm Relief Lasts 15 Minutes.
- For Cold Therapy: After Placing In The Freezer 2 Hours, Cool Relief Lasts 15 Minutes.
- Includes Cloth Sleeve For Additional Lid Protection.
- Easy To Use, And Can Be Cleaned And Reused Multiple Times.
- Available 5 Units Per Box.

For More Information Call 727-209-2244



1301 Rev.C

3360 Scherer Drive, Suite B, St. Petersburg, FL 33716  
800-637-4346 • Tel: 727-209-2244 • Fax: 727-341-8123  
Email: [Info@RheinMedical.com](mailto:Info@RheinMedical.com) Website: [www.RheinMedical.com](http://www.RheinMedical.com)

Woman Wearing Dry Eye Heat Mask



VIDEO CODE  
AC88



# After the Gold Rush

Refractive surgery's boom years are over. And now that the bloom is off the rose, its success or failure rests in your hands. **By Jack Persico, Editor-in-Chief**

When the bottom dropped out of the LASIK market a few years ago, were you maybe just a little bit relieved? It's OK to admit it. At first blush, refractive surgery seems antithetical to optometric practice. If optometrists derive a good portion of their practice revenue by providing corrective lenses, and along comes a surgery that obviates the need for that service, it's easy to have mixed emotions. If your desire to give patients the best care possible is ever at odds with what's best for your practice, someone loses out.

Tread carefully here: Should patients sense a reticence on your part to discuss refractive surgery, that will color their impressions of

you and the care you provide. As Richard Mangan, O.D., points out in this month's cover story, just about 10% of optometrists actively tout the benefits of refractive surgery to their patients. Maybe the other 90% of O.D.s genuinely believe that an expensive surgery just doesn't stack up all that well against safe, affordable, non-permanent corrective lenses. Or maybe there are ulterior motives for keeping mum about laser vision correction.

It doesn't have to be that way. Better to embrace refractive surgery than—excuse the pun—turn a blind eye. Making it an integral part of your practice gives you a serious measure of control over its impact. *You* choose the best candidates for it, based on their visual demands and psychological make-up. *You* choose the surgeon who'll perform the surgery, rather than letting patients be lured in by advertising messages. *You* provide the follow-up care that ensures success and keeps the patient in your practice. And *you* get the referrals of friends and family from a happy LASIK patient's pool of acquaintances.

In other words, as Michael Corleone says in *The Godfather Part II*, "Keep your friends close, but your enemies closer."

Refractive surgery and its practitioners need not be enemies of optometrists. We aren't heading toward a future where refractive error is permanently eliminated as a matter of routine. (Ever notice how hardly anyone in sci-fi movies wears glasses? Not gonna happen.)

LASIK will remain an attractive option for a subset of people with the means, and the chutzpah, to undergo elective surgery on their eyes to replace the eminently serviceable option of corrective lenses. But the reality is that plenty of people will continue to prefer glasses or contacts for reasons of fashion, safety, cost savings, or all three. Either way, they deserve to hear about all their corrective options from the doctor entrusted with their vision.

In fact, it's fair to say that you hold the future of the market in your hands.

In the late 1990s, the gee-whiz novelty of LASIK's debut—which had the good fortune of coinciding with an era of, well, good fortunes—led to an early surge in interest and surgical volume. Ophthalmologists traded on the public's fascination (a cynic might call it gullibility) with the cachet of high-tech laser surgery. Nowadays, with the economy on life support and refractive surgery off the cultural radar, the procedure will require a good deal of in-office education and awareness if it's to be undertaken. And because most routine eye care is provided by optometrists, O.D.s call the shots now.

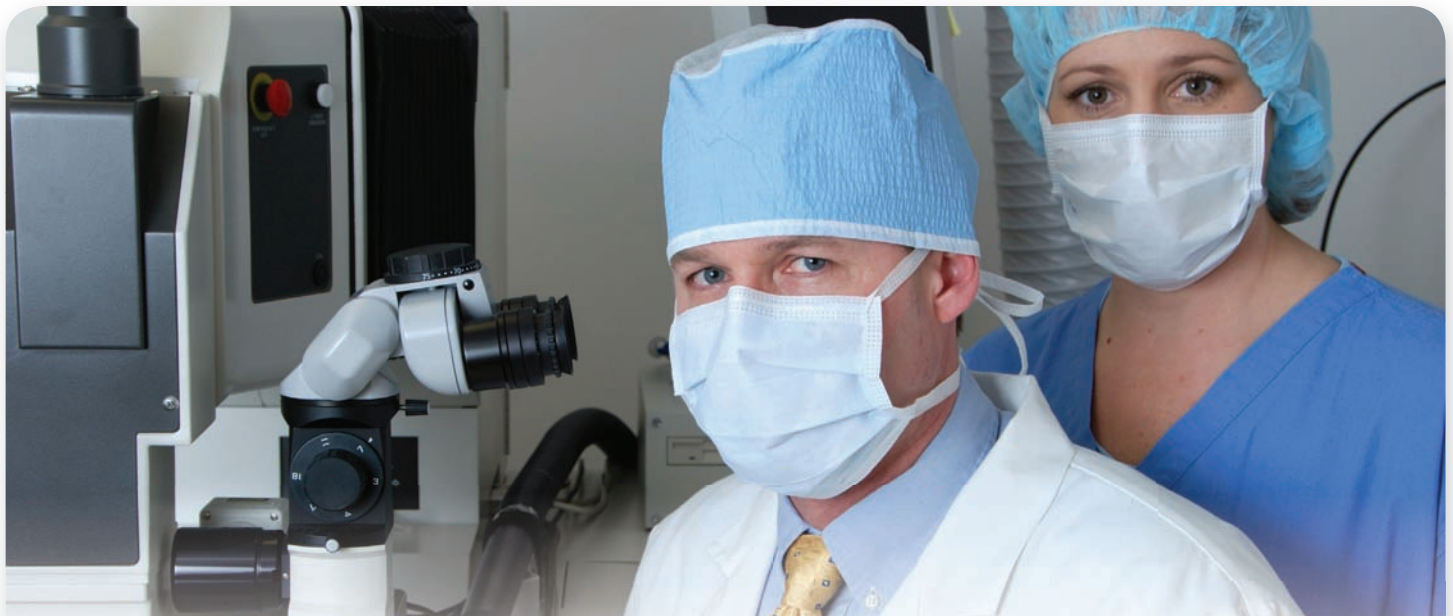Ironically, the outcomes of LASIK have never been better, with a good many patients achieving 20/16 (some even 20/12) postop acuity. If you want to give surgical candidates the clearest vision possible, you need to be a bit of a visionary yourself. ■

*Jack Persico*

## In the Wake of Sandy

The terrible devastation Hurricane Sandy wrought left millions of people in dire straits, and our hearts go out to them for what they've had to endure.

One small consequence of that upheaval: This issue of *Review of Optometry* may have arrived in your mailbox a few days later than usual. Our East Coast-based offices were without power and personnel during the storm and its aftermath. We thank you for tolerating this inconvenience. As life returns to normal, so will our publishing schedule.



# THE ALLIANCE ADVANTAGE

BECOMING A MEMBER OF THE ALLIANCE GIVES YOU MORE OF WHAT YOU WANT...

**MORE  
SAVING**



**MORE  
CHOICES**



**MORE  
PURCHASING  
POWER**



The Alliance offers:

- Exceptional Customer Service
- Group Purchasing Power
- Discounts on Optical Supplies, Medical Supplies and Scrubs/Attire
- Over 2,000 Vendors

On average, The Alliance can save your practice 30% on medical surgery products and offers access to additional savings on pharmaceuticals.

**THE ALLIANCE...A BUSINESS PARTNER THAT HELPS PROVIDE THE BEST EXPERIENCE AND OUTCOMES FOR PATIENTS AND SURGEONS.**



# How Do You Spell ‘Success’?

Some doctors measure success by money. Then again, some doctors can’t measure even if you hold the PD ruler for them. **By Montgomery Vickers, O.D.**

**H**ow do you define success? To me, how one defines success is very personal. It’s not always about money, although money is the traditional way some people keep score in the game of success. But does money really equal success? Always? Sometimes? *Always* to some people and *sometimes* to all people.

So, how do I spell SUCCESS?

- “S” is for the one letter that all patients call a “B” on the Snellen chart. Even after you tell them it’s an “S,” they still say “B” the next time they read the chart. To be a successful optometrist—or, as the patient might say, a “BucceBBful” optometrist—you sometimes have to forgive your patients. They’re only human after all and I’ll bet you yourself have made stupid, *give-me-a-break* kinda mistakes from time to time. No, you haven’t? Never? OK, if you Bay Bo.

- “U” is how you understand your success. I understand that I have a nice house and car because my wonderful forefathers dug themselves out of whatever muck they started in and taught each generation to do the best they could with whatever gifts the good Lord gave them. For example, I can snap my fingers and shoot a beer cap across the room with laser precision. That took four years of college to master. I’m almost certain my forefathers would understand that is cool as can be.

- “C” is for just make ’em “C” better. When in doubt, try that with your next patient. It seems to

make them happy and that makes you more successful! The opposite rarely works but is a common approach with recent grads. Ask my earliest patients, who never returned.

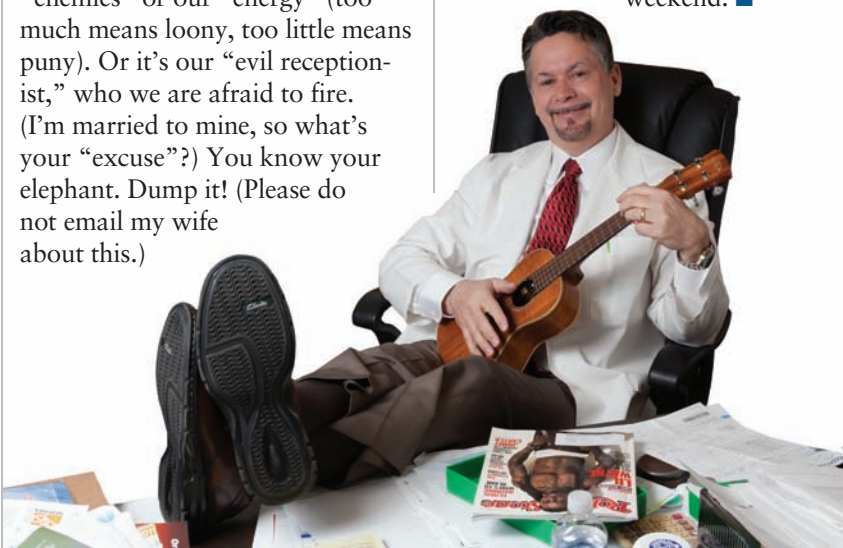- “C” again? But *this* “C” is different. This “C” stands for “cents.” If it don’t make dollars, it don’t make “cents.” The road to ruin is paved with good-hearted optometrists who give away their services and goods for nothing, just to be nice. Optometry is at least board certified in that department because we constantly sign up for any vision plan, no matter how dumb. You cannot be successful unless you make a profit in your office, so make sure your decisions make “cents.”

- “E” is the elephant in the room. We all have some variation of pachyderm stomping around, whether it’s our “ego” or our “enemies” or our “energy” (too much means loony, too little means puny). Or it’s our “evil receptionist,” who we are afraid to fire. (I’m married to mine, so what’s your “excuse”?) You know your elephant. Dump it! (Please do not email my wife about this.)

- “S” is for “shhhh.” Quiet yourself. Get zen. Find your happy place. To be successful, you have to know when to chill. You do not always have to be productive. In fact, if you are my friendly optometric colleagues down the street, you *never* have to be productive. Stay home with the family. I’ll handle the patients for you. I’m just that kind of guy.

- “S”... The final “S” is for “stay.” Stay true to yourself. As the should-be Grammy winning song (that I wrote) says, “Be who you are.” However, the “S” for “stay” does not mean you should be “stuck.” That’s not the ticket, people. “Stay” means keep your practice and your life true to your ideals and beliefs—unless of course those beliefs and ideals are “sick,” in which case you’re “sunk.”

What is success? I’ll let you know after I visit my grandbabies this weekend. ■



**Unmatched  
Support**

**+**

**Quality  
Materials**

**=**

**Unrivaled  
Leadership**

**Maybe that's why Boston® lenses are  
prescribed **3** times more often.\***

The Boston team knows what it takes to be a leader in the GP lens market. For years we have provided products with excellent performance and high Dk. In addition, we offer education and fitter training for specialty lenses, both on our own and partnered with our authorized laboratories. It's what our customers tell us they need to provide better vision care. And it is exactly what they can expect from a leader.



**Boston®**  
Materials

[www.fit-boston.com](http://www.fit-boston.com)

**BAUSCH+LOMB**

\* Boston lenses are prescribed 3 times more often than the closest GP competitor. Source: Survey conducted by Decision Analyst, March 2011.

© 2012 Bausch + Lomb Incorporated. ®/™ denote trademarks of Bausch + Lomb Incorporated. All other product/brand names are trademarks of their respective owners.  
Global-0961 Rev Date: 08/2012



# 5 Little Things Before 2013

Get your contracts, codes and fees in order before the year is out. **By John Rumpakis, O.D., M.B.A., Clinical Coding Editor**

**I** realize that it's only November and we have a full month to go before 2012 is out and 2013 is upon us—but there are a few tasks that probably need your consideration or attention.

## 1. Get Updated Agreements

Create a form letter that requests a current copy of your provider agreement (i.e., contracts) from each carrier. Send it to the plan administrator or to the provider relations department. It's important to request an updated copy every year, because your carriers have the ability to unilaterally change your provider agreement without notification. So, unless you have the most recent version, you're in the dark about your—and their—contractual obligations.

## 2. Organize Your Contracts

Create a notebook that indexes all of your provider agreements for all of your insurance carriers, both refractive and medical. Divide your notebook into two sections—one for refractive carriers and another for medical carriers. Organize copies of your contracts in your notebook in alphabetical order.

## 3. Update Your CPT Codes

Educate yourself and your staff about the most up-to-date code definitions and characteristics.

One of the most astonishing things that I encounter when working with practices is that they use CPT codes that are either obsolete or inappropriate for the care deliv-

ered. An online or cloud-based system (such as [ReimbursementPLUS.com](http://ReimbursementPLUS.com)) provides easy access to real-time CPT code definitions, changes and proper use protocols. Likewise, be sure to update your EMR and routing slips with the new CPT codes.

## 4. Take Stock of ICD Codes

Update your ICD-9 codes for 2013, and begin a training program for implementing the upcoming ICD-10 codes.

One of the most common reasons for denied medical claims is the use of an incomplete or obsolete diagnosis code. So, it's vital for your practice to stay updated on this information. The ICD codes can be revised and updated as frequently as every three months, with the annual update occurring on October 1 of every year.

Meanwhile, you should be preparing for the ICD-10 codes. Here is the timeline for the transition:

- October 1, 2011: The last annual updates to both ICD-9-CM and ICD-10 code sets were made.
- October 1, 2012/October 1, 2013: Limited code updates to both the ICD-9-CM and ICD-10 code sets to capture new technologies and diseases.
- On October 1, 2014: Limited code updates to ICD-10 code sets to capture new technologies and diagnoses, but no updates to ICD-9-CM because it will no longer be used for reporting.
- October 1, 2015: Regular updates to ICD-10 will begin.

## 5. Update Your Fees

While I can't tell you how to set your fees specifically, I can tell you that most practices are leaving hard-earned revenues on the table because they haven't evaluated their fee structure in an objective, analytical manner.

Perform an annual, semi-annual, quarterly or even monthly review and analysis of your fees. Allowable reimbursements vary significantly by carrier—make sure to include all of your carriers in your analysis to evaluate how your pricing per CPT code stacks up. While this can be cumbersome, it is critical to your profitability. (You also can use a tool like the Fee Schedule Analyzer on [ReimbursementPLUS.com](http://ReimbursementPLUS.com), which allows you to automatically evaluate and update your fee structure.)

As a rule, you shouldn't charge less than your carriers are willing to pay. But, keep in mind that you have to charge every patient equally for the same CPT code, whether he or she pays out of pocket or uses an insurance plan.

When you pay attention to your professional service revenues, you'll likely realize increases in both gross and net income. This is like getting "free money" because you're simply increasing your reimbursements for professional services for the same work performed. That's working smarter, not harder. ■

*Disclosure: Dr. Rumpakis is the founder, developer and owner of [ReimbursementPLUS.com](http://ReimbursementPLUS.com) and has a financial interest in it.*



Now is not the time to worry about product quality.



## COMMITMENT

## PERSONAL SERVICE

## INDEPENDENCE

## PRODUCT QUALITY

Three Rivers Optical produces the best lab quality, period. We know that your reputation rides on how well we do our job, and we won't disappoint you. Across all lens designs, materials and designs, we are dedicated to optimizing the optics and cosmetics of the final product that you dispense to your patient.

And our See-More line of products gives you the option of the very best value in each major lens category. Does this sound like the product quality you want?

Call Steve Seibert, Three Rivers Optical CEO, for more information. And stop worrying.

# Maximize MRSA Management

By Jimmy D. Bartlett, O.D., D.Sc.

Infection caused by methicillin-resistant *Staphylococcus aureus* (MRSA) is a growing concern that has important implications for both systemic and ophthalmic health.

When first introduced in the early 1940s, the beta-lactam antibiotics (penicillins and cephalosporins) generally demonstrated great efficacy against *S. aureus* infections. During the next 70 years, however, these agents gradually lost ground to resistant pathogens.

The acronym "MRSA" refers to isolates of *S. aureus* that are resistant to all beta-lactam antibiotics (penicillins and cephalosporins)—not just methicillin. The most common manifestations of ophthalmic MRSA infections include preseptal cellulitis and conjunctivitis; however, sight-threatening infections—including corneal ulcers, endophthalmitis, orbital cellulitis and blebitis—also occur.<sup>1</sup> The practical importance for the optometrist is that empirical antibiotic treatment of these infections does not adequately cover for the MRSA isolate in up to 50% of cases.<sup>1</sup>

## Evolving Prevalence of MRSA

In 1944, researchers found that *S. aureus* exhibited some resistance to penicillin, likely in response to the widespread use of beta-lactam drugs.<sup>2</sup> Resistance to penicillin grew during the 1950s, and increasing resistance to the semisynthetic penicillinase-resistant antimicrobial agents followed in the 1960s.<sup>2</sup> Resistance to these penicillins had become so prevalent by the 1990s that they could no longer be used as first-line empirical therapy for serious staphylococcal infections.

Before the 1980s, MRSA primarily was considered to be a nosocomial (healthcare-associated or hospital-acquired [HA-MRSA]) infection. Infections caused by HA-MRSA are distinguished from those acquired in the general community (CA-MRSA) outside the healthcare setting. In cases of CA-MRSA, patients typically present with skin infections—including pimples, abscesses and other pus-filled lesions.<sup>2</sup>

Most current research reports reveal a significant increase in the prevalence of MRSA ophthalmic infections over the past decade; however, the current prevalence rates vary widely (3% to 52.8%) throughout individual study

populations.<sup>3-6</sup> Note that prevalence rates can appear to be inconsistent due to the demographics of the research environment as well as the source of the ocular specimens (primary care settings generally have lower rates of reported MRSA than tertiary hospital settings, where more complex cases are encountered). Of 548 external infections caused by *S. aureus* in an eye hospital in the United Kingdom, just 3% were associated with MRSA.<sup>7</sup> By contrast, during a recent 10-year interval in Taiwan, the average rate of MRSA infections was high but stable at 52.8%.<sup>8</sup>

In a nationwide prevalence study in the United States, the proportion of *S. aureus* infections that tested positive for MRSA increased from 29.5% in 2000 to 41.6% in 2005.<sup>5</sup> During a similar period, the prevalence of MRSA infections increased from 4.1% in 1998 to 16.7% in 2006 in a prominent ophthalmic microbiology laboratory database.<sup>4</sup>

In Edmonton, Alberta, Canada, the prevalence of MRSA steadily increased from 0.5% in 2002 to 12.6% in 2010.<sup>6</sup> Similar prevalence rates recently were reported in a representative sample of isolates that were collected from patients with bacterial conjunctivitis in the United States and Asia. Of the *S. aureus* isolates, 13.7% were methicillin-resistant.<sup>9</sup> In contradistinction, of 200 *S. aureus* isolates recently collected from ocular infections (excluding endophthalmitis) in a national surveillance program, 39% were resistant to methicillin.<sup>10</sup>

## Clinical Significance for the O.D.

As with methicillin-sensitive *S. aureus* infections, MRSA can be associated with a wide range of ophthalmic infections. In one study, 78% of patients with MRSA had blepharoconjunctivitis, 2.4% had cellulitis, 2.4% had dacryocystitis, 15% had keratitis and 2% had endophthalmitis.<sup>4</sup> Both HA-MRSA and CA-MRSA orbital cellulitis have been reported in adults, and the first documented case of orbital cellulitis secondary to CA-MRSA in a non-immunocompromised child was documented in 2008.<sup>11,12</sup> Other less common infections caused by MRSA include infectious scleritis and chronic dacryocystitis secondary to congenital nasolacrimal duct obstruction.<sup>13,14</sup>

## The Best Therapeutic Options

To track evolving antimicrobial susceptibility patterns among common ocular microorganisms, several national surveillance programs were initiated during the past decade. The Ocular Tracking Resistance in U.S. Today (TRUST) was created in 2005 in an effort to test and catalogue national samples of ocular isolates against a panel of antibacterial agents, including fluoroquinolones, trimethoprim, azithromycin, tobramycin, polymyxin B and penicillin.<sup>15</sup> It is of interest that, with the exception of trimethoprim and tobramycin, fewer than one-third of MRSA strains were susceptible to ophthalmic antimicrobials (besifloxacin was not included in the panel of tested drugs). MRSA's susceptibility to ciprofloxacin, gatifloxacin, levofloxacin and moxifloxacin was approximately 15%, indicating a high-level of in vitro MRSA resistance.<sup>15</sup> This suggests that clinicians must consider alternative therapies to traditional fluoroquinolones when MRSA is a suspected pathogen.

Investigators from another surveillance program, Antibiotic Resistance Monitoring in Ocular Microorganisms (ARMOR), recently reported that almost all (96%) MRSA isolates are resistant to azithromycin, and nearly 80% are resistant to ciprofloxacin.<sup>10</sup> In contrast, all *S. aureus* isolates tested were susceptible to vancomycin.<sup>10</sup> Indeed, many other reports currently consider vancomycin to be the most effective agent against MRSA infections of the ocular surface.<sup>3,4,6,16</sup> However, for topical ocular use, the drug must be compounded from the commercially available powder intended for injection. The 500mg vial is reconstituted with 10mL of sterile water, and is transferred to an ophthalmic bottle and shaken. Then, 5mL is transferred to an ophthalmic dropper bottle, and another 5mL of sterile water is added. This process yields a final concentration of 25mg/mL.<sup>17</sup>

Although the commercially available ophthalmic fluoroquinolones provide broad-spectrum coverage for the empirical treatment of most ocular surface bacterial infections, they show stark differences in their potencies against staphylococcal isolates.<sup>18</sup> In the ARMOR study, besifloxacin was the most potent fluoroquinolone tested—especially against ciprofloxacin-resistant isolates.<sup>10</sup> Compared with other fluoroquinolones, besifloxacin—as a novel

## Treatment Options for the Initial Empirical Therapy of MRSA

Topical	Systemic <sup>22</sup>
Vancomycin Besifloxacin Trimethoprim/polymyxin B	<p>Oral Administration:</p> <p>Trimethoprim/sulfamethoxazole Clindamycin Doxycycline</p> <p>Intravenous Administration:<sup>#</sup></p> <p>Vancomycin Daptomycin Linezolid Telavancin Ceftaroline Tigecycline</p>

<sup>#</sup>Monotherapy for the treatment of skin and skin-structure infections in patients with comorbidities or signs of systemic illness.

8-chlorofluoroquinolone—exhibits a lower minimum inhibitory concentration (MIC<sub>90</sub>) against multidrug-resistant staphylococcal strains. Further, besifloxacin is as few as four times to more than 128 times more potent than other fluoroquinolones against ciprofloxacin-resistant MRSA.<sup>9,19</sup> Finally, this drug has less selective pressure for development of resistance because it has no systemic formulation counterpart.<sup>19,20</sup>

While the prospect of ocular infection by a multidrug-resistant strain is unsettling, clinicians should understand that resistance breakpoints reported by laboratories are developed based upon a drug concentration that safely can be achieved in human serum. Ocular infections, however, usually are treated topically, which permits much higher drug concentrations at the infected site. Thus, a bacterial isolate that is labeled “resistant” to a given drug still can be treated successfully with a topical agent—if the ocular tissue drug concentration sufficiently exceeds the MIC.<sup>10</sup> When the conjunctival drug residence times are compared for besifloxacin, gatifloxacin and moxifloxacin, besifloxacin demonstrates the longest mean contact time and has the highest drug concentration-to-MIC ratio for the treatment of MRSA.<sup>21</sup>

The increasing prevalence of MRSA has resulted in a paradigm shift to include this group of organisms in the differential diagnosis of many ocular infections. Effective antimicrobial therapy may require treatment with topical vancomycin, besifloxacin or systemic agents (see table, above).

1. Blomquist PH. Methicillin-resistant *Staphylococcus aureus* infections of the eye and orbit (an American Ophthalmological Society thesis). *Trans Am Ophthalmol Soc.* 2006;104:322-45.
2. Bartlett JD, Snyder C. Methicillin-resistant *Staphylococcus aureus*: challenges and risks; Part I: Overview of methicillin-resistant

3. Adebayo A, Parikh JG, McCormick SA, et al. Shifting trends in in vitro antibiotic susceptibilities for common bacterial conjunctival isolates in the last decade at the New York Eye and Ear Infirmary. *Graefes Arch Clin Exp Ophthalmol.* 2011 Jan;249(1):111-9.
4. Freidlin J, Acharya N, Lietman TM, et al. Spectrum of eye disease caused by methicillin-resistant *Staphylococcus aureus*. *Am J Ophthalmol.* 2007 Aug;144(2):313-5.
5. Asbell PA, Sahm DF, Shaw M, et al. Increasing prevalence of methicillin resistance in serious ocular infections caused by *Staphylococcus aureus* in the United States: 2000 to 2005. *J Cataract Refract Surg.* 2008 May;34(5):814-8.
6. Zhou AW, Lee MC. Ocular microbiology trends in Edmonton, Alberta: a 10-year review. *Can J Ophthalmol.* 2012 Jun;47(3):301-4.
7. Shanmuganathan VA, Armstrong M, Buller A, Tullo AB. External ocular infections due to methicillin-resistant *Staphylococcus aureus* (MRSA). *Eye (Lond).* 2005 Mar;19(3):284-91.
8. Hsiao CH, Chuang CC, Tan HY, et al. Methicillin-resistant *Staphylococcus aureus* ocular infection: a 10-year hospital-based study. *Ophthalmology.* 2012 Mar;119(3):522-7.
9. Haas W, Gearinger LS, Usner DW, et al. Integrated analysis of three bacterial conjunctivitis trials of besifloxacin ophthalmic suspension, 0.6%: etiology of bacterial conjunctivitis and antibacterial susceptibility profile. *Clin Ophthalmol.* 2011;5:1369-79.
10. Haas W, Pillar CM, Torres M, et al. Monitoring antibiotic resistance in ocular microorganisms: results from the Antibiotic Resistance Monitoring in Ocular Microorganisms (ARMOR) 2009 surveillance study. *Am J Ophthalmol.* 2011 Oct;152(4):567-74.e3.
11. Vazan DF, Kodsi SR. Community-acquired methicillin-resistant *Staphylococcus aureus* orbital cellulitis in a non-immunocompromised child. *J AAPOS.* 2008 Apr;12(2):205-6.
12. Shome D, Jain V, Natarajan S, et al. Community-acquired methicillin-resistant *Staphylococcus aureus* (CA-MRSA)—a rare cause of fulminant orbital cellulitis. *Orbit.* 2008;27(3):179-81.
13. Feiz V, Redline DE. Infectious scleritis after pars plana vitrectomy because of methicillin-resistant *Staphylococcus aureus* resistant to fourth-generation fluoroquinolones. *Cornea.* 2007 Feb;26(2):238-40.
14. Kodsi S. Community-acquired methicillin-resistant *Staphylococcus aureus* in association with chronic dacryocystitis secondary to congenital nasolacrimal duct obstruction. *J AAPOS.* 2006 Dec;10(6):583-4.
15. Asbell PA, Colby KA, Deng S, et al. Ocular TRUST: Nationwide antimicrobial susceptibility patterns in ocular isolates. *Am J Ophthalmol.* 2008 Jun;145(6):951-8.
16. Kottus BS, Wyms RA. In vitro activity of fluoroquinolones, vancomycin, and gentamicin against methicillin-resistant *Staphylococcus aureus* ocular isolates. *Am J Ophthalmol.* 2006 Nov;142(5):726-9.
17. Extemporaneous Preparations. In: Bartlett JD, Bennett ES, Fiscella RG, et al (eds). *Ophthalmic Drug Facts*. St. Louis: Wolters Kluwer Health; 2012:447-55.
18. Haas W, Gearinger LS. Microbiological etiology and susceptibility of bacterial conjunctivitis isolates from clinical trials with ophthalmic, twice-daily besifloxacin. *Adv Ther.* 2012 May;29(5):442-55.
19. McDonald M, Blondeau JM. Emerging antibiotic resistance in ocular infections and the role of fluoroquinolones. *J Cataract Refract Surg.* 2010 Sep;36(9):1588-98.
20. Comstock TL, Karpecki PM, Morris TW, Zhang JZ. Besifloxacin: a novel anti-infective for the treatment of bacterial conjunctivitis. *Clin Ophthalmol.* 2010 Apr 26;4:215-25.
21. Torkildsen G, Proksch JW. Concentrations of besifloxacin, gatifloxacin, and moxifloxacin in human conjunctiva after topical ocular administration. *Clin Ophthalmol.* 2010 Apr 26;4:331-41.
22. Rivera AM, Boucher HW. Current concepts in antimicrobial therapy against select gram-positive organisms: methicillin-resistant *Staphylococcus aureus*, penicillin-resistant pneumococci, and vancomycin-resistant enterococci. *Mayo Clin Proc.* 2011 Dec;86(12):1230-43.

# Slowing Myopia Progression in Children

Although you can't cure myopia, there are an increasing number of promising treatment options you can use to curtail it. **By David Kading, O.D., and Amber Mayberry**

**A**s a practice that emphasizes children, specialty contact lenses and research (including myopia control research), we often are referred patients seeking an alternative method of vision correction to reduce myopia progression. These patients are among the more than 41% of people in the United States suffering from myopia.<sup>1</sup> Although there are currently no interventions that cease myopic progression, it has been suggested that a number of treatment options can decrease its progression.

If we can slow this progression in children, not only could we potentially reduce the cost of U.S. vision care, but also possibly save them from the devastating vision loss due to myopic retinopathy, retinal detachment and glaucoma that is associated with myopia.<sup>2-4</sup>

Like many practitioners, we have found it challenging at times to address parent and patient questions regarding the methods and treatment options to stop or slow



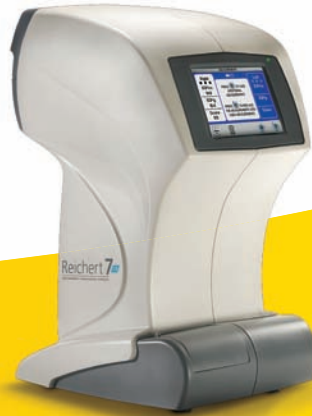the progression. However, with several studies ongoing and many on the verge of publication, we might soon have more answers.

In the last decade, we have seen an increasing interest in research to slow myopia progression—especially in children, given that we see the greatest amount of myopia

progression before adulthood. Evidence has shown a reduction in progression using a number of treatments, including anti-muscarinic therapy and orthokeratology.

While some of these treatment modalities have been approved in other countries, there are no FDA-approved treatment methods

The World's Best Tonometer for Diagnosing and Managing Glaucoma.



# CORNEA. SCHMORNEA.

Tired of the smorgasbord of tonometers, pachymeters and fudge factors needed to calculate IOP? Send them to the curb. The Reichert<sup>®</sup> 7CR doesn't care about the cornea. The patented Corneal-

Compensated IOP (IOPcc) nullifies the effect of corneal properties, providing you with the best IOP measurement available.

The guessing game stops here. Call **1.888.849.8955**, or visit **Reichert.com/iopcc**.

specifically targeting myopia control in the United States. As such, you will need to explain to patients that these interventions are off-label should you decide to use them in practice.

## Spectacles

While these various spectacle lens options offer mild help for some patients, we have not seen the significance to be large enough in our clinic to actively recommend any type of lens for patients on a regular basis.

However, if a child is progressing in myopia and is unwilling or unable to use any of the other methods, we will consider progressive addition lenses (PALs). Additionally, we are keeping our eyes peeled on the studies looking at novel spectacle lens options for patients.

## Undercorrected Single Vision Lenses

Parents often get concerned when their children's spectacle prescriptions increase, fearing that their child will end up highly myopic. So, many times, they ask us to prescribe lenses that are not as strong in order to "keep their child's prescription from getting worse." The bottom line is there's no evidence to back it up—in fact, it's just the opposite.

A 2006 study looked at myopic children between ages six and 15 years old over a period of 18 months.<sup>5</sup> Twenty-three of the participants were fully corrected, while 25 were undercorrected by +0.50. Although statistically insignificant, there was a slight progression of myopia (0.17D) in the children who were undercorrected.<sup>5</sup>

A 2002 study showed similar results of increased myopia progression (0.23D) over a two-year

period.<sup>6</sup> Although the increase was not significant, both studies suggest that undercorrecting myopes has a negative effect on the progression of myopia.<sup>5-6</sup> Ergo, undercorrected single vision lenses should not be used for slowing the progression of myopia.

At our practice, we bring patients with a history of increasing myopia corrected by spectacle lenses back for refraction in six months to ensure their myopia is not progressing further. If we note that their myopia has progressed, we will make a change to

**At our practice, we bring patients with a history of increasing myopia corrected by spectacle lenses back for refraction in six months to ensure their myopia is not progressing further.**

their spectacles rather than waiting another six months (one year total), as we do not want them to be undercorrected for a significant period of time.

The data shows undercorrected children progress faster in their myopia—therefore, we make sure these children have a new update prescription as soon as their eyes change in an effort to stabilize their vision as best as possible.<sup>5-6</sup>

## Traditional Bifocal Glasses

Since Dr. Robert Wick first reported on the use of bifocals to correct myopia in 1947, practitioners have been using them with varied success.<sup>7</sup> One study noted that myopic children who were appropriately corrected showed an accommodative response to near objects that was weaker than emmetropic patients.<sup>8</sup>

This inspired the hypothesis that patients with progressing myopia

who have a decreased accommodative response may have a slight blur on the retina that stimulates increased myopia development. Thus, bifocal glasses may offer a benefit, as they compensate for the reduced accommodative response, especially in children who are esophoric as they show an even greater accommodative lag.

In 2000, researchers randomized 82 myopic children with esophoria to bifocals or single vision lenses. They found that bifocals reduced the progression of myopia by 0.25D over 30 months compared

to single vision lenses.<sup>9</sup> The mean change in vitreous chamber depth was 0.36 +/- 0.34mm in the bifocal group and 0.48 +/- 0.28mm in the single vision group. Overall, there was a 20% reduction in myopia progression with bifocal lenses vs. the single vision lens counterpart.<sup>9</sup> Older studies have suggested that bifocals could provide reduction in myopia progression of 44% or more.<sup>10</sup>

## Progressive Addition Lenses

Given the improvements that progressive addition lenses (PALs) offer to adult patients with presbyopia, it makes sense to consider using PALs for children with decreased accommodative issues and as a consideration for decreasing myopia's progression.

PALs offer many advantages to patients, but for young children and adolescents, the appearance of the lenses cannot be overstated.

Patients enjoy the smooth transition of vision from their distance to near vision without the distinct junction line. One of the inherent drawbacks to PALs is that there can be an adaptation period where the patient experiences peripheral distortion, and some patients are unable to adapt to PALs.

The Correction of Myopia Evaluation Trial (COMET) looked at the effect of PALs compared to single vision lenses on myopic progression.<sup>11</sup> Investigators enrolled 469 subjects, age six to 11, with myopic prescriptions between -1.25 and -4.50 spherical equivalent. One arm of the study had single vision distance correction while the other had PAL lenses with a +2.00 add.

The researchers looked at the progression of myopia through cycloplegic refraction over the course of three years, and found a difference between PAL and single vision lenses of 0.20 D.<sup>11</sup> Although their findings were statistically significant, the authors concluded that the use of PALs as a clinically significant treatment option is not warranted on a routine basis. Considering the significant cost of PALs compared to single vision lenses and how minimal the reduction is, PALs do not merit the frequent use that we currently see in the optometry field.

One theory related to myopia progression suggests a correlation to hyperopic defocus in the peripheral retina. One recent study looked at a control group of single vision-wearing children and compared them to patients wearing lenses that were intended to reduce peripheral hyperopic defocus.<sup>12</sup> In this 12-month study, there was no statistically significant difference between the novel designs and the control group. However,

when evaluating the differences between the control group and children who were younger (six to 12 years) with a parental history of myopia, there was a difference of 0.29D.<sup>12</sup>

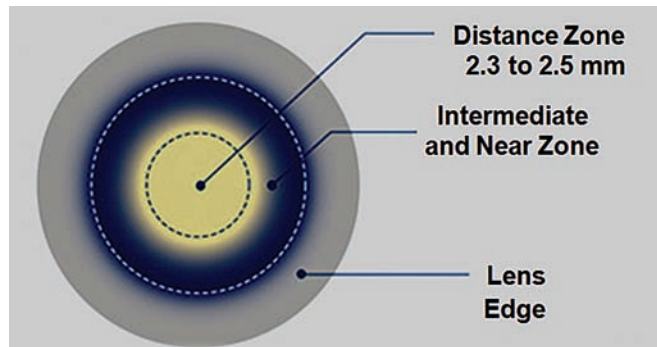
### Contact Lenses

Now that optometrists are fitting younger children with contact lenses, they are a much more viable option for treating myopia progression. While many children feel insecure about wearing glasses, contact lenses have been found to improve their self image and self worth, allowing them to both see and feel better.<sup>13</sup>

However, there are some drawbacks—namely, the possibility of infection and increased chair time. Luckily, the array of contact lenses in today's market gives us plenty of options to find the right fit for each patient.

### Gas Permeable Contact Lenses

Gas permeable (GP) contact lenses have been used in practice for years in attempts to slow myopia progression. The possible mechanism behind GPs slowing myopia progression is in the improved retinal image compared to other forms of correction, the flattening of the cornea with GP wear and/or an overcorrection for myopic patients when fitting contact lenses.<sup>14</sup> Many studies have looked at the relationship between GPs and myopia progression; one



**Center distance multifocal contact lenses are a form of peri-focus lens design for myopia control. Customized design and visual axis registration may be required to optimize refractive therapy.**

of the more recent studies concluded that rigid GPs didn't slow the rate of myopia progression, even among children who used them regularly.<sup>14</sup>

In this study, the children assigned to GP contact lenses (105) remained more myopic by 0.20D than those in the spectacle group did (192).<sup>14</sup> The study authors concluded GP contact lenses likely did not hold any promise for slowing the rate of myopia progression in children.

While GP lenses are effective for vision correction and offer a fantastic option for children just starting lens wear, we do not recommend discussing them as a treatment option for myopia progression. We typically reserve these for more complicated patients who have some sort of astigmatism (regular or irregular), purely because of their adaptation time.

### Soft Spherical Contact Lenses

Soft contact lenses are used readily in the United States and elsewhere. As they are a popular option for vision correction, patients often discuss them during a myopia progression assessment. The Adolescent and Child Health Initiative to Encourage Vision Empowerment (ACHIEVE) study

# Myopia Control

found that soft contact lenses do not cause a clinically relevant increase in myopia.<sup>15</sup>

The rate of change per year was 0.06D greater in soft contact lens wearers than spectacle wearers, which was not a statistically significant difference—even after three years.<sup>15</sup>

We don't feel, in our practice, that such a minute increase warrants eliminating soft contact lenses as a potential option for vision correction in children with myopia.

Usually, we choose a single-use disposable lens for these patients in an effort to emphasize compliance and reduce maintenance. However, we do not turn to soft contact lenses as a modality for myopia reduction.

## Multifocal Soft Contact Lenses

Multifocal and bifocal soft contact lenses have reemerged in the spotlight with regards to myopia progression.

In one study, myopia progression and eye elongation were reduced significantly with the use of bifocal contact lenses.<sup>16</sup> Forty children, age 11 to 14, wore a dual-focus lens in one randomly assigned eye and a single vision distance lens in the fellow eye for 10 months. The lenses were then swapped between eyes and worn for another 10 months.

Researchers found that for 70% of the children, myopia progression was reduced by 30% or more in the eye wearing the bifocal lens compared to the single vision lens.<sup>16</sup> The data suggest that with bifocal lenses, the sustained myopic defocus can slow myopia progression without compromising visual function—even when presented to the retina simultaneously with a clear image.<sup>16</sup>

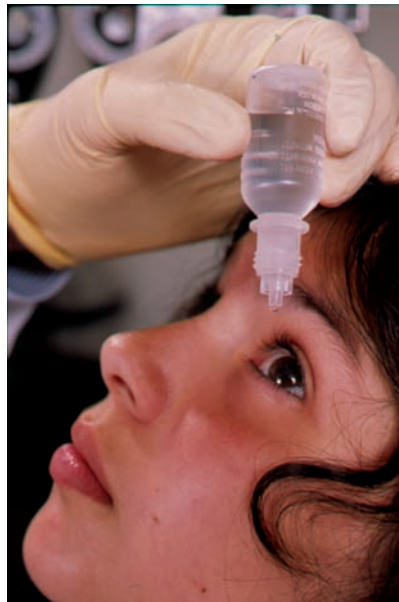

Photo: National Eye Institute—National Institutes of Health

**A recent review of myopia treatments in children found that anti-muscarinic eye drops had the largest positive effects for slowing myopia progression.**

However, we still need a better understanding of the design type (near center v. distance center) that needs to be used and the amount of add power to provide the most appropriate retinal image and blur to achieve the best results. One identical twin study showed that a distance center lens achieved greater success in the eyes wearing

the multifocal lens.<sup>17</sup> At our practice, we use multifocal lenses as an off-label treatment for patients progressing in their myopia. As the research is still emerging, however, we typically do not use multifocal lenses as a first-line treatment.

Instead, we see this as an option for children who have higher amounts of refractive error and would be more difficult to fit with orthokeratology lenses. Additionally, if a patient has a large amount of cylinder, we will order a lens that is multifocal and toric. We use lenses with distance center and higher adds—typically in the realm of +3.00 to +4.00.

Although we do not have published evidence to back up our treatment methods yet, through our relationship with the clinical and research team in Pacific University's contact lens department we believe that the higher add powers are more effective than lower add powers.

One major drawback is that this eliminates the use of many of the standard multifocal lenses that are in stock. Instead, the lenses must be custom made or ordered directly from the manufacturer or distributor.

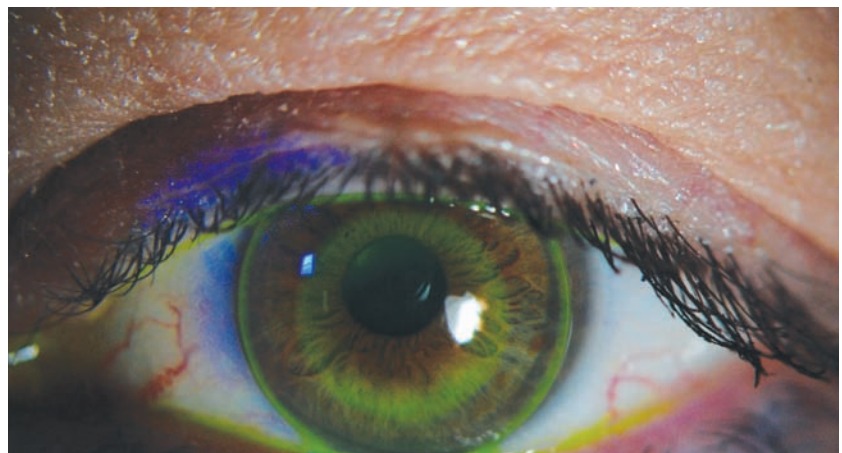


Photo: Joseph Riskiewicz, O.D., M.P.H.

**Image of a 20-year-old female patient who was successfully fitted with overnight ortho-k lenses when she nearly 12 years old.**



## Anti-Muscarinic Therapy

A recent review that included 23 clinical investigations of myopia treatments in children found that anti-muscarinic medications (eye drops) had the largest positive effects for slowing myopia progression.<sup>18</sup> At one year, children receiving pirenzepine gel, cyclopentolate eye drops or atropine eye drops showed significantly less myopic progression compared with children receiving placebo.<sup>18</sup>

In Singapore, researchers used topical atropine on 400 myopic children ages six to 12 years. The treatment was found to be well tolerated and effective in slowing the progression of low and moderate myopia and ocular axial elongation in Asian children. The mean reduction of myopia in the atropine-treated eyes was 0.03 +/- 0.50D, while there was progression of myopia of -0.76 +/- 0.44D in the placebo-treated eyes.<sup>19</sup>

Although this intervention appears to be somewhat effective, it is not a first-line treatment in our office due to the potential side effects that are encountered by anti-muscarinic medications.<sup>18</sup>

## Orthokeratology

Orthokeratology has long been used to treat myopia in adults and children, with great success for daily vision without the aid of glasses or daytime contact lenses. Throughout the years, practitioners have begun to notice that their younger patients have had a reduction in their myopia progression as a result of using orthokeratology lenses. In recent years, several studies have come out with evidence that appears to mirror this anecdotal experience.<sup>20-22</sup>

The Longitudinal Orthokeratology Research in Children (LORIC) study followed 35 children over a two-year period. Researchers looked at children wearing ortho-k lenses and compared them to a historical control group of children wearing single vision lenses.<sup>20</sup> Rather than comparing the refractive outcomes of the children, the LORIC study evaluated axial length changes.

Following the two-year study, the ortho-k group increased in their myopia by 0.29mm vs. 0.54mm in the control group.<sup>20</sup> A similar study looked at children wearing ortho-k lenses vs. a control group of children wearing soft lenses.<sup>21</sup> These researchers also followed participants for two years and found a similar reduction in the progression of axial length elongation.<sup>21</sup>

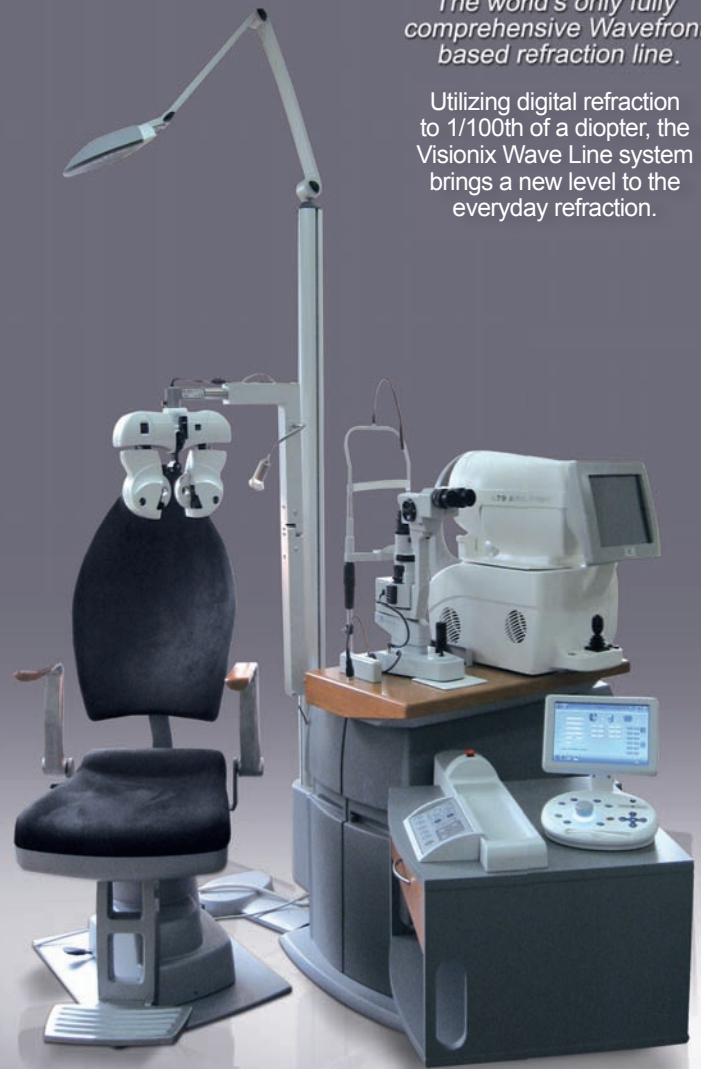
Currently, we are awaiting the completion of the five-year Stabilization of Myopia by Accelerated

# Refraction made simple and affordable.



*The world's only fully comprehensive Wavefront based refraction line.*

Utilizing digital refraction to 1/100th of a diopter, the Visionix Wave Line system brings a new level to the everyday refraction.



**VISIONIX**  
The Vision of the Future

For more information on the Visionix product line, please call  
**(800) 292-7468**

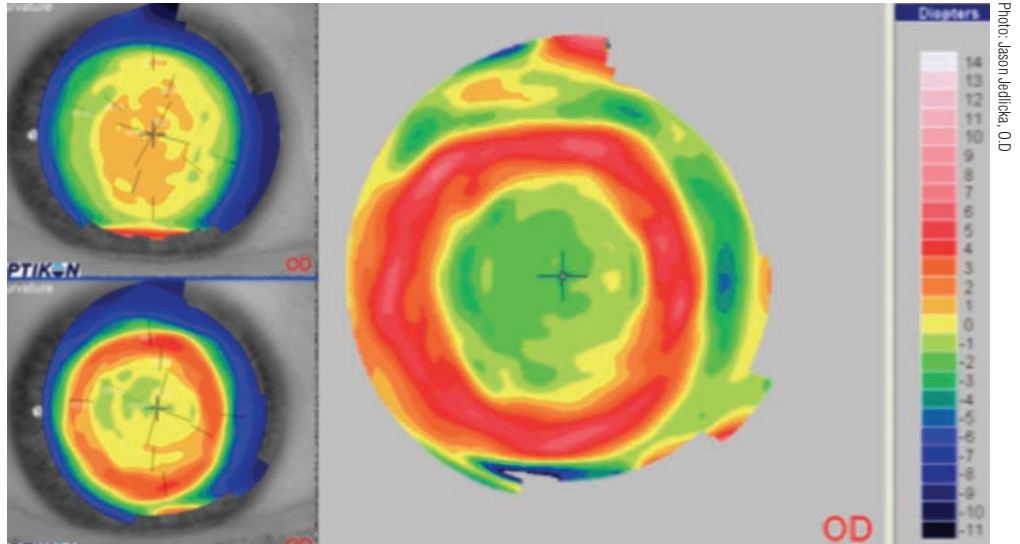
# Myopia Control

Reshaping Technique (SMART) trial, which will end next year.<sup>22</sup> It is the largest clinical investigation yet to look at whether overnight vision correction with orthokeratology lenses can stop myopia progression in children.

Researchers have been following 200 children, ages eight to 14, who were separated into groups at the start of the study—one wearing ortho-k lenses and other wearing conventional soft contact lenses. Interim results showed that participants wearing overnight ortho-k lenses experienced a minimal change in myopia after three years of wear, while the average prescription level had worsened in the soft lens wearers.<sup>25</sup>

Ortho-k is the number one myopia progression treatment method for patients referred to our office. We discuss its off-label status with parents; however, we believe that the current literature supports the clinical use of the lenses as an excellent option for our patients. We talk with them about the studies, explaining their limitations and smaller sample size, as well as the anecdotal success that practitioners have had with these lenses for decades. We also review the limited options on the market and explain to parents why we believe that their child is best suited for ortho-k lenses.

With so many potential treatment options, there is a lot to look forward to for the future. At this time, the literature and research



**Pre- and post-treatment corneal maps, as well as a difference map for a child being corrected with orthokeratology lenses. Not only is the central cornea reduced in power, the mid-periphery is actually increased in power.**

point us in the direction of using ortho-k and bifocal soft contact lenses for the greatest decrease in the progression of myopia. ■

*David Kading, O.D., owns Specialty Eyecare Group in Seattle, a group practice with multiple locations. He specializes in anterior segment disease and custom contact lens fitting. Amber Mayberry, a 4th year student at University of Saint Louis Missouri College of Optometry, is an optometric intern at Specialty Eyecare Group.*

- Vitale S, Sperduto RD, Ferris FL 3rd. Increased prevalence of myopia in the United States between 1971-1972 and 1999-2004. *Arch Ophthalmol.* 2009 Dec;127(12):1632-9.
- Celorio JM, Pruett RC. Prevalence of lattice degeneration and its relation to axial length in severe myopia. *Am J Ophthalmol.* 1991 Jan 15;111(1):20-3.
- Sørensen KE, Baggesen K. Retinal detachment following intracapsular cataract extraction. *Acta Ophthalmol (Copenh).* 1990 Oct; 68(5):549-53.
- Saw SM, Katz J, Schein OD, et al. Epidemiology of myopia. *Epidemiol Rev.* 1996;18(2):175-87.
- Adler D, Millodot M. The possible effect of undercorrection on myopic progression in children. *Clin Exp Optom.* 2006 Sep;89(5):315-21.
- Chung K, Mohindin N, O'Leary DJ. Undercorrection of myopia enhances rather than inhibits myopia progression. *Vision Res* 2002 Oct;42(22):2555-9.
- Wick RE. The use of bifocals in myopia; a case report. *Am J Optom Arch Am Acad Optom.* 1947 Aug;24(8):368-71.
- Gwiazda J, Thorn F, Bauer J, Held R. Myopic children show insufficient accommodative response to blur. *Invest Ophthalmol Vis Sci.* 1993 Mar;34(3):690-4.
- Fulk GW, Cyert LA, Parker DE. A randomized trial of the

- effect of single-vision vs. bifocal lenses on myopia progression in children with esophoria. *Optom Vis Sci.* 2000 Aug;77(8):395-401.
- Goss DA, Uyesugi EF. Effectiveness of bifocal control of childhood myopia progression as a function of near point phoria and binocular crosscylinder. *J Optom Vis Dev.* 1995 June;26(2):12-7.
- Gwiazda J, Hyman L, Hussein M, et al. A randomized clinical trial of progressive addition lenses versus single vision lenses on the progression of myopia in children. *Invest Ophthalmol Vis Sci.* 2003 Apr;44(4):1492-500.
- Sankaridurg P, Donovan L, Varnas S, et al. Spectacle lenses designed to reduce progression of myopia: 12-month results. *Optom Vis Sci.* 2010 Sep; 87(9): 631-41.
- Walline JJ, Jones LA, Sinnott L, et al. Randomized trial of the effect of contact lens wear on self-perception in children. *Optom Vis Sci.* 2009 Mar;86(3):222-32.
- Katz J, Schein OD, Levy B, et al. A randomized trial of rigid gas permeable contact lenses to reduce progression of children's myopia. *Am J Ophthalmol.* 2003 Jul;136(1):82-90.
- Walline JJ, Jones LA, Sinnott L, et al. A randomized trial of the effect of soft contact lenses on myopia progression in children. *Invest Ophthalmol Vis Sci.* 2008 Nov;49(11):4702-6.
- Anstice NS, Phillips JR. Effect of dual-focus soft contact lens wear on axial myopia progression in children. *Ophthalmology.* 2011 Jun;118(6):1152-61.
- Aller TA, Wildsoet C. Bifocal soft contact lenses as a possible myopia control treatment: a case report involving identical twins. *Clin Exp Optom.* 2008 Jul;91(4):394-9.
- Walline JJ, Lindsley K, Vedula SS, et al. Interventions to slow progression of myopia in children. *Cochrane Database Syst Rev.* 2011 Dec 7; (12):CD004916.
- Chua WH, Balakrishnan V, Chan YH, et al. Atropine for the treatment of childhood myopia. *Ophthalmology.* 2006 Dec;113(12):2285-91.
- Cho P, Cheung SW, Edwards M. The longitudinal orthokeratology research in children (LORIC) in Hong Kong: a pilot study on refractive changes and myopic control. *Curr Eye Res.* 2005 Jan;30(1):71-80.
- Walline JJ, Jones LA, Sinnott LT. Corneal reshaping and myopia progression. *Br J Ophthalmol.* 2009 Sep;93:1181-5.
- Eiden B, Davis R. Stabilization of myopia by accelerated reshaping technique. Presented at Global Specialty Lens Symposium, January 2011; Las Vegas.

Photo: Jason Jeddica, O.D.

# Infiltrative Keratitis and Gram-Negative Bacterial Resistance to PQ-Aldox Lens Care Products

The rate of infiltrative keratitis especially with daily wear silicone hydrogel lenses has been reported with greater frequency.<sup>1-4</sup> Infiltrative keratitis is associated with several factors<sup>1-8</sup> including lens care solutions,<sup>9,10</sup> lens type,<sup>1,3</sup> smoking,<sup>5</sup> and bacterial bioburden.<sup>5-8</sup> Contact lens associated infiltrative keratitis (CLAIK) has been reported at higher rates in particular with polyquaternium (PQ)-Aldox (myristamidopropyl dimethylamine) based Multi-Purpose Solutions (MPS).<sup>1-5,9</sup>

Notably, CLAIK has repeatedly been associated with one PQ-Aldox MPS, Opti-Free RepleniSH in independent studies.<sup>1-4</sup> In one report, this solution was being used in 71% of CLAIK cases.<sup>3</sup> Importantly, there has been no demonstrated correlation between transient, solution related corneal staining and inflammatory keratitis.<sup>11</sup>

Low levels of lens case contamination may occur with any MPS or peroxide system in asymptomatic patients, but gram-negative contamination was reported highest with Opti-Free RepleniSH.<sup>12</sup> Recent scientific findings in patients using lens care solutions with CLAIK, demonstrate case contamination with certain gram-negative clinical isolates, the predominant species being *Stenotrophomonas maltophilia* and *Achromobacter*.<sup>13</sup> These gram-negative bacteria have also been cultured in the lens cases of patients using PQ-Aldox MPS.<sup>12,14</sup> Additional research has shown that these clinical isolates are

	Log Unit reduction	
	Achromobacter*	Stenotrophomonas*
Biotrue® MPS (PHMB-PQ)	2.9	3.5
OPTI-FREE PureMoist (PQ-Aldox)	0.1	1.2
OPTI-FREE RepleniSH (PQ-Aldox)	0.0	1.3
OPTI-FREE Express (PQ-Aldox)	0.2	1.2

**Table 1. MPS Biocidal Efficacy Against *Achromobacter* and *Stenotrophomonas* Clinical Isolates Associated with CLAIK<sup>18</sup>**

resistant to a PQ-Aldox MPS and can re-grow during storage in PQ-Aldox MPS in as few as 6 days.<sup>14-16</sup> Non-Aldox PQ-based MPS, such as those containing PHMB, and peroxide lens care solutions have demonstrated excellent biocidal efficacy against these same clinical isolates.<sup>14-17</sup> Table 1 presents biocidal efficacy against clinical isolates of *Achromobacter* and *Stenotrophomonas* when exposed to PQ-Aldox MPSs and a PHMB-PQ MPS.<sup>18</sup> Lens care solutions that are ineffective against these clinical isolates may be prone to case contamination and CLAIK may result directly from these bacteria and/or their endotoxins being repeatedly exposed to the ocular surface.<sup>14</sup>

Further investigation is warranted to understand the causality between infiltrative keratitis events and the use of PQ-Aldox MPS products. The inefficacy of PQ-Aldox MPS against clinical isolates cultured from CLAIK patients should be considered by eye

care practitioners in recommending lens care systems for their patients.

CLAIK has the potential of creating a significant economic burden on patients<sup>19</sup> and may contribute to patients choosing to stop wearing lenses. Switching patients to MPS products with broad antimicrobial efficacy and proven biocompatibility, along with recommending appropriate lens and lens case cleaning regimens,<sup>6</sup> may help to prevent CLAIK, minimize risk for future recurrence<sup>20</sup> or contact lens drop out.

Biotrue® MPS from Bausch + Lomb has proven biocompatibility and also demonstrates excellent disinfection efficacy compared to competitive multi-purpose solutions,<sup>21,22</sup> even against clinical isolates such as *Stenotrophomonas* and *Achromobacter*, which are known to be associated with corneal infiltrative keratitis.

REFERENCES:

1. Camt NA, Evans VE, Naduvilath TJ, et al. Contact lens-related adverse events and the silicone hydrogel lenses and daily wear care system used. *Arch Ophthalmol*. 2009;127(12):1616-1623. 2. Diec J, Evans V, Naduvilath T. Performance of Polyquad, PHMB and Peroxide Solutions With Silicone Hydrogel Lenses. *ARVO Meeting Abstracts*. 2009;50(5):5633. 3. Kislak T. Case Characteristics of Persons Presenting With Contact Lens-associated Infiltrative Keratitis (CLAIK) With Multipurpose Solutions and Contact Lens Combinations. *ARVO Meeting Abstracts*. 2011;52(6):6521. 4. Reeder R. Trends associated with corneal infiltrative events in soft lens wearers. *Global Specialty Lens Symposium*. 2011. 5. Szczotka-Flynn L, Lass JH, Sethi A, et al. Risk Factors for Corneal Infiltrative Events during Continuous Wear of Silicone Hydrogel Contact Lenses. *Invest Ophthalmol Vis Sci*. 2010;51(11):5421-5430. 6. Bates AK, Morris RJ, Stapleton F, Minassian DC, Dart JKG. "Sterile" corneal infiltrates in contact lens wearers. *Eye*. 1989;3(6):803-810. 7. Sankaridurg PR, Sharma S, Wilcox M, et al. Colonization of Hydrogel Lenses with *Streptococcus pneumoniae*: Risk of Development of Corneal Infiltrates. *Cornea*. 1999;18(3):289. 8. Wilcox M, Sharma S, Naduvilath TJ, Sankaridurg PR, Gopinathan U, Holden BA. External Ocular Surface and Lens Microbiota in Contact Lens Wearers With Corneal Infiltrates During Extended Wear of Hydrogel Lenses. *Eye Contact Lens*. 2011;37(2):90-95. 9. Reindel W, Cairns G, Bateman K. Using a meta-analysis to determine relationships between various safety parameters and lens care solutions. *Optometry*. 2009. 10. Camt N, Jalbert I, Stretton S, Naduvilath T, Papas E. Solution Toxicity in Soft Contact Lens Daily Wear Is Associated With Corneal Inflammation. *Optom Vis Sci*. 2007;84(4):309-315. 11. FDA Medical Devices Advisory Committee. Ophthalmic Devices Panel meeting. June 10, 2008. Gaithersburg, MD; 2008. Available at: <http://www.fda.gov/ohrms/dockets/ac/08/minutes/2008-4363m1.pdf>. 12. Wilcox M, Camt N, Diec J, et al. Contact lens case contamination during daily wear of silicone hydrogels. *Optom Vis Sci*. 2010;87(7):456-464. 13. Wiley L, Bridge D, Wiley LA, Odorn JV. Bacterial biofilm diversity in contact lens related disease: Emerging role of *Achromobacter*, *Stenotrophomonas* and *Delta*. *Invest Ophthalmol Vis Sci*. 2012. 14. Kivington S, Shovin JP, Nikolic M. Characterization of bacteria from contact lens storage cases of corneal infiltrative event patients. *Association of Research and Vision in Ophthalmology*. 2012. 15. Nikolic M, Kivington S, Cheung S, Lam A, Brady N, Huth S. Survival and Growth of *Stenotrophomonas maltophilia* in Multipurpose Contact Lens Solutions. *ARVO Meeting Abstracts*. 2010;51(5):1540. 16. Cheung S, Kivington S, Nikolic M, Brady N. Biocidal Efficacy of Multipurpose Contact Lens Care Solutions Against *Stenotrophomonas* and *Delta*: Resistance and Regrowth. *ARVO Meeting Abstracts*. 2011;52(6):5847. 17. Walsh P, David B. AN EVALUATION OF THE ANTIMICROBIAL ATTRIBUTES OF BAUSCH & LOMB'S DUAL-DISINFECTANT MULTIPURPOSE SOLUTION AGAINST AN ARRAY OF MICROBIAL ORGANISMS. 2011:1-1. 18. Testing was performed according to methods described in ISO 14729 to demonstrate the antimicrobial efficacy using a disinfectant multipurpose solution. Efficacy (average of 3) was evaluated against clinical isolates of *A. xylosoxidans* and *S. maltophilia*. Organic soil was used following the ISO organism preparation guidelines. The test solution was evaluated at the labeled 4hr disinfection time for Biotrue and 6hr disinfection time for PureMoist and Optifree RepleniSH. The challenge inoculum for each organism was prepared at ~5.0x10<sup>5</sup> colony forming units (CFU)/ml. 19. Smith AF, Orsborn G. Estimating the Annual Economic Burden of Illness Caused by Contact Lens-Associated Corneal Infiltrative Events in the United States. *Eye & Contact Lens: Science & Clinical Practice* 2012:1. 20. Diec J, Evans V, Naduvilath T, et al. The Recurrence Rate of Corneal Inflammatory Events With Silicone Hydrogel Lens and Care Products. *ARVO Meeting Abstracts* 2010;51:1538. 21. Results of in vitro study following FDA/ISO stand-alone procedure for disinfecting products. Log reduction values at a minimum soak time without organic soil. 22. Results of in vitro study following FDA/ISO stand-alone procedure for disinfecting products. Tests against all solutions were modified with organic soil to create a more rigorous test condition. Primary criteria for effective disinfection are defined as a reduction in the number of bacteria by a minimum of 3 logs (99.9%) and a reduction of mold and yeast by a minimum of 1 log (90%) within the recommended disinfection time. © Bausch & Lomb Incorporated. ®TM are trademarks of Bausch & Lomb Incorporated or its affiliates. All other product/brand names are trademarks of their respective owners. Global 0996

# EHR: Embracing the Next Phase of Meaningful Use

The Final Stage 2 Rule for meaningful use and certification of EHR technology signals some new requirements for O.D.s, while scaling back on other proposed thresholds, so don't delay EHR adoption. **By Mark McGraw, Contributing Editor**

**W**ith the issuance of September's Stage 2 Final Rule under the Medicare and Medicaid EHR Incentive Programs, the march toward establishing "meaningful use" of EHR systems continues in medical practices and facilities across the health care spectrum.

At first blush, the new ruling—which introduces new clinical quality measures reporting mechanisms for practitioners—may seem to slow down the pace of that march for optometrists. But while the update does push back Stage 2's timeframe for establishing meaningful use from 2013 to 2014, experts advise optometrists to stay on track for becoming meaningful users of EHR by next year.

## Change on the Menu

Stage 2 begins in 2014, a year later than the 2009 American

Recovery and Reinvestment Act originally required—or two years after a provider first achieves requirements for Stage 1.

While eligible providers, including optometrists, can start to earn Stage 1 incentive payments as late as 2014 under the Medicare EHR Incentive Program, and 2016 under the Medicaid EHR Incentive Program, Medicare will begin to impose penalties on those not achieving meaningful use by 2015.

While the Stage 1 meaningful use criteria were met with criticism for being essentially primary care-based, National Health Information Technology Coordinator Farzad Mostashari, M.D., Sc.M., has described the Stage 2 rule as being "potentially more relevant to specialists."

Most notably, the rule makes the optional menu items from Stage 1 mandatory, adding a require-

ment for patient engagement and allowing medical groups to attest to meaningful use for multiple providers at one time, while raising the bar for meeting other mandatory items in Stage 1. For instance, providers are now required to enter medication orders electronically for at least 60% of their patients, whereas Stage 1 only required providers to do so 30% of the time.

And, under patient reporting demographics for Stage 1, demographics only had to be reported for more than 50% of unique patients—defined as patients seen multiple times during a given reporting period but only counted once. In Stage 2, that number has gone up to 80%.

In addition, under Stage 1, more than 80% of all unique patients seen must have at least one entry—or an indication that the patient is not currently prescribed any

## Meaningful Use: Changes from Stage 1 to Stage 2

Stage 1	Stage 2
<b>Eligible Professionals</b> 15 core objectives <u>+5 of 10 menu objectives</u> 20 total objectives	<b>Eligible Professionals</b> 17 core objectives <u>+3 of 6 menu objectives</u> 20 total objectives
<b>Eligible Hospitals &amp; CAHs</b> 14 core objectives <u>+5 of 10 menu objectives</u> 19 total objectives	<b>Eligible Hospitals &amp; CAHs</b> 16 core objectives <u>+3 of 6 menu objectives</u> 19 total objectives

medication—recorded as structured data. This measure is no longer a separate objective under Stage 2, and has been incorporated into the Stage 2 measure of summary of care record.

While some thresholds have been raised, others have been added that hold optometrists accountable for patient utilization of information. For example, providers must now offer online access to health information and secure messaging for only 5% of patients, as opposed to the 10% of patients that had previously been proposed. In response to a federal advisory board, the final certification rule also adds a requirement that all personally identifiable health data must be encrypted while at rest.

Also worth noting is that the Stage 1 core set measure for recording vital signs has changed for 2013, adds Jeff Grant, president and founder of HealthCare Management & Automation Systems, a practice management and IT consulting firm in Shell, Wyo. “Essentially, this change separates blood pressure from height and weight, which means, for example, that optometrists can exclude height and weight if they believe blood pressure is relevant but height and weight are not.”

“CMS recognized that the whole idea of using vital signs for anyone other than primary care physicians was a bit questionable,” Mr. Grant adds. “So, Stage 2 created some flexibility that wasn’t there before. Stage 1 didn’t take specialties into account.”

### Do the Math

In a nutshell, meaningful use criteria are divided into groups of core objectives that all providers must complete. In total, individual providers must now meet 17 core measures for meaningful EHR use, as well as choosing from a menu of six additional measures.

On the surface, the differences between Stage 1 and Stage 2 criteria may seem numerous, but providers must still essentially meet the same number of requirements, says Jay W. Henry, O.D., M.S., a partner at Hermann & Henry Eyecare, in Pickerington, Ohio. “The obvious comparison would be going from 15 core and five-out-of-10 menu objectives in Stage 1 to 17 core and three-out-of-six menu objectives for Stage 2,” he says.

This move adds some new objectives, removes others and combines many Stage 1 objectives into single objectives in Stage 2.

“Now, some of the core objec-

tives have exemptions or exclusions, and if a provider meets an exemption, he wouldn’t need to complete that objective, but would get credit for it,” Dr. Henry explains. “In Stage 1, that meant that you must either complete, or meet, an exclusion to those 15 core items.

From the menu set, providers could select the five that they wanted to complete out of the 10 available to choose from,” says Dr. Henry. “However, one of the two public health measures still had to be completed. In the end, providers were going to complete or get credit for 20 objectives.”

Under Stage 2, however, the 17 core objectives must now be completed or exempted from, and providers must choose three of the six menu items, but “in the end, you are still reporting on 20 objectives. The truly important part of this is understanding what these new 20 objectives are, how they have changed—including the new quality measures—and how they will impact you clinically,” Dr. Henry explains.

### No Surprises

The provisions within the Stage 2 final rule shouldn’t come as a great shock to optometrists who

## Practice Management

have been following the meaningful use incentive program's progress, Mr. Grant says. "We knew this was coming," he says. "What the update does is somewhat change the timeline. The original law indicated that Stage 2 would be for 2013. So this is a nice reprieve, to have an extra year at Stage 1."

And, while the Stage 2 final rule mandates that the next phase won't take hold until 2014, optometrists will still be impacted in the upcoming year, he says.

For example, practices that attest for the 2013 payment year will avoid the 2015 penalty payment. Those that don't attest for next year, however, will see Medicare reimbursements decreased by 1% when the penalties take effect in 2015. As such, providers must continue to attest in 2013.

This requirement, says Mr.

Grant, will be the same for providers who attested in 2011 or 2012, and whose reporting period is the full calendar year, or those for whom 2013 is the first payment year and have a reporting period of only 90 days. It's worth noting, he adds, that Stage 2 includes a special provision for eligible professionals demonstrating meaningful use for the first time in 2014. In other words, providers attesting no later than Oct. 1, 2014 would avoid the 2015 penalty.

### Clear Communication

For EHR vendors, numerous changes must be made so that their EHR systems support the new and combined Stage 2 objectives. This may require adding some new features, such as secure messaging and electronic submission of clinical quality measures, as well as

making workflow changes to meet the changed objectives, says Philip J. Gross, O.D., partner at Vision Quest Eye Care Center, in Dover, Del.

"More importantly, EHR vendors will need to support multiple rules simultaneously," he says. For instance, some optometrists will start their first year as meaningful users in 2014. Therefore, these optometrists will be under the Stage 1 rules, while others will be starting their third year of meaningful use, and thus will be held to the Stage 2 rules.

"This is going to create much more complexity for the EHR vendors, as well as create more time needed for design and engineering to support these multiple simultaneous tracking and reporting systems," Dr. Gross says.

Optometry practices must be

# Powerful Hiring Made Simple.



*Post your Eye Care Job on*  
**LocalEyeSite.com**  
*and experience effective hiring*  
through the **LES Power Network**



careful to make sure the vendors providing their EHR systems are on top of the certification process.

“Doctors need to be communicating with software vendors to ensure that they’re certified in a timely manner,” he says. “No vendor could *not* be certified, or else they would cease to be in business. But optometrists need to make sure that their vendor is certified in a timely enough fashion so as not to jeopardize their status as a meaningful user in 2014.”

### No Time Like the Present

Consistent communication with vendors about their certification is just one piece of the process for optometrists gearing up for meaningful use by 2014, however. “The first step for optometrists is to choose a certified EHR system that they’re comfortable with,” says Dr. Henry. “Optometrists should demo the product and be sure they like how the information goes into the EHR and what it looks like once it is in there.” For example, evaluate how easy previous results such as past refractions or past posterior segment results can be viewed, and how they can adapt to the workflows that the EHR uses.

Once the system is in place, it’s important for optometrists to understand that, given the new changes that have just been released, the first two years that a practice participates in meaningful use will always be in Stage 1, Dr. Gross adds.

After that, you will move to the newer Stage 2 rules and objectives. Still, optometrists should register for the EHR incentive program as early as possible in the year they plan to participate, Dr. Gross says. “Then, any problems with registration can be addressed before the due date of March 1 the following calendar year.” (For instance, participants in 2012 must register and attest before March 1, 2013).

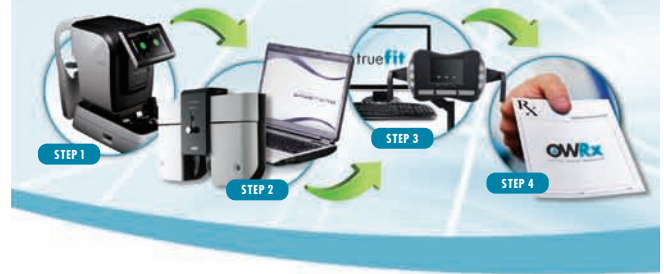“Finally,” says Dr. Gross, “once the objectives for the EHR reporting period are completed, the practice needs to attest before March 1 of the following calendar year as well,” he explains.

Indeed, Mr. Grant says “there’s really no reason for anyone to put off” working toward meaningful use of an electronic health record until 2014, tempting as it may be.

“2012 is pretty much over,” he says. “To ensure the maximum incentive possible that’s remaining—and to prevent incurring the penalties that begin in 2015—optometrists should work hard to become meaningful users in 2013.” ■

## The Complete Digital Eye Exam

SIMPLIFIED • DIGITIZED • PERSONALIZED



# OWRx

## Digital Screening



### Quickly acquire precise patient's Rx with OWRx Digital Screening and the Huvitz HRK-8000A

- Combines aberrometer, auto-refractor/keratometer
- HOA blended correction with advanced OWR algorithm
- Rx accuracy up to 0.01 Diopter
- Prescribe Digital Freeform Lenses

## Enhanced IMAGE

SPECIAL  
Limited Time Offer  
**\$14,995.00**  
with qualified trade-in



136 W. Orion Street | Suite 3 | Tempe, Arizona | 85283

888.315.1256

[www.voi2020.com](http://www.voi2020.com)

# Ocular Complications in IV Drug Users

Two case reports illustrate the visually devastating risks associated with the use of injectable street drugs. **By Amanda S. Legge, O.D.**

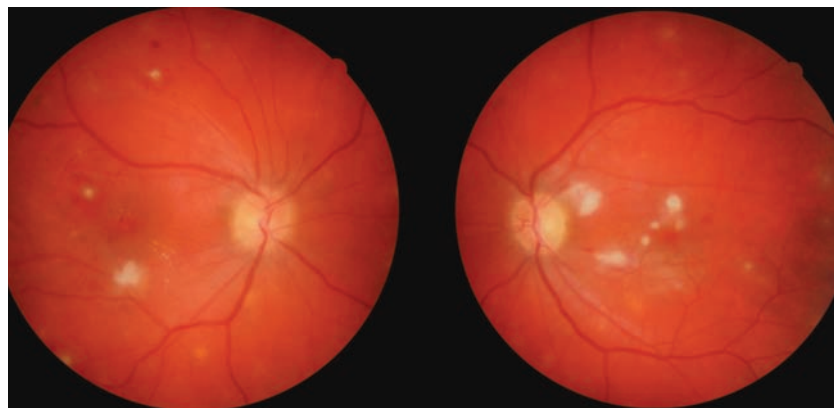
Intravenous drug use is directly associated with a variety of localized and systemic complications. In addition, it can yield numerous ophthalmological consequences. The most devastating ocular side effects of intravenous drug use include the formation of choroidal and retinal nodules, infarction and inflammation. Typically, such associated lesions form in the posterior pole near the macula.

Eliciting a thorough patient history is crucial for appropriate testing, culturing and treatment. Prompt diagnosis and management is of utmost importance to decrease both ocular and systemic morbidity.

The following case reports describe complicated infections and potential posterior segment damage secondary to intravenous drug abuse.

## Case 1 History

A 30-year-old white male presented to our office for the first time with a chief complaint of decreased visual acuity (O.S.>O.D.). His vision had



**1. Fundus photographs of the patient described in Case 1 revealed the presence of bright retinal infiltrates, hemorrhages and dull choroidal infarcts in both eyes as well as exudates in his right eye (O.D. left, O.S. right).**

decreased suddenly about two weeks earlier but had remained stable O.U. since. He denied the presence of floaters, photopsia, diplopia, pain or discomfort.

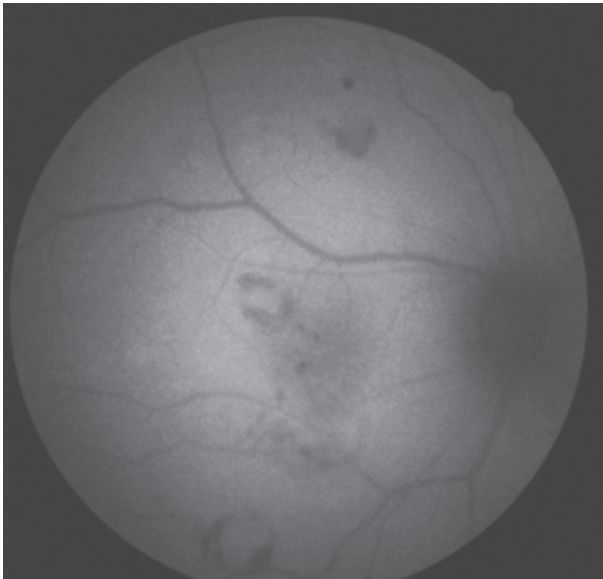
The patient's medical history was remarkable for post-traumatic stress disorder, bipolar affective disorder, chronic cluster headaches and depression. He did not take any medications.

The patient's ocular history was unremarkable because he reported never undergoing a formal eye exam. His family ocular and medi-

cal histories were unremarkable.

Prior to vision loss, the patient experienced low-grade fevers, severe cluster headaches and diffuse joint pain for one month. His primary care physician (PCP) performed an extensive lab work-up, which included complete blood count (CBC), partial thromboplastin time, international normalized ratio, lupus anticoagulant, amylase, lipase, fluorescent treponemal antibody (FTA), rheumatoid factor, antinuclear antibodies, rapid plasma reagin (RPR), urinalysis and





**2. Fundus autofluorescence of his right eye illustrated multiple hemorrhages surrounding the white infarcts (Roth's spots), which blocked the autofluorescence.**

HIV screening. All test results returned within normal limits. The patient also had a negative CT scan of the head and chest without contrast. He had not seen his PCP since receiving these results.

Upon further questioning, the patient admitted to injecting crack cocaine dissolved in vinegar intravenously. He said that he had injected the drug approximately 10 to 15 times per week for the past five years. He stated that he was aware of the risks of his behavior, but had not sought any counseling or rehabilitation.

### Diagnostic Data

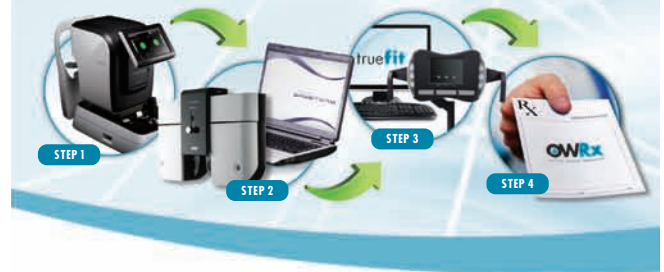The patient's uncorrected visual acuity measured 20/40 O.D. and 10/300 O.S. with direct fixation. No improvement was observed upon pinhole testing. He achieved 20/200 O.S. with eccentric fixation. His pupils were equal, round and reactive to light, without evidence of afferent defect O.U. Extraocular motility testing showed no restrictions in muscle movement. Confrontation visual fields were full to finger counting O.U.

Intraocular pressure measured 11mm Hg O.D. and 12mm Hg O.S. Anterior segment examination was unremarkable. We detected no inflammatory cells or protein flare in the anterior chamber.

Gonioscopy revealed that the most posterior structure in all quadrants was the ciliary body face O.U.

## The Complete Digital Eye Exam

SIMPLIFIED • DIGITIZED • PERSONALIZED



# OWRx

## Digital Eye Exam



## Enjoy Refracting Again!

- Reduce stress and strain
- Increase patient throughput
- Increase revenues
- Blended HOA correction
- Patient **WOW** factor!

Special Limited Time Offer  
**BASIC DIGITAL EYE EXAM**  
**\$26,995**  
 MSRP \$37,504  
 Plus FREE Installation & Training

## Enhanced REFRACTING



136 W. Orion Street | Suite 3 | Tempe, Arizona | 85283

888.315.1256

[www.voi2020.com](http://www.voi2020.com)

# Case Report

No sign of microhyphema, microhypopyon, peripheral anterior synechiae or neovascularization was noted O.U. Posterior segment evaluation revealed multiple choroidal and retinal infarcts of varying duration (*figure 1*) as well as the presence of Roth's spots throughout the posterior pole O.U. (*figure 2*).

Nerve fiber layer hemorrhages and exudates as well as retinal infiltrates were noted, indicating a septic chorioretinitis. The optic nerves appeared flat, pink and distinct, with no sign of disc edema O.U.

The left macula was affected dramatically by multiple infarcts and intraretinal edema, which correlated with the severe visual decrease in that eye. The right eye exhibited subtle macular edema and exudates, accounting for the mild decrease in vision.

Following the examination, we ordered additional blood work, including another CBC with platelet count and differential, troponin I, Westergren sedimentation rate, C-reactive protein (CRP) and a blood culture.

## Diagnosis and Follow-Up

We tentatively diagnosed our patient with septic chorioretinitis, pending further testing. We educated the patient about the emergent nature of this condition and informed him that it likely was caused by bacterial endocarditis. We made an immediate referral to a local hospital, and indicated the need for a transesophageal echocardiogram (TEE) to confirm the diagnosis and begin prompt administration of intravenous antibiotics.

He did not report to the hospital as recommended. Upon investigation, a relative informed us that he had died from a gunshot wound to the head. Apparently, he was murdered the night of the referral. We later confirmed this report.

The lab results were received within 48 hours, revealing an elevated troponin I, sedimentation rate and CRP. The CBC remained within normal limits. The blood culture revealed growth of *Staphylococcus aureus*, which may have been methicillin resistant.

Although the TEE could not be obtained to confirm, we presumed

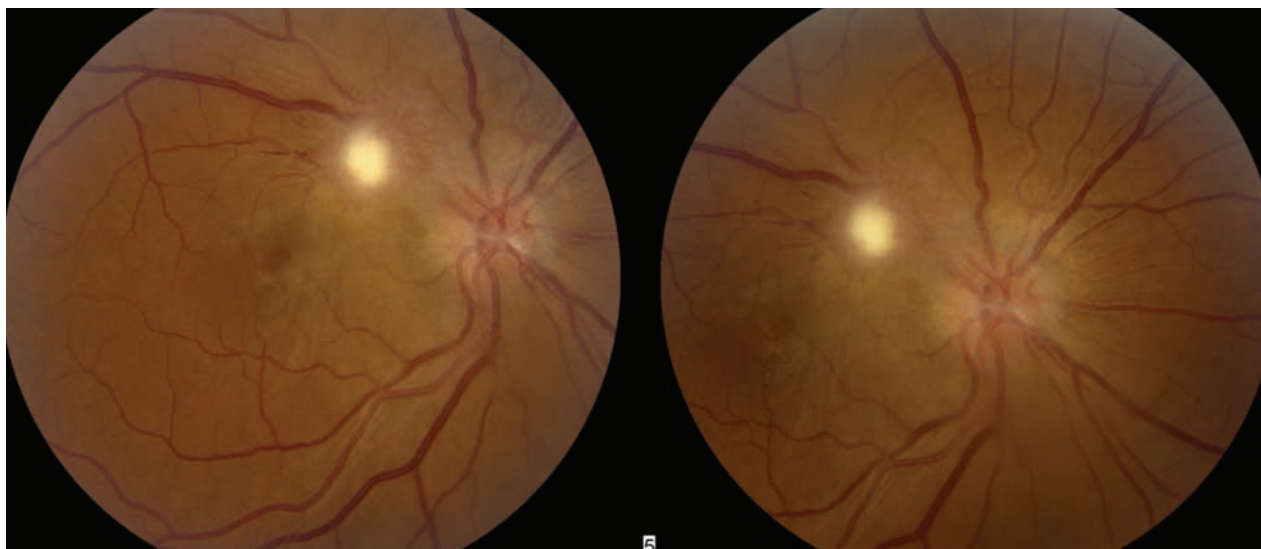
the diagnosis to be bacterial endocarditis secondary to *S. aureus* infection, very likely due to street drug use.

## Case 2 History

A 42-year-old white female presented with a chief complaint of severe blurred vision in her right eye that had persisted for a week. Her vision decreased rapidly and painlessly over the course of two to four days and had remained stable since that time. She did not complain of pain, irritation, diplopia, photopsia or floaters. Additionally, she exhibited no associated systemic signs or symptoms.

The patient's medical history was unremarkable, but she admitted that she had not seen a PCP in at least 10 years. Her ocular history was unremarkable; however, she reported wearing glasses since age 12. Her current prescription was at least four to five years old. The patient's family ocular and medical histories were unremarkable.

Upon additional questioning, the patient admitted to intravenous



**3. Color fundus photography of our patient in Case 2 revealed the position of the retinal lesion as well as the blurred disc margins. Few retinal striae can be seen located temporal to the lesion (O.D. left, O.S. right).**

heroin use since age 15. She reported that, during the past year, she had reduced her drug usage to “just a few times a month.” However, she admitted to using heroin up to six times per day in the past. She acknowledged the risks of her behavior, and had attended multiple counseling sessions during the last five years. Still, she never enrolled in a formal rehabilitation program.

### Diagnostic Data

Upon evaluation, the patient’s corrected visual acuity measured 20/100 O.D. and 20/20 O.S. No improvement was documented upon pinhole testing. Her pupils were equal, round and reactive to light, with no evidence of afferent defect. Extraocular motility testing showed no restrictions in muscle movement. Confrontation visual fields were full to finger counting O.U.

On color vision testing, the patient correctly identified 14/14 Ishihara plates O.U. No red desaturation was detected.

Her intraocular pressure measured 18mm Hg O.D. and 19mm Hg O.S. The anterior segment examination was unremarkable, with no evidence of inflammatory cells or protein flare in the anterior chamber. Gonioscopy revealed that the most posterior structure in all quadrants was the ciliary body face O.U. We documented no sign of microhyphema, microhypony, peripheral anterior synechiae or neovascularization O.U.

The posterior segment evaluation revealed a round, yellow-white pre-retinal lesion (*figure 3*) with surrounding telangiectasia (*figure 4*) and 2+ posterior vitreous cells in her right eye. Furthermore, we noted trace to 1+ cells in the anterior vitreous.

The right optic nerve had blurred margins. This presentation likely was caused by traction and vitreal inflammation rather than true disc edema, because no afferent defect was noted on pupil testing and color vision was normal.

The fundus examination of the left eye was unremarkable.

### Diagnosis and Follow-Up

Immediately, we referred her to the hospital for blood work and intravenous antimicrobial therapy. The patient received an MRI of the brain and orbits, both with and without contrast. Additionally, she underwent FTA, RPR, HIV screening, Lyme titer, angiotensin-converting enzyme, *Toxocara* screening, purified protein derivative, chest X-ray, CBC testing

## The Complete Digital Eye Exam

SIMPLIFIED • DIGITIZED • PERSONALIZED



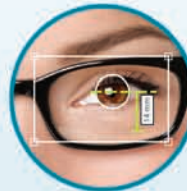# OWRx

## Digital Dispensing



### Image Capture

- Sonar based
- Ergonomic
- User Friendly



### Digital Measurements

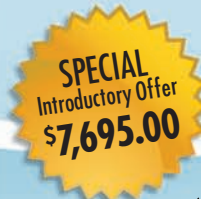- Sonar based
- No frame attachments
- Reduce remakes



### Digital Demonstrations

- High index lenses
- Anti-reflective coatings
- Frame try on

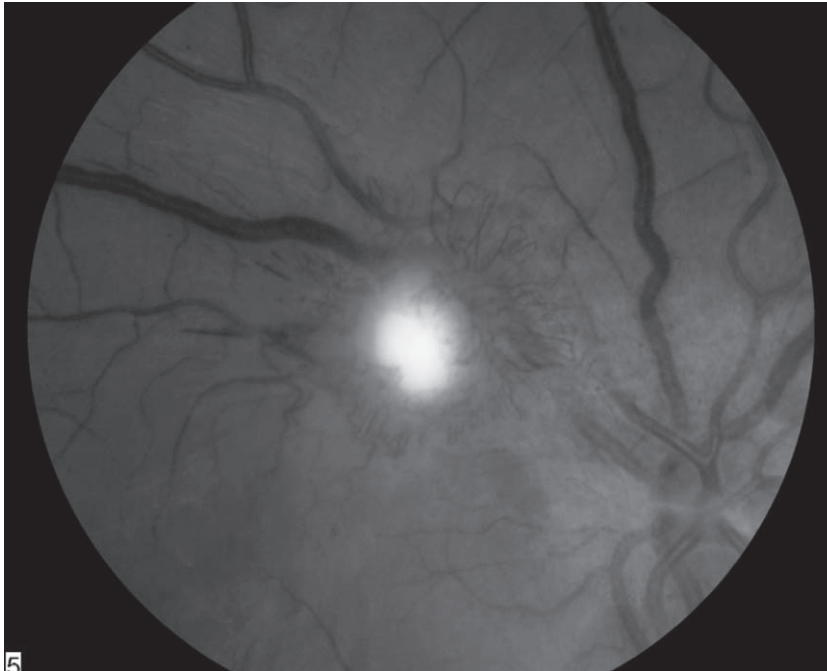
## Enhanced REVENUES



136 W. Orion Street | Suite 3 | Tempe, Arizona | 85283

888.315.1256

[www.voi2020.com](http://www.voi2020.com)



**4. Magnified red-free image of the retinal lesion outlined the surrounding telangiectatic vessels in her right eye.**

and a blood culture.

Further, a vitreal culture was taken the following day. A mold infection of unknown species was identified in the vitreal cultures. All other blood testing was negative. The patient was started on intravenous amphotericin B, because of its broad-spectrum coverage. The mold did not reproduce in the mycology lab, which was necessary for species identification.

Because amphotericin B has poor vitreal penetration when prescribed orally, the patient also was started on 5µg/0.1mL intravitreal injection of the drug. She received two in-patient intravitreal injections during the five-week hospitalization period. Following discharge, the patient was transitioned from intravenous to oral amphotericin B by her infectious disease specialist. Recently, she reported a moderate improvement in vision with mild distortion. Approximately five and a half weeks after the initial

diagnosis, her visual acuity measured 20/50 O.D. and 20/20 O.S.

Vitreous cells were not observed at follow-up. The pre-retinal nodule had formed into a fibrotic scar, causing retinal traction and striae (figure 5). Blood cultures were performed again both two and four weeks after hospital admittance; all cultures returned negative. Eight weeks after initial culture, we identified the mold as a *Malbranchea* species.

During the next year, we will closely monitor the patient for advancing retinal traction and a potential detachment O.D. We educated her extensively on the risks associated with intravenous drug abuse, and she promised to begin an official rehabilitation program as soon as possible.

## Discussion

Recreational injection of street drugs directly is associated with a variety of local and systemic com-

plications. It is also linked to the transmission of infectious diseases through needle sharing and sexual activity. The most serious ocular complications have been reported from the use of crack or crack-cocaine, methylenedioxymethamphetamine or diamorphine (heroin) injections.<sup>1</sup>

Ophthalmological complications include corneal ulcers, reduced corneal sensitivity, microalcal retinopathy, retinal or choroidal infarcts, central retinal artery or vein occlusion, endophthalmitis, nystagmus, and cerebrovascular accidents that cause neuro-ophthalmic manifestations.<sup>2</sup>

Retinal or choroidal infarct, inflammation or infiltrates cause some of the most devastating visual sequelae, because they typically are located in the posterior pole.<sup>1</sup> These signs are indicative of general septic chorioretinopathy. The underlying cause is bacterial or fungal (or, less commonly, parasitic). Inflammatory causes of chorioretinopathy must also be ruled out.

Eliciting a history of illicit intravenous drug abuse is imperative when septic chorioretinopathy is suspected. This helps to facilitate prompt testing for the most commonly associated pathogens and also could help guide the most appropriate treatment regimen.

Bacterial pathogens, specifically those of the *Staphylococcus* genus, are the most common cause of infection in intravenous drug users.<sup>2</sup> Without question, eye care clinicians should be most concerned about the potential for methicillin-resistant *Staphylococcus aureus*. Other common pathogens associated with this behavior include streptococci, gram-negative bacilli, enterococci, *Fusarium*, *Aspergillus* and *Candida*.<sup>2</sup>

The development of Roth's

# ...less has never meant more.



**\$1,000 Trade-In**  
on any tonometer  
traded in through  
November 30, 2012!

Easiest To Use  
Smallest Footprint  
Lowest Price

#### *Less is more.*

Pulsair Desktop is uncomplicated and therefore quick to use for the novice and professional alike. Taking control of tonometry has never been easier or faster. Clear user controls and a color video alignment screen combine to set a new standard in usability.

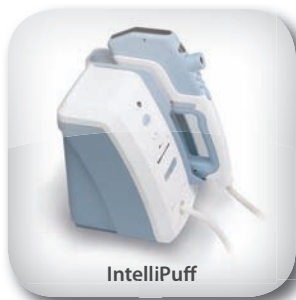The Pulsair Desktop has a small and space saving footprint that combined with the elegant, slim optical mainframe allows it to blend seamlessly into the clinical environment. The openness of the design increases the confidence of both patient and clinician.

Contact Keeler or your preferred Keeler distributor today to learn more about the Pulsair Desktop and the rest of the Keeler family of tonometers.

The Keeler Family of Tonometers offers your practice  
the choice of technology that's right for you!



Keeler K.A.T.



IntelliPuff

Great Low Price!  
**\$6,250.00**

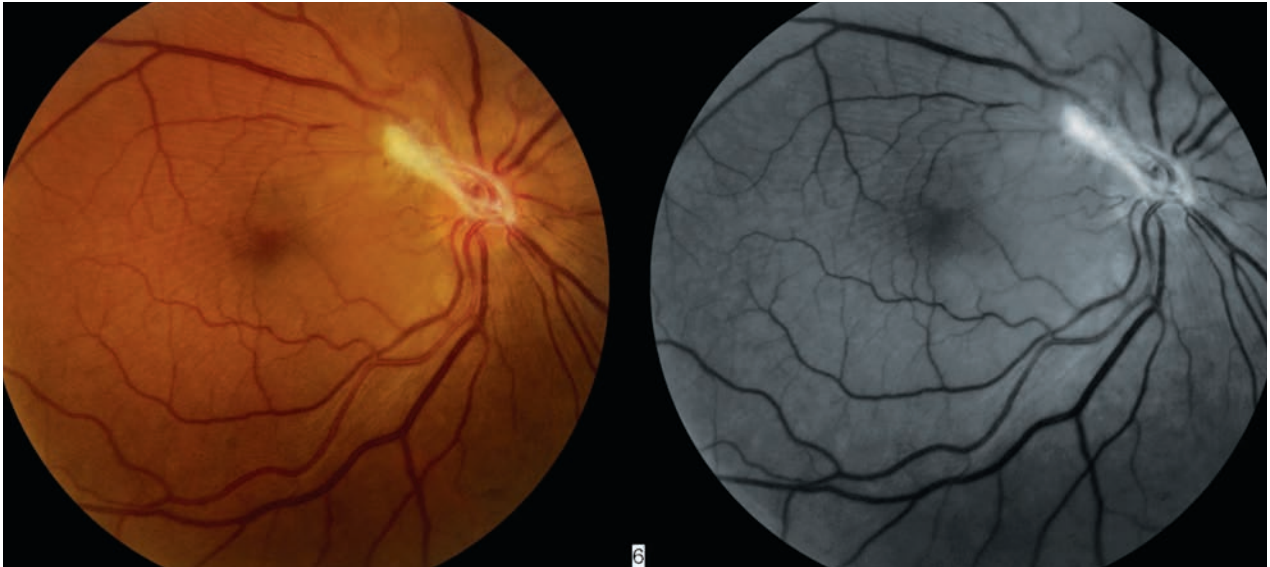Buy Online!  
[keelerusa.com](http://keelerusa.com)



# Keeler

[www.keelerusa.com](http://www.keelerusa.com) | 800-523-5620

A HALMA COMPANY



**5. Color and red-free fundus photography of the patient's right eye five weeks after the initial diagnosis and commencement of treatment. Fibrotic scarring now is present in the area of the nodule, with moderate traction and retinal striae throughout the macula and superior vascular arcade.**

spots is one of the most serious presentations in intravenous drug users who are suspected of bacterial chorioretinitis or endocarditis. Roth's spots are white-centered hemorrhages that classically are indicative of bacteremia and bacterial endocarditis; however, they also are seen in diseases such as leukemia, pernicious anemia, sickle cell disease and connective tissue disorder.<sup>3</sup>

In bacterial endocarditis, Roth's spots are formed as a result of thrombocytopenia and a low-grade, disseminated, intravascular coagulopathy.<sup>4</sup> The clinically viewed, white-centered hemorrhages are most likely caused by anoxia, which causes a sudden increase in venous pressure. This causes capillary rupture and extrusion of whole blood. Platelet release causes the coagulation cascade to initiate, eventually causing a platelet-fibrin thrombus surrounded by heme.<sup>5</sup>

Because of this specific pathology, Roth's spots are now part of

the standard used to determine a diagnosis of bacterial endocarditis.<sup>6</sup>

According to the standard Duke criteria, infective endocarditis definitely is present under three conditions:<sup>6,7</sup>

- *Two major clinical criteria are present.*
- *One major and three minor clinical criteria are present.*
- *Five minor clinical criteria are present.*

Major clinical criteria include persistently positive blood cultures for organisms that typically cause bacterial endocarditis, vegetations or abscesses present in heart valves (as seen on echocardiogram), evidence of new echocardial damage, or culture evidence of infection with *Coxiella burnetii*.

Minor critical criteria include fever, the presence of a predisposing valvular condition or intravenous drug abuse, vascular phenomenon (includes emboli to organs or brain and hemorrhages in the mucous membranes around the eyes), immunologic phenom-

enon (includes Roth's spots and Osler's nodules), and positive blood cultures that do not meet the strict definitions of the major criteria.<sup>7</sup>

Compared to other classification systems, the Duke Criteria exemplifies the highest validity. Multiple studies have shown its predictive value to be approximately 80%, and it rarely rejects any infective endocarditis that is ultimately pathologically confirmed.<sup>6-8</sup> The patient in Case 1, although unable to undergo further testing, had a probable diagnosis of bacterial endocarditis according to these criteria. A definitive diagnosis would have required additional testing, including a TEE.

Early treatment of bacterial endocarditis is crucial to maintaining low morbidity and mortality rates. Treatment consists of prolonged parenteral therapy of bacteriocidal agents.

Serial blood cultures are necessary to document sterilization. As previously noted, the most common

pathogen associated with bacterial endocarditis in intravenous drug users is *Staphylococcus aureus*, which accounts for more than half of these infections.<sup>9</sup>

The most common treatment regimen for *S. aureus* infective endocarditis is intravenous nafcillin and an aminoglycoside for two weeks.<sup>10</sup> Several studies also have evaluated a regimen of oral antimicrobials, because many intravenous drug users refuse hospitalization. However, these agents have not been as successful. Standard of care remains a two-week hospitalization period with serial blood cultures.<sup>11</sup>

Fungal infections also may cause choroidal or retinal nodules, infarcts and inflammation in intravenous drug abusers. However, Roth's spots are not typically caused by fungal or parasitic infections.

In intravenous drug users, the most common cause of fungal chorioretinopathy is *Candida*.<sup>12</sup> Chorioretinopathy caused by *Candida* presents as a round, white, fluffy lesion with a mild to moderate vitritis. This presentation must be differentiated from toxoplasmosis, which is similar in appearance; however, the active lesion often is located directly adjacent to a chorioretinal scar. Other differentials include tuberculosis, syphilis, Lyme disease, sarcoidosis and *Toxocara*.<sup>3</sup>

Endogenous fungal endophthalmitis typically is caused by a chorioretinitis that subsequently progresses into the vitreous. Transient fungemia may seed in the highly vascularized choroid.<sup>13</sup> Once in the choroid, the yeast proliferates, invokes an inflammatory response and can subsequently rupture into the vitreous cavity. Once in the vitreous cavity, the

infection is considered a true fungal endophthalmitis.<sup>14</sup>

Unless the vitreous is involved, treatment should consist of oral antifungals. A vitritis secondary to a fungal infection is best treated with early vitrectomy and intravitreal amphotericin B.<sup>13,15</sup> Be sure to consult an infectious disease specialist once a diagnosis of fungal chorioretinitis or endophthalmitis is made.

At minimum, the duration of treatment for fungal endophthalmitis is five weeks. Ultimately, however, the treatment schedule is dictated by improvement documented on ophthalmological examinations.<sup>16</sup>

Unfortunately, the species of the mold in Case 2 could not be determined during the treatment period. Therefore, we used broad-spectrum anti-fungals and achieved moderate success.

A diagnosis of septic chorioretinitis warrants further investigation into a patient's social history; so if you see it, you must inquire about recreational drug use. This is especially true if the patient is in a high-risk population for illicit drug abuse.

Prompt diagnosis and management is crucial to lowering the risk for ocular and systemic morbidity and mortality associated with these findings. Comanage with an infectious disease specialist early in the treatment course for the best possible outcome.

We must also offer and encourage patient education and rehabilitation services immediately following any hospitalization requirements.

Intravenous drug abuse is associated with a variety of local and systemic complications. Numerous ophthalmological consequences

can be observed with or without patient symptoms. Observation of suspicious signs warrants a thorough history, including recreational drug use. Eliciting a connection between intravenous drug abuse and clinical signs is essential to quickly and accurately diagnose and manage both the ocular and systemic complications. ■

*Dr. Legge is in private practice at Wyomissing Optometric Center in Pennsylvania. She graduated from Salus University in 2012 with a concentration in advanced retinal studies.*

1. Firth A. Ocular sequelae from the illicit use of class A drugs. *Br J Orthopt J.* 2004 Jan;1:10-8.
2. Cherubin C, Sapira J. The medical complications of drug addiction and the medical assessment of the intravenous drug user: 25 years later. *Ann Intern Med.* 1993 Nov 15;119(10):1017-28.
3. Wills Eye Hospital. *The Wills Eye Manual: Office and Emergency Room Diagnosis and Treatment of Eye Disease*, 5th ed. Philadelphia: Lippincott; 2008.
4. Ling J, James B. White centered retinal hemorrhages (Roth spots). *Postgrad Med J.* 1998 Oct;74(876):581-2.
5. Urbano F. Peripheral signs of endocarditis. *Hosp Phys.* 2000 May;5:41-6.
6. Durack DT, Lukes AS, Bright DK. New criteria for diagnosis of infective endocarditis: utilization of specific echocardiographic findings. *Duke Endocarditis Service. Am J Med.* 1994 Mar;96(3):200-9.
7. Li JS, Sexton DJ, Mick N, et al. Proposed modifications to the Duke criteria for the diagnosis of infective endocarditis. *Clin Infect Dis.* 2000 Apr;30(4):633-8.
8. Hoen B, Selson-Suty C. Evaluation of the Duke criteria versus the Beth Israel criteria for the diagnosis of infective endocarditis. *Clin Infect Dis.* 1995 Oct;21(4):905-9.
9. Mathew J, Addai T, Anand A, et al. Clinical features, site of involvement, bacteriologic findings, and outcome of infective endocarditis in intravenous drug users. *Arch Intern Med.* 1995 Aug 7-21;155(15):1641-8.
10. Chambers HF, Miller RT, Newman MD. Right-sided *Staphylococcus aureus* endocarditis in intravenous drug abusers: two-week combination therapy. *Ann Intern Med.* 1988 Oct 15;109(8):619-24.
11. Heldman AW, Hartert TV, Ray SC, et al. Oral antibiotic treatment of right-sided staphylococcal endocarditis in injection drug users: prospective randomized comparison with parenteral therapy. *Am J Med.* 1996 Jul;101(1):68-76.
12. Klotz SA, Penn CC, Negvesky GJ, Butrus SI. Fungal and parasitic infections of the eye. *Clin Microbiol Rev.* 2000 Oct;13(4):662-85.
13. Aguilar G, Blumenkrantz M, Egbert P, McCulley J. *Candida* endophthalmitis after intravenous drug abuse. *Arch Ophthalmol.* 1979 Jan;97(1):96-100.
14. Omuta J, Uchida K, Yamaguchi H, Shibuya K. Histopathological study on experimental endophthalmitis induced by bloodstream infection with *Candida albicans*. *Jpn J Infect Dis.* 2007 Feb;60(1):33-9.
15. Essman TF. Treatment outcomes in a 10-year study of endogenous fungal endophthalmitis. *Ophthalmic Surg Lasers.* 1997 Mar;28(3):185-94.
16. Popovich K, Malani PN, Kauffman CA, et al. Compliance with Infectious Diseases Society of America guidelines for ophthalmologic evaluation of patients with candidemia. *Infect Dis Clin Pract.* 2007;15:254.

If your presbyopic patients aren't in AIR OPTIX® AQUA Multifocal contact lenses,

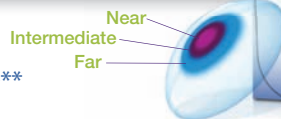
they may **NOT** be seeing the full picture.



Make a smooth transition with a great multifocal lens—  
AIR OPTIX® AQUA Multifocal contact lenses



- AIR OPTIX® AQUA Multifocal contact lenses outperform monovision for superior vision with emerging presbyopes,<sup>2\*\*</sup> and are preferred by patients over PureVision<sup>^</sup> Multi-Focal<sup>3†</sup> and ACUVUE<sup>^</sup> OASYS<sup>^</sup> for PRESBYOPIA contact lenses<sup>4††</sup>



- Precision Profile™ Lens Design has a smooth transition from center near to intermediate and distance zones
- 96% of eye care practitioners agreed AIR OPTIX® AQUA Multifocal contact lenses are easy to fit<sup>5</sup>

Visit [myalcon.com](http://myalcon.com) to learn more.

\*AIR OPTIX® AQUA Multifocal (lotrafilcon B) contact lenses: Dk/t = 138 @ -3.00D. \*\*Based on subjective ratings of intermediate and distance vision, and vision for daytime driving, night driving, and TV viewing. †In emerging presbyopes, among those with a preference. ††Among those with a preference. ^Trademarks are the property of their respective owners.

**Important information for AIR OPTIX® AQUA Multifocal (lotrafilcon B) contact lenses:** For daily wear or extended wear up to 6 nights for near/far-sightedness and/or presbyopia. Risk of serious eye problems (i.e. corneal ulcer) is greater for extended wear. In rare cases, loss of vision may result. Side effects like discomfort, mild burning or stinging may occur.

**References:** 1. Based on third-party industry report, Alcon data on file, Jan 2010-Sep 2011. 2. Woods J, Woods C, Fonn D. Early symptomatic presbyopes—What correction modality works best? *Eye Contact Lens*. 2009;35(5):221-226. 3. Rappon J. Center-near multifocal innovation: optical and material enhancements lead to more satisfied presbyopic patients. *Optom Vis Science*. 2009;86:E-abstract 095557. 4. In a randomized, subject-masked clinical study at 20 sites with 252 patients; significance demonstrated at the 0.05 level; Alcon data on file, 2009. 5. Rappon J, Bergenske P. AIR OPTIX® AQUA Multifocal contact lenses in practice. *Contact Lens Spectrum*. 2010;25(3):S7-S9.

See product instructions for complete wear, care, and safety information.

**Alcon**

© 2012 Novartis 2/12 AOM12002JAD

**Rx only**



# An O.D.'s View on the Latest Monofocal IOLs

Here's an overview of the features optometrists should consider when discussing single-vision cataract surgery with their patients. **By Jim Owen, O.D., M.B.A.**

**W**hat if developers from a surgical device company actually asked an optometrist to design his or her ideal intraocular lens (IOL)? No, I'm not talking about one of those "Ph.D./O.D., optics guru-type" optometrists. I'm talking a real optometrist—one who has to fix broken toilets, fight with VSP, fit contacts, coach little league and refer patients for cataract surgery.

If given this opportunity, I'd be willing to bet that a majority of optometrists would be interested in designing a "premium monofocal IOL." Although we have been thoroughly saturated with information about the advantages of multifocal and accommodating IOLs during the last decade, they simply aren't appropriate for every individual.

Many patients, for example, are turned away by the potential for significant night glare or reduced contrast sensitivity. And let's face it, in daily practice, most O.D.s see significantly fewer patients with multifocal/accommodating IOLs than single-vision lenses, anyway.

During the last five years, a variety of advanced monofocal IOLs have become available in the U.S. Many of these lenses have been designed to reduce the incidence of

common postoperative problems, such as inflammation, posterior capsular opacification (PCO) and spherical aberration (SA). This article provides a review of the features that O.D.s should be most interested in when counseling a patient on monofocal cataract surgery.

## What O.D.s Want

It's no big secret—when it comes to cataract procedures, eye surgeons chiefly are concerned about the insertion technique, incision size, and how the IOL will sit in the capsular bag. While those surgery-related considerations may be somewhat relevant to a comanagement specialist, most O.D.s likely have a markedly different list of associated concerns.

Without question, optometrists chiefly are interested in the postoperative outcome and care of cataract surgery patients. More specifically, we want enhanced lens biocompatibility, improved optics and excellent postoperative safety.

## Enhanced Biocompatibility

As an optometrist, the first feature I'd want in an IOL is biocompatibility. In short, I want the patient's eye to "play nice" with this new piece of plastic.

For our purposes, biocompatibility can be assessed by measurements of uveal compatibility (which relates to inflammation within the eye) and capsular bag compatibility (which relates to PCO). It is important to note that these lens aspects are inversely proportional.

Typically, hydrophilic lenses exhibit greater uveal compatibility than hydrophobic lenses. Unfortunately, however, hydrophilic lenses have been shown to have a higher PCO rate than their hydrophobic counterparts.<sup>1</sup> Recent studies of newer hydrophobic acrylic IOLs have shown that they do not create significantly more inflammation than hydrophilic lenses, even in eyes at an increased risk (e.g., patients with pre-existing uveitis).<sup>2</sup> Therefore, more surgeons are now leaning toward the implantation of hydrophobic acrylic lenses, which have very low rates of inflammation and PCO.

Today, we also are witnessing improvements in the biocompatibility of the lens capsule. Accordingly, PCO rates continue to decline as IOL designs and materials improve.

There are several ways in which surgeons can help reduce PCO in single-vision cataract surgery patients:

- **Lens material.** In one recent study of rabbit eyes, Bausch + Lomb's enVista IOL exhibited a trend toward lower PCO rates.<sup>3</sup> The enVista lens, which recently received FDA approval in June 2012, is made of hydrophobic acrylic material with a 4% water content. It is important to note that this lens demonstrates both reduced inflammation levels and lower PCO rates—effectively combining the typical benefits of both hydrophilic and hydrophobic lens materials.<sup>3</sup>

- **Lens design.** In a 2012 study published in the *Journal of Cataract and Refractive Surgery*, researchers at the John A. Moran Eye Center in Salt Lake City evaluated a modified, one-piece, hydrophilic acrylic monofocal IOL (Zephyr, Anew Optics) that incorporated haptic perforations between the peripheral rings.<sup>4</sup> The researchers determined that the IOL design produced low amounts of capsular bag opacification.<sup>4</sup> They hypothesized that an open capsular bag enhances endocapsular inflow of aqueous—thus reducing PCO.<sup>4</sup>

Further, it appears that an IOL's edge design has a direct impact on the amount of postoperative PCO. Many studies have shown that a square-edge or sharp-edge design yields a reduction in PCO.<sup>5</sup> A mathematical model indicated that a square-edge IOL exerts 60% to 70% more pressure on the posterior capsule at the optic edge than a round-edge IOL.<sup>5</sup> Also, it appears that sharp edges provide a physical barrier to lens epithelial cells as they migrate within the capsular bag.

- **Surgical improvements.** One additional way to marginalize the impact of PCO is via improvement of the surgical procedure itself. A consistent, uniform overlap of the anterior capsule and the IOL edge prevents epithelial cells from

#### O.D.s Want an IOL to:

- Be biocompatible with the eye.
- Deliver the correct power and yield optimal vision.
- Provide long-term safety for the retina.

migrating beyond the edge of the lens. Femtosecond lasers used in cataract surgery create a more circular capsulorhexis, which could create a regular seal at the IOL edge and potentially reduce PCO rates. But, because femtosecond cataract surgery in the United States still is a relatively new procedure, published study data is somewhat limited.

In another recent study in the *Journal of Cataract and Refractive Surgery*, researchers documented less PCO in patients who underwent small-incision cataract surgery than in patients who had a micro-incision procedure.<sup>6</sup> The advantage of micro-incision cataract surgery is a tendency for less postoperative astigmatism. But, with increased use of femtosecond lasers and toric IOLs, postoperative astigmatism likely will become less of a concern during the next several years.

#### Improved Optics

Following enhanced biocompatibility, I want a monofocal IOL with excellent optics. Because we are considering only single-vision IOLs, the most important variables are how effectively the device addresses spherical and chromatic aberrations as well as postoperative astigmatism. Wavefront analysis has increased our knowledge of the eye's refractive properties. Specifically, spherical aberrations have been shown to reduce contrast sensitivity in both phakic and pseudophakic patients.<sup>7</sup>

- **Spherical aberration.** Cur-

rent technology can measure the amount of SA that is attributed to the cornea vs. the lens using corneal topography and wavefront aberrometry technology. This data can be used to determine the required amount and type of SA to correct for during the implantation of an aspheric IOL. In this instance, the surgeon's primary goal is to achieve an optimum SA in the given eye, which will translate to maximal contrast sensitivity.

Today, we know that the cornea has positive SA that does not vary with advancing age. On average, corneal SA has been reported to be +0.27 $\mu$ m in patients with pupil diameters of 6mm.<sup>6</sup> Different IOL manufacturers have designed monofocal lenses that neutralize a fixed amount of SA. For example, the Acrysof IQ Aspheric (Alcon) provides 0.20 $\mu$ m of SA; the Tecnis 1-Piece (Abbott Medical Optics) provides 0.27 $\mu$ m; and the SofPort AO Aspheric (Bausch + Lomb) provides 0.00 $\mu$ m.

It appears that, for the aforementioned IOLs to make a difference, the patient must exhibit a pupil diameter greater than 3mm.<sup>9</sup> By neutralizing SA, patients can achieve a better quality of vision—especially for night driving. It is worth noting that the Tecnis 1-Piece was tested specifically in night driving situations, and was shown to yield better vision function than traditional, non-aspheric IOLs.<sup>10</sup>

- **Astigmatism.** While it is nice to reduce the number of higher-order aberrations following cataract surgery, patients still require—and often demand—precise correction of lower-order aberrations to be happy with their postoperative visual outcome.

During the last 15 years, optometrists have come to realize that astigmatism correction

is fundamentally critical to the success of cataract surgery. To put this consideration in better perspective, imagine only being able to use spherical contact lenses in your patients. Many patients would report that their vision was completely inadequate.

Today's advanced monofocal toric IOLs can correct more than 4.00D of astigmatism in the corneal plane. Because the crystalline lens is removed during a cataract procedure, it is important to evaluate corneal astigmatism—not lenticular astigmatism.

Currently, Alcon's Acrysof IQ toric is one of the leading astigmatism-correcting IOL on the market. It is comprised of the same materials as other IOLs in the Acrysof portfolio, and has been shown to exhibit very little rotation within the capsular bag.<sup>11,12</sup> Therefore, as an optometrist recommending this IOL, I do not have to worry about lens rotation in the same way I might with a contact lens.

To determine the appropriateness of the Acrysof IQ toric, the surgeon uses an online lens calculator, which accounts for the incision site, size, keratometry in determining the proper power, and location of the toric IOL. For patients who have more than 0.75D of corneal astigmatism, I'll often recommend a toric IOL.

### Postoperative Safety

Ideally, an IOL will exhibit physiological properties that are at least the same as—if not better than—those offered by our natural lens. Our crystalline lens blocks most UV light within the spectrum of 300nm to 400nm. So, it's only natural for our patients to expect the same level of light protection from an IOL.

- **UV/blue-blocking.** There has

been considerable debate about whether the blockage of blue light is a benefit or a hindrance to our patients. Fifty-six reports on topics related to blue-blocking lenses, including sleep disturbance, visual outcomes, cataract surgery success, lens transmittance, sunlight exposure and macular disease, were published in peer-reviewed journals from 1962 to 2009.<sup>14</sup> Only one independently written article showed a deleterious impact on scotopic vision and circadian rhythms in patients who were fitted with blue-blocking IOLs.<sup>14</sup> However, none of the other studies documented any associated complications.<sup>14</sup>

The primary purpose of blue-blocking IOLs is to protect the macula from harmful light rays associated with macular degeneration. But, what's up for debate is how effective these lenses are in protecting the retina from blue-light exposure, and/or if completely blocking blue light is, in fact, truly beneficial to patients.<sup>15</sup>

Clinical science points to a correlation between photo-oxidative stress and macular degeneration; however, published epidemiological studies suggest mixed results.<sup>15</sup> Bottom line: The postulation that age-related macular degeneration can be attributed to UV light exposure is seductive, yet still unproven.

So, is there a definitive answer regarding the benefit of blue-blocking IOLs? Personally, I have worked with surgeons who implant both blue-blocking IOLs and clear IOLs. My experience has been that patients who have macular degeneration appreciate the implantation of IOLs that may be more protective of their retinas.

We are living in exciting times for cataract surgery. Several

currently available monofocal IOLs easily meet and exceed our patients' visual and physiological needs. Discussing appropriate single-vision lens options with your cataract patients is an important task, and should be part of your preoperative consultation. ■

*Dr. Owen is a graduate of the Illinois College of Optometry and has a master's degree in Business Administration from San Diego State University. He is the optometric director of Encinitas Optometry in Encinitas, Calif. and Vice President of Business Development for nJoy Vision.*

1. Saeed MU, Jafree AJ, Saeed MS, et al. Intraocular lens and capsule opacification with hydrophilic and hydrophobic acrylic materials. *Semin Ophthalmol.* 2012 Jan-Mar;27(1-2):15-8.
2. Tognetto D, Toto L, Minutola D, et al. Hydrophobic acrylic versus heparin surface-modified polymethylmethacrylate intraocular lens: a biocompatibility study. *Graefes Arch Clin Exp Ophthalmol.* 2003 Aug;241(8):625-30.
3. Ollerton A, Werner L, Fuller SR, et al. Evaluation of a new single-piece 4% water content hydrophobic acrylic intraocular lens in the rabbit model. *J Cataract Refract Surg.* 2012 Oct;38(10):1827-32.
4. Leishman L, Werner L, Bodnar Z, et al. Prevention of capsular bag opacification with a modified hydrophilic acrylic disk-shaped intraocular lens. *J Cataract Refract Surg.* 2012 Sep;38(9):1664-70.
5. Boyce JF, Bhermi GS, Spalton DJ, El-Osta AR. Mathematical modeling of the forces between an intraocular lens and the capsule. *J Cataract Refract Surg.* 2002 Oct;28(10):1853-9.
6. Gangwani V, Hirschnall N, Koshy J, et al. Posterior capsule opacification and capsular bag performance of a microincision intraocular lens. *J Cataract Refract Surg.* 2011 Nov;37(11):1988-92.
7. Piers PA, Manzanera S, Prieto PM, Gorceix N, Artal P. Use of adaptive optics to determine the optimal ocular spherical aberration. *J Cataract Refract Surg.* 2007;33(10):1721-6.
8. Beiko G. Measurement of the wavefront aberrations using the Oculus Easygraph Topographic System. Presented at ASCRS Annual Meeting, San Diego: May 2004.
9. Schmidinger G, Menapace R, Pieh S. Intraindividual comparison of color contrast sensitivity in patients with clear and blue-light-filtering intraocular lenses. *J Cataract Refract Surg.* 2008 May;34(5):769-73.
10. Tecnis foldable posterior chamber intraocular lens. Package insert. Abbott Medical Optics, Inc.
11. Zuberbuhler B, Signer T, Gale R, Haefliger E. Rotational stability of the AcrySof SA60TT toric intraocular lenses: a cohort study. *BMC Ophthalmol.* 2008 May 6;8:8.
12. Ferreira TB, Almeida A. Comparison of the visual outcomes and OPD-scan results of AMO Tecnis toric and Alcon Acrysof IQ toric intraocular lenses. *J Refract Surg.* 2012 Aug;28(8):551-5.
13. Qiu X, Kumbalasisiri T, Carlson SM, et al. Induction of photosensitivity by heterologous expression of melanopsin. *Nature* 2005;433:745-9.
14. Henderson BA, Grimes KJ. Blue-blocking IOLs: a complete review of the literature. *Surv Ophthalmol.* 2010 May-Jun;55(3):284-9.
15. Mainster MA, Turner PL. Blue-blocking IOLs decrease photoreception without providing significant photoprotection. *Surv Ophthalmol.* 2010 May-Jun;55(3):272-89.

# Monthly Multifocal Pearl



## The Benefits of the AIR OPTIX® AQUA Multifocal Contact Lens Design

By David L. Kading, OD, and Mile Brujic, OD

When it comes to presbyopic patients, many of us roll our proverbial eyes when they ask about contact lenses. Our minds start racing as to the options that might be suitable for these patients who work on computers all day, but spend their weekends biking or hiking.

Historically, our options have been relatively limited due to relatively poor success rates with multifocal contact lens designs. Because of this, many practitioners tried everything they could to avoid fitting multifocals. Fortunately, those days are gone for most of our presbyopic patients! With improvements in current multifocal contact lens designs, we can confidently look to these lenses to provide our patients with vision from near to far.

### FIRST AND FOREMOST, VISION & COMFORT

Some presbyopes may suffer from temporary conditions such as ocular dryness and seasonal allergies. First, ensure that these conditions are addressed and there is no underlying clinical condition that would interfere with contact lens wear.

Choosing the right lens material is very important. We prefer silicone hydrogel lenses for their high oxygen permeability and low lipid-depositing surface. The AIR OPTIX® AQUA Multifocal contact lens provides both of these benefits, with a Dk of 110 and a proprietary plasma surface treatment that resists lipid deposition and promotes comfortable lens wear. They're specifically designed to work in unison with a patient's eyes to provide clear vision with an uninterrupted range of focus, near through far. We find that many patients can wear the lens for most, if not all, of their waking hours.

### EASE OF FIT: A CRITICAL COMPONENT

With all of our regular daily activities, having a simplified fitting method and streamlined approach that works is critical to today's multifocal lens fitting success. AIR OPTIX® AQUA Multifocal contact lenses feature a proven aspheric back surface design for optimal centration and fitting. One pre-market evaluation looked at 2,455 patients seen by 294 practitioners and revealed that practitioners required an average of just 2.4 visits per patient to get a successful fit with AIR OPTIX® AQUA Multifocal contact lenses.<sup>1</sup>

In a typical practice, most spherical and toric lens patients require an initial fitting and at least one follow-up visit. In this same survey, 95.1% of the practitioners agreed that AIR OPTIX® AQUA Multifocal contact lenses were easy to fit. In fact, 64% said they were as easy to fit as spherical lenses and 66% said they were as easy to fit as monovision lenses.<sup>1</sup> Note that the practitioners in this evaluation were brand new at fitting the design, so with practice and by following the fitting guide-

lines, many practitioners can reduce the number of lenses needed to get that successful fit. In fact, around 85% of clinicians experience first lens fit success with the AIR OPTIX® AQUA Multifocal contact lenses.<sup>2</sup> We have personally seen great success with the lens on initial application and at the follow-up visit.

### GIVE THEM WHAT THEY WANT

Patient satisfaction is also high on our list, and we strive to exceed patient expectations at every opportunity. In the past, many of us have been disappointed with the performance of multifocal contact lenses, but study results for both real-world vision quality and ease of fit with

AIR OPTIX® AQUA Multifocal contact lenses are exceptional. In a study by Woods, emerging presbyopes fit with AIR OPTIX® AQUA Multifocal contact lenses were more satisfied than patients fit with monovision for intermediate and distance vision, as well as re-focusing from distance to near. Furthermore, emerging presbyopes rated their vision better with AIR OPTIX® AQUA Multifocal contact lenses for real-world activities such as day and night driving and viewing television.<sup>3</sup>

### PRINCIPLES BY WHICH TO PRACTICE

The AIR OPTIX® AQUA Multifocal contact lens offers good visual acuity, a favorable comfort profile, ease of fit, high patient satisfaction and opportunities for practice success. It is a viable option for patients who desire a full range of vision, whether they are emerging into their presbyopic years and require low amounts of ADD or are more advanced presbyopes that require higher amounts of ADD. The greatest key that we can provide is to follow the fitting guidelines. We always find ourselves steering back to it because it has truly brought about better success.

*Dr. Kading is in practice in Seattle and is an adjunct faculty member at Pacific University. Dr. Brujic is a partner of Premier Vision Group, a four-location optometric practice in northwest Ohio.*

AIR OPTIX® AQUA Multifocal (lotrafilcon B) contact lenses: Dk/t = 138 @ -3.00D

1. Rappon J, Bergenske P. AIR OPTIX AQUA Multifocal contact lenses in practice. *Contact Lens Spectrum*. 2010;25(3):57-9.
2. In a randomized, subject-masked clinical study at 20 sites with 252 patients; significance demonstrated at the 0.05 level; Alcon data on file, 2009
3. Woods J, Woods CA, Fonn D. Early symptomatic presbyopes — What correction works best? *Eye Contact Lens*. 2009;35:221-226.

Important information for AIR OPTIX® AQUA Multifocal (lotrafilcon B) contact lenses: For daily wear or extended wear up to 6 nights for near/far-sightedness and/or presbyopia. Risk of serious eye problems (i.e., corneal ulcer) is greater for extended wear. In rare cases, loss of vision may result. Side effects like discomfort, mild burning or stinging may occur.

See product instructions for complete wear, care, and safety information.



### DETAILS AT A GLANCE

**AIR OPTIX® AQUA Multifocal contact lenses, with Precision Profile Design, successfully fit a wide range of presbyopic patients. With three ADD ranges for different stages of presbyopia, they are designed to transition patients smoothly for longer retention.**

#### Emerging Presbyopes

LO (spectacle add up to +1.25D)

#### Established Presbyopes

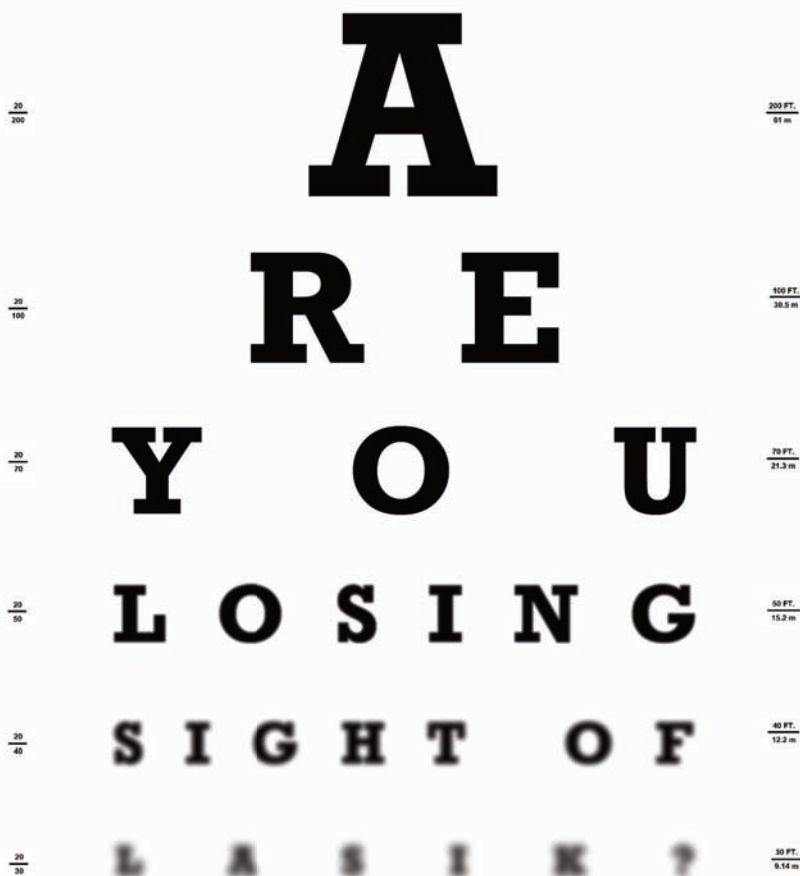MED (spectacle add +1.50D to +2.00D)

HI (spectacle add +2.25D to +2.50D)

Sponsored by

**Alcon**

## 18<sup>TH</sup> ANNUAL REFRACTIVE SURGERY REPORT



As a flat-lining economy struggles to rebound, O.D.s give LASIK mixed reviews as a means to boost the bottom line.

**By Jane Cole, Contributing Editor**

Soon after its FDA approval in 1998, LASIK became the most popular surgery among patients looking for a permanent means of correcting refractive error—easily eclipsing PRK as the procedure of choice. After the heady days of the initial boom, the LASIK market went bust. But, with the initial pent-up demand satisfied and a downturn in the economy in recent years, is LASIK still prominent in the hearts and minds of eye care practitioners, and their patients?

Here, your colleagues—some in

private optometric practice, others in comanagement settings—offer their insights on current LASIK trends, comanagement pointers and how to best help your patients set expectations for surgical outcomes.

### **LASIK: Trends and Numbers**

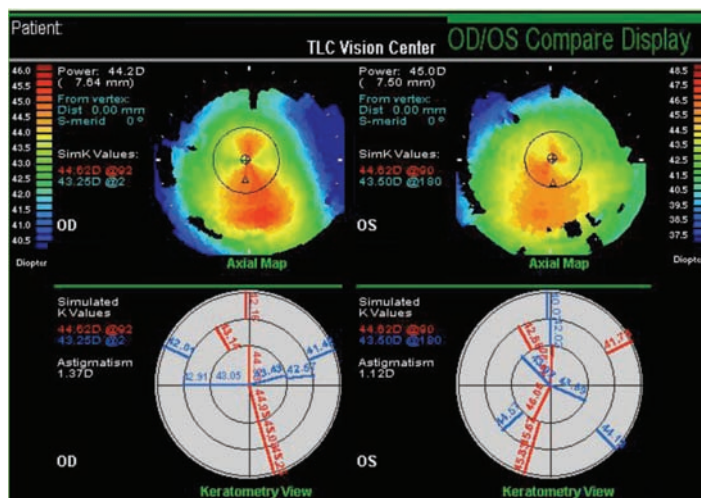
About five years ago, Scott Hauswirth, O.D., saw a decrease in both LASIK and PRK at his Minnesota Eye Consultants practice, which has 10 offices, including five located within the Twin Cities. “Patient interest in laser surgery is

still there—the means to justify the expense sometimes is not,” he says. And while he says both refractive procedures have been relatively flat in recent years, he’s noticed a shift towards PRK among those who choose laser surgery, which he attributes to “a more conservative mindset in surgical approach, where we are preserving more corneal integrity.”

James Thimons, O.D., founding partner of Ophthalmic Consultants of Connecticut, concurs. “Less than five years ago, LASIK was 95% or more the market in most

offices,” Dr. Thimons says. Today, almost 25% to 30% of his patients undergo PRK because it provides a safer and more predictable outcome, he says.

At TLC Laser Eye Center in St. Louis, the volume of LASIK surgery has remained steady, according to clinical director Eric Polk, O.D. One change, however: Dr. Polk is noticing an increasing trend of younger patients taking the plunge. “Patients who are in their late 20s and mid 30s are more interested” these days, Dr. Polk says. “These patients are aware that they have other choices besides glasses and contact lenses and are more willing to embrace new technology.”



**Forme fruste keratoconus need not contraindicate LASIK, if the patient is carefully screened and the condition is accounted for in the surgical approach.** Image courtesy of James Thimons, O.D.

Dr. Thimons sees this as well. “The average age of patients undergoing LASIK has decreased noticeably over the last several years. We now routinely are seeing patients five to 10 years younger than when we first began LASIK,” he says. Dr. Thimons, who esti-

mates he and his surgical partners have comanaged 60,000 LASIK patients over the last 16 years, has also noticed another trend: more women are having LASIK surgery today. A decade ago, the vast majority of patients being treated at his practice were men. But now, Dr. Thimons says the split of men vs. women is at least 50:50.

While LASIK has remained steady for some practices, other O.D.s have not had

the same experience. In 1996, Randall Fuerst, O.D., opened his first laser surgery center in Sacramento, Calif. As the business grew, he and a group of investing doctors expanded to 10 locations throughout California and Reno. Business continued to grow until the tech bubble burst in 2000, then his practice weathered the economic downturn and resumed growth until 2008. But the stock market crash that September, coupled with a pricey investment in a laser that was later recalled by the FDA, hit Dr. Fuerst’s business hard; ultimately, it could not withstand the financial loss.

Today, Dr. Fuerst is a partner in a multi-location practice in the Sacramento suburbs. Having ridden the highs and lows, he does not believe LASIK currently offers much to boost a practice’s bottom line. “LASIK in this economy continues to struggle,” he says. While it remains a revenue stream, he believes that it won’t account for more than a few patients per month.

## Price Wars: The Unkindest Cut

When competition among refractive surgeons heated up, many turned to price cutting—sending the entire market into a downward spiral. Those who remained above the fray are better positioned today.

Dr. Thimons says that, because his office is based on a comanagement model, they do no external marketing, so the cost per patient is extremely low. While many practices chose to lower their fees to attract volume during the lean years, Dr. Thimons says his practice chose a different option. “We maintained fees, but made a commitment to clinical excellence through advances in technology and patient care,” he says. As a result, “the comanagement network and word-of-mouth referrals from satisfied patients have allowed us to stay very competitive in a challenging market.”

Conversely, Dr. Thimons says many of his competitors who offered low prices for LASIK fell by the wayside and couldn’t stay in the market when patient volume diminished. “They wound up with financial problems because they offered lower prices, and when volume went away they could not sustain the model,” he says.

Dr. Thimons also cites advances in LASIK surgery that have improved patient outcomes and significantly broadened the patient base, including the femtosecond laser and iris registration, which improves outcomes in astigmatic patients. To keep current with technology requires continual investment in capital equipment—and that can’t be sustained by a low-price business model.

Still, in the past six to eight months, Dr. Fuerst says he has seen a slight increase in patient interest. "We learned in LASIK to follow the consumer confidence data. If consumer confidence rose, almost invariably LASIK volume rose. Conversely, if it dropped, LASIK volume dropped. In 2009, consumer confidence fell to all-time lows," he says." Recently, consumer confidence levels have been trending upward, he notes.

Although the economy can adversely influence those considering LASIK, motivated patients "will have the surgery done regardless of what the state of the economy is at that time," Dr. Polk says. "These patients are willing to finance the cost of their surgery and pay for it in the next few years."

### To Refer Or Not To Refer

With LASIK in the doldrums, are optometrists still actively discussing it with patients and referring for a surgical consult?

Richard Mangan, O.D., Center Director of Whitewater Eye Centers in Indiana and Ohio, says that, generally, out of all doctors who refer to his practice, just 10% are proactive in discussing refractive surgery with their patients. "While most may have brochures in their waiting rooms promoting it, usually it takes the patient to speak up and express interest. With that said, most optometrists today are more accepting of referring out for LVC than maybe 10 years ago," he says.

Dr. Polk advises his practice's doctors not to wait for the patient to ask about refractive surgery.

Interested patients, he believes, will have the surgery with or without the involvement of their optometrist. Some don't ask their O.D. about LASIK because they believe the doctor does not want them to have surgery, he says. "These patients will do their own research on LASIK and may choose a provider they discovered on the Internet or heard about in an advertisement." Dr. Polk believes the O.D. should offer surgery as an option and let the patient know that he or she can be comanaged at the optometry office. The optometrist benefits by keeping the patient in his or her office, instead of losing the individual to the ophthalmologist or laser center, he says. Secondly, it also allows the optometrist to recommend a known and trusted surgeon, he adds.

# DIGITAL REFRACTOR

*By: Ezer*

Patients complaining about waiting time?  
The **EDR-5200 Digital Refractor** allows you cut time between patients!

View Our Site

**Benefits of the Digital Refractor**

- Quick and Accurate Results
- Happy Patients
- Compact and Automated Refractor
- Combining labor & equipment increases efficiency
- Examine patients from the comfort of your chair

Distributed By: US OPTHALMIC

Toll Free: 888-334-4640 - [www.usophthalmic.com](http://www.usophthalmic.com) - [info@usophthalmic.com](mailto:info@usophthalmic.com)

Despite Dr. Fuerst's experience, he still offers LASIK as a side-by-side option along with glasses and contact lenses. "I believe that I provide better patient care if I present all viable options to patients for their visual well being."

Several of his partners no longer mention LASIK, instead waiting for the patient to inquire. "The rationale is that the marketplace is substantially different than it was in 1996-2000, when we began partnering with ophthalmologists in providing LASIK," he explains. "We have much better contact lens options now—the polymers, surface coatings, dry eye treatments and multifocal contact lens designs often are better options than monovision LASIK or bilateral distance LASIK with reading

glasses." The case for LASIK is now less compelling in the face of better corrective lens options, many O.D.s believe.

## Optometrists' Role in Comanagement

Despite the ups and downs of the LASIK market, optometrists still play an integral role in comanagement. For Dr. Mangan, this includes these key steps:

- **Refractive consultation.** This complete exam covers all necessary testing to design a treatment plan for laser vision correction—including topography, wavefront analysis, ocular surface assessment and other presurgical testing. "If a patient is a candidate and has realistic expectations, I design a treatment plan, review

the risks, benefits and alternatives, and then hand the patient off for scheduling of the procedure," Dr. Mangan says.

- **Postoperative care.** The refractive surgeon reviews the clinical findings prior to surgery and will hold a meet-and-greet the day of the procedure to review any last-minute questions and provide reassurance. Dr. Mangan will then see the patient for their one-day postoperative visit. Assuming a normal outcome, the patient is then released to their optometrist for ongoing follow-up.

The process is essentially the same for patients who self-refer, although Dr. Mangan's practice recommends a free screening first

*Continued on page 86*

## Comanagement 101

Carefully setting patient expectations is a key part of comanagement, of course.

Dr. Fuerst begins by letting the patient know he will do everything in his power to take good care of his or her vision and eye health "for many years to come," not just during a lone surgical procedure. "From this long-term perspective, I am more closely aligned with the patient's interests." The high cost of acquiring an excimer *and* a femtosecond laser, plus their maintenance costs and expenses for staffing and marketing "can create enormous pressure to continually bring patients in to 'feed the laser,'" he says.

Now, no longer working in that environment, Dr. Fuerst says he can counsel a patient as to what their expectations can and should be. "I do not mind telling patients who have realistic expectations for distance and near vision that they will be delighted with LASIK. If we are discussing monovision with a patient who is on the computer eight to 10 hours per day, I discuss and/or demonstrate what this means via the use of monovision contact lenses. Finally, having comanaged more than 2,500 patients in the past 17 years, I can speak with knowledge and understanding as to how LASIK can impact the patient's world."

At Dr. Mangan's practice, patients first fill out a questionnaire and watch a video about LASIK. These educational tools give the patient an opportunity to write down any questions that they may have. "The most important thing, however, is simply the dialogue between patient and doctor," Dr. Mangan says. "It doesn't take very long for an astute clinician to determine whether a patient has realistic expectations or not. I have on more than one occasion said to a patient: "If you need a 100% guarantee that you will be free from glasses after surgery, you should not have the surgery. I prefer to under-promise and over-deliver."

Dr. Polk stresses the importance of personalizing the patient expectations. The presbyope needs a different consent than the patient who's under age 40, and the patient who has a high prescription needs a different consent than one with a low prescription, he says. Presbyopes should be given the option of monovision or partial monovision, he adds. "However, I tell patients that presbyopia is a dynamic process—even if we get it right, they will eventually need readers for some things as they age. Many patients do not realize this and have an expectation that their monovision will be perfect for all distances for the rest of their lives."

Patients with a low to moderate prescription can expect a good refractive outcome.

Those with high prescriptions, especially high hyperopes, are at greater risk for a residual Rx after surgery and may need an enhancement. Dr. Polk has stopped recommending surgery to hyperopes who are above +3.00D (particularly if they're also presbyopic), instead advocating refractive lens exchange with a multifocal or accommodating IOL. "I also do not recommend LASIK or PRK for any patient with an Rx above -9.00D," he says. "The phakic intraocular lenses are a better option for the pre-presbyopic highly myopic patient."



Winner of Popular Science  
Best of What's New Award



# YOUR SOLUTION

for making lens wear easier  
on her eyes.<sup>1</sup>

Inspired by the biology of your eyes<sup>®</sup>, Biotrue<sup>®</sup> is the only multi-purpose solution that brings together three bio-inspired innovations:

- matches the pH of healthy tears
- utilizes a lubricant found in the eyes
- keeps key beneficial tear proteins active

**Recommend Biotrue – and help make wearing contact lenses easier on your patients' eyes.**

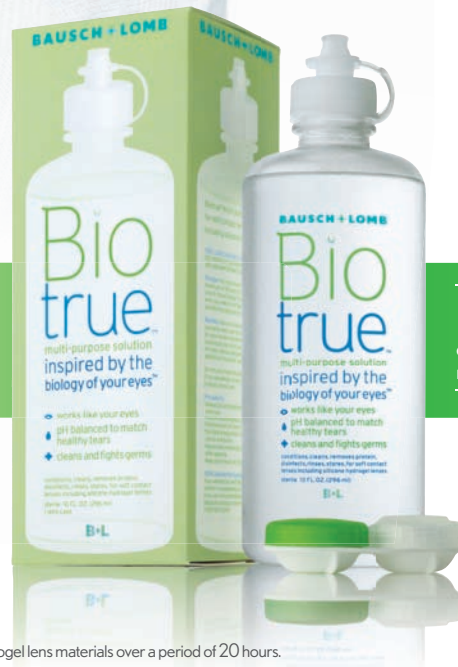[biotrue.com](http://biotrue.com)

<sup>1</sup>Based on patient satisfaction study.

<sup>2</sup>Results of a U.S. in vitro study performed to evaluate the release of wetting agents from various silicone hydrogel lens materials over a period of 20 hours.

<sup>3</sup>Based on a U.S. survey of 130 patients who used both Biotrue and OPTI-FREE RepleniSH.

© 2012 Bausch & Lomb Incorporated. ®/™ are trademarks of Bausch & Lomb Incorporated or its affiliates. PNS06544 HL5183



UP TO  
**20**  
hours of  
moisture in  
every drop<sup>2</sup>

Preferred 3:1  
over the leading  
multi-purpose solution<sup>3</sup>

**BAUSCH + LOMB**  
See better. Live better.



# Unlocking Leber's Hereditary Optic Neuropathy

Promising new research offers a glimmer of hope for an otherwise intractable disease.

By Jerome Sherman, O.D., and Jinyoung Choe, B.A.

**A** century and a half ago, ophthalmologist Theodor Leber discovered an acute onset optic neuropathy that typically affects males in their 20s and invariably leads to bilateral optic atrophy and irreversible blindness.

This disorder, now known as Leber's hereditary optic neuropathy (LHON), usually occurs in young men aged 15 to 30 years and less commonly in women of the same age.<sup>1</sup> It presents as an acute or subacute disease resulting in characteristic sudden, painless, sequential, bilateral loss of central vision, and ultimately in the formation of centrocecal scotomas.

During the acute phase, the optic disc appears swollen and peripapillary retinal telangiectasias (corkscrew-appearing vessels) are typical. However, there is no disc leakage observed on fluorescein angiography (*figure 1*).

In the vast majority of cases, vision loss is sequential—involvement of the second eye occurs weeks to months after the first. Visual deterioration is extreme, with acuity often plummeting to worse than 20/200

in each eye; vision reduced to bare light perception is common. Reports of LHON have usually described its course as a rapid visual deterioration (with the exception of one study that reported cases of slow and insidious visual loss).<sup>5</sup>

In addition to LHON, Dr. Leber also described a congenital retinal disorder similar to retinitis pigmentosa but present at birth. This outer retinal disorder, termed Leber's congenital amaurosis (LCA), affects the photoreceptors and RPE but has no relationship to the optic nerve disorder LHON.

Electroretinography (ERG), the best overall objective test of the retinal function of photoreceptors, is often extinguished or dramatically reduced in LCA. The outer retina (containing the photoreceptors) is normal in patients with LHON; hence, the ERG will be normal. Because LHON is an optic nerve disorder, the visual evoked potential (VEP) will be abnormal. Of interest, the VEP can demonstrate transmission delays even prior to vision loss in LHON.

**Release Date:** November 2012

**Expiration Date:** November 1, 2015

**Goal Statement:** Leber's hereditary optic neuropathy is an uncommon presentation in the optometrist's office, but its quickly advancing effects will devastate a patient's vision. While the condition was identified more than a century ago, there are no effective or approved treatments for it. However, at least one promising treatment is in the offing. This course reviews the characteristic ocular signs of Leber's hereditary optic neuropathy and its typical progression, and also offers some new information on the potential

treatment for this devastating condition.

**Faculty/Editorial Board:** Jerome Sherman, O.D., and Jinyoung Choe, B.A.

**Credit Statement:** COPE approval for 2 hours of CE credit is pending for this course. Check with your local state licensing board to see if this counts toward your CE requirement for licensure.

**Joint-Sponsorship Statement:** This continuing education course is joint-sponsored by the Pennsylvania College of Optometry.

**Disclosure Statement:** Dr. Sherman is on the Speakers Bureau for Carl Zeiss Meditec. Ms. Choe has no relationships to disclose.

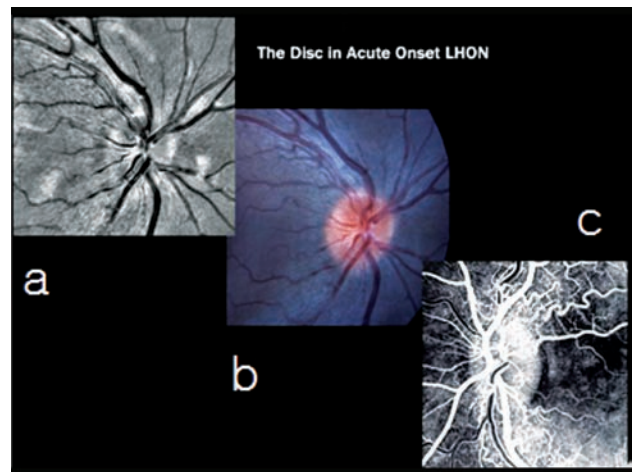
Another inherited optic neuropathy is Kjer's or autosomal dominant optic atrophy. It can be transmitted by either parent and can be present in every generation. It is now believed that Kjer's is a mitochondrial optic neuropathy with involvement of the OPA1 gene.<sup>6</sup> These patients have a slowly progressive bilateral loss of visual acuity, color vision and central visual fields.

### Current and Emerging Treatments

Although the disease was identified in 1871, there are no effective or approved treatments for LHON or other related mitochondrial optic neuropathies.<sup>7</sup> Attempts to treat LHON have been largely unsuccessful, but early identification of LHON and avoidance of trigger mechanisms—such as smoking and alcohol—are now stressed to those with the genetic predisposition.

Recently, a small open-label trial of an experimental therapeutic, EPI-743, which is being developed for life-threatening inherited respiratory chain diseases of the mitochondria, has demonstrated preliminary success in treating patients in the acute conversion phase of LHON.<sup>7</sup> EPI-743 arrested LHON progression and reversed vision loss in four out of five treated patients. Hopefully, the results of this pilot study will be validated through upcoming multicenter randomized controlled studies.

EPI-743 may be the first effective treatment for LHON—which has a well-known history of irreversible vision loss in patients (save for those cases with the 14484 mutation)—as well as other diseases with mitochondria-based pathophysiologic conditions. Edison Pharmaceuticals, the developer of the drug, announced in September 2012 that all subjects with



**1. The disc in acute onset LHON with red-free (a), standard color (b), and fluorescein angiographic (c) fundus images. Note the characteristic swollen optic disc and peripapillary retinal telangiectasias (corkscrew-appearing vessels).**

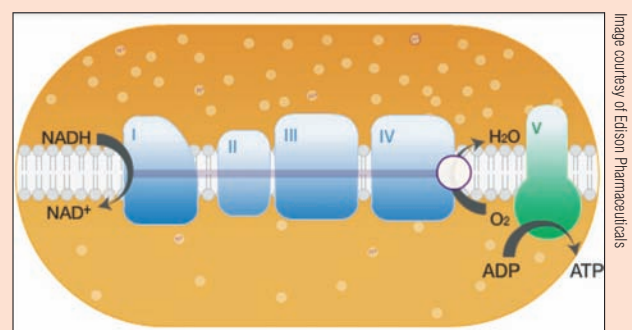
Leigh syndrome—a severe neurological disorder in children with mitochondrial inheritance and with no approved treatments—treated with EPI-743 exhibited reversal of disease progression.<sup>8</sup> This is remarkable because Leigh syndrome is considered to be 100% progressive and 100% fatal.

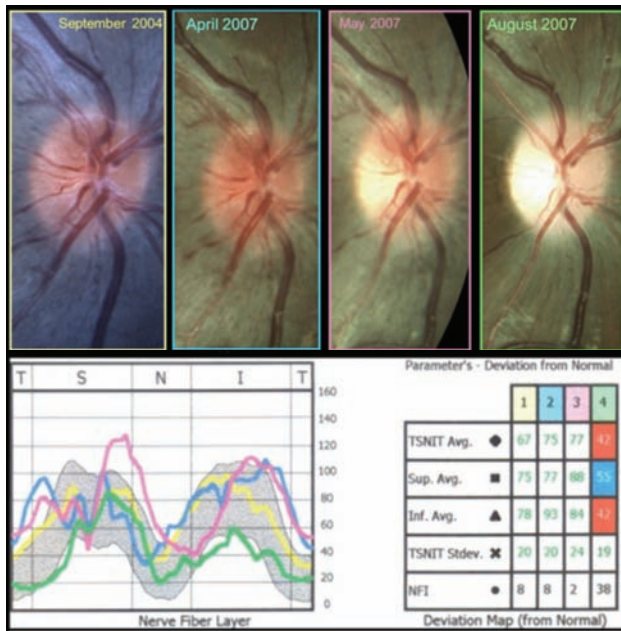
Gene therapy also is emerging as a possible, attractive option. A team at Bascom Palmer Eye Institute has reported the use of mitochondria-targeted adeno-associated virus (AAV)-based gene vector in experimental models of LHON.<sup>9</sup> These experiments suggest that this safe virus vector may act as a vehicle for the introduction of almost any mitochondrial gene into the adult organelle. The researchers have used this intervention

### Leber's Hereditary Optic Neuropathy: A Maternally-Transmitted Disorder

LHON has been demonstrated to be maternally transmitted and the result of a single point mutation occurring in mitochondrial DNA (mtDNA). More than 90% of cases are traced back to point mutations in mtDNA 11778 (G to A, or guanine to adenosine nucleotide base substitution at nucleotide position 11778), mt 3460 (G to A) or mt 14484 (A to G), while the remaining 10% of cases are mostly unknown.<sup>2</sup> These three mutations take place respectively in the ND4, ND1 and ND6 NADH dehydrogenase subunit genes of complex I, which affect oxidative phosphorylation.<sup>3</sup> A mutation at nucleotide position 14484 in mtDNA is the least devastating of the three and is associated with a 50% spontaneous remission rate.

Only females can pass these mitochondrial mutations on to their children because an embryo receives its mitochondria from the mother's egg cell, not the father's sperm cell at conception. (Mitochondria are found in the cytoplasm of the cell, and the sperm cytoplasm does not enter into the egg.) As such, although LHON can appear in each successive generation of a family and can affect both males and females, fathers do not contribute to its mitochondrial pattern of inheritance.<sup>4</sup> In other words, LHON follows a non-mendelian pattern of inheritance; it is not an autosomal recessive, autosomal dominant or X-linked transmitted disorder.





**2. Note that the VEP TSNIT (temporal, superior, nasal, inferior, temporal) RNFL first increased in thickness in April and May 2007, and then thinned dramatically in August 2007. (Note the color coding of the rectangles and the waveforms.)**

to restore functional ND4 levels in LHON; hopefully, more promising research advances are on the horizon.<sup>9</sup>

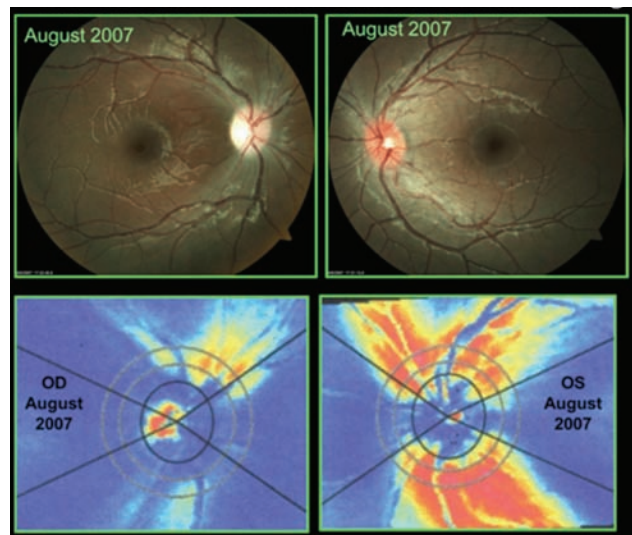
## Case Presentations

Because Leber's is a relatively uncommon presentation in the optometrist's office, and because diagnosis and treatment of LHON are experiencing revolutionary changes, let's take a closer look at this condition through three different clinical case studies.

### Case 1: Left Eye Follows Right

A 15-year-old Filipino male with an established family history of LHON mt 11778 was followed closely prior to and during the acute phase of LHON. Vision loss began in his right eye and was followed by similar changes in his left eye several months later. His progression to blindness was well documented with GDx scanning laser polarimetry (Carl Zeiss Meditec), Stratus OCT (Carl Zeiss Meditec), Humphrey automated perimetry (Carl Zeiss Meditec), visual evoked potentials and fundus photography.

Both OCT and scanning laser polarimetry have shown that retinal nerve fiber layer (RNFL) thickening can precede vision loss, and that it occurs in a specific temporal sequence typically starting in the inferior temporal quadrant.<sup>10</sup> Temporal pallor several months after the acute onset correlates with the attenuation of the



**3. Increased disc pallor (representing optic atrophy) as well as increased RNFL thickness is more evident in the right eye, which had converted first.**

RNFL in the papillo-macular bundle, which was well documented in the patient's right eye. At the same time, thickening of the remaining RNFL was well revealed with the GDx.

Several months after the RNFL thickened in the right eye—most likely as a result of both axoplasmic stasis and upregulation of mitochondria—it began thinning and resulted in optic atrophy.

Although the patient had no symptoms from age nine to 12 and had 20/20 best-corrected visual acuity (BCVA) in each eye during this period, both discs were not normal and displayed the characteristic findings of LHON carriers who are at risk of converting. Symptoms and VA reduction began in the right eye in May 2007 (at age 15). By August of that year, VA was reduced below 20/400 and serial fundus photos revealed progression to marked temporal pallor.

Advanced serial analysis, using the September 2004 GDx as a baseline, first revealed thickening and then thinning of the RNFL. Similar RNFL findings on OCT have been reported in other LHON patients.<sup>11</sup>

The patient's VA was 20/20 in September 2004, but the right disc revealed the characteristic peripapillary telangiectatic microangiopathy. In April 2007, slight worsening of the disc, and increased RNFL thickness on GDx, was documented at the time of conversion. By May 2007, we observed temporal disc pallor and the VA had dropped to 20/400 O.D. By August 2007, the entire disc appeared pale and BCVA was now reduced to counting fingers (*figure 2*).

The left disc and surrounding structures were nearly

normal back in September 2004, except for slight disc hyperemia and subtle relative opacity of the RNFL. During the April 2007 visit, the disc and surrounding retina appeared relatively unchanged. BCVA in the left eye at this time was 20/20. Perhaps there was a slight increase in the relative opacity of the RNFL in the left eye in May 2007. BCVA was still 20/20 O.S.

But by August 2007, progression of disc and changes in the surrounding retina were appreciable in the left eye. There was observable increase in disc hyperemia, increased thickness of the RNFL and the presence of some telangiectatic (corkscrew) vessels on and surrounding the optic disc in the left eye. BCVA had dropped to 20/40 O.S.

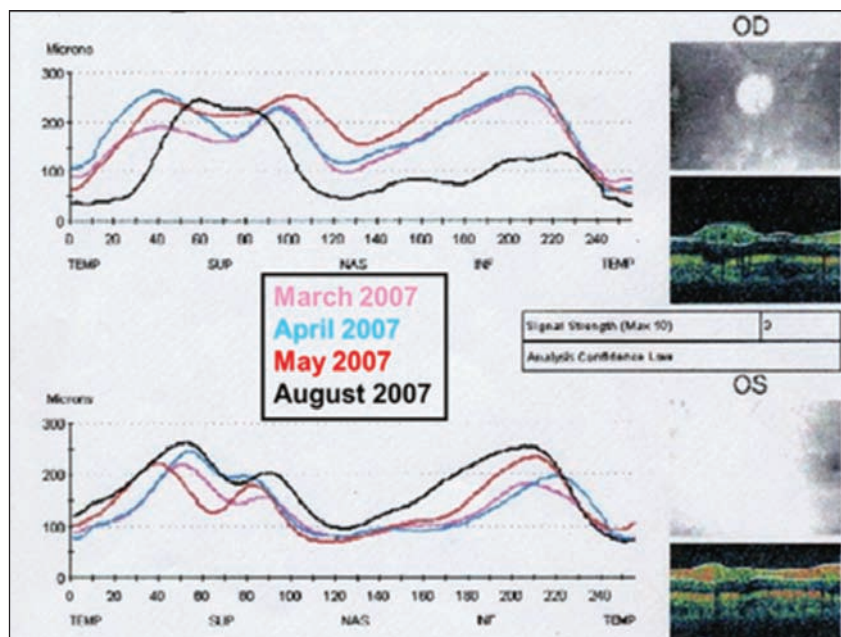
Likewise, GDx Advanced Serial Analysis did not reveal any major change in the left eye until August 2007. During this visit, GDx revealed marked increased thickness inferior temporally in the left eye. Meanwhile, VA had dropped to 20/40 O.S., and the disc and surrounding RNFL had visibly worsened.

Between September 2004 and April 2007, increased RNFL thickness was visualized in the right eye but not as marked in the left eye.

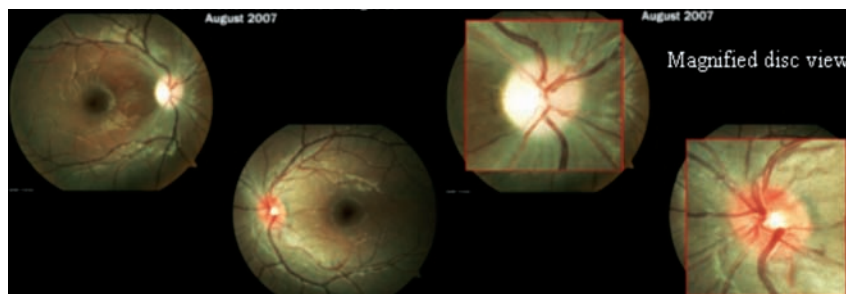
Since the right eye converted first, we expected that increased disc pallor (representing optic atrophy) would be more evident in the right eye from May 2007 to August 2007 (figure 3).

On the same day that the RNFL was attenuated in the right eye (as revealed on the August 2007 visit), the RNFL in the left eye was increased in thickness. The RNFL was markedly reduced inferiorly in the right eye but increased in the left eye (figures 4 and 5). Within the next year, both RNFLs were profoundly and equally reduced in thickness and both discs were equally pale.

By April 2007, there was an obvious central scotoma in the right eye. Most of the visual field was lost during the next five months. By the August 2007 visit, a central-cecal scotoma was documented in the left eye. The field loss was far more dramatic in the right eye during this period.



4. Note the comparison of the right eye on August 2007 (black curve) shown in the upper image and the left eye (black curve) on the same date shown in the lower image.



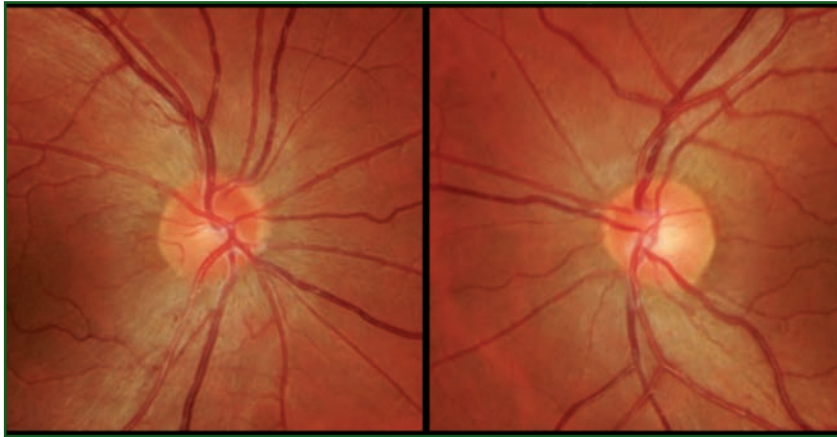
5. Disc hyperemia corresponds to increased RNFL thickness, as shown in the patient's left eye.

About a year later, the field was profoundly reduced and equal in each eye. Currently, the patient has visual acuity of counting fingers O.U.

### Case 2: A Trial Treatment

The mother of a 27-year-old white male called and reported that her son began experiencing blurred vision in his right eye several weeks earlier. The patient has a family history of optic atrophy, and genetic testing nearly two decades earlier revealed a mitochondrial mutation at 11778, confirming Leber's hereditary optic neuropathy.

We suspected acute or sub-acute conversion from a carrier state to affected state, so we evaluated the patient that evening. With a low myopic correction, BCVA was a slow 20/25- O.D. and 20/20 O.S. Pupils were normal with no relative afferent pupillary defect



**6. A careful comparison of the discs revealed subtle findings—disc hyperemia, relative opacity of the retinal nerve fiber layer, and mild telangiectatic (corkscrew) vessels—that were more marked in the right eye.**

(RAPD). (Of interest, the pupil is often spared in LHON due to the preservation of the melanopsin retinal ganglion cells.<sup>9</sup>) OCT fundus images revealed the characteristic signs of disc hyperemia and telangiectatic vessels (*figure 6*).

A Macular Integrity Assessment (MAIA, Ellex) central field was obtained in each eye. This device uses a near infrared scanning laser ophthalmoscope to provide high-resolution retinal images; it is designed to evaluate the patient's macula threshold, fixation stability and change over time. The MAIA monitors eye position 25 times each second and then adjusts the placement of each stimulus onto the intended location regardless of fixation errors.

For the patient's MAIA sensitivity map and threshold histogram O.D., sensitivity values depicted in green are normal, those in yellow are borderline and those in red are reduced significantly (*figure 7*). The patient's fixation was determined to be quite stable in the right eye. The pattern of sensitivity reduction corresponded to the papillo-macular bundle.

In the traditional 30-2 visual field, the defect is located primarily in the central superior field. In the MAIA field, the defect is projected

back onto the corresponding retina.

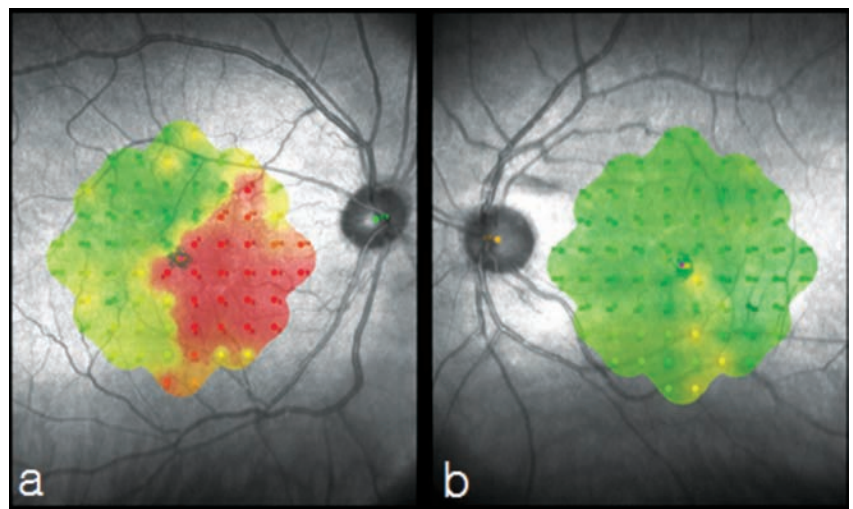
In the right eye as in the left eye, fixation was stable, and four points had a mildly reduced sensitivity to 23dB.

Virtually all patients with the LHON mt 11778 progress to profound vision loss within weeks to months following initial vision loss. The second eye becomes affected within just several months, and final VA is typically the same in each

eye. Visual fields are far better than VA to assess any change over time. When VA drops, many patients with various optic nerve and macula disorders change fixation to a more sensitive retinal location. With standard fields, the visual field loss "moves" when fixation is altered. Unlike standard fields, MAIA monitors eye position, corrects for changes in fixation (25 times per second) and tests the same points on any future MAIA visual field.

Although the BCVA was 20/25-O.D. and 20/20 O.S., the MAIA visual field (*figure 7*) demonstrates a dramatic difference in the central visual field sensitivity between the two eyes.

The ganglion cell complex, or GCC (which is composed of the RNFL, the ganglion cell layer and the inner plexiform layer), appeared normal and equal in each eye. Very minor differences between all GCC measurements suggest that the central field loss at this point is reversible because the ganglion cells and corresponding axons and dendrites are still intact.



**7. This MAIA pattern is equivalent to the standard 10-2 Humphrey Zeiss in which the stimuli are all 2° apart and the total field is 20° x 20°. Note the dramatic reduction in sensitivity of nearly half of the tested field, as portrayed by the red points in the right eye (a). In the left eye (b), most of the tested points have a normal threshold and are depicted in green, with a few borderline sensitivity values depicted in yellow.**

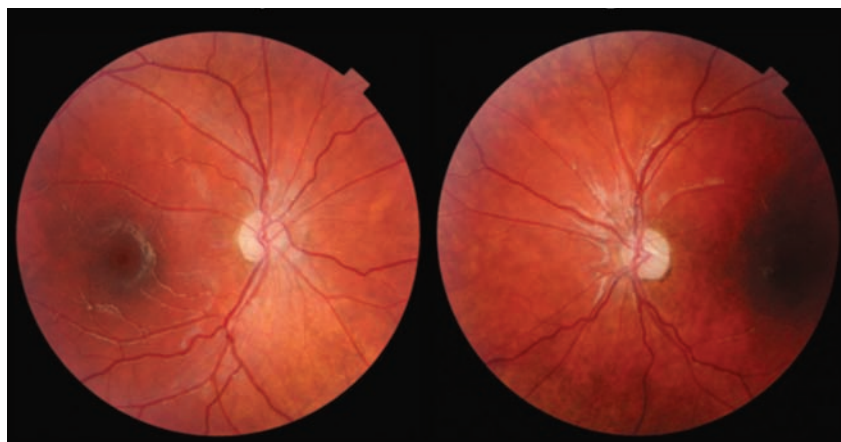
All the findings supported the diagnosis of acute-onset LHON. Accordingly, we recommended that the patient take the first plane the next morning to Los Angeles for possible treatment with Edison Pharmaceutical's new drug EPI-743. All the data, including the previous genetic confirmation of LHON mt 11778, was shared with the group at Doheny Eye Institute, USC Keck School of Medicine. Within a week, treatment was initiated once the FDA approval was obtained.<sup>7</sup> As mentioned previously, favorable results in four other patients with LHON will perhaps lead to an FDA clinical trial in the near future.

The MAIA was repeated 24 days after the initial visit (two weeks after the initiation of treatment). The sensitivity of many points decreased significantly in the right eye. But in the left eye, sensitivity of various points tested improved slightly, although none reached statistical significance. Take note that the drug has only been tested on a small number of people with LHON, so we have only limited information about how long the drug takes to work. The consensus among researchers involved with EPI-743 is that the drug does not demonstrate a significant effect until six to eight months after initiation of treatment.<sup>12</sup>

Because the patient in this case was treated very early in the course of the disease, improvement in visual field sensitivity is still possible because the ganglion cell complex has yet revealed no loss of cells.

### Case 3: Atypical, Early LHON

A 7-year-old hyperactive white male was evaluated because of possible reduction of VA and possible disc pallor. He was previously diagnosed with attention deficit hyperactivity disorder (ADHD), which likely explained the difficulty in



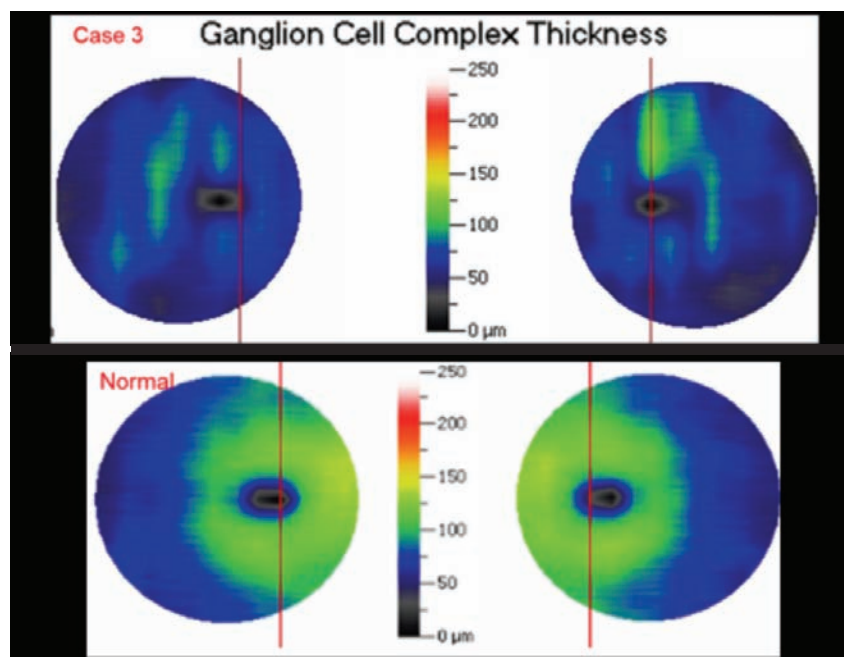
**8. Disc images of a 7-year-old reveal temporal pallor, although it is unclear whether this is physiologic or pathologic.**

examining the patient. A female resident who spent considerable time with him was able to correct his VA to 20/20 O.D. and O.S. Although ophthalmoscopy revealed temporal pallor, it was unclear whether this was physiologic or pathologic (*figure 8*). Digital tonometry revealed soft globes.

Optovue iWellness Exam revealed normal sections through the retina

(not shown) in the posterior pole but a profound reduction of the thickness of the GCC in both eyes (*figure 9*). Note the comparison to a normal patient above.

Diopsys VEPs were obtained under NOVA-DN conditions (*figure 10*). The amplitudes of the VEP under both high contrast and low contrast conditions were normal in both eyes. However, the latency was



**9. Optovue iWellness Exam shows a profound reduction of the thickness of the ganglion cell complex in both eyes (top). Note the comparison to a normal patient (bottom).**

abnormal under all conditions tested. The amplitudes are consistent with the normal VA, but the large latency increases clearly indicate a bilateral optic neuropathy. Automated visual fields were attempted but were not possible on either of two visits due to the boy's ADHD.

The dramatic reduction in ganglion cell complex and the VEP delays in both eyes confirm an optic nerve disorder. So what could the etiology of this optic neuropathy possibly be?

Because our 7-year-old appears to have pale discs without cupping and soft globes, glaucoma is effectively ruled out. But other non-glaucomatous optic neuropathies need to be considered, which can be done using the VITAMINES mnemonic (*below*).

MRIs were obtained, which were within normal limits. However, a detailed family history revealed an optic neuropathy, specifically LHON with a point mutation at mt 4360. Hence, our

VITAMINES mnemonic was helpful in guiding the differential diagnosis and workup.

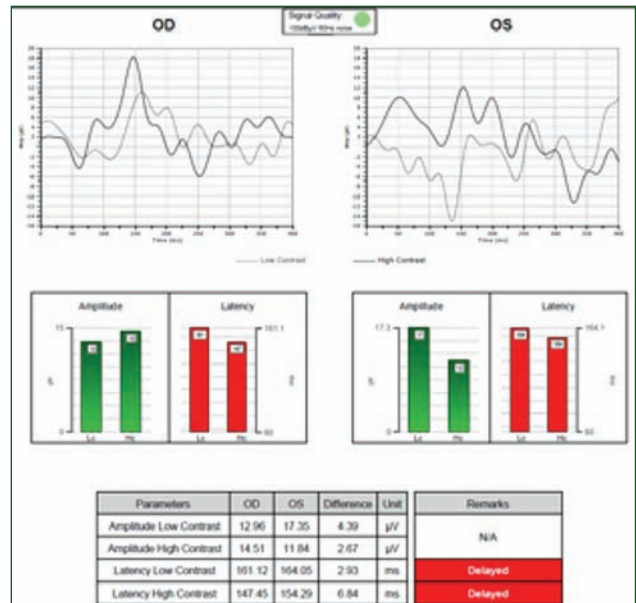Although LHON is considered to be an acute-onset disorder at an average age of 25, it can occur in the first decade of life with a subacute

presentation.<sup>10</sup> The entire family is in the process of being evaluated. A confirmed diagnosis of LHON is more important than ever because treatment may soon be available.

This was an unusual case in that the patient had normal VA but showed dramatic reduction in the ganglion cell complex and delayed VEPs. Currently, this patient (and his older brother and sister) are being followed very carefully for any change.

In summary, acute-onset LHON typically begins in one eye followed within several months by the other eye. Disc hyperemia and peripapillary telangiectasia correspond to an increased RNFL thickness, as revealed with fundus photography, GDx and OCT. As the first eye begins to experience RNFL loss and disc pallor, the second eye may begin the same sequence. Within a year or so after the initial acute presentation in one eye, both eyes appear very similar.

One goal in the treatment of LHON is to prevent the



**10. Visual evoked potential shows normal amplitudes in both eyes, yet the large latency increases clearly indicate a bilateral optic neuropathy.**

second eye from converting. For the first time in the 150 years since Dr. Leber reported this progressive optic neuropathy, an effective treatment to meet this goal may be on the horizon. It may be instituted at the time of initial vision loss in the first eye. If successful, perhaps the second eye can be protected from converting and a large difference between the two eyes will still exist a year or so following the initiation of treatment. ■

*Dr. Sherman is a distinguished teaching professor at State University of New York College of Optometry and the Schnurmacher Institute of Vision Research. He also practices at The Eye Institute and Laser Center, New York City, and is the current president of the Optometric Retina Society.*

*Ms. Choe graduated from University of California-Berkeley with a B.A. in Integrative Biology. She is now a pre-optometry student at SUNY College of Optometry and working for Dr. Sherman as a volunteer research assistant.*

- Gerstenblith AT and Rabinowitz MP. The Wills Eye Manual: Office and Emergency Room Diagnosis and Treatment of Eye Disease. Lippincott Williams & Wilkins. 2012 May.
- Achilli A, Iommarini L, Olivieri A, et al. Rare primary mitochondrial DNA mutations and probable synergistic variants in Leber's hereditary optic neuropathy. PLoS ONE. 2012 Aug; 7(8): e42242.
- Carelli V, Ross-Cisneros FN, Sadun AA. Mitochondrial dysfunction as a cause of optic neuropathies. Prog Retin Eye Res. 2004 Jan;23(1):53-89.
- National Library of Medicine. Genetics Home Reference: Leber Hereditary Optic Neuropathy. Updated Oct. 23, 2012. Available at: <http://ghr.nlm.nih.gov/condition/leber-hereditary-optic-neuropathy>. Accessed October 30, 2012.
- Sherman J, Kleiner L. Visual system dysfunction in Leber's hereditary optic neuropathy. Clin Neurosci. 1994; 2(2): 121-129.
- Alexander C, Votruba M, Pesch U, et al. OPA1, encoding a dynamin-related GTPase, is mutated in autosomal dominant optic atrophy linked to chromosome 3q28. Nat Genet. 2000 Oct;26(2):211-5.



7. Sadun AA, Chicani CF, Ross-Cisneros FN, et al. Effect of EPI-743 on the clinical course of the mitochondrial disease Leber hereditary optic neuropathy. *Arch Neurol* 2012 Mar; 69(3):331-338.

8. Edison Pharmaceuticals. Edison Pharmaceuticals announces positive results of EPI-743 phase 2A Leigh syndrome clinical trial [Press release]. Sept. 13, 2012. Available at: [http://edisonpharma.com/PressReleases/120913\\_Edison%20Pharmaceuticals%20Announces%20Positive%20Results%20of%20EPI-743%20Phase%202A%20Leigh%20Syndrome%20Clinical%20Trial.pdf](http://edisonpharma.com/PressReleases/120913_Edison%20Pharmaceuticals%20Announces%20Positive%20Results%20of%20EPI-743%20Phase%202A%20Leigh%20Syndrome%20Clinical%20Trial.pdf). Accessed October 30, 2012.

9. Yu H, Koilkonda RD, Chou TH, et al. Gene delivery to mitochondria by targeting modified adenoassociated virus suppresses Leber's hereditary optic neuropathy in a mouse model. *Proc Natl Acad Sci U S A*. 2012 May

15;109(20):E1238-47.

10. Barboni P, Savini G, Valentino ML, et al. Leber's hereditary optic neuropathy with childhood onset. *Invest Ophthalmol Vis Sci*. 2006 Dec;47(12):5303-9.

11. Barboni P, Carbonelli M, Savini G, et al. Natural history of Leber's hereditary optic neuropathy: longitudinal analysis of the retinal nerve fiber layer by optical coherence tomography. *Ophthalmology*. 2010 Mar;117(3):623-7.

12. Personal communication with Alfredo A. Sadun, M.D., Ph.D., and Guy Miller, M.D., Ph.D., of the Doheny Eye Institute, Department of Ophthalmology, USC-Keck School of Medicine, Los Angeles.

## OSC QUIZ

**Y**ou can obtain transcript-quality continuing education credit through the Optometric Study Center. Complete the test form (page 66), and return it with the \$35 fee to: Optometric CE, P.O. Box 488, Canal Street Station, New York, NY 10013. To be eligible, please return the card within one year of publication.

You can also access the test form and submit your answers and payment via credit card at *Review of Optometry* online, [www.revoptom.com](http://www.revoptom.com).

You must achieve a score of 70 or higher to receive credit. Allow eight to 10 weeks for processing. For each Optometric Study Center course you pass, you earn 2 hours of transcript-quality credit from Pennsylvania College of Optometry and double credit toward the AOA Optometric Recognition Award—Category 1.

Please check with your state licensing board to see if this approval counts toward your CE requirement for relicensure.

1. Leber's hereditary optic neuropathy (LHON) is transmitted through:

- a. An autosomal recessive trait.
- b. An autosomal dominant trait.
- c. An X-linked trait.
- d. A non-mendelian inheritance pattern.

2. Which Leber's mutation is associated with a 50% spontaneous remission rate?

- a. mt DNA11778.
- b. mt DNA 3450.
- c. mt DNA 14484.
- d. None, because Leber's always progresses to blindness.

3. What DON'T sperm cells contribute to the fertilized egg?

- a. Cytoplasm.
- b. Mitochondria.
- c. Nuclear DNA.
- d. Both cytoplasm and mitochondria.

4. LHON typically affects:

- a. Young males in their 20s.
- b. Young females in their 20s.
- c. Older males or females.
- d. Children under the age of 10.

5. The typical clinical presentation LHON is:

- a. Invisible to ophthalmoscopy.
- b. Described as peripapillary telangiectatic micro-angiopathy.
- c. Includes telangiectatic vessels in the macula in the far temporal periphery.
- d. Includes alterations at the level of photoreceptors and retinal pigment epithelium.

6. Leber's congenital amaurosis (LCA) and LHON:

- a. Are similar in their clinical presentations.
- b. Are vastly different in that LCA is an outer retinal disease whereas LHON is an optic nerve (or inner retinal) disease.
- c. Occur equally as frequent in males and females.
- d. Never progress to blindness.

7. The retinal nerve fiber layer in LHON:

- a. Typically follows a pattern of progression similar to glaucoma.
- b. Typically increases in thickness before the retinal nerve fiber layer (RNFL) becomes quite attenuated.
- c. Is not affected.
- d. Is abnormal in a fashion similar to what occurs in LCA.

8. Although there is no established effective treatment for LHON,

- a. Avoidance of epigenetic triggers is strongly advisable.
- b. Most cases improve anyway without treatment.
- c. Genetic testing can decrease the incidence.
- d. There is also no present research with any chance of success.

9. Pupillary constriction in LHON is:

- a. Similar to the pupillary findings in glaucoma.
- b. Often normal or near normal due to the selective sparing of the melanopsin retinal ganglion cells.
- c. Markedly abnormal and pupils may be nearly fixed at the time of initial vision loss.
- d. Paradoxical in that light results in pupillary dilation.

10. A young child with nystagmus, significantly reduced VA and relatively unreactive pupils may have:

- a. LHON.
- b. LCA.
- c. Leber's military aneurysms.
- d. Fungal keratitis—another entity first described by Theodor Leber.

11. A 25-year-old female in good health presents with sudden onset of vision loss and a 3+ MAIA in the same eye. The disc appears mildly hyperemic in the affected eye. What is the most likely diagnosis?

- a. Diabetic papillopathy.
- b. Papillitis.
- c. LHON.
- d. Anterior ischemic optic neuropathy (AION).

12. A hyperactive 5-year-old male presents because he failed a school screening; VA is difficult to measure, the discs reveal possible temporal pallor, visual fields are impossible to take, and there is no family history of optic nerve disorders. First consider:

- a. An ERG under anesthesia.
- b. Genetic analysis for LHON mutations.
- c. Trial vision therapy for six sessions.
- d. Imaging with either CT or MRI.

13. In acute-onset LHON, which test is often abnormal?

- a. ERG.
- b. Visual evoked potential (VEP).
- c. Pupils.
- d. Electro-oculogram (EOG).

14. Which two tests may be abnormal in LHON even prior to subjective vision loss?

- a. ERG and EOG.
- b. ERG and fundus autofluorescence (FAF).
- c. B-scan ultrasound and EOG.
- d. VEP and RNFL.

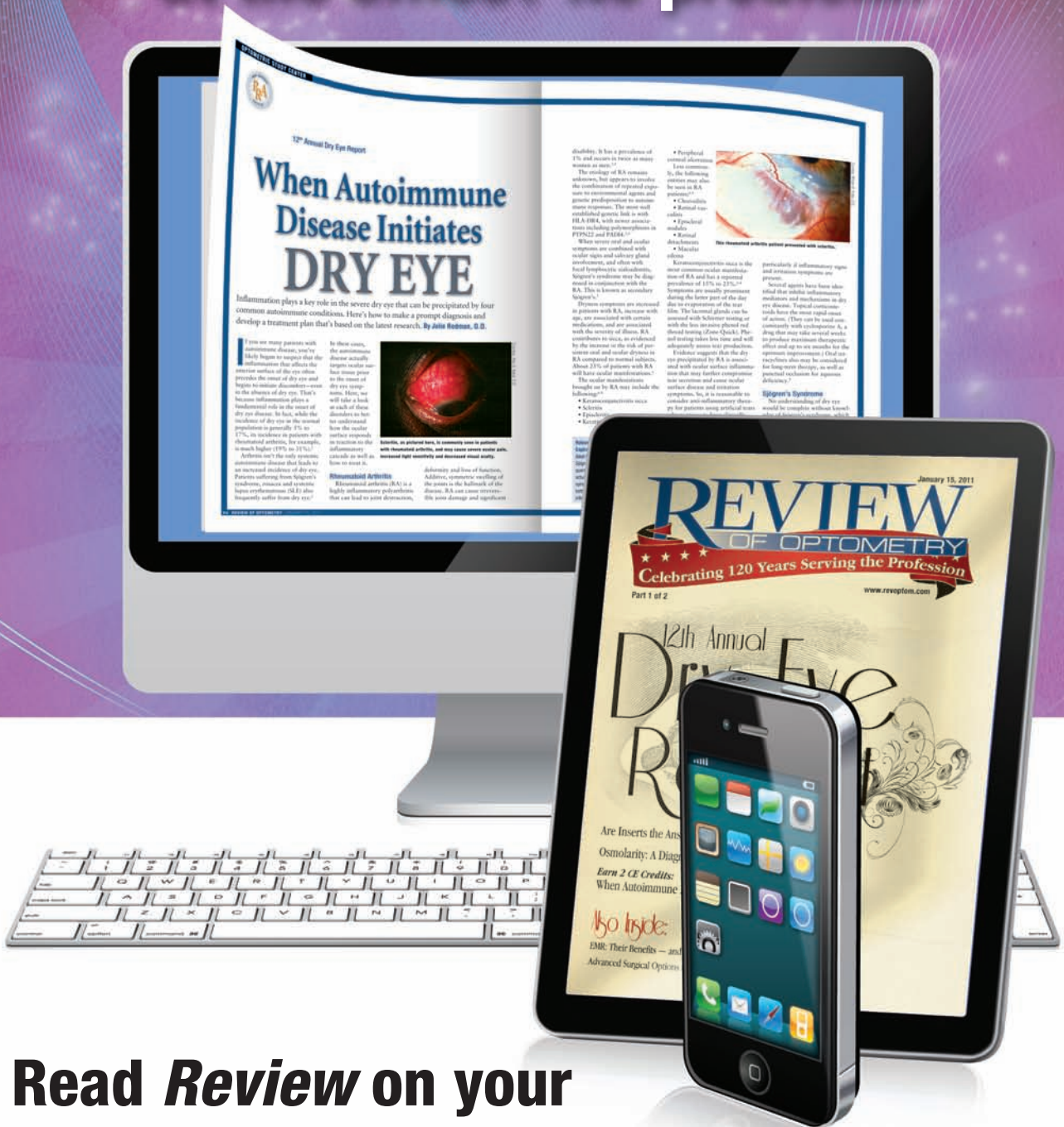15. A 65-year-old female with unilateral vision loss, a relative afferent pupillary defect and a small hyperemic disc most likely has:

- a. LCA.
- b. LHON.
- c. AION.
- d. Retrobulbar optic neuritis.

16. A 10-year-old girl presents with mild VA reduction in both eyes and central visual field defects. Her ERGs are normal,



# Left your issue of *Review of Optometry* at the office? No problem!



Read *Review* on your desktop or mobile device!

Simply go to [www.revoptom.com](http://www.revoptom.com) and click on the digital edition link to read the current issue online.



# See Glaucoma from a New Angle

With glaucoma patients, keep this poem in mind: “I think that I shall never see/  
An angle without gonioscopy.” **Edited by Paul C. Ajamian, O.D.**

**Q** A patient presented to an optometric referral center with a diagnosis of open-angle glaucoma, which was being treated with a prostaglandin and a beta-blocker. But because the IOP had not improved, the patient was referred for selective laser trabeculoplasty (SLT). Is anything amiss about this approach? Should any other tests be done?


**A** “Yes, there is something wrong with this picture,” says Howell Findley, O.D., of Commonwealth Eye Surgery, a comanagement and ocular surgery center in Lexington, Ky. “Further evaluation is necessary before subjecting the patient to surgery. Specifically, why is the IOP not responding to conventional therapy?”

The answer: Take a look at the angle.

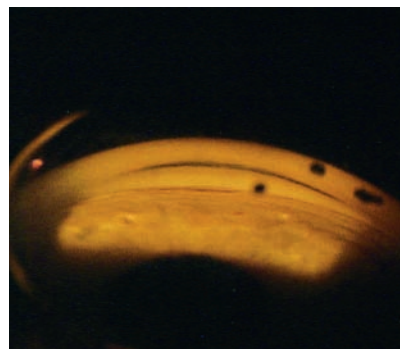
“Appropriate treatment of glaucoma requires accurate assessment of the anterior chamber angle,” Dr. Findley says. “Gonioscopy is an essential, but often overlooked, part of glaucoma management. I’ll bet you that this patient has a closed angle, but did not have gonioscopy performed.”

In acute angle closure, the classic symptoms—steamy vision with halos around lights, a red, painful eye, mid-dilated pupil, markedly elevated IOP, and sometimes nausea and vomiting—are easy to identify, Dr. Findley says.

“However, if the angle closes gradually, your patient may remain asymptomatic. Intermittent angle



**Slit lamp exam (left) shows a narrow angle, which should prompt you to perform gonioscopy. However, subsequent gonioscopy (right) revealed a nearly closed angle with only a small area of trabecular meshwork visible on either side.**



closure and chronic angle closure are not uncommon conditions. These patients may even present with IOP in the normal range and a clear cornea,” he says.

Slit lamp estimation may or may not reveal a narrow angle, so you can’t rely on it alone. “The only way to know the status of the drainage system is to visualize it directly, which requires gonioscopy,” Dr. Findley says.

Gonioscopy is an easily learned procedure, he says. “I recommend a four-mirror lens that uses the tear film as an interface (e.g., Zeiss, Posner or Sussman). Have adequate support for the gonio lens on the patient’s eye—hold the handle or the body of the gonio lens with the thumb and forefinger, while the ring finger and pinkie anchor onto the slit lamp or touch the patient’s cheek. Support for the elbow is also very helpful in maintaining steady contact with the eye,” Dr. Findley says.

Unlike an acute angle-closure

attack, which is first treated medically, chronic angle-closure glaucoma is treated primarily by laser peripheral iridotomy (LPI). “But if treatment is delayed, the angle may remain permanently closed and require a filtering procedure. Post-LPI, some patients may still require continued use of glaucoma medications,” he says.

If the patient has a visually-significant cataract, removal of the crystalline lens may achieve the dual purpose of improving vision and deepening the angle. “Consider this option rather than LPI if the angle does not appear to be in imminent danger of closure,” Dr. Findley says.

In this patient’s case, the slit lamp exam showed what appeared to be a narrow angle, and gonioscopy confirmed that the angle was actually closed 360°. The angle remained closed after LPI.

The patient was scheduled for a surgical consult with a glaucoma subspecialist. ■



The 90s called.  
They want their  
HEMA lenses back.

Give your patients an upgrade with AIR OPTIX® AQUA contact lenses



- In a post-launch evaluation with ECPs experienced in fitting AIR OPTIX® AQUA contact lenses,\*\* 91% of HEMA lens patients were successfully converted to AIR OPTIX® AQUA contact lenses<sup>1†</sup>
- Unique TriComfort™ Lens Technology provides moisture retention, superior deposit resistance,<sup>2††</sup> and breathability<sup>3\*</sup>
- Monthly replacement schedule promotes patient compliance<sup>4‡</sup> and may increase practice profitability<sup>5</sup>

Visit [myalcon.com](http://myalcon.com) to learn more.

\*AIR OPTIX® AQUA (lotrafilcon B) contact lenses: Dk/t = 138 @ -3.00D. \*\*Prior to evaluation, 100% fit AIR OPTIX® AQUA contact lenses and 85% indicated AIR OPTIX® AQUA contact lenses were their preferred SiHy lens for new fits. †Successful conversion defined as the patient received a prescription for or purchased AIR OPTIX® AQUA contact lenses. ††Compared to ACUVUE® OASYS®, ACUVUE® ADVANCE®, PureVision®, Biofinity®, and Avaira® contact lenses. ‡Compliance with manufacturer-recommended replacement frequency. §Trademarks are the property of their respective owners.

**Important information for AIR OPTIX® AQUA (lotrafilcon B) contact lenses:** For daily wear or extended wear up to 6 nights for near/far-sightedness. Risk of serious eye problems (i.e. corneal ulcer) is greater for extended wear. In rare cases, loss of vision may result. Side effects like discomfort, mild burning or stinging may occur.

**References:** **1.** Based on a post-launch evaluation in which 88 eye care practitioners refit over 400 patients in AIR OPTIX® AQUA contact lenses. Alcon data on file, 2011. **2.** Nash W, Gabriel M, Mowrey-McKee M. A comparison of various silicone hydrogel lenses; lipid and protein deposition as a result of daily wear. *Optom Vis Sci.* 2010;87:E-abstract 105110. **3.** Compared to HEMA contact lenses; based on the ratio of lens oxygen transmissibilities; Alcon data on file, 2010. **4.** Dumbleton K, Richter D, Woods C, et al. Compliance with contact lens replacement in Canada and the United States. *Optom Vis Sci.* 2010;87(2):131-139. **5.** Compared to 2-week replacement lenses; based on self-reported lens replacement time and third-party industry pricing information; Alcon data on file, 2012.

See product instructions for complete wear, care, and safety information.

**Alcon**®

© 2012 Novartis 2/12 AOA12002JAD

**Rx only**



# Why Isn't MK on the Decline?

Many contact lens materials and solutions have changed in the last 20 years, but the rates of microbial keratitis haven't followed suit. What's the story? **Edited by Joseph P. Shovlin, O.D.**

**Q** In spite of significant advances in contact lens materials and solutions, several population-based studies have shown very little reduction in the rate of microbial keratitis in contact lens wearers over the past two decades. Why haven't we been able to effectively reduce the number of new cases seen each year?

**A** Although microbial keratitis is a relatively rare condition, it remains one of the most serious complications of contact lens wear. Epidemiologic studies over the past decade haven't indicated much change in rates of microbial keratitis, but they have helped clinicians pinpoint significant risk factors for the disease.

"We may not have shifted the absolute number, but we do have some additional information about how we can limit severity," says Fiona Stapleton, Ph.D., MCOptom, head of the School of Optometry and Vision Science at the University of New South Wales and senior research associate at the Brien Holden Vision Institute, Sydney, Australia. "We have gained some insight into how to lessen the impact of the microbial keratitis—avoiding a delay in getting appropriate treatment, proper storage case hygiene practice, and having the patient present back to the optometrist rather than a general practitioner."

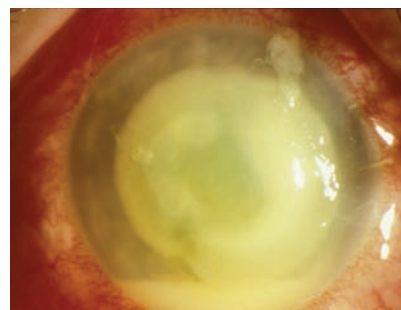
Researchers also have identified overnight wear and poor contact lens hygiene as the major risk factors.<sup>1</sup> "In daily contact lens wear, we know contact lens storage case

practice is paramount, particularly for severe disease—namely case replacement and cleaning," Dr. Stapleton says. "If we can sort out those two, we can eliminate 60% of the disease load in daily wear."<sup>2</sup> She believes new innovations like antimicrobial lenses and cases could make a difference in the incidence of microbial keratitis, but says that products such as new lens types and solutions historically have not made a difference.

Many optometrists believe daily disposable lenses could also be beneficial because they make it easier for patients to comply with their lens care routine. "We have seen that with daily disposables, there is a lower rate of severe disease—probably because there is a lower rate of those environmental organisms found in the storage case," Dr. Stapleton says.

Robin Chalmers, O.D., an independent clinical trial consultant and adjunct professor at Indiana University School of Optometry, agrees that daily disposable lenses could be useful because there's less chance of contamination from storage, everyday handling and reuse. In a recent study she conducted, daily disposable lenses were protective with a 12.5 times lower risk of inflammatory events compared with reusable daily wear lenses.<sup>3</sup>

"If we take that and make the assumption—and this is a bit of a leap—that inflammatory events are driven by the same bacterial bio-burden on the lenses that infections are, I'm hoping that the microbial



**This contact lens wearer developed a *Pseudomonas* ulcer with a central ring infiltrate and hypopyon.**

keratitis rate would be lower when more patients are using daily disposable lenses," Dr. Chalmers says.

But to get definitive answers, she believes we need new studies incorporating more modern products. New data could provide a more accurate picture of the incidence of contact lens-related microbial keratitis today.

"I don't think the population-based studies that were conducted about 10 years ago accurately reflect the current mix of lenses or care products," Dr. Chalmers says. "Ten years ago, we found that there really wasn't much change in the rate of microbial keratitis, and I would say that we just don't know much about what has happened since then." ■

1. Stapleton F, Keay LJ, Edwards K, et al. The incidence of contact lens-related microbial keratitis in Australia. *Ophthalmology*. 2008 Oct;115(10):1655-62.
2. Stapleton F, Edwards K, Keay L, et al. Risk factors for moderate and severe keratitis in daily wear contact lens users. *Ophthalmology*. 2012 Aug;119(8):1516-21.
3. Chalmers RL, Keay L, McNally J, Kern J. Multicenter case-control study of the role of lens materials and care products on the development of corneal infiltrates. *Optom Vis Sci*. 2012 Mar;89(3):316-25.

# REVIEW<sup>®</sup> OF OPTOMETRY

**Introduces a New  
Exclusive Service for  
Eye-Care Professionals**



## Eyecare Resources Online

This **service** allows you to capture needed measures for two meaningful use objectives:

- 1) *electronic transmission of patient prescriptions*
- 2) *distribution of patient-specific education materials*

ECP Resources and ePrescribing from *Review of Optometry* and Healthcare Resources Online enable you to provide patient education, electronic prescribing and generate reports that allow you to attest for meaningful use incentives; however, determination of your bonus payments from CMS depends on other factors and qualifications specific to your practice.

**For More Information, Visit Our OD E-Prescribing Resources Website Page:**

**[www.revoptom.com/ecp\\_resources\\_erx/](http://www.revoptom.com/ecp_resources_erx/)**



*Download a QR scanner app.  
Launch app and hold your mobile  
device over the code and get ready  
to view our website.*



# Cholesterol Check-In

High cholesterol doesn't just negatively impact your patients' heart health; it can put their vision at risk too. **By Carlo J. Pelino, O.D., and Joseph J. Pizzimenti, O.D.**

**T**he CDC recently delivered some heartening news: Cholesterol levels among U.S. adults have dropped an average of 10 points over the past two decades.<sup>1</sup> However, an estimated 71 million American adults have high cholesterol, so there is still a ways to go.<sup>2</sup>

High cholesterol increases your patients' risk for coronary heart disease, heart attack and stroke.<sup>3</sup> Its damaging effects are not limited to arteries and vessels, as high cholesterol can significantly affect vision and eye health as well.

This month, we'll review the basics about cholesterol, its relationship with ocular health and common treatments.

## Back to Basics

Cholesterol, comprised of a lipid and a sterol, is so essential for survival that the body makes about 75% of its supply—with the remainder coming from the foods that we eat.<sup>3</sup> The body needs cholesterol to produce the outer membrane of cells, create the bile acids that help digest food in the intestine and make vitamin D and hormones, like estrogen and testosterone.<sup>4</sup>

Because lipids are oil-based and blood is water-based, it isn't easy for cholesterol to flow through the bloodstream.<sup>5</sup> For example, if cholesterol were dropped directly into the bloodstream, it would form into blobs like oil does in vinegar and would be unusable.

To allow it to mix more easily with blood, the body packages cholesterol and other fats into small

protein-covered particles called lipoproteins (lipid + protein).<sup>5</sup>

The five major types of lipoproteins are:<sup>6</sup>

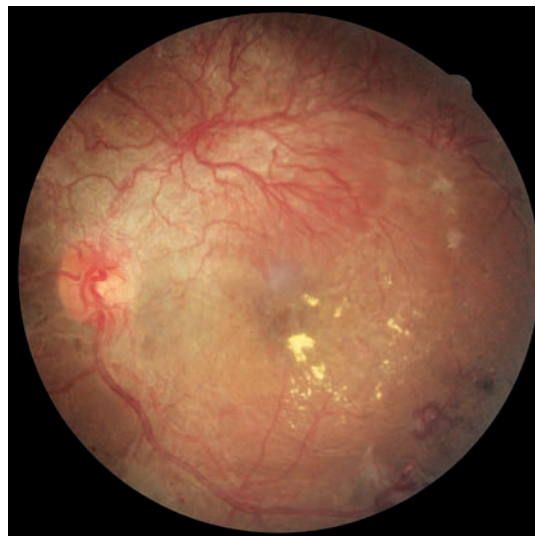
- Chylomicrons.
- Very low-density lipoproteins (VLDL).
- Intermediate-density lipoproteins (IDL).
- Low-density lipoproteins (LDL).
- High-density lipoproteins (HDL).

The proteins that combine with the cholesterol are called apolipoproteins. The fat in these particles is comprised of cholesterol, triglycerides and phospholipids (which help to hold the whole particle together).<sup>5</sup> The body needs triglycerides for energy but, like cholesterol, too much is bad for the arteries and the heart.<sup>5,7</sup>

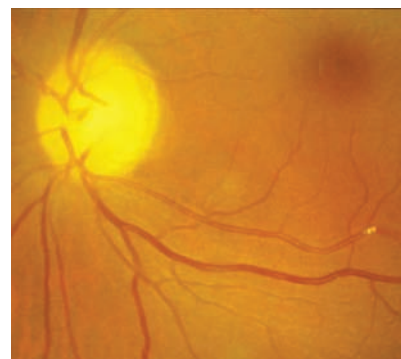
## Testing and Causative Factors

Because there are no symptoms of high cholesterol, it is crucial that patients keep up with regular monitoring through simple blood testing that can provide a breakdown of cholesterol levels. Elective determinations of plasma lipid concentrations should be made after an overnight fast (preferably 10 to 14 hours). Directly measured components include triglycerides, total LDL and HDL.

High cholesterol can result from a number of possible causes: a genetic predisposition, a diet too



**This image highlights fat (exudate) deposits in the retina of a diabetic patient.**



**In this patient, you can see cholesterol plaque has lodged in a retinal artery.**

high in cholesterol or the inability to excrete cholesterol efficiently.<sup>5</sup> Some of these factors are unavoidable but treatable, while others are entirely controllable.

For instance, evidence suggests that Americans tend to have higher blood cholesterol levels than people in the Far East or Africa largely



# Review Meetings 2013

## SAVE THESE DATES FOR 2013

Join us for up to 15 CE\* credits!  
Educational Chair: Paul Karpecki, OD

**Maui 2013**  
...a meeting of clinical excellence

**JUNE 13-16, 2013**  
Wailea Beach Marriott, Maui

**BERMUDA 2013**  
...a meeting of clinical excellence

**JULY 25-28, 2013**  
Fairmont Hamilton Princess, Bermuda

**New Technology  
& Treatments**  
IN VISION CARE  
WEST COAST

**SEPTEMBER 20-22, 2013**  
Marriott Del Mar, San Diego

More information and registration available shortly.

Please contact Lois DiDomenico with questions at [ReviewMeetings@Jobson.com](mailto:ReviewMeetings@Jobson.com) or 1-866-658-1772.

Check back for more information: [www.revoptom.com/conferences](http://www.revoptom.com/conferences)



\*Approval Pending

because of America's high-fat, high-cholesterol diet.<sup>5,8</sup>

## How Cholesterol Moves

After a meal, the intestines absorb the nutrients the body needs from food. In the small intestine, intestinal enzymes degrade lipids into component fatty acids. They are then reassembled and bundled into new triglyceride molecules and packaged, along with some cholesterol, into chylomicrons.<sup>5,7,9</sup>

At the same time, carbohydrates and proteins pass to the liver, which converts some of these nutrients to triglyceride molecules, packages them with apolipoproteins and cholesterol, and releases them into the blood as VLDL.<sup>7</sup>

As mentioned earlier, the body produces the majority of cholesterol. Even if an individual were to eat a completely cholesterol-free diet, the body would make about 1,000mg of cholesterol—the amount it needs to function properly.<sup>5</sup> The body can regulate the amount of cholesterol in the blood, creating more when diet doesn't provide enough.<sup>5</sup>

Nearly all cells in the body can make the cholesterol they need, but the liver is especially efficient in producing cholesterol, which makes it central to the regulation of cholesterol levels.<sup>5,6,9</sup>

The liver packages most of its cholesterol into lipoproteins that are delivered to cells throughout the body, which provides each cell with an additional supplement to what it makes on its own.<sup>5</sup> Once released into the circulation, VLDLs supply free fatty acids to tissues as well as transport fats. When they give up their fat, VLDLs turn into IDLs.

Over time, IDLs turn into LDL cholesterol. If there are too many LDL particles in the bloodstream, they deposit the cholesterol onto

## Cholesterol and the Eye

Patients with abnormally high LDL cholesterol levels or uncharacteristically low HDL cholesterol levels can be at risk for a number of ocular comorbidities.

- **Corneal arcus** is a particularly sensitive sign of familial hypercholesterolemia, an inherited form of high LDL cholesterol.<sup>11-12</sup> It's especially serious when detected in persons younger than 50 years old, in which case it also is referred to as arcus juvenalis.<sup>11-13</sup> Corneal arcus appears as a thin gray or white ring at the edge of the patient's cornea.
- **Corneal opacification** may be seen in patients who have very low HDL cholesterol due to mutations in their regulatory genes.<sup>11</sup> Resulting from an accumulation of free cholesterol and phospholipids, the opacification may cause a significant reduction in vision.<sup>11</sup>
- **Lipemia retinalis** primarily is caused by an elevation of the serum triglyceride levels, which gives the blood a milky color. Typically, it is not observed until triglyceride levels are extremely elevated (> 2,500mg/dL).<sup>14</sup> Initially, the retinal vessels appear salmon-pink, but they become whitish as the triglyceride level rises further. Appearance and function improve as the triglyceride levels return to normal with appropriate treatment.<sup>11,14</sup>
- **Retinal vein occlusion** also may be more common in patients with high cholesterol levels. In the same way that cholesterol lines blood vessels in other parts of the body, it may damage endothelial cells, leading to thrombus formation in the vessel from the retina.<sup>15</sup> One study suggested that high cholesterol levels increase the risk of retinal vein occlusion as much as 2.5-fold.<sup>15</sup>
- **Xanthelasmata** typically are caused by elevated levels of triglycerides and cholesterol in the blood as well as metabolic disorders, including familial hypercholesterolemia.<sup>16</sup> These yellowish deposits of cholesterol appear underneath the skin, usually on or around the eyelids.<sup>16</sup>

the walls of the arteries and blood vessels, which can lead to build-up and blockages.<sup>5</sup> The liver and the intestines also make HDLs, which scavenge cholesterol from the blood and artery walls and take it to the liver for disposal.<sup>5,7,9</sup>

## Cholesterol Medications

Intervention studies in the 1990s showed that cholesterol reduction by means of diet or drugs reduced the risk of development or progression of coronary heart disease.<sup>6</sup>

If an individual has high cholesterol, a total cholesterol level that is 200mg/dL or higher or a low-density lipoprotein cholesterol (LDL) level that is 130 mg/dL or higher, a cholesterol-lowering medication may be recommended (depending upon other risk factors involved).<sup>10</sup>

Let's look at some of the most

commonly used drugs:<sup>4,7</sup>

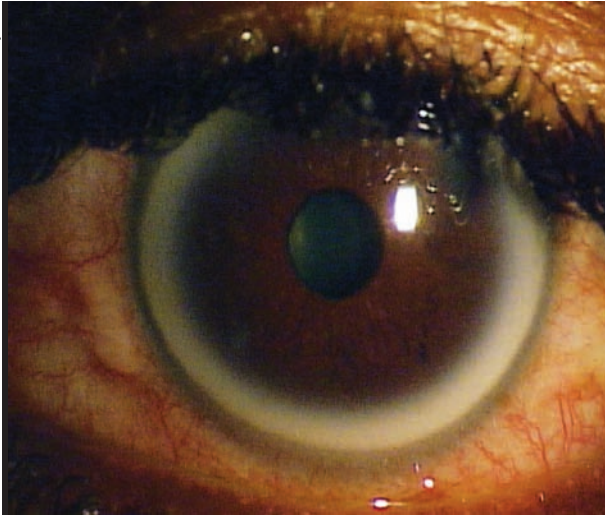
- **Statins** (e.g., Lipitor [atorvastatin, Pfizer]) are the most widely prescribed cholesterol-lowering drugs. They block HMG-CoA reductase, a key liver enzyme involved in the production of cholesterol.
- **Bile acid sequestrants** (e.g., Colestid [colestipol, Pfizer]) inhibit the body's absorption of dietary cholesterol.
- **Niacin (nicotinic acid)** is said to increase HDL levels and decrease triglyceride and LDL levels when used at high doses.
- **Omega-3 fatty acids** increase the level of HDL and lower the level of triglycerides.
- **Cholesterol absorption inhibitors** (e.g., Zetia [ezetimibe, Merck]) decrease the amount of cholesterol absorbed from food in the digestive tract.

# CAN'T WAIT

Optometric Physician delivers  
**UP-TO-DATE** news and research  
to your inbox every Monday morning,  
allowing you to view all of the latest  
clinical information on a convenient  
and consistent basis.

Subscribing to Optometric Physician  
is an efficient and easy way to stay  
current with all of the information and  
events going on in the field. To order your  
free subscription, e-mail:  
[optometricphysician@jobson.com](mailto:optometricphysician@jobson.com) today.

Photo: Howell Findley, O.D.




**Corneal arcus is a particularly sensitive sign of familial hypercholesterolemia.**

• **Fibrates** (e.g., Lopid [gemfibrozil, Pfizer]) decrease triglycerides by reducing the liver's production of VLDL and accelerating its removal from the blood.

Most cholesterol medications lower cholesterol with few side effects, but effectiveness may vary from person to person.

Healthy lifestyle choices—such as smoking cessation, exercise, weight loss, stress management, and a healthy diet that is low in saturated fat, cholesterol and salt—should be considered.<sup>5</sup> ■

1. Carroll MD, Kit BK, Lacher DA, et al. Trends in lipids and lipoproteins in US adults, 1988–2010. *JAMA*. 2012 Oct 17;308(15):1545–54.
2. CDC. Vital signs: prevalence, treatment, and control of high levels of low-density lipoprotein cholesterol. United States, 1999–2002 and 2005–2008. *MMWR*. 2011;60(4):109–14.
3. American Heart Association. Cholesterol. 2012 Aug 8. Available at: [www.heart.org](http://www.heart.org). Accessed November 7, 2012.
4. Understanding cholesterol and heart health. *NIH Medline Plus*. 2012;7(2):4.
5. Freeman MW, Junge C. The Harvard Medical School guide to lowering your cholesterol. Boston: McGraw-Hill; 2005:1–12.
6. Lange RA, Hillis LD. Coronary heart disease. In: Andreoli and Carpenter's Cecil Essentials of Medicine. 7th ed. Philadelphia: Elsevier Inc.; 2007:97–117.
7. What to do about high cholesterol: a Harvard Medical School special health report. Boston: Harvard Health Publications; 2012.
8. All in the family: when high blood cholesterol occurs in families. *NIH Medline Plus*. 2012;7(2):8–9.
9. Linder T, Melby AE. Cholesterol, lipoproteins, and the liver. University of Washington. Available at: <http://courses.washington.edu/conn/bess/cholesterol/liver.html>. Accessed November 7, 2012.
10. Pyeritz RE. Disorders of lipid metabolism. In: Andreoli and Carpenter's Cecil Essentials of Medicine. 7th ed. Philadelphia: Elsevier Inc.; 2007:617–24.
11. Miller M. Signs and symptoms of dyslipidemia: ophthalmologic signs. *Medscape Education*. Available at: [www.medscape.org/viewarticle/585045](http://www.medscape.org/viewarticle/585045). Accessed November 7, 2012.
12. Fernández A, Sorokin A, Thompson PD. Corneal arcus as coronary artery disease risk factor. *Atherosclerosis*. 2007 Aug;193(2):235–40.
13. Patterson L. Arcus senilis: an important forensic physical finding. *Am J Forensic Med Pathol*. 1982;3(2):115–8.
14. Park YH, Lee YC. Images in clinical medicine. Lipemia retinalis associated with secondary hyperlipidemia. *N Engl J Med*. 2007 Sep 6;357(10):e11.
15. O'Mahoney PR, Wong DT, Ray JG. Retinal vein occlusion and traditional risk factors for atherosclerosis. *Arch Ophthalmol*. 2008 May;126(5):692–9.
16. Kohnle D. Xanthelasma and xanthoma. Beth Israel Deaconess Medical Center. Available at: [www.bidmc.org/YourHealth/ConditionsAZ.aspx?ChunkID=202823](http://www.bidmc.org/YourHealth/ConditionsAZ.aspx?ChunkID=202823). Accessed November 7, 2012.



Optometric  
Physician™

Save the Date!



Mark your calendars for the

3<sup>rd</sup> Annual

# West Coast Optometric Glaucoma Symposium



**Course Director:**  
Murray Fingeret, OD

**Speakers:**

Michael Chaglasian, OD  
John Flanagan, MCOptom, PhD  
I. Ben Gaddie, OD  
Sameh Mosaed, MD  
Tony Realini, MD  
Robert N. Weinreb, MD

## 3 WAYS TO REGISTER

**Online:** [www.revoptom.com/2012WCOGS](http://www.revoptom.com/2012WCOGS)

**Email:** [ReviewMeetings@Jobson.com](mailto:ReviewMeetings@Jobson.com)

**Call:** Lois DiDomenico 877-451-6514

For questions, please email Denette Holmes at [ReviewLogistics@jobson.com](mailto:ReviewLogistics@jobson.com) or call 866-627-0714.

**December 14-15, 2012**  
**Fairmont Newport Beach**  
Newport Beach, California

Limited time reservations for \$143/night  
Call (949) 476-2001 and mention this program

Identify yourself as a participant of the West Coast  
Optometric Glaucoma Symposium (WCOGS)

## 12 COPE Credits\* for only \$125!

*I invite you to join us for this comprehensive glaucoma symposium that will take place at the Fairmont Newport Beach in Newport Beach, California. We will have a group of renowned doctors who specialize in glaucoma. The program will consist of short talks and Q&A panels. Interaction with the faculty is a large part of the program. The agenda will cover the steps taken in establishing the diagnosis of glaucoma, information on new instrumentation and changing paradigms with regard to glaucoma therapy. The program runs Friday from 9:00 am – 6:00 pm, and Saturday from 8:00 am – 1:30 pm.*

*I look forward to seeing you in Newport Beach!*  
Murray Fingeret, OD

Partially supported by an educational grant from

Sponsored by

**REVIEW**  
OF OPTOMETRY



\*COPE approval pending

**Alcon**



# Fungal Meningitis a Factor?

This HIV+ patient recently was hospitalized for cryptococcal meningitis. Did the infection damage his eyes? **By Mark T. Dunbar, O.D.**

**A** 54-year-old Hispanic male presented for his annual eye exam. He wore progressive lenses and did not report any vision problems.

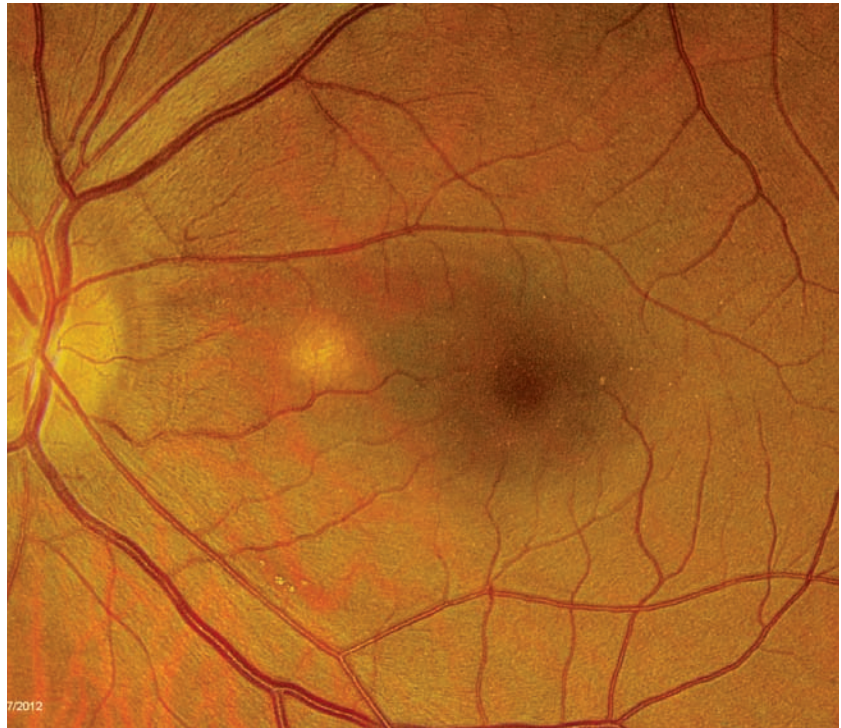
Approximately four months earlier, the patient had been hospitalized for cryptococcal meningitis. At that time, he was in the hospital for approximately three weeks. He reported no ocular sequelae from the meningitis.

His systemic history was positive for HIV, and the patient wanted to make certain that there was nothing wrong with his eyes. His current medications included Diflucan (fluconazole, Pfizer), Celexa (citalopram hydrobromide, Forest Pharmaceuticals), Imitrex (sumatriptan, GlaxoSmithKline), Abilify (aripiprazole, Bristol-Myers Squibb) and clonazepam.

On examination, his best-corrected visual acuity measured 20/20 O.U. Confrontation fields were full to careful finger counting O.U. His pupils were equally round and reactive, with no evidence of afferent defect. The anterior segment examination was unremarkable in each eye. Intraocular pressure measured 12mm Hg O.U.

Dilated fundus exam showed a clear vitreous O.U. Both optic nerves appeared healthy, with small cups with good rim coloration and perfusion.

The macula and periphery of the right eye were normal. The peripheral retina in the left eye



**1. A view of our patient's left posterior pole. Note the yellow-white lesion located between the optic nerve and macula.**

was normal; however, we noted a small, yellow-white lesion located between the optic nerve and macula (*figure 1*). We obtained a spectral domain optical coherence tomography (SD-OCT) scan of the left eye to further evaluate the lesion (*figure 2*).

## Take the Retina Quiz

1. How would you describe the appearance of the lesion located in our patient's left eye?

a. Nonspecific depigmentation of the retinal pigment epithelium (RPE).

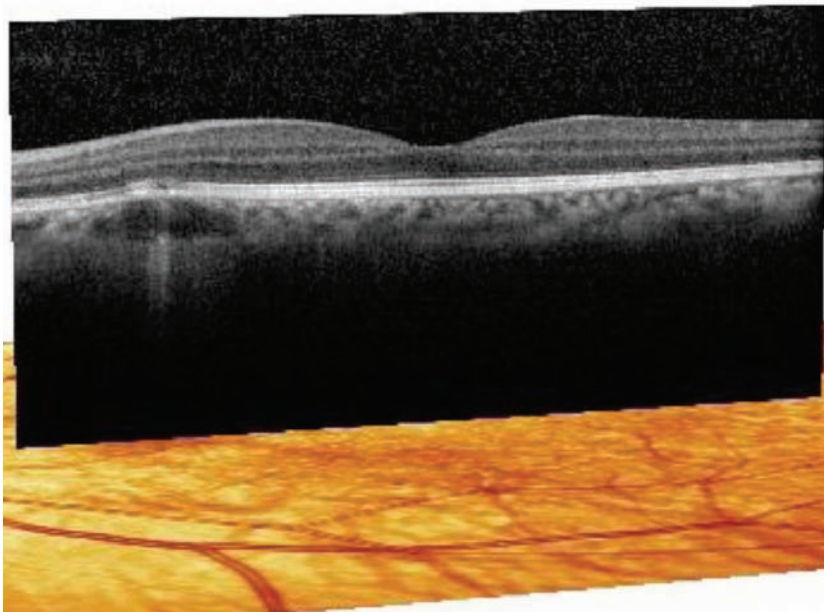
b. Area of active retinitis.  
c. Area of active choroiditis.  
d. Both a and c.

2. What does the SD-OCT scan show?

a. Normal retina.  
b. Neurosensory detachment.  
c. RPE detachment.  
d. Localized choroidal lesion.

3. What is the likely diagnosis?

a. Nonspecific depigmentation of the RPE.  
b. HIV retinopathy.  
c. Cytomegalovirus retinitis.



2. Here is the SD-OCT scan of our patient's left eye. What does it reveal?

- d. Cryptococcal choroiditis.
4. How should we manage this patient?
- a. Observation.
  - b. Referral to infectious disease specialist.
  - c. Antiviral therapy.
  - d. Antibiotic therapy.

For answers, go to page 98.

## Discussion

At first glance, the retinal lesion located in the left eye looked like nothing more than a nonspecific RPE depigmentation. However, we had just seen the patient a year earlier and did not notice the lesion. Given his recent medical history, we ordered the SD-OCT scan. And, without question, we were surprised at the results.

The SD-OCT revealed extensive retinal and choroidal detail. Within the choroid, we observed a localized circular lesion that was located below the area of RPE depigmentation. It stood out as

being optically empty when compared to the surrounding, more homogenous choroid.

Above the lesion, the RPE appeared slightly elevated and the photoreceptor integrity layer was disrupted marginally. Had this presentation occurred in the fovea, his vision likely would have been affected. But, because it was located outside the fovea, he was asymptomatic.

Having recently been hospitalized for cryptococcal meningitis, the retinal lesion was highly suspicious for choroidal infiltration. Cryptococcal meningitis is caused by the fungus *Cryptococcus neoformans*, which is found in various soils and plants from around the world.<sup>1</sup>

Most infections caused by *C. neoformans* affect only the lungs; however, meningitis may result in patients with weakened immune systems secondary to HIV, diabetes and lymphoma.<sup>1</sup> And indeed, our patient's CD4 count was 268, which indicated that he was

sufficiently immunocompromised to develop cryptococcal meningitis.

Ocular involvement from cryptococcal meningitis presents in approximately 6% of patients.<sup>2</sup> In addition to choroiditis, other ocular complications include chorioretinitis, vitritis, endophthalmitis and neuroretinitis. Further adverse complications also may arise from the meningitis, such as papilledema, ophthalmoplegia, ptosis, optic atrophy and sixth nerve palsy.<sup>2</sup>

Fortunately, it appeared that our patient's infection was limited to a small area located within his choroid. Of interest, he was already taking a medication for his cryptococcal meningitis—Diflucan. This raises two important questions:

- *Was the infection much worse several months ago, when the patient was first hospitalized with the meningitis?*
- *If the presentation was new, was the antifungal medication being dosed at an adequate therapeutic level to treat the choroiditis?*

Given that this lesion was isolated, and he didn't have any other ocular complications, we elected simply to observe our patient. We sent a note to his infectious disease physician to inform him of our findings. Also, we asked our patient to continue use of his antifungal medications.

We saw the patient several times during the subsequent five months and documented slow resolution of the RPE depigmentation and the choroidal lesion. Thereafter, he continued to be asymptomatic. ■

1. Kauffman CA. Cryptococcosis. In: Goldman L, Ausiello D (eds.). Cecil Medicine. 23rd ed. Philadelphia: Saunders-Elsevier; 2007:357.

2. Carney MD, Combs JL, Waschler W. Cryptococcal choroiditis. Retina. 1990;10(1):27-32.



# Double Trouble II

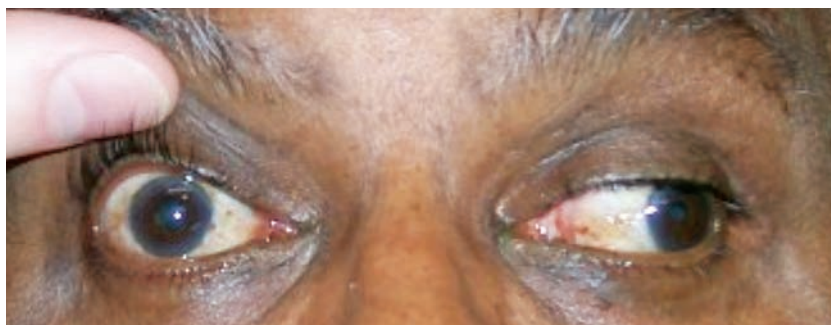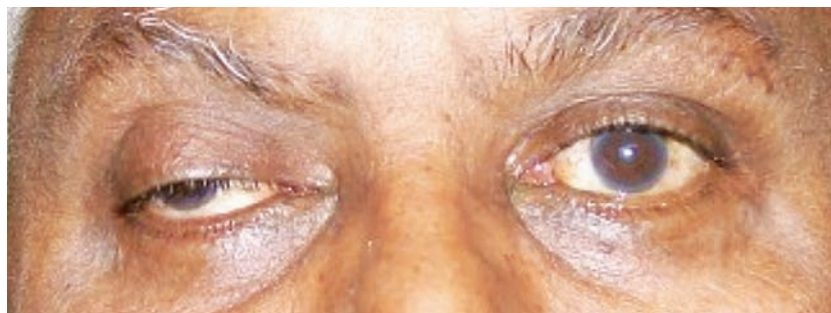Another glaucoma patient presented with double vision. Is this more serious than our previous case? **By Joseph W. Sowka, O.D., and Alan G. Kabat, O.D.**

In our September column, “Double Trouble,” we described a patient who was being managed for primary open-angle glaucoma (POAG) and subsequently developed double vision from coincident cranial nerve (CN) VI palsy. This month, we discuss yet another patient with glaucoma who developed double vision from a more sinister cause.

The patient is a 61-year-old black male being managed for POAG who developed a severe headache on a Friday, which he described as “right sided” and a “nine out of 10” in terms of pain and discomfort severity.

At nearly the same time as the onset of his headache, his right eyelid began to droop and he developed double vision. He took over-the-counter analgesics throughout the weekend and, when the debilitating pain did not subside, he came into the office urgently on Monday morning.

Evaluation revealed a well-nourished man in acute distress with a near complete right-sided ptosis. Upon manually elevating the lid, the right eye had assumed a “down-and-out” position. He had significant ophthalmoplegia with an adduction, elevation and depression deficit. Abduction was normal in the right eye and motility was normal in the left. Tellingly, his right pupil was mid-dilated and minimally reactive to light, while the left pupil was smaller and normally reactive.



**Our patient in primary gaze with right ptosis and an eye that appears down and out (top). In left gaze, he demonstrates an inability to adduct; anisocoria also is evident.**

Clearly, the patient had a right CN III palsy. The dilated right pupil and severe hemicranial pain indicated that the likely cause was an intracranial aneurysm, which was compressing the nerve and pupillomotor fibers. In this month’s column, we discuss one of the only true ophthalmic emergencies: aneurysmal CN III palsy.

## What is CN III Palsy?

A patient with acute CN III palsy usually presents with a sudden onset of unilateral ptosis and ophthalmoplegia, which is frequently accompanied by significant eye or head pain—depending

on the underlying cause.<sup>1-4</sup> Such patients often complain of double vision. But, in some instances, the diplopia may be masked by the ptosis, which obscures the vision in the affected eye; however, when the lid is manually elevated, the patient will experience diplopia. Acuity typically is unaffected unless the provoking lesion occurs in the superior orbital fissure, causing simultaneous CN II involvement.

CN III palsy produces a non-comitant exotropic, hypotropic eye position (down and out). There is limitation of elevation, depression and adduction as well as an underaction of the superior, inferior and

medial recti muscles and the inferior oblique muscle.<sup>1-3</sup> The underaction of these muscles may be complete or incomplete.<sup>5-7</sup> In any case of CN III palsy, the pupil may be dilated and minimally reactive to light (pupillary involvement), totally reactive and normal (pupillary non-involvement) or sluggishly responsive (partial pupillary involvement).<sup>3,4,7-10</sup>

Various neurological signs—such as contralateral intention tremor, cerebellar ataxia or contralateral hemiplegia—may present concomitantly with the development of CN III palsy, depending on the cause and location of damage to CN III within the brainstem.<sup>3</sup>

Patients who develop acute CN III palsy tend to be older (>55 years of age). CN III palsy is uncommon in children, although it can occur.<sup>7</sup> Often, there is concurrent diabetes and/or hypertension in older adults.<sup>3,6,7,11</sup> Occasionally, head trauma is associated with the development of CN III palsy.<sup>12</sup>

Third nerve palsy results from damage to the oculomotor nerve anywhere along its route from the nucleus in the dorsal mesencephalon, its fascicles in the brainstem parenchyma, the nerve root in subarachnoid space, the cavernous sinus or the posterior orbit.<sup>3,13</sup>

The main concern in an isolated CN III palsy occurring within the subarachnoid space is nerve compression caused by an expanding aneurysm of the posterior communicating artery (most common) or the internal carotid, basilar, anterior communicating or temporal arteries (less common).<sup>8,9,14-16</sup>

Approximately 15% of isolated CN III palsies occurring secondary to damage within the subarachnoid area are due to aneurysms.<sup>11</sup> Vasculopathic infarct, often associ-

ated with concurrent diabetes or hypertension, accounts for 35% of isolated CN III palsy cases.<sup>11</sup>

Aneurysmal compression is marked by head or retro-orbital pain and anisocoria with ipsilateral pupil dilation, because the expanding aneurysm compresses the pupillomotor fibers traveling with CN III as well as pain-sensitive dura and other such structures. Patients who develop CN III palsy from aneurysmal compression may not present initially with anisocoria or pupil involvement.<sup>5,8-10</sup> Instead, these patients typically present with an incomplete palsy that evolves and develops pupil dilation over several days.<sup>3,7,11</sup>

## Managing CN III Palsy

Management of CN III palsy in adults depends on the associated findings and etiology. In complicated CN III palsies—where other neural structures are involved—the patient should undergo MRI scanning in order to ascertain the etiology.<sup>3</sup>

In cases of isolated, complete CN III palsies that have no pupillary involvement in patients over 50 years of age, the primary cause is typically ischemic vascular infarct. Giant cell arteritis also is a potential etiology. Magnetic resonance imaging (MRI) and magnetic resonance angiography (MRA), erythrocyte sedimentation rate, C-reactive protein, blood pressure measurement, complete blood count with differential, and blood glucose testing are indicated. CT scan and CT angiography (CTA) are often used to identify intracranial bleeding as well as identify the aneurysm location.

Close observation is required, because pupil involvement may be delayed by five to seven days. This is especially true for patients

with incomplete CN III palsy with pupil sparing, because they are more likely to develop an incipient aneurysm.<sup>5</sup>

In ischemic vascular CN III palsy, the pupil will not evolve, aberrant regeneration will not occur, and the palsy will spontaneously improve or resolve over the course of three to six months.<sup>3,11</sup> If the palsy shows no improvement over six to eight weeks or aberrant regeneration develops, MRI/MRA or CT/CTA is required to rule out the presence of an occult mass in the subarachnoid space.<sup>3</sup>

If the patient is less than 50 years of age and has an isolated, non-pupillary-involved CN III palsy, imaging or intracranial angiography is indicated. In this age group, ischemic vasculopathy is less likely to occur than an aneurysm.

If an adult patient of any age presents with isolated, complete or incomplete CN III palsy with pupillary involvement, this should be considered a medical emergency. The patient should undergo immediate MRA/MRI or intracranial angiography. In these cases, the cause likely is an aneurysm located at the junction of the internal carotid and posterior communicating arteries, or at the tip of the basilar artery. These patients should be sent immediately to a hospital emergency room with the diagnosis and recommendations for consultation.

If the aneurysm ruptures, there is a risk of death from subarachnoid hemorrhage and brainstem herniation through the foramen magnum. In cases of CN III palsy caused by subarachnoid aneurysm, immediate neurosurgical intervention is necessary. Common endovascular treatment involves direct clipping of the aneurysm or embo-



lization with detachable coils.<sup>16,17</sup>

Pupil-involved CN III palsy in adults is one of the few true medical emergencies seen in eye care. These patients must be sent to the hospital immediately for neurosurgical consult.

In this patient's case, we immediately suspected an intracranial aneurysm. The patient and his wife were well educated about the potential mortality risk and promptly agreed to go to the hospital emergency room, where a triage nurse had already been alerted and was waiting. The patient's wife called back 45 minutes later to report that her husband was undergoing neuroimaging and a neurosurgical consult.

Ultimately, he was diagnosed with an internal carotid artery

aneurysm and underwent embolization with detachable coils. The patient spent 22 days in the intensive care unit and more than one year later still continues to recover, underscoring the seriousness of this condition. ■

1. Satyarthee GD, Mahapatra AK. Unusual neuro-ophthalmic presentation of anterior communicating artery aneurysm with third nerve paresis. *J Clin Neurosci*. 2004 Sep;11(7):776-8.
2. Bahmani Kashkoui M, Khalatbari MR, Yahyavi ST, et al. Pituitary apoplexy presenting as acute painful isolated unilateral third cranial nerve palsy. *Arch Iran Med*. 2008 Jul;11(4):466-8.
3. Yanovitch T, Buckley E. Diagnosis and management of third nerve palsy. *Curr Opin Ophthalmol*. 2007;18(5):373-8.
4. Delengocky T, Bui CM. Complete ophthalmoplegia with pupillary involvement as an initial clinical presentation of herpes zoster ophthalmicus. *J Am Osteopath Assoc*. 2008 Oct;108(10):615-21.
5. Takahashi M, Kase M, Suzuki Y, et al. Incomplete oculomotor palsy with pupil sparing caused by compression of the oculomotor nerve by a posterior communicating posterior cerebral aneurysm. *Jpn J Ophthalmol*. 2007;51(6):470-3.
6. Capó H, Warren F, Kupersmith MJ. Evolution of oculomotor nerve palsies. *J Clin Neuroophthalmol*. 1992 Mar;12(1):21-5.
7. Richards BW, Jones FR Jr, Younge BR, et al. Causes and prognosis in 4,278 cases of paralysis of the oculomotor, trochlear, and abducens cranial nerves. *Am J Ophthalmol*. 1992;113(5):489-96.
8. Kasoff I, Kelly DL Jr. Pupillary sparing in oculomotor palsy from internal carotid aneurysm. Case report. *J Neurosurg*. 1975 Jun;42(6):713-7.
9. Kissel JT, Burde RM, Klinge TG, et al. Pupil-sparing oculomotor palsies with internal carotid-posterior communicating artery aneurysms. *Ann Neurol*. 1983 Feb;13(2):149-54.
10. Saito R, Sugawara T, Mikawa S, et al. Pupil-sparing oculomotor nerve paresis as an early symptom of unruptured internal carotid-posterior communicating artery aneurysms: three case reports. *Neurol Med Chir (Tokyo)*. 2008 Jul;48(7):304-6.
11. Akagi T, Miyamoto K, Kashii S, et al. Cause and prognosis of neurologically isolated third, fourth, or sixth cranial nerve dysfunction in cases of oculomotor palsy. *Jpn J Ophthalmol*. 2008 Jan-Feb;52(1):32-5.
12. Adams ME, Linn J, Yousry I. Pathology of the ocular motor nerves III, IV, and VI. *Neuroimaging Clin N Am*. 2008 May;18(2):261-82.
13. White JB, Layton KF, Cloft HJ. Isolated third nerve palsy associated with a ruptured anterior communicating artery aneurysm. *Neurocrit Care*. 2007;7(3):260-2.
14. Aiba T, Fukuda M. Unilateral oculomotor nerve paresis associated with anterior communicating artery aneurysm rupture—two case reports. *Neurol Med Chir (Tokyo)*. 2003 Oct;43(10):484-7.
15. Asakura K, Tasaki T, Okada K. A case of unruptured anterior temporal artery aneurysm showing pupil-sparing oculomotor palsy. *No Shinkei Geka*. 1986 May;14(6):777-82.
16. Inamasu J, Nakamura Y, Saito R, et al. Early resolution of third nerve palsy following endovascular treatment of a posterior communicating artery aneurysm. *J Neuroophthalmol*. 2002 Mar;22(1):12-4.
17. Ahn JY, Han IB, Yoon PH, et al. Clipping vs coiling of posterior communicating artery aneurysms with third nerve palsy. *Neurology*. 2006 Jan;66(1):121-3.

## Connect With Patients... on their terms with the EyeDocApp!

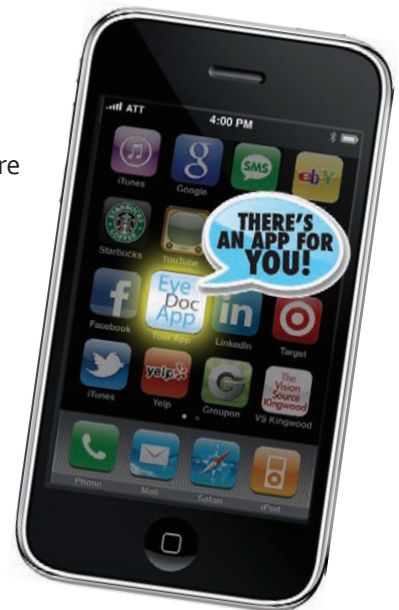EyeDocApp is the first customized mobile application designed specifically for eye care professionals. Now, your patients can instantly schedule appointments, share their experiences with others via Facebook and Twitter, access unique offers and updates about your practice, and much more!

EyeDocApp is an innovative and affordable way for eye care professionals to impact core business metrics such as:

- Higher Patient Retention
- Attracting New Patients
- Increasing Office Traffic

For a low monthly cost and one time set-up fee, your customized EyeDocApp bridges the communication gap between annual patient visits and adds that 'wow' factor to your business!

Visit [EyeDocApp.com](http://EyeDocApp.com) to Order Today! ←



Marketed exclusively by:



EyeDocApp

# Why We're Stuck on *Pseudomonas*

*Pseudomonas aeruginosa* is one of the most feared pathogens in contact lens patients. But what makes it so dangerous? **By Paul M. Karpecki, O.D., and Diana L. Shechtman, O.D.**

**P***seudomonas aeruginosa* is a common inhabitant of soil, water and vegetation, and often is associated with bacterial infection secondary to a vegetation-related corneal insult.<sup>1</sup> In fact, several reports indicated that *Pseudomonas* was more likely to cause infection following a vegetation injury than fungal infiltrates.<sup>1</sup> *Pseudomonas* also has a relatively complex genetic makeup, which permits it to survive fairly easily in a variety of outdoor and indoor environments.<sup>2</sup>

In North America, the incidence of microbial keratitis (MK) secondary to *Pseudomonas* is 2.76 cases per 10,000 individuals a year.<sup>3</sup> However, when considering only contact lens wearers, this number increases dramatically to 13.04 cases per 10,000 individuals a year.<sup>3</sup> In other words, contact lens patients are more than nine times as likely to develop a *Pseudomonas* infection as those who don't wear contacts.

## Why CL Patients?

*Pseudomonas aeruginosa* is the most common bacterial cause of MK in contact lens wearers.<sup>4</sup> But, why is that? One of the primary explanations is that *Pseudomonas* bacteria adhere to contact lens surfaces more easily than many other pathogens.<sup>5</sup> More specifically, *Pseudomonas* bacteria often exhibit pili and flagella that can facilitate the adhesion processes.<sup>5</sup> Within 24 hours of exposure, *Pseudomonas* microbes typically form a biofilm with the contact lens, which causes permanent, irreversible surface adhesion.<sup>6</sup>

Complicating this association, there is a non-piliated *Pseudomonas aeruginosa* strain that easily can adhere to the contact lens surface as well. Some researchers believe that this occurs due to surface hydrophobicity.<sup>2</sup> (In short—the more hydrophobic the lens surface, the more likely the bacteria are to adhere.)

For several years, researchers suggested that increased lens wettability could help combat pathogen adhesion. However, more recent data indicated that, although certain surfactants yielded a small decrease in the binding rate of *Pseudomonas* bacteria, mean adhesion rates were not dramatically affected by contact lens surface wettability.<sup>7</sup> Further, it is worth mentioning that this underlying binding process leads to the development of not only MK, but also corneal inflammatory events, infiltrative keratitis, contact lens-related acute red eye and contact lens peripheral ulcers.<sup>8</sup>

## Topical Therapeutic Options

Given the virulence of *Pseudomonas aeruginosa*, an aggressive approach to therapeutic management is required. Contact lens patients who present with a grayish-white infiltrate, an overlying epithelial defect, a very inflamed eye, significant conjunctival injection, lid edema and an anterior chamber reaction often have MK secondary to *Pseudomonas*. These patients often will complain of an acute onset of significant pain, photophobia, discharge (sometimes only evident in the tear film under high magnification) and


decreased vision.

Patients who present with ulcers located within 1mm of the central axis, multiple infiltrates, large infiltrates (>3mm) or a history recent ocular surgery should be cultured. Furthermore, immunocompromised patients who exhibit atypical ulcers (e.g., in the presence of a hypopyon or that cause significant tissue loss) should be cultured immediately and referred to a corneal specialist.

Initiate treatment with a broad-spectrum bacteriocidal agent, such as a topical fluoroquinolone every 30 minutes to hourly while awake and q2h at night. In severe cases, a fortified antibiotic, such as tobramycin 12.5mg/ml should be alternated with the fluoroquinolone. Cycloplegic agents will help minimize pain and photophobia. Also, after the first 24 hours of treatment, tobramycin ointment may be applied overnight.

Although some corneal specialists advocate topical corticosteroids to manage the severe inflammation and potential scarring caused by MK, you should use these agents with caution. In fact, topical corticosteroids are only appropriate if you have positively identified the underlying organism, confirmed that the pathogen is susceptible to the selected antibiotic, and determined that the patient has exhibited significant improvement since the initiation of treatment. And, if you confirm that the causative bacteria are *Pseudomonas*, do not consider steroid use until the patient has had 72 hours of antibiotic therapy.

Other treatment options include amniotic membrane transplantation.



One study showed that this procedure was associated with immediate pain relief, lower density of the resultant corneal opacity and better uncorrected acuity at final follow-up.<sup>9</sup>

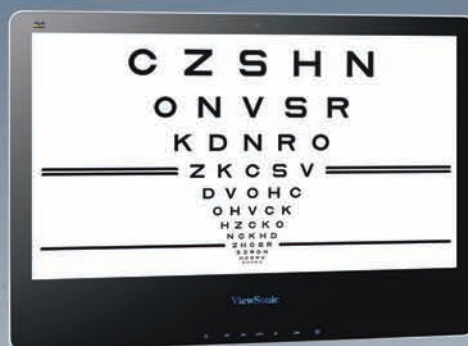Based on the research, there are many reasons to be concerned about *Pseudomonas aeruginosa* infections in your contact lens patients—especially as this bacterial strain continues to mutate and evolve. Fortunately, newer anti-infective agents—such as besifloxacin—have specific indications for *Pseudomonas* isolates.

Nonetheless, it is your job to make a prompt diagnosis of any suspected infection in a contact lens patient. Then, you should initiate an aggressive treatment approach that includes frequent follow-up and/or comanagement with a corneal specialist. This approach will help protect the patient from prolonged ocular discomfort as well as help facilitate a good visual outcome. ■

*Dr. Karpecki is a paid consultant and advisor to Bausch + Lomb and Bio-Tissue Inc. He has no direct financial interest in any of the products mentioned.*

1. Norina TJ, Raihan S. Microbial keratitis: aetiological diagnosis and clinical features in patients admitted to Hospital University Sains Malaysia. *Singapore Med J.* 2008 Jan;49(1):67-71.
2. Bruinsma GM, van der Mei HC, Busscher HJ. Bacterial adhesion to surface hydrophilic and hydrophobic contact lenses. *Biomaterials.* 2001 Dec;22(24):3217-24.
3. Jeng Bh, Gritz DC. Epidemiology of ulcerative keratitis in northern California. *Arch Ophthalmol.* 2010 Aug;128(8):1022-8.
4. Willcox MD, Holden BA. *Biosci Rep.* 2001 Aug;21(4):445-61.
5. Duran JA, Refojo MF. *Pseudomonas* attachment to new hydrogel contact lenses. *Arch Ophthalmol.* 1987 Jan;105(1):106-9.
6. Marshall KC. *Interfaces in Microbial Ecology.* Cambridge, Mass: Harvard University Press; 1976:156.
7. Tran VB, Sung YS, Copley K, et al. Effects of aqueous polymeric surfactants on silicone-hydrogel soft contact lens wettability and bacterial adhesion of *Pseudomonas aeruginosa*. *Cont Lens Anterior Eye.* 2012 Aug;35(4):155-62.
8. Szczotka-Flynn LB, Pearlman E. Microbial contamination of contact lenses, lens care solutions, and their accessories: A literature review. *Eye Contact Lens.* 2010 Mar;36(2):116-29.
9. Kheirkhah A, Tabatabaei A, Zavareh MK, et al. A controlled study of amniotic membrane transplantation for acute *Pseudomonas* keratitis. *Can J Ophthalmol.* 2012 Jun;47(3):305-11.

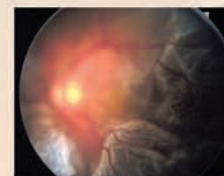# Total Refraction Satisfaction



**Acuity Pro V8**  
**Marco Integration**  
**Dual Monitor and Win 7 Compatible**

**Your Refractions Will Be Faster and More Accurate.**

**See All Options**  
**ACUITYPRO.COM 877-228-4890**



  
**Acuity Pro**  
**VisionScience Software**



# Product Review

## Diagnostic Testing

### TearScan


TearScan from Advanced Tear Diagnostics can provide a one-step ocular diagnostic test by measuring tear lactoferrin—the only available diagnostic biomarker to determine aqueous deficiency. The company believes that tear fluid holds the source material needed to identify aqueous deficient dry eye, assist in diagnostic differentiation between aqueous-deficient and evaporative dry eye, and develop effective treatments.

TearScan also provides data that enables the provider to grade the level of dry eye severity and monitor the effectiveness of treatment. The test, which uses reflectance photometry, takes approximately four minutes and provides measurements with 98% specificity, the company says.

Visit <http://teardiagnosics.com>.

### AdenoPlus

Need reassurance in differential diagnosis of conjunctivitis? A new in-office test may help. The FDA-approved, CLIA-waived AdenoPlus is now available in the United States. Using human tears on the inside of the lower eyelid, it detects adenovirus—which is responsible for 90% of all viral conjunctivitis and 25% of acute conjunctivitis cases.



A technician or physician can perform the test when a patient presents with a red eye or other symptoms of conjunctivitis. The simple four-step test has 90% sensitivity and 96% specificity, takes two minutes to complete, and provides a definite result in less than 10 minutes, according to the company.

Visit [www.nicox.com](http://www.nicox.com).

## Optical Design

### Video Monitors (Photo)

If you need to ramp up your sales in the optical, some new video monitors might help you catch more attention from customers. Eye Designs introduces video monitors to promote styles and brands, communicate current trends in fashions and increase product awareness to customers in the optical.



Displays with motion can increase sales by up to 317%, according to the Point of Purchase and Advertising Institute. As a product option for the Milan collection, Eye Designs currently offers video monitors preloaded with general marketing video content. Eye care professionals also can create and upload their own video content, which can be brand specific and tailored to their opticals.

Visit [www.eyedesigns.com](http://www.eyedesigns.com).

## Contact Lenses

### Astera Multifocal Toric

Launched at Academy 2012 Phoenix, the Astera multifocal toric soft lens from Alden Optical features dual elliptical stabilization for improved orientation and rotational stability, and center-near multifocal optics with large stabilized zones at near and distance. This unique approach to stabilization is available in custom prescriptions and multiple replacement cycles, including conventional, quarterly, bimonthly and monthly. Made with hioxifilcon D, Astera has a 54% water content and also is available without cylinder for spherical wearers who require custom lens prescriptions or designs.

Visit [www.aldenoptical.com](http://www.aldenoptical.com).



### iSee Ortho-k

Looking for an ortho-k lens to correct patients with high myopic powers? You might be able to use the new iSee lens from GP Specialists. It incorporates a more aggressive treatment zone that allows practitioners to treat



patients with higher degrees of myopia, thus increasing the number of likely candidates for ortho-k treatment, the company says.

iSee brand ortho-k lenses are FDA approved up to -3.00D, while extended powers are manufactured as doctor-customized designs. The company claims iSee's corneal reshaping design provides faster results and promotes healthy long-term wear for the patient.

Visit [www.gpspecialists.com](http://www.gpspecialists.com).

## Eyeglasses



### Leonardo Collection

If you have patients who are tired of carrying around multiple pairs of glasses for different tasks or activities, the Superfocus Leonardo collection might be an option for them. Users can adjust the focus on

these eyeglasses for clarity at any distance with an easy-to-use wheel located on the bridge of the frames.

To avoid distortion, blurriness or "jump" in the wearer's field of view, Superfocus lenses have no zones or lines. Currently, they are available in light or dark

tortoise and may be ordered with clear, tinted or Transitions front lenses.

Visit [superfocus.com](http://superfocus.com).

## Tablet App

### CV-Tablet

With the new CV-Tablet, you can have full wireless control of Topcon's CV-5000 automated phoropter and CC-100 digital chart directly from your Android or iPad. This unique app allows you to provide wireless subjective refraction, while giving you the flexibility to move to other exam rooms.

With the swipe of a finger, you can quickly import, export and print data from Topcon lensmeters, autorefractors and autokeratometers. The CV-Tablet incorporates all refractive tests and visual acuity formats, including LogMar, decimal and feet.

Visit [www.topcon-medical.com](http://www.topcon-medical.com).



## Frames

### Sean John Fall/Winter 2012 Collection

With a variety of patterns, stripes and diagonals, the fall/winter 2012 Sean John eyewear collection has a linear theme. Patterns are milled down into the double-laminate zyl temples to reveal the second color beneath, giving the frames some depth and dimension.



**SJ2056**

pattern of stripes and diagonals decorate the zyl temples, revealing contrasting color accents. This studious-looking frame is available in black, gray, brown and navy.

• SJ1037. The metal temples on this classic frame are highlighted with a cutout linear pattern, adding contrast. The style is offered in



**SJ2053**

masculine hues, such as gunmetal, brown, olive and black.

• SJ2053. This feminine zyl frame comes in rich hues of red, navy, black and brown that complement its soft rectangular shape.

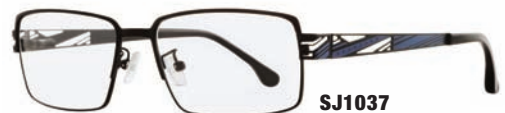Visit [www.marchon.com](http://www.marchon.com).



**SJ4058**

• SJ4058. The flat metal front gives this classic rectangular shape a more modern look. Colors include light gun, navy, brown and black.

• SJ2056. A linear



**SJ1037**

*Continued from page 56*

so that patients fully understand the fees. Also, the screening will permit the clinical staff to determine if the patient is indeed a surgical candidate. "We do not have this concern when a patient has already seen their optometrist. We still encourage comanagement, even if the patient bypassed their O.D. and came directly to our office," he says.

For Dr. Thimons, the most important part of comanagement occurs before the procedure. "Patient selection is the key reason for success or failure." Just last month, he turned down two patients interested in LASIK; other clinicians, he believes, may have given the green light. Concerns related to hyperopic correction, corneal steepness and pre-existing disease such as anterior basement membrane dystrophy, dry eye and forme fruste keratoconus, are all issues that can make or break a successful outcome. If properly managed, they pose no hindrance. But preoperative inattention to these factors can create postoperative complications and unhappy patients, he says.

At the one-day postoperative visit, Dr. Thimons checks to make sure that the LASIK flap is in the correct position, the surface epithelium is intact, the wound margins are healing and there are no underlying inflammatory issues. He also confirms that the uncorrected visual acuity meets expectations. "I am not concerned if vision is not perfect on day one, but I do want the patient to perceive the success of the procedure. This is often more of an encouragement visit for the patient." At this time, he also reviews temporary lifestyle restrictions, such as prohibitions

on swimming, gardening and heavy lifting.

At the two-week visit, Dr. Thimons evaluates corneal health and checks the refraction. If everything is on point, the patient is scheduled for a three-month follow-up. If not, he or she comes back in two weeks to be rechecked.

Fortunately, today's advanced, all-laser procedures have reduced the demand for subsequent retreatments. The need for enhancement procedures when using the Intralase (Abbott Medical Optics) femtosecond laser for flap creation has gone down to 1% to 5%, depending on refractive correction, Dr. Thimons says. Additionally, careful patient selection and realistic postoperative expectations also should diminish the need for enhancements.

At the two-week visit, Dr. Thimons spends time talking about the visual outcome. "We discuss what they can do now that wasn't possible before, such as driving without glasses, seeing the alarm clock in the morning and not worrying about contact lens care. This is an opportunity to teach patients about the process of laser vision correction. "There is some cheerleading involved, but it is mostly informative," he says. "Hopefully, they will talk to others about what a great experience it was."

At the three-month visit, he stresses that the cornea has changed, but not the retina or optic nerve. "I remind the patient they need to be seen on a yearly basis to assess the aspects of their ocular health that are related to their preoperative myopia."

## To the Future

Many promising advances in technology may impact the LASIK market in the near future. Dr. Thimons cites these four breakthroughs

on the horizon that may change the landscape of refractive surgery:

- LASIK has been limited in its ability to provide near-point correction, Dr. Thimons says. One new technology in clinical trials that addresses this is an inlay with pinholes called Kamra (AcuFocus) that's implanted under the LASIK flap. "This would be a major step forward. A number of patients decline LASIK because of limits in near-vision correction."

- Collagen crosslinking, which strengthens the cornea up to 200x its pretreatment level, effectively removing the risks of ectasia in patients with thin corneas or early keratoconus.

- Currently, IOL technology is evolving faster than LASIK. There may come a point when younger patients will more routinely opt for clear lens extraction and IOL implantation instead of LASIK, since it addresses both distance and near vision, Dr. Thimons says. New technologies may allow doctors to routinely reduce the age for lens replacement surgery to into the fourth and fifth decades to address the onset of presbyopia.

- Topography-guided laser vision systems, now under FDA review, would allow surgeons to design an ablation profile completely unique to the patient, improving results for patients with irregular corneas and other surface abnormalities. This technology may be on the market as early as 2014.

Despite the downturn in the economy, LASIK can still remain an important part of an optometric practice. With the advent of new technology, refractive surgery may yet reach the pinnacle it once enjoyed in the culture and in the clinic. ■

## ENRICH YOUR PRACTICE

OUR FLAGSHIP TITLE, *REVIEW OF OPTOMETRY*, IS THE MARKET'S LEADING RESOURCE FOR ALL OF YOUR OPTOMETRY NEEDS.

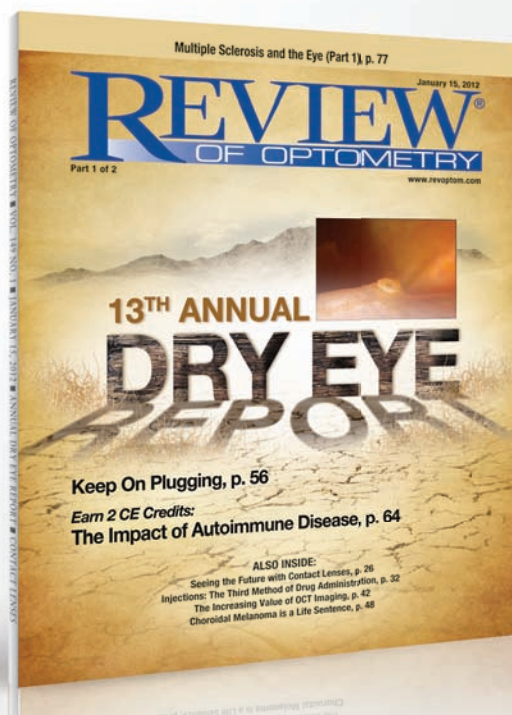
*Review of Optometry* is your primary source for ground-breaking clinical information as well as timely news, market trend information and continuing education programs.

*Review of Cornea & Contact Lenses* serves as a valuable resource for all practitioners and features detailed articles focusing on various fitting methods, solutions and corneal cases. Also available is the *Review of Cornea & Contact Lenses "Annual Contact Lenses & Lens Care" Guide*, a yearly publication detailing the newest lenses and lens care products.

The *Review* Group's *Ophthalmic Product Guide* brings you the newest and most innovative products on the market. Published every February and July, the guide provides concise information about new literature, drugs and equipment designed to help your practice thrive.

The *Review* Group also offers valuable **Continuing Education** sessions in both print and online formats, allowing a convenient way for you to earn **CE credits**. In addition, *Review* also offers an impressive fleet of **free e-newsletters**, such as Optometric Physician, the Optometric Retina Society quarterly e-newsletter and the Optometric Glaucoma Society E-Journal so you can keep up to date on breaking news and the latest research online.

*The Review Group is dedicated to the constant growth and education of the profession. Review offers many different publications and services to help enhance your practice and patient care.*



On top of these products, the *Review* Group also spearheads meetings and conferences, bringing together experts in the field and providing a forum for practitioners to earn CE credits and learn from others in the profession.

[www.revoptom.com](http://www.revoptom.com)



Jobson Medical Information LLC  
Review Professional Publications Group

## November 2012

■ **30-Dec. 2.** *New Technology & Treatments in Vision Care East Coast.* Loews Hotel Philadelphia. Hosted by: *Review of Optometry*. Meeting chair: Paul Karpecki, O.D. CE hours: 15. Contact Lois DiDomenico at [ReviewMeetings@jobson.com](mailto:ReviewMeetings@jobson.com) or (866) 658-1772. Visit [www.revoptom.com/conferences](http://www.revoptom.com/conferences).

## December 2012

■ **1-2.** *Glaucoma Grand Rounds Program with Live Patients.* Western University College of Optometry, Pomona, Calif. Email [ceoptometry@westernu.edu](mailto:ceoptometry@westernu.edu) or call (909) 706-3493. Visit [www.westernu.edu/optometry-continuing-education](http://www.westernu.edu/optometry-continuing-education).

■ **1-2.** *29th Annual Cornea, Contact Lens & Contemporary Vision Care Symposium.* The Westin Memorial City, Houston, Texas. Hosted by: University of Houston College of Optometry. CE hours: 16. Email [optce@uh.edu](mailto:optce@uh.edu) or call (713) 743-1900. Visit <http://ce.opt.uh.edu/live-events/cccls2012>.

■ **1-2.** *2012 MOA Annual Convention and Continuing Education Forum.* Hyatt Regency Baltimore. Hosted by: Maryland Optometric Association. CE hours: 12. Email [moa@assnhqtrs.com](mailto:moa@assnhqtrs.com) or call (410) 727-7800. Visit [www.marylandeyes.com](http://www.marylandeyes.com).

■ **7-9.** *2012 Fall Congress.* Hilton Sedona Resort & Spa, Sedona, Ariz. Hosted by: Arizona Optometric Association. CE hours: 16. Contact Kate Diedrickson at [kate@azoa.org](mailto:kate@azoa.org) or (602) 279-0055. Visit [www.azoa.org](http://www.azoa.org).

■ **14-15.** *3rd Annual West Coast Optometric Glaucoma Symposium.* Fairmount Newport Beach, Newport Beach, Calif. Hosted by: *Review of Optometry*. Meeting chair: Murray Fingeret, O.D. CE hours: 12. Contact Lois DiDomenico at [ReviewMeetings@jobson.com](mailto:ReviewMeetings@jobson.com) or (866) 658-1772. Visit [www.revoptom.com/conferences](http://www.revoptom.com/conferences).

■ **23-30.** *Christmas Week Cruise 2012: Current Trends in Contemporary Optometry.* Norwegian Cruise Line sailing from New Orleans. Presented by: Edward L. Paul, Jr., O.D., Ph.D. CE hours: 12. Email [info@drtravelinc.com](mailto:info@drtravelinc.com) or call (800) 436-1028. Visit [www.drtravel.com/optometristsSeminars.html](http://www.drtravel.com/optometristsSeminars.html).

## January 2013

■ **11-13.** *AZOA 2013 Bronstein Contact Lens and Cornea Seminar.* Doubletree Paradise Valley Resort, Scottsdale, Ariz. Hosted by: Arizona Optometric Association. CE hours: 16. Contact Kate Diedrickson at [kate@azoa.org](mailto:kate@azoa.org) or (602) 279-0055. Visit [www.azoa.org](http://www.azoa.org).

■ **12.** *2013 Glaucoma Symposium.* Willows Lodge, Woodinville, Wash. Chaired by: Howard Barneby, M.D., and Murray Fingeret, O.D. Visit [www.pacificu.edu/optometry/ce](http://www.pacificu.edu/optometry/ce).

■ **12-14.** *24th Annual Berkeley Practicum.* DoubleTree Hotel, Berkeley Marina, Berkeley, Calif. Hosted by: University of California, Berkeley, School of Optometry. CE hours: 20. Email [optoCE@berkeley.edu](mailto:optoCE@berkeley.edu) or call (800) 827-2163. Visit <http://optometry.berkeley.edu/ce/berkeley-practicum>.

■ **18-19.** *High Performance Vision/Sports Vision Consulting Weekend.* Hollywood Beach Marriott, Hollywood, Fla. Contact Don Teig, O.D., at [contact@ultimateeventslc.com](mailto:contact@ultimateeventslc.com) or (203) 312-3123. Visit [www.ultimateeventslc.com](http://www.ultimateeventslc.com).

■ **19-20.** *Gold Coast Educational Retreat.* Hyatt Regency Pier 66, Ft. Lauderdale, Fla. Hosted by: Broward County Optometric Association. CE hours: 17. Email [browardeyes@gmail.com](mailto:browardeyes@gmail.com) or visit [www.browardeyes.org](http://www.browardeyes.org).

■ **20-26.** *30th Annual Island Eyes Conference.* Hyatt Regency Maui, Hawaii. Hosted by: Pacific University College of Optometry. CE hours: 25. Contact Jeanne Oliver at [jeanne@pacificu.edu](mailto:jeanne@pacificu.edu) or (503) 352-2740. Visit [www.pacificu.edu/optometry/ce](http://www.pacificu.edu/optometry/ce).

■ **26-28.** *58th Annual Kraskin Invitational Skeffington Symposium on Vision.* Hyatt Regency Bethesda, Bethesda, Md. Hosted by: The Institute for Behavioral Optometry. Contact Chairman Jeffrey Kraskin, O.D., at [jkraskin@rcn.com](mailto:jkraskin@rcn.com) or (202) 363-4450. Visit <http://skeffingtonsymposium.org>.

■ **30-31.** *Seeing is Believing 2013.* Virtual Conference. Time: 2 p.m.–10 p.m. (EST). Faculty: Alan Glazier, O.D., Gary Gerber, O.D., Neil Gailmard, O.D., Nate Bonilla-Warford, O.D., Cheryl Murphy, O.D., and more. Contact Michael Porat at (347) 618-0784 or [michael@sibconference.com](mailto:michael@sibconference.com). Visit [www.sib2013.com](http://www.sib2013.com).

## February 2013

■ **6.** *IOA Winter Seminar.* Ritz Charles, Carmel, Ind. Hosted by: Indiana Optometric Association. Email [blsims@ioa.org](mailto:blsims@ioa.org) or call (317) 237-3560. For more information, visit [www.ioa.org](http://www.ioa.org).

■ **6-7.** *MOA Winter Seminar.* Kellogg Hotel & Conference Center, East Lansing, Mich. Hosted by: Michigan Optometric Association. Contact Amy Possavino at [amy@themoa.org](mailto:amy@themoa.org) or (517) 482-0616. Visit [www.themoa.org](http://www.themoa.org).

■ **8-10.** *3rd Annual Final Eyes CE.* Baptist Hospital Conference Center, Jacksonville, Fla. CE hours: 16. Contact Valerie Fernandez at [valerie.fernandez@bmcjax.com](mailto:valerie.fernandez@bmcjax.com) or call (904) 202-2080. Visit [FinalEyesCE.com](http://FinalEyesCE.com).

■ **12-14.** *The Eye Show London 2013.* London ExCeL International Exhibition Centre, United Kingdom. Hosted by: Emergexpo plc. CE hours: 18. Email [conference@theeyeshow.com](mailto:conference@theeyeshow.com) or visit [www.theeyeshow.com](http://www.theeyeshow.com).

■ **15-17.** *52nd Annual Heart of America Contact Lens Society Contact Lens and Primary Care Congress.* Sheraton Kansas City Hotel and Crown Center, Kansas City, Mo. Contact Dr. Steve Smith at [registration@thehoacils.org](mailto:registration@thehoacils.org) or (918) 341-8211. Visit [www.hoacils.org](http://www.hoacils.org).

■ **16-20.** *SkiVision 2013.* Viceroy Snowmass Luxury Mountain Resort, Snowmass Village, Colo. CE hours: 23. Email [questions@skivision.com](mailto:questions@skivision.com) or call (888) SKI-2530. Visit [www.skivision.com](http://www.skivision.com).

■ **21.** *7th Central Jersey Optometric Seminar.* CentraState Medical Center, Freehold, N.J. Time: 7:00 p.m.–10:30 p.m. CE hours: 4. Contact William Potter, O.D., at [eyedoc2180@aol.com](mailto:eyedoc2180@aol.com) or (609) 947-8545. Visit <http://optometryonwest44th.webs.com>.



# Advertisers Index

■ **27-March 3.** *SECO International 2013.* Building A, Georgia World Congress Center, Atlanta. CE hours: 300+. Contact Bonny Fripp at [bfripp@secostaff.com](mailto:bfripp@secostaff.com) or (770) 451-8206, ext. 13. Visit [www.seco2013.com](http://www.seco2013.com).

■ **28-March 2.** *MOA Big Sky Conference.* Huntley Lodge, Big Sky Conference Center, Big Sky, Mont. Hosted by: Montana Optometric Association. Contact Executive Director Sue Weingartner at [sweingartner@rmsmanagement.com](mailto:sweingartner@rmsmanagement.com) or (406) 443-1160. Visit [www.mteyes.com](http://www.mteyes.com).

## March 2013

■ **3-8.** *27th Annual Eye Ski Conference.* The Lodge at Mountain Village, Park City, Utah. CE hours: 20. Contact Tim Kime, O.D., at [tandbkime@buckeye-express.com](mailto:tandbkime@buckeye-express.com). Visit [www.eyeskiutah.com](http://www.eyeskiutah.com).

■ **10.** *6th Annual Evidence Based Care in Optometry Conference.* BWI Marriott, Linthicum Heights, Md. Hosted by: Maryland Optometric Association and the Wilmer Eye Institute. Email [moa@assnhqtrs.com](mailto:moa@assnhqtrs.com) or call (410) 727-7800. Visit [www.marylandeyes.com](http://www.marylandeyes.com).

■ **14-17.** *International Vision Expo & Conference East 2013.* Jacob K. Javits Convention Center, New York, N.Y. CE hours: 350. Visit [www.visionexpoeast.com](http://www.visionexpoeast.com).

■ **16-17.** *7th Annual Conference on Comprehensive Eye Care.* The Sheraton Hotel, Niagara Falls, N.Y. Hosted by: PSS EyeCare. Featured speakers: Ron Melton, O.D., Randall Thomas, O.D., Paul Karpecki, O.D., and Deepak Gupta, O.D. CE hours: 18. Email [education@psseyecare.com](mailto:education@psseyecare.com) or call (203) 415-3087. Visit [www.psseyecare.com](http://www.psseyecare.com).

## April 2013

■ **13-14.** *5th Annual Symposium on Ocular Disease.* Crowne Plaza, Tyson's Corner, Va. Hosted by: PSS EyeCare. Featured speakers: Deepak Gupta, O.D., and Kimberly Reed, O.D. CE hours: 18. Email [education@psseyecare.com](mailto:education@psseyecare.com) or call (203) 415-3087. Visit [www.psseyecare.com](http://www.psseyecare.com).

■ **19-21.** *WFOA Spring Seminar 2013.* Hilton Sandestin Beach Golf Resort & Spa, Destin, Fla. Hosted by: West Florida Optometric Association. Contact Jennifer Major, O.D., at [wfoatreasurer@gmail.com](mailto:wfoatreasurer@gmail.com). Visit [www.wfoameeting.com](http://www.wfoameeting.com).

■ **27-29.** *28th Annual Morgan/Sarver Symposium.* DoubleTree Hotel, Berkeley Marina, Berkeley, Calif. Hosted by: University of California, Berkeley, School of Optometry. CE hours: 20. Email [optoCE@berkeley.edu](mailto:optoCE@berkeley.edu) or call (800) 827-2163. Visit <http://optometry.berkeley.edu/ce/morgan-sarver-symposium>. ■

### To list your meeting, contact:

Colleen Mullarkey, Senior Editor

E-mail: [cmullarkey@jobson.com](mailto:cmullarkey@jobson.com)

Phone: (610) 492-1005

**Accutome, Inc.**..... 8  
Phone ..... (800) 979-2020  
Fax..... (610) 889-3233

**Acuity Pro/VisionScience Software, Inc.** ..... 83  
Phone ..... (877) 228-4890 or  
..... (580) 243-1301  
Fax..... (580) 243-1377

**Alcon Laboratories** ..... 48, 52  
..... 69, 100  
Phone ..... (800) 451-3937  
Fax..... (817) 551-4352

**Bausch + Lomb** ..... 23, 26-27  
..... 35, 57  
Phone ..... (800) 323-0000  
Fax..... (813) 975-7762

**Keeler Instruments**..... 11, 45  
Phone ..... (800) 523-5620  
Fax..... (610) 353-7814

**Lombart Instruments** ..... 9  
Phone ..... (800) 446-8092  
Fax..... (757) 855-1232

**Luxvision**..... 55  
Phone ..... (888) 881-1122  
[info@luxvision.net](mailto:info@luxvision.net)  
[www.LUXVISION.com](http://www.LUXVISION.com)

**Marchon** ..... 13  
Phone ..... (800) 645-1300  
Fax..... (800) 544-1334

**Marco Ophthalmic**..... 14  
Phone ..... (800) 874-5274  
Fax..... (904) 642-9338

**Merck Sharp & Dohme Corp.**  
..... 18 A-B, 66 A-B  
Phone ..... 1-800-NSC-MERCK  
..... (1-800-672-6372)

**NicOx, Inc.**..... 99  
Phone ..... (214) 346-2913  
[www.nicox.com](http://www.nicox.com)

**Reichert Technologies**  
..... 5, 29  
Phone ..... (888) 849-8955  
Fax..... (716) 686-4545

**Rhein Medical** ..... 19  
Phone ..... (800) 637-4346  
Fax..... (727) 341-8123

**The Alliance** ..... 21  
Phone ..... (888) 466-8263  
[www.thealliancebg.com](http://www.thealliancebg.com)

**Three Rivers Optical** ..... 25  
Phone ..... (800) 756-2020  
Fax..... (800) 756-0034

**ThromboGenics Inc.** ..... 7  
Phone ..... (732) 590-2901

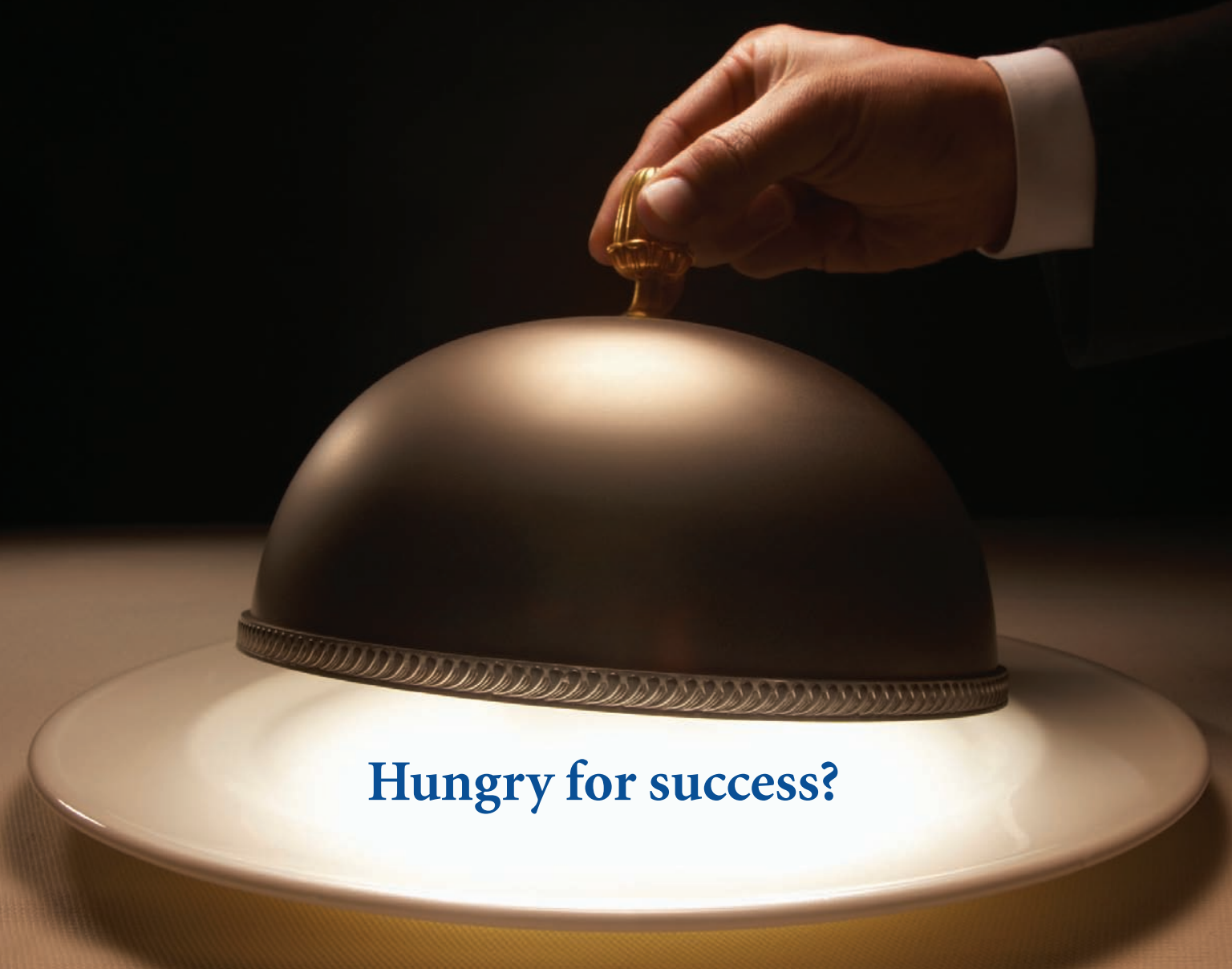**Veatch**..... 39, 41, 43  
Phone ..... (800) 447-7511  
Fax..... (602) 838-4934

**Visionix, Inc.** ..... 33  
Phone ..... (800) 292-7468  
Fax..... (770) 889-8445  
[www.visionix.com](http://www.visionix.com)

**Vistakon** ..... 2-3  
Phone ..... (800) 874-5278  
Fax..... (904) 443-1252

**Vmax Vision, Inc.**..... 17  
Phone ..... (888) 413-7038  
[Info@VmaxVision.com](mailto:Info@VmaxVision.com)  
[www.VmaxVision.com](http://www.VmaxVision.com)

*This advertiser index is published as a convenience and not as part of the advertising contract. Every care will be taken to index correctly. No allowance will be made for errors due to spelling, incorrect page number, or failure to insert.*



## Hungry for success?

At Jobson, we have more effective ways for you to reach the optical market than anyone. So our approach to serving clients is unique. First, we develop a thorough understanding of your specific goals. This understanding, plus our extensive offering of products and services, enables us to then suggest solutions that will help achieve those goals. This often includes innovative ideas and premium positions. For advertising information contact Michele Barrett (610-492-1014, [mbarrett@jobson.com](mailto:mbarrett@jobson.com)) or Jim Henne (610-492-1017, [jhenne@jobson.com](mailto:jhenne@jobson.com)). Let us satisfy your hunger for success.

**REVIEW**<sup>®</sup>  
OF OPTOMETRY

*Review of*  
Cornea & Contact Lenses

**REVIEW**<sup>®</sup>  
OF OPTOMETRY  
[www.revoptom.com](http://www.revoptom.com)

**REVIEW**<sup>®</sup>  
of Ophthalmology  
[www.revophth.com](http://www.revophth.com)

**Jobson**  
Optical Group

**The vision to help you succeed**

Merchandise Offered

**FREE DESIGN SERVICE**  
 SHOP FOR 2000+ DISPLAY & FURNITURE PRODUCTS AT  
**WWW.FRAMEDISPLAYS.COM**

**Frame Displays.com**  
**1-877-274-9300**

Frame Displays USA 22821 Silverbrook Center Dr., Suite 140, Sterling, VA 20166 • 1-703-435-7770 • www.framedisplays.com • info@framedisplays.com  
 Frame Displays CANADA 67 Mowat Ave, Suite 309, Toronto, ON M6K 3E3 • 416-877-7415 • www.framedisplays.ca • info@framedisplays.com

**REVIEW**  
 OF OPTOMETRY

Do you have Products and Services to offer?

**CLASSIFIED ADVERTISING WORKS**

Contact us today for classified advertising:  
 Toll free: **888-498-1460**  
 E-mail: **sales@kerhgroup.com**



**www.eyewear4less.com**

**TIRED OF RISING FRAME PRICES?**

**MAXIMIZE YOUR PROFIT**

**FRAME BUYERS - VIEW OUR COLLECTIONS**

**BRAND NAME EYEWEAR AT 40 TO 80% OFF LIST PRICE**

**YOUR PRACTICE YOUR PROFITS**

**1-800-294-4127**

**Products and Services**

**ACCESS**   
 HEALTHCARE CAPITAL

Access Healthcare Capital is your key to practice financing. Specialized loans tailored to meet your professional practice needs. We specialize in the Optometry Field with over 75 years of combined management, ownership, and financing. Let us help you realize your dream!

- 100% Financing plus Working Capital
- Practice Acquisitions
- Practice Start Ups
- Partnership Buy-In Programs
- Practice Improvements & Equipment
- Fixed Rate Terms up to 15 years
- Flexible Payment Options

**www.accesshealthcarecapital.com • info@narxeye.com**

Access Healthcare Capital • 1-888-727-4470 • P.O. Box 349, Gladwyne, PA 19035

**Merchandise Offered**

**NEW!**

**ON THE RISE!**

Not Your Average Frame Risers

**NEW!**

Frame Towers

Optical Platforms

opticaldisplays.com™

- Solid Glossy White Bases
- Brushed Aluminum Components
- Modern Sleek Design
- Showcases Frames with Minimum Distractions

Aluminum Frame Risers Shown OD418

00-11101

**Practice For Sale**

**Practice Consultants**

Practice Sales • Appraisals • Consulting  
www.PracticeConsultants.com

**PRACTICES FOR SALE  
NATIONWIDE**

Visit us on the Web or call us to learn more about our company and the practices we have available.

info@PracticeConsultants.com  
**800-576-6935**

**www.PracticeConsultants.com**

Place Your Ad Here!

Toll free: **888-498-1460**

E-mail: **sales@kerhgroup.com**

**Products and Services**

*Are you STILL asking people to place hot towels on their eyes and scrub their lashes with baby shampoo?*

**Excellent... There's a lot of science behind it: this works!**

Introducing **EYE-PRESS™** Self-heating, REUSABLE warm compresses for the eyes, pre-moistened with baby shampoo & natural lavender extract...

- INSTANT, Temperature-controlled, Steady-state heat that won't burn the eyes
- pH-controlled soap-free hypo-allergenic baby shampoo
- Refreshing Natural Lavender Scent
- Convenient, Hygienic, Safe, & EFFECTIVE!
- FDA cleared, patented technology

**#1 effective treatment for:**

- Sties & Chalazia
- Blepharitis
- Meibomian-gland Dysfunction

**#1 supplement to artificial tears for dry eyes**

- Promotes outstanding ocular hygiene

**Now available online and nationwide at Rite-Aid!**

For samples or to order for your own office shelf, please call (855) EYE-7377  
www.eyepress.com

**Equipment and Supplies**



**OPTINOMICS**  
Pretesting Solutions

It's What the Best  
Pretest on!  
**(800) 522-2275**  
www.optinomics.com  
sales@optinomics.com

**Professional Opportunities**

**STAFF OPTOMETRIST**

Bard Optical is a leading vision care organization based out of Peoria, IL with 19 offices throughout central IL. Once again this year we were named to the Top 50 Optical Retailers in the United States by Vision Monday – currently ranking 37th.

Currently we are accepting cv/resumes for our Canton, Springfield, Peoria and Sterling offices. Candidates must have an Illinois license with therapeutics. The practice includes (but is not limited to) general optometry, contact lenses, and geriatric care. Salaried, full-time positions are available with excellent growth programs and benefits.

Email to [hr@bardoptical.com](mailto:hr@bardoptical.com).

*Come grow with us.*

Bard Optical is a proud Associate Member of the Illinois Optometric Association.



[www.bardoptical.com](http://www.bardoptical.com)



**FOR CLASSIFIED  
ADVERTISING  
CONTACT US  
TODAY:**

Toll free: **888-498-1460**  
E-mail: [sales@kerhgroup.com](mailto:sales@kerhgroup.com)

**Equipment and Supplies**

**YES YOU CAN STILL GET THEM!!!**  
Humphrey HARK 599 with Glare – Lens Analyzer 350 & 360  
ECA has calibration systems, loaners and units in stock!



HUMPHREY 599  
w/Glare

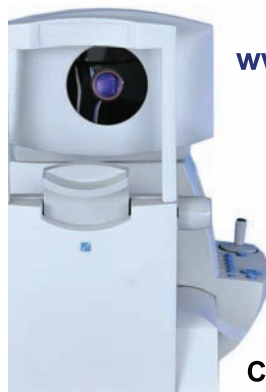LENS  
ANALYZER

**800-328-2020**  
[www.eyecarealliance.com](http://www.eyecarealliance.com)

Refurbished Units with  
Warranties In Stock

Full Repair and  
Refurbishment Services

**CALL FOR A FREE ESTIMATE**

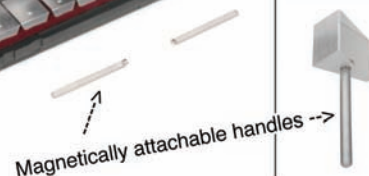

We will also buy your HARK 599 and LA 350/360 - Call for a quote today!

**NEW! Stick Prism Set with Magnetically Attachable Handles**

Patented, magnetically attachable handles for ophthalmic and other medical devices.

The handles permit much easier and less cumbersome counter-top storage, transport, and use than devices with permanently attached handles. Initially, the handles



are available for Gulden's prism sets used during vision exams with patients.

**Visit our new website search "11L23"**

**Gulden Ophthalmics**  
time saving tools  
800-659-2250 [www.guldenophthalmics.com](http://www.guldenophthalmics.com)

Do you have Equipment  
and Supplies for Sale?



Contact us today for classified advertising:  
Toll free: **888-498-1460** • E-mail: [sales@kerhgroup.com](mailto:sales@kerhgroup.com)

Continuing Education

*Seminars In Paradise™*  
**President's Week Cruise**  
**Royal Caribbean's Oasis of the Seas**  
 February 16 - 23, 2013

Sailing from Ft. Lauderdale, FL



**COPE**  
 Dr. TRAVEL, LLC  
 is a COPE approved provider

**Expanding the Scope of Primary Care (12 CE)**  
 presented by  
**Blair Lonsberry, MS, OD, MEd, FAAO**

**Cruise Prices from \$984' pp / dbl. - Seminar \$595\***  
*\*Please add \$371.42 to cover port charges, taxes, fees, and all tips / \*When purchased together with the cruise*

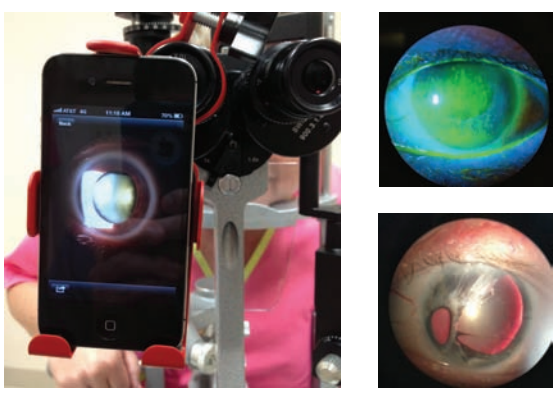
**4<sup>th</sup> Of July Week (June. 30 - July. 7, 2013) - Western Mediterranean**  
**Norwegian Cruise Line's Epic - Roundtrip Barcelona**  
**Retinal Disease Seminar - Diana L. Shechtman, OD, FAAO (16 CE)**

**800 436 1028      Dr. TRAVEL, LLC      DrTravel.com**



Equipment and Supplies


**iPhone Slit Lamp Adapter**

- High resolution anterior segment photography with the convenience of the iPhone!
- Compatible with iPhone 3G, 3GS, 4, and 4S
- Quickly swing away for normal slit lamp use when not taking pictures



- Great for corneal ulcers, epithelial defects, retroilluminate of cataracts and more!
- Full adjustability for multiple slit lamp models



**\$249.95 + S&H**


**www.iExam.com**

Continuing Education



**Final Eyes CE**  
 North Florida's Largest  
 Continuing Education  
 Event for Eye Doctors

**2013 Annual Final Eyes CE Event**  
*Jacksonville, Florida*  
**Friday, February 8, 2013**  
 Golf tournament  
 TPC-Sawgrass  
 Dinner Reception

**Saturday and Sunday, February 9-10, 2013**  
*Dupont Conference Center*  
 Baptist Hospital  
 800 Prudential Drive  
 Jacksonville, FL 32207

Golf is limited to the first 24 entrants and is included with the cost of registration for the entire event.

*Final Eyes CE provides courses with CME, COPE and 6 hours of TQ credit.*

**CONTACT & REGISTER**  
 Valerie Fernandez, CME Coordinator  
 Baptist Health  
 904.202.2080 • 904.202.2331 (fax)  
 valerie.fernandez@bmcjax.com  
 To download the Final Eyes  
 CE Registration Form, go to:  
[www.FinalEyesCE.com](http://www.FinalEyesCE.com)

Final Eyes CE's Mission is to provide quality education for eye care professionals including Ophthalmologists and Optometrists.

**REVIEW**  
 OF OPTOMETRY

Targeting  
 Optometrists?

**CLASSIFIED  
 ADVERTISING  
 WORKS**

Contact us today for  
 classified advertising:  
 Toll free: **888-498-1460**  
 E-mail: [sales@kerhgroup.com](mailto:sales@kerhgroup.com)



Frames



# National Lens

America's Leading Discount Lens and Frames Distributor  
 Phone: 1-866-923-5600 • Fax 1-866-923-5601 • www.national-lens.com



October 2012	Low	Lower	Lowest	2012	Low	Lower	Lowest
Color	1 to 5	6 to 10	11 & over	Cooper Vision	1 to 5	6 to 10	11 & over
IMPRESSIONS COLOR Available in Rx!	19.95	19.75	18.95	AVAIRA	18.95	17.95	15.45
Alcon	1 to 5	6 to 10	11 & over	BIOFINITY	24.50	22.50	20.50
AIR OPTIX AQUA	26.50	26.00	23.75	BIOFINITY TORIC	36.00	34.00	32.00
AIR OPTIX FOR ASTIGMATISM	36.95	35.95	32.95	BIOMEDICS XC, 38% & 55%	16.15	13.95	11.75
AIR OPTIX MULTIFOCAL	42.95	41.95	39.95	BIOMEDICS PREMIER	16.15	13.95	12.95
AIR OPTIX NIGHT & DAY AQUA	41.25	39.95	38.75	EXPRESSION OPAQUE-PLANO	21.95	20.95	19.96
DAILIES AQUA COMFORT PLUS 90	38.92	35.95	32.95	PROCLEAR	22.92	21.00	19.25
FRESHLOOK COLORS/COLORBLENDS	CALL	CALL	CALL	Johnson & Johnson	1 to 5	6 to 10	11 & over
Bausch & Lomb	1 to 5	6 to 10	11 & over	ACUVUE OASYS	22.50	21.75	19.95
PUREVISION 2 HD	30.95	28.50	26.95	ACUVUE OASYS FOR ASTIGMATISM	23.95	23.50	22.95
SOFLENS 38	14.50	12.75	11.75	ACUVUE 2	15.00	14.75	14.25
SOFLENS ONE DAY 90 PACK	33.50	32.50	29.95	ACUVUE ADVANCE	18.25	17.75	17.50
SOFLENS 59	9.25	8.95	8.75	ACUVUE 1 DAY MOIST 90 PACK	47.95	47.25	44.75

Please call for prices on Ophthalmic Lenses      **\*\*FREE SHIPPING\*\***      Please call for a full product and price list  
**We'll Meet or Beat Any Competitors Price on Any In Stock Lens**

**SOFTWARE**



**QUIKEYES ONLINE**  
**WEB-BASED OPTOMETRY EHR**

- \$99 per month after low cost set-up fee
- Quick Set-Up and Easy to Use
- No Server Needed
- Corporate and Private OD practices
- 14 Day Free Demo Trial
- Users Eligible for 44K incentives

[www.quikeyes.com](http://www.quikeyes.com)



**SOFTWARE**

Secure Access Anytime  
 EHR Certified  
 Industry Experts







**Web-based Platform**  
**Certified Complete Exam Module**  
**Secure & Scalable**

800.788.3356  
[www.eyecom3.com](http://www.eyecom3.com)

**REVIEW**  
OF OPTOMETRY

Looking to  
increase sales?

**Place Your Ad here.**

Contact us today for  
classified advertising:

**888-498-1460**

E-mail: [sales@kerhgroup.com](mailto:sales@kerhgroup.com)

Do you have Equipment  
and Supplies for Sale?

**REVIEW**  
OF OPTOMETRY

Contact us today for classified advertising:

Toll free: **888-498-1460**

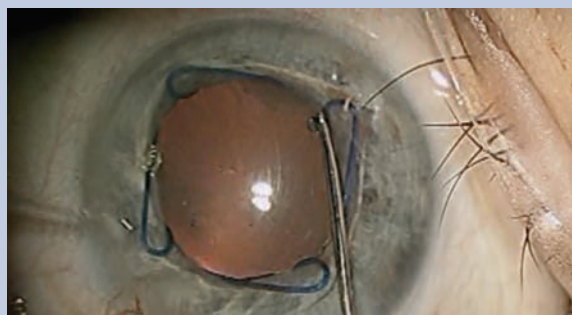
E-mail: [sales@kerhgroup.com](mailto:sales@kerhgroup.com)



## Small Pupils in Cataract Surgery

The Malyugin Ring can ensure complete dilation, helping to reduce peri- and intraoperative complications.

By Derek N. Cunningham, O.D., and  
Walter O. Whitley, O.D., M.B.A.



Using the Malyugin Ring to maintain good pupil dilation helps the surgeon avoid iris trauma, capsular tear/rupture and vitreous loss. Photo/video courtesy of John Sheppard, M.D.



Go to [www.revoptom.com](http://www.revoptom.com) or scan the QR code at left to see video footage of the procedure.

On The Web >> View a narrated video of Malyugin Ring placement in a cataract patient.

Small pupils can increase the risk of complications during and after any surgical procedure, and should be documented on the referral notes. A pupil that fails to dilate can yield a poor capsulotomy, which makes cataract removal more difficult and might result in iris trauma, anterior capsular tear, posterior capsular rupture, vitreous loss, increased inflammation, irregular pupil shape and photophobia.

Inadequate dilation often is seen in patients with intraoperative floppy iris syndrome (IFIS), pseudo-exfoliation syndrome, uveitis, posterior synechiae, trauma or previous intraocular surgery.<sup>1</sup> Take note that certain medications, such as Flomax (tamsulosin, Boehringer Ingelheim), increase the risk of IFIS. Hallmark signs of IFIS include limited preoperative pupil dilation, iris stromal billowing, iris prolapse and pupillary constriction during cataract surgery.

There are several steps that can help minimize the risk of IFIS and ensure adequate dilation:

- **Pharmaceuticals.** Therapeutic agents with strong anti-cholinergic drops (atropine 1%), non-steroidal anti-inflammatory drops and preservative-free lidocaine with epinephrine used intracamerally can maximize dilation.

- **Intraoperative techniques.** Manual separation and stretching of the iris breaks the adhesions between the iris, the lens capsule and the cornea (synechiolysis).<sup>2</sup> Also, high-viscosity ophthalmic viscosurgical devices can help enlarge the pupil. Adjustments can be made to the flow settings dur-

ing phaco to lower the risk of iris incarceration.

- **Surgical devices.** Pupil expansion devices, including iris hooks and the Malyugin Ring (MicroSurgical Technology), permit adequate views of intraocular structures. Currently, there are several pupil-expanding devices on the market. This month's Surgical Minute video will illustrate the use of the Malyugin Ring.

The Malyugin Ring is a useful tool for phacoemulsification surgery. It's a one-piece design that exhibits a square shape and four equidistantly located circular loops, which include a gap to accommodate the iris tissue. The device catches and holds the pupillary margin steady, maximizes pupil dilation with eight touch points, is easy to insert and remove, protects the iris sphincter during surgery and allows the pupil to return to its normal shape, size and function after the operation.<sup>3</sup>

In both of our practices, surgeons prefer the Malyugin Ring to iris hooks because of easier insertion and removal, maximal pupil dilation (up to 7mm), fewer incisions (iris hooks require four additional paracenteses spaced 90° apart) and a lower risk of capsular tear. ■

1. Loden JC, Gayton JL, Snyder ME, et al. Cataract surgery in an eye with a small pupil. *Cataract Refract Surg Today*. May 2012. Available at: [http://bmctoday.net/crstoday/pdfs/crst0512\\_phacopearls.pdf](http://bmctoday.net/crstoday/pdfs/crst0512_phacopearls.pdf). Accessed November 9, 2012.


2. Malyugin B. Pupil issues in cataract surgery. *Cataract Refract Surg Today*. March 2012. Available at: [http://bmctoday.net/crstodayeurope/pdfs/0312CRSTEuro\\_Malyugin\\_Fundamentals.pdf](http://bmctoday.net/crstodayeurope/pdfs/0312CRSTEuro_Malyugin_Fundamentals.pdf). Accessed November 9, 2012.

3. MicroSurgical Technology. Products: Malyugin Ring. Available at: [www.microsurgical.com/our-products/malyugin-ring](http://www.microsurgical.com/our-products/malyugin-ring). Accessed November 9, 2012.



# CAN'T WAIT UNTIL NEXT MONTH?

Optometric Physician delivers **UP-TO-DATE** news and research to your inbox every Monday morning, allowing you to view all of the latest clinical information on a convenient and consistent basis.



Subscribing to Optometric Physician is an efficient and easy way to stay current with all of the information and events going on in the field. To order your free subscription, e-mail: [optometricphysician@jobson.com](mailto:optometricphysician@jobson.com) today.

Optometric  
Physician™



## Cut at the Root

By Andrew S. Gurwood, O.D.

### History

A 20-year-old black female presented for follow-up care after sustaining a blunt trauma injury to her right eye. The insult occurred approximately one month earlier.

A local hospital's emergency room staff and ophthalmology department managed the initial acute trauma associated with the injury. However, she switched practitioners because our office was closer to her house.

The patient explained that she had exhausted her supply of eye drops—one with a “red cap” and one with a “white cap”—and that her right eye felt achy.

Except for the traumatic injury, she had no documented ocular history and reported no allergies.

### Diagnostic Data

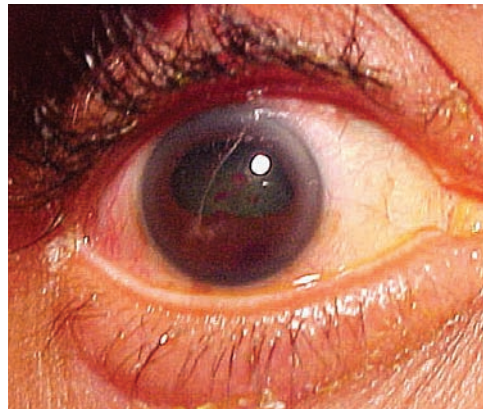
Her best-corrected visual acuity was 20/30 O.D. and 20/20 O.S. at both distance and near. Her extraocular muscle motilities were

normal, with no evidence of diplopia. However, she reported mild photophobia and pain upon right eye movement.

Confrontational fields were normal. There was no evidence of afferent pupillary defect; however, her right pupil had a pronounced “D shape.” Refraction improved her visual acuity to 20/25 O.D. and revealed the presence of mild myopia.

Biomicroscopic examination of the right eye uncovered grade 1 cell and flare with evidence of either old inflammatory synechia or impact pigmentation (Vossius' ring) on the anterior lens capsule.

Intraocular pressure measured 19mm Hg O.U. The dilated fundus findings were normal O.U. The pertinent external/anterior segment findings O.D. are illustrated in the photograph.



The right eye of our 20-year-old patient who suffered blunt trauma. What do you notice?

### Your Diagnosis

How would you approach this case? Does this patient require any additional tests? What is your diagnosis? What's the most likely prognosis?

To find out, please visit [www.revoptom.com](http://www.revoptom.com). Click on the cover icon for this month's issue, and then click “Diagnostic Quiz” under the table of contents. ■

**Retina Quiz Answers** (from page 77): 1) d; 2) d; 3) d; 4) a.

### Next Month in the Mag

Our December issue features the Dispensary Report. Topics include:

- *Properly Prescribe Prism for Binocular Vision Disorders*
- *Learn to Plan an 'Optical Trunk Show'*

Also in December:

- *'New Look' Office Design Contest*

### Feedback

*Review of Optometry* welcomes questions and comments. E-mail Jack Persico, editor-in-chief, [jpersico@jobson.com](mailto:jpersico@jobson.com), with “Letter to the Editor” as the subject line.

Or, write to *Review of Optometry*, 11 Campus Blvd., Suite 100, Newtown Square, PA 19073.

REVIEW OF OPTOMETRY (ISSN 0147-7633) IS PUBLISHED MONTHLY, 12 TIMES A YEAR BY JOBSON PUBLISHING LLC., 100 AVENUE OF THE AMERICAS, NEW YORK, NY 10013-1678. JOBSON PUBLISHING LLC, A WHOLLY-OWNED SUBSIDIARY OF JOBSON MEDICAL INFORMATION, LLC. PERIODICALS POSTAGE PAID AT NEW YORK, NY AND ADDITIONAL MAILING OFFICES. POSTMASTER: SEND ADDRESS CHANGES TO REVIEW OF OPTOMETRY, PO BOX 2025, SKOKIE, IL 60076. SUBSCRIPTION PRICES: US: ONE YEAR \$56; TWO YEARS \$97, CANADA: ONE YEAR \$88, TWO YEARS \$160, INT'L: ONE YEAR \$209, TWO YEARS \$299. FOR SUBSCRIPTION INFORMATION CALL TOLL-FREE (877) 529-1746 (USA ONLY); OUTSIDE USA, CALL (847) 763-9630 OR FAX (847) 763-9631. PUBLICATIONS MAIL AGREEMENT NO: 40612608. CANADA RETURNS TO BE SENT TO BLEUCHIP INTERNATIONAL, P.O. BOX 25542, LONDON, ON N6C 6B2.



# Follow the Evidence.

Nicox Ophthalmic Diagnostics is leading eye care in a new direction—where diagnostic evidence is the standard. With the introduction of an innovative platform of cutting-edge diagnostic tests and best-in-class service and training, Nicox is advancing clinical practice beyond traditional diagnostic approaches.

Learn more about where we are going.  
Call **1.855.MY.NICOX** or visit **[nicox.com](http://nicox.com)**



**Ophthalmic Diagnostics**

# Experience **TRIPLE-ACTION CLEANING** for your contact lenses.

Clean contact lenses are key to comfortable lens wear, and CLEAR CARE® Cleaning and Disinfecting Solution has Triple-Action Cleaning.

SEE HOW  
IT WORKS



Deep cleans



Loosens dirt



Enhances  
protein removal

CLEAR CARE® Cleaning and Disinfecting Solution is great for people who:

- Have sensitive eyes
- Have solution-related allergies
- Experience build-up on their lenses

YOU CAN  
SEE IT  
WORKING!

