



SUPPLEMENT TO

NOVEMBER 2010

REVIEW OF OPTOMETRY

www.revoptom.com

▶▶ Clinical Application of Electrodiagnostic Testing

*By Julie K. Hutchinson, O.D.,
and Andrew S. Gurwood, O.D., F.A.A.O., Dipl.*

▶▶ Retinal Venous Occlusions: A Systematic Review and Update on Current Treatment Options

By William D. Kress, O.D.

THE 7TH ANNUAL GUIDE TO

RETINAL DISEASE

▶▶ PHP Technology: A New Concept in Monitoring AMD

*By Steven Ferrucci, O.D., F.A.A.O.,
and Jay M. Haynie, O.D., F.A.A.O.*

▶▶ Genetic Advancements in AMD: A Glimpse at the Future

By Mark T. Dunbar, O.D., F.A.A.O.



THE 7TH ANNUAL GUIDE TO

RETINAL DISEASE

This year's Annual Guide to Retinal Disease includes:

- **Clinical Application of Electrodiagnostic Testing, pg. 4**

*By Julie K. Hutchinson, O.D.,
and Andrew S. Gurwood, O.D., F.A.A.O., Dipl.*

Electrodiagnostic testing is often an overlooked and underutilized tool for diagnosing and monitoring several diseases of the optic nerve, macula and retina. Such testing may also be helpful in differentiating subclinical retinal pathologies from functional vision loss.

Here, Drs. Hutchinson and Gurwood review several different forms of electrodiagnostic testing as well as discuss how these tests can help clinicians diagnose several devastating retinal conditions, such as retinitis pigmentosa, Best's disease and Stargardt's disease.

- **PHP Technology: A New Concept in Monitoring AMD, pg. 8**

*By Steven Ferrucci, O.D., F.A.A.O.,
and Jay M. Haynie, O.D., F.A.A.O.*

Age-related macular degeneration is a leading cause of severe vision loss and legal blindness in patients older than 65 years of age. Fortunately, earlier disease detection with advanced technologies, such as preferential hyperacuity perimetry, will help give your AMD patients an opportunity to maintain functional vision throughout life.

"One critical factor in the successful management of AMD is early monitoring to help detect the onset of neovascular AMD as soon as possible, when lesions are still relatively small and visual acuity is not greatly affected," explain Drs. Ferrucci and Haynie. Therefore, "The Foresee PHP preferential hyperacuity perimeter (Reichert Technologies) was designed specifically to monitor dry AMD patients for the early development of choroidal neovascular membrane (CNV)."

- **Retinal Venous Occlusions:
A Systematic Review and Update on
Current Treatment Options, pg. 12
(earn 1 CE credit)**

By William D. Kress, O.D.

Retinal vein occlusion (RVO) is one of the most common acquired retinal vascular diseases in adults. It is your duty to correctly identify the ocular manifestations of retinal venous occlusion, educate your patients on the associated findings, consider indicated laboratory testing, and provide appropriate treatment and management options based upon documented clinical evidence.

Here, Dr. Kress discusses the risk factors, symptoms and pathophysiology of RVO as well as several management considerations and treatment options.

- **Genetic Advancements in AMD:
A Glimpse at the Future, pg. 18**

By Mark T. Dunbar, O.D., F.A.A.O.

Anti-VEGF therapy is the current standard of care for the treatment of wet AMD. But, even as remarkable as anti-VEGF treatment is, there are some drawbacks.

Fortunately, current and ongoing genetic research has helped us to better understand the intricate disease processes associated with dry AMD development. In the very near future, these findings may ultimately lead to the production of several cutting-edge pharmaceutical agents that specifically target the genes responsible for macular degeneration.

"Even though it may be several years before we actually know if any of these drugs work, it appears that we have taken a giant step forward in combating, or even completely curing, age-related macular degeneration," Dr. Dunbar concludes.

Clinical Application of Electrodiagnostic Testing

By Julie K. Hutchinson, O.D., and Andrew S. Gurwood, O.D., F.A.A.O., Dipl.

THE HUMAN RETINA is a complex, nine-layered neurosensory structure that converts electromagnetic light energy (photons) into electrical energy. These signals are conveyed to the cerebral cortex via the visual cortex in the occipital lobe (Brodmann's areas 17,18,19) for visual interpretation. Phototransduction and visual processing is a complicated chain of events that is carried out within histologically and physiologically complex neural tissue.^{1,4}

The neurosensory retina's outermost layer (in proximity to the retinal pigment epithelium [RPE]) is comprised of the photoreceptors (rods—scotopic vision, cones—photopic vision). The photoreceptors are responsible for absorbing streams of photons that come from sources of electromagnetic energy in the environment (i.e., light). The collection of these photons by the photoreceptive elements of the neurosensory retina causes a photochemical/electrical conversion within those cells. The photoreceptor cells synapse in the outer retina with a bipolar cell, which synapses with a ganglion cell in the inner retinal layer. Supporting neuronal cells, such as amacrine cells, horizontal cells, glial cells and Müller cells, interdigitate with this neuronal pathway, enabling parallel processing.¹ An energy cascade shuttles from the outer retinal layers (closest to the RPE) to the inner retinal layers (closest to the vitreous) through these main and supporting retinal neurons before being bottlenecked into the visual pathway via the bundled axons of ganglion cells known as the optic nerve. The optic chiasm, optic tract and geniculocalcarine radiations complete the non-pupillary visual pathway, which terminates in the occipital cortex.

Each retinal layer is subspecialized for phototransduction. The outer retinal layers contain the cell bodies of photoreceptor cells, which mainly, via an opsin pigment (rhodopsin in rods and scotopsin in cones), absorb light photons. Specialized molecules within the rods and cones catalyze complex biochemical events enabling the conversion of light to electrical energy.¹

Phototransduction is a metabolically

expensive event that requires active support from the RPE layer. While the RPE has many physiological functions (e.g., serves as an insulator for capturing light, dissipates heat), one of its most important roles is to phagocytize photoreceptor outer segments—a metabolic process that is continuously required as light-absorbing opsin-containing organelles are damaged beyond repair throughout the course of a single day.^{1,3}

Photon absorption causes a variable flux of potassium and sodium ions across the photoreceptor/retinal pigment epithelial membrane through transmembrane active transport pumps, causing hyper- or depolarization of the membrane.⁴ This constant movement of charged molecules creates a variable standing electrical charge that can be measured with appropriate electrodiagnostic instruments.

Once the initial event of energy conversion occurs in the outer nuclear layer, the photoreceptors' axons carry the signal to the outer plexiform layer where the first synapses occur with the dendrites of the bipolar, amacrine, Müller or horizontal cells.¹ Bipolar cells communicate directly with photoreceptor cells, primarily via release of glutamate neurotransmitters and are involved in signal modification via "ON" and "OFF" channels.^{1,5} Separate pathways are involved in specialized processing of illumination, color, motion and fine detail.¹

The terminal retinal synapses occur in the inner plexiform layer where the axons of the bipolar, amacrine, Müller or horizontal cells communicate and transmit their signals to the dendrites of the ganglion cells. Specialized mid- and parasol ganglion cells enable higher-order processing and recognition of color, movement and form.

The axons of the ganglion cells form the optic nerve, which transmits information to the lateral geniculate nucleus (LGN) via the optic chiasm. The geniculocalcarine radiations continue the transmission to the occipital cortex.

The neurosensory retina is referred to as a "duplex retina" due to differences in the electropotential that is

generated along the membrane of the rods and cones.² This inherent duplicity combined with discrepancy in number (roughly 100 million rods vs. five million cones) and distribution throughout the retinal tissue makes the structure amenable to electrodiagnostic testing.²

Electrooculogram

The electrooculogram (EOG) is an electrodiagnostic test with limited diagnostic application. The EOG is performed by placing recording electrodes on the skin adjacent to the lateral canthi and reference electrodes adjacent to the medial canthi.^{6,7} Patients are asked to make multiple sets of swift horizontal saccades between fixation targets under both photopic and scotopic conditions.⁶⁻¹⁰ The EOG approximates the difference between the electrical potential of the retina (negative charge) and the cornea (positive charge).^{7,10} This effectively estimates the resting voltage of the retina.⁹ Interestingly, the "resting" potential of the RPE is not a static voltage; instead, it oscillates, reaching peaks in photopic conditions and lows during scotopic conditions.⁶

The diagnostic outcome of the EOG is the Arden ratio, which is defined as the ratio of the highest resting amplitude measured in "light" to the lowest resting amplitude in "dark."^{6,9} Because different physiology should be occurring when a retina is exposed to conditions which are "light" and "dark," an expected ratio between the measurement of the resting retinal voltages compared to resting voltage of the RPE in light and dark can be anticipated. Arden ratio norms vary somewhat across the literature, but "normal" is generally considered 1.8 or greater with borderline data falling between 1.6 and 1.8.^{6,7,10} An Arden ratio below 1.6 generally signifies that the physiology that creates the resting voltages across the retina, as compared to the resting voltages in the RPE in light and dark conditions, is performing below the standard.^{6,7}

Because the EOG quantifies the standing potential between the outer

retina and underlying RPE, its results can be affected whenever the RPE is “sick” or damaged.¹⁰ When the RPE is altered, its standing potential will be altered and thus the signal amplitudes and Arden ratio will be diminished.¹⁰

Because the test itself is, in part, a function of the contraction of the extraocular muscles, the process must be monitored carefully. Over- or under-shooting saccades may cause the EOG waveform to be inaccurate.⁶ Other variables, such as electrode misplacement; anatomical variants; and even ingestion of certain chemicals, including ethyl alcohol, hyperosmotic agents, and carbonic anhydrase inhibitors (CAIs), have the potential to cause skewed or non-reproducible results.^{6,11}

The EOG is commonly helpful in diagnosing Best’s disease, adult-onset vitelliform dystrophy, fundus flavimaculatus and the pattern dystrophies.⁶⁻¹⁴ The EOG is not considered a test of first choice. It should only be ordered following an initial electroretinogram (ERG) in patients with a suspected macular dystrophy.⁸ It may also be ordered to assess individuals who are suspected of being genetic carriers of certain macular dystrophies.⁹

Electroretinogram

Full-field ERG (ffERG) tests evaluate the sum of the retina’s electrical responses to a light stimulus.^{4,7,15} More focused algorithms, including focal ERG (fERG), multi-focal ERG (mfERG) and pattern ERG (pERG), allow detailed functional assessments of specific retinal locations.^{4,7,15}

In ERG testing, a recording electrode is placed on an anesthetized cornea and a reference electrode is grounded to the skin at the orbital rim or forehead.^{4,15} Patients adapt to the desired luminance (dark vs. light adaptation) and then are asked to view stimuli of varying intensity, duration and pattern. The electrical signal captured from the retina is amplified and recorded as the ERG waveform.

ffERG tests evaluate rod and cone function. They summarize the response of both neuronal and non-neuronal retinal cells (excluding ganglion cells).⁴ ERG testing specifically targets the rod or cone system depending on the stimulus that is used and the background illumination upon which the fixation target is superimposed.

There are three standard scotopic

Common Ocular Pathologies and Common Electrodiagnostic Findings

Disease	Test	Results indicating positive diagnosis
Retinitis pigmentosa ^{7,8}	ERG	Delayed cone implicit time progressing to markedly reduced rod/cone response to bright flash. Markedly reduced cone response to 30Hz.
Best’s ^{13,16}	EOG	Normal to severely decreased.
Adult vitelliform macular dystrophy ¹³	EOG	Normal to mildly decreased.
Pattern dystrophy ¹⁶	ffERG EOG xERG	Within normal limits or mildly impaired. Arden ratio borderline or abnormal. Variable response, depending on severity of presentation.
Rod-cone dystrophy ¹⁴	ERG	B-waves subnormal (rods). Peak times prolonged. Reduced amplitude of mixed b-waves. Subnormal response to 30Hz flicker. Subnormal a-waves. Subnormal or non-recordable oscillatory activity.
Stargardt’s ¹⁶	ERG EOG fERG/mfERG	Within normal limits or may show impaired rod/cone response. Arden ratio normal or reduced. Diminished or undetectable macular response.
Glaucoma ^{17,18}	pERG	Decreased amplitude. Asymmetric waveforms between the two eyes.
Ischemic optic neuropathy ¹⁹	PVEP, FVEP	Decreased amplitude.
Optic nerve demyelination ¹⁹	VEP PERG	Conduction delay. Reduced amplitude related to retinal ganglion cells.
Functional vision loss ^{7,23}	VEP	Normal findings.

responses elicited with ERG testing: a rod-only response secondary to the presentation of a dim flash; a rod-cone response secondary to the presentation of a white flash; and oscillatory potentials secondary to the presentation of a standard flash.⁴ Two photopic responses are elicited: a cone response secondary to the presentation of a white or red flash on a white background and the cone response from a 30Hz flicker stimulus.^{4,8}

Usable measurements include amplitude of the a- and b-waves, implicit time (time elapsed between stimulus presentation and peak amplitude) and overall shape of the waveform. The exact origin of each wave remains unclear, with presumed and speculative origins for each component described in the literature.^{4,7}

The a-wave on the ERG waveform is thought to be derived from photoreceptor inner segment activity, with both cones and rods contributing to the wave shape.^{4,7} B-waves are also thought to be formed by both rod and cone activity, with some passive contribution from the Müller cells.^{4,7} Oscillatory potentials can be recorded

in both scotopic or photopic conditions and are small “wavelets,” which are likely related to amacrine and bipolar cell activity.⁴ Decreased amplitude of these curves, diminished oscillatory potentials and prolonged implicit times can signify an abnormal result.

Because ffERG elicits a total retinal response, fERG, mfERG or pERG may be ordered to target specific areas of interest, including the macula and optic nerve.¹⁶⁻¹⁸ When abnormal waveforms are derived from these more specific test algorithms, one can more readily pinpoint pathologic anatomy and physiology, confirming clinical diagnoses.

ERG testing is widely used in diagnosing and monitoring patients with chorioretinal changes (see, “Common Ocular Pathologies and Common Electrodiagnostic Findings,” above), as well as in patients with reduced vision in the absence of fundus findings. New research has found pERG to be useful in identifying glaucoma suspects and in predicting visual field defect progression in glaucoma patients.^{17,18} (However, ERG testing it is not a substitute for standard perimetry

testing.^{17,18}) MfERG and pERG have also been used to assess optic nerve diseases, including optic neuropathies and demyelinating disease.¹⁷⁻¹⁹

Visual Evoked Potential

The visual evoked potential (VEP) is the only electrodiagnostic test capable of assessing cortical responses to visual stimuli.^{20,21} Because VEP assesses the response of the terminal component of the visual pathway, its outcomes may be affected by pathological changes located anywhere along the visual pathway.^{20,21} The VEP is obtained via cutaneous electrodes that are placed on the scalp overlying the occipital cerebral area.²⁰⁻²² Grounding and reference electrodes are also placed on the earlobes or skin of the forehead.^{20,21} Typically, a black-and-white, checkerboard stimulus pattern is presented to the patient. This specific pattern maximally elicits responses from three specific retinal ganglia cells: magnocellular (detects movement in space), parvocellular (integral in color and acuity perception) and koniocellular (detects form).^{20,22} Other visual targets include pattern-reversal, sweep, multifocal, motion and standard bright-flash stimuli.²⁰⁻²² Each target is specialized to assess a different component of cortical processing. For example, sweep VEP assesses the response to increasing spatial frequency and multifocal VEP maps out electrical responses and cortical magnification.²⁰

The VEP waveform that is derived from the test varies based on the stimulus presentation. Because of the variability of output depending on the stimulus used, there is no standard interpretation applicable to all VEPs.

VEP is not a first-line test. In fact, it has very specific applications. Because VEP may be abnormal with any defect along the entire visual pathway, electrodiagnostic tests that are better able to localize intraocular pathology are more preferable, such as the mfERG. VEP testing is often indicated in patients who are pre-verbal or pre-literate. It is also used when other diagnostic testing has been found to be within normal limits in the presence of a reduced visual condition or the persistent symptom of a visual disturbance.^{7,22-24}

Dark Adaptometry

Dark adaptometry measures threshold light sensitivity in dark-adapted patients.^{25,27} Patients are placed in a

dark room and the retina is bleached with a bright stimulus. An adaptometer then presents continuously dimmer stimuli for the patient to recognize as dark adaptation occurs.^{25,26} The end-point is the dimmest detectable stimulus, which, in healthy patients, is usually identified 35 to 40 minutes after initiation of standard paradigm testing.²⁵ The test may target different areas of the retina to assess any suspected variable degree of retinal disability.²⁵

The output of this testing is a curve that displays threshold stimulus luminance as a function of time. The curve has two distinct slopes, representing first the cones regaining sensitivity and then the rods more slowly regaining sensitivity.²⁶ It illustrates both cone and rod threshold as well as the point at which the rod system takes over in dark adaptation.²⁶ An abnormal curve is indicative of a posterior segment pathology and would reveal reduced rod and cone sensitivities and decreased slope, leading to an eventual flattening of the curve toward higher thresholds.

Dark adaptometry is useful in evaluating patients who present with complaints of night vision impairment. It is also indicated in assessing suspected cases of retinitis pigmentosa (RP), choroideremia and macular degeneration.^{25,27} Results also have been found to be reproducible and useful in tracking the progression of the aforementioned diseases.²⁸ One study indicated that dark adaptometry was useful in aiding clinicians in identifying patients with the earliest visual changes secondary to AMD.²⁷ The test may also reveal the first sign of central serous retinopathy. The dark adaptometry curve seems to become increasingly depressed as the condition evolves.²⁷

Electrodiagnostic testing is an often overlooked and underutilized, clinically efficacious tool for diagnosing and monitoring disease progression for multiple optic nerve, macular and retinal pathologies. These tests may also be helpful in differentiating subclinical retinal pathology from functional vision loss. Identification of facilities in the community that perform these tests as well as experts who can lend their experience to interpretation of the results can facilitate incorporation of electrodiagnostic testing into clinical practice. ■

Dr. Hutchinson is an adjunct associate professor at the University

of Missouri-St. Louis College of Optometry. Dr. Gurwood is professor of clinical sciences at the Eye Institute of the Pennsylvania College of Optometry at Salus University in Philadelphia. They acknowledge John Siegfried, Ph.D., for his expertise and input on this subject.

- Sharma RK, Ehinger BJ. Development and structure of the retina. In: Kaufman PL, Alm A, Adler's Physiology of the Eye: Clinical Application. St Louis: Mosby; 2003:319-47.
- Carr RE, Siegel IM. Fundamentals of electroretinography. In: Carr RE, Siegel IM. Electrodiagnostic testing of the visual system: a clinical guide. Philadelphia: FA Davis; 1990:3-8.
- La Cour M. The retinal pigment epithelium. In: Kaufman PL, Alm A, Adler's Physiology of the Eye: Clinical Application. St Louis: Mosby; 2003:319-47.
- Lam BL. Full-field electroretinogram. In: Lam BL. Electrophysiology of Vision: Clinical Testing and Applications. Boca Raton, Fla.: Taylor & Francis; 2005:1-64.
- Schubert HD. Structure and function of the neural retina. In: Yanoff M, Duker JS. Ophthalmology. Philadelphia, Mosby; 2009:511-4.
- Lam BL. Electro-oculogram. In: Lam BL. Electrophysiology of Vision: Clinical Testing and Applications. Boca Raton, Fla.: Taylor & Francis; 2005:1-64.
- Schwartz SH. Gross electrical potentials. In: Schwartz SH. Visual Perception: A Clinical Orientation. New York: McGraw Hill; 1999:337-54.
- Cleary TS, Reichel E. Electrophysiology. In: Yanoff M, Duker JS. Ophthalmology. Philadelphia: Mosby; 2009:545-9.
- Carr RE, Siegel IM. Electrical activity from the retinal pigment epithelium. In: Carr RE, Siegel IM. In: Electrodiagnostic Testing of the Visual System: A Clinical Guide. Philadelphia: FA Davis; 1990:50-5.
- Ridder WH, Siegfried JB. Clinical electroretinography. In: Benjamin WJ, Borish's Clinical Refraction. St Louis: Butterworth-Heinemann; 2006:611-22.
- Shinomiya K, Itsuki N, Kubo M, et al. Analyses of the characteristics of potential and cross-talk at each electrode in electro-oculogram. J Med Invest. 2008 Feb;55(2):120-6.
- Boon CJ, Klevering J, den Hollander AI, et al. Clinical and genetic heterogeneity in multifocal vitelliform dystrophy. Arch Ophthalmol 2010 Mar;125(3):1100-6.
- Booi JC, Boon CJ, van Schooneveld MJ, et al. Course of visual decline in relation to the Best1 genotype in vitelliform macular dystrophy. Ophthalmology 2010 Jul;117(7):1415-22.
- Burstedt MS, Ristoff E, Larsson A, et al. Rod-cone dystrophy with maculopathy in genetic glutathione synthetase deficiency. Ophthalmology. 2009 Feb;116(2):324-31.
- Carr RE, Siegel IM. Physiology of ERG activity. In: Carr RE, Siegel IM. Electrodiagnostic Testing of the Visual System: A Clinical Guide. Philadelphia: FA Davis; 1990:12-5.
- Lam BL. Macular disorders. In: Lam BL. Electrophysiology of Vision: Clinical Testing and Applications. Boca Raton, Fla.: Taylor & Francis 2005: 277-329.
- Ventura LM, Porciatti V. Pattern electroretinogram in glaucoma. Curr Opin Ophthalmol. 2006 Apr;17(2):196-202.
- Bowd C, Vizzeri G, Tafreshi A, et al. Diagnostic accuracy of pattern electroretinogram optimized for glaucoma detection. Ophthalmology. 2009 Mar;116(3):437-43.
- Holder GE. Electrophysiological assessment of optic nerve disease. Eye (Lond). 2004 Nov;18(11):1133-43.
- Lam BL. Visual evoked potential. In: Lam BL. Electrophysiology of Vision: Clinical Testing and Applications. Boca Raton, Fla.: Taylor & Francis; 2005:123-49.
- Carr RE, Siegel IM. Visual evoked cortical potentials. In: Carr RE, Siegel IM. Electrodiagnostic Testing of the Visual System: A Clinical Guide. Philadelphia: FA Davis; 1990:56-78.
- Diamond GR. Evaluating vision in preverbal and preliterate infants and children. In: Yanoff M, Duker JS. Ophthalmology. Philadelphia: Mosby; 2009:1309-12.
- Raghunandan A. The utility of clinical electrophysiology in a case of nonorganic vision loss. Optometry. 2008 Aug;79(8):436-43.
- Krasodomska K, Lubiński W, Potemkowski A, Honczarenko K. Pattern electroretinogram (PERG) and pattern visual evoked potential (PVEP) in the early stages of Alzheimer's disease. Doc Ophthalmol. 2010 Oct;121(2):111-21.
- Sieving PA, Caruso RC. Retinitis pigmentosa and related disorders. In: Yanoff M, Duker JS. Ophthalmology. Philadelphia: Mosby; 2009:550-9.
- Schwartz SH. Duplex nature of the retina. In: Schwartz SH. Visual Perception: A Clinical Orientation. New York: McGraw Hill; 1999:25-64.
- Jackson GR, Edwards JG. A short-duration dark adaptation protocol for assessment of age-related maculopathy. J Ocul Biol Dis Infor. 2008 Mar;1(1):7-11.
- Kiser AK, Mladenovich D, Eshraghi, et al. Reliability and consistency of dark-adapted psychophysical measures in advanced eye disease. Invest Ophthalmol Vis Sci. 2006 Jan;47(1):444-52.

PHP Technology: A New Concept in Monitoring AMD

By Steven Ferrucci, O.D., F.A.A.O., and Jay M. Haynie, O.D., F.A.A.O.

AGE-RELATED MACULAR DEGENERATION (AMD) is a primary cause of severe vision loss and legal blindness in patients who are older than 65 years of age. Current estimates indicate that nearly eight million Americans are in the intermediate stage of AMD.¹ Even more alarming, 1.3 million patients with intermediate AMD will progress to neovascular AMD within the next five years.¹

While new treatment options, such as photodynamic therapy (PDT), anti-angiogenic agents and anti-VEGF therapy, are now available, many neovascular AMD patients are still losing their vision. So, what's the explanation? One reason is that patients are presenting to the clinic too late—well after AMD has already caused significant damage to retinal function—which makes successful treatment far more difficult. In fact, several studies indicate that eyes with a smaller lesion size at the time of treatment exhibit better visual acuity two years after treatment than eyes with larger subfoveal lesions.²

Therefore, one critical factor in

the successful management of AMD is early monitoring to help detect the onset of neovascular AMD as soon as possible, when lesions are still relatively small and visual acuity is not greatly affected. Until recently, the Amsler grid has been the only tool available for self-monitoring. Numerous studies have confirmed the futility of the Amsler grid at detecting lesions in a timely fashion due to various limiting factors, including fixation, cortical completion and visual crowding.^{3,5} Furthermore, by the time the Amsler grid reveals metamorphopsia, the patient's condition has already progressed significantly.³

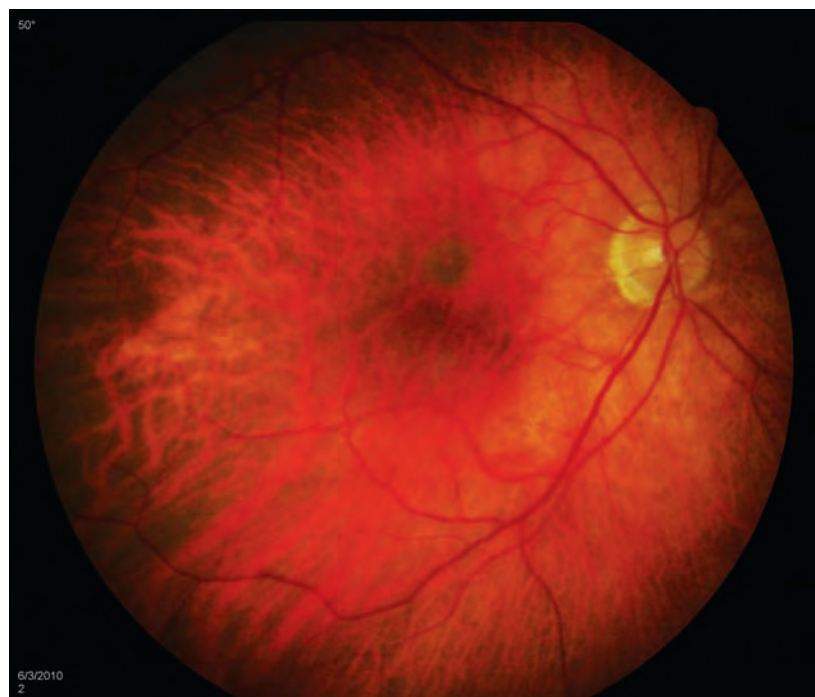Foresee PHP

To address some of the limitations associated with Amsler grid testing, the Foresee PHP preferential hyperacuity perimeter (Reichert Technologies) was designed specifically to monitor dry AMD patients for the early development of choroidal neovascular membrane (CNV). The Foresee PHP is an FDA-approved device that utilizes


hyperacuity, or Vernier acuity, which is the ability to perceive a minute difference in the relative spatial localization of two or more stimuli. This allows the Foresee PHP to determine when a patient begins to exhibit retinal or retinal pigment epithelium (RPE) elevation.^{6,7} A report is then generated, which indicates whether conversion from dry to wet AMD is suspected.

The Foresee PHP test consists of a series of white dots in a line on a black background that are flashed for 160 μ s across the central 14° of the subject's central visual field. These white dots would appear straight when presented to a healthy retina, but would be perceived as distorted or shifted when projected on a retinal lesion or elevation, as may be noted in patients with AMD.⁷

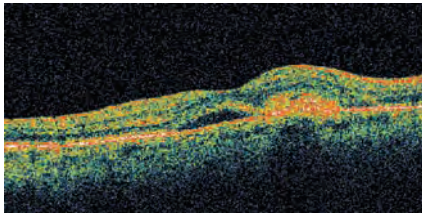
The subject is instructed to identify any perceived distortion in the dotted lines by touching the screen with a stylus. During the test, a series of artificial distortions—similar to those seen by subjects with AMD-related lesions—are displayed. These artificial distortions



1. Subtle gray thickening is seen superior nasal to the central fovea.



2. Foresee PHP (Reichert Technologies) reveals a dense scotoma in the patient's right eye.



3. Optical coherence tomography confirms thickening of the retinal pigment epithelium with adjacent subretinal fluid.

help to quantify the defect as well as check the reliability of the subject. The subject's responses are recorded and analyzed by a predetermined algorithm. Finally, the device generates a report, which indicates whether progression of AMD is suspected.

Several studies have indicated that the Foresee PHP has a greater sensitivity than the Amsler grid in detecting AMD-related lesions with a standardized protocol.⁸⁻¹⁰ The studies also confirmed the poor reliability of the Amsler grid in detecting neovascular AMD. Additionally, it has been documented that Foresee PHP is useful in detecting recent onset CNV (within 60 days), with high sensitivity, specificity and accuracy.¹¹ Furthermore, smaller lesions were detected in AMD patients who had relatively good vision, further supporting the contention that prompt treatment could result in better final visual acuity.¹¹

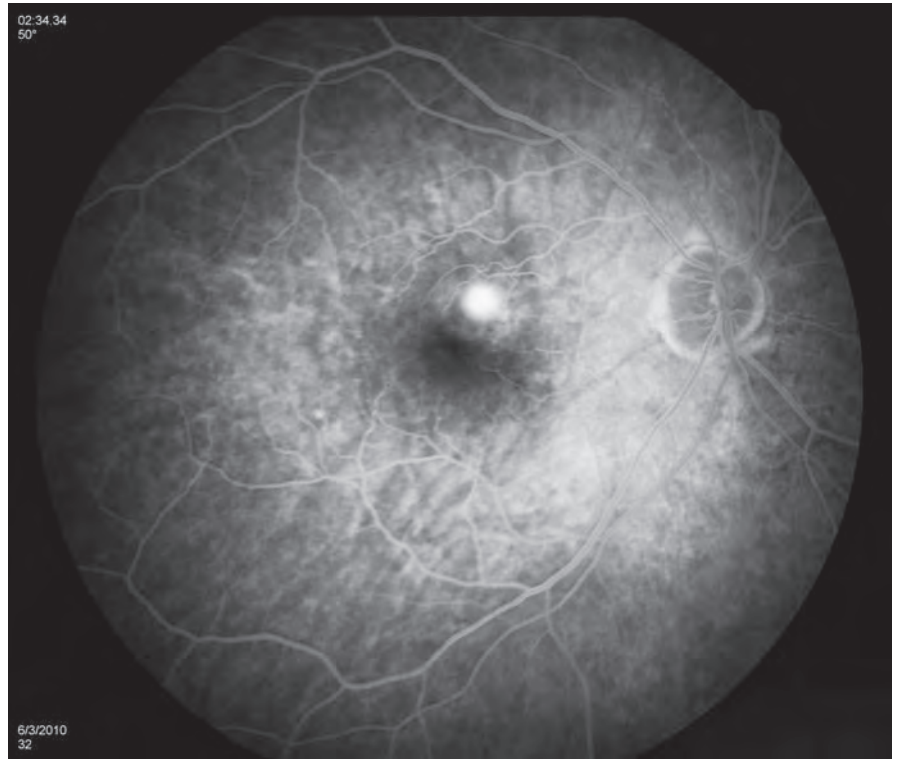
Here, we will discuss two case reports in which Foresee PHP helped to confirm our clinical findings in two patients with AMD.

Case Report 1

- **History.** A 77-year-old white male was referred for an evaluation after noting a "blurry spot with distortion" in his right eye that had persisted for the last four weeks. The patient's ocular history was significant for cataract surgery O.D. His medical history was significant for hypertension. Systemic medications included lisinopril and terazosin as well as various nutritional supplements.

- **Diagnostic data.** His visual acuity measured 20/20- O.U. Intraocular pressure was 8mm Hg O.D. and 10mm Hg O.S. Anterior segment examination was normal in both eyes. We noted a posterior chamber intraocular lens implant in the patient's right eye as well as moderate nuclear sclerotic cataract change in his left eye.

Dilated retinal examination revealed




4. Fluorescein angiography confirms a classic choroidal neovascular membrane that corresponds precisely to the metamorphopsia pattern seen on PHP.

a subtle gray thickening that was located in the superior nasal macula of the right eye (figure 1). There was no frank hemorrhage or obvious subretinal fluid.

Preferential hyperacuity perimetry showed a metamorphopsia pattern that corresponded with the area of gray thickening seen clinically (figure 2). We then performed optical coherence tomography, which confirmed an emerging choroidal neovascular membrane with mild subretinal fluid (figure 3), and intravenous fluorescein angiography (FA), which confirmed a classic choroidal neovascular membrane of the right eye (figure 4).

- **Treatment.** The patient was treated with intravitreal Avastin (bevacizumab, Genentech) and triamcinolone injections, which cleared the subretinal fluid, stopped the leakage that was seen on FA and reduced the metamorphopsia pattern that was seen on PHP (figure 5). Early diagnosis of the CNV complex followed by prompt treatment preserved retinal function and

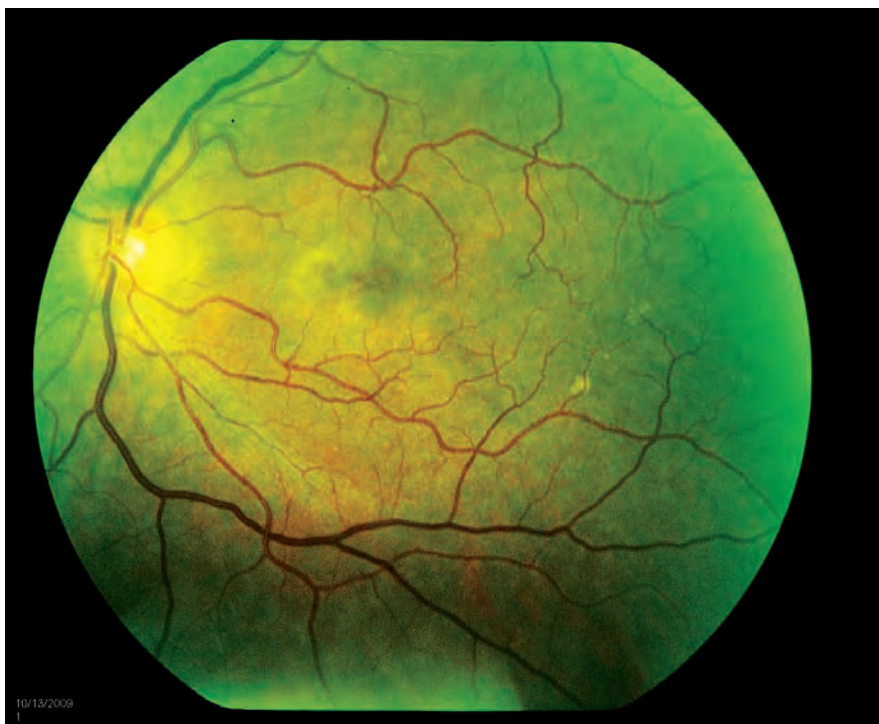

5. Post-treatment PHP shows some clearing of the original scotoma, which indicates preservation of retinal function.

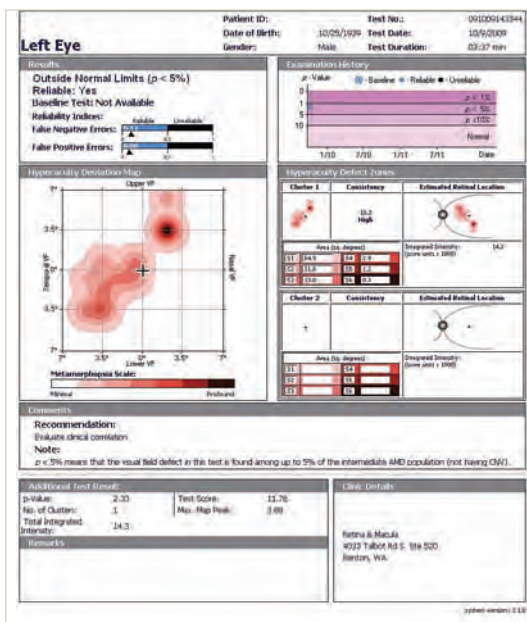
maintained 20/20 visual acuity in his right eye.

Case Report 2

- **History.** A 71-year-old white male presented with decreased vision in his left eye secondary to cataract development. His primary care optometrist



6. Retinal thickening in the nasal macula with a subtle hemorrhage.



7. PHP reveals a metamorphopsia pattern that corresponds to the area of retinal thickening.

referred him for a retinal examination before scheduling him for a cataract procedure. The patient reported seeing a “spot” in his left eye that had persisted for the last two weeks.

The patient’s ocular history was significant for early cataracts and macular degeneration. His medical history included hypertension, hyperlipidemia and asthma. Systemic medications

included lisinopril, lovastatin, Preservision Eye Vitamins (Bausch + Lomb), omega-3 fish oil capsules and vitamin D supplements.

• *Diagnostic data.* Visual acuity was 20/20 O.D. and 20/25 O.S. Intraocular pressure measured 17mm Hg O.U. Anterior segment examination was normal in both eyes. A grade I nuclear cataract was seen bilaterally.

Dilated retinal examination revealed a few macular drusen in both eyes as well as a small hemorrhage and adjacent retina thickening in the left eye (figure 6). Preferential hyperacuity perimetry showed a metamorphopsia pattern that corresponded with the area of retinal thickening, which suggested the presence of wet AMD (figure 7). Optical coherence tomography and FA revealed an occult choroidal neovascular membrane of the left eye (figures 8 and 9).

• *Treatment.* We treated the patient with intravitreal Avastin and triamcinolone injections, which cleared the subretinal fluid, stopped the leakage that was seen on FA and reduced the metamorphopsia pattern that was seen on PHP (figure 10). Additionally, we

A Home Version of PHP Testing

A home version of the PHP (ForeseeHome, Notal Vision) is also in clinical trials. It essentially uses the same preferential hyperacuity technology found in the office version, but has been modified to allow unsupervised use as a portable instrument. Clearly, the ability for patients to test themselves at home at any frequency, without having to come into a doctor’s office, has many advantages. One study revealed that the ForeseeHome demonstrated 85% specificity and sensitivity in patients with intermediate AMD or CNV.¹⁹ Limitations included the ability to operate a computer mouse, as well as a fairly high rate of false positives. However, it is hopeful that with increased use, these concerns would be minimized, allowing for better overall results.¹⁹ Long-term monitoring of patients who are at high-risk for AMD is currently underway.

noted normal retinal contour with complete resolution of the subretinal fluid on OCT six months after treatment (figure 11). Early diagnosis of the CNV complex followed by prompt treatment resulted 20/20 visual acuity in the patient’s left eye.

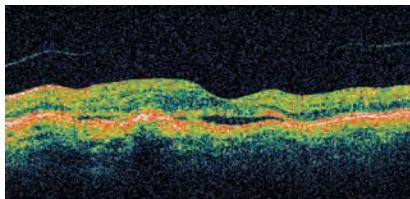
These two clinical cases have illustrated the benefit of Foresee PHP in confirming an early conversion from dry to wet AMD. Although the clinical signs of neovascular AMD will eventually blossom into visible hemorrhage that clinicians are well trained to identify, PHP technology has proven that cases of neovascular AMD can be detected without substantial visual change or clinical signs in the retina.

Further Discussion

CNV causes profound vision loss if left untreated. The lesions can increase 10µm to 18µm in size every day and will grow closer to the foveal center in more than half of documented cases.¹²⁻¹⁴ Therefore, early detection of a CNV—before it has caused acuity loss—is essential, as shown in our case examples.

One way to look for early progression is to perform dilated retinal examinations on a monthly basis. Obviously, however, this is scenario is neither practical nor cost effective. Because of these limitations, monitoring with the Foresee PHP is perhaps more advisable.

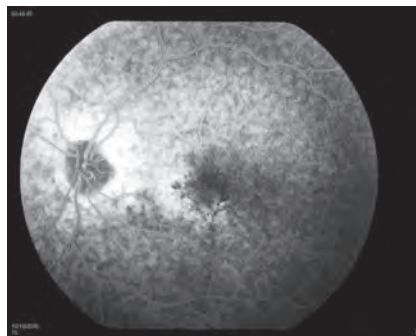
Many advocates of the PHP recommend baseline testing at the onset of intermediate AMD, followed by



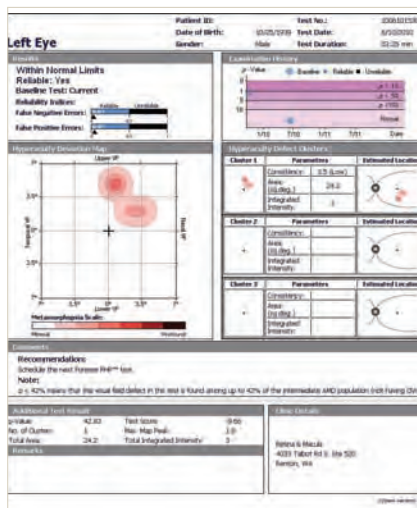
8. OCT shows an area of subretinal fluid.

serial testing on a quarterly basis. Some studies as well as clinical experience seem to indicate that such testing may diminish the need for FA in some patients who have persistent symptoms that are indicative of neovascular AMD development, such as metamorphopsia, when more conventional examinations reveal no obvious features.^{11,15,16}

Newer studies are also evaluating whether PHP technology has additional roles. One such study evaluated 17 patients before and after treatment with Lucentis (ranibizumab, Genentech) for neovascular AMD. The study demonstrated a correspondence between PHP results and macular morphology, indicating that PHP may



9. Fluorescein angiography reveals an occult choroidal neovascularization.



10. PHP reveals a reduced metamorphopsia pattern following treatment of the CNV.

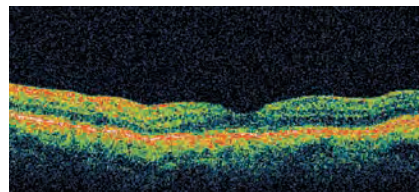
be helpful in monitoring responsiveness to anti-VEGF therapies used in the treatment of neovascular AMD.¹⁷ A second study evaluated whether PHP technology could detect retinal toxicity as a result of hydroxychloroquine or chloroquine usage.¹⁸ In patients with either known or suspected retinal toxicity, PHP technology demonstrated dense defects seen concomitantly with visual field testing and/or FA. No patients in the control group exhibited such defects.¹⁸

The socioeconomic impact of early detection has also been evaluated. One study estimated that Medicare-only related costs for a patient with severe visual impairment is approximately \$4,000 per year.²⁰ Based on population studies, there are approximately 50,000 AMD patients who have a second affected eye every year. With an average life expectancy of 10 years, the annual savings for Medicare only with early detection can be estimated to be \$2.25 billion.

When you also consider the significant deterioration in a patient's quality of life, which has been shown to be improved upon preservation of nominal acuity in the poorer eye, both the economic and personal savings are overwhelming.^{21,22}

As treatments for neovascular AMD continue to evolve, so too must the methods of detection. Earlier detection with instruments, such as the Foresee PHP and ForeseeHome, will help give our patients with neovascular AMD the opportunity to maintain functional vision throughout life. In all of the major studies that looked at treatments for neovascular AMD, lesion size was the single most important predictive factor of final visual acuity. In the not-so-distant future, technological advances in AMD detection will likely become an integral part of primary care in any optometric setting. ■

Dr. Ferrucci is chief of optometry and residency director at the Sepulveda



11. OCT six months after treatment. No subretinal fluid was noted.

VA Ambulatory Care Center & Nursing Home in California. He is on the speakers' bureau and advisory board for several companies, including Reichert Technologies, Alcon, Allergan, VSP and ZeaVision. Dr. Haynie is the executive clinical director at Retina & Macula Specialists in Tacoma, Wash. He has received honoraria from Reichert Technologies, Carl Zeiss Meditec and Notal Vision.

- Bressler NM, Bressler SB, Congdon NG, et al. Potential public health impact of Age-Related Eye Disease Study results: AREDS report no. 11. *Arch Ophthalmol*. 2003 Nov;121(11):1621-4.
- Photodynamic therapy of subfoveal choroidal neovascularization in age-related macular degeneration with verteporfin: one-year results of 2 randomized clinical trials--TAP report. Treatment of age-related macular degeneration with photodynamic therapy (TAP) Study Group. *Arch Ophthalmol*. 1999 Oct;117(10):1329-45.
- Fine AM, Elman MJ, Ebert JE, et al. Earliest symptoms caused by neovascular membranes in the macula. *Arch Ophthalmol*. 1986 Apr;104(4):513-4.
- Schuchard RA. Validity and interpretation of Amsler grid reports. *Arch Ophthalmol*. 1993 Jun;111(6):776-80.
- Achard OA, Safran AB, Duret FC, Ragama E. Role of the completion phenomenon in the evaluation of Amsler grid results. *Am J Ophthalmol*. 1995 Sep;120(3):322-9.
- Westheimer G. The spatial sense of the eye. Proctor lecture. *Invest Ophthalmol Vis Sci*. 1979 Sep;18(9):893-912.
- Enoch JM, Williams RA, Essock EA, Barricks M. Hyperacuity perimetry: assessment of macular function through ocular opacities. *Arch Ophthalmol*. 1984 Aug;102(8):1164-8.
- Goldstein M, Loewenstein A, Barak A, et al. Results of a multicenter clinical trial to evaluate the preferential hyperacuity perimeter for detection of age-related macular degeneration. *Retina*. 2005 Apr-May;25(3):296-303.
- Sharma S, Brown GC, Brown MM, et al. The cost-effectiveness of photodynamic therapy for fellow eyes with subfoveal choroidal neovascularization secondary to age-related macular degeneration. *Ophthalmology*. 2001 Nov;108(11):2051-9.
- Fine SL. Early detection of extraretinal neovascular membranes by daily central field evaluation. *Ophthalmology*. 1985 May;92(5):603-9.
- Alster Y, Bressler NM, Bressler SB, et al. Preferential Hyperacuity Perimetry (PreView PHP) for detecting choroidal neovascularization study. *Ophthalmology*. 2005 Oct;112(10):1758-65.
- Vander JF, Morgan CM, Schatz H. Growth rate of subretinal neovascularization in age-related macular degeneration. *Ophthalmology*. 1989 Sep;96(9):1422-6.
- Klein ML, Jorizzo PA, Watzke RC. Growth features of choroidal neovascular membranes in age-related macular degeneration. *Ophthalmology*. 1989 Sep;96(9):1416-9.
- Bressler NM, Frost LA, Bressler SB. Natural course of poorly defined choroidal associated with macular degeneration. *Arch Ophthalmol*. 1988 Nov;106(11):1537-42.
- Loewenstein A, Richard & Hinda Rosenthal Foundation. The significance of early detection of age-related macular degeneration: Richard & Hinda Rosenthal Foundation lecture. The Macula Society 29th annual meeting. *Retina*. 2007 Sep;27(7):873-8.
- Loewenstein A, Malach R, Goldstein M, et al. Replacing the Amsler grid: a new method for monitoring patients with age-related macular degeneration. *Ophthalmology*. 2003 May;110(5):966-70.
- Das R, Shi Y, Silvestri G, Chakravarthy U. Distortion maps from preferential hyperacuity perimetry are helpful in monitoring functional response to Lucentis therapy. *Retina*. 2009 Jul-Aug;29(7):1013-8.
- Anderson C, Pahk P, Blaha GR, et al. Preferential hyperacuity perimetry to detect hydroxychloroquine toxicity. *Retina*. 2009 Sep;29(8):1188-92.
- Loewenstein A, Ferencz JR, Lang Y, et al. Toward earlier detection of choroidal neovascularization secondary to age-related macular degeneration: Multicenter evaluation of a preferential hyperacuity perimeter designed as a home device. *Retina*. 2010 Jul-Aug;30(7):1058-64.
- Javitt JC, Zhou Z, Wilke RJ. Association between vision loss and higher medical costs in Medicare beneficiaries are greater for those with progressive vision loss. *Ophthalmology*. 2007 Feb;114(2):238-45.
- Slatker J, Stur M. Quality of life in patients with age-related macular degeneration: impact of condition and benefits of treatment. *Surv Ophthalmol*. 2005 May-Jun;50(3):263-73.
- Berdeaux GH, Nordmann JP, Colin E, Arnould B. Vision related quality of life in patients suffering from age-related macular degeneration. *Am J Ophthalmol*. 2005 Feb;139(2):271-9.

Retinal Venous Occlusions: A Systematic Review and Update on Current Treatment Options

By William D. Kress, O.D.



Release Date

November 2010

Expiration Date

November 30, 2013

Goal Statement

Retinal vein occlusion (RVO) is one of the most common acquired retinal vascular diseases in adults. It is the optometrist's responsibility to correctly identify the clinical characteristics of RVO, educate the patient about the condition and provide individually tailored management strategies. This paper discusses the risk factors, symptoms and pathophysiology of RVO as well as several management considerations and treatment options.

Faculty/Editorial Board

William D. Kress, O.D.

Credit Statement

This course is COPE approved for 1 hour of CE credit. COPE ID is 29750-PS. Please check your state licensing board to see if this approval counts toward your CE requirement for relicensure. There is a \$35 fee to take this course.

Joint Sponsorship Statement

This continuing education course is joint-sponsored by the Pennsylvania College of Optometry.

Disclosure Statement

Dr. Kress has no relationships to disclose.

RETINAL VEIN OCCLUSION (RVO) is one of the most common acquired retinal vascular diseases in adults. RVO has a reported prevalence of 0.1% to 1.6%.^{1,2} This vasculopathic process is known to have a strong association with various systemic disease processes, such as hypertension and diabetes mellitus. It is the optometrist's responsibility to correctly identify the clinical characteristics of RVO, educate the patient about the condition, co-manage the patient with his or her primary care physician, consider indicated laboratory testing, and provide individually tailored management strategies. This is why it is now more important than ever to have at least some understanding of the available treatment options for patients with RVO.

Here, we will discuss the risk factors, symptoms and pathophysiology of retinal venous occlusions as well as several management considerations and treatment options.

Central Retinal Vein Occlusion

Central retinal vein occlusion (CRVO) has the potential to be a major, sight-threatening condition. Although not as common as branch retinal vein occlusion (BRVO), CRVO has been reported in up to 0.5% of the adult population, but can occur in patients of any age.² Typical risk factors/associated conditions of CRVO include arterial hypertension, hypercholesterolemia, diabetes mellitus, arteriosclerosis and smoking.^{3,5} Certain hematologic conditions have been identified as potential etiologies associated with CRVO (*see "Hematologic Factors in CRVO," above*).⁶ CRVO patients who are 50 years of age or younger who exhibit a bilateral presentation should be evaluated for a hematologic disorders and coagulation conditions. Inflammation (vasculitis) and/or infectious etiologies should be considered as a cause of retinal venous occlusion for any age, especially if other systemic risk factors or retinal vascular anomalies are ruled out. Ocular conditions that have been associated with CRVO include glau-

Hematologic Factors in CRVO

- Hyperhomocysteinemia
- Elevated Plasminogen Activator Inhibitor-1
- Factor V Leiden
- Activated protein C resistance
- Antiphospholipid antibodies
- Factor XII deficiency
- Plasminogen deficiency
- Dysproteinemia

coma and ocular hypertension.¹⁰⁻¹⁴

CRVO is caused by a thrombotic obstruction of the central retinal vein at the lamina cribrosa, which results in a thrombotic event.¹⁵ Based upon histopathologic and fluorescein angiographic studies, Sohan Singh Hayreh, M.D., M.S., Ph.D., proposed a separate hypothesis. He suggested that the site of occlusion is actually located posterior to the lamina cribrosa; the location of the obstruction relative to the lamina may attribute to an ischemic vs. non-ischemic RVO, as well as to the severity of the respective retinal presentation.¹⁶ Although the exact location of the thrombotic obstruction is not wholly agreed upon, the general mechanism of pathogenesis is widely accepted.

CRVO can be identified by both subjective symptoms and objective fundus evaluation. Patients typically present with a mild to marked, sudden, painless, unilateral decrease in vision and/or a sudden onset of photopsia. Anterior segment evaluation may reveal an afferent pupillary defect as well as neovascularization of the iris and/or anterior chamber angle, depending on the extent of posterior segment pathology. Upon clinical evaluation, CRVO patients typically present with dilated, tortuous veins, retinal edema, exudates, optic nerve edema, cotton wool spots, and varying degrees of retinal hemorrhaging in all four quadrants. One primary cause of visual morbidity in patients with CRVO is macular edema; however, neovascularization of the retina (NVE), optic disc (NVD), iris (NVI), and/or angle (NVA), neovascular glaucoma, and vitreous hemorrhage may also occur during the

latter-stages of CRVO.

CRVO is classified as ischemic or non-ischemic, and can vary in prognosis, associated findings and natural history (see “Ischemic CRVO Findings,” below).^{17,18} Although non-ischemic CRVO is significantly more common than ischemic CRVO (80% of cases are non-ischemic), it carries a better overall prognosis.¹⁶ Reported studies indicate that 13% to 34% of non-ischemic CRVO convert to ischemic CRVO over a 1.5 to three-year period.^{19,20}

Risk factors for progression to ischemic CRVO include increased intra-retinal hemorrhaging, severe macular edema, markedly reduced visual acuity (less than or equal to 20/100), and duration of occlusive incident lasting less than one month.²¹⁻²³

For all cases of CRVO, the presenting acuity is typically poor (< 20/40). In the Central Vein Occlusion Study Group (CVOS), baseline visual acuity was worse than 20/40 in 63% of the non-ischemic cases and 93% of identified ischemic cases.²³ Over the course of the disease process, patients with ischemic CRVO are more likely to experience a decline in measured visual acuity than patients with non-ischemic CRVO because of extensive capillary non-perfusion and the potential for worsening macular edema.

In addition to macular edema and the related decrease in visual acuity, the clinician should also be aware of the potential risk for neovascularization, including NVE, NVD, NVI and NVA. Additionally, neovascular glaucoma may develop

in 8% to 10% of all CRVO cases and in 45% to 82% of ischemic CRVO cases.²⁴⁻²⁶

Iris and angle findings are more common than retinal findings in patients with CRVO due to the level of retinal hypoxia

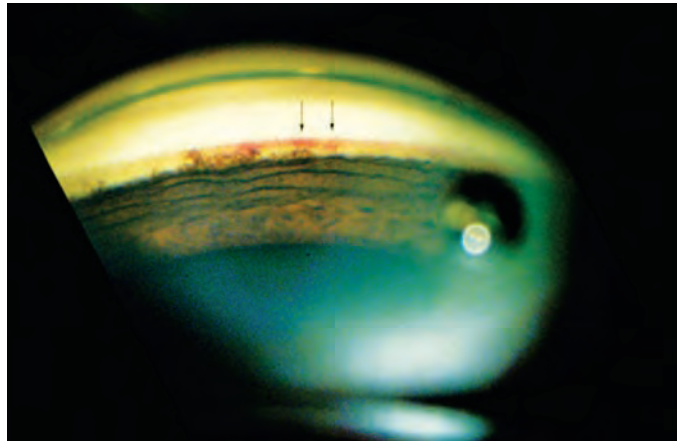
and reduced capacity of retinal vasculature to propagate neovascularization.²⁴ Careful evaluation of the pre-dilated pupillary border with full slit lamp illumination and 25X to 40X magnification is essential to the identification of early rubeosis irides. Additionally, a gonioscopic evaluation of the anterior chamber angle is necessary for all follow-up exams in order to rule out NVA, outflow obstruction and resultant IOP elevation.

Iris and angle neovascularization typically occurs within six months of the initial vascular insult; however, these neovascular findings have been identified in affected individuals up to one to two years after vein occlusion.^{20,22,23,26} So, you should regularly repeat anterior chamber angle evaluation to rule out NVI/NVA over a period of several years, with higher frequency in the initial months following initial CRVO discovery.

Hemi-Central Retinal Vein Occlusion

Hemi-central retinal vein occlusion (HRVO) has similar risk factors and characteristics as CRVO.^{3,12} The prevalence of HRVO is documented in one study as approximately 5%, but the true prevalence is not well-defined and is likely much lower than this.²

In HRVO, the central retinal vein appears to be bifurcated when traversing the lamina cribrosa and



This patient with central retinal vein occlusion demonstrates neovascularization of the angle.

joins up further back (post-laminar) in the optic nerve. This anatomical variation occurs in approximately 20% of individuals.^{27,28}

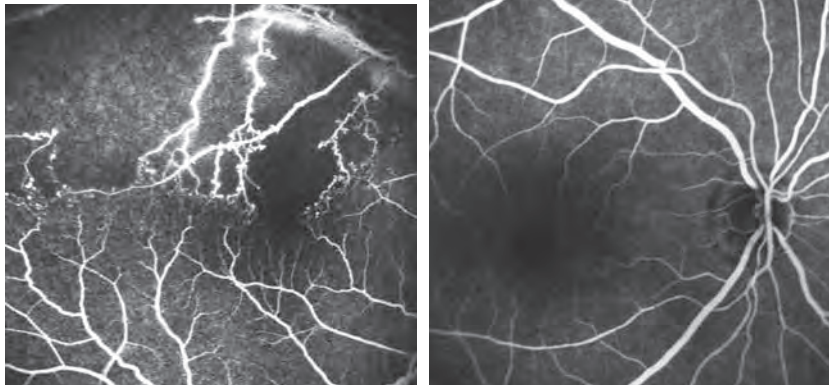
Similar to CRVO, the suspected etiology of HRVO is thought to be thrombotic occlusion. And, the classification of HRVO is also divided into non-ischemic (also known as venous stasis retinopathy [VSR]) and ischemic (also known as hemorrhagic retinopathy [HR]) forms.²⁸

The symptoms of HRVO are similar to those of CRVO, including sudden blur or vision loss. Fundoscopically, the clinician may find a combination of hemorrhaging that respects the horizontal raphe (in the vascular arcades and/or the periphery), cotton wool spots, macular edema, exudates, optic disc edema, and in latter stages NVD, NVE, NVI, NVA or vitreous hemorrhage. Both CRVO and HRVO may present with collateral vessels at the optic nerve, especially in chronic or advanced stages of the disease process.

Patients with HRVO are less likely to develop macular edema than patients with CRVO. However, neovascularization of the retina—and especially of the optic disc—is more common in HRVO patients than CRVO patients due to viable retinal vasculature that can support new vessel growth. Additionally, NVI occurs in 13% of ischemic cases of HRVO, which is less common than ischemic CRVO, but more common

Ischemic CRVO Findings

- Acuity typically \leq 20/200.
- Afferent pupillary defect.
- Reduced visual field.
- Reduced b-wave amplitude on electroretinogram.
- At least 10 disc areas of capillary non-perfusion on intra-venous fluorescein angiography (IVFA).



This patient with chronic branch retinal vein occlusion exhibits collateral vessel formation at the posterior pole (left) as well as arterio-venous crossing changes.

than BRVO.^{12,28}

Like CRVO, patients with HRVO should be followed carefully for the onset of macular edema (if not already present) and NVI/NVA as well as the development of neovascular glaucoma. Unlike CRVO, retinal evaluations are needed more often to identify potential NVE, NVD or vitreous hemorrhage.

Branch Retinal Vein Occlusion

BRVO is the second most common retinal vascular disease after diabetic retinopathy. The prevalence of BRVO has been found to be approximately 0.6% to 1.1%.^{1,2,29} Associated risk factors include increased age (one study suggested that patients 75 years of age or older were 4.6 times more likely to develop BRVO than patients between 43-54 years of age), systemic hypertension, abnormal arterio-venous crossing changes, cerebrovascular disease, chronic obstructive pulmonary disorder and cardiovascular disease.^{1,3,12,30-32} Unlike CRVO, glaucoma and ocular hypertension do not appear to be a significant risk factor for BRVO.¹⁶

BRVO is caused by an abnormal interaction between an arteriole and underlying vein at the point of crossing. An atherosclerotic process causes stiffening of the arteriole, which results in compression and subsequent constriction of the underlying vein. It has also been shown that the focal narrowing of the venous lumen secondary to arteriole compression causes blood

flow turbidity, leading to thrombotic formation at the arterio-venous crossing site as well as downstream.^{33,34}

Like CRVO, BRVO venous stasis results in upstream leakage of blood from capillary beds. This causes significant damage to these capillaries, ultimately leading to atrophy and the potential for permanent non-perfusion. Typically, the branch veins located in the supero-temporal quadrant are commonly involved due to more arterio-venous crossings in this area. One study found the percentage of venous-quadrant involvement to be 52.3% supero-temporal, 38.5% infero-temporal and 9.2% nasal.³⁵

Unlike CRVO, patient awareness of this retinal process may go unnoticed. This may depend upon the extent and/or location of retinal involvement, as well as presence of associated macular edema. However, similar to CRVO, some patients may complain of sudden, unilateral vision or visual field loss. Anterior segment findings will be limited relative to CRVO, but may

include an afferent pupillary defect depending upon extent of retinal involvement. Posterior segment findings will include a combination of the following: sectoral intra-retinal hemorrhaging respecting the horizontal raphe, adjacent dilated and tortuous vein with associated narrowing arteriole overlying exudates, cotton-wool spots, and/or retinal edema.

The primary cause of vision loss in patients with BRVO is macular edema. Initial visual acuity in these individuals can range anywhere from 20/20 to less than 20/200 depending upon the severity of macular edema. Macular edema occurs in approximately 5% to 15% of major branch vein occlusions over a one-year period.³⁸

Chronic BRVO, like chronic CRVO and HRVO, may lead to formation of collateral vessels that cross the horizontal raphe or appear at the optic disc.

BRVO can be classified based upon location of compression. This includes first-order (intermediate) or second-order (twig) occlusions. First-order occlusions occur after the first bifurcation of the major vein in a quadrant, and second-order occlusions involve the small vessels that drain the macular area only.

BRVO, like CRVO, can be further classified into ischemic (20%) and non-ischemic (80%) variations. Ischemic BRVO is defined as five disc areas or more of capillary non-perfusion on IVFA.³⁶

NVE and NVD are more common than NVA and NVI patients with BRVO, due to the viability of remaining retinal vasculature and the ability to support new vessel growth.

Neovascularization of the retina is of concern for individuals who present with BRVO, especially the ischemic variation. NVD and NVE occur in less than 20% to 25% of major branch vein occlusions.^{36,37} NVE typically forms at the junction of perfused and non-perfused retinal tissue. Neovascularization is less common in second-order occlusions because a smaller area of retinal tissue is affected. However, you still

Lab Tests for CRVO and BRVO

- CBC with differential
- ESR
- Pt/Ptt
- Fasting blood sugar and/or HbA1C
- RF
- ANA
- Lipid panel/cholesterol levels
- Homocysteine analysis

CVOS/BVOS Treatment Summary

CVOS ³⁹	BVOS ^{36,40}
<p>Macular Edema:</p> <ul style="list-style-type: none"> • Laser photocoagulation shows no benefit to visual outcome. <p>Neovascularization:</p> <ul style="list-style-type: none"> • Pan-retinal photocoagulation indicated after development of neovascularization (NVI, NVD, NVE); prophylactic pan-retinal photocoagulation (PRP) not beneficial. • Eyes with extensive intraretinal hemorrhaging that precludes a diagnosis of ischemic vs. non-ischemic CRVO should be treated as ischemic until otherwise determined. 	<p>Macular Edema:</p> <ul style="list-style-type: none"> • Laser photocoagulation shows benefit to reduced vision caused by macular edema, and treatment is recommended if vision remains 20/40 or worse after three months of observation (IFVA confirms either macular perfusion or non-perfusion). <p>Neovascularization:</p> <ul style="list-style-type: none"> • Sector or complete PRP, as indicated, after the development of neovascularization (NVE, NVD, NVI), including for the prevention of vitreous hemorrhage.

should carefully evaluate the pre-dilated pupillary border with full slit lamp illumination and 25X to 40X magnification when looking for rubeosis irides, as well as perform a gonioscopic evaluation of the anterior chamber angle when looking for NVA during the first three to six months after the BRVO incident.

Over time, there is an 8% to 10% risk for fellow eye involvement following either CRVO or BRVO.

Management Strategies

In addition to the comprehensive examination with dilated fundus exam, the clinician should perform gonioscopy, as well as a blood pressure evaluation, on all patients who present with either CRVO or BRVO. Initial lab work-up may be warranted as well (see, "Lab Tests for CRVO and BRVO," page 14).

In addition to initial blood work-up, hematologic factors mentioned above and a RPR/VDRL, ACE, or sickle cell testing (Sickle-dex, Streck Inc.) may be indicated in particular cases of CRVO, or if initial labs come back negative. A referral for a cardiovascular consult may be necessary for patients with BRVO if the individual is not already being followed for such conditions.

Preservation and/or improvement of visual acuity is vital in cases of both CRVO and BRVO. Typically, the presence and degree of macular edema dramatically affects the visual prognosis.

Although IVFA has been a mainstay in the identification of macular edema and is consistently used throughout the treatment progress, optical coherence tomography (OCT) is now proving to be more accurate and user/patient friendly in the quantification of edema during subsequent follow-up management. In addition, the clinician must differentiate any findings that help identify the presence of an ischemic or non-ischemic variance in both CRVO and BRVO, because this will dictate the frequency of follow-up care.

Patients without macular edema or neovascularization should be seen every month for the first six months, and then at decreased, regular intervals thereafter based upon the state of ocular findings.

Contemporary management of macular edema and neovascular findings follows the results of the CVOS/BVOS study groups (see "CVOS/BVOS Treatment Summary," left). However, newer, more advanced treatment options are delivering increased positive visual outcomes, especially in the management of macular edema secondary to CRVO and BRVO (see "Macular Edema Treatment Summary," below).

Treatment Options

Concerning visual reduction secondary to macular edema, the treatment option of isolated laser photocoagulation did not prove to be beneficial in the CVOS study group. The BVOS study group showed moderate improvement with grid laser, with 65% maintaining at least a two-line acuity improvement after three years.⁴⁰

Treatment of macular edema secondary to RVO using ranibizumab received FDA approval in July 2010. Results from the BRAVO and CRUISE clinical trials have shown promise in the treatment of this condition. The approved treatment protocol from these studies is a monthly intravitreal injection of ranibizumab for at least six months.

Ozurdex (dexamethasone, Allergan) was FDA approved in June 2009 for the treatment of macular edema secondary to RVO. Ozurdex is an intravitreal steroid implant that is biodegradable and can persist in the vitreous from

Macular Edema Treatment Summary

SCORE ^{41,42}	CRUISE ⁴³	BRAVO ⁴⁴
<p>BRVO:</p> <ul style="list-style-type: none"> • Laser photocoagulation is still a safer and more effective option than intravitreal triamcinolone for treatment for macular edema. <p>CRVO:</p> <ul style="list-style-type: none"> • Intravitreal triamcinolone may be a viable option for treatment of macular edema (based on one-year follow-up). 	<p>BRVO & CRVO:</p> <ul style="list-style-type: none"> • Intravitreal ranibizumab (Lucentis, Genentech) for the treatment of macular edema secondary to CRVO. 	<p>BRVO & CRVO:</p> <ul style="list-style-type: none"> • Intravitreal ranibizumab for the treatment of macular edema secondary to BRVO.

anywhere between one to three months.^{45,46} The results of clinical studies involving Ozurdex show promise in the overall reduction in macular edema during the initial stages of the disease process. Within the first two months following implantation, approximately 20% to 30% of patients experience a 15-letter or greater improvement in best-corrected visual acuity.⁴⁷

No longer is the only treatment option for the development of anterior segment neovascularization pan-retinal photocoagulation. Anti-VEGF treatment involving ranibizumab or bevacizumab is being used for the off-label treatment of NVI/NVA. The use of pan-retinal photocoagulation and anti-VEGF therapy in combination is proving to be an effective treatment option as well.⁴⁸⁻⁵⁰

Ultimately, clinicians who manage retinal vein occlusions must be aware of the risks for developing potential complications. We must be aware of the potential for underlying systemic etiologies by understanding what to look for as well as know the pertinent laboratory testing indicated to identify these conditions.

Additionally, comanagement with the appropriate healthcare professional is essential in not only preserving ocular health and vision, but also in maintaining the overall health of our RVO patients. ■

Dr. Kress is a clinical instructor in The Eye Center at Southern College of Optometry in Memphis, Tenn.

1. Klein R, Klein BE, Moss SE, Meuer SM. The epidemiology of retinal vein occlusion: the Beaver Dam Eye Study. *Trans Am Ophthalmol Soc.* 2000;98:133-41.
2. Mitchell P, Smith W, Chang A. Prevalence and association of retinal vein occlusion in Australia. The Blue Mountains Eye Study. *Arch Ophthalmol.* 1996 Oct;114(10):1243-7.
3. Hayreh SS, Zimmerman MB, McCarthy MJ, Podhajsky P. Systemic disease associated with various types of retinal vein occlusion. *Am J Ophthalmol.* 2001 Jan;131(1):61-77.
4. O'Mahoney PR, Wong DT, Ray JG. Retinal vein occlusion and traditional risk factors for atherosclerosis. *Arch Ophthalmol.* 2008 May;126(5):692-9.
5. Klatt C, Purtskhvanidze K, Hasselbach H, et al. Retrospective case analysis of ophthalmological and systemic risk factors in patients with retinal vascular occlusion. *Ophthalmologie.* 2010 May;107(5):446-51.
6. Marucci R, Bertini L, Giusti B, et al. Thrombophilic

- risk factors in patients with central retinal vein occlusion. *Thromb Haemost.* 2001 Sep;86(3):772-6.
7. Prisco D, Marucci R, Bertini L, Gori AM. Cardiovascular and thrombophilic risk factors for central retinal vein occlusion. *Eur J Intern Med.* 2002 May;13(3):163-9.
8. Trope GE, Lowe GD, McArdle BM, et al. Abnormal blood viscosity and haemostasis in long-standing retinal vein occlusion. *Br J Ophthalmol.* 1983 Mar;67(3):137-42.
9. Peduzzi M, Debbia A, Guerrieri F, Bolzani R. Abnormal blood rheology in retinal vein occlusion. A preliminary report. *Graefes Arch Clin Exp Ophthalmol.* 1986;224(1):83-5.
10. Hayreh SS, Zimmerman MB, Beri M, Podhajsky P. Intraocular pressure abnormalities associated with central and hemi-central retinal vein occlusion. *Ophthalmology.* 2004 Jan;111(1):133-41.
11. Chew EY, Trope GE, Mitchell BJ. Diurnal intraocular pressure in young adults with central retinal vein occlusion. *Ophthalmology.* 1987 Dec;94(12):1545-9.
12. Appiah AP, Trempe CL. Differences in contributory factors among hemicentral, central, and branch retinal vein occlusion. *Ophthalmology.* 1989 Mar;96(3):364-6.
13. Vannas S, Tarkkanen A. Retinal vein occlusion and glaucoma. Tonographic study of the incidence of glaucoma and its prognostic significance. *Br J Ophthalmol.* 1960 Oct;44:583-9.
14. Rath EZ, Frank RN, Shin DH, Kim C. Risk factors for retinal vein occlusions. *Ophthalmology.* 1992 Apr;99(4):509-14.
15. Green WR, Chan CC, Hutchins GM, Terry JM. Central retinal vein occlusion: a prospective histological study of 29 eyes in 28 cases. *Trans Am Ophthalmol Soc.* 1981;79:371-422.
16. Hayreh SS. Prevalent misconceptions about acute retinal vascular occlusive disorders. *Prog Retin Eye Res.* 2005 Jul;24(4):493-519.
17. Hayreh SS. An experimental study of the central retinal vein occlusion. *Trans Ophthalmol Soc UK.* 1964;84:586-93.
18. Hayreh SS. Occlusion of the central retinal vessels. *Br J Ophthalmol.* 1965 Dec;49(12):626-45.
19. Hayreh SS, Zimmerman MB, Podhajsky P. Incidence of various types of retinal vein occlusion and their recurrence and demographic characteristics. *Am J Ophthalmol.* 1994 Apr 15;117(4):429-41.
20. McIntosh RL, Rogers SL, Lim L, et al. Natural history of central retinal vein occlusion: An evidence-based systematic review. *Ophthalmology.* 2010 Jun;117(6):1113-1123.e15.
21. Pollack A, Leiba H, Oliver M. Progression of non-ischemic central retinal vein occlusion. *Ophthalmologica.* 1997;211(1):13-20.
22. Minturn J, Brown GC. Progression of non-ischemic central retina vein obstruction to the ischemic variant. *Ophthalmology.* 1986 Sep;93(9):1158-62.
23. Baseline and early natural history report. The Central Vein Occlusion Study. *Arch Ophthalmol.* 1993 Aug;111(8):1087-95.
24. Hayreh SS, Rojas P, Podhajsky P, et al. Ocular neovascularization with retinal vein occlusion-III. Incidence of ocular neovascularization with retinal vein occlusion. *Ophthalmology.* 1983 May;90(5):488-506.
25. Hayreh SS. Classification of central retinal vein occlusion. *Ophthalmology.* 1983 May;90(5):458-74.
26. Zegarra H, Gutman FA, Conforto J. The natural course of central retinal vein occlusion. *Ophthalmology.* 1979 Nov;86(11):1931-42.
27. Chopdar A. Dual trunk central retinal vein incidence in clinical practice. *Arch Ophthalmol.* 1984 Jan;102(1):85-7.
28. Hayreh SS, Hayreh MS. Hemi-central retinal vein occlusion. *Arch Ophthalmol.* 1980 Sep;98(9):1600-9.
29. Cheung N, Klein R, Wang JJ, et al. Traditional and novel cardiovascular risk factors for retinal vein occlusion: the multiethnic study of atherosclerosis. *Invest Ophthalmol Vis Sci.* 2008 Oct;49(10):4297-302.
30. Wong TY, Larsen E, Klein R, et al. Cardiovascular risk factors for retinal vein occlusion and arterial emboli: the Atherosclerosis Risk in Communities & Cardiovascular Health studies. *Ophthalmology.* 2005 Apr;112(4):540-7.
31. Wong TY, Mitchell P. The eye in hypertension. *Lancet.* 2007 Feb 3;369(9559):425-35.

32. Cugati S, Wang JJ, Rochtchina E, Mitchell P. Ten-year incidence of retinal vein occlusion in an older population: the Blue Mountains Eye Study. *Arch Ophthalmol.* 2006 May;124(5):726-32.
33. Kumar B, Yu DY, Morgan WH, et al. The distribution of angio-architectural changes within the vicinity of the arteriovenous crossing in branch retinal vein occlusion. *Ophthalmology.* 1998 Mar;105(3):424-7.
34. Bowers DK, Finkelstein D, Wolff SM, Green WR. Branch retinal vein occlusion. A clinicopathologic case report. *Retina.* 1987;7(4):252-9.
35. Klein R, Moss SE, Meuer SM, Klein BE. The 15-year cumulative incidence of retinal vein occlusion: The Beaver Dam Eye Study. *Arch Ophthalmol.* 2008 Apr;126(4):513-8.
36. No authors listed. Argon laser scatter photocoagulation for prevention of neovascularization and vitreous hemorrhage in branch vein occlusion. A randomized clinical trial. Branch Vein Occlusion Study Group. *Arch Ophthalmol.* 1986 Jan;104(1):34-41.
37. Hayreh SS, Rojas P, Podhajsky P, et al. Ocular neovascularization with retinal vascular occlusion-III. Incidence of ocular neovascularization with retinal vein occlusion. *Ophthalmology.* 1983 May;90(5):488-506.
38. Rogers SL, McIntosh RL, Lim L, et al. Natural history of branch retinal vein occlusion: An evidence-based systematic review. *Ophthalmology.* 2010 Jun;117(6):1094-1101.e5.
39. Natural history and clinical management of central retinal vein occlusion. The Central Vein Occlusion Study Group. *Arch Ophthalmol.* 1997 Apr;115(4):486-91.
40. No authors listed. Argon laser photocoagulation for macular edema in branch vein occlusion. The Branch Vein Occlusion Study Group. *Am J Ophthalmol.* 1984 Sep 15;98(3):271-82.
41. Scott IU, Ip MS, VanVeldhuisen PC, et al. A randomized trial comparing the efficacy and safety of intravitreal triamcinolone with standard care to treat vision loss associated with macular edema secondary to branch retinal vein occlusion: the Standard Care vs. Corticosteroid for Retinal Vein Occlusion (SCORE) study report 6. *Arch Ophthalmol.* 2009 Sep;127(9):1115-28.
42. Ip MS, Scott IU, VanVeldhuisen PC, et al. A randomized trial comparing the efficacy and safety of intravitreal triamcinolone with observation to treat vision loss associated with macular edema secondary to central retinal vein occlusion: the Standard Care vs Corticosteroid for Retinal Vein Occlusion (SCORE) study report 5. *Arch Ophthalmol.* 2009 Sep;127(9):1101-14.
43. Brown DM, Campochiaro PA, Singh RP, et al. Ranibizumab for macular edema following central retinal vein occlusion: six-month primary end point results of a phase III study. *Ophthalmology.* 2010 Jun;117(6):1124-1133.e1.
44. Campochiaro PA, Heier JS, Feiner L, et al. Ranibizumab for macular edema following branch retinal vein occlusion: six-month primary end point results of a phase III study. *Ophthalmology.* 2010 Jun;117(6):1102-1112.e1.
45. Haller JA, Dugel P, Weinberg DV, et al. Evaluation of the safety and performance of an applicator for a novel intravitreal dexamethasone drug delivery system for the treatment of macular edema. *Retina.* 2009 Jan;29(1):46-51.
46. Fialho SL, Behar-Cohen F, Silva-Cunha A. Dexamethasone-loaded poly (epsilon-caprolactone) intravitreal implants: a pilot study. *Eur J Pharm Biopharm.* 2008 Mar;68(3):637-46.
47. Ozurdex. Package Insert. Allergan Inc. Available at: www.allergan.com/assets/pdf/ozurdex_pi.pdf (Accessed October 18, 2010).
48. Kahook MY, Schuman JS, Neecker RJ. Intravitreal bevacizumab in a patient with neovascular glaucoma. *Ophthalmic Surg Lasers Imaging.* 2006 Mar-Apr;37(2):144-6.
49. Davidoff FH, Mouser JG, Derick RJ. Rapid improvement of rubeosis iridis from a single bevacizumab (Avastin) injection. *Retina.* 2006 Mar;26(3):354-6.
50. Silva Paula J, Jorge R, Alves Costa R, et al. Short-term results of intravitreal bevacizumab (Avastin) on anterior segment neovascularization in neovascular glaucoma. *Acta Ophthalmol Scand.* 2006 Aug;84(4):556-7.

Questions

1. What is the reported worldwide prevalence of retinal vein occlusions?

- a. 0.6% to 1.6%.
- b. 0.1% to 1.6%.
- c. 0.6% to 1.0%.
- d. 1.0% to 1.6%.

2. Which of these systemic conditions is NOT an associated risk factor the development of CRVO?

- a. Diabetes mellitus.
- b. Hypercholesterolemia.
- c. Arteriosclerosis.
- d. Hepatitis C.

3. Which of the following hematologic conditions should be considered when managing an individual younger than 50 years of age with a presenting CRVO?

- a. Hemolytic anemia.
- b. Idiopathic thrombocytopenia purpura.
- c. Antiphospholipid antibodies.
- d. Thalassemia.

4. Ischemic CRVO is likely to present with all of the following, EXCEPT:

- a. Sudden, unilateral vision loss (typically worse than 20/200).
- b. Reduced visual field.
- c. Corneal edema.
- d. Afferent pupillary defect.

5. In cases of ischemic CRVO, the patient should be initially followed closely for the development of:

- a. Retinal detachment.
- b. Neovascularization of the iris (NVI).
- c. Choroidal neovascular membrane (CNV).
- d. Retinal collateral vessel formation.

6. Neovascularization of the _____ is more common in HRVO than in CRVO due to viable vasculature that can support new vessel growth.

- a. Iris.
- b. Anterior chamber angle.
- c. Optic disc.
- d. Choroid.

7. What is a systemic risk factor for the development of BRVO?

- a. Hyperthyroidism.
- b. Cardiovascular disease.
- c. Hyperhomocysteinemia.
- d. Neurofibromatosis.

8. What is the primary cause of vision loss in BRVO?

- a. Vitreous hemorrhage.
- b. Neovascular glaucoma.
- c. Macular edema.
- d. Optic atrophy.

9. According to BVOS, laser photocoagulation shows benefit to reduced vision caused by macular edema, and treatment is recommended if vision remains 20/40 or worse after how many months of observation?

- a. One month.
- b. Two months.
- c. Three months.
- d. Six months.

10. According to _____, laser photocoagulation shows no benefit to visual outcome in the treatment of macular edema secondary to CRVO.

- a. CRUISE.
- b. SCORE.
- c. CVOS.
- d. BRAVO.

Examination Answer Sheet

Valid for credit through November 30, 2013

Retinal Venous Occlusions: A Systematic Review and Update on Current Treatment Options

Directions: Select one answer for each question in the exam and completely darken the appropriate circle. A minimum score of 70% is required to earn credit. There is a \$35 fee to take this course

Mail to: Optometric CE, PO Box 488, Canal Street Station, New York, NY 10013
COPE approved for 1 hour of CE Credit. COPE ID: 29750-PS.

There is an eight-to-ten week processing time for this exam.

1. (A) (B) (C) (D) 11. The goal statement was achieved:
 Very Well Adequately Poorly
2. (A) (B) (C) (D) 12. The information presented was:
 Very Useful Useful Not Very Useful
3. (A) (B) (C) (D) 13. The difficulty of the course was:
 Complex Appropriate Basic
4. (A) (B) (C) (D) 14. Your knowledge of the subject was increased:
 Greatly Somewhat Hardly
5. (A) (B) (C) (D) 15. The quality of the course was:
 Excellent Fair Poor
6. (A) (B) (C) (D) How long did it take to complete this course?

7. (A) (B) (C) (D) Comments on this course:

8. (A) (B) (C) (D) Topics you would like in the future CE articles:

9. (A) (B) (C) (D)
10. (A) (B) (C) (D)

Please retain a copy for your records. Please print clearly.

You must choose and complete one of the following three identifier types:

① SS # _____ - _____ - _____

Last 4 digits of your SS # and date of birth State Code and License #: (Example: NY12345678)

② _____ - _____ ③ _____

First Name _____

Last Name _____

E-Mail _____

The following is your: Home Address Business Address

Business Name _____

Address _____

City _____ State _____

ZIP _____

Telephone # _____ - _____ - _____

Fax # _____ - _____ - _____

By submitting this answer sheet, I certify that I have read the lesson in its entirety and completed the self-assessment exam personally based on the material presented. I have not obtained the answers to this exam by any fraudulent or improper means.

Signature _____ Date _____

Genetic Advancements in AMD: A Glimpse at the Future

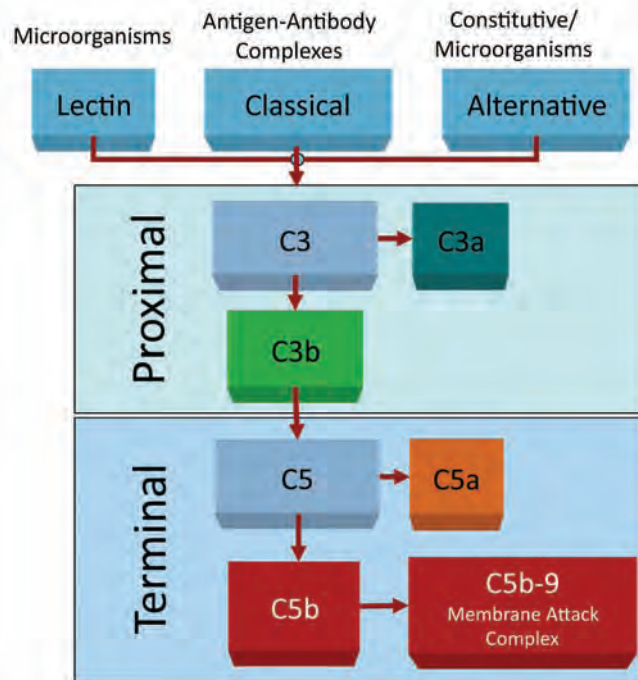
By Mark T. Dunbar, O.D., F.A.A.O.

THE ADVENT OF ANTI-VEGF THERAPY

marked a new era in the treatment of wet AMD. For the first time ever, the vast majority of patients with choroidal neovascularization (CNV) exhibited stabilized visual acuity, as opposed to continued progressive acuity loss. Many patients experienced stabilized visual acuity following anti-VEGF therapy, and a significant percentage of patients actually showed improvement in acuity—with approximately 40% seeing at least 20/40 or better.^{1,2} This even held true for patients with occult CNV, which no prior treatment had been able to treat effectively.¹ Unfortunately, success came at a cost. Not only was the treatment expensive at more than \$2,000 per ranibizumab injection, but also patients required monthly injections.

As remarkable as anti-VEGF treatment is, there are drawbacks. For one, it doesn't work for all patients, which investigators have yet to fully understand. Additionally, as long as the injections are given on a regular interval, the medications seem to control the growth of these membranes; however, once anti-VEGF therapy is stopped, the CNV often reoccurs. What's more, investigators started to recognize a significant issue when intraocular VEGF is blocked over a long period of time: The dry form of the disease continues to progress.³

So, even though inhibition of VEGF might prevent the development of pathologic neovascularization, it does nothing to stop or slow the progression of dry AMD, which, in reality, represents the vast majority macular degeneration cases. Fortunately, most patients with dry AMD do not suffer the same kind of visual morbidity as those with the wet form of AMD. However, as the baby-boomer population continues to age, these numbers will quickly multiply and could represent a significant number worldwide. Unfortunately, at this time, there is no treatment for dry AMD. But, with the development of several cutting-edge drugs, a treatment or cure may be within reach.



The complement system has three distinct pathways: The classical pathway, the alternative pathway and the mannose-binding lectin pathway. The classical pathway is activated by antigen-antibody complexes, while the lectin pathway is stimulated by various micro-organisms. Microbial particles or other foreign substances activate the alternative pathway. All three activation pathways drive the cascade of proximal and then terminal complement activity with the end result being activation of the cell-killing "membrane attack complex" (MAC).

Genetic Breakthroughs

Perhaps one of the most significant breakthroughs in AMD research occurred in 2005 when several independent academics discovered that one particular gene is strongly associated with the development of AMD—complement factor H (CFH).^{4,7} CFH is located at the region of chromosome 1q32 and it produces a protein that helps regulate inflammation.^{4,7} CFH is primarily synthesized in the liver, but can also be produced in other tissues, including the eye, kidney and vascular organs. More importantly, it helps regulate a primitive pathway referred to as the complement system, which is part of the body's natural defense immune system.^{4,8}

The complement system was originally described more than 100 years ago.⁸ It was originally thought to play a supplementary role in regulating

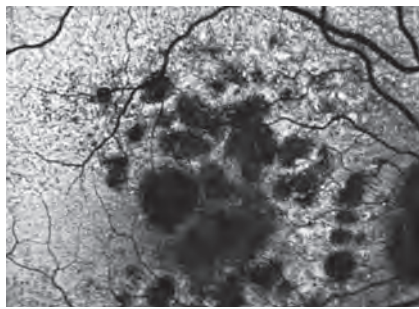
the body's immune defense system; however, it is now recognized that the complement system plays a much more significant role.⁸ The complement system is a complicated enzyme cascade comprised of numerous serum glycoproteins that circulate within the blood. More than 40 proteins and protein fragments make up the complement system, including serum proteins, serosal proteins and cell membrane receptors. These proteins account for about 5% of the globulin fraction of blood serum. The glycoproteins normally exist in an inactive form, but can be triggered to activate by any number of mediating factors. When the complement system becomes activated, the system cleaves specific proteins to release cytokines, which triggers the cascade of further cleavages.^{8,9}

Most molecules involved in the complement system are given the name

“C” and then a number, such as “C1.” The molecules within the complement system are activated sequentially by successive cleavages of the various molecules. When a complement protein is split, two fragments are formed. These are referred to as “a” and “b.” C5, for example, is cleaved into fragments C5a and C5b.^{8,10}

The complement system has three distinct pathways: The classical pathway, the alternative pathway and the mannose-binding lectin pathway. The classical pathway is activated by antigen-antibody complexes, while the lectin pathway is stimulated by various microorganisms. Microbial particles or other foreign substances activate the alternative pathway. All three activation pathways drive the cascade of proximal and then terminal complement activity. The proximal area of the cascade generates complement proteins, such as C3b, which is a very active protein that helps the body defend against microbes and helps clear immune complexes. The terminal area of the cascade generates C5a, a potent anaphylaxis toxin.

While each pathway is unique, each one exhibits a similar terminal sequence that activates the cell-killing “membrane attack complex” (MAC). The MAC is one of the primary ways in which the immune system fights against foreign invaders.^{8,9,11} It can be deposited on any number of viruses, fungi, bacteria or other cells. MAC formation allows water, ions and other small molecules to move freely into and out of a cell, and this quickly results in cell death. As detrimental this is to foreign invaders, it can also have a negative collateral effect on



We now recognize that AMD, as documented in this patient, develops as a result of a complement system regulation deficiency.

local host cells and tissues where damage and/or cell death may occur.

Since the CFH-AMD discovery, researchers quickly identified additional genes in the complement pathway that were also associated with the development of AMD. These include complement factor B (CFB), complement component 2 (C2) and complement component 3 (C3).¹¹ With further research, investigators discovered that drusen contain nearly all of the proteins that make up the complement system as well as components of the MAC. What’s more, MAC may actively contribute to the development of drusen as well as RPE/photoreceptor degeneration and disruption of Bruch’s membrane, which, in turn, may lead to the development of choroidal neovascularization. This suggests that drusen develop as a byproduct of chronic, localized inflammation likely due to a robust activation of the complement cascade at the level of the RPE-choroid interface.^{10,11}

We now recognize that AMD develops as a result of a complement system regulation deficiency. External

considerations, such as smoking, poor diet, obesity, total fat intake and many other factors, may also play a role in regulating this system. However, what is not completely understood is to what extent these external factors influence disease development and progression based on the individual’s genetic predisposition.

Some experts believe that it’s part of a “two-hit” process. More specifically, genetics alone may not be enough to result in a patient developing AMD, and initiation of the disease process in certain individuals may require a second “hit,” such as smoking or any of the other external factors previously described. At this time, the genetic/external variable interplay is not completely understood. However, it is believed that the effect of these variables probably is not cumulative in nature, but is more likely a result of a specific combination of these risk factors in a given individual that leads to a greater risk for AMD development.^{11,12}

With the discovery of several key genes that are responsible for the development of AMD, a Canadian company named Artic Dx developed a simple test that allows patients to determine if they have a genetic predisposition for the condition.¹³ The Macula Risk test has an 83% predictive value and it involves a simple swab of the cheek that is then sent to the lab for evaluation.^{13,14} The patient is sent a 10-page report that explains the test results and places the patient into one of five different risk categories, which correlate to the patient’s risk for AMD development. Subjects who are placed into category five have a 75% chance to develop AMD, while subjects in category one have less than a 5% chance.¹³ The test costs approximately \$400 and is covered by most medical insurances. For providers that are interested, Artic Dx will provide a kit that includes several Macula Risk testing swabs as well as an addressed envelope in which the swab can be sent.

A New Era in Modern Medicine

With a much better understanding of the pathogenesis of AMD, scientists quickly set out to develop new drug therapies for dry AMD that specifically target regulation of the complement system. This utilizes a new science of pharmacogenetics in which patients may eventually receive customized medical therapy based on their own

Diseases in Which the Complement Pathway Has Been Implicated

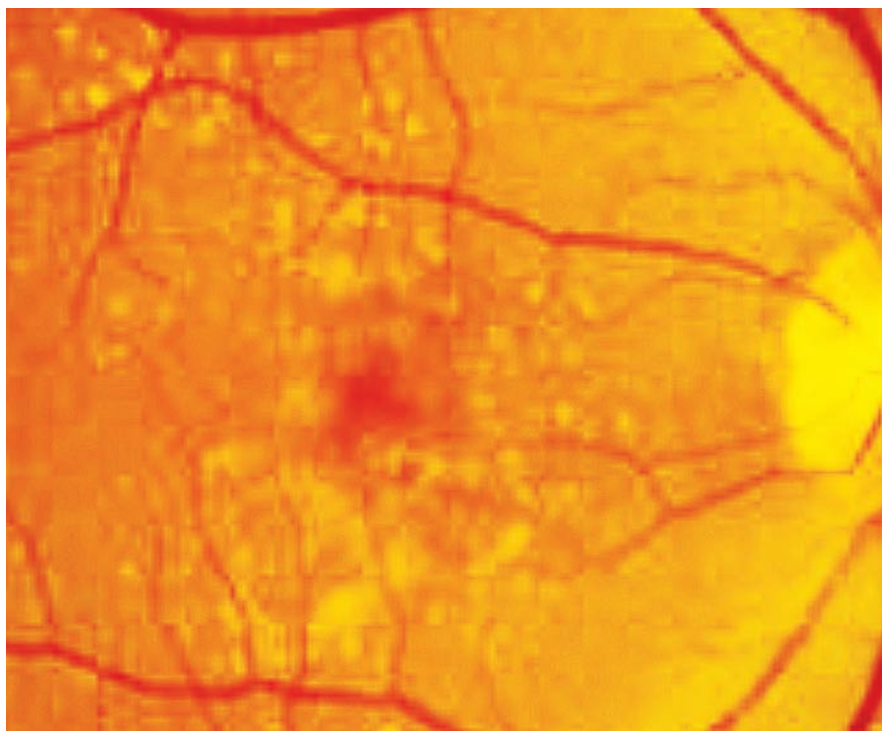
- Membranoproliferative glomerulonephritis type II (MGNII)
- Atypical hemolytic uremic syndrome (aHUS)
- Paroxymal nocturnal hematuria (PNH)
- Rheumatoid arthritis
- Systemic lupus erythematosus (SLE)
- Myocarditis
- Multiple sclerosis (MS)
- Traumatic brain injury
- Traumatic spinal cord injury
- Intestinal and renal IR (ischemia-reperfusion) injury
- Anti-phospholipid Ab syndrome
- Recurrent pregnancy loss syndrome
- Asthma
- Ab-mediated cutaneous disease

unique genetic signature. Currently, there are several ongoing clinical trials in various phases of activity that are evaluating the ability of these drugs to prevent the progression of AMD. Some of the more promising drugs target specific areas within the complement pathway. So far, drugs that attack C3a and C5a have shown great promise. When C3 and C5 are inhibited, VEGF expression, leukocyte recruitment and CNV formation are significantly reduced. Here, is an overview of several drugs that regulate the complement system:

- *Eculizumab*. Eculizumab (Soliris, Alexion Pharmaceuticals) is one drug that is showing early promise. Eculizumab is a humanized anti-C5 IgG antibody that is already FDA approved for the treatment of paroxysmal nocturnal hemoglobinuria, a particularly severe form of hemolytic anemia. Eculizumab prevents cleavage of C5 into C5a and C5b, which results in inhibition of downstream complement activation. In its current form, eculizumab is administered as an intravenous infusion.^{11,15}

Currently the COMPLETE (Complement Inhibition with Eculizumab for the Treatment of Non-Exudative Age-Related Macular Degeneration) study is a 12-month single-center, randomized, prospective controlled clinical trial that is evaluating the effectiveness of eculizumab at halting the progression of dry AMD to wet AMD.¹⁵ Another arm of the trial is looking at the ability of eculizumab to prevent the progression of geographic atrophy.¹⁵

- *ARC1905*. ARC1905 (Ophthotech) is another potent, selective inhibitor of factor C5. Inhibition of the

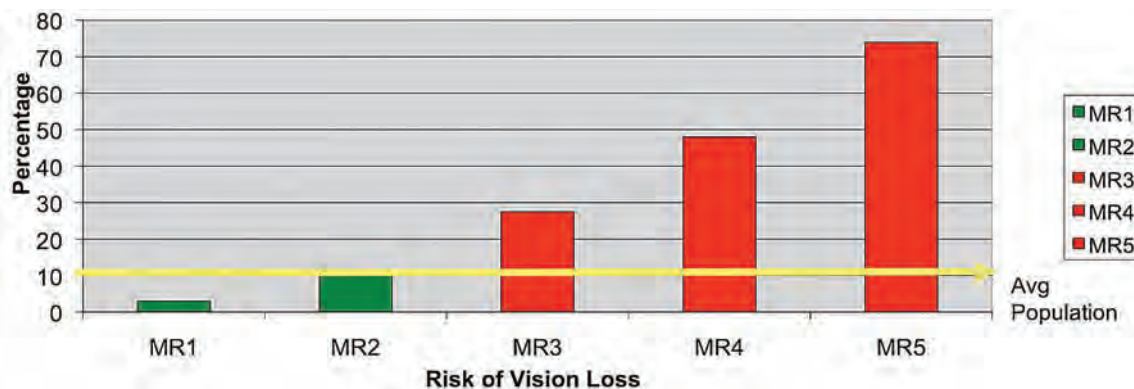


Several cutting-edge pharmaceutical agents that regulate the complement system might be able to successfully treat age-related macular degeneration, as seen here.

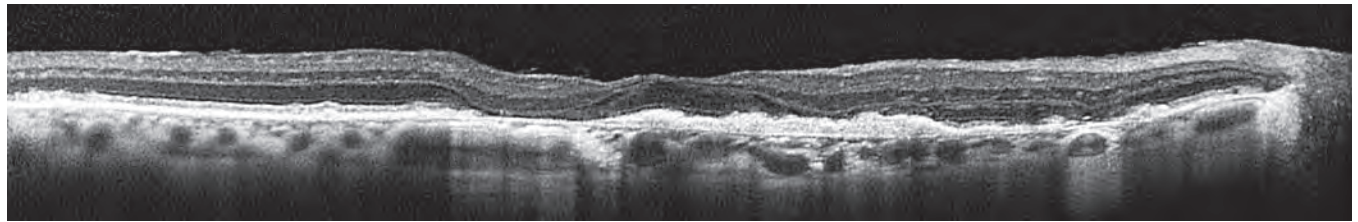
complement cascade at the level of C5 prevents the formation of C5a and MAC—both key terminal fragments that are responsible for tissue pathology. By inhibiting C5-mediated inflammatory and MAC activities, therapeutic benefit may be achieved in both dry and wet AMD while sparing the immunoprotective functions of the complement system. A Phase I, open-label, multicenter study of ARC1905, in combination with Lucentis (ranibizumab, Genentech) in patients with wet AMD is ongoing. A second study that is investigating ARC1905 in patients with dry AMD was initiated in 2009.^{11,15}

- *JPE-1375*. JPE-1375 (Jerini AG) is a small molecule peptidomimetic antagonist that also targets the complement pathway at the level of C5. It targets C5aR, which is believed to attract inflammatory cells. The goal is to block inflammation associated with complement activation, but leave components that form the MAC alone. This, in turn, will prevent activation of other mediators, such as VEGF, and hence the development of CNV.¹¹

- *POT-4*. POT-4 (Potentia Pharmaceuticals/Alcon) is a C3 peptide inhibitor that is being evaluated in patients with geographic atrophy.



The Macula Risk (ArcticDx) results place the patient in one of five different categories which correlate to his or her risk for developing AMD that may progress to vision loss. Patients in MR1 have the lowest risk of AMD progression (less than 5%), while patients in MR5 have the highest risk (nearly 75%).



On spectral domain OCT (SD-OCT), clinicians can not only visualize the RPE, but also the size and volume of individual drusen. SD-OCT can also be used to map out the size and exact area of geographic atrophy. Most importantly, however, SD-OCT's ability to follow patients over time will allow clinicians to determine if complement-regulating drugs are able to slow or stop disease progression.

When C3 is inhibited, it prevents cleavage of C3 to its active fragments C3a and C3b, thereby blocking the downstream complement activation pathway. POT-4 is administered intravitreally and is currently in Phase 2 clinical trials.^{11,15}

- **TNX-234.** TNX-234 (Tanox/Genentech) is a humanized antibody that is directed against complement factor D. This Phase I, open-label, multicenter study consists of a single-dose, dose-escalation study that will evaluate the safety, tolerability, pharmacokinetics and immunogenicity of an intravitreal injection of TNX-234 in patients with geographic atrophy.¹¹

In addition, there are other drugs in clinical trials that target key factors beyond the complement pathway that also show promise. These include:

- **Copaxone.** Copaxone (glairamer acetate injection, Teva Pharmaceuticals) is an immunomodulatory drug that has been proven safe and effective for a neurodegenerative disease. Its effectiveness is currently being evaluated in the prevention of dry AMD progression.¹⁵ Various delivery options are also being explored, including a weekly vaccination.

- **ACU-4429.** ACU-4429 (Acucela and Otsuka Pharmaceutical) is a drug that may be able to slow the eyes' visual cycle of light processing. It is believed that the drug may have the ability to prevent or inhibit the creation of naturally toxic byproducts by the visual cycle that may contribute to the development of AMD.^{15,16}

In preclinical studies, ACU-4429 has demonstrated the ability to selectively target the human eye's rod system, while leaving the cone system unaffected. In doing so, ACU-4429 is able to successfully reduce the activity of the rod system. Researchers have suggested that even when the rod system is not being used (for night vision), rods continue to send essentially unused information to the brain, which creates

toxic by-products within the retina.¹⁶ ACU-4429 is administered to patients as an oral, daily pill rather than by injection like many other treatments.

The Challenges

If we are able to develop drugs that regulate the complement pathway, will they indeed result in slowing, or even stopping, the progression of AMD? Furthermore, because progression to wet AMD can take several years, how and when will we know if the treatments even work? Finally, how should investigators design a clinical trial that can overcome some of these inherent challenges? Fortunately, OCT may be able to help ameliorate these concerns.

On spectral domain OCT (SD-OCT), "segmentation" allows investigators to isolate and visualize the RPE by partitioning out the sensory retina. With newer advancements in imaging software, clinicians will not only be able to visualize the RPE, but also the size and volume of individual drusen. Then, at follow-up, the SD-OCT will be able to objectively determine whether the drusen have increased in size or if there are more drusen, as well as the rate of progression.

SD-OCT can also be used to map out the size and exact area of geographic atrophy. Like those with drusen, patients with geographic atrophy can be followed to determine progression rates. Most importantly, however, SD-OCT's ability to follow patients over time will allow clinicians to determine if the aforementioned drugs are able to slow or stop disease progression.

It is becoming more obvious that chronic inhibition of VEGF as a treatment option for AMD isn't quite the Holy Grail we once touted it to be. But, it still remains to be seen if any of these new, complement-targeting agents will, in fact, be able to prevent

the development and/or progression of dry AMD. Even though it may be several years before we actually know if any of these drugs work, it appears that we have taken a giant step forward in combating, or even completely curing, age-related macular degeneration. ■

Dr. Dunbar is the director of Optometric Services and Optometry Residency Supervisor at the Bascom Palmer Eye Institute in Miami.

1. Rosenfeld PJ, Brown DM, Heier JS, et al. Ranibizumab for neovascular age-related macular degeneration. *N Engl J Med.* 2006 Oct 5;355(14):1419-31.
2. Brown DM, Kaiser PK, Michels M. Ranibizumab versus verteporfin for neovascular age-related macular degeneration. *N Engl J Med.* 2006 Oct 5;355(14):1432-44.
3. Marmoros AG, Fan J, Yokoyama Y, et al. Vascular endothelial growth factor expression in the retinal pigment epithelium is essential for choriocapillaris development and visual function. *Am J Pathol.* 2005 Nov;167(5):1451-9.
4. Edwards AO, Ritter R, Abel KJ, et al. Complement factor H polymorphism and age-related macular degeneration. *Science.* 2005 Apr 15;308(5720):421-4.
5. Hageman GS, Anderson DH, Johnson LV, et al. A common haplotype in the complement regulatory gene factor H (HF1/CFH) predisposes individuals to age-related macular degeneration. *Proc Natl Acad Sci U S A.* 2005 May 17;102(20):7227-32.
6. Haines JL, Hauser MA, Schmidt S, et al. Complement factor H variant increases the risk of age-related macular degeneration. *Science.* 2005 Apr 15;308(5720):419-21.
7. Llein RJ, Zeiss C, Chew EY, et al. Complement factor H polymorphism in age related macular degeneration. *Science.* 2005 Apr 15;308(5720):385-9.
8. The complement system. In: Kuby J. *Immunology.* 5th ed. New York: W. H. Freeman; 2003:299-316.
9. Donoso LA, Vrabec T, Kuivaniemi H. The role of complement factor H in age-related macular degeneration: A review. *Surv Ophthalmol.* 2010 May-Jun;55(3):227-46.
10. Neely T. Complement Modulation: How Complement Works. Available at: www.brown.edu/Courses/Bio_160/Projects1999/ies/how.html (Accessed October 21, 2010).
11. Gehrs KM, Jackson JR, Brown EN, et al. Complement, age-related macular degeneration and a vision of the future. *Arch Ophthalmol.* 2010 Mar;128(3):349-58.
12. Scholl HP, Fleckenstein M, Charbel Issa P, et al. An update on the genetics of age-related macular degeneration. *Mol Vis.* 2007;13:196-205.
13. ArcticDX. Macula Risk. Available at: www.macularisk.com/en/physicians/macularisk.html (Accessed October 26, 2010).
14. Seddon JM, Reynolds R, Maller J, et al. Prediction model for prevalence and incidence of advanced age-related macular degeneration based on genetic, demographic, and environmental variables. *Invest Ophthalmol Vis Sci.* 2009 May;50(5):2044-53.
15. Boman N. Study of the safety, tolerability, pharmacokinetics and pharmacodynamics of ACU-4429 in subjects with geographic atrophy. Clinical Trials ID#: NCT01002950. Available at: www.clinicaltrials.gov/ct2/show/NCT01002950?term=acu-4429&rank=1 (Accessed October 26, 2010).
16. Acucela and Otsuka Pharmaceuticals. Acucela and Otsuka Pharmaceutical Receive FDA Fast Track Designation for ACU-4429 in Patients with Dry AMD. Available at: www.acucela.com/news/2010-03-17_000.pdf (Accessed October 26, 2010).